

**A smaller atlas of illustrations of clinical surgery / by Jonathan Hutchinson.**

**Contributors**

Hutchinson, Jonathan, Sir, 1828-1913.

**Publication/Creation**

London : West, Newman, 1895.

**Persistent URL**

<https://wellcomecollection.org/works/x4sbkvy8>

**License and attribution**

This work has been identified as being free of known restrictions under copyright law, including all related and neighbouring rights and is being made available under the Creative Commons, Public Domain Mark.

You can copy, modify, distribute and perform the work, even for commercial purposes, without asking permission.



Wellcome Collection  
183 Euston Road  
London NW1 2BE UK  
T +44 (0)20 7611 8722  
E [library@wellcomecollection.org](mailto:library@wellcomecollection.org)  
<https://wellcomecollection.org>



SMALLER  
ATLAS

HUTCHINSON



108 G



22102172812



108 G



A SMALLER ATLAS  
OF  
ILLUSTRATIONS OF CLINICAL SURGERY.

LONDON:  
WEST, NEWMAN AND CO., PRINTERS,  
HATTON GARDEN, E.C.

A SMALLER ATLAS  
OF  
ILLUSTRATIONS  
OF  
CLINICAL SURGERY

CONSISTING OF

ONE HUNDRED AND THIRTY-SIX PLATES  
WITH  
DESCRIPTIVE LETTERPRESS.

BY

JONATHAN HUTCHINSON, LL.D., F.R.S.,

CONSULTING SURGEON TO THE LONDON HOSPITAL,  
AND LATE PRESIDENT OF THE ROYAL COLLEGE OF SURGEONS.

LONDON:  
WEST, NEWMAN & CO.,  
54, HATTON GARDEN.

—  
1895.



714774676



M19201

WELLCOME INSTITUTE LIBRARY	
Coll.	welM0mec
Call	
No.	W017
	1895
	H97s



## PREFATORY REMARKS.

---

IN 1875 I commenced the publication, in folio size, of 'Illustrations of Clinical Surgery.' The first volume of the work was concluded in 1877, having comprised thirty-nine Plates. With the second volume, which was finished in 1882, the work came to an end. Ninety-three Plates had in the whole been issued. On account of its size this work was somewhat expensive, and when I concluded it an intention was in my mind of recommencing it in a smaller and cheaper form. Of this intention the present 'Atlas' is the outcome.

I am a firm believer in the value of pictorial illustration as an aid to the acquisition of clinical knowledge, and my aim has been to produce a volume which should place such assistance within reach of all. In this endeavour I have been loyally helped by my publishers and artists.

This 'Smaller Atlas' may be regarded as a continuation of the 'Clinical Illustrations,' for it deals with similar subjects, and none of the Plates in the former have been reproduced. The principle of selection has been the same in both works. I have taken what interested myself in the hope that it would interest others. It has not been possible to classify the subjects, but I trust that the Index will prevent any real inconvenience on this score.

A few of the Plates now published have been copied from other sources, but the great majority are from original drawings executed under my own supervision. I have to thank

Mr. Edwin Burgess and Miss Mabel Green for the care and skill with which they have executed, often under considerable difficulties, the artistic tasks imposed upon them.

All the Plates now collected together have appeared during the last five years in my 'Archives of Surgery.' I have endeavoured to give in the letterpress which accompanies each an adequate explanation, but respecting not a few of the cases which they illustrate additional details will be found in the Journal mentioned. The life-size original drawings from which these Plates have been copied may in almost all instances be seen in the galleries of the "Clinical Museum."

It is not needful to make many comments on the individual Plates. Respecting most of them it may be remarked that the artistic effect has been much marred by the endeavour to give details in the largest possible size. Thus many of the figures are much too large for the page. Any one who may care to take the book to pieces and remount the Plates with wider margins will be astonished to observe how much they are improved. This procedure will also admit of their being rearranged, and make them much more useful for teaching purposes, or for museums.

Amongst the Plates to which I attach most value as illustrating novel subjects, I may venture to mention the following:—

Plates I, II, XLV, XLVI, which illustrate herpetiform congenital streaks, ichthyotic in some cases.

Plates III, IV, V, XVIII, XIX, XX. Illustrating exceptional forms of drug eruptions and arsenic-cancer.

Plates VI, VII, X, LI. Examples of the Philip Holmes series (a form of chilblain-lupus with acne, &c.).

Plate IX. Unique at the time the portrait was taken (infective angeioma or nævus-lupus).

Plates XI, CXXXII. The crateriform ulcer.

Plates XIII and XIV. A very exceptional form of lupus.

Plates XV, XVI, LXXVIII, LXXXVI. Lupus lymphaticus (an infective lymph-angioma).

Plates XVII, XXX, XXXI. Acro-sclerodermia and acrosphacelus.

Plates XXXVI and XXXVII. The Thelan group of primary sarcoma of skin.

Plates LX, LXI, LXIII, CXXII. Illustrating some remarkable affections of the hands and feet.

Plates LXVII, LXVIII, LXXV, LXVII. All illustrating, at different stages, the same case,—one of multiple lupus.

Plates XC, CXIX, CXX. Three examples, from different cases, of tendency of sebaceous tumours on the scalp to become sarcomatous. "The Ansell Series."

Plates CIII, CIX. Delineations of Bazin's legs.

Plate CVII. An unnamed malady, probably a form of lupus.

Plate CVI. Illustrating senile freckles and melanotic pigmentation leading to cancer.

Plate CX. Illustrating eruptions due to sun exposure.


Plates C and CXXX. Gynæcomazia and obesity of a feminine type in the male.

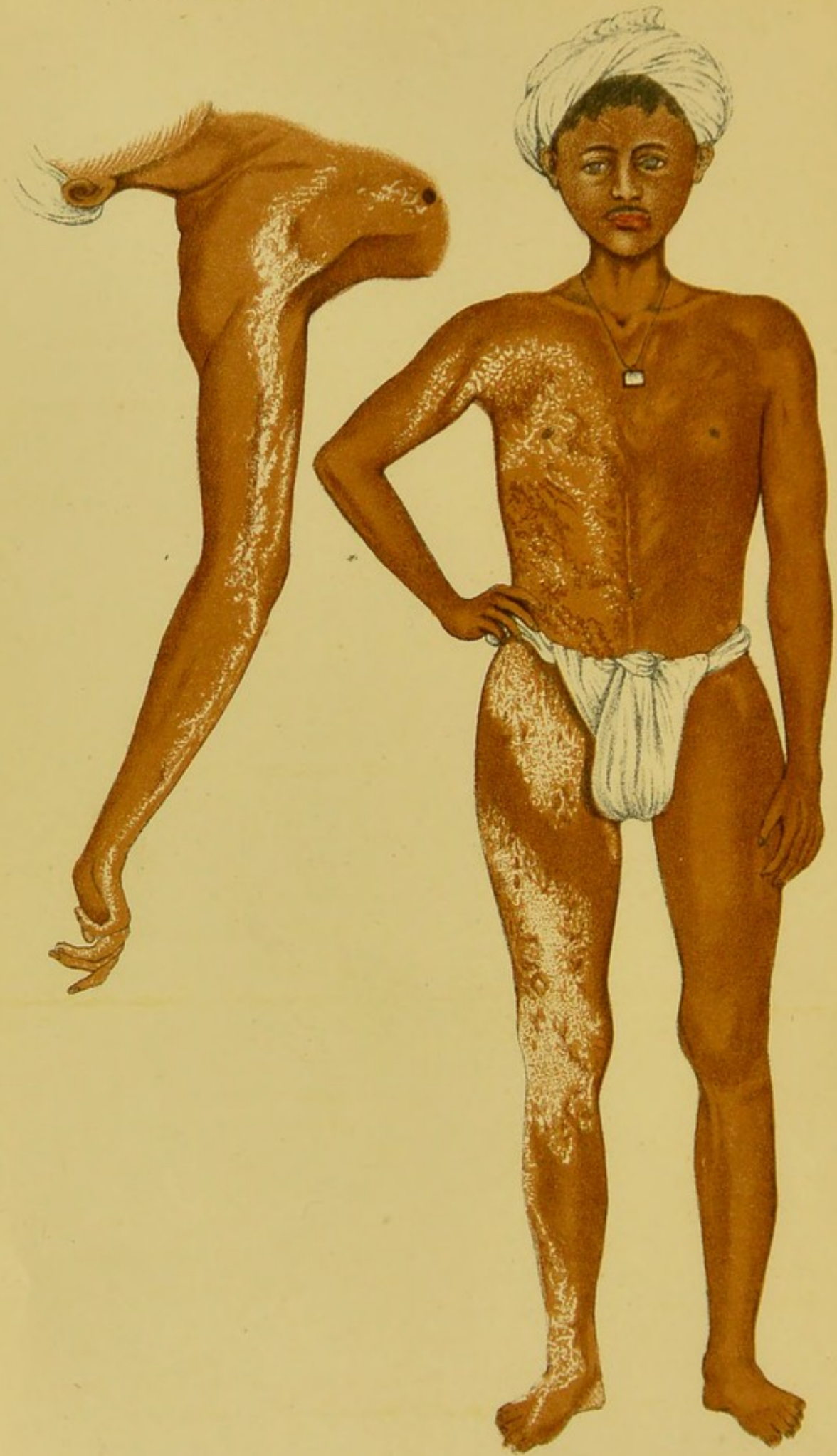A large number of additional Plates are in hand, and will appear from time to time in the 'Archives.' Should life be prolonged and health permit, these will, I hope, in due course, make up a second volume of the 'Smaller Atlas.'

LONDON, *July*, 1895.

The first part of the report is devoted to a general description of the country and its resources. It is followed by a detailed account of the various industries and occupations of the people. The report then proceeds to a description of the climate and the various diseases which are prevalent in the country. It concludes with a list of the principal towns and cities of the country.

Report of the





## PLATES I & II.

CONGENITAL STREAKS & PATCHES ARRANGED UNILATERALLY.

(ICHTHYOSIS HERPETIFORMIS.)



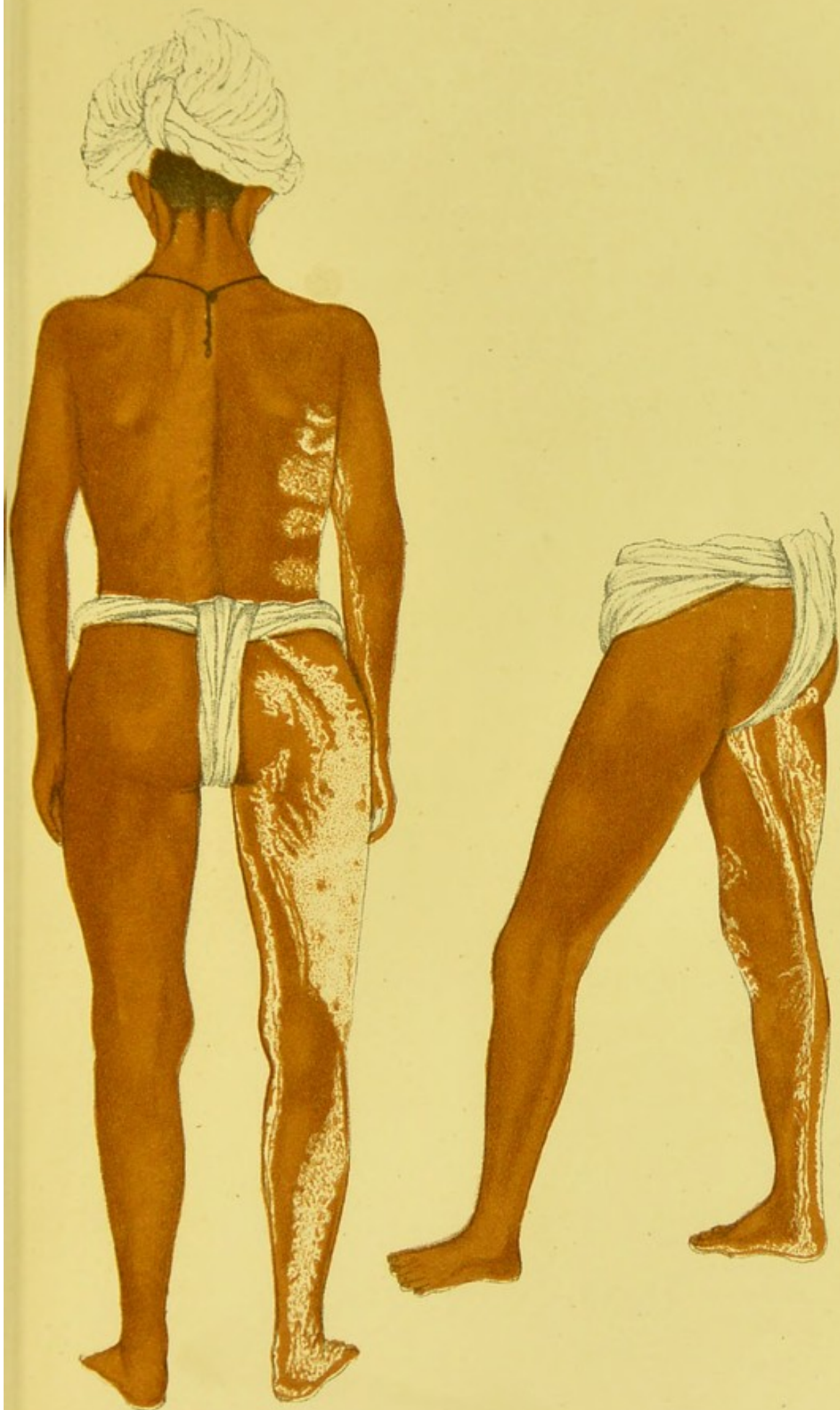
THIS portrait and the next show front and back views of a remarkable example of congenital affection of the skin in a Hindoo man. The original portrait was given me by Mr. Fred. Mackenzie, now of Hans Place, by whom it was sketched from the living subject. The affection is the converse as regards colour of what we see occasionally on the white skins of Europeans. Its most important peculiarity is that of its strict limitation to one side, both on trunk and limbs, and next its arrangement in streaks and bands. These latter, on the trunk, curve forwards from the spine to the middle of the abdomen, much like herpes zoster, although by no means with the same definiteness of arrangement. On the limbs the bands run lengthwise, and in some instances reach the digits. Although at first sight suggestive of nerve-distribution, it is yet quite impossible to trace their location in connection with any known nerves; nor do they, like herpes, assume a corymbose expansion at their distal extremities. In some instances the band keeps to pretty nearly the same width from the upper part of the limb to the digit. These streaks in the white races are often more or less pigmented, or being somewhat papillary become discoloured, like ichthyosis, by dirt. They are usually observed either at birth or in early infancy, being no doubt essentially congenital, but they become much more conspicuous during childhood. Sometimes, indeed, they continue to grow for many years; the growth, however, is always simply an increase in papillary development, and there is never any extension of the patches at their edges. The disease is evidently mapped-out during intra-uterine life. Many years ago I ventured to conjecture that they might be due to something of the nature of intra-uterine zoster. They constitute a very important piece of evidence as to the possibility of unilateral





PLATES I & II (*continued*).

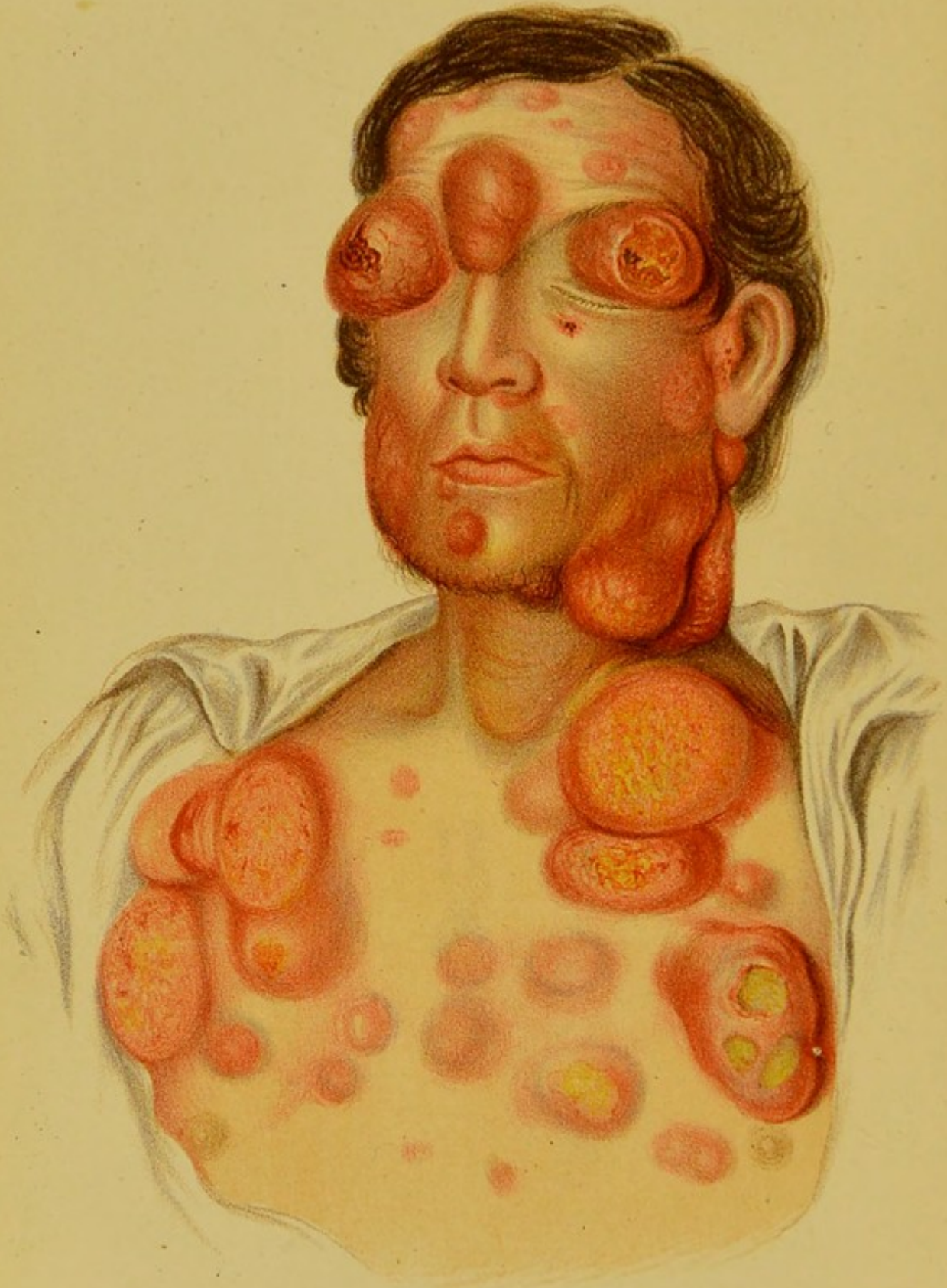
disturbances of nutrition during foetal life. In the present instance the patches were simply white, and there was little or no evidence of tendency to papillary outgrowth.

For further remarks upon these singular conditions, I may refer to my presidential address at the Neurological Society, which was reported, with illustrations, in the 'Illustrated Medical News.' I must mention also an important paper by Dr. Stephen Mackenzie in the same Journal. In the Clinical Museum are a series of drawings representing these unilateral streaks. In some cases almost the entire surface is covered; but even when this is so there are almost always conspicuous deviations from bilateral symmetry. When the condition is general, it has always been classed as ichthyosis; I therefore venture to propose for the cases in which only streaks are present the descriptive name of **ICHTHYOSIS HERPETIFORMIS**.









## PLATES III & IV.

### A CASE OF IODIDE OF POTASSIUM ERUPTION.



THIS portrait and the following belong to the same case, and illustrate the most exaggerated form of iodide of potassium eruption which I have ever seen. I do not think that there could be any reasonable doubt that the huge tuberous masses here depicted were really the result of the use of the iodide. As such I diagnosed them before knowing anything of the man's antecedents, and subsequent enquiry confirmed the suspicion. It will be observed that they are very similar in all local characters to others which have been not unfrequently observed after the use of the iodides and bromides, differing simply in the size attained. In illustration of this it will be of interest to refer to a portrait published in the New Sydenham Society's 'Atlas,' in which the eruption was undoubtedly due to the bromide. The explanation of the very large size of the growths in the present case was to be found in the fact that the dose of iodide had been steadily increased as the eruption advanced.

The patient was a man aged twenty-six, who was admitted into the London Hospital much in the condition shown in the portraits. The latter were indeed taken on the day after his admission. He died from exhaustion a few days later. On enquiry at the Hospital in which the man had been treated before he came to us, it was ascertained that he had been admitted there on account of some swelling in the groin, which was diagnosed as syphilitic. He had at that time no skin eruption whatever. Iodide of potassium in five-grain doses was at once ordered. An eruption soon began to appear, and as it was considered to confirm the diagnosis of syphilis the dose of iodide was increased to ten grains at the end of a week. Ten days later it was increased to fifteen, and later still to twenty. He continued it without intermission from July the 23rd to October the 9th, when mercury was

substituted. The eruption had been steadily getting worse the whole time, but as it had been throughout considered to be syphilitic the specific had been pressed.

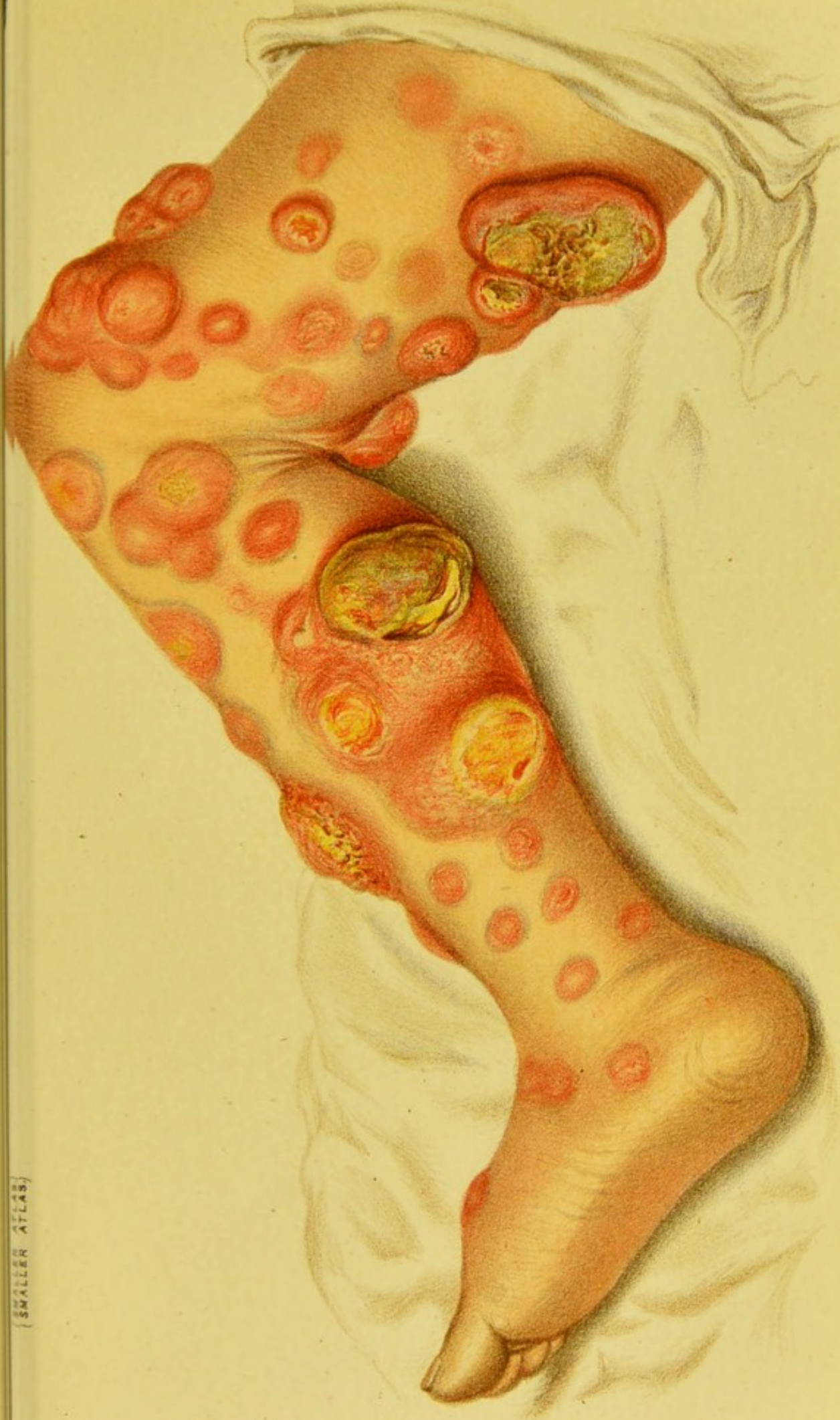On careful enquiry I did not think that there was much reason to suspect that the man had really had syphilis. He lived for about a fortnight after the iodide had been completely left off, but during this time no material change occurred in the eruption. He was in an extremely feeble condition the whole time; and his death was from exhaustion. The microscope was carefully used, but revealed nothing of importance.

In the Guy's Hospital Museum there is a model (No. 117), which may perhaps belong to a closely similar case. Some of the tubers were as large as plums, and one of them even measured two inches across. Unfortunately no history is obtainable. I was indebted to my friend the late Dr. Hilton Fagge, the author of the Catalogue of the Guy's Collection, for drawing my attention to the close similarity between this model and my own case. I cannot but suspect that not a few cases which have been classed as cutaneous gummata in connection with syphilis have been really examples of iodide of potassium eruption, and I can call to mind several in bygone years in which patients died with severe eruptions of an anomalous character which were not improbably due to this cause. The frontispiece to Dr. Prince Morrow's (New York) work on 'Eruptions due to Drugs' shows the conditions in a fatal case of iodide poisoning. In it the tubers were not so large as in mine, but the inflammation of skin was more diffuse. Death was caused by a much smaller quantity of the drug than in my case.

Not only is it necessary in the diagnosis of syphilitic gummata of the skin to first eliminate iodide eruptions, but the same remark applies to the various conditions which have been grouped together under the name of "Granuloma Fungoides."


[The Clinical Museum is now rich in illustrations of iodide eruptions, and these two portraits, which were regarded twenty years ago with much incredulity as to the diagnosis, are now well supported.]


(SMALLER ATLAS)



West, Newman & Co. lith.







## PLATE V.

### ERUPTION CAUSED BY CHLORAL.

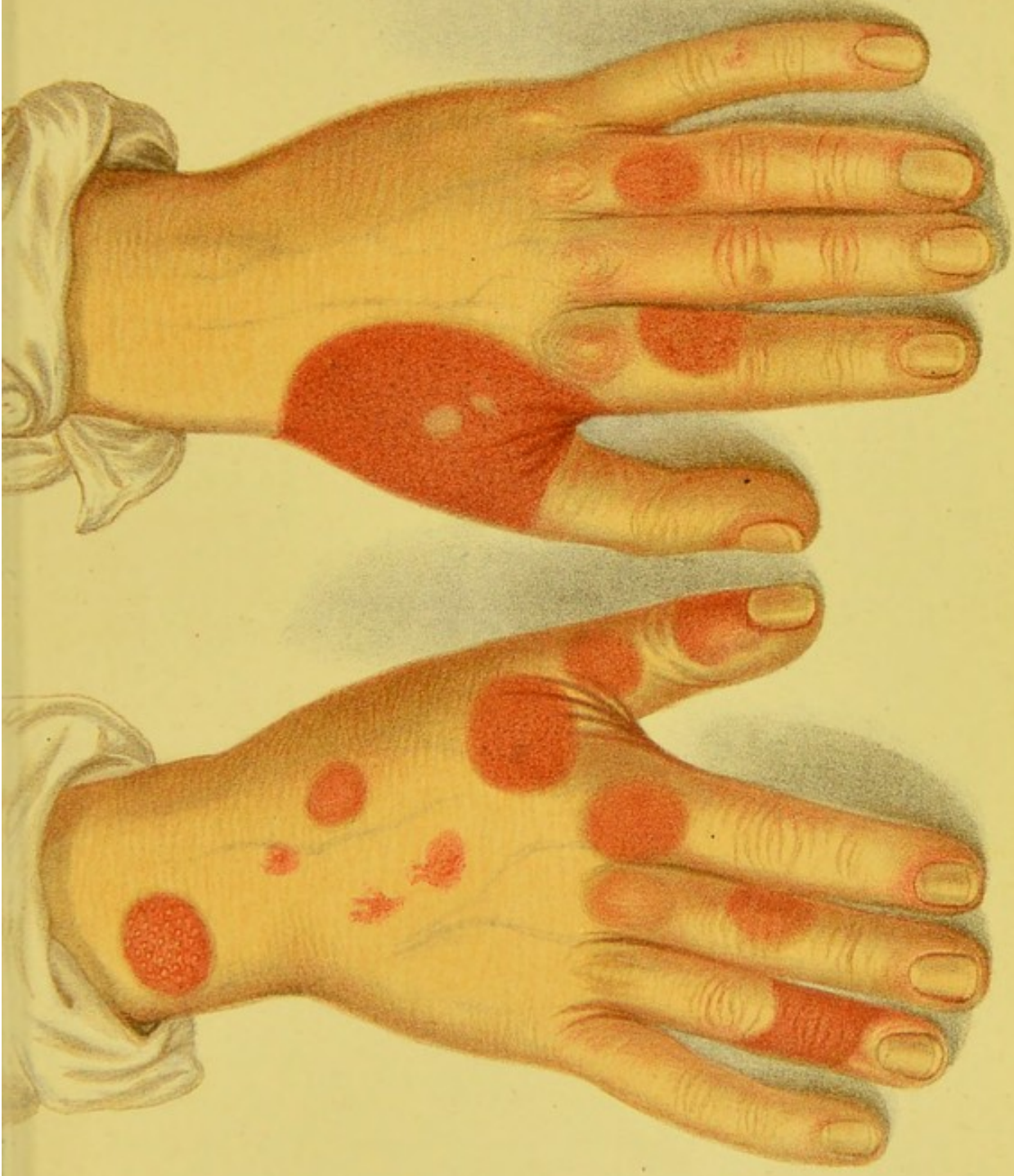
---


THIS Plate represents an eruption due to the use of chloral. It occurred on the hands of a gentleman, aged thirty-four. The patient had frequently taken the drug as a remedy for sea-sickness, &c., and on no less than fifteen occasions had observed the appearance of the eruption here shown. He usually took thirty grains of chloral, and on the following morning his hands would exhibit erythematous patches, with some thickening, and sharply defined margins. No other part of the body was affected. The patches, which were of a dusky red colour, were tolerably symmetrical, though not always of the same size on the two hands. They would remain out, causing much burning and itching, for a week or more, and then gradually disappear, the whole attack lasting at least three weeks. Some of the patches whilst fading showed an almost eczematous condition, as seen in the one on the back of the right wrist.


In the middle of the patch on the left thumb are seen two small pale areas, which were, I believe, old scars not admitting the erythematous condition.

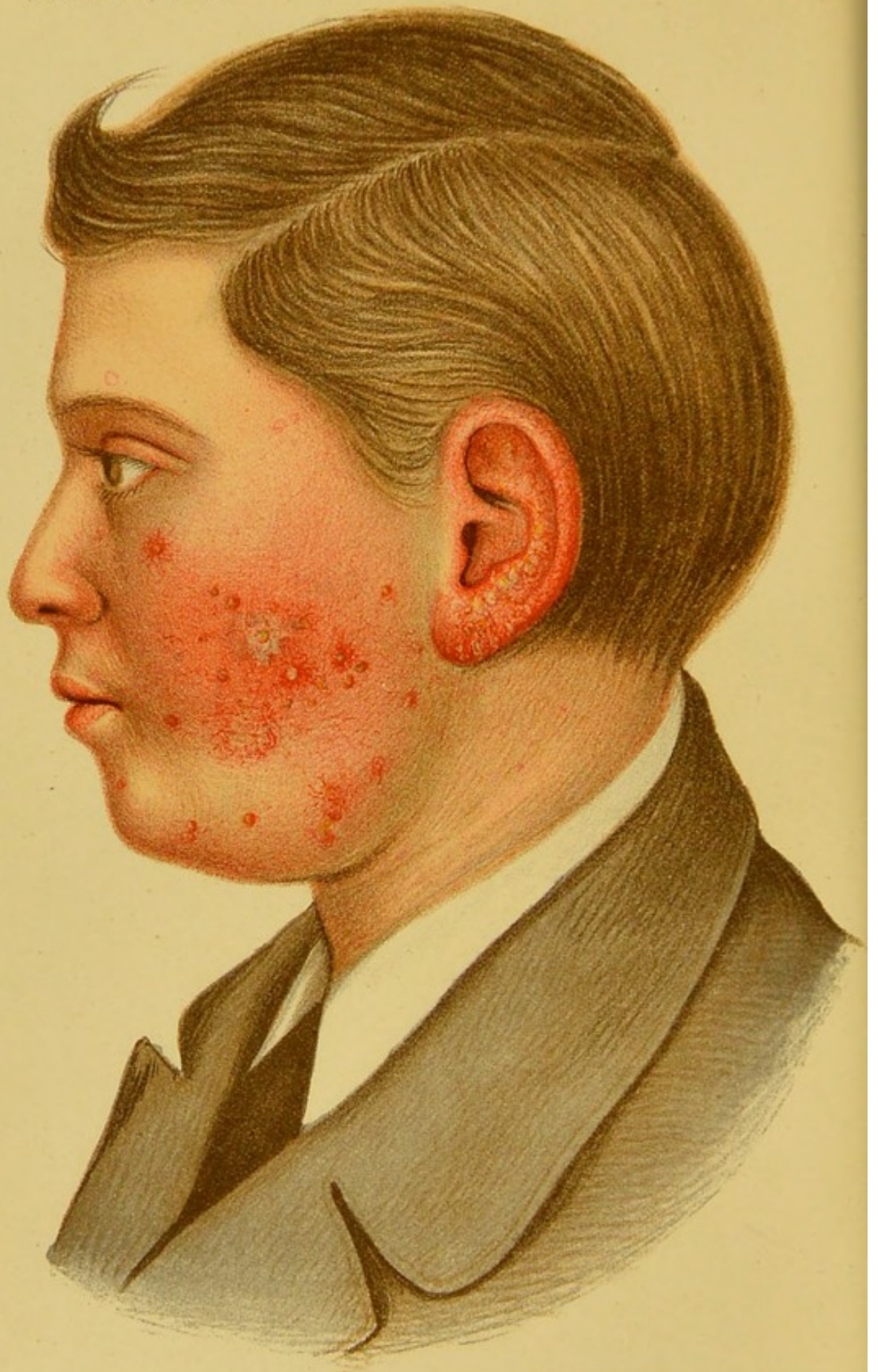
The patient was of gouty stock, and had himself suffered a single attack of gout; otherwise he was in excellent health. Once after the use of the Bath waters he had a five-weeks' attack of urticaria. It may from this fact be assumed that his skin was specially susceptible.

[For a good description of the eruptions usually met with from chloral, see Dr. Prince Morrow's work, New Sydenham Society, volume 143, page 456.]









## PLATES VI. & VII.

### A MIXED FORM OF LUPOID SKIN DISEASE.

(CASE OF PHILIP HOLMES.)


---

It is difficult to give a concise name to the eruption illustrated by these Plates (VI. & VII.). It is a connecting link between psoriasis, acne, lupus, and chilblains. The patient was a lad of twelve, delicate, and possibly phthisical, who had suffered from chilblains, and whose grandfather had been the subject of psoriasis. His eruption had begun in infancy, and had varied with the time of year, becoming, on the whole, steadily worse as he got older. As will be seen by the patch on his elbow (and there were others on the fronts of his knees), it was arranged something like psoriasis. From psoriasis, however, it differed in that everywhere scars were left when the spots healed. On the parts which were uncovered, as is seen on the hands and face, the eruption inflamed, and was attended with scabs. As in Kaposi's disease, little tufts of dilated capillaries, stigmata, were left after the eruption. Some of the spots, especially those on the cheeks, showed a tendency to the production of the apple-jelly growth which is characteristic of lupus. His cheeks indeed might be said to offer an example of "acne-lupus." The disease, however, was, in the main, a pustular form of lupus erythematosus. I have no doubt that the disease resulted from a mixed inheritance of tendency to scrofula and psoriasis, with that peculiar state of feeble circulation which gives proclivity to chilblains.

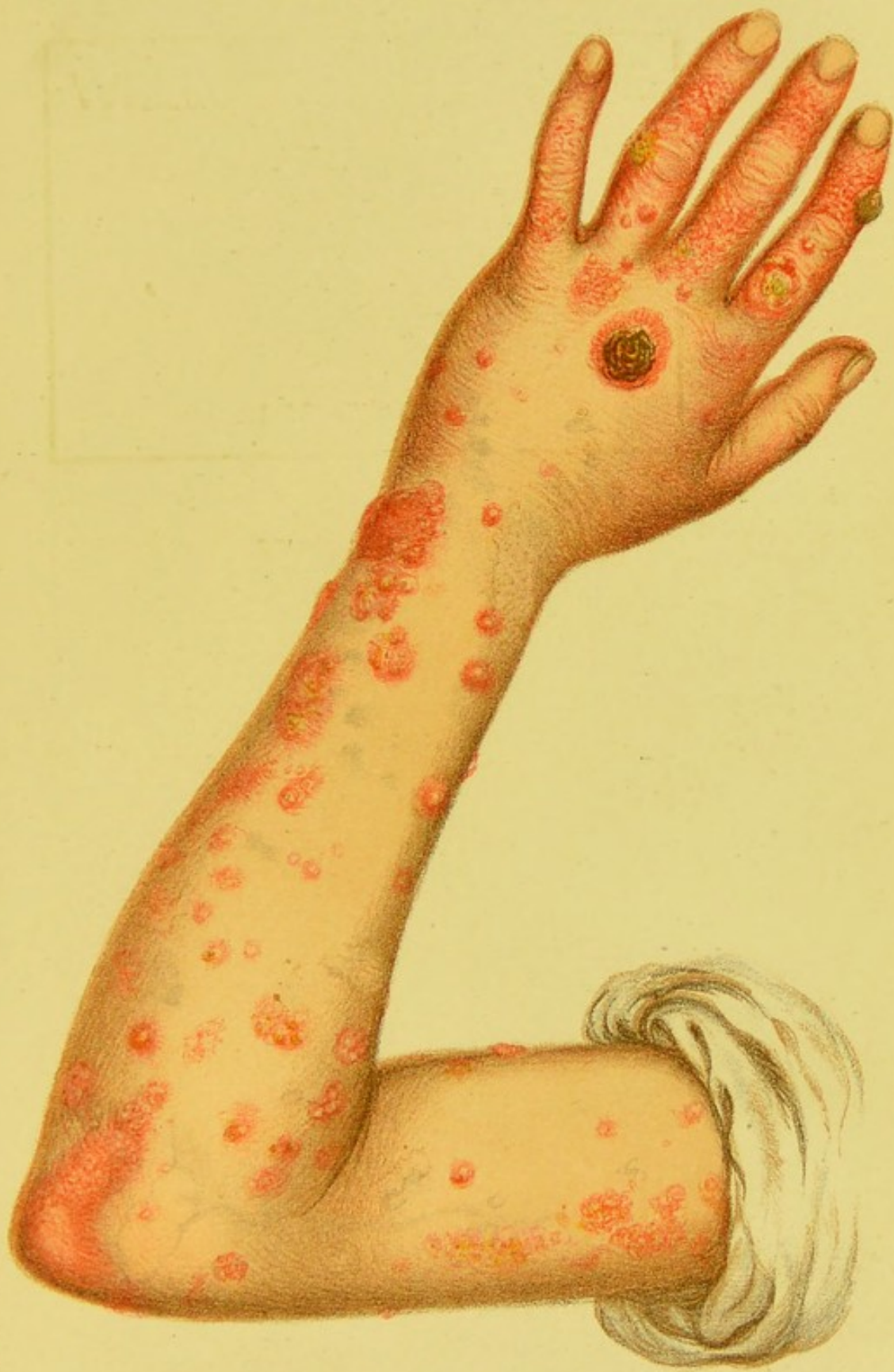I have seen several other cases exactly like the above, and with similar histories.

Those who hold that such words as lupus, psoriasis, and acne are names for "morbid entities," which always keep close to their type, may find such cases as these very difficult to classify. For myself, having long held and taught that these names apply only to certain peculiar forms of inflammation of the skin due to causes and inherited proclivities which may be easily intermixed, I feel no hesitation in assigning them to a numerous and very varied class of hybrids. They are examples of pathogenetic partnerships.







HUTCHINSON'S CLINICAL ILLUSTRATIONS.  
(SMALLER ATLAS.)



West, Newman chromo.



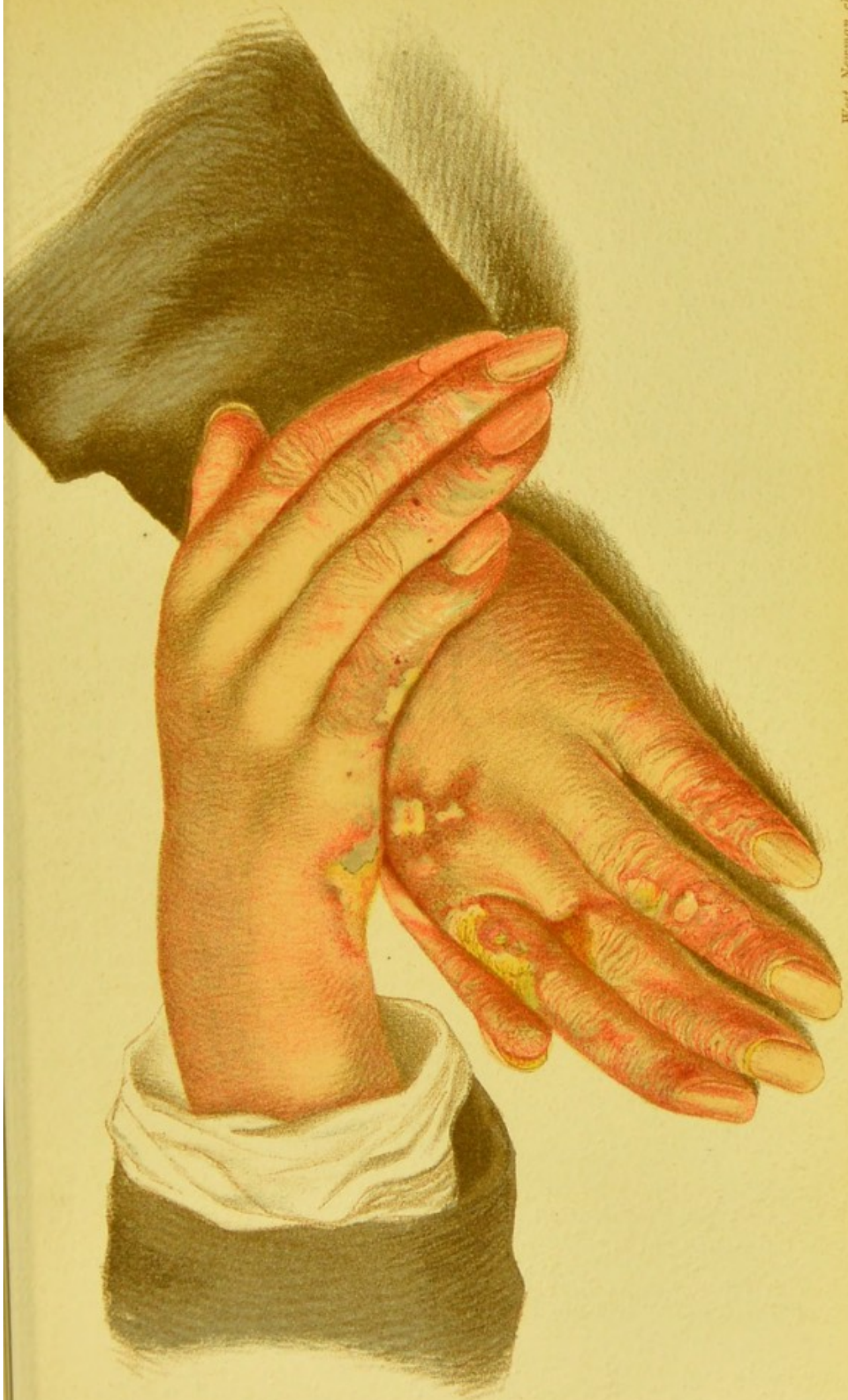


## PLATE VIII.

### THE HANDS IN LUPUS ERYTHEMATOSUS.



THIS Plate may suitably be compared with the preceding one. It shows the condition of diffuse erythema of the digits and adjacent parts of the hands which not unfrequently attends typical lupus erythematosus of the face. The sketch was made from the hands of a boy of twelve who was the subject of the disease mentioned. He had large patches on his cheeks. (See New Sydenham Society's 'Atlas,' Portrait No. XLII.) The erythema of the hands may sometimes closely resemble chilblains, a condition to which, indeed, lupus erythematosus is itself closely allied. Often, however, the erythema is not in patches, but diffuse, involving all the fingers, and perhaps a large part of the hand also. It is often attended by small pustules, which ulcerate, and sometimes by the formation of tallowy white patches, which may pass into superficial gangrene. These but rarely involve the whole thickness of the skin. The case here figured is one in which these conditions showed especial severity.





## PLATE IX.

### INFECTIVE ANGIOMA. NÆVUS-LUPUS.

(A PECULIAR FORM OF SERPIGINOUS AND INFECTIVE NÆVOID DISEASE.)

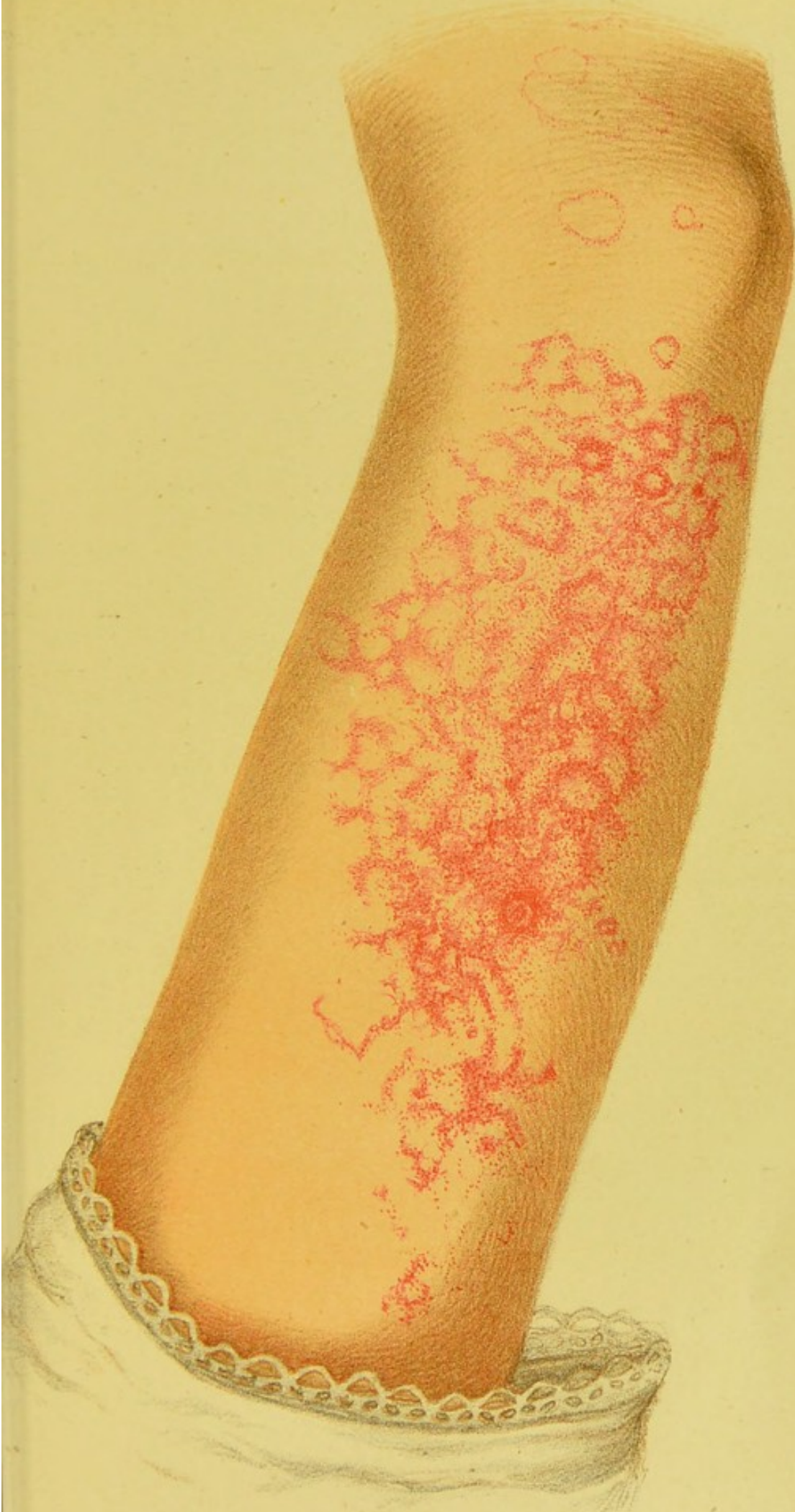---


THIS portrait, which was taken from the arm of a young lady about fifteen years of age, purposes to illustrate a very peculiar condition of serpiginous or infective nævus. Although nævi often increase in size and in number during the first few months of life, it is very rare indeed for the growth to continue to spread. Such, however, was the case in this instance, and with the addition of other peculiarities. A very slightly marked port-wine stain was observed at the back of the arm soon after the infant's birth. For some years it scarcely spread at all, and no notice was taken of it. It then began slowly to advance, and the condition shown in the portrait was gradually produced. A careful inspection of the Plate will show that the mode of advance is somewhat peculiar, and that it has not been by a continuous edge. It would appear as if little satellite spots had been produced, which had spread into circles, and, by gradually advancing by infective edges, had coalesced, producing the irregular pattern which is here displayed. Some very good examples of these spreading circles are seen over the elbow, quite isolated from the rest of the disease. These conditions are no ordinary part of nævoid disease. They were extremely superficial, and it was even difficult to be sure whether or not they left any state of scar behind them. I have, however, no doubt that such was their tendency, and that in some places a slightly-marked superficial scar could be demonstrated. The enlarged capillaries could be partially emptied by pressure, but not wholly, and in many places little tufts were distended with deep-purple venous blood, which could not be pressed out. In this latter condition, as well as in its tendency to serpiginous spreading, and the production of satellites, the case closely resembled what is seen in the disease which I have ventured to name *Lupus Lymphaticus*.




This latter malady, although often spontaneous, has been repeatedly observed in connection with "port-wine stain," and it always shows little tufts of capillaries which cannot be emptied. Its lymphatic element consists in the presence of little vesicles which contain lymph-fluid. It is serpiginous, infective, prone to produce satellites and to leave scars, and is thus clearly a member of the lupus family. In the present case there was little, if any, evidence of lymphatic disease, but the vascular changes and other features were much like those of the disease referred to, of which I cannot doubt that it is an ally.

*Postscript.*—Since this portrait and description were first published, I have seen several similar cases. Dr. Lassar, of Berlin, was kind enough to give me a wax model showing exactly the same changes. He had named it *Lupus Erythematosus*. The girl who was the subject of the portrait is now twenty-five years old and married. Although no special treatment has been adopted, the disease has ceased to spread, and her arm is now much in the same condition as when the portrait was taken. Indeed, I think that the changes have become decidedly less conspicuous.







## PLATE X.


### A MIXED FORM OF LUPUS IN ASSOCIATION WITH ULCERATION ON THE HANDS.


THE patient in this case was a young woman, named H——. Her case was of interest as showing a mixed condition of common lupus and lupus erythematosus, in conjunction with a scar-leaving eruption on the hands. There was a strong history of phthisis in her family; she had herself always been delicate, and of very feeble circulation. Her hands presented a very peculiar condition, the fingers being covered with little red patches, in the centre of which were depressed white scars: these patches were arranged in groups, and were especially abundant near to the last joints and on the ulnar borders of the fingers. The patch on her cheek had been present for four years, and consisted chiefly of erythema, which resulted in scar; it had very slowly extended at its edge. The gums about her lower incisor-teeth were receding from the fangs, and were red and soft (a minimized form of lupus). She was liable to chilblains on the feet, and her hands were always worse in cold weather. During cold her fingers became dusky, and on several occasions her nails had inflamed and exfoliated.

The case shows strongly the association of liability to chilblains with the tendency to lupus. It was one in which an inherited predisposition to tuberculosis was combined with feeble circulation and the chilblain-tendency. The patch on the cheek got well under treatment by cauterization, and Miss H—— was much improved in general health. She died of typhoid fever about three years after the portrait was taken.

See portrait of Miss H——'s hand in Plate LI.









## PLATE XI.

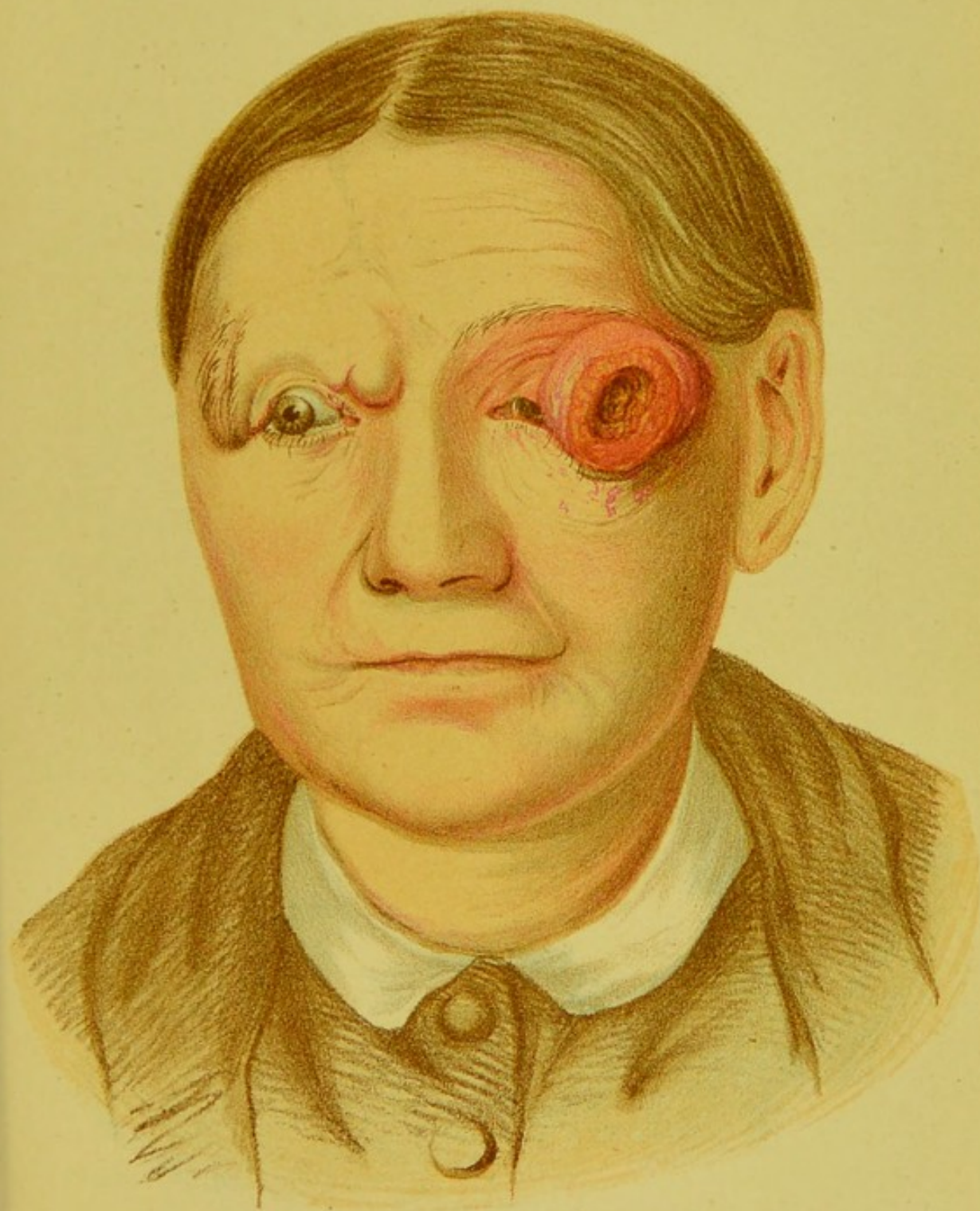### THE CRATERIFORM ULCER.


(ACUTE EPITHELIAL CANCER.)


---

THIS portrait shows a typical example of what I have ventured provisionally to call the Crateriform Ulcer. The ulcer so named is an acute form of epithelial cancer, which occurs on the face, much in the same position as "the rodent ulcer" does. It occurs also at the same ages, and in the same class of patients, as rodent. Its features and clinical course are, however, quite different from those of rodent. It makes as much progress in weeks as rodent often does in years. It is indeed one of the most rapidly-growing forms of malignant disease with which I am acquainted. Its development is very peculiar and is much alike in all cases. It begins as a red, firm tubercle, which involves the deeper parts of the skin, and rapidly develops into an elevated mass shaped like a bee-hive; this soon breaks down in the centre, and produces the condition which is denoted in the term "crateriform." There is very little inflammation at the base, the surrounding skin remaining quite sound. I have not as yet myself observed any cases in which the lymphatic glands became implicated, but, as regards this point, it must be remembered that all the cases which I have seen were promptly treated by free excision, and, so far as I know, cured. I have given a full report of this peculiar form of cancer in the last volume of Pathological Society's Reports. Since it was published, however, several other good examples of the disease have been brought under my notice. One of the best was shown by Mr. Harrison Cripps at a meeting of the Dermatological Society. It affected the same part as in the present portrait, and had indeed produced a condition of things which was a *facsimile* reproduction of what this portrait shows. The patient was a middle-aged man, in whom the ulcer had commenced as a little red pimple only three or four months before. A portrait has been secured for the College of Surgeons collection.

In the case which this portrait illustrates, the entire eye-lid on the opposite side had been excised, with transplantation of skin from the forehead, two years before. The ulcer for which this was done was exactly like the one shown, but much larger. It will be seen that there had been no local recurrence, nor any enlargement of lymphatics.





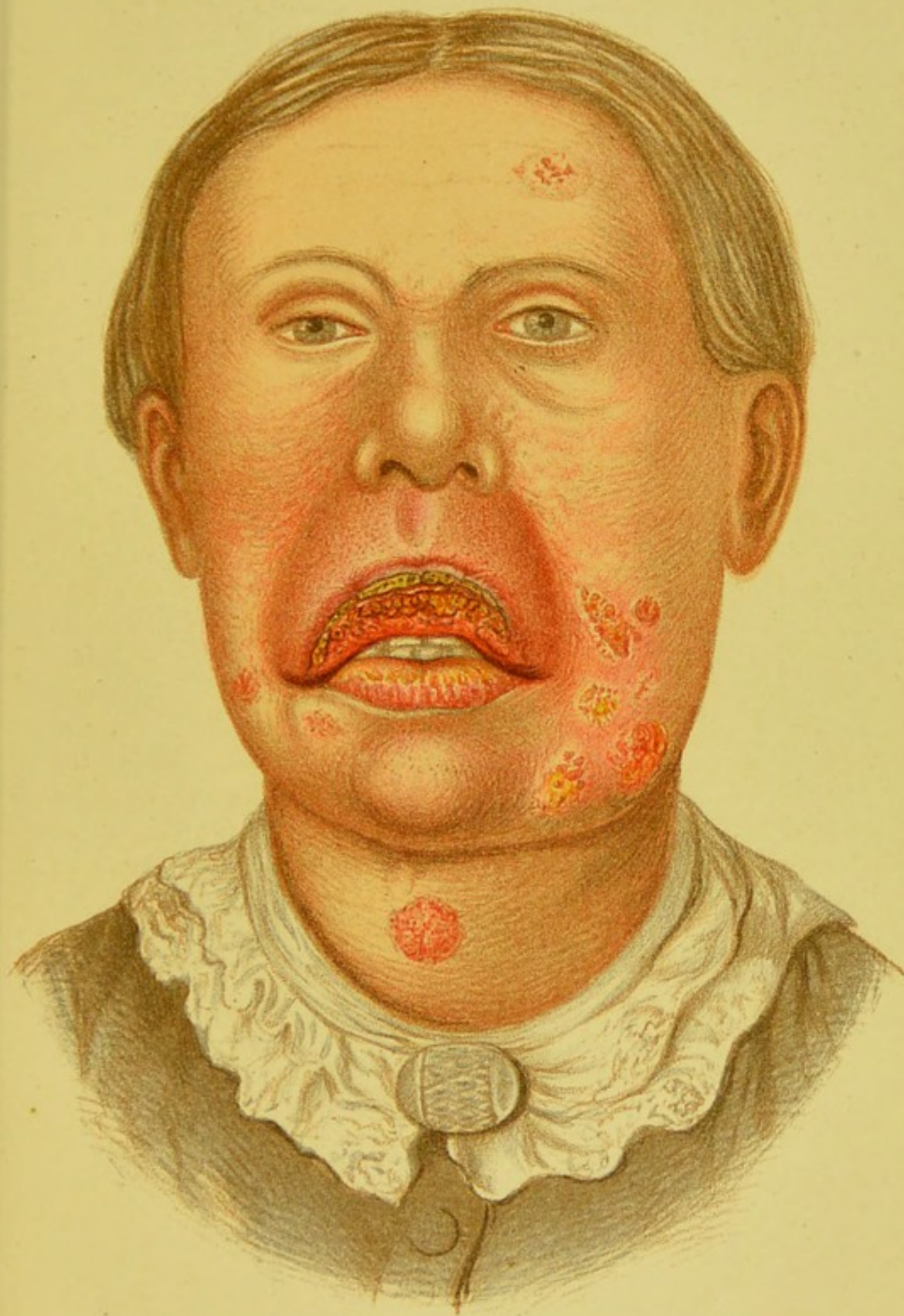



## PLATE XII.


LUPUS BEGINNING ON THE GUM, AND IN ASSOCIATION  
WITH GREAT ŒDEMATOUS HYPERTROPHY OF THE  
UPPER LIP.

---

Miss P—— was sent to me by Dr. Hogarth Clay, of Plymouth. She had suffered from lupus for six years, and had had much treatment. There was no history of tubercle in her family, but some members were said to have been “scrofulous.” She had suffered much formerly from chilblains, and had always had cold hands and feet. Something which was said to have been a polypus had once been removed from her nose. An interesting point in the case was that the lupus had begun on the gums, and that she still had considerable ulcers behind the front teeth. On the face there were many little patches, looking like bruises in the rind of an apple; some of these were on the forehead, but the greater number near to the mouth. In connection with the disease of the gums and the under surface of the lip, her whole upper lip had become the site of chronic œdema and hypertrophy. It was in order to show the great hypertrophy of the lip and the association of lupus of the face with lupus of the mucous membrane that I had the portrait taken. It is, I think, not very usual for lupus beginning on a mucous membrane to affect the skin afterwards. The patient was admitted into the London Hospital, under Mr. Waren Tay’s care, with a view to treatment by scraping and cauterization.









## PLATE XIII.

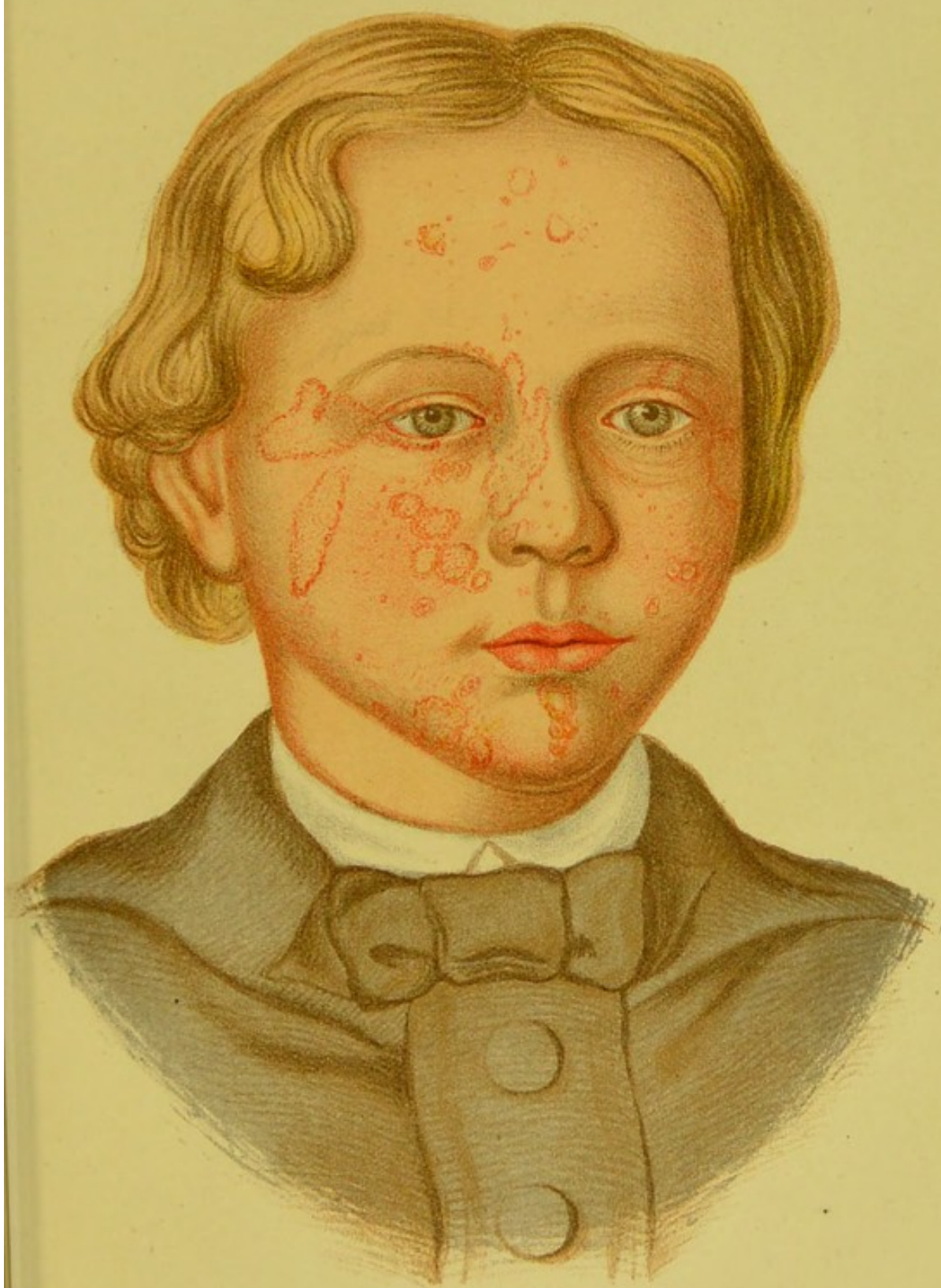A RARE FORM OF LUPUS (MARGINATUS)  
(HILLIARD'S CASE. THE TYPE CASE OF A GROUP.)


---


IN this Plate we have an illustration of a very rare form of skin disease allied to lupus. I support that statement as to its nature by the same class of facts which will be mentioned in reference to lupus lymphaticus. The morbid condition was a very chronic serpiginous inflammation of the skin, clearly infective, producing satellites, and which, when it underwent resolution, left the affected integument in the condition of cicatrix. Such are for me the essential features of a lupus-inflammation. It is needless to say again that it differs in some respects from common lupus, lupus erythematosus, and lupus lymphaticus. There are, however, features of family resemblance which are more important than the differences.

The portrait, as will be seen, shows the face of a young fair-complexioned lad, covered with very abruptly-margined patches. These patches have delicately tuberculated or lichenoid borders, and show a pale thin cicatrix in their areas. They are plentiful, but not quite symmetrical, and certainly not arranged in the bat's-wing form of lupus erythematosus. Nor was there anything which could be definitely recognised as the apple-jelly deposit of lupus vulgaris. The new growth or effusion present in the aggressive edge, and which preceded the scarring, was in fact exceedingly small in quantity. There had been no open ulceration. I saw the boy at intervals during several years, but have not had any recent opportunity for ascertaining his condition. (See next Plate also.)

A case exactly resembling this has recently been under observation at one of my clinical demonstrations. The patient was a woman under Mr. Tay's care at the London Hospital. A report of her case is given in the 'Clinical Journal.' Portions were subsequently excised, and declared by microscopical examination to be lupus.







## PLATE XIV.

A RARE FORM OF LUPUS (MARGINATUS).

(HILLIARD'S CASE.)

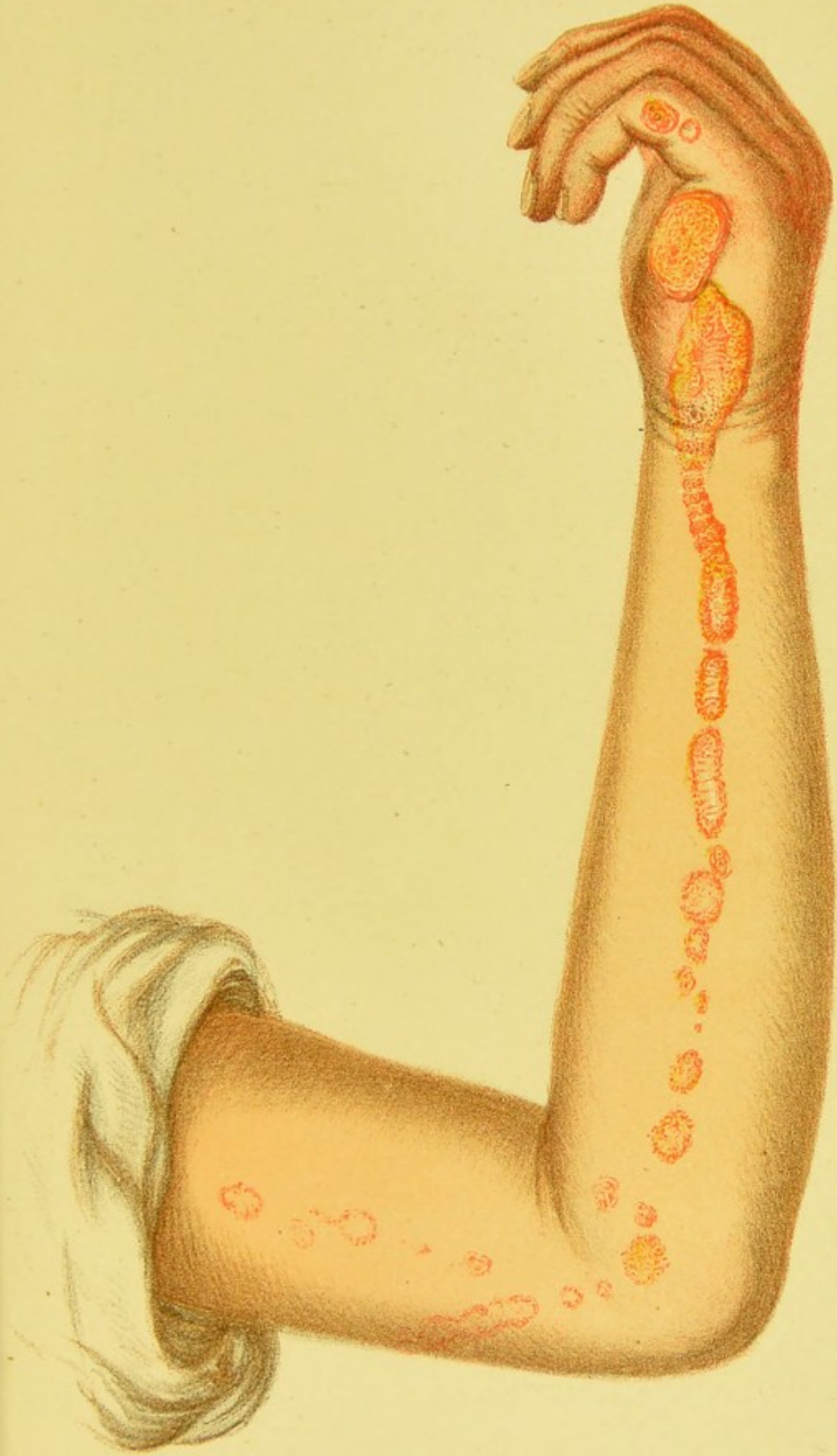---

IN this portrait is shown the arm of the boy whose face is the subject of the preceding one. The condition displayed is a long streak of irregular, slightly tuberculated patches passing down the forearm. A glance at the patches, as seen on the upper arm, will convince any one that it is the same disease as that shown on the face. We have a finely tuberculated border with scar in the centre, the edge clearly being aggressive. Low down on the forearm and on the ulnar border of the hand the changes are of a coarser kind. The patches are thicker and more lumpy, and attended perhaps somewhat with papillary growth. The reader may profitably compare the appearances presented on the upper arm with those shown in Plate IX. Plate XLIV., also copied from a St. Louis photograph, is almost an exact repetition of this.


The case which is illustrated in these two portraits is one of which I have seen but very few parallels. I possess another portrait showing exactly the same state of things on the arm of a young lady, and with similar arrangement, but in this instance the patient had no spots on the face. The disease appears to be an extremely chronic one, for in both these two instances I have had opportunities for watching the patient during several years, and there has been no material progress. The long streak-like arrangement on the forearm might suggest at first sight distribution by the ulnar nerve, but a moment's consideration will, I think, convince any one that this is not the case, for the patches on the upper arm overlie the trunk of the nerve and not its filaments of distribution. In both the cases mentioned the disease had begun in early childhood.


Of the four cases referred to, in two there was the streak on the arm only, in one the face alone was affected, whilst in one (the subject of this Plate) both face and arm were affected together.

(SMALLER ATLAS.)



West, Newman chromo.







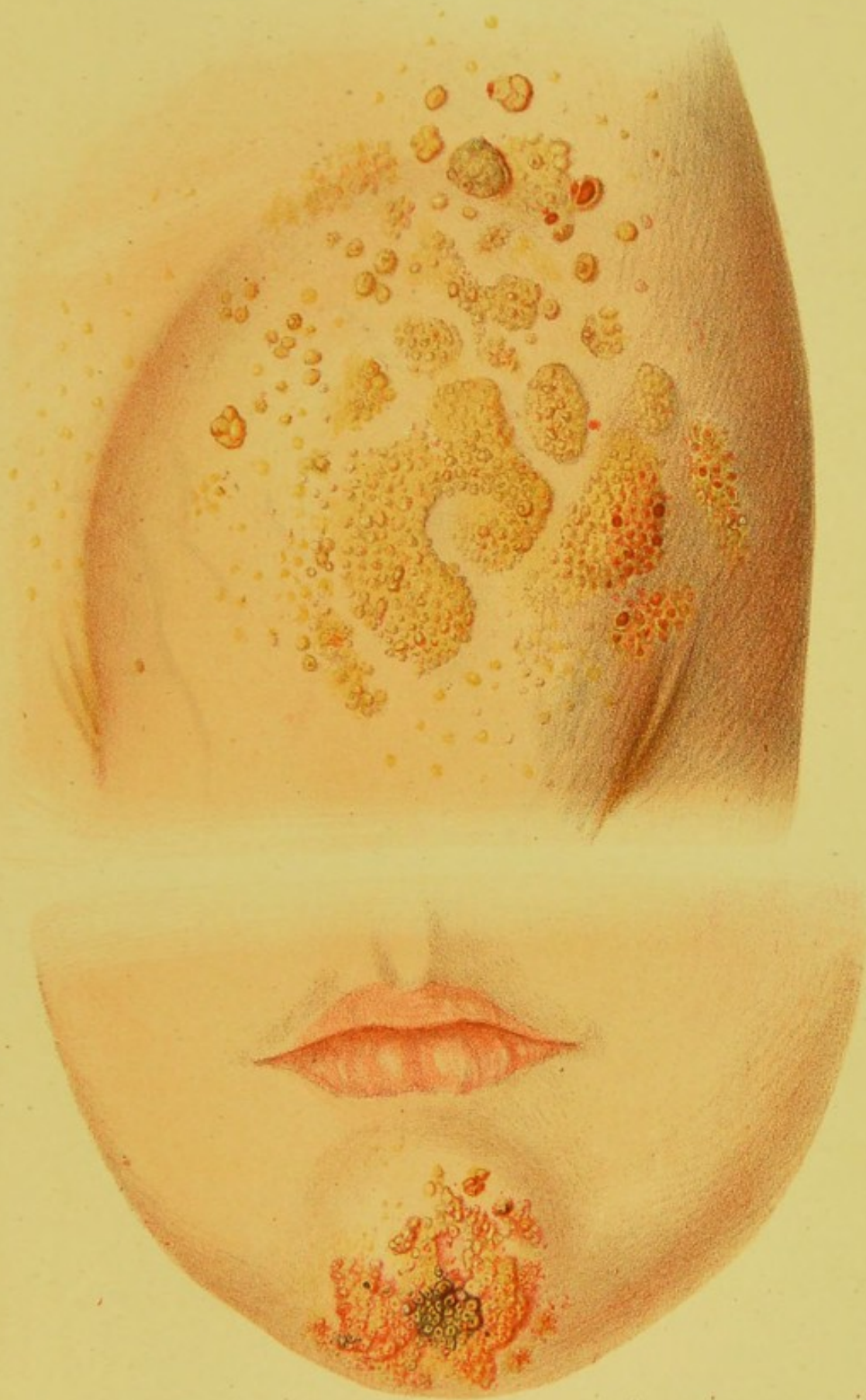## PLATE XV.


### LUPUS LYMPHATICUS. (INFECTIVE LYMPH-ANGEIOMA.)


---

THE two figures in this Plate are from different subjects, both of them young boys. The details of both cases have been published in the 'Pathological Transactions' for 1880. The disease was exactly alike in the two cases, and in each instance it had been developed without any preceding nævoid condition. In one case it began on the chin, by what looked like a little wart, at about the age of nine; and in the other on the shoulder, at the age of four, apparently as the result of friction from the boy's braces. In each instance the morbid condition had spread near to the part first affected, but had not developed itself on any more distant region of the body. It consisted of groups of coherent vesicles, upon and amongst which were little tufts of dilated capillaries. There was some general thickening of the skin at the base of the vesicles; the latter, which were firm and very persistent, yielded a fluid which was not distinguishable from lymph. There was no outgrowth of papillæ whatever. The character of the eruption was remarkably the same in all parts, varying chiefly in the presence or absence of the little capillary tufts. There was no discharge of any kind from the eruption, but the patches were liable to attacks of erysipelalous inflammation. The treatment adopted consisted in destroying the patches by caustics and the actual cautery. The report in the Pathological Society's volume is accompanied by a description of microscopical appearances, and an engraving by my friend Dr. Sangster.

See also Plates XVI. and LXXVIII., and a series of drawings in the Clinical Museum.







## PLATE XVI.

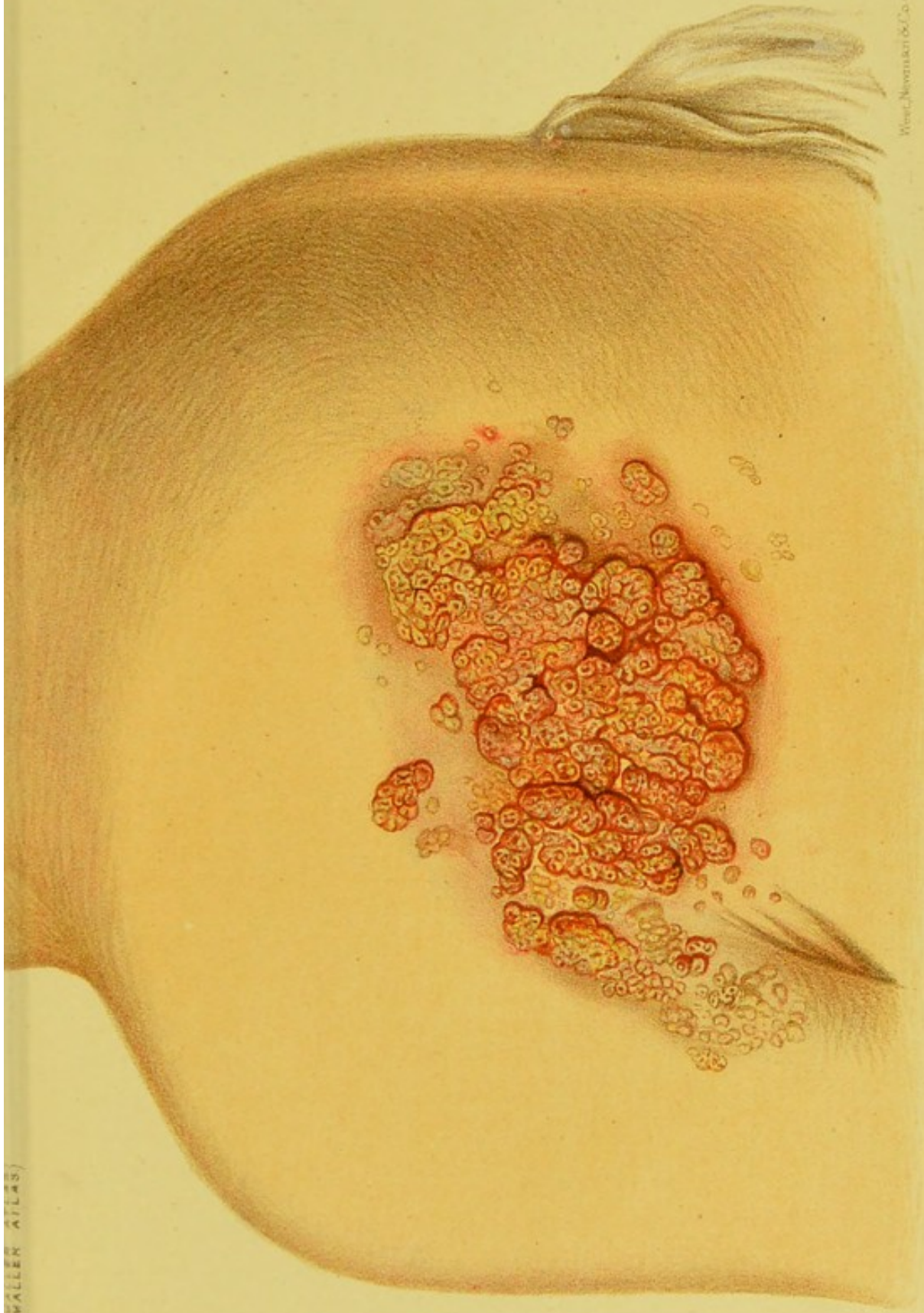### LUPUS LYMPHATICUS. (INFECTIVE LYMPH-ANGEIOMA.)

—◆—


In this Plate a third example of this curious disease is shown, and the identity of all three will be readily admitted. In this instance the patient was a young man of about 17, under care in the London Hospital. The eruption had been present several years, and was spreading, as in the other cases, at its borders and by the production of satellites. There were no similar patches on more distant parts of the body. Several attacks of erysipelatous swelling of the affected skin had occurred.


The curious disease here illustrated, and which I ventured some years ago to name as above, has now been well investigated by several observers. All agree that the cystic-formations, which constitute such a peculiar feature, are of lymphatic development. These little lymph-cysts have been observed principally under two conditions,—first, in association with congenital nævi; and secondly, as in my present cases, wholly without such connexion. It would be convenient, I think, if the two groups of cases were kept apart. In justifying the term *lupus lymphaticus* as applicable to the non-nævoid class here illustrated, I take into consideration the facts (*a*), that the disease is of local origin; (*b*), that it is infective, spreading at its edges and producing satellites; (*c*), that it is very chronic, but at the same time very persistent in its course; (*d*), that it begins usually in the young; (*e*), that it leaves scars when cured; and lastly (*f*), that it is attended by cell-formations indistinguishable from those of *lupus*. It is of course very different both from *lupus vulgaris* and *lupus erythematosus*, but scarcely differs more from them than they from each other. All I contend for is that it should be placed in the *lupus* family. I have now seen about eight examples of the malady, and several have been recorded by other observers. The nævoid form was, I believe, first illustrated by Mr. Bryant, in the Pathological Society's 'Transactions,' and subsequently, in much more detail, by Dr. Tilbury Fox. The latter observer gave excellent microscopic descriptions, and fully recognised its lymphatic nature.

(SMALLER ATLAS)



West, Newman & Co. del. lith.





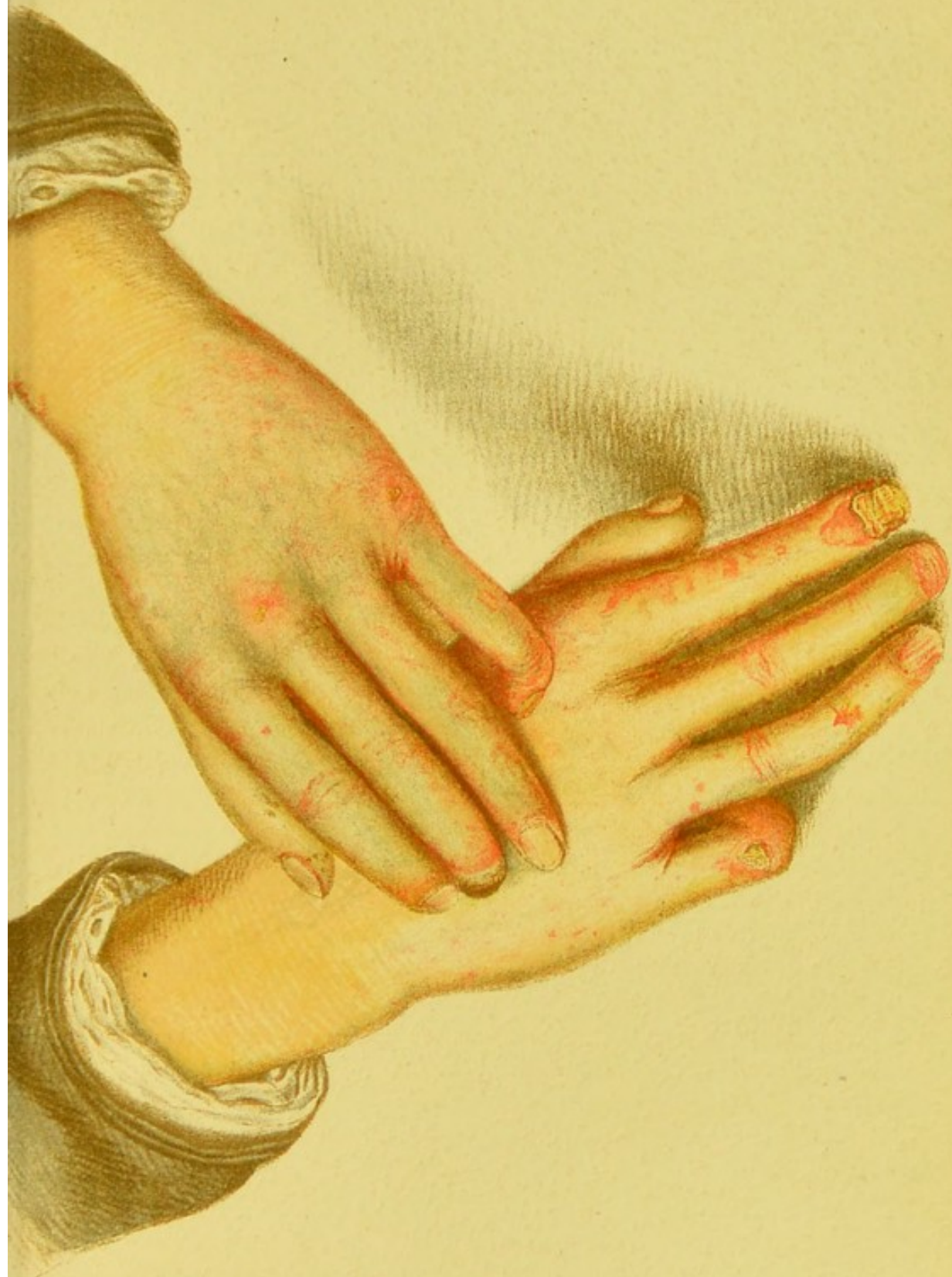

## PLATE XVII.


### ACRO-SCLERODERMIA: A LATE STAGE OF SCLERODERMIA OR DIFFUSE MORPHŒA.



THE hands shown in this Plate offer a good example of the atrophic condition of diffuse morphœa or sclerodermia. The fingers have lost all plumpness, and become slender, pale, and wooden. The greater part of the hand is of wax-like pallor, but there are numerous patches of congestion (stigmata), like red seaweed, and here and there are a few little ulcers. It was quite impossible to pinch the skin up anywhere, as it was tight and parchment-like. Although there had been no gangrene of appreciable extent, the nails and tips of the fingers had suffered more or less. It is worth while to look carefully at the portrait, and note how symmetrical the changes are. Another view of the same hands is given in Plate XXXI. It will be seen that the thumb has almost escaped (probably on account of its shortness); that the index and middle finger have suffered more than the ring; and that the little finger has had its terminal phalanx twisted and flexed. This form of morphœa is always especially severe in the hands and face, and may on that account be appropriately described by the prefix "*acro.*" Its subjects are always liable to Raynaud's phenomena; but, on the other hand, it is by no means true that these phenomena produce sclerodermia.





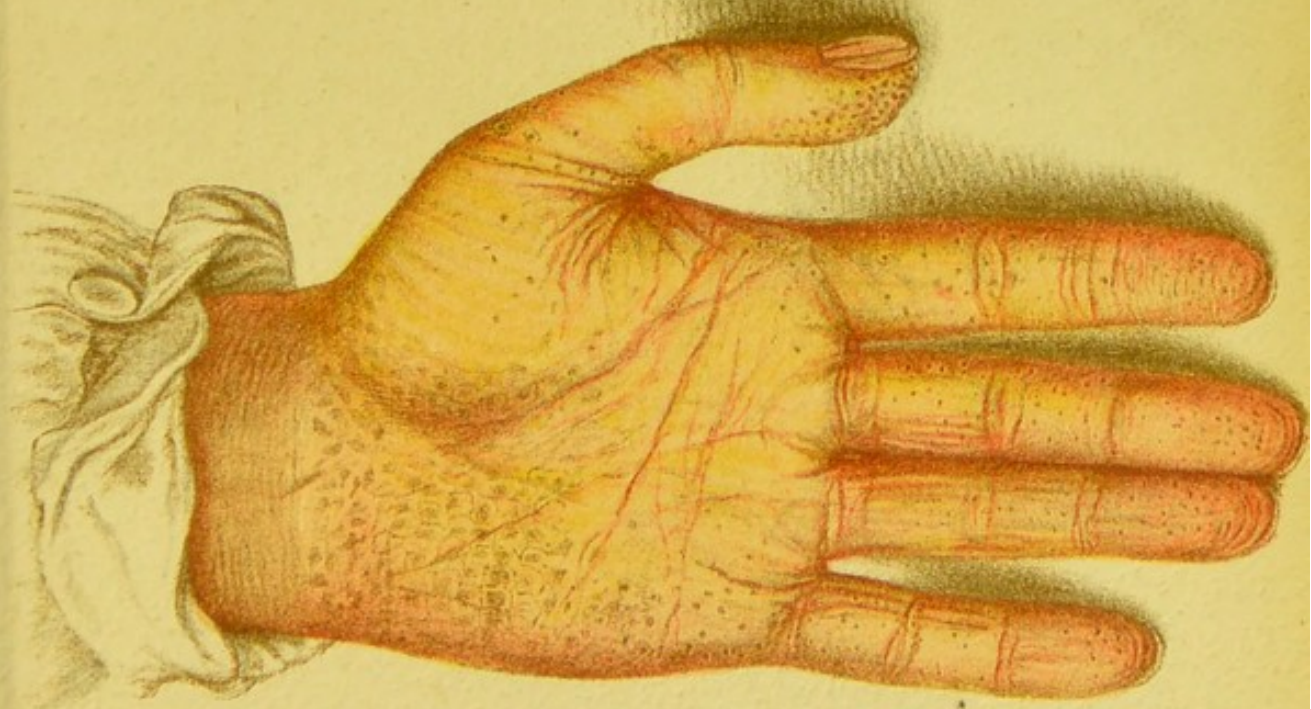
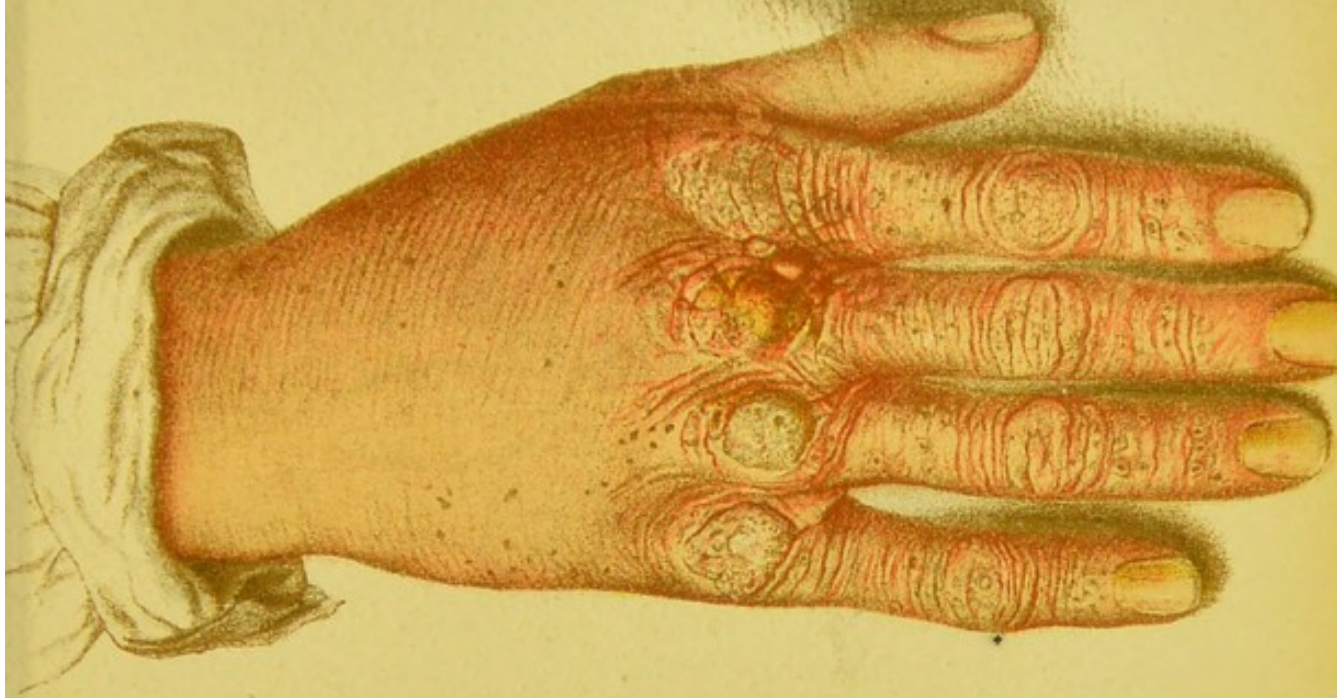


## PLATE XVIII.


### ARSENIC-PSORIASIS AND KERATOSIS.



THE back and front surfaces of the hands of Mr. D——, the patient whose elbow is shown in the next Plate. It will be seen that across the knuckles of the hand a number of dry, thick, scaly crusts have formed. On the backs of the fingers there are numerous little pits where the epidermis is broken, while the skin generally is discoloured and harsh. The patches across the knuckles are exactly like psoriasis, excepting, perhaps, that there is more thickening beneath the crusts. They do not occur precisely in the parts where psoriasis is most common, that is, on the back of the hand. The palmar surface of the hand shows the epidermis dry and cracked, and there are numerous little pits where it has been broken. The extremities of the fingers are especially affected and somewhat reddened. It has been difficult to represent the little corn-like patches of thickened epidermis which were present.









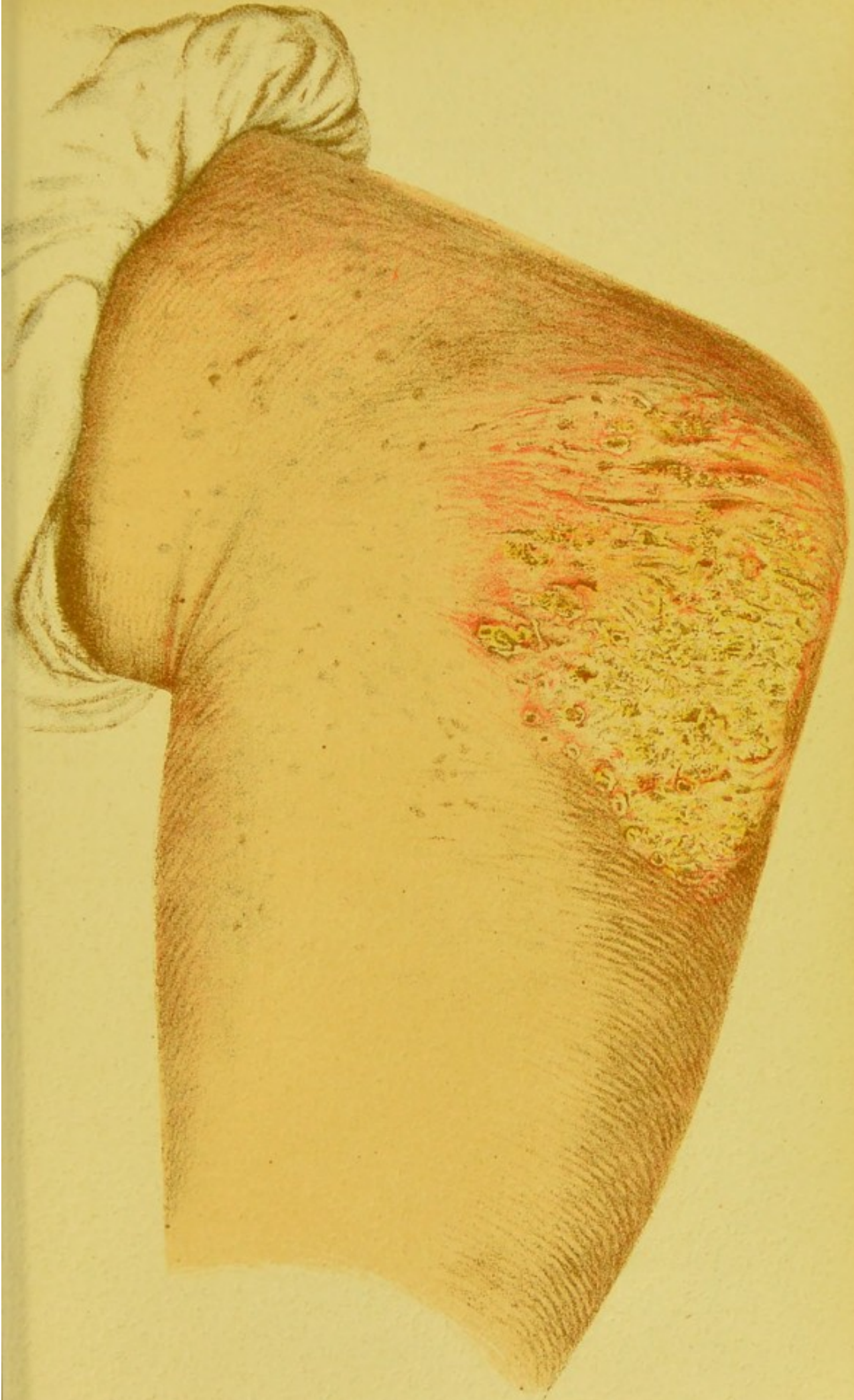## PLATE XIX.


### ARSENIC-PSORIASIS.



THE Plate shows the elbow of a gentleman whose hands are delineated in Plate XVIII. It will be seen that the whole skin is of a dirty brown tint, and that a large scaly patch has been developed near to the elbow. This patch was quite dry, but it was somewhat less circumscribed, and showed more of redness about its edges than common psoriasis usually does. The patient had a perfectly healthy skin previous to the administration of arsenic.

The arsenic had been given in the hope of arresting a malignant growth.







## PLATE XX.

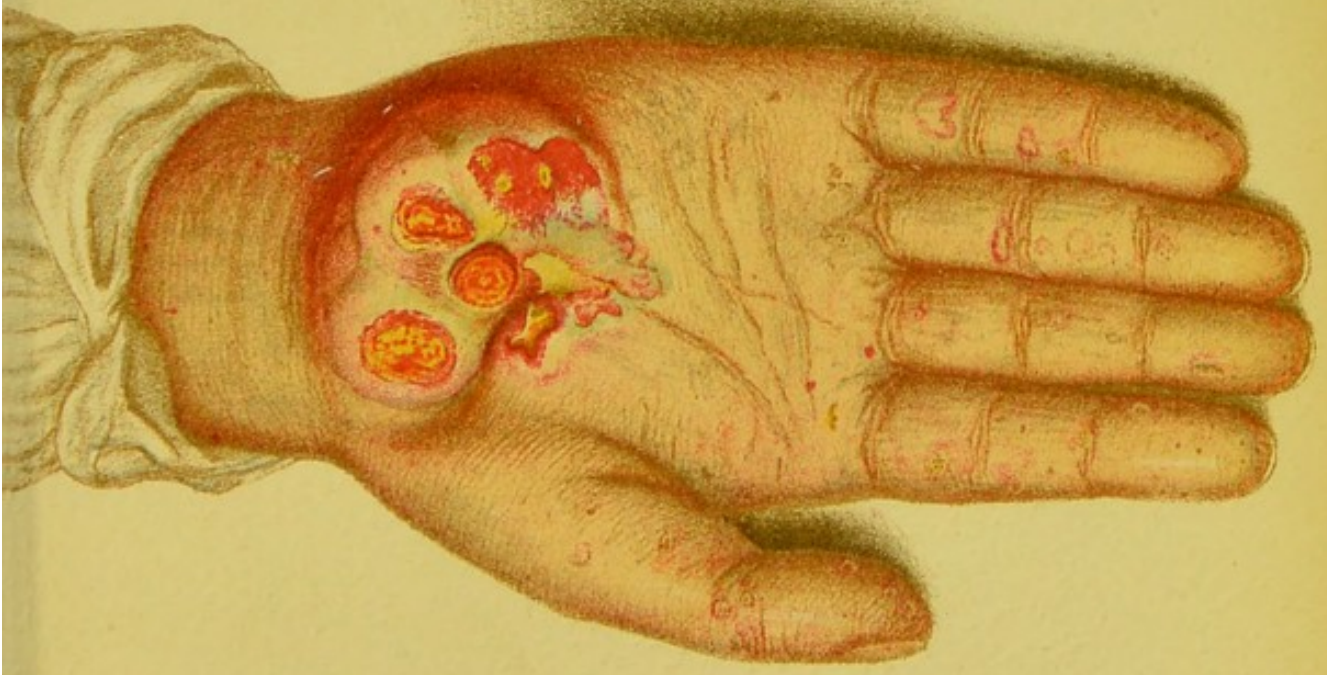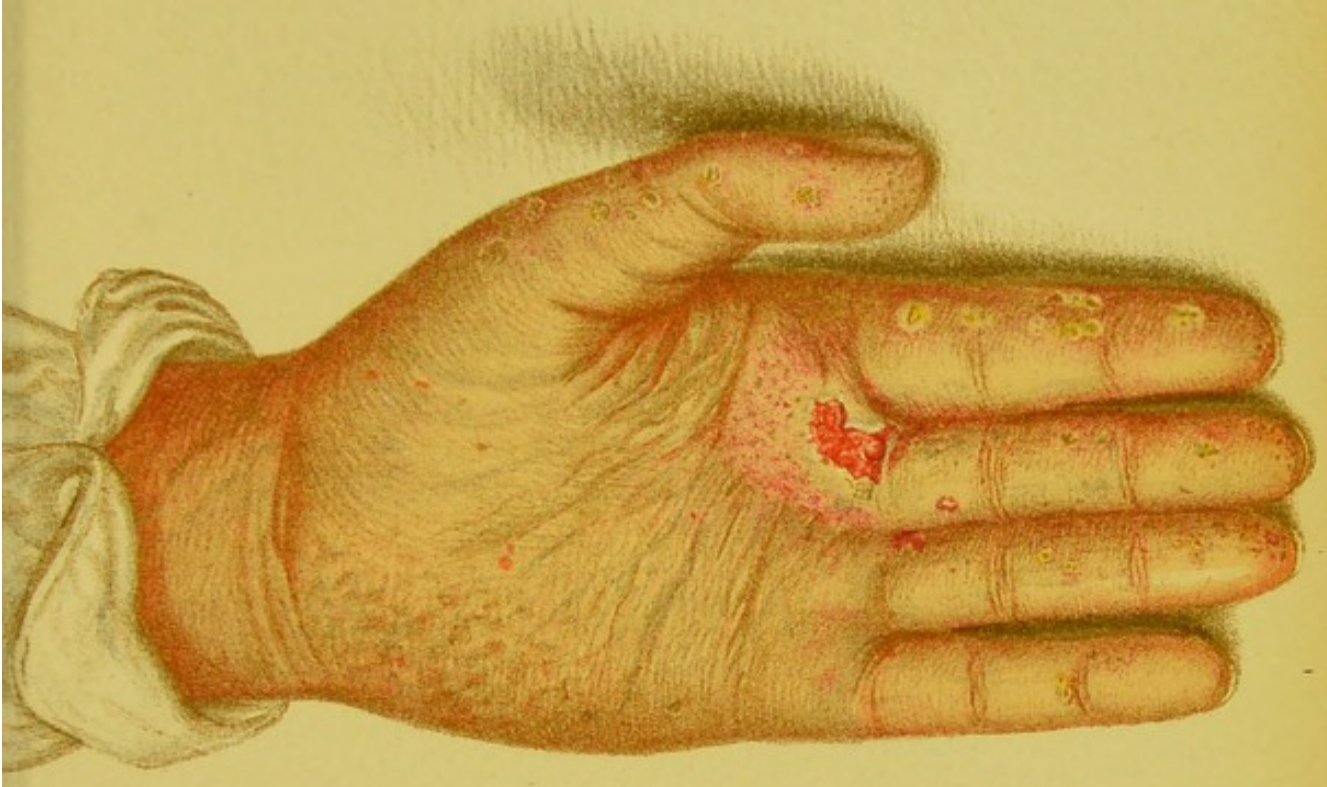### ARSENIC-KERATOSIS AND ARSENIC-CANCER.


---

THE palmar surfaces of the two hands of Dr. W——, who became the subject of arsenic-cancer. It will be seen that the palms are exactly like that of the hand shown in Plate XVIII., but with the addition of a fungating growth in each. That in the right palm is of considerable size and thickness, and is placed just above the wrist. That in the left is much smaller, having been of more recent development, and shows only a reddened excoriation between the index and middle fingers, beneath which there is a certain amount of thickening. In this case common psoriasis had been present in the first instance, and arsenic had been given in large doses over a long time for its cure.

After this portrait was taken, Dr. W—— had his right hand removed by amputation through the forearm. He died within a year, with recurred malignant growths in the glands and viscera. The form of cancer was a modification of epithelial.

The case is narrated in full in the 'Pathological Transactions,' and I possess reprints of the paper.









## PLATE XXI.

### LUPUS-CANCER.

---

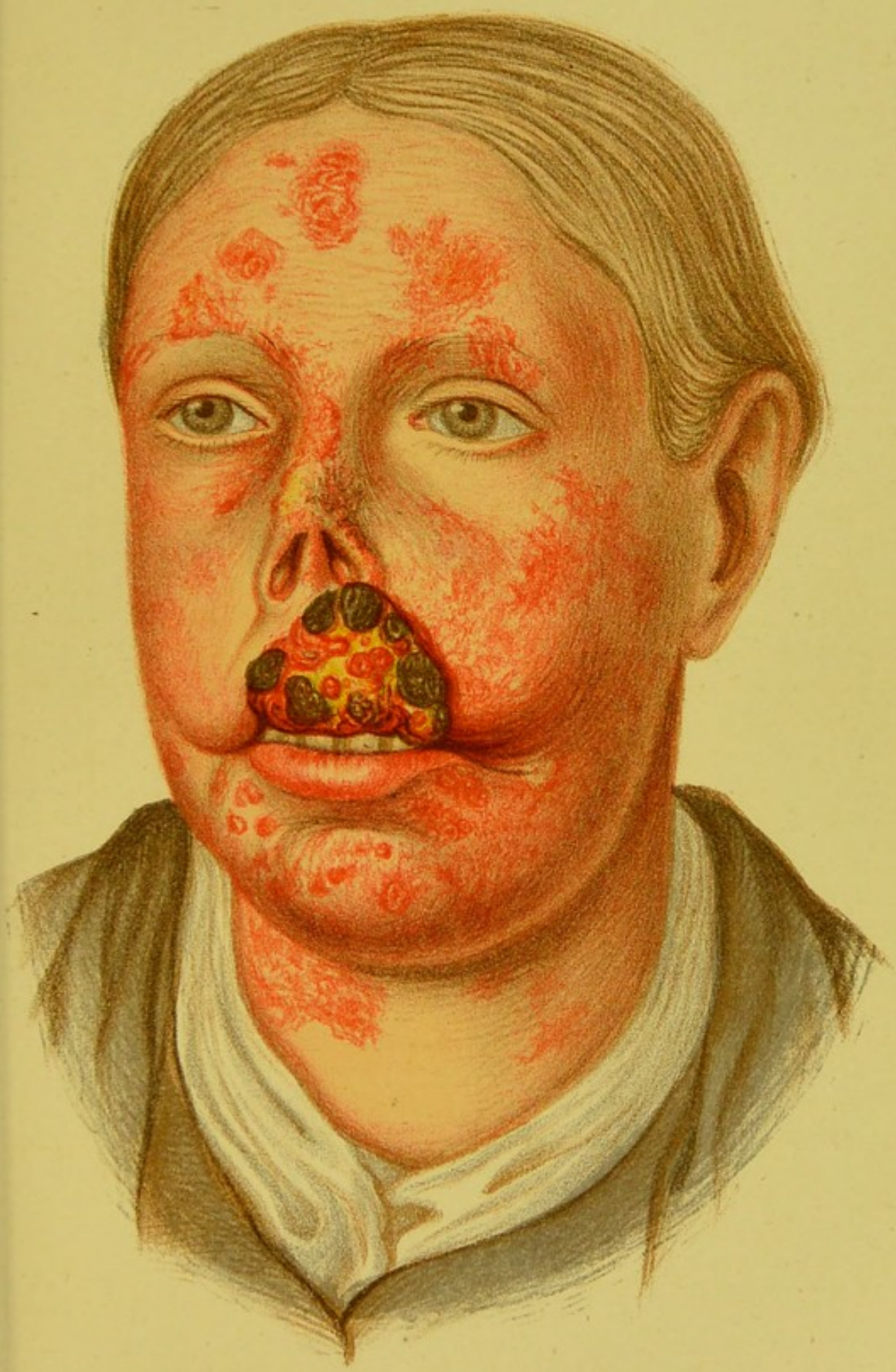
THIS portrait shows the occurrence of epithelial cancer in the scar of lupus. The patient was a woman aged fifty-one, who had suffered from lupus of the face for about thirty years. In the scar of the lupus, on the upper lip, malignant ulceration had occurred about a year before I saw her. I excised the lip in October, 1873, making a free incision into the cheek in order to bring the parts together without tension. It healed soundly, but within six months another patch of malignant ulceration developed in the scar of the cheek at some distance from the original one. Chloride of zinc was now applied, but after a short time she declined further treatment. I believe that she died of the disease within a year of the commencement of the cancer.


The microscope showed only the usual conditions of epithelial cancer, but the disease conformed to the type of rodent cancer in this, that it did not produce any disease of glands. In rapidity of progress it was, however, in marked contrast with what is usual in rodent cancer, destroying the parts widely and deeply.


See 'Archives,' vol. ii., page 138, and vol. iii., pages 205 and 337.

I have seen several cases like this in which cancer attacked the scar left by lupus, and in all it proved rapidly aggressive.

A considerable series of portraits in the Clinical Museum illustrates the development of cancer in the scars of lupus. In several the tendency to spread rapidly and to fungate was most marked.







## PLATE XXII.

### DESQUAMATIVE DERMATITIS CURED BY OPIUM.

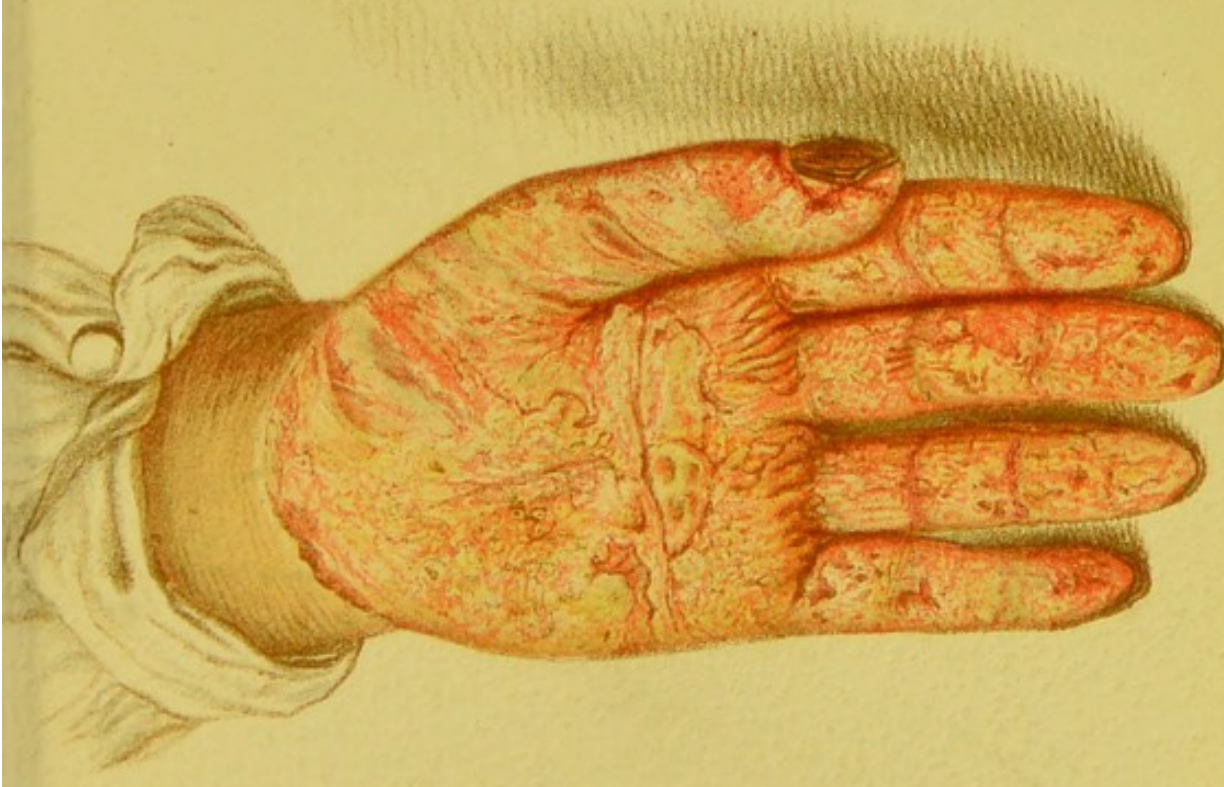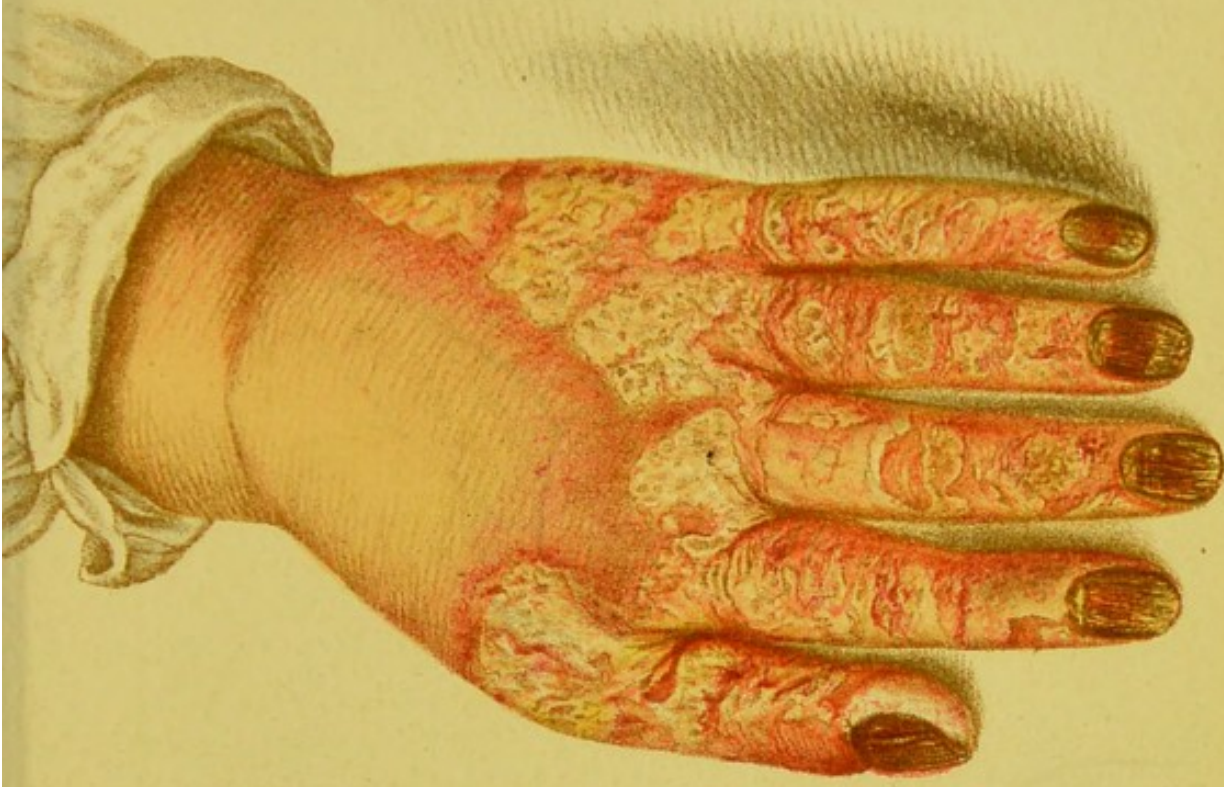
---


THE patient from whose left hand this drawing was made was a woman aged sixty-one, of gouty tendencies, but, apart from the eruption, in excellent health. Both hands and feet, the scalp, the groins, the corners of the mouth, and the canthi of the eyelids were affected by a chronic exfoliative dermatitis, which had commenced nine months before, in the form of red spots between the fingers, and three months later had attacked the toes. No cause could be assigned, and there was no history of skin-diseases in the family. Her tongue was very clean and red, almost "beefy." Both hands and feet were attacked in a precisely symmetrical manner; on the latter all the toes were affected, but the disease did not extend much above them. All the nails were inflamed and rough. The disease tended to spread from the digits upwards. On the backs of the wrists and on the neck there were a few small detached patches, and these were increasing in number; they also showed a strong tendency to advance at their edges. They were for the most part quite dry, were attended by peeling of the epidermis and by some slight swelling, and tended to form fissures. When the scales were removed by applications the surface left was smooth, raw-looking, and red. The scalp was everywhere involved, and the hair very thin. There were symmetrical patches at the corners of the mouth, which were gradually extending, with abrupt margins, on to the cheeks. The inner commissures of the eyelids were also affected, and there were symmetrical patches in the groins.

The patient had undergone much skilled treatment before I saw her; arsenic had been freely used, and, amongst other measures, she had been salivated. A complete cure finally resulted under the use of opium. The hair grew again, the nails were completely restored, and the skin of the hands became soft and healthy. I do not think that there could be the least doubt as to the opium being really the cause of the recovery. It was continued for upwards of three months. The dose was from five to fifteen minims of the liquor opii sedativus. The patient regained good health, and remained well several months after the opium was disused. Six months later there was a slight tendency to relapse, but she again recovered.

Several years later she passed through a very severe attack of acute erysipelas-eczema which involved the whole surface.

See 'Archives,' vol. iv., page 82 (Mrs. L—).





STATE OF NEW YORK

IN SENATE, January 15, 1907.

REPORT

OF THE

COMMISSIONERS OF THE LAND OFFICE

IN ANSWER TO A RESOLUTION PASSED BY THE SENATE, APRIL 11, 1906,

RELATIVE TO THE

LANDS BELONGING TO THE STATE.

ALBANY: J. B. WARD, STATE PRINTER, 1907.



## PLATE XXIII.

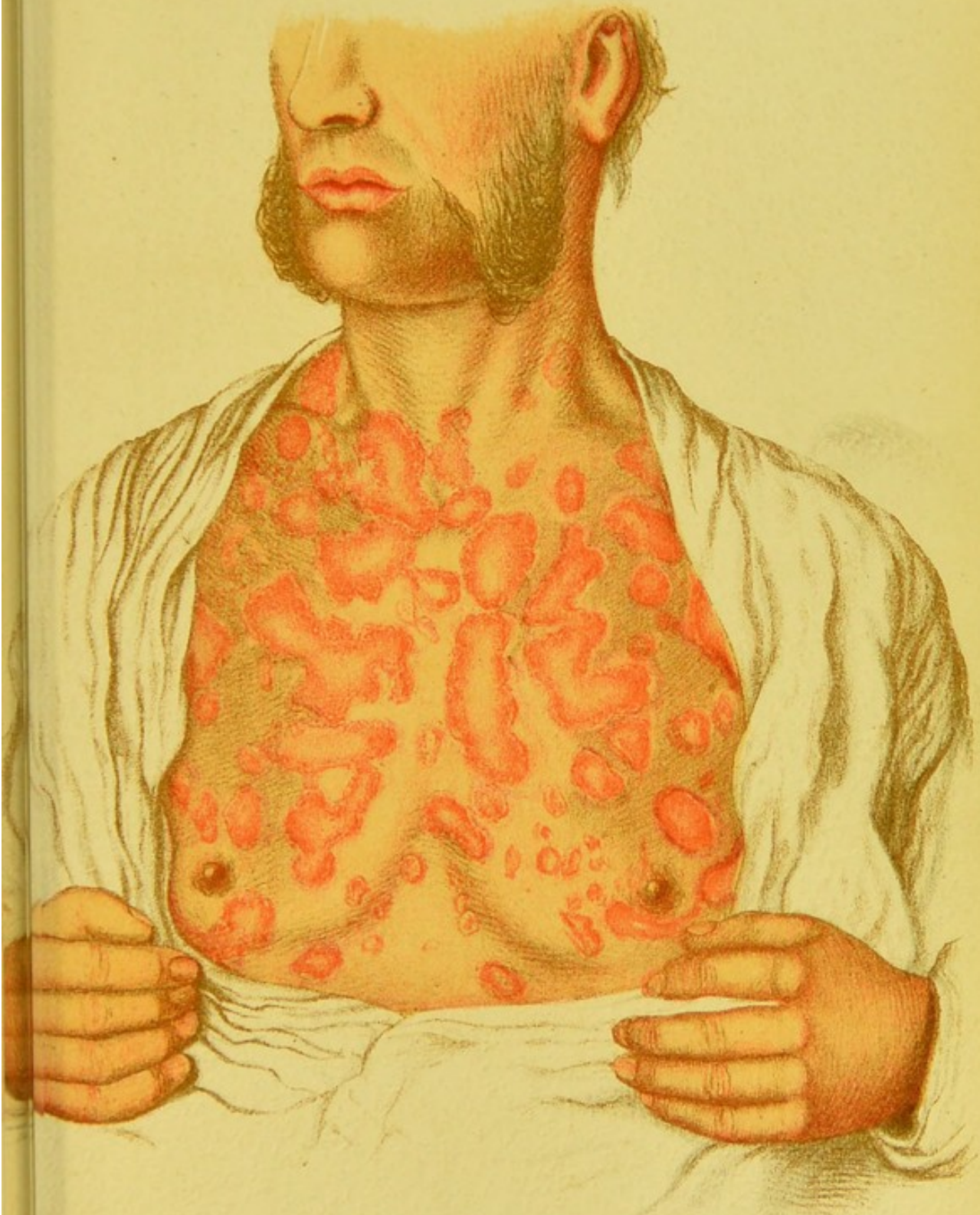
### ERYTHEMA-URTICARIA FROM VEST-IRRITATION.

---

It might, perhaps, be useful if a classified arrangement of the causes of skin disorders were attempted, in addition to endeavours to group the diseases themselves. There are certain eruptions to which the term "Vest-Eruption" is more practically appropriate than any which should attempt to designate the character of the rash itself. They come in consequence of the irritation of the vest, and usually of a flannel vest. Sometimes it is the case that the patient has recently adopted some new material, or changed from his thin summer garment to a thicker one for winter. Vest-rashes are usually limited to the parts touched by the vest, but they are by no means always the same in character. Sometimes they show a tendency to spread to other adjacent parts.

In the portrait is shown the chest of an adult man, who had been working hard in very hot weather with a woollen vest on. He had perspired very freely indeed, but had not dared to put aside his vest for fear of catching cold. The result was a profuse erythematous-urticaria over all parts where the vest touched. The eruption, as shown, was in margined patches raised at their borders, of a bright red tint, whilst their centres were pale and depressed. It differed from a true urticaria in the persistence of the individual patches, and its limitation to the parts which had been irritated. It soon got well on removal of the cause. In other cases, vest-eruptions may present features very different from those here shown. An excellent portrait, in 'Wilson's Atlas,' shows a lichenoid eruption, exactly limited to the vest regions. No doubt it was of the causation above described.

Vest-eruptions form an important group of the class of "Skin diseases due to the irritation of clothing."





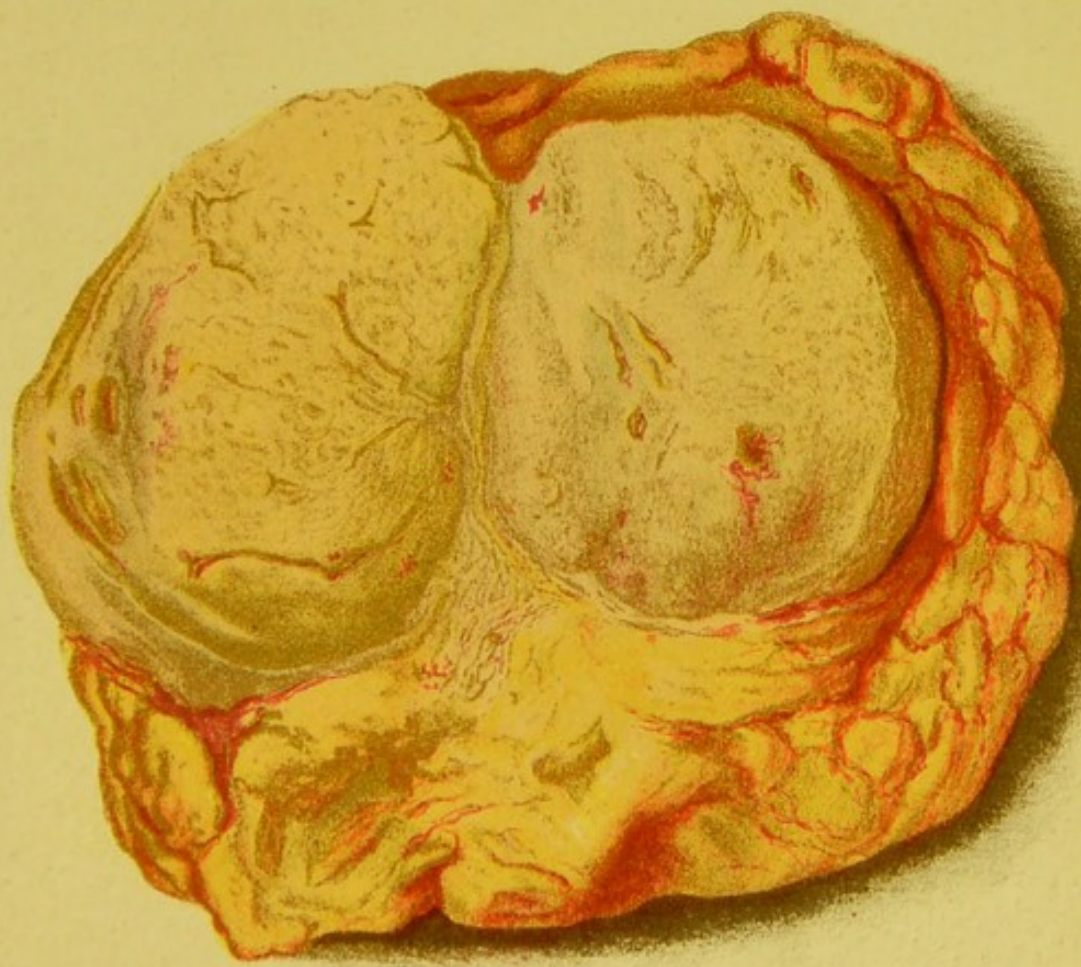
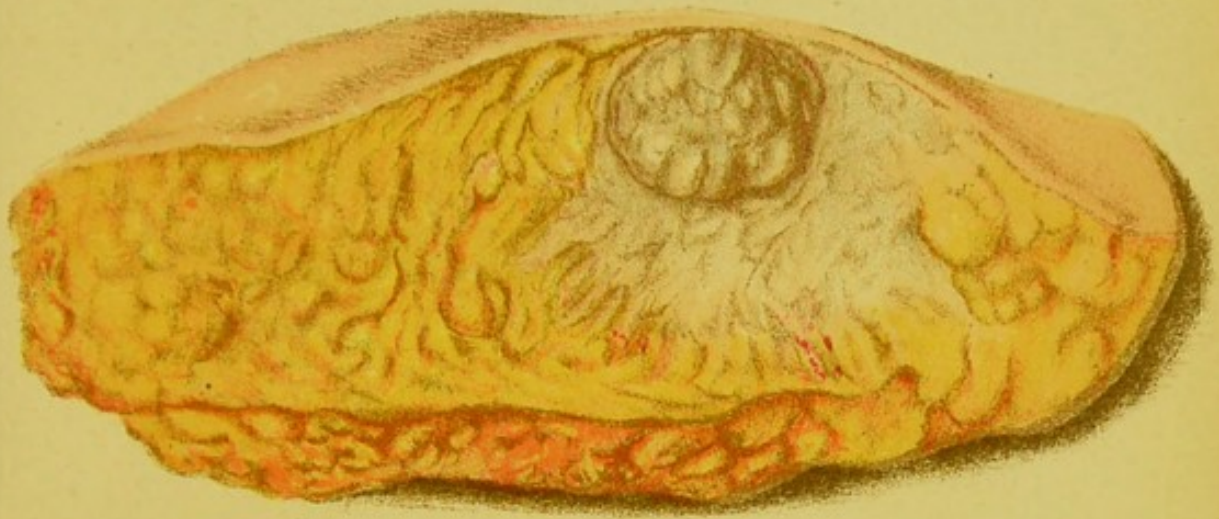



## PLATE XXIV.


### ADENOID TUMOURS IN THE BREAST IN THREE GENERATIONS, WITH SCIRRHUS IN ONE OF THEM.

---

THIS Plate is of interest as an illustration of inheritance, and also of the supervention of malignant disease in close proximity with an innocent growth. The lower portrait shows the breast of a lady named Mrs. H—, and the upper one is that of one of her daughters. Twenty years ago I removed Mrs. H—'s breast on account of a rather rapidly-growing tumour. It proved to be a soft adenoid; no recurrence or gland implication ever took place, and she is still living and well. She was about fifty years of age at the time. A few years ago one of her daughters, Mrs. W—, aged forty, came under my care for a growth which I could not doubt was scirrhus. She asserted that she had a tumour ever since girlhood. The section of the breast is shown in the sketch. It will be seen that there is an encapsuled and lobulated adenoid growth the size of a marble, and that around this there is a pale fibrous-looking, ill-defined area of thickened tissue. The latter was characteristically scirrhus. It adhered to the adenoid growth, but did not infiltrate it. I have since removed the axillary glands on account of their implication. One of Mrs. W—'s daughters, a granddaughter of the first patient, has, at the present time, an adenoid tumour in one breast.









## PLATE XXV.

FIG. 1.—CANCER OF THE MALE BREAST.

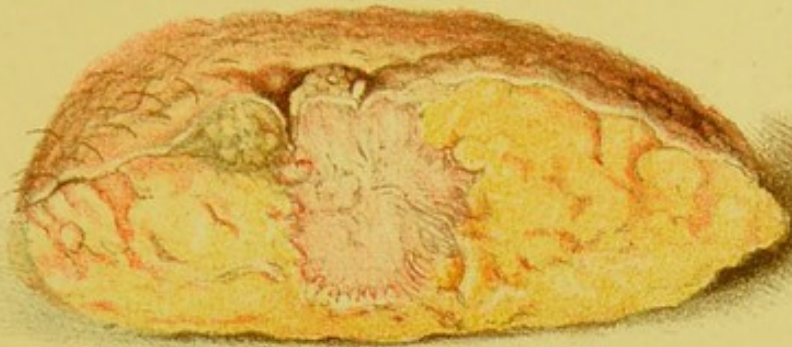
THE upper figure shows the section of the breast of an old man with a mass of scirrhus in the centre. The nipple is deeply retracted, and by its side is a small cyst-cavity containing greenish fluid. The scirrhus mass is very dense, pale, and fibrous-looking. It puckers-in the surrounding fat, and apparently involves almost the whole gland.


The patient was an old gentleman of seventy-four, who had known of the tumour for six months before its removal (Feb. 15th, 1870). I believe that he remained well after its excision, and had no recurrence.


FIG. 2.—CANCER OF BREAST, WITH CYSTS AND ADENOID GROWTH.

The lower figure shows the section of the breast of Mrs. C., aged fifty-four, in whom scirrhus was developed, together with cystic and adenoid disease. She had had a sore nipple for two years, but had noticed a tumour only eight months. To the left is seen a congeries of cysts, which contained blood-stained fluid and soft endogenous growths. Above the cysts is a circumscribed mass of adenoid growth, and to the right of the latter the structures are puckered by infiltrating scirrhus.

The illustration is of value as enforcing the desirability of excision of the whole breast in all cases of cystic disease in which induration remains after evacuation of the cyst-contents. It may perhaps be said that in all cases in which the cyst-contents are blood-stained, excision ought to be done. In this instance a large quantity of cyst-fluid had been evacuated by tapping some weeks before the operation.







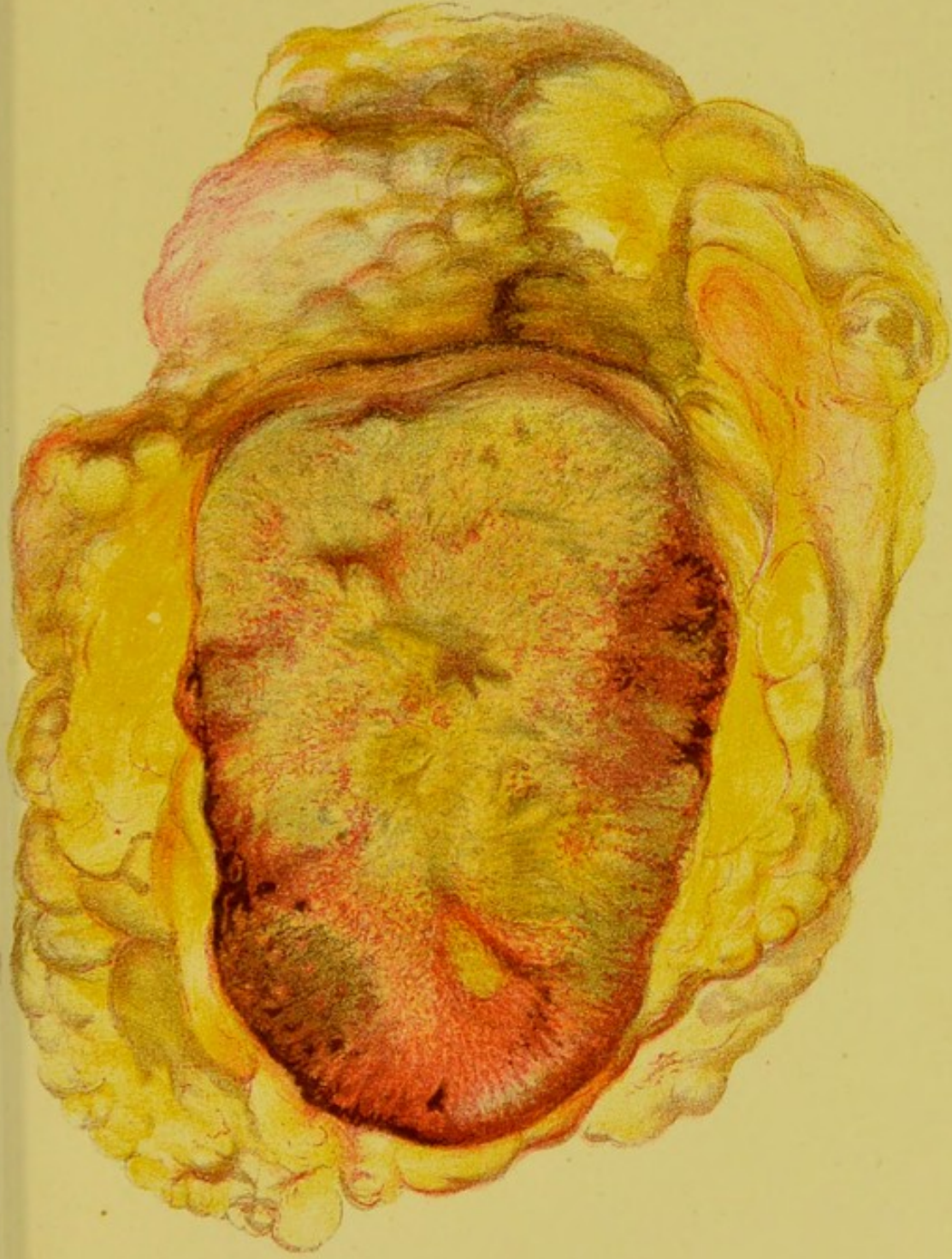## PLATE XXVI.


### RAPIDLY GROWING SCIRRHUS OF THE BREAST.




THE drawing shows a large, well-circumscribed mass of scirrhus in the middle of a breast loaded with fat. The growth was unusually soft and vascular, and had developed very rapidly. It shows large areas of yellow fatty degeneration.

I have lost the address of the patient (who was a woman of middle age), and cannot speak positively as to recurrence; but I believe that she was living several years after the operation, and free from symptoms. My experience has been that some of these cases of most rapidly growing tumours of the breast have given the best results as regards non-recurrence.









## PLATE XXVII.

### MYELOID AND CYSTIC TUMOUR OF THE FEMUR.

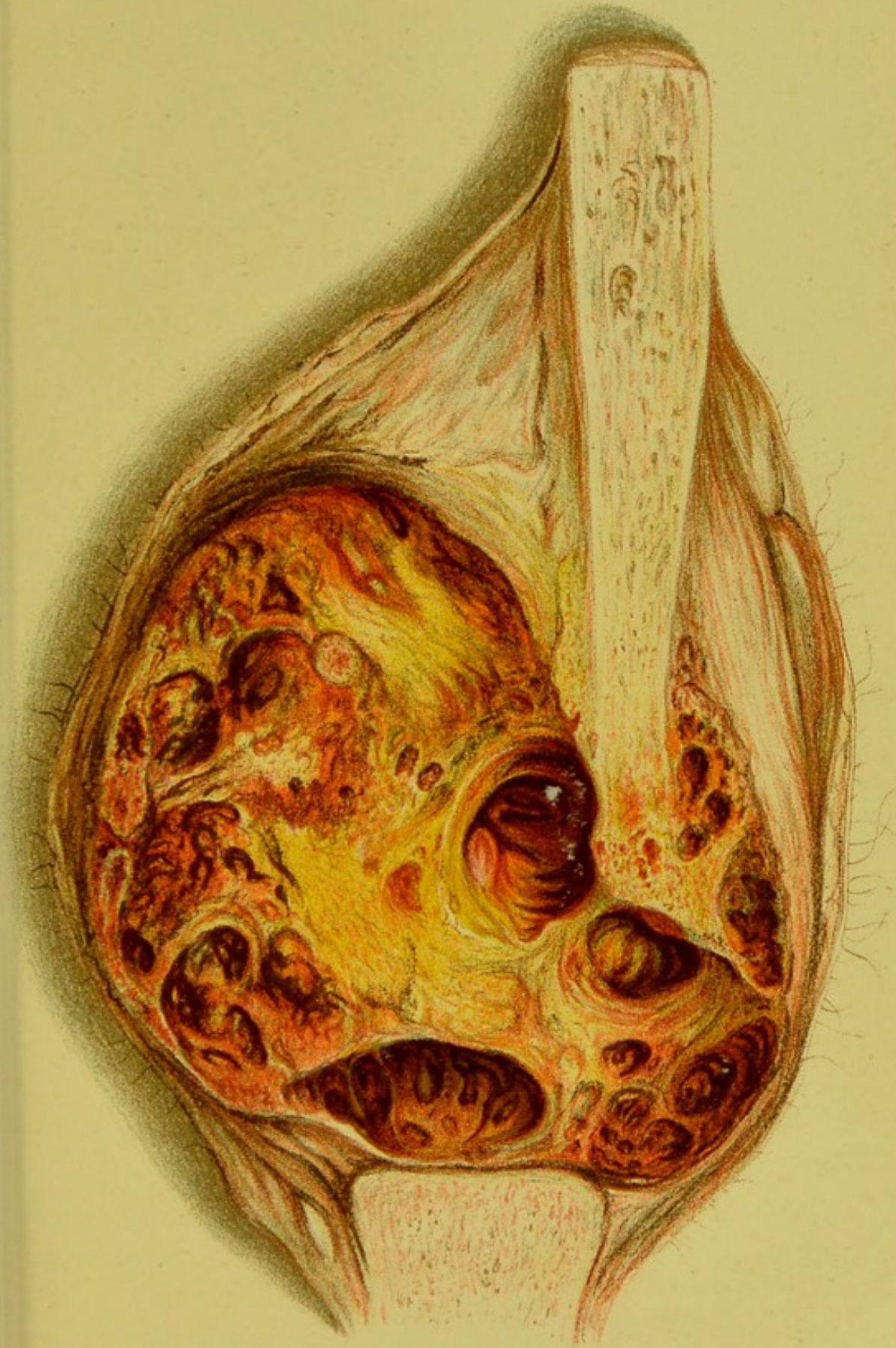



THIS portrait represents the section of a tumour which had developed slowly in the condyles and lower part of shaft of the femur. The patient was a man of about twenty-eight, and the tumour had been growing several years. I amputated through the thigh (in the London Hospital), and he made a good recovery. He is, I believe, still living (ten years after the operation).


The portrait shows the condyles and shaft expanded by a well-defined and partially encapsuled growth. The section shows, in the solid parts, the various tints of brown and yellow which characterize myeloid sarcoma. There are numerous cysts of considerable size, and many nodules of ossification. The tumour bulges into the knee-joint, so as to appear to occupy it. It is everywhere surrounded by a thin capsule of bone.

As illustrating the law under which similar growths occur under similar conditions, I may mention that I possess another drawing, which can scarcely be distinguished from this.

See 'Illustrations of Clinical Surgery,' Plate LVIII.







## PLATE XXVIII.

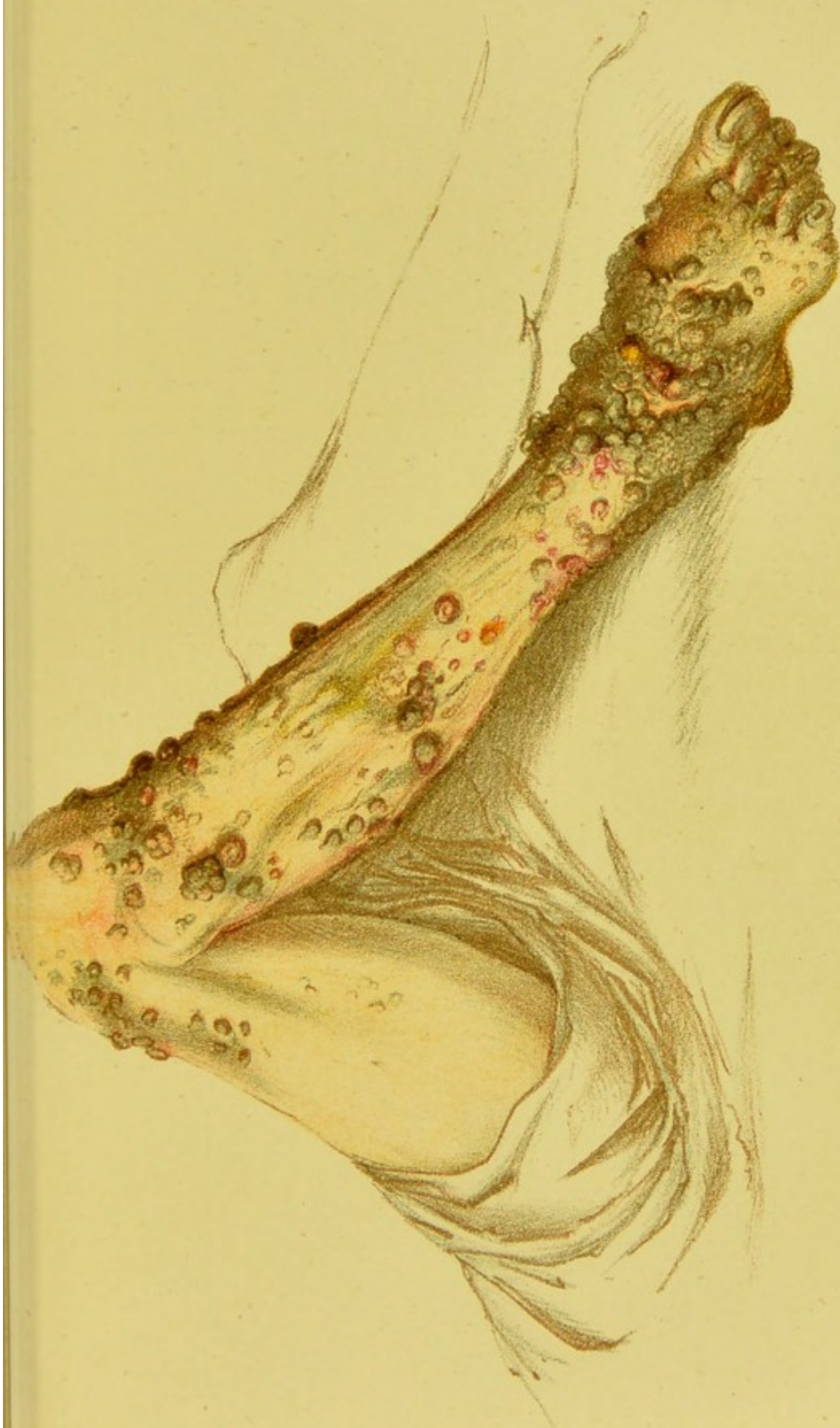MULTIPLE MELANOTIC GROWTHS IN SKIN, CONFINED TO  
THE LIMB IN WHICH THE PRIMARY GROWTH HAD  
OCCURRED.




THIS portrait is copied from a drawing given to me by Professor Gairdner, of Glasgow. The patient died with melanotic growths in various parts, within a year of the date at which the portrait was taken. It shows a whole crop of little melanotic tubers, like currants or small grapes, in the skin and subcutaneous cellular tissue of one lower extremity of an old woman. The primary disease had been, I believe, on the third toe. The portrait is of great interest, as illustrating the tendency in some forms of melanosis to infect in the first instance the lymphatic trunks of the parts adjoining to the primary disease. Thus the first indications of infective spreading are local. To this tendency I have adverted in 'Archives,' vol. ii., page 202.

The portrait is almost the exact representation of the leg of another woman, also referred to in 'Archives.'

The original portrait may be seen in the Clinical Museum.





1847

1848

1849

1850

1851

1852

1853

1854

1855

1856

1857

1858

1859

1860

1861

1862

1863

1864

1865

1866

1867

1868

1869

1870

1871

1872

1873

1874

1875



## PLATE XXIX.

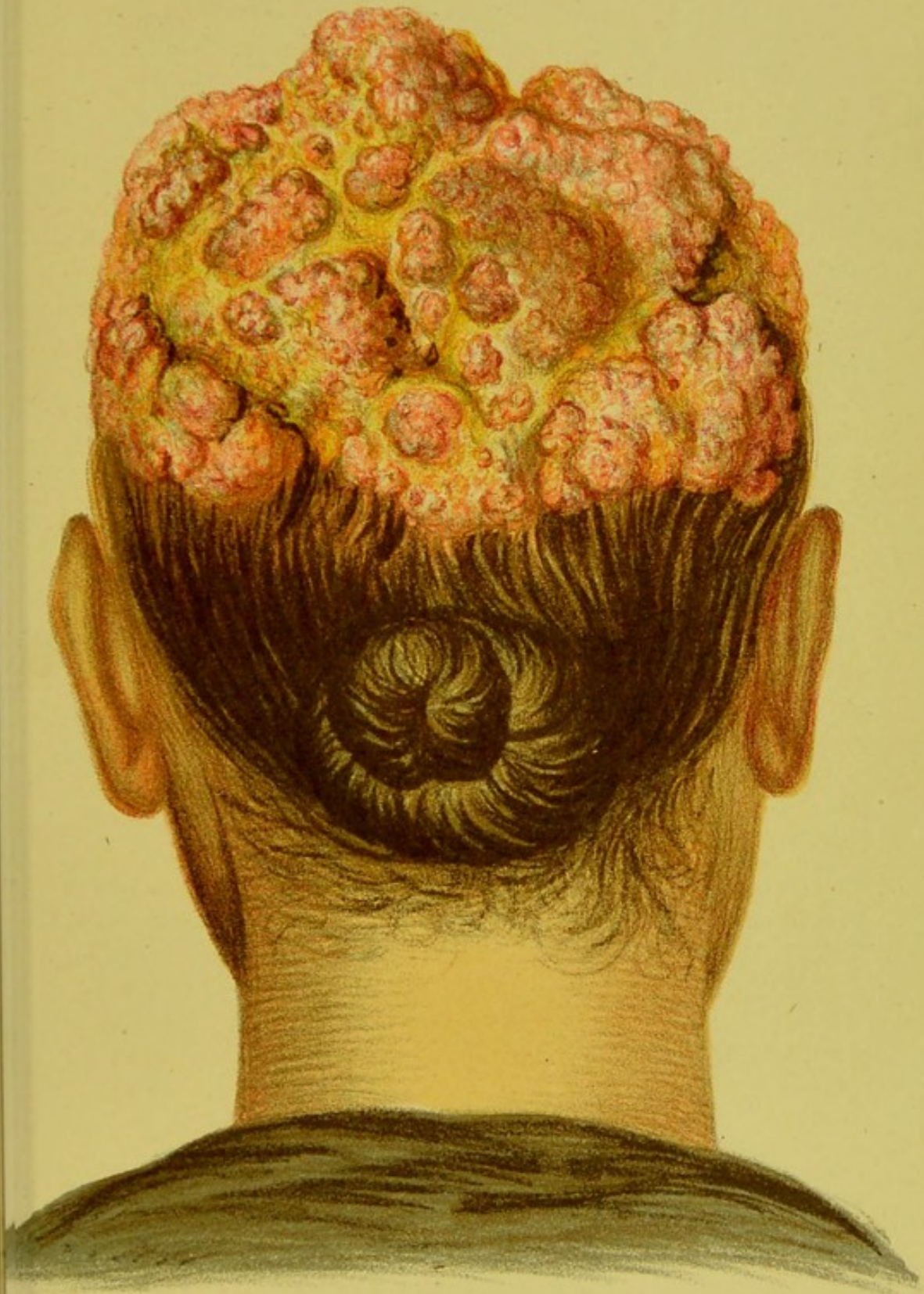
### FUNGATING GROWTH ON SCALP.


—♦—


THIS portrait shows the condition of the scalp in an elderly woman, in whom large masses of firm fungating granulations had been produced, as was believed, secondarily to ulceration of a sebaceous cyst. There was, however, no clear evidence as to its earliest stage. There was no gland disease. The patient was under Mr. Rivington's care in the London Hospital, by whom the whole of the diseased growth was excised. The operation was done chiefly by means of Paquelin's cautery, but was attended by very profuse hæmorrhage. The wound healed well, and five years later there had been no return of the disease. At this latter date the patient, then seventy-three years of age, was under my own care in the London Hospital on account of senile gangrene of one foot, and made a good recovery after amputation through the thigh.

A microscopic examination of the parts removed showed conditions which were not easily distinguished from those of epithelial cancer. There had, however, never been any gland disease, and the fact that no tendency to recurrence was shown after the removal of such an extensive growth proved that the vital endowments of the new tissue must have been very different from those of most forms of epithelioma. The tendency to fungate without any deep ulceration was the peculiar feature of the case. It belongs, I have no doubt, to the group of tumours which Mr. Cock described many years ago in the Guy's Hospital Reports as occurring in connection with enlarged sebaceous follicles of the scalp. Mr. Cock has not, however, described any case in which the disease at all approached in extent that shown in this drawing. Its extent might indeed have been almost held to be a bar to operation, and the successful result is certainly an encouragement to surgical energy even under unpromising conditions.

This case has already been published as Plate LXIX. in my 'Clinical Illustrations.'







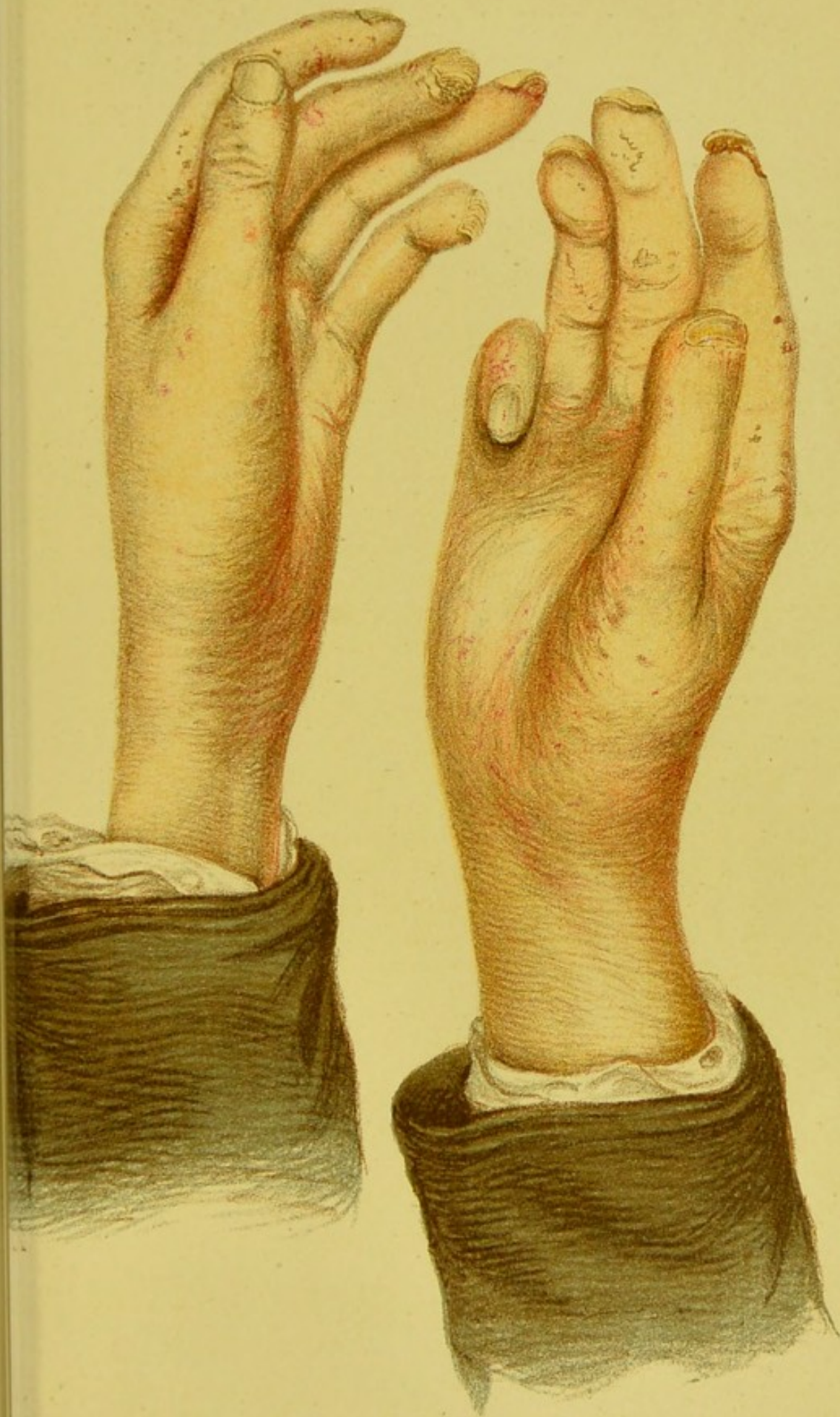## PLATE XXX.


LATE STAGE OF SCLERODERMIA OR DIFFUSE MORPHŒA.



THIS Plate and the following one illustrate the conditions shown in the hands in late stages of Sclerodermia or Diffuse Morphœa. It will be seen that the hands are pale and very thin, and the fingers slender. There are also many little scars about the fingers, and a few stigmata. The extremities of most of the digits have been damaged by inflammation occurring under the nail and in the pulp. These changes are tolerably symmetrical, and very like those shown in the next Plate. As a point of interesting detail, it may be noted that the little finger has its terminal phalanx twisted and flexed in all the five hands delineated in these three Plates (XVII., XXX., XXXI.).

Excellent models, showing conditions precisely similar to those illustrated in these Plates, are in the Museum of the Hôpital St. Louis, at Paris.





THE HISTORY OF THE

... ..

... ..

... ..



## PLATE XXXI.

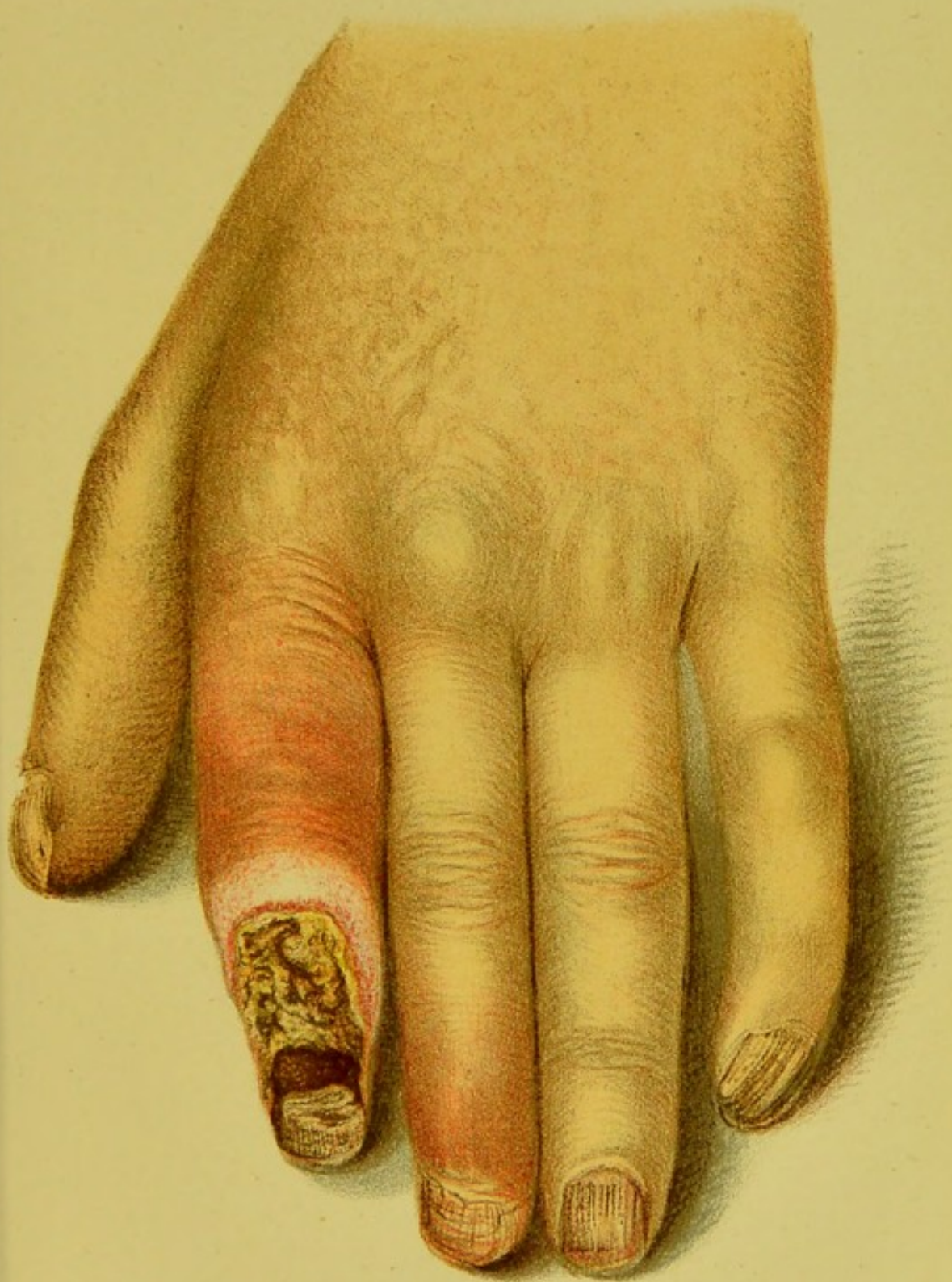SYMMETRICAL GANGRENE OF EXTREMITIES, PRECEDED  
BY RAYNAUD'S PHENOMENA AND RESULTING IN A  
SLIGHT FORM OF SCLERODERMIA.


---


Shows the condition of gangrene in the hand of Miss F——. It will be seen that the end of the left index finger is in a condition of gangrene. The finger is not mummified, but moist, and the proximal portion is distinctly swollen. On a subsequent occasion, a year or two later, the other finger passed into a precisely similar condition. There was on this occasion decided inflammation of the hand, and bullæ formed on the adjacent parts. After the gangrenous part separated the ulcer healed well. Attention is specially asked to the fact that in this case the fingers had not become slender and wooden, but retained a moderate degree of plumpness.

The case partook more of the nature of Raynaud's disease than of sclerodermia, but it is to be remembered that the patient's face was in the condition of the latter malady. There can be no doubt that the two are sometimes combined.

Miss F——'s case is given in detail in 'Archives,' vol. ii., page 33.





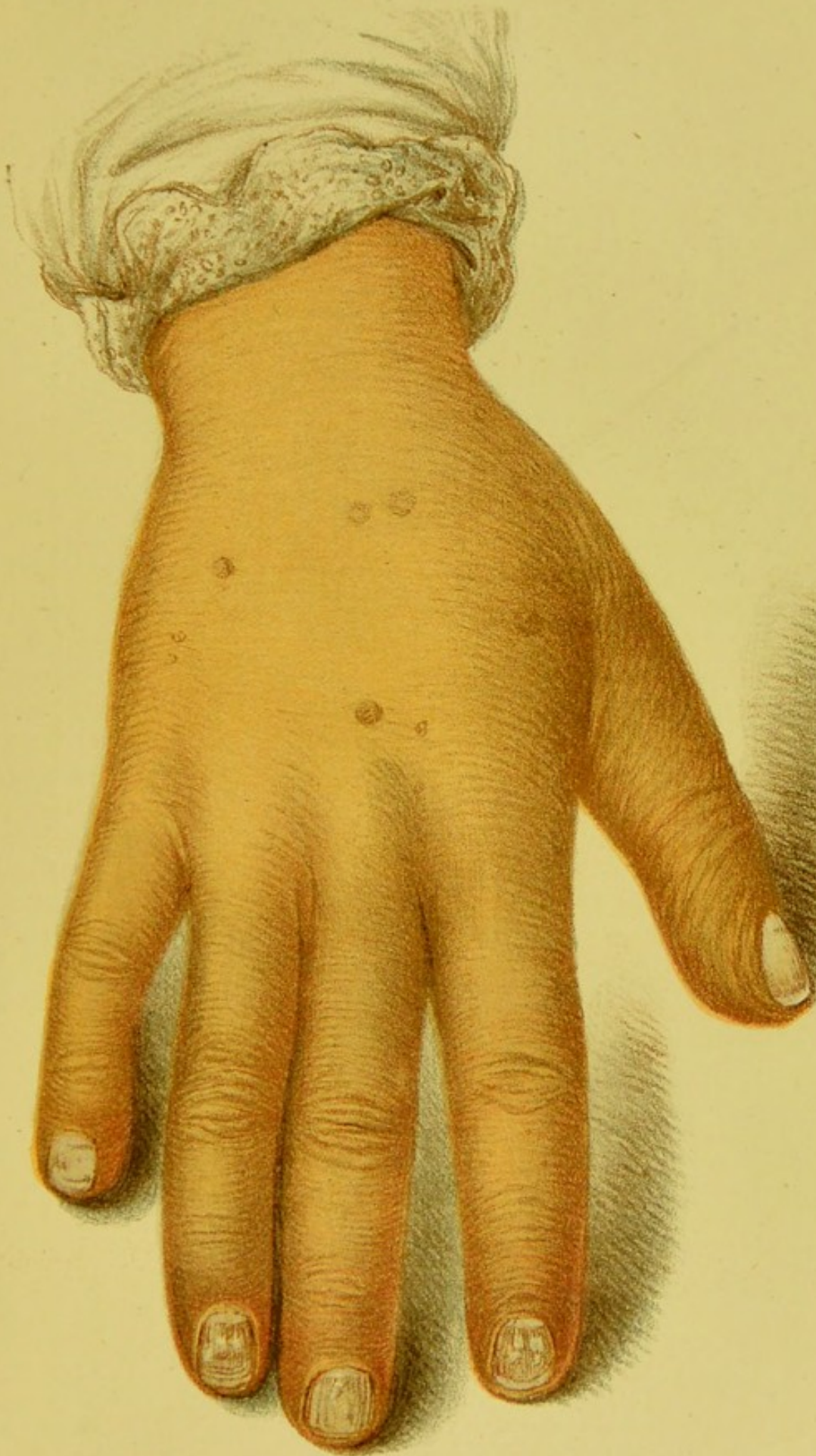


## PLATE XXXII.


### ACRO-ASPHYXIA (RAYNAUD'S PHENOMENA)



IN this portrait is shown the hand of a young lady who suffered habitually from a very feeble circulation. Whenever she was exposed to any degree of cold, her hands became livid, and would remain so for days together. The degree of blueness has hardly been sufficiently marked by the artist, since on the day on which the portrait was taken they were not at their worst. On several occasions I saw the hands so livid as to suggest anxiety lest gangrene might occur. None was, however, ever produced. This condition may be regarded as the simplest, most common, and least severe of the forms of what is known as Raynaud's Disease. Its main feature is a lifelong, and constantly present, excess of susceptibility to the influence of cold, with the result, not of pallor (*digiti mortui*), but of asphyxia and blueness. These cases differ from the forms in which Acro-sphacelus is threatened in that paroxysmal exacerbations are far less marked. The liability is a constant one, and, having once been developed, usually persists through life.









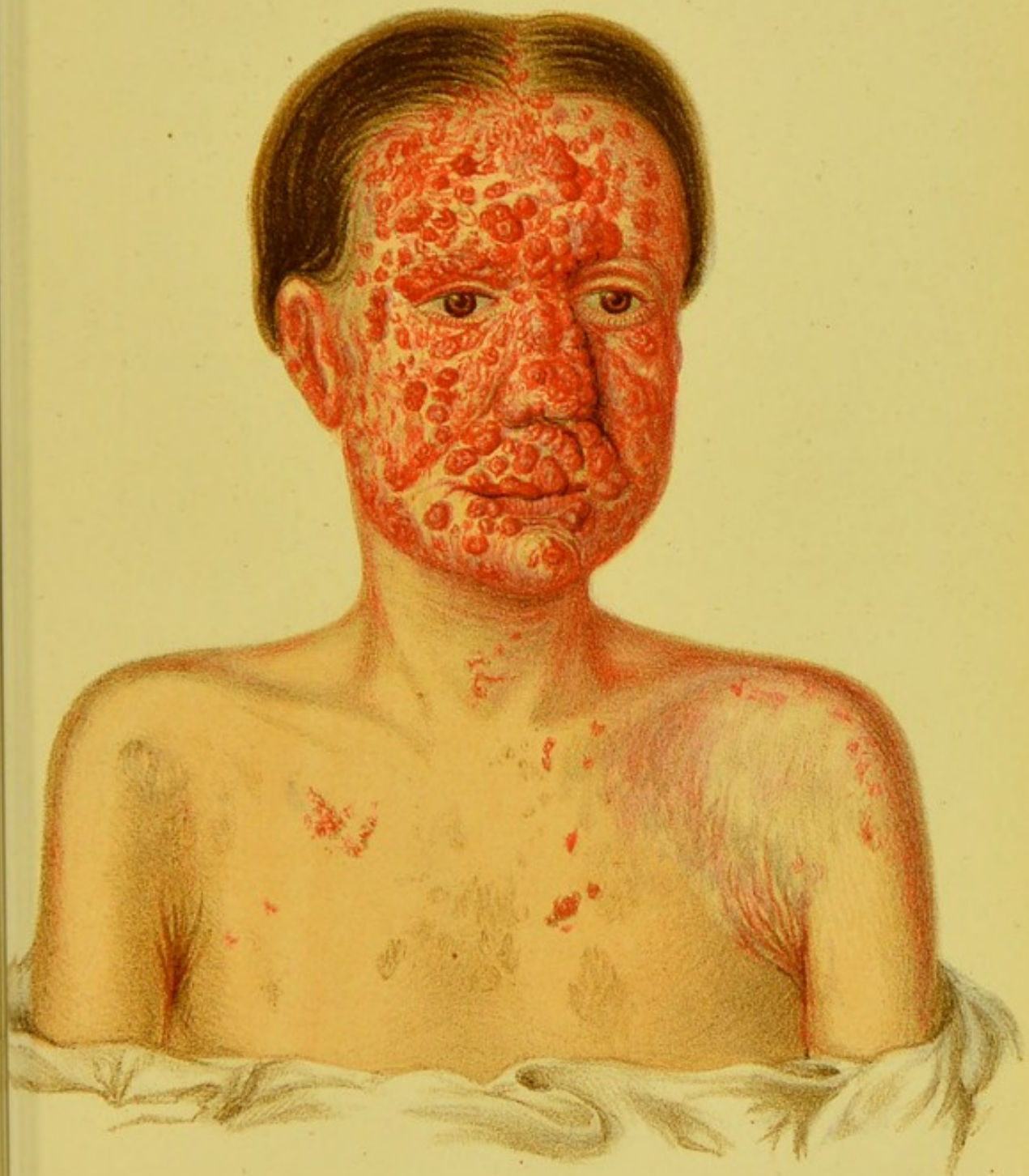
## PLATE XXXIII.


### TUBERCULAR SYPHILITIC LUPUS.


---

THIS portrait exhibits the condition which was present in a woman who was under my care in the London Hospital, suffering from tertiary syphilis. It is a good example of the tubercular form of syphilitic lupus. That it was really syphilitic was proved by its complete disappearance under specific treatment. It will be seen that on the chest and fronts of shoulders there were large areas of superficial scar; and after the cure was complete the patient's face was left in a similar condition. The whole of the face as seen in the portrait was covered with elevated, tuberculous masses. These were of very various sizes, and in many instances had become confluent. They differed only from those of true lupus in that they presented none of the brownish semitransparent material to which the term "apple-jelly" is appropriate. The occurrence of the disease in scattered patches on the chest, and the completeness of its cure in many of them, were also features which strongly suggest a diagnosis of syphilis.

I do not see any reason for attempting to avoid the expression "syphilitic lupus." In the late stages of syphilis we undoubtedly meet with a great number of cases of lupus-like affections of the skin in which it is very difficult indeed to determine whether the disease is of specific origin or not. There are of course minor features of difference which aid the diagnosis, but not unfrequently the history of the case is what we have chiefly to rely upon. All the different forms of lupus vulgaris and lupus erythematosus may in turn be simulated. The most frequent is the serpiginous form, which creeps at the edge and heals in the centre, and to which the old name of "horse-shoe sore" is applicable. The portrait here given is not of that form, but of a much less common one. It corresponds to certain cases of lupus vulgaris, also not very common, in which numerous isolated patches or tubercles are produced. These are chiefly of the nature of satellites, as regards the parent one, and they in turn are productive of others. It was to this form, among the older nosologists, that the term "tubercular lupus" was applicable.







## PLATE XXXIV.

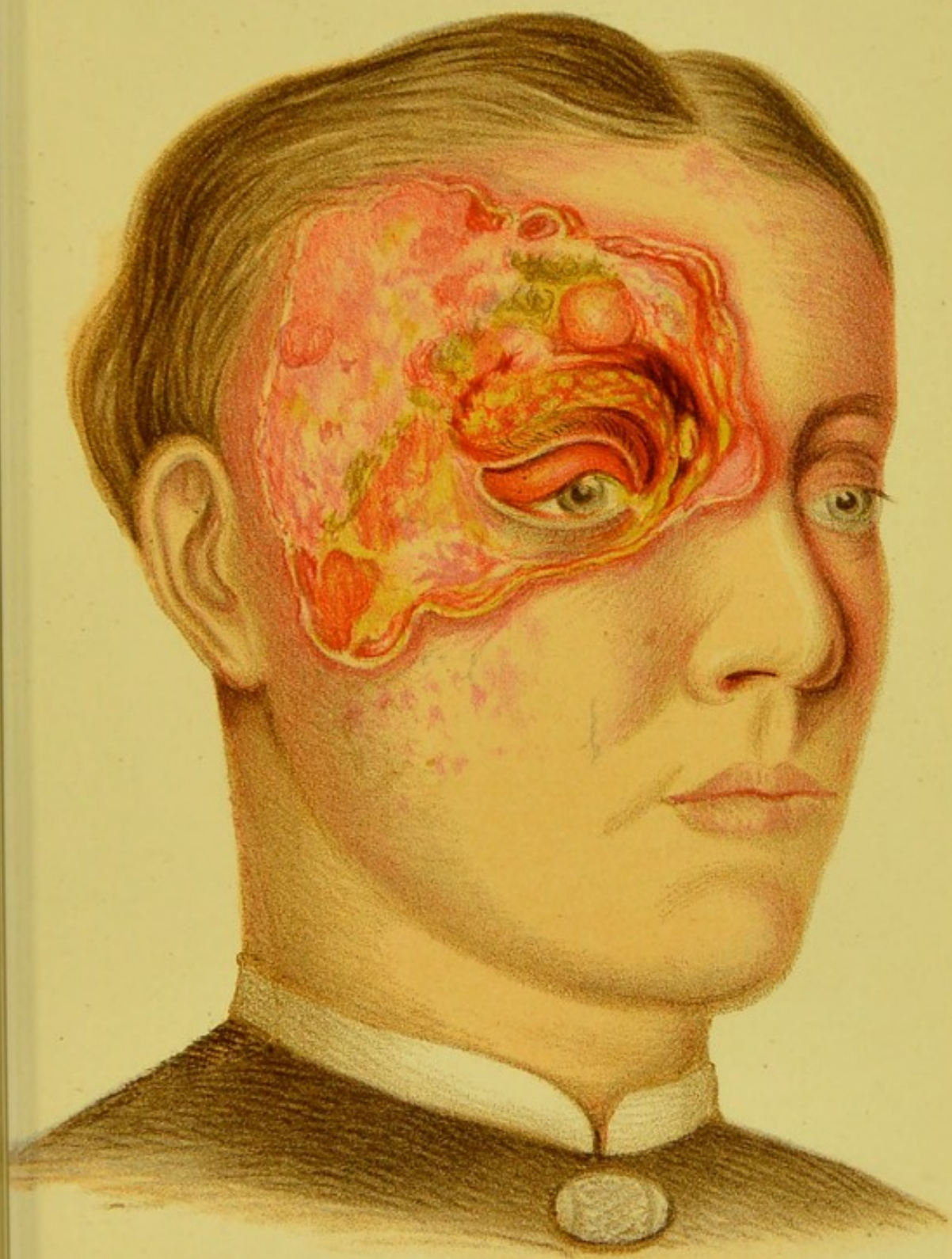
### SUPERFICIAL RODENT CANCER.


—◆—


THIS portrait exhibits the condition produced by rodent epithelioma when it travels superficially over a large extent of surface, and nowhere shows any tendency to grow deeply. A large part of the temporal, frontal, and nasal regions are seen to be involved. Attention is to be particularly given to the character of its edge, which is a sinuous, elevated roll, everywhere alike. A careful inspection of the peculiar characters of this narrow, wavy border will, in almost all cases, enable the observer to make a correct diagnosis of rodent ulcer.

It will be noticed that not only is there no deep ulceration anywhere, but that there is no development of papillary growths or granulation-masses. The disease consists simply of the narrow "rolled" edge, which is steadily aggressive, and disorganises the skin, but leaves an ulcer which may soon cicatrise behind it. These extremely superficial conditions are exceptional in rodent cancer, and in all cases they are probably only temporary. Sooner or later the disease tends to pass more deeply. Nor is the absence of tendency to fungate and develop papillary excrescences by any means constant. In the present instance the patient was a woman of about thirty-five, much younger than the ordinary subjects of rodent. The disease had been in progress six or seven years.

In the Clinical Museum there are several portraits placed side by side with the original of this one. One of the most remarkable of these was given me by the late Mr. Cæsar Hawkins. Another was taken for me recently by Mr. Swainson from an old man in the Kensington Workhouse.









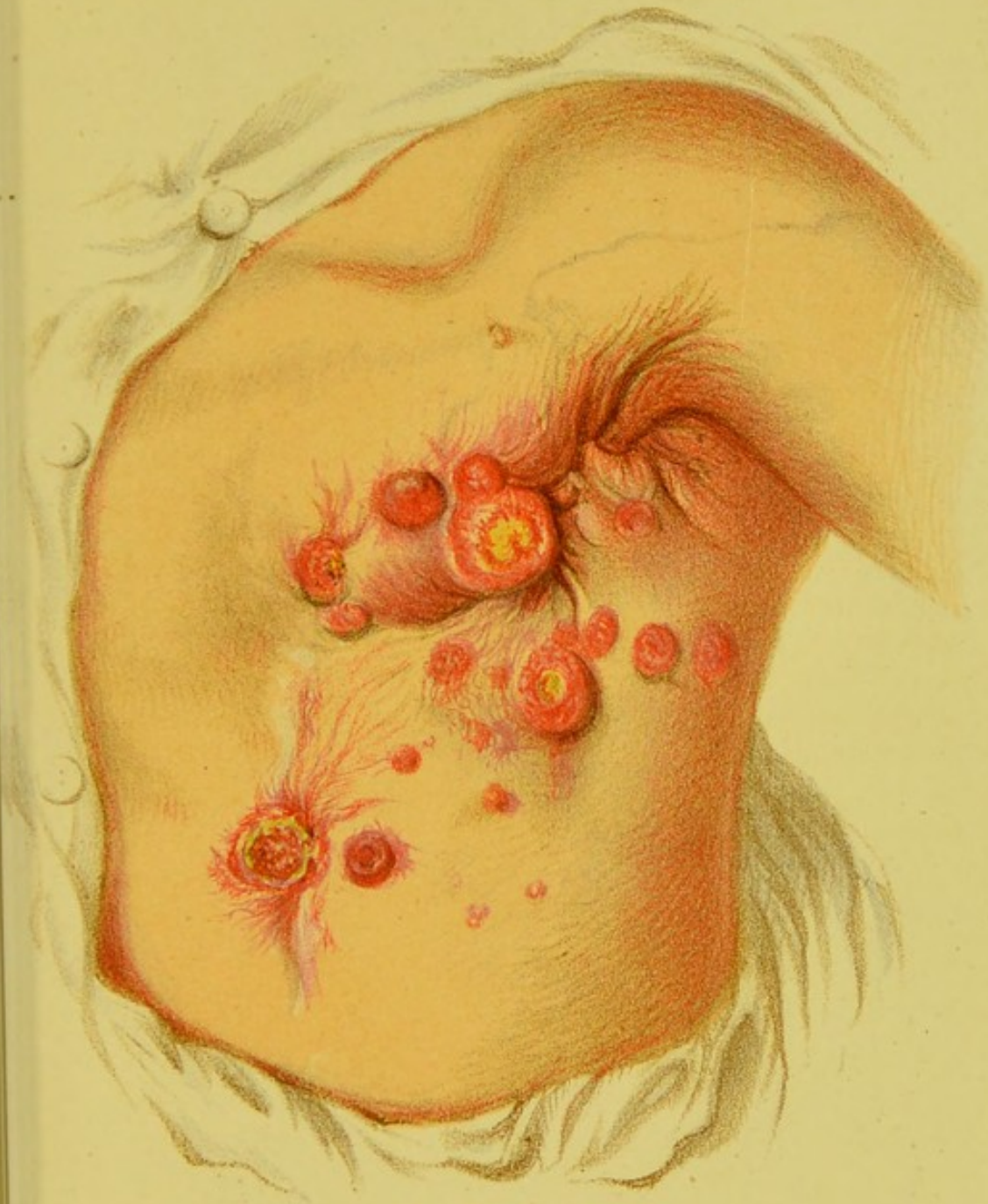
## PLATE XXXV.


### RECURRED SCIRRHUS IN PECTORAL REGION.




IN this Plate are shown the conditions produced by a return of scirrhous cancer of the skin after excision of the breast. It will be seen that there are a number of ulcerated nodules adjacent to the scar. These are scattered somewhat irregularly, and there is no general infiltration of the integument, such as is known under the term "Scirrhous en cuirasse."

The patient was an elderly woman, whose breast had been excised many years previously.







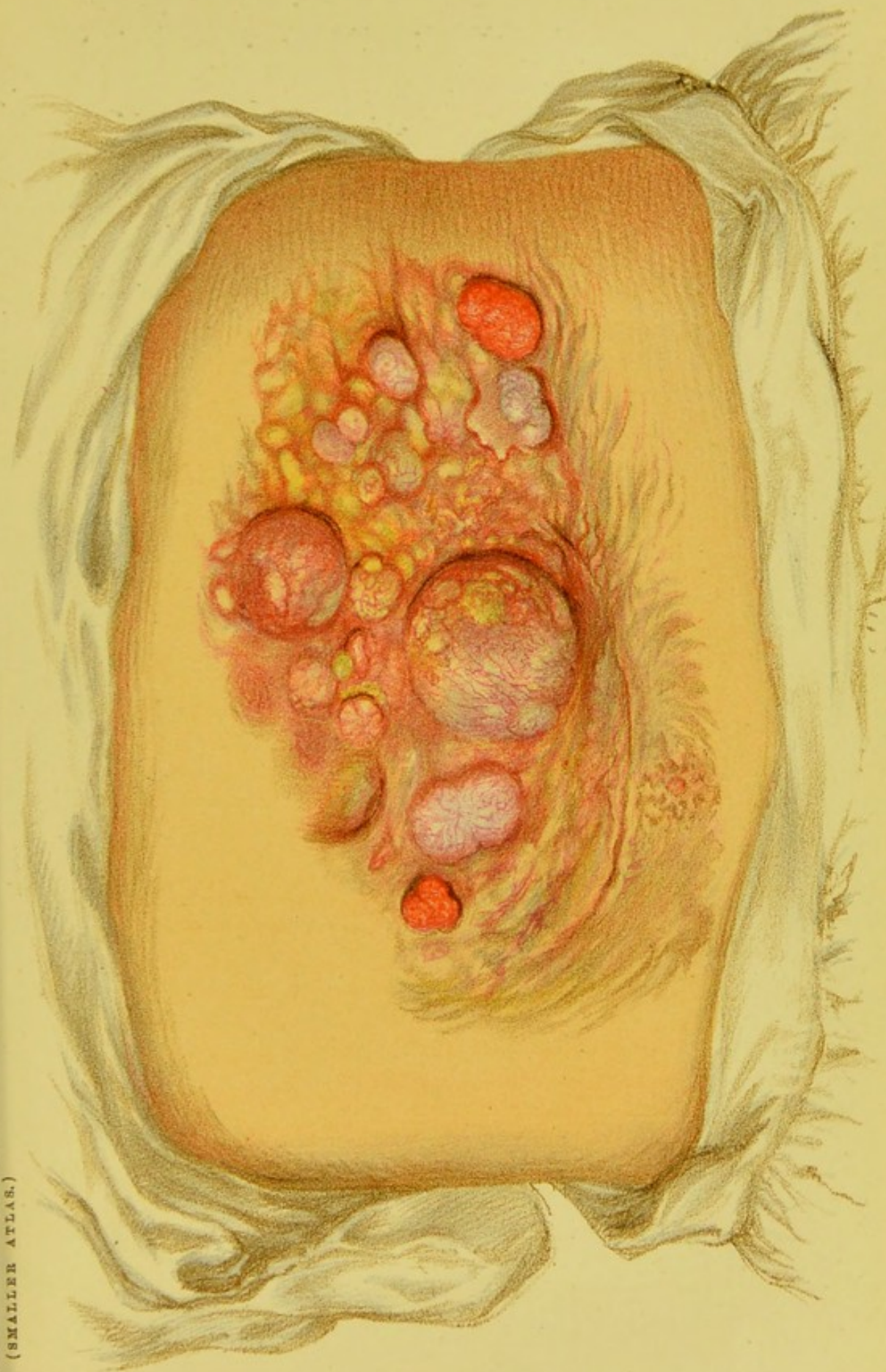
## PLATE XXXVI.

### PRIMARY SARCOMA OF SKIN.

(THE THELAN GROUP).


---


THIS portrait is given as a good example of a group of cases in which the external appearances are always very similar, and in which also the clinical history is often much the same. The cases are rare. The subject of the case is a woman now aged 52 (1895), and in whom the growths began at the age of 30. The portrait from which the lithograph is copied was taken in 1885. During the ten years which have passed since, the tumours in the skin have continued to grow and to increase in number. There has been no further evidence of malignancy, and the patient still enjoys fairly good health. There has never been any implication of lymphatic glands. The characteristic features are fairly well shown in the drawing. The tumours, which are developed in a group, vary in size from a pea to a cherry. They project strongly, and have a tendency to become slightly pedunculated. They show very little tendency to ulcerate, and are for the most part smooth and glossy. When cut out the wound usually heals well. Histologically they belong to the spindle-celled sarcoma group (see 'Archives,' vol. iii., page 192; see also a paper by Mr. Thomas Smith in the St. Bartholomew's Hospital Reports for 1892).



West, Neuman chromo.

(SMALLER ATLAS.)







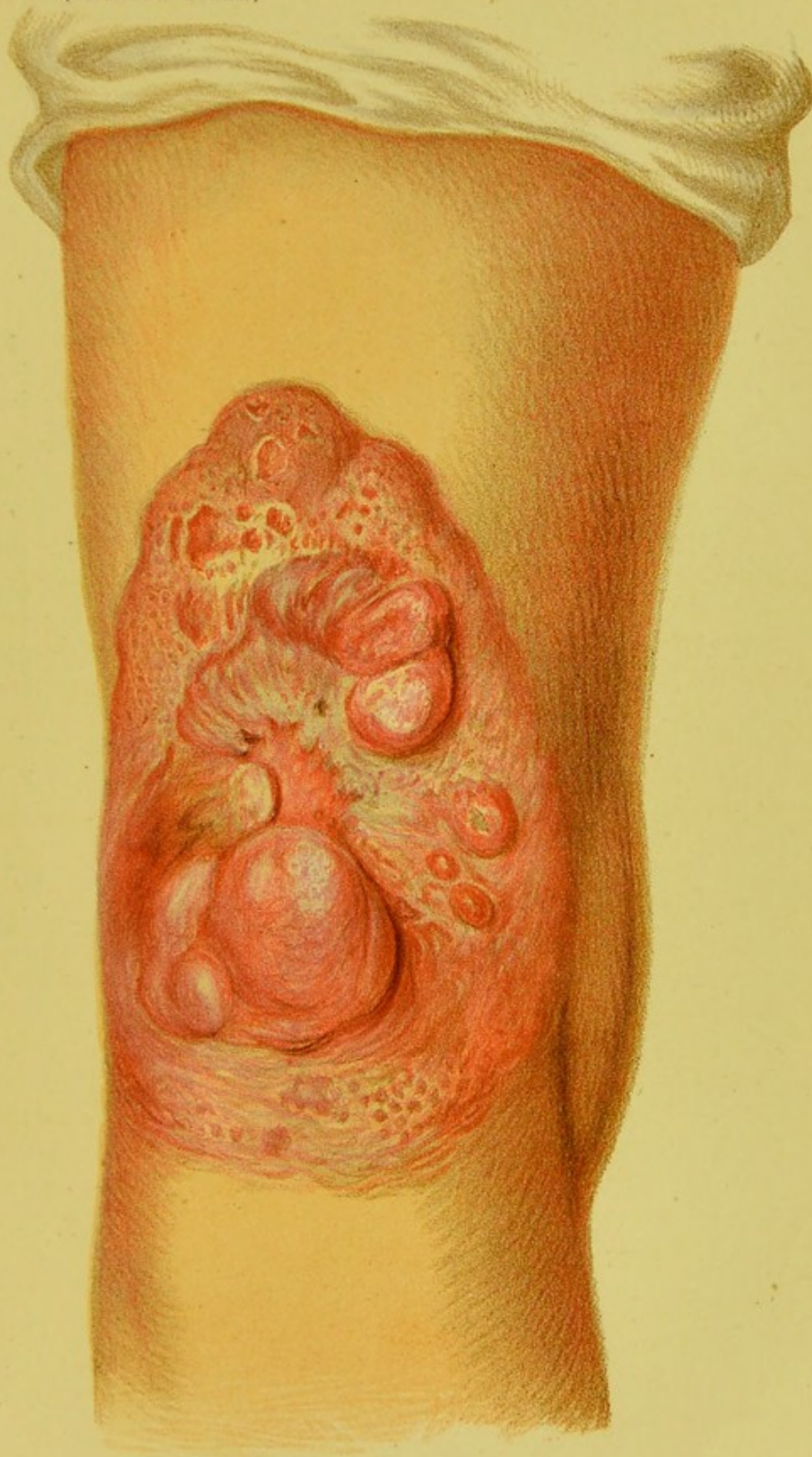## PLATE XXXVII.


### PRIMARY SARCOMA OF THE SKIN. (THE HAMILTON GROUP).




IN this portrait the conditions are very similar to those shown in Plate XXXVI. The disease was, however, of a more acute type. It had recurred repeatedly after most free excisions. In its later stages the tubers grew rapidly, and were liable to fungate and bleed. The patient was a gentleman about 54 years of age at the time of his death, and the whole duration of his disease had been seven years. As in the preceding case, there was no tendency to gland disease, and no internal growths were produced. Six operations had been performed by Mr. James Adams, Sir James Paget, and myself. In its earlier stages the growth was considered to be a spindle-celled sarcoma, but in its later ones the disease partook rather of the characters of the round-celled form. Death was finally caused by exhaustion from bleeding and discharges.

I have notes of three cases in which the disease, as in the subject of the preceding Plate, had lasted in a quiet form through many years, and did not seem to threaten the patient's life (the "Thelan" group). I have also the notes of three others, which resemble rather the subject of the present case in tendency to rapid growth, early recurrence after removal, and death of the patient in about seven years (the "Hamilton" group). All the cases were remarkably similar as regards external appearances. They are clearly all closely allied, differing only as regards the tendency to more or less rapid growth. They constitute a very well-marked group and offer definite differences from all other forms of sarcoma of the skin.







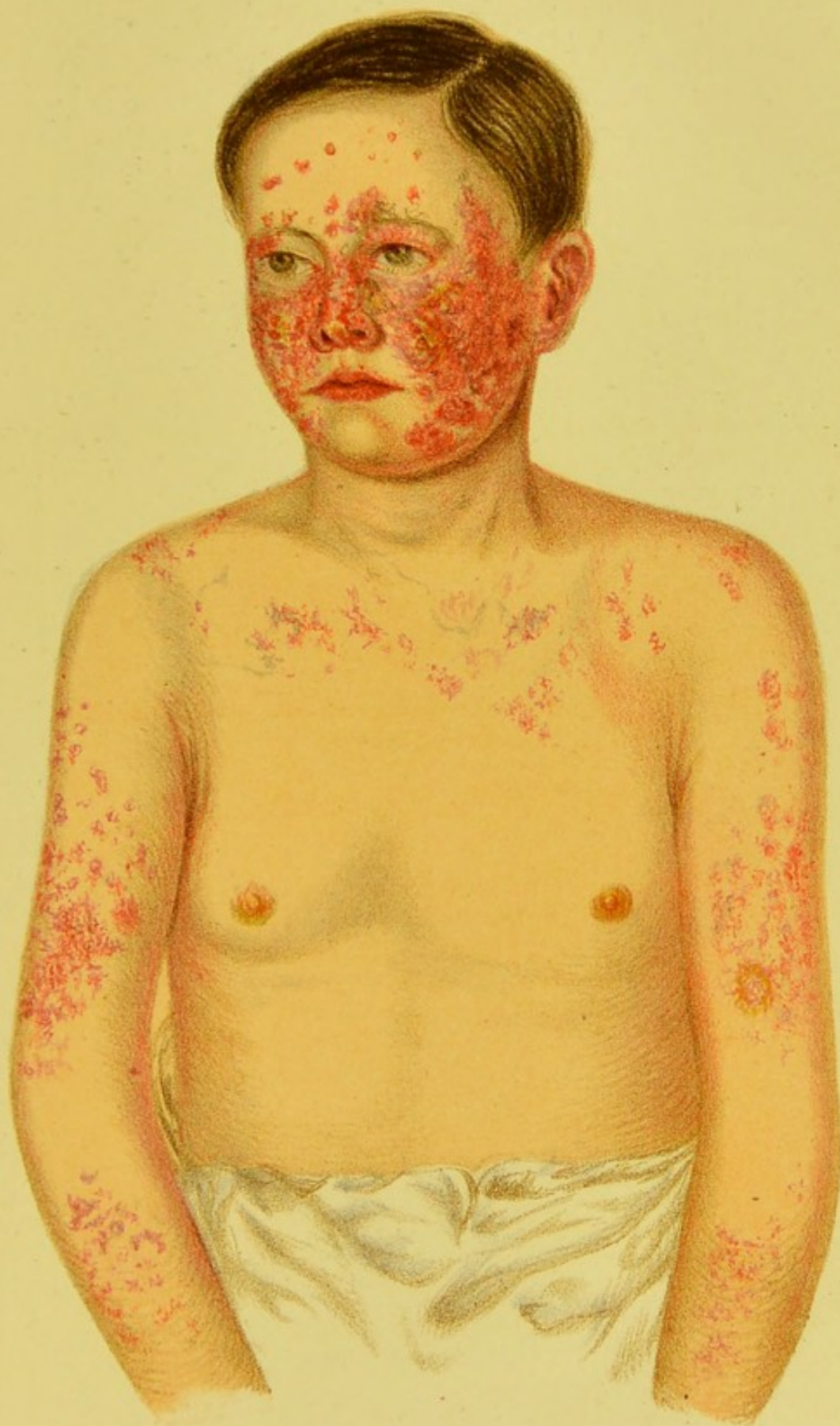## PLATE XXXVIII.


### LUPUS ERYTHEMATOSUS BECOMING GENERAL.

---

THIS portrait is copied from a drawing lent to me by Dr. Stephen Mackenzie. The particulars of the case will be found in full detail in the 'Clinical Society's Transactions,' vol. xv., page 252. The portrait illustrates the peculiar form of lupus erythematosus in which the eruption, in addition to symmetrical bats'-wings on the nose and cheeks, tends to become universal, affecting the limbs and trunk also. Although I have used the word universal, it is seldom until a very late stage that the trunk itself is attacked, the disease still showing marked preference for the exposed parts. In all cases of lupus erythematosus of this type, the upper part of the chest immediately beneath the clavicles is a region on which patches appear early. It will be seen that this part is especially affected in the present case, whilst the lower part of the chest and the whole of the abdomen are quite free. It is a not improbable suggestion that the disease is mainly located by exposure to sun, air, and cold. No one can look at this portrait without, so far as the regions attacked are concerned, being forcibly reminded of Kaposi's disease, xeroderma pigmentosum. Dr. Mackenzie's patient was a boy, aged 19. He had been liable to chilblains, but had otherwise enjoyed good health. The eruption began on the face at the age of 16, and subsequently spread over almost the whole surface. It was attended by the formation of the characteristic discs which left dull reddish scars. It was abundant on the buttocks. It is one of the most remarkable examples of universal extension of lupus erythematosus with which I am acquainted, and probably affords a good instance of a connecting-link between that malady and psoriasis. Whilst the boy was in the hospital, he had an attack of erysipelas, and was very ill. From this he entirely recovered, and the eruption was much improved. Dr. Mackenzie informs me that he died, a few years after the portrait was taken, at his own home—it is believed, of fever.

At pages 107 and 100, 'Archives,' vol. ii., will be found references to other cases of lupus erythematosus affecting the trunk.





1872

1873

The first thing I noticed when I stepped  
out of the train was a sense of relief  
and freedom. The air was fresh and  
the sun was shining brightly. I had  
been waiting for this moment for so  
long. The people around me were  
friendly and welcoming. I felt like  
I had found a new home. The  
scenery was beautiful and I was  
in good luck. The weather was  
just what I needed. I was  
in luck. The people were  
friendly and welcoming. I felt  
like I had found a new home.

I had been waiting for this moment  
for so long. The people around me  
were friendly and welcoming. I  
felt like I had found a new home.  
The scenery was beautiful and I  
was in good luck. The weather  
was just what I needed. I was  
in luck. The people were  
friendly and welcoming. I felt  
like I had found a new home.



## PLATE XXXIX.

### OCCIPITAL MENINGOCELE.





THIS portrait, which is copied from a drawing given me by Dr. Roddick, of Montreal, shows the head of a child who was the subject of an occipital meningocele. It may be suitably compared with one which I have published as Plate XLV. in my 'Illustrations of Clinical Surgery.' In my case, in which I removed the tumour very unwillingly, I was fortunate enough to find the canal of communication between the cyst and the meninges quite obliterated, and the patient recovered. Traces of the obliterated canal were, however, easily seen in the pedicle of the tumour, and I had to thank my good fortune for the favourable result. In Dr. Roddick's case the canal was still open, and a fatal result from meningitis followed the operation. The occipital bone, as removed at the autopsy, is shown below. It will be seen that the opening communicating with the skull was separated from the foramen magnum by a bony ridge. In many cases the separation is only by ligament.

A successful case of the removal of a tumour of this kind, very similar to my own, is published in the 'Medico-Chirurgical Transactions' by Mr. Solly. The great point in diagnosis is, of course, to make quite sure that the tumour receives no impulse when the child cries, or otherwise makes a forcible expiration. Unless this can be proved beyond doubt, all operations are very dangerous. Even the strictest antiseptic measures cannot be trusted in these cases.

(This case is briefly mentioned in Trans. Path. Society, vol. xxxi., page 333.)





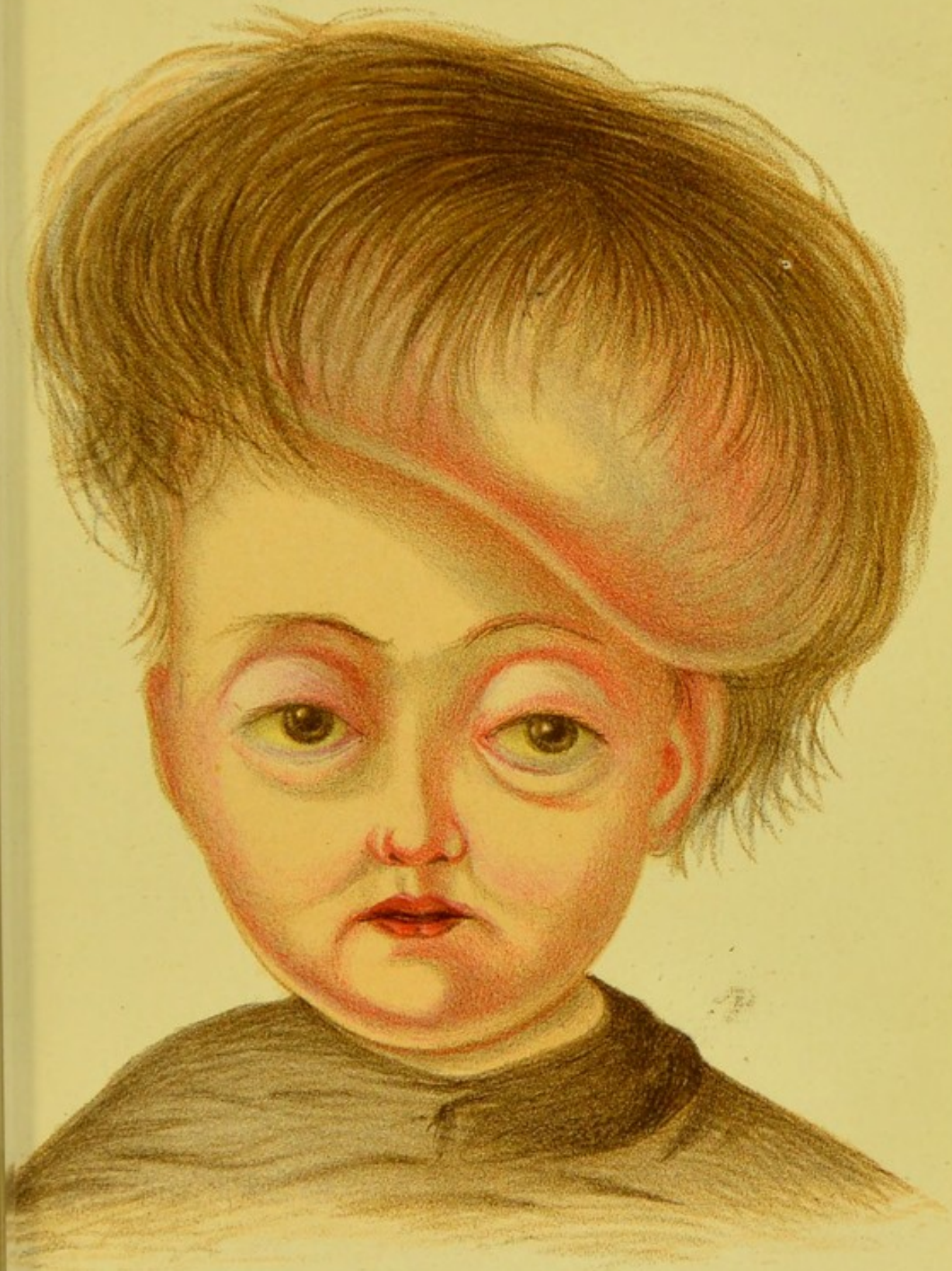


## PLATE XL.

### MICROCEPHALUS, FOLLOWED BY HYDROCEPHALUS AND BULGING OF THE BRAIN THROUGH THE SKULL.

---

THIS portrait illustrates a most extraordinary case, in which microcephalus was followed by the development of chronic hydrocephalus. Such at least is my explanation of the conditions which occurred. The case is recorded in the *Trans. Clin. Society*, vol. ix., with a supplement at page 359, vol. xxii. I first saw the child in October, 1871, when six months old. Its face was small, eyeballs prominent, and there was a large hemispherical bulging in the middle of the forehead. This had been present at birth. When I saw it, the swelling was hard and covered with bone. The rest of the skull was small. The child was moderately intelligent. Four years later the bone over this region had been to a great extent absorbed, and a large, bulging, soft mass was present. It appeared as if the child's brain was growing through its skull, in consequence of the non-expansion of the latter. Some years later still, the conditions shown in the portrait had been produced. It still appeared as if the skull-bones had been incapable of expansion, and the brain and its meninges had bulged through. The orbits were very shallow, and the eyeballs occasionally became dislocated. A few years later still the child died, in consequence of an operation. I had always resisted the desire of the patient's parents that something should be attempted by the knife, and after I had watched the case for about ten years, a bolder surgeon was consulted. The incisions made at the operation disclosed, I believe, the conditions which I had suspected. The overhanging scalp contained brain matter, and some, but not much, hydrocephalic fluid. No post-mortem was obtained. The case is, so far as my knowledge extends, unique. A discussion upon it will be found in the '*Lancet*,' Oct. 30th, 1875.





## PLATE XLI.

---

### RECURRED INFLAMMATION IN THE SITES OF CHANCRES.

FIG. 1.—The upper figure in this Plate shows the arm of a gentleman who had chancres from vaccination. The appearances exhibited, however, are not those of the chancres themselves, but of conditions which occurred about the scars four years later. They are of interest as examples of recurrence of disease at the site of a former infection. The chancres had in the first instance disappeared quickly under treatment by mercury, and nothing peculiar remained in their scars. After about four years of good health, two of the chancre-scars again inflamed, and the conditions resulted which are shown in this portrait. There was slight redness and thickening. The process was rather slow in development, and suggested the formation of a lupus patch. Under specific treatment internally and locally, all trace of the recurred disease disappeared rapidly and completely. The patient has since enjoyed good health. He is married, and the father of a healthy family. The vaccination was in February of 1871.

The recurrence of disease in the site of chancres which have long ago been cured is, I am sure, not very uncommon, and it illustrates a most important law in reference to the natural history of syphilis. I may add to the above narrative that the father of the young man who was the subject of this case was vaccinated at the same time as his son, and was also infected with syphilis. The vaccination was in 1871, and in 1886, after an interval of sixteen years, one of his vaccination scars became red and ulcerated. For further particulars, see my little work on 'Syphilis,' page 307. See also 'Illustrations of Clinical Surgery.'

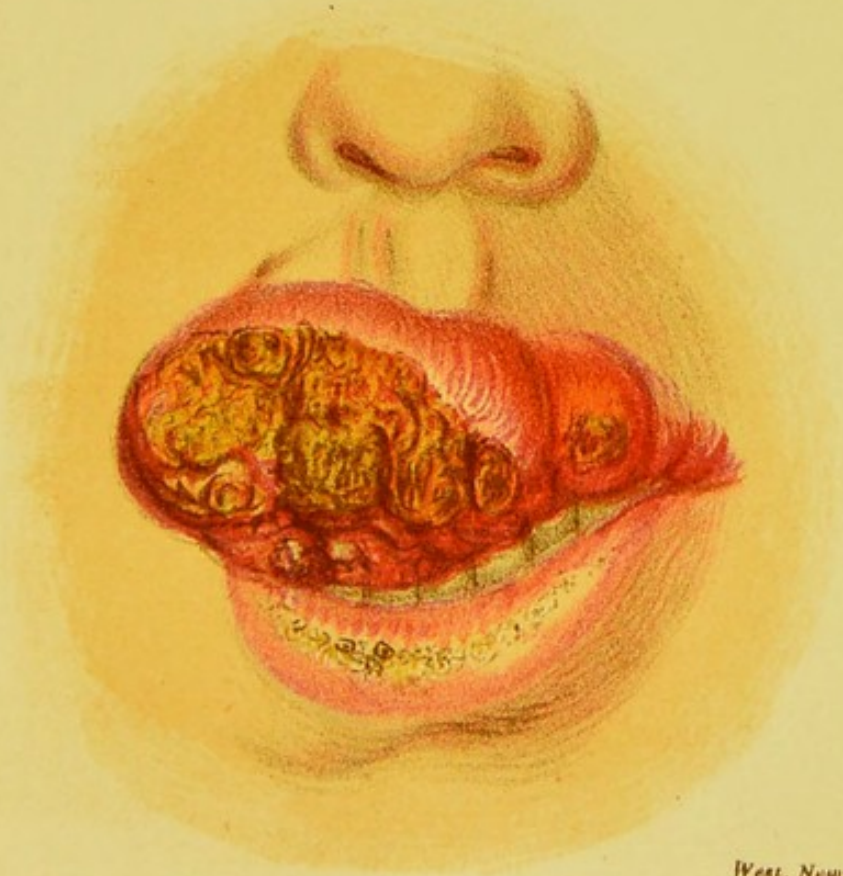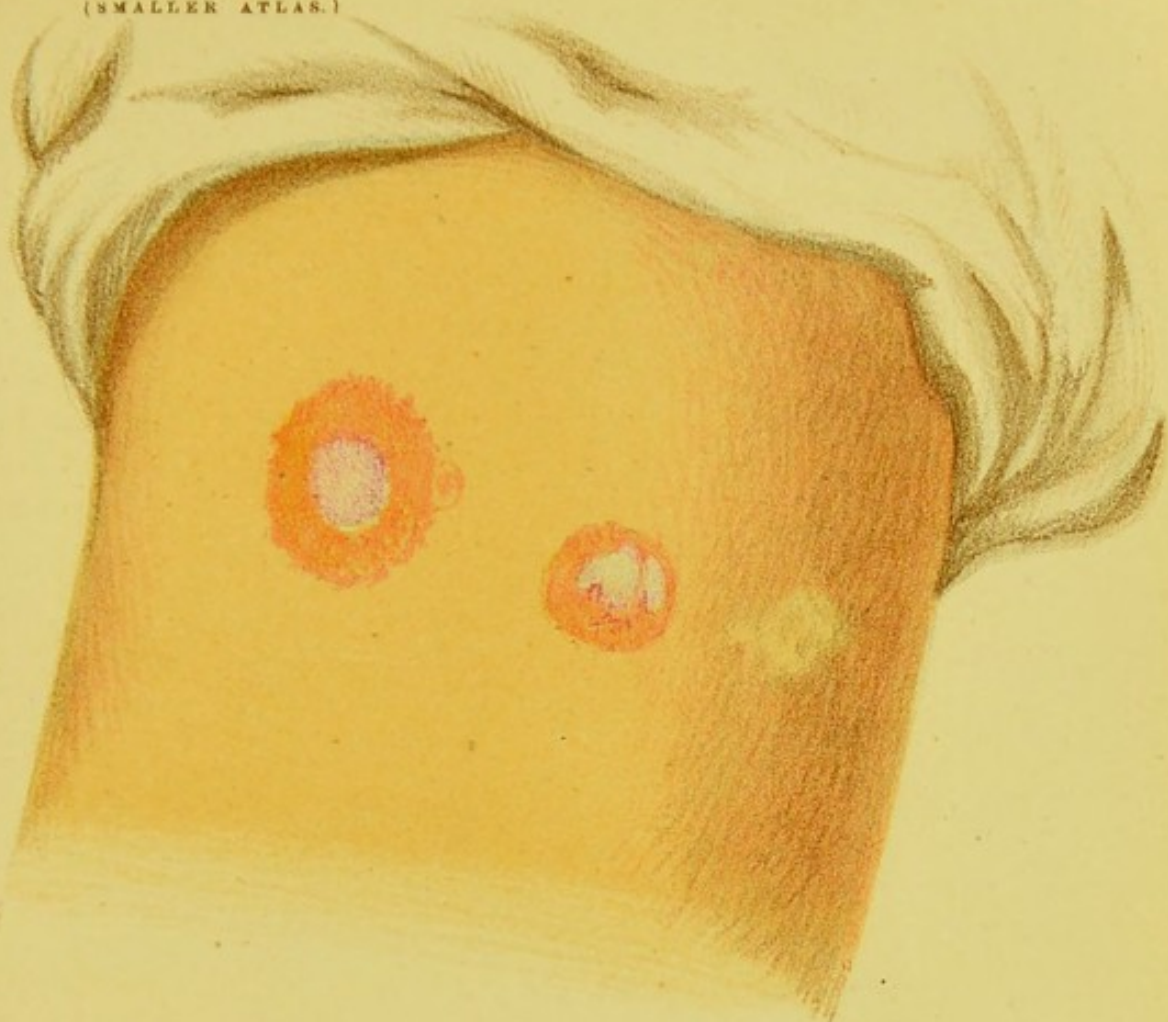
### CHANCRE OF THE LIP.


FIG. 2.—About the diagnosis of the formidable appearances here depicted there was not the slightest doubt. It was a primary chancre of unusual dimensions. The patient was a young woman




PLATE XLI. (*continued*).

from a country town, engaged, if I remember rightly, in the management of a post-office. In all probability the sore had been contracted from kissing, but as to any special exposure to risk in this way she would admit nothing. The chancre was attended by a large bubo under the jaw, and by a severe syphilitic eruption. All the symptoms disappeared as usual under treatment. I have seen many chancres on the lips, but I think this worthy of publication on account of the exaggerated swelling and induration which attended it. They were such as might very easily have led to an error in diagnosis. I have never seen a larger chancre on the lip, but I have seen one developed in the cheek at least five times as large as this. It involved almost the whole of a man's cheek in one mass of inflammatory induration. A portrait showing a chancre of unusual size near to the lip will be found in my 'Clinical Illustrations,' Plate LXXXIV.







## PLATE XLII.

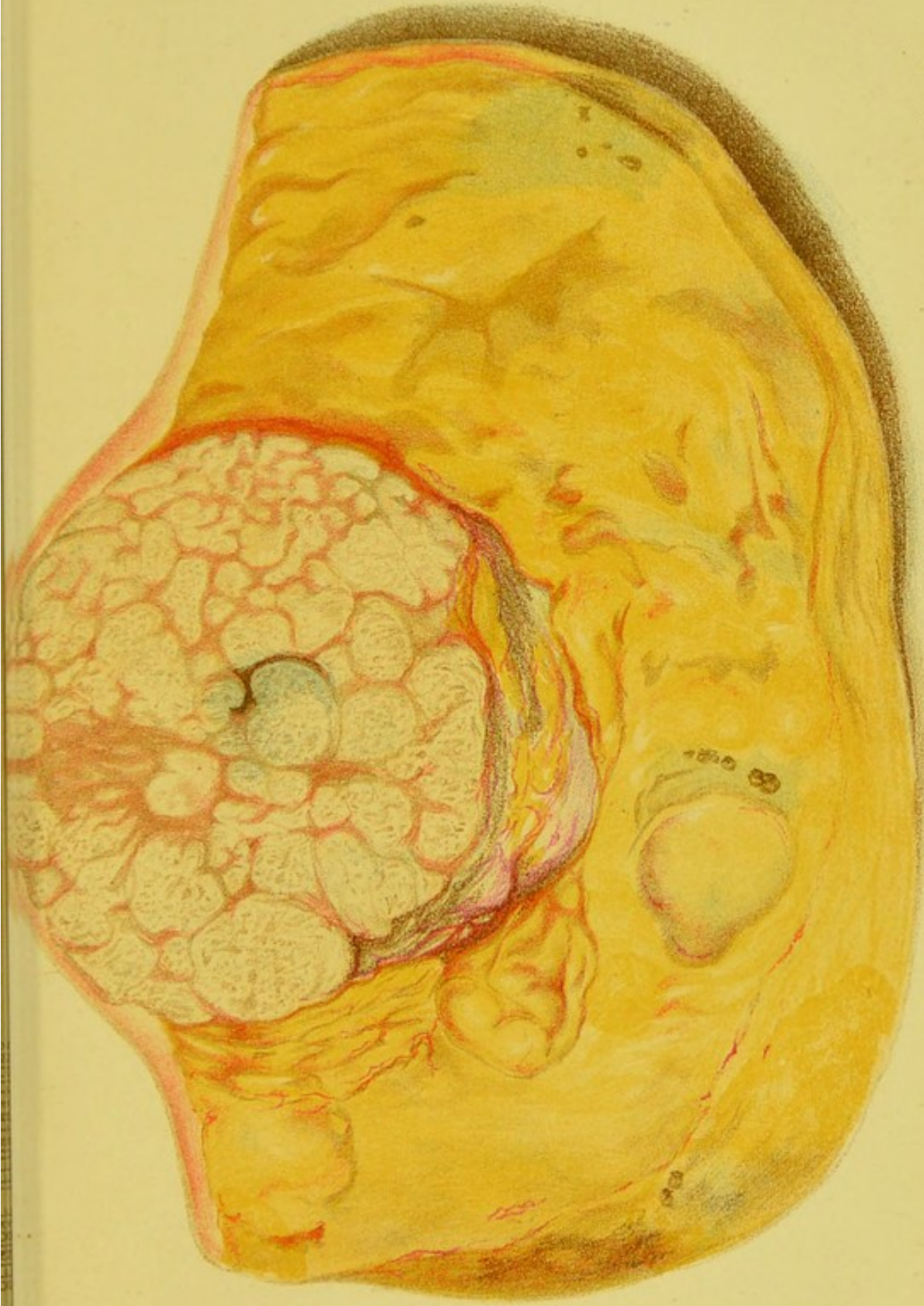
A SOFT, MUCH LOBULATED ADENOMA OF THE BREAST.




THIS portrait may serve as a fair typical illustration of a rapidly growing adenomatous tumour. It will be seen that the growth is limited, encapsuled, and almost round. It is close beneath the skin, which has been lifted by it. Its structure shows very distinctly arrangement in lobules. The section of these is chiefly of a dull white colour, but here and there stained green, and containing small mucous cysts. The breast itself has been almost entirely replaced by yellow fat, in which were many small cysts containing a greenish mucoid fluid.

The patient was a woman, aged forty-eight, under my care in the London Hospital in October, 1876. She was very stout. The growth was so soft that fluctuation was suspected.

Mr. Robert W. Parker was good enough to prepare sections for me, which well demonstrated its adenoid structure.



West. Neuman chromo.



## PLATE XLIII.

A CASE IN WHICH CONGENITAL ANGEIOMATA AND EN-  
CHONDROMATA CO-EXISTED IN THE UPPER AND  
LOWER EXTREMITIES OF THE SAME SIDE.



THIS Plate exhibits the aspect during life of a limb which may now be found as No. 410A, in the Museum of the Royal College of Surgeons. The conditions were in part congenital, but they had undergone great increase during the patient's lifetime. The limb had finally become such an encumbrance that amputation was gladly submitted to. The patient, at the time that he was under my care in the London Hospital, was a man of about forty-six and in good general health. He believed that the affected limb had been dwarfed from infancy, and that tumours had been present in his fingers and toes as long as he could remember. The right limbs only were affected. The right femur had been fractured four times, and the tibia and fibula once. In addition to the conditions shown in the portrait, there were numerous lumpy masses in the cellular tissue of the upper part of the thigh. These were left behind at the amputation, which was performed through the thigh, and they showed but little tendency to growth. The hand was to a large extent disabled by tumours which were developed partly in the cellular tissue and in part in connexion with the bones. These were probably some of them cartilaginous and some angiomatous.

I am indebted to Mr. F. Eve, then Assistant Conservator at the College of Surgeons, for a very careful report as to the nature of the growths. This report was published in detail in vol. xxxviii. of the Pathological Society's 'Transactions,' page 327. Mr. Eve found:—1st. That the swelling surrounding the ankle-joint consisted of a soft, semi-fluctuating "sarcoma." It was white, semi-diffluent, and of cartilaginous aspect. It had destroyed the ankle-joint and infiltrated its adjacent bones. This growth was probably of recent formation, or, at any rate, had undergone recent changes. 2nd. Around the phalanges of the toes were smooth tumours of bony hardness, probably ossified enchondromata. 3rd. In the head of



the tibia, and in various parts in connexion with the femur, were islands of imperfectly formed cartilage. 4th. And lastly, the most interesting fact was the demonstration of very numerous cavernous angeiomata in the cellular tissue. These had been developed chiefly in connexion with the larger veins, but they had supplying arteries. They were easily injected from the veins. They were very numerous and most of them subcutaneous. They "constituted softish rounded swellings, having much the appearance of the common subcutaneous fibrous tumour."

This case appears to me to present several features of extreme interest to the student of intra-uterine disease, and of the tendencies of congenital tissue-malformations.

1st. We have the fact that multiple enchondromata in connexion with the bones, and multiple angeiomata in connexion with the subcutaneous veins, were present at birth in the same limbs.

2ndly. That these multiple tumours were coincident with dwarfing of the affected limbs, and with brittleness of the large bones.

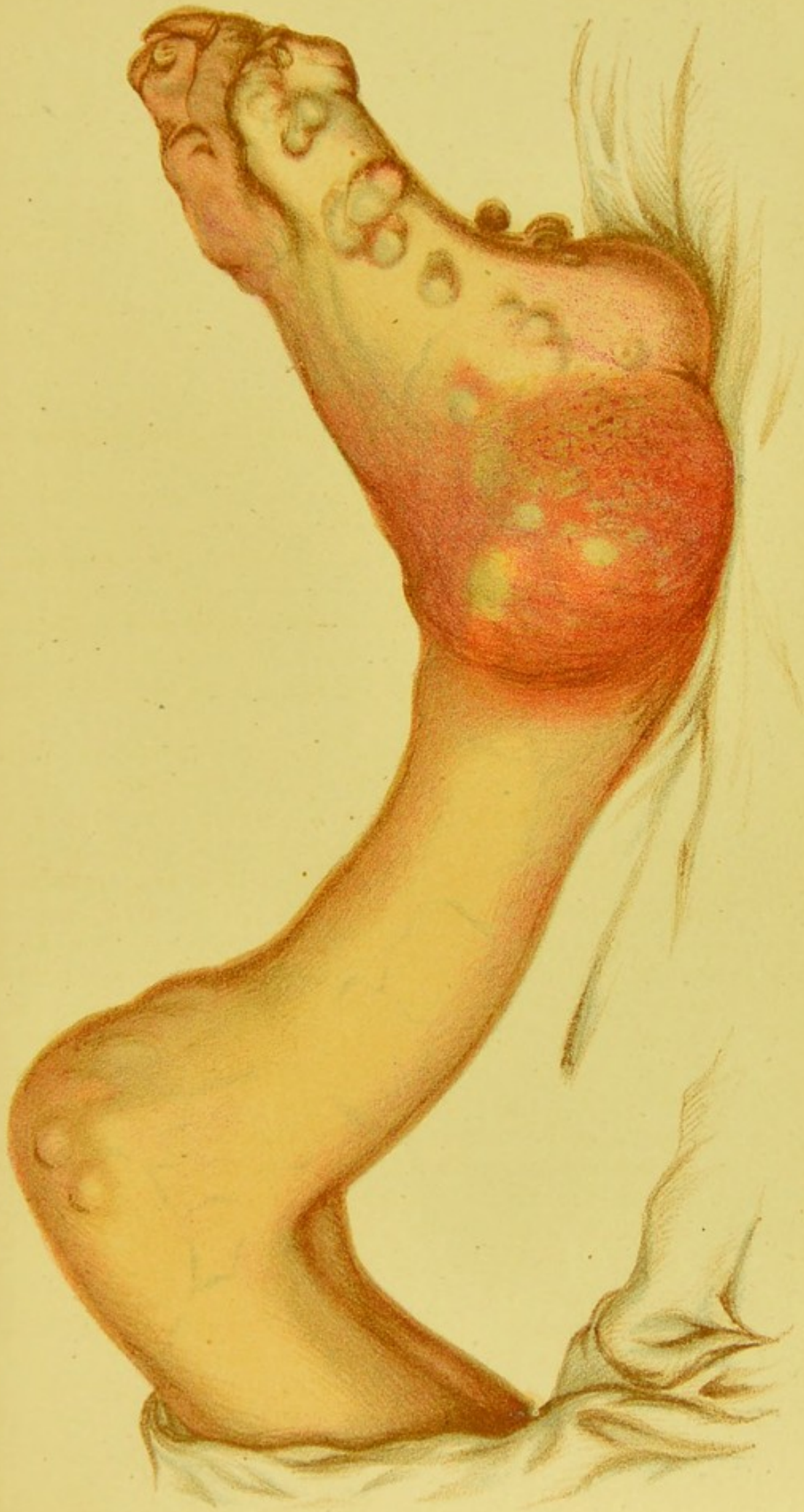3rdly. That the changes occurred in an upper and lower extremity on the same side.

4thly. The evidence of distinct tendency to growth on the part of the abnormal tissues subsequent to the patient's birth.


5thly. The assumption on the part of one or more of the growths of a sarcomatous character.


We may suitably compare the angeiomata and cartilaginous tumours with the defects in tegumentary development which are classed as moles. They are, making allowance for difference of tissue involved, of the same character, and might be designated subcutaneous moles. I have frequently asked attention to the fact that moles are often of multiform characters—thus we may see pigment moles, papillary moles, and *nævi*, all present together—and also to the additional fact that all forms of moles are liable exceptionally to take on growth in after life. Their liability to become the seat of sarcomata has long been recognised. It is, however, very rare to find moles arranged unilaterally. There are certain rare cases of congenital angeioma with hypertrophy of an entire limb, which may possibly be in some sort the parallels of this case in an exaggerated form.

I must refer the reader interested in the subject to the admirable report by Mr. Eve, from which I have quoted.



Исст. Нервная система.





## PLATE XLIV.

### LUPUS ERYTHEMATOSUS.

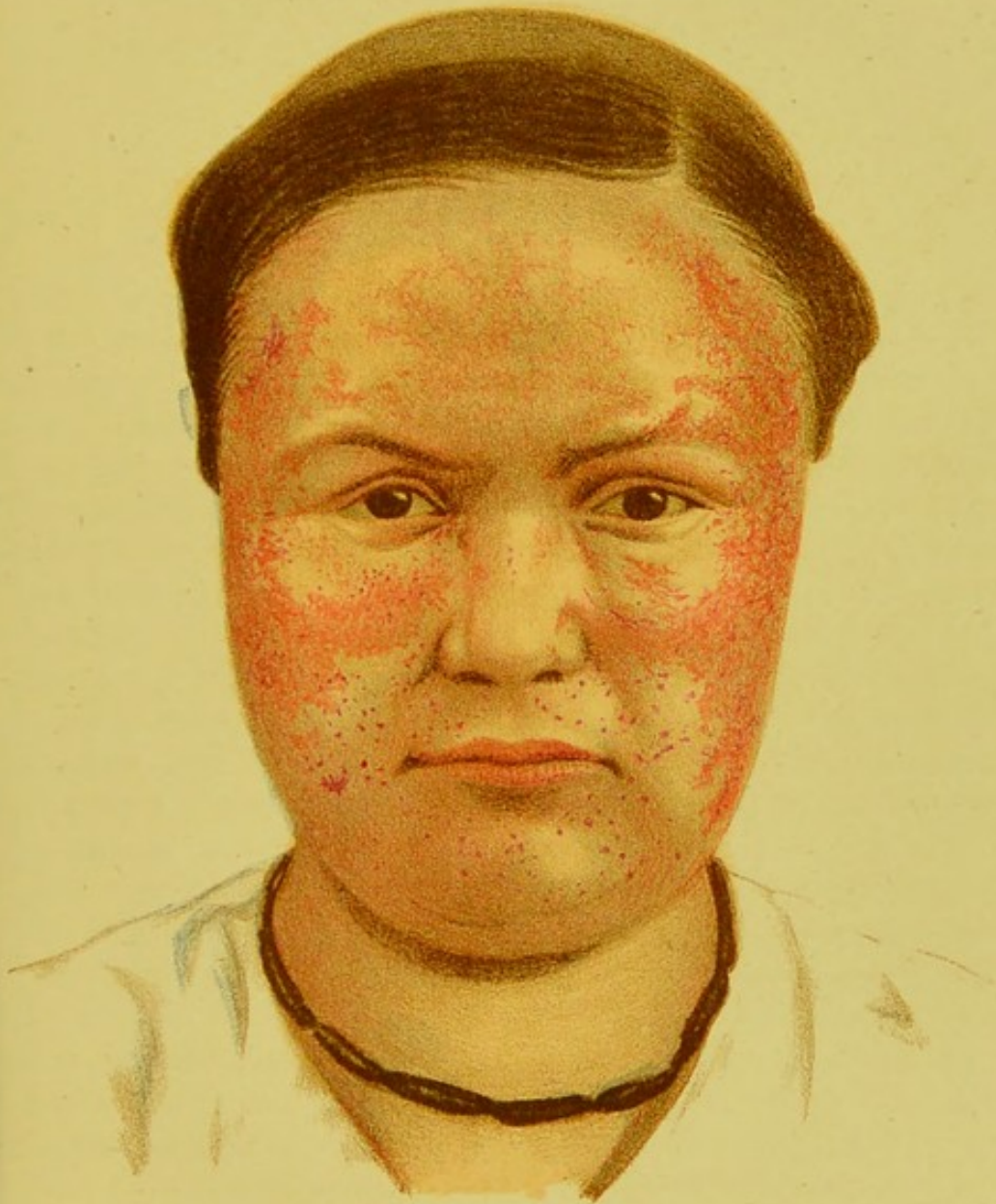(THE MOST SUPERFICIAL FORM.)




I HAVE copied this Plate from Montmeja's Atlas (photographic), because it illustrates better than any original one which I possess the most superficial and purely erythematous form of lupus erythematosus. It will be seen that almost the whole face is occupied by erythematous patches which are somewhat ill-defined, but are arranged in tolerable symmetry. With the exception that the nose itself has almost escaped, the bat's-wing, or butterfly, form is very fairly attained. It will be observed that there is no thickening of the parts affected, and nowhere any crusts. The little discs and crescents, which are so often characteristic of lupus erythematosus, are here represented by mere dots. These latter are seen to be scattered over the nose and chin.

This portrait may be suitably compared and contrasted with that given in 'Archives,' vol. iii., page 130, Plate XXXVIII., which represented a somewhat more severe form of the same malady. I am not able to give any history of this individual patient, and the portrait must stand simply for an illustration of this particular disease. Something may perhaps be inferred as to its history from the fact that it is designated by Montmeja as "Scrofulide erythémateuse."

This type of lupus erythematosus is, in my experience, one of the most serious of all, and the most difficult of cure. It is always associated with much delicacy of constitution, and often very closely with tuberculosis. The hands and other parts of the body often become affected later on in the case.





## PLATE XLV.

ICHTHYOSIS HERPETIFORMIS (NON-SYMMETRICAL).

("TIGER ICHTHYOSIS.")



THIS portrait is of great interest and value as illustrating one of the most extensive cases of ichthyosis of the non-symmetrical form which I have ever seen. Many years ago I drew attention to the occurrence of congenital streaks of pigmental patches or of papillary growths occurring on the limbs or on the body, and always definitely unilateral. The suggestion was made that they looked as if they might be the result of a sort of intra-uterine herpes zoster. I directed attention, however, prominently and especially in my Presidential Address at the Neurological Society, to the fact that these streaks do not run in the course of distribution of nerves, although they may often, on superficial examination, appear to do so. Plates I. and II. of this 'Atlas' illustrate the unilateral distribution of white streaks on the dark skin of a Hindoo. The present portrait is of special interest from the fact that the streaks, which were covered with papillary growths, black with dirt, involve almost the entire surface. Certain forms of papillary ichthyosis are diffuse and symmetrical, but careful inspection of the portrait will convince any one that, although so extensive, the disease, in this instance, has a definite tendency to non-symmetry. It is also not diffuse, but arranged in streaks. It will be seen that the right half of the child's trunk is almost free, the line of demarcation passing vertically up the front of the body and chest. The right upper arm is also free, and the right side of the forehead almost so, whilst the corresponding regions of the other side are covered with papillary streaks. This form of non-symmetrical ichthyosis differs entirely from the diffuse one in the fact that it is never a family disease. I have never, with one exception, seen more than one child in a family who was suffering from it, whereas in



PLATE XLV. (*continued*).

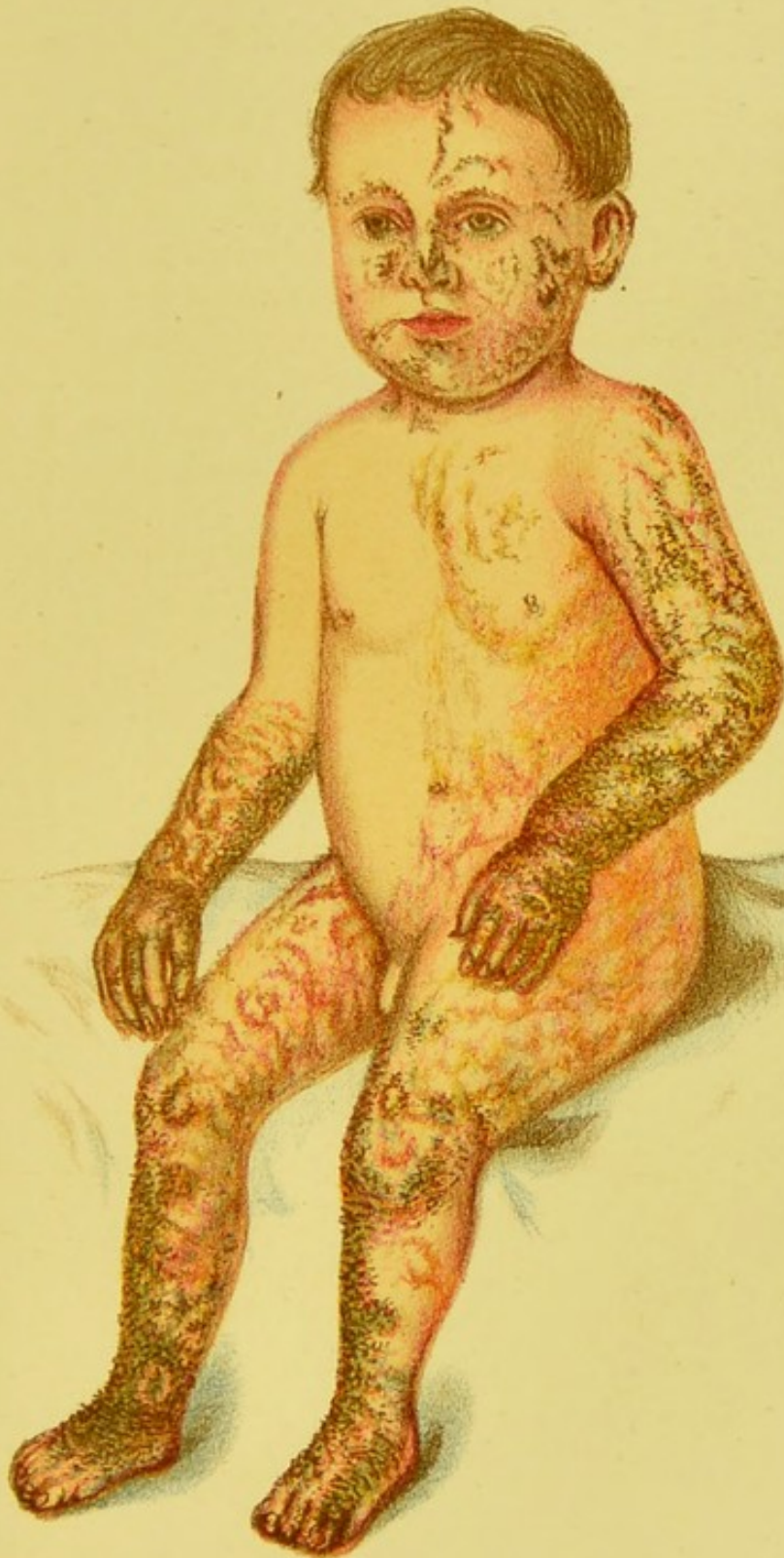common ichthyosis one-half of the family is almost invariably affected.


As regards treatment, I may remark that great benefit will be obtained by snipping away the papillary growths with a pair of scissors curved on the flat; or, should they be too small to use this procedure, by destroying them with the actual cautery.

The subject of the portrait was an infant, aged six months, who was sent to me in 1886 by Mr. E. H. Carter, of Chelmsford. The conditions had become very much more conspicuous since the infant's birth, and were still increasing. I do not think, however, that there had been any real increase in the number or size of the streaks.

There were three other children in the family, and none of them presented any peculiarity.

See descriptions of Plates I. and II.





Faint, illegible text, possibly bleed-through from the reverse side of the page.

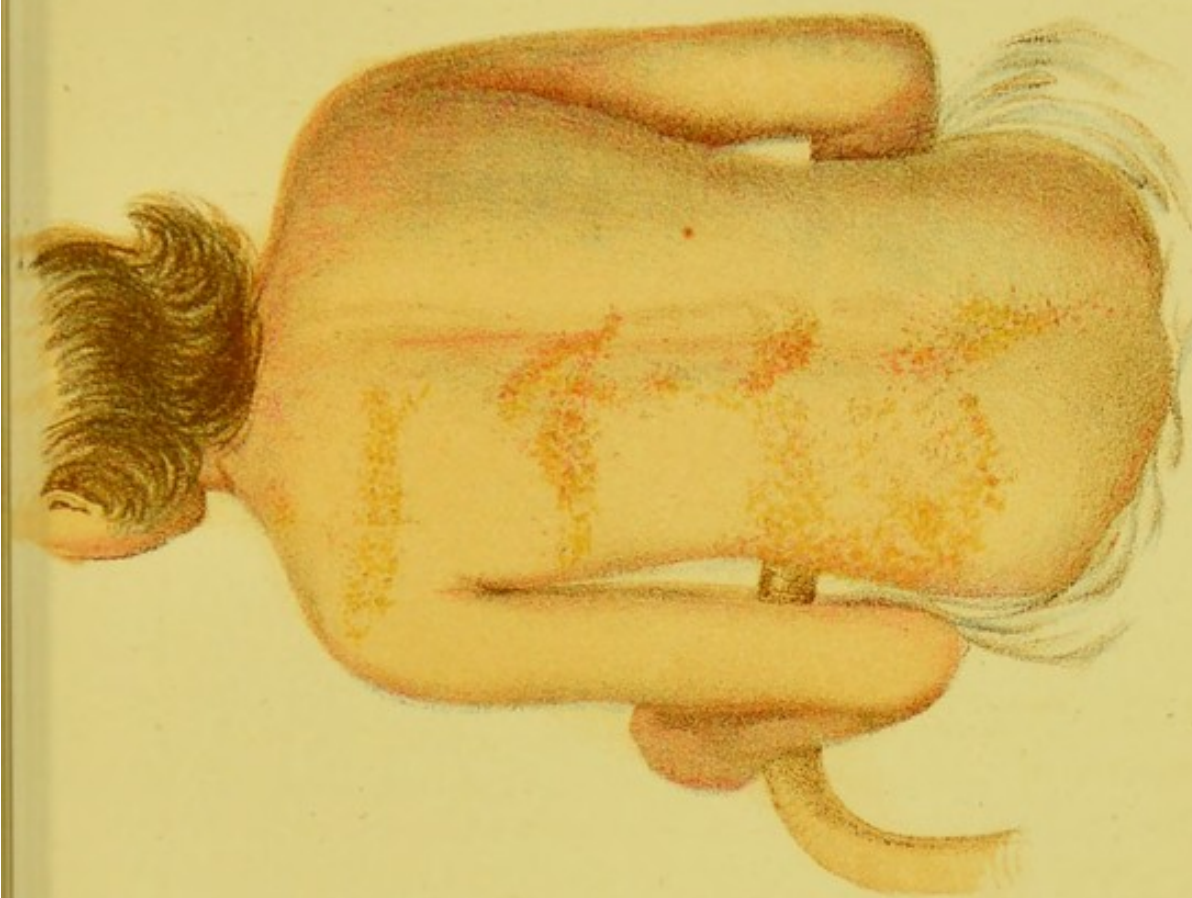
## PLATE XLVI.

### ICHTHYOSIS HERPETIFORMIS.

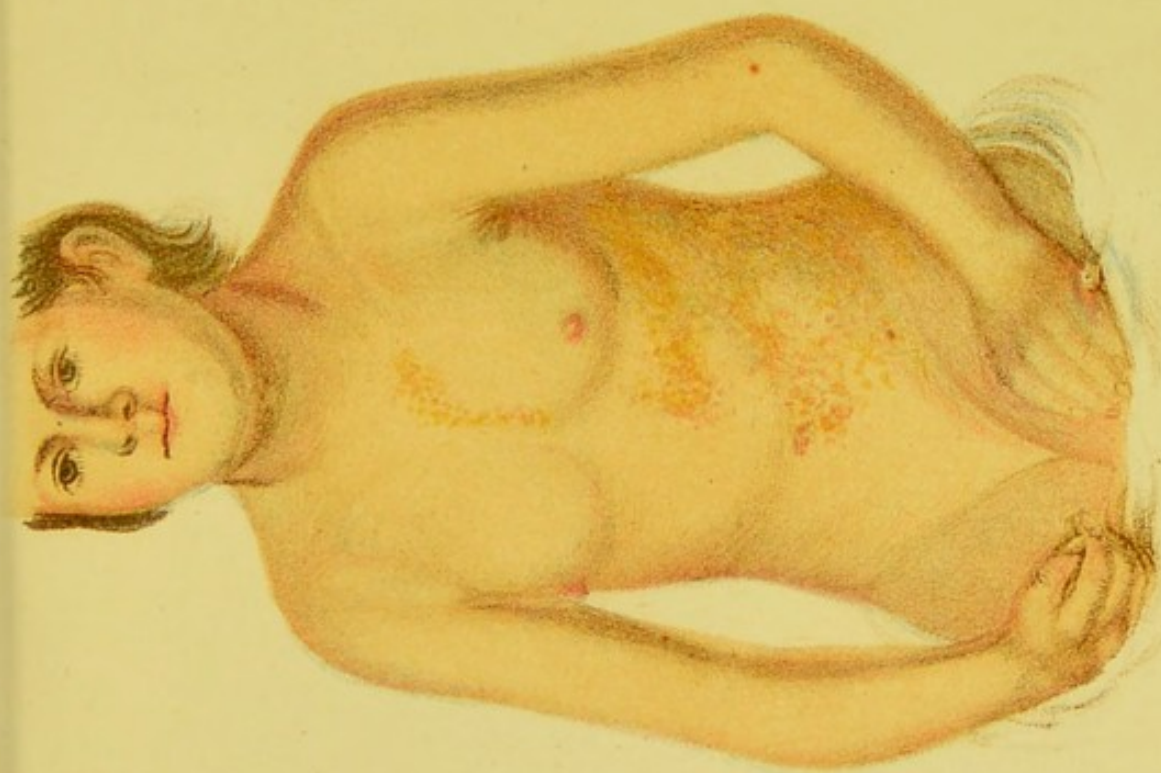


THESE two portraits give a back and front view from the trunk of a girl of twelve, named Cook, who was under my care in 1870. The spots had not been observed at her birth; they had not indeed attracted attention until she was three or four years old, after which it was believed that they had definitely increased. A younger brother was stated to have similar streaks, but yet more marked. It will be seen that the spots were wholly confined to the left side, and that they were arranged very much like herpetic clusters. They were brownish, and very slightly papillary. They were, however, but little raised, and gave her no inconvenience. Although not observed at first, there can be little doubt that potentially they were congenital.


I have published several other portraits illustrating the arrangement of these one-sided papillary and pigmented streaks. The reader is referred to Plates I., II., and XLV., and to the descriptions which accompany them.



H est, Neuman chronio.









## PLATE XLVII.

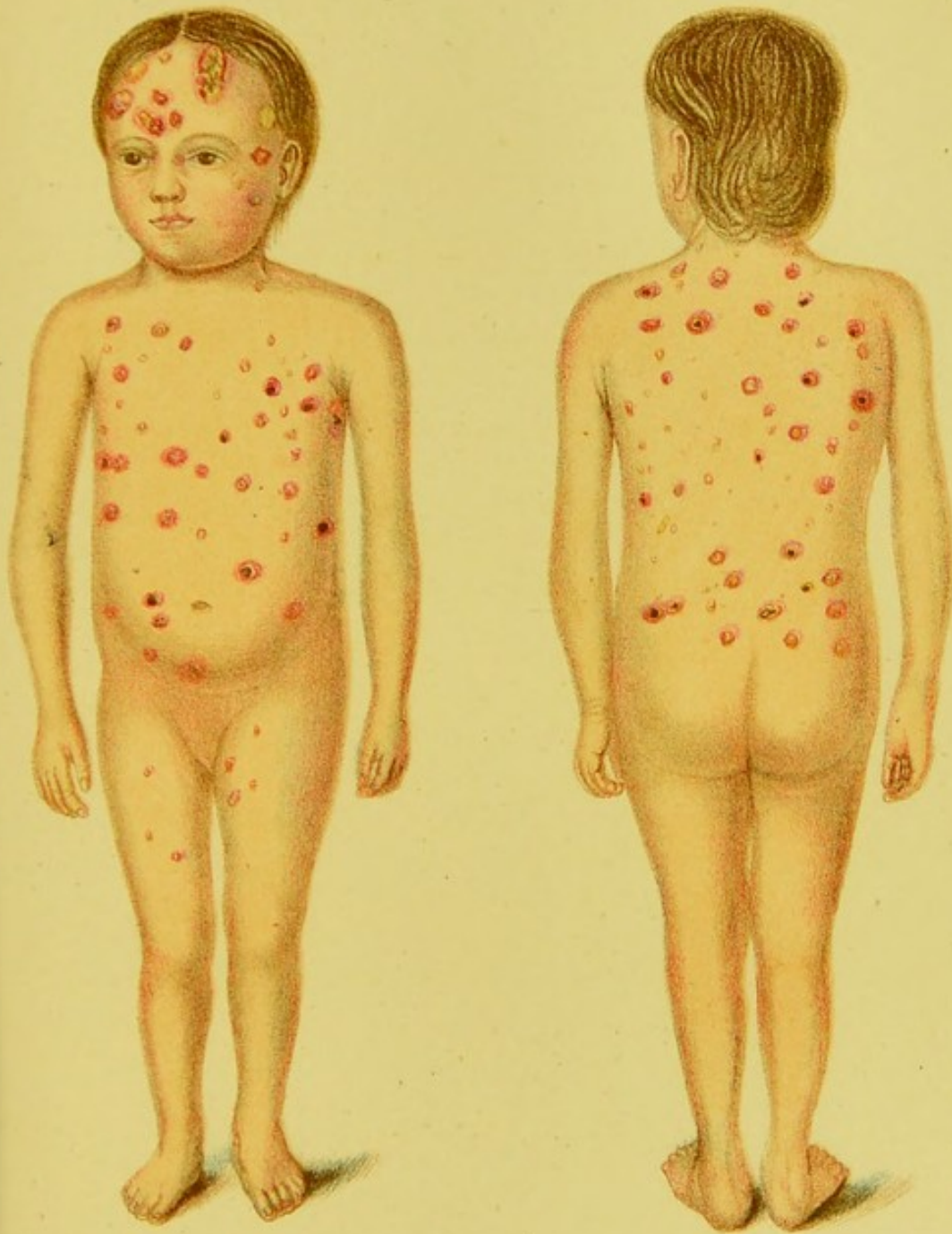
### VARICELLA GANGRENOSA.




IN this Plate we have a portrait showing the back and front view of a child who was the subject of gangrenous varicella. It must be taken as chiefly indicating the distribution of the eruption and its relative severity in different parts. It will be seen that it affects the face most severely and next the trunk, the four extremities being almost exempt.

The subject of the case was a child named Emily Stevens, aged two years and a half, who was under observation in February, 1880. She afterwards made a good recovery. It will be noticed that on many of the varicella spots a portion of skin has sloughed and become black; in others the condition is one rather of necrotic ulceration than actual sphacelus.

See 'Medico-Chirurgical Transactions,' vol. lxxv., page 1, for a full report of the case and of several similar ones. Several other portraits illustrating gangrenous chicken-pox are in my museum.



*West, Newman chromo.*





## PLATE XLVIII.

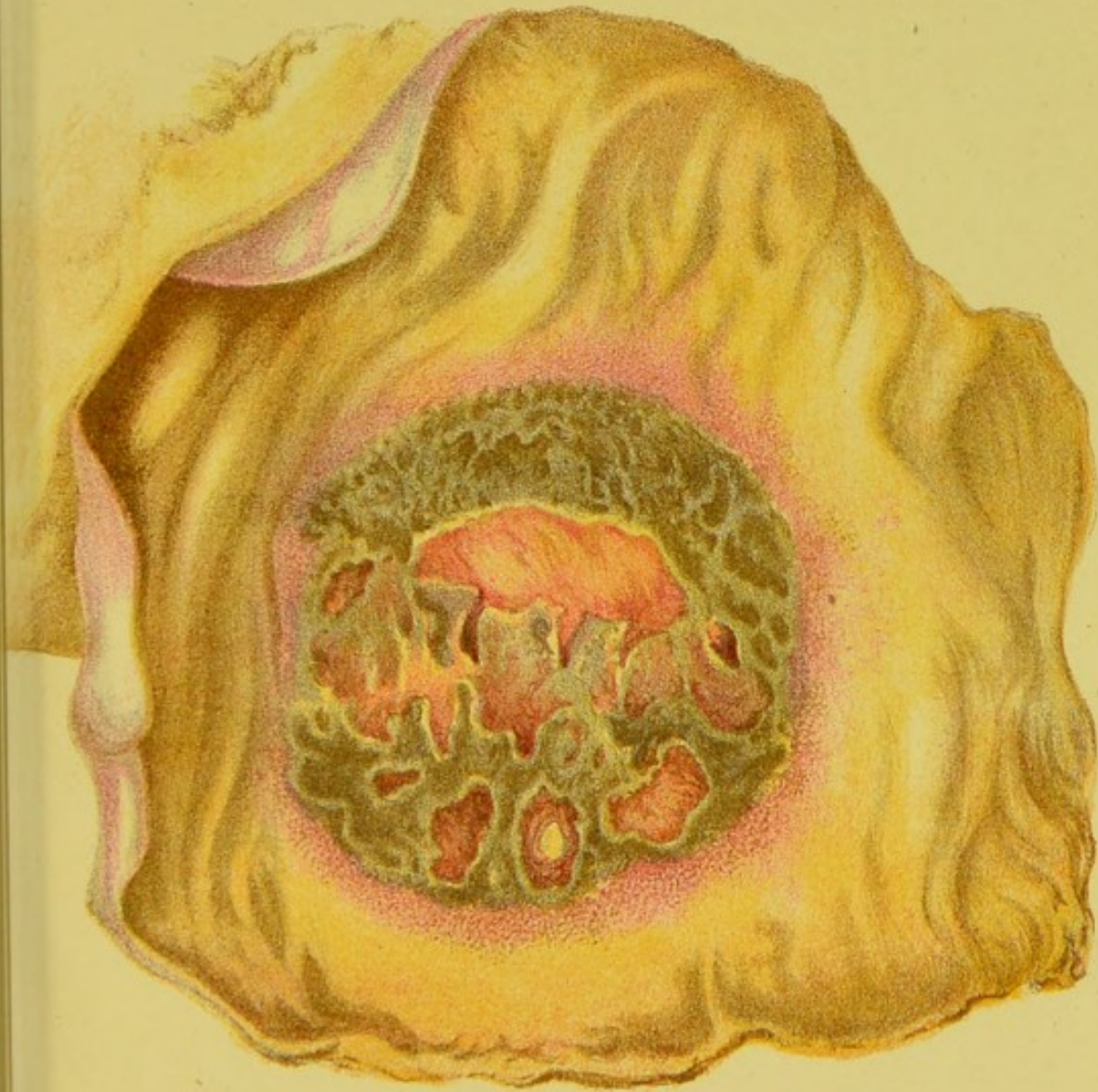
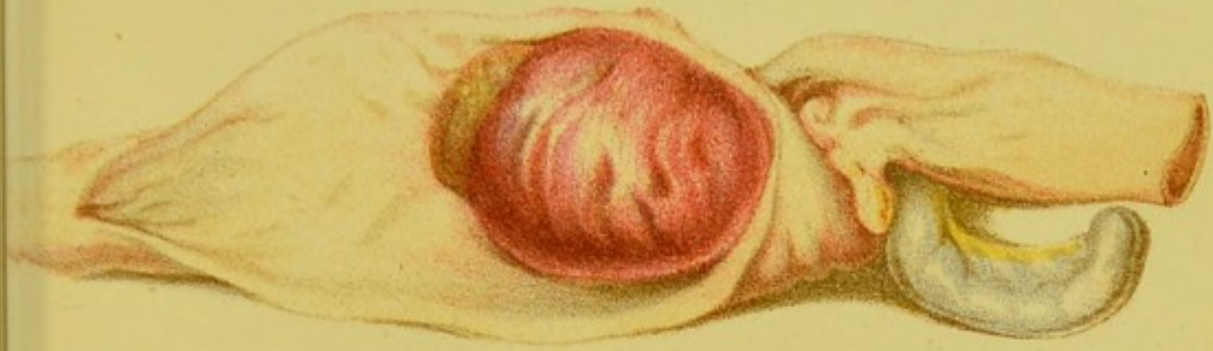


FIG. 1.—INTUSSUSCEPTION OF CÆCUM.


THE upper figure in this Plate shows the commencement of an intussusception of the ileum and cæcum into the colon. The latter has been laid open, and the florid mucous membrane of the involuted bowel is exposed. To the right is seen the ileum, and by its side the terminal portion of the appendix vermiformis, just about to be swallowed in the progress of the intussusception. The sketch was taken by Mr. Frederick Mackenzie, many years ago, from a child who died in the London Hospital after a severe burn. It may be accepted as a good illustration of the earliest stage of the condition of which the next Plate shows the completion. Intussusceptions are very common at this part of the bowel.

FIG. 2.—ULCERATION OF COLON FROM DISTENTION.

THE lower figure in this Plate shows commencing ulceration of the mucous membrane of an over-distended colon. At one spot perforation was just about to occur. The patient, an elderly woman, had died of exhaustion after nearly six weeks of almost complete obstruction of the bowels consequent on a malignant stricture. The diseased portion of the bowel was almost close to the stricture. The sketch was taken (many years ago) in order to exhibit the processes which in cases of long continued obstruction precede perforating ulcer; and also the part most prone to be affected. The proper treatment of the case would have been a colotomy in the right loin. The portrait is a warning against too long delay of operative measures in similar cases.









## PLATE XLIX.

### INTUSSUSCEPTION PROTRUDING AT THE ANUS.



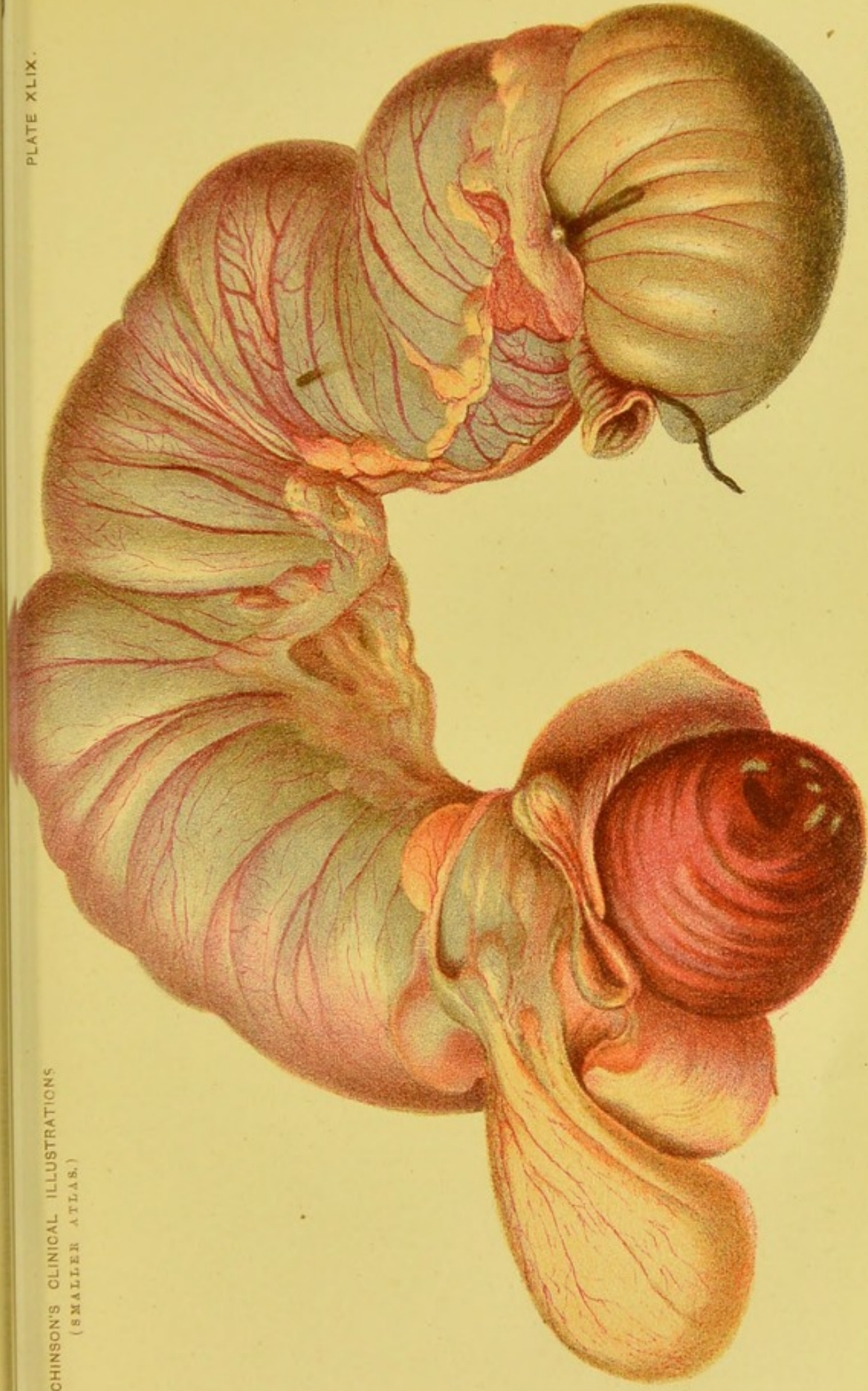
IN Plate XLVIII. is shown the commencement of an intussusception beginning with the ileo-cæcal valve. In the present one we have illustrated the final condition of this lesion, the ileum having travelled the whole length of the colon, and appeared at the anus. The ileo-cæcal valve itself still forms the apex of the involuted tract. The appendix cæci, completely swallowed and being of course in contact with the peritoneal surfaces, is concealed from view. This portrait is of especial interest as showing the exact condition of things which was present in the case upon which I operated in 1873, and which is referred to at page 25 of 'Archives,' vol. iv. In that case, during the operation, when the involution was drawn out, the last structure to make its appearance was the appendix cæci.

This drawing was from a child in whom the disease, after the usual symptoms, had ended fatally. It will be seen that there are not the least indications of tendency to gangrene, nor any evidences of tight strangulation. So far as appearances go, had an operation been performed, a reduction would probably have been easy.


The sketch represents the orifice of the anus. The structure turned to the left is the urinary bladder. At the opposite end a probe has been passed into the intussusception, by the side of the contained gut.


The original drawing from which this Plate is copied was given me by Professor Gairdner, of Glasgow. It is a very valuable one, and I do not know of the existence of any other.

See my Report on this subject in the 'Medico-Chirurgical Transactions,' vol. lvii., 1874.



HUTCHINSON'S CLINICAL ILLUSTRATIONS  
(SMALLER ATLAS.)



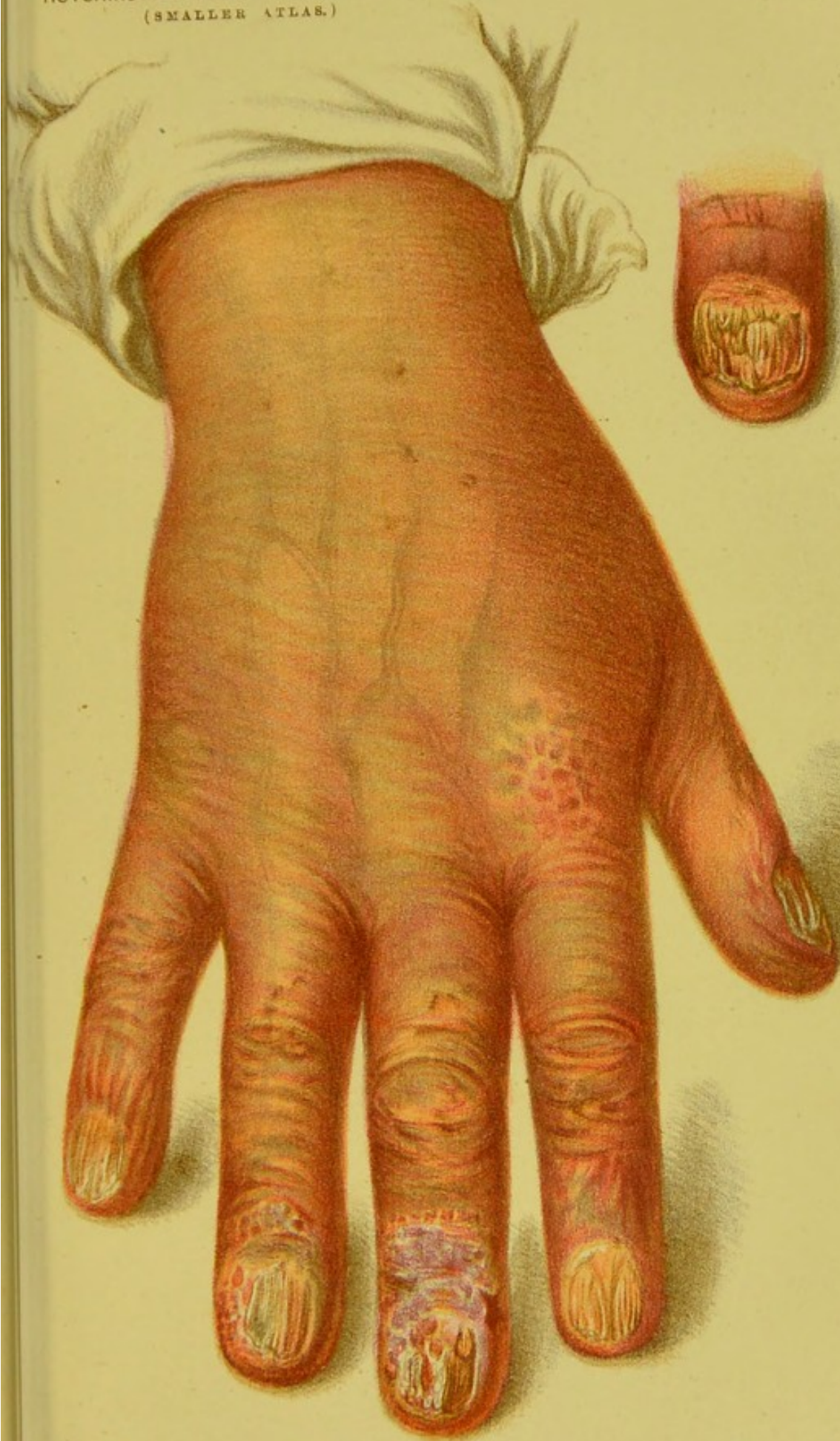


## PLATE L.


### ACRO-DERMATITIS WITH DISEASE OF THE NAILS.



THE hand of an old man who suffered from acro-dermatitis with chronic disease of his nails. His case is fully described at page 251 of 'Archives,' vol. ii. He was a man originally in vigorous health, and in childhood had never suffered from chilblains. At the age of 32, that is, forty years before this sketch was taken, he had suffered severely from frost-bite in Canada. During the last ten years, as an amateur gardener, he had exposed his hands a good deal to cold. A few days of frosty weather were, he said, always sufficient to make his nails brittle and his finger-ends sore. I have little doubt that both the chronic eczema and the disease of the nails were attributable to the influence of cold upon a patient whose circulation, originally vigorous, was enfeebled by age, and by the previous occurrence of frost-bite. They must rank, therefore, as a form of acro-dermatitis in definite alliance with a modification of Raynaud's phenomena.







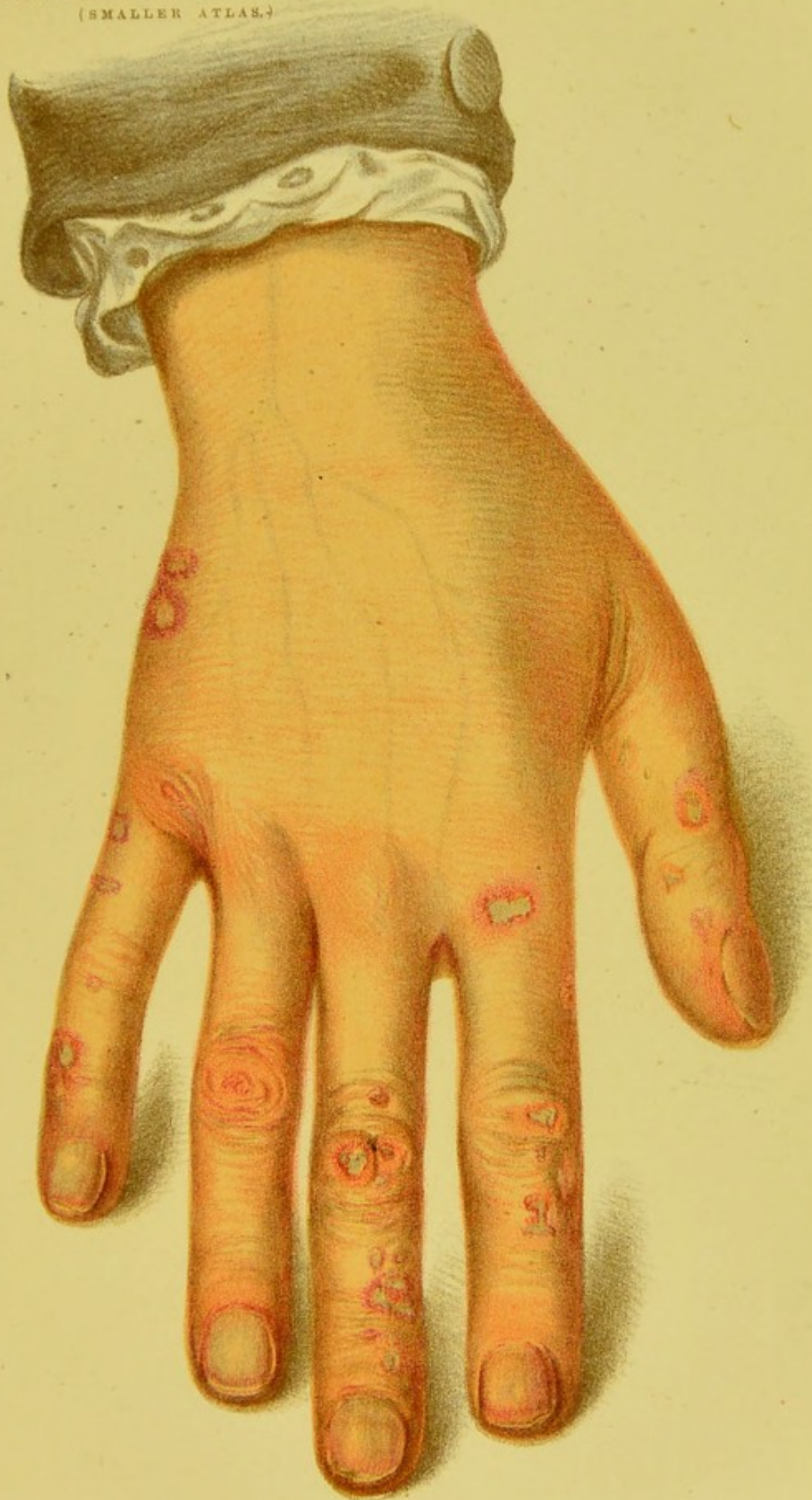


## PLATE LI.


### CHILBLAIN-LUPUS OF HANDS.



THIS portrait shows the condition of the hands in the case of a young woman (Miss Herbert) who was the subject of lupus on one cheek, and of ulcerations of the ear. The conditions exhibited may perhaps be ranked as a peculiar form of chilblains. They are met with in association with certain special types of the lupus process, and with feebleness of the circulation. It will be seen that there are numerous pits which have been left by the healing of ulcers, and other little patches where the skin has become white and gangrenous. A portrait showing the condition of the face of the same patient is given in Plate X., and both may be profitably compared with Plates VI. and VII., which illustrate the case of Philip Holmes; also with Plate VIII., illustrating lupus erythematosus. These conditions are generally worse in winter and cold weather, but sometimes appear to be almost independent of season.







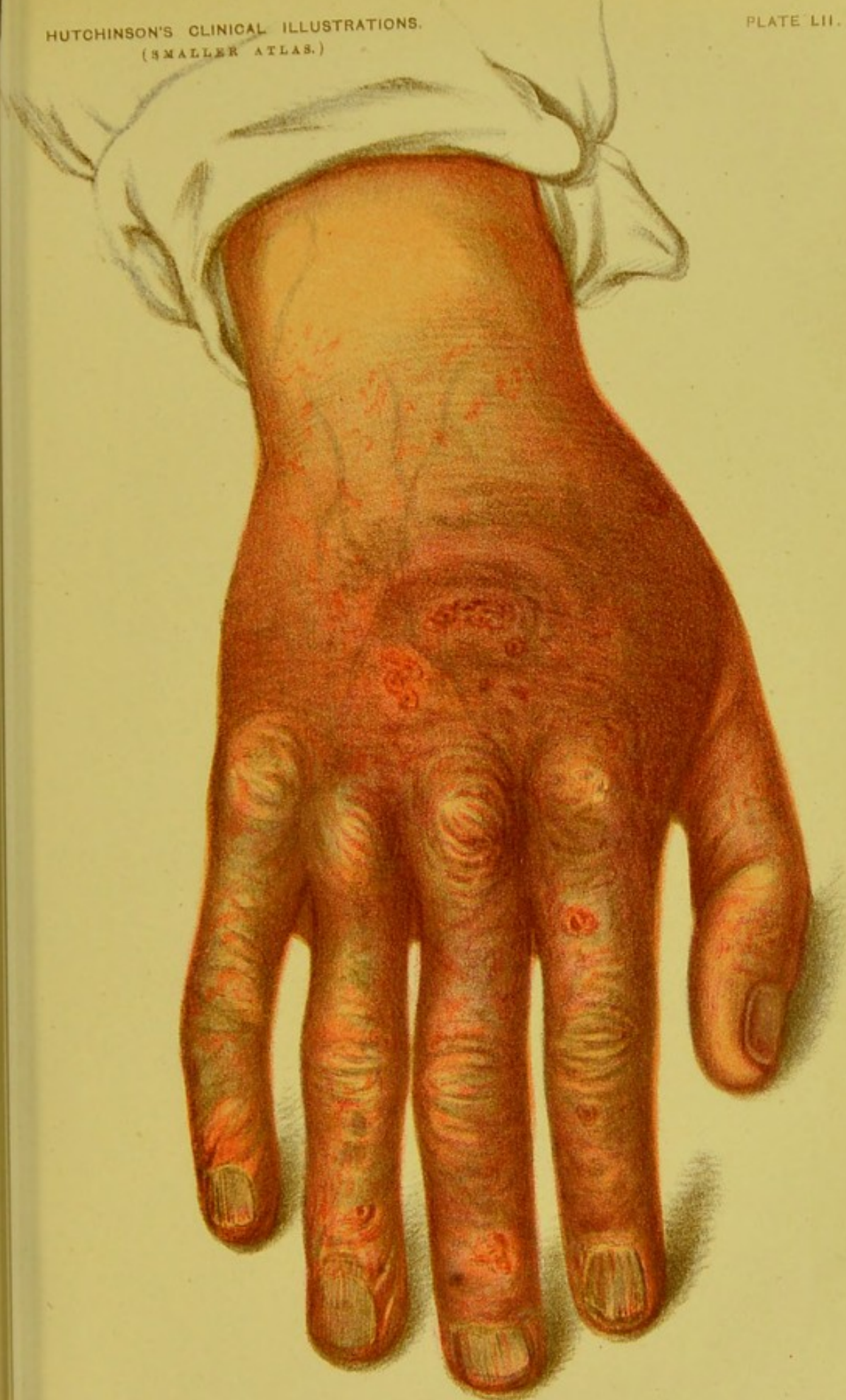## PLATE LII.


### ACRO-DERMATITIS: A FAMILY FORM OF DISEASE.


---

THIS Plate shows the condition of the hand in a young man who had passed through a very exceptional form of illness. His case is fully described in 'Archives,' vol. i., page 337. He had passed through a protracted illness, which had at first been thought to be typhoid fever. This illness had been attended by the formation of large indurations in and under the skin, somewhat resembling erythema nodosum. From the middle of October to the end of March his temperatures had been high, usually above  $100^{\circ}$ , often  $103^{\circ}$ , and repeatedly  $104^{\circ}$ . During this illness ulcerations occurred on both hands and feet. After recovery from it he had a temporary proptosis of one eye, and a year later another febrile illness of shorter duration and milder type.

The Plate shows the condition of one of Mr. G——'s hands. It was dusky, and covered on its back with small ulcers and scars. The nails were fibrous, showing many longitudinal furrows, with a tendency to split. The lesions were those of acro-dermatitis in connection with congenital feebleness of circulation. It is not certain that the condition of the hands was in any very close relation with the febrile illnesses above mentioned, other than that in all probability the congenital organization predisposed to the attacks of illness. Two of the man's sisters had their hands in a very similar state. Thus it would appear to have been "a family disease," and had probably alliances with chilblains on the one hand and with Kaposi's malady on the other. (For full details see 'Archives,' vol. i., page 341.)









## PLATE LIII.

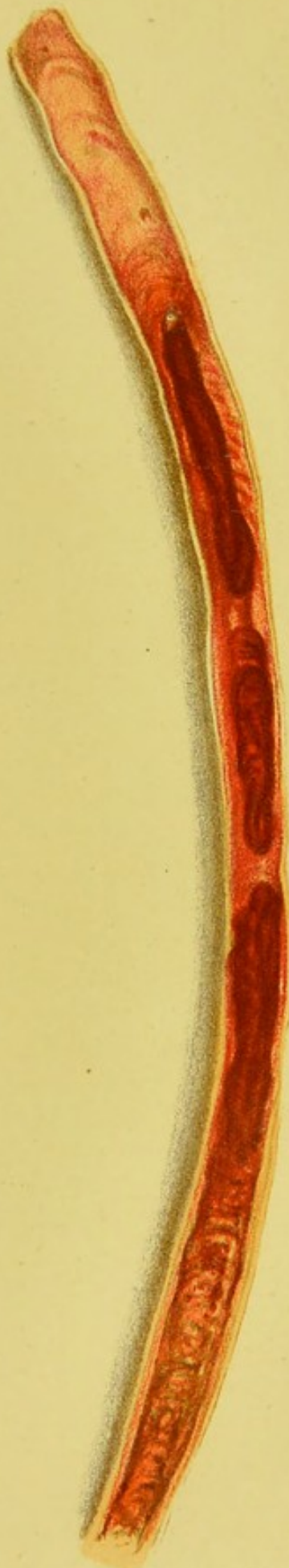
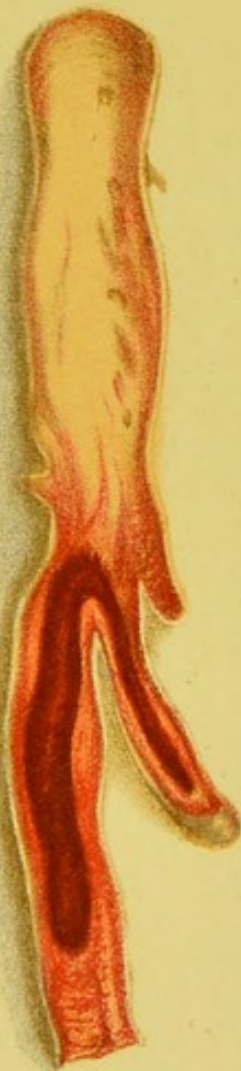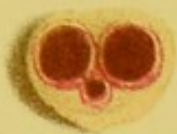### THROMBOTIC ARTERITIS.



THIS Plate shows, first, the popliteal artery from place of section in the amputation, secondly the posterior tibial laid open longitudinally, and lastly a transverse section of the lower part of the anterior tibial with two large veins. In the last both veins and artery are seen to be firmly plugged, and the latter contracted. In the vessels laid open lengthwise it will be seen that the thrombus does not fill the entire calibre and in most parts appears to adhere but loosely. As explained in the text the clot had become detached somewhat by handling, &c., before the specimen was put into the artist's hands.

The specimens were from a case in which a lady of 74 had died after amputation through the thigh for spontaneous gangrene. The gangrene had been present only ten days when the amputation was done, and the leg as well as the foot was already involved. The patient was of gouty family, and suffered much from a gallstone. To the latter her death was probably in part due.

See 'Archives,' vol. i. page 326.





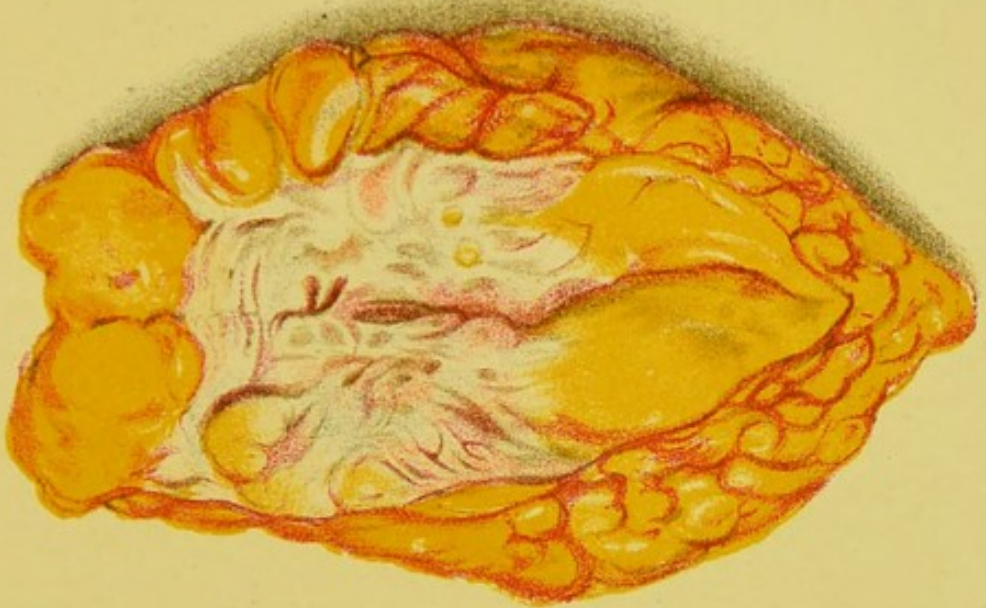

## PLATE LIV.

### CANCER OF UMBILICUS.

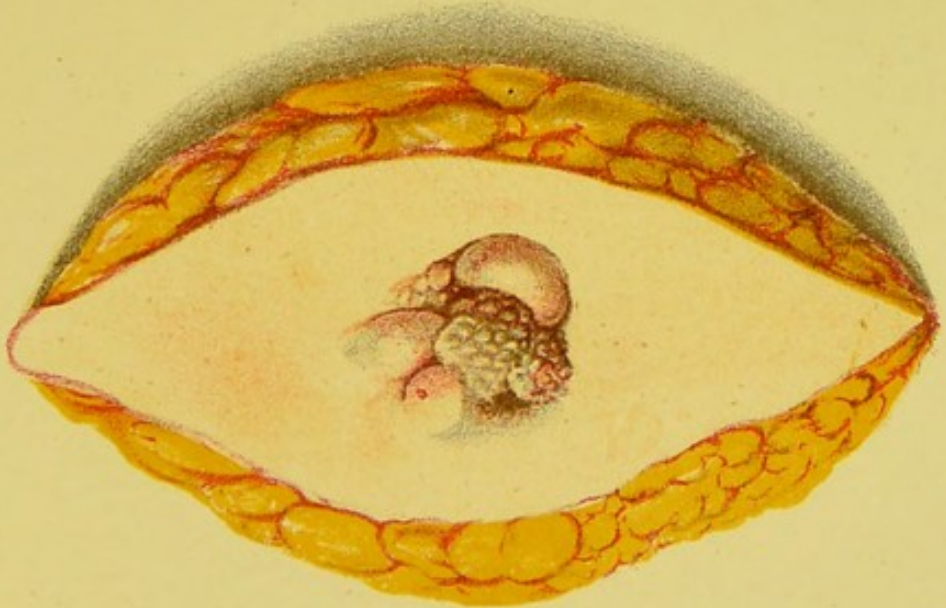
---

IN this Plate are shown the conditions which were present in a case of cancer of the umbilicus. The patient was a lady of about 50 years of age, who had noticed a warty nodular growth on her navel for two or three months, and who was considerably out of health. As there did not appear to be any conclusive evidence of the existence of primary disease elsewhere, I thought it best to excise the affected part. This was done by cutting through into the peritoneal cavity, and taking away the elliptical portion of the whole thickness of the abdominal wall shown in the left-hand figure. The peritoneal surface was found to be unaffected, but the scirrhus growth adhered to it. An incision from below into the indurated part displayed the section which is shown in the right-hand figure. The patient recovered well from the operation, but within two months of its performance there was evidence of nodular induration of the liver. Great irritability of the stomach supervened, and death from cancer of the liver followed about four months after the operation. Having regard to this sequel, I have little doubt that the primary disease was in, or near to, the liver itself, and that the growth on the umbilicus was a secondary one. The infection was probably carried directly by lymphatic trunks passing along the round ligament. I have had two other cases in which a malignant growth, making its appearance at the umbilicus, was really secondary to disease in the liver. In one of these a very remarkable tendency was subsequently displayed for the infection to travel along the lymphatic trunks. The disease spread downwards, on both sides, in the abdominal wall as indurated cords, and caused enlargement of the inguinal glands.




West, Newman, chrom.

HUTCHINSON'S CLINICAL ILLUSTRATIONS.  
(SMALLER ATLAS.)









## PLATE LV.

### PRURIGO ÆSTIVALIS. SUMMER ACNE.

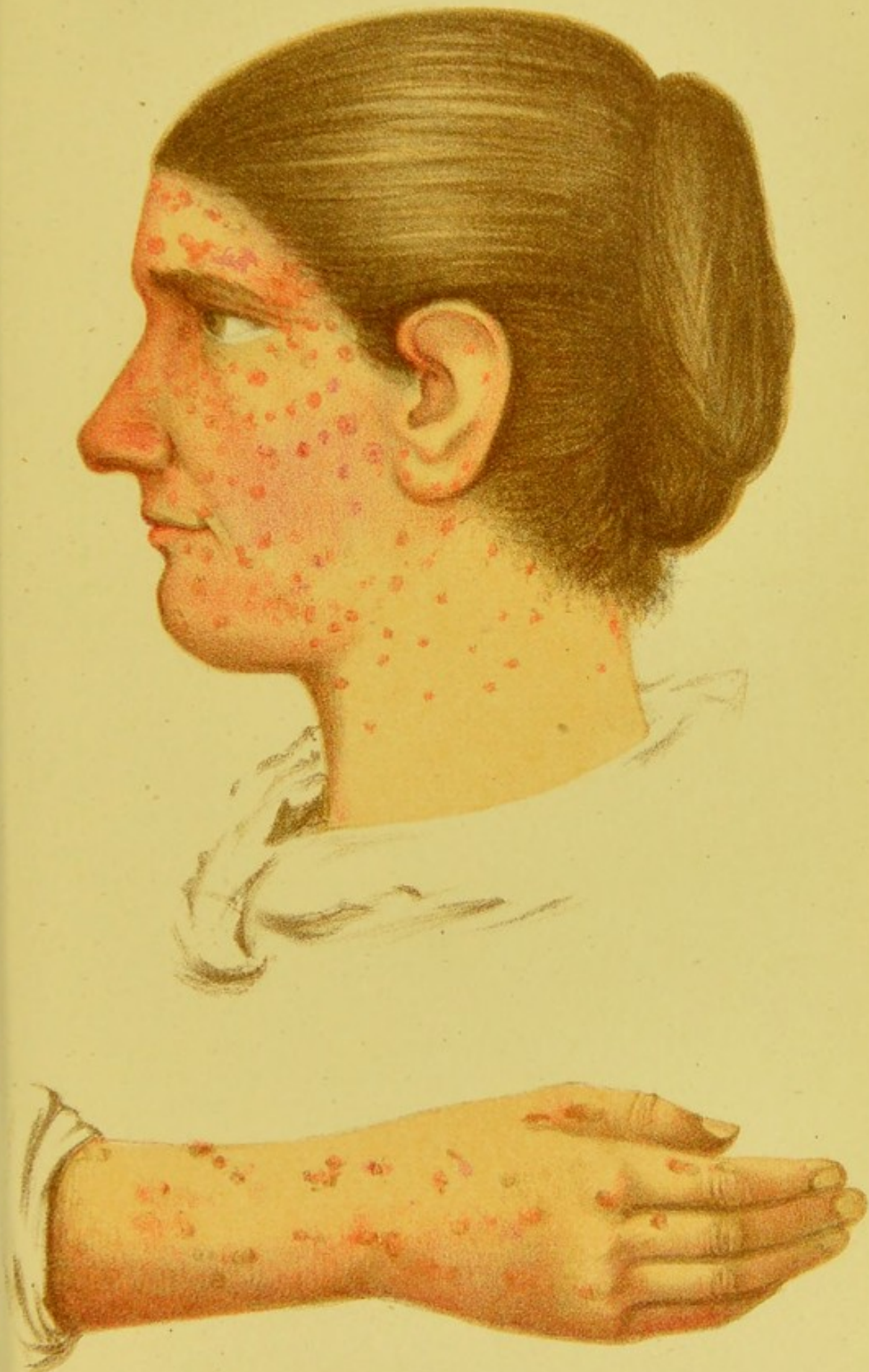---


AMONGST the eruptions, which, although not wholly produced by summer, are yet much aggravated by it, we have a form of pruriginous acne. This disease is well illustrated in one of the New Sydenham Society's portraits, and I have described it under the name of Prurigo Æstivalis. It is especially frequent in young persons, and particularly in young women. The eruption is almost always worse in hot weather, and gets almost or quite well in winter. The liability to this form of summer acne in most cases ceases between the 20th and 30th year.

The portrait which I now give well illustrates this malady as it occurred in a lady of middle age who had been liable to it almost from girlhood. She was in excellent health, but her face, neck, and the backs of her hands were, as is shown in the portrait, covered by little indolent papules, most of which showed the effects of scratching. The eruption occurred only on the exposed parts, and I was assured that, although it never got quite well, it disappeared almost wholly in winter, and was always at its worst in hot weather. The lady was married and had a family. The distinction of the disease from any of the ordinary forms of acne will be recognised, first, in the fact that the hands were affected, and next in the absence of any limitation of the papules on the face to the ordinary acne positions. I may also point out the absence of pustules and comedones.

I have referred to this disease in page 106 of 'Archives,' vol. ii.

Although I have seen many more examples of pruriginous summer acne in young women than in men, yet the type case of the malady occurred in a young man. I have repeatedly referred to his case, and have even ventured to call the malady by his name "Pennman's Prurigo-Acne." It constitutes only one form of "Eruptions due to Summer and Sun."





1847

1847

## PLATE LVI.

### DIFFUSE LIPOMATA OF NECK.


---

THIS portrait is a good type-example of the common form of diffuse lipoma which produces great bulging masses behind the ears and on the nape of the neck. The patient was, as is usual, a man of middle age, accustomed to a city life, and who had drunk beer freely. He was of excitable temperament, and at times it was feared he would become insane. The fatty masses were developed under his lower jaw, as well as on the back of his neck. If he could be persuaded to desist from beer-drinking, they usually subsided somewhat, and definite diminution was in one instance produced by a couple of months' active exercise in the country, whilst drinking only water. As the tumours caused him great inconvenience, I consented, at his urgent request, to attempt a partial removal. The operation was done in the London Hospital. The wound did not unite by first intention, and some troublesome suppuration ensued. The man, however, finally recovered, and was pleased with the result. He died a few years later, but I do not know the nature of his illness.


Several valuable contributions to our knowledge of this malady have been made by Mr. Marrant Baker. It was, I believe, first recognised by Sir Benjamin Brodie. It is never seen in women.

(This case is referred to in 'Notes on Operative Surgery.' See 'Archives,' vol. iii., page 134.)

The Museum contains many illustrations of these extraordinary hypertrophies of fat.



Diffuse Lipoma.



## PLATE LVII.

### ILLUSTRATIONS OF THE SIZE AND SHAPE OF GALL-STONES.

---

FIG. 1.—The stone removed by Mr. Bryant in the case quoted at page 10. It measured more than three inches in circumference. It was removed by a laparotomy operation, but unfortunately with a fatal result.

FIG. 2.—A stone, which was removed by Mr. Bryant from the gall-bladder of a woman, aged 53. A sinus existed; the concretion could be felt by a probe. The sinus was enlarged, the stone extracted, and the patient made a good recovery (see 'Transactions of the Clinical Society,' vol. xii. page 20). No jaundice or symptoms of biliary disease had ever occurred.

FIG. 3.—A stone, which was passed per anum by a woman, aged 53, after five days' severe symptoms of obstruction. The subsequent recovery was complete. The obstruction had been supposed to be due to an umbilical hernia, from which she suffered. She had never in her life had jaundice, nor had there been any attack indicative of the escape of the stone from the gall-bladder to the intestine. The stone had a largest circumference of more than three inches. It was of light sp. gr., but weighed 228 grains. (See 'Medico-Chirurgical Transactions,' vol. vi. Case by Mr. H. L. Thomas.)

FIGS. 4, 5, & 6 are given to illustrate a fatal case of chronic obstruction by gall-stones, and at the same time the great difficulties which attend diagnosis. The patient, a woman, aged 59, died of perforation of the ileum, just above the cæcum, eight months after the probable date of escape of the stones from the gall-bladder, and after eight weeks of incomplete obstruction. The symptoms had been vomiting, constipation, and severe griping pain, but they had been repeatedly relieved by treatment; the bowels had acted well, and at no time, until the last few days, had there been abdominal



distention. There had never been jaundice, and the patient had usually enjoyed fair health. Eight months before her death she had passed through an attack of constipation, with great pain, and at that time a hard tumour could be felt in the right hypochondrium. At the autopsy the gall-bladder was healthy, and no conditions were found which threw any light upon the mode by which the stones had escaped. Each of the larger stones measured about four inches in circumference. There was no proof that any accretion had been received by them from the contents of the intestine.

It will be seen that in this case no permanent obstruction was caused, and that for months together the bowels acted well. Death was not from obstruction, but from perforation from irritation. The fact that there were several stones, and some small, probably conduced to this result.

The case is recorded, by Mr. Le Gros Clark, in the Medico-Chirurgical Society's 'Transactions.' It is republished in full, with other important illustrations of gall-stones, in the 'Pathological Atlas of the New Sydenham Society' (Fascic. VII.).

I am acquainted with the particulars of a case in which a lady, after a very prolonged and repeatedly almost fatal illness, voided a calculus as large as the largest of those here shown, and recovered.

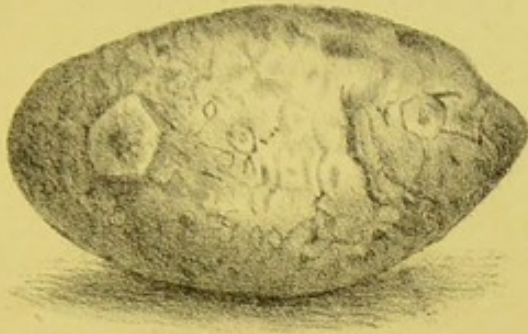

Fig. 1.

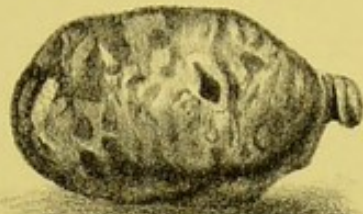

Fig. 2.

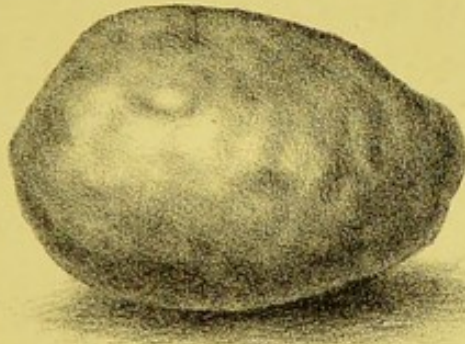

Fig. 3.



Fig. 4.

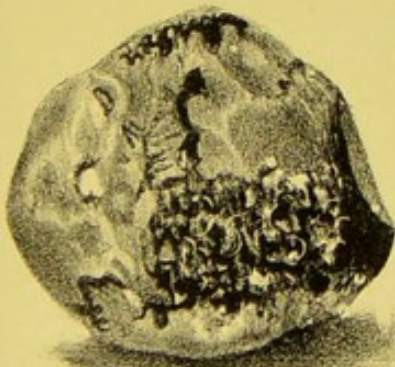


Fig. 5.

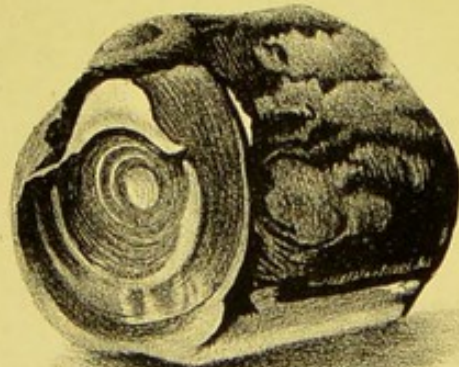



Fig. 6.

Gall Stones.

(Copied from various sources to show form & size.)

West, Newman, lith.



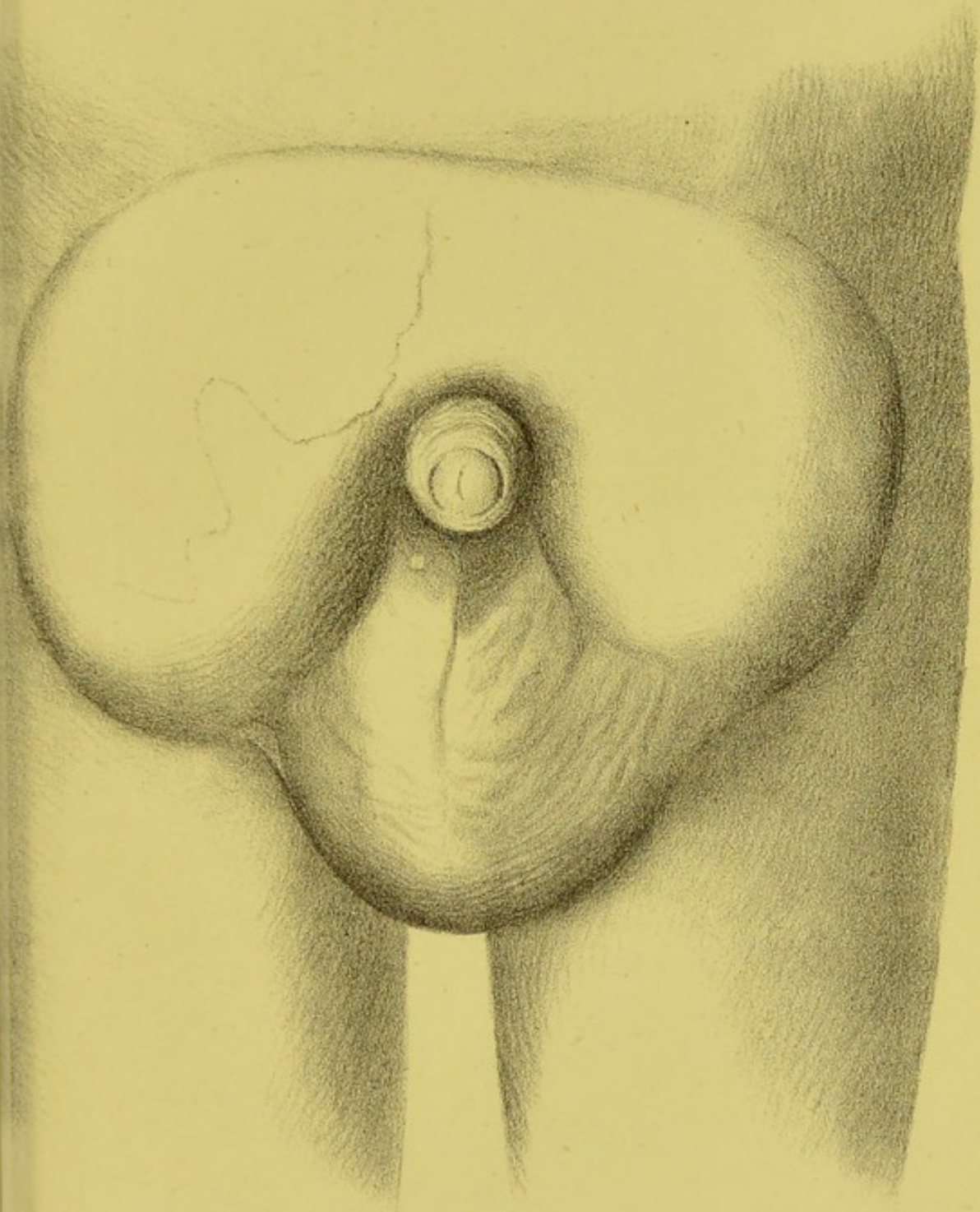


## PLATE LVIII.

### DIFFUSE LIPOMATA OF PUBES AND PERINEUM.


---

THIS Plate illustrates the occurrence of diffuse lipomata in a position where these growths are not very common, that is, in connection with the genitals. I have only seen one other example of them in this position, and in it the growths had not attained anything like the size of those here depicted. The subject of this case was a man of middle age, who had been accustomed to the liberal use of malt liquors. He had large growths at the back of his neck and under his jaws, but in these positions they had not attained any very unusual size. In the pubic and perineal regions they had become so inconvenient that, as described at page 136 of 'Archives,' vol. ii., it was thought advisable to remove them. They did not invade either the scrotum or the penis, although these parts were almost buried in the masses of fat which surrounded them. There has been no attempt at renewal of growth since the operation. Under treatment, chiefly dietetic, the growth of those in the neck appears to have been arrested. The sulphide of calcium in full doses has appeared to be useful.



Diffuse Lipoma.

*West, Newman, lith.*







## PLATE LIX.

### PHAGEDÆNIC ULCERATION IN INHERITED SYPHILIS.



THIS Plate contains the portraits of three girls, the subjects of inherited syphilis. It is intended to illustrate the results of a form of phagedænic ulceration which is sometimes mistaken for lupus. It may be easily distinguished from the latter by the fact that it progresses rapidly, and destroys the nose as extensively in a few weeks as lupus would do in years. It differs also from lupus in that it not infrequently affects the bones themselves, and that it heals with a sound scar which shows no tendency to relapse. This form of phagedænic ulceration may in some cases be more or less chronic. It is usually seen before the age of puberty. It requires vigorous treatment by the application of nitric acid and iodoform, and the internal use of the iodides. It is sometimes attended by a similar form of ulceration on the soft palate.

See several references to this form of ulceration in the 'Clinical Journal' for 1895; and also in 'Archives of Surgery,' vol. iv.; and the author's manual on 'Syphilis,' page 156.

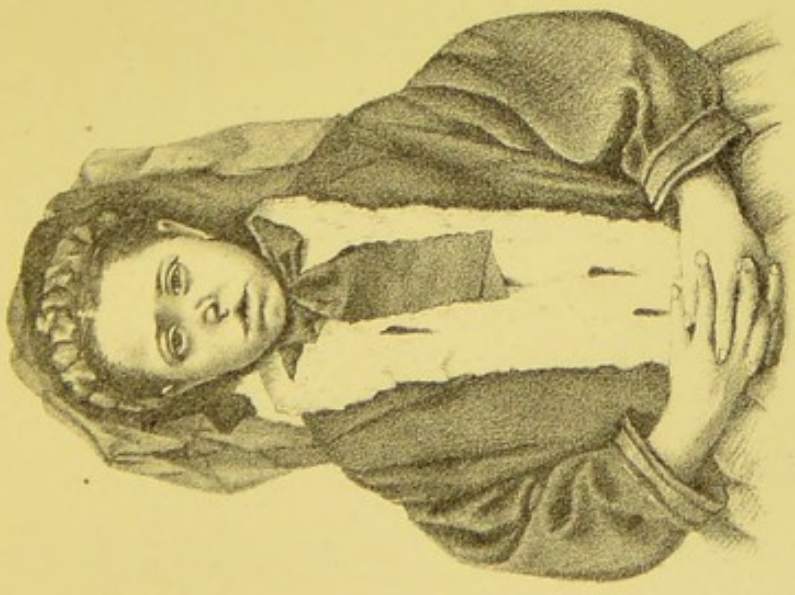

Fig. 1.

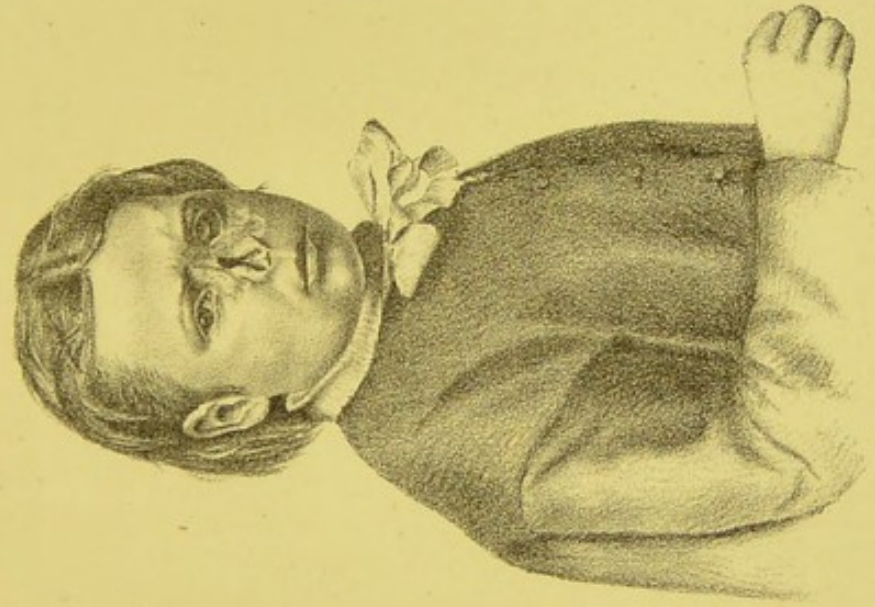



Fig. 2.

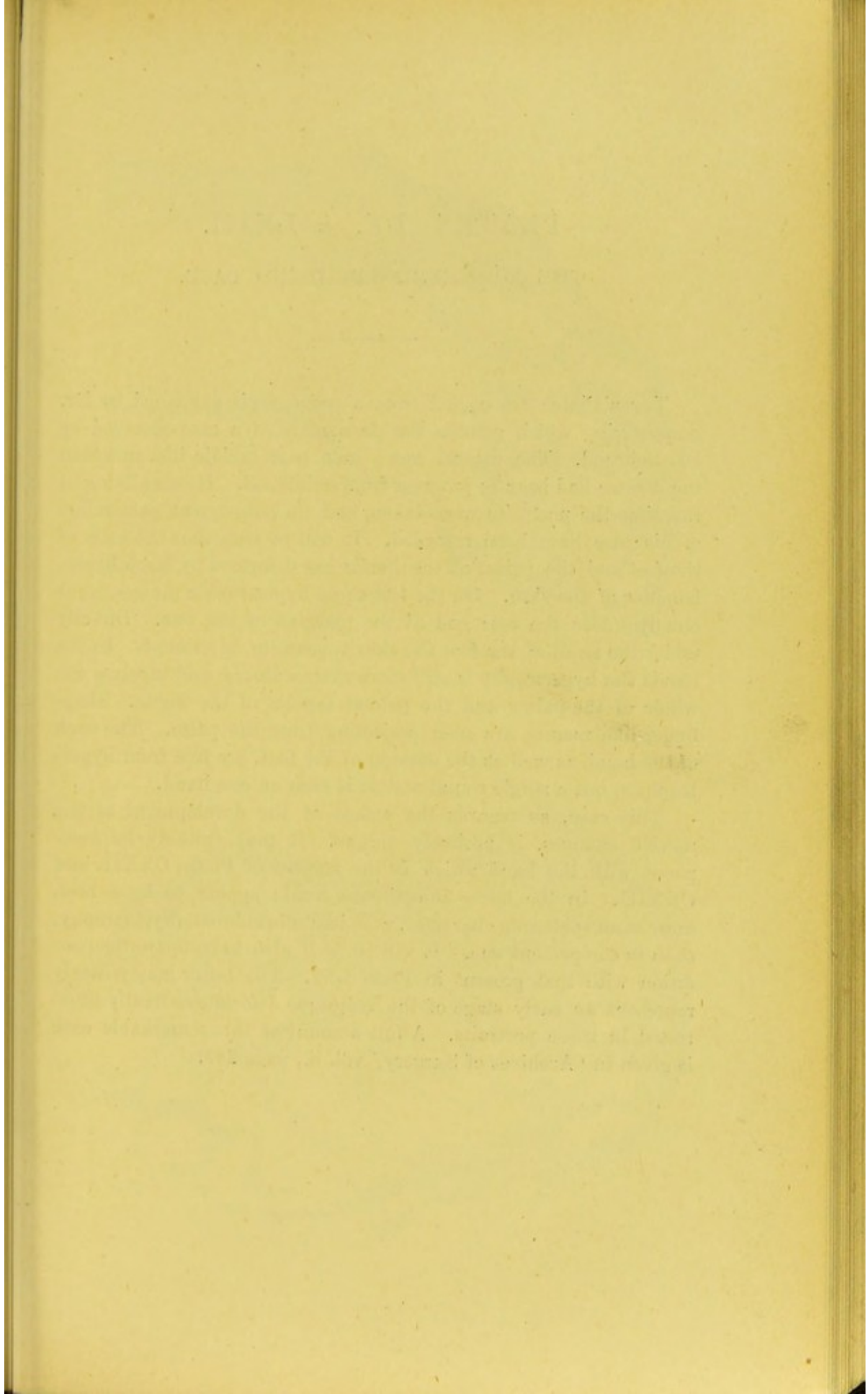
Inherited Syphilis.

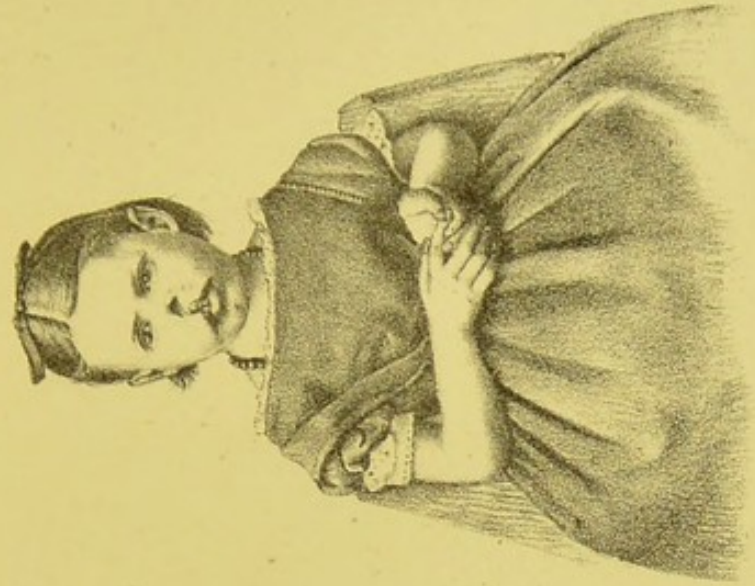

Fig. 3.

West, Newman, lith.





## PLATES LX. & LXIII.

### THE SÖMMERRING-BEHREND CASE.

---

THESE Plates are copied from a monograph published by Dr. Sömmerring which records the particulars of a case observed by Dr. Behrend. The patient was a man past middle life, in whom the disease had been in progress from childhood. He was living at the time the portraits were taken, and no subsequent particulars of his case have been recorded. It will be seen that the soles of the feet and the palms of the hands are deformed by large hypertrophies of the skin. On the feet these hypertrophic masses occur chiefly under the toes and at the margins of the sole. Directly under the tread of the foot the skin appears to be exempt. In the hands the hypertrophy is still more extraordinary, and involves the whole of the palms and the palmar aspects of the digits. Huge finger-like masses are seen projecting from the palm. The back of the hand, as well as the dorsum of the foot, are free from hypertrophies, but a single round nodule is seen on one hand.

This case, as regards the extent of the development of the morbid changes, is probably unique. It may suitably be compared with the hand which is the subject of Plates CXXII. and CXXIII. In the latter the disease would appear to have been more of an epidermic character, with less subcutaneous hypertrophy, than in the present one. It will be well also to compare the condition with that present in Plate LXI. The latter may possibly represent an early stage of the grotesque deformities finally illustrated in these portraits. A full account of this remarkable case is given in 'Archives of Surgery,' vol. ii., page 299.

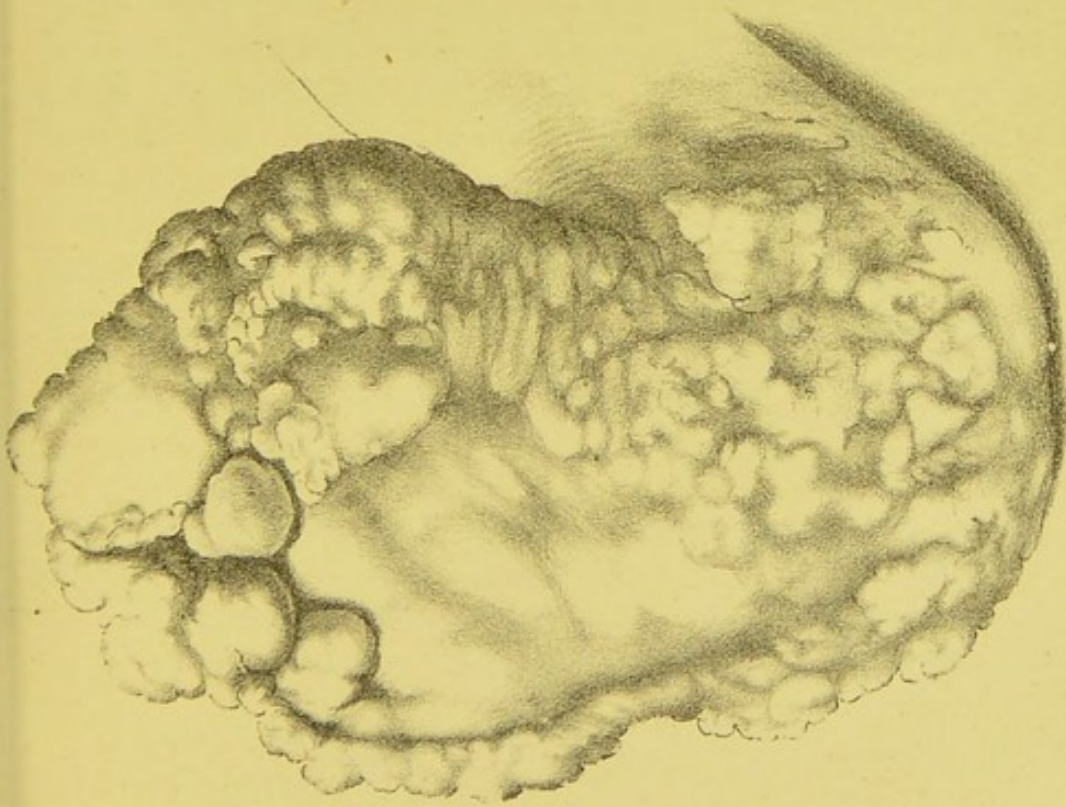


Fig 1.

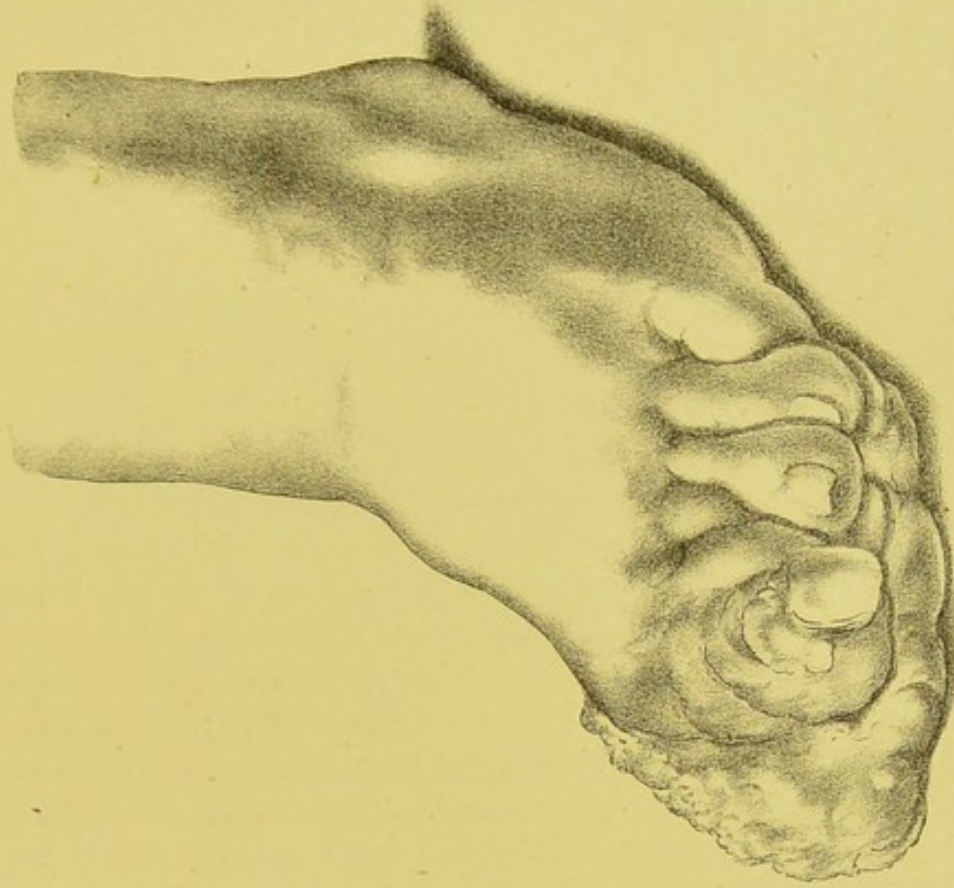



Fig. 2.

A remarkable disease of Hands and Feet.  
(Copied from *Behrends*.)

West, Neuman, lith.



## PLATE LXI.

### PECULIAR DISEASE OF SKIN OF HANDS, &c.

---

I HAVE copied this portrait from a drawing given me by Dr. Judson Bury, of Manchester. It is the one to which I have referred in the text at page 301; and the case is reported in detail in the 'Illustrated Medical News' for May, 1889. Dr. Judson Bury has been kind enough to supply me with particulars which bring the case up to date. The patient is a child who was twelve years old when the hands were sketched, and is now fifteen. But very little change in the local conditions has occurred during the last three years. A few of the patches have entirely disappeared, but most of them remain as they were; some of them have become decidedly thicker and more nodular. The girl is in good general health.

Her curious eruption began in July of 1888, and consisted of purple erythematous patches, with considerable thickening, on the palms of the hands, backs of elbows, and fronts of knees. There were the remains of a patch, which had faded, over the left loin. The toes were slightly livid and swollen, and it was stated that the disease had first shown itself on them, and subsequently spread to the knees. On the backs of the digits there were some thickened, almost nodular, patches of a similar character. Thus the fingers presented a lumpy, knotty condition. The patient's family history was good; she was the youngest of twelve, and neither gout nor rheumatism had occurred in her relatives. She had herself however, had an attack called rheumatic fever, after scarlet fever, at nine years of age.

It is very difficult to speak as to the precise nature of this disease. It certainly very closely resembles, in general features, some cases which I have myself published,\* without venturing to give the disease any name; but which were, I have no doubt, of

\* See 'Illustrations of Clinical Surgery,' Plate VIII., and page 42. Also the 'British Journal of Dermatology,' November, 1888.



PLATE LXI. (*continued*).

the same nature as the disease figured by Hebra as "Sarcoma Melanodes," and which now ranks as one of those which make up the Dermatologist's group of "Sarcoma Cutis." I can scarcely doubt that Dr. Bury's case is of the same nature as my own, but I have never myself seen any approach to it in a young person. The persistence of the condition during three years, and in spite of much treatment, separates it of course very widely from all forms of psoriasis and erythema.

I have special interest in publishing this portrait at the present time, because it seems to me very possible that the disease shown may be an introductory condition to the extraordinary state which occurred in the Sömmerring-Behrend case, published at page 219.

*Postscript.*—Since the above was written I have seen several similar cases, and am now inclined to connect the malady definitely with hereditary gout. See 'Archives,' vol. v. page 237, and also vol. vi. page 132.



Fig. 1.

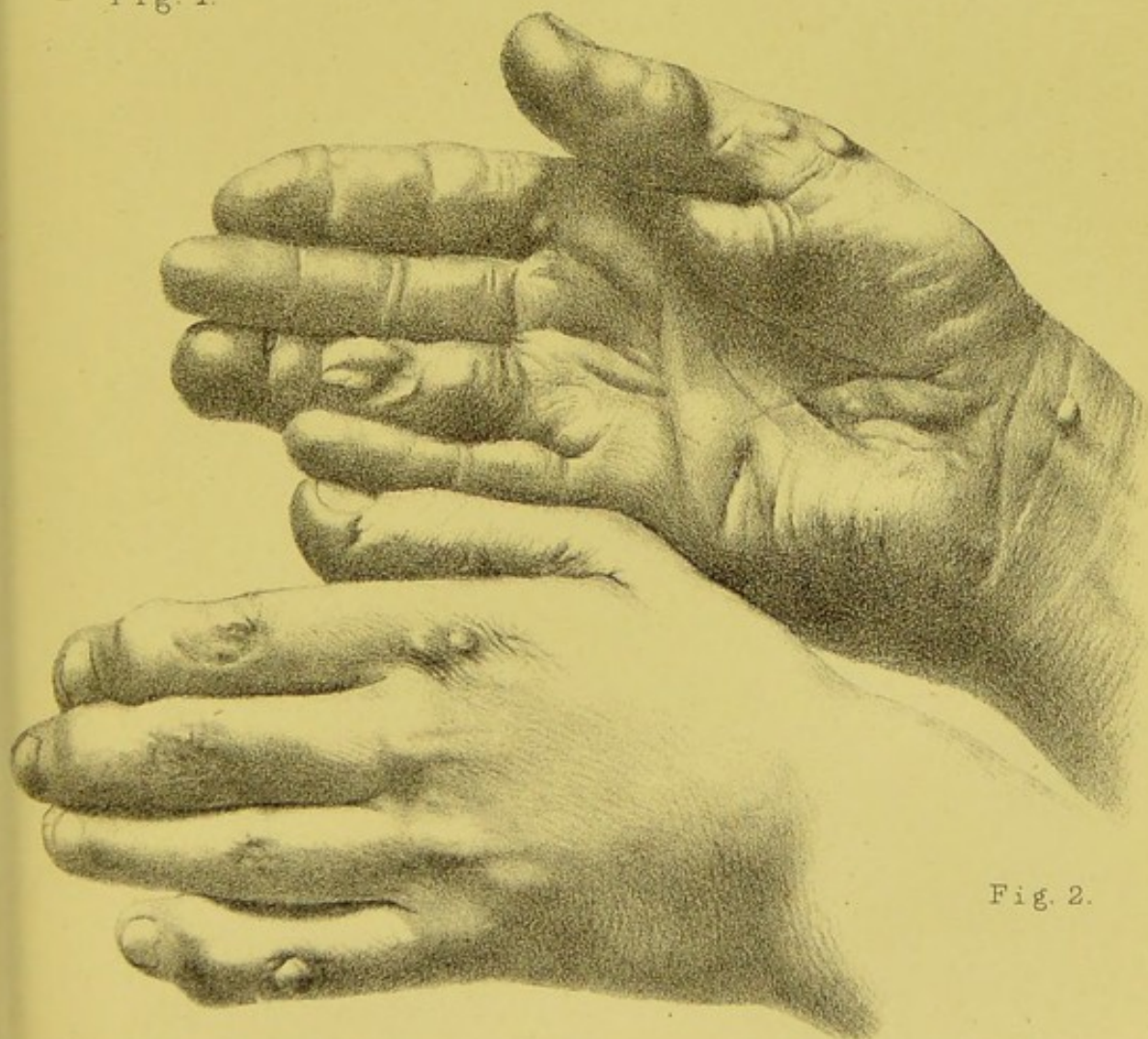




Fig. 2.

Remarkable disease of Hands.  
(Copied from Dr. Judson Bury.)

West, Newman, lith.





## PLATE LXII.

### LUPUS-CANCER.

---

FOR particulars concerning this Plate see 'Archives,' vol. ii., page 145, and vol. iii., page 338. The four portraits are copied from an important report on lupus-carcinoma, published by Dr. Bayha, of Tübingen. The Clinical Museum contains a series of portraits illustrating this disease. When cancer attacks the scar of lupus vulgaris it is usually in a late stage of the disease. At first a hard-edged indolent ulcer is produced, but after a few months' duration the base of the ulcer begins to fungate and a large excrescence results. The course of the disease is then usually very rapid. If the tumour be excised, speedy return is almost certain. The patient's death usually follows within a year or two of the development of the carcinoma. Some of the portraits in the museum illustrate this tendency to fungate remarkably well. It is also seen very definitely in the four portraits which are here reproduced. See also for an example of lupus-cancer Plate XXI.

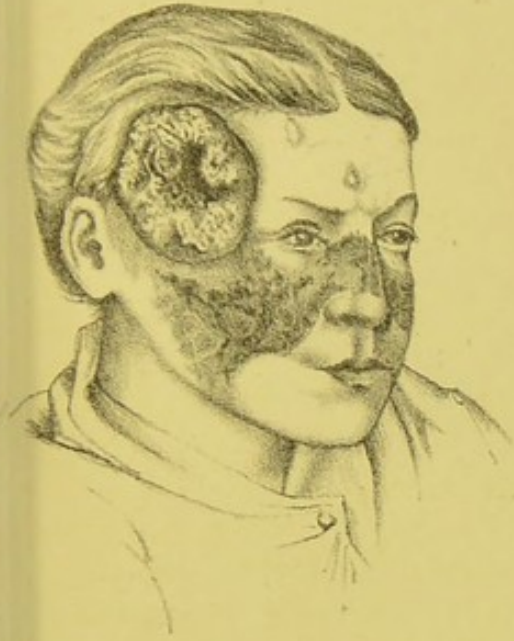

Fig. 1.

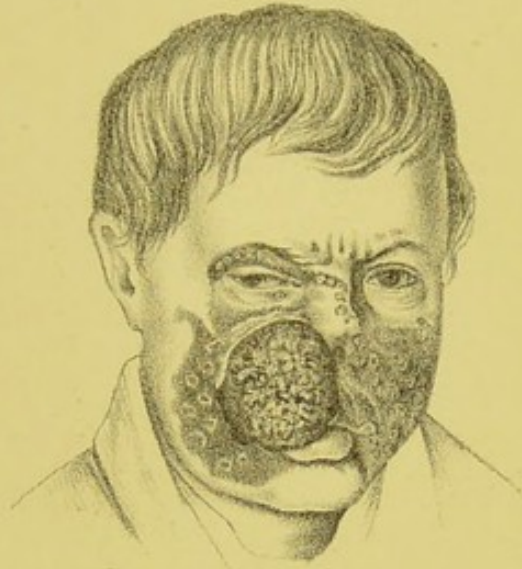

Fig. 2.

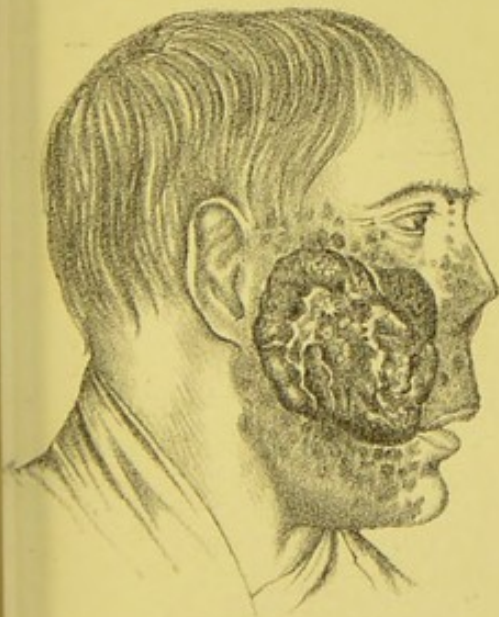


Fig. 3.

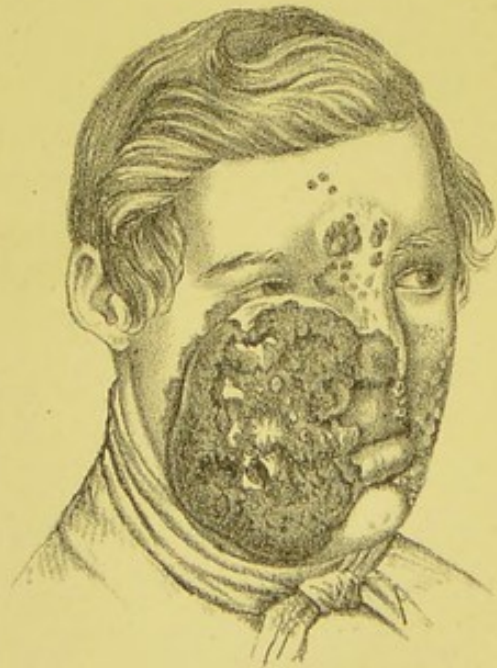

Fig. 4.

Cancer following Lupus.  
(Copied from Dr. Bayha.)

West, Newman, lith.








PLATE LXIII.

THE SÖMMERRING-BEHREND CASE.

SEE DESCRIPTION OF PLATE LX.

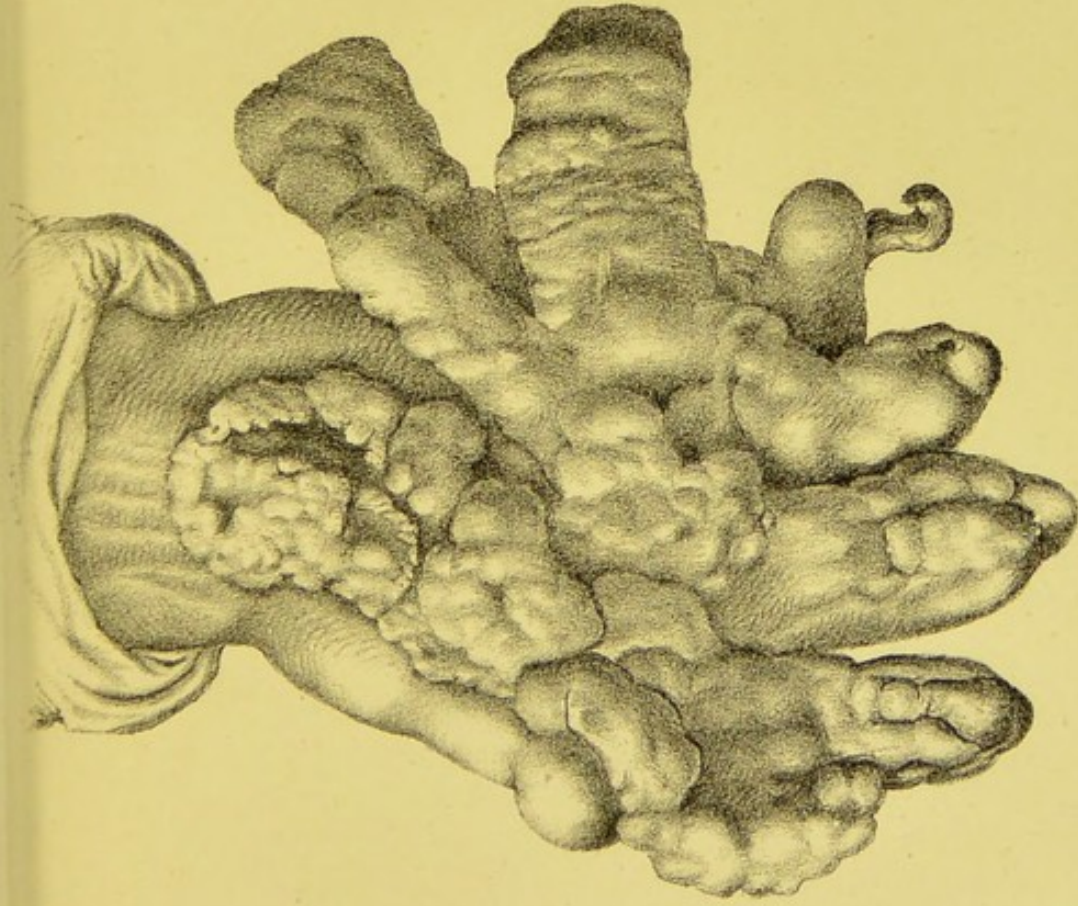


Fig. 1.

Remarkable disease of Hands and Feet.  
*(Copied from Behrend's.)*

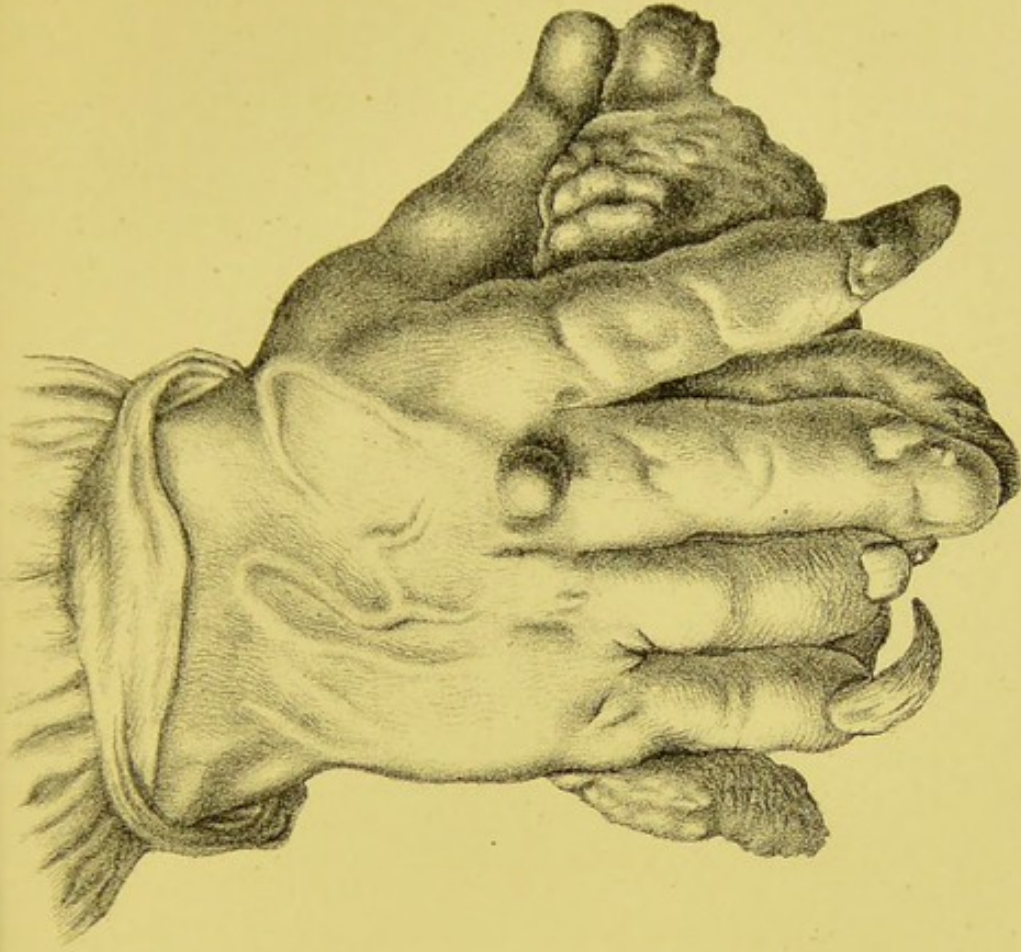




Fig. 2.

West, Newman, lith.





## PLATE LXIV.

### MOLLUSCUM FIBROSUM.

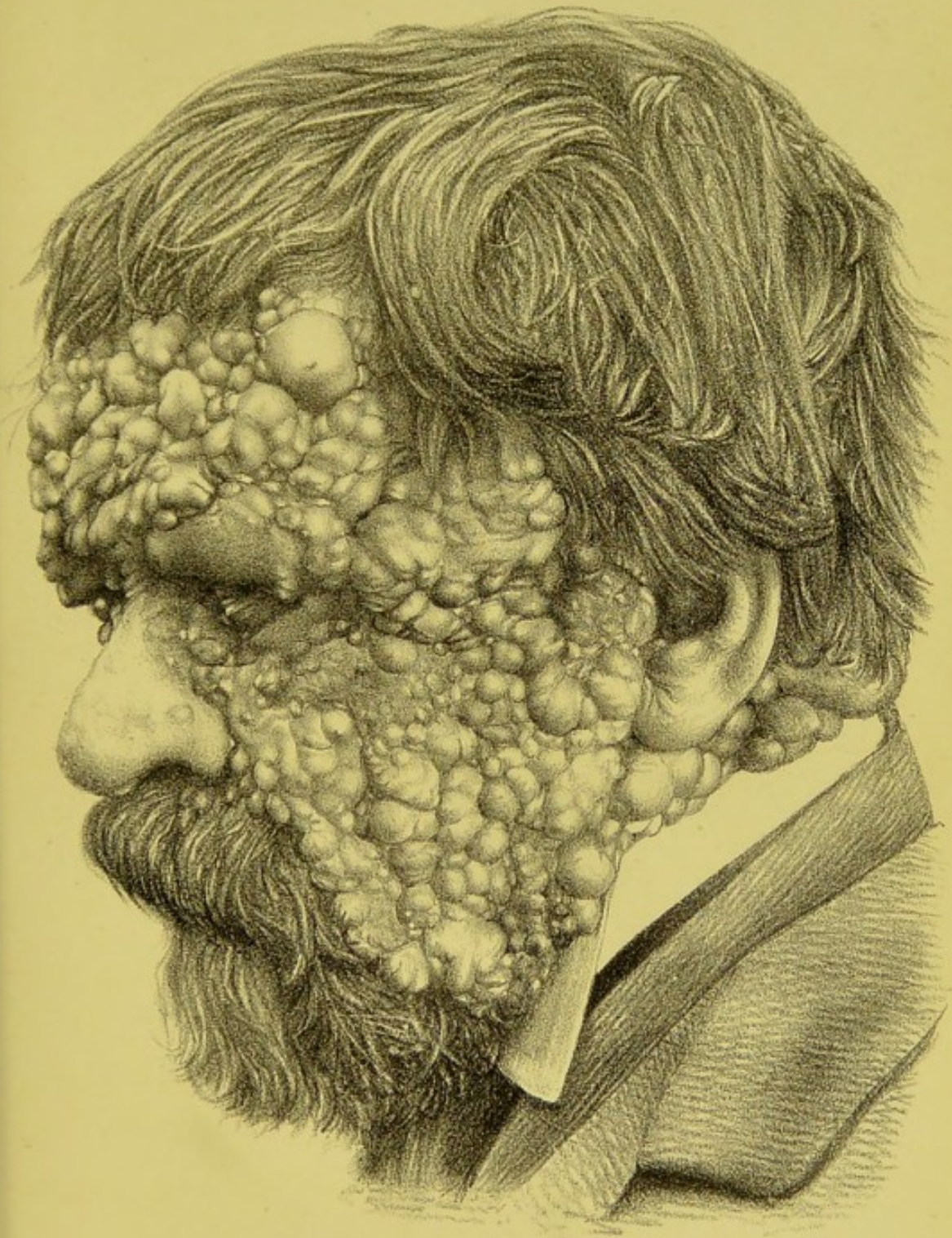
---


THIS portrait shows the present condition (1892) of a man who has for the last five and twenty years been under the observation of dermatologists in London. He now affords an example of most extensive molluscum changes. His portrait was published by myself in the New Sydenham Society's Atlas of Skin Diseases more than twenty years ago. It is Plate XVIII., and a full description of the man's condition is given in the catalogue.

A comparison of that portrait with the one now given is of great interest as showing the advance which the disease has made. At various times I have excised a great many of the growths from the face, more especially from the eyelids, where they were very inconvenient. It will be seen from the Plate that, although the molluscum growths are so numerous as to have become confluent over most of the exposed parts of the face, the ear and the nose are wholly exempt. The skin of the trunk and limbs is now affected in almost the same degree as the face, and it is of much interest to note that a certain number of tumours have formed inside the mouth, on the palate, lips, &c. The tendency to the formation of these growths was first observed in early childhood, and they have been gradually increasing ever since. Although so severely disfigured the man still retains good health.

The case is a good example of what is usual in molluscum fibrosum. It is perhaps one of the most advanced cases yet recorded.

See a series of drawings in the Clinical Museum illustrating this and other similar cases.






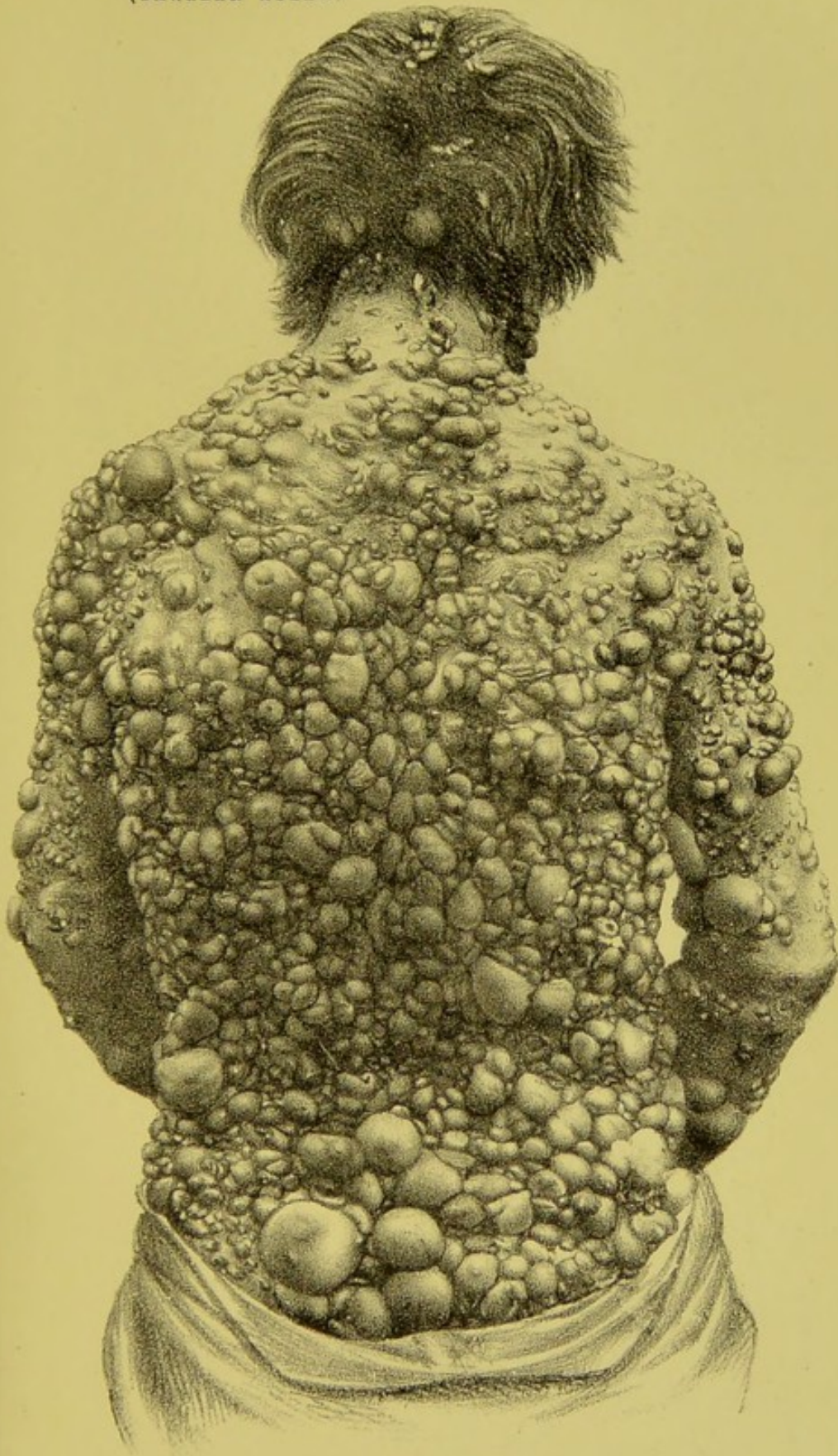




PLATE LXV.  
MOLLUSCUM FIBROSUM.



SEE description of Plate LXIV.







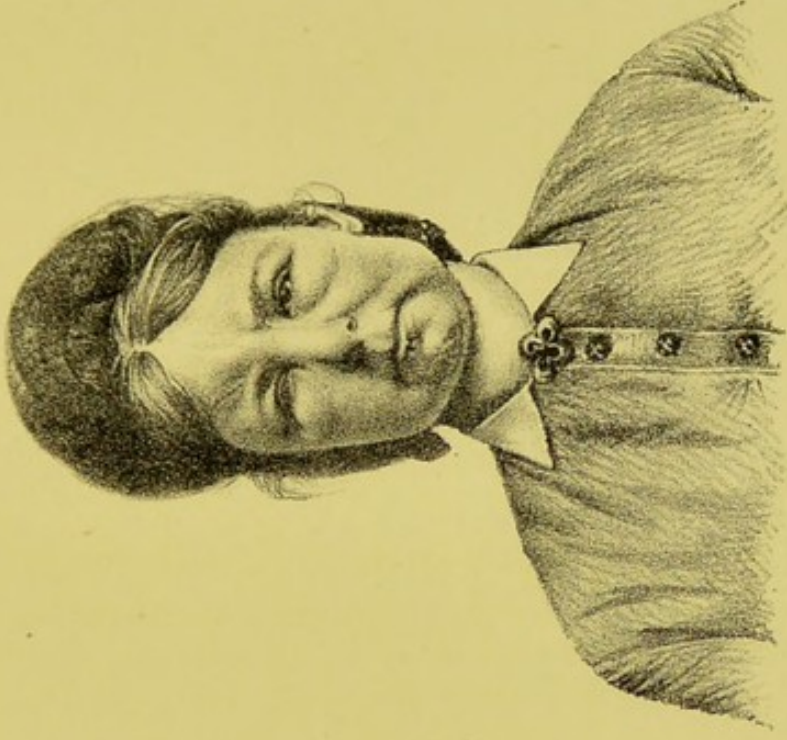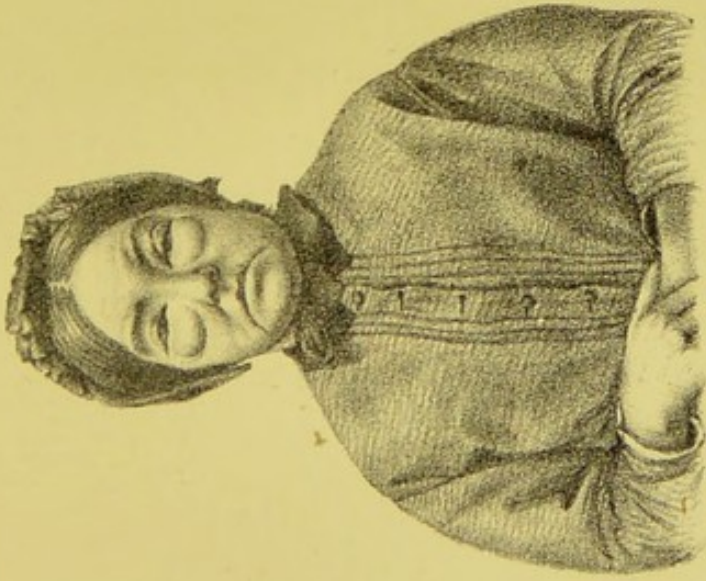## PLATE LXVI.


### SOLID ŒDEMA OF THE EYELIDS.




THIS Plate shows the portraits of two women who were the subjects of that form of solid œdema which not unfrequently occurs as a result of repeated attacks of an erysipelatous swelling of the face. The disease may occur at any age, but is more common in adults than in young persons, and produces, as a rule, more conspicuous deformity in women than in men. I have published on different occasions a considerable number of examples of this malady. The usual history is that the patient has been liable for years to recurring attacks of erysipelas, transitory in duration and limited to the face, but attended with very considerable œdema.

The final condition is one allied to Elephantiasis. The disease is almost wholly local.









## PLATE LXVII.

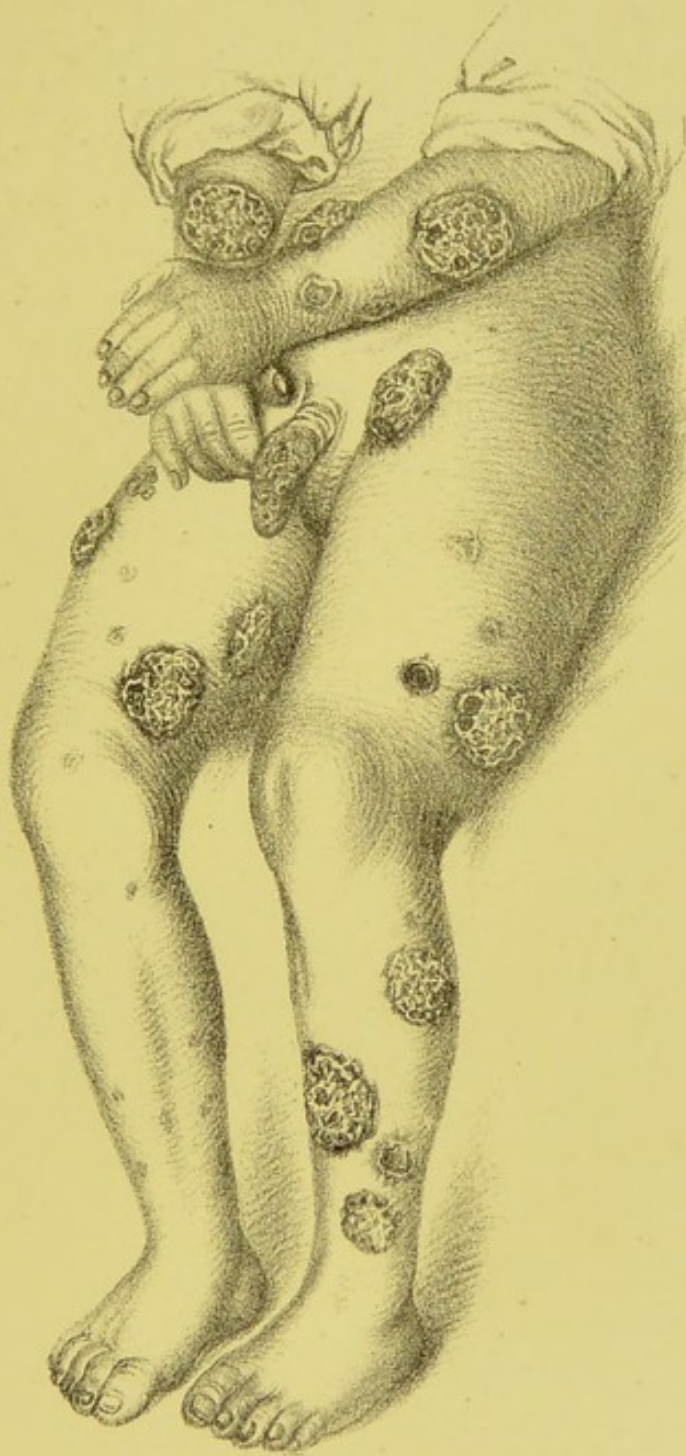
### MULTIPLE LUPUS VULGARIS.


---

THIS portrait shows the earlier stage of the same case as that depicted in Plate LXVIII., the interval being about five years. The patient was a healthy boy, in whom, at the age of about three, an acute general eruption occurred, the nature of which was not easily recognised. Some of the patches were almost rupial, whilst others were lichenoid or pustular. At a later stage, however, many of the smaller spots had disappeared, whilst the larger ones had extended into patches characteristic of lupus vulgaris. It will be seen that the individual patches in Plate LXVIII. are very much larger than those in LXVII.

In Plate LXVII. it will be seen that the whole of the prepuce is involved in a lupus patch. In Plate LXVIII. this had been removed by excision. A full narrative of this case is given in my Harveian lectures on lupus, which will shortly be reprinted. The boy is now about twelve years old. He is well grown, and in fair health, but is almost covered by huge patches of exfoliative lupus.

Coloured portraits representing the face of the same patient in the two different stages of the disease will be found in Plates LXXVI. and LXXVII.



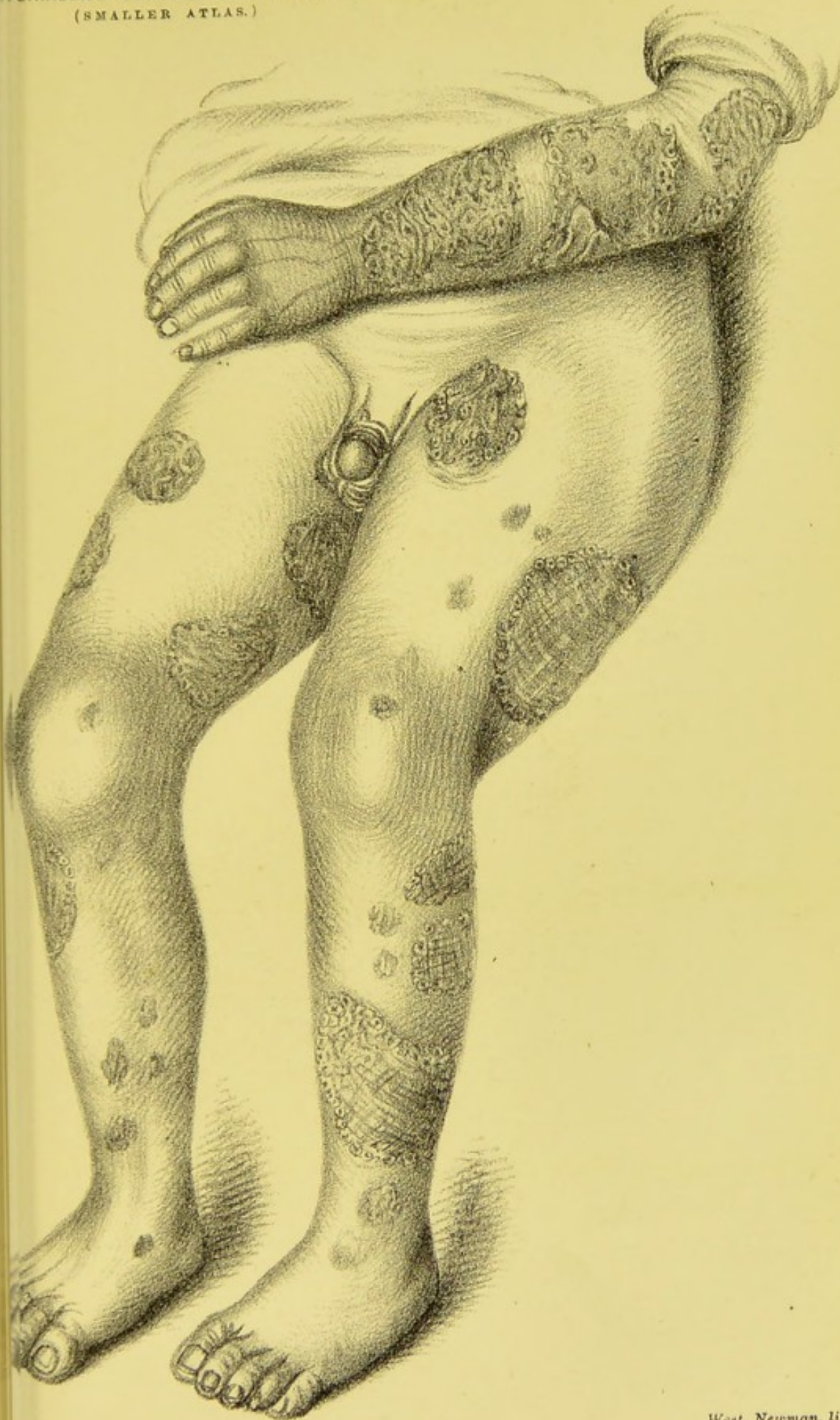



Faint, illegible text, possibly bleed-through from the reverse side of the page.


## PLATE LXVIII.



THIS portrait represents the condition of the lupus patches in the boy Ll — n, who was also the subject of Plate LXVII. A comparison of these two Plates shows the extent to which the disease had advanced during the four years which had intervened between the dates at which they were taken. It will be seen that all the patches are much larger in size, and that in some places several have coalesced. The prepuce, which in the first Plate is seen to be involved in lupus, has in the second been removed by circumcision. The Plate is not to be regarded as anything more than a map indicating the size of the patches.









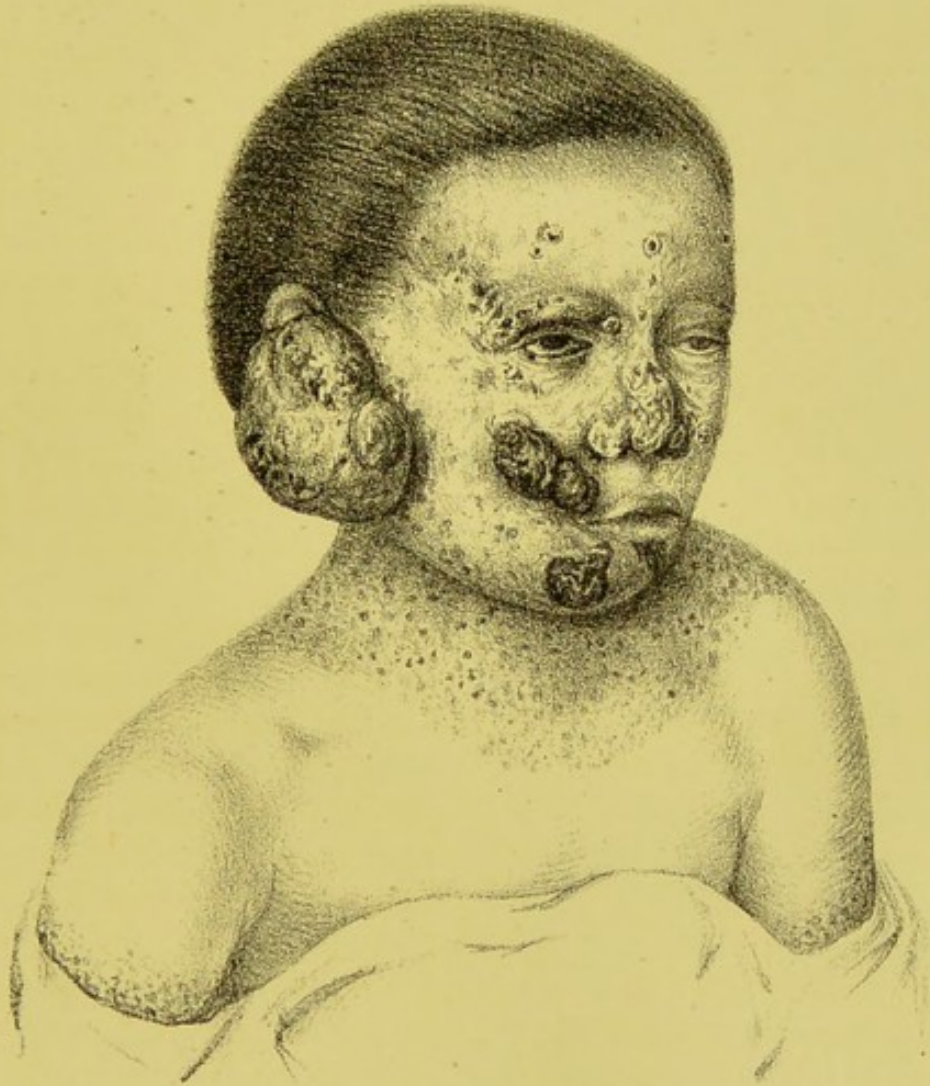## PLATE LXIX.


### KAPOSI'S DISEASE.

(XERODERMIA PIGMENTOSUM. LENTIGO MALIGNA FAMILIE.)

---

THIS lithograph has been copied from a portrait kindly lent to me by Dr. Radcliffe Crocker. It is taken from a patient whom I had myself seen. I reproduce it on the present occasion, in order to illustrate the suggestion that the malady known as Kaposi's disease ought possibly to rank as a family form of lupus. It has perhaps a nearer relation in certain particulars to lupus erythematosus than to lupus vulgaris, but it probably partakes of the characters of both. It might possibly be suitably known as lentigo lupus, or the lupus that attacks freckles. It is a family disease, almost always attacking three or four members of the same family, and commencing in early life. It is clearly evoked under the influence of exposure to sunlight, and its first stage is one of extensive freckling, affecting the face and hands. Next follows a stage of ulceration, and bossy masses of granulation grow out; and finally there is a tendency to develop fungating masses, which are of the character of epithelial cancer. In most of these features it has close parallels to certain cases of lupus. In the portrait given it will be seen that the girl's neck is covered with freckles. The tip and alæ of the nose have been destroyed, almost in the same manner so often seen in lupus; whilst on various parts of the face, more especially just in front of the right ear, there are ulcers, covered by bossy masses of soft granulation-structure. That on the ear was, I believe, already carcinomatous. Three or four brothers and sisters suffered from the disease. The cases have been fully published by Dr. Radcliffe Crocker in the 'Medico-Chirurgical Transactions.'





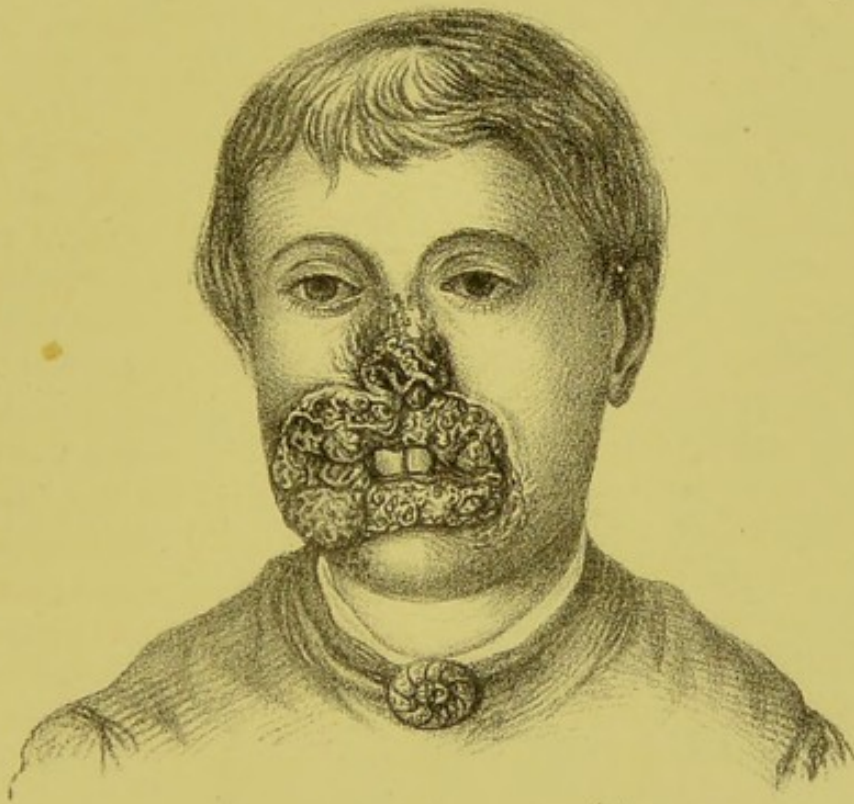



## PLATE LXX.


### LUPUS VULGARIS AFFECTING THE NOSE AND LIPS.



THIS Plate is the portrait of a young lady who died of pulmonary phthisis about a year after it was taken. She was of a somewhat delicate family, and one of her sisters suffered from lupus of the septum nasi. There was no syphilis in the case. The portrait was taken in order to show the very extensive ravages which occasionally attend lupus when it attacks the lips. It will be seen that the whole of the parts around the mouth have been destroyed, together with the entire upper lip and a great part of the nose. The ulcer was usually crusted over with a thick scab, and readily bled when the latter was removed. The treatment had, in the earlier part of the case, unfortunately been neglected, on account of the patient's unwillingness to submit to the pain which it caused. Had she survived, it is probable that the final condition, after cicatrisation, would have resembled that shown in the woodcut given at page 376, 'Archives,' vol. iv.









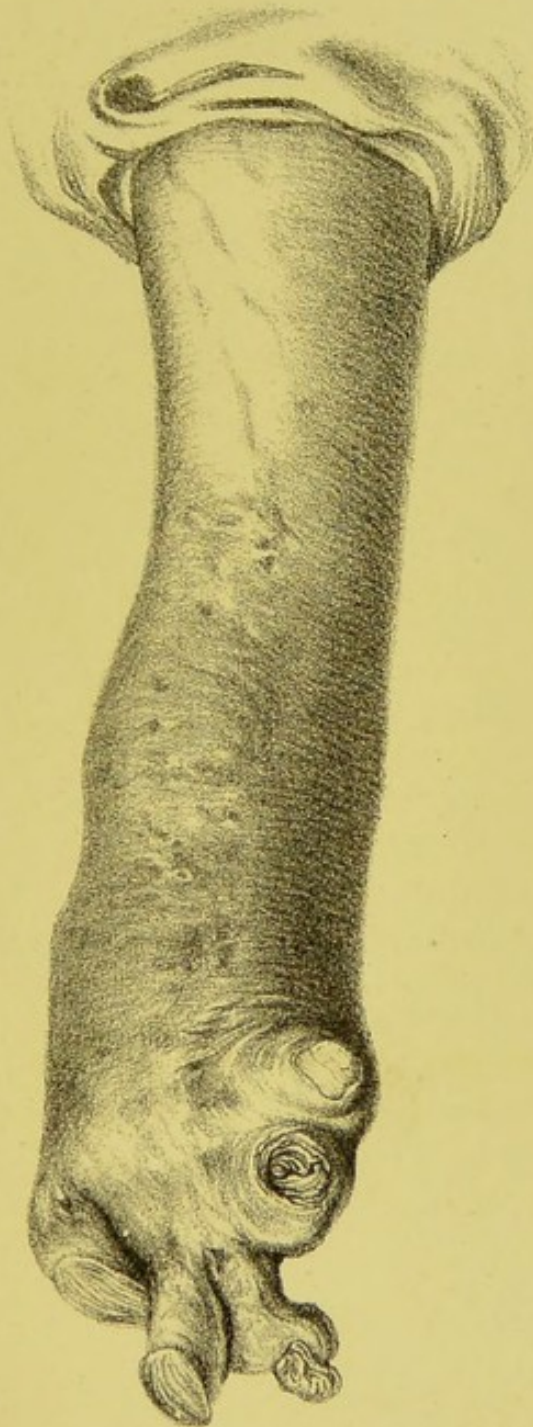
## PLATE LXXI.


### LUPUS MUTILANS.

---

IN this lithograph we have shown the hand of a young woman, in whom lupus had commenced in early childhood. The skin of the entire hand and of the lower part of the forearm had been reduced to a condition of scar. The two ulnar digits had been entirely destroyed, and the other three shortened and deformed. The mutilation much resembles that which is sometimes seen in cases of leprosy. It had been brought about partly by exfoliation of the bones of the digits, and partly by their interstitial absorption.

I have seen but very few cases of lupus mutilans approaching the condition here shown. In all it was associated with lupus vulgaris on other parts, and in all the disease had begun in early life. It is, I suspect, necessary to the production of the exaggerated conditions here shown that the disease shall begin in youth, and that it shall spread over the whole hand. The late Mr. Sibley once brought to me a patient suffering from lupus of the face, one of whose hands was exactly in the condition shown in this Plate. She was a lady of about thirty years of age, and had suffered from childhood. A similar condition is sometimes produced in the foot.





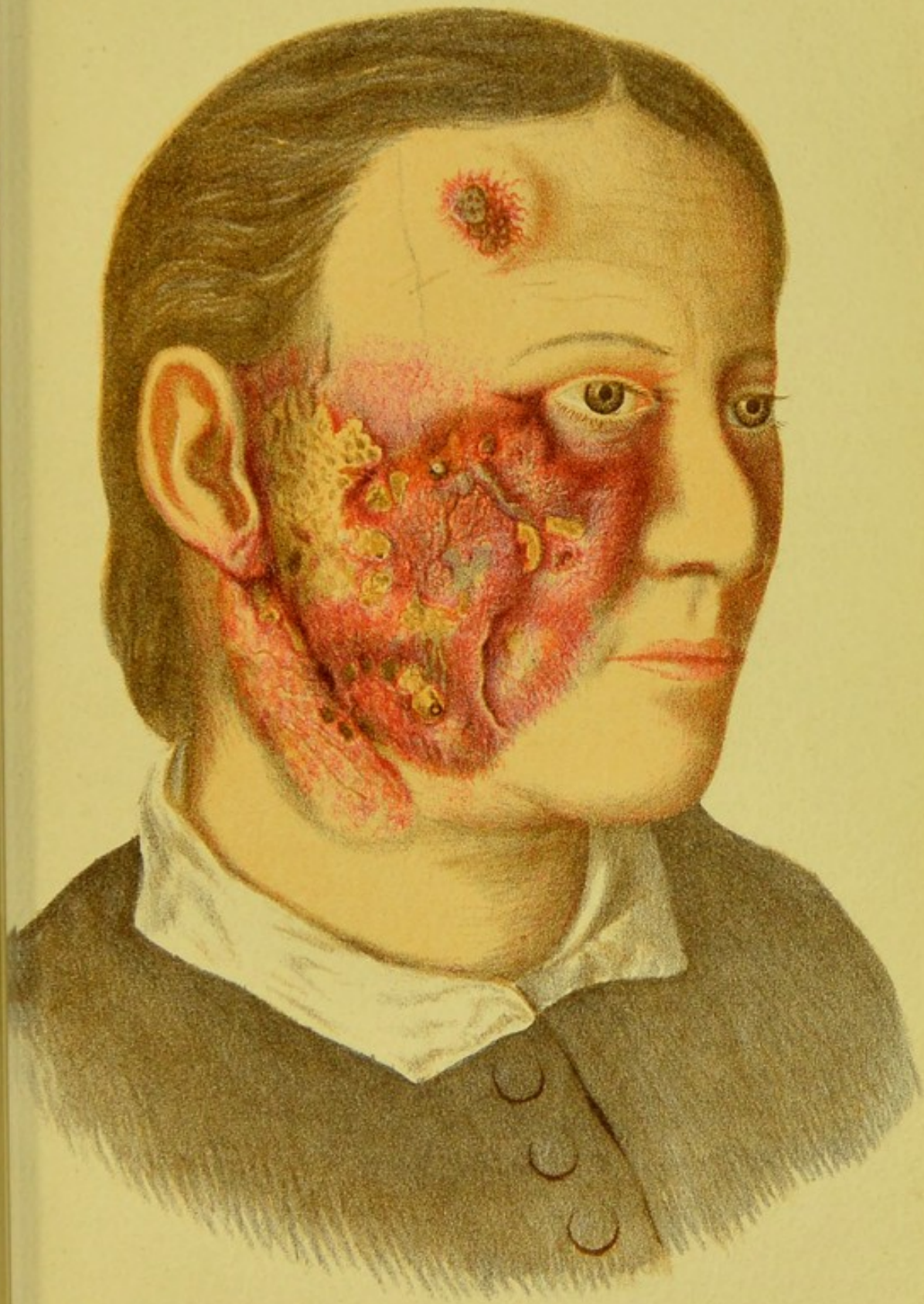



## PLATE LXXII.


### AN EXCEPTIONAL FORM OF LUPUS.

---

THIS portrait represents the face of a woman about fifty years of age, in whom the disease had existed only six months. The disease was, I believe, essentially lupus vulgaris, but presented exceptional features and had spread with immense rapidity. There was no reason whatever to suspect syphilis. The disease had commenced in the middle of the flush-patch of the cheek, and with so much inflammatory induration that it was at first suspected to be carbuncular. After a little time the swelling subsided, and the disease lapsed into a chronic form and spread by contagion-of-continuity at its edges. At the same time a satellite sore was developed on the forehead. There was no implication of the lymphatic glands, and the mode of spreading was quite characteristic of lupus. There was never at any time anything which could be recognised as "apple-jelly growth." Great benefit was obtained by free cauterisation with the acid nitrate of mercury.









## PLATE LXXIII.


### THE SEBACEOUS FORM OF LUPUS ERYTHEMATOSUS.

(Copied from Hebra's Atlas.)

---

LUPUS ERYTHEMATOSUS presents itself in different forms. In some cases the parts implicated present erythematous congestion almost solely. (A good illustration of this is given in the next Plate.) In others there is an extensive implication of the sebaceous glandular system. Comedones are frequently found, and the patches are roughened over, like a piece of orange-peel, by the open orifices of glands and little plugs of dried sebum. The portrait which is given in this Plate is one which I have copied from Hebra's Atlas, because I do not myself possess one which so well illustrates the combination of conditions characteristic of the sebaceous and erythematous form. In many cases of lupus sebaceus the disease remains long limited to the nose, and but rarely assumes the bat's-wing form, or becomes accurately symmetrical. Thus it would appear to be a sort of connecting-link between lupus vulgaris and lupus erythematosus. In this portrait, however, we see the disease very accurately symmetrical, whilst the implication of sebaceous glands is extensive and conspicuous. The margins of the patches consist of confluent groups of enlarged glands and are covered by dry seborrhaic secretion.





1875

THE HISTORY OF THE

REIGN OF KING CHARLES THE FIRST

IN WHICH IS CONTAINED A FULL AND COMPLETE HISTORY OF THE REIGN OF KING CHARLES THE FIRST FROM HIS MARRIAGE TO THE DEATH OF KING CHARLES THE FIRST

3


## PLATE LXXIV.

### THE ERYTHEMATOUS FORM OF LUPUS ERYTHEMATOSUS.



THIS Plate is the portrait of a boy who was the subject of the most superficial and purely erythematous form of lupus erythematosus. It will be seen that almost the whole of his nose is involved in erythema, and that bat's-wing patches extend symmetrically over both cheeks. There was little or no thickening, and only the slightest possible desquamation; and there is no evidence of special involvement of sebaceous glands. In this latter respect the case may be contrasted with the preceding Plate. It will be seen that on the boy's upper lip, close to the pro-labium, there is a half disc of erythema which shows more thickening than other parts. The development of satellite discs of this kind is, as all know, a very characteristic feature of the disease.





Faint, illegible text, possibly bleed-through from the reverse side of the page.



## PLATE LXXV.

### LUPUS VULGARIS IN MULTIPLE DEVELOPMENT.



THIS portrait shows a condition of most extensive multiplicity of patches of common lupus. The conditions of the several patches were quite characteristic, the "apple-jelly" growth being abundant and well characterised. The patches were spreading at their edges, and some of them already showed cicatrices in their centres. The patient had almost innumerable patches on the face, shoulders, and limbs. They were so abundant and so nearly symmetrical that I was inclined at the time to consider the case an example of lupus-psoriasis. The symmetry was, however, by no means exact or complete, and I am quite prepared to admit that the case does not differ in any feature from common lupus, excepting in the exceptional number of patches. As is usual, when lupus vulgaris occurs in multiple patches, the multiplicity was produced in the first stage of the disease. The patient was a girl about twelve years old, who was under my care at the London Hospital many years ago, and who was the subject of angular curvature of the spine with abscess.

The multiplicity of patches of common lupus, just as shown in this portrait, is well illustrated in two models in the Museum of the St. Louis Hospital at Paris. In both, as in the above, the patient was a child. The reader may also refer with interest to Plates LXXVI. and LXXVII.

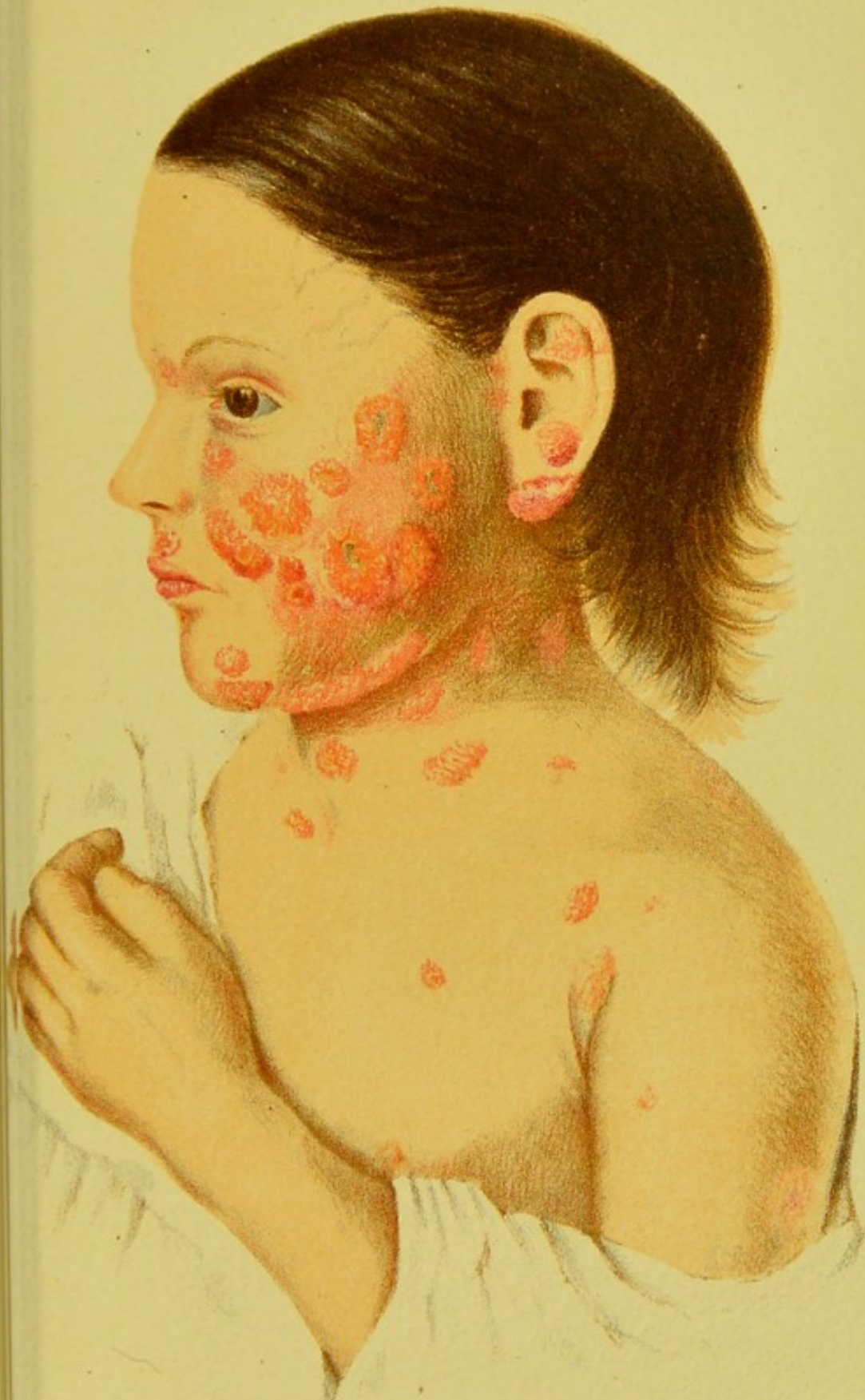






PLATE LXXVI.

MULTIPLE LUPUS VULGARIS.



PORTRAIT of a boy the subject of multiple lupus in the early stage. For the later stage, after an interval of five years, see Plate LXXVII. For further particulars see the description of Plates LXVII. and LXVIII.

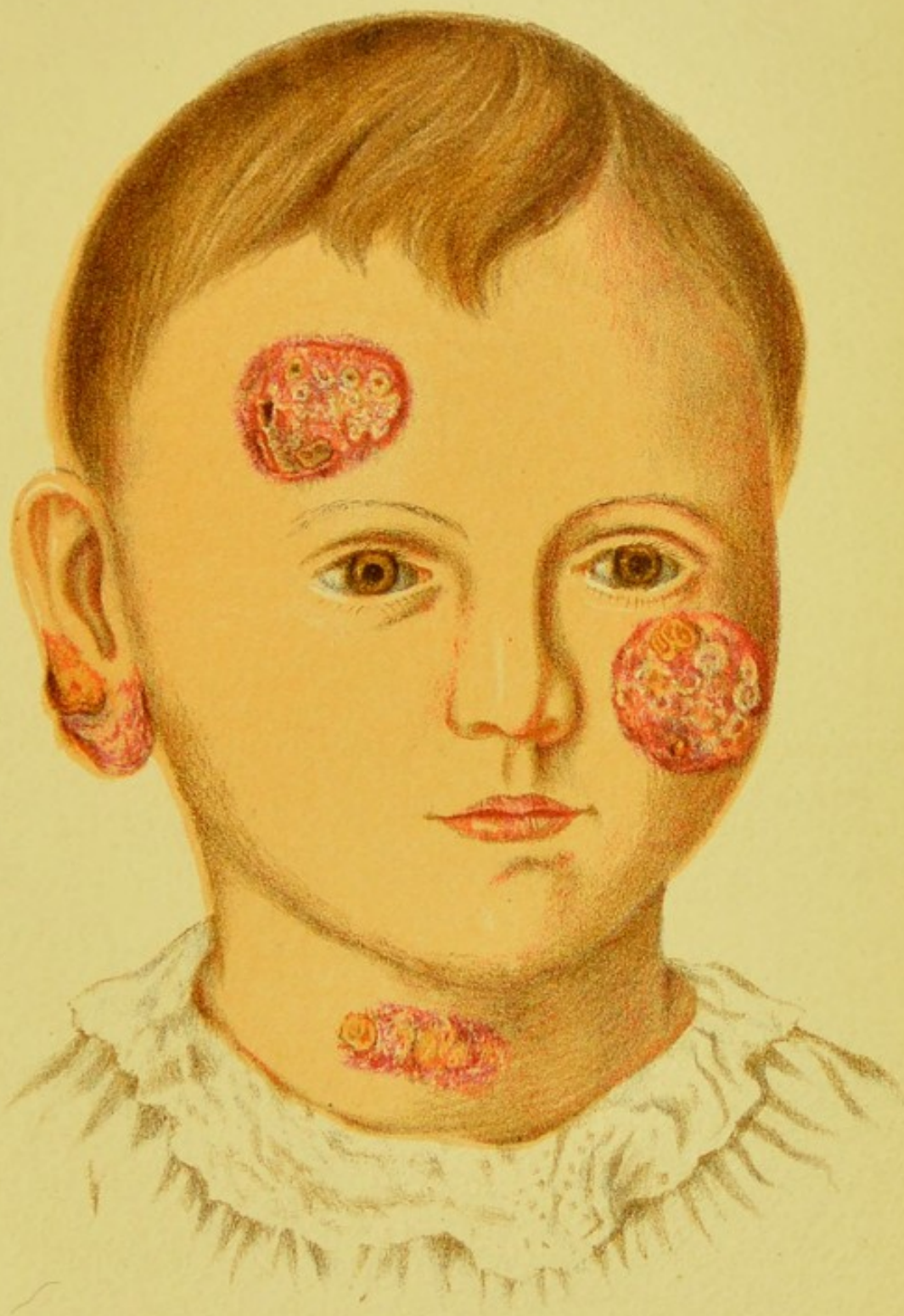






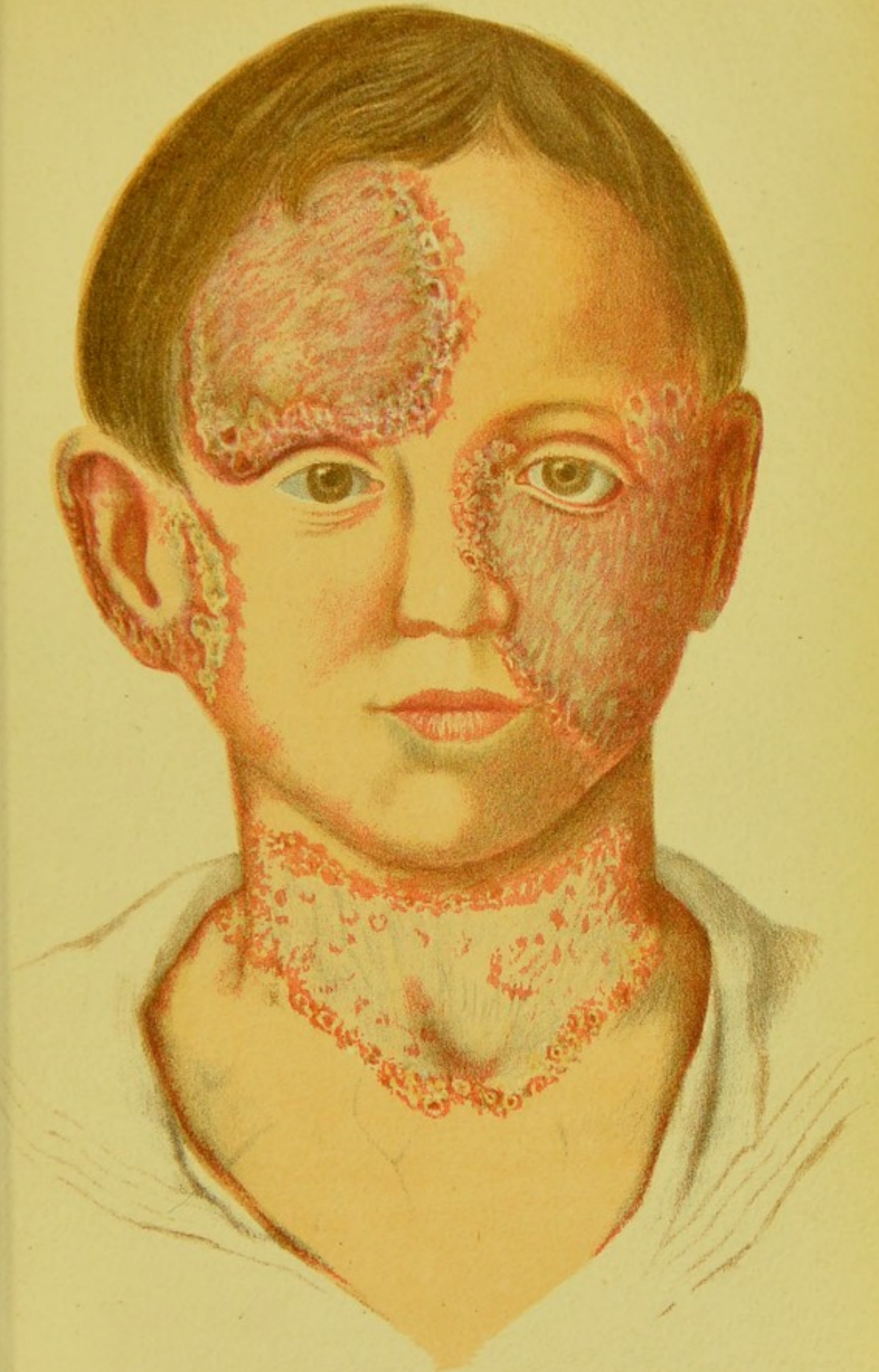



PLATE LXXVII.

MULTIPLE LUPUS VULGARIS.



PORTRAIT of a boy the subject of multiple lupus in the later stage. For the earlier stage see Plate LXXVI.; and for further particulars see the description of Plates LXVII. and LXVIII.







## PLATE LXXVIII.

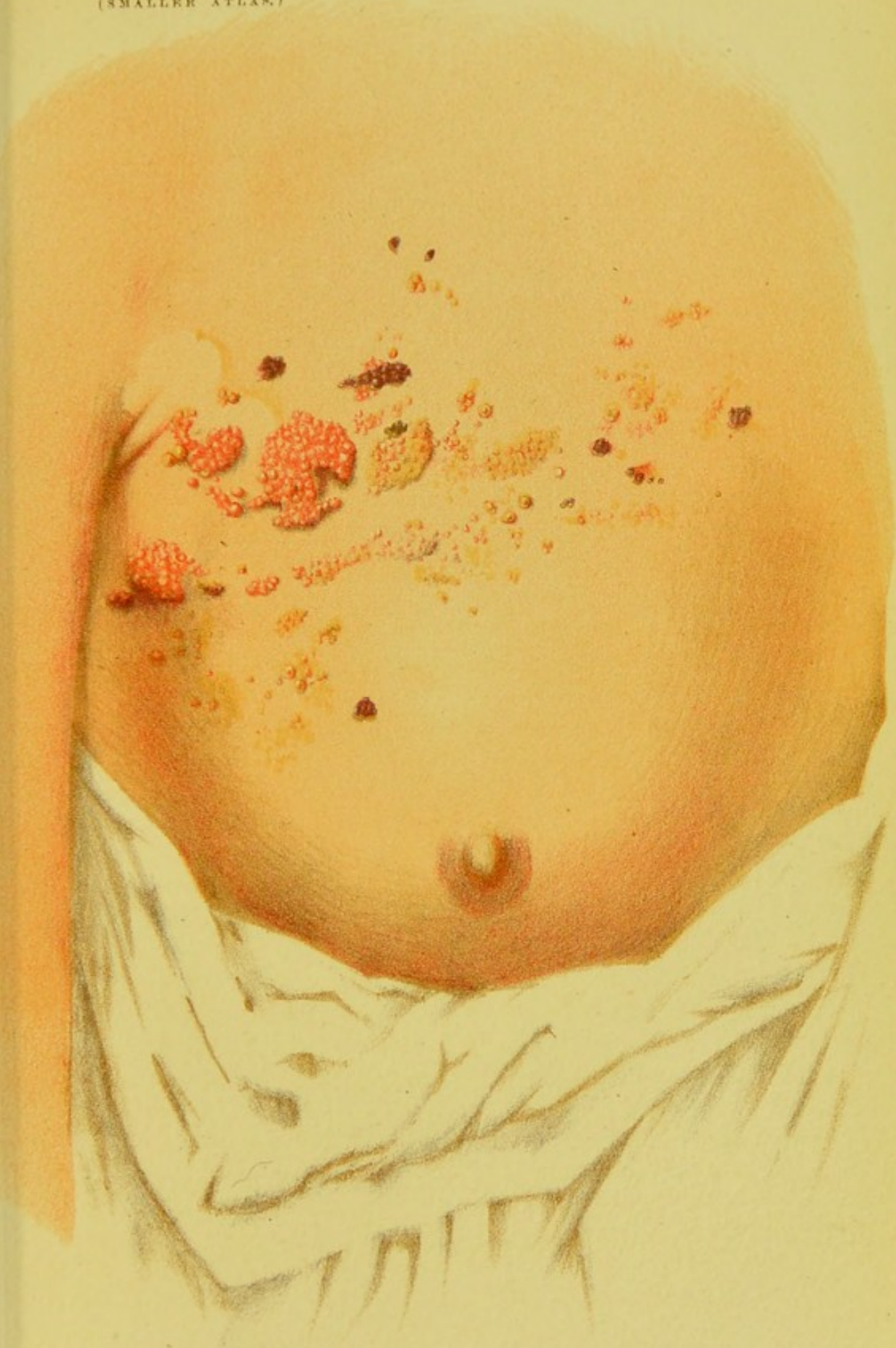### LUPUS LYMPHATICUS (LYMPHANGEIOMA).

---

THIS portrait represents the condition of the disease in Miss D——'s case before the operation. The description of the cure will be found in 'Archives,' vol. iv., page 75. Miss D—— was a young lady of 18, in excellent health. The history was that something resembling a *nævus* or port-wine stain had been observed in early childhood, although nothing had been noticed at birth. An excision-operation for a so-called *nævus* had been performed by a London surgeon in childhood. Of this the scar which remained is shown in the drawing. After this operation, the little lymph-warts, which are characteristic of the disease, began to increase in number, and to extend over the upper part of the breast. Gradually the condition of things here depicted was produced. The so-called warts were vesicles with firm walls, which contained lymph-fluid. Near to them, and sometimes upon them, were numerous little tufts of dilated capillaries, which contained blood, and which could not be emptied by pressure. Some of these were almost black in tint, and others brown, like grains of cayenne pepper. The pathological process was clearly an infective one, and the disease had advanced by the production of satellites near to the original growth.

This case is a typical example of the disease to which some years ago I gave the name of *Lupus Lymphaticus*, and of which a full description, one by the late Dr. Tilbury Fox, and another by myself, will be found in the Pathological Society's 'Transactions.' Dr. Fox was the first to describe its pathological anatomy. Anatomically it consists of persistently dilated capillaries and lymph-spaces, and may be named, as it has been by most dermatologists, *Lymphangioma*. Clinically, however, it is an infective and serpiginous malady, and very prone to attacks of erysipelas. It is curable only by complete destruction of the morbid elements. The features just named appear to me to place it in close alliance with *lupus*, although of course constituting a separate group in that family.

Compare with Plate XVI.









## PLATE LXXIX.

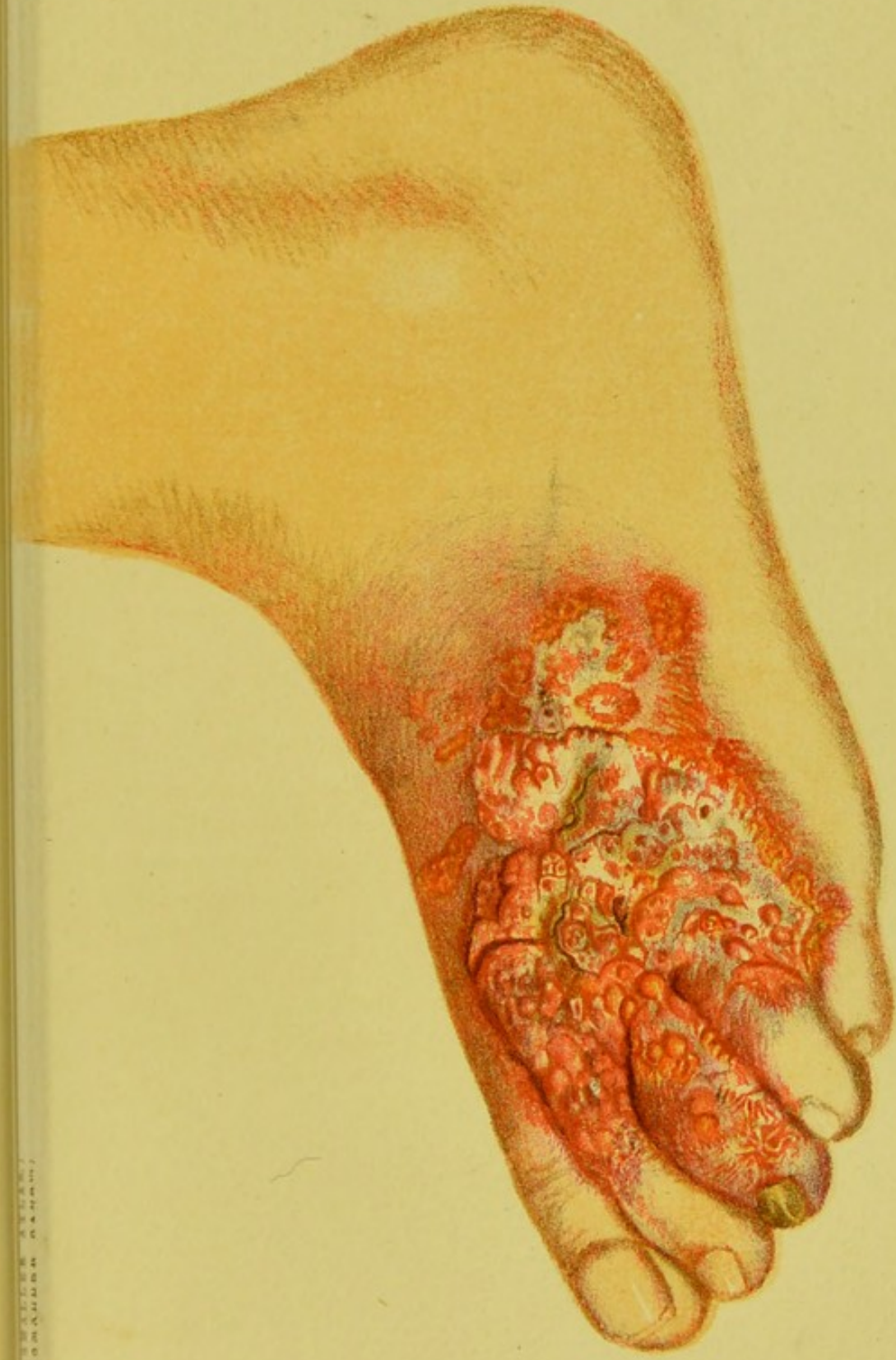
### LUPUS VULGARIS.




IN this Plate I have endeavoured to represent the conditions not unfrequently shown when lupus vulgaris attacks one of the extremities. Owing no doubt to peculiarities of the circulation in these parts, and their great liability to suffer from exposure to cold, lupus processes, when affecting them, are always attended by an excess of inflammatory action. On the hands and feet we never see the quiet, uninflamed, apple-jelly patches which are so characteristic on other parts of the body. On the other hand, œdema, congestion, ulceration, granulation masses, and thick crusts are the ordinary conditions. In the present instance the crusts have been cleared away, and ragged ulceration, with much thickening of the adjacent tissues, and bossy granulation lumps, are seen. It will be observed that the middle toe is swollen and livid. The lupus had commenced, as it often does in young persons, between the toes, and had been gradually spreading for several years. The patient was a girl of fifteen, who had lupus presenting its more ordinary conditions on other parts.


This is the condition which, when more extensive and occurring at an earlier period of life, may end in such mutilation as that shown in Plate LXXI.

West, Newman, chromo.



1 10 20 30 40 50 60 70 80 90 100 110 120 130 140 150 160 170 180 190 200 210 220 230 240 250 260 270 280 290 300 310 320 330 340 350 360 370 380 390 400 410 420 430 440 450 460 470 480 490 500 510 520 530 540 550 560 570 580 590 600 610 620 630 640 650 660 670 680 690 700 710 720 730 740 750 760 770 780 790 800 810 820 830 840 850 860 870 880 890 900 910 920 930 940 950 960 970 980 990 1000





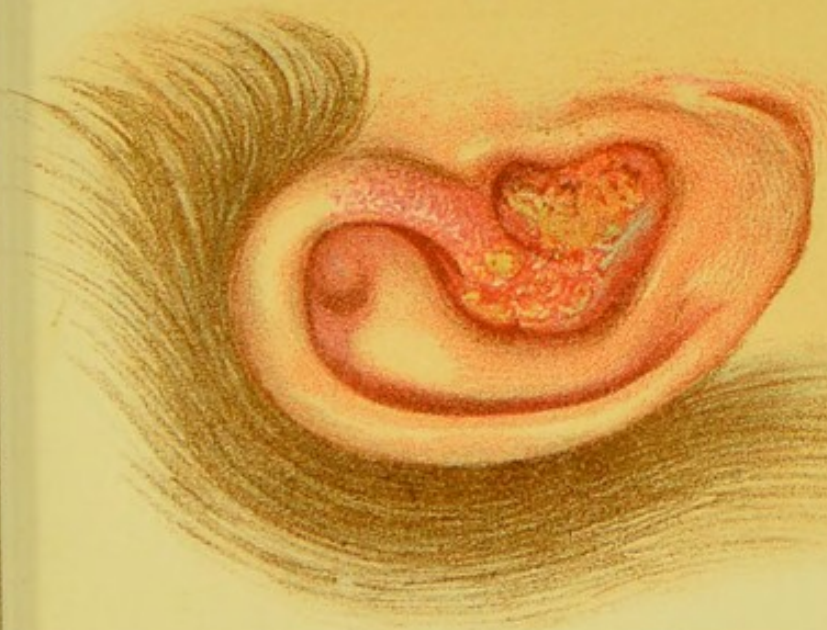
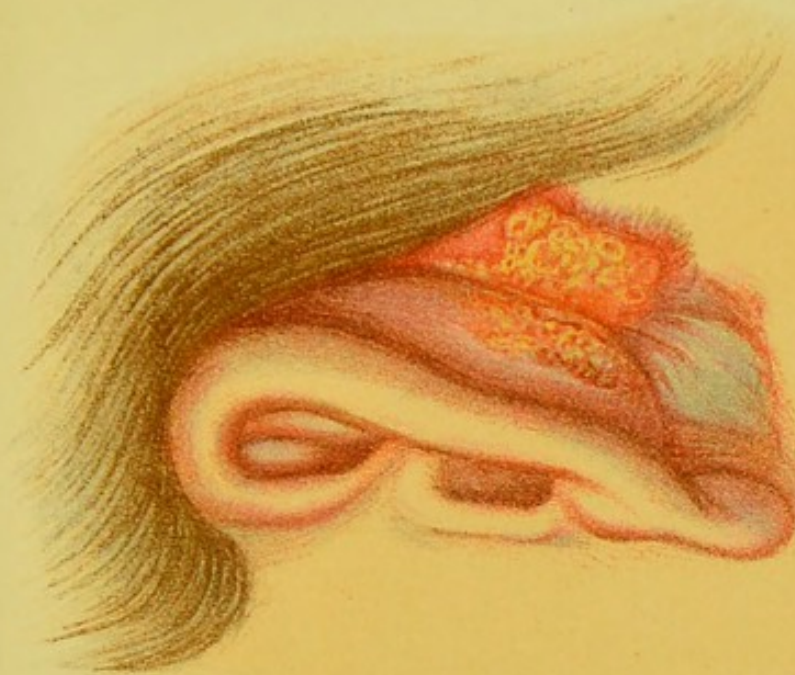
## PLATE LXXX.

### ECZEMA-LUPUS.





IN this Plate it has been endeavoured to delineate one of the forms of lupus which is often diagnosed as eczema. The patient was a young woman in whom lupus vulgaris affected both ears. On the right side it occupied the concha, and on the left it was behind the ear. Thus the conditions were not symmetrical. The disease had been present for some years. It will be seen that beneath the patch behind the left ear there is a scar. The fact that a scar is left, when the lupus process undergoes resolution, is conclusive in the diagnosis from eczema. The form of lupus to which the term eczema-lupus may be conveniently applied, is often much more peculiar and more closely resembling eczema than that delineated in this Plate. It is very superficial, and wholly unattended either by apple-jelly deposit or the granulation masses which are so common in lupus vulgaris. Its surface weeps freely, or may form a thin eczematous crust. Its resemblance to eczema is indeed so close that it is almost constantly diagnosed under that name. Its persistence, however, in spite of treatment; its extreme chronicity, and the fact that it always leaves scars as it recedes, are conclusive as to its being of the nature of lupus. It is a rare condition.

West, Neuman, chromo.



WEST, NEUMAN, CHROMO.





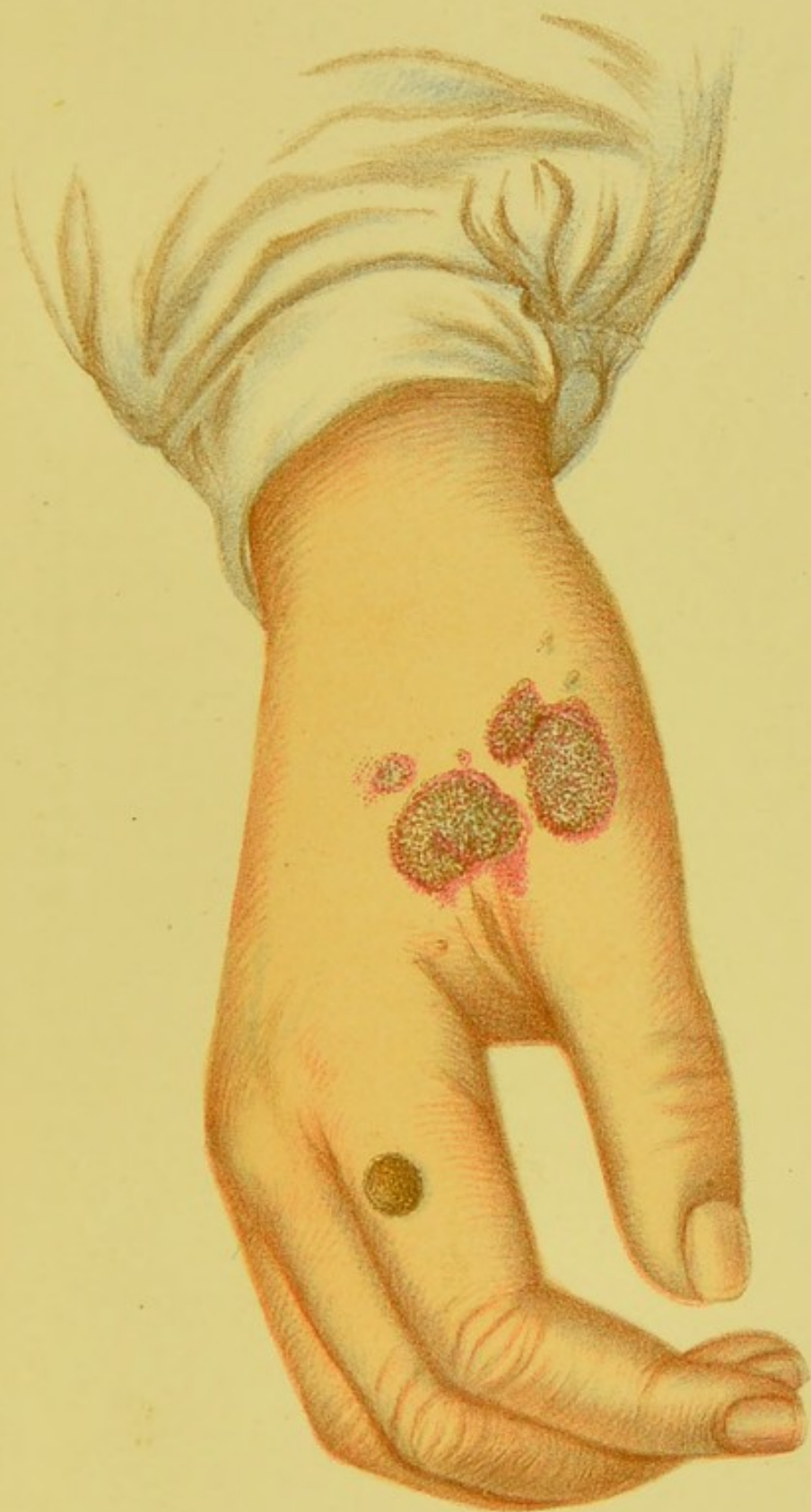


## PLATE LXXXI.

### A MIXED FORM OF LUPUS-NÆVUS.



Two conditions are represented in this sketch, which must not be confused with each other. The round spot on the back of the forefinger was nothing but a common wart, and was easily and permanently cured. The patches seen near the base of the thumb were of a totally different nature. They had been present for many years, and were gradually spreading at their edges in the manner of lupus. They were in fact just about to coalesce. They consisted in part of nævoid tissue, in part of low papillary growths. They differed from the ordinary nævoid condition in that it was not possible to empty some of the vessels by any amount of pressure. It is obvious that they also differed from ordinary nævus in their tendency to spread by infection of tissue, and to produce satellites. I possess several portraits which illustrate different stages of this case. The patient was a girl, aged about twelve. After she had been for a year or more under my observation, she was operated upon at one of our hospitals by the actual cautery. A very large and deep sore was produced, which was long in healing. After healing was complete the scar took on a nævoid condition, which at present, six years later, it still displays. There is, however, no longer any tendency to papillary growth.





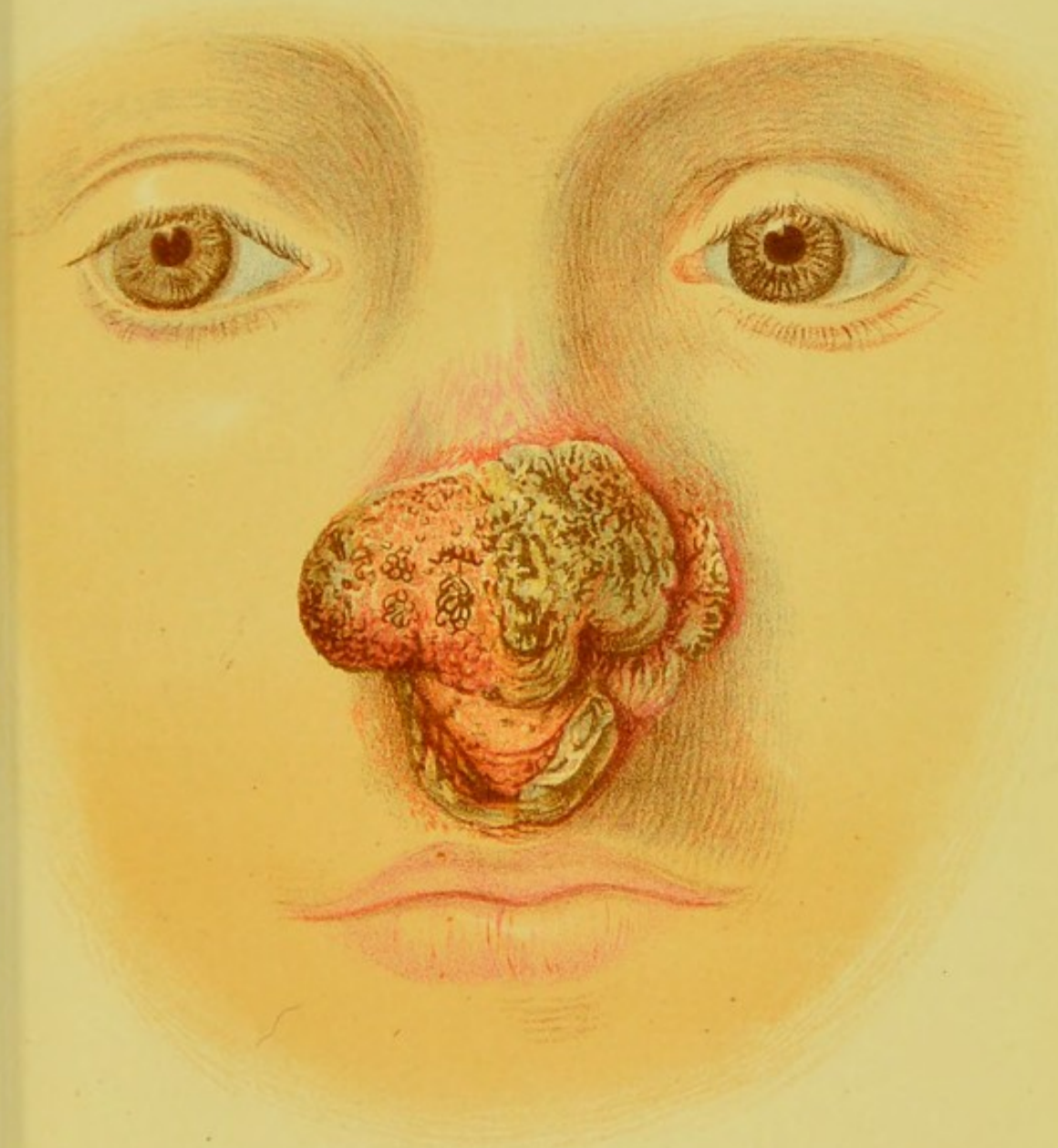



## PLATE LXXXII.

### LUPUS VULGARIS OF THE NOSE.



THE tip of the nose partakes of the peculiarity, as regards its nutrition, circulation, and liabilities to disease, of the hands and feet. Like them it is liable to chilblains and to frostbite. When affected by lupus, the process is almost always attended by excess of inflammation. The part swells, ulcerates, and becomes covered with scab. The quiet stage of apple-jelly infiltration is rarely observed. These statements are well illustrated in the Plate here given. It was from a girl, aged about seventeen. The proneness to ulceration, when the nose is attacked by lupus, led in former days to the use of such expressions as "lupus exulcerans," "lupus exedens," and the like. It is now well recognised that these adjectives were applied rather to peculiarities assumed by the lupus process on a special part of the body, than to any specialised form of the disease. Lupus at the end of the nose is, in nine cases out of ten, attended by ulceration and destruction of the part (*exedens*).





THE  
 HISTORY OF THE  
 UNITED STATES OF AMERICA  
 FROM 1763 TO 1876  
 BY  
 CHARLES A. BEAN

This work is published by the  
 American Historical Association  
 and is one of the most valuable  
 contributions to the history of  
 the United States. It is a  
 comprehensive and accurate  
 account of the events of the  
 century, and is written in a  
 clear and concise style. It is  
 a valuable work for all who  
 are interested in the history  
 of the United States.

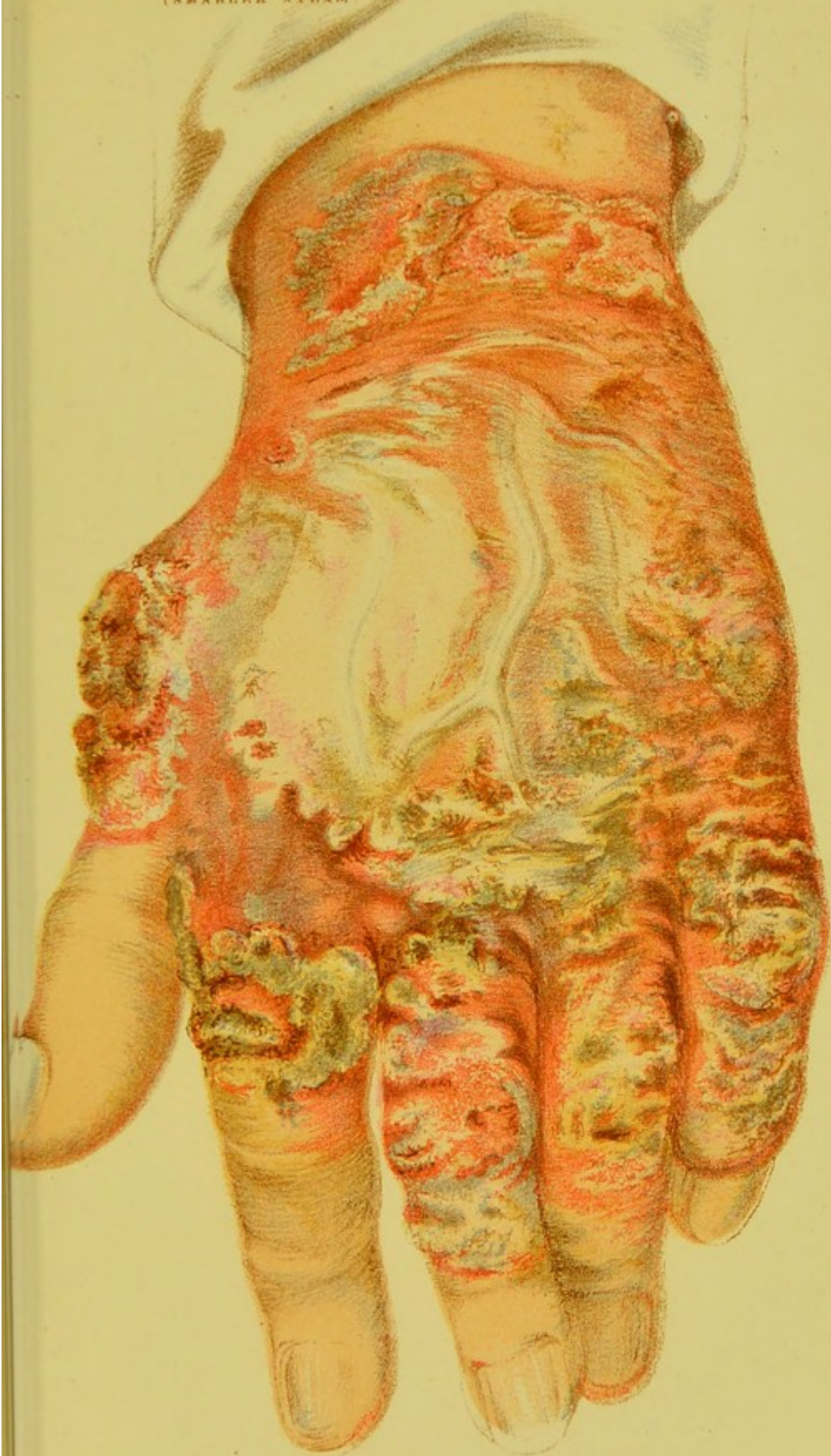


## PLATE LXXXIII.

### LUPUS VULGARIS OF THE BACK OF THE HAND.

---

I HAVE copied this Plate from one given in Hebra's 'Atlas,' since it shows better than any that I possess of my own the ravages of lupus on the hand. It will be seen that the whole of the back of the hand, including most of the fingers, is occupied by an inflamed ulceration which presents a thin scar in the middle, and at its borders is covered with crust. It is one of the most ordinary conditions of lupus in this situation. When lupus affects either the hand or the foot, it is always attended by an excess of inflammatory action, and usually by the formation of crusts. In these situations we never or very seldom see it in a quiet condition, and anything approaching to the apple-jelly formation never occurs. It varies much, however, in relation to the vigour of the health of the patient, and to the time of year, being always more inflamed when the patient is out of health, and when the weather is cold. The conditions shown in this Plate are not unfrequently seen on the hand coincidentally with the more ordinary conditions of the quiet lupus patch on other parts. A good illustration of inflamed lupus on the foot is given in my large 'Atlas of Clinical Illustrations,' and one showing the deformation of the hand consequent upon very severe lupus beginning in early life is shown in Plate LXXI.





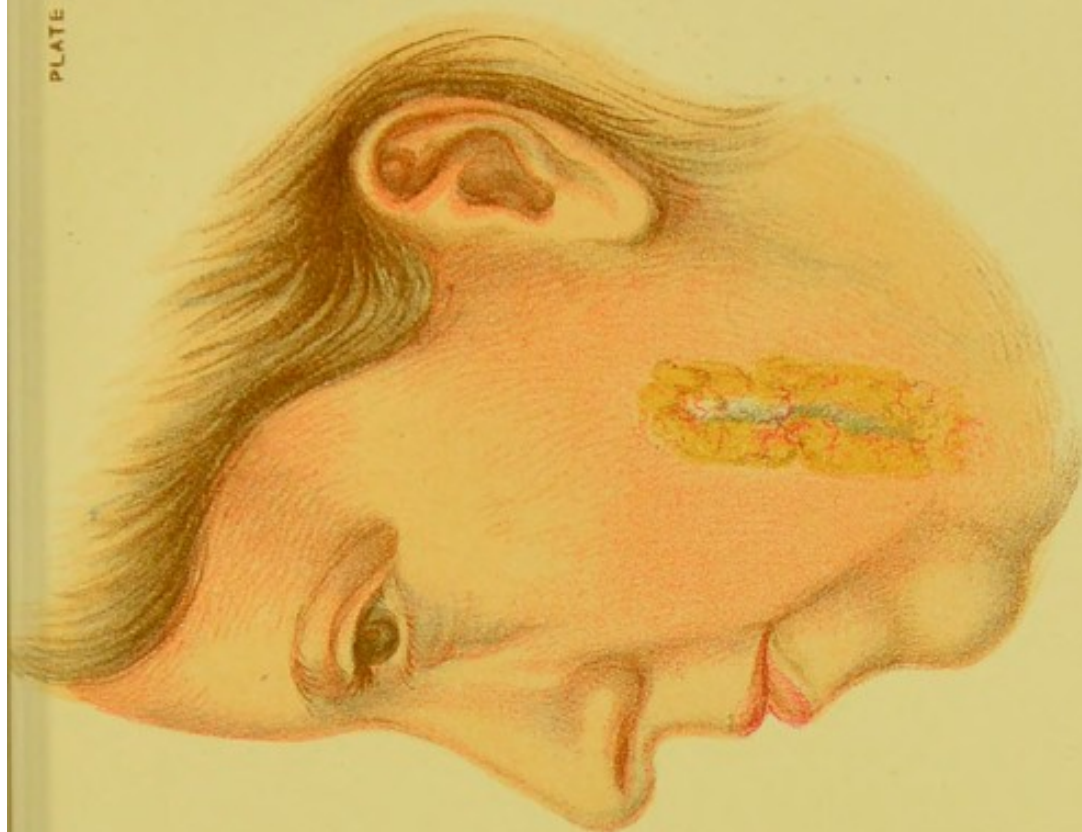

## PLATE LXXXIV.

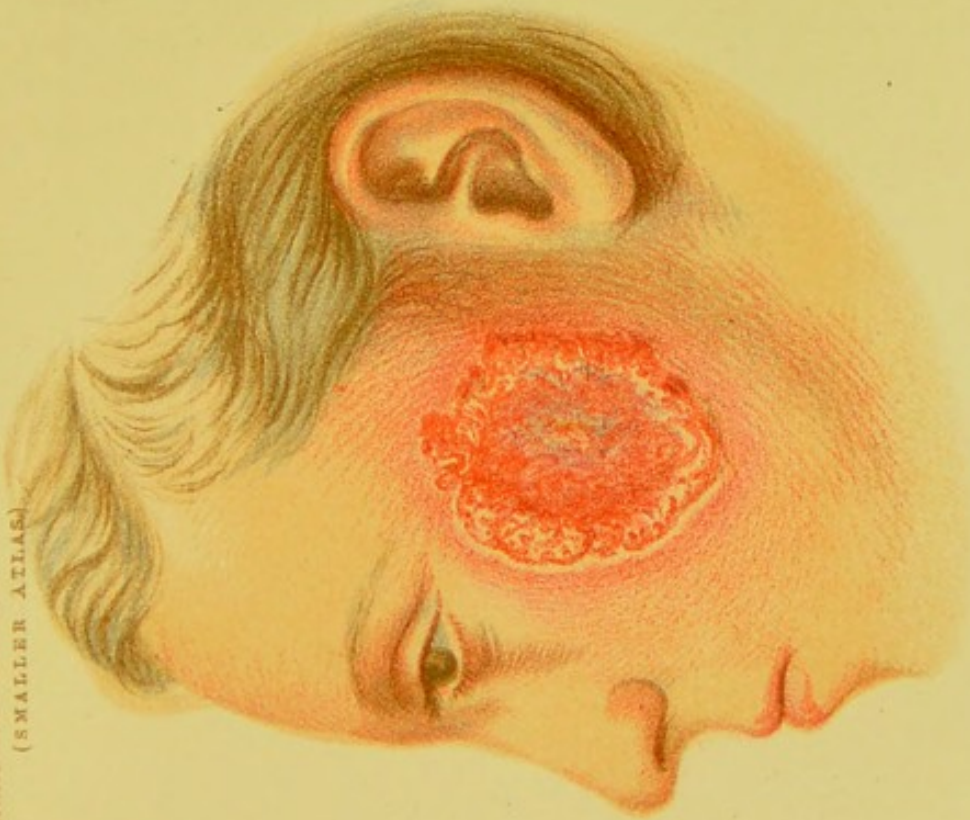LUPUS VULGARIS OF THE MOST CHRONIC FORM.




IN this Plate two portraits are copied, both from adults of middle age, in each of whom a single patch of lupus on the cheek had been present for many years. In both instances the patients were in good health, and there were no other evidences of struma. The disease had accordingly spread very slowly, and had for the most part been unattended by any inflammatory action. Neither of the portraits have been very successfully copied by the lithographic artists, and consequently the apple-jelly condition is not so well shown as could be wished. In both cases it was in the patient exceedingly characteristic. It will be seen that in both cases, as is usual, there is the formation of scar in the middle of the patch. In the case of the woman the freedom from congestion is properly represented; but in that of the man the colouring is much too high. It is for these cases of single-patch, uninflamed lupus, that the operation of excision is especially advisable.



HUTCHINSON'S CLINICAL ILLUSTRATIONS  
(SMALLER ATLAS)







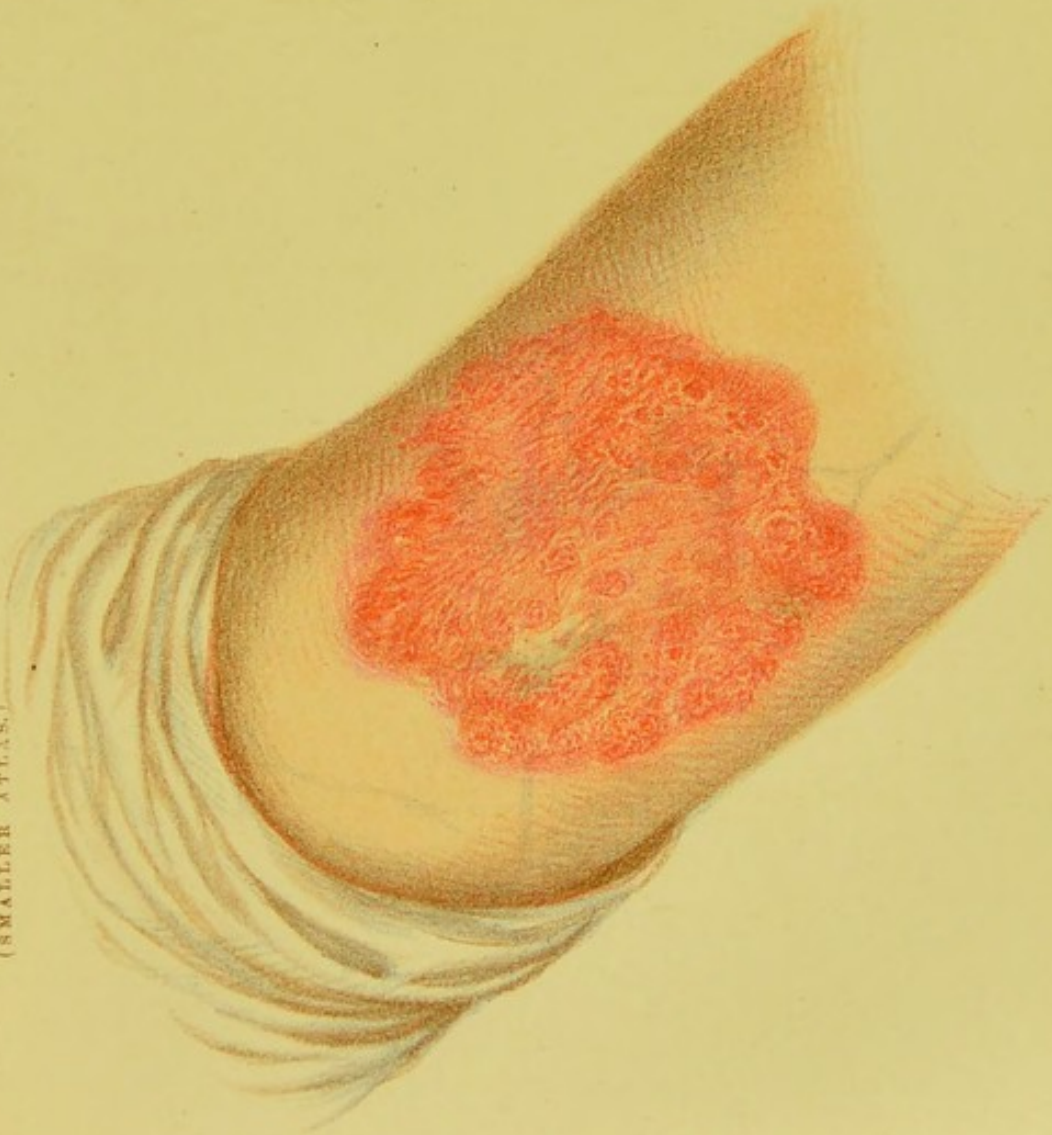


## PLATE LXXXV.

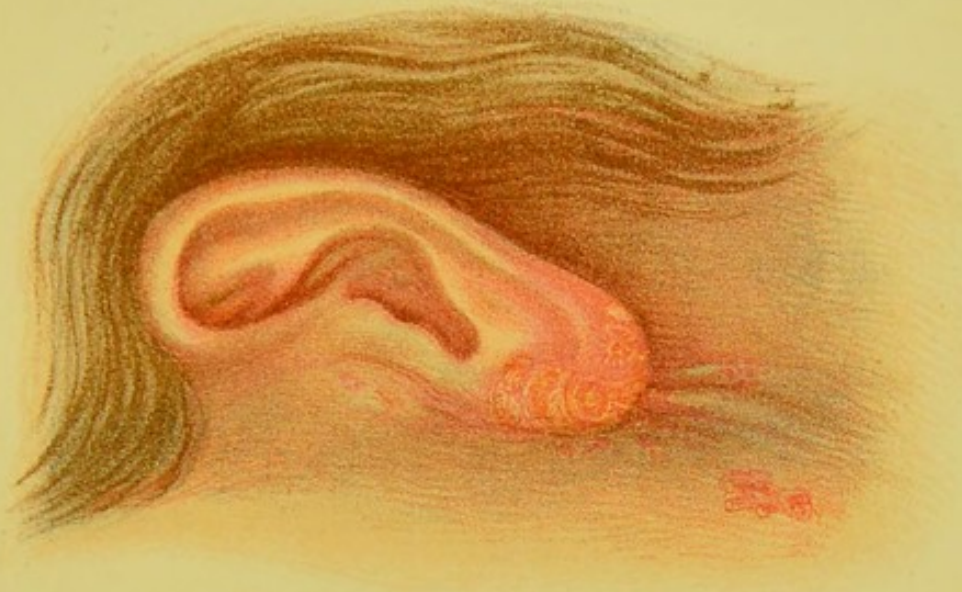
### LUPUS VULGARIS.




IN these portraits, from the same patient, patches of lupus vulgaris of a very superficial kind are represented upon the arm and ear of a young woman. The apple-jelly condition is not characteristically seen anywhere. The patch on the arm shows indolent tubercles on some parts of its edge, and a scar in its centre. On the ear the lobule is affected, and on the skin of the neck, immediately beneath it, there are satellite spots so superficial that they might almost rank as eczema-lupus.



HUTCHINSON'S CLINICAL ILLUSTRATIONS.  
(SMALLER ATLAS.)





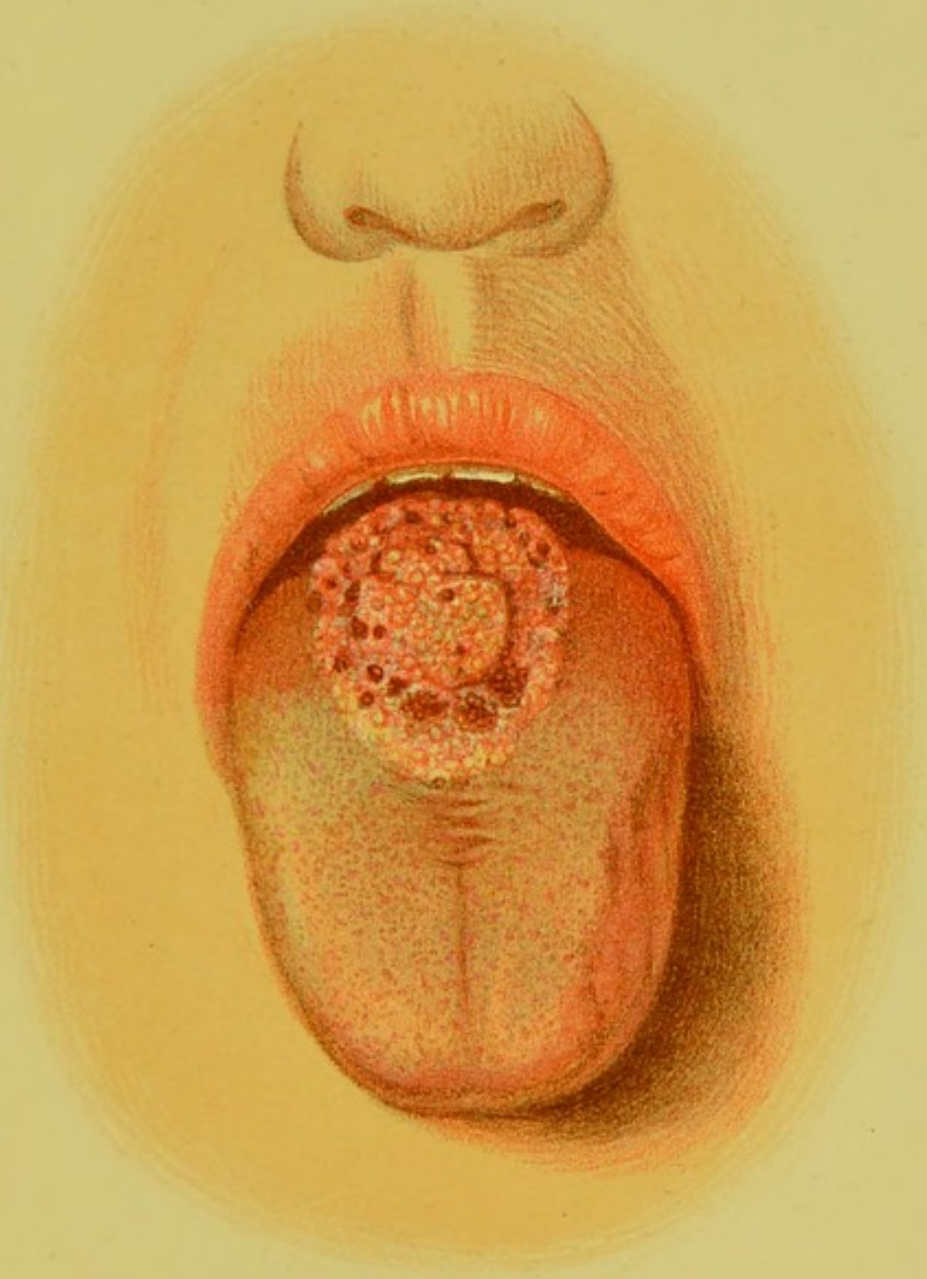


## PLATE LXXXVI.


### INFECTIVE LYMPHANGEIOMA OF THE TONGUE—LUPUS LYMPHATICUS.



IN this portrait is represented a round elevated patch in the middle of the dorsum of the tongue of a young girl. The patch consisted of clear lymph-vesicles which had coalesced, and amongst which were many tufts of dilated capillaries. The latter contained very dark blood. These conditions are exactly the same as those seen in lupus lymphaticus of the skin. The pathological process and its results are the same in the mucous membrane as in the skin, and in each instance the disease is infective, and may continue to spread slowly for many years. It is also, in whatever situation it may occur, liable to attacks of erysipelatoid swelling. In the patient who was the subject of this sketch the patch was excised and cauterised. I possess several other portraits showing this curious disease affecting the tongue.







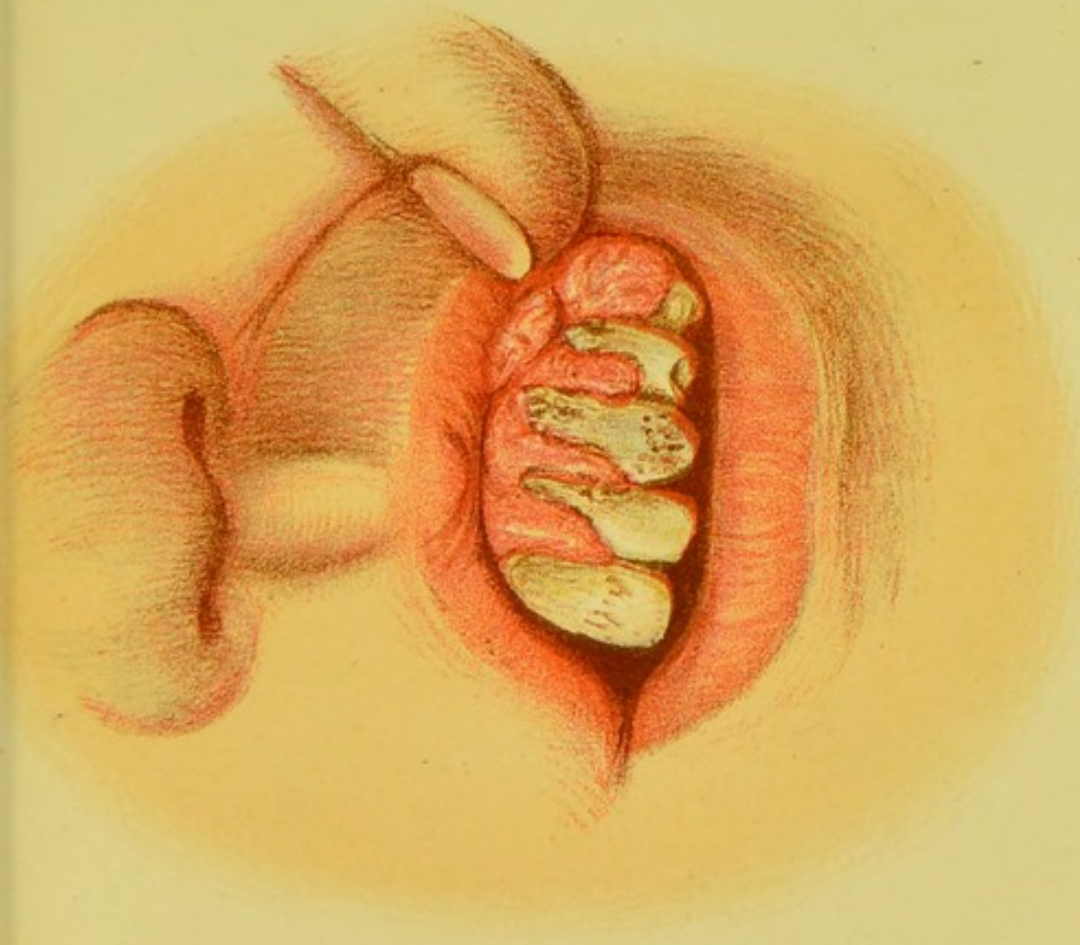
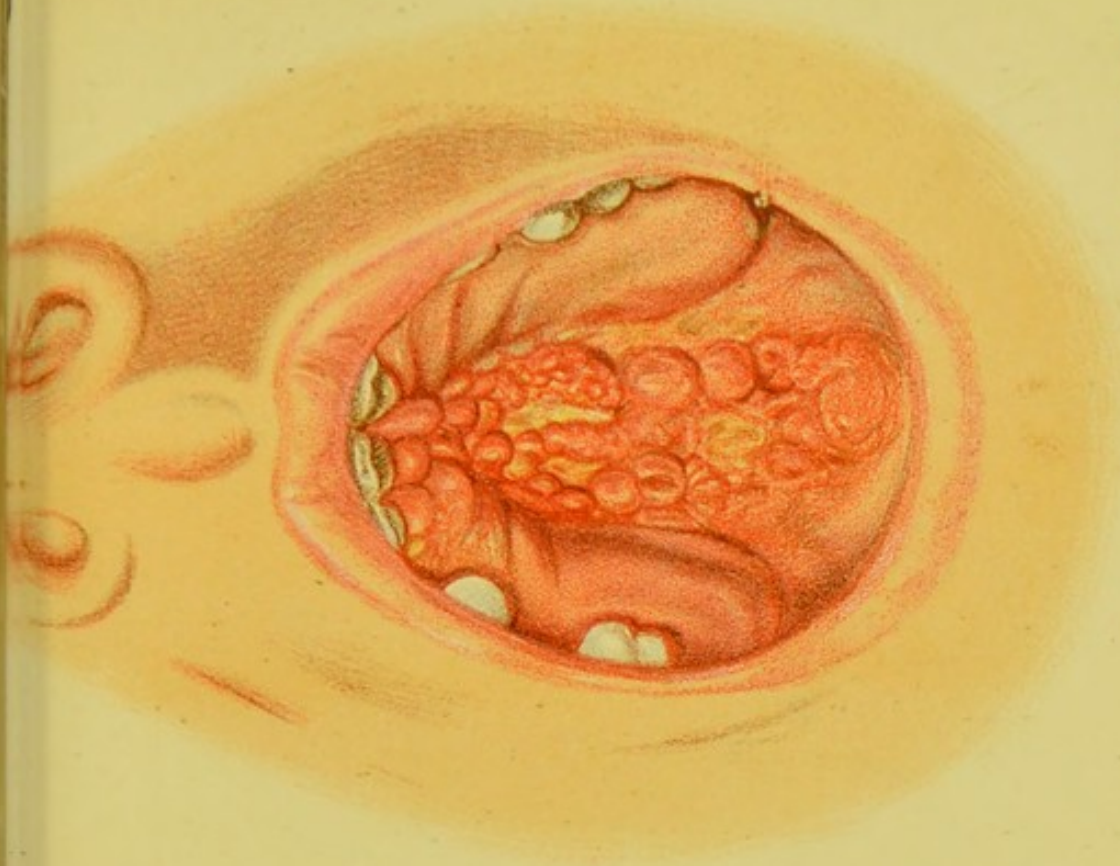



## PLATE LXXXVII.


### LUPUS VULGARIS OF THE GUM AND PALATE.



THIS Plate shows delineations, from two different patients, of the ordinary conditions of lupus vulgaris when it affects the mouth. In each instance the patient was a young woman, and the subject of lupus on other parts. In the portrait representing the gums it will be seen that the fangs of the teeth have in part been laid bare, and that masses of soft, swollen tissue bulge between them. In the portrait representing the hard palate the condition is one of ulceration, with the formation of soft, fleshy tubercles.







## PLATE LXXXVIII.

### GALL-STONES.



FIG. 1 in this Plate is copied from Richter's medical and surgical observations. It shows probably one of the largest gall-stones ever described. It weighed three ounces and five drachms. It broke into three pieces during removal. It occupied the ductus communis, and was bathed in fluid bile. The thick end of the stone bulged into the duodenum, whilst the more pointed one was in the neck of the gall-bladder. The patient was a man aged forty, who died in the hospital of Gottingen. He had had a long and severe illness, and had suffered from jaundice for four years, his skin being in parts almost black. There were thirty smaller gall-stones in the gall-bladder.

Fig. 2 is given to show the size of a gall-stone in section which had been voided by an old woman after nine days' severe illness. It weighed 160 grains, and had a diameter of an inch and two lines. A synopsis of the patient's illness is given at page 9 of 'Archives,' vol. iii. She had been so ill that she was not expected to live, but after voiding the stone made a rapid recovery.

HUTCHINSON'S CLINICAL ILLUSTRATIONS.  
(SMALLER ATLAS.)

Fig. 1

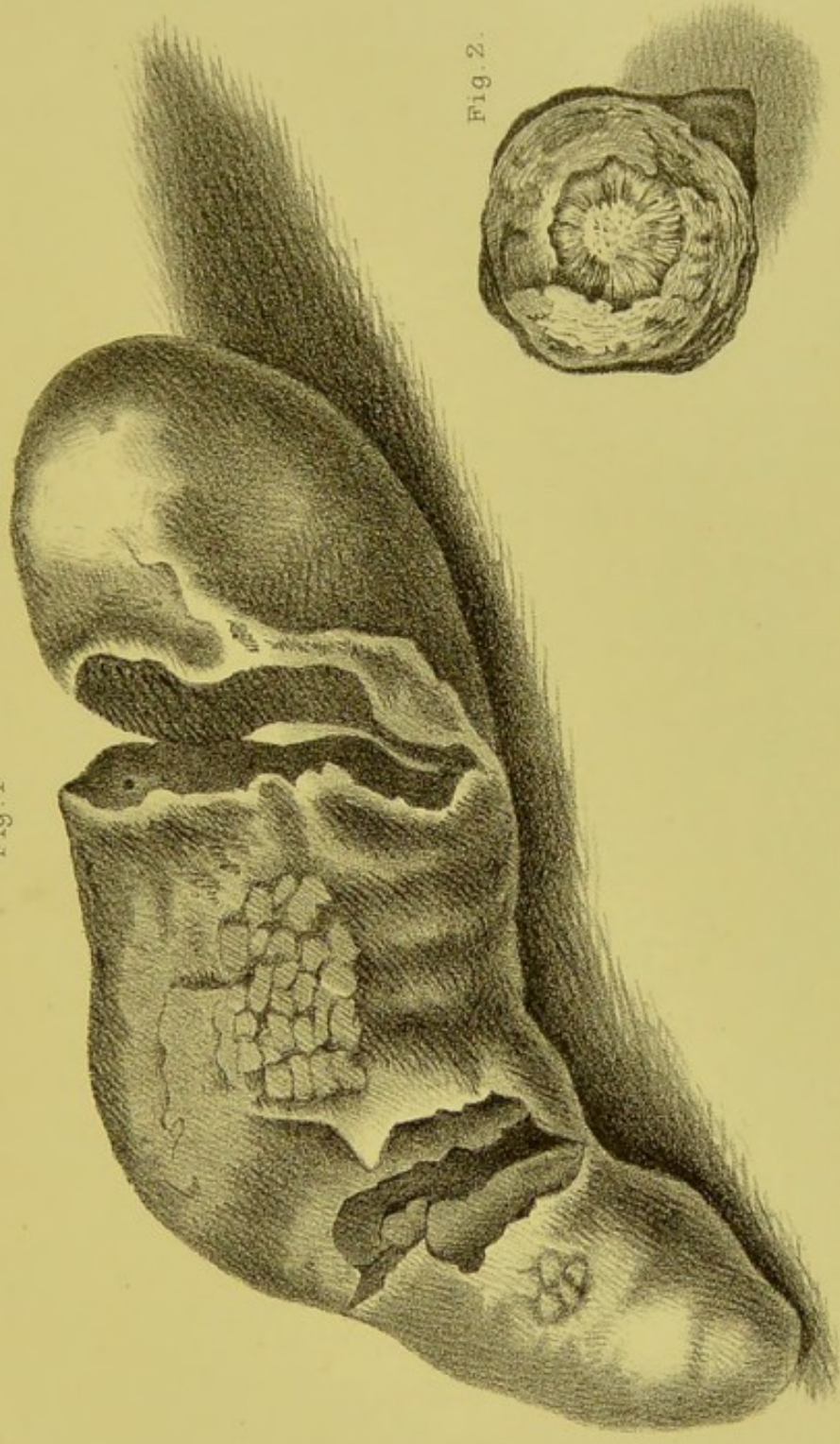
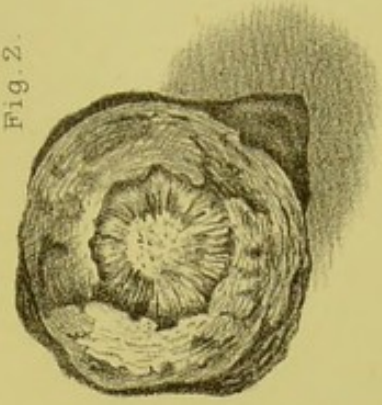



Fig. 2.





THE HISTORY OF THE UNITED STATES

The history of the United States is a story of growth and expansion. From a small collection of colonies on the eastern coast, it grew into a vast nation that spanned the continent. The early years were marked by struggle and conflict, as the colonies fought for their independence from Britain. The American Revolution was a turning point in the nation's history, leading to the birth of a new republic. The years following the revolution were a time of rapid growth and development. The United States expanded its territory westward, and its economy flourished. The nation's population increased, and its influence grew. The American dream of a better life for all became a reality for many. The United States emerged as a world power, and its values and ideals were spread across the globe. The history of the United States is a testament to the power of the human spirit and the pursuit of a better future.



## PLATE LXXXIX.

### THE RESULTS OF MORPHŒA HERPETIFORMIS AFFECTING THE FIFTH NERVE.



THESE two portraits are given to show the results of arrest of development of one half of the face after morphœa in childhood. The term hemi-atrophy is often, and not very correctly, applied to these cases. The condition results simply from morphœa changes in the district of the fifth nerve occurring in early life. If the attack happens after the full development of the face, no such result ensues. It is an arrest of growth from interference with nutrition, and not a process of atrophy. The muscles and even the bones, as well as the skin, are often involved in it. In both these portraits it will be seen that the whole of the left side of the face is involved, a vertical line passing up the middle of the forehead. In some cases, however, certain regions supplied by branches of the fifth nerve may be exempt whilst others suffer. These portraits are copied, one from that of a girl whose case is published by Mr. Jessop in the St. Bartholomew's Hospital Reports, the other from the photograph of a German, who, some years ago, was in London for the purpose of exhibiting his peculiarity.

HUTCHINSON'S CLINICAL ILLUSTRATIONS.  
(SMALLER ATLAS.)

Fig. 2

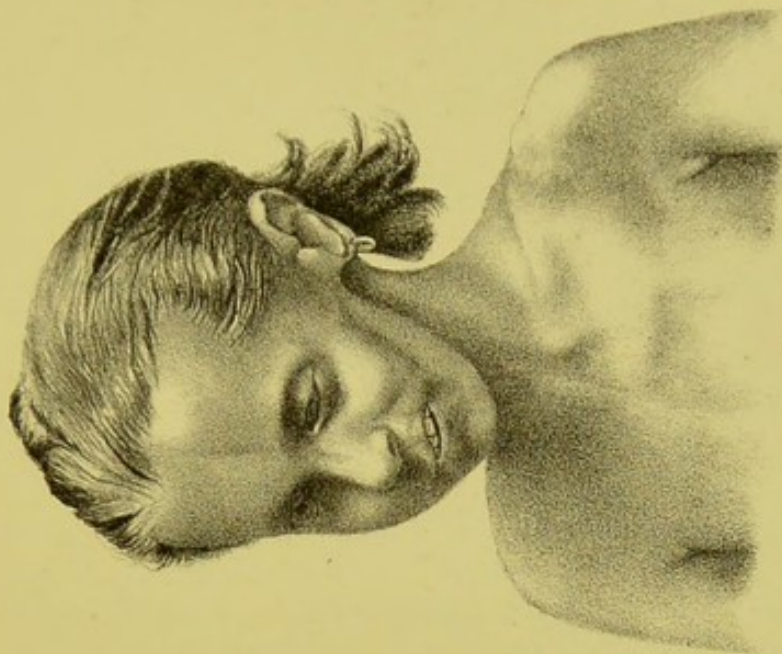
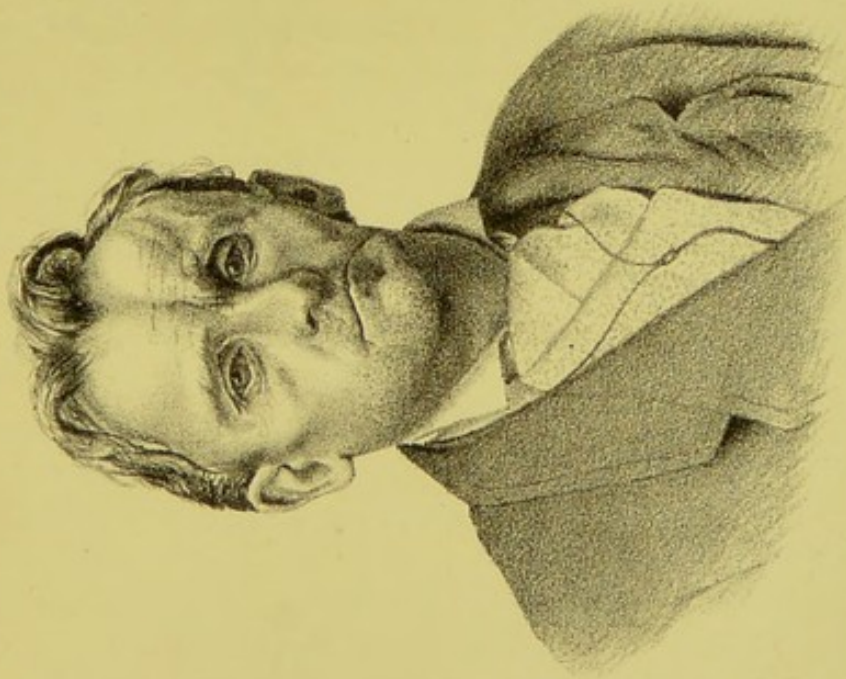



Fig. 1





## PLATE XC.

### TUMOURS OF THE SCALP ASSUMING MALIGNANCY. (ANCELL'S CASE.)



THIS portrait is copied from Mr. Henry Ansell's paper in the 'Medico-Chirurgical Transactions.' It shows the later stage of a patient in whom sebaceous tumours of the scalp (which had occurred in several generations) were followed by the multiple production of solid growths (carcinomatous) on other parts of the skin and in the internal organs.

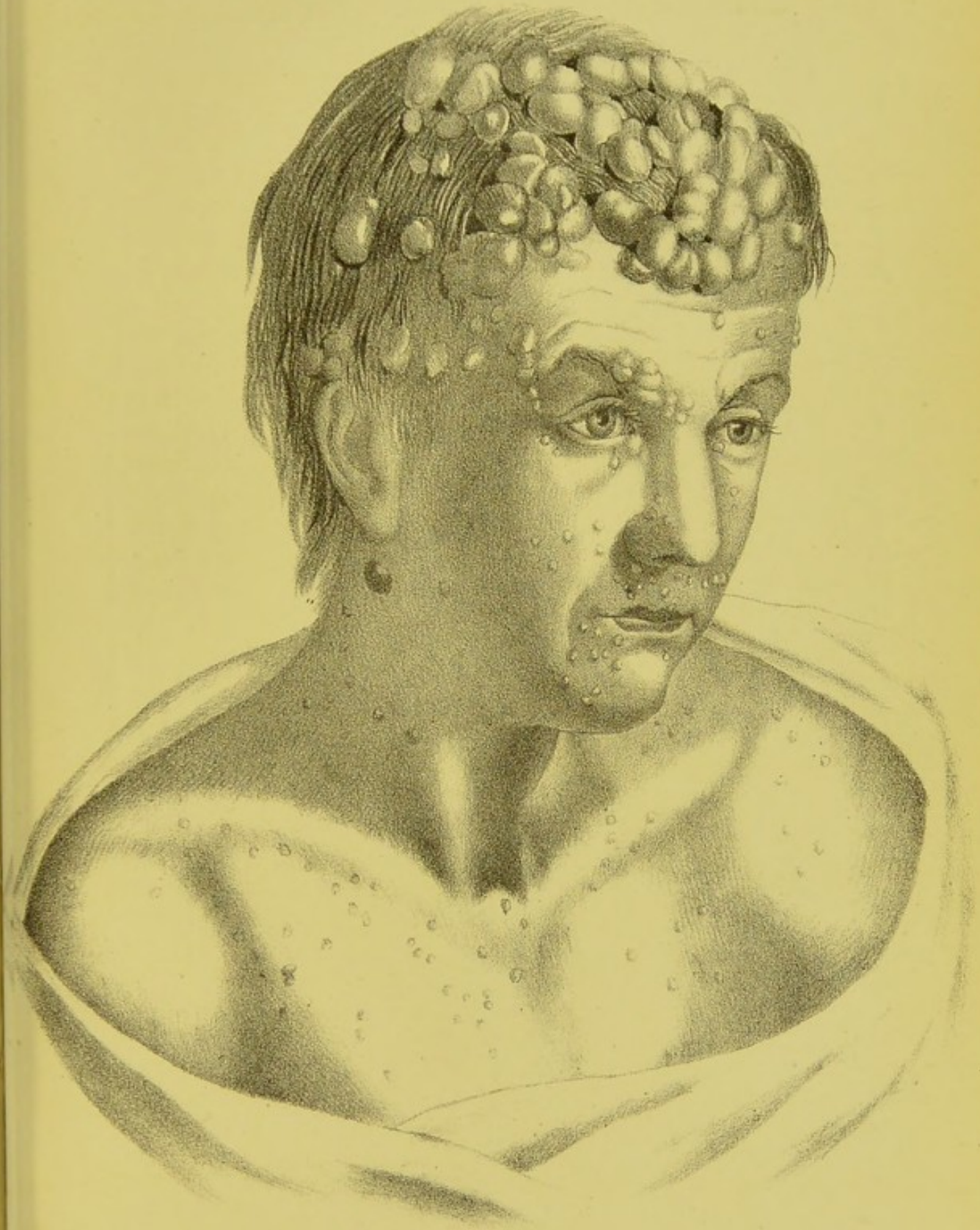
The case is described on page 336, and the original paper will be found at page 236, of vol. xxv. of 'Medico-Chirurgical Transactions.' The tumours of the scalp are said to have looked like tomatoes. The patient stated that the first tumour had appeared at the age of fifteen, and she was fifty-two at the time the portrait was taken. Her failure of health and the conditions indicating visceral disease extended over about two years before her death. There was a very large growth in the liver, and innumerable small ones covering the peritoneum, omentum, and mesentery.


Although there was no conclusive proof that at any stage of the disease the tumours had presented in this patient the conditions of ordinary steatomata, yet there was reason to believe that they had done so in her relatives; and there could be little doubt that they took their origin in sebaceous glands.


The following is a review of the evidence on this point. Mr. Ansell's patient had previously been under the care of the late Mr. Bryant, and the latter gentleman had stated that, when he saw the patient, the character of the tumours was different. "They were less firm, and, on making a longitudinal incision, their contents were easily turned out." Mr. Bryant at one sitting removed sixty. It will, I think, be admitted that these tumours could have been none other than the ordinary sebaceous cyst; and as such Mr. Bryant appears to have regarded them. In the case of a sister of the patient, who had a

PLATE XC. (*continued*).

large crop of tumours on the forehead, temples, and about the ears, and whom Mr. Ancell states that he had frequent opportunities of examining, one of the tumours was quite different from the others. It had the appearance of an "ordinary steatoma," being round, quite movable under the scalp, and rather soft. The skin over it retained its hair, and was quite natural. This tumour, however, did not contain the ordinary sebaceous matter of a steatoma. It was punctured, and a quantity of very tenacious, transparent, gelatinous matter was pressed out. The facts as regard inheritance in Mr. Ancell's case are as follows. The patient herself, a woman of fifty-two, was unmarried. In her the tumours commenced to appear at the age of fourteen or fifteen. Her grandmother was reputed to have had similar ones. Her mother had one large one (probably a wen). A younger sister had had a tumour of the breast removed. An elder sister, who was free, and who had borne fifteen children, and who had forty grandchildren, did not know of a single instance amongst her descendants. Another sister, aged sixty-two, had a large crop of similar tumours on her head. She was the mother of a large family, several of whom, including two sons, were similarly affected. In no instance was there any history of the disease having been transmitted by the males. It would be of very great interest to know whether in all these instances the scalp tumours really were solid, or whether they reverted to the original type of sebaceous cysts.









## PLATE XCI.

### TUMOUR OF THE UPPER EYELID.



THIS Plate, copied from a German source, illustrates a peculiar form of tumour to which the upper eyelid is liable. Many years ago I had at Moorfields a case exactly resembling it which excited great interest. I excised the growth, and it was carefully examined for me by Mr. Nettleship. For the present, however, I have mislaid my notes of it, as well as the photographic portrait. The patient was a man of middle age.

In the German Monograph it is named Elephantiasis of the upper eyelid, but I do not believe that the growth has any real relationship to Elephantiasis.

I should have preferred to omit this Plate from the 'Atlas' on account of incompleteness of narrative, but that it has been numbered in the series. It has not yet appeared in the 'Archives.' I purpose at an early date to recur to the subject.

Fig. 1.

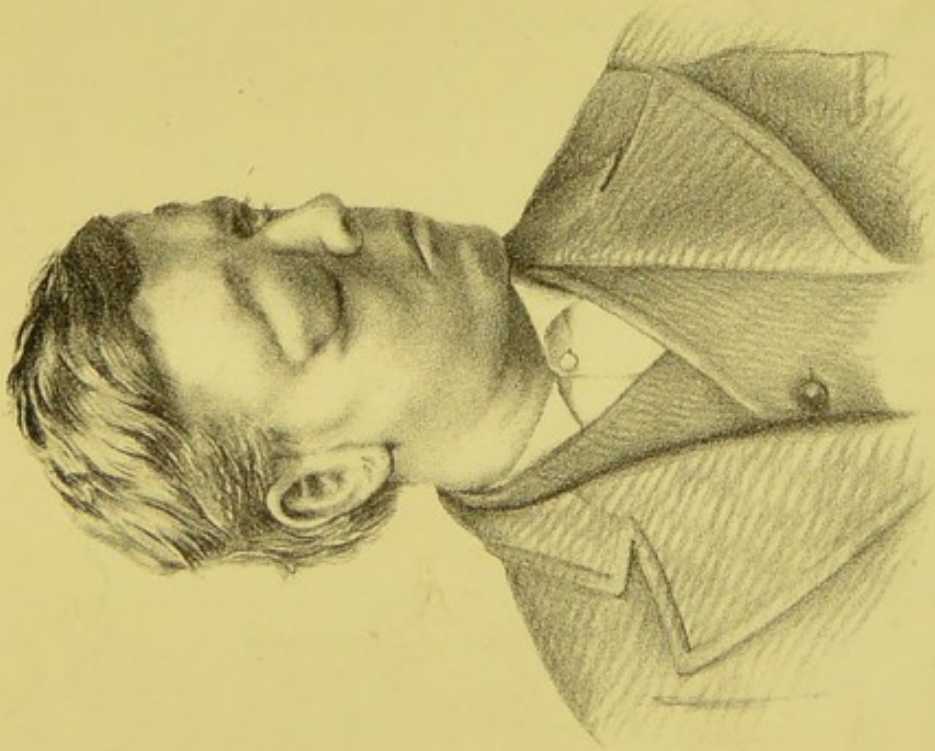



Fig. 2.





## PLATE XCII.

### A SHORT-LIMBED POLYDACTYLOUS DWARF.

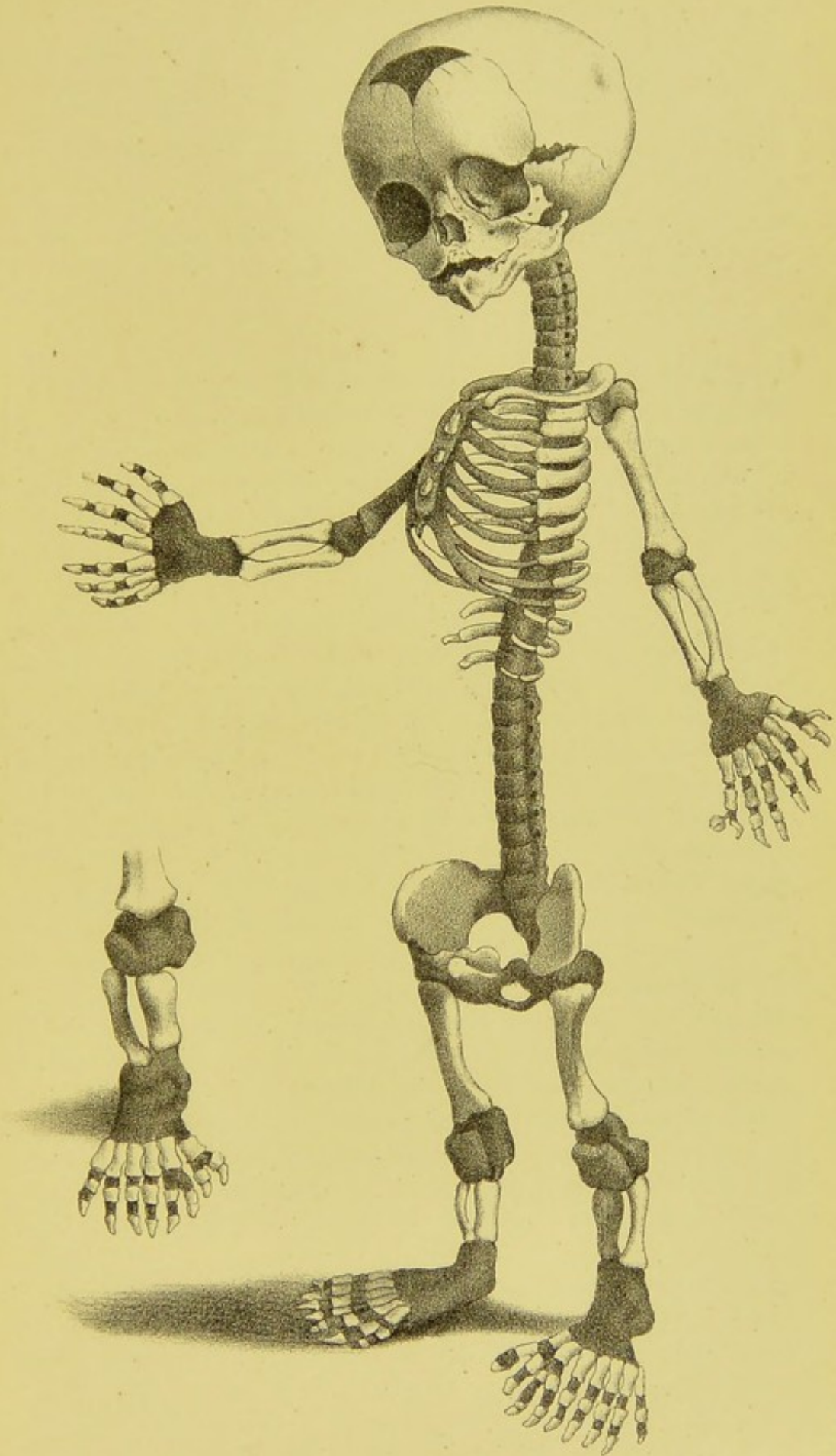
---


THIS quaint figure is copied from Theodore Kerckring's '*Spicillegium Anatomicum*,' published in Amsterdam in 1670. The description states that the body was that of an infant found drowned in the river on Oct. 16, 1668. It was dissected by the renowned Ruysch. A detailed description of the skeleton is given. My reason for now reproducing the Plate is that it offers an important item of evidence in reference to the development of short-limbed dwarfs. Although we must not place too much reliance on the accuracy of the draughtsman, since he has figured some superfluous lumbar vertebræ, yet there can be no doubt that the limbs are much too short for the trunk and head. This remark especially applies to the lower limbs and pelvis. These are exactly like those of the Norwich dwarf, and of the skeleton in the Heidelberg Museum which I described in a recent number of the '*Archives*.' The point of extreme interest in the present case is that this dwarfing of the limbs is associated with polydactylism. Both the hands have seven digits. The right foot has eight and the left nine. The conditions are not exactly symmetrical, since in some instances a metacarpal or metatarsal bone is wanting; or, to put it otherwise, two are welded together. It will be seen that the upper extremities are so short that the tips of the digits will only just touch the iliac crests.

This occurrence of short limbs with polydactylism seems to prove conclusively that the condition may be due to a modification of development of a totally different nature from rickets. It is probable that the infant was not at full term. Amongst the points which the author has noticed in his description are—that the fontanelle was double its usual size; that the orbits were somewhat deformed; that the two halves of the lower jaw were already united; and that the ribs were short and badly formed.

PLATE XCII. (*continued*).

He also, of course, draws attention to the shortness of the limbs, the stoutness of the long bones, and the supernumerary digits. I find no statement that the skeleton was deposited in any museum, but it is very possible that it is still in existence in Amsterdam, and if so, it is very desirable that it should be more exactly described.





## PLATE XCIII.

### TUMOURS IN THE CAUDA EQUINA.

—◆—

THIS engraving is copied from one that was published in the 'Transactions of the Provincial Association,' by the late Dr. Fisher, Down Professor of Physics at Cambridge. It represents a mass of tumours connected with the Cauda Equina, respecting the pathological nature of which I must be content by transcribing Dr. Fisher's own words:—

"The tumour or rather mass of tumours, on which a great number of vessels are spread, was surrounded on all sides by the roots of the nerves forming the Cauda Equina. The lower portion of this morbid growth had the form of a tubercle. It presented several traces of vascularity in the centre, and had a scirrhus appearance; I could not, however, make anything out satisfactorily with regard to its minute structure. The upper portions of the tumour were softer, and were involved in a fine glistening covering; sections of several portions of them show them to be composed of a grey, semi-transparent, jelly-like substance, infiltrated amidst reticulated tissue, and marked with sanguineous striæ, several of which appear like two vessels."

Dr. Fisher further adds that the dura mater and arachnoid appeared to be quite healthy, and that the cord itself was also sound. Some of the nerves appeared to pass through the tumours, but the greater portion of them could be easily detached. There can, I think, be little doubt, when we regard the case in the light of more recent experience, that the tumours were of the nature of fibromata. The case is of much interest in reference to one at least of those given by Mr. Robert Smith in his splendid monograph.

A reference may also be made to two preparations which are in the Institute of Pathological Anatomy at Vienna, and which I have briefly referred to in 'Archives,' vol. iv., page 142. These two

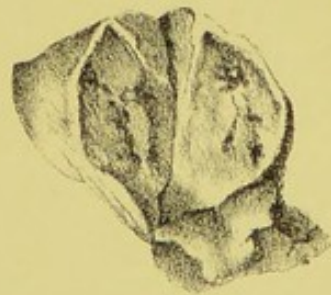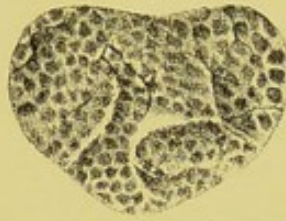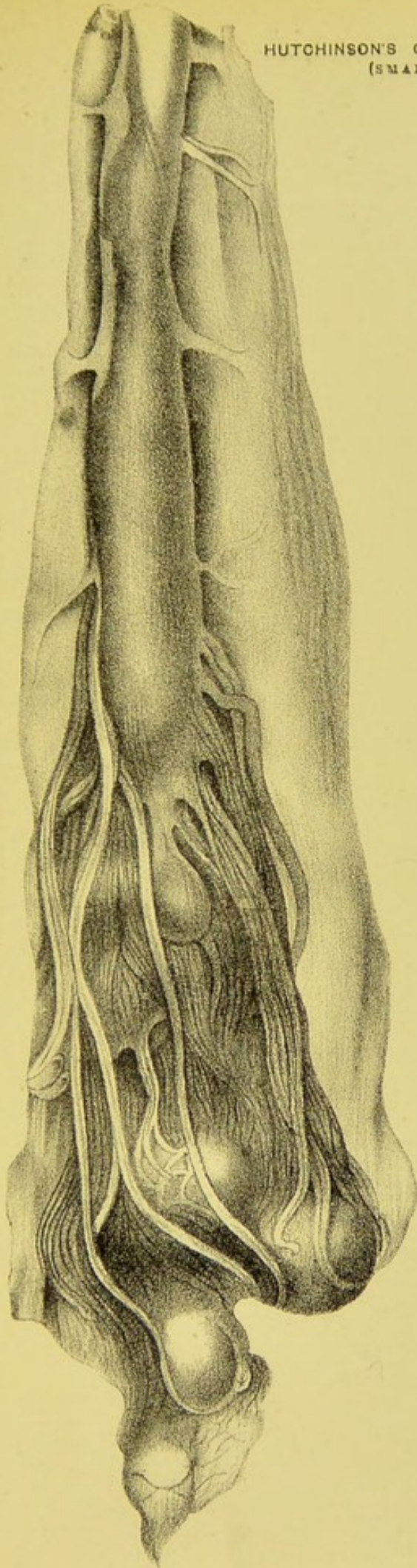



specimens are regarded by Professor Kundart as examples of multiple gummata in the Cauda Equina. Excepting that the tumours were more fusiform, Professor Kundart's specimens much resembled the appearances shown in this lithograph.


To return now to the history of Dr. Fisher's case. The patient was a man aged 38. He died in May, 1840, having been nearly six months under Dr. Fisher's observation. It is recorded that he had been intemperate in his habits, but nothing is said as to syphilis. He believed that he had injured his back, in riding, about three years before his death, and from that time onwards he had suffered from pain in the loins, which was at first called rheumatism, but which gradually increased in severity and extended down the legs. One year before his death he was obliged to desist from his occupation as a tailor, and a few months later still he became bed-ridden. He was unable to lie down, but rested on his hands and knees. There was great numbness in the lower extremities, more especially in the left leg. He had difficulty in making water and some incontinence of urine. He was entirely free from symptoms in reference to his head, chest, and upper extremities; and notwithstanding the awkward position which he was compelled to take, he did some work as a tailor till within a week of his death.

There were large pressure-ulcers on his knees, which however gave him no pain.

It will be seen that the above history fits well with the slow growth of fibromata; and that there is nothing suggestive either of syphilis or of any infective form of malignant growth.







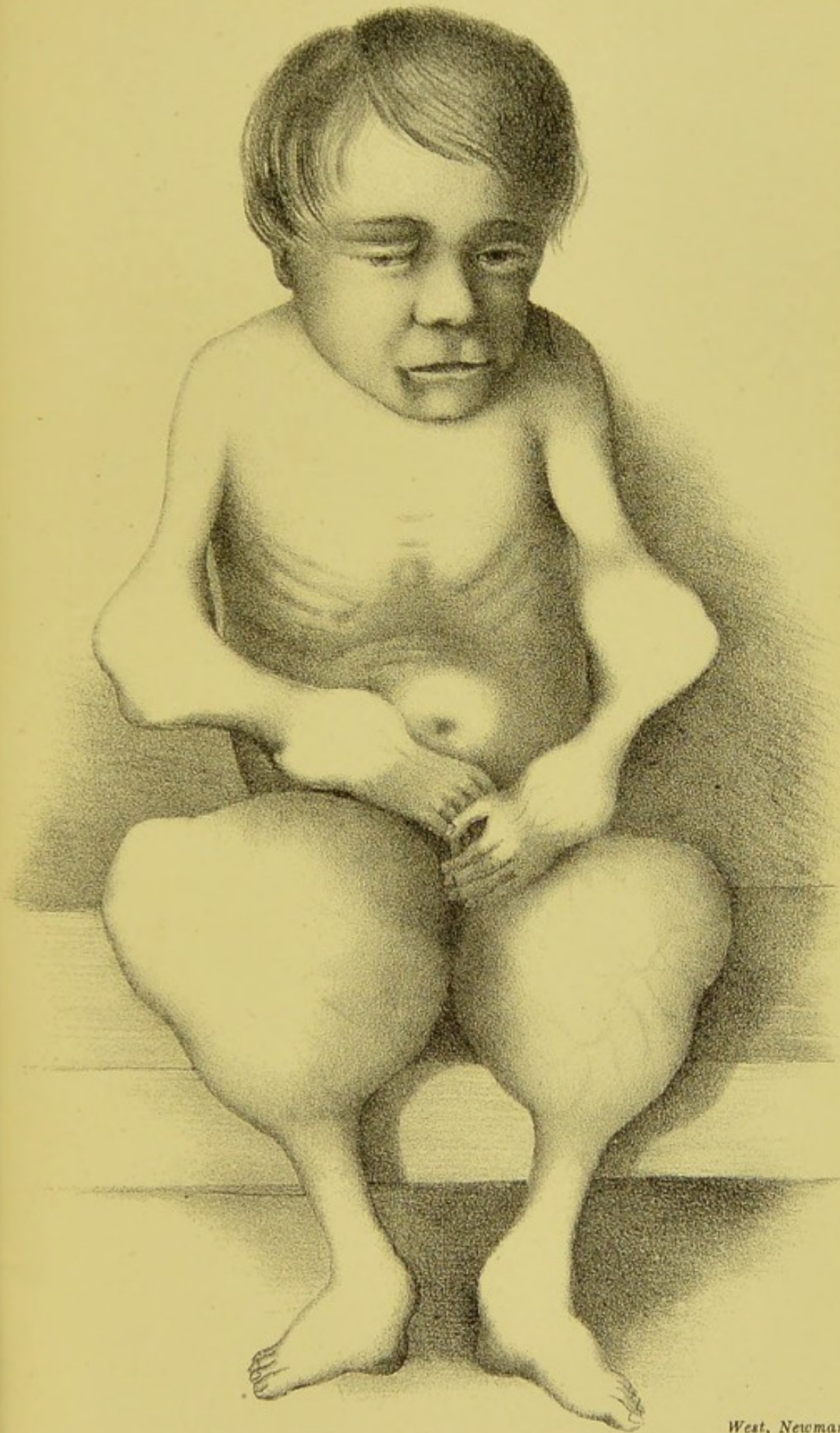
## PLATE XCIV.


### OSTEO-ARTHRITIS IN EARLY LIFE.

---

THE portrait here given is copied from one published by Mr. Thomas Braine, of Banbury, in the 'Transactions of the British Medical Association' for 1834. It was regarded as an example of rickets, and it probable illustrates a severe form of rheumatoid arthritis in conjunction with some rachitic tendency. None of the long bones were curved, nor was the chest malformed. The knees and ankles, elbows and wrists, had, as is shown in the portrait, suffered severely, and with symmetry. The hips and the shoulders had escaped. The small joints of the fingers, although not in the drawing showing any peculiarities, are in Mr. Braine's text stated to have been clumsy and ill-formed. The boy's head was large, and, although he was seven years of age, the anterior fontanelle was not quite closed. The circumference of the cranium was twenty inches. The enlargement of the joints is described as being not due, as might be suspected, to synovial effusion, but to overgrowth of the epiphyses. The surface was firm and unyielding, and crossed by large veins. The joints were fixed, much in the position represented by the Plate, and the back was arched. The boy was the sixth of eight children, born of healthy parents. His brothers and sisters were fairly healthy, but more or less strumous. During infancy he had suffered for a long time from diarrhœa, and had become much emaciated. Symptoms of stiffness about the right elbow were observed during the first month or two after birth. The boy had a sallow aspect, and a somewhat vacant expression, but was of good intelligence. His skin was dry, and on his forehead, neck, and shoulders were "spots like psoriasis guttata." The boy was living at the time the case was published, and no further record of him is forthcoming.

For fuller details, see 'Archives,' vol. v., page 82.





1872

Faint, illegible text, possibly bleed-through from the reverse side of the page.

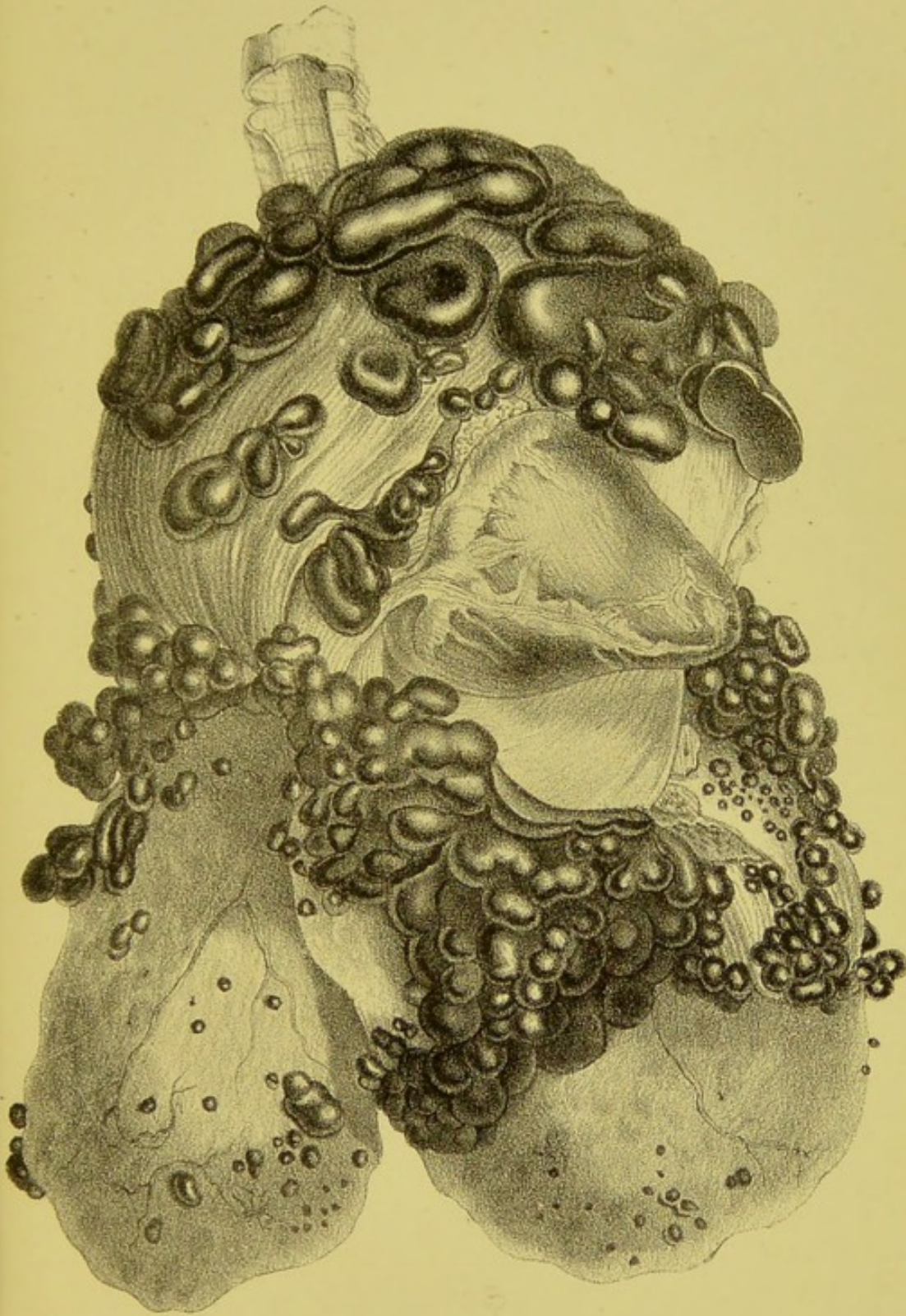


## PLATE XCV.

### MELANOTIC GROWTHS ON THE THORACIC ORGANS OF A HORSE.

---

THE parts represented in the appended Plate are the thoracic viscera of a horse. I have copied it from an illustration in the 'Veterinary Record' for 1846 by Mr. J. Veson. My object in reproducing it is to illustrate the wide diffusion which melanotic sarcoma finally assumes. In Mr. Oliver Pemberton's work on melanosis some not dissimilar illustrations will be found, taken from the human subject, and most of our museums contain specimens demonstrating the same facts. I do not, however, know of any which exhibit them in quite such a graphic manner as does the engraving which I have here copied. It will be seen that the visceral pleura is covered with black nodules of various sizes, perfectly smooth, and many of them quite isolated and without any infiltration of the parts on which they grow. Most of them are sessile, but some are arranged like bunches of grapes. The record of the post-mortem states that the parietes of the chest, especially near the attachment of the diaphragm, was studded over with jet-black tumours exactly like those here shown. The liver also contained melanotic growths, and there were many tumours on the external part of the body. It will be seen that the heart itself and the pericardium are apparently free from disease. The mass represented between the heart and trachea is described as a tumour, and had not improbably sprung, in part at least, from the mediastinal glands. The subject of the case was an old grey horse. The symptoms displayed during life had been supposed to be those of heart disease, attended with great distension of the veins of the head and neck. No search appears to have been made for the primary growth. This, no doubt, had been on some part of the surface, and very probably near to the anus; this being the common site for melanotic moles in grey horses.





THE HISTORY OF THE

REPUBLIC OF THE UNITED STATES OF AMERICA

The history of the Republic of the United States of America is a story of the struggle for freedom and justice. It is a story of the people who have fought for the principles of liberty and equality. It is a story of the men and women who have shaped the destiny of this great nation. It is a story of the triumphs and the failures, of the hopes and the dreams. It is a story that is still being written.


PLATES XCVI. & CI.


NÆVUS OF FACE CURED BY CAUTERISATION.



My favourite method for the treatment of nævi on the face, and in all positions where the avoidance of scar is important, is by the repeated use of the actual cautery. These two portraits show the condition of the same child before treatment and after cure by this means. I may assure the reader that there is not the slightest exaggeration in the second one. The cautery (Paquelin's) had been used repeatedly at intervals of about two months.









## PLATE XCVII.

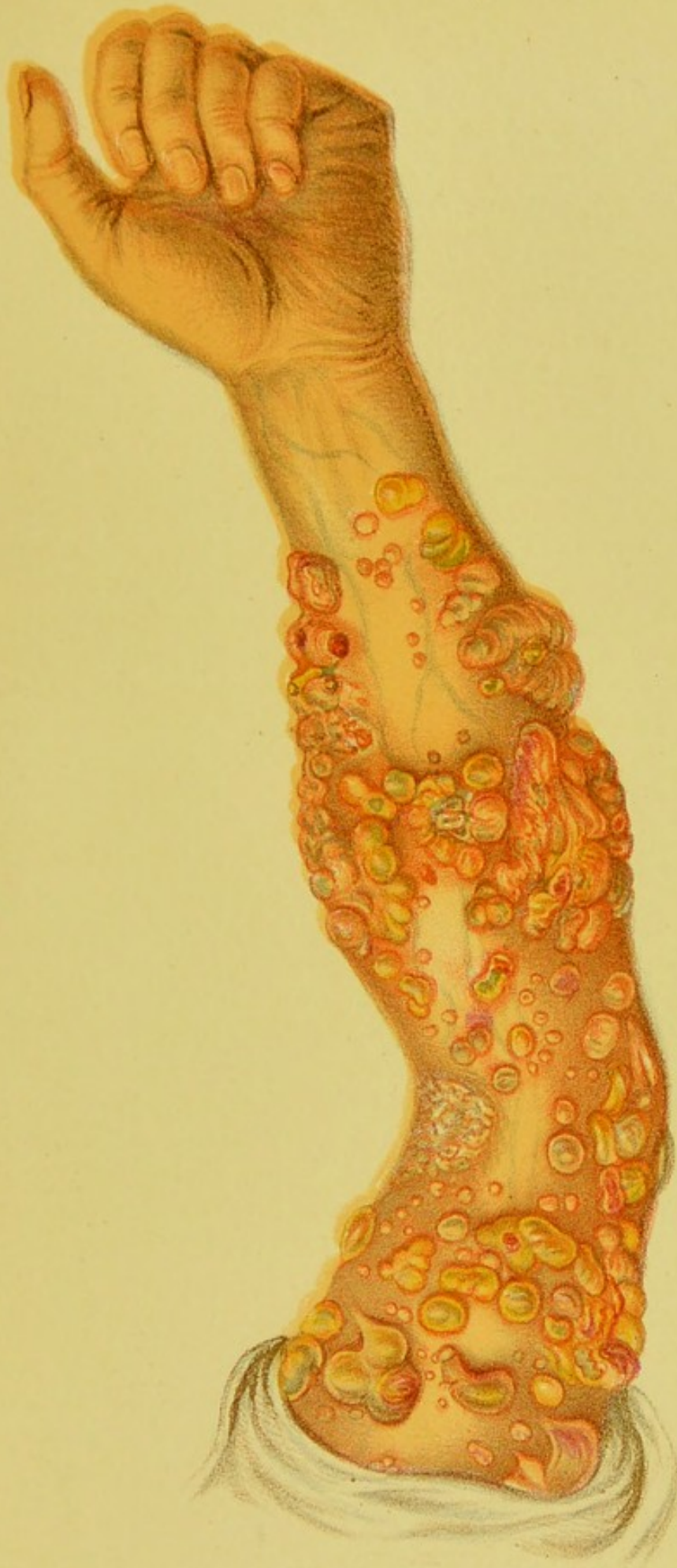### PEMPHIGUS IN SECONDARY SYPHILIS.


---


THIS Plate represents an eruption of acute pemphigus, which occurred as the exanthem in the secondary stage of syphilis. The bullæ were exceedingly well characterised and very large. The eruption covered the arms and legs with bullæ, but on the trunk it caused only erythematous patches. It was said to have exactly resembled the chicken-pox at the time of its first appearance. The chancre was still present, as also some very hard glands in the groins, and ulceration of the tonsils. The early treatment had been neglected. The treatment proved very difficult. Iodide of potassium made the eruption worse, and mercury did not cure it. When, at length, arsenic was given simultaneously with mercury, but not in combination, then very satisfactory results were obtained. The patient was, however, still, at the end of two years, not perfectly well. He was in good health, but the eruption tended to return unless the two specifics were continued. The case is recorded in detail in 'Archives,' vol. iv., page 195.

*Postscript.*—Since the publication of the case in 'Archives,' the patient has remained under treatment, and a perfect recovery has resulted. He has attended several times at my Clinical Demonstrations.

This case and some similar ones which I have published prove, I think, that the special type which the secondary eruption of syphilis assumes depends upon the pre-existing peculiarities of the individual. Hence the necessity for modifications of treatment.







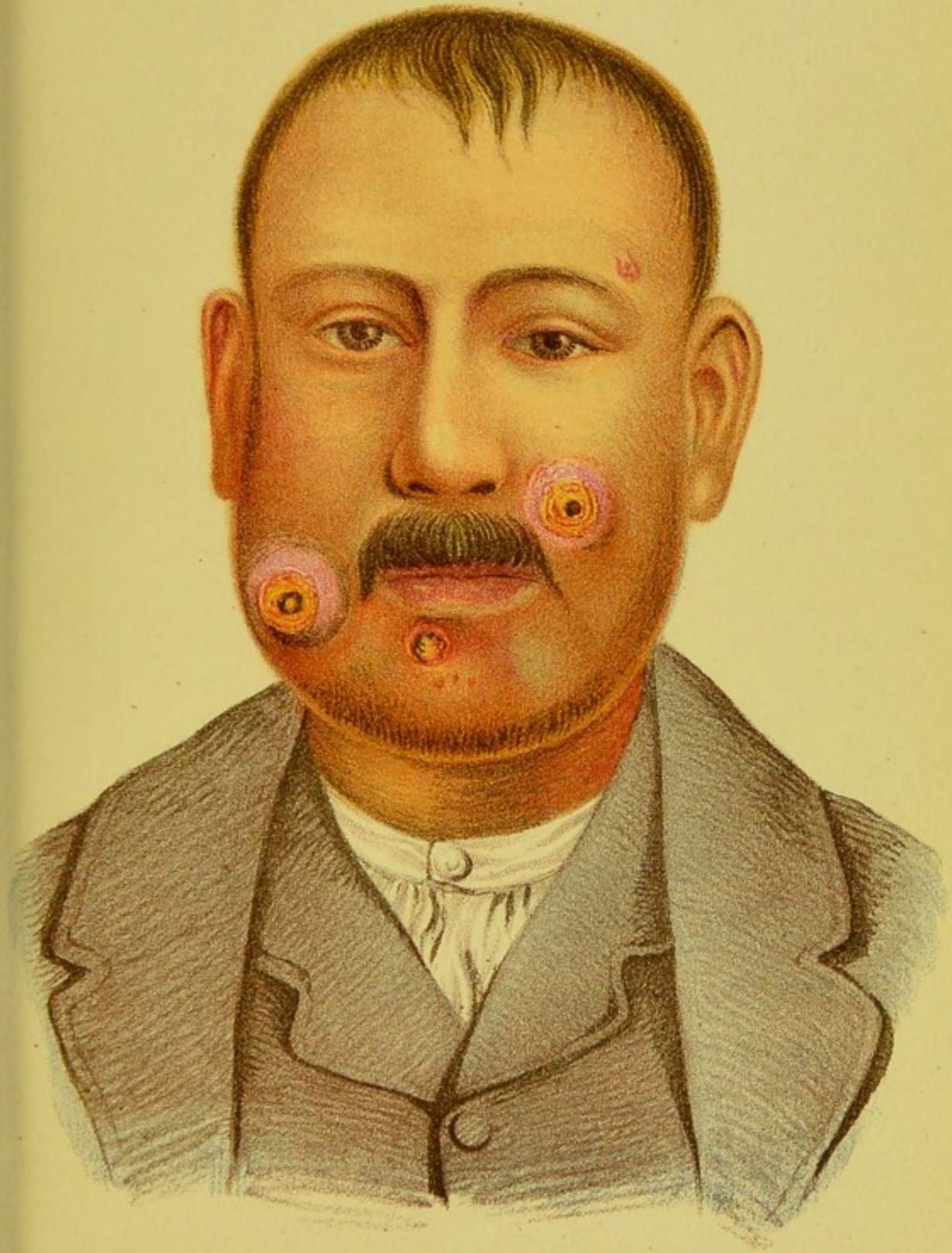
## PLATE XCVIII.


### ULCERS ON THE FACE FROM INOCULATION.

---

Portrait of a man under care at the London Hospital on account of sores on the face, which somewhat resembled malignant pustule. The patient was a horse-keeper, and he believed that the sores were due to inoculation from the secretion of grease. No proof was, however, forthcoming on this point. The patient was not seriously ill, and the sores healed after a short treatment. It is to be noted that the ring of vesicles around the sore, so characteristic of anthrax, was not present. The sores might have been claimed by Jenner as an illustration of the identity of grease with vaccinia.

A portrait showing a not dissimilar eruption on the arm of a man is framed in the Museum by the side of this. It is from a paper published in the Clinical Society's 'Transactions,' by Mr. Langton. It shows large pocks with depressed centres. The patient was a horse-keeper, and had been engaged in dressing the heels of horses suffering from grease.









## PLATE XCIX.

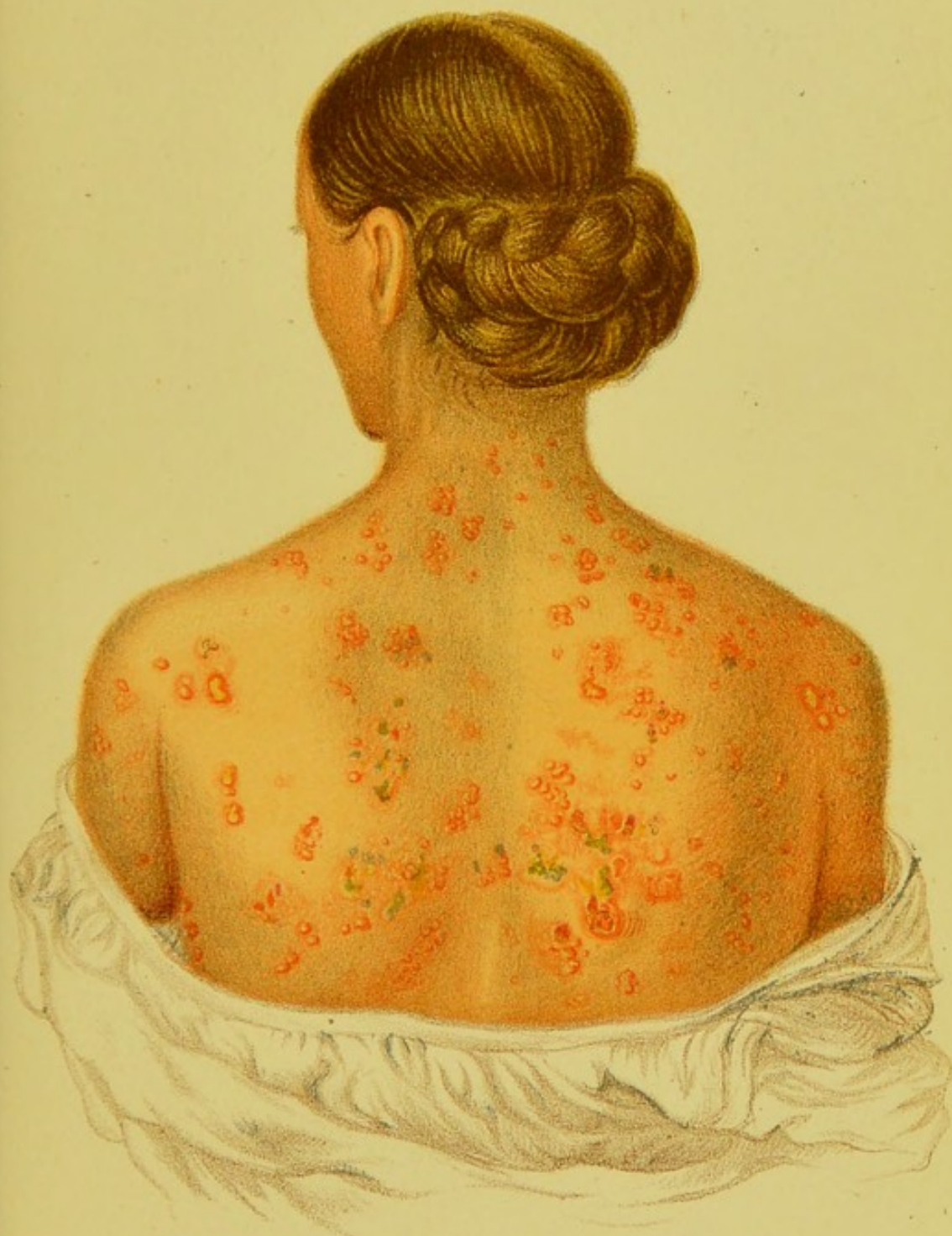### DERMATITIS HERPETIFORMIS.—HERPETIFORM PEMPHIGUS.

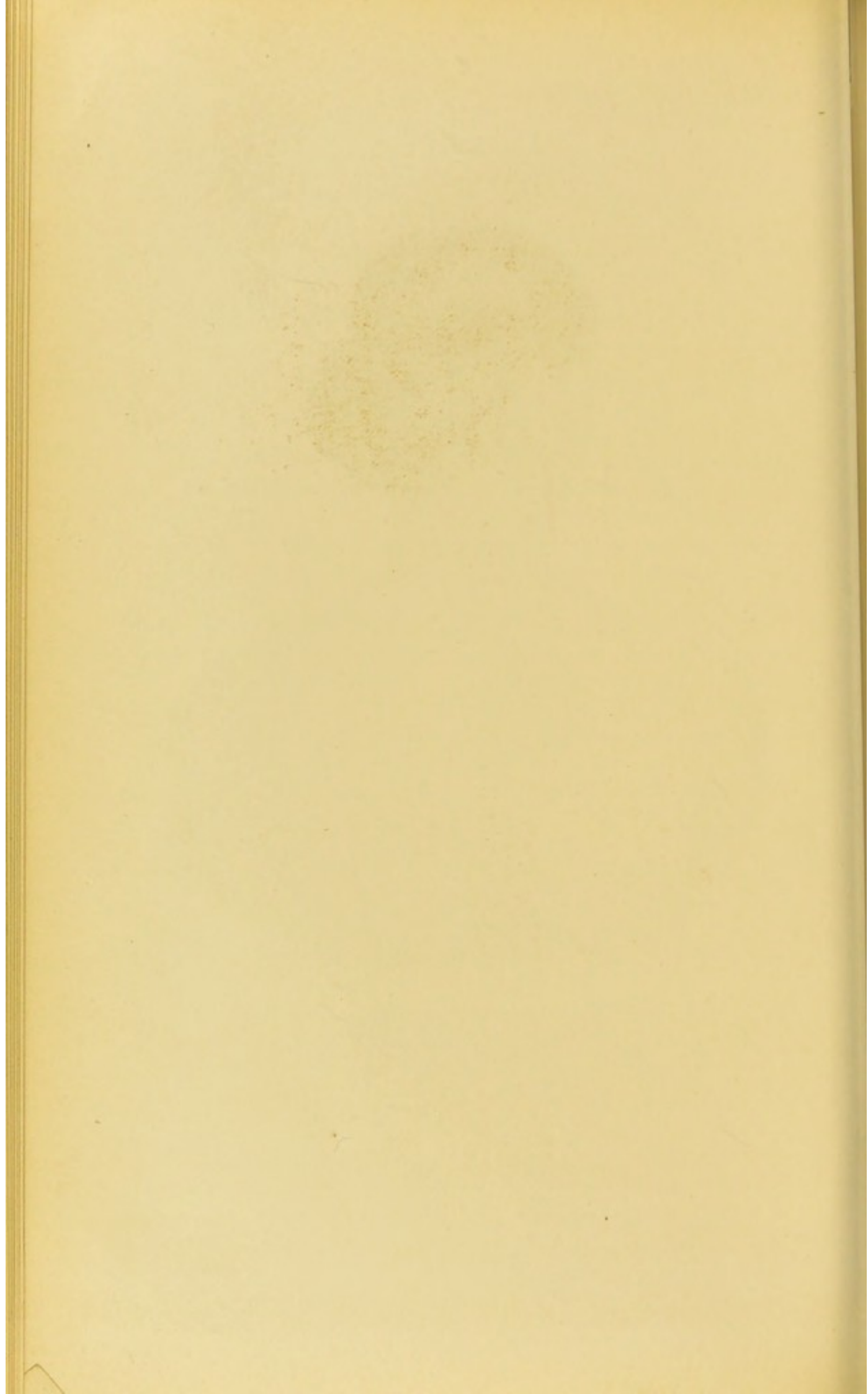
---

THIS portrait shows well the condition of the eruption in the case of Mrs. Esther Ann B——, recorded in 'Archives,' vol. v. It will be seen that the shoulders are covered by a vesicular and congested eruption, any single part of which might readily pass for a group of herpes. The progress of the different vesicles also much resembled that of shingles, for they dried up, leaving thin, dark crusts. The history of the case (given in detail in 'Archives,' vol. v., page 10) is that the patient suffered, during at least seven years, from relapses of the eruption, and that it was always cured for the time by arsenic. The final result is not known. The eruption avoided the loins, the genitals, and the upper parts of the thighs (patient's statement), but, with these exceptions, was present on almost all other parts. It appeared probable that the arsenic would in the end effect a complete cure; for on the last occasion she had remained one year without any relapse. The case no doubt belongs to the group described by Dr. Duhring as *Dermatitis herpetiformis*. Its real relationship would, I believe, be indicated by the name *Pemphigus herpetiformis*.

See also Plate C., in which the details of the eruption are depicted on larger scale.

This patient was under my care from 1875 to 1877. Her eruption had commenced in 1870.








PLATE C.


DERMATITIS HERPETIFORMIS.—HERPETIFORM  
PEMPHIGUS.



THIS Plate is a careful study of the eruption in the preceding case. The vesicles, bullæ, and crusts are shown. It will be seen that the vesicles do not tend to coalesce so much as is usual in herpes, and that they present very various stages at the same time. Some of them are large enough to constitute small bullæ, and around all there is very vivid congestion.

See Plate XCIX.

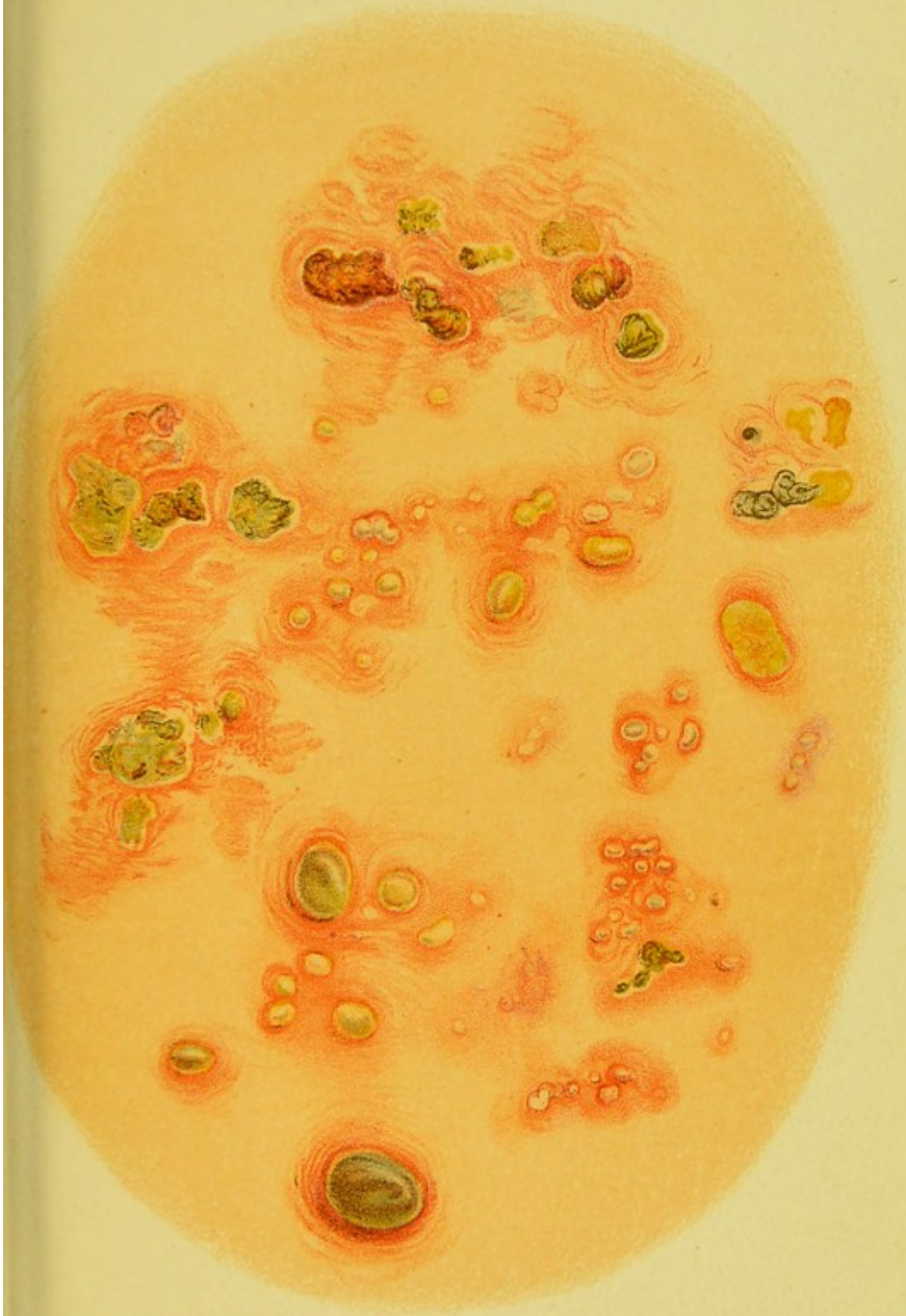






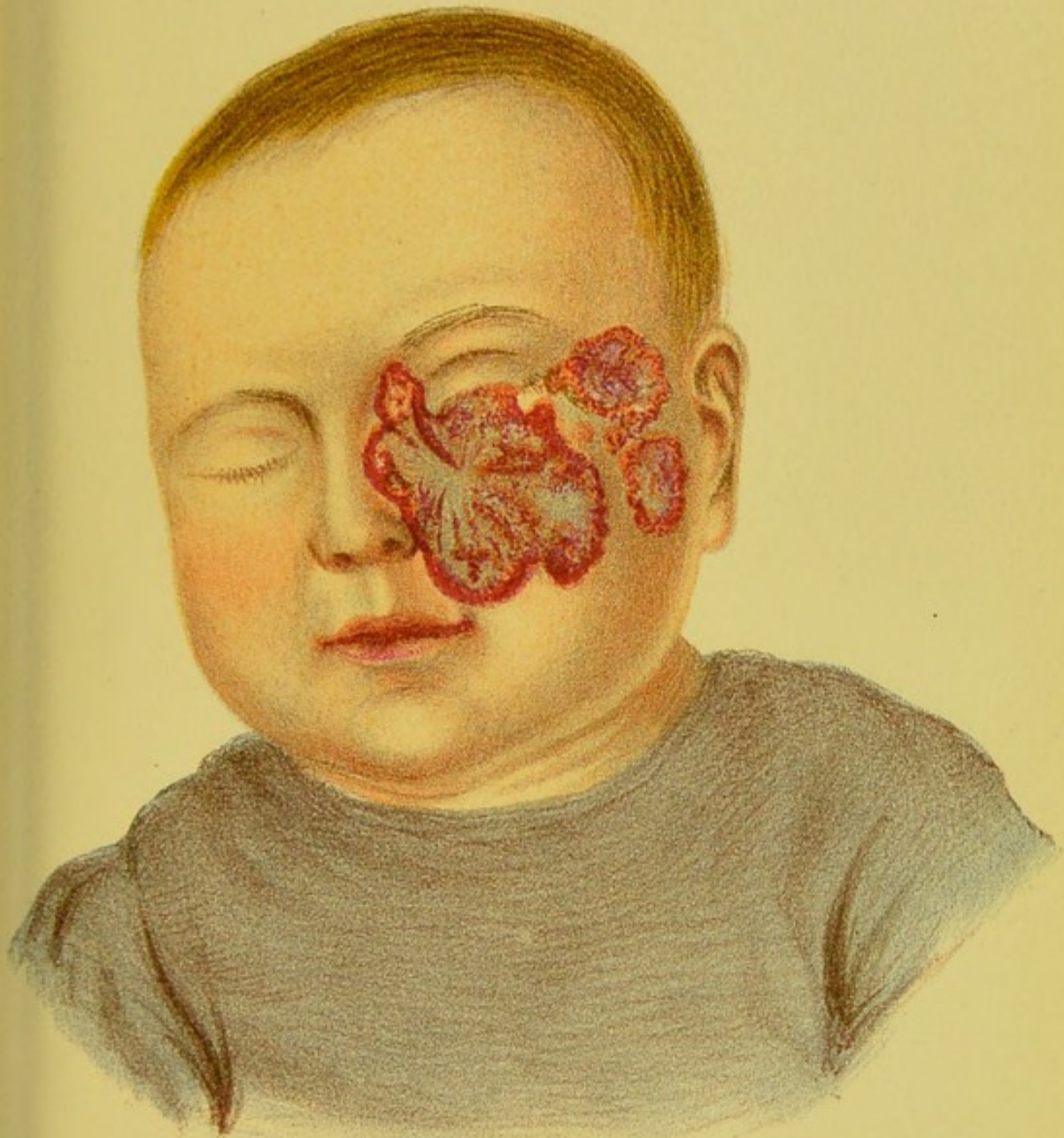


PLATE CI.


NÆVUS OF FACE CURED BY CAUTERISATION.



For description see Plate XCVI.







## PLATE CII.

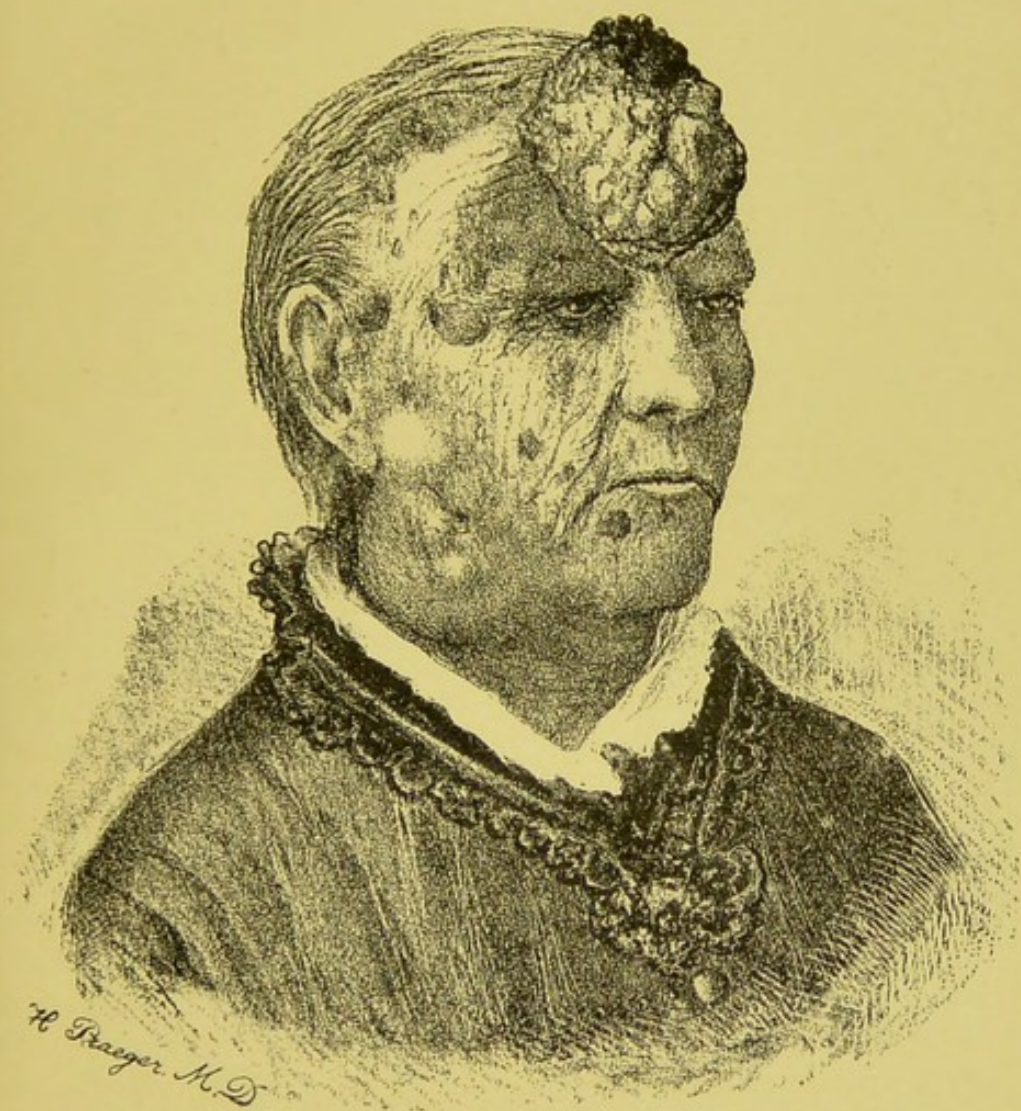
### DUHRING'S NEOPLASM.


(COPIED.)

—♦—

This portrait is copied from one which was published by Dr. Duhring, of Philadelphia, in 1880, and illustrates the disease to which the name of "Duhring's Neoplasm" has since been accorded. Dr. Duhring's paper is a very able one, and deals very fully with the facts which seem to show that the disease illustrated stands as a sort of connecting link between inflammation and new growths. It has since been claimed by other writers as an example of *granuloma fungoides*, and, as such, has been associated with other cases to which it bears no very close similarity.

The patient was a woman past middle age, who died in May, 1879. The details of the autopsy are recorded in 'Archives of Dermatology,' January, 1880. Briefly, it may be stated that she had suffered from a skin disease during more than two years, which had been characterised by growths similar to those shown in the portrait, which would fungate and ulcerate, and were attended by much foetid discharge. A tumour on her forehead is said to have resembled a huge roasted tomato. A very remarkable feature in the case was that some of the tumours would, from time to time, shrivel and disappear. There was little or no implication of the lymphatic glands, but, towards the end of the case, enlargement of the parotid and submaxillary glands took place. On various occasions some of the tumours were excised and their histology carefully investigated. The boundaries of the growths were very ill-defined, and of those which had undergone spontaneous removal it was in some cases impossible to discover any trace whatever. It is stated that iodide of potassium always produced alarming exacerbations, but it was not thought that the iodide was responsible for the beginning of the disease. At the autopsy no tumours were found in the viscera, with the exception of a number of almond-shaped tumours, half an inch in thickness, under the mucous membrane of the bladder. Even after the most detailed microscopic examination there remained much difference of opinion as to whether the growths should be classed as sarcomata or not. Dr. Duhring himself thought that they ought not, and concluded his narrative with the very suitable caution, "Better let it be unnamed and unclassified than be placed and become fixed wrongly."





THE HISTORY OF

THE CITY OF BOSTON

FROM THE FIRST SETTLEMENT TO THE PRESENT TIME

---

BY

JOHN HUTCHINGS

OF THE BOSTON BAR

IN TWO VOLUMES

VOLUME I

BOSTON: PUBLISHED BY G. B. LITTLE & J. B. TOWNSEND, 1858.

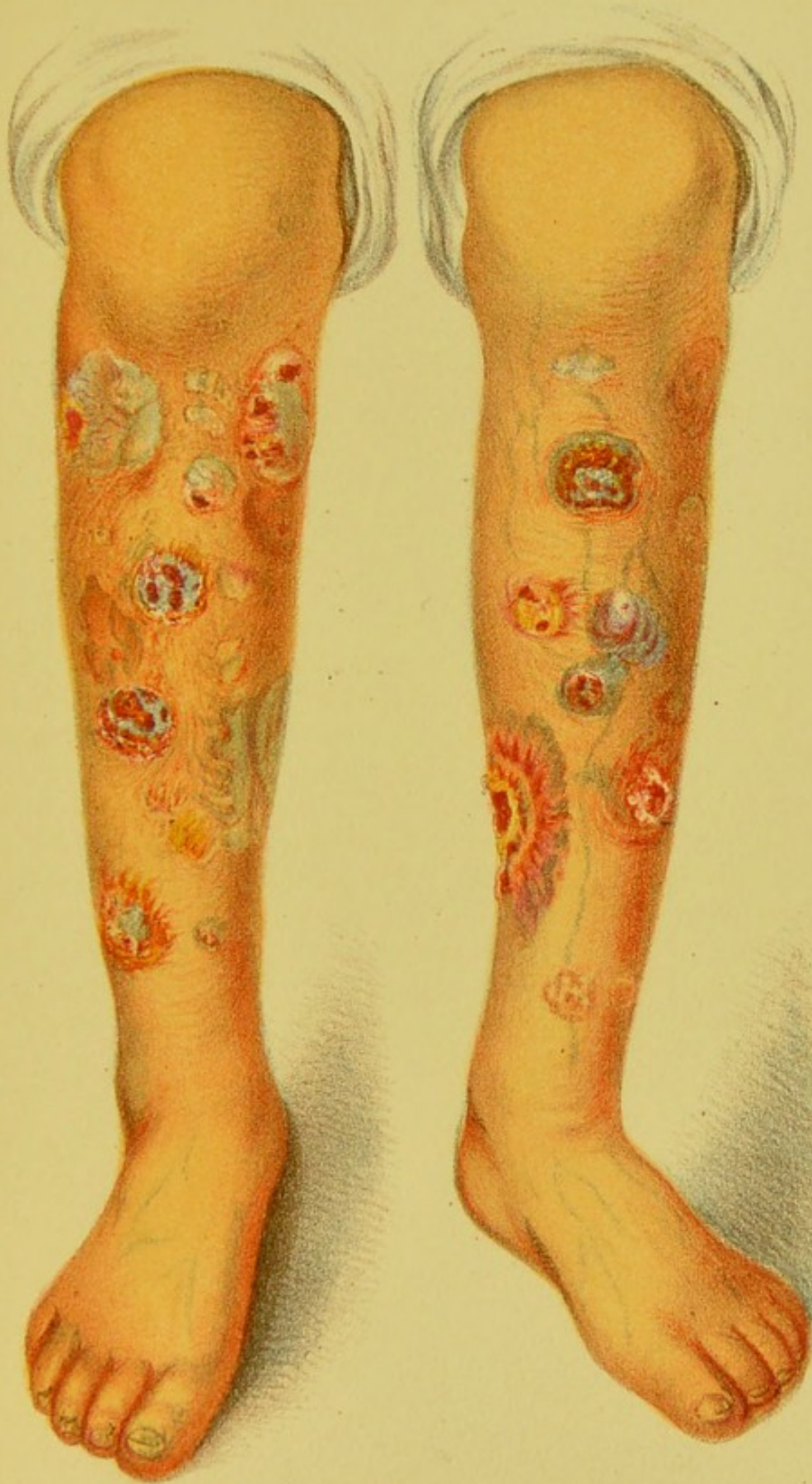


## PLATE CIII.

BAZIN'S MALADY.—MULTIPLE ULCERS ON THE LEGS.



THIS portrait shows the legs of Master R——, whose case is alluded to in 'Archives of Surgery,' vol. v., page 107, Case xi. It will be seen that there is slight general swelling, and that the legs are covered by scars and superficial ulcers. The latter are not well seen, being more or less covered by crust. The portrait was taken at a time when considerable improvement had been effected by treatment; but many of the ulcers still displayed, when the crusts were removed, irregular and somewhat undermined borders, and a surface destitute of granulations. The ankles and feet were wholly free, and so also, with very slight exceptions, were the parts above the knees. The portrait was taken about two years ago. At the present time all the sores are healed (July, 1893). Many of the scars are rather deep, and will be permanent.





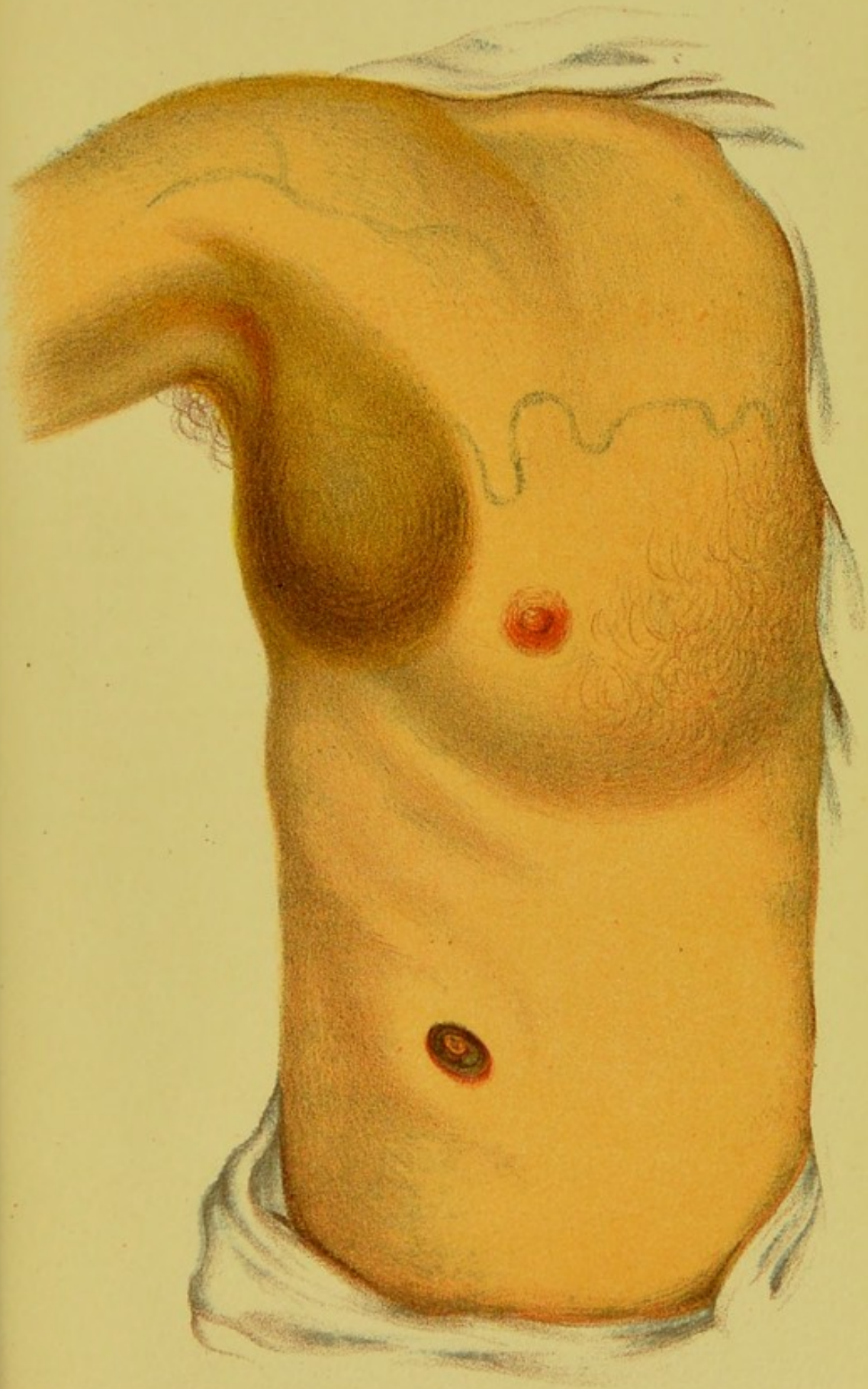



## PLATE CIV.


### MELANOSIS IN A MOLE, WITH SECONDARY GLAND DISEASE.



ON the right side of the abdomen is seen a little black patch. At the site of this patch there had been a congenital mole. During the year preceding the sketch, this mole had grown and produced a little fungating excrescence which a surgeon removed by ligature. The wound healed, but the base of the sore remained black, and shortly afterwards the glands below the axilla began to enlarge. When I was consulted, not only was there a mass in the armpit, but a long chain of indurated glands extended up the neck, under the sterno-mastoid. Any further operation was clearly impracticable. The man died with an enormous gland mass, and with indications of internal visceral disease, within about a year of the time when his mole first began to fungate. The case affords the clearest possible proof of the necessity for free and early excision of all moles which show any tendency to take-on growth.







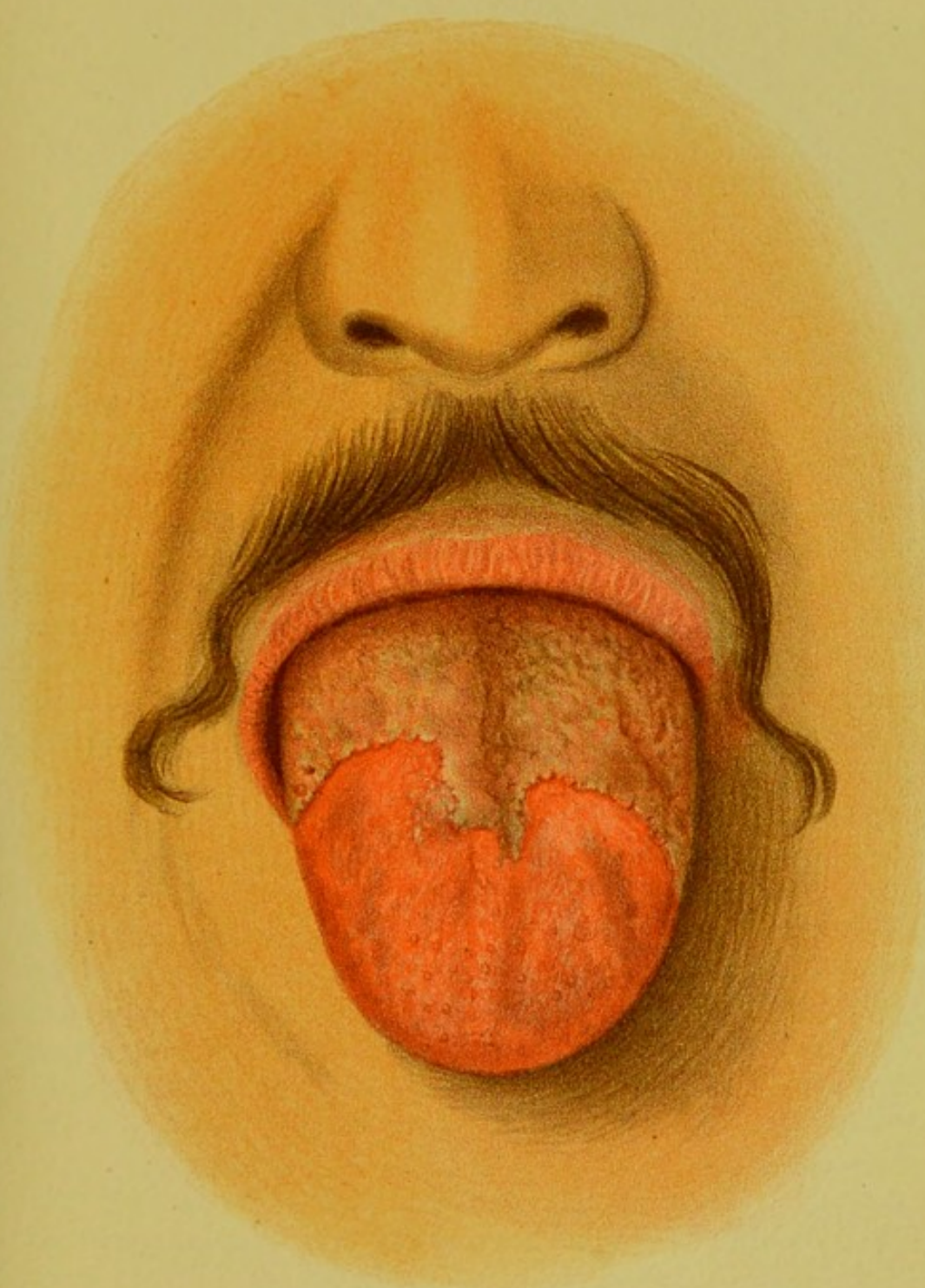



## PLATE CV.

### A TONGUE IN SECONDARY SYPHILIS.

---

THIS portrait, taken from the tongue of a young man who had been irregularly under treatment, for secondary syphilis, for some months, shows complete removal of the filiform papillæ over the front part of the surface. The margin of the patch is very abrupt, and looks almost as if there were ulceration. There was, however, none. The process was one of absolute atrophy of the papillæ, leaving the surface quite bald. The fungiform papillæ can still be seen, though in a shrivelled condition, on the denuded surface. The condition was unattended by any soreness, and it had been developed in the course of a few weeks, the patient being a smoker. In the course of a month, under mercurial treatment, the filiform papillæ had grown again, and not the slightest trace of the bald patch remained. I have had the patient under observation, for two years, since this portrait was taken, and, although he has been liable to various slight recurrences of syphilis on the skin, his tongue has never suffered since, and has indeed never presented other conditions than those of a perfectly normal state. In this feature of a complete and permanent recovery, the case differs from the more ordinary ones of what is known as ringworm of the tongue, in which the patches vary very much from time to time. During the secondary stage of syphilis we observe very peculiar and remarkably different conditions on the surface of the tongue. In many instances the papillæ are destroyed, and in a few they are hypertrophied.





## PLATE CVI.

### SENILE FRECKLES.—MELANOTIC STAINING.— EPITHELIAL CANCER.

---

THE uppermost figure in this Plate represents the condition of the eyelids in Mrs. P. L., whose case was given in 'Archives,' vol. iii., page 321. She was the subject of senile freckles, which on the left side had advanced to a condition of melanotic staining, and were accompanied by a small, unpigmented epithelial growth. This latter growth is seen on the lower eyelid under its outer half. The pigment patches, which are near it, were gradually extending. It will be seen that on the eyelid of the opposite side there are some slightly-marked patches of pigment-staining. Some treatment by scraping had been practised for the cure of the epithelial growth before I saw the patient. I had some doubt as to whether the little nodules shown in the portrait were not of the nature of keloid; but as the patient passed from under my care, I had no opportunity for making a microscopic examination.

The central figure shows the state of the eyelids in another lady of about the same age as in the preceding case (sixty-two years). It will be seen that the lower eyelid is very extensively pigmented. The stained part was mostly but little, if at all, thickened. The pigmentation was definitely aggressive, and had extended very considerably during the three years that the patient had been under my observation. There is little or nothing on the opposite eyelids which can be counted as senile freckles; but it will be seen that there is a little *nævus* very near to the edge of the lid. A similar and larger *nævus* is seen just over the inner canthus on the right side.

The left-hand lowest figure represents the eye of the same patient as the preceding, at a somewhat later stage. The lower eyelid has been drawn down, in order to show that the conjunctiva and even the cornea itself are pigment-stained. At the present date,

PLATE CVI. (*continued*).

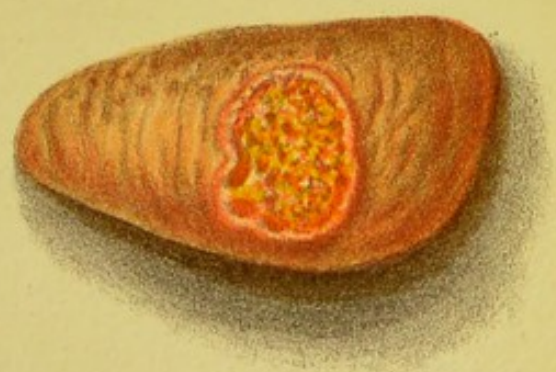
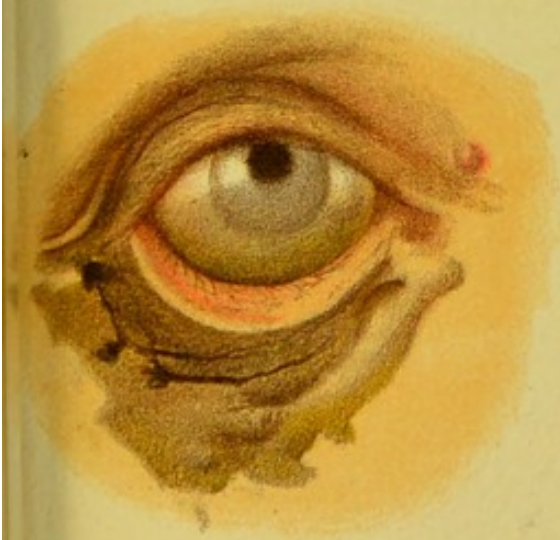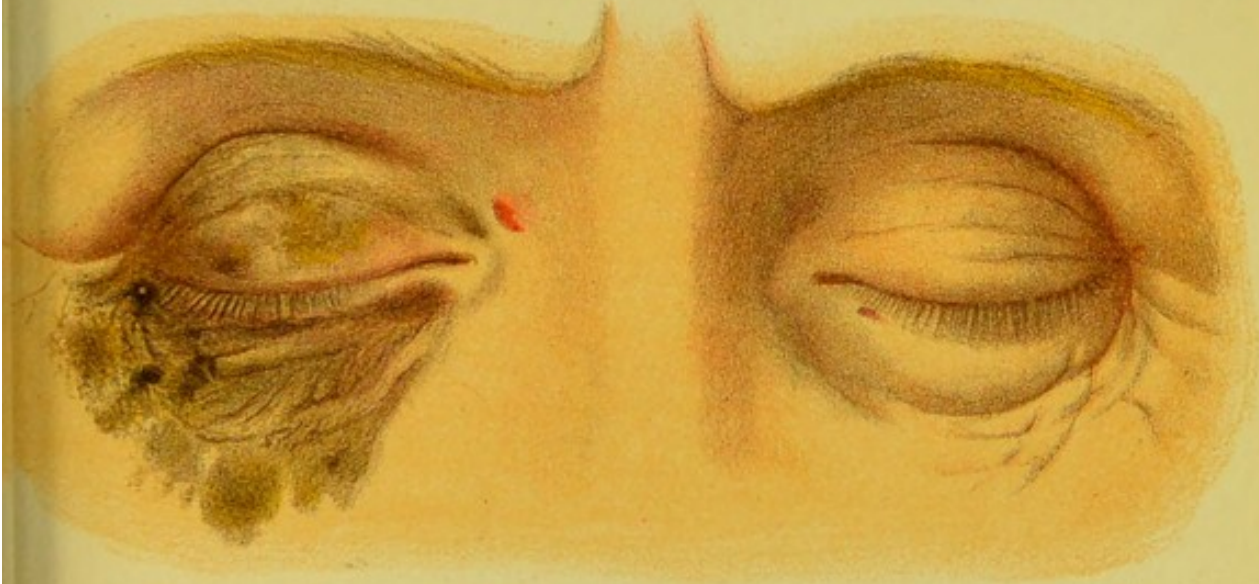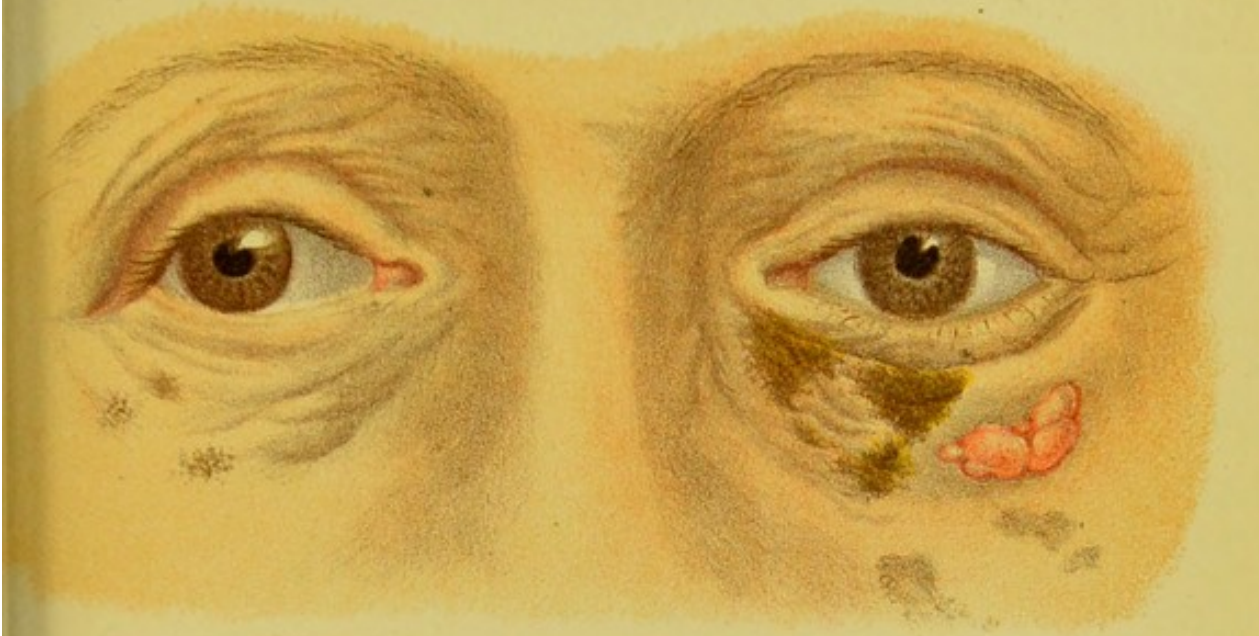two years after this sketch, the conjunctiva has become of a very deep brown, and in the cornea a narrow margin of sepia tint, affecting the arcus senilis, has extended round almost the entire circle. Only a very small portion of the corneal rim, in the middle line under the upper lid, is now free from staining. After watching this case for three years, much in the condition shown in the sketch, I have recently had to excise a portion of the lower lid on account of an epitheliomatous growth close to the edge, which, although still of small size, was developing rapidly. It was not pigmented. I have not attempted to remove the pigmented parts, as it will be seen that not only the eye itself, but the upper lid also is involved.


EARLY STAGE OF EPITHELIOMA OF THE TONGUE.


The right-hand lowest figure shows the portion of the tongue which I excised in the case of the late Mr. K. The little ulcer here shown had formed in connection with a sharp tooth, when Mr. K. was sent to me by his dentist. The characters of the ulcer are well shown. It was small, clean, and quite superficial; but it had a rolled edge, and a slightly hardened base. It had been present only a few weeks. The sketch, which was made after the operation, will prove that I excised it freely. No return of the disease ever took place in the tongue itself; but the patient died two years later from secondary disease of the glands of the neck.

This sketch may, I hope, prove useful in assisting towards the diagnosis of cancer of the tongue at an earlier stage than it is usually made. Perhaps cancer of the tongue was never in any case excised whilst apparently so insignificant, or under conditions apparently so hopeful as to permanency of recovery. Yet, as has been shown, the lymphatics were already infected.

*Postscript.*—Since the above was written, I have excised several undoubtedly cancerous ulcers of the tongue of yet smaller size than that shown in this Plate.







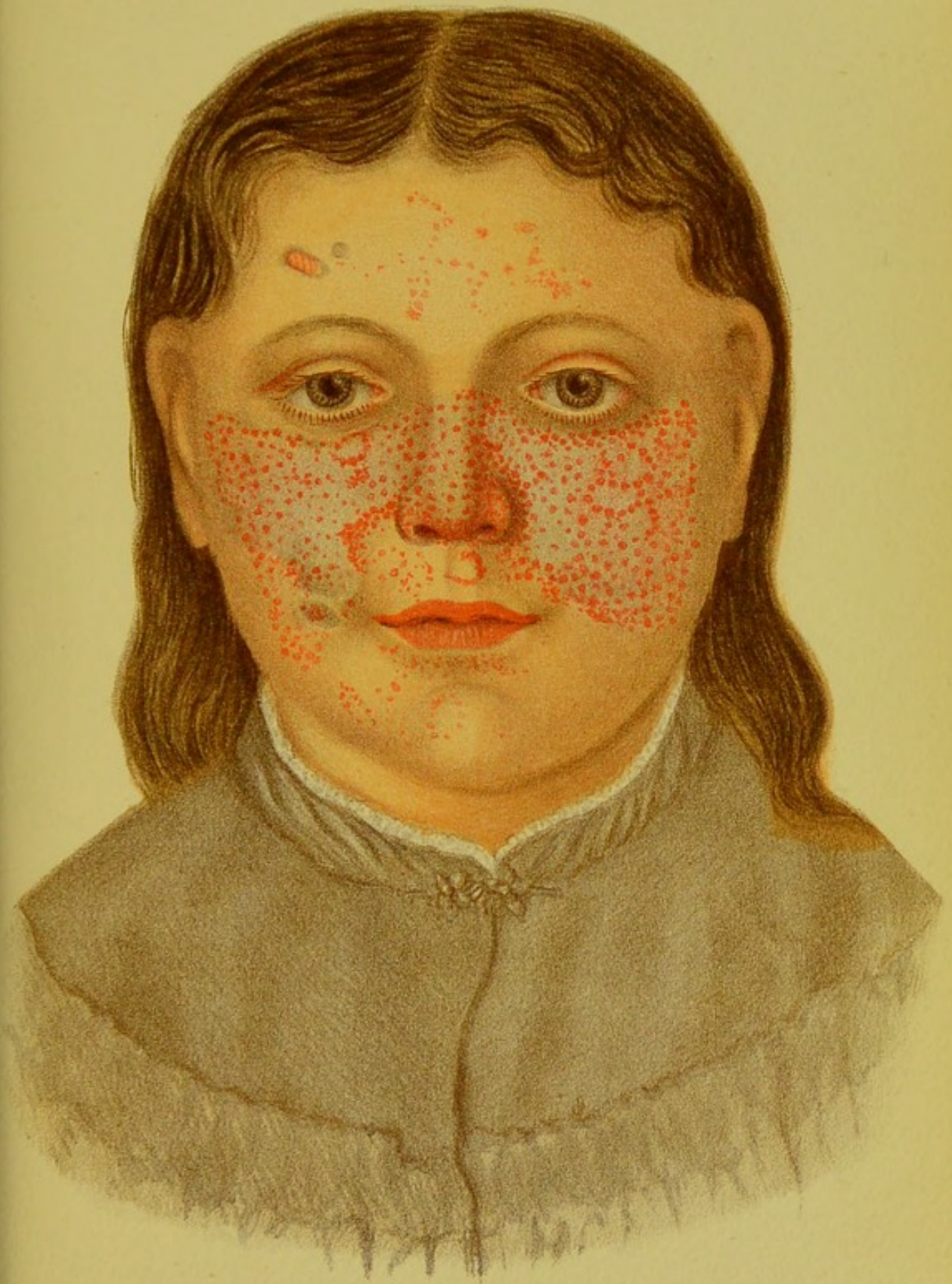


## PLATE CVII.


### A PECULIAR FORM OF LUPUS OF THE FACE.

---

THIS Plate is copied from a portrait which represents the state of the face in a young girl, who was sent to me by Dr. Waldo, of Bristol, for the purpose of diagnosis. The whole of her nose and the greater part of her cheeks were occupied by bats' body and wing superficial scar, stippled over with red lichenoid spots. On the upper lip a little crescent, or disc, of these lichen spots is seen, and a number of isolated spots are scattered over the forehead and lower parts of the face. It appeared that this lichen- or acne-papule was the first stage of the disease. The girl had had much local treatment, and it was uncertain as to how far the condition of scarring was due to it, but probably it was in the main a result of the disease itself. The child had suffered from three years of age. It will be seen that the disease differed as regards its initial lesion, and in the persistence of conspicuousness of the lichen papules, from what is usual in lupus erythematosus. It had also commenced at a much earlier age than this disease is ordinarily seen. The process was, however, evidently one of lupus, and I should incline to name it an Acne- or Lichen-Lupus.





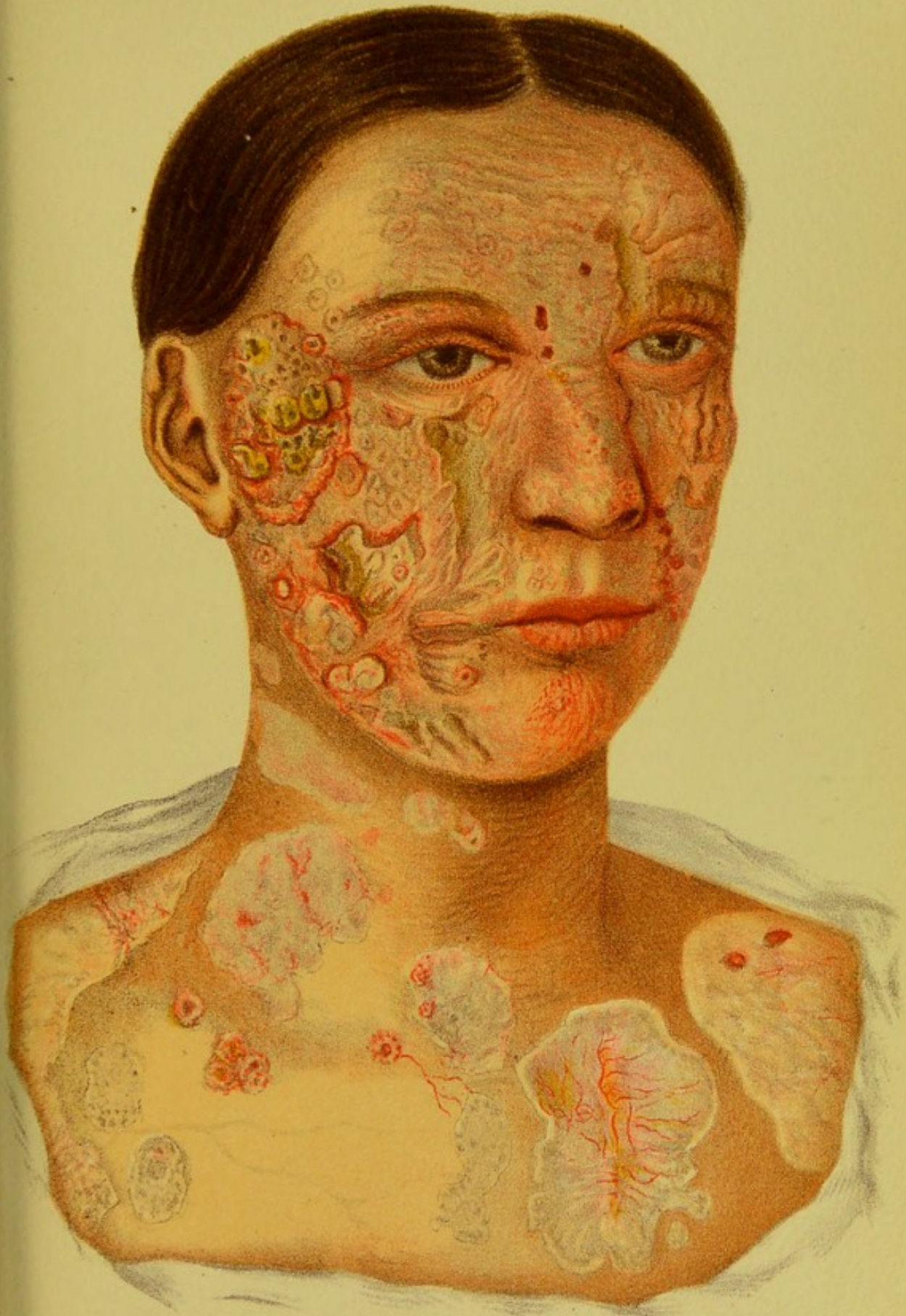


## PLATE CVIII.


AN ULCERATING SUMMER ERUPTION ON THE FACE.

---

THE patient whose face is here represented was under the care of Dr. Edison in the Leeds Infirmary. She was a girl of about eighteen, who had been admitted into the hospital every summer for several years. Her eruption always relapsed with the return of spring-weather, and she was accustomed to leave the hospital comparatively well every autumn. It could not be said, however, that she was absolutely cured even in winter. The eruption consisted of the formation of bullæ, which ulcerated and left large scars. In the first instance the disease had been confined to her face and hands, but of late it had extended to her shoulders. It still, however, restricted itself to these regions, and was clearly under the influence of exposure to air and sun. In another portrait the condition of the girl's hand and one ear is shown. Her ears were eroded, just as in certain forms of chilblain, and in some others of Summer Eruptions.









## PLATE CIX.


BAZIN'S MALADY.—MULTIPLE ULCERS ON THE LEGS.




THIS portrait represents the condition of things in Case 1, published in the 'Archives,' vol. v., page 85. The patient was a girl of thirteen, under the care of Dr. Colcott Fox, by whom another portrait, taken independently, was preserved. The girl had suffered from the ulcers of the legs for about four months. There was much dusky erythema, and the edges of the ulcers were considerably undermined. There was no reason to suspect syphilis; but there was a definite history of scrofula, both in the patient herself and her family.

[Dr. Fox has published a portrait of this case in the 'Dermatological Journal' for August, 1893. The reader may compare them with advantage, and also read Dr. Fox's excellent paper.]

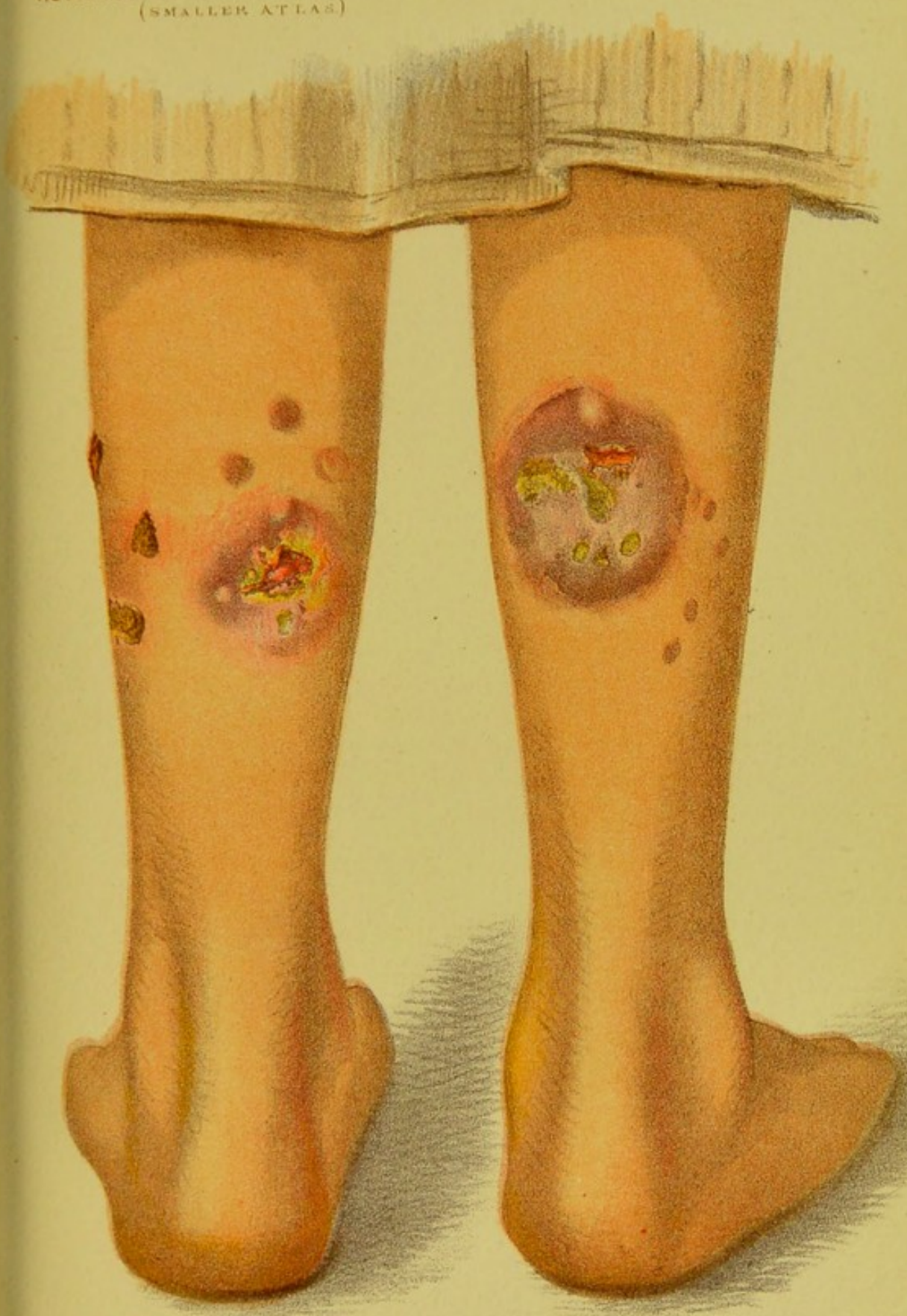






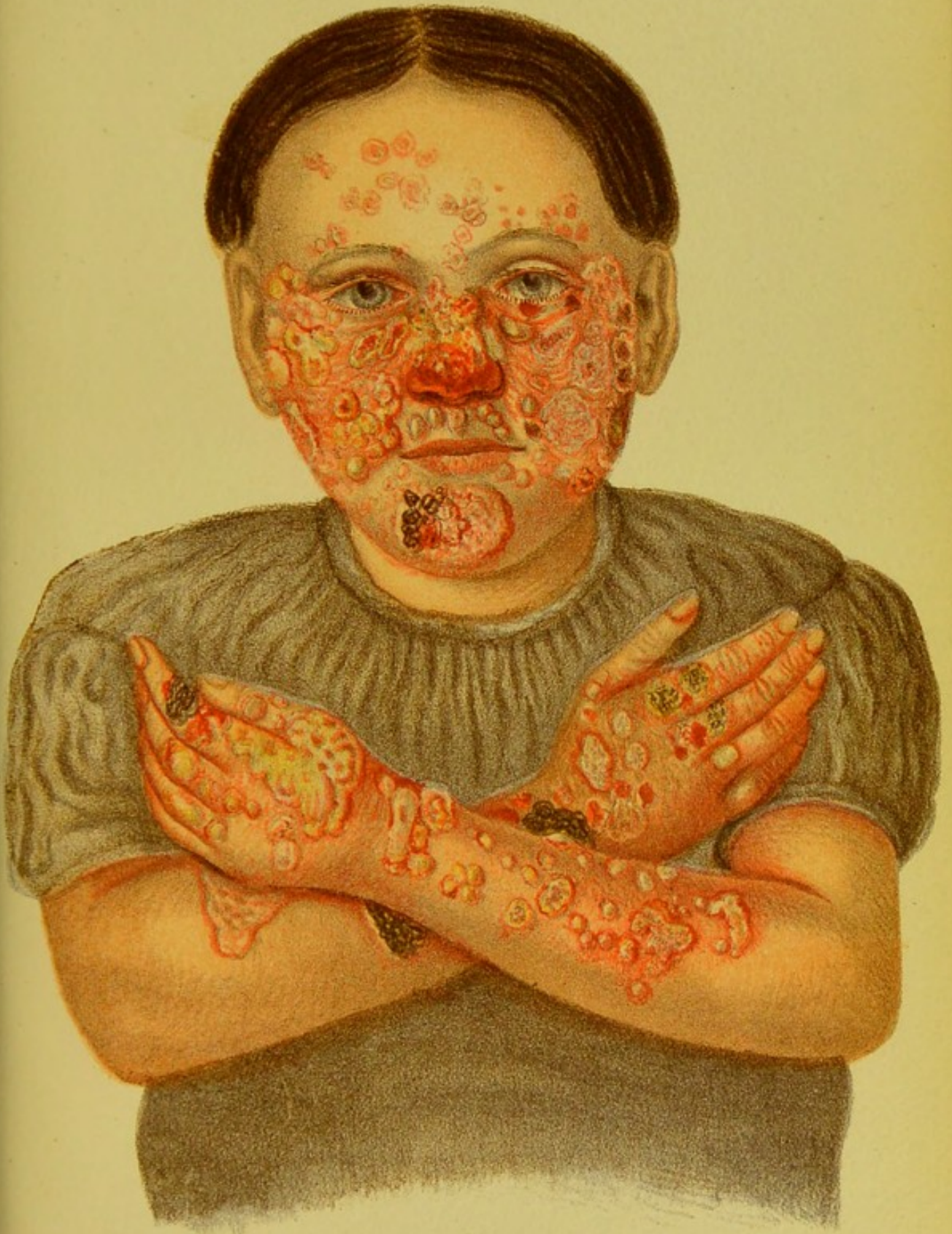


PLATE CX.


A SUN-ERUPTION.



THE subject of this portrait was a girl of seven, of a rather fair complexion, and possessing a skin very susceptible to the influence of sun. The whole of what is shown in this portrait was brought out by a single exposure, on one of the first hot days of early summer. She had had many previous attacks of less severity.









## PLATE CXI.

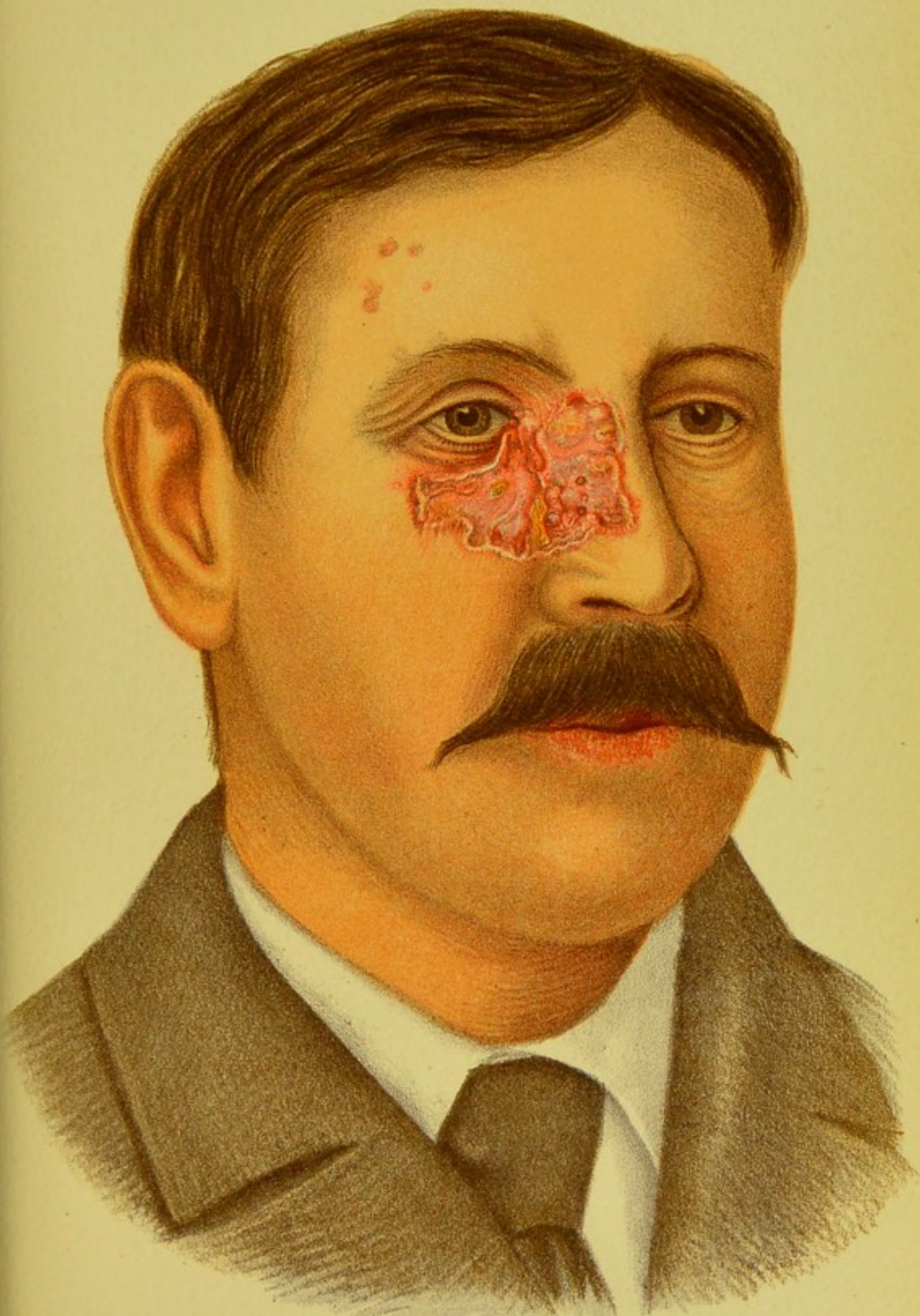
### RODENT CANCER IN A YOUNG MAN.


---


THIS portrait exhibits a well-characterised rodent ulcer, with a hard, rolled, sinuous border, which had been spreading for nearly ten years, in a man who, at the time the portrait was taken, was only twenty-five. It had been twice excised, and had twice recurred. A most interesting point in the history of the case is that the young man's father had been the subject of rodent cancer for many years before his son's birth. He (the father) died of the disease thirty years after its commencement. The greater part of his face had been eaten away.

In the present case my son performed a third operation, freely excising the growth, and transplanting on to the wound a large flap of skin from the forehead. The result appeared to be very satisfactory when the patient was last seen, but it is much to be feared that the disease will sooner or later return.

See also 'Archives,' vol. v., page 44.







## PLATE CXII.

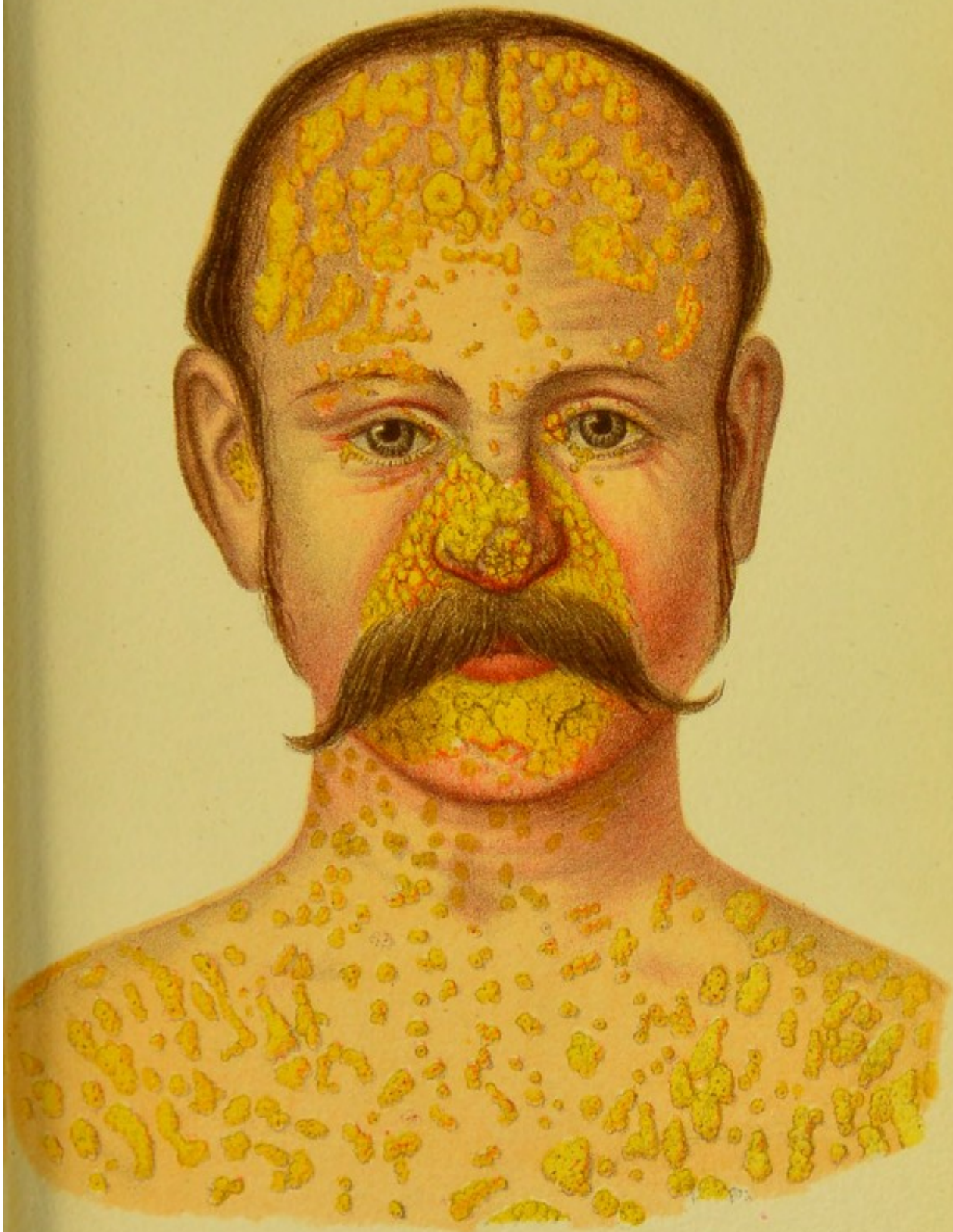
### XANTHELASMA DIABETICORUM WITHOUT GLYCOSURIA.


---


THIS portrait shows the condition in a patient whose case I have recorded in 'Archives,' vol. i., page 381. The patient was a healthy, florid man, who had suffered from the eruption for about eight months. Its advent had been preceded by a three weeks' attack of severe biliousness, after which the eruption had developed very rapidly. The spots were of a bright yellow, and in most places appeared to begin as a form of lichen around the orifices of the hair follicles. In most parts they were more or less grouped, and in many they had coalesced. They were most abundant on the face, forehead, genitals, and thighs. The usual positions of xanthelasma on the eyelids were avoided, nor were there any bands along the creases of the hands as in the multiple xanthelasma of jaundice. The patient had never had jaundice, and the only ailment which he admitted was a liability to sick headaches. Repeated examinations of the urine failed to detect any trace of sugar. It was of specific gravity 1020, clear, and of good colour.

The patient was sent to me by Dr. Williams, of Barrow-in-Furness, and I am indebted to that gentleman for repeated reports as to his progress. In the course of about a year or eighteen months, the eruption had, I believe, almost wholly disappeared. The treatment had consisted in the use of taraxacum, mercury, and nitric acid.

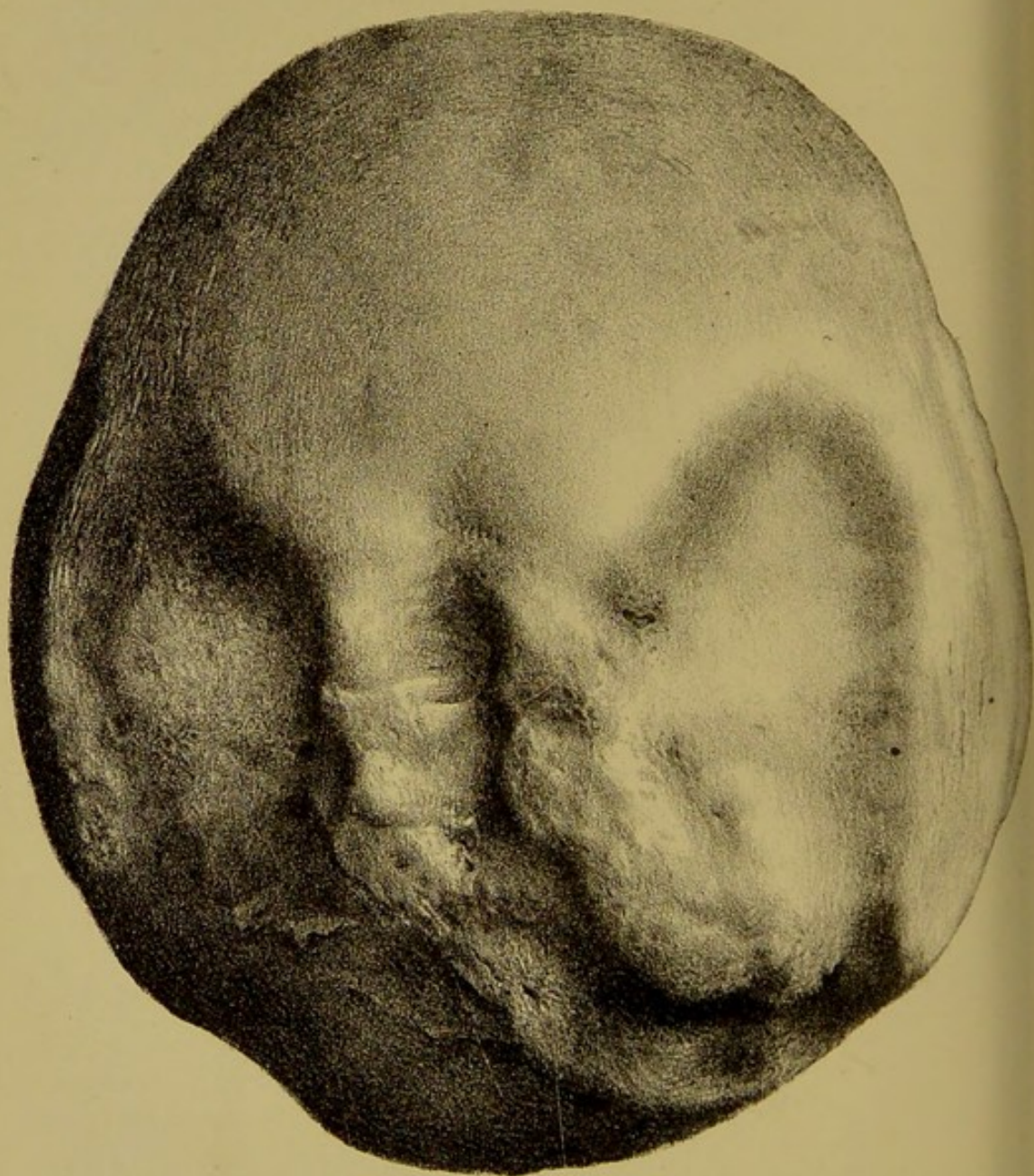In spite of the absence of sugar in the urine, the case must clearly be placed with those first described by Sir William Gull in which a special form of transitory xanthelasma occurs in association with diabetes. It was no doubt in association with functional disorder of the liver, and although in the ordinary sense of the word there was no jaundice present, it ought perhaps to be regarded as being in itself a form of jaundice.











## PLATES CXIII. & CXIV.

### SYMMETRICAL HOLLOWs ON THE SURFACE OF THE SKULL.

---

BOTH these Plates are taken from photographs of specimens in the Dupuytren Museum in Paris. They illustrate the curious symmetrical depressions in the parietal bones which have now been recognised in a considerable number of instances. Skull-caps showing these depressions may be found in most of our large pathological museums. They are usually those of elderly persons. They have as yet scarcely been connected with any known life-histories. It has been conjectured that they are due to some senile change. I have myself ventured the hypothesis that they may, in some cases at least, be consequent upon carrying burdens on the head. In 'Archives,' vol. v., page 359, I have published a case in which these depressions were recognised during life in a patient who had suffered from syphilis, and since then I have met with another case of a similar kind. Dry caries resulting in deep pits is a not very uncommon condition in tertiary syphilis, but it is not usually symmetrical. The depressions shown in these Plates are usually accurately bilateral, the hollow being commonly of oval form and taking the place of the parietal eminence. Its shape and size are much as if a hen's egg had been pressed down on to a soft solid. This description applies well to Plate CXIV.; but in Plate CXIII., in addition to the two lateral hollows, there is another placed almost centrally. For some notes on this condition see 'Archives,' vol. v., page 228.

That these depressions are not invariably in association either with carrying burdens or with syphilis is rendered certain by a specimen in the Cambridge Museum of Anatomy. In it the skull of an Orang displays these hollows in precisely the same positions in which they are usually seen in the human subject. Cambridge, thanks to the zeal of Sir George Humphry, is rich in specimens of this kind. The Museum of Pathology contains no fewer than eight specimens, one of them showing an extreme condition in which over large bilateral areas only a paper-like layer of bone remains. Sir George Humphry has given much attention to the subject, and his theory is that the hollows result from the attrition of the posterior part of the occipito-frontalis, or bones the nutrition of which has been rendered feeble by age.

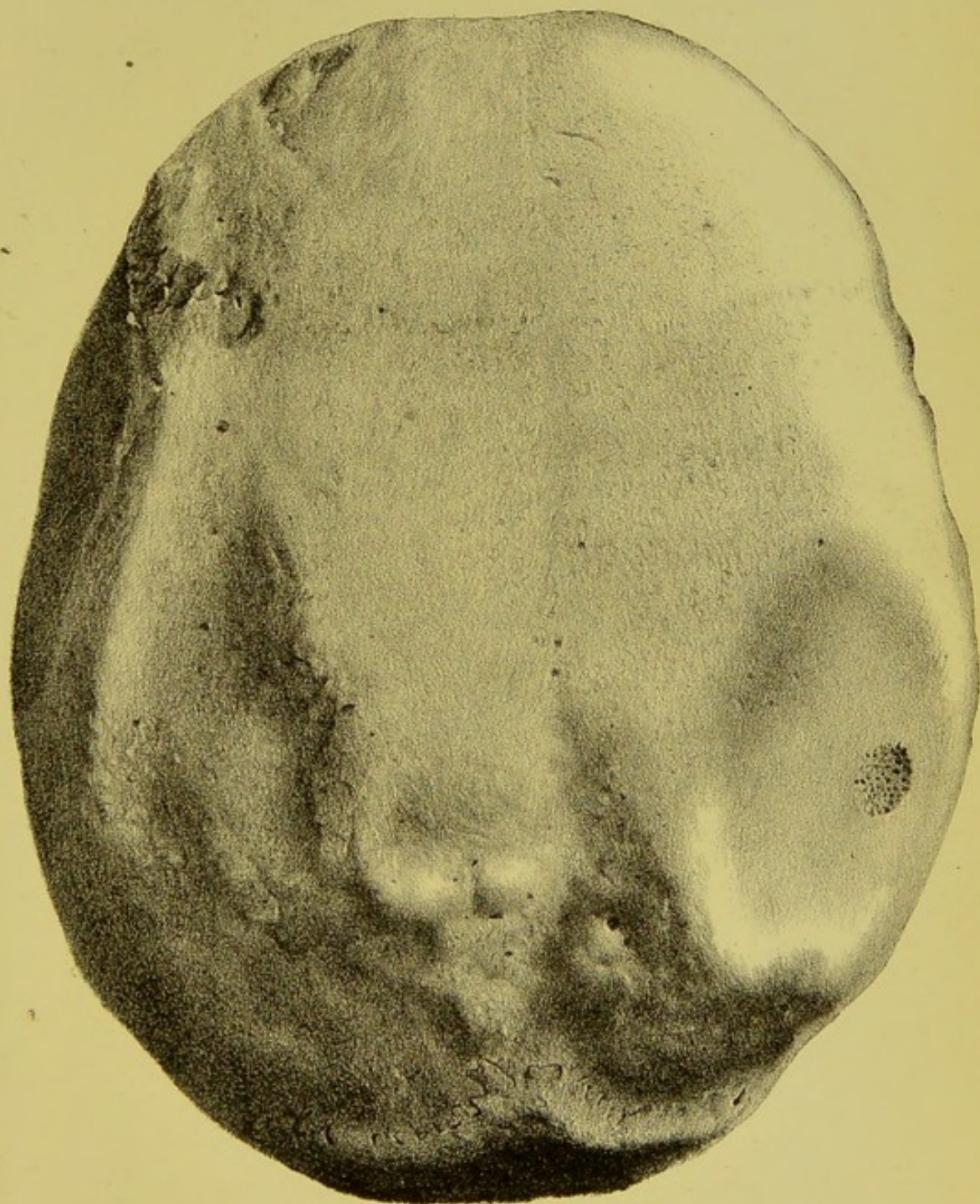
THE UNIVERSITY OF CHICAGO  
LIBRARY


THE UNIVERSITY OF CHICAGO  
LIBRARY


THE UNIVERSITY OF CHICAGO  
LIBRARY

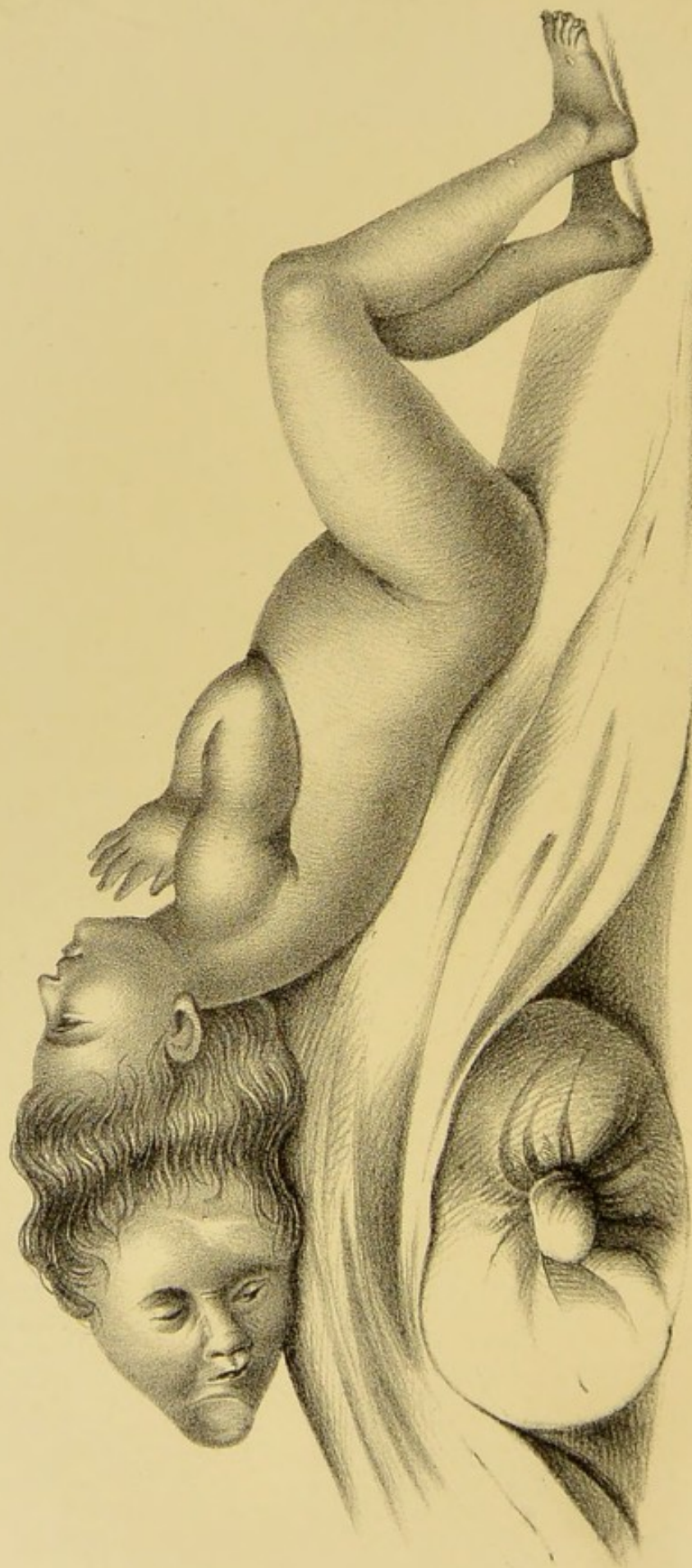
THE UNIVERSITY OF CHICAGO  
LIBRARY

THE UNIVERSITY OF CHICAGO  
LIBRARY










## PLATES CXV. & CXVI.

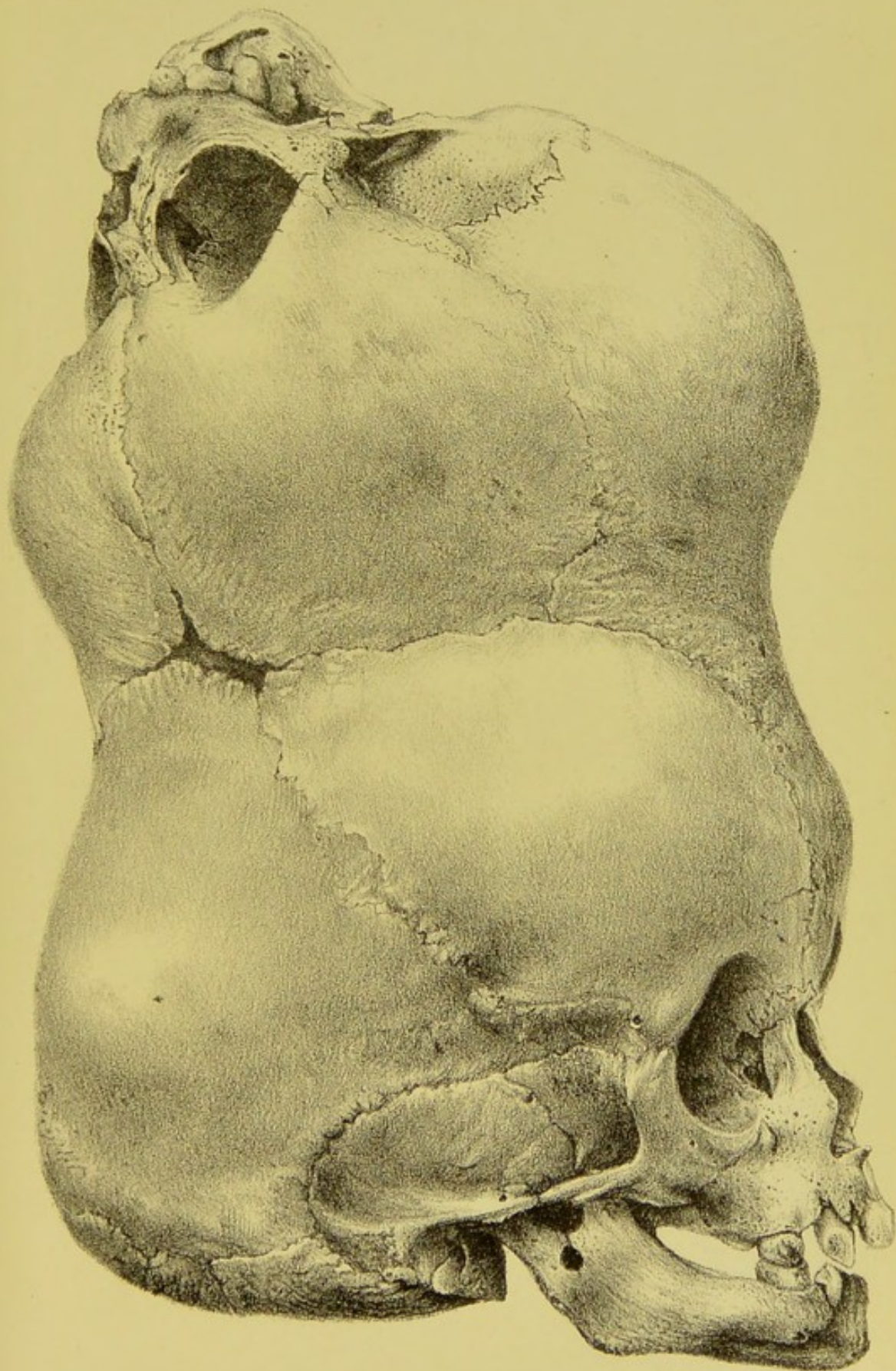
### DUPLICATION OF THE SKULL. CRANIOPAGUS.




THESE Plates are taken, the one from a specimen in the Museum of the Royal College of Surgeons, and the other copied from a Plate published by John Hunter in the Transactions of the Society for the Improvement of Medical Science. The Plate CXV. shows the condition during life of the child whose skulls are depicted in Plate CXVI. The child was born in India, and lived to the age of four years, when it was killed by the bite of a rattlesnake. As will be seen, it possessed two heads united by their crowns. The face of each was complete, and there were no other abnormalities in the development of the body or limbs. The duplicate head possessed the power of moving its eyes, cheeks, and lips. There was no neck. The base of the skull shows the foramen magnum and the other foramina considerably smaller than those of its fellow skull. The lower jaw was also less well-developed. The specimen is described by Mr. Lowne in the catalogue of the Teratological Collection of the College, page 37, No. 138. It will be seen that the faces are not directed in the same line. The left frontal bones of one skull articulate by sutures with the right frontal bones of the other, and *vice versa*. The external ears were represented by mere folds of skin, and there was no auditory meatus. The brains were distinct, each invested in its own membranes, which adhered at the points of contact. It is stated that the movements of the face of the accessory head were not controlled by the feelings or desires of the child, and that the eyelids were usually open, even during sleep.










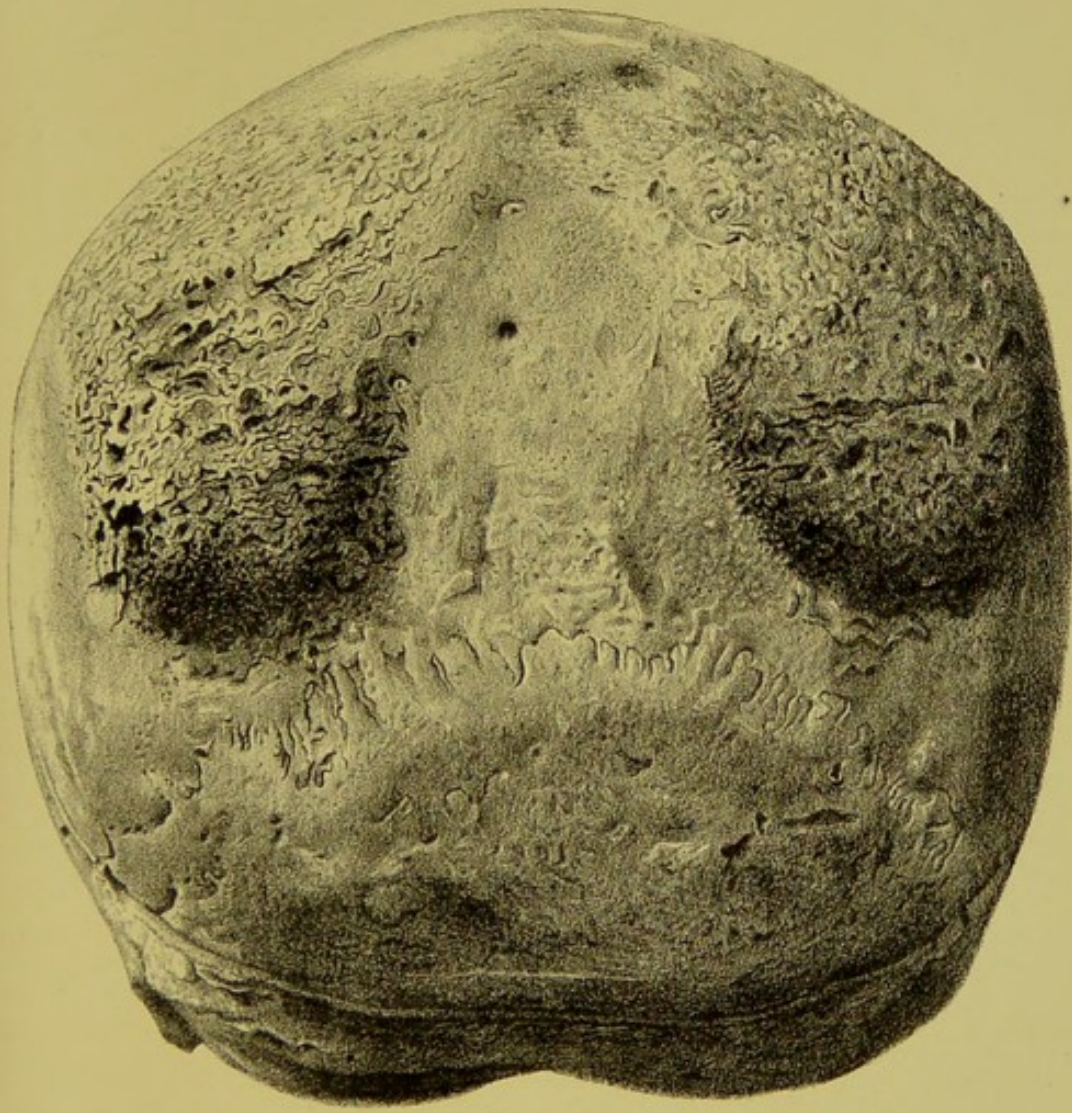


PLATE CXVII.


“PARROT'S BOSSES.”



THIS Plate, taken from a specimen in the Dupuytren Museum, shows the usual position of the periosteal deposits on the parietal bones known as “Parrot’s Bosses.” They are characteristic of inherited syphilis.









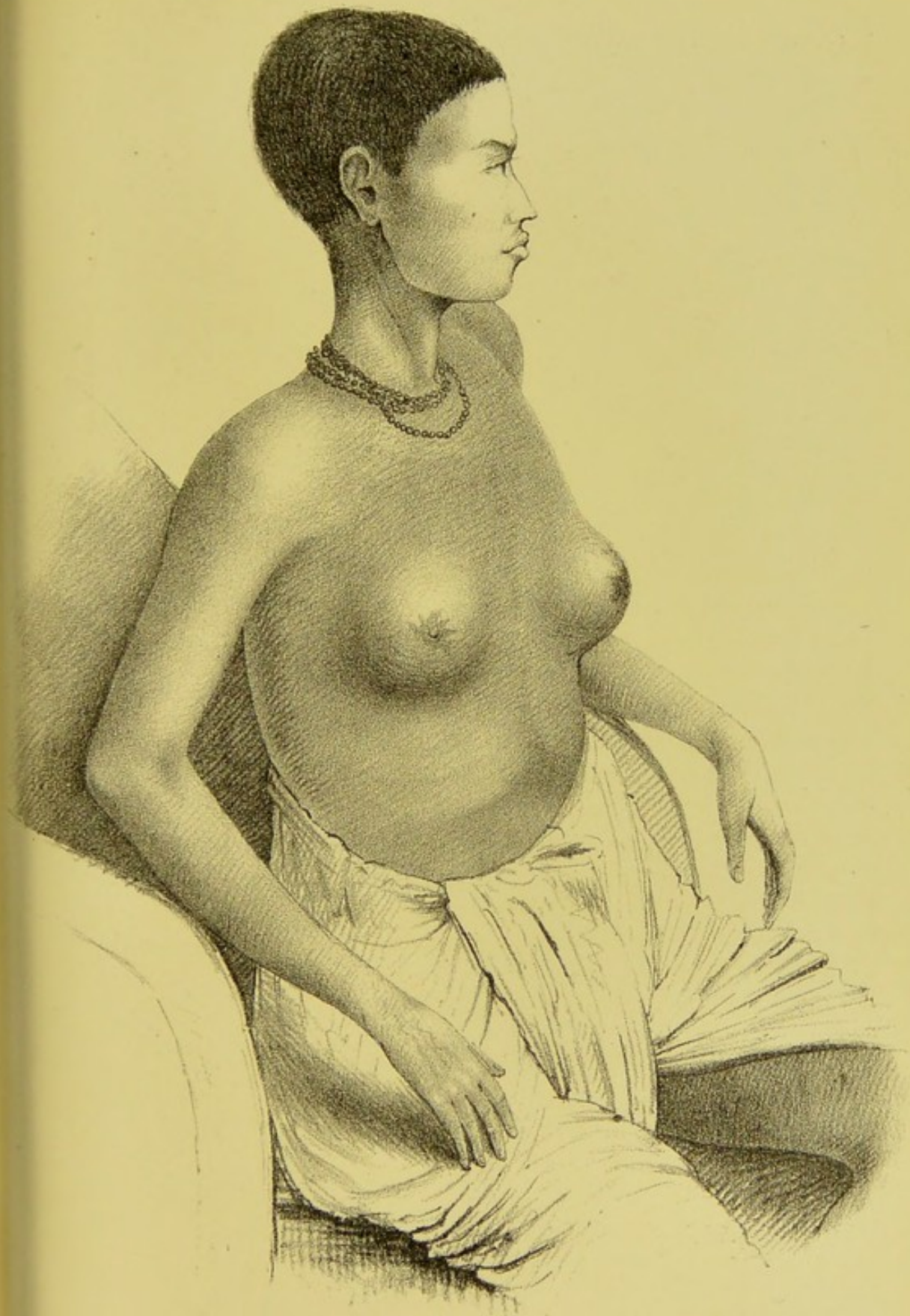
## PLATE CXVIII.


### GYNÆCOMAZIA WITHOUT OBESITY.




I AM not able to give any particulars respecting the subject of this portrait beyond the fact that he was a man, and that he applied at a hospital to have his breasts removed, because their size rendered him an object of ridicule.

The portrait is copied from one which I procured by purchase, and with nothing more than these bare facts recorded on it. Nothing is said as to the condition of the other sex-organs or as to evidences of virility. It may be assumed, however, that no abnormality was detected. Although not in any degree stout, the man has certainly a feminine appearance; but allowance upon this point must be made for his race, age, and the addition of a feminine ornament on his neck. The nipples do not appear to be enlarged in ratio with the bulk of the glands.







## PLATE CXIX.

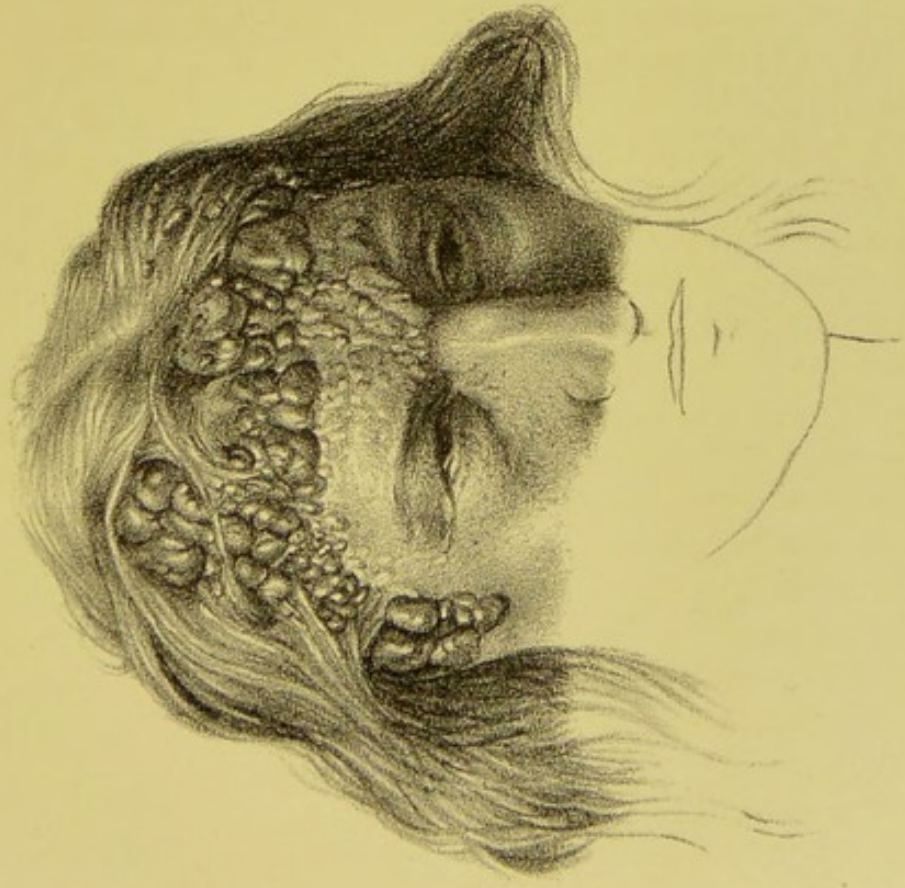
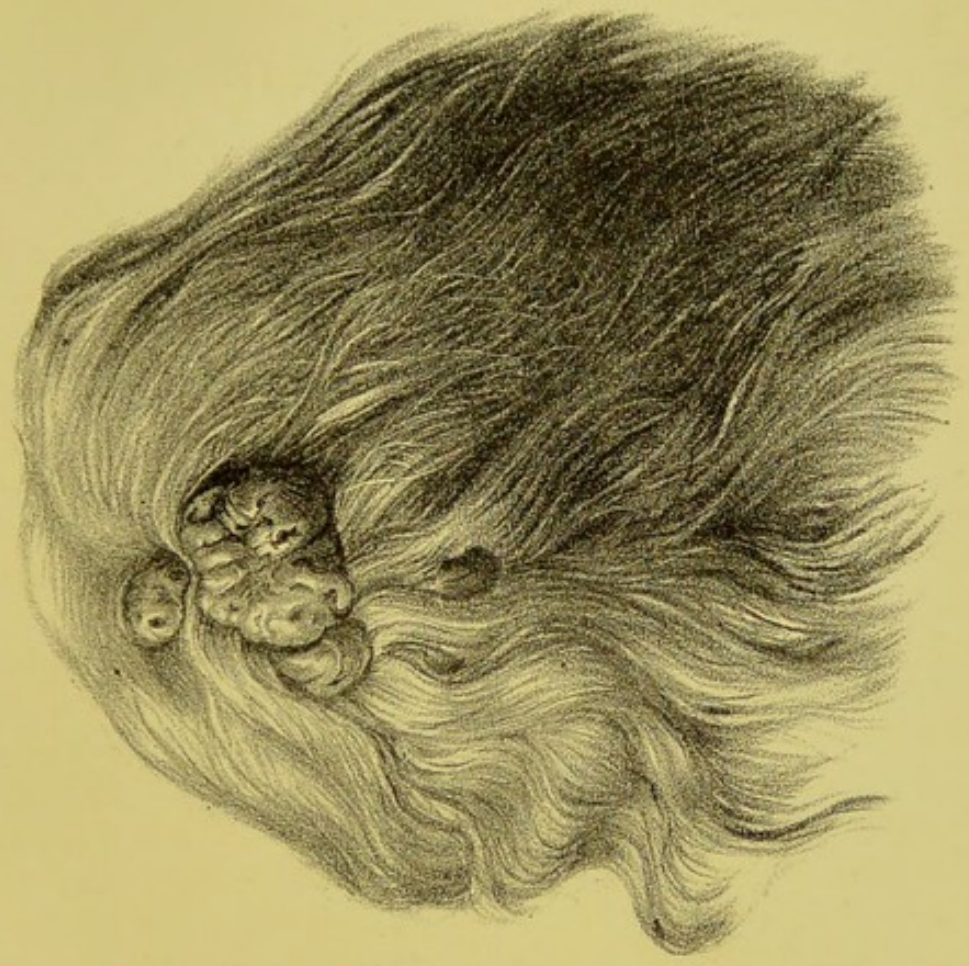### TUMOURS OF THE SCALP.


(DR. ANCELL'S GROUP.)

THE particulars of the case to which these photographs belong have been recorded by Dr. James W. Barrett and Dr. Percy Webster, of Melbourne, in the 'British Medical Journal' of February 6th, 1892. The patient was a healthy widow-woman, sixty years of age, who came under care for cataract. She said that she had always had good health, but that in girlhood she had had some eruption of boils on her scalp. These, however, got quite well, and it was not till her twenty-third year, when after the birth of her fifth child she had her head shaved in order to strengthen the hair, that the growths from which she was afterwards never free were discovered. For some years she thought they were not bigger than peas, and she believed that some would disappear and new ones form. After a time, however, they began to increase both in number and size, and during the last twenty-five years they had been steadily spreading over the whole scalp and forehead. They gave no trouble and never ulcerated. Two which were excised quickly grew again, and one which was cauterised was very slow to heal. At the time that the photo was taken, some of the tumours were small subcutaneous nodules over which the skin was quite healthy; others had grown to the size of a small tomato and become more or less pedunculated. Some of the largest were evidently formed by the coalescence of smaller ones. No history is given as to this patient's predecessors, but it is recorded that two of her daughters had developed tumours exactly similar to those in their mother. In one of these, now dead, they began at the age of seventeen or earlier: and in another, aged twenty-six, the scalp and forehead were covered much as in the mother's case, though not so extensively. In this daughter some small growths had occurred on the chest and shoulder.

A microscopic examination of one of the tumours was made. The section showed an "even, yellowish, granular surface, without any coarse septa." The microscope revealed "solid masses of epithelioid cells, arranged in spheres and cylinders, separated by fibrous tissue, and giving the whole the appearance of a solid adenoma."

See Plates XC. and CXX.





# STATE OF

NEW YORK

In SENATE,

January 1, 1880.

REPORT

OF THE

COMMISSIONERS OF THE LAND OFFICE

IN ANSWER TO A RESOLUTION PASSED BY THE SENATE, APRIL 1, 1879.

ALBANY: PUBLISHED BY THE STATE PRINTING OFFICE, 1880.



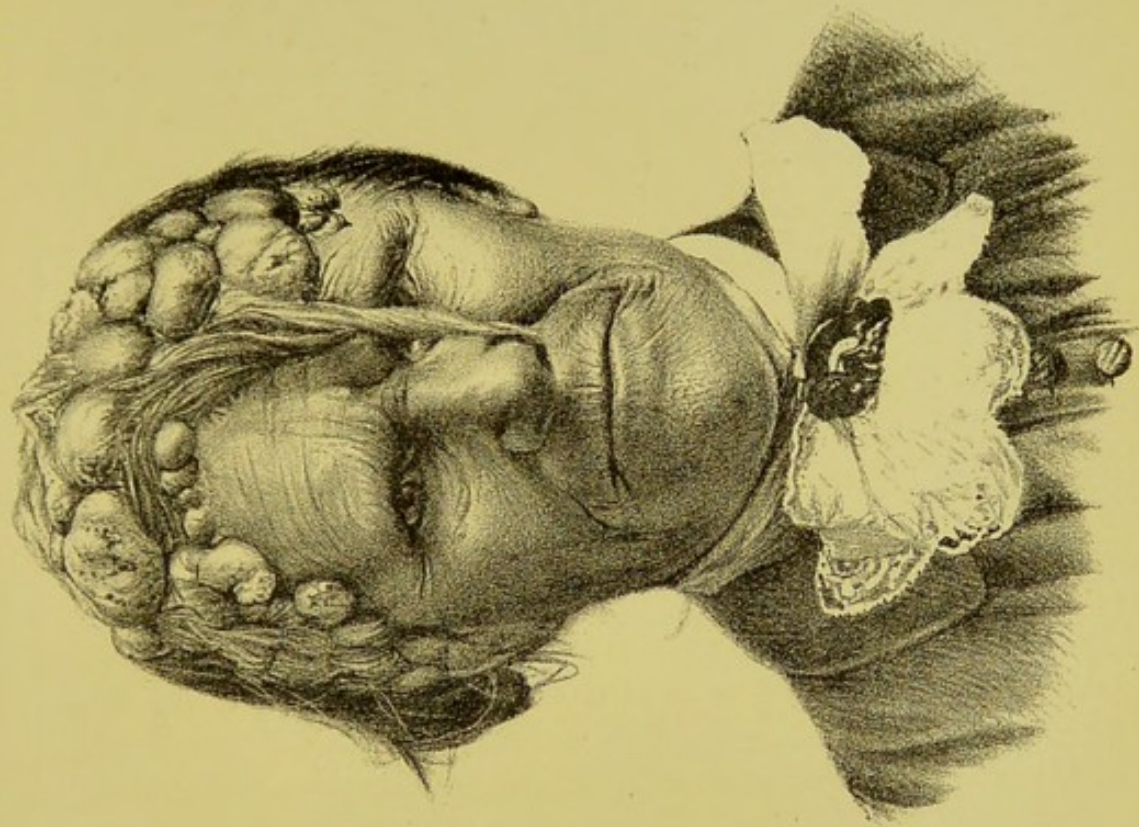
## PLATE CXX.

### TUMOURS OF SCALP.

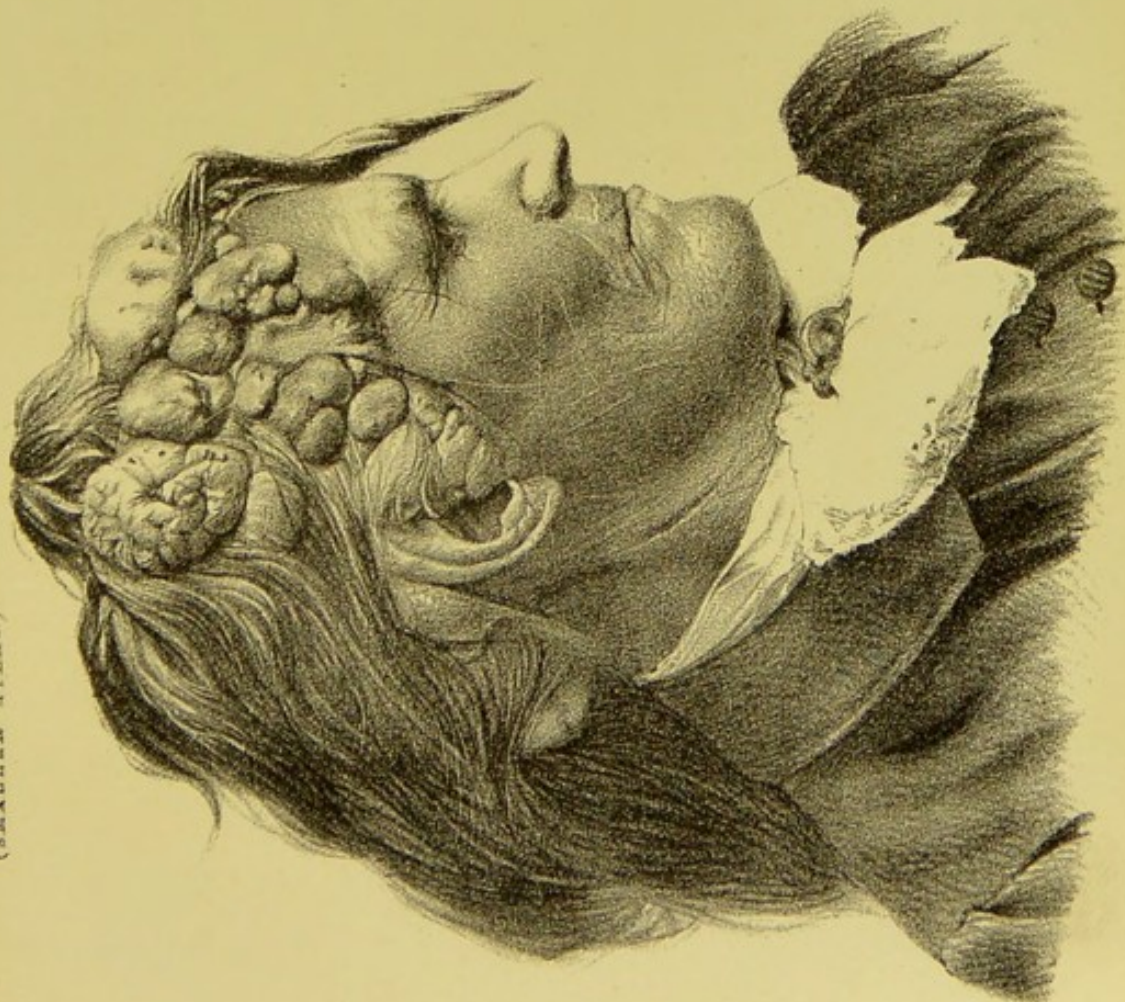
(DR. COHN'S CASE. THE ANCELL GROUP.)


---


THE portraits given in this Plate are copied from photographs kindly given me by Dr. J. S. Cohn, of Portland, U.S.A. They represent the condition of the scalp in a woman of about fifty. The tumours had been present for many years, and were gradually increasing in numbers. There was a hereditary history, but no conclusive evidence that these tumours, which were solid, had ever been preceded by cystic ones. The close similarity of the case to the other two will be obvious to any one who compares the engravings. At first glance one might mistake the Australian portrait for that of Dr. Cohn's patient. As the previous occurrence of cystic tumour is proved in Dr. Ansell's patient, it may fairly be inferred that the others had a similar history, had it been obtainable. Dr. Cohn has published the details of his case, but at the present moment I have mislaid the reference. I am much indebted to him for his kindness in sending me several photographs and answering my questions respecting the case.



West Newman lith.







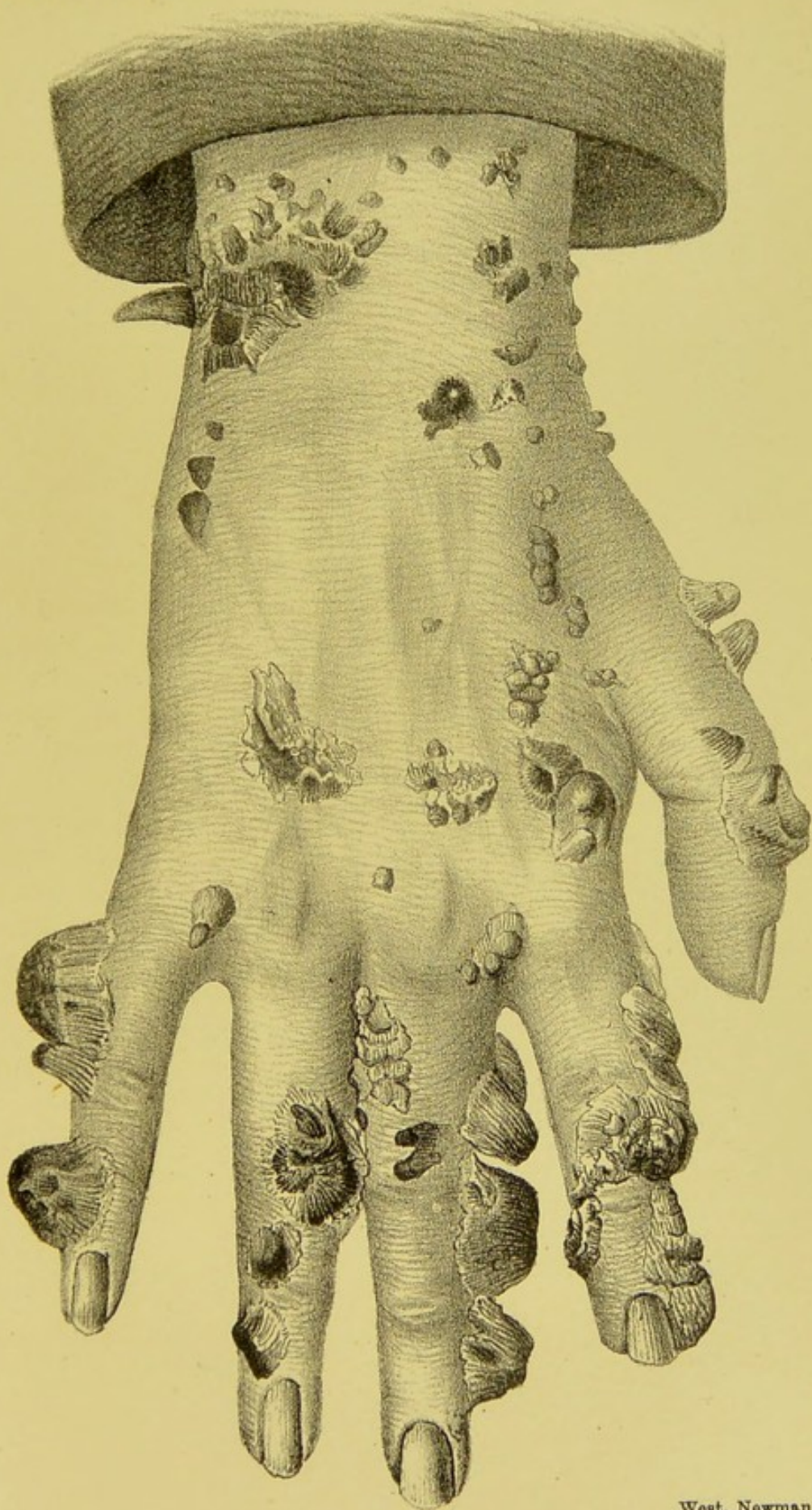
## PLATE CXXI.


### ICHTHYOTIC HORNS.




THIS lithograph, which has been copied from one published by Dr. Radcliffe Crocker in Vol. XII. of the 'Clinical Society's Transactions,' illustrates the growth of horns on the hand in connection with Ichthyosis. The patient was a boy, and the disease was congenital. Although it was very extensive, it was not universal, being arranged more or less in streaks and patches. It will be seen that on the hand the portion of skin between the horns appears to be healthy. I have introduced it on the present occasion, thinking that it may possibly illustrate the early stage of the same malady which Cruveilhier's portrait shows in one much more advanced. The forefinger of Dr. Crocker's patient may be suitably compared with the thumb in the other portrait. The horns were of epidermic structures.

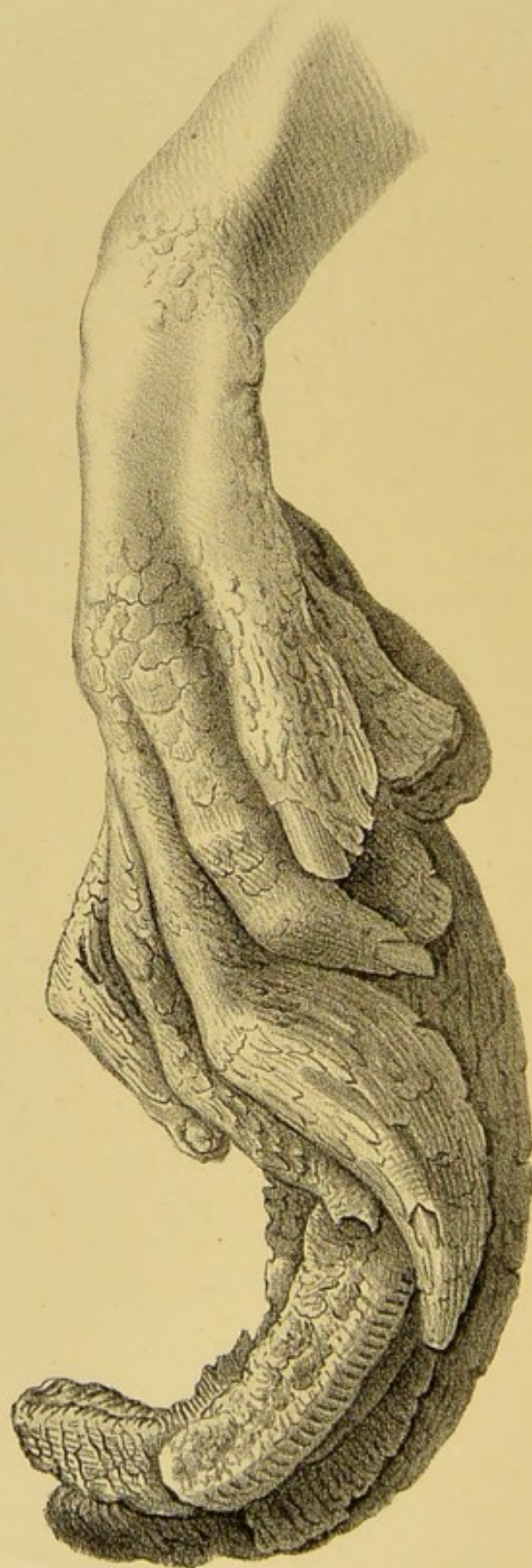See Cruveilhier's portraits, Plates CXXII. and CXXIII.; also for further details see 'Archives of Surgery,' vol. vi., page 3.












## PLATES CXXII. & CXXIII.

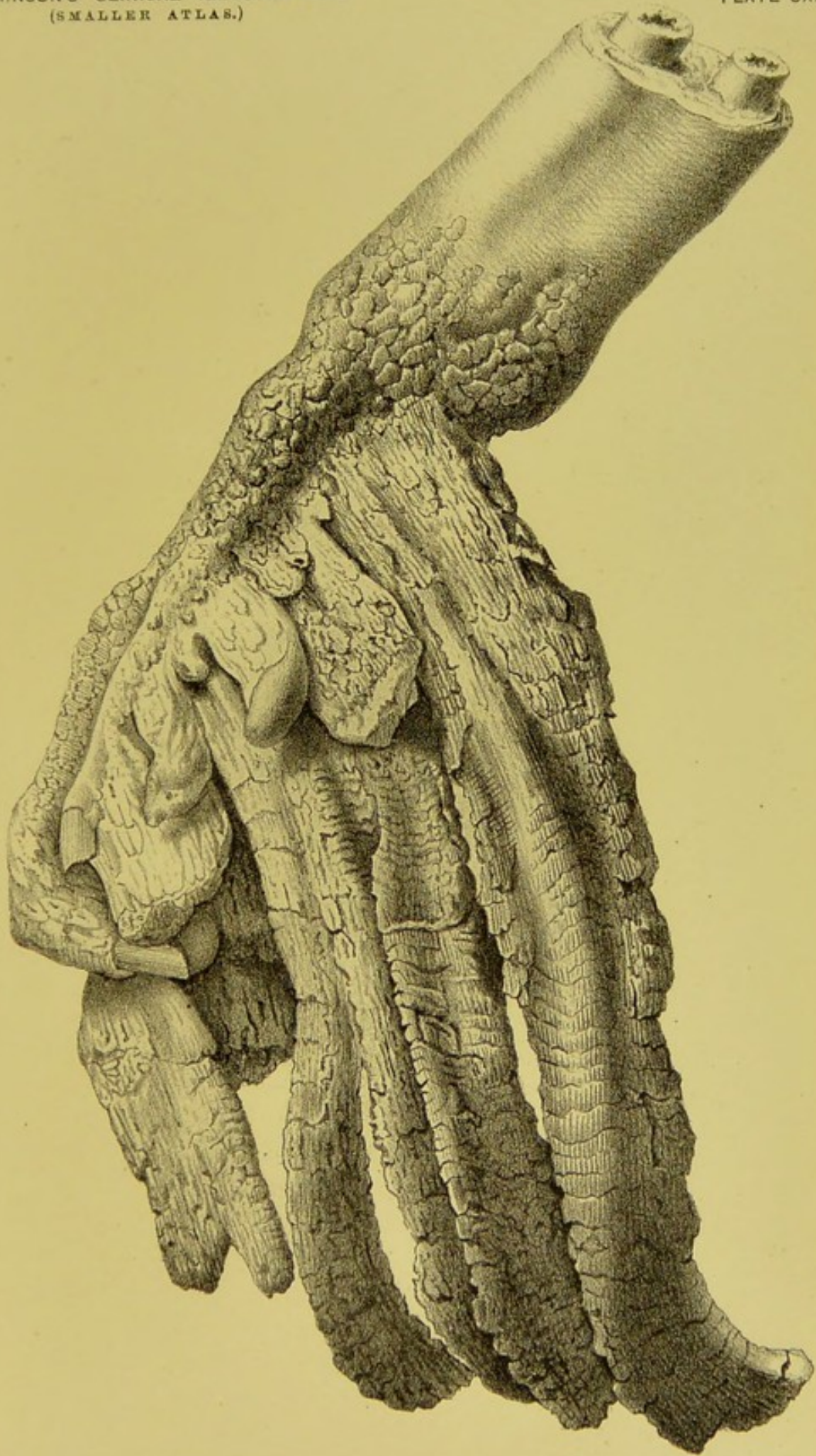
### A REMARKABLE CONDITION OF HAND, PROBABLY ICHTHYOTIC HORNS.




THESE portraits, copied from a plate in Cruveilhier's Atlas, represent the hand of a patient of whom no history was obtainable. A most extraordinary condition has been produced, apparently by epidermic modifications of an ichthyotic kind. The digits are hardly to be recognised, and it will be seen that the longest projections are of the nature of horns growing from their palmar aspects, or perhaps from the palm of the hand itself. The thumb is seen to be covered with epidermic prolongations, some of which project by the side of the nail. The nail of the index finger is dwarfed, and the skin is affected much like that of the thumb, but less severely. The middle finger has its end very much prolonged, apparently by the involvement of its nail and of the whole of its pulp in horny growth. The ring- and little-fingers are affected on the same pattern as the thumb and index. The larger growths appear to be from the palm. It may be conjectured that the case was one of congenital ichthyosis, which had been neglected, and in which the patient had attained adult age.

The hand had clearly been removed by a circular amputation during life.









## PLATE CXXIV.

### ENCHONDROMA OF THE PAROTID.




THIS portrait, taken from a photograph, represents the size and shape of an enormous parotid tumour. The patient was a man who was gardener to my late friend Mr. Edwards, of Keston. Mr. Edwards told me that he had known of the tumour for five and twenty years, and that it had been slowly growing without pain, and without much inconvenience except from its bulk. It had well illustrated the law of tumour-growth, *i. e.*, of population increase, in that its rate of growth had increased in ratio with its size. The old man had always refused to have it removed. It finally, between the ages of 70 and 80, ulcerated, and brought about his death. I have seen one or two other parotid tumours almost as large, but none which had attained quite the dimensions which this portrait shows. In one which I saw under the care of the late Sir William Ferguson, its removal was followed by death. The lesson is obvious that these tumours ought to be excised whilst small.









## PLATE CXXV.

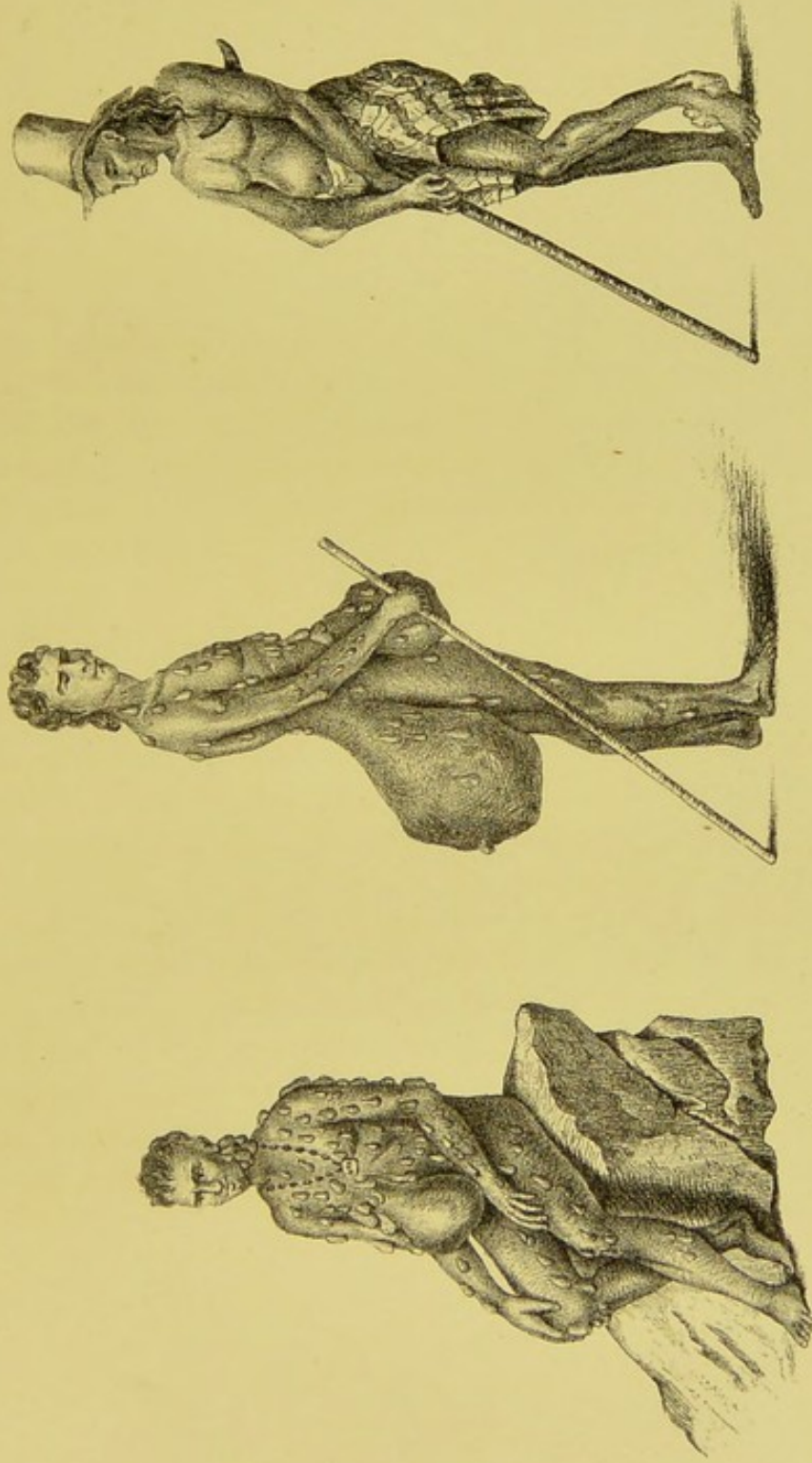
### MOLLUSCUM FIBROSUM MISTAKEN FOR "LEPROSY" AND "ELEPHANTIASIS."





I HAVE copied this Plate from one given in a French geographical work, in which it is said to represent Leprosy and Elephantiasis as occurring amongst the natives of the Ladrões (Pacific). It is of interest as showing, first, that molluscum fibrosum in its aggravated forms has been observed; and, secondly, as illustrating the untrustworthy character of the assertions of unskilled travellers as to the diagnosis of leprosy. In no one of the three portraits is there any indication of the latter disease. Two of them are obviously molluscum fibrosum only. In the third, so far as diagnosis may be ventured from the portrait, the disease might be thought to be yaws or syphilitic lupus. The foot is in exactly the condition represented in a portrait of yaws which is exhibited in the Clinical Museum. The patient, however, is obviously not a negro, a fact which opposes this diagnosis.

Not any one of the three shows either "Leprosy" or "Elephantiasis." The Plate becomes of value as enabling the reader to correct the errors of the printed statement. In reference to Leprosy these mistakes in recognition are of great importance. They have been, and perhaps still are, of frequent occurrence, and have probably often misled the student of medical geography. Countries are credited with Leprosy where, in fact, the disease is unknown.

HUTCHINSON'S CLINICAL ILLUSTRATIONS.  
(SMALLER ATLAS.)





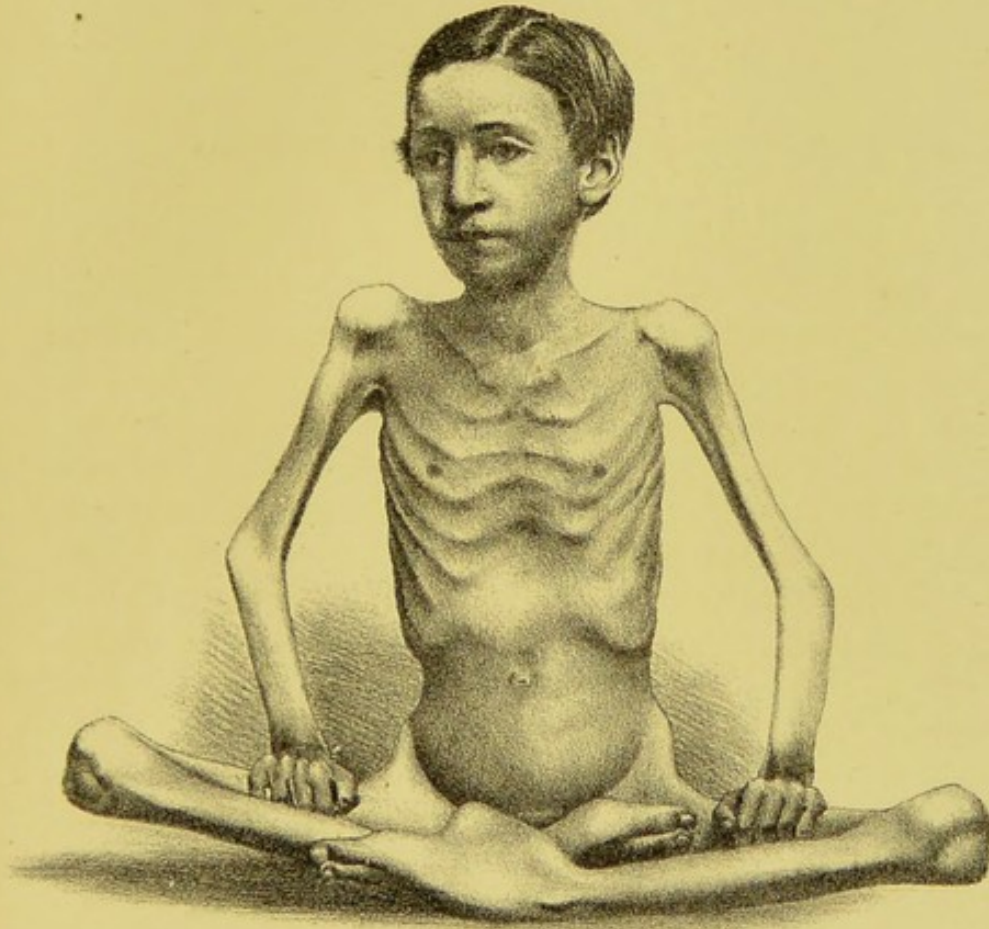


## PLATE CXXVI.


AN EXAMPLE OF EXTREME EMACIATION.




THIS portrait represents the condition of a boy whom I saw in the London Hospital, thirty years ago, under the care of the late Mr. Luke. He was taken in with the object of fattening him, but the result was an entire failure; and, although he took food well and was liberally supplied, he left the hospital in the same condition as he entered it. Massage was at that time not known. No organic disease could be detected. It will be observed that his head and face show none of the leanness which was such a remarkable feature in his limbs and trunk. His coracoid processes were easily visible. The Plate is copied from a photograph.









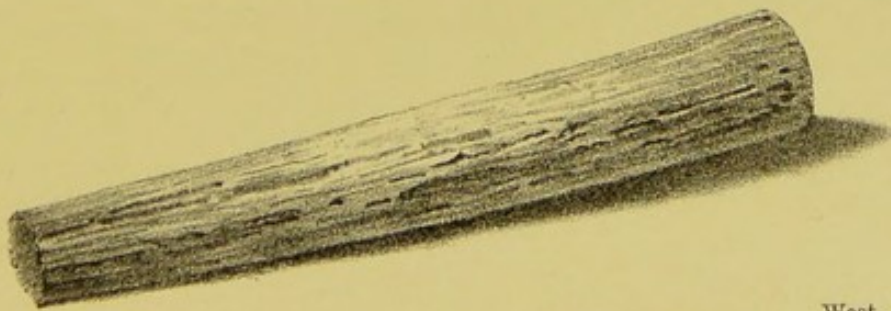
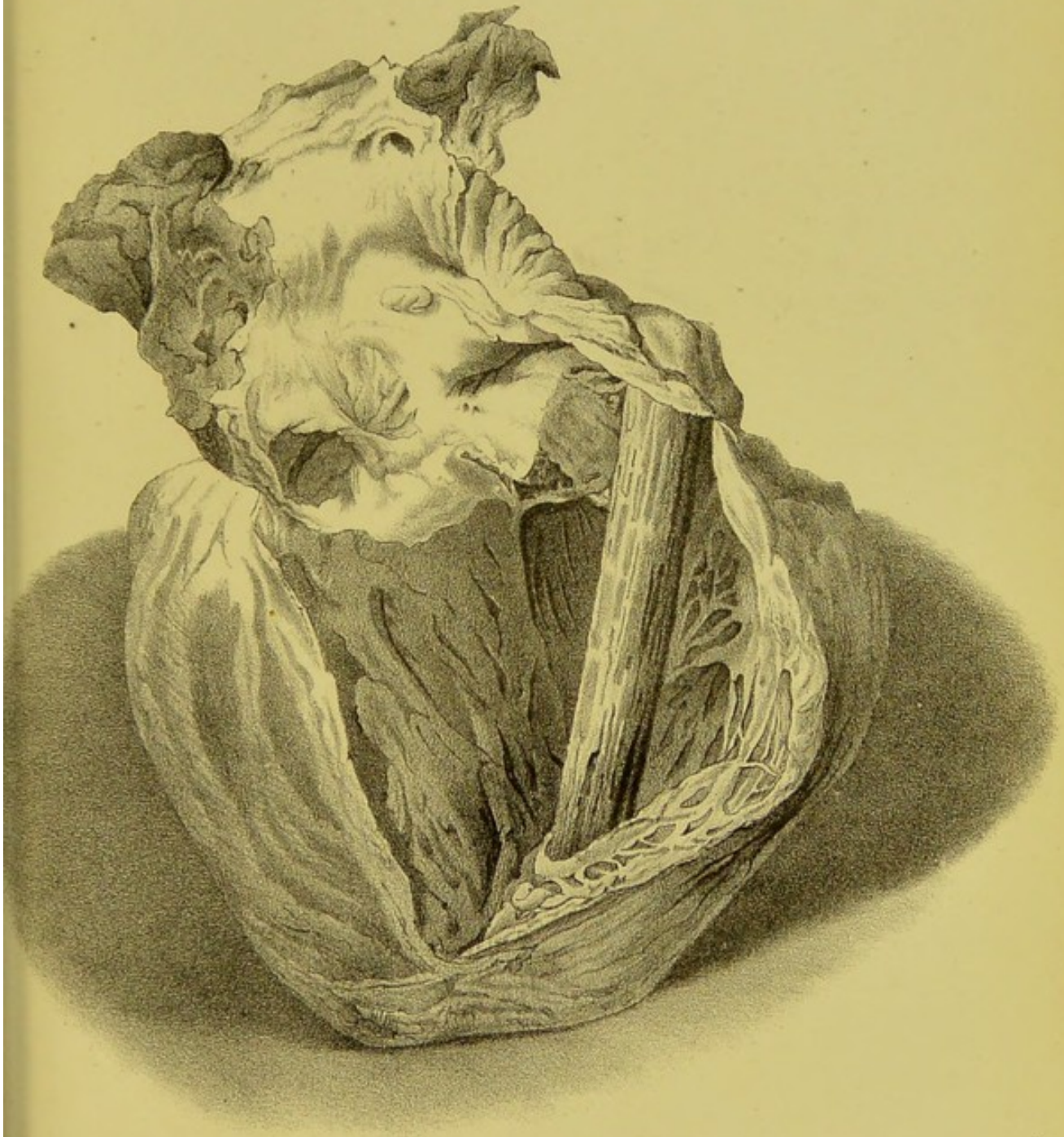
## PLATE CXXVII.

### FOREIGN BODY LODGED IN THE HEART.


I HAVE thought it worth while to copy this Plate from one given in an old volume of the Transactions of the British Medical Association, as it affords a most remarkable illustration of what is possible in connection with the lodgement of foreign bodies in the heart. The body was a piece of wood which had served to plug a toy cannon, and which, having been driven out backwards, had entered the boy's chest. For some days it was not recognised that he had been seriously hurt, but after death, a piece of wood as thick as a cedar-pencil and three inches in length was found lodged in the right ventricle. Its exact position is shown in the sketch. A very curious fact was that no aperture of entrance was discovered. This led to the suggestion that possibly it might not have gained its present position until just before the boy's death, and that it might originally have been lodged in the vena cava. No indications of injury to this vessel had, however, been observed.

The case has some medico-legal value as indicating the necessity for caution in forming a definite opinion as to the date of any given injury.

The following are some additional particulars of the case. The boy had lived five weeks and two days after the accident. Immediately after the accident he walked a distance of forty yards to his home. During the next ten days he was cheerful, and said that he was well; and on one occasion walked a distance of eighty yards and attended to his garden. After the first fortnight he emaciated and had frequent rigors which were followed by faintness. He had no pain throughout his illness. At the autopsy a small cicatrix was visible between the cartilages of the third and fourth ribs, but no scar whatever was to be found in the pericardium or heart. The piece of wood was found as shown in the Plate, but it was thickly incrustated with fibrin. The recorder of the case was Mr. Thomas Davis, of Upton-on-Severn (1833). At the time of the accident there was free venous bleeding from the external wound.







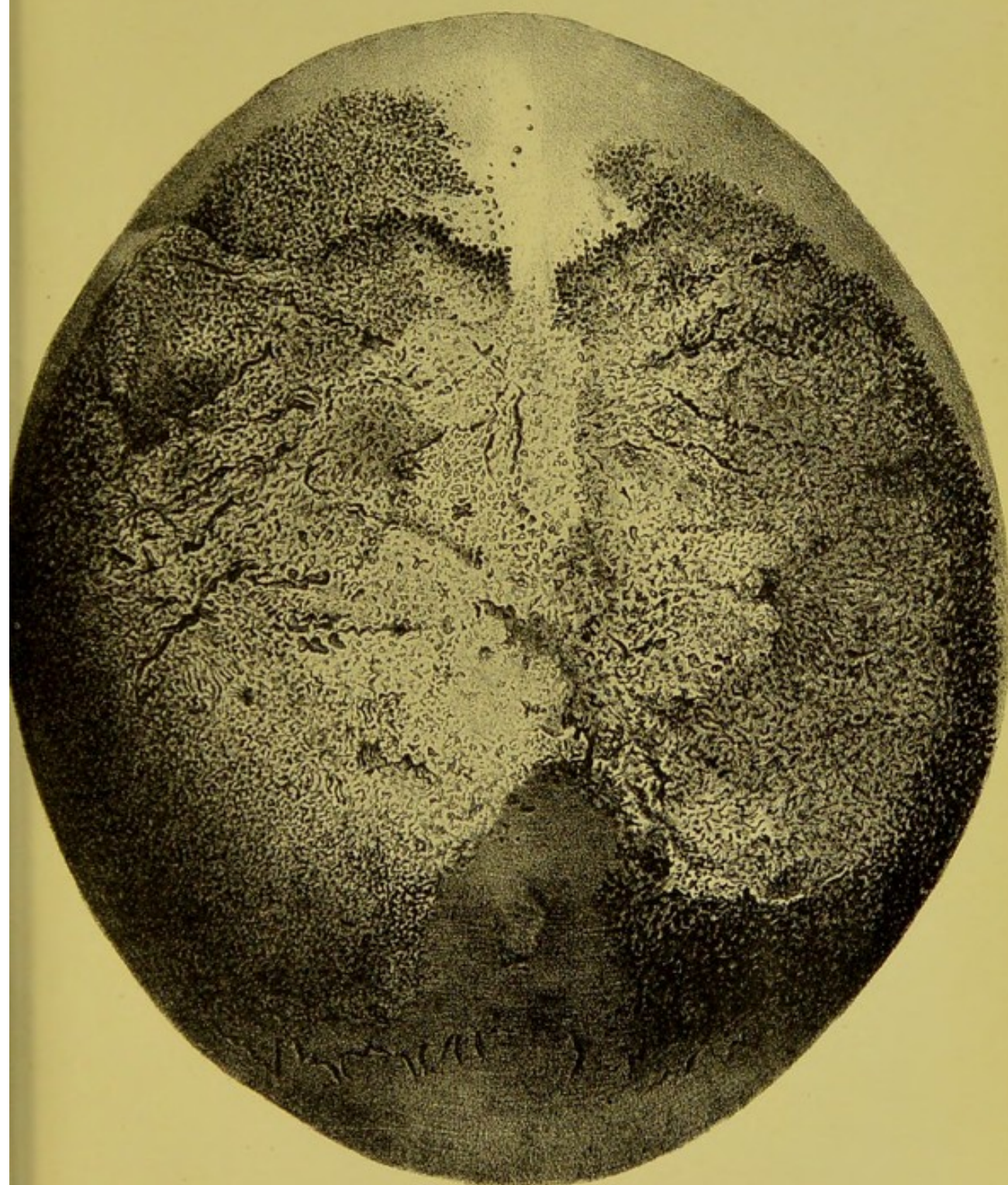
## PLATE CXXVIII.

A CALVARIA AFFECTED WITH DIFFUSE PERIOSTITIS  
SECONDARY TO FAVUS.





THE skull-cap from which this Plate is taken is in the Dupuytren Museum at Paris. The patient had suffered for many years from favus, no doubt with much destruction of the scalp. As a consequence, the whole of the top of the skull had been roughened over by the deposit of new bone. It will be seen that the deposit is not arranged in the position of Parrot's bosses, so that there is no reason to suspect that it was due to inherited syphilis.

Several portraits showing extensive destruction of the scalp by Favus are in the Museum. I am not aware of any other specimen in which the skull-cap is shown to have been affected.









## PLATE CXXIX.

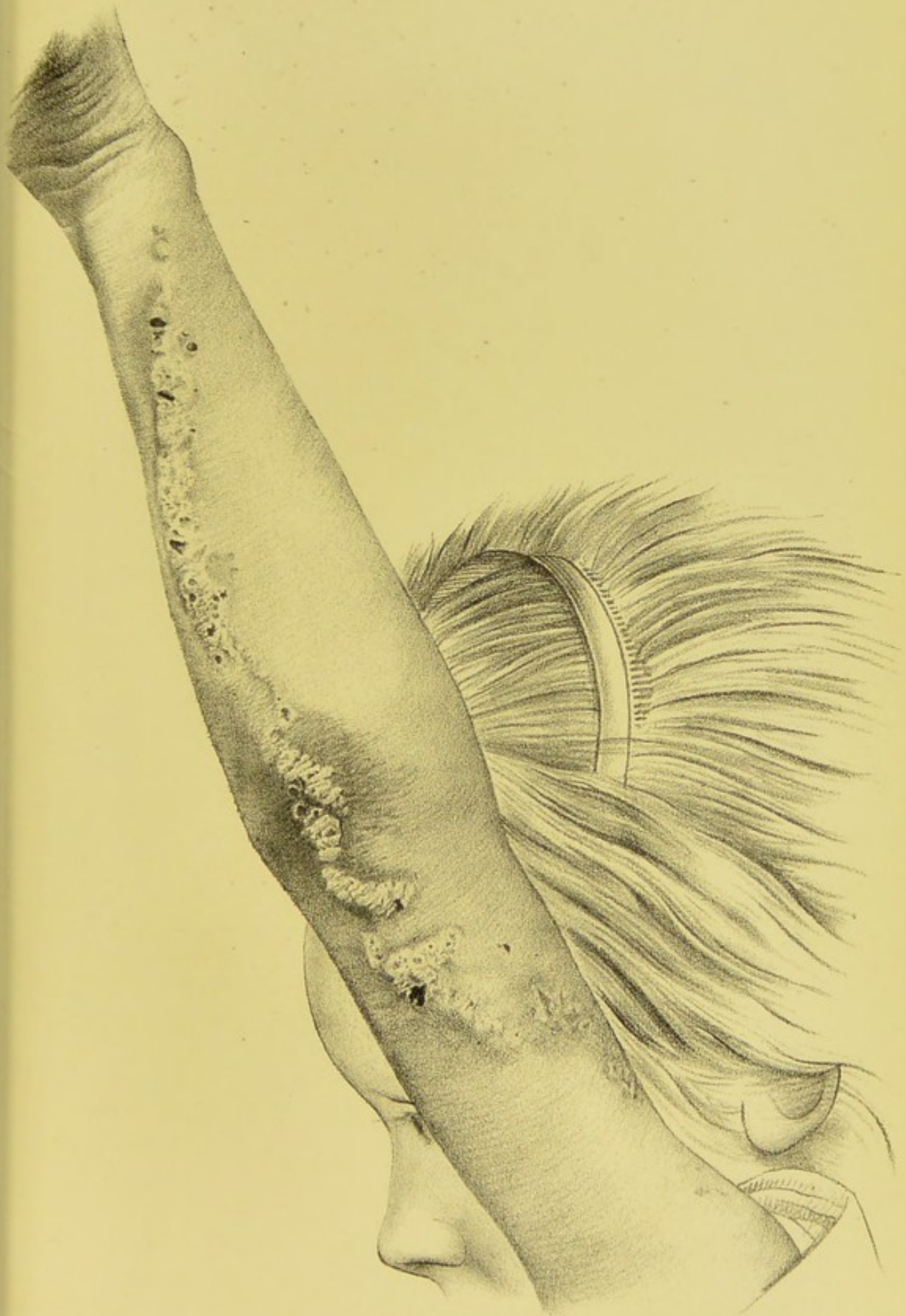### A PECULIAR FORM OF LUPUS ARRANGED IN A STREAK.


—◆—


THIS portrait is copied from a photograph preserved in the Museum of the St. Louis Hospital at Paris. It shows the arm of a young girl with a long narrow streak extending from the middle of the upper arm to near the styloid process of the ulna. The patch consists of indurated, almost warty papules, which have coalesced, forming a band. In some parts the papules are covered with dry crust, and at others small scars are seen.

I was much interested in this portrait because I possess two others which show exactly the same condition of things. In one of these the patient was a young lady, and in the other a boy. In a fourth instance, a patient brought to one of my clinical demonstrations showed a band passing down the fore arm in the same position, and of much the same character. In two of my patients there was present also a peculiar form of lupus of the face. Of one of these the condition is represented in Plate XIII. In this there was no doubt as to the disease leaving a scar, and I ventured to name it *Lupus Marginatus*. It seems clear from the close similarity of these four cases that there is some law of development, or anatomical peculiarity, which locates the band of disease in this position. It is difficult, however, to see how it is to be explained. A similar arrangement is occasionally observed in *Ichthyosis Herpetiformis* and in *Lichen Planus*. I feel justified in claiming this malady as a form of lupus on account of its persistence, aggressive characters, and tendency to leave scars.

Devergie has referred (see page 299) to this peculiar arrangement under the name of "*Lichen perpendiculaire ou en ruban*," and records an example.







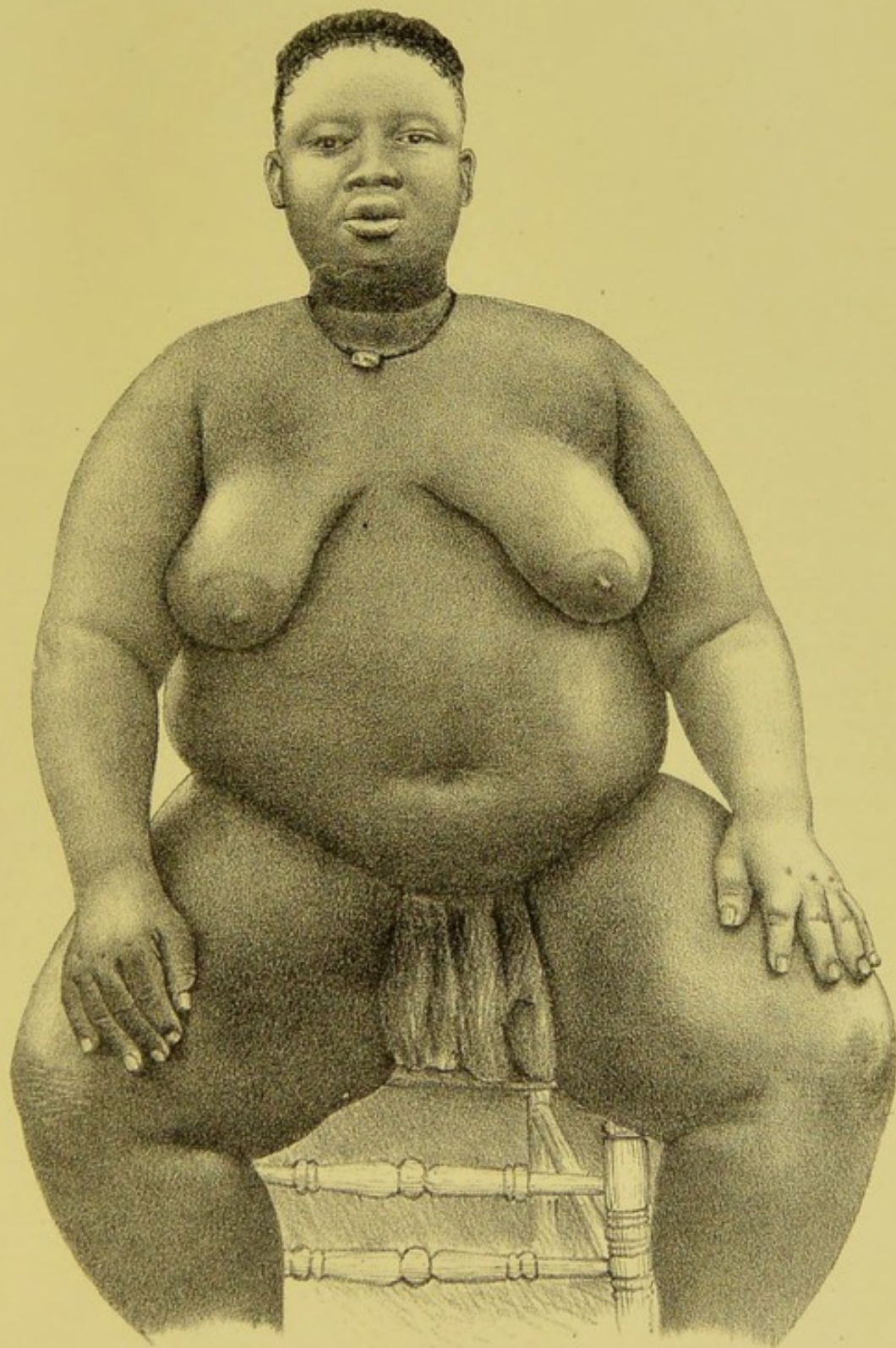## PLATE CXXX.

GYNÆCOMAZIA WITH FEMININE OBESITY—LOBENGULISM.





THIS portrait is copied from a photograph which was given me by Dr. Eustace Callender. It represents the condition of a man of one of the South African tribes. He was the husband of three wives, none of whom had, however, borne him children. He had, as will be seen, large pendulous breasts, with well-developed nipples and areolæ. He was also uniformly fat; his limbs, neck, shoulders, &c., presenting the rounded outlines which are usual in women. Obesity is, I am informed, not at all uncommon in the South African races. When associated with gynæcomazia, I believe that it is generally indicative of a low condition of the virile functions; but in the case of the man here represented there was no evidence in that direction.

See 'Archives of Surgery,' vol. vi., page 155.









## PLATE CXXXI.

### THE CRATERIFORM ULCER (EPITHELIAL CANCER).

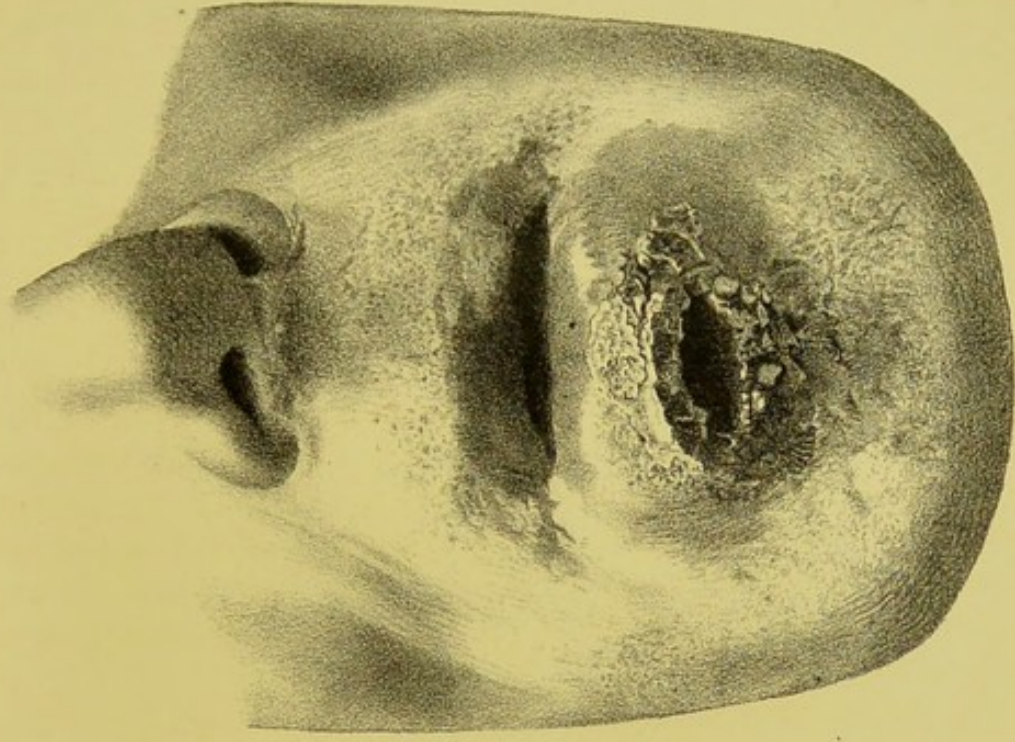
—◆—

THESE two portraits are from models in the Museum of the Hôpital St. Louis in Paris. They are described in the catalogue as examples of epithelial cancer, and in each instance the patient was senile. My special interest in them is that they appear to represent that particular form of epithelial cancer which I have ventured as a matter of clinical convenience to name the Crateriform Ulcer.

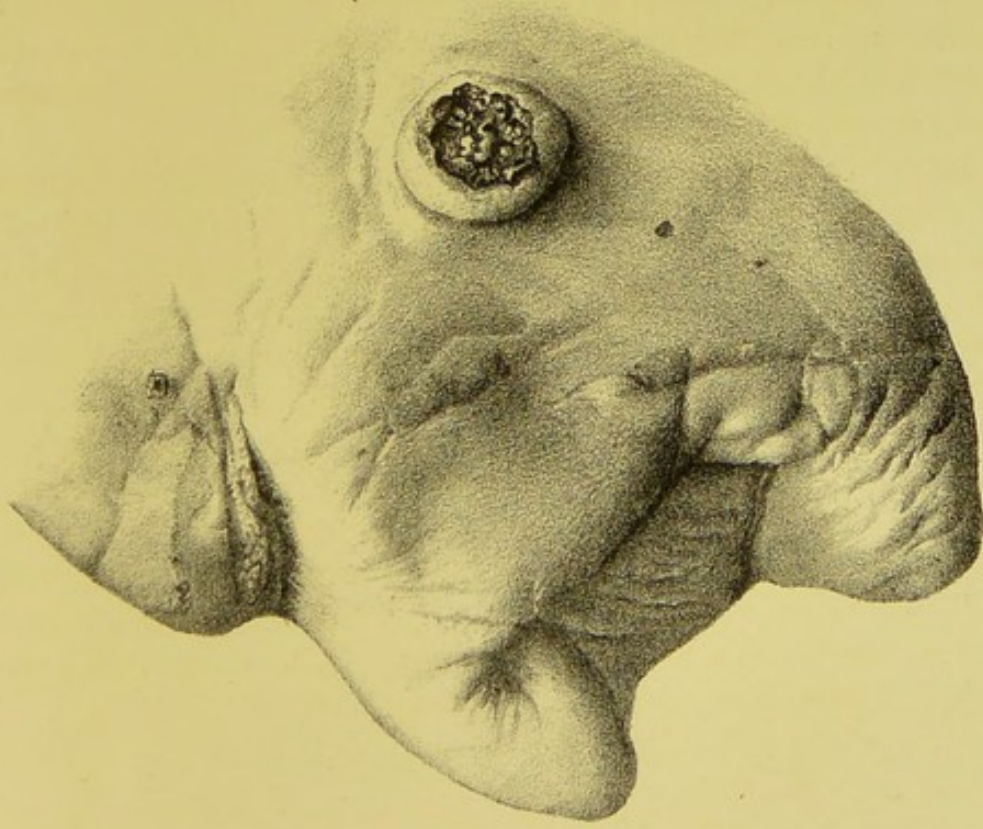
In the left-hand portrait, in which the disease is placed on the middle of the cheek, the tuberos and crateriform character is well seen. The features of this growth are precisely those shown in one or two portraits in the Clinical Museum, which I regard as most typical of the crateriform ulcer.


The right-hand portrait, showing the ulcer on the chin, is much less marked in its features, but it yet represents a central excavation with bossy edges very different from the more ordinary forms of epithelial cancer of the skin of the face.


I was much interested when last in Paris in searching through the magnificent collection at St. Louis to see whether any representations of this kind of ulcer had been preserved. These two were the only ones which I could find. I wish it to be especially observed that my diagnosis does not in the least differ from that of the distinguished editor of the catalogue of the museum. I have only given a more specialised name to a variety of epithelial cancer. I do not know the history of the case in either instance. The model of the ulcer on the chin is No. 551 in the museum, and bears the label—"Epithéliome caverneux de la lèvre inférieure. Prof. Fournier. 1878." The model of the other ulcer (that on the cheek) is No. 1231 in the same museum, and bears the label—"Epithéliome, Face. Prof. Besnier. 1887."



HUTCHINSON'S CLINICAL ILLUSTRATIONS.  
(SMALLER ATLAS.)







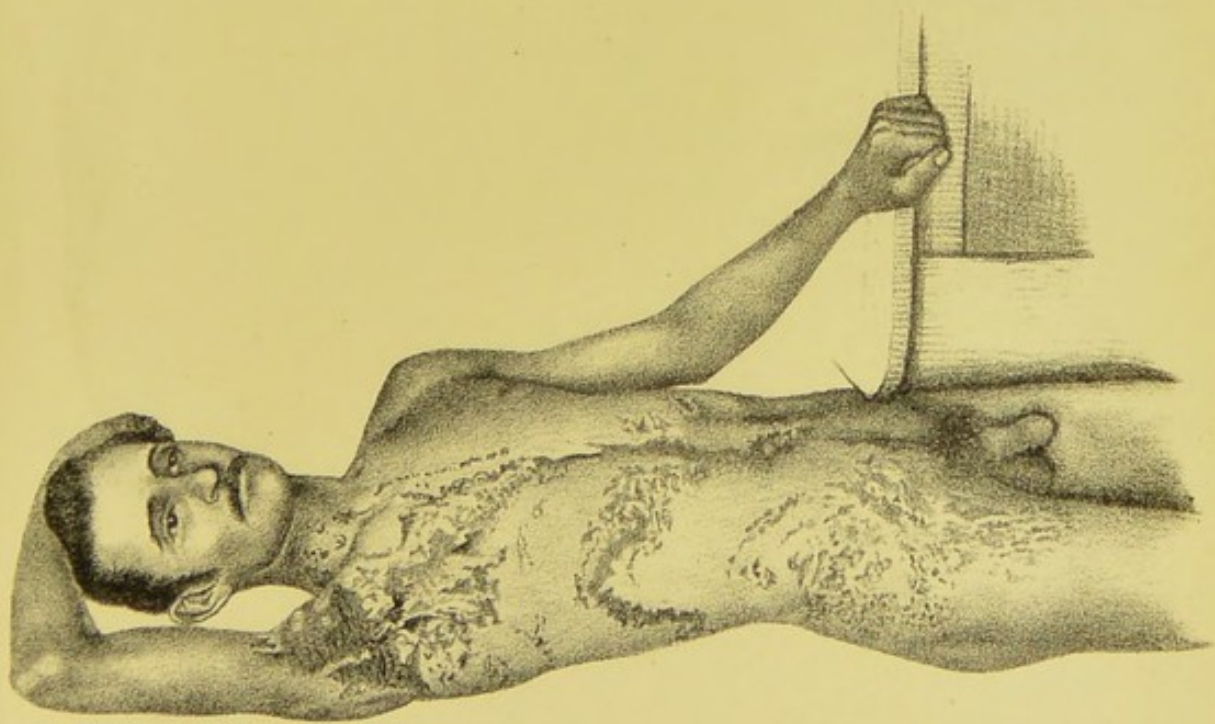
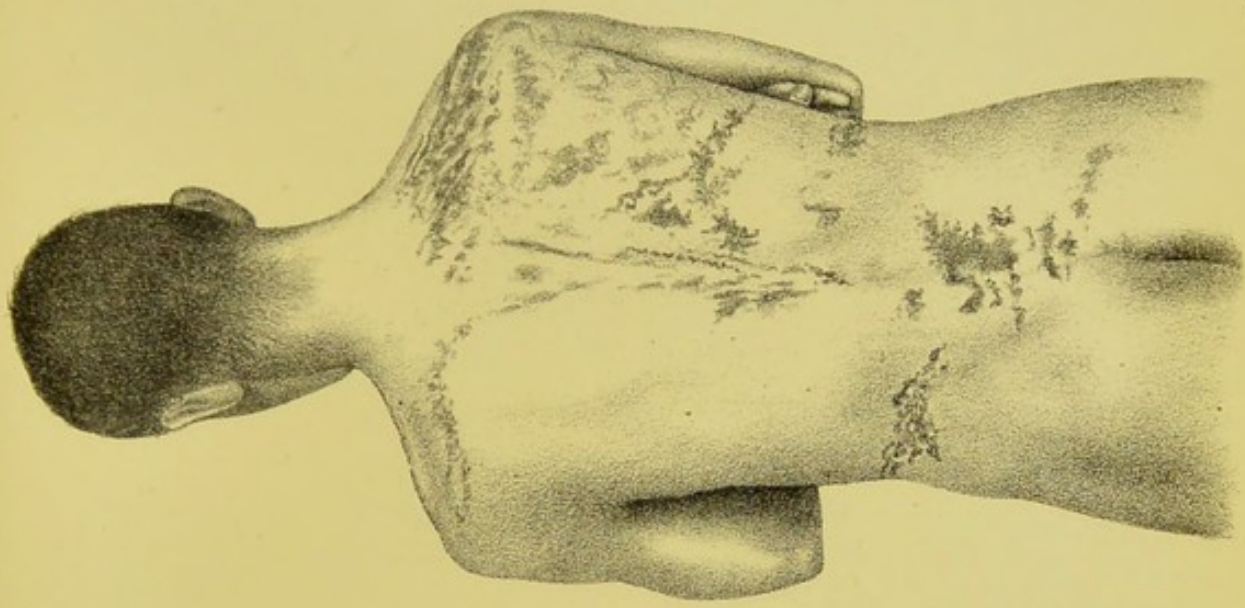
## PLATE CXXXII.

### ICHTHYOSIS HERPETIFORMIS.




THESE Plates, from photographs, represent the arrangement in streaks or bands of a papillary form of ichthyosis. Their chief interest lies in the definite illustration given of deviation from bilateral symmetry. Although the left side is not exempt, almost all the patches occur on the right. They are arranged as usual in somewhat irregular bands, some of which curve downwards like herpes, whilst others run almost vertically. This is the usual arrangement. It will be seen that the axilla again, as usual, has suffered severely. The patches consisted of hard dry papillæ, blackened by dirt, from which it was impossible to free them.

This form of ichthyosis may be very successfully treated by carefully snipping away the papillæ by means of scissors curved on the flat. There is no tendency to recurrence of the growth.








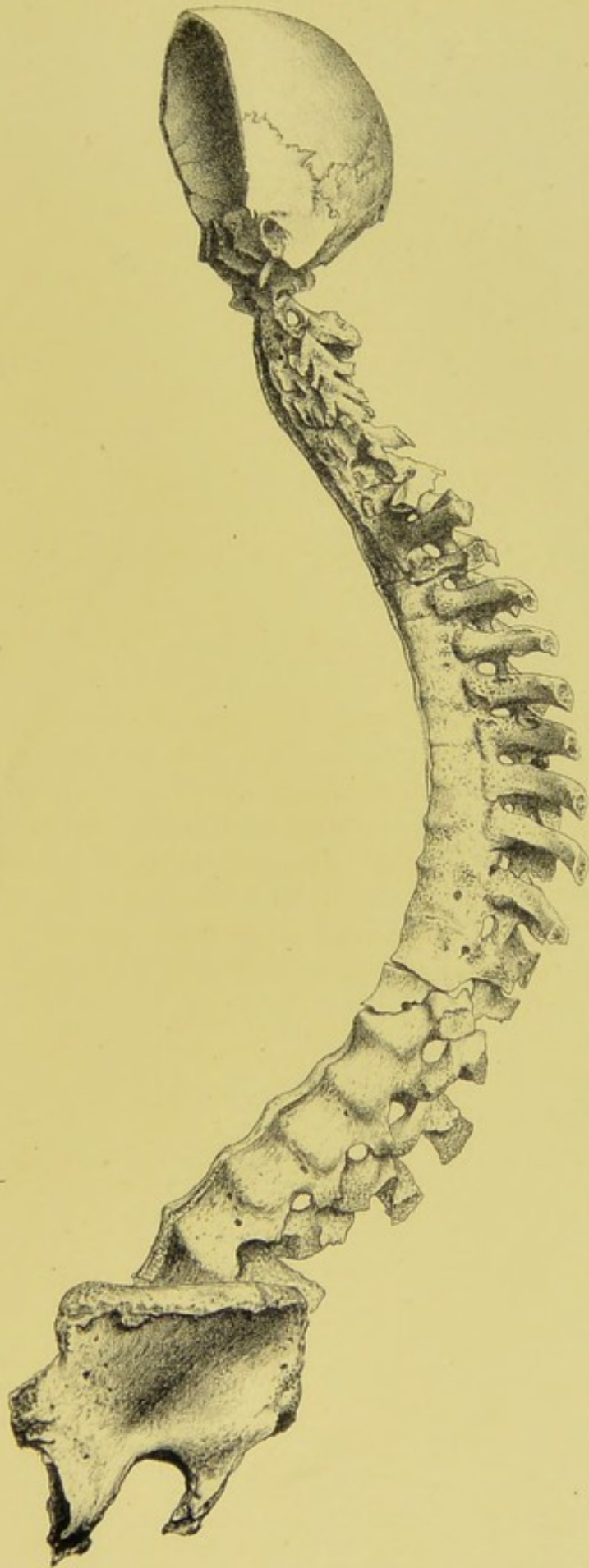


PLATE CXXXIII.


SPONDYLITIS DEFORMANS.



THIS Plate is copied from a photograph of a specimen which is in the Dupuytren Museum in Paris. It was one prepared by Dupuytren himself. The conditions shown are complete ankylosis between the bodies of all the vertebræ, and of all the smaller joints, including those of the ribs. There is the usual posterior curve, which is strongly marked. The label attached to the specimen is as follows:—"Ankylose périphérique avec cyphose générale de toutes les vertèbres de la colonne vertébrale de nommé Séraphin. 652A. Dupuytren."







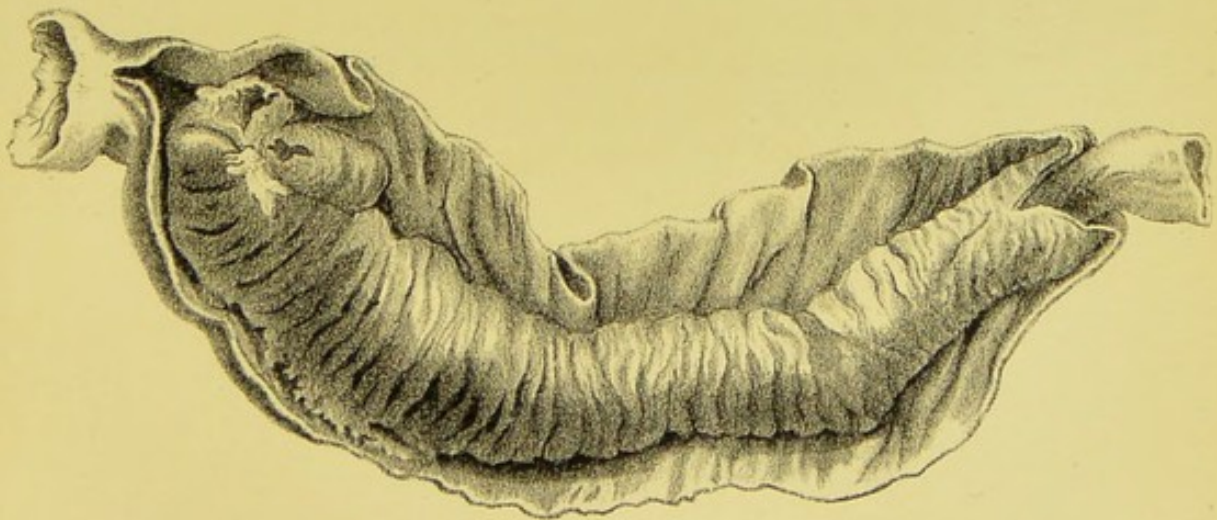
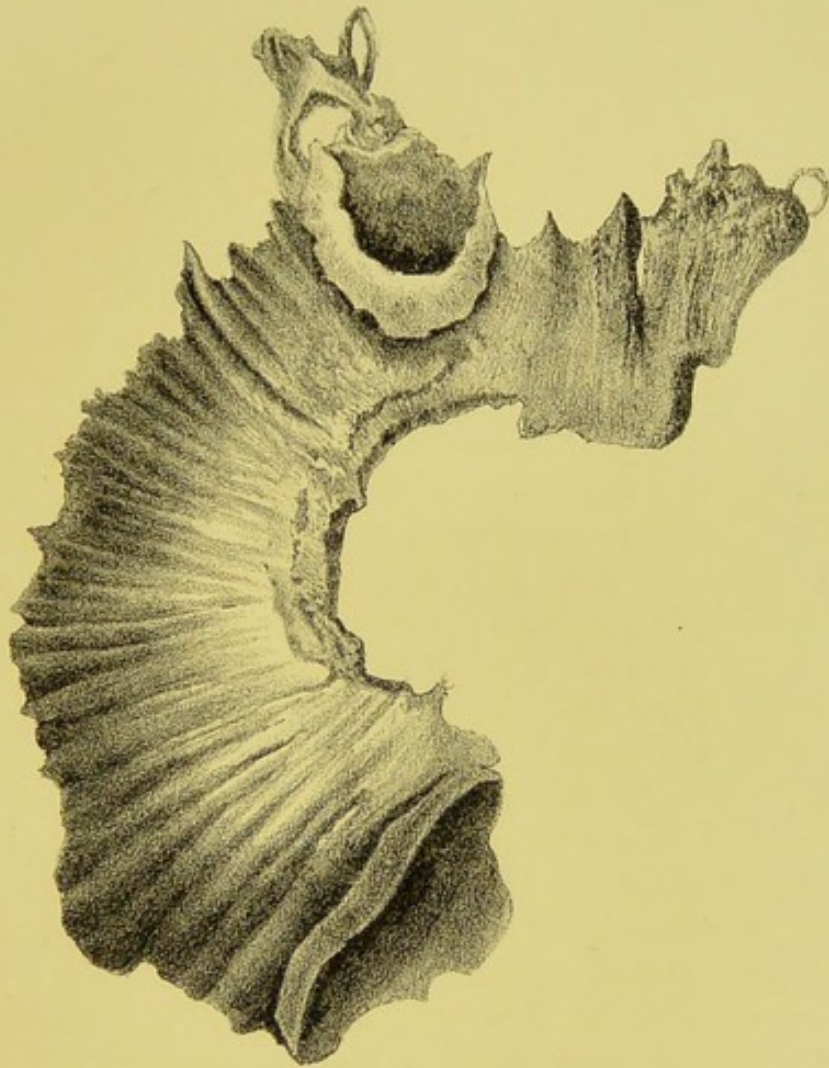
## PLATE CXXXIV.

### INTUSSUSCEPTION.





THE uppermost of these two figures shows a portion of intestine which had sloughed off in a case of intussusception, the patient afterwards making a good recovery. It is copied from an illustration given by Mr. John Fox, of Cerne Abbas, in an old volume of the 'Transactions of the British Medical Association.' The patient was a lad of sixteen. His illness had lasted fourteen days when the portion of gut was passed. The symptoms had differed a little from what was usual in that there had never been any bloody mucus observed in the stools. Flatus had been passed on the sixth day, and had been followed by copious motions. The treatment had been by purgatives and bleeding. The bowel, as shown in the drawing, is turned inside out. Most of our pathological museums contain specimens of this kind.

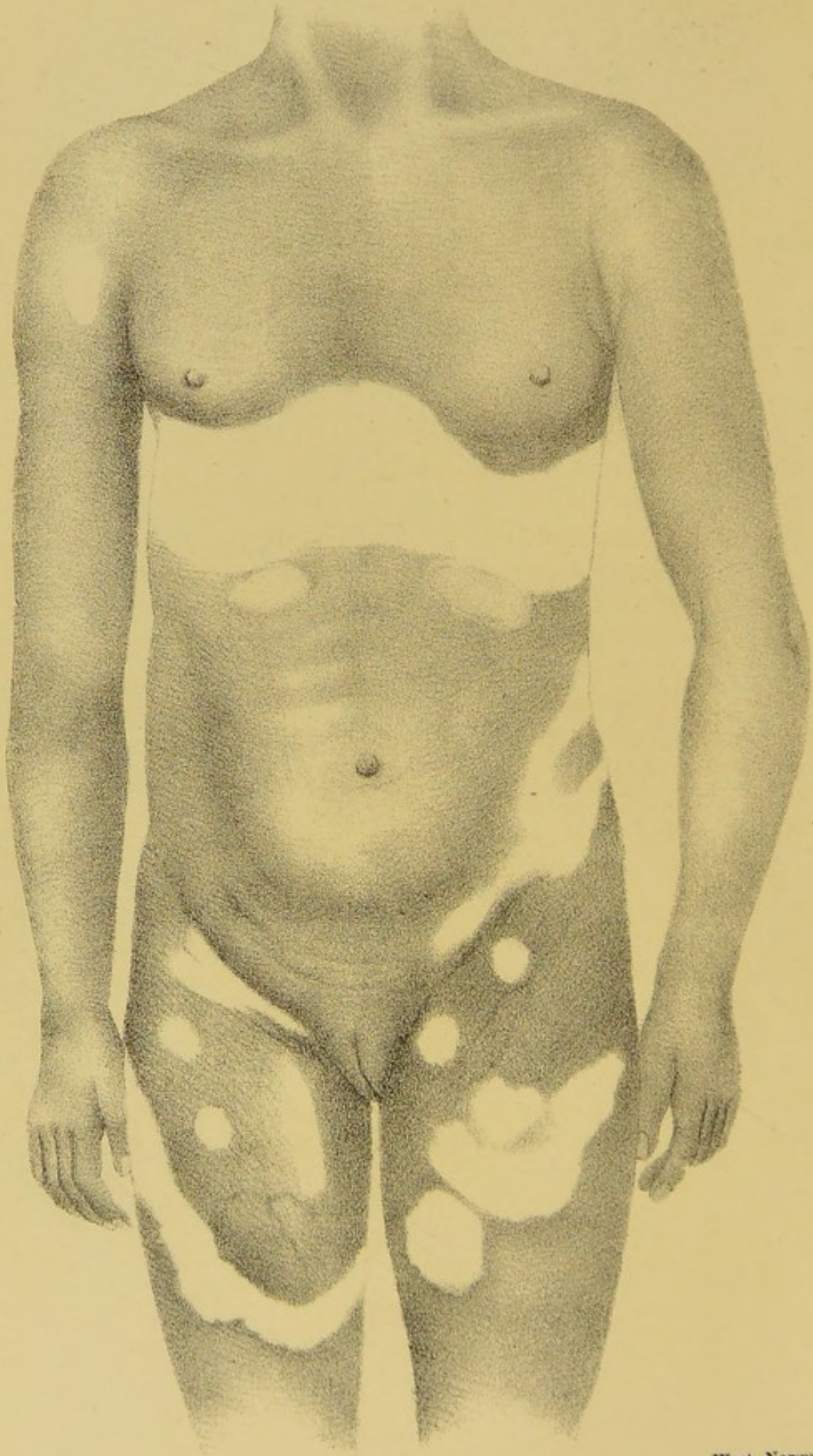
The lower drawing is from one made by Mr. Clift for Sir Thomas Blizard, and published by him in the first volume of the 'Medico-Chirurgical Transactions.' It is of some historical interest as being probably the first delineation of an intussusception in which the gut had passed within reach of the anus. The patient was a child of five months, and death took place on the fifth day of symptoms. Six inches of the ileum with the whole of the cæcum and ascending colon had passed into the descending colon and rectum. The drawing may be compared with that given in Plate XLIX., which shows an almost exactly similar state of things.












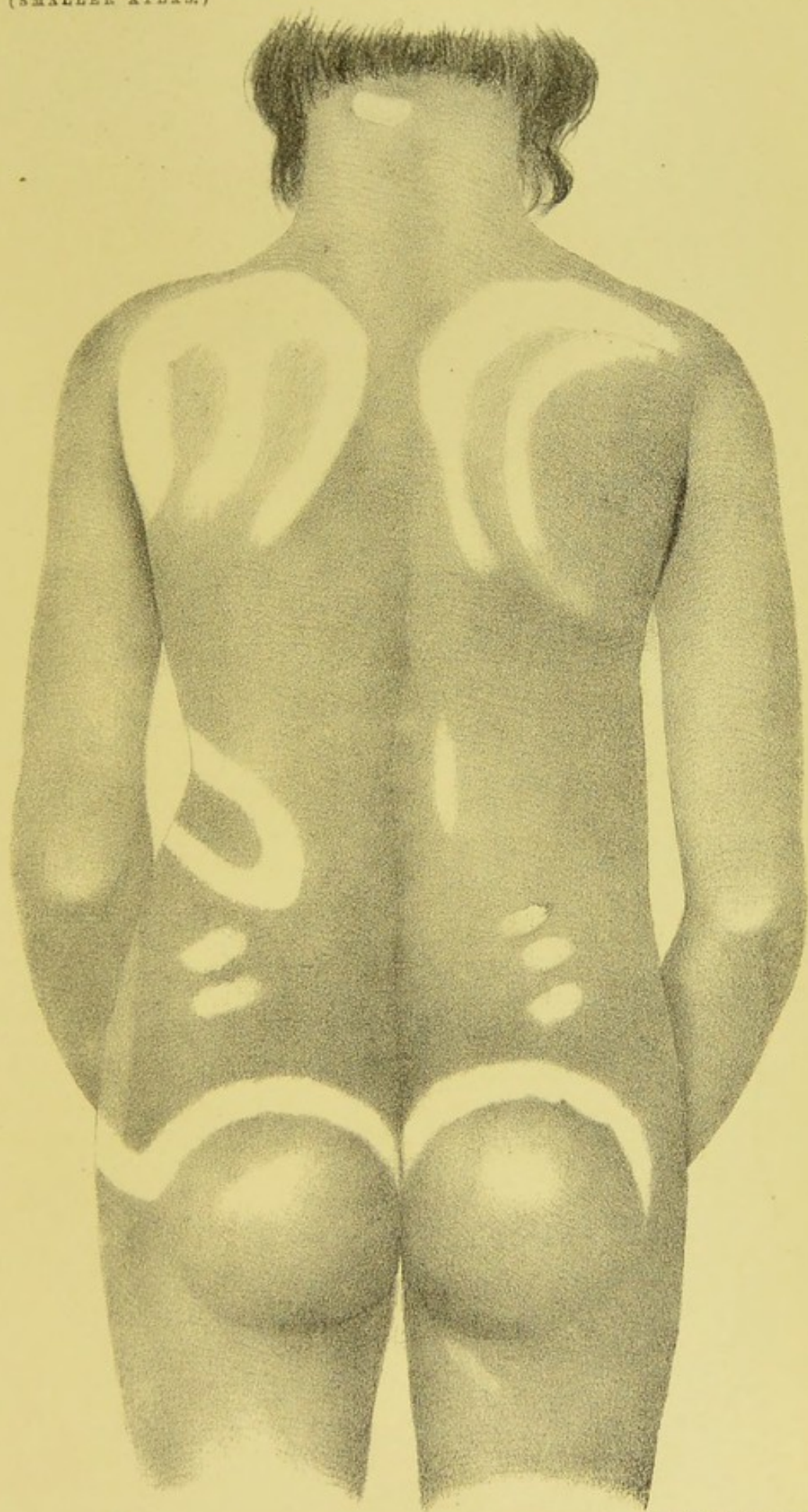
## PLATES CXXXV. & CXXXVI.

### MORPHŒA HERPETIFORMIS.



THESE Plates, which must not be regarded as more than mere maps indicating local arrangement, show the position taken by patches of ivory morphœa in a young girl. The disease had been present for more than a year. She was otherwise in excellent health. It will be seen that the patches were arranged somewhat in zones, and, although in the main symmetrical, that there were some definite deviations from bilateral sameness. Thus there is a patch on the left side of the back of the neck which has no representative on the right, and one on the front of the right upper arm which has none on the opposite limb. The patches which curl round the scapulæ are fairly symmetrical, and are continued on the front of the chest by a broad band under the mammæ, which is quite so. The symmetry is almost exact on the buttocks and fronts of the thighs. A large patch curls round above the crest of the left iliac bone, which has no definite representative on the other side. The limbs in this case were exempt, with the exception already noticed. No one looking at these Plates can doubt that the patches were in some way arranged through the influence of the nervous system, but at the same time it is difficult to assign all the separate patches to the exact distribution of any known nerves. I have described in other places several cases resembling this under the name of herpetiform morphœa arranged in zones.







# INDEX.

	PLATE
Acne, summer. . . . .	LV
Acne-lupus . . . . .	CVII
Acro-asphyxia . . . . .	XXXII
„ dermatitis, family form . . . . .	LII
„ „ with disease of nails . . . . .	L
„ sclerodermia . . . . .	XVII
Adams, Mr. James, operations by . . . . .	XXXVII
Adenoid tumours in breast . . . . .	XXIV
Adenoma of breast . . . . .	XLII
Ancell, Mr. Henry, case . . . . .	XC, CXIX, CXX
Angeioma, infective. . . . .	IX
Angeiomata and Enchondromata, congenital . . . . .	XLIII
Anus, intussusception protruding at . . . . .	XLIX
Arsenic-cancer . . . . .	XX
Arsenic-keratosis . . . . .	XVIII, XIX, XX
Arsenic-psoriasis and keratosis . . . . .	XVIII, XIX
Baker, Mr. Marrant, case . . . . .	LVI
Barrett, Dr. J. W., of Melbcurne, case . . . . .	CXIX
Bayha, Dr., cases . . . . .	LXII
Bazin's malady . . . . .	CIII, CIX
Besnier, Prof., copy of case . . . . .	CXXXI
Braine, Mr. Thomas, case . . . . .	XCIV
Bryant, Mr. Thomas, cases . . . . .	XVI, LVII, XC
Bury, Dr. Judson, case . . . . .	LXI
Cæcum, intussusception of . . . . .	XLVIII
Callendar, Dr. Eustace, case . . . . .	CXXX
Cancer of breast . . . . .	XXV
„ of umbilicus. . . . .	LIV
„ rodent, in a young man . . . . .	CXI
„ superficial rodent. . . . .	XXXIV
Carter, Mr. E. H., case . . . . .	XLV
Cauda equina, tumours of . . . . .	XCIII
Chancre of lip . . . . .	XLI
Chancres, recurred inflammation in sites of . . . . .	XLI
Chilblain-lupus of hands . . . . .	LI
Chloral, eruption due to . . . . .	V
Clark, Mr. Le Gros, case. . . . .	LVII
Clay, Dr. Hogarth, case . . . . .	XII
Cock, Mr., on sebaceous follicles on scalp . . . . .	XXIX
Cohn, Dr. J. S., of Portland, U.S.A., case copied . . . . .	CXX
Colon, ulceration of. . . . .	XLVIII
Congenital streaks, unilateral . . . . .	I, II




	PLATE
Craniopagus . . . . .	CXV, CXVI
Crateriform ulcer . . . . .	XI, CXXXI
Cripps, Mr. Harrison, case . . . . .	XI
Crocker, Dr. Radcliffe, cases . . . . .	LXIX, CXXI
Cruveilhier's 'Atlas,' copies from . . . . .	CXXII, CXXII
Davis, Mr., of Upton-on-Severn, case . . . . .	CXXVII
Dermatitis, desquamative . . . . .	XXII
"    herpetiformis . . . . .	XCIX, C
Desquamative dermatitis cured by opium . . . . .	XXII
Devergie's case of 'Lichen en ruban' . . . . .	CXXIX
Diffuse lipomata of neck . . . . .	LVI
"    "    of pubes and perineum . . . . .	LVIII
Duhring, Dr., on dermatitis herpetiformis . . . . .	XCIX
Duhring's neoplasm . . . . .	CII
Duplication of skull . . . . .	CXV, CXVI
Dupuytren Museum, copies from . . . . .	CXXVIII, CXXXIII, CXIII, CXIV,
Dwarf, short-limbed polydactylous . . . . .	XCII [CXVII
Eczema-lupus . . . . .	LXXX
Edwards, Mr., of Keston, case . . . . .	CXXIV
Emaciation, extreme . . . . .	CXXVI
Enchondroma of parotid . . . . .	CXXIV
Epithelial cancer . . . . .	XI, CVI, CXXXI
Eruptions due to summer and sun . . . . .	LV, CVIII, CX
Erythema-urticaria from vest-irritation . . . . .	XXIII
Eve, Mr. F., case . . . . .	XLIII
Fagge, the late Dr. Hilton, case by . . . . .	III, IV
Favus, destruction of scalp by . . . . .	CXXVII
Femur, myeloid and cystic tumour of . . . . .	XXVII
Fisher, Dr., copy of portrait by . . . . .	XCIII
Foreign body lodged in the heart . . . . .	CXXVII
Fournier, Prof., copy of portrait . . . . .	CXXXI
Fox, Dr. Colcott, case . . . . .	CIX
"    Dr. Tilbury, case . . . . .	XVI, LXXVIII
"    Mr. John, of Cerne Abbas, case . . . . .	CXXXIV
Fungating growth on scalp . . . . .	XXIX
Gairdner, Prof., cases . . . . .	XXVIII, XLIX
Gall-stones, illustrations . . . . .	LVII, LXXXVIII
Gangrene, symmetrical, of extremities . . . . .	XXXI
Gull, Sir William, case . . . . .	CXII
Gynæcomazia with feminine obesity . . . . .	CXXX
"    without obesity. . . . .	CXVIII
Hamilton group . . . . .	XXXVII
Hawkins, Mr. Cæsar, case . . . . .	XXXIV
Hebra's 'Atlas,' copies from . . . . .	LXXIII, LXXXIII
Herpetiform pemphigus . . . . .	XCIX, C
Hilliard's case, lupus marginatus . . . . .	XIII, XIV
Humphry, Sir George, on depressions in skull . . . . .	CXIII, CXIV
Hydrocephalus . . . . .	XL
Ichthyosis herpetiformis . . . . .	I, II, XLV, XLVI, CXXXII
"    "    (non-symmetrical) . . . . .	XLV
Ichthyotic horns . . . . .	CXXI, CXXII, CXXIII
Intussusception . . . . .	CXXXIV
"    of cæcum . . . . .	LXVIII
"    protruding at anus . . . . .	XLIX
Iodide of potassium eruption . . . . .	III, IV

## PLATE

Jessop, Mr., case . . . . .	LXXXIX
Kaposi's disease . . . . .	LXIX
Kerckring's 'Spicilegium Anatomicorum,' copy	XCII
Kundart, Prof., cases by . . . . .	XCIII
Langton, Mr., case by . . . . .	XCVIII
Lassar, Dr., case . . . . .	IX
Lentigo maligna familie . . . . .	LXIX
Lichen-lupus . . . . .	CVII
Lipomata, diffuse . . . . .	LVI, LVIII
Lobengulism (gynæcomazia) . . . . .	CXXX
Luke, Mr., case . . . . .	CXXXVI
Lupoid skin disease, mixed form . . . . .	VI, VII
Lupus, mixed form, with ulceration of hands .	X
" exceptional form . . . . .	LXXII
" of face, peculiar form . . . . .	CVII
" peculiar form, arranged in a streak . . . . .	CXXIX
" tubercular syphilitic . . . . .	XXXIII
" with œdematous hypertrophy of lip . . . . .	XII
" cancer . . . . .	XXI, LXII
" erythematous . . . . .	XLIV, LXXIV
"       " becoming general . . . . .	XXXVIII
"       " sebaceous form . . . . .	LXXIII
"       " on hands . . . . .	VIII
" lymphaticus . . . . . XV, XVI, LXXVIII, LXXXVI	
" marginatus . . . . .	XIII, XIV
" mutilans . . . . .	LXXI
" nævus, mixed form . . . . .	LXXXI
" vulgaris . . . . .	LXXIX, LXXXV
"       " multiple LXVII, LXVIII, LXXV, LXXXVI, LXXXVII	
"       " of gum and palate . . . . .	LXXXVII
"       " of hand . . . . .	LXXXIII
"       " of nose . . . . .	LXXXII
"       " of nose and lips . . . . .	LXX
"       " of most chronic form . . . . .	LXXXIV
Lymph-angioma, infective . . . . .	XV, XVI, LXXVIII
"       " of tongue . . . . .	LXXXVI
Mackenzie, Dr. Stephen, case . . . . .	XXXVIII
"       " paper . . . . .	I, II
"       " Mr. Fred., cases . . . . .	I, II, XLVIII
Melanosis in a mole with secondary gland disease.	CIV
Melanotic growths in skin . . . . .	XXVIII
"       " in thoracic organs of horse.	XC
"       " staining . . . . .	CVI
Meningocele, occipital . . . . .	XXXIX
Microcephalus . . . . .	XL
Molluscum fibrosum . . . . . [elephantiasis	LXIV, LXV
"       " mistaken for leprosy and	CXXV
Montjema's 'Atlas,' copy from . . . . .	XLIV
Morphœa, diffuse . . . . .	XVII, XXX, XXXI
"       " herpetiformis . . . . .	CXXXV, CXXXVI
"       " affecting fifth nerve . . . . .	LXXXIX
Morrow, Dr. Prince, on drug eruptions . . . . .	III, IV, V
Multiple lupus vulgaris . . . . . LXVII, LXVIII, LXXXVI, LXXXVII	
"       " ulcers on the legs . . . . .	CIII, CIX
Myeloid and cystic tumour of femur . . . . .	XXVII

Nævus of face cured by cauterisation . . . . .	XCVI, CI
„ lupus . . . . .	IX
Nettleship, Mr., case . . . . .	XCI
Œdema, solid, of eyelids . . . . .	LXVI
Osteo-arthritis in early life . . . . .	XCIV
Paget, Sir James, case under . . . . .	XXXVII
Parrot's bosses . . . . .	CXVII
Peculiar disease of skin of hands, &c. . . . .	LXI
Pemberton, Mr. Oliver, on melanotic growths.	XCv
Pemphigus in secondary syphilis . . . . .	XCvII
„ herpetiformis . . . . .	XCIX, C
Periostitis, diffuse, secondary to favus . . . . .	CXXVIII
Phagedænic ulceration in inherited syphilis . . . . .	LIX
Philip Holmes, case of . . . . .	VI, VII
Primary sarcoma of skin . . . . .	XXXVI, XXXVII
Prurigo æstivalis . . . . .	LV
Raynaud's phenomena . . . . .	XXXI, XXXII
Recurred inflammation in sites of chancres . . . . .	XLI
Richter's medical observations, copy from . . . . .	LXXXVIII
Rivington, Mr., case . . . . .	XXIX
Roddick, Dr., case . . . . .	XXXIX
Sangster, Dr., case . . . . .	XV
Sarcoma melanodes. . . . .	LXI
„ of skin, primary . . . . .	XXXVI, XXXVII
Scirrhus in adenoid tumour of breast . . . . .	XXIV
„ of breast, rapidly growing . . . . .	XXVI
„ recurred, in pectoral region . . . . .	XXXV
Sclerodermia, late stage . . . . .	XVII, XXX, XXXI
Senile freckles . . . . .	CVI
Short-limbed polydactylous dwarf . . . . .	XCII
Sibley, the late Mr., case by . . . . .	LXXI
Smith, Mr. Thomas, quoted . . . . .	XXXVI
Solid œdema of eyelids . . . . .	LXVI
Solly, Mr., case . . . . .	XXXIX
Sommerring-Behrend case . . . . .	LX, LXIII
Spondylitis deformans . . . . .	CXXXIII
Summer eruptions . . . . .	CVIII, CX
Sun-eruption . . . . .	CX
Symmetrical hollows on surface of skull . . . . .	CXIII, CXIV
Syphilis, inherited, phagedænic ulceration in . . . . .	LIX
„ secondary, tongue in . . . . .	CV
„ pemphigus in secondary . . . . .	XCvII
Syphilitic lupus, tubercular . . . . .	XXXIII
Tay, Mr. Waren, cases . . . . .	XII, XIII
Thelan group . . . . .	XXXVI
Thomas, Mr. H. L., case. . . . .	LVII
Thrombotic arteritis . . . . .	LIII
“Tiger Ichthyosis” (herpetiformis). . . . .	XLV
Tongue in secondary syphilis . . . . .	CV
Tubercular syphilitic lupus . . . . .	XXXIII
Tumour of upper eyelid . . . . .	XCI
Tumours of cauda equina . . . . .	XCIII
„ of scalp . . . . .	CXIX, CXX
„ „ assuming malignancy . . . . .	XC
Ulceration of colon from distention . . . . .	XLVIII

	PLATE
Ulcerating summer eruption of face . . . . .	CVIII
Ulcers of face from inoculation . . . . .	XCVIII
Umbilicus, cancer of . . . . .	LIV
Varicella gangrenosa . . . . .	XLVII
Veson, Mr. J., case by, copied. . . . .	XCV
Vest-eruption . . . . .	XXIII
Waldo, Dr., case . . . . .	CVII
Webster, Dr. Percy, of Melbourne, case . . . . .	CXIX
Williams, Dr., of Barrow, case . . . . .	CXII
Wilson's 'Atlas,' portrait alluded to . . . . .	XXIII
Xanthelasma diabeticorum, without glycosuria.	CXII
Xeroderma pigmentosum . . . . .	LXIX



*Published Quarterly, Price 2s. 6d.; Annual Subscription 10s.;  
Demy 8vo, about 112 pp. and four Plates in each Part.*

THE  
ARCHIVES OF SURGERY.

BY  
JONATHAN HUTCHINSON, LL.D., F.R.S.

---

*London: WEST, NEWMAN & CO., 54, Hatton Garden, E.C.*

In Two Volumes, Imperial 4to. Vol. I. £3 10s.;  
Vol. II. £4 10s.

MR. HUTCHINSON'S  
ILLUSTRATIONS OF  
CLINICAL SURGERY

CONSISTING OF

PLATES, PHOTOGRAPHS, WOODCUTS, DIAGRAMS, &c.

ILLUSTRATING SURGICAL DISEASES, SYMPTOMS AND ACCIDENTS,  
ALSO OPERATIVE AND OTHER METHODS OF TREATMENT.

WITH

DESCRIPTIVE LETTERPRESS.

---

*N.B.—The Contents of the two Volumes, together with the Alphabetical Index to the subjects treated, are given in the following pages.*

---

Contents of Volume I.

- PLATE I.—Frontal Encephalocele.  
PLATE II.—Ivory Exostosis of the Orbit.  
PLATE III.—Rodent Cancer or Jacob's Ulcer.  
PLATE IV.—Different varieties of Chancre.  
PLATE V.—Varieties of Soft Sore, Balanitis, &c. (3 figures, life-size).  
PLATE VI.—Melanosis (7 figures).  
PLATE VII.—Hydrocele of the Neck.  
PLATE VIII.—Fig. I., Erysipelatoid Swelling, with Ecchymosis; Fig. II., Livid Papillary Psoriasis.  
PLATE IX.—Osseous Nodes on the Arms in connexion with Inherited Syphilis.  
PLATE X.—Cheiro-Pompholyx.  
PLATE XI.—Mammillary Teeth.  
PLATE XII.—Chronic Ulcerative Rheumatic Arthritis.  
PLATE XIII.—Direct Traumatic Arachnitis.  
PLATE XIV.—Inflammation of Pia Mater at Base of Brain after Fissure Fracture of Petrous Bone.  
PLATE XV.—Extreme Passive Congestion, with Diffuse Ecchymosis of Pia Mater  
PLATE XVI.—Contusion and Ecchymosis of Under Surface of Brain.  
PLATE XVII.—Subarachnoid Meningitis on Surface of Hemisphere.  
PLATE XVIII.—Thrombosis of Longitudinal Sinus (with Pyæmia) after Osteitis.  
PLATE XIX.—Gangrenous Inflammation of the Skull Bones after Contusion.  
PLATE XX.—Inflammation of Dura Mater and Thrombus in Longitudinal Sinus  
PLATE XXI.—Suppurative Inflammation of Dura Mater and Superior Longitudinal Sinus after severe Contusion of Skull.  
PLATE XXII.—Vaccination Chancres and Secondary Eruption (2 figures).  
PLATE XXIII.—Vaccination Chancres, and Eruption on the Arm around them.  
PLATE XXIV.—Figs. I. & II., Vaccination Chancres.  
PLATE XXV.—Fig. I., Lupus in Scar of Vaccination; Fig. II., Vaccination Chancres; Fig. III., Unhealed Vaccination Sores of nine months' duration.  
PLATE XXVI.—Xanthelasma Palpebrarum (3 figures). Confluent Acne in Xanthelasma positions.  
PLATE XXVII.—Xanthelasma Palpebrarum. Cystic Xanthelasma.  
PLATE XXVIII.—Various Fractures of the Skull (3 figures).

*Mr. Hutchinson's Illustrations of Clinical Surgery.*

*(Contents of Vol. I. continued.)*

- PLATE XXIX.—Various Fractures of the Skull (4 figures).  
PLATE XXX.—Various Fractures of the Skull (3 figures).  
PLATE XXXI.—Illustrations of Compound Fracture and trephining.  
PLATE XXXII.—Different Forms of Fracture of the Skull.  
PLATE XXXIII.—Bullet Perforations of the Skull.  
PLATE XXXIV.—State of the Eye in Vaso-motor Paralysis.  
PLATE XXXV.—Compression of Brain by Abscess between Dura Mater and Skull.  
PLATE XXXVI.—Phlebitis and Pyæmia (3 figures).  
PLATE XXXVII.—Osteitis and Pyæmia.  
PLATE XXXVIII.—Bullet Perforations of Skull.  
PLATE XXXIX.—Bullet Perforations of Skull.

**Contents of Volume II.**

- PLATE XL.—Detachment of Lower Epiphysis of the Femur; with Woodcut of another Specimen, and two showing Normal Relations of Epiphysial Line.  
PLATE XLI.—Bony Union of an Intra-capsular Fracture of the Neck of the Femur.  
PLATE XLII.—Malformed Teeth in Hereditary Syphilis; with four Woodcuts of Syphilitic Teeth, and Notes on the Diagnosis of Inherited Syphilis.  
PLATE XLIII.—Peculiarities in the Development of the Teeth from various Causes.  
PLATE XLIV.—Congenital Fibro-cystic Tumour; with three Woodcuts of other Cases.  
PLATE XLV.—Occipital Meningocele.  
PLATE XLVI.—Meningocele over the Anterior Fontanelle.  
PLATE XLVII.—Occipital Encephalocele (five figures).  
PLATE XLVIII.—Congenital Coccygeal Tumour (External Aspect).  
PLATE XLIX.—Congenital Coccygeal Tumour (in Section); with four Woodcuts of other Cases; Report on the Microscopic Anatomy of one Case (illustrated), and Notes (with Woodcut) on a Case of Spina Bifida with Hydrocephalus.  
PLATE L.—Two Cases of Fracture of Skull and Contusion of the Brain.  
PLATE LI.—Exfoliation of the Skull after Injury.  
PLATE LII.—A peculiar Form of Inherited Gout (Last-joint Arthritis).  
PLATE LIII.—Cancer of the Tongue and Smokers' Glossitis (four figures).  
PLATE LIV.—Blood-clot between Dura Mater and Bone.  
PLATE LV.—Various Morbid Conditions of the Tongue.  
PLATE LVI.—Various Morbid Conditions of the Tongue.  
PLATE LVII.—Various Morbid Conditions of the Tongue.  
PLATE LVIII.—Myeloid Tumours, Epulis, &c.  
PLATE LIX.—The Fungating Form of Rodent Cancer.  
PLATE LX.—Various Examples of Fracture.  
PLATE LXI.—Fractures of the Lower Part of the Femur.  
PLATE LXII.—Various Results from Intra-capsular Fracture of the Neck of the Femur.  
PLATE LXIII.—Extra-Capsular Fractures of the Neck of the Femur.  
PLATE LXIV.—Lupus of Mucous Membranes.  
PLATE LXV.—Superficial Forms of Rodent Cancer.  
PLATE LXVI.—Chancres in Unusual Positions.  
PLATE LXVII.—Gout and Rheumatic Gout.  
PLATE LXVIII.—Sebaceous Gland Tumours in the Scrotum.  
PLATE LXIX.—Extensive Fungating Growth in the Scalp.  
PLATE LXX.—Mal-Union after Fracture of the Femur.  
PLATE LXXI.—Injuries near to the Wrist, &c., Fractures and Separations of Epiphyses.  
PLATE LXXII.—Elephantiasis of Prepuce.  
PLATE LXXIII.—Various Cases of Elephantiasis.

*Mr. Hutchinson's Illustrations of Clinical Surgery.*

(Contents of Vol. II. continued.)

- PLATE LXXXIV.—Elephantiasis of both Legs.  
 PLATE LXXXV.—Various Forms of Epithelial Cancer; the Pre-cancerous Stage.  
 PLATE LXXXVI.—Surgical Kidney from Stone in the Bladder.  
 PLATE LXXXVII.—Epithelial Cancer upon the Cornea, &c.  
 PLATE LXXXVIII.—Secondary Changes in connection with Sebaceous Tumours of the Scalp.  
 PLATE LXXXIX.—Keloid in the Scar of a Blister.  
 PLATE LXXX.—Three Portraits of Keloid.  
 PLATE LXXXI.—Diseases of the Nails in Congenital Syphilis and other Subjects.  
 PLATE LXXXII.—Various Forms of Eye Disease.  
 PLATE LXXXIII.—Diseases of the Eye.  
 PLATE LXXXIV.—Chancre in the Chin showing Unusual Features.  
 PLATE LXXXV.—Syphilitic Tertiary Ulcer resembling Rodent Cancer.  
 PLATE LXXXVI.—Lupus Lymphaticus.  
 PLATE LXXXVII.—Psoriasis Cured by Chrysophanic Acid.  
 PLATE LXXXVIII.—Very large Keloid Patch in the Scar of a Burn.  
 PLATE LXXXIX.—Multiple Keloid in the Scars of Acne.  
 PLATE XC.—Various Diseases of the Tongue.  
 PLATE XCI.—Various Diseases of the Tongue.  
 PLATE XCII.—A Peculiar Form of Cancer of the Skin.  
 PLATE XCIII.—Lupus of the Foot.

Index to Volume I.

	Page		Page
Abscesses, external, in pyæmia	228	Balanitis	19
Acne, confluent, in xanthelasma positions	143	Belladonna a possible cause of cheiro-pompholyx	52
Adams, Dr. Robert, on rheumatic gout	60	Blindness, temporary, with xanthelasma palpebrarum	169
„ Mr. John, case of abscess compressing brain	215	Blood inoculation of syphilis	130
Albuminuria in syphilis	46	Boeck, Professor, case of skin disease	43
Alopecia with xanthelasma palpebrarum	171	Bracey, Mr. C. J., case of encephalocele	7
Amaurosis with xanthelasma palpebrarum	169	Brain, abscess compressing the, case of	215
Anomalous disease of skin	41	„ „ in	67, 107
Anti-vaccination agitators, unfairness of	114	„ compression of	68, 215
Arachnitis as cause of death	68	„ concussion of 67, 80, 83, 178, 195	195
„ direct traumatic	69	„ „ as a cause of death	83
„ hemiplegia from	70, 102	„ contusion of 68, 80, 83, 85, 174-195	195
„ of sub-arachnoid spaces	68, 73, 89	„ depression of, by compression from above by an abscess	215
Astley Cooper Prize Essay	63	„ laceration of	64, 97, 178, 185
Arthritis, rheumatic, with absorption of cartilage	59	Bright, Dr., on ecchymosis from concussion	84
„ „ affecting all the joints	59, 238	Bruns, reference to a dissection of encephalocele	6
„ „ distinct from arthritis deformans	59	Bubo, diagnosis from	22
„ „ unattended by outgrowths	59	Catarrhal, lamellar, with mercurial teeth	54
		Cerebro-spinal meningitis	73



Mr. Hutchinson's Illustrations of Clinical Surgery.

(Index to Vol. I. continued.)

	Page		Page
Chancre after vaccination, description of . . . . .	113	Encephalitis . . . . .	68
"    incubation period . . . . .	17, 21	Encephalocele . . . . .	5
"    diagnosis of . . . . .	21	"    frontal, diagnosis of . . . . .	6
"    inflamed . . . . .	135	"    "    dissection . . . . .	7
"    "    and indurated . . . . .	17	"    "    prognosis . . . . .	8
"    soft and hard . . . . .	17	Erysipelatoid œdema with ecchymosis . . . . .	39
"    "    often precedes hard . . . . .	17	Exostosis, ivory, of orbit . . . . .	9
"    unusually large induration . . . . .	17	"    spontaneous necrosis of . . . . .	9
"    varieties of . . . . .	17	"    operation for removal of . . . . .	10
Cheiro-pompholyx . . . . .	49, 235	"    in frontal sinus . . . . .	10
"    "    after childbirth . . . . .	52	"    symmetrical . . . . .	11
"    "    attended by a general lichen . . . . .	52	"    operation treatment . . . . .	11
"    "    frequent recurrence . . . . .	51	First year of syphilis . . . . .	26
"    "    not related to pemphigus . . . . .	52	Fissure fracture of petrous bone . . . . .	76
"    "    possibly catarhal . . . . .	52, 236	"    "    symptoms of . . . . .	83
"    "    "    produced by belladonna . . . . .	52	Fox, Dr. Tilbury, on dysidrosis . . . . .	235
"    "    "    probably a neurosis . . . . .	52, 236	Fractures of skull . . . . .	173-191
Childs, Mr. Borlase, his case of exostosis . . . . .	9	Frontal sinus, exostosis in . . . . .	10
Chronic ulcerative rheumatic arthritis . . . . .	61	Gangrenous osteitis . . . . .	101
Chronological statement of events in syphilis . . . . .	26	Globe, retracted, in injury to cervical sympathetic . . . . .	207
Compression of brain, absence of symptoms of, in case of . . . . .	215	Hare, Dr., case of vaccination syphilis . . . . .	129
Concussion of brain . . . . .	68	Hawkins, Mr. Cæsar, on rodent cancer . . . . .	15
"    "    ecchymosis after . . . . .	79	Head, injuries to . . . . .	63
"    "    death from, without lesion . . . . .	80, 84	"    "    causes of death after . . . . .	64
"    "    tabular statement of symptoms . . . . .	86	"    "    duration of life in fatal cases . . . . .	68
Couper, Mr., case of wound of brain . . . . .	89	"    "    injury to . . . . .	40
Crus cerebri torn through . . . . .	80	Headaches, sick, xanthelasma palpebrarum associated with . . . . .	165
Daly, Dr., case of pyæmia . . . . .	228	Hemiplegia from arachnitis . . . . .	70
Diday on periostosis from inherited syphilis . . . . .	47	Hulke, Mr., histology of rodent cancer . . . . .	15
Dog-bite of scalp followed by osteitis . . . . .	96	Hydrocele of neck . . . . .	35
Dura mater, inflammation . . . . .	95, 105, 109	"    "    treatment, &c. . . . .	36
Dysidrosis in relation to cheiro-pompholyx . . . . .	235	"    "    relation to nævus . . . . .	37
Ear, discharge from . . . . .	40	Incubation period in syphilis . . . . .	117
Ecchymosis and congestion of pia mater . . . . .	79	Indurated chancre . . . . .	17
"    "    &c., curious case of . . . . .	39	Inherited syphilis, family history . . . . .	47
Eye, state of the, in vaso-motor paralysis . . . . .	203	Iodide of potassium of little use . . . . .	48
Enamel, defects of, from stomatitis . . . . .	54, 238	Jacob's ulcer . . . . .	13
		Jaundice, black, with xanthelasma palpebrarum . . . . .	170
		Lamellar cataract with mercurial teeth . . . . .	54
		Life, duration of, after fatal injury to head . . . . .	68
		Liver, enlarged, in hereditary syphilis . . . . .	46
		Livid patches on fingers . . . . .	41
		Locomotor ataxy with xanthelasma palpebrarum . . . . .	171
		London Hospital Reports, case from . . . . .	91

Mr. Hutchinson's Illustrations of Clinical Surgery.

(Index to Vol. I. continued.)

	Page		Page
Longitudinal sinus, thrombosis	108	Pyæmia in connection with osteitis	66, 102, 106
of 99, 105,	108	"    "    throm-	66, 102
"    "    suppurative	109	"    "    phlebitis.	221
inflammation of.	109	"    theory of.	95, 106, 224
Lupus around vaccination scar	137	Rheumatic gout, pathology of	59
Melanosis	29	Robinson, Dr., on cheiro-pompholyx	236
its malignancy	30	Rodent cancer	13
of fingers and toes.	31	"    a true cancer	14
with gland disease.	31	"    histology of	15
of the eye	32	"    operations for.	15
of face	33	"    never seen in the	15
treatment by escharotics.	34	"    young.	15
&c.	34	"    influence of age on	14
prognosis	34	"    importance of early	15
Meningitis, cerebro-spinal	73	"    treatment	15
subarachnoid. on surface of	194	Rules for diagnosis of chancres	21
hemisphere 89, 178, 186, 190,	194	Scalp, laceration of, followed by	96
Meningocele	5	osteitis	35
"Mercurial teeth"	53	Sequelæ of syphilis	35
"    to be carefully	53	Sick headaches, xanthelasma palpebrarum associated with	165
distinguished from	53	Skull, bullet perforations of the	201
syphilitic	53	chipped fracture of	109
Mercurial treatment of syphilis	119, 132	circular, vertical fracture of	173
"    "    delayal	133	the anterior part of	187
of symptoms by.	133	compound depressed fracture	187
Mercury a cause of malformed	53	of, trephining in	187
teeth.	53	compound depressed "gut-	187
influence in syphilis.	24	ter-like" fracture of	186
Mole the seat of melanosis	34	compound fracture of side of,	69
Moon, Mr., on stomatitis teeth	238	with extensive depression	177
Moore, Mr. C. H., on rodent can-	15	compound fractures of	183
cer	15	depressed fracture of vault,	179
Multiplicity of nodes	48	with fracture of base	173-191
Mundie, Dr., case of ecchymosis,	40	extensive fractures of base of	180
&c.	40	fissure fracture of roof of or-	183
Nodes from inherited syphilis	47	bit	180
multiple	48	fractures of the	183
Ogle, Dr. Wm., case of injury to	210	fracture of base of, caused by	183
cervical sympathetic	210	lower jaw	176
Orbit, exostosis of.	9	lengthwise fracture of base	193
fissure fracture of roof of	179	of	173
Osseous nodes, &c.	47	linear fracture with osteitis	176
Osteitis of skull bones	95, 101, 109	oblique bullet perforation of,	193
gangrenous	101	from without	173
Payne, Dr., case of injury to cervi-	211	radiating fracture with "pond	173
cal sympathetic	211	depression"	173
Petrous bone, fissure fracture of	73	scratch fracture of the fron-	173
"    "    a cause	74	tal bone	75
of arachnitis.	74	Sleeplessness in meningitis	19
Phagedæna in relation to syphilis.	23	Soft sores	19
Phlebitis, gangrenous	221	and hard sores, relationship	5
Pia mater, inflammation of	73, 90	Spina bifida cervical	6
ecchymosis of	79	"    often with occipital	6
Pictorial illustrations, value of	6	encephalocele	6
Pons Varolii, hæmorrhage into	79		
Pupil, state of the, in vaso-motor	203		
paralysis	203		
Pus contagion	21		

Mr. Hutchinson's Illustrations of Clinical Surgery.

(Index to Vol. I. continued.)

	Page		Page
Statistical statement of causes of death after injuries to head . . .	65	Vaccination syphilis, general statements . . .	130
"    "    summary of . . .	67	"    "    course of events . . .	131
Stages of syphilis . . .	25	"    "    precepts for avoidance of . . .	133
Stomatitis as a cause of malformed teeth . . .	53, 238	"    "    incredulity respecting . . .	133
Subarachnoid spaces, inflated . . .	68, 73	"    "    chancres described 113, 131	131
"    "    case of . . .	74	"    "    observe the usual stages . . .	114
Sympathetic, cervical, injury to, cases of . . .	207-213	"    "    dusky scar left by . . .	128
"    "    injury to, state of eye in . . .	203	"    "    treatment of . . .	131
Symptoms of concussion, statement of . . .	87	Vaccination sores, unhealthy . . .	137
"    "    stages of . . .	87	"    "    scar, lupus in . . .	137
Syphilis from vaccination . . .	113	Vaccinifers, syphilitic . . .	116, 122, 126, 127, 133
"    "    general remarks on . . .	129	Valves, tricuspid, vegetations on . . .	221
"    "    inherited, nodes in . . .	46	Vaso-motor paralysis, state of the eye in . . .	203
"    "    scheme of stages . . .	25	Ward, Mr. Nathaniel, case of encephalocele . . .	6
"    "    course of . . .	27	Warren, Dr. Collins, on rodent cancer . . .	15
"    "    treatment of . . .	119	Xanthelasma palpebrarum . . .	165
"    "    with & without treatment . . .	132	"    "    age of patient . . .	165
Tay, Mr. Waren, cases of vaccination syphilis . . .	128	"    "    association with other disease . . .	165
"    "    his case of hydrocele of neck . . .	36, 238	"    "    alopecia with . . .	171
Teeth, first molars the test teeth for mercury . . .	54	"    "    amaurosis with . . .	169
"    "    the first to decay . . .	54	"    "    and its allies 143-172	143-172
"    "    in inherited syphilis . . .	46	"    "    general remarks on . . .	147
"    "    mercurial . . .	53, 234	"    "    begins on left side . . .	144
"    "    escape of bicuspid . . .	54	"    "    black jaundice with . . .	170
"    "    first molars of great importance . . .	54	"    "    "chamois leather" raised patches . . .	148
"    "    with lamellar cataracts . . .	56	"    "    "chamois leather" patches not raised . . .	140
"    "    often associated with syphilitic teeth . . .	54	"    "    disease of liver in . . .	165
"    "    syphilitic and mercurial . . .	54, 238	"    "    locomotor ataxy with . . .	171
Thin, Dr., on cheiro-pompholyx . . .	235	"    "    parts affected . . .	164
Thrombosis of cerebral sinuses . . .	96, 105	"    "    positions, acne in . . .	143
"    "    connection with pyæmia . . .	108, 109, 223	"    "    cysts in . . .	145
Thrombus, examination of . . .	108	"    "    sick headaches in . . .	165
Trephining in compound depressed fracture of the skull . . .	187	"    "    symmetry . . .	164
Tricuspid valves, vegetation on . . .	223	"    "    tabular report on cases of . . .	153
Ulcerative rheumatic arthritis . . .	69	"    "    temporary blindness with . . .	169
"    "    "    accounts of autopsies in . . .	61	"    "    with great enlargement of liver . . .	167
Vaccination syphilis . . .	113	"    "    with sebaceous plugs . . .	149
"    "    first series of cases . . .	115	"    "    with jaundice . . .	166
"    "    second " . . .	122		
"    "    third " . . .	125		
"    "    fourth " . . .	126		
"    "    fifth " . . .	128		
"    "    sixth " . . .	129		

*Mr. Hutchinson's Illustrations of Clinical Surgery.*

**Index to Volume II.**

	Page		Page
Acne as a cause of keloid . . . . .	155	Eye, various diseases of . . . . .	139
Arthritis, last-joint . . . . .	55	Femur, detachment of epiphysis . . . . .	1
Black, Dr. Cornelius, case of coccygeal tumour . . . . .	39	" fracture of neck of . . . . .	5
Blood-clot between dura mater and bone . . . . .	63	" fracture through condyles . . . . .	86
Bony union after fracture of neck of femur . . . . .	5	" fracture of, with mal-union . . . . .	107
Brain, contusion of . . . . .	45	" fractures of . . . . .	83, 85
Bristowe, Dr., on myeloid tumours . . . . .	78	Filmy patches on tongue . . . . .	72
Butlin, Mr., on myeloid sarcoma . . . . .	78	Foot, lupus of . . . . .	163
Cancer of tongue . . . . .	59	Fournier, Dr. Alfred, his illustrations of disease of tongue . . . . .	60
" of cheek, crateriform . . . . .	81	Fracture with mal-union . . . . .	83
" epithelial, affecting glands . . . . .	123	" intra-periosteal . . . . .	83
"    " of cornea . . . . .	129	Glossitis, superficial . . . . .	59
" of lip from smoking . . . . .	123	" syphilitic . . . . .	75
" of scar . . . . .	123	Gout, illustrations of . . . . .	101
" the pre-cancerous stage . . . . .	123	" with rheumatic arthritis . . . . .	101
Canine tooth, malformation of . . . . .	16	" the kidney in . . . . .	101
Cervix femoris, fracture of . . . . .	5	Great trochanter, epiphysis of, detached . . . . .	109
" various forms of . . . . .	5	Gumma of testis in inherited syphilis . . . . .	138
" fracture through . . . . .	87	Hawkins, Mr. Cæsar, case of superficial rodent ulcer . . . . .	93
" extra-capsular . . . . .	87	" on cancer of scar . . . . .	124
" fractures of . . . . .	89	Heath, Mr. Christopher, on nasal encephalocele . . . . .	33
Chancre on the finger . . . . .	95	Hewitt, Sir Prescott, on meningocele . . . . .	27, 33
" of the tongue . . . . .	95	Holmes, Mr., on coccygeal tumours . . . . .	35
" of the eyelid . . . . .	95	Hydrocephalus, association with spina bifida . . . . .	42
" on the chin . . . . .	145	Inherited gout . . . . .	55
Chrysophanic acid treatment of psoriasis . . . . .	151	" syphilis, physiognomy of . . . . .	137
Cock, Mr., on sebaceous tumours . . . . .	106	Interstitial opacity of cornea . . . . .	140
Colles's fracture . . . . .	109	Intra-capsular fracture of neck of femur . . . . .	87
Compression of brain from blood-clot . . . . .	63	Iritis in an infant . . . . .	139
Conjunctiva, lupus of . . . . .	91	Jackson, Mr. Vincent, cases of Colles's fracture . . . . .	109
Cornea, cancerous growth on . . . . .	129	Kaposi's disease, its association with cancer . . . . .	125
Coccygeal tumours . . . . .	35	Keloid in the scar of a blister . . . . .	134
" microscopic anatomy of . . . . .	40	" in various positions . . . . .	135
Crateriform ulcer of the cheek . . . . .	81	" general facts concerning . . . . .	135
Cyclitis, relapsing . . . . .	143	" spontaneous disappearance of . . . . .	136
Cyst in tongue . . . . .	160	" in scar of burn . . . . .	154
Elephantiasis of the prepuce . . . . .	113	" in the scars of acne . . . . .	155
" of various parts . . . . .	115	Keratitis, syphilitic . . . . .	139
" symmetrical, of legs . . . . .	118	" punctata . . . . .	143
" general remarks on . . . . .	119	Kidney, surgical, from calculus . . . . .	127
Encephalocele, occipital . . . . .	31	Last-joint arthritis . . . . .	55
Epiphysis, detachment of . . . . .	1	Lawrence, Mr. Zachariah, on encephalocele . . . . .	33
" fracture near to . . . . .	83	Lead deposit in ulcer of cornea . . . . .	144
" detached . . . . .	109	Leucomata of tongue . . . . .	67
Epiphyses, normal position of . . . . .	112	Lichen psoriasis, states of tongue in . . . . .	72
Episcleritis . . . . .	144	Lupus of mucous membranes . . . . .	91
Epulis, myeloid and fibrous . . . . .	78		
Erratic chancres . . . . .	97		
" memoranda concerning . . . . .	98		
Exfoliation of skull after injury . . . . .	51		
Extra-capsular fractures of neck of femur . . . . .	89		

*Mr. Hutchinson's Illustrations of Clinical Surgery.*

(Index to Vol. II. continued.)

	Page		Page
Lupus of foot . . . . .	163	Skull, fracture of, with brain con-	45
„ lymphaticus . . . . .	149	„ exfoliation of, after injury .	51
Luschka's glands, site of coccygeal		Smith, Mr. Thomas, on congenital	
tumours . . . . .	39, 43	cystic tumours . . . . .	21
Mabey, Miss, her hands . . . . .	55	Smokers' tongue . . . . .	59
Mackenzie, Dr. Stephen, on con-		Solly, Mr., case of meningocele .	25
genital sacral tumours . . . . .	40, 43	Spina bifida with hydrocephalus .	42
Macro-glossa . . . . .	153	Stomatitis teeth . . . . .	17
McCarthy, Mr., case of detached		Stone in bladder causing surgical	
epiphysis . . . . .	109	kidney . . . . .	127
Meningocele, occipital . . . . .	25	Sympathetic ophthalmia . . . . .	144
„ over anterior fonta-		Syphilis passing into cancer . . . . .	147
nelle . . . . .	28	Syphilitic papilloma on tongue .	95
Mercurial teeth . . . . .	17	„ teeth . . . . .	7
Moon, Mr., on syphilitic teeth .	12	„ „ rules for diagnosis . . . . .	12
Mouth, scars round, in inherited		Teeth in hereditary syphilis . . . . .	9
syphilis . . . . .	137	„ the milk set, in syphilis . . . . .	16
Mucous membranes, lupus of . . . . .	91	„ craggy . . . . .	16
Multiple keloid . . . . .	155	„ mercurial . . . . .	17
Musée-Dupytren, specimens from 85,	105	„ peculiarities in development .	15
Myeloid tumours . . . . .	77	„ not always deformed in sy-	
„ gland affected . . . . .	77	philis . . . . .	16
Nails in inherited syphilis . . . . .	137	„ serrated . . . . .	16
Necrosis of skull after injury . . . . .	51	„ stomatitis . . . . .	17
Ninth nerve, paralysis of . . . . .	71	Testis, syphilitic disease of (in-	
Occipital meningocele . . . . .	25	herited) . . . . .	137
Œdema, solid, of one leg . . . . .	121	Tongue, cancer of . . . . .	59
Palate, lupus of . . . . .	91	„ smokers' . . . . .	59
Papilloma of tongue introductory		„ syphilitic disease of . . . . .	67
to cancer . . . . .	75	„ chronic sclerosis of . . . . .	67
Patella, fracture of, with bony union	83	„ true psoriasis of . . . . .	68
Phlyctenular ophthalmia . . . . .	140	„ in thrush . . . . .	69
Philaria found in the blood in ele-		„ in follicular stomatitis . . . . .	68
phantiasis . . . . .	113	„ in paralysis of ninth nerve .	71
Physiognomy of hereditary syphilis	14	„ fern leaf pattern . . . . .	72
Power, Mr. Henry, occipital encephalo-		„ congenital unilateral hy-	
cele . . . . .	32	pertrophy . . . . .	75
Pre-cancerous stage of cancer . . . . .	123	„ syphilitic warts on . . . . .	75
Psoriasis of the tongue . . . . .	73	„ cancer after chronic glos-	
„ cured by chrysophanic		itis . . . . .	75
acid . . . . .	151	„ fissured . . . . .	161
Radius, epiphysis of detached . . . . .	109	„ hypertrophy in ridges, sy-	
„ arrested growth of . . . . .	109, 111	philitic . . . . .	162
Relapsing cyclitis . . . . .	144	„ morbid condition, with	
Ringworm of the tongue (so called)	157	œdema of lip . . . . .	162
Rivington, Mr., case of scalp growth	105	Tophi in ear . . . . .	101
Rodent cancer, the fungating form	81	Tumour, congenital fibro-cystic .	19
„ ulcer, the superficial form	93	„ nævoid . . . . .	20
„ „ simulation of, by sy-		„ spontaneous shrinking of .	21
philis . . . . .	147	„ myeloid . . . . .	77
Salmon "patch" in keratitis . . . . .	139	„ peculiar, on leg . . . . .	130
Scalp, fungating growth on . . . . .	105	Urate of soda deposits in gout .	101
Scar of blister affected by keloid . . . . .	134	Wheelhouse, Mr., case of detach-	
Scrotum, gland tumours on . . . . .	103	ment of epiphysis . . . . .	3
Sebaceous gland tumours . . . . .	103	Wrist, fractures near to . . . . .	109
„ tumours, changes in . . . . .	132		





