

Diseases and injuries of the eye : their medical and surgical treatment / by George Lawson.

Contributors

Lawson, George, 1831-1903.

Publication/Creation

London : Henry Renshaw, 1885 (London : Ballantyne and Hanson.)

Persistent URL

<https://wellcomecollection.org/works/yy6n7pkp>


License and attribution

This work has been identified as being free of known restrictions under copyright law, including all related and neighbouring rights and is being made available under the Creative Commons, Public Domain Mark.


You can copy, modify, distribute and perform the work, even for commercial purposes, without asking permission.



Wellcome Collection
183 Euston Road
London NW1 2BE UK
T +44 (0)20 7611 8722
E library@wellcomecollection.org
<https://wellcomecollection.org>



HENRY KIMPTON
Medical Bookbinder



22101467211

617.7

WITHDRAWN
BRITISH POSTGRADUATE
LIBRARY
MEDICAL SCHOOL



Digitized by the Internet Archive
in 2015

<https://archive.org/details/b2039195x>

617.7



MANUAL
OF THE
DISEASES AND INJURIES
OF
THE EYE.

BY THE SAME AUTHOR.



INJURIES OF THE EYE, ORBIT, AND EYELIDS.

THEIR IMMEDIATE AND REMOTE EFFECTS.

8vo, cloth, with 92 Woodcuts, price 12s. 6d.



Copied from Prof. Holmgrens plate for illustrating the mistakes made by the color-blind when examined by his colored worsted tests. See pp. 234.235.

I.



1.

2.

3.

4.

5.



Colour Blindness.

II a.



6.

7.

8.

9.



Red Blindness

Green Blindness.

II b.



10.

11.

12.

13.



Red Blindness.

Green Blindness.

E. F. Bright
Jan. 4.

DISEASES AND INJURIES

OF

THE EYE:

THEIR

Medical and Surgical Treatment.

BY

GEORGE LAWSON, F.R.C.S.

MEMBER OF THE COUNCIL OF THE ROYAL COLLEGE OF SURGEONS, ENG.
HONORARY FELLOW OF KING'S COLLEGE, LONDON;
SURGEON TO THE ROYAL LONDON OPHTHALMIC HOSPITAL, MOORFIELDS
AND SURGEON TO THE MIDDLESEX HOSPITAL.

FIFTH EDITION,

*WITH NINETY-EIGHT WOOD ENGRAVINGS,
AND COLOURED PLATE ON COLOUR BLINDNESS.*

HENRY RENSHAW,
356, STRAND, LONDON.
1885.

[The right of Translation reserved.]

95400

12229

Ballantyne Press

BALLANTYNE, HANSON AND CO., EDINBURGH
CHANDOS STREET, LONDON

M20447

WELLCOME INSTITUTE LIBRARY	
Coll.	welMOMec
Call	
No.	WW100
	1885
	L42d

PREFACE TO THE FIFTH EDITION.

IN this, the Fifth Edition of my Manual, many subjects have been completely re-written, and several new articles added. Whilst relating the experiences of others, I have endeavoured, at the same time, to make this book a record of my own practice.

12 HARLEY STREET, CAVENDISH SQUARE, W.

September 1884.



CONTENTS.

CHAPTER I.

DISEASES OF THE CONJUNCTIVA.

Catarrhal Ophthalmia—Chronic Ophthalmia—Purulent Ophthalmia of newly born Infants—Purulent or Contagious Ophthalmia—Gonorrhœal Ophthalmia—Diphtheritic Ophthalmia—Granular Lids—Syndectomy—Xerophthalmia—Pemphigus Conjunctivæ—Pterygium—Pinguecula—Dermoid Tumours of the Cornea and Sclerotic—Fibro-fatty Tumours of the Conjunctiva—Cysts of the Conjunctiva—Warts of the Conjunctiva—Injuries of the Conjunctiva—Ecchymosis of the Conjunctiva—Lacerations of the Conjunctiva . pp. 1-30

CHAPTER II.

DISEASES OF THE CORNEA AND SCLEROTIC.

Corneitis—Chronic Interstitial Corneitis—Strumous Corneitis—Diffuse Suppurative Corneitis—Hypopion—Onyx—Abscess of the Cornea—Paracentesis of the Cornea—Sämesch's Operation—Marginal Corneitis—Phlyctenular Ophthalmia—Corneo-Iritis—Ulcers of the Cornea—Superficial Ulcers of the Cornea—Superficial Nebulous Ulcers—Superficial Transparent Ulcers—Deep Ulcers of the Cornea—Sloughing Ulcers—Crescentic or Chiselled Ulcers—Chronic Vascular Ulcers—Fistula of the Cornea—Nebula of the Cornea—Leucoma of the Cornea—Operation for Tattooing the Cornea—Opacity of the Cornea from Lead—Calcareous Film of the Cornea—Conical Cornea—Kerato-globus—Staphyloma of the Cornea, partial and complete—Ciliary Staphyloma—Cyclitis—Episcleritis—Arcus Senilis—Injuries of the Cornea and Sclerotic—Foreign Bodies on the Cornea—Abrasions of the

Cornea—Penetrating Wounds of the Cornea and Sclerotic— Rupture of the Eye through the Sclerotic—Sarcoma of the Cornea and Sclerotic	pp. 31-82
---	-----------

CHAPTER III.

DISEASES OF THE IRIS AND VITREOUS HUMOUR.

Iritis—Classification of—General Symptoms of—Syphilitic Iritis —Rheumatic Iritis—Gouty Iritis—Serous Iritis—Suppura- tive Iritis—Traumatic Iritis—Cysts of the Iris—Cysticercus on the Iris—Melanotic Sarcoma of the Iris—Functional Derangements of the Iris—Mydriasis—Mydriatics—Sulphate of Atropia—Sulphate of Daturine—Hydrobromate of Homa- tropine—Sulphate of Duboisine—Myosis—Myotics—Calabar Bean—Sulphate of Eserine—Nitrate of Pilocarpine—Opera- tions on the Iris—Iridectomy—Artificial Pupil—1. With a Broad Needle and Tyrrell's Hook—2. By Iridectomy—3. By Division of the Iris with a pair of Scissors—Injuries to the Iris—Hæmorrhage into the Anterior Chamber—Core- dialysis—Prolapse of the Iris—Irido-Choroiditis—Choroido- Iritis—Sympathetic Ophthalmia—Glaucoma—The Acute and Sub-acute Inflammatory Glaucoma—The Chronic or Simple Glaucoma—The Intermittent Glaucoma—The Con- secutive or Secondary Glaucoma—Pathology of Glaucoma— Sclerotomy—How to ascertain the Tension of the Globe— Tremulous Iris—Coloboma of the Iris—Diseases of the Vitreous—Hyalitis—Muscæ Volitantes—Opacities of the Vitreous—Sparkling Synchysis—Fluidity of the Vitreous— Foreign Bodies in the Vitreous—Hæmorrhage into the Vitreous	pp. 82-137
---	------------

CHAPTER IV.

DISEASES OF THE CRYSTALLINE LENS.

Cataract—Causes of—Classification of—Soft and Hard Cataracts —Congenital and Infantile Cataract—Lamellar Cataract— Cortical Cataract—Operations for Soft Cataract—Operation by Solution—Linear Extraction—Suction Operation—Hard Cataracts—Varieties of—Nuclear, Striated, Black and Senile Cataracts—Operations for Hard Cataracts—Flap Extraction Operation—Accidents which may happen in Flap
--

Extraction of Cataract—The Traction Operation—Von Graefe's Modified Linear Extraction—Liebreich's Extraction Operation—Pagenstecher's Operation for Extracting the Lens in its Capsule—Macnamara's Operation for Cataract—Treatment of the Eye after an Extraction of the Cataract—The Casualties which may occur after an Extraction of a Hard Cataract—Capsular Cataract—Capsulo-lenticular Cataract—Diabetic Cataract—Fluid Cataract—Traumatic Cataract—Secondary Cataract—Capsular Opacities—Treatment of—Dislocations of the Lens—1. Into the Anterior Chamber—2. Into the Vitreous—3. Beneath the Conjunctiva—Partial Dislocations of the Lens . . . pp. 137-177

CHAPTER V.

DISEASES OF THE RETINA, CHOROID, AND OPTIC NERVE.

Hyperæmia of the Retina—Retinitis—Retinitis Albuminurica—Retinitis Syphilitica—Retinal Apoplexy—Retinitis Pigmentosa—Detachment of the Retina—Embolism of the Central Artery of the Retina—Cysts of the Retina—Diseases of the Choroid—Disseminated or Exudative Choroiditis—Sclerotico-Choroiditis Posterior—Suppurative Choroiditis—Deposits of Bone on the Choroid—Colloid Degeneration of the Choroid—Tubercles in the Choroid—Hæmorrhage from the Choroid—Injuries of the Choroid—Hæmorrhage between the Choroid and Retina—Hæmorrhage between the Choroid and the Sclerotic—Hæmorrhage into the Vitreous—Intra-ocular Tumours—Glioma of the Retina—Sarcoma of the Choroid—Melanotic Sarcoma of the Choroid—Sarcoma of the Choroid, originating in Lost Eyes—Diseases of the Optic Nerve—Optic Neuritis or Descending Neuritis—Pathology of Neuritis—The Choked Disc—Neuro-retinitis or Ascending Optic Neuritis—Atrophy of the Optic Nerve—Atrophy of the Optic Nerve from Tobacco—Amaurosis—Causes of—Amblyopia—Nyctalopia—Snow-blindness—Colour-blindness—Perimetry—Tumours of the Optic Nerve—Injuries of the Optic Nerve—Opaque Optic Nerve Fibres—The Ophthalmoscope—Fixed Ophthalmoscopes—How to Work with the Ophthalmoscope—Lateral or Focal Illumination of the Eye—Retinoscopy pp. 177-247

CHAPTER VI.

ANOMALIES OF REFRACTION AND DISEASES OF ACCOMMODATION.

Accommodation—Myopia—Ophthalmoscopic Appearances of a Myopic Eye—Treatment of Myopia—Degree of Myopia—General Rules for Selection of Glasses—Whether Myopia is Progressive—Whether Myopia is Simple or Complicated—General Directions for Myopic Patients—Hypermetropia—Classification of Hypermetropia—Treatment of Hypermetropia—To ascertain the Degree of Hypermetropia—Peculiarities of the Hypermetropic Eye—Ophthalmoscopic Appearances of a Hypermetropic Eye—Presbyopia—Treatment of Presbyopia—Astigmatism—Irregular Astigmatism—Regular Astigmatism—Asthenopia—Causes of—Treatment of Asthenopia—The Metrical System of Numbering Glasses pp. 247-273

CHAPTER VII.

STRABISMUS.

Strabismus—Causes of—To Ascertain the Degree of—Convergent Strabismus—Causes of—Divergent Strabismus—Causes of—Treatment of Strabismus—The Moorfields' Operation for Strabismus—Graefe's Operation for Strabismus—Liebreich's Operation for Strabismus—Treatment of Strabismus after the Operation—Divergent Strabismus following Division of the Internal Recti Muscles—Strabismus following Paralysis of the Opponent Muscle—Critchett's Operation for bringing forward the Internal Rectus Muscle—Tweedy's Modification of Critchett's Operation—Paralysis of the Ciliary Muscle—Spasm of the Ciliary Muscle—Diplopia—Homonymous Diplopia—Crossed Diplopia—The Action and Uses of Prisms—To Ascertain the Presence of Binocular Vision—To Test the Strength of the Muscles of the Eye—To Wear as Spectacles to Correct Diplopia—Paralytic Affections of the Muscles of the Eye—Causes of—Paralysis of the Third Nerve—Paralysis of the Fourth Nerve—Paralysis of the Sixth Nerve—Treatment of Paralytic Affections of the Muscles of the Eye—Involuntary Oscillations of the Globe—Miners' Nystagmus—Voluntary Nystagmus pp. 274-302

CHAPTER VIII.

SPECIAL INJURIES OF THE EYE.

Foreign Bodies within the Eye—Injuries of the Eye from Escharotics—Injuries from Mortar, Lime, and Plaster—Burns and Scalds of the Eye—Injuries from Strong Sulphuric and Nitric Acid—From Vinegar, Dilute Acetic Acid, or any of the Weak Acids—Injuries from Percussion Caps, Gunpowder, and Small Shot—Excision of the Eye—Artificial Eyes—Directions for Wearing Artificial Eyes . . pp. 302-314

CHAPTER IX.

DISEASES OF THE LACHRYMAL APPARATUS.

Epiphora—Causes of—Chronic Inflammation of the Lachrymal Sac—Treatment of—Stricture of the Lachrymal Canal—Sites of Stricture of—Treatment of—Acute Inflammation of the Lachrymal Sac—Treatment of—Fistula of the Lachrymal Sac—Epiphora from Mechanical Obstruction by Tumours—To Slit up the Canaliculus—Obliteration of the Lachrymal Sac—Removal of the Lachrymal Gland—Diseases of the Lachrymal Gland—Inflammation of the Lachrymal Gland—Cysts of the Lachrymal Gland—Fistula of the Lachrymal Gland—Chronic Enlargement of the Lachrymal Gland—Treatment of—Sarcoma of the Lachrymal Gland
pp. 315-328

CHAPTER X.

DISEASES OF THE EYELIDS.

Tinea Tarsi—Hordeolus—Eczema of the Lids—Trichiasis—Distichiasis—Operation for the Removal of the Eyelashes—Repositio Ciliorum—Entropion—Spasmodic Entropion—Chronic Entropion—Causes of—Treatment of—Burow's Operation for Entropion—Ectropion—Causes of—Treatment of—Paralytic and Spasmodic Affections of the Eyelids—Ptosis—Complete and Partial—Paralysis of the Orbicularis Muscle—Blepharospasm—Nictitation—Ulceration of the Eyelids—Syphilitic Ulcers of the Eyelid—Treatment of—Rodent Cancer of the Eyelid—Epithelial Cancer of the Eye-

lid—Treatment of Epithelial and Rodent Cancer—Tumours of the Eyelid—Tarsal Cysts—Nævus of the Eyelid—Sebaceous or Dermoid Cysts—Xanthelasma Palpebrarum—Treatment of—Epicanthus—Injuries of the Eyelids—Ecchymosis of the Eyelid—Abscess of the Eyelid—Wounds of the Eyelid—Results of Injuries and Ulcerations of the Eyelids—Anchyloblepharon—Treatment of—Symblepharon—Treatment of—Herpes Zoster Frontalis—Treatment of

pp. 329-372

CHAPTER XI.

DISEASES OF THE ORBIT.

Protrusion of the Globe—Abscess of the Orbit—Acute and Chronic—Treatment of—Fractures of the Bones of the Orbit—Foreign Bodies in the Orbit—Treatment of—Penetrating Wounds of the Orbit—Periostitis of the Orbit—Treatment of—Necrosis and Caries of the Orbit—So-called Aneurisms of the Orbit—Idiopathic or Spontaneous Aneurism of Orbit—Traumatic Aneurism of Orbit—Aneurism by Anastomosis of Orbit—Venous Nævus of the Orbit—Exophthalmic Goitre—Treatment of—Tumours of the Orbit—1. Those which Originate Within the Orbit—2. Those which Commence Within the Eye—3. Those which have their Origin Beyond the Eye or Orbit—4. Congenital Tumours of Orbit—Treatment of Tumours of the Orbit—Acute Inflammatory Exudation into the Orbit—Distension of Frontal Sinus—Anatomy of Frontal Sinus—Causes of Distension of Frontal Sinus—Treatment of Distension of Frontal Sinus . pp. 372-413

FORMULARY OF PRESCRIPTIONS p. 415

TEST-TYPES pp. 431-434

INDEX pp. 435-452

Erratum.—At page 153, in the small type, under Fig. 41, for
“ring finger” read “index finger.”

MANUAL

OF

DISEASES OF THE EYE.

CHAPTER I.

DISEASES OF THE CONJUNCTIVA.

CATARRHAL OPHTHALMIA—*Acute Conjunctivitis*—is an inflammation of the conjunctiva covering the eye and lining the lids. It may come on without any apparent cause, or it may be produced by rapid alternations of temperature, or by exposure of the eye to cold. Catarrhal ophthalmia will sometimes assume an epidemic character, and large numbers in the same locality will suffer from it; or it will attack every member of a family in succession, notwithstanding that due precautions have been taken to prevent it spreading by direct communication.

Symptoms.—A feeling of grittiness, as if dust or fine sand were in the eye, with some stiffness of the lids. The conjunctiva becomes red, and this increase of vascularity generally commences from the circumference of the globe, and fades as it approaches the cornea. In the advanced stage of this affection the white of the eye becomes of one uniform red colour. The redness is superficial, and of a brighter and darker shade than that caused by inflammation of the deeper structures of the eye, for which it can hardly be mistaken. There is an increased secretion from the surfaces of the eye and lids; at first only of mucus but afterwards of muco-pus, small quantities of which will collect in little beads over the caruncle at the inner angle of the eye, or form little

scabs on the edges of the lids by caking on the eyelashes. If the lower lid be drawn down by the finger, one or two streaks of pus or lymph will be often seen in the oculo-palpebral fold. The patient complains that the lids are sticky, and that in the morning they are gummed together by dried secretion. On looking at the eyes, there is a peculiar sticky and gummy appearance which is quite characteristic of the disease. There is often associated with these symptoms chemosis of the conjunctiva and swelling of the lids. The conjunctiva looks blown up from the serous effusion into the subjacent cellular tissue, sometimes to an extent sufficient to make the cornea appear sunken below it. The cornea is clear, and the pupil is active. The rapid action of the pupil will at once decide that the inflammation is superficial and that the iris is not affected by it.

Catarrhal ophthalmia usually commences in both eyes simultaneously, or one eye may be attacked a little in advance of the other, but it is seldom that this disease is limited to only the one eye. In this respect catarrhal ophthalmia offers a marked difference from gonorrhœal ophthalmia, which is generally, in the first instance, strictly confined to the one eye. (See GONORRHOËAL OPHTHALMIA, page 8.)

Prognosis.—This affection is usually very amenable to proper treatment, and the eyes will recover without a trace of the disease remaining. But if no treatment be adopted, or unsuitable remedies be used, the conjunctival inflammation may extend to the cornea, and corneitis with superficial or deep ulcerations may follow.

Treatment.—The eyes should be bathed every two or three hours, or oftener if the case is severe, with a lotion of alum, or sulphate of zinc and alum (F. 47, 48, 50), taking care that with each application a little is allowed to flow into the eyes. A solution of nitrate of silver (F. 22), or of chloride of zinc (F. 25), is very useful in catarrhal ophthalmia, and especially in those cases where there is chemosis of the conjunctiva and swelling of the lids. Two or three drops should be dropped into the eye twice a day, and every two or three hours, or oftener if necessary, the eyes should be cleansed from discharge by bathing them with a lotion of boracic acid (F. 45). To prevent the gumming together of the eyelids during sleep, a little unguent. cetacei or vaseline should be smeared along their tarsal borders every night. At the

commencement of the attack the bowels should be acted on by some purgative, and if the patient is hot and thirsty an alkaline or effervescing draught (F. 66, 68) may be prescribed, but as a rule tonics such as bark, quinine, or iron will be required; and these are given with most benefit after the first febrile symptoms which often usher in an attack of catarrhal ophthalmia have passed away.

CHRONIC OPHTHALMIA may be consequent on catarrhal ophthalmia, the acute disease subsiding into a chronic form, but this is quite exceptional. Chronic ophthalmia generally occurs in patients who are below the standard of health, and in those who have to earn their living by the long-continued use of their eyes at fine work.

Symptoms.—The eye has a reddish and irritable appearance; it will not face the light without a sense of discomfort and watering. The caruncle and edges of the lids often look red and prominent, and the secretion of the mucous surfaces of the lids and globe is slightly increased. Reading or fine work soon tires the eye, and causes it to flush up. The patient is generally more or less out of health, oftentimes used up from want of rest.

Treatment.—When there is reason to believe that over-use of the eyes has been the exciting cause of the disease, rest must be strictly enjoined. Close reading, the casting up of figures, and all fine work should be forbidden. The state of the patient's health should be improved, and any irregularity in the discharge of the functions of the different organs of the body should be as far as possible corrected.

Local Applications.—When there is any extra secretion from the mucous surfaces of the lids or eye, mild stimulating drops or lotions do good. Two or three drops of the *guttæ argenti nitratis* (F. 22), or of *zinci sulphatis* (F. 26), may be dropped into the eye twice a day. Lotions with alum or with alum and sulphate of zinc combined (F. 48, 50), are very efficacious; a weak solution of the acetate of lead (F. 52), provided there is no abrasion of the cornea, will be often found very useful. The tarsal edges of the lids should be anointed at night with a little unguent. *cetacei*, to prevent their gumming together; or if there is much secretion from the Meibomian follicles, the unguent. *hydrarg. nitratis dilut.* (F. 129) may be advantageously used. When there is

much dread of light, stimulating applications to the eye fail to do good, and are apt to excite considerable irritation. In chronic ophthalmia counter-irritation will be frequently found beneficial; a small blister of emplastr. cantharidis, or a piece of Brown's blistering tissue of the size of a shilling, may be applied to the temple, or behind the ear, and repeated in two or three nights if necessary.

If the remedies named fail to afford relief, a seton in the temple of a single or double thread of thick corded silk will occasionally do good. The seton should not be allowed to remain more than three or four weeks, or the ulceration at the entrance and exit of the thread may cause an unsightly scar. In cases of persistent chronic ophthalmia the lids should be everted and carefully examined for granulations, as, if the conjunctiva has become granular, the ophthalmia will continue until the granulations are cured. (See GRANULAR LIDS.)

PURULENT OPHTHALMIA OF NEWLY-BORN INFANTS—*Ophthalmia neonatorum*—is one of the most important diseases of the eye which the surgeon can have under his care. When rightly treated it is one of the most remediable, but when neglected, or, what is often worse, when unsuitable and improper remedies are used, it is one of the most disastrous of all the inflammatory affections of the eye. The responsibility of any one undertaking a case of purulent ophthalmia who is not thoroughly acquainted with its nature and treatment is very great. Many a useful life has been blighted in the first month of its existence by irreparable blindness, which might have been prevented if the simple means, which seldom fail to arrest this formidable disease, had been rightly applied. Purulent ophthalmia usually commences from the second to the seventh day after birth. Both eyes are commonly affected simultaneously, but to this there are occasional exceptions; thus, one eye only may be involved, or the first eye may suffer twelve or twenty-four hours in advance of the second.

Symptoms.—The first indication of the disease is usually detected by the nurse, who notices that there is a slight discharge from the eyes, and that the edges of the lids are glued together during sleep. In a short time, often within a few hours, the discharge increases greatly in quantity and changes in quality; it first becomes muco-purulent, and ultimately, if the case is

severe, is converted into almost pure pus. The eyelids now become red and swollen, and their tarsal margins caked together, pen up the discharge, which accumulates behind the lids, and streams over the cheeks when the eyes are opened. The quantity of pus which literally pours from between the eyelids in a bad case, and the rapidity with which it is secreted, are very remarkable.

In the *slight* cases of purulent ophthalmia the discharge is of a whitish colour with scarcely a tinge of yellow, and it is not very abundant in quantity. In the *very severe* forms of the disease the discharge is of a deep yellow colour and very profuse. Between these extremes there are many gradations.

Prognosis.—When a child suffering from purulent ophthalmia is seen sufficiently early, and proper remedies are rightly applied, recovery is almost certain. It should, however, be remembered that cases occasionally occur of so severe a nature that all treatment is unavailable to arrest the progress of the disease, and one or both eyes are rapidly and irrecoverably destroyed. In such instances it will generally be found that the discharge was of a deep yellow colour, very copious, and that it commenced on the first or second day after birth. It will also be probably ascertained on inquiry that the mother had gonorrhœa at the time of her confinement or leucorrhœa of so severe a type that the discharge was yellow and puriform.

Treatment.—The indications for treatment are to wash away the discharge from the eye as often as it collects, and to use some astringent lotion to arrest the resecretion of the purulent matter. Lotions of alum, or of sulphate of zinc and alum (F. 47, 50), and drops of nitrate of silver, are the most useful astringents in purulent ophthalmia. The lotion which I generally use is one of alum (F. 47). The mode, however, of applying the remedies is of as much importance as the remedies themselves. The lotion should be gently squirted into the eye with an india-rubber syringe with an ivory nozzle, or with a small glass syringe, every half-hour or hour, according to the severity of the case, the object being to thoroughly cleanse the eye from all discharge as often as it is resecreted. This treatment should be pursued by night as well as by day. The intervals between the use of the lotion may be increased as the discharge decreases in quantity. The carrying out of these instructions should

be entrusted solely to the nurse, as the mother, so soon after her confinement, is unfitted for the duty, and rest is also essential for her in order to ensure a due supply of milk for the child.

The easiest way of applying the lotion is as follows :—The nurse should lay the child on her lap, turning its head a little to one side or the other, according to the eye she is going to wash out. With the thumb and finger of her left hand she gently separates the lids, whilst with the right hand she squirts a stream of the lotion into the eye from the nasal side, allowing it to run away from between the lids on to a soft napkin, which she has placed under the child's head to receive it.

If the case be very severe, the surgeon should see the child once or twice a day himself, and having washed the eye thoroughly from all discharge with a stream of cold water, he should drop into it two or three drops of a solution of nitrate of silver, gr. 2 ad aquæ $\bar{5}$ l, and order the alum lotion to be continued as directed during his absence. In some cases, where the nurse is very awkward, and cannot rightly use the lotion with a syringe, it may be efficiently applied by means of a soft camel's-hair brush. From time to time a little unguent. cetacei or unguent. iodoformi (F. 133) should be smeared on the edges of the lids, to prevent their sticking together.

It occasionally happens in bad cases of purulent ophthalmia that the upper eyelid becomes completely everted. This ectropion is due partly to the tendency to eversion which is induced by the swollen conjunctiva, and partly also to the spasmodic action of those fibres of the orbicularis which pass over the upper border of the upper lid. For the relief of this form of ectropion there are several modes of treatment. In many cases the everted lid may be returned to its normal position and kept in situ by a fold of lint tied over the closed lids with a bandage and kept wet with lotio aluminis (F. 47). In very obstinate cases I have divided the external canthus with a pair of scissors so as to relieve the spasm of the orbicularis, and having replaced the everted lid, kept it in position for a few days by uniting it to its fellow by two sutures through their tarsal margins.

Evil results of the Purulent Ophthalmia of Infants.—The great danger in this disease is lest the inflammation which was originally confined to the conjunctiva of the lids and globe, should extend to the cornea.

When this happens, acute corneitis follows; the cornea becomes at first hazy, then ulcerates either superficially or deeply, or, if the case be very severe, a large portion of it may slough. As the result of such casualties we get nebula, leucoma, or staphyloma of the cornea. Each of these subjects will be found fully treated of under their respective headings.

PURULENT OPHTHALMIA—*Contagious Ophthalmia*.—To this disease very many names have been applied, but the two mentioned are sufficient to indicate its nature. This form of ophthalmia is both purulent and contagious. It has been called *Egyptian Ophthalmia*, from its being ever present in Egypt, where the severest types of the disease are to be constantly found.

In its mild form it closely resembles catarrhal ophthalmia, for which it may be mistaken; but in the worst cases it almost equals in severity the gonorrhoeal affection of the eyes.

Purulent ophthalmia commences with a slight discharge from the eye, and swelling of the lids. The discharge soon increases in quantity, and becomes puriform, the conjunctiva gets chemosed, and the lids grow red, shining, and œdematous. If the disease progresses unchecked, the cornea first becomes cloudy, then ulcerates, or portions of it slough, and the eye is destroyed. The peculiar tendency of purulent ophthalmia is to attack masses of people who are congregated together, and living without due attention to cleanliness and ventilation. Hence it is that the disease has frequently broken out amongst soldiers in barracks, amongst the poor in workhouses, and in large pauper schools in the country.

Although purulent ophthalmia is undoubtedly propagated by inoculation, yet there is abundant evidence to show that it may be epidemic, and spread without any direct conveyance of the purulent secretion from eye to eye. I think myself that the ordinary catarrhal ophthalmia may, and frequently does, assume a contagious form, and that it is liable to do so, whenever it attacks members of a community who are living in violation of the laws of health.

Treatment.—A *mild* case of purulent ophthalmia should be treated in the same way as catarrhal ophthalmia, page 2; but if the case is *severe* the plan of treat-

ment recommended for gonorrhœal ophthalmia, page 10, should be adopted. After the severity of the disease has been arrested, there is apt to remain a muco-purulent discharge, which will obstinately resist all treatment for many weeks, or even months. Upon everting the lids it will be often found that this chronic discharge is due to a granular condition of the palpebral conjunctiva induced by the disease. (See TREATMENT OF GRANULAR LIDS, page 18.)

In all outbreaks of the disease sanitary precautions should be taken to prevent it spreading, and the bad cases should be kept apart from the others. A daily inspection should be also made to treat each fresh case as soon as the early symptoms show themselves.

Results of Purulent Ophthalmia.—1st. If the disease resists all treatment, the eye may be lost from ulceration or sloughing of the cornea. 2nd. The eye may recover, but with a nebula of the cornea, or a leucoma, to the inner surface of which the iris is frequently attached, causing a distortion of the pupil. 3rd. A granular state of the lids, with a chronic muco-purulent discharge.

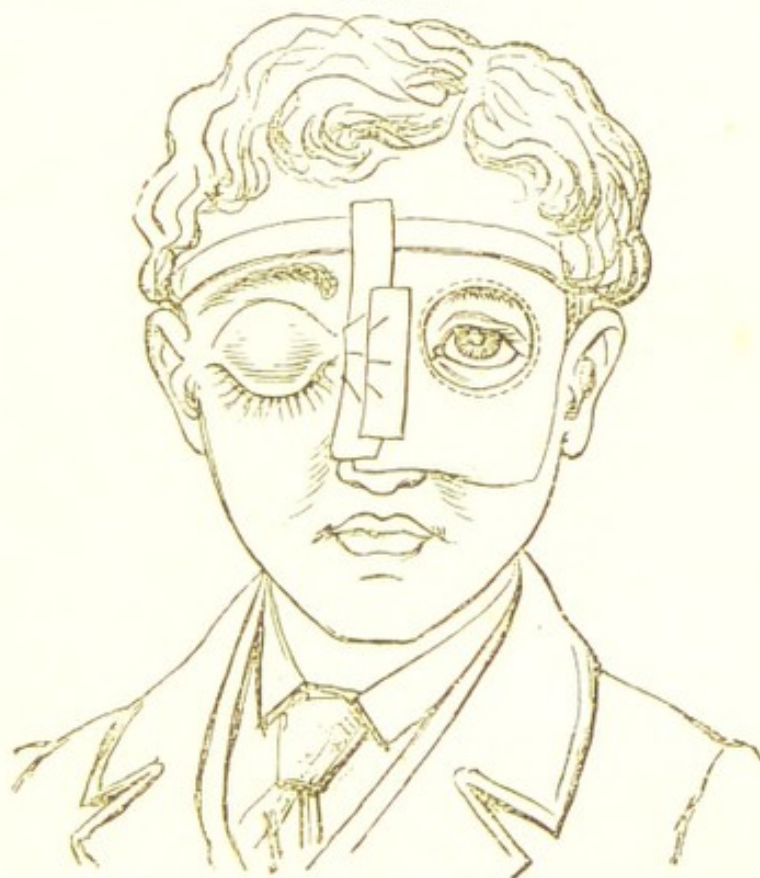
GONORRHOËAL OPHTHALMIA is an acute specific inflammation of the conjunctiva of the lids and globe, induced by the inoculation of some gonorrhœal matter into the eye. It is characterised by a profuse purulent discharge from between the lids, which is of a yellow colour, and exactly corresponds in appearance with that which flows from the urethra. The disease is rapid in its progress and very destructive; unless it is soon checked, the eye is lost.

Symptoms.—Acute inflammatory action usually commences in from six to eighteen hours after the inoculation has been effected. The early symptoms resemble those of catarrhal ophthalmia, but they are more severe. A slight thin discharge first begins to ooze from between the lids, accompanied by a sense of heat and fulness of the eye. The conjunctiva of the globe grows red, swollen, and chemosed, often rising above the level of the cornea, which will appear as if it were partially buried below it. The lids are swollen, red, and shining, and completely closed over the eye. The discharge has now become excessive in quantity, of a thick consistence and yellow colour, and streams over the cheeks from between the lids. The

cornea is almost certain to become involved, and if the inflammation be not quickly subdued, ulceration and sloughing of its structure will surely follow. The patient suffers severely from the pain in the eye and around the orbit, with an oppressive feeling of heat and fulness of the lids and globe. The disease is usually confined to the one eye. When the second becomes affected it is generally on account of due precaution not having been taken to shield it from the danger of inoculation.

The most efficient mode of protecting the sound eye from contagion is by covering it with the eye-shield designed by Mr. F. Buller. The following is his description:—"It consists of a square piece of macintosh, into the centre of which a watch-glass is fastened, and of three

FIG. 1.



strips of adhesive plaster. The macintosh is trimmed to fit the nose and forehead of the patient, and should extend across one side of the forehead about half an inch above the eyebrow, and downwards nearly to the tip of the nose, the nasal portion reaching a little beyond the median line.

"A strip of adhesive plaster, about an inch in width,

and long enough to reach from just in front of one ear to a corresponding point on the opposite side, is applied along the upper border of the shield. The second strip may vary in width according to the height of the nose, and must be snipped in three or four places, in order that it may be adapted to the uneven surface upon which it rests, the lower part only slightly overlapping the edge of the shield. For additional security, a third and somewhat shorter strip is placed along the dorsum of the nose. The eye is thus completely protected by a water-proof shield, the upper and inner sides of which are firmly adherent to the skin of the forehead and nose, whilst the lower and outer borders are free, so that the eye is exposed to the air almost as freely as when an ordinary shade is worn. Moreover, the surfaces of the watch-glass being parallel, vision is not interfered with, and the patient is able to attend to the affected eye.

“As the strips of adhesive plaster become softened in the course of a few days by the warmth and secretion of the skin, they require to be renewed. This may be done as often as necessary without any difficulty or danger of infecting the healthy eye.”*

Treatment.—A few years ago the treatment consisted in excessive bleedings from the arm, and in the use of strong depressing medicines. Experience has shown the error of such proceedings, and by now adopting a directly opposite course a far larger proportion of cases recover with good and useful eyes. In gonorrhœal ophthalmia the treatment must be constitutional and local.

Constitutional Treatment.—From the very commencement of the attack the strength of the patient must be supported by tonics, diffusible stimuli, and a liberal diet. The whole history of gonorrhœal ophthalmia is of a depressing character. The patient generally suffering from gonorrhœa at the time the eye becomes inoculated, is, from the nature of his complaint and the treatment adopted to cure it, below the standard of health. The disease itself is also very exhausting; but the prospect of loss of vision, with the utter annihilation of all future prospects, adds to his sense of loneliness and despair. The fact that the patient is suffering from a severe urethral discharge will not forbid the free use of tonics and stimulants. The danger of ulceration and sloughing

* *Lancet*, May 16, 1874.

of the cornea is increased in proportion as the vital powers are depressed. Having therefore first acted freely on the bowels by a moderate purgative, quinine in 2 gr. doses, or the mineral acids with cinchona (F. 75), should be given every four hours. If there is much pain or irritability, opium should be prescribed, either in small quantities frequently repeated, or in one full dose at bedtime. Where there is heat of skin, with thirst and a furred tongue, an effervescing mixture with ammonia (F. 66) may be advantageously ordered before prescribing the direct tonics. The diet should be one of meat or beef-tea, with a certain amount of wine or brandy, according to the strength of the patient.

Local Treatment.—The best applications are the local astringents and antiseptic lotions given below. In severe cases, owing to the swelling of the lids, it is very difficult to make any application to the conjunctival surfaces of the eye and lid. To remedy this, the external canthus may be freely divided, and the lid will then be more easily everted. In a patient with bad gonorrhœal ophthalmia at the Middlesex Hospital, the late Mr. Critchett divided the upper lid through its centre by a vertical incision and stitched the edges apart. The local applications could then be freely applied and the patient did well. He afterwards pared the edges of the gap and united them.

1st. Nitrate of Silver.—This is best used in the form of solution, varying in strength from gr. 10—gr. 30 ad aquæ $\bar{3}$ l, according to the severity of the case. The lids should be everted and the conjunctival surfaces painted over with a camel's-hair brush with the solution, which should be allowed to remain a few seconds so as to whiten the parts, and be then washed off with a stream of cold water, or of salt and water, gr. 5 ad aquæ $\bar{3}$ l, from an india-rubber bottle. This should be repeated once daily, and in very bad cases a second application may be necessary. For the mode of applying the solution of the nitrate of silver, see TREATMENT OF GRANULAR LIDS, page 18. When the lids are so swollen that they cannot be everted, two or three drops of a weaker solution of nitrate of silver, from gr. 2—gr. 5 ad aquæ $\bar{3}$ l, may be dropped twice a day into the eye, after it has been first cleansed by syringing away the discharge with cold water.

2nd. Lotions of Alum, or Alum and Sulphate of Zinc (F. 47, 50) should be used at least once

every hour, to wash away the discharge as often as it accumulates. The lotion should be gently injected over the surface of the globe by a syringe or india-rubber bottle, so as to thoroughly wash away all purulent matter at each application.

3rd. Lotions of Carbolic Acid and Quinine.—I frequently use a lotion of carbolic acid, varying in strength, according to the severity of the case, from min. 2.—min. 6 to the ounce of distilled water, in preference to the alum, or alum and zinc lotions, and with excellent results. The carbolic lotion should be applied with a syringe every one or two hours, and the solution of nitrate of silver with a camel's-hair brush once a day.

I have also used with good effect the quinine lotion (F. 53), with which the eye should be constantly washed, and with each application some allowed to go into the eye. The quinine and carbolic lotions may be used alternately with good results.

4th. Cold is very grateful to the patient, and may be applied during the intervals between using the lotion, by placing a fold of lint wet with iced water over the eyelids, and changing it as often as it becomes hot or dry. The patient may also be allowed to wash away the discharge with a piece of linen dipped in the iced water as fast as it exudes from between the lids.

5th. If the cornea should become ulcerated and there be danger of perforation, the guttæ eserix (F. 18) should be used twice daily in addition to the other treatment, so as to keep the pupil contracted, and thus avoid, as far as possible, the danger of prolapse of the iris. To prevent the gumming of the lids together, and as a good antiseptic, the tarsal margins may be anointed daily with the unguent. iodoform. (F. 133).

By a steady perseverance in this line of treatment the best chance of saving the eye is afforded to the patient; but the disease is frequently of so virulent a character that, in spite of all remedies and the most judicious management, the cornea sloughs, and the eye, for all useful purposes, is irretrievably lost.

There is a form of gonorrhœal ophthalmia consequent on the urethral discharge, but which is *not produced by inoculation*. The two eyes are affected simultaneously within a few days or a week after the appearance of the gonorrhœa. It closely resembles a very severe attack of catarrhal ophthalmia. I have had one gentleman under

my care who has had three attacks of this form of inflammation of the eyes, coming on each time shortly after he had contracted a fresh gonorrhœa. The purulent discharge from the eyes was at one time so copious that I thought it must have been caused by inoculation, but its reappearance in both eyes with each recurrence of the urethral discharge has now convinced me that it was due to other causes. I should add that this patient with each attack of gonorrhœa suffered severely from gonorrhœal rheumatism. It is possible that this form of ophthalmia may be due to the same absorption of the poison as that which induced the rheumatism, and that the discharge from the eyes is an attempt to eliminate the poison through the mucous surfaces of the globe and lids. Another explanation is, that in some people there exists a peculiar sympathy between the mucous membranes of one part of the body with those of another; thus, it is not uncommon to find in common catarrh the whole mucous lining of the body more or less affected at one time, and in one gentleman with whom I am acquainted a severe catarrhal attack is frequently accompanied by a discharge from the urethra.

Treatment.—The same as for the gonorrhœal ophthalmia caused by inoculation, but as the symptoms are less severe, so the strength of the remedial applications to the eye may be reduced. Repeated doses of balsam copaiba will sometimes have a beneficial effect, and check materially the purulent secretion. A good nutritious diet, with a moderate allowance of stimulants, should be prescribed.

DIPHTHERITIC OPHTHALMIA is a disease which is almost unknown in England. It was first described by the late V. Graefe,* who witnessed several epidemics of this peculiar affection. It is characterised by the formation of false membranes which are not mere surface exudations which can be peeled off, but distinct plastic infiltrations into the conjunctiva which cannot be entirely detached. The false membranes are usually confined to the conjunctiva of the lids.

Diphtheritic ophthalmia may be a primary disease, when the symptoms are usually very acute; and it may

* Archiv f. Opthal., . 168, 1854-5.

be epidemic. In England it is generally secondary to a purulent or a gonorrhœal ophthalmia, and the stages of the disease are usually less marked than those which V. Graefe described as characteristic of diphtheritic ophthalmia.

Symptoms.—When diphtheritic ophthalmia occurs as a primary disease, it usually commences suddenly, the eyelids become red, swollen and rigid from fibrinous effusion into the subcutaneous tissues: there is chemosis of the ocular conjunctiva, not from serous effusion as in the purulent ophthalmia, but from fibrinous infiltration; and a thin discharge, mixed with flocculi of lymph, oozes from the eye. As the disease advances, the swelling and redness of the lids increase and exudations of lymph take place on the surface and into the substance of the conjunctiva of the lids, and are seen on everting the lids, either as small isolated grey patches, or else as a continuous membrane. This membrane may sometimes be partially peeled off, when the conjunctiva below it bleeds; or more frequently only the superficial layers of lymph can be detached, and the deeper portion is seen to be incorporated with the mucous membrane and incapable of separation. The cornea is very apt to suffer, probably from the constriction of the vessels caused by the fibrinous infiltrations into the conjunctiva and subconjunctival tissues. It first becomes hazy, portions of its epithelium are detached and an ulcer is formed, which may lead to perforation and prolapse of the iris; or parts of the cornea may slough and the eye be destroyed. After a variable period, generally from two or three days to a week, the disease drifts into its second stage; the lids become less rigid, the redness subsides, and the discharge becomes purulent; the fibrinous exudations are thrown off, and the conjunctiva of the lids appear almost bared of their epithelium. Cicatrization and contraction now set in, and not unfrequently cause some inversion of the lids. Such are the symptoms of a severe case of diphtheritic ophthalmia, but there are many which run a much milder course.

When the diphtheritic affection is secondary to a purulent ophthalmia, the character of the discharge changes. It becomes more watery, and adherent false membranes are formed on the conjunctiva, in the manner described in the previous sections. The disease runs the same course as the primary diphtheritic ophthalmia.

Treatment.—The treatment which I have found by far the most efficacious is the one first suggested and practised by my colleague, Mr. Tweedy. I give his own account of the treatment, which is taken from *The Lancet*, 1882, vol. i. p. 6. In writing of four cases which had been under his care, he says:—"As soon as the nature of the disease was definitely recognised, all other treatment, if any, was stopped, and quinine lotion, containing four grains of sulphate of quinine, with a minimum of dilute sulphuric acid to an ounce of water, was alone employed. As far as possible the diseased surfaces were kept constantly bathed with the solution, the conjunctival sac being converted, as it were, into a trough holding the quinine lotion. A bowl of the solution was also placed within reach of the patient, who washed the eye frequently and kept a well-soaked compress constantly applied in the intervals. Besides these applications by the patient and by the nurse, the house-surgeon visited each case three or four times a day. On these occasions the lids were everted, and the conjunctival sac thoroughly cleansed with the quinine lotion. The superficial disintegrated portions of the exudations were then gently removed with wet lint, care being taken not to aggravate the inflammation by rough handling, or by rude attempts to tear off the pseudo-membrane. Usually the quinine lotion was iced." When the discharge has become purulent, and the false membranes have ceased to form, an astringent and antiseptic lotion (F. 25, 45, 56) may be used frequently.

GRANULAR LIDS—*Granular Ophthalmia*.—These terms have been loosely applied to a rough and granular condition of the lids associated with a muco-purulent discharge from the conjunctiva.

There are three distinct varieties of granular lids, arising from different causes and producing different results.

1. Trachoma.
2. Follicular conjunctivitis.
3. Papilliform granulations.

1. **TRACHOMA**—*Trachomatous Granulations*.—This is the disease which is known as the true granular lids, which induces cicatrization of the conjunctiva, frequently leads to entropion, and is usually associated with a

vascular condition of the cornea, known as pannus. In itself trachoma is a very intractable disease, and the effects it produces on the cornea are often disastrous.

Trachoma commences as distinct new growths in the lymphoid tissue immediately beneath the conjunctiva covering the tarsus of the lids. They appear as small round opaque whitish bodies scattered in the conjunctiva of both the upper and lower eyelids, slightly projecting from the surface, and usually in the greatest numbers over the tarsus of the upper lid. They are solid growths, and so firmly implanted that it is impossible to remove them, as when punctured they will not shell out from the subconjunctival tissue in which they are embedded. They have been regarded by Dr. De Wecker as closely allied to tubercle.

Following the formation of these opaline bodies, plastic exudations infiltrate the sub-mucous tissue, and thus thicken the substance of the lid and reduce its pliancy. It is this thickened state which causes the lid to droop slightly and gives to patients with granular lids their peculiar sleepy and characteristic appearance. The conjunctival mucous membrane next undergoes changes; it first becomes over-vascular, its papillæ are increased in size, and its surface is rendered still more uneven by the irregular projections of the sub-mucous exudations. The inner surfaces of the lids now present a rough granular state which, rubbing against the cornea, produces the vascular condition called pannus.

The trachomatous process is very chronic and may continue for years, but the time comes when reparative changes begin. The trachomata undergo retrogressive changes and finally disappear; the enlarged papillæ diminish in size and ultimately shrink from sight; the conjunctiva becomes glazed and contracted, and looks like cicatricial tissue. Whilst these changes are going on in the conjunctiva, a cicatricial process also occurs in the sub-mucous lymphoid tissue: the increased thickness subsides, cicatrization and contraction of the exudative products take place, and if the case has been severe, the tarsal cartilage becomes more or less infolded and entropion results, and this entropion increases so long as the contraction from cicatrization continues. During the whole period of the disease there is a muco-purulent discharge from the conjunctiva, with some dread of light, and from time to time there are acute attacks of

inflammation which are recognised as acute granular ophthalmia, when the eye suffers from excessive photophobia, with spasm of the orbicularis muscle.

Symptoms of Trachoma.—A feeling of constant grittiness and a sense of heat in the eye, with some photophobia, and a muco-purulent discharge sufficient to cause the lids to gum together in the morning. There is redness of the caruncle and tarsal margins, and in advanced cases the upper lid droops as if it hung heavily over the eye. As the disease progresses the cornea suffers from the constant friction of the roughened palpebral conjunctiva. It becomes vascular and nebulous; its surface grows uneven, and at points frequently ulcerates. This vascular condition of the cornea dependent on granulations has been termed "*trachomatus pannus*," to distinguish it from that pannus which is the result of corneitis induced from other causes. In some cases the pannus is confined to the upper half of the cornea, the part which is under the cover, and consequently subjected to the friction of the upper lid; but in granulations of long standing, the whole surface of the cornea becomes vascular, every portion of it being pervaded with blood-vessels. All these symptoms are greatly increased if the eyes are overworked, or exposed to cold winds or bright lights. Occasionally the eyes will become acutely inflamed, constituting the condition described as *Acute Granular Ophthalmia*; the lids are then red, swollen, and spasmodically closed, from the excessive photophobia, and any attempt to open them is followed by a gush of hot tears, with some muco-purulent discharge. Under treatment these acute symptoms will gradually subside, and the eyes will again relapse into their previous state of chronic irritability.

Prognosis.—Judicious management, coupled with the reparative power of time, will generally succeed in obliterating the granulations and restoring a smooth surface to the palpebral conjunctiva. If the disease has been slight, or of only short duration, there is good reason to hope that the eye will so recover from the irritation to which it has been subjected that it will regain the greater part, if not the whole, of the sight it had lost. If, however, the granulations have been severe and long-continued, they will probably have produced mischief which neither time nor remedies will ever completely eradicate. The *conjunctiva* will frequently become changed, both in

appearance and structure. Although its surface may have grown smooth, yet it will be more contracted and dense than formerly, and have acquired in different parts a whitish glistening aspect, closely resembling cicatricial tissue. This contraction of the palpebral conjunctiva is the most frequent cause of entropion and distichiasis. (See articles on each of these subjects.)

The *cornea*, from the constant friction of the roughened lids against it, will often become so uneven, vascular, and cloudy, that for all useful purposes the eye will be practically blind.

Treatment.—The object to be accomplished is to restore a smooth surface to the lining membrane of the lids by the obliteration of the granulations; but, in endeavouring to gain this end, care must be taken to avoid the use of all strong remedies which will destroy the conjunctiva and produce deep cicatrices. The treatment from which I have found the greatest benefit has been the application to the palpebral conjunctiva of a strong solution of the *nitrate of silver*, varying in strength, according to the severity of the case, from gr. 5—gr. 20 ad aquæ $\bar{3}$ l. This should be applied in the following manner:—The patient is to be seated in a chair, and the surgeon, standing behind him, with a probe everts the upper lid so as fully to expose the palpebral conjunctiva, over the surface of which he paints with a camel's-hair brush the solution of the nitrate of silver, taking care to apply it thoroughly to the reflection of conjunctiva which forms the oculo-palpebral fold. After waiting for about half a minute, he then, with a syringe, gently squirts over the granular surface a stream of cold water, or, what is better, a solution of common salt of about the strength of gr. 5 ad aquæ $\bar{3}$ l, to wash away and neutralize all the surplus nitrate of silver, so as to prevent it irritating the eye, or blackening the ocular conjunctiva—a misfortune I have seen occur when strong solutions of the caustic have been frequently used without taking these precautions. This application should be repeated every second or third day, and in the intervals the patient should frequently bathe the eyes with cold water, and every night and morning drop into them a little of a weak solution of the chloride of zinc (F. 25), or some other mild astringent. The nitrate of silver may be also conveniently applied to the granulations by using the diluted nitrate of silver points (F. 6).

Sulphate of Copper, or a combination of this salt with alum, "*lapis divinus*," or "*green stone*," as it is commonly called (F. 5) are excellent astringents in granular lids. Every second or third day the lid should be everted, and having first dried the surface with a piece of linen, the granulations *only* should be freely touched with the sulphate of copper or green stone, taking as much care as possible to prevent the caustic from affecting the conjunctiva. Between the applications a few drops of the *guttæ cupri sulphatis* (F. 27) should be dropped twice a day into the eye.

Acetate of Lead is a useful remedy when there is excessive roughness from the whole palpebral conjunctiva being covered with red granulations of varying sizes, but unattended by any acute inflammatory symptoms. The acetate of lead should be finely powdered and laid over the granulations, and, after waiting one or two minutes the surplus should be washed off with a stream of cold water. This application does good, first, by rendering the surface more smooth by filling up the chinks between the granulations, and afterwards by its astringent powers causing them to shrink. It may be repeated three or four times, at intervals of from three to six days.

Liquor Potassæ.—Mr. Dixon speaks very highly of the benefit to be derived from the local application of *liq. potassæ* to the granulations. He says: "The fluid is dabbed upon the everted lids, so as to be thoroughly brought into contact with the whole surface." And further on he remarks: "It may be applied at intervals of a few days; and in some cases I have seen the granulations removed, and much of the original clearness of the cornea restored, in the course of six weeks."*

When there are severe inflammatory symptoms, as in acute granular ophthalmia, it is best to postpone the use of astringents until they have partially subsided. In such cases great relief is often derived from applying a slight compress and bandage (F. 3) over the closed lids, and only removing it for the purpose of bathing the eyes three or four times during the twenty-four hours with the *lotio belladonnæ* (F. 40), or the *lotio belladonnæ cum alumine* (F. 41). If, however, as sometimes happens, the compressing bandage should prove hot and uncomfortable, it should be given up, and in its place a fold of lint wet

* Dixon on Diseases of the Eye, third edition, p. 56.

with the *lotio belladonnæ cum alumine* should be suspended over the eye by a piece of broad tape tied round the forehead. As soon as the swelling and redness of the lids have sufficiently abated to allow of their being everted without much pain, a weak solution of the nitrate of silver should be painted once daily over the palpebral conjunctiva, and in the intervals between the applications the belladonna lotion may be continued. Even in cases of granular lids where there are no severe inflammatory symptoms, but where the photophobia and lachrymation are excessive, I have often found benefit from the use of the compressing bandage, as by it the eye is kept completely at rest, and the friction between the lids and the cornea is prevented.

Inoculation with purulent matter for the cure of severe granular lids is a most successful mode of treatment. It requires, however, great caution in the selection of cases fitted for this procedure, and also in the choice of the pus with which to inoculate the eyes. The whole, or certainly two-thirds, of the cornea should be so permeated with vessels as to render it semi-opaque, as the purulent ophthalmia established by the inoculation is very liable to induce sloughing in any portion of the cornea which is quite transparent. The pus should be chosen from the eye of an infant suffering from purulent ophthalmia. Its strength may be determined, firstly, by the colour, and secondly, by the severity and duration of the inflammation it has excited in the eye from which it is taken. The yellow pus is always more active than the whitish discharge seen in slight cases of purulent ophthalmia. The period of the disease at which the pus is taken influences materially the amount of inflammation and suppuration it is capable of setting up. Pus from the eye of an infant in the early and most acute stage of purulent ophthalmia will produce more serious effects than that taken from the same eye at a later period of the disease, after it has undergone some treatment and is on the decline. If one eye only is to be inoculated, the other should be protected from contagion by Buller's eye-shield, page 9. Great care and cleanliness will be required during the whole of the treatment to prevent the other eye from becoming infected.

To inoculate the eye, a single drop of pus should be taken with a small scoop or the end of the little finger from the eye of an infant with purulent ophthalmia, and placed on the conjunctiva of the lower lid. In from eight to twenty-four hours the first symptoms of puru-

lent ophthalmia will begin to show themselves, and will rapidly increase until the disease has reached its height. The activity of the inflammation usually lasts from eight to ten days, but the discharge will not completely abate for six or eight weeks. As soon as the discharge becomes profuse, the patient should be allowed to wash the eyes with cold water every hour, or even oftener if he desires it, and if there is much pain he may use iced water, and when lying down keep a fold of lint wetted with it over the eyelids. No astringent application should be given to check the discharge, but the disease must be allowed to run its course uninterrupted. The danger to be apprehended is sloughing, or ulceration of a portion of the cornea. During the progress of the inflammation it is often very difficult to decide whether the cornea is still entire, as from its red and swollen villous appearance it is difficult to even distinguish it from the surrounding vascular conjunctiva. The only test then, is to notice its curvature, and if this remains unchanged, and there is no depression in one part with a lump of swollen granulations in another, no anxiety need be felt. The patient should be allowed a liberal meat diet, with a fair amount of stimulants, during the whole period of treatment; if his appetite or strength fail, quinine or bark (F. 75, 79) should be prescribed; and if from pain his nights are disturbed, opiates may be given at bedtime. It should be remembered that, although inoculation will obliterate the granulations from the lids and the vessels from the cornea, yet it will not efface previously existing nebulosities. Some operation is often afterwards required to alter the shape of the pupil, so as to bring it opposite that portion of the cornea which is most transparent. The results of my experience of inoculation in severe cases of granular lids have been most brilliant. I have seen patients practically blind for years, and condemned to the workhouse, regain sufficient sight to resume their former occupations.

Instead of inoculation Dr. De Wecker, of Paris, speaks favourably of an infusion of Jequirity seeds, the produce of the *Abrus precatorius*, which induces a purulent ophthalmia which tends to obliterate the granulations. The infusion is prepared thus:—Macerate 3 parts of the powdered seeds in 500 parts of cold water for 24 hours, then add 500 parts of hot water, and filter immediately after the liquid cools. The infusion may be used as a lotion three times in one day, and be repeated on the

second and third days, if necessary ; or be painted on the everted lids.*

2. FOLLICULAR CONJUNCTIVITIS. — *Follicular granulations* are an irritative or inflammatory hypertrophy of the lymphoid follicles of the subconjunctival tissue, and especially of those towards the oculo-palpebral fold, and are usually most easily seen in the lower eyelid. On drawing down the lower lid groups of round and oval semi-translucent bodies may be seen, chiefly in the cul-de-sac formed by the conjunctiva as it passes on to the globe. In severe cases, however, and especially when due to toxic causes, as the irritation of atropine or eserine, &c., they occupy the whole mucous surfaces of the lids.

Unlike trachoma, these enlarged follicles do not induce cicatrization and contraction of the lid ; and further, whilst trachoma has its seat of election in the conjunctiva covering the tarsus of the upper lid, the enlarged follicles affect chiefly the oculo-palpebral fold of the lower lid.

Follicular conjunctivitis may be caused by living in a crowded, unhealthy atmosphere, or by any local irritant, such as dust or smoke, or by the frequent instillation of atropine or eserine into the eye ; and it is a frequent concomitant of uncorrected errors of refraction, and especially hypermetropia.

Treatment.—When follicular conjunctivitis is due to an irritant, remove the exciting cause. If it be atropine or eserine, omit them for a time. In cases where it is advisable to continue the use of some mydriatic, a weak solution of daturine will sometimes be better tolerated than atropine. As a local application, a weak solution of the chloride of zinc gr. $\frac{1}{2}$ to gr. 1 to the ounce of distilled water ; or a lead lotion (F. 52) may be ordered. If very obstinate, a weak solution of nitrate of silver (F. 22) may be tried ; but all powerful caustics, such as sulphate of copper or strong solutions of nitrate of silver, should be avoided.

3. PAPILLIFORM GRANULATIONS are the result of a purulent ophthalmia or of chronic conjunctivitis. They are simply the enlarged papillæ of the conjunctiva of both lids. The papillæ appear to be elongated, somewhat thickened, and many of them pedunculated. They are very vascular, and give to the mucous membrane of the lids a bright red appearance.

* Ophthal. Review, vol. ii. p. 19, 1883.

The absence of trachomatous growths and of follicular granulations well distinguish this affection from either of the two preceding. The bright red villous appearance of the conjunctiva is also very characteristic.

Treatment.—These cases are often tedious, but with care they get quite well. Mild astringent and antiseptic applications suit best. A weak solution of chloride of zinc (F. 25) or of nitrate of silver (F. 22) may be dropped twice a day into the lower eyelid, and the eyes may be washed frequently during the day with the boracic acid or resorcin lotion (F. 45, 46), or the lotion with alum and sulphate of zinc (F. 50) or the lotio plumbi (F. 52). If the case does not improve under these applications, the lids may be painted with the solution of nitrate of silver gr. 10 to distilled water ʒi, as described at page 18. Tonics of cinchona, quinine, or quinine and iron (F. 75, 79, 81) should also be ordered.

SYNDECTOMY—*Peritomy*.—This operation was first practised by Dr. Furnari, of Paris, in 1862.* It consists in excising a band of conjunctiva and subconjunctival tissue of about one-eighth of an inch in width from around the cornea and close up to its margin. It may be performed in the following manner:—The patient being placed under chloroform, and the lids widely separated with a spring speculum, a fold of conjunctiva is to be seized with a pair of finely-toothed forceps, and with a pair of blunt-pointed curved scissors an incision is to be carried through that membrane around the cornea, at about one-eighth of an inch distant from it. The band of conjunctiva surrounding the cornea is now to be dissected off, and all the subconjunctival tissue and vessels between it and the sclerotic carefully removed close up to the corneal margin. The operation being now completed, the lids are to be closed and covered with a wet compress and a bandage.

After three or four days the wound will be found covered with lymph, and in a few weeks it will be perfectly closed, partly from contraction of the surrounding conjunctiva, but partly also by the formation of a smooth cicatrix tissue. This operation is well suited for severe cases of pannus which continue after the granulations of the lids have been obliterated; but my experience of it for the cure of granulations is that it is unsuccessful. I have on several occasions performed syndectomy as a pre-

* Gazette Médicale, Nos. 4-6, 8, &c., 1862.

liminary to inoculation, and allowed the eye to recover from all effects of the operation before introducing the pus. The virulence of the purulent ophthalmia seemed to have been materially diminished by the removal of the portion of conjunctiva, and by the broad cicatrix which it had produced around the cornea. For a detailed account of these cases, see "Royal London Ophthalmic Hospital Reports," vol. iv. p. 182.

XEROPHTHALMIA—*Xerosis*—*Cuticular Conjunctiva*—is an excessive dryness of the cornea and of the conjunctiva covering the globe and lining the lids. In a case of confirmed xerosis there is usually some symblepharon or partial union of the lids to the globe, or else there are membranous frena passing between the lids and the globe; the eyelids are contracted and will not close over the eye, and the tarsal edges of the lids are more or less inverted with some of the lashes brushing against the eye. The conjunctiva of the globe has a dusky, dry, cicatricial aspect, and the cornea is dull and cuticular. The dry and contracted conjunctiva passes abruptly from the inner surfaces of the lids on to the globe, so that the sulci which ought to exist between the lids and globe are destroyed. The puncta are usually closed and sometimes obliterated. The eye is almost useless to the patient and a source of much trouble from recurrences of inflammation.

Causes.—The most frequent cause is prolonged conjunctivitis, with a muco-purulent discharge from granular lids, probably also assisted by the application of too strong caustics to the lids, or the long-continued use of powerful astringents. The palpebral conjunctiva gradually becomes thickened and contracted, and the lids inverted, so that some of the cilia brush against the eye. With the contraction and thickening of the palpebral conjunctiva the lids lose their normal softness and cease to close completely over the eye. The constant irritation of the lashes, and the exposure due to the imperfect closure of the lids, lead to the formation of cuticular conjunctiva. Any cause which prevents the proper closing of the lids over the eye may induce xerosis, and consequently we occasionally meet with this affection after injuries of the conjunctiva of the lids from escharotics, lime, and strong acids.

Treatment.—There is no application to the eye which

will really benefit it. Milk has been recommended, and a lotion of glycerine (F. 55) will sometimes afford temporary benefit. The only way to obtain complete relief is to keep the lids closed and thus prevent the drying of the conjunctiva. This can only be accomplished in extreme xerosis by completely uniting the tarsal edges, but in less severe cases it will be sufficient to join the margins of the lids together at two points so as to leave a central chink through which the patient can see.

In a lad, æt. eleven, with extreme xerosis, I closed the eyelids of one eye by uniting their tarsal edges, and left them closed for eleven months. I then divided the line of adhesion and reopened the lids, and I found that the cornea had become more clear, the conjunctiva moist, and the sight greatly improved.* Unfortunately the lids could not close over the eye, and the xerosis soon recurred. Mr. Buller has advanced a step further, and after having closed the lids by uniting their margins, he trephined a hole with the trephine (Fig. 8, page 60) through about the centre of the line of junction between the lids, and succeeded in making a window through which the patient had considerably improved sight.†

PEMPHIGUS CONJUNCTIVÆ is a severe but fortunately a very rare affection. The bullæ appear on the conjunctiva of the lids and eye, whilst the pemphigus blisters are coming and going on other parts of the body. The formation of the bullæ is accompanied by swelling of the lids, chemosis of the conjunctiva and a muco-purulent discharge. The bullæ seem to affect both the ocular and palpebral conjunctiva. With the breaking of the bullæ raw surfaces are left which afterwards unite at opposed points and form adhesions which bind the lids to the globe, and sometimes also the margins of the lids to each other. If the surface of the cornea has been involved in one of the bullæ, it loses much of its transparency, assumes a fibrous aspect, and probably becomes united by bands of adhesions to the inner surfaces of the lids. When pemphigus has once attacked the conjunctiva, the bullæ may reappear from time to time until the destruc-

* The history of this patient is related as Case I. in Mr. Buller's paper on Xerophthalmia, Royal London Ophthalmic Hospital Reports, vol. viii. p. 421.

† Ibid. p. 424.

tion of the eye is complete. I have seen the disease limited to one eye, but both may be affected by it.*

Treatment.—The applications to the eye should be slightly astringent and sedative. The *lotio aluminis cum atropiâ* may be used frequently; or if the cornea be not affected the *guttæ zinci chloridi* may be dropped into the eye night and morning, and during the day the eye may be bathed with the *lotio belladonnæ*. The astringents should be omitted if they create irritation. The edges of the lids should be anointed with a little vaseline every night, and a piece of vaseline the size of a hemp-seed may be introduced between the lids twice daily, with the view of keeping an unctuous material between the opposed pemphigus wounds, and thus preventing their union during the period of cicatrization.

The constitutional treatment should be tonics of quinine (F. 79), or cinchona (F. 75). If there is much pain, sleep should be produced by opiates at night.

PTERYGIUM is a peculiar morbid growth of the conjunctiva and subconjunctival tissue. It is of a triangular shape, with its base usually at the semilunar fold close to the inner canthus, and extending outwards it gradually tapers to a rounded end which is implanted on the surface of the cornea, generally reaching to a point opposite the inner margin of the pupil, and sometimes spreading half-way across it. I have never seen the pupil completely occluded by the growth. A pterygium is more or less vascular, and one or two large conjunctival vessels may be frequently seen coursing along it. In some cases it is red, fleshy, and prominent, whilst in others it is pale and membranous, and so thin as to be almost translucent.

A pterygium is almost invariably a single growth confined to the inner half of the eye, although to this there are occasional exceptions, and cases have been reported where there have been two pterygia, one on each side of the cornea, and also where they have occurred in the upper and lower parts of the eye, in lines corresponding with the superior and inferior recti muscles. The disease may be limited to one eye, or both may be affected by it. I have seen many cases in which a pterygium existed in both eyes; in all of them the growths were symmetrical.

* In a case related in a pamphlet by Dr. James Campbell, St. Louis, Mo., both eyes were destroyed by this disease.

Patients about the middle age are most liable to pterygium, and especially those who have served long in tropical climates. It is seldom seen in the young. The disease is of slow and almost imperceptible growth, and it is not until it has attained a considerable size that it causes any annoyance. When it extends partially over the pupil it interferes with vision.

Treatment.—There are only two ways of efficiently dealing with a pterygium. It may be excised, or its apex may be transplanted from the cornea to a part of the conjunctiva, where even if it were to grow it would cause no impairment of vision. No local application to the eye will be of any benefit in eradicating the disease.

1. Excision of the Pterygium.—The lids being separated by a spring speculum, the pterygium is to be seized from above downwards by a pair of forceps and drawn slightly from the eye. With a pair of fine scissors or a Beer's knife its attachment to the cornea is to be separated, and then with a few snips of the scissors the greater part of the pterygium, or the whole of it, if it be small, is removed.

If the base of the growth be large no attempt should be made to excise the whole of it, as the too free removal of the conjunctiva will cause a tight cicatrix, which will greatly impair the outward movements of the eye. After the pterygium has been removed, the cut edges of the conjunctiva should, if the gap is not too wide, be drawn together with one or two fine sutures.

2. Transplantation of the Pterygium.—This operation was first suggested and practised by Desmarres. I have tried it myself on many occasions, and much prefer this operation to excision of the growth. The operation may be performed as follows:—The lids having been separated by the spring speculum, the extremity of the pterygium is to be seized with a pair of forceps close to the cornea, and its union with that structure carefully parted by a few snips with a pair of fine scissors. One cut is then to be made with the scissors through the conjunctiva along the upper, and another along the lower border of the pterygium. At the point of the lower free cut edge of the conjunctiva, to which it is desired to plant the apex of the growth, a small nick is to be made with the scissors, and into this the cone of the pterygium is to be fixed by a single fine thread suture.

The pterygium, now separated completely from the

cornea and implanted into the conjunctiva, generally wastes, and becomes so shrunken that it ceases to draw attention to the eye. Such has been the result in the cases in which I have performed this operation. The great advantage which transplantation offers over excision of the pterygium is, that as there is no removal of a portion of the conjunctiva, there is afterwards no dense cicatrix to cause a drawing in of the eye, or to limit its movements outwards.

PINGUECULA is a term applied to a small yellowish patch which is frequently seen on the eye near the margin of the cornea, and is apparently in the substance of the conjunctiva. In a specimen examined by Desmarres the growth was found to be composed exclusively of hypertrophied conjunctival epithelium. It creates annoyance sometimes from its being a little conspicuous, but it is perfectly innocuous. If its presence worries the patient, it may be removed by seizing hold of it with forceps, and snipping it off with a pair of fine scissors.

DERMOID TUMOURS generally spring from the margin of the cornea and the adjacent sclerotic. They are usually smooth light-coloured growths, covered with conjunctiva and with a few hairs sprouting from their surface. They are congenital, and consist of elastic and connective tissue and fat.

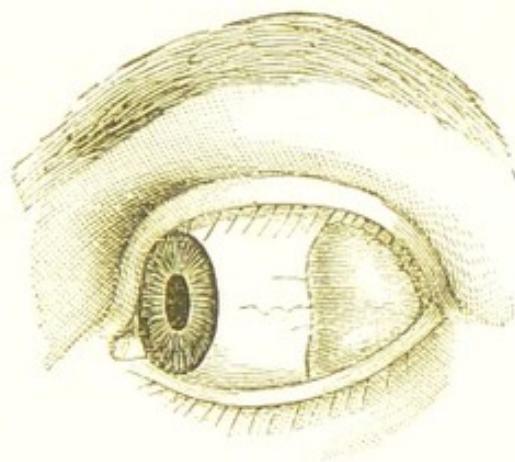
Treatment.—The only way to get rid of these tumours is by excision. Whilst operating care must be taken not to dissect deeply into the sclerotic and cornea, even though the origin of the tumour should apparently be below their surfaces.

FIBRO-FATTY TUMOURS OF THE CONJUNCTIVA.—The tumour to which I now refer is seen in the outer portion of the eye, and appears as a solid fatty-looking vertical fold, extending outwards from the conjunctiva beyond the cornea to the external canthus. When the eye is everted the tumour is little noticed, it seems to sink back into the fat of the orbit; but if the eye be inverted, the thick whitened fold of conjunctiva at once becomes manifest.

Treatment.—Unless the deformity be very great, it is wise to leave the tumour alone. It usually causes no inconvenience. If an endeavour be made to remove the

tumour, it will be found to be so intimately connected with the conjunctiva covering it, that it will be difficult, if not impossible, to isolate it. The evils which I have

FIG. 2.



seen follow an attempt to remove the growth are a marked unsightly cicatrix and a limitation of the inward movement of the eye.

CYSTS OF THE CONJUNCTIVA are generally the simple serous cysts. They usually appear as small round or oval translucent bodies, and occasion inconvenience only by their size or their position. Their most frequent site is in the fold of conjunctiva which is reflected from the lower lid on to the globe. They are easily removed by first seizing them with a pair of finely-toothed forceps, and then with a pair of scissors snipping through the portion of conjunctiva which holds them.

WARTS OF THE CONJUNCTIVA usually grow from near the tarsal margins of the lids, but they may spring from other portions of the conjunctiva, and even cover a large portion of the globe. They may either be pedunculated or sessile.

The proper *treatment* is excision.

INJURIES OF THE CONJUNCTIVA.

ECCHYMOSIS OF THE CONJUNCTIVA—*Subconjunctival Hæmorrhage*—may be caused by a blow on the eye, by coughing, or by any violent exertion. The effused blood at first appears as a bright red mark abruptly

limited to a portion of the conjunctiva, but during the process of absorption the colour loses its intensity, and passes through a variety of shades which diffuse themselves over the front of the eye.

Treatment.—A few days' rest is generally all that is required. Cold applications are grateful, and may be used either by allowing the patient to sponge his eyes three or four times a day with cold water, or by prescribing for him some cool evaporating lotion (F. 51, 52).

LACERATIONS OF THE CONJUNCTIVA covering the eye, but without any other injury to the eye or eyelids, are generally occasioned either by the patient striking his eye against some sharp projecting object which catches the conjunctiva and tears it as the head is moved away; or else by some second person running a shutter, or a pole, or whatever he may be carrying, against the eye. The injury is usually followed by swelling of the lids and conjunctiva, often sufficient to render it difficult to make a thorough examination of the eye a few hours after the accident.

Treatment.—The eye should be closed, some water dressing should then be laid over the lids, and fastened in its place by one turn of a roller. It is very rarely necessary to apply any sutures to keep in situ the torn edges of the conjunctiva, as they usually fall together of their own accord; and there is seldom afterwards any sufficient strain to draw them apart, or to prevent union. An exceptional case might occur in which sutures would be called for: thus, if a flap of the conjunctiva was torn from the globe, so that it was reflected back on itself, one or two fine stitches would be required to hold it, after it had been restored to its proper position. When all the swelling of the lids and conjunctiva has completely subsided, if there is some muco-purulent discharge, two or three drops of a lotion of sulphate of zinc (F. 26) may be dropped into the eye twice a day.

For diseases and injuries of the conjunctiva of the eyelids, see Section DISEASES OF EYELIDS.

CHAPTER II.

DISEASES OF THE CORNEA AND SCLEROTIC.

CORNEITIS—*Keratitis*—*Inflammation of the Cornea*— is a disease of impaired nutrition most frequently seen in children and young people. It is met with in the pale and half-starved, as well as in the over-fat and improperly-fed child; or it may be caused from some constitutional taint, such as struma or inherited syphilis. The two latter, however, present peculiarities which distinguish them from the simple form of corneitis we are now considering. True or simple corneitis is a disease which extends itself over an uncertain period of time, runs a definite course, and with a strong tendency to get well if not thwarted by the injudicious use of drops and nostrums, suggested by the zeal of the surgeon or the restlessness of the patient. Corneitis may be confined to the one eye, but both are generally affected. It usually commences in one eye and steadily progresses until it has reached a certain stage, when the second eye becomes attacked, and passes through exactly the same series of symptoms. Both eyes are now affected, but the one in which the disease began is in advance of the other, and is the one first to recover. The interval which elapses before the second eye is involved is very variable, in some cases it may only be a few weeks, in others as long as three or four months. The progress of the disease towards recovery is very slow; it may vary, according to the acuteness of the attack, from six months to one and a half or two years, dating from the commencement of the attack in the first eye to the ultimate recovery of that in the second. With the knowledge of these facts, the prognosis of the surgeon ought to be guarded.

Symptoms.—The disease usually commences with a pinkish redness of the ciliary region, shading off and becoming lost in the general whiteness of the eye. This redness will occasionally be at first confined to one or more vascular patches around the margin of the cornea, or there may be present from the very beginning a distinct pinkish tinge of the whole ciliary zone. The eye is irritable and shirks the light. The cornea now begins to look hazy and the sight is dimmed. As the corneitis advances, the haziness of the cornea, the vascularity of the

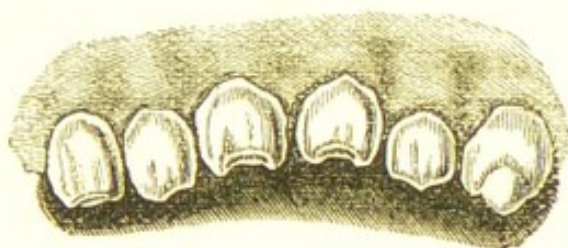
eye, and the intolerance of light increase. The brilliancy of the cornea becomes so dulled that it looks like a window-pane which has been breathed on, or like a piece of ground-glass. One part of the cornea is frequently more deeply affected than another, and a patchy appearance is thus given to the cloudiness. There is generally considerable lachrymation, and oftentimes a good deal of pain in and around the eye, with a sense of grittiness of the lids. The disease having reached its height, the process of repair sets in. The vessels around the margin of the cornea shoot into the substance of the corneal tissue and give to the part of that structure which they invade a red velvety appearance. In very severe cases this condition of pannus will extend over the greater part of the cornea. It is quite distinct in appearance from the vascular cornea, which is induced by the friction of granular lids. Gradually this excessive vascularity subsides, and as the blood-vessels disappear from sight, patches of cornea again become transparent, until at length the reparative process is completed. Such is the course of a simple uncomplicated case of corneitis, which having run through the various stages of the disease has terminated favourably. The disease, however, may not progress so satisfactorily, and ulcers may form either at the margin, or central portion of the cornea, which will considerably retard recovery. (See *ULCERS OF THE CORNEA*, p. 43.)

Results of Corneitis.—The eye may completely recover, the cornea regain its transparency, and the sight be restored. Generally, however, even in favourable cases, the acuteness of vision is diminished, either by a haziness so diffused and slight as not to be noticed by an ordinary observer, or else by a faint nebula which slightly invades the region of the cornea opposite the pupil. When the corneitis has induced ulceration or sloughing of the corneal tissue, there will always remain a more or less dense nebula or leucoma.

CHRONIC INTERSTITIAL CORNEITIS, or inflammation of the cornea dependent on hereditary syphilis, was first accurately described by Mr. Jonathan Hutchinson in his work on Syphilitic Diseases of the Eye and Ear, published in 1863. Patients suffering from this affection usually present marked signs of constitutional syphilis, or evidence can be obtained from the parents of their having had during infancy some specific symptoms.

Mr. Hutchinson states that in almost all cases the subjects of this disease "present a *very peculiar physiognomy*, of which a coarse flabby skin, pits and scars on the face and forehead, cicatrices of old fissures at the angles of the mouth, a sunken bridge to the nose, and a set of permanent teeth peculiar for their smallness, bad colour, and the *vertically notched edges of the central upper incisors*, are the most striking characters"* (Fig. 3). He also

FIG. 3.



(After Hutchinson.)

notices the fact that this disease is frequently accompanied or preceded by iritis, and followed by such changes in the choroid as are often seen in heredito-syphilitic patients.

Symptoms.—The disease usually commences in one eye with a diffuse haziness near the central part of the cornea, which when carefully examined is found to consist of dots of opacity in the substance of the corneal tissue. These interstitial deposits increase in number and size, whilst some of them coalesce with others, gradually rendering the whole cornea opaque, with the exception of a circumferential band which commonly retains more or less of its transparency. The cornea loses its brilliancy, and ultimately assumes a dull ground-glass appearance, but the cloudiness is seldom uniform, patches of it being of deeper density than the rest. There is intolerance of light, varying in intensity, but generally not very severe; there is supra-orbital pain and redness of the ciliary zone of vessels around the cornea. After a time the opacity of the cornea begins to clear, and gradually its transparency and polish are either partially or entirely restored. It is, however, very rare that the recovery is complete; patches of nebulosity remain which impair vision in accordance with their situation and density. The second

* Syphilitic Diseases of the Eye and Ear, p. 30.

eye usually becomes affected from one to three months after the first one, and runs through a similar course.

In this disease ulcers of the cornea seldom occur. The duration of an attack of chronic interstitial corneitis, from its commencement in one eye to its termination in the other, is generally from twelve to eighteen months. The time will, however, necessarily vary with the extent and severity of the disease.

STRUMOUS CORNEITIS resembles in its general characters the simple corneitis already described. The patients are usually children or young persons, who exhibit all the characteristics of struma. There is great photophobia and lachrymation; and a peculiar tendency to ulceration, which may take place at one or more points on the surface of the cornea. The disease is very tedious, and generally both eyes are affected, but like most forms of corneitis one eye is attacked some weeks in advance of the other.

GENERAL TREATMENT OF CORNEITIS.—As this affection naturally extends over a long space of time, it is well to remember that the effects of remedies are slow, and that judicious treatment consists rather in guiding the disease to a favourable termination than in the endeavour to cut it short by the use of powerful agents, which generally exert a prejudicial influence.

Constitutional Treatment.—At the commencement of the attack the bowels should be cleared out by a purgative (F. 153, 154, 158), and if the attack is acute and the dread of light is severe, a saline mixture (F. 135), or one containing small doses of tartarated antimony (F. 136), may be prescribed; but these must in a few days give way to tonics of the mineral acids with cinchona (F. 138), or to some of the preparations of iron, quinine, or both combined. During the continuance of the attack the state of the health should be carefully attended to, and medicines should be prescribed or omitted as the case may seem to demand. Where there is great intolerance of light and lachrymation, or where the patient is restless and sleeps badly at night, opiates are of great service, taking care that during their administration the bowels act regularly. Small doses of tinct. opii, or tinct. belladonnæ (F. 140) may be given with the bark mixture every four hours during the day; or a larger dose of the opiate

may be ordered every night. In children of two or three years of age, a powder of pulv. ipecac. comp. cum potass. nitrat. (F. 150) at bedtime is often very useful in allaying the excessive irritability and restlessness which are so frequently seen in corneitis.

In all cases of inflammation of the cornea, or indeed of any of the tissues of the eye in which there is a dread of light, the eyes ought to be protected from painful exposure to glare. In the house this is best effected by drawing down the blinds, or partially closing the shutters, and by shading both eyes with a broad light shade; but out of doors dark-coloured glasses should be used. The neutral-tint glasses are far more efficient in affording relief from glare than those of a cobalt-blue colour—they may be obtained of any shade. In making a selection, those neutral tints should be chosen which do not contain much yellow. The cobalt-blue glasses, from being less unsightly, are generally preferred by the patient, and in the slight cases of photophobia answer their purpose exceedingly well. The best form of spectacles are those with large curved glasses; they sufficiently protect the eye from light and wind, whilst they do not make it hot.

The popular system of tying up the eye with a handkerchief to exclude it from light is essentially wrong, and should not be allowed.

In the **chronic interstitial Corneitis**, Mr. Hutchinson recommends "the cautious use of mercurials and iodides, at the same time supporting the system by tonics and a liberal diet." He advises a little of the mild mercurial ointment to be rubbed in behind the ear, or beneath the axilla every night, but a *strict watch* should be kept to prevent the patient from becoming salivated. Internally, the syrup of the iodide of iron (F. 142), or the mist. potassii iodidi cum ferro (F. 143) may be ordered; but should these medicines disagree, or the patient be very feeble, tonics of iron, quinine, or bark may be substituted.

In **strumous children**, cod-liver oil and the syrup of the iodide of iron in small doses do much good. Where there is a tendency to rickets, the phosphates and hypophosphites of iron and lime, either singly or combined (F. 145, 146), are often of service. But the greatest benefit will be derived from bracing country or seaside air, strict cleanliness, and a well-regulated nutritious diet, in which pure milk and new-laid eggs form a part.

Local Applications.—In corneitis, sedatives to the eye give great relief, and of these belladonna is the most efficacious. When there is great irritability a warm fomentation of belladonna (F. 9) may be applied to the closed lids by means of a cupped sponge; or, if cold is more agreeable to the patient, the eye may be frequently splashed with cold water, or a fold of lint wet with the belladonna lotion (F. 40) may be tied over the lids, and moistened as often as it becomes dry. A few drops of a solution of atropiæ sulph. gr. 2 ad aquæ $\bar{3}$ l may be dropped two or three times a day into the eye when the dread of light is very severe. Thus frequently applied, it acts as a direct sedative to the ciliary nerves, and also paralyses the accommodative power, and places the eye in a state of rest. It is, however, very difficult to use atropine drops in young children, as the struggling which ensues whenever the attempt is made to put them into the eye often does more harm than the remedy is likely to do good. In such cases the compound belladonna ointment (F. 124) rubbed in over the brow night and morning, or the belladonna liniment smeared over the brow, will probably act beneficially. Stimulating applications to the eye almost invariably do harm; they are very painful and increase the irritation.

Counter-irritation is often of great benefit. The brow and integument of the upper eyelid may be painted with the tinct. iodi, taking care not to paint it too thickly on the upper lid. A stick of nitrate of silver moistened with water, drawn twice or three times across the skin of the upper lid, is a good counter-irritant, and sometimes does much good in relieving excessive photophobia; it must be applied *very cautiously*, as when it is laid on too thickly it will blister, or even produce a slough of the skin, and in addition it is very painful. If the application of the iodine or the nitrate of silver affords relief, it may be repeated at intervals of a few days or a week.

DIFFUSE SUPPURATIVE CORNEITIS is generally the result of an injury such as a contused or lacerated wound of the cornea, but it may also come on from constitutional causes. It may follow any operation on the eye in which the cornea is involved; and it is one of the most fatal terminations of the operations for cataract. The state of health of the patient at the time of the injury determines very much the form of the inflammation

which may arise from it. A simple incised wound or an abrasion of the cornea, from which a strong healthy person would probably recover without an untoward symptom in a few days, may be sufficient to induce in an unhealthy patient a diffuse suppurative corneitis which will destroy the eye.

Symptoms.—The cornea grows dull and steamy; pus is effused between its lamellæ, at first only in a small quantity at one spot, but it soon increases and diffuses itself throughout the corneal structure. In severe cases I have seen the whole tissue of the cornea pervaded with pus, but in the slighter ones it is generally confined to one part.

The eye is hot and painful; there is great congestion of the conjunctival and sclerotic vessels; dread of light, and lachrymation. The deeper parts of the eye participate in the inflammation, the iris loses its mobility, the aqueous becomes serous, and pus is effused into the anterior chamber (hypopion).

The pus between the layers of the cornea now makes an exit for itself, and this it does by progressive ulceration either anteriorly towards the surface, or posteriorly into the anterior chamber. In the majority of cases the corneal abscess bursts anteriorly, and a sloughing-looking ulcer is left.

Results of Suppurative Corneitis.—If the whole cornea has been involved in a diffuse suppurative inflammation, and pus has been effused throughout the whole or greater part of the corneal tissue, complete loss of the eye must follow. If, however, the abscess of the cornea has been limited in extent the eye may recover, but a leucoma will remain, which will impair the sight in proportion to its size, density, and position with respect to the pupil.

It will be well to explain here the meanings of the terms hypopion, onyx, and abscess of the cornea, as considerable confusion prevails amongst students as to their right application.

Hypopion is an effusion of pus into the anterior chamber.

Onyx is often indefinitely used to signify a collection of pus between the lamellæ of the cornea; but it is only applicable to those small effusions at the lower part of the cornea, from the fancied resemblance of which to the posterior end of the finger-nail it has derived its name.

Abscess of the cornea and onyx are by many

regarded as synonymous terms; but as the word "onyx" indicates the appearance and locality of the disease rather than the disease itself, the term "abscess" should be considered as applicable to those larger effusions of pus between the corneal lamellæ into which onyx occasionally passes; or to the diffused purulent infiltrations which are the result of diffuse suppurative corneitis.

Treatment.—Warm fomentations of belladonna (F. 9) or of poppy-heads to the eye; and in the intervals between using the fomentations, a fold of linen wet with the belladonna lotion (F. 40) may be laid over the closed lids. In many cases, and especially in those where there is a tendency to tension, I have found much benefit follow the use of the guttæ eserici (F. 18) twice a day, and the frequent application of warm fomentations of poppy-heads. When there is pus between the corneal lamellæ and with a tendency for the pus to extend, Sämesch's operation (p. 39) will be of the greatest service.

In cases of onyx and hypopion, *when there is an increased tension of the globe*, Sämesch's operation, or iridectomy, should be performed. It is oftentimes the only mode of treatment which affords a chance of recovery. Paracentesis of the cornea will also be of service when there is increased tension, but its effects are not so permanent or beneficial. The paracentesis may be repeated at intervals of one or two days if it gives relief.

Constitutional Treatment.—The patient should be supported with a liberal diet and a fair allowance of wine or beer. Diffusible stimulants (F. 67) and tonics (F. 77, 79) are the most suitable medicines; and if there is much pain or inability to sleep, opiates should be given either in small doses during the day, or in one full dose at bedtime. Attention should be paid to the regular and healthy action of the bowels, and, if necessary, some mild purgative or alterative be prescribed.

Paracentesis of the Cornea may be performed as follows:—A broad needle is made to puncture the cornea towards its lower margin, the point being kept well forwards towards the cornea to avoid wounding the lens, when by suddenly turning the flat of the blade on to its edge so as to render patulous the opening it has made, the aqueous is allowed to run off. As soon as the iris closely approaches the cornea, which it will do when the aqueous has nearly escaped, the blade of the needle should

be again turned on the flat, and quickly withdrawn from the eye.

Sämesch's operation consists in making an incision with a fine Graefe's knife through the centre of the ulcer of the cornea, or the spot which is infiltrated with pus, and sufficiently deep to open the anterior chamber throughout the length of the cut. The incision should include a minute portion of healthy cornea on each side of the ulcer. The lids should be then closed with a compress and bandage, and gutt. eseriæ (F. 18) dropped twice daily into the eye. In the after-treatment the eye should be examined daily, and the incision kept open either by gently passing a fine probe or the point of a Graefe's knife between its edges, or by pressing the upper or lower eyelid upon one of the margins of the wound, so as to cause it to gape. This treatment should be continued until healthy reparative action commences.

MARGINAL CORNEITIS.—This name is well applied to a low form of inflammation which commences at the extreme border of the cornea, and creeps on slowly, slightly invading the corneal tissue for a short distance, but seldom if ever involving the whole of its structure.

Symptoms.—It commences with slight dread of light, lachrymation, and grittiness of the eye, which increase in intensity as the disease advances. On examining the eye there will be found at one spot close upon the cornea a vascular patch, and the corneal edge which corresponds to it looks swollen and softened. This condition may involve a third or even more of the margin of the cornea, but it seldom includes the whole of its circumference. In a few days a small diffused haze will be noticed near the margin of the cornea, and this will gradually extend, sometimes so as to include the part which is opposite the pupil, but it rarely invades the whole cornea. Occasionally this form of corneitis is accompanied with one or more small marginal herpetic ulcers, so as to closely resemble the phlyctenular ophthalmia. The disease is tedious; it may be acute at the onset, but in its duration and recovery it is generally chronic. It is also very recurrent. The patients who are most liable to marginal corneitis are those who are in a low state of health. It is consequently met with amongst the anxious and overworked, and in mothers who are enfeebled from over-lactation; and it

may be brought on by an exhausting disease, such as leucorrhœa or menorrhagia.

Treatment.—The eye should be shaded from strong lights, and rested as far as practicable by the avoidance of reading, writing, and all kinds of close work. If there is much dread of light, gutt. atropiæ (F. 15) may be used once or twice daily; or the eye may be bathed frequently with a lotion of atropine (F. 39), or of belladonna (F. 40). If the marginal corneitis is apparently dependent on overwork, or close confinement to business, change of air and recreation are the most powerful curative agents. The medicines which do the most good are tonics of bark or iron, combined with the mineral acids, or with small doses of liq. strychniæ, or tinct. nucis vomicæ (F. 73, 74, 75, 84, 86).

PHLYCTENULAR OPHTHALMIA — *Scrofulous Ophthalmia*—is most frequent in young children from two years old and upwards, but it is seldom seen in patients after the age of puberty. It is characterised by intense intolerance of light; the photophobia is greater in this than in any other disease of the eye. In severe cases the child is commonly seen with the lids tightly closed, and with a fist over each eye, or with his face buried in the dress of the nurse who is carrying him. Any attempt to look at the eyes is met by violent spasmodic contraction of the lids, and if after severe struggles the lids are parted, the globe is found to be so turned upwards that it is impossible even to see the cornea. The exposure of the eye to the slightest light often brings on a fit of rapid sneezing. In such cases when it is desired to see the eye, the child should be given a few sniffs of chloroform, sufficient to dull his sensibility, without putting him completely under its influence. An examination can then be made without any struggling; but in addition to this the chloroform often exerts by its sedative influence a very beneficial effect on the eye, and the child awakes from his sleep with a decided diminution of the photophobia. It will be often found that the severity of the symptoms is quite out of proportion to the apparent disease; frequently there is but little to be seen except one or more small phlyctenulæ close upon the margin of the cornea. These phlyctenulæ are, however, of an herpetic nature, and run a course somewhat similar to an herpetic eruption on other parts of the body. At first

they appear as small vesicles, the contents of which soon become turbid; the vesicles then burst and form small superficial ulcers, which eventually heal without leaving any visible scars to show where they have been. The whole eye in some cases is much bloodshot, whilst in other instances when the lids are first opened the conjunctiva is found to be scarcely tinged, but it soon flushes up on exposure to the light. Occasionally a leash of red vessels may be seen running up to one or two of the phlyctenulæ.

Scrofulous ophthalmia is more frequent amongst the poor than the rich; the strumous child is the most liable to it, but the impure air of dirty confined lodgings, combined with an insufficiency of sunlight, improper diet, and want of care, will induce the disease in children who, under more favourable circumstances, would not suffer from it. This form of ophthalmia is frequently associated with eczema, impetigo, sores about the nose and lips, and with enlarged cervical glands, indeed with all those kindred complaints which are so frequently met with amongst the poor scrofulous children in a London hospital. Scrofulous ophthalmia is tedious in its progress, and very recurrent.

Treatment.—During the early and acute stage of the disease, when the photophobia is very intense, the vinum antimoniale in doses of from min. 10 to min. 20 every four hours often exercises an almost specific effect in relieving the dread of light. If, however, it fails to do decided good in three or four days, it should be discontinued. Sedatives will sometimes prove of great service, and small doses of tinct. hyoscyami, succus conii, tinct. belladonnæ, tinct. opii, or sol. morphiæ muriat., may be given singly at short intervals during the day; or they may be combined with bark, or with the mineral acids, or with any other medicine which the state of the patient may suggest. Where there is much debility with languor, and restlessness at night, mist. cinchonæ (F. 138, 139) may be prescribed during the day, and pulv. ipecac. comp. cum potass. nitrate (F. 150) in doses of gr. 3 or gr. 4, according to the age of the patient, at bedtime.

The preparations of iron are very valuable in scrofulous ophthalmia, but they should not be continued for too long, or be ordered with a hot skin and furred tongue. In decidedly scrofulous children, the syrup. ferri iodid. or the syrup. ferri hypophosphit. in doses min. 15 to min. 20, twice a day in water, are of much benefit. Where

there is simply anæmia, the ferrum redactum gr. $\frac{1}{2}$ to gr. 1, or the ferri carb. saccharat., in doses of from gr. 2 to gr. 5, are the best. Cod-liver oil may be often advantageously prescribed with the iron; it is especially serviceable where there are evidences of failing nutrition.

When there is much eczema of the eyelids, with discharge from the nose, and swelling of the lips, small doses of the liquor arsenicalis (F. 147) will frequently afford great relief when all other remedies have failed.

The regular and healthy action of the bowels should be strictly attended to, and purgatives ordered when necessary. If the child suffers from ascarides, means should be taken to rid him of them. This is best done by an injection of two or three ounces of infusion of quassia into the rectum; or, if this fails, an injection with a few minims of tinct. ferri perchlorid. to the ounce of water may be used. After the injection, a powder of cal. cum scammon. (F. 157, 158) should be given.

Local applications may be considered under two headings: *a.* Sedatives to the eye; *β.* Counter-irritants.

a. Sedatives to the Eye.—Of these the most useful is the sulphate of atropia, a solution of which gr. 1 ad aquæ $\overline{51}$ may be dropped into the eye three or four times daily. Unfortunately the use of this remedy is very often impracticable, from the resistance the child offers to every attempt to put the drops into the eye. When there is much struggling the drops ought to be discontinued. Much comfort is frequently obtained from bathing the eyes with the belladonna lotion (F. 40), and when the child is asleep applying a fold of linen wet with the lotion over the closed lids; or iced water may be used in a similar manner. The belladonna liniment of the British Pharmacopœia rubbed into the brow will occasionally afford ease; or the unguent. belladonnæ comp. (F. 124) may be applied over the brow and temple, and allowed to remain on during the day. When there is eczema of the lids, the best application is the lotio boracis, or the lotio boracis cum soda (F. 59, 61).

β. Counter-irritants.—1. A stick of nitrate of silver moistened with water may be drawn *once* or *twice* across the skin of the upper lid. It is a painful application, but it frequently gives marked relief. If applied too freely, it will blister, and may cause sloughing of the lids.

2. The tinct. iodi may be painted over the brow and upper eyelid, taking care that none of it runs between

the lids into the eye. Over the integument of the lid it must be painted lightly, as it soon blisters.

3. Small blisters, the size of a sixpence or a shilling, may be applied to the temple. If the emplastr. cantharidis be used, the blister should be removed at the expiration of four hours. For children, the best and least painful blister is Brown's cantharidine or blistering tissue.

CORNEO-IRITIS is an inflammation of the cornea and iris. The disease usually commences in the cornea and afterwards extends to the iris. It mostly occurs in patients enfeebled by disease or excessive work, and in those who have previously suffered from syphilis.

Symptoms.—Haziness of the cornea, ciliary redness, a sluggish and irregular pupil, pain in the eye and around the orbit, and frequently great photophobia and lachrymation.

Treatment.—The pupil should be kept dilated with the guttæ atropiæ (F. 15), dropped twice daily into the eye; or the lotio belladonnæ (F. 40) may be frequently used. If there be much pain in the eye and around the brow, a little of the unguent. hydrarg. cum belladonnâ (F. 126) or the unguent. hydrarg. cum atropiâ (F. 125) rubbed into the temple night and morning often affords relief. As the patient is generally in a low state of health, tonics of quinine and iron (F. 80, 81), or bark with the mineral acids (F. 75) should be prescribed. When, however, there is a distinct syphilitic history, the mist. potass. iodid. (F. 91), or the mist. potass. iodid. cum ferro (F. 92), should be given. It is seldom advisable to give mercury internally in these cases. The disease is one of low power, and all the benefit likely to be gained from mercury will be obtained by the mercurial inunction above mentioned into the temple.

ULCERS OF THE CORNEA.

ULCERS OF THE CORNEA may be caused by severe inflammation of the conjunctiva, or cornea, and may occur during the progress of the attack. They are thus frequently seen in purulent and gonorrhœal ophthalmia, and in corneitis, especially in the strumous and diffuse suppurative forms of the disease. There are, however, some special ulcers which seem to originate in

the cornea, and not to be secondary to active inflammation of either that structure, or of the conjunctiva. Ulcers of the cornea are always indicative of impaired health, and are consequently met with in the feeble, the overworked, the strumous, and the rheumatic patient. They are always accompanied with pain and grittiness of the eye, photophobia, and lachrymation. The cornea, except in the immediate vicinity of the ulcer, may retain its transparency, but the conjunctival surface of the globe is usually more or less reddened, and rapidly flushes on undue exposure of the eye to light. Ulcers of the cornea may be either acute or chronic, superficial or deep.

SUPERFICIAL ULCERS OF THE CORNEA are most frequently met with in young people, and especially in delicate children. The disease may be confined to one eye, or both may be affected, or they may be attacked alternately. There is considerable photophobia and lachrymation, with a sense of heat and grittiness in the eye. There are two forms of superficial ulcers of the cornea: *the nebulous* and *the transparent ulcer*.

The Superficial Nebulous Ulcer may occur at any part of the cornea, either towards its periphery or its centre. Carefully examined, it appears as a small, irregular, ill-defined, greyish-looking ulcer. The edges of the ulcer are frequently slightly raised and of a darker grey tinge than the central portion, which will be found occasionally almost transparent. The ulcer having been formed, it may remain almost stationary for a short time, and then begin to heal. This is the course which such superficial ulcers usually run; it is exceptional for them to penetrate deeply the corneal tissue and to lead to perforation and prolapse of the iris. As the ulcer advances towards recovery it first assumes a more opaque appearance, the central excavation then becomes filled in and its edges bevelled. Frequently one or more red vessels may be seen running to it from the margin of the cornea; these are vessels of repair, and ought when they have accomplished their duty to become so reduced and contracted as to cease to be visible, or to interfere with the normal transparency of the cornea. Gradually the opacity of the healing ulcer is reduced, and day by day the parts slowly become clearer, until at length complete or partial transparency is restored. These ulcers of the cornea are gene-

rally acute at their onset, but they will often drift into the chronic state.

Superficial Transparent Ulcers of the Cornea.—

The symptoms which accompany the formation and progress of these ulcers resemble those of the nebulous ulcer just described, and they occur amongst the same class of patients. There is the same photophobia and lachrymation, with redness of the eye on exposure to light, the only characteristic difference being the appearance of the ulcer. On gently raising the lids so as to examine the eye, the epithelium of the cornea seems as if it were abraded or scratched off at one or more points. The transparency and polish of the cornea at this stage of the disease is unimpaired, and each ulcer, if there be more than one, is seen as a glistening facet. The first indication of a healing action in these ulcers is shown by their losing their transparency and becoming grey and cloudy; the cloudiness often extending beyond the margin of the ulcer. Their clear outline is soon lost, their slight excavation filled in, and the even surface of the cornea is restored. If the ulcer has not penetrated below the epithelium, transparency is regained; but if it has extended into the true corneal structure, a nebula or semi-transparent leucoma will be afterwards left.

Treatment.—Soothing applications to the eye, which may be used either hot or cold, in accordance with the feelings of the patient. Fetus papaveris, lotio belladonnæ (F. 40); or if there be great irritability, the guttæ atropiæ (F. 15) dropped into the eye three or four times daily. All stimulating drops or lotions are injurious. In children, an alterative powder of hydrarg. cum cretâ cum rheo (F. 152, 153), given every second or third night, is very beneficial. If the skin be hot and the tongue furred, the mist. salin., or mist. antimonii tartarati (F. 135, 136), should be ordered; but as soon as the secretions have become healthy, bark, the mineral acids, preparations of iron, and cod-liver oil, are the most suitable remedies.

DEEP ULCERS OF THE CORNEA.—The superficial ulcers described in the preceding paragraphs may become deep, and so be rightly included under this heading; but this is not the course they usually pursue. There are, however, certain ulcers the tendency of which is to ex-

tensive destruction of corneal tissue, leading frequently to perforation and prolapse of the iris, and to these the term "deep" is fitly applied. They may be seen in patients of all ages, and, unless produced by injury, are usually dependent on some constitutional defect. Generally they proceed from want; but occasionally from excess.

SLOUGHING ULCERS OF THE CORNEA may be the result of a diffuse suppurative corneitis, induced either by injury or disease; the pus between the lamellæ of the cornea having worked its way to the surface by progressive ulceration. They may also occur amongst the half-starved and overworked, as well as the drunken and dissipated. They must be then regarded as evidences of failing nutrition and want of nervous power. A sloughing ulcer of the cornea usually presents an irregularly excavated surface, with a whitish-yellow sloughy appearance, and with its margins shelving and ill-defined. Around the ulcer the cornea is hazy. These ulcers often lead to complete destruction of the eye for all visual purposes; but even when they yield to treatment and the eye recovers, it is always more or less a damaged organ. Sometimes they will perforate the cornea, and prolapse of the iris will follow; or occasionally they will penetrate the true corneal tissue, but their further progress will be stopped by the posterior elastic lamina or Descemet's membrane. An aperture is then seen in the cornea, the bottom of which is closed by a transparent membrane (Descemet's), which projects slightly into the wound. In this condition I have seen the eye remain for many weeks; the corneal wound may then begin to granulate and heal, but generally the posterior elastic lamina in the end gives way, the iris prolapses, and cicatrization follows. During the healing process, the cornea in the immediate vicinity of the ulcer becomes more cloudy, red vessels are seen invading its substance and running towards the ulcer, and in some cases in such numbers as to present a perfect pannus; but these disappear from sight as soon as cicatrization is completed. The cornea in the locality of the ulcer may resume its transparency; but the new material which has replaced that lost by ulceration will be more or less opaque and leucomatous.

Treatment (see TREATMENT OF DIFFUSE SUPPURATIVE CORNEITIS).—There are, however, a few points to be specially noticed. All stimulating applications to the ulcer

as a rule do harm. The touching the ulcer with a stick of the diluted nitrate of silver, as recommended by some, is, I believe, in most cases positively prejudicial. When there is severe pain in the eye, paracentesis of the cornea will often afford much relief. In a sloughing ulcer of the cornea with increased intra-ocular tension, an iridectomy is of the greatest service. I have in my own practice seen the whole train of distressing symptoms immediately relieved by the operation; the ulcer has taken on a healing action, and the eye has rapidly recovered.

CRESCENTIC, or CHISELLED ULCERS OF THE CORNEA.—This is one of the worst and most intractable forms of ulceration to which the cornea can be subjected, but fortunately it is one of the most rare. I have called these ulcers "crescentic" from their shape, and "chiselled" from their peculiar characteristic appearance, as if a portion of the epithelium and true corneal tissue had been cut away with a chisel, or scooped out with the thumb-nail from the margin of the cornea. They always occur at the extreme edge of the cornea, but they are strictly confined to that structure, and do not in the slightest degree encroach upon the sclerotic. In their progress they follow exactly the curve of the rim of the cornea, by which they are abruptly limited; the circumferential edge of the ulcer being cut sharply and deeply. They spread rapidly and increase both in length and depth. There may be two or even three of these ulcers at different parts of the margin of the cornea, and, unless their progress be arrested, they may spread and unite, and so insulate the central portion. At the commencement of the disease the ulcers are perfectly transparent; it is during their healing stage that they grow nebulous. They frequently perforate the cornea, and cause extensive prolapse of the iris; or, as in the sloughing ulcers, the advance of the ulceration may be stopped by the posterior elastic lamina of the cornea; but this usually in the end gives way, and prolapse of the iris ensues. During the reparative process they become first cloudy, then of a greyish-white colour; vessels shoot into them from their sclerotic border, and they are ultimately filled in with a semi-opaque cicatricial tissue. These crescentic ulcers are the source of great pain in the eye and around the orbit, accompanied with photophobia and lachrymation on the slightest exposure to light. They do not seem to be connected in any way with any

constitutional taint, such as syphilis or struma. The patients whom I have seen affected by them have always been in that state of health which is best described as "being thoroughly out of condition."

Treatment.—These ulcers are so intractable, and so many means have been tried without success to check their progress, that it is difficult to say what is the wisest course to pursue. My own experience is, that in most cases it is best to leave the ulcers alone, and to apply either hot fomentations or cold lotions of belladonna (F. 9, 40) to the eye. In some cases I have seen rapid improvement follow the use of guttæ eserix (F. 18) twice a day, and closing the lids with a compress kept moist with a warm decoction of poppy-heads. All exposure to strong light should be strictly avoided, by obliging the patient to shade his eyes, and to keep the room in which he lives darkened. A liberal diet and tonics with diffusible stimuli should be ordered, and if there is pain or restlessness opiates should be given either in small doses at short intervals, or in one full dose at bedtime. In two cases I have seen a partial syndectomy performed by excising close up to the margin of the cornea a portion of the conjunctiva and subconjunctival tissue about $\frac{1}{8}$ inch in width, and in a line exactly corresponding with the ulcer, but in both it failed to do any good. Mr. Bowman, however, relates one case in his private practice in which he performed this operation with most marked success. The ulcer, which had before resisted all treatment, at once took on a healing action, and soon cicatrized.

Another mode of treatment is to touch the ulcers freely with the nitrate of silver so as to destroy their surfaces with this escharotic, on the same principle as a phagedænic sore is treated with nitric acid. A fine camel's-hair brush, moistened with water, should be drawn several times across a solid stick of nitrate of silver, and then applied to the whole surface of each ulcer, and this should be repeated every three or four days, until a healthy action is set up. At the same time opium should be given to the patient in doses of from gr. $\frac{1}{2}$ to gr. 1 every four or six hours according to the severity of the symptoms. I have seen this plan of treatment followed by great success.

I have treated successfully several cases in the following manner:—A lotion of carbolic acid min. 3 ad aquæ \mathfrak{z} l, to be used as a wash every two or three hours, and a

little to be allowed to go into the eye with each application; and in the intervals the eye to be closed with a compress of absorbent cotton wool, kept wet with the quinine lotion (F. 53); quinine and opium (F. 112) to be given every four or six hours, and the regular daily action of the bowels maintained by the mist. sennæ comp. when necessary. Each case of crescentic ulcer of the cornea must be treated on its own merits, and if one plan of treatment fails, another should at once be tried.

CHRONIC VASCULAR ULCER OF THE CORNEA.

—This name has been applied to what is generally rather a vascular nebula than an ulcer; it is the remains of an ulcer which has become filled in, but in which the vessels originally destined for its repair have, from some cause, become stationary, and by their presence keep the eye in a state of constant irritation.

Symptoms.—Continued irritability of the eye, with lachrymation and dread of light, varying in intensity but never entirely absent. The history is generally that of an ulcer of the cornea which had recovered up to a certain period, from which date the eye had ceased to mend, and had since been more or less irritable. On examination a small nebula will be seen on the cornea at a short distance from its margin, with one or more vessels, sometimes a regular bundle of them, running up to it from the sclerotic and adjoining the corneal edge. It frequently happens that the patient has been under treatment for many months, and sometimes even for two or three years, during which time he has persistently dropped drops into the eye, both stimulating and sedative in turn, but without gaining the slightest benefit from either.

Treatment.—Omit for a time all applications to the eye, and insert a double silk-thread seton into the skin of the temple. The seton should be placed so high on the side of the temple as to be almost amongst the short hairs, as there will then be no noticeable cicatrices from the ulcerations at the points of ingress and egress of the threads. Care also should be taken to avoid wounding the branch of the temporal artery, which is in this locality. The seton should be worn for about three or four weeks; but it may be continued longer if it acts beneficially on the eye, and does not excite too great an irritation. In conjunction with the seton, other remedies may be tried. The lids of the affected eye may be kept closed, and a

compress bandage (F. 3) applied over them, so as to give the eye for a time absolute rest; or if the patient should find the compress hot and uncomfortable, it may be given up, and a cool lotion (F. 45, 51), or iced water, or a cold douche may be used, with the lids closed, three or four times daily. The state of the patient's health should be carefully looked after, and any irregularity should be corrected. In order to give the treatment every possible chance of success, the patient should, if his circumstances will permit of it, abstain from all work with the sound eye, and enjoy for three or four weeks rest with recreation.

A FISTULA OF THE CORNEA is a small opening in the cornea which has little or no tendency to close, and through which the aqueous humour is constantly oozing.

Causes.—1st. A perforating ulcer of the cornea, which from some cause has been imperfectly healed.

2nd. A contused or lacerated wound of the cornea, after which there has not been perfect union.

3rd. A wound of the cornea with wound of the lens. The swollen lens pressing on the iris may keep up such constant irritation of the eye as to retard the union of the edges of the corneal wound.

4th. A glaucomatous state of the eye following a perforating wound of the cornea.

5th. The presence of a foreign body within the eye; the wound through which it entered having failed to completely unite.

Symptoms.—A shallow or scarcely perceptible anterior chamber, with a minute opening in the cornea, through which drops of the aqueous humour may be seen to exude. One useful method of diagnosing a fistula of the cornea is, to separate the eyelids with the fingers from the globe, and having dried the suspected spot of the cornea with a piece of blotting-paper, to notice if the surface again becomes moist whilst the eye is kept open.

Treatment.—When dependent on a perforating ulcer, or a wound of the cornea, the fistulous orifice may be touched with nitrate of silver. This is best applied by a fine camel's-hair brush, which has been first moistened with a little water, and then drawn a few times across a stick of nitrate of silver. This application may be repeated three or four times at intervals of two days, if it

does not excite undue inflammation. If this treatment should fail, an iridectomy should be performed; the spot at which it is made is not of much consequence, as in any part it will equally succeed in promoting the closure of the fistula.

When the fistula is due to a cataractous lens pressing on the iris, and by the irritation it excites preventing the perfect union of the corneal wound, the lens should be removed. If, however, the maintenance of the fistula is caused by a glaucomatous state of the eye, an iridectomy should be made. Lastly, if all other means have failed, the edges of the fistula may be pared with a broad needle, and united by a single fine silk suture.

NEBULA or CLOUDINESS OF THE CORNEA may be caused by inflammation or superficial ulceration of the cornea, or by an injury which has induced a traumatic corneitis. It may be limited to a portion of the cornea, or it may be irregularly diffused over its whole surface. In some cases the nebula is due to an interstitial deposit of lymph in the true corneal tissue; whilst in other instances it is produced by a layer of fine semi-transparent cicatricial tissue formed during the healing process of a superficial ulceration.

Treatment.—When the eye is free from all irritation some mild stimulating application will occasionally do good, by exciting the absorbents of the cornea to an increased activity; but there are no specific remedies for the cure of nebula. The applications from which I have found the most benefit are the following:—

1. *Lotio hydrarg. perchlorid.* (F. 57.) Two or three drops to be dropped into the eye twice a day. This remedy is often a powerful irritant, and should be discontinued if the eye becomes inflamed or painful.

2. *Guttæ ol. terebinth. cum ol. olivæ.* (F. 29.) At first these drops should be used very weak, but their strength may be increased if the eye is tolerant of them.

3. Dusting calomel into the eye every or every other day for a short time.

4. *Guttæ zinci sulphatis* (F. 26), or *zinci chlorid.* (F. 25) may be prescribed.

5. A solution of the iodide of potassium (F. 24) dropped twice a day into the eye is thought by many to do good.

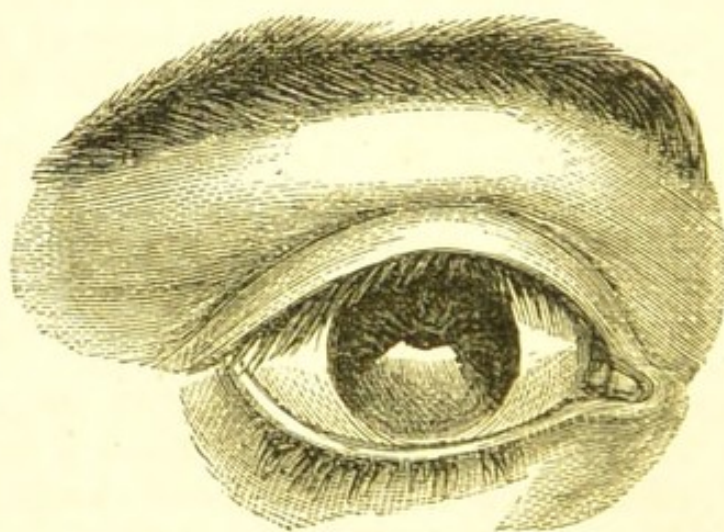
6. Sulphate of soda. Mr. Power speaks favourably of

the general results he has obtained from the use of this drug in corneal opacities. He says that "in the employment of this salt the quantity that should be introduced at one time into the eye should not exceed one or two grains, and the most convenient mode of application consists in everting the upper lid, and brushing the powder lightly over the surface with a camel's-hair brush."*

7. The late Dr. Mackenzie, of Glasgow, recommended the vapour of hydrocyanic acid.†

LEUCOMA OF THE CORNEA.—A leucoma is a dense white opacity of the cornea, caused by a loss or destruction of a part of its substance, the gap thus made being replaced by cicatrix tissue, which is opaque and white, instead of transparent and colourless like healthy cornea. It may be the result of an injury, but more frequently it is occasioned by inflammation and deep ulceration induced by other causes. It is irremediable. With the leucoma

FIG. 4.



A Leucoma of the Cornea, copied from Dalrymple's Plates.

there is often some alteration in the shape of the pupil, from a portion of the iris having become adherent to the cicatrix. In such cases the ulcer which had caused the leucoma had penetrated the cornea, and the iris had

* Power on Sulphate of Soda for Removing Opacities from the Cornea: *The Practitioner*, vol. i. p. 155.

† Mackenzie on the Diseases of the Eye, 4th edition, pp. 639 and 428.

either been dragged into the wound as the aqueous escaped, or else, falling forwards, had contracted adhesions to the granulations which were afterwards to be converted into the cicatrix tissue.

One of the evils which frequently results from a leucoma is, that the normal curvature of that portion of the cornea which remains transparent is changed in one or more of its meridians, and the eye rendered astigmatic; a defect which may sometimes be neutralized to a great extent by a properly-fitted cylindrical glass.

When the leucoma occludes so much of the pupil as to impede the sight, an artificial pupil may be made opposite to that portion of the cornea which is most normal both as regards its transparency and curvature.

To lessen the defect in appearance caused by a leucoma, the white patch may be partially or completely tattooed black, according to its size and situation. In cases of central leucoma a circular pupil may be tattooed on the cornea, and the outward defect be thus almost obliterated whilst the sight may be to a great extent restored by the formation of an artificial pupil.

OPERATION FOR TATTOOING THE CORNEA. —

This is done by making a series of small punctures into the corneal tissue, and running into them a strong solution of Indian ink. The operation may be performed by a single-grooved needle fixed in a handle. A little Indian ink should be rubbed down on a palette and made sufficiently fluid to run easily after it has been placed into the groove of the needle by a camel's-hair brush. With the needle well charged with Indian ink a series of punctures are to be made close to each other over the whole area of the spot to be coloured. Each puncture of the needle should pass through the corneal epithelium into the true corneal tissue. Two or three sittings are generally required to make a good representation of a pupil on the leucoma.

OPACITY OF THE CORNEA FROM LEAD is caused by the use of a lead lotion when the cornea is ulcerated or abraded; the lead is deposited on the surface as a carbonate, producing a milky-white patch, which is often sufficiently opaque to occlude either the portion of iris or the pupil which lies behind it.

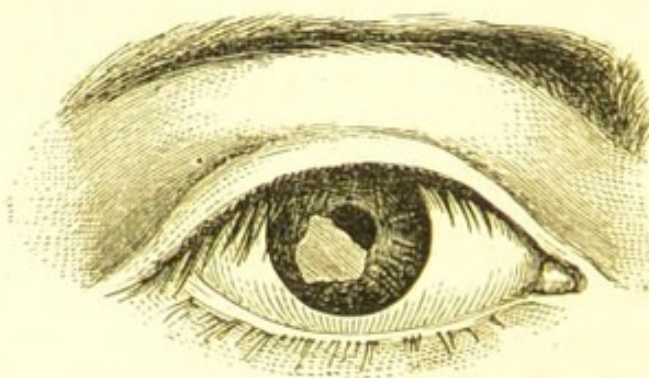
The treatment consists in removing the layer of lead

deposit which has coated the abraded surface of the cornea. This may be done with a small knife curved convexly on its cutting edge, as in Fig. 5. The lids being separated by a speculum, the operator with one hand fixes the eye with a pair of forceps, whilst with the other he gently scrapes the whitened surface of the cornea, until, having detached the epithelium, he comes down to the thin coating of lead: steadily but gently scraping, he will generally succeed in detaching all that is required. Having completed the operation, a few drops of olive oil should be dropped into the eye, and a fold of wet lint laid over the closed lids.

FIG. 5.



FIG. 6.

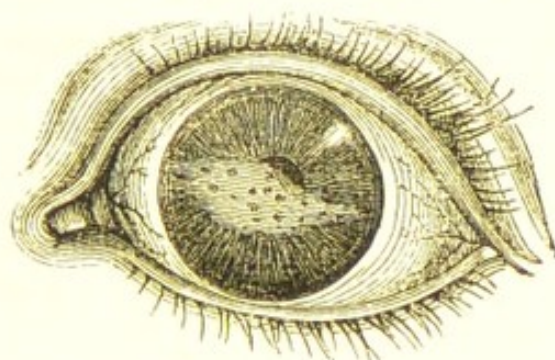


The woodcut (Fig. 6) represents the appearance produced by using a lead lotion to an eye, whilst there was a large ulcerated surface of the cornea. On the patient from whom this drawing was made, I performed the operation above described; a portion of the film of lead chipped off in fine white scales, and the remainder was removed by steady scraping.

CALCAREOUS FILM OF THE CORNEA.—*Symmetrical Opacities of the Cornea.*—These terms have been applied to a peculiar form of opacity of the cornea caused by a deposit of the earthy salts between the epithelium and the anterior elastic lamina of the cornea. Mr. Bowman, in his "Lectures on the Parts concerned in the Operations on the Eye," has recorded two cases, one in his own practice and the other in that of Mr. Dixon. Since then Mr. Fairlie Clarke has published two cases in the *Pathological Transactions* for 1870, p. 331. In all

these cases the patients were adults—the youngest forty, the oldest fifty-eight; both eyes were affected by an opaque transverse band extending across the centre of the cornea opposite the pupil, their margins were shaded off abruptly, and beyond them the cornea was clear. The opacities were said to be “of a brownish tint,” and “of a greyish-brown and rusty-brown colour.” In all the cases the disease commenced as a haze in each cornea, which deepened in intensity and increased in size. The progress of the growths was slow, occupying from six to fifteen years before they reached the dimensions described. There was no constitutional taint, such as gout, struma, or syphilis, which could account for the development of these opacities; neither was there anything in the occupation of the men which could have led to their formation.

FIG. 7.



Calcareous Opacity of the Cornea (after Bowman).

Treatment.—No medicine nor local application will stay the progress of the disease. When, however, the opacity has reached a sufficient density to interfere seriously with sight, an attempt should be made to remove it. The plan adopted by Mr. Bowman in 1849, and afterwards followed by Mr. Dixon, was to scrape away the epithelium of the cornea until the lancet came down upon the calcareous opacity, and then to detach by scraping and chipping as much of the film as possible. The result of this operation was most satisfactory. In Mr. Bowman's case, the man, owing to his defect of sight, had been thrown out of employment for twelve months, but after the film was removed he could see almost as well as he could eight years before, and could read with care the smallest type.

The calcareous deposit was examined by the late Dr. Miller, of King's College, and found to consist of

phosphates of lime and magnesia, with a considerable portion of carbonate of lime.

CONICAL CORNEA is a staphylomatous bulging of the middle portion of the cornea. caused by a thinning of its structure in that region. The conicity is not always quite central, but frequently a little to one side of the pupil, and such cases give excellent results after a trephining operation, as only a portion of the pupil is affected by the leucoma which follows. The disease comes on very imperceptibly, and progresses without pain. It first manifests itself to the patient by a change in the focus of the eye, which becomes irregularly myopic; and this defect grows worse as the bulge increases, until, in severe cases, the sight is so much impaired as to render the eye almost useless. Usually there is no undue vascularity of the globe, but in some instances where the conicity is rapidly advancing there is slight ciliary redness. After the cone has attained a certain size its apex loses its transparency and becomes nebulous or semi-opaque, with its epithelial surface roughened. One or both eyes may be affected; but when both are involved the conicity is generally much greater in one eye than the other.

The disease will frequently advance rapidly in one eye, whilst it remains stationary in the other.

Diagnosis.—In the advanced stage, conical cornea is easily recognised, but at the commencement of the disease it is often difficult to diagnose, and its presence may be easily overlooked. The cornea is best examined by looking at the eye from its outer side so as to see the cone, if one exists, in profile. In a paper by Mr. Bowman, on "Conical Cornea," in the Royal London Ophthalmic Hospital Reports, vol. ii., he says, "Soon after the immortal invention of Helmholtz, I found the ophthalmoscope very useful in detecting slight degrees of conical cornea. For this purpose the concave mirror only is to be used without a convex lens. On turning the mirror so as to throw light at different angles, the side of the cone opposite to the light is darkened."

In speaking of conical cornea, Donders remarks, "High degrees strike the eye at once. Slight degrees, on the contrary, are often enough overlooked. The disturbance of the power of vision frequently suggests the idea of amblyopia combined with myopia." . . . Further on,

he recommends the use of the ophthalmoscope as a means of diagnosis in slight cases of conical cornea, and observes that "in the inverted image where there is a tolerably wide pupil, we overlook at the same time a rather large portion of the fundus oculi; the image, therefore, of one part or other, for example of the optic disc, remains in the field of vision both on moving the head of the observer, and on shifting the lens before the observed eye. At the same time, however, the rays which, proceeding from the optic disc, strike the eye of the observer, pass each time through other parts of the cornea. Now, if its curvature is irregular, the result is, that the form of the disc each time alters, it shortens in this direction, extends in that direction, and moreover is never seen acutely in its integrity." *

Pathology of Conical Cornea.—It is very difficult to ascribe any cause for the structural changes in the cornea which give rise to the staphylomatous bulging. The tension of such eyes is seldom if ever in excess; indeed, it is more frequent to find them slightly soft. All that we are at present able to say of conical cornea is, that from some cause, possibly failing nutrition, the central portion of the cornea becomes thinned and its power of resistance diminished, so that it yields before the normal pressure from within the eye, and bulges conically. The bulging may increase until the apex of the cone seems to be on the verge of bursting, but this is an accident which seldom, if ever, occurs spontaneously. Mr. Bowman thinks that this fact may be thus explained: "As the cornea becomes thinner, the escape of the aqueous humour by exosmose is facilitated, and thus the internal pressure is reduced so as to be no longer in excess of the diminished resisting power of the cornea."

The following is an account of a microscopical examination made by Mr. Hulke of a conical cornea taken from an eye which had been excised by Mr. Bowman during an operation for the removal of a large sebaceous cyst from the orbit:—

"The central conical nebulous portion was much thinner than the transparent periphery of the cornea, where the curve was natural. This thinning began at the base of the cone, and progressively increased towards the apex,

* Donders on the Accommodation and Refraction of the Eye, pp. 550-551.

where it reached its maximum. At this point the mean depth of several vertical sections was only one-third of that of the peripheral region. The continuity of the anterior elastic lamina was perfect, but upon the cone this structure was much thinner than elsewhere, and wrinkled; it was underlaid by a stratum of crowded, elongated, club-like nuclei, and beneath these the normal lamellar tissue was replaced by a web of caudate and nuclear fibres, amongst the meshes of which clusters of large oval and fusiform cells were packed. The structure of the transparent peripheral region was perfectly normal, and at the base of the cone there was a gradual transition from the healthy to the diseased tissue, the interlamellar corpuscles becoming more plentiful, branched and drawn out into fibres, which in many instances coalesced with those from neighbouring corpuscles. The posterior elastic lamina, and the epithelium both on the front and on the back of the cornea, were unchanged."

"The changes I have described," adds Mr. Hulke, "were confined to the laminated tissue of the cornea and the anterior elastic lamina. The substitution of a web of nuclear fibres and cells for the regular lamination of the cornea explains the nebulosity of the cone and the liability to bulge."*

Treatment.—When conical cornea is in its earliest stage it is possible that by judicious prophylactic treatment its progress may be retarded; but when the cone is steadily advancing, I know of no help except by operation which is likely to be of any avail.

As preventive treatment, all work which strains or reddens the eyes should be avoided. The cold or tepid douche, whichever is the more pleasant, may be used three or four times daily. When there is any ciliary redness, two or three leeches may be advantageously applied to the temple. If the patient is feeble tonics of quinine, iron, &c., should be ordered. Except in the very commencement of the disease, but little if any benefit will be derived from either concave, spherical or cylindrical glasses. The astigmatism produced by the conicity is so irregular that it cannot be sufficiently corrected by lenses to afford much improvement of sight. Occasionally a stenopaic slit placed behind a concave spherical lens is found of decided service, and when this is the case the

* Royal London Ophthalmic Hospital Reports, vol. ii. p. 154.

patient may be provided with similar spectacles, but with the understanding that they must be laid aside if they fatigue the eyes.

Operative Treatment.—The method now adopted for the relief of cases of advanced conical cornea is to excise the apex of the cone, and afterwards, if the leucoma which follows impedes the sight, to make an artificial pupil opposite to that portion of the cornea which has the most normal curvature.

There are two operations for the removal of the apex of the cone, both of which have been followed with very excellent results:—

1st. By excising an oval piece of the cone, the length of the oval being made in the vertical axis of the cornea.

2nd. By excising a circular piece of the cone with a small cutting trephine as suggested by Mr. Bowman.

1. Operation for the Excision of a small oval piece of the Cone of the Cornea.—Before operating, a solution of atropine (F. 15) should be dropped into the eye so as to have the iris under its influence when the operation is completed; and thus to get the pupil dilated as soon as the aqueous is again retained within the anterior chamber.

A speculum is to be introduced between the lids, and the eye held down by a pair of finely-toothed forceps whilst a Graefe's extraction knife is passed from above downwards through the apex of the cone, and so directed as to cut a small vertical flap of the cornea not exceeding one-eighth of an inch in length and one-twelfth of an inch in width. This is to be seized by a pair of iris forceps and cut off by a pair of scissors. The cut edges of the cornea should then be allowed to fall together, and a pad of cotton wool and lint be placed over the closed lids and secured in its place by a compress bandage (F. 3). After twenty-four hours the pad and bandage may be changed, but the lids should not be opened to look at the eye until at least forty-eight hours after the operation.

A solution of atropine, gr. 1 ad aquæ $\bar{5}$ 1, may now be dropped into the lower lid, and repeated once daily so as to keep the pupillary edge of the iris away from the corneal wound. After the wound of the cornea has healed a small central leucoma will remain, which will, according to its size, impede the sight. To remedy this defect, an artificial pupil should be made opposite to that portion of the cornea which presents the most normal curvature.

2. Operation for the Excision of a small circular piece of the Cone of the Cornea by a Trephine.—This operation was first suggested and practised by Mr. Bowman.

Its object is to remove the most prominent part of the cone, and by the contraction caused by the healing of the wound to restore the curve of the cornea to a more normal state. The trephines vary in diameter, so as to excise portions of different sizes, as may be requisite. They are provided with a movable "stop" to regulate the depth of penetration. The trephine usually required is one-tenth of an inch in diameter. (Fig. 8.)

FIG. 8.



The patient having been placed under chloroform a speculum is introduced between the lids, and the trephine, adjusted by the "stop" to the depth it has to penetrate, is applied firmly to the apex of the cone and rotated with the finger and thumb. The trephine is not to be carried through the entire thickness of the cornea, but withdrawn when it may be calculated to have reached Descemet's membrane. The circular piece of cornea which has been thus cut is then seized by iris forceps and peeled off, but if it cannot be thus readily detached it may be severed with a few touches of a cataract knife. A few drops of atropine should now be dropped into the eye, and the lids closed with a wet cotton wool compress and a bandage over them. One operation is usually sufficient to produce such a change in the curve of the cornea as to greatly improve the sight, but if necessary the trephine may be again applied after an interval of some months. A slight leucoma follows the operation, and it is generally necessary to make an artificial pupil opposite the best portion of the cornea. The results of this operation are most satisfactory.

KERATO-GLOBUS—*Hydrophthalmia*—is a uniform enlargement of the anterior half of the globe, which often attains to such dimensions as to prevent the lids from closing over it. Both eyes are usually affected, although one may be more seriously involved than the other. It is sometimes congenital, and may possibly be due to some hereditary syphilitic taint: but it may also come on after

corneitis. It most frequently occurs in young children. The peculiar amazed stare which this deformity of the eyes gives to the patient is very unsightly. The *cornea* will sometimes be seen of almost double its normal proportion. In some cases it is slightly cloudy, whilst in others its transparency is unimpaired. The adjacent *sclerotic* is thinned and of a bluish colour, from the subjacent choroid shining through it. The *anterior chamber* is large and deep, and the *iris* is pushed backwards, frequently tremulous, and so greatly stretched that its ciliary attachment is occasionally drawn within the anterior chamber; and in severe cases I have seen large rents in the iris, caused by the separation of its fibres from extreme stretching. The pupil is usually rather dilated and sluggish, and sometimes oval or pear-shaped; but occasionally the pupillary margin is completely adherent to the lens capsule from the attacks of inflammation to which it has been subjected. The sight is always very defective, and in the worst cases completely destroyed. The disease is usually slowly progressive.

Treatment.—Unless the disease is steadily increasing, and the sight diminishing, I believe it is best to leave hydrophthalmic eyes alone. Their powers of repair are enfeebled, and they stand operations badly. I have certainly seen an iridectomy occasionally do good, but, on the other hand, I have seen cases in which it did positive harm. In a few cases where the hydrophthalmia has been clearly associated with congenital syphilis, I have given the pulv. hydrarg. cum cretâ (F. 151) every night for some weeks, and obtained a marked diminution of the size of the globe. If one eye is quite blind, and suffering from not being fully protected by the lids, it may be excised.

A STAPHYLOMA OF THE CORNEA is a projecting forwards or bulging of the whole or a part of the cornea, or of the new tissue which supplies its place when a part or the whole of it has been destroyed by injury or disease.

A staphyloma of the cornea may be either *partial* or *complete*, that is to say, it may be limited to a small portion, or it may involve the whole of the cornea or the new structure which represents it.

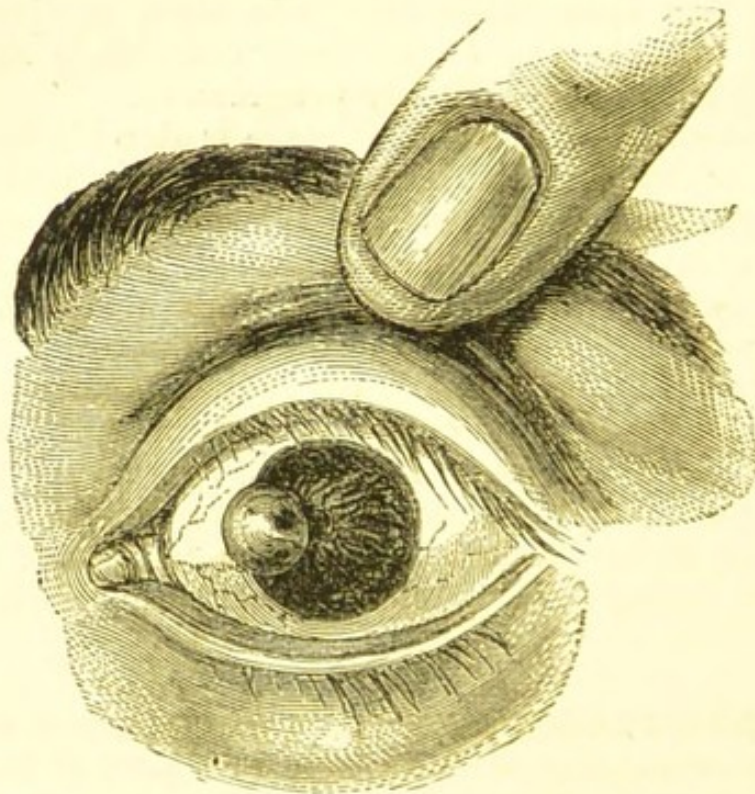
PARTIAL STAPHYLOMA OF THE CORNEA.—When a portion of the cornea has been destroyed by

sloughing or ulceration, its place is made good by cicatricial tissue, which is more or less white or opaque, and in many cases incapable of resisting the normal outward pressure of the parts within the eye; slowly yielding, it bulges and forms an unsightly prominence on the cornea.

Treatment.—The objects to be accomplished are: 1st, to arrest the progress of, and, if possible, to diminish the bulge; and, 2nd, to restore some of the lost sight to the eye. Both of these conditions may be often attained by the operation of iridectomy.

The removal of a piece of the iris by iridectomy exercises an important influence in diminishing the tension of the globe, and thus frequently prevents any further increase of the staphyloma, and in a few instances which have come under my notice the bulging has decidedly

FIG. 9.



Partial Staphyloma of the Cornea, copied from
Dalrymple's Plates on the Eye.

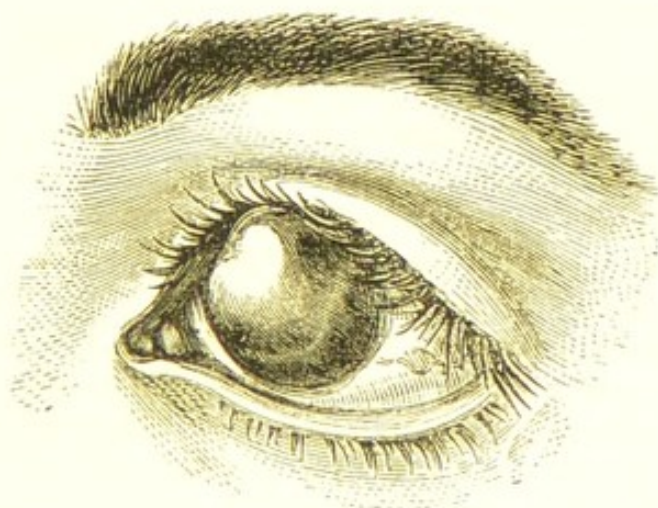
receded. But, in addition to this, by the excision of a portion of the iris opposite to that part of the cornea which is in the most healthy state, an artificial pupil is made, and if the fundus of the eye be sound, and the transparency and curvature of the cornea opposite the new pupil tolerably good, useful sight will be regained.

If the partial staphyloma be large or increasing in size, a small circular piece of its most projecting part may be removed with the trephine, Fig. 8, p. 60. I have adopted this treatment, and with complete success.

COMPLETE STAPHYLOMA OF THE CORNEA is a bulging of the entire structure which has replaced the original cornea after it has been destroyed by ulceration or sloughing.

Progress of the Disease.—After the loss of the cornea, the exposed surface of the iris is soon coated with a film of lymph; this becomes organized and ultimately converted into a bluish white cicatricial tissue, to which the iris is firmly adherent. The eye will now either gradually shrink, or the new tissue will yield before the pressure from within and become staphylomatous.

FIG. 10.



A Complete Staphyloma of the Cornea, copied from Dalrymple's Plates on the Eye.

Treatment of Commencing Staphyloma.—If the patient be seen early, the first object in view is to prevent the formation of the staphyloma, and this is best accomplished by the removal of the lens, if it has not already escaped from the eye. After the slough of the cornea has separated, the lens will be often seen lying in the centre of the pupil, perfectly transparent and projecting slightly forwards; it may then be removed by gently lifting it away with the point of a fine needle.

If the eye be not seen until a later period, but when the staphylomatous bulging is still recent, and the new

tissue which occupies the corneal space is yet but imperfectly formed, the plan recommended by Mr. Bowman for the removal of the lens may be adopted. A broad needle is passed through the most prominent part of the staphyloma in the direction of the lens, so as to penetrate its capsule, and the lenticular matter is freely broken up. The needle is then withdrawn, and through the aperture it has made a curette is introduced, and as much of the lens matter as is sufficiently soft and diffuent is allowed to escape from the eye along its groove. The puncture made with the broad needle may be repeated every two or three days until the prominence of the staphyloma is reduced.

Treatment of Complete Staphyloma of the Cornea.—The eye being lost for all visual purposes, the objects to be accomplished are to get rid of the unsightly staphylomatous bulging, and to enable the patient to wear an artificial eye. One of the following modes of treatment may be adopted:—

1. The staphylomatous eye may be excised.
2. The staphyloma may be trephined.

1. The Staphylomatous Eye may be Excised.—When the eye is blind and the bulging large and unsightly, and causes the patient annoyance from the obstruction it offers to the free movements of the lids over it, this is the best operation. The patient will recover from it more quickly than from any other, all chance of future trouble is avoided, and an artificial eye can be worn.

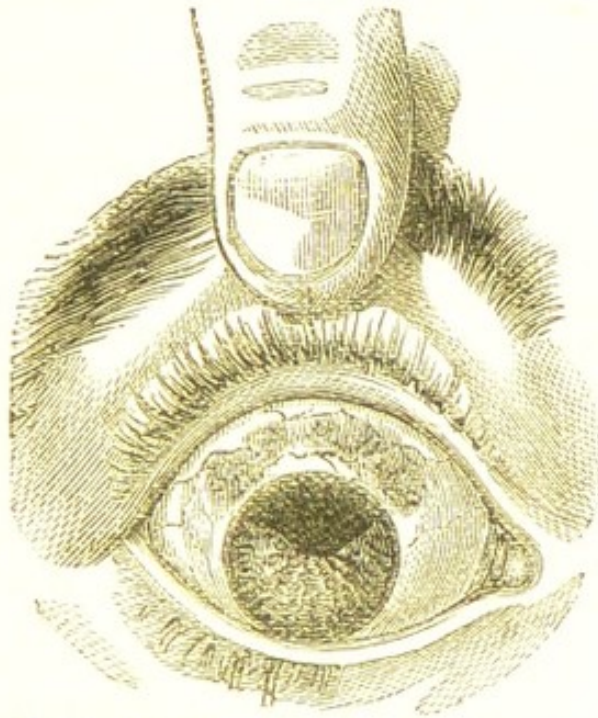
2. The Staphyloma may be Trephined.—When the object is simply to reduce the size of the staphyloma, but not to form a bed upon which an artificial eye can be worn, the operation of trephining is well suited. A small circular piece of the most prominent part of the staphyloma may be removed by the trephine, Fig. 8, as described in the operation for conical cornea, page 60. If the lens be seen through the small opening thus made, its capsule should be pricked with a fine needle and the lenticular matter broken up, and as much of it as will come away be allowed to escape along the groove of a curette. The lids should be then closed and covered with a wet compress and bandage.

ABSCISSION OF THE STAPHYLOMA.—I have omitted the description of this operation as my feeling is against the performance of it. I prefer the complete

removal of the globe to the abscission of the front of it, as I have known cases in which sympathetic symptoms have arisen in the sound eye from the irritation caused by the recurrence of inflammation in the stump of the one which had been abscised.

CILIARY STAPHYLOMA—*Anterior Staphyloma of the Sclerotic*—is a staphylomatous projection of the sclerotic in the ciliary region of the eye. It consists of a series of grape-like bulgings, with such a thinning of the sclerotic

FIG. 11.



The woodcut represents the appearance of a ciliary staphyloma produced by a blow on the eye, which had caused a rupture of the sclerotic and a dislocation of the lens beneath the conjunctiva.

coat that the dark colour of the ciliary processes with which it is in contact is distinctly seen through it. It may be limited to a part, or it may involve the whole of the ciliary region of the eye.

Ciliary staphyloma may be the result of disease or injury. In the majority of cases it is dependent on a chronic irido-choroiditis, accompanied with a gradual wasting of the sclerotic in the immediate vicinity of the ciliary processes, so that it loses its normal power of resisting the outward pressure from within the eye, and slowly yielding, a dark irregular nodulated prominence is developed. As the *direct* result of an injury, ciliary

staphyloma may be produced by a rupture of the sclerotic, and especially when there is also associated with it an extensive prolapse of the iris and choroid, as is represented in Fig. 11.

The Prognosis of ciliary staphyloma is always most unfavourable; even when slight there is considerable impairment of vision; but the danger to be apprehended is that it will increase, and as it enlarges all sight will be destroyed.

Treatment.—When a ciliary staphyloma is dependent on disease, no matter whether it has originated from constitutional causes, or from some remote injury to the eye, it may frequently in its early stages be arrested by the operation of iridectomy. It is the only remedy from which I can really feel satisfied that I have seen any decided benefit; and although in some cases it may fail in accomplishing the desired end, yet it is certainly the most successful of all the remedial agents I have known practised for the relief of this disease. By reducing the tension of the eye, the tendency of the staphyloma to increase is certainly diminished, and in some instances completely stopped. It should be remembered that even though the tension of the eye at the time of the operation may be normal, yet the resisting power of the sclerotic has been lowered by disease, and that by lessening the tension which exists, the condition of the eye is improved.

If, however, the ciliary staphyloma is produced by a rupture of the sclerotic, I know of no remedy. The sight which such an eye retains, even when the staphyloma is small, is usually very limited; but if the bulging be sufficiently large to interfere with the free movements of the lid, the eye is generally blind. When an eye thus completely lost for all visual purposes is unseemly in appearance, and troubles the patient, the best treatment is to excise it.

CYCLITIS, or inflammation of the ciliary body, may arise—

1. From an injury to the eye.
2. From the extension to the ciliary body of an inflammation of the iris or choroid.
3. From constitutional defects.

Cyclitis, like iritis, may be either plastic, serous, or suppurative. When it is excited by an injury, cyclitis is

usually either serous or suppurative; when it is due to an extension of sympathetic or syphilitic iritis it is always plastic; but when it is caused by some constitutional defect, *not syphilitic*, it is mostly serous.

1. **Cyclitis from an injury to the eye** may be primary, and originate simultaneously with iritis as the immediate result of the injury; or it may be secondary to an inflammation of the iris which the injury has excited.

The injuries which are most liable to produce cyclitis are penetrating or incised wounds in the ciliary region; the lodgment of a foreign body within the eye; a dislocation of the lens; or the forcible removal of a piece of opaque capsule, especially if during the operation any drag has been made on the ciliary processes.

Symptoms.—Pain in the ciliary region, with marked tenderness on pressure; a pinkish zone around the cornea from distension of the ciliary vessels; photophobia and lachrymation; and turbidity of the vitreous from inflammatory exudations into it from the ciliary processes. After wounds in the ciliary region large masses of lymph or pus may be frequently seen with the unaided eye, lying behind and to one side of the lens. The iris always participates in the inflammation, even when the disease originates in the ciliary body, its striæ become indistinct and its colour changed, the pupil sluggish or inactive, and posterior synechiæ are formed; the aqueous grows serous and turbid, and there is frequently hypopion. The sight is greatly impaired, and the tension of the globe is often increased.

2. **Cyclitis from the extension to the ciliary body of an inflammation of the iris or choroid.**—Inflammation of the iris, produced either by injury or disease, may spread first to the ciliary body, and then to the choroid; and in like manner an inflammation which has started in the choroid may, by extension, give rise to cyclitis and iritis.

This secondary cyclitis is always a very severe complication of the original disease, and frequently leads to the complete loss of the eye. It is often induced by syphilitic inflammation of the iris or choroid; it also frequently follows traumatic iritis, and it thus becomes one of the causes of failure after the operation for extraction of cataract.

The **Symptoms** are similar to those described in the preceding section, but in this secondary form of cyclitis

the advent of the extension of the inflammation to the ciliary body is marked by an addition to the severity of the pre-existing symptoms; there is increased vascularity, photophobia and lachrymation, pain in the ciliary region, which is increased by pressure, and frequently also an increased tension of the globe.

3. **Cyclitis from constitutional defects.**—Under this heading I do not include the secondary cyclitis which may arise from an extension of an iritis or choroiditis produced by any constitutional cause. I refer only to a special class of cases in which the cyclitis occurs as a primary disease and seems to be always due to some constitutional defect, such as great debility, exhaustion from mental anxiety or overwork, anæmia, menorrhagia, profuse leucorrhœa, and amenorrhœa. This form of cyclitis is a comparatively rare affection, but it is sufficiently frequent to deserve careful study, as it is very destructive to the eye. The patients whom I have seen have been generally women, and the causes have been usually menorrhagia, profuse leucorrhœa, and amenorrhœa. I have, however, met with a few cases of this affection in men, and in them the disease has been clearly referrible to nervous exhaustion from overwork combined with great mental anxiety.

Constitutional cyclitis is a disease of long duration, very recurrent, and but slowly amenable to treatment. Its attacks will generally last from six weeks to three months or longer. I have had several cases of cyclitis in females which have extended over periods of from eight to twelve years, the attacks recurring at intervals of from three to six months.

Symptoms.—The disease usually commences on one side of the cornea in the ciliary region with a small patch of a purplish-red colour closely resembling episcleritis. This gradually extends and soon a bluish-red halo exactly corresponding with the ciliary region surrounds from one-third to the entire circumference of the cornea. When only a portion of the region surrounding the cornea is affected, the purplish-red shades off at each extremity into the colour of the rest of the eye. The margin of the cornea corresponding to the deep red zone is slightly blurred and indistinct, and seems to blend with the sclerotic. In some cases the whole surface of the eye is red, but the peculiar purplish tint which corresponds with the ciliary region is always distinct, and serves to

mark well the nature of the affection. As the disease progresses the iris becomes involved, the aqueous grows serous, and there is occasionally hypopion. The sight is impaired, in some cases to a great extent, and the tension of the globe is frequently increased. If the disease continue unchecked, the sclerotic corresponding to the ciliary region will become thin and of a bluish colour, from the ciliary processes shining through it, and occasionally staphylomatous; the sight will continue to fade, and ultimately the eye will be blind. Through all the stages of the disease there is pain in the eye, varying in degree from tenderness to a dull heavy aching; there is frequently also pain in the brow and down the inner side of the nose.

Prognosis of Cyclitis.—1. When cyclitis is due to an extension of the inflammation from the iris or choroid it may, under judicious treatment, subside, but it must always be regarded as a very serious complication. 2. When, however, it arises from an injury, the prognosis is very unfavourable; if the inflammation subside under treatment, the eye generally becomes soft and partially shrinks, and all sight is destroyed; the great danger to be feared is lest, while endeavouring to save the injured eye, the other should become sympathetically affected. 3. When cyclitis is caused by some constitutional defect, as mentioned in the last section, it is generally very tedious, but ultimately amenable to treatment. There are, however, occasionally cases in which the disease resists all remedies, and the eye is lost.

Treatment of Cyclitis.—When cyclitis is secondary and proceeds from iritis or choroiditis, the treatment recommended in the sections devoted to these diseases must be followed. When, however, it is caused by an injury, no special medicinal treatment will be of service. At the commencement of the attack, leeches should be applied to the temple, and warm belladonna fomentations (F. 9), to the eye, and in the intervals between the applications, the eye may be kept at rest by a slight compress and bandage. If this should fail to give relief, a fold of linen wet with the belladonna lotion, may be laid over the closed lids. The bowels should be freely acted on by a purgative, and if the pain is severe opiates should be given at bedtime. The strength of the patient must be maintained by a liberal diet, and a moderate amount of stimulants may be allowed. If necessary tonics of quinine or bark should

be prescribed. The results, however, of cyclitis proceeding from injury are so unfavourable, both as respects the injured eye and the risk to which the sound one is exposed from sympathy, that if the inflammation does not yield rapidly to treatment I would strongly urge the removal of the globe, and this especially if the accident be a wound in the ciliary region.

When cyclitis arises from some constitutional defect, the treatment must be directed to the special cause in each individual case. If it proceed from exhaustion due to overwork or mental fatigue, rest must be given to the patient, and tonics of iron, quinine, or bark combined with the mineral acids, and in some cases with small doses of liquor strychniæ (F. 75, 79, 81). If the disease be caused by functional menorrhagia the mineral acids with tincture of cinnamon (F. 70) will be often found beneficial, or should these fail, small repeated doses of the fluid extract of ergot (F. 72) will frequently afford relief. When there is profuse leucorrhœa the tincture of the perchloride of iron with dilute hydrochloric acid (F. 85) or with quinine (F. 81) will generally do good. If amenorrhœa be the cause of the cyclitis means must be taken to restore the uterine functions, and the iodide of potassium with ammonia (F. 94), or the iodide and bromide of potassium with iron (F. 93), or the borax mixture (F. 71) may be tried. In all such cases the bowels should be made to act regularly and rather freely, and for this purpose small doses of the decoct. aloës with gentian (F. 103), or the pil. aloës cum jalapâ (F. 107), or the pil. aloës cum nuce vomica (F. 108), may be given as often as may be found necessary. Half a small tumblerful of Friedrichshall water taken with the same quantity of warm water whilst dressing in the morning often acts in a very satisfactory manner, and may be repeated every or every other morning if required. When there is pain it may be relieved by the croton chloral hydrat, given either in pills or mixture (F. 78, 110) for two or three doses. If the pain be sufficient to prevent sleep, opiates should be given at night.

If the disease resists all medicinal treatment, or if the tension of the globe be increased, or if the sclerotic around the cornea become thinned and bluish, I would perform an iridectomy. I have frequently done this operation for cyclitis and with admirable results. It exercises a wonderful influence in arresting the recurrence of the attacks.

EPISCLERITIS is a small diffuse swelling beneath the conjunctiva, usually on the temporal side of the cornea, and near the insertion of the recti muscles. It has a smooth surface and is of a dusky-red colour, and is apparently caused by some plastic effusion on the sclerotic. There is generally some redness of the conjunctiva immediately over it, and sometimes chemosis. The dark hue of the swelling seems due to its being supplied by the deep subconjunctival vessels which in some cases may be seen running up to it. The affection appears to be local and confined to one side of the cornea. The degree of suffering it produces is very variable. In some patients I have seen considerable irritation, with severe neuralgic pain in the eye; whilst in others the only annoyance has been the disfigurement which the bloodshot appearance has produced. The disease is generally very tedious in its course, and frequently recurrent. For a time the swelling seems to increase in size and redness; it then gradually fades in colour, diminishes, and ultimately disappears.

Treatment.—When there is no irritation, a mild stimulating application to the eye does the most good, and the guttæ zinci chlorid. (F. 25), or the guttæ zinci sulphatis (F. 26), may be ordered twice a day. If, however, there is photophobia and lachrymation the guttæ atropiæ (F. 15), or the lotio belladonnæ should be prescribed. The state of health should be carefully inquired into, and if any irregularity of the functions of any of the organs be detected, suitable medicines should be prescribed. In some cases I have found benefit from the administration of the iodide of potassium, given either with an alkali (F. 91), or with small doses of iron (F. 92), according to the requirements of the patient.

ARCUS SENILIS is a term wrongly applied to a whitish crescent which frequently appears near but not quite up to the margin of the cornea, as beyond the white marking there is usually a clear rim of transparent cornea. It may begin at either the upper or lower margin of the cornea, and gradually extend until the whole cornea is surrounded. In old people it frequently assumes a dense white and almost chalky appearance.

Canton regards the arcus as due to a fatty degeneration of the circumferential portion of the cornea, and it has been considered by some as indicative of fatty de-

generative changes in the heart and arteries. There really is no evidence in support of such a theory. The arcus is not a senile change, as it is frequently seen in young healthy subjects under thirty, and it certainly does not point to degenerative changes in the heart or arteries. I have known patients who have had a well-marked arcus for over thirty years and still enjoy good health. I have frequently seen a dense arcus surrounding the cornea in patients over eighty years of age, and with no evidence of cardiac or arterial disease; and I have seen an old patient with gangrene of both legs from arterial degeneration and who had not a trace of an arcus. I have frequently operated for cataract on eyes with a pronounced arcus, and carried my section through it, and the wound has healed perfectly. An arcus senilis does not interfere with the perfection of vision.

INJURIES OF THE CORNEA AND SCLEROTIC.

FOREIGN BODIES ON THE CORNEA OR ON THE CONJUNCTIVA LINING THE LIDS:—

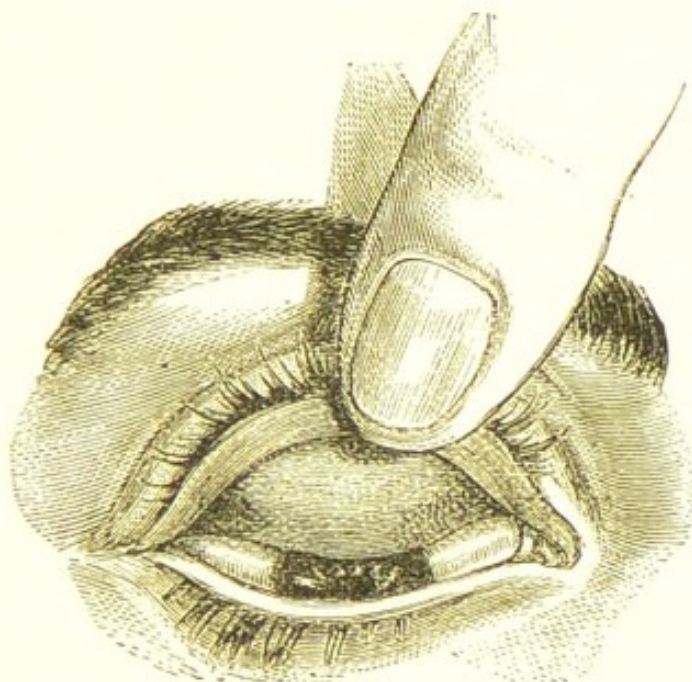
Symptoms.—Great irritability of the eye accompanied by a copious flow of tears; an almost absolute inability to raise the upper eyelid and face the light; and a distinct feeling of grittiness as if something were in the eye. The suddenness of the attack and the exposure to which the eye has been subjected are also points to be noted.

Treatment.—To examine an eye which is suspected to be suffering from the presence of a foreign body, the patient should be made to sit in a chair with his face towards a window, so that a good light may fall upon the eye. The lower lid should be first drawn down, and if any particle of dust or chip of iron is seen it can be readily removed. Next the cornea should be carefully scanned over, by turning the head of the patient in different positions, so as to cause the light to fall obliquely on the eye, first on one part of its surface, and then upon another; or by using a two-inch focus convex lens a column of light may be directed over the cornea, so as to illumine each portion of it in succession. Often it is exceedingly difficult to detect a fine spiculum of steel, or a fragment of glass, or indeed any minute shining substance which may have been impacted on the cornea. In cases of doubt or difficulty the question may be settled by taking

the patient into a darkened room and examining the corneal surface by oblique illumination with ophthalmoscopic light. Should the cornea be free, the under surface of the upper lid should be then examined.

To evert the upper lid, the surgeon, standing behind the head of the patient, seizes with his left finger and thumb the lashes of the eyelid, and drawing them slightly away from the globe, he at the same moment with his right

FIG. 12.



hand presses the end of a probe on the integument of the lid downwards and forwards, so as to tilt the upper edge of the tarsal cartilage downwards, and by this manœuvre to evert it. One finger of the left hand is then made to press gently the turned-up edge of the lid against the brow, to maintain it in its everted state, and the patient is told to look down so as to expose as fully as possible the oculo-palpebral fold of mucous membrane which extends from the posterior edge of the cartilage on to the eye as shown in Fig. 12. The under surface of the lid thus exposed may be then carefully inspected, and the cause of the irritation, if any is found, be removed.

If the foreign body is not deeply buried, but is either lying on the surface or slightly sunk into the epithelium of the cornea or conjunctiva of the lids, it may be easily removed by a spud (Fig. 13), or by a broad needle.



If the foreign body is buried deeply in the corneal tissue, a broad needle should be passed into, but without penetrating the cornea, inserting it just by the side of the object, it should be made to traverse the corneal lamellæ until the broad part of the blade is behind the foreign body, when, by thus giving a firm support upon which to act, another needle may be fearlessly used to pick gently from the surface until it reaches the object, which can then be lifted away. Should, however, the foreign body have so deeply penetrated the cornea that it is feared any attempts to reach it from its surface may end in pushing it into the anterior chamber, a broad needle should be passed into the anterior chamber, and pressed against the inner surface of the cornea immediately behind the foreign body, and carefully and steadily held in this position whilst the surgeon, with another needle, scrapes through the cornea, layer after layer, until he reaches it.

Having removed the foreign body, one or two drops of olive or castor oil may be dropped into the eye. The eyes should not be used for two or three days, and if there is pain, or a continuance of the irritation excited by the foreign body, two or three leeches should be applied to the temple, and the eye fomented with hot water or decoction of poppy heads or belladonna (F. 9, 10).

When the foreign body has been allowed to remain for some days imbedded in the cornea, it frequently lights up a halo of inflammation around it, which may extend until it includes the whole or the greater part of the corneal tissue. The epithelium of the cornea immediately around the foreign particle becomes first whitened and swollen, the foreign body is loosened from its bed, and if not buried too deeply in the corneal tissue, may be detached, and washed away by the tears to the inner corner of the eye. But while these changes are going on in the cornea, the vascularity of the eye is increased, a zone of red vessels is seen around the cornea, and the eye is very intolerant of light. Generally all these symptoms subside after the foreign body has been removed, whether it be by the surgeon, or, as in some cases, by the natural reparative efforts of the eye; but occasionally the inflammation of the cornea which the foreign body has lighted up is severe and difficult to arrest, and even when cured leaves behind it a nebula which impairs the vision of the eye.

ABRASIONS OF THE CORNEA.—An abrasion of the cornea is the forcible removal of a portion of the epithelium from its surface. It is always the result of an injury.

Symptoms.—Immediately after the accident there is photophobia, great lachrymation, and conjunctival redness, with a feeling as if a foreign body were in the eye. On examination of the eye before a good light, the abrasion will be recognised by the glistening facet, which will be seen at the part where the cornea has been denuded of its epithelium.

Prognosis.—Favourable in a healthy person; but, in a delicate or exhausted patient, ulceration of the cornea, diffuse suppurative corneitis, and ultimate loss of the eye, may be caused by this apparently slight accident. Abrasions of the cornea frequently occur in mothers who are suckling; the child unconsciously claws at the eye, and scratches off a little of the epithelium from the cornea. As the health of the mother during lactation is often very unfavourable for the repair of injuries, very severe inflammation may follow, which may lead to complete destruction of the eye.

Treatment.—If there is a simple abrasion of the cornea, and the patient is seen soon after the accident, a drop of castor or olive oil, or cream dropped into the eye, will often give temporary relief, and may be repeated every two or three hours for the first day or two. Gently closing the eye and applying over it a cotton-wool compress with a single turn of a soft roller will give great ease, by effectually excluding the eye from light, and by preventing the up and down movement of the lid, which serves to irritate the abraded surface. If the eye is very painful, the bandage may be removed three or four times during the day, whilst the eye is bathed with hot water, or with a decoction of poppy heads, and two leeches may be applied to the temple. If untoward symptoms come on, such as ulceration, or abscess of the cornea, warmth and soothing remedies are still best suited. A warm belladonna fomentation (F. 9) may be used, frequently applying it to the eye with a hollow sponge, so as to steam it, and thus relax and soothe the inflamed parts. In addition to this, two or three drops of a solution of atropine, gr. 1 ad aquæ 31, may be dropped twice a day into the eye. If the aqueous grows turbid, and hypopion follows, tapping the anterior chamber with a fine needle,

and letting off the aqueous, will often do good, or if there is pus between the lamellæ of the cornea, Sämesch's operation, page 39, will frequently give great relief.

When abrasions of the cornea take on these unfavourable symptoms, as they frequently do, it is usually on account of some condition of the patient's health specially unfavourable for the repair of injuries. Too great plethora, anæmia, a constitution broken by drink and rough living, or one enfeebled from some exhausting cause, such as suckling, may retard recovery, or induce symptoms dangerous to the eye. Such conditions of system must regulate our constitutional treatment. In the one class of cases moderate antiphlogistic treatment will be called for, whilst in the other the patient must be propped up by stimulants, and all irritation be allayed by sedatives. Opiates in these cases are of the greatest service, and a few minims of the liq. opii sedativ. combined with liq. cinchonæ given three or four times a day will sometimes completely change the character of the inflammation, and induce a healthy action and a speedy recovery. If it should be preferred to give the opiate in one dose at night, it should be sufficient in quantity to produce sleep, as a single moderate dose will excite rather than tranquillize.

PENETRATING WOUNDS OF THE CORNEA AND SCLEROTIC.—A small incised wound of either the cornea or sclerotic, provided none of the other textures of the eye are injured, is almost harmless: it rapidly heals, and no after-inconvenience is experienced. We have evidence of this in the numerous operations on the eye, and especially in those for cataract and iridectomy. Wounds, however, which are produced by accident, are generally complicated by either contusion, hæmorrhage, prolapse of the iris, laceration of the lens capsule, or loss of vitreous; and sometimes by all these casualties together. The danger of a corneal wound is immensely increased if it should extend into the ciliary region, as there is then great risk of the other eye becoming affected with sympathetic ophthalmia.

Perforating wounds in the sclerotic are much more fatal to the eye than similar wounds in the cornea; they are more difficult to heal, and they will occasionally remain patulous, and this especially if the cut be in the lower region of the eye, and there has been a loss of vitreous at the time of the accident.

This occasional incapacity to unite is due to the continued gaping of the wound, caused partly by the rigid cup-like sclerotic being unable to adapt itself to the sudden diminution of bulk induced by an escape of vitreous; and partly also by the continued draining of the vitreous through the wound, which tends to keep the cut edges apart by preventing the eye from being again plumped out by an abundant secretion of aqueous. If however, the wound in the sclerotic be closed by a fine

FIG. 14.

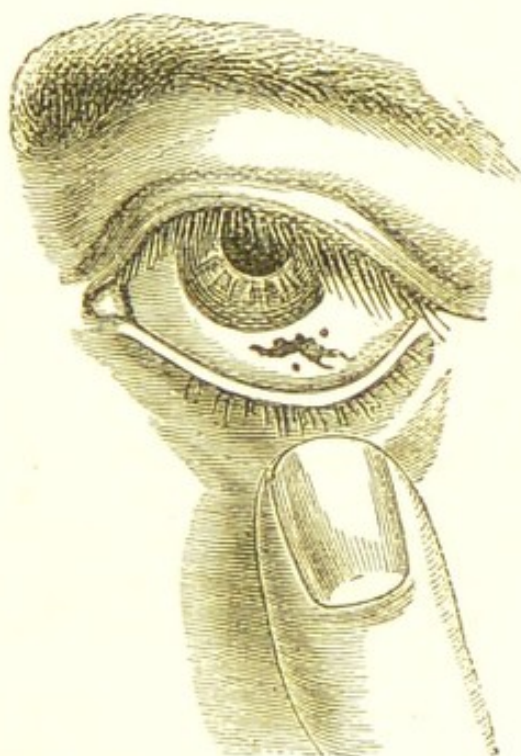


Fig. 14 represents an eye with a gaping wound of the sclerotic, which was successfully treated with a fine suture.

suture, and the escape of vitreous be thus arrested, union will at once take place.

The suture should be of the finest silk, to each end of which a small needle should be fastened so as to allow of the silk being drawn through each edge of the wound separately, and from *within* outwards.

General Treatment.—The primary treatment must be soothing; the patient should be kept in a subdued light, and the injured eye should be closed, and a compress bandage (F. 3) applied over the lids. Two or three leeches should be applied to the temple, thus anticipating rather than waiting for any excessive action which may

arise, and one or two drops of a solution of atropine (F. 15) should be dropped into the eye twice a day, each time the compress is readjusted. After a few days the compressing bandage may be discontinued, and warm or cold applications to the eye may be substituted in accordance with the feelings of the patient. Belladonna may be used either in the form of a cold lotion or a warm fomentation.

The Constitutional Treatment will vary somewhat with the condition of the patient. It must, however, be remembered that affections of the cornea, even though they are traumatic, will not bear much depletion. The inflammation which follows such injuries is reparative in its action, and requires to be watched and kept from exceeding its proper limits, rather than that means should be taken completely to check it, as the part may perish from a want of vital action, as well as from an excess of energy.

If the patient is robust, a brisk purgative (F. 113—115) may be prescribed, with some saline or diaphoretic medicine (F. 65, 66). A regular antiphlogistic course is seldom if ever required. A moderate, well-regulated diet, the avoidance of more stimulants than the case demands, and rest both to the eyes and body, place the patient in the condition most favourable for recovery. Pain in the eye sufficient to prevent sleep should be relieved by opiates, taking care at the same time that there is a regular daily action of the bowels.

In delicate and feeble patients it may be necessary to order from the very commencement a liberal diet and a certain amount of stimulants; and to prescribe tonics, such as the mineral acids with cinchona, or quinine (F. 75, 79), combining a few minims of liq. opii with each dose, to allay the constant irritability which injuries to the cornea often excite in such patients; or the opiate may be given in one full dose at bedtime.

For wounds of the cornea complicated with prolapse of the iris, or wound of the lens, see Articles PROLAPSE OF THE IRIS, and TRAUMATIC CATARACT.

RUPTURE OF THE EYE THROUGH THE SCLEROTIC.—This is the most severe injury that can happen to the eye. It either destroys the eye at once, or else so impairs it that it seldom sufficiently recovers to be of much service. It is usually caused by blows on the eye with the

fist, or with some blunt or semi-blunt instrument, or by the patient falling and striking his eye against some projecting object. The exact spot at which the eye will burst depends partly on the situation of the point which receives the force of the blow; still the locality in which the rupture takes place is so frequently the same that the coincidence must be due to more than mere accidental circumstances.

The split in the sclerotic is almost invariably near the margin of the cornea, following somewhat the direction

FIG. 15.

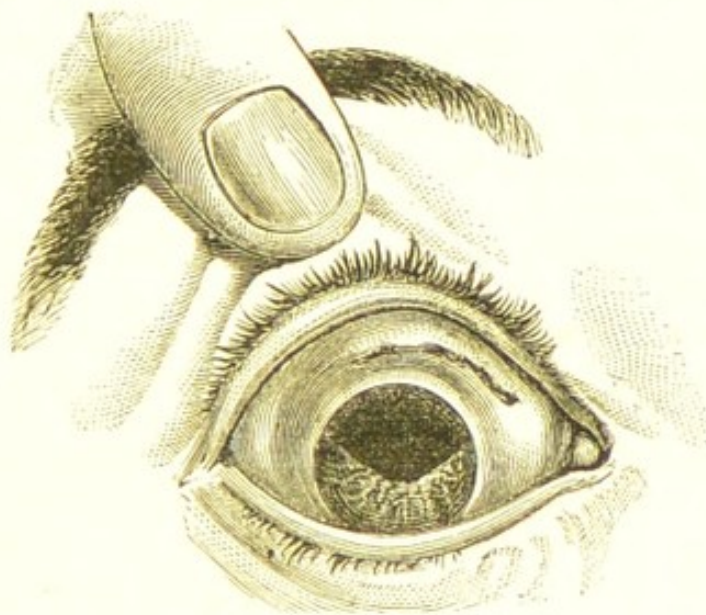


Fig. 15 represents the appearance of an eye which had been ruptured through the sclerotic.—There was a dark cicatrix in the upper and inner region of the eye, marking the extent of a rupture in the sclerotic. The upper half of the iris was wanting, having been carried away by the lens, which had been extruded through the rent in the sclerotic at the time of the injury.

of its curvature, about one-sixteenth to one-eighth of an inch distant from it, and immediately anterior to the insertion of the recti muscles. The rent most commonly occurs in the horizontal diameter and upper region of the eye, in a line extending inwards from between the margin of the cornea and the superior rectus, as shown in Fig. 15. The next most frequent site is towards the inner side, between the cornea and the internal rectus. It is comparatively seldom that it occurs to the lower or outer side of the cornea. If the rent be either to the inner or the

outer side of the cornea, the split is more or less vertical, thus following the curve of the cornea.

The cornea itself may be, and is frequently, ruptured by blows on the eye; but the injury, when confined to the cornea, is usually less severe and the result less disastrous than when the rent is through the sclerotic. A blow to rupture the sclerotic must be direct, or nearly so, and inflicted with great force; whereas a side or glancing one will split the cornea.

In rupture of the sclerotic, the injury is unfortunately not confined to the laceration only of this coat. The force which is required to produce it is so great that all the tissues within the eye suffer more or less. A portion of the iris is often prolapsed through the wound, and in some cases the greater part or even the whole of the iris is detached and shot out with the lens. The lens is usually dislocated;—most frequently it is jerked out through the wound, and escapes unnoticed.

There is generally free hæmorrhage from the different structures of the eye involved in the injury. From the torn iris and ciliary processes blood is usually effused into the anterior chamber and into the vitreous; and from the ruptured choroidal vessels blood clots are formed between the choroid and retina, and frequently also between the choroid and sclerotic. Vitreous humour may escape from the wound at the time of the accident, and occasionally in a sufficient quantity to cause a partial collapse of the globe.

Prognosis.—Our prognosis in cases of rupture of the eye must always be very unfavourable; the wound is a contused and lacerated one—the most unfavourable for primary union—and it is in the ciliary region, the part of the eye worst suited for the reception of injuries.

There are, however, cases in which a certain amount of sight is regained after a rupture of the globe through the sclerotic, and in my work on “Injuries of the Eye” I have recorded the history of patients who after a rupture of the globe and dislocation of the lens from the eye have recovered sufficient sight to be able to read with a lens No. 20 of Jaeger’s test types.*

Treatment.—When the patient is seen shortly after the accident which has ruptured the sclerotic, it is often diffi-

* Injuries of the Eye, Orbit, and Eyelids, p. 266.

cult to ascertain the exact amount of damage the eye has sustained, as the anterior chamber is usually filled with blood, and the deeper parts of the eye thus masked from observation. In such cases it is well to watch the patient and to wait a few days before deciding on the ultimate course to be adopted. Two or three leeches should be applied to the temple of the injured side, and repeated in twelve or twenty-four hours if the eye is very painful. Soothing applications afford the greatest relief, and a double fold of linen wet with the opium or the belladonna lotion (F. 40, 43) may be laid over the closed lids. If the eye progresses favourably, towards the end of the week the blood in the anterior chamber will have been sufficiently absorbed to allow of a more accurate examination being made. The patient, though unable to discern objects, ought now to have a fair perception of light; failing to possess this, a very unfavourable prognosis must be formed.

If after a fair trial of treatment the eye is found to be irreparably destroyed for all purposes of vision, my own feeling is, that it is by far the safest and wisest plan to remove it; a long period of certain anxiety will be thus saved; all further suffering will be ended, and the safety of the other eye will be secured.

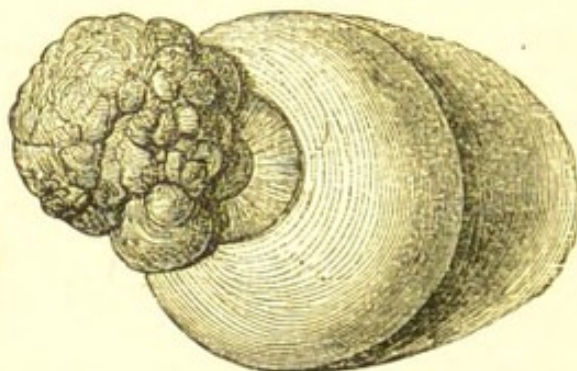
There are, however, certain cases of rupture of the globe in which the injury has been so extensive that the eye has been manifestly destroyed at the time of the accident. A severe rent in the sclerotic or cornea, with extrusion of the lens, and a portion of the iris and choroid, together perhaps with a collapsed or softened state of the globe from a loss of vitreous, would render any attempt to preserve the eye not only futile but trifling. After such an injury the only proper treatment is at once to excise the globe.

SARCOMA OF THE CORNEA AND SCLEROTIC is a rare affection. It usually commences as a small warty mass near the margin of the cornea. At first it may remain almost stationary, but after a time it usually takes on rapid growth, and compels the patient to seek advice. Occasionally, these warty tumours bleed, and the hæmorrhages recur so often, and to such an extent, as to endanger life. They are sometimes very painful.

The prognosis is very unfavourable: if excised, they almost invariably recur, and if allowed to remain they

will probably infect other and distant organs. In three cases which have been under my notice, the growth was excised, but it soon returned, and in each the eye had ultimately to be removed. In one of these cases the disease afterwards recurred in the orbit. Examined under the microscope, the structure of these tumours is that of the round and spindle-celled Sarcomas.

FIG. 16.



The woodcut Fig. 16 represents an eye with a warty sarcoma, which I removed from a patient æt. 62. He suffered from excessive pain, and frequent hæmorrhages from the tumour. The case is reported in the "Pathological Transactions," vol. xxvi. p. 179.

Treatment.—If the patient is seen early, when the disease is in its infancy and very small, it may be excised; but if it recur the eye should be removed. It is the only chance for the patient. If the growth is large when first seen by the surgeon, the eye should be removed.

CHAPTER III.

DISEASES OF THE IRIS AND VITREOUS HUMOUR.

IRITIS, OR INFLAMMATION OF THE IRIS, may be a *primary disease*, or it may be *secondary* to an inflammation of one or other of the coats of the eye.

Primary Iritis may arise—1. From some constitutional taint, as syphilis, rheumatism, or gout. 2. From sudden exposure to cold. 3. From an injury to the eye, which may be either mechanical or chemical, and to this form the term *traumatic* is applied.

Secondary Iritis is caused by the extension of an inflammation from one of the tissues of the eye with which the iris is connected, as in corneo-iritis and choroido-iritis; the first word in each name indicating the site in which the disease commenced. Primary iritis may also in its turn implicate *secondarily* the neighbouring structures; thus, we have irido-cyclitis and irido-choroiditis. In the first-mentioned case, the ciliary body has become secondarily involved; and, in the second, the choroid. Some authors have classified iritis in accordance with the inflammatory exudation which is supposed to characterize each form of the disease, and have described iritis as plastic, serous, and suppurative. It should, however, be remembered that iritis is seldom either solely plastic, serous, or suppurative; in rheumatic and syphilitic iritis we have effusions both of serum and lymph; and traumatic iritis is often at first serous and afterwards suppurative. I prefer, therefore, where it is practicable, to prefix to the term iritis the name of its exciting cause, as it indicates the course of treatment to be adopted. I shall describe, therefore, in sections, the following varieties of the disease, and shall point out the peculiarity of the inflammatory exudations in each.

- | | |
|------------------------|-----------|
| 1. Syphilitic | } Iritis. |
| 2. Rheumatic and gouty | |
| 3. Serous | |
| 4. Suppurative | |
| 5. Traumatic | |

Iritis may be either acute or chronic: but whichever it is, its symptoms and progress are modified by the cause which produced it.

GENERAL SYMPTOMS OF IRITIS.—The aqueous becomes yellow and serous, and as the disease advances it frequently grows turbid from flocculi of lymph or pus which will sometimes sink to the bottom of the anterior chamber, forming hypopion.

The iris loses its striated appearance from lymph effused on its surface and into its texture; its colour becomes consequently changed, and its brilliancy is dulled. A blue or a grey iris assumes a greenish hue, and the darker irides grow of a rusty or brownish red. The change of colour of the iris at the commencement of the attack is often more apparent than real, and is

due to the iris being seen through a yellow serous aqueous, which imparts to a blue or a grey iris a greenish tinge, but in the more advanced stages the altered colour and loss of striation are dependent on fibrinous effusion.

The pupil is contracted and sluggish in its action, and the pupillary margin soon contracts adhesions to the capsule of the lens, at first only at points, so that when dilated with atropine, the unattached parts only being acted on, the pupil assumes a jagged irregular outline. But if the disease be unarrested by treatment, the whole pupillary margin becomes sealed to the lens capsule, forming what is termed *complete synechia*; and so firm is the bond of adhesion that atropine will frequently fail to dilate any portion of the pupil. The disease still progressing, lymph is effused on the capsule of the lens within the pupillary space.

The Vascularity of the Eye in Iritis.—The conjunctival surface is generally suffused, and in some cases there is great redness with slight œdema; but the chief seat of the increased vascularity is in the ciliary vessels, which are seen as a red zone around the cornea. This vascular ring is one of the early symptoms of iritis, and one of the most constant.

In severe cases the increased vascularity of the iris is so great that distended varicose vessels may be often seen with the unaided eye coursing along the surface of the iris.

The impairment of vision is always considerable, and it increases as the disease advances. It is due to the following causes—the turbid aqueous, the lymph on the capsule of the lens in the pupillary area, and frequently also to the impaired power of accommodation caused by an extension of the inflammation to the ciliary body.

The degree of pain in iritis is very variable: in some cases it is slight, whilst in others it is most acute, and forms one of the prominent symptoms. The pain is of a neuralgic character—in the eye, around the brow extending upwards over the side of the head, and downwards along one side of the nose. In syphilitic iritis the pain is usually slight, whilst in the rheumatic form it is often very intense.

Intolerance of light is not as a rule a marked symptom in iritis. There is generally some photophobia, but it is seldom that it amounts to the intense dread of light

which is witnessed in some of the affections of the cornea. To this, however, there are occasional exceptions; and in a few cases of rheumatic and traumatic iritis I have seen as much photophobia as is met with in the most acute corneitis.

In iritis there is a strong tendency to recurrence. An eye which has once suffered is rendered specially liable to another attack, and this is peculiarly the case in the rheumatic form of the disease. So frequent, indeed, are the recurrences of this variety of iritis, that by some it is designated by the special name of *recurrent iritis*. Such are the general symptoms of iritis; but any one of them may be modified by the cause which has given rise to the disease. I will now briefly consider some of the characteristic and diagnostic symptoms of the special forms of iritis already mentioned at page 83.

SYPHILITIC IRITIS usually first appears during the secondary eruption, or just as it is beginning to fade. It is characterised by a peculiar tendency to the rapid effusion of lymph, which, if not arrested by appropriate treatment, soon leads to permanent damage of the eye. The effusion of lymph is often so copious that nodules of it as large as millet seeds will be seen along the margin of the iris, and sometimes the deposits are in single isolated patches of a greater size. I have seen a third of the iris covered with one solid mass of lymph, and the pupil completely occluded by it. I have never known a case of syphilitic iritis go on to suppuration. The pain and dread of light are not usually marked symptoms, and certainly are not so severe as is commonly found in the rheumatic form of the disease.

Treatment of Syphilitic Iritis—Mercury is here imperatively called for. It should be given in doses sufficiently large and frequent to bring the patient quickly under its influence, but as soon as the gums begin to grow tender and spongy, the quantity should be diminished so as to avoid anything like profuse salivation. A piece the size of a nut of the unguent. hydrarg. may be rubbed into the axilla night and morning; or a pill with calomel and opium (F. 119) may be given twice a day. If the patient is feeble, quinine may be prescribed at the same time, and this may be conveniently ordered in a pill or mixture (F. 79) during the day, whilst the mercurial inunction is

used night and morning. If the patient has already been salivated before he first comes under treatment, the iodide of potassium mixture (F. 91) should be given, and a slight mercurial action may be kept up by a little of the unguent. hydrarg. c. belladonna (F. 126) being rubbed into the brow and temple, and allowed to remain on during the day; or, if the patient can bear it, pil. hydrarg. subchlorid. comp. gr. 5 may be ordered every other night. Pain and restlessness should be relieved by repeated doses of opium. Half a grain of the extract of opium may be ordered every four or six hours as required. It often seems to exercise a marked beneficial influence in controlling the inflammation. When all the effused lymph has been absorbed, and the iritis has nearly subsided, the mercurial medicines should be omitted, but the iodide of potassium should be continued for two or three months, combined with a bitter tonic, or if the patient is anæmic, with some preparation of iron (F. 92). If the iritis recur after some months, or if it assume a chronic form, a mixture of the perchloride of mercury with the iodide of potassium (F. 98) will be often found of great service. Atropine is essential in the treatment of every form of iritis, and should be ordered at the very commencement of the attack, and persevered in during its continuance. A solution of the strength of gr. 2 ad aquæ 3 i should be dropped into the eye twice or three times a day. The object is to keep the pupil dilated, and by so doing to tear through any adhesions which may have formed between it and the lens capsule. It also allays irritation, and by paralysing the accommodative power places the eye in a state of rest. When the atropine fails to give ease, or acts as it does in exceptional cases as an irritant, the belladonna lotion (F. 40) may be substituted.

If, however, the pupil should become closed by the effusion of lymph on the pupillary area of the lens capsule, and by posterior synechiæ, an iridectomy should be performed when the eye is free from inflammation, for the purpose of making an artificial pupil, and for preventing the recurrence of the iritis.

RHEUMATIC IRITIS is chiefly a serous inflammation; some lymph is effused, sufficient to cause tags of adhesion between the iris and lens capsule, or even in severe cases to produce a complete closure of the pupil; but it is not poured out as in the syphilitic form in

quantities to be easily seen on the surface of the iris with the naked eye. The aqueous is yellow and serous. The apparent change of colour in the iris in rheumatic iritis is often mainly due to the yellow aqueous through which it is seen. I have frequently noticed the greenish-coloured iris at once restored to its normal grey or blue, when the yellow aqueous escaped, either from a puncture in paracentesis of the cornea, or in the operation of iridectomy. Rheumatic iritis is often associated with rheumatism elsewhere, such as pains in the limbs or joints; or the patient has suffered previously from rheumatic fever. In some cases where there are frequent recurrences of iritis, the patient is never completely free from rheumatic pains; if the limbs and the joints are exempt, the soles of the feet or the heels are tender.

Rheumatic iritis is very recurrent, and although the eye may recover from each attack, yet fresh traces of the disease are each time left, which greatly cripple if they do not eventually destroy the eye. The pain is severe and neuralgic, and sometimes very intense. There is also frequently a great dread of light, which is often quite out of proportion to the severity of the attack. I have had patients with rheumatic iritis suffer such intense photophobia that they were unable to tolerate a ray of light in their room, and for a time lived in absolute darkness. This excessive dread of light is, however, exceptional.

Gonorrhœal rheumatism is often followed by a serous iritis of a very recurrent nature, and in no way differing from the ordinary rheumatic type of the disease. In one patient who was under my care, the recurrence of the iritis was usually preceded by a return of the urethral discharge, which lasted for a few days and then disappeared.

Treatment.—Rheumatic and gouty iritis do not require the active mercurial treatment recommended for the syphilitic form of the disease. Iodide of potassium in small doses combined with the bicarbonate of potash (F. 91) may be given during the day, and at night a pill with calomel gr. 1, pulv. ipecac. comp. gr. 5; or the unguent. hydrarg. c. belladonnâ (F. 126) may be rubbed daily into the temple. In some cases this treatment will fail to give any relief, and quinine in 2-grain doses may then be ordered with great benefit; or the quinine may be combined with the tinct. ferri perchlorid. (F. 81). When there

is great photophobia and pain in the eye, the quinine, or quinine and iron treatment, together with a mild mercurial inunction into the temple, will be found most useful; to relieve the pain, the fourth or a third of a grain of the acetate of morphia (F. 30) may be injected subcutaneously into the arm, or half a grain of the extract of opium may be given every four or six hours. Turpentine has been prescribed with advantage in obstinate cases of *non-syphilitic iritis*. The ol. terebinth. may be ordered in small and repeated doses as in (F. 102); or the Chian turpentine may be given in 5-grain doses three times a day. During the whole of the attack of iritis the pupil should be kept dilated either by means of atropine, or with the belladonna lotion (F. 40).

If the pupil should become partially or completely closed by adhesions between the pupillary border of the iris and the lens capsule, an iridectomy should be performed. The removal of the portion of iris tends to prevent a recurrence of the iritis, and in cases where there is complete occlusion of the pupil it greatly improves the sight. The time for the operation should be in the interval between the recurrences of the iritis when the eye is quiet.

GOUTY IRITIS.—Mr. Jonathan Hutchinson has described a form of iritis which he has noticed in the children of gouty parents. He says: "Its subjects are usually the immediate offspring of those who have suffered from true gout. The iritis occurs at an early age, and differs from the other forms of arthritic iritis in being insidious and persistent rather than paroxysmal. Without any attack of acute inflammation, adhesions quietly form between the iris and the capsule of the lens. These gradually increase in number, the pupil first becomes excluded and afterwards occluded, and, as a last stage, effusion behind the iris completes the disorganization of the eye. I have as yet observed it pass on to complete destruction of sight in only a single instance. In the latter stages I believe that opacities in the vitreous usually form, but, owing to the blocking up of the pupil, it is not always easy to demonstrate them. The malady in question usually begins in but one eye, and advances to almost entire loss of sight in it before attacking the other. Ultimately, however, I believe that both are almost always affected. Although I wish to assert strongly that it differs from

all the common types of arthritic iritis in having no paroxysms, and in being insidious and for the most part painless, I by no means intend to deny that it is liable to exacerbations and periods of improvement. Thus, the patient will usually complain that the eye feels hot and uncomfortable at the time that the adhesions are forming, and sometimes there may be a slight and transitory congestion of the conjunctiva. These symptoms of inflammation are comparatively rather than absolutely absent. I have thus far found the disease remarkably intractable under treatment."*

SEROUS IRITIS—*Aquo-capsulitis*—*Keratitis punctata*—comes on frequently without any apparent cause, and is most commonly seen in young people, and in those who present either the markings of the teeth or the creasings about the mouth which point to some hereditary taint of syphilis. It is characterised by an increased secretion of the aqueous, which is usually somewhat turbid, and by small punctated opacities on the posterior surface of the cornea. These opacities are caused by a deposit of small conical masses of lymph from the aqueous humour.

Symptoms.—Diffused haziness of the cornea with small dotted opacities on its posterior surface. The anterior chamber is deepened from an increased secretion of aqueous, which is serous and slightly turbid. The iris is a little discoloured from being viewed through a yellowish medium, and the pupil is either of about its normal size or slightly dilated. In this respect serous iritis shows a marked difference from all the other forms of inflammation of the iris, and it is to be attributed to the increased tension which is so often met with in this affection, and also to its being frequently associated with disease of the deeper structures of the eye. There is increased vascularity, especially in the ciliary region. Occasionally there is much pain, dread of light, and lachrymation, but these are by no means constant symptoms, as in some patients they are excessive, whilst in others one or all may be almost wanting.

Treatment of Serous Iritis.—Small doses of the iodide of potassium combined with iron (F. 92), or with a

* Lancet, Jan. 1, 1873, p. 1

bitter tonic (F. 91), may be prescribed; or if the patient is very feeble, quinine with iron (F. 80), or the mineral acids with bark (F. 75) will be better suited. In children the syrup of the iodide or the compound phosphate of iron (F. 142, 146) will be often found beneficial, with small alterative doses of the hydrarg. cum cretâ cum rheo once or twice a week. The pupil should be kept under the influence of atropine, and the eyes frequently bathed with the belladonna lotion. The internal administration of mercury, except in occasional alterative doses, is prejudicial. If the eye should become glaucomatous, an iridectomy should be performed.

SUPPURATIVE IRITIS is generally consequent on an injury, or it may follow an operation on the eye, but it may also occur without any very apparent cause in patients who are in a low state of health. The disease is characterised by a rapid inflammatory exudation which soon fills the pupil. The iris at first appears hazy, and the markings of it indistinct or lost; its surface then becomes partially or entirely coated with a film of puro-lymph. Particles of lymph and pus gravitate to the bottom of the anterior chamber, and constitute the condition known as hypopion. Up to this stage the cornea will often continue clear and bright, and if the iritis be now arrested, the eye may recover, but the pupil will be closed by adhesions to the capsule of the lens, and by a false membrane. Unfortunately the disease usually progresses, the cornea next grows steamy and dull, it then ulcerates in part, pus is effused between its laminae, and onyx is formed; perforation will follow, and the eye will be probably, for all useful purposes, lost. (For treatment, see **TRAUMATIC IRITIS**, next Section.)

TRAUMATIC IRITIS is due to an injury, generally a penetrating wound of the eye, which has involved either the iris, or the lens, or both. It is most apt to follow when the iris is either contused or lacerated, or partially strangled, as in cases of prolapse.

Wounds of the lens are peculiarly apt to cause iritis; the lens swelling from the imbibition of the aqueous presses on the back or uveal surface of the iris, and acts as a most powerful irritant. We have illustrations of this occasionally after needle operations for soft cataract, or after the extraction of hard cataracts, when fragments

of cortical matter remain after the lens has been taken away.

Traumatic iritis may occur in two forms—the acute and chronic.

The acute usually comes on within the first four or five days after the injury, and is ushered in with œdema of the lids and chemosis of the conjunctiva. The inflammation may be *plastic*, producing a rapid exudation of lymph into the pupil and on to the surface of the iris, but more frequently it is *suppurative* (see preceding Section, p. 90).

Acute traumatic iritis may terminate in three ways:—
1. Under suitable treatment the eye may recover; but as the result of the inflammation, there will probably remain a more or less complete closure of the pupil from a false membrane, with adhesions of the pupillary border of the iris to the lens capsule. 2. The acute symptoms may gradually subside, and then become chronic. 3. The eye may be destroyed by an extension of the inflammation to the cornea, or to the deeper structures—the choroid and retina.

The chronic form usually commences from one to three weeks after an injury. It is frequently seen after operations for the extraction of cataract, and especially if the iris has been much pressed upon in the passage of the lens from the eye. It is always accompanied with photophobia and lachrymation, and the edges of the lids often become puffy, thickened, and excoriated. The aqueous becomes serous and the striation of the iris indistinct. The pupil is but slightly and irregularly acted on by atropine, and there is a slow dull pain in the eye. This chronic condition will last frequently many weeks, and it yields but slowly to treatment.

Treatment.—In traumatic iritis mercury is seldom required, and in the early stages should not be prescribed. The iritis is due to an injury, and time and rest must be given to allow the eye to recover from the mischief it has sustained. Soothing applications to the eye are beneficial. The solution of atropine (F. 15) should be dropped into the eye two or three times daily, and a fold of linen wet with the belladonna lotion (F. 40) may be laid over the closed lids. If there be much pain, two or three leeches should be applied to the temple, and these may be repeated if necessary. The bowels should be freely acted on by a mild purgative, and if there be

much constitutional irritation, an effervescing or saline mixture (F. 66, 68) may be given during the day, and an opiate at night to relieve pain. After the first acute symptoms have passed away, the patient will generally be benefited by the mineral acids with bark (F. 75). If the iritis should become chronic, a slight mercurial inunction into the temple will sometimes afford relief. If the iritis be *suppurative*, and there is hypopion, warm applications will afford the greatest comfort, and the fofus belladonnæ (F. 9) or fofus papaveris (F. 10) may be ordered. When there is hypopion and great pain, paracentesis of the cornea will often be found very beneficial.

CYSTS OF THE IRIS usually occur after an injury to the eye, generally a penetrating wound, from which the iris has suffered either by prolapse or puncture; but they are occasionally met with in eyes where no assignable cause for their origin can be traced. They are round or oval in shape, and generally filled with a transparent fluid. Although apparently on the surface of the iris, yet they are developed in its substance between the anterior or muscular, and the posterior or uveal layers of the iris. Mr. Bowman, in his "Lectures on the eye,"* says—"It is evident in this disease that the muscular tissue of the iris is expanded over the fluid;" and further on, "that the uvea (which is always dark) is not protruded with the muscular tissue, but separated and thrown posteriorly; for if it were in front of the fluid of the vesicle, its pigment would be obvious enough in the attenuated tissue, whereas it is not visible there."

In a case which came under the care of Mr. Hulke, the cyst was pedunculated, and he succeeded in removing it entire. In the microscopical examination which he afterwards made, he was enabled to confirm the description previously recorded by Mr. Bowman. He found that "the cyst wall was a delicate, homogeneous membrane, varying from $\frac{1}{4300}$ " to $\frac{1}{8600}$ " in thickness. Its outer surface was overlaid by a net of fusiform cells, identical with those of the contractile tissue of the iris; and its inner surface was lined by a pavement epithelium, the cells of which differed much in size in different parts of the cyst."†

* Lectures on the Parts concerned in the Operations on the Eye, 1849, p. 76.

† Royal London Ophthalmic Hospital Reports, vol. vi. p. 14.

A cyst of the iris may exist without giving the patient any inconvenience, but if it increases so as to encroach upon the pupil, it at once produces impairment of vision. It may, however, excite great irritation, and in the case already mentioned as having been reported by Mr. Hulke, it gave rise to sympathetic symptoms in the other eye.

Treatment.—Excise the cyst with the portion of iris to which it is attached. This is best accomplished by the ordinary operation of iridectomy, taking care that the cyst is drawn out of the wound before the segment of iris is cut off with the scissors. Puncturing the cyst with a fine needle has been tried, but with only temporary success, as the cavity is soon refilled.

CYSTICERCUS ON THE IRIS.—Cysticerci may appear on the iris, in the vitreous, or behind the retina. They look like transparent vesicles, with a slight constriction in one part, dividing the head from the body. When on the iris, the hydatid cyst should be removed, and this may be readily accomplished by excising the portion of iris on which the vesicle is implanted, as in the operation of iridectomy. An interesting example of this rare disease is recorded by Mr. T. Pridgin Teale in the Royal London Ophthalmic Reports, vol. v. page 320. A cysticercus within the eye must be regarded as a very grave affection; and if it be detected in the vitreous, an attempt should be made to remove it, even though the endeavour to do so would necessitate a preliminary extraction of the lens, as in the case recorded by Von Graefe.*

MELANOTIC SARCOMA will occasionally spring from the iris, although the usual site for this growth is from the choroid. When the disease has been satisfactorily diagnosed, there should be no delay in excising the eye. See INTRA-OCULAR TUMOURS.

FUNCTIONAL DERANGEMENTS OF THE IRIS.

MYDRIASIS, or dilatation of the pupil, may arise from intra- and extra-ocular causes, and also from the action of certain drugs on the sphincter pupillæ of the iris.

The intra-ocular changes, or morbid states of the eye, which produce mydriasis, are—increased or glaucomatous

* Archiv für Ophthalmologie, iv. ii. 171.

tension of the globe; diseases of the choroid or retina; and injuries which affect the ciliary nerves either by laceration or by pressure on them by a blood-clot.

The **extra-ocular** causes are complete paralysis of the third nerve, or palsy only of those filaments of it which supply the pupil; disease of the optic nerve beyond the eye; or the presence of a cerebral tumour or some other disease of the brain. It is often very difficult to ascertain the cause of mydriasis, as it will frequently occur suddenly in one eye, without any other paralytic symptoms, and with only a very slight impairment of vision. In this condition I have known an eye remain for many years, the pupil continuing fixedly dilated a third or a half more than that of the other eye, and without any further evidence of disease being manifested. In such cases it is probable that there is no absolute paralysis of the filaments of the third nerve which supply the iris, but simply a preponderance of power in the radiating over the sphincter fibres, possibly due to some reflex irritation. This theory is strengthened by the fact that atropine will usually induce a further dilatation, showing that the sphincter of the iris still exerted some control in limiting the size of the pupil. With mydriasis there is diminution and sometimes complete loss of the accommodative power of the eye. To ascertain if the impairment of vision be due solely to the dilated pupil, it is only necessary to try the effect of making the patient look with the affected eye through a pinhole aperture in a piece of card held close to the eye, when, if there be no loss of accommodation and the retina be sound, the acuteness of vision will be restored.

Treatment.—In some cases of mydriasis I have found great benefit from the guttæ eserix (F. 18) dropped once daily into the eye. It will sometimes give complete relief to the sense of aching caused by ordinary daylight, and also benefit the sight. The mist. potass. bromid. c. ferro (F. 100) will often do good.

MYDRIATICS.—Of the drugs which exercise a dilating influence on the pupil, the most prominent are sulphate of atropia, extract of belladonna, sulphate of duboisine, sulphate of daturine, and hydrobromate of homatropine.

The sulphate of atropia prepared from belladonna is the most rapid and efficient of all the mydriatics we at present possess. Its effects are produced by the solution

of atropia permeating the cornea, and coming into direct contact with the nerves of the iris. This has been proved by tapping the anterior chamber of an eye under the influence of atropine, and with the aqueous dilating the pupil of another eye. Its action is chiefly if not entirely due to its paralyzing the filaments of the third nerve, which go to the iris, and thus producing complete relaxation of the sphincter pupillæ. From Ruete's observations it would appear that atropine also stimulates the radiating or dilating fibres of the iris to contract, as he found that the widely dilated pupil which accompanies complete paralysis of the third nerve would expand further under the influence of atropine. In practice the sulphate of atropia is preferred to the alkaloid, on account of its greater solubility. Applied to the eye in solution, it is in most cases a direct sedative, but after long-continued and frequent instillation, it will often create a good deal of conjunctival irritation, and occasionally a granular condition of the conjunctiva, which will, however, generally subside after giving up the atropine. In exceptional cases it is a powerful irritant, and will give rise to acute inflammatory symptoms. I have related examples of the anomalous effects of atropine in a short paper in the *Ophthalmic Hospital Reports*.* They are no doubt due to some peculiar idiosyncrasy on the part of the patient which renders him intolerant of atropine. It has been suggested that the presence of some free acid is the reason of the sulphate of atropia acting occasionally as an irritant; but this theory is untenable, as the drug is a neutral salt.

Sulphate of daturine prepared from the *datura stramonium* is a very useful mydriatic in cases where the sulphate of atropine produces irritation. It is often tolerated without inconvenience when atropine cannot be borne.

Hydrobromate of Homatropine is a very good mydriatic. It is less liable to irritate the eye than the sulphate of atropine, and its effects on the pupil are far more transient. For these reasons it is specially useful for dilating the pupil for ophthalmoscopic examinations of the eye. The general properties of this drug have been well worked out by Dr. Ringer and Mr. Tweedy.* Gela-

* On some of the Anomalous Effects of Atropine on the Eye : *Royal London Ophthalmic Hospital Reports*, vol. vi. p. 119.

† *Lancet*, May 22, 1880.

tine discs of this drug are prepared by Savory and Moore, of New Bond Street.

Sulphate of Duboisine.—The mydriatic power of the *Duboisia myoporoides* was first accidentally discovered by Dr. Bancroft, but for the complete investigation of the properties of this drug we are indebted to Dr. Ringer and Mr. Tweedy.* It is the most powerful mydriatic we at present possess, and is of use in paralyzing the accommodation before testing the refraction of the eye. It must be used with caution, as the dropping of a solution of it into the eye is apt to produce poisonous symptoms which are very alarming to the patient. The symptoms occasioned by the drug are restlessness, hallucinations, giddiness, and, in extreme cases, loss of voluntary power of the extremities.

All the mydriatics have a tendency to favour, and will occasionally even produce, an increased tension of the globe. They should not therefore be used in glaucoma, nor in those affections of the eye in which there is any increase of tension.

MYOSIS, or contraction of the pupil, may arise from a spasmodic action of the sphincter pupillæ, or from a loss of power in the dilator or radiating fibres of the iris. It may be produced by hyperæsthesia or over-sensibility of the retina; or it may be acquired from the constant habit of working at minute objects, as in watchmaking, &c. The most frequent cause, however, of myosis is some affection of the spino-sympathetic filaments which supply the radiating or dilating fibres of the iris. Myosis is met with in disease of the upper part of the spinal cord—that portion of it which sends nervous filaments to the cervical sympathetic ganglia. Tumours in the neck pressing on the sympathetic nerves have been long known to produce myosis. Dr. Ogle† has reported a very interesting case in which the right carotid was tied by Mr. Henry Lee, on account of an aneurism in the right side of the neck. The right pupil was small (not contracted, however, so much as it might be), and not influenced by the light of a candle, whilst the left pupil was large and responsive to light. The man had been for nineteen years and a half a soldier, and had generally enjoyed

* *Lancet*, March 2, 1878.

† *Ibid.*, March 13, 1869.

good health until about five years before, when he was shot by a bullet, which passed through the outer third of the right clavicle, making its exit about an inch behind that bone. Between seven and eight weeks afterwards, the wound quite healed, and he rejoined his regiment in the field. Since that time he has had a series of abscesses in the neck. He was ultimately invalided to England, and sent to Netley, where he was found to have an aneurism in the neck, for which he was afterwards admitted into St. George's Hospital. In this patient the myosis was probably due to injury of the cervical sympathetic nerve.

Atropine has usually but little influence upon the contracted pupil; it may enlarge it slightly, but it will seldom dilate it widely, showing that the cause of the myosis in such cases is due to a more or less complete paralysis of the radiating fibres of the iris, which will not dilate the pupil even when the sphincter or circular fibres have been completely relaxed. The pupils of one or both eyes may be affected with myosis. I have seen several cases where both pupils have been contracted to the size of pins' heads, and have remained in this state for years without more annoyance than a slight diminution in the acuteness of vision. When myosis is dependent on some morbid state of the spino-sympathetic nerves, there is generally a great desire for strong lights, with which the patient is often able to read the smallest type; but in a subdued light the sight is often very defective. I have lately had a patient suffering from extreme myosis who literally surrounds himself at night with a blaze of artificial lights to enable him to read, whilst by day he sits with the full glare of the sun on his book.

Another defect which is occasionally met with in spinal myosis, is colour-blindness. Dr. Argyll Robertson has recently related in a pamphlet,* a very interesting case of spinal disease in which myosis and colour-blindness were prominent symptoms. He has also cited other instances of this peculiar impairment of sight as having been produced both by disease and injury of the spinal cord.

Treatment of Myosis.—No special line of treatment can be laid down for the cure of myosis, as it is dependent on so many and such varied conditions. An endeavour

* Eye Symptoms in Spinal Disease. Oliver & Boyd, Edinburgh, 1869.

should be made to ascertain the cause of the contracted state of the pupil, and according to the information thus gained the patient must be treated. A weak solution of atropine may be used once daily to the eye, and it may be continued, if it affords relief. It is seldom, however, that the use of mydriatics is of any service in myosis.

MYOTICS.—Of the drugs which exercise the power of contracting the pupil, the most efficient are extract of Calabar bean, sulphate of Eserine, and nitrate of Pilocarpine.

CALABAR BEAN—*Physostigmatis Faba*.—For the knowledge we possess of the peculiar properties of the Calabar bean we are indebted to Dr. Fraser and Dr. Argyll Robertson. The former gentleman in 1862 discovered its influence on the pupil; and the latter in 1863, its effects upon the accommodation of the eye.

The Calabar bean rapidly induces extreme contraction of the pupil, and a myopic state of vision, and this it does by stimulating the branches of the third nerve, and producing a temporary spasm of the sphincter pupillæ and ciliary muscle. In from five to ten minutes after the application of the drug the pupil begins to contract, and in from half to three-quarters of an hour it has reached its maximum effect. The pupil is then reduced to rather less than a line in diameter, and the eye is rendered myopic, the near and far points being approximated to the eye. These changes last for a variable time in accordance with the strength of the solution which has been used. The accommodative power is often restored in a few hours, whilst it will frequently take two or three days before the pupil will regain its normal size. The bean also possesses the power of counteracting for a time the influence of atropine. Thus, if a little of a strong solution is introduced into the eye whilst the pupil is dilated to its utmost with atropine, it will generally cause it to contract to its natural size, and sometimes even below it, if the dilatation of the pupil is due to a weak solution of atropine. This effect, however, of the bean is evanescent, and passes off in a few hours as the atropine resumes its sway over the pupil.

The best preparations of the Calabar bean are the sulphate of eserine and the extract of the Calabar bean.

Gelatine discs impregnated with either of these drugs are very efficacious.

SULPHATE OF ESERINE, prepared from the Calabar bean, is the most efficient myotic we possess. The solution (F. 18), when made with the freshly prepared sulphate, is of a light dirty-greenish colour, but it rapidly changes to a dark red. This decomposition does not affect its activity.

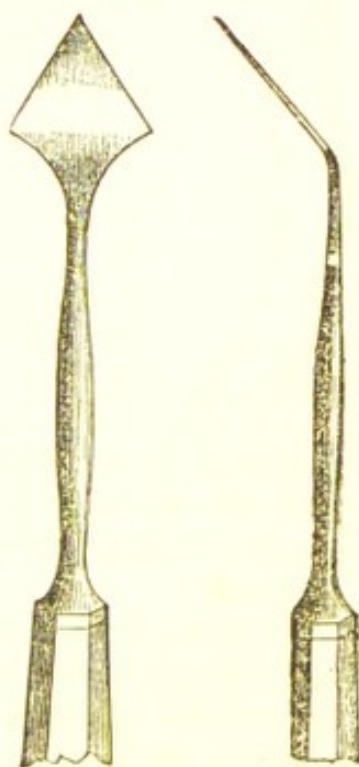
NITRATE OF PILOCARPINE is obtained from Jabonrandi (the leaves of a species of *Pilocarpus*). It is an efficient myotic, but is less active than eserine. It may be used in solution (F. 21), or in gelatine discs.

All the myotics have a tendency to reduce excess of tension of the globe. They are very valuable in cases of incipient glaucoma, and in those ulcerations of the cornea which are associated with increased tension.

OPERATIONS ON THE IRIS.

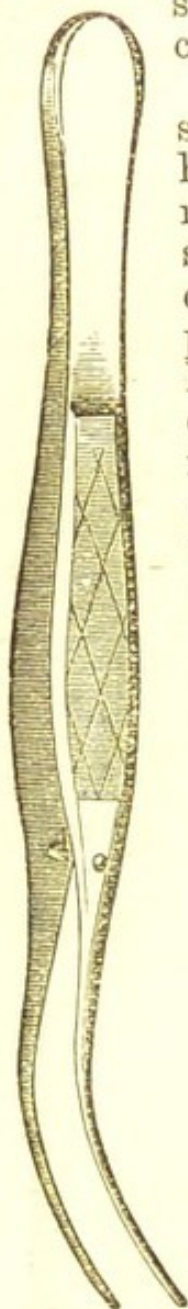
THE OPERATION OF IRIDECTOMY may be performed either with a narrow Graefe's cataract knife, or with a lance-shaped knife (Fig. 17). I very much prefer a Graefe's cataract knife, and now always use it, as with it there is less danger of wounding the lens, as the point of the knife is kept in front of the iris, and does not cross the pupil. A spring-stop speculum having been placed between the lids, the operator standing behind the head of the patient, seizes with a pair of forceps the conjunctiva close to the margin of the cornea on the nasal side, and with a narrow Graefe's knife enters its point in the outer and upper portion of the margin of the corneo-sclerotic junction, first directing it obliquely downwards towards the pupil until the point is seen in the anterior chamber; then turning the point slightly upwards, he traverses the rim of the anterior chamber in front of the iris for not more than a quarter of an inch, and makes his counter-

FIG. 17.



puncture, and then cutting abruptly upwards completes his section. The iris is next seized with the iris-forceps,

FIG. 18. drawn out of the wound, and cut off with iris-scissors close to the extreme edges of the incision.



If the iridectomy be performed with the lance-shaped-knife (Fig. 17), the spring-stop speculum having been placed between the lids, the operator standing behind the head of the patient, seizes with a pair of forceps in his left hand the conjunctiva and subjacent fascia of the eye, at a part near the cornea, opposite to that at which he is about to introduce the point of the iridectomy knife; whilst with his right hand he makes an incision in the sclerotic with a lance-shaped knife (Fig. 17) at about one line from the margin of the cornea, so that the point of it may enter the anterior chamber just in front of the ciliary attachment of the iris. In directing the blade of the knife across the anterior chamber, care should be taken to keep the point of the instrument slightly forwards, so as to avoid the risk of wounding the lens. The surgeon now hands over the forceps, which fixed the eye, to his assistant, who, if necessary, rotates the globe a little downwards, and steadies it whilst he excises a portion of the iris. If the iris is already prolapsed, as often happens, he at once seizes it with a pair of iris-forceps (Fig. 18); or, if not, he introduces the blades of the forceps through the wound, and makes them grasp the iris near the pupillary border, and then drawing a portion of it out of the wound, he cuts it off with a pair of fine scissors.

When the anterior chamber is so shallow that the iridectomy knife cannot be used without incurring the risk of wounding the lens, the incision in the sclerotic should always be made with a narrow Graefe's cataract knife.

If there be excessive dilatation of the pupil, as in cases of advanced glaucoma, it is well to cause its contraction by means of the Calabar bean before proceeding to iridectomy. A few drops of the guttæ physostigmatis fabæ (F. 20) or guttæ esericiæ (F. 18) may be dropped into the eye about one hour before the operation. With the pupil

contracted, the surface of the lens is protected by a broad band of iris, and the chance of its being pricked by the point of the knife is greatly lessened.

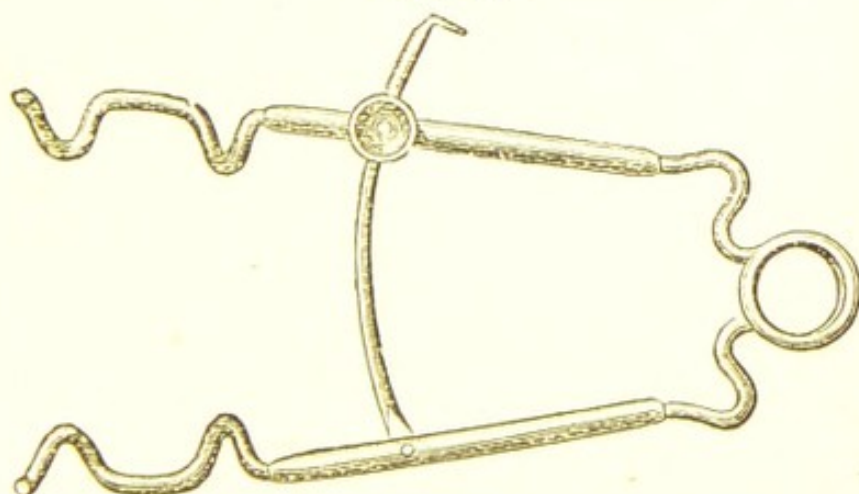
ARTIFICIAL PUPIL.—To gain the full benefit which an artificial pupil will afford in properly selected cases, the cornea should be first very carefully examined, and, if necessary, by oblique illumination with ophthalmoscopic light, to determine the part opposite to which an artificial pupil will be the most effective. In examining the cornea, the two points to be noted are—1, its transparency, and 2, its curvature: that part should be selected which is the most transparent, and which has the most normal curve.

The operation most in use for the formation of an artificial pupil is iridectomy; but there are many cases for which it is not suited, when one of the other methods may be selected, according to the special indications which the eye may present:—

1. With a broad needle and Tyrrell's hook.
2. By iridectomy.
3. By division of the iris with a pair of scissors.

1. **To make an Artificial Pupil with a Broad Needle and Tyrrell's Hook.**—The patient lying on a couch, a spring-stop speculum (Fig. 19) is to be introduced

FIG. 19.



between the lids, so as to keep them apart. The operator standing behind the head of the patient, with one hand seizes the conjunctiva and submucous tissue of the eye with a pair of forceps, so as to steady it, whilst with the

other he makes an opening in the extreme margin of the cornea with a broad needle. Having completed the incision, the broad needle is to be withdrawn, and

FIG. 20.



the eye being still held by the forceps, a Tyrrell's hook (Fig. 20) is to be passed *sideways* through the corneal wound into the anterior chamber and onwards across the iris to the pupil, when it is to be turned with the hook downwards, so as to catch the pupillary edge of the iris, and then to be slowly and carefully withdrawn from the eye. When the hook approaches the opening at the margin of the cornea, it must be again turned on its side, or a difficulty will be experienced in getting it out of the eye. As soon as the iris is drawn from the eye, the assistant should cut it off close to the cornea with one snip of a pair of

fine scissors. The operation is now finished ; the speculum should be removed from the eye and a fold of wet linen laid over the closed lids.

This operation is applicable to those cases where there is a pupil, or at least a portion of one, to the free edge of which the hook can fasten itself.

2. Artificial Pupil by Iridectomy.—By the operation of iridectomy, described at page 99, an artificial pupil may be made at any part of the circumference of the cornea by removing a portion of the iris.

3. Artificial Pupil by Division of the Iris with a Pair of Scissors.—This operation is suited to a special class of cases ; those eyes in which there is *no lens*, and in which only a trace of a pupil remains, the iris appearing as a plane surface stretched tightly from the cicatrix to the circumference of the cornea.

The point of an iridectomy knife is to be passed into the anterior chamber just within the corneo-sclerotic junction, and an opening made sufficiently large to admit easily the closed blades of the scissors (Fig. 21). The scissors are then to be introduced within the chamber, and the sharp-pointed blade made to penetrate the iris and to pass some distance behind it, when by one clip of the scissors the iris is divided, and a good pupil made. If, however, owing to the iris having lost its natural elasticity, the edges of the cut should fail to retract so as to form a new pupil, a piece of the iris must be drawn out of the wound with a pair of iris-forceps, and cut off with a pair of fine scissors as in iridectomy.

Artificial Pupil by Iridodesis or Ligature of the Iris.—I have omitted the description of this operation as I never now perform it. I believe that the entanglement of the iris in a wound made in the extreme margin of the cornea, and the securing it there by tying it in a loop of silk, is fraught with danger to the other eye.

FIG. 21.



INJURIES TO THE IRIS.

HÆMORRHAGE INTO THE ANTERIOR CHAMBER.—This is the most common form of intra-ocular hæmorrhage, and at the same time the least severe. It may vary in extent from a few drops of blood to a quantity sufficient to fill both the anterior and the posterior chambers.

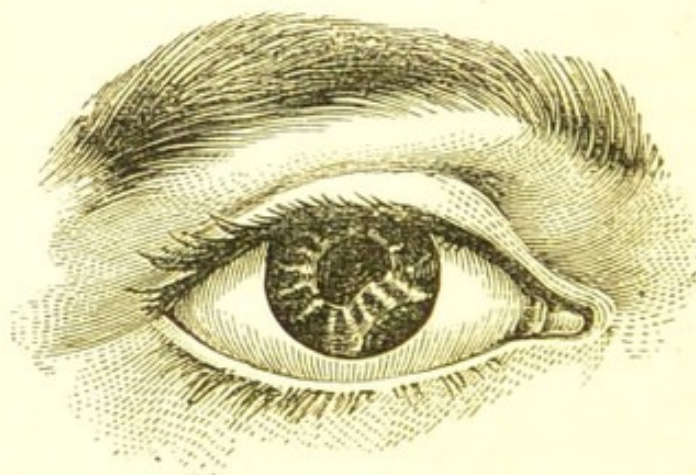
The most usual causes of hæmorrhage into the anterior chamber are, either rupture of one or more of the superficial vessels of the iris, or a distinct laceration of its structure; or a detachment of a portion of the iris from its ciliary circumference (coredialysis). The blood, as it is effused from the lacerated vessels of the iris, sinks at once to the bottom of the anterior chamber, quickly coagulates, and, if not much in quantity, may be seen as a small clot, occupying its lower part, and moulded as it were to it. If, however, the bleeding be more severe, the whole anterior chamber may be filled with one large coagulum, which will entirely occlude the pupil and iris. This more extensive hæmorrhage is usually owing to a detachment of the iris from its ciliary border, when, on account of the number of vessels necessarily torn through, and also of their larger size, the quantity of blood which is poured out is considerable.

Prognosis and Treatment.—When the hæmorrhage is confined to the anterior chamber, and there is no rupture of any of the external tunics of the eye, the case generally does well. The blood is first macerated by the

aqueous humour, and then rapidly absorbed. In this, as indeed in all cases of injury, rest to the eyes is essential: all work should for a time be forbidden, and the eyes should be shaded from strong light. Cold applications are the best suited, and afford the most comfort to the eye. A double fold of linen, wet with cold water, may be laid over the eye, and kept in its place with a single turn of a light roller, and moistened from time to time with a little fresh water from a sponge; or, if the eye be painful, a cold lotion of belladonna may be used in the place of the water-dressing.

COREDIALYSIS is a detachment of the iris from its ciliary border by which a new pupil is frequently formed. It is generally caused by sharp blows on the eye, such as with the handle of a whip, with the cork from a bottle of soda-water, or an accidental back blow from the hand of another person, or, indeed, from any sharp sudden violence. Coredialysis may be associated with rupture of the external coats of the eye, but in the majority of cases it has

FIG. 22.



Extensive coredialysis caused by a squib which struck the eye as it exploded.

not this severe complication. The separation of the iris from its ciliary connection is always immediately followed by free bleeding, often sufficient in quantity to fill the whole of the anterior chamber with a blood clot. The extent of the coredialysis varies very much: in some cases the detachment is so small as scarcely to be visible after all the blood has been absorbed; whilst, in other instances,

a third or even more of the iris may be loosened from the ciliary body.

The pupillary border of the iris corresponding to the dialysis is paralysed from a tearing through of the ciliary nerves which supply it, and that part of it is uninfluenced by the action of light and shade. The complete circle of the pupil is thus destroyed—a defect which is most observable when the pupil is dilated.

The Prognosis of cases of coredialysis, when there is no rupture of the external coats of the eye, is favourable. A guarded opinion should, however, be always given, as the blow which has force enough to cause a coredialysis may also produce cataract or posterior hæmorrhage.

Treatment.—The same as in “hæmorrhage into the anterior chamber.” (See preceding section.)

PROLAPSE OF THE IRIS.—Penetrating and incised wounds of the cornea are generally followed by immediate prolapse of the iris. The extent of the protrusion varies with the size and the position of the wound. A small penetrating wound near the margin of the cornea is more likely to be attended with a prolapse than a large incised one near the centre.

Prolapse of the iris is very commonly associated with injury to the lens; but as a rule, we have first to direct our attention in the treatment of the case to the prolapsed iris, leaving the traumatic cataract to be dealt with at a future period.

A prolapse of the iris may be treated in three different ways:—

1. By removing with a pair of fine scissors the prolapsed iris.
2. By a compress applied externally over the closed lids.
3. By frequent puncturings of the prolapsed iris with a fine needle.

1. By Removing with a Pair of Scissors the Prolapsed Iris.—There is no doubt that, when it can be accomplished, the best treatment is to excise the prolapsed iris cleanly from the wound, so as to allow its edges to fall together. In a recent case, the speculum having been introduced between the lids, the prolapsed iris should be seized with a pair of iris-forceps and drawn from the wound, and then snipped off sharply with a pair of fine

scissors. A drop of eserine (F. 18) may be then dropped into the eye, so as to cause the pupil to contract, and the lids be closed with a compress. This operation requires great care, and should generally be done under an anæsthetic.

2. **By Compress.**—When either from the time which has elapsed since the accident, or from the state of the wound, it is found impossible or deemed inadvisable to excise the prolapsed iris, a compress should be applied over the closed lids. It keeps the eye in a state of rest, excludes light, and tends to prevent an increase of the prolapse.

3. **Frequent Puncturings of the Prolapse with a Fine Needle** are most useful in cases of extensive prolapse of the iris, near the margin of the cornea, of long standing, and where the prolapsed iris has become adherent to the edges of the wound and coated with lymph. In such cases it is impossible to excise the protruded iris, and frequent puncturings of it do good. The prolapse should be pricked at one or two points, so as to cause the aqueous to escape and its sides to collapse, and at the same time to permit the edges of the wound to close upon it.

The General Treatment must be strictly soothing, and great care should be taken of the eye for at least six months after a wound followed by prolapse of the iris, even though the lens may have escaped all injury. Both eyes should be shaded, and all strong lights should be carefully excluded. The eyes should be protected from glare when out of doors by spectacles with dark neutral-tint glasses.

Soon after the accident two or three leeches should be applied to the temple of the injured eye; and three or four times during the day the eye should be bathed with a belladonna lotion (F. 40); or it may be fomented with a warm decoction of poppy heads. A few drops of the solution of the sulphate of atropia, gr. 1 ad aquæ $\bar{\text{℥}}$ 1, should also be dropped into the eye twice a day, as it is of importance to keep the eye under the influence of belladonna for the first two or three days at least after the accident. If a compress is applied over the eye, it should be removed three times daily, to allow of the eye being bathed with the lotion; but if one of the other plans of treating the prolapse be adopted, in addition to bathing the eye, a fold of linen wet with the lotion may be laid over the closed lids.

No prolapse of the iris should be very lightly regarded; for I have seen complete blindness follow from what has appeared at first a comparatively slight injury.

IRIDO-CHOROIDITIS AND CHOROIDO-IRITIS.

Inflammation of the iris and choroid is not a primary disease, that is to say, the two structures are seldom simultaneously affected. It is caused either by the extension of an iritis to the adjoining choroid, or by the spreading of an inflammation of the choroid to the iris. Two forms of inflammation of the iris and choroid may therefore be recognised.

1st. When the disease commences with iritis and the *choroid* is *secondarily* affected. To this form the term **irido-choroiditis** is applied.

2nd. When the primary disease is in the choroid, and the *iris* is *secondarily* involved. To this form the term **choroido-iritis** is applied. The prefix in each name indicates the structure first affected. This classification is important, as the two diseases are not identical, but differ both in their progress and ultimate results.

1st. **IRIDO-CHOROIDITIS** is an extension of an inflammation from the iris to the choroid. It is most liable to occur in eyes which have had frequent recurrences of iritis, and where a complete adhesion has formed between the pupillary margin and the capsule of the lens. This "exclusion of the pupil" exerts a very prejudicial influence on the eye. The pupillary border, tied down by synechiæ to the lens capsule, is repeatedly pulled on by the iris in its abortive efforts to dilate and contract the pupil under the influence of light and shade, or in concert with the action of the iris in the other eye; and thus a constant source of irritation is maintained. The communication between the anterior and posterior chambers of the eye through the pupil is closed, and the proper balance of fluid between them is destroyed. The aqueous consequently accumulates in excess in the posterior chamber, and presses forward the iris towards the cornea, rendering its surface convex, and throwing into small irregular bulgings those portions of the iris which have undergone atrophic changes from the frequent recurrences of inflammation.

Symptoms.—The early symptoms are those of iritis,

from the first attack of which the patient may have recovered, but having suffered from one or more relapses the whole or the greater part of the pupil becomes bound down by synechiæ, and lymph is effused on the capsule of the lens within the pupillary area. The iris is now gradually pushed forwards towards the cornea from an accumulation of the aqueous in the posterior chamber; its striation is blurred and indistinct; its surface, discoloured and hazy, is convex instead of being plane; and, if the disease has been of long standing, it is marked by irregular knotty bulgings from atrophic portions yielding to the pressure of the fluid behind it. At this stage there is frequently a diffused haze of the vitreous with floating opacities. The *vision* is always greatly impaired, and especially in those cases where the iris is much arched forwards; and occasionally there is considerable limitation of the field. The contracted pupil, opacity of the pupillary portion of the lens capsule, and hazy vitreous prevent the ophthalmoscope from affording much information as to the state of the parts at the fundus of the eye. This must be estimated partly by the general appearance of the structures which can be seen, but chiefly by an accurate examination of the amount of sight and the extent of the field of vision. During the inflammatory attacks, the tension of the globe is apt to be greatly increased, but in the later stages of the disease the eye becomes soft from atrophy of the structures within it.

2nd. **CHOROIDO-IRITIS** is an inflammation which commences in the choroid, and afterwards extends to the iris. It is a more severe affection than the preceding, and less amenable to treatment.

Symptoms.—The early symptoms are failing sight, a slightly dilated and sluggish pupil, and turbidity of the vitreous. There is nothing in the external appearance of the eye to account for the great impairment of sight. The disease at this stage is confined to the choroid, but after a time it gradually extends itself to the iris, and symptoms of a low form of iritis are developed. The iritic symptoms are of a subacute form, and very insidious in their progress. They are usually accompanied with some irritability and redness of the eye, especially in the ciliary region. The impairment of sight steadily increases, the field of vision becomes contracted, and por-

tions of it are occasionally destroyed either from partial detachments of the retina, or from patches of atrophy of both the choroid and retina. The *tension* of the globe as a rule remains unaltered, until during the later stages of the disease, when atrophic changes in the recently inflamed structures cause the eye to become soft.

The Prognosis of irido-choroiditis is more favourable than that of choroido-iritis. In the former the defect of sight may be chiefly due to the central opacity of the lens capsule, the vitreous being still clear, and the choroid but little affected. When such is the case, there is a good prospect of the eye under proper treatment regaining useful vision. In choroido-iritis the impairment of vision is usually great, and clearly dependent on changes at the fundus of the eye. The most hopeful cases are those in which there is a fair field of vision, with an ability to read large type, and with the globe of the normal tension. When the eye is soft, the field much contracted, and there remains only an imperfect perception of light, the prognosis is very bad, for no benefit will be derived by any operative procedure.

Treatment. — Although both irido-choroiditis and choroido-iritis may arise from many causes, yet a large number of the cases are dependent on syphilis. A careful inquiry should therefore be always made into the previous history of the patient, as if a syphilitic taint can be discovered, it forms a good ground upon which to found the treatment, and the prognosis is more favourable than when the source of the disease cannot be traced. If syphilis is the probable cause, the treatment recommended for RETINITIS SYPHILITICA should be followed. If, however, the source of the inflammation should be due to a rheumatic diathesis, the treatment advised for RHEUMATIC IRITIS, page 87, should be adopted. No permanent benefit, however, will be gained by the mere use of medicines, and soothing applications to the eye; so long as the iris remains tied down to the lens capsule, and the communication between the anterior and posterior chambers is destroyed, recurrences of the inflammation are liable to occur. As soon, therefore, as the eye has become free from active irritation an iridectomy should be performed: firstly, with the object of restoring the channel through the pupil between the anterior and posterior chambers; and, secondly, for the purpose of making an artificial pupil, and exposing a portion of

transparent lens and capsule, through which the patient may have better vision. There are several difficulties which beset the operation of iridectomy in these cases.

a. From the shallowness of the anterior chamber, owing to the iris being pressed forwards towards the cornea, it is often unsafe to use the triangular-shaped iridectomy knife. In such cases Graefe's cataract knife should be used in the manner recommended in "the operation of iridectomy," page 99.

β. In drawing out the portion of iris through the wound, previous to excising it, the pupillary border which is adherent to the lens capsule often becomes detached, and remains in situ. No attempt should be afterwards made to get it away, as it in no way interferes with the good effect of the operation.

γ. The iris may be so rotten and have formed such broad adhesions between its posterior surface and the lens capsule, that there may be difficulty in drawing out a portion of it with the forceps; or, after the iridectomy has been completed, the sight may be in no way improved, owing to the exposed lens capsule being covered with uvea. In such cases it is generally advisable to remove the lens at a future operation.

δ. The pupillary border of the iris is often so firmly adherent to the capsule of the lens that, in drawing out the portion of iris previous to excising it, the lens capsule is torn. As a consequence of this accident, which is absolutely unavoidable, cataract follows.

SYMPATHETIC OPHTHALMIA

Is a peculiar inflammation of one eye, excited by some special irritation in the other.

There are *two* forms of sympathetic ophthalmia.

The first, from being the slighter of the two, may be called **sympathetic irritation**.

The second is the severe disease now so well known by the name of **sympathetic ophthalmia**.

SYMPATHETIC IRRITATION consists of attacks of extreme irritability of the sound eye, which may come on whenever the lost or injured one becomes inflamed. There is a slight indistinctness of vision, the objects seem to dance about, and reading tires the eye. The patient may be able to read No. 1 of Jaeger, and to see distant

figures rightly, but he cannot do so for any length of time, the effort of accommodation soon fails, and the eye becomes fagged. During the attack the eye is slightly reddened, watery, and irritable: occasionally it is painful; the patient has neuralgic shootings in it, and this may then be the symptom which gives the greatest trouble. The attack generally lasts for some days, or it may even continue for one or two weeks, and then gradually cease; the recovery being frequently coincident with the cessation of the irritation in the injured eye.

The points in which sympathetic irritation differ from sympathetic ophthalmia are—

1. Although the eye may be subjected to frequent recurrences of the attacks, yet no fibrinous effusions nor disorganizing changes of its different tissues take place.
2. The excision of the lost or injured eye at once arrests the disease. All sympathetic irritation ceases when the cause which gave rise to it is removed.

SYMPATHETIC OPHTHALMIA is essentially an adhesive or fibrinous inflammation. Seldom if ever does an eye with sympathetic inflammation suppurate. Its tendency is to rapid plastic effusions, which soon become organized and incapable of absorption—blending the different tissues together, impairing their textures, and destroying their functions. The eye is generally attacked by the disease *without having pain* as a warning. The inflammation often creeps on unheeded by the patient, and the first symptom which frequently draws the attention to the apparently sound eye is a slight defect in its ability to define clearly, and a general pinkiness of the globe. In children I have seen the disease thoroughly established before they have been brought for advice, simply from the fact that the absence of pain induced the parents to think lightly of the affection. When once fairly started, sympathetic ophthalmia is very difficult to subdue, and even when arrested *it is liable to frequent recurrence*.

The peculiar tendency of this sympathetic inflammation to cause rapid effusion of lymph is manifested from the very commencement of the disease. In the earliest stage there are usually spotty deposits of lymph on the inner surface of the cornea; then follows a plastic inflammation of the iris, which binds the pupil by adhesions to the an-

terior capsule of the lens, and which rapidly extends to the ciliary processes, the choroid and the vitreous. The lymph is not deposited on the surface in nodules, as in syphilitic iritis, but it occurs as an infiltration invading the very texture of the iris, ciliary processes, and choroid. In the synechiæ which are formed, it is not simply the pupillary margin, but the whole posterior surface of the iris which contracts adhesions to the capsule of the lens, so that if at a future period an attempt be made to form an artificial pupil by tearing away a portion of the iris, the exposed part of the lens capsule will be found covered with uvea, indicating exactly the extent of adhesion which had existed between it and the posterior surface of the iris.

Early in the disease when the iris is saturated with lymph, it is soft and rotten; but at a later date when all the acute symptoms have passed away, the iris has become completely changed in its texture; it is excessively tough, has lost all its elasticity, and is converted into a dense fibrous membrane.

The Causes of Sympathetic Ophthalmia are—

1. Wounds of the eye, and especially those which involve the ciliary region or that part which extends for about one-eighth of an inch backwards from around the cornea, a space in which lie the ciliary muscle and ciliary processes; and wounds, and near the margin of the cornea in which there is an entanglement of iris.

2. The lodgment of foreign bodies within the globe.

3. The irritation excited by degenerative changes taking place in eyes already lost either by injury or disease.

Sympathetic ophthalmia is seldom, if ever, excited by a suppurative inflammation of one eye. This fact was noticed by the late Von Graefe, and my own experience accords with it. If, however, a foreign body is within the globe, suppuration does not lessen the danger which its presence in the stump will keep up.

The age of the patient has a remarkable influence on this disease.—The young are much more prone to it than the old, and it runs its course more rapidly in the child or the young adult than it does in the middle-aged or the old.

The period at which sympathetic ophthalmia may come on after an injury.—It is difficult to assign any date at which sympathetic ophthalmia may be expected,

or after which the sound eye may be considered as safe. So long as the irritation primarily excited by the injury continues, the sound eye may sympathize. The risk cannot be said to have passed away until the injured eye has quite recovered; the sclerotic must have regained its normal whiteness, and all photophobia and lachrymation have ceased.

If the injury is from a foreign body within the eye the sound eye may become sympathetically affected at any time, and after the lapse of any number of years.

Symptoms.—In the *first stage* of the attack the eye is irritable and abnormally sensitive to light; there is some lachrymation, and the conjunctiva is a little injected; there are usually spotty deposits of lymph on the inner surface of the cornea (*corneitis punctata*), sometimes only to be detected by looking at the cornea with a lens; and the pupil is decidedly sluggish in its action; the power of focusing the eye for near objects is diminished; and the patient is unable to maintain a prolonged accommodative effort. Reading quickly induces fatigue, the words become confused, blurred, and at last indistinguishable. A

FIG. 23.

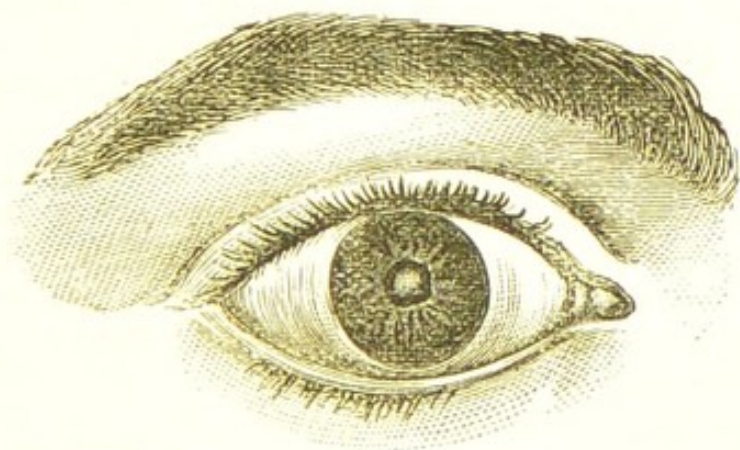


Fig. 23 represents, as well as an engraving can, the appearance of an eye suffering from sympathetic ophthalmia. It was drawn from a young man, æt. eighteen, a glass-blower, who had lost his left eye from an injury he received ten months previously.

A few minutes' rest and the eye can resume its work, but the same symptoms shortly reappear and oblige it to desist. At this stage of the disease there is generally *no pain*, not even sufficient to draw proper attention to the eye.

In the *second stage* of the disease fibrinous exudations take place within the eye, and lymph is effused in large quantities as an infiltration into the different tissues involved in the inflammation; the pupillary area of the capsule of the lens is covered and the iris almost soaked with it. This exudation rapidly becomes organized, and contracts firm adhesions between the whole posterior surface of the iris and the lens capsule. If atropine be dropped into the eye, the pupil is either not affected by it, or it dilates only slightly, irregularly, and partially. The aqueous becomes serous, and the striation of the iris, at first indistinct, is afterwards completely lost.

The *third stage* of the disease is characterized by increased tension of the globe, and this condition is *generally associated with pain*, oftentimes very severe, and sufficient to make the patient willing to submit to any means suggested for his relief. The increase of tension may come on at any time after the inflammatory exudations within the eye have commenced, and may continue during many months, or even last beyond a year. If the disease runs on the vitreous atrophies, loses consistence, and diminishes in bulk; and with these changes the increase of tension subsides, and the eye gradually becomes softer than normal, and sinks to—T 2 or 3. As the atrophy of the vitreous proceeds, the retina is deprived of its normal support, and falling forward, becomes partly or completely detached.

The increased tension of the eye combined with the inflammatory changes in the ciliary region sometimes lead to a thinning of the sclerotic around the cornea, and to ciliary staphyloma. I have seen several such cases, and they have generally been painful eyes.

Treatment.—In the treatment of sympathetic inflammation of the eye, we must consider—

1. How to arrest the progress of the disease.
2. How to proceed when the injured eye still retains some useful sight.
3. The general constitutional and local treatment in each of the three stages of the affection.

1. **How to arrest the progress of the disease.**—If the sympathetic inflammation of one eye is dependent on injury to the other, and it is clear that the wounded eye is irreparably blind; or if the exciting cause of the mischief proceeds from a previously lost eye becoming inflamed, then there cannot be a moment's hesitation about

the propriety of at once extirpating the injured, or the diseased, eye.

The importance of removing at an early period an eye which has been so injured as to be useless, and which is exciting or is likely to excite irritation in the other; or the inflamed remnant of a lost eye which is acting as an irritant, cannot be exaggerated; for though *in the very early stage* of sympathetic ophthalmia the removal of the cause of irritation will frequently induce its subsidence, yet when the disease has thoroughly taken hold of the sound eye, even the removal of the lost one will rarely arrest its progress. My own experience leads me to believe that if an injured eye be excised before symptoms of irritation occur in the other eye, then the sound eye is safe from sympathetic ophthalmia. There may be exceptions to this rule, but I believe they are very few.

2. **How to proceed if the injured eye still retains some useful sight.**—On several occasions I have seen the sound eye destroyed by sympathetic ophthalmia, while the injured eye has ultimately so recovered that useful sight has been restored to it, and the patient has been able to get about without assistance. As the removal of the injured eye will probably not arrest the sympathetic ophthalmia, and especially if plastic exudations have commenced, the conclusion at which I have arrived is, that if sympathetic ophthalmia be established, the injured eye should not be removed if it retains any useful sight.

3. **General constitutional and local treatment.**—In the *early stage* of the disease absolute rest to the eyes is imperatively demanded; all reading, writing, or fine work of any kind, must be forbidden; when at home the room should be kept darkened, and when out, dark neutral-tinted glass goggles should be worn. It is impossible to overrate the importance of keeping the patient for a long period in a very subdued light; it affords the best hope of success, and places the eyes in a position to receive most favourably the influence of any other treatment which may be adopted. However well the patient may progress, the order to rest the eyes and abstain from work should not be rescinded for at least from six to eight months. The disease is very recurrent in its nature, and the too soon exposing the eyes to the stimulus of strong light will increase the chances of relapse.

During this stage mercurial inunction into the temple

with the unguent. hydrarg., or the hydrarg. oleat., 5 per cent. c. morphia every night may be tried and continued for two or three months, care being taken to avoid salivation by diminishing or omitting the rubbing in for a few days as required. The patient should be well fed, as the disease is very depressing, and quinine in one- or two-grain doses, according to the age of the patient, combined with extract of belladonna, or bark with belladonna, (F. 140) should be given. From the use of iodide of potassium and perchloride of mercury, both of them favourite medicines in the treatment of irido-choroiditis, I have never known the slightest benefit.

Local applications.—A weak solution of atropine (F. 15) may be dropped into the eye three or four times a day, or the belladonna lotion (F. 40) may be frequently used. In the later stage of the disease, when the whole posterior surface of the iris is adherent to the capsule of the lens, I believe that all mydriatics do harm by stimulating the dilating fibres of the iris to contract when from the adhesion of the iris to the lens-capsule they cannot act. Mydriatics also favour the development of the state of increased tension which usually comes on at a later period of the disease.

In the *second stage* of the disease, when the union between the iris and lens-capsule has been effected, but after the acute symptoms have subsided and the eye is quiet, it is a question whether an operation may be attempted to improve the sight. My opinion is that if the sight is sufficient for immediate requirements, and will enable the patient to walk about without assistance, the eye should be left alone. It is the only eye, and operations on eyes sympathetically inflamed are so unfavourable, that it is better to let the patient enjoy the sight he has, rather than to risk the loss of it with the prospect only of a slight improvement.

If, however, the sight is so defective as to be almost useless, and there is a fair field of vision, then an attempt should be made to improve it by an operation, but no operation should be performed whilst the eye is inflamed. The objects to be attained are, the formation of a new pupil and the extraction of the lens. There are very few eyes which have suffered from sympathetic ophthalmia in which an artificial pupil can be satisfactorily made without at the same time removing the lens. The iris has become so changed in structure, and so adherent to the

lens-capsule, that it is difficult and often impossible to perform an iridectomy; and even when this can be accomplished, it usually fails to benefit the sight, from the exposed capsule of the lens being coated with adherent uvea. It is therefore generally advisable to endeavour to remove a portion of iris and to extract the lens in the one operation:—First, make a section of the cornea with a narrow Graefe's cataract knife, then, if possible, remove a portion of iris; but failing to accomplish this, tear open the pupil and through the capsule of the lens with a cystotome; or if this be insufficient, remove a portion of iris and the adherent lens-capsule with a pair of iris scissors; and, lastly, with a little pressure on the globe with the back of the curette cause the escape of the lens through the corneal wound. This operation may generally be accomplished without the loss of any vitreous, and the eye will usually recover from its effects well, but the pupil will probably again become closed. Another operation will afterwards be required for the formation of a new pupil.

The extraction of the lens seems to exert a beneficial influence on the eye, as after it has recovered from the effects of the operation, it is much less disposed than it was before to a recurrence of the inflammation.

In the *third stage* of the disease, when there is an increased tension of the eye, active treatment is necessary. If the state of tension be long continued the little sight that is left soon vanishes; and relief also is required for the pain which so frequently accompanies the tension. An attempt to do an iridectomy I have always found unsuccessful. In these cases sclerotomy is the better operation. A narrow Graefe's knife is to be made to pierce the sclerotic just external to the corneo-sclerotic junction, and to be directed across the front of the iris to a corresponding point on the opposite side. After slight cutting, so as to make the section a little broader than the breadth of the blade, the knife is to be withdrawn, leaving a wide bridge between the sections. I have performed sclerotomy in sympathetic ophthalmia where there has been great pain associated with increased tension; and in cases where there have been pain, tension and ciliary staphyloma, and with very good results.

GLAUCOMA.

GLAUCOMA is a disease which is characterized by an increased tension of the globe, impairment of the field of vision, and fading sight.

There are four forms of this disease :—

1. The acute and subacute inflammatory.
2. The chronic or simple.
3. The intermittent.
4. The consecutive or secondary.

The progress of each differs, but if uninterrupted by treatment the end is the same—sooner or later irreparable blindness.

To ascertain the tension of the globe.—See page 129.

The impairment of the field of vision in glaucoma is very great. It usually commences at the inner or nasal side, at which part it is sometimes completely wanting. In some cases the field is simply contracted, and this occasionally goes on to such an extent that the patient will describe his limitation of vision “as if he were looking through a tube.” In other cases portions of the field are completely obliterated, so that in certain directions the eye is blind.

To determine and map out the field of vision.
(See Article on this subject.)

Glaucoma is a disease of advanced life, the large majority of the cases being in patients over forty-five years of age. There are, however, exceptional instances in which it has occurred at a much earlier date. Glaucoma may be idiopathic, that is, it may develop itself in an eye without any apparent cause; or it may be dependent on an injury, or on some form of inflammation of the eye to which it is secondary.

The advent of an attack of acute glaucoma seems to be sometimes due to a sudden mental shock occurring to a person already depressed, and with eyes probably predisposed to the disease. Thus, I have on several occasions seen it come on after severe affliction caused by the death of near relations, or by great pecuniary loss. In one case which came under my notice, a sudden fright in a patient exhausted by night-watching apparently induced the disease. The patient, a nurse, had from sheer fatigue fallen asleep by the bedside of the patient she was watch-

ing, when she was suddenly awoke in the night by the snapping of the sash cord, and the sudden falling of the window. Within a few hours she had an attack of acute glaucoma. Patients who have suffered from gout or from disorders of the digestive system have been supposed to be specially liable to glaucoma, but this has not been satisfactorily proved. Both eyes may be simultaneously involved; but it is more usual for one to be first affected, and for the disease to follow in the other after a varying interval. When one eye has suffered from glaucoma the other is specially liable to be attacked.

The premonitory symptoms of glaucoma are—

1. **Rapidly increasing presbyopia**, the patient finding it necessary to frequently change his convex glasses for stronger ones on account of his defect of sight increasing.

2. **Periodic obscurations**, sudden dimness, varying in degree and lasting from a few minutes to several hours.

3. **Halos or rainbows** around the candle or any other light is a frequent symptom, and one which generally draws the patient's attention to his eye.

4. **Diminution of the field of vision and fading sight.**

5. **A gradual increasing hardness of the globe.**

Such are the warning symptoms of glaucoma, but they may be all so slight, or may make their appearances so slowly that they may be unheeded, and this is especially the case if one eye only is affected.

1. **ACUTE INFLAMMATORY GLAUCOMA** is generally sudden in its attack, occurring usually in eyes which have had premonitory symptoms, though they may not have been appreciated by the patient; or it may supervene on the simple form of the disease, the chronic glaucoma rapidly and suddenly assuming the acute inflammatory type.

Symptoms.—The eye exhibits all the external manifestations of great internal congestion and acute inflammatory action. There is distension of the ciliary vessels, both of the viens which emerge through the sclerotic in front of the insertion of the recti, and of the zone of arteries around the cornea; occasionally there is also chemosis of the conjunctiva. The anterior chamber is diminished in size, sometimes to such a degree as to bring the iris almost into contact with the cornea; the

pupil is dilated and either very sluggish or completely inactive. The patient sees rainbows or halos of bright-coloured light around the candle or gaslights. The field of vision is diminished, or parts of it are obliterated. The sight is greatly impaired, and is rapidly getting worse; in a few hours it may be so reduced as to be able only to distinguish No. XX. or to count fingers. The tension of the globe is increased from T 1 to T 3, or stony hardness. The pain is usually most severe, oftentimes of an almost maddening character. There is a sense of aching and tightness of the globe, with pain extending around the orbit, along the side of the head, and down the nose, but the most acute agony is often referred to the back of the head. This is usually accompanied with severe vomiting, so as to give to the symptoms an aspect of a bad bilious attack, for which, indeed, it is unfortunately too often mistaken.

Examined with the Ophthalmoscope the vitreous may be so turbid as to prevent the fundus from being seen; but if the humours are still sufficiently clear, there will be found cupping of the optic nerve; pulsation of the retinal arteries, either spontaneous, or produced by the slightest pressure on the globe; and a dilated and tortuous condition of the retinal veins. Small blood spots will be often seen scattered at different parts of the retina. They are the result of capillary hæmorrhages, which take place in most cases of the acute, and in many of the chronic glaucoma. Filmy blood clots are also often found in the vitreous.

The Characteristics of a Glaucomatous Cup.—The glaucomatous cup involves the whole optic disc: its margin is abrupt, sharp, and sometimes excavated, overlapping the cup, and the vessels as they curl over its edge appear to be either interrupted or distorted. If the excavation is *deep*, the continuity of the vessels, as they ascend the side of the cup and mount over its edge, seems to be lost, and the vessels look as if they were interrupted or broken in their course; whilst if the cupping of the nerve is *shallow* the vessels appear bent or distorted as they pass over its edge. The optic disc is encircled by a light-coloured zone. This is caused by the edge of the sclerotic ring shining through a rim of atrophied choroid, and it is best seen in those cases where the excavation is deepest. The central portion of the papilla has often a peculiar bluish-grey tinge which increases in

intensity towards the circumference of the nerve. So deceptive is the appearance of a deeply excavated nerve that it resembles more the prominence of a sphere than the hollow of a cup. The *glaucomatous* excavation is perfectly distinct from what is termed the *physiological cup*.

The **physiological cup** is simply a shallow depression confined to the centre of the optic disc, in the site where the retinal vessels pass; it looks white and glistening, and its sides are usually bevelled or sloping; it varies greatly in size, but it is surrounded by healthy looking nerve structure; it is congenital, and has no unfavourable omen. In addition to these two, there is a third form of excavation of the disc produced by atrophy of the optic nerve. (See ATROPHY OF OPTIC NERVE.)

Two modifications of this acute form of glaucoma should be noticed. A *subacute* in which all the symptoms are diminished in intensity; and a *hæmorrhagic* form in which there is a peculiar tendency to retinal hæmorrhages, and in which bleeding between the choroid and retina will sometimes occur immediately the tension of the globe is relieved by iridectomy.

Results of Acute Glaucoma.—The vision may be reduced to a mere perception of large objects in a few days, or, in very acute cases, as in the “Glaucoma fulminans” of Graefe,* in even a few hours. If the acute symptoms subside, and some of the lost sight is regained, the eye is still left in a very unhealthy and unsatisfactory state. The sight remains impaired, the tension of the globe will generally continue too great, and there is a probability, amounting almost to a certainty, that the eye will sooner or later be subjected to another attack which will still further damage the sight, if it does not altogether destroy it. After one or more of these acute attacks, the eye will drift into the state of hopeless blindness which has been described as *glaucoma absolutum*. This is, in fact, the last stage of the disease, when the eye is irremediably blind, and when all hope of benefit from treatment has passed. The globe is of stony hardness, the pupil widely dilated, and often irregularly so; the anterior chamber is so shallow that the iris is almost in contact with the cornea, which is anæsthetic and dull in appearance, having lost much of its normal lustre. The humours

* Archiv für Ophthal. viii, 2.

are turbid, so that the fundus cannot be seen; and it may be that the lens is also cataractous. But, in addition, the eye is often subject to severe pain, which is either constant or so frequently recurring as to destroy sleep and impair health. The suffering may be due either to a repetition of the acute inflammatory attacks, which continue even though the eye is lost; or to the irritation which is excited by degenerative changes taking place in the tissues within the globe.

Treatment.—For the acute inflammatory glaucoma there is but one plan of treatment which holds out the promise of regaining much of the lost sight, and at the same time of relieving pain, and that is *iridectomy*. The results of this operation in acute glaucoma have been most brilliant; its curative effect is now an established fact, and cannot be controverted by ignorance or prejudice. I prefer iridectomy to sclerotomy in acute glaucoma.

To Von Graefe is to be ascribed the honour of having originated the operation, and the thanks of all who are benefited by it are due to him. The effect of iridectomy is to relieve tension, and the symptoms which are dependent on it at once begin to subside. The operation should be performed as soon as possible after the acute symptoms have set in, as every hour tends to diminish the chances of recovery.

For the eye which has been lost by glaucoma, and continues painful, or is liable to frequent recurrence of inflammation, the best treatment is excision. The operation of iridectomy in such cases generally fails to give relief.

2. CHRONIC, or SIMPLE GLAUCOMA.—The progress of this disease is usually unaccompanied by pain. It may involve one or both eyes; but when both are affected, it is generally more advanced in one eye than in the other. The vision gradually fades, and there are occasional obscurations in which the dimness is greatly increased—in some cases almost to darkness; but after a varying time the sight is regained. The patient sees rainbows or halos of coloured light around the candles. The pupil is sluggish and more dilated than normal. The anterior chamber becomes shallow, and the humours turbid. The tension of the eye is increased; and the field of vision is contracted, or in parts lost. These symptoms may steadily progress, with occasional remissions or exacerbations, until all sight is extinguished. Frequently,

however, an acute attack supervenes, and all the symptoms which characterize the acute inflammatory glaucoma are at once developed.

Examined with the Ophthalmoscope the same appearances are presented which were mentioned in the section on ACUTE GLAUCOMA, page 120—viz., cupping of the optic disc with pulsation of the retinal arteries, either spontaneous or produced under the slightest pressure of the fingers on the globe; undue fulness of the retinal veins; turbidity of the vitreous, and occasionally small extravasations of blood on the retina.

Treatment.—Iridectomy affords the best chance for the eye; but the results of this operation in the chronic or simple glaucoma are not nearly so favourable as when performed for the acute form of this disease. It will generally arrest the progress, and retain for the patient the vision he still has, but it will often fail to bring back the sight which has been lost. Still, so long as the eyes possess perception of light, it is worth performing iridectomy, as the results of the operation will often far exceed the expectations, and especially if the disease has been of short duration. In some cases which have been under my care, where the vision was so reduced that the patients could only count fingers, I have been gratified by such a restoration after the operation as has enabled them to read fair-sized type, such as from No. 6 to No. 10 of Jaeger.

For medicinal treatment, the guttæ eseriæ (F. 18) should be dropped twice daily into the eye, and the pil. sodæ arseniatis may be given twice daily. When there is pain in or about the eye the croton chloral (F. 78, 110) may be given every one or two hours until relieved, but for three doses only.

The cases of chronic glaucoma which hold out the best promise of success are those in which the field of vision is still entire, and where the disease has not continued long enough to produce severe atrophic changes in the optic nerve and retina.

3. INTERMITTENT GLAUCOMA.—The symptoms in this form of the disease are not continuous; they last for a variable time, and then there is a distinct intermission, an interval of freedom from the glaucoma, with a restoration of sight which may be nearly, if not quite, equal to that enjoyed previous to the attack. After a short

respite, the glaucomatous symptoms recur, and again recede in a similar manner. In the intervals the patient may be able to read No. 1 of Jaeger's test types and to see distant objects well, but if the field of vision be carefully taken, it will generally be found to be more or less contracted, and this contraction is likely to increase with the recurrences of the glaucoma. In these cases there is usually one of the glaucomatous symptoms specially pronounced, and which forms the predominant feature during the attack. In some patients the prominent symptom is the temporary obscuration of sight, which may vary from great dimness to periods of almost complete darkness;—in others there is only an indistinctness of vision, but with marked halos around lights, and with some pain in the eye;—in all there is an increase of tension during the attack.

These recurrences and intermissions may extend over many months, or even beyond a year; but my experience is that sooner or later they will be followed by an acute attack of glaucoma, which, if not arrested in time, will destroy sight.

Treatment.—When the glaucomatous symptoms are not very marked, and the recurrences are at long intervals, we may fairly try the effects of drugs. The *guttæ eseriæ* (F. 18) may be dropped three times daily into the eye, and the *succus conii* may be given in doses of from half a drachm to a drachm, combined with half-drachm doses of the tincture of yellow cinchona two or three times a day. I have frequently found this treatment beneficial.

In addition, all reading and close application of the eyes should be avoided. If, however, the symptoms of glaucoma are pronounced, and the attacks frequent, I would strongly urge an iridectomy, and without delay. The fact that the patient can see well during the intervals is no argument against the operation: the acute attack in which these intermittent glaucomas usually culminate may be close at hand.

4. CONSECUTIVE, or SECONDARY GLAUCOMA, may complicate many of the diseases and injuries of the eye. It may follow a perforating wound in which the lens has been injured; or it may come on after a needle operation for cataract or for opaque capsule; or after a dislocation of the lens into the anterior or vitreous chambers. It is

then known as *traumatic glaucoma*. Secondary glaucoma is also occasionally met with in cases of iritis and irido-choroiditis, in staphyloma, in sympathetic ophthalmia, and in some forms of deep ulceration of the cornea. Whenever it occurs, it must always be regarded as a grave symptom.

Treatment.—In those cases where the increased tension of the globe is dependent on removable causes, the source of the irritation should be taken away. Where a wounded or broken-up lens is pressing upon the iris, and exciting glaucomatous symptoms, it should be either sucked out with a syringe, or removed by linear extraction. When a dislocated lens is the cause of irritation, it should be extracted. In cases of increased tension after capsular operations, paracentesis of the cornea will generally afford relief. The same operation may be also tried when glaucomatous symptoms are associated with deep ulceration of the cornea; but should it fail to diminish the tension, a portion of the iris should be excised by iridectomy, or Samesch's operation be performed. In iritis, or irido-choroiditis with increased tension of the globe, iridectomy should be performed.

The following are occasional complications of glaucoma which raise difficult questions of treatment:—

1. **Glaucoma recurring in an eye in which an iridectomy has been already performed.**—The choice rests between performing sclerotomy and the making another iridectomy in the opposite direction. With my present experience, I am in favour of another iridectomy in preference to sclerotomy. I have had good results from a second iridectomy.

2. **Glaucoma recurring in an eye in which an iridectomy had been previously performed, but with the lens now cataractous.**—If there is still some sight in the eye, the best treatment is to extract the lens, making the section with a narrow Graefe's knife. The prospect of success is not good, but it affords the best chance.

3. **Glaucoma coming on in an eye in which there is an advancing but still an immature cataract.**—The glaucoma is probably due to a swelling lens pressing against the posterior surface of the iris. I would first make a large iridectomy; it is an operation I have performed in such cases and with success. If the tension should recur, or the operation should fail to relieve the tension, I would extract the lens.

PATHOLOGY OF GLAUCOMA.—In order that the student may understand the theories of the causation of glaucoma, it is essential that he should clearly appreciate the relations of the structures near the angle of the anterior chamber. The following description of the parts in that locality is taken from "Quain's Anatomy," ninth edition, vol. ii. p. 397:—

"The membrane of Descemet or Demours (posterior elastic lamina, Bowman), not very closely united with the fibrous part of the cornea, is transparent and glossy in appearance. It is firm and structureless, but very elastic. . . . In thickness it varies from $\frac{1}{3000}$ to $\frac{1}{2000}$ of an inch. It is lined next the anterior chamber with an epithelium, which resembles that on serous membranes, consisting of a single layer of flattened polygonal cells with distinct nuclei.

At its circumference the membrane breaks up into bundles of fibres, which are partly continued into the front of the iris, forming the "pillars of the iris," and partly into the fore part of the choroid and sclerotic coats. To these festoon-like processes passing between the iris and posterior part of the cornea at its junction with the sclerotic, and which are very much more marked in the eyes of the sheep and the ox than in the human eye, the name *ligamentum pectinatum iridis* was given by Hueck. The processes in question are covered with epithelioid cells, continued from Descemet's membrane, but these cells do not stretch across the *intervals* between the processes, so that the cavity of the aqueous chamber is prolonged into, and freely communicates with, cavernous spaces (*spaces of Fontana*) in the tissue between the processes. A similar, but rather larger, space is found slightly anterior to these in the substance of the sclerotic, close to its junction with the cornea. This, which is elliptical in section, is known as the *sinus circularis iridis*, or *canal of Schlemm*. According to Schwalbe, the canal of Schlemm communicates through the other spaces with the aqueous chamber of the eye."

Ciliary muscle.—"At the anterior part of the choroid, between it and the sclerotic, is a zone of plain muscular tissue, the ciliary muscle of Bowman. It arises by a thin tendon from the fore part of the sclerotic close to the cornea, between the canal of Schlemm and the spaces of Fontana, and its fibres, spreading out, are directed backwards to be inserted into the choroid opposite to the ciliary processes, and partly further back. Near their insertion the fibres pass equatorially and inter-cross, so as to form peculiar stellate figures. According to Waldeyer, a small portion, the outermost, is sometimes inserted into the sclerotic coat. These antero-posterior, or *meridional and radiating fibres*, pass at the side next the iris into a ring of fibres, which have a circular course around the insertion of the iris. This set forms the *circular ciliary muscle* of H. Muller. This circular muscle is much developed in hypermetropic eyes, but is atrophied, or may even, it is said, be absent in myopic (Ivanoff). The ciliary muscle, at least its inner part, was formerly described as the *ciliary ligament*. In birds the ciliary muscle is composed of cross-striated muscular fibres."

All the symptoms of glaucoma arise from an increased intra-ocular pressure due to an excess of the fluids within the eye. This excess may be caused by an over-secretion of the fluids, or by some obstruction to the natural outflow of the fluids from the eye; or possibly both these causes may act together in producing an increase of the tension of the globe. The normal exit of the fluids probably takes place in the corneo-iridian angle of the anterior chamber, through the spaces of Fontana and Schlemm's canal, and in the healthy eye an exosmosis of the fluids from within the eye is constantly going on, and by it the proper tension of the globe is regulated. If from any cause there is a narrowing, or an obliteration, of this angle, the balance between the secretion and excretion of the fluids is disturbed, and the tension of the globe is increased. It is probable that in the cases of acute glaucoma which have come on suddenly, and have been apparently induced by some mental disturbance such as anxiety, great sorrow, or fright, that the exosmotic area at the angle of the anterior chamber had been previously narrowed, or partially obliterated by some structural change, but not of sufficient extent to produce definite symptoms. In such cases the mental shock may have caused through the vaso-motor nerves a sudden increased intra-ocular blood pressure, and a consequent over-secretion of fluid within the eye: the area of excretion being blocked, rapid glaucomatous tension has come on, and with it the usual symptoms of an attack of acute glaucoma have been manifested.

Mr. Brailey has kindly given me the following notes of his views of glaucoma:—"Glaucoma is due to an increase in the contents of the globe, which increase is usually in the vitreous chamber. The vitreous body is itself larger by an increase of the fluid in its meshes, and contains more cell elements than normal. It pushes back the lamina cribrosa, causing absorption of the overlying nerve fibres, and presses forwards the lens together with the ciliary processes and base of the iris. Should this last be so far advanced as to touch the meshwork of the ligamentum pectinatum, it closes like a valve all access to Schlemm's canal, and prevents the outflow of the ocular fluids by this channel. Thus the tension is augmented by this obstruction, whereas it was in the first place due to increased secretion of the intra-ocular fluids, such being due almost entirely to increased activity of the pigment epithelium cells of the

ciliary body. This increased activity of secretion is due to an affection of the fifth nerve, and is frequently associated with neuralgia of some of its branches. This neurosis is attended with atrophy and formation of connective tissue in the ciliary body, iris and optic nerve.

"Secondary glaucomas are mainly due to obstruction, and may depend on prolapse of the iris against the cornea, as after perforating ulcers; or on exclusion of the pupil, or on swelling of the lens, as after wounds.

"Intermittent glaucomas are due to hyper-secretion alone.

"In glaucoma absolutum the changes began in hyper-secretion and ended in obstruction as above explained."

Dr. Priestley Smith's opinions on glaucoma are embodied in the following notes which he has kindly given me:—"Glaucoma is the expression of obstructed filtration of fluid from the eye. The obstruction differs in different forms of the disease:—*Primary Glaucoma*.—The immediate local cause is pressure of the ciliary processes against the base of the iris, and consequent compression of the angle of the anterior chamber. Any condition which brings the processes and the margin of the lens too near together constitutes a *liability* to glaucoma; any condition which brings them into close contact, and pushes the processes forwards induces the glaucomatous attack. The healthy lens continually increases in size with the advance of life, encroaching on the space which separates it from the processes, and on the aqueous chamber: hence the increasing liability to glaucoma with advancing age. Chronic glaucoma depends chiefly upon structural disproportions, *e.g.*, a too large lens, or a too small globe. Acute glaucoma depends chiefly upon swelling of the ciliary processes, and is *excited* by nervous and vascular disturbances of various kinds. When the angle of the anterior chamber is already dangerously narrow, dilatation of the pupil, by thickening the iris, may at once occlude it; when such occlusion is recent, contraction of the pupil, by thinning the iris, may relieve it. *Secondary glaucoma*. The obstruction arises in various ways, but results in all cases in impaired filtration through the angle of the anterior chamber."

Sclerotomy.—This operation was originated by Dr. De Wecker, of Paris, as a substitute for iridectomy for the relief of glaucoma. He performs the operation as

follows:—The lids being separated by a spring speculum, and the eye steadied with a pair of forceps, “a Graefe’s cataract knife should penetrate the sclerotic very precisely at a distance of one *millimètre* from the clear cornea, and then, the blade being held perfectly parallel to the plane of the iris, it should be passed very slowly in front of the latter, so that the counterpuncture may fall also exactly at a distance of one *millimètre* from the internal border of the cornea. If the blade be not held quite parallel with the plane of the iris, there is danger that it may pass through the cornea, and that the sclerotomy may be but half performed; or, if it be directed too deeply, it may come out through the sclerotic at an exaggerated distance from the cornea, may wound the ciliary body, and may provoke troublesome hæmorrhage and irritative symptoms of an alarming kind. A complete curative effect should not be expected from sclerotomy unless it is performed strictly *lege artis*; and, in order that this may be, it is necessary that the operator should have the proceeding at his fingers’ ends. The section should be made by slow sawing movements, leaving exactly one-third of the flap undivided.” He further says: “I do not confine myself strictly to the formation of a flap two *millimètres* high, of which the middle third is left undivided, but, especially if the depth of the anterior chamber permit it, I form a flap of from three to four *millimètres* high.”*

The results of my experience of sclerotomy are, that it is a useful operation.

1. In glaucoma occurring in eyes from which the lens has been removed.
2. In the late stage of sympathetic ophthalmia where there is tension and pain.
3. In cases of hæmorrhagic glaucoma.
4. In glaucoma occurring in eyes with a very high degree of myopia.

For the acute glaucoma I much prefer iridectomy; and in chronic glaucoma I think iridectomy affords a better prospect of arresting the disease than sclerotomy.

To Ascertain the Tension of the Globe the patient should be told to gently close his eyes and look downwards whilst the surgeon places his two forefingers on the

* Abstract from a Paper on Sclerotomy, by De Wecker, *British Medical Journal*, Nov. 22, 1879.

upper part of the eye, and by an alternating pressure with first one finger and then the other, as if feeling for fluctuation, he determines the degree of tightness of the globe. The tension of eyes varies considerably in different patients even in health; it is well, therefore, when deciding on the degree of tension of a diseased eye, to examine also the sound one so as to compare the two, as their normal condition may be either slightly above or below the usual standard of tightness.

The following symbols were suggested by Mr. Bowman, in the *British Medical Journal*, October 11, 1862, for recording accurately the varying degrees of increase and diminution of tension:

"T represents *tension* ('t' being commonly used for 'tangent,' the capital T is to be preferred): 'Tn, *tension normal*. The interrogative, ? marks a *doubt*, which in such matters we must often be content with. The numerals following the letter T on the same line indicate the *degree of increased tension*; or, if the T be preceded by — of *diminished tension*, as further explained below. Thus:

"T 3. *Third degree, or extreme tension*. The fingers cannot dimple the eye by firm pressure.

"T 2, *Second degree, or considerable tension*. The fingers can slightly impress the coats.

"T 1. *First degree. Slight but positive increase of tension*.

"T 1 ? *Doubtful if tension increased*.

"Tn. *Tension normal*.

"— T 1 ? *Doubtful if tension be less than natural*.

"— T 1. *First degree of reduced tension. Slight but positive reduction of tension*.

"— T 2 } *Successive degrees of reduced tension, short*

"— T 3 } *of such considerable softness of the eye as allows the finger to sink in the coats. It is less easy to define these by words.*"

TREMULOUS IRIS—*Iridodonesis*—are terms applied to an iris which trembles and vibrates with each movement of the eye. It is most frequently caused by the loss of the lens, and is thus occasionally seen after the extraction of cataract, or it may be produced by a partial or complete dislocation of the lens either into the anterior chamber or vitreous. The iris is also generally tremulous in cases of hydrophthamos, owing to the loss of support

of the lens from an increase in the size of the posterior aqueous chamber, and a stretching of the suspensory ligament.

COLOBOMA OF THE IRIS is a congenital deficiency of a portion of the iris, caused by an arrest of development in early foetal life. It usually occurs in the lower part of the iris, and is associated with a similar defect in the choroid. A case is reported by Mr. Hulke,* in which there was a coloboma of the iris, choroid, retina, and optic nerve-sheath. Coloboma of the iris most frequently occurs in both eyes, but it is not uncommon to find only one eye affected. It is occasionally associated with microphthalmos or congenitally stunted eyes. Mr. White Cooper has related the history of three children out of a family of seven, each of whom was afflicted with microphthalmos and coloboma of the iris in both eyes.†

DISEASES OF THE VITREOUS HUMOUR.

HYALITIS, or inflammation of the vitreous rarely occurs either as an idiopathic or a primary affection. It is usually associated either with disease of the iris, the choroid, or retina, to which it is secondary. It may be induced by an injury, and especially the lodgment of a foreign body in the vitreous or the adjoining ciliary processes.

The inflammation may be either simple or suppurative.

In **simple hyalitis** there is a diffused haziness of the vitreous, with here and there small filmy opacities. These may be caused by portions of the connective tissue becoming opaque, or by small effusions of lymph into the vitreous from the neighbouring ciliary processes. When the hyalitis is due to the presence of a foreign body within the eye, large masses of lymph will be frequently seen behind the edge of the lens projecting into the vitreous, whilst the rest of its structure is so turbid as to exclude the fundus of the eye from ophthalmoscopic view. If the inflammation is long continued, the vitreous loses its consistency, and becomes more or less fluid and reduced

* Royal London Ophthalmic Hospital Reports, vol. iii. p. 335.
 † Ibid., vol. i. p. 110.

in bulk. With this diminution of volume, detachment of the retina and shrinking of the globe are apt to occur.

Suppurative hyalitis is met with in ophthalmitis and suppuration of the globe. The effusion of pus may be often seen to commence in the ciliary region behind and to one side of the lens, but it soon diffuses itself throughout the whole of the vitreous.

Treatment.—As hyalitis is seldom a primary affection, the treatment for it will be found under the heading of the diseases to which it is secondary.

MUSCÆ VOLITANTES ; *Opacities of the Vitreous.*—Opacities of the vitreous, the result of disease, must be distinguished from the motes or muscæ volitantes, which are perfectly compatible with healthy eyes, although they are the source of much anxiety, and even of misery to the patient. Two varieties of muscæ—the transparent and the opaque—are commonly met with—and they occur mostly amongst myopic patients and those who use their eyes much for fine or close work.

The transparent muscæ are best seen when looking up in the light, or against a white surface through a small aperture in a card, or with the lids partially closed. They consist of numerous small transparent bead-like bodies, some of them hanging together in rows or in clusters, whilst others are floating as isolated circles in myriads before the eye. They do not obscure vision, as everything is seen clearly through them, or by their side. If the eyes are suddenly turned upwards and then fixed, they will be observed by the patient to float slowly downwards, as if gravitating to the fundus of the globe. They are perfectly innocuous, and merely represent the corpuscles of the vitreous and débris of cells, which in certain lights become obvious to the eye in which they exist. The different shapes assumed by these transparent muscæ are caused by aggregations of the corpuscles either into groups or strings.

Opaque muscæ.—The second form of mote, which is often complained of, consists of one or more dark spots of different fantastic shapes, which are constantly floating before the field of vision, and shifting with the movements of the eye. They will appear suddenly, and remain for years without increasing or diminishing, or without the eye becoming in any other way affected. They will also disappear occasionally for months or longer, and then

turn up again in their old familiar form. This, perhaps, may be explained by supposing that the body of which the mote is composed floated out of, and was for a time accidentally kept from, the field of vision, when, again becoming free, it reappeared. The cause of these opaque *muscæ* it is difficult to ascertain. They may be the débris of cells congregated together, or opaque detached filaments from the connective tissue of the vitreous, or a little of the pigment of the uvea which has been accidentally detached from the ciliary processes and worked its way into the vitreous. Donders, in speaking of *muscæ volitantes*, says: "I succeeded in finding, on microscopic examination, with Professor Jansen, some, and subsequently with Dr. Duncan, all forms in the vitreous humour of the human eye." He detected "pale cells and débris of cells in a state of mucine-metamorphosis; fibres furnished with granules, and groups of granules with adherent granular fibres."*

Treatment.—Rest the eyes by abstaining from all close work, and avoid constantly looking for the *muscæ*. If in bright lights they become visible without the patient searching for them, he should be provided with neutral-tint or dark cobalt-blue glasses. Tonics of quinine or iron frequently do good by improving the health, and rendering the eye and the mind of the sufferer less impressionable to little defects. No local applications will be of any service for the getting rid of the true *muscæ volitantes*. The patient should be assured that they are not portentous of coming blindness, and that they may continue for years without causing any more than their present annoyance. *Muscæ* must not be confounded with *scotomata*, which are fixed blind spots in the field of vision, dependent on a complete loss of sensibility of a portion of the retina.

OPACITIES OF THE VITREOUS are a frequent result of disease of the iris, choroid, and retina, and especially of those affections which have a syphilitic origin. They may be due to inflammatory changes in the cells or connective tissue of the vitreous, or to small effusions of lymph, or to extravasations of blood. They are frequently

* Donders on the "Accommodation and Refraction of the Eye," Sydenham Society, p. 199.

associated with a general turbidity of the vitreous, but they may also exist in large numbers when that structure is perfectly transparent, so that with the aid of the ophthalmoscopic mirror these opaque bodies may be seen floating in a perfectly clear medium. The opacities may assume a variety of forms resembling either grains of soot, dark threads, or membranous expansions. When they are numerous, there is usually great impairment of vision; but this is often as much due to the disease which has led to their formation as to the impediment they offer to the passage of light to the retina. Those which are placed deeply in the vitreous create the most confusion by throwing their shadows on to the retina.

Treatment.—Opacities of the vitreous must be treated by attacking the disease which has given rise to them. Those which have a syphilitic origin, and are dependent on small plastic effusions, are more amenable to remedies than any of the other forms. For the filmy opacities due to hæmorrhage nothing can be done. In the course of time they will shrink considerably, and many of them will disappear from the field of vision. The dense membranous opacities, which greatly obstruct vision by floating in front of the object, Von Graefe treated successfully by dividing with a fine needle, as in a capsular operation after cataract.

SPARKLING SYNCHYSIS—*Synchysis scintillans*.—These euphonious titles have been given to the beautiful appearance which is presented by sparkling flakes of cholesterine floating in a fluid vitreous. They frequently abound in such quantities that they may be seen to descend in a perfect shower after every movement of the eye. With the ophthalmoscope the crystals of cholesterine look like chips of gold leaf, and make the vitreous closely resemble the liqueur called gold-water. The cholesterine is probably derived from blood, which at some distant period had been effused into the vitreous.

FLUIDITY OF THE VITREOUS—*Synchysis*—is the beginning of the end of many of the diseases of the eye which lead to blindness. It may be due to ophthalmitis, or to inflammation of the iris, choroid, or retina. It is one of the terminations of sympathetic ophthalmia, and is a frequent result of injuries of the eye accompanied with

deep or posterior intra-ocular hæmorrhage. It also usually occurs in hydrophthalmos, and in most cases of general staphylomatous enlargement of the globe. In many diseases, fluidity of the vitreous with softening of the eye follows increased tension: it is so in sympathetic ophthalmia, and in irido-choroiditis, and frequently also in glaucoma. It then indicates that the disease has done its worst, and atrophy of the tissues within the eye has commenced. A fluid vitreous does not necessarily imply a soft eye; the globe may in certain cases be of its normal tension, or it may be even glaucomatous and have its hardness increased. A soft eye, however, usually indicates a fluid vitreous, unless the diminution of tension has been caused by a recent escape of vitreous from an injury. Although a loss of consistence of the vitreous is commonly produced by some inflammatory disease, yet it may occur in eyes which have never suffered from an inflammatory affection and which still retain very fair sight. Such eyes, however, are prone to the early formation of cataract, and to detachment of the retina. This fluid state of the vitreous is frequently met with in extreme myopia associated with large posterior staphyloma, and in cases of cataract coming on in young people without any assignable cause, but probably due to defective nutrition arising from some constitutional ailment.

A loss of vitreous occasioned by some penetrating wound is rapidly replaced by aqueous. Fresh vitreous is never generated. If the amount lost be small, no ill effects may follow, as sufficient aqueous will be kept secreted to supply its place; but if the escape of vitreous be large, the eye usually suffers. For a while the globe is plumped out by aqueous, but the supply after a time fails to meet the demand, and the eye first becomes soft, then shrinks, and ultimately all sight vanishes.

FOREIGN BODIES IN THE VITREOUS.—A foreign body may be lodged in the vitreous and remain there for a long period provided it does not exert any injurious pressure on any of the other parts within the eye. The danger is, that with the motions of the globe its position may be shifted, and falling to the fundus may then excite a dangerous inflammation, which may lead to destruction of the other eye from sympathetic ophthalmia,

Treatment.—If the Foreign Body can be seen, an endeavour should be made to remove it. (See Article "Foreign Bodies within the Eye.")

HÆMORRHAGE INTO THE VITREOUS may take place,—1, from rupture of some of the vessels of the ciliary processes; 2, from choroidal hæmorrhage, the blood breaking through the retina and becoming extravasated into the vitreous; or, 3, it may ensue from the rupture of a retinal vessel, but this is rare.

Sudden and spontaneous hæmorrhage from the ciliary vessels or from the vessels in the anterior portion of the choroid occurs occasionally in young and middle-aged persons. It is sudden in its attack, and very liable to recur. The symptoms are sudden loss of sight, in some cases partial, in others complete. If the pupil be dilated with atropine, a blood clot may be seen either between the lens and the ciliary processes, or behind the lens and lying upon the front of the vitreous. In the latter class of cases some of the blood will generally find its way into the vitreous, and will then be seen with the ophthalmoscope as dark floating masses.

The prognosis in these cases is much more favourable than in retinal hæmorrhage; when the blood clot is anterior to the lens, the recovery is usually almost complete, but when the blood has been extravasated into the vitreous, although the patient may regain much of his lost sight, yet the recovery is slow. The unfavourable point in these cases is the liability to recurrence, as after each attack the eye becomes more damaged, and if the recurrences be frequent or severe, the sight may be destroyed.

Blood effused into the vitreous is but slowly absorbed. If the clot be small, it gradually loses its colouring matter, and shrinks, and after a few weeks or months it is seen with the ophthalmoscope either as a small dark mass, or as floating filaments in the vitreous. If, however, there has been much hæmorrhage, loss of the eye is certain to follow. To allow the blood to be extravasated, the hyaloid has to be ruptured, and wherever the blood forces its way, it breaks down the texture of the vitreous. From this mutilation of structure the vitreous does not recover; it atrophies, loses its consistence, and becomes fluid. The blood clot softens and is gradually dissolved, and its colouring matter stains the whole of the fluid

which occupies the vitreous space to a yellow or brownish-yellow tinge, which colour may last for years. The mischief, however, does not end here: for, as the vitreous becomes fluid, it diminishes in bulk; and the retina, losing the support which it had received from the healthy vitreous, falls forward and becomes detached.

Treatment.—Rest to the eyes by abstaining from reading or close work, and the avoiding of stooping positions. If there be pain the *lot. atropiæ* (F. 39) may be used, or a fold of lint wet with cold water may be laid over the closed lids. The medicines from which I have seen the most benefit have been the liquid extract of ergot (F. 72) and the iron alum (F. 88), given twice a day and continued for some weeks. The bowels should be kept regular, and a saline purgative given once or twice in the week if there be any tendency to constipation.

CHAPTER IV.

DISEASES OF THE CRYSTALLINE LENS.

CATARACT is an opacity of the lens. In the great majority of cases the opacity is confined to the lens substance, the capsule remaining transparent.

Capsular Cataract is the term used when the opacity is apparently limited to the lens capsule.

Capsulo-lenticular Cataract is when there is opacity of both the lens and its capsule.

CAUSES OF CATARACT.—Whatever interferes with the due nutrition of the lens tends to produce cataract.

a. It may occur from old age; it is then one of the results of senile decay, and has been rightly called “senile cataract.”

β. It may be dependent on a constitutional disease in which the general nutrition of the body fails, as in diabetes. This form is recognized as a “diabetic cataract.”

γ. It may be due to disease of the deep structures of the eye, the choroid and retina, to which it is indeed secondary. This class is distinguished as “secondary cataract.”

δ. It may be produced by injury, and it is then termed "traumatic cataract."

ε. Lastly, it may be congenital, or infantile.

CATARACTS may be divided primarily into two great classes—*soft* and *hard* cataracts.

I. SOFT CATARACTS may occur at any period between infancy and thirty or thirty-five years of age. They may be congenital, or they may be dependent on one or other of the causes already related; the consistence of the cataract being mainly determined by the age of the patient.

CONGENITAL AND INFANTILE CATARACTS.

THE CONGENITAL CATARACT, as its name implies, is a congenital defect, and differs from the infantile cataract which comes on after birth. Congenital cataracts are usually shrunken opaque lenses in eyes which are below the normal standard in size. They are frequently associated with nystagmus or involuntary oscillations of the globe,* and occasionally with congenital deficiencies, such as microphthalmos or small ill-developed eyes; or with a stunted bodily growth; or occasionally with mental impairments, varying from slight imbecility to idiocy. On the other hand, it is only right to say that I have seen congenital cataracts in well-grown patients, with good mental and bodily development.

THE INFANTILE CATARACT comes on after birth, and occurs in well-developed eyes. It is usually discovered during the early years of infancy, and is frequently associated with infantile convulsions.

There are two kinds of infantile cataract, each of which requires to be specially noticed—the "lamellar" and the "cortical."

Lamellar Cataract.—This form presents a peculiar and characteristic appearance. Within the lens there is seen a central opacity surrounded by a transparent margin, in which are occasionally a few striæ and opaque specks. The central nucleus and the superficial lamella of the lens are clear, and between these is a layer of

* See article on "Involuntary Oscillations of the Globe."

opaque matter of a uniform density, which constitutes the cataract. This is the usual form of infantile cataract. The sight is always more or less dim, and this defect is often attributed to myopia, as, to increase the size of the retinal images, the child holds his book close to his eyes. When the circumference of the lens is clear, the sight is improved by slight dilatation of the pupil, as in reading with his back to the light. Mr. Jonathan Hutchinson has shown that lamellar cataract is generally connected with an imperfect development of the enamel of the teeth. He says, "It is wholly different from that met with in congenital syphilis, and consists not so much in alteration of the form of the teeth as in defective development of the enamel." "The incisors, the canines, and the first molars are the teeth which suffer most; and as a rule, with but very few exceptions indeed, the bicuspid escape entirely. The contrast between the clean, white, smooth enamel of the latter, and the rugged, discoloured, spinous surface of the first molar, is often very striking. The first molars may, indeed, be counted as the test teeth as regards this condition; just as the upper central incisors are in that which is due to syphilis. In these teeth it occurs equally in both jaws. They are sometimes affected when all the other teeth escape, and I believe they never escape when the others suffer."*

The Cortical Cataract is where the opacity commences in the margin of the lens, and is seen as opaque striæ running from its circumference towards its centre. In the early stage of this form of cataract, the intermediate spaces are clear, and through them the fundus of the eye can be examined with the ophthalmoscope; but patches of cloudiness or opaque dots soon appear in different parts of the lens, and these gradually diffuse themselves and ultimately render the whole opaque. This form of cataract is rare in infancy.

Treatment—1. of Congenital Cataract.—If there is a small shrunken lens, consisting chiefly of opaque capsule, and with but little lenticular matter, the best plan is, having dilated the pupil with atropine, to make an opening well within the margin of the cornea with a triangular iridectomy knife, and through the wound to introduce a pair of iris forceps and seize the shrunken lens and draw it out.

* British Medical Journal, March 6, 1875.

If there should be any prolapse of the iris, it is better to snip it off with a pair of scissors than to return it.

If the lens should not be much shrunken, and there is evidently some lenticular matter, then an operation for solution or linear extraction may be performed.

2. Infantile Cataract.—In those cases in which the opacity is central, and the margin of the lens clear, and where there is reason to hope that the cataract is not progressive, an artificial pupil may be made either by a small iridectomy (page 99) or by a broad needle and Tyrrell's hook (page 101) opposite to that portion of the inner margin of the lens which is transparent. Good sight is often thus secured, and with less risk than that which accompanies the removal of the lens by solution. The patient sees through the margin of his own lens, and is able to use his eyes without the aid of cataract glasses. It should be remembered that in after years, when the whole lens becomes opaque, another operation will be required for its removal.

The operations which are suited for lamellar or other forms of soft cataract are—

1. Solution and absorption of the lens.
2. Linear extraction.
3. The suction operation.

OPERATION BY SOLUTION—*Keratonyxis*—consists in breaking up with a fine needle the central portion of the capsule of the lens, so as to freely admit the aqueous, and allow it to exert its solvent influence on the lenticular matter. A description of this operation is given at page 141, under the heading of "the first stage of the operation of linear extraction," the only difference being that the lens substance should not be quite so freely comminuted. The precautions which are there given, both prior to and after the operation, with reference to the dilatation of the pupil, must be rigidly followed. Occasionally one needle operation will suffice, but generally it has to be repeated two or three times before the whole of the lens is absorbed. The intervals between each operation must be regulated by the progress of the case; from three to six months is the time which is usually required. If after one of the needle operations the swollen lens should press injuriously on the iris and produce symptoms of irritation, the second stage of linear or suction extraction, page 142, should be at once

performed, and the lens, or what remains of it, be removed.

This method of dealing with a congenital or soft cataract is undoubtedly the safest of all the operations, and I believe the results on the whole are the most satisfactory. It presents, however, these difficulties: the process of the absorption of the opaque lens occupies a long period, and it is essential for the safety of the eye that the patient should continue during that time under the supervision of the surgeon.

LINEAR EXTRACTION OF CATARACT.—The operation known as Gibson's, from the late Mr. Gibson of Manchester, having first suggested and performed it, is now recognised and practised with some slight modifications, under the name of linear extraction.

It is well adapted to a large majority of the cases of soft cataract, but it is an operation which requires great care and great delicacy of manipulation.

Prior to performing the operation, the pupil should be fully dilated with atropine, so that the whole of the lens may be under the observation of the operator, and the iris may be drawn away as far as possible from the chance of injury.

The operation may be divided into two stages.

The first stage of the operation is to break up with a fine needle (Fig. 24) two-thirds of the anterior capsule of the lens; and by carefully moving the needle through the soft lenticular matter, so to comminute it that every portion of it may be brought in contact with the aqueous.

Great care must be taken not to injure the posterior layer of the capsule of the lens, as by so doing the hyaloid membrane would be ruptured, and the vitreous mixing with the particles of the lens would materially interfere with the due action of the aqueous humour on them, and also render more difficult the second part of the operation.

The difficulties which may beset this stage of the operation are—

1. The lens-capsule may be so tough that the point of the needle will puncture but not lacerate it, and all attempts to tear an opening will only cause the lens to shift about before the pressure of the needle without

FIG. 24.



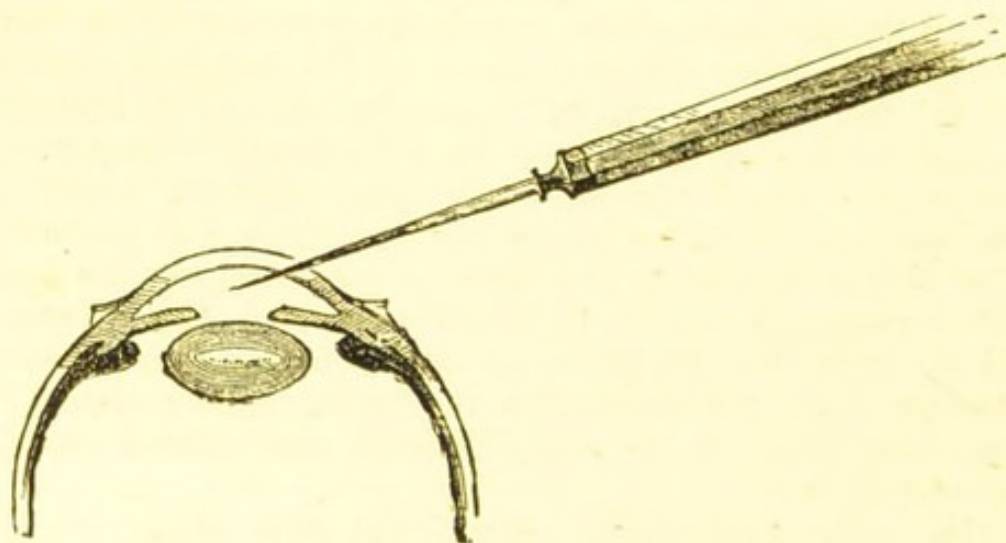
making any sufficient rent in the capsule. In such a case two needles should be used. The first needle should be introduced through one side of the cornea into the centre of the lens-capsule so as to fix the lens, whilst the second needle is passed through the opposite side of the cornea and made to penetrate the capsule at the same spot at which the first needle entered. The points of the two needles should now be drawn apart, and thus a free opening may be torn in the capsule without exerting any strain upon the suspensory ligament of the lens.

2. The central portion of the anterior capsule of the lens may be chalky or semi-opaque. When this is the case, the needle which is used to break up the lens substance should before its withdrawal from the eye detach the semi-opaque portion of capsule. A free opening should then be made with a broad needle in the cornea at a point corresponding with the pupillary edge, and with a pair of iris forceps the semi-opaque capsule should be seized and drawn out of the eye.

After the operation, the patient should be kept in a darkened room, but not in bed, and a solution of atropine of the strength of gr. 2 ad aquæ $\bar{3}$ 1 should be dropped into the eye twice a day.

The second stage of linear extraction consists in removing the broken-down lens through a small linear

FIG. 25.



opening in the cornea. Before it is attempted, if nothing has happened since the first operation to necessitate its immediate performance, sufficient time should be allowed to elapse for all the transparent portions of the lens to


become opaque, and somewhat macerated by the aqueous. From three to six days will be about the time required for the desired changes to take place, but much depends on the condition of the cataract at the time of the operation, and upon the extent to which the capsule has been torn, and the lenticular matter broken up.

The pupil being widely dilated with atropine, an opening is to be made in the cornea with a broad needle (Fig. 26) at a point just external to where the pupillary margin of the iris is seen. Instead of insert-

ing the needle through the cornea directly from before backwards, it should, as Sir W. Bowman has suggested, be made to pass obliquely inwards through the lamellæ of the cornea, as is represented in Fig. 25. The aperture thus made will be valve-shaped, the object being, that the curette in and after its introduction shall not press at all upon the iris.



FIG. 27.



A sufficient opening having been made, the curette (Fig. 27) is next to be introduced, and this should be done with a gentle lateral

motion. The eye being still held by the surgeon with a pair of forceps in the most convenient position, the curette is moved gently from side to side, pressing slightly on the mouth of the wound to permit the aqueous with the softened lens to flow down its groove. When the largest portion of the lenticular matter has escaped, small opaque pieces will occasionally be seen which have not flowed away in the stream; these may be followed by the curette, and on the point of it being dipped beneath them, they will also escape along its groove. All the movements of the curette must be conducted with the greatest caution, as it is essential that the posterior capsule should not be broken. When this accident happens, the opaque fragments of lens become entangled in the vitreous, and no further attempt should be made to remove them.

The lens having been removed, or as much of it as will readily flow away, the patient is to be sent to bed in a darkened room, and the pupil is to be kept under the influence of atropine.

When it is deemed advisable to extract a soft cataract,

I much prefer the "linear extraction" to a suction operation.

EXTRACTION OF SOFT CATARACT BY SUCTION.—This method of removing a soft cataract was reintroduced by Mr. T. Pridgin Teale, jun., of Leeds, who suggested the operation, and performed it with success in December, 1863, on a young man who had a traumatic cataract.

The extraction of the lens by suction may be completed in one operation, but my own feeling is that it is better, as a rule, to divide it into two stages. The first stage is the same as the preliminary needle operation for linear extraction described at page 141. Two, three, or four days having elapsed, *the second stage* or suction part of the operation may be performed, and the whole lens, now opaque and diffuent, will be readily drawn through the tubular curette of the instrument.

The second stage, or the suction part of the operation, may be performed as follows:—The pupil having been previously fully dilated with atropine, an opening is made in the cornea with a broad needle immediately within the pupillary margin of the dilated pupil, sufficient in size to allow of the *easy entrance* of the tubular curette. A delicate manipulation of the instrument is required to move it from point to point, so as to place the open mouth of the curette in the most favourable positions for sucking in the lens matter without in any way injuring the iris. The suction power must be carefully regulated by the operator, who is able to arrest it instantly if necessary.

In the suction instrument made by Messrs. Weiss of the Strand (Fig. 28), the suction is obtained through a delicate metal syringe placed at one extremity of a glass tube, which is furnished at the other end with a tubular curette, the aperture of which is countersunk. The syringe is so contrived, that with one hand the piston can be worked, and the movements of the curette within the eye guided, whilst the other hand is left free to fix the globe with a pair of forceps.

In the instrument devised by Mr. Teale, the suction power is applied by the mouth of the operator. It consists of a glass tube, to one end of which is fastened a tubular curette, whilst to the other extremity is attached a piece of india-rubber tubing with a glass mouth-piece.

II. HARD CATARACTS

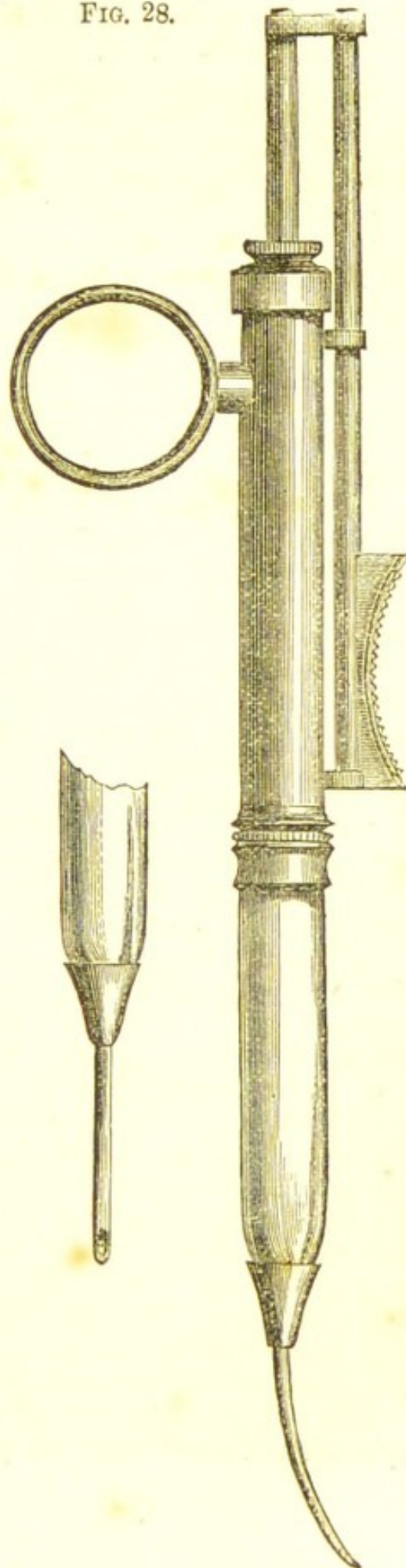
are characterized by a firm nucleus, and may occur at any period of life after thirty-five or forty years of age. Both eyes are usually affected, but not simultaneously. In the majority of cases the cataract commences in the left eye, and in its subsequent progress keeps in advance of the cataract in the right. There are different forms of hard cataracts, which are distinguished from each other—1, by the part of the lens in which the opacity begins; 2, by its general appearance; and 3, by the age of the patient.

Nuclear Cataracts are those in which the opacity commences in the nucleus, the marginal portion of the lens remaining for a time transparent.

Striated Cataracts.—The opacity first shows itself in opaque lines in the cortical substance of either the anterior or posterior surface of the lens, or in some cases in both simultaneously. These striæ radiate from the circumference towards the centre of the lens.

Black Cataracts.—There are two classes of cataract to which the name black has been given—1, to the hard opaque senile lenses, in which the nucleus has acquired an exceptionally dark reddish-brown colour; 2, to those rare cases in which a lens

FIG. 28.



with commencing cataract has become darkly stained with hæmatine from some prior extravasation of blood into the aqueous chamber. Dissolved in the aqueous, the hæmatine has permeated the lens capsule and been deposited in the lens substance.

Senile Cataracts usually occur from fifty to fifty-five years of age. They may be either nuclear or striated. They vary greatly in consistence, but are always distinguished by the presence of a distinct firm nucleus. In some cases the nucleus is small and hard, with a good deal of soft cortical matter surrounding it; in other patients the nucleus is large, hard, and amber-coloured, and with scarcely a trace of cortical substance. Lastly, there is a third class of senile cataracts, in which there is a small or medium-sized nucleus surrounded by an opaque but fluid cortex.

The progress of hard cataracts is very variable. In one patient its formation will be very rapid, whilst in another it will take many years before the whole lens becomes opaque. Again, it may be slow in the early stage, but develop itself quickly in the last.

Treatment of hard Cataracts.—As a rule it is wise to postpone an operation for the extraction of a hard cataract until the whole lens is opaque. This may be always conveniently done when one eye only is affected; but it often happens that the cataract is slowly advancing in both eyes, and the sight has become so far dimmed as to prevent the patient following the business on which his daily bread depends. In such a case the patient cannot afford to wait, and one of two courses may be pursued.

1. The lens may be removed from one eye by an extraction operation with iridectomy, see p. 152. If some soft cortical matter remains behind, the pupil must be kept dilated with atropine after the section has united.

2. Before attempting any operation the surgeon may tear through the central portion of the lens capsule with a fine needle, so as to admit freely the aqueous to render opaque the transparent portions of the lens. The patient should then be placed for a few days in a darkened room and the pupil kept under the influence of atropine, so as to ward off any of the inflammatory effects which pricking a hard lens will sometimes produce. When all irritation has subsided, the opaque lens may be extracted by the operation the surgeon may select.

When both eyes are affected with cataract, the two operations should *never* be performed at the same time.

The risk is too great. Some accidental cause, which on a future occasion might be averted, may influence the patient unfavourably, and both eyes may be lost. No operation should be done on the second eye until the result of the first has been decided.

For the extraction of a hard cataract one of the following operations may be selected:—

FLAP EXTRACTION OPERATION FOR CATARACT.—The principle of this operation is to make a section of the cornea of such a size as will admit of the easy exit of the lens. The incision should be confined throughout its extent to the true corneal tissue. The patient should lie on a couch with his head slightly raised, and the operator should stand behind. If he is ambidextrous, the knife should be held in his right hand for the right eye, and in his left for the left eye; but if he is unable to work with his left hand, he must stand in front of the patient, and make the corneal incision in the left eye with his right hand.

Operation.—First Step.—The upper lid is to be raised by the index finger of the operator, and maintained in this position by its tarsal margin being pressed slightly against the edge of the orbit, whilst the pulpy end of his middle finger is placed against the sclerotic on the inner side of the globe, to prevent its rolling inwards before the point of the knife has transfixed the cornea. The lower lid is to be drawn down by one finger of the assistant, with which he presses it against the malar bone, so as to avoid making any pressure on the eye. The point of a Beer's or Sichel's knife (Fig. 29), with its edge upwards, is now made to enter the cornea, just within the corneal margin, and at about the level of the centre of the pupil. The blade is then thrust steadily onwards across the anterior chamber in front of the iris, until its point transfixes the cornea at a spot corresponding to that at which it entered. The section is to be completed *slowly* in the withdrawal of the knife, the edge of which is to be directed slightly forwards as it cuts its way out. A too rapid completion of the incision is apt to be followed by a spasmodic contraction of the muscles of the eye

FIG. 29.



with an escape of the lens, and very probably of a part of the vitreous also.

When there is much spasm of the ocular muscles or straining on the part of the patient, it is often wise to draw out the knife before quite finishing the section, and thus leave a small bridge of cornea to be cut through with a small secondary knife (Fig. 30), after the capsule has been opened.

The second step of the operation is to tear through the anterior capsule of the lens. The patient is told to look downwards at his hands or his feet, so as

FIG. 30.



FIG. 31.



FIG. 32.



to expose fully the corneal wound, through which the ordinary pricker, or Graefe's cystotome (Figs. 31, 32) is then introduced sideways, and the capsule freely opened.

The third step is the evacuation of the lens through the corneal section. The patient is again directed to look towards his feet, when the operator places the point of his finger on the upper eyelid, and presses gently on the globe, whilst he applies the side of the curette (Fig. 27) along the lower lid, through which he exerts a steady pressure on the eye, which, if necessary, is so regulated as to alternate with that being made by the finger above. As the lens begins to escape through the wound, the pressure on the globe must be relaxed; and in many cases, just before its expulsion is completed, it must be entirely removed, as the too rapid exit of the lens is often accom-

panied by an escape of vitreous. After the operation is completed, and before finally closing the lids, one or two drops of gutt. eseriæ (F. 18) should be dropped into the eye. By contracting the pupil it tends to prevent prolapse of the iris.

ACCIDENTS WHICH MAY HAPPEN IN THE COURSE OF THE OPERATION.—*a.* The aqueous may escape too soon, so that the iris may fall in front of the knife. When this happens the operator should press the cornea gently against the blade with one of his fingers, whilst at the same time he continues the section with the edge of the knife turned slightly forwards. By this manœuvre the iris will often be made to recede, and the section be completed without cutting it.

β. The section may be too small. When this is the case, the incision should be enlarged with a secondary knife.

γ. The vitreous may escape before the lens. This may be caused by the incision being carried into the sclerotic, or from the straining and struggling of the patient. When this casualty occurs, all pressure on the eye should be at once released, and the lens should be withdrawn from the eye, if possible, in its capsule, by one of the spoons (Figs. 33, 34) used in the traction operation for cataract.

δ. Deep intra-ocular hæmorrhage may occur. This is the most fatal accident which can happen; the eye is always irrecoverably lost. It most frequently occurs in eyes which are glaucomatous, or otherwise previously diseased. The bleeding usually takes place from between the choroid and sclerotic. (See Article HÆMORRHAGE BETWEEN CHOROID AND SCLEROTIC.)

THE TRACTION OPERATION FOR CATARACT was first suggested by Von Graefe for those forms of traumatic cataract where the nucleus was too dense to be easily removed by linear extraction. His assistant, Dr. Schufft (now Waldau) extended the application of this operation to cases of ordinary cataract, and designed a series of scoops for the drawing out of the opaque lens from the eye. His description of the operation is published in the Royal London Ophthalmic Hospital Reports, vol. iii. page 159. The object of the operation

is to draw the opaque lens out of the eye through a slit-like opening, in preference to the large incision with the corneal flap.

The first stage of the operation is to make an incision in the margin of the cornea at the corneo-sclerotic junction with a lance-shaped iridectomy knife. The opening should always be made sufficiently large to allow of the easy introduction of the scoop, and the ready escape of the lens. If the aperture is found on the withdrawal of the knife not to be ample enough, it should be enlarged laterally by a pair of scissors. A piece of iris is next to be exercised as in the operation for iridectomy, p. 99.

The second stage of the operation is to tear through the capsule of the lens. This is to be done with an ordinary pricker (Fig. 31), or with Von Graefe's fleam-cystotome (Fig. 32), which should be gently introduced sideways through the section, so as to avoid tearing the iris or scratching the inner surface of the cornea.

FIG. 33.

FIG. 34.

FIG. 35.

FIG. 36.

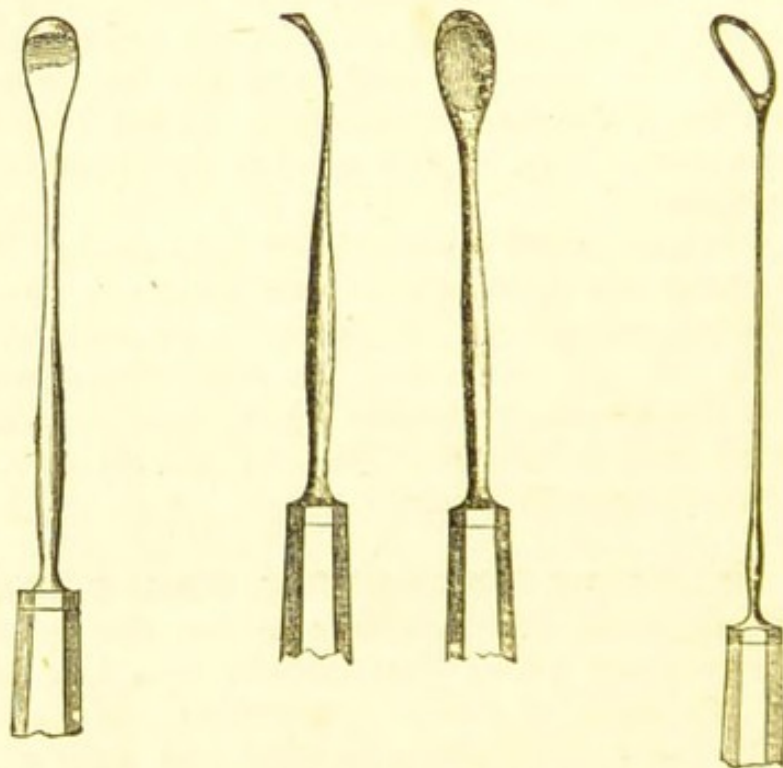


Fig. 33, Front view of Critchett's spoon. Figs. 34, 35, Front and side view of Bowman's spoon. Fig. 36, Taylor's scoop.

The third stage of the operation is the withdrawal of the lens from the eye. This is accomplished

by gently introducing the traction instrument through the wound, using scarcely any perceptible force, but urging it onwards by one or two slight lateral movements, directing it at the same time first a little backwards, so as to insinuate its extremity between the posterior surface of the lens and its capsule, and then downwards and slightly forwards, allowing it almost by its own weight to follow the posterior curvature of the lens. Having secured the lens within its grasp, the instrument is to be gradually withdrawn, slightly depressing its handle during this movement, so as to draw the lens with it out of the eye. If the whole lens, as occasionally happens, is brought out with the first withdrawal of the instrument, the operation is completed. Generally, however, some soft lenticular matter is left behind, and sometimes some fragments of the nucleus which have become detached. A cataract spoon must now be reintroduced to bring away the lens matter which remains.

This operation is seldom performed except in cases of dislocation of the lens, when it is generally desirable to extract the lens in its capsule with one of the traction instruments.

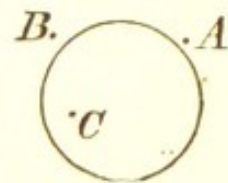
GRAEFÉ'S MODIFIED LINEAR EXTRACTION.—The principle of this operation is the extraction of the lens through an almost straight opening, the arc of a large circle made in the sclerotic close to the margin of the cornea.

The lids should be separated by a stop-speculum, and the globe steadied by a pair of forceps in the left hand of the operator, with which he takes hold of the conjunctiva and deep fascia at a point just below the centre of the cornea. The point of a fine knife (Fig. 37) is then inserted at A Fig. 38, about $\frac{1}{2}$ " from the margin of the cornea; it is first to be directed towards C, so as to extend slightly the inner wound, and when it has fairly entered the anterior chamber, it is to be turned upwards

FIG. 37.



FIG. 38.



to B, where the counter-puncture is made. The blade is now pushed on a little way in the scleral plane, and then being turned steeply forwards, it should cut its way out. The section should be completed in the withdrawal of the knife. The length of the incision must be proportioned to the size and density of the lens. A small flap of conjunctiva is generally made with the sclerotic section.

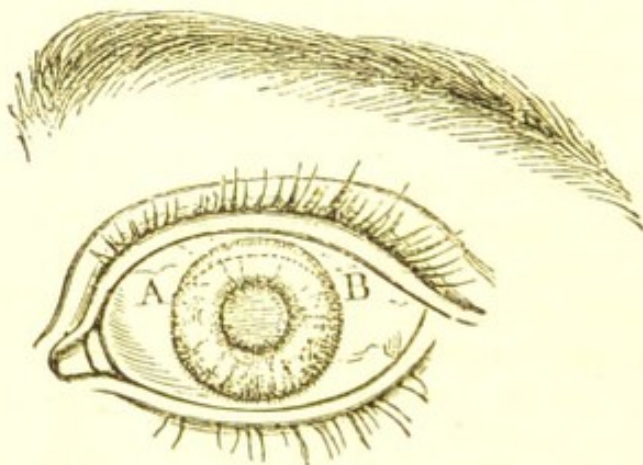
A portion of iris is next seized with the iris forceps and cut off, taking care that no ends of it are left in the edges of the wound. The lens-capsule is then opened with the cystotome; and finally the lens is made to escape through the scleral incision by one of the methods described at page 153.

The objections to Graefe's operation are, from the incision being made in the sclerotic, there is a tendency to produce sympathetic ophthalmia in the other eye, a calamity I have known happen several times. There is also a greater risk of loss of vitreous than when the section is made either in the cornea, or through the corneo-sclerotic junction.

The operation which I perform, when the patient is able and willing to take an anaesthetic, is the following:—

The speculum having been introduced between the lids, and the eye fixed by seizing a small fold of the conjunc-

FIG. 39.



tiva near the margin of the cornea with the fine-toothed forceps, the section of the cornea is made with a Graefe's knife (Fig. 37), the point of which should enter the margin of the cornea on a level with the upper edge of the pupil, as represented in Fig. 39. I prefer to confine

the section to the cornea, and not to trespass on the sclerotic.

A and B in Fig. 39 show the points of entrance and exit of the knife in the incision. A piece of iris is then to be seized with the iris forceps, and being drawn out of the wound, removed with one snip of the scissors. The capsule is next opened with the pricker.

FIG. 40.



The last step in the operation is to expel the lens from the eye through the corneal wound. This is facilitated by several manœuvres.

1. The method I prefer is to press with the curette slightly against the sclerotic edge of the wound, so as to cause it to gape, whilst a sliding upward pressure is made against the lower edge of the cornea with the back of the tortoise-shell spoon. (Fig. 40.)

2. If the eye is turned much upwards, the globe may

FIG. 41.

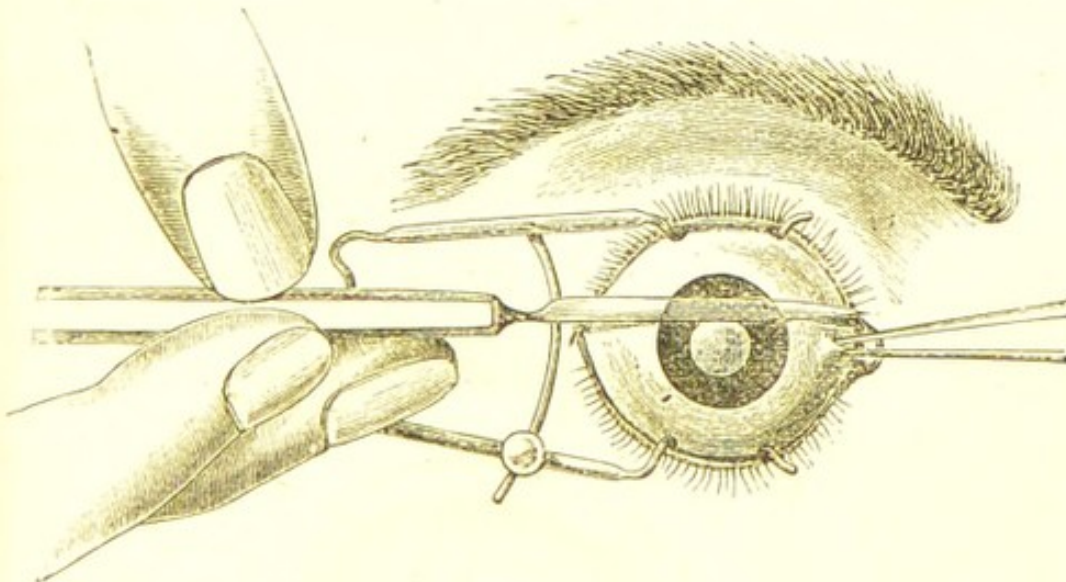


Fig. 41 shows how the knife is held during the extraction of cataract. The handle near the blade rests on the side of the extremity of the middle finger, and against the end of the ring finger, the end of the thumb steadying the handle from above. In the woodcut, the operator is supposed to be behind the head of the patient, and the operation on the right eye.

be drawn downwards with the fixing forceps, and at the same time an upward pressure be made against the lower edge of the cornea with the tortoise-shell spoon.

3. If preferred, the method recommended in the Article on Flap Extraction of Cataract may be adopted.

The lids are now to be closed with a single narrow strip of adhesive plaister placed across their margins, and the cataract bandage applied.

When, from any cause, the anæsthetic is not given, I perform a flap extraction, but make the corneal section with a Graefe's knife. (See Flap Extraction, p. 147.) The section made with a Graefe's knife is the arc of a larger circle than that made with a Sichel's, and is less of a flap. No speculum nor fixing forceps are required, and no iris is excised. The operation is thus made with but little suffering, and the danger of loss of self-control on the part of the patient, as far as possible, avoided.

I prefer it to Liebreich's operation, as the section is entirely within the cornea. The cases best suited for this operation are senile cataracts in thin, wiry patients, who have rather deep-set eyes, and who possess good control over their emotions.

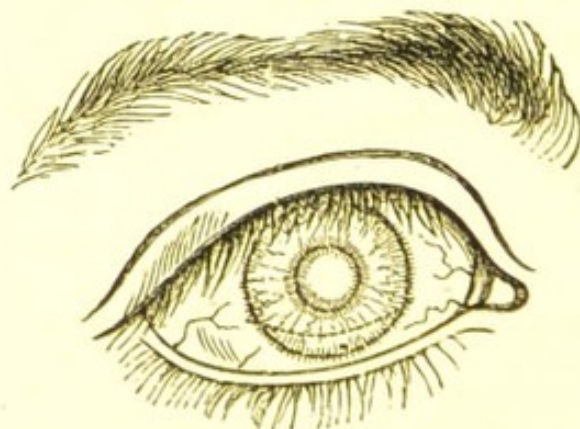
LIEBREICH'S OPERATION FOR CATARACT.—

The following is Dr. Liebreich's description of his operation:—

“The incision of the cornea is to be made with the smallest possible Graefe's knife in the following manner:

“Puncture and contra-puncture are made in the sclero-

FIG. 42.



tic about one millimetre beyond the cornea, the whole remaining incision passing with a very slight curve through

the cornea, so that the centre of it is about one millimetre and a half distant from the margin of the cornea. (Fig. 42.) This incision can be made upwards or downwards, with or without iridectomy, and the lens can be removed through it with or without the capsule.

"If, as I now practise, the extraction is made downwards without iridectomy, the whole operation is reduced to the greatest simplicity, and does not require narcosis, assistance, elevator, or fixation; and only two instruments—namely, Graefe's knife and one cystotome, with Daviel's spoon."*

PAGENSTECHER'S OPERATION FOR CATARACT differs from all the others in that he removes the lens in its capsule entire. He makes a flap incision, usually downwards, and entirely through the sclerotic, leaving a small bridge of conjunctiva at the apex of the flap. He next excises a large segment of the iris, and then completes his section by dividing the conjunctival bridge. By gentle pressure on the eye he now endeavours to urge the lens in its capsule through the sclerotic wound, but should he fail in doing so, or if any vitreous should escape, he at once introduces a scoop behind the lens, and draws it out of the eye in its capsule. Pagenstecher states that on several occasions he has succeeded in thus extracting the lens without the loss of any vitreous, notwithstanding that in some of the cases it was accomplished by the aid of the scoop. He also refers to the remarkable absence of iritis after this operation.

MACNAMARA'S OPERATION FOR CATARACT.—The following abstract is from Mr. Macnamara's account of his own operation:—

"The pupil having been fully dilated with atropine, the patient laid on his back, and placed under the influence of chloroform, the operator adjusts a stop-speculum. Supposing the right eye is to be operated upon, the surgeon standing behind his patient, with a pair of fixing forceps seizes a fold of the conjunctiva together with the tendon of the internal rectus so as to have a steady firm hold of the eyeball, and in the other hand takes a short and broad-bladed triangular knife, and thrusts its point

* *British Medical Journal*, Dec. 2, 1871.

through the line of junction of the cornea and sclerotic, on the temporal side of the eye. The blade of the knife is to be passed steadily onwards, nearly up to its heel, so that the incision made through the sclerotic is at least half an inch long. The knife being laid on one side, but the speculum and hold of the internal rectus retained, the scoop is to be inserted so far into the anterior chamber as to enable us to reach the margin of the pupil; the handle of the instrument being raised, and its rounded extremity depressed, the latter evidently rests on the capsule of the lens, immediately within the margin of the pupil. The scoop is now to be slightly withdrawn, still keeping its extremity on the lens, but so as to draw open the pupil far enough to enable us to pass the scoop round the outer circumference, and thus behind the lens, the scoop being thrust onwards along the posterior capsule, until its toothed extremity embraces the inner margin of the lens; in this way the lens comes to lie in the concavity of the scoop, and may be removed from the eye, if possible, without breaking the capsule. Should the capsule of the lens be ruptured, however, during the above-described manipulation, the bulk of the lens must still be drawn out of the eye by means of the scoop; and subsequently particles of lenticular matter remaining in the anterior chamber must be taken away.*

TREATMENT OF THE EYE AFTER AN EXTRACTION OF THE CATARACT.—After the operation is completed, both eyelids should be gently closed, and a Moorfields bandage (F. 1) applied; and the patient should then be placed in bed in a darkened room with the head slightly raised. If the case progresses favourably, the patient may be allowed to get up after thirty-six hours, and lie on a sofa, or, if in a hospital, rest on the outside of his bed. After a flap extraction, the lids should not be opened to look at the eye until the seventh day; but after a modified linear, or a traction, operation, the eye may be examined with safety on the third or fourth day. The bandage should be changed night and morning, as the flow of tears renders the linen wet and uncomfortable. If the lids become gummed together, a piece of linen wet with tepid water should be drawn a few times

* Macnamara, On Diseases of the Eye, 3rd edit. p. 508.

across their tarsal borders, and then gently pulling down the lower lid with one finger, they may be sufficiently parted to allow any pent-up tears to escape. If the patient should complain that the cotton-wool pad makes the eye hot, it may be removed, but the fold of linen over the eyes and the bandage should be continued. After about eight or ten days the bandage may be given up, and a broad shade be worn over both eyes. Three or four times during the day the lids should be bathed with tepid water, or, if there is any irritation, with the belladonna lotion (F. 40). When there is restlessness after the operation, an opiate, or, what is better, a subcutaneous injection of from one-sixth to one-fourth of a grain of morphia should be given at bedtime; and if the patient complains of severe pain in the eye, sufficient to prevent sleep, two or three leeches should be applied to the temple. If these fail to give relief, the bandage should be removed, and a fold of linen wet with cold or iced water should be laid over the closed lids, and changed as often as it becomes hot or dry. A mild purgative must be ordered if necessary, so as to insure the regular daily action of the bowels without straining. The patient should be allowed his regular diet, with the exception of the day of the operation, when I generally advise only beef-tea and farinaceous food.

THE CASUALTIES WHICH MAY OCCUR AFTER AN EXTRACTION OF A HARD CATARACT are:—

1. Prolapse of the iris. This is peculiar to the flap-extraction, and to those operations in which no portion of the iris is removed.
2. Iritis.
3. Suppuration of the cornea.
4. Acute ophthalmitis and suppuration of the globe.
5. Imperfect union of the corneal wound, and consequent fistula.
6. Cystoid cicatrix.

1. Prolapse of the iris may come on from the first to the fifth day after an extraction operation in which no portion of iris has been excised, and sometimes even later. It is the most frequent cause of failure of flap extraction, and in many cases seems to be due to the irritation excited by some cortical lens matter left in the pupil at the time of the operation. It is, however, often produced by some

spasmodic action on the part of the patient, such as coughing or sneezing, or by some violent emotion.

Treatment.—At first apply a compress bandage (F. 3), and leave the prolapse alone. If after a fortnight or three weeks the prolapse continues large and shows no tendency to subside, it may be pricked at two or three points with a fine needle, and the compress be reapplied. This pricking operation may be repeated two or three times at intervals of three or four days.

2. **Iritis** after extraction, is usually **chronic and serous**. It commences as a rule from one to three weeks after the operation. It is always accompanied with photophobia and lachrymation, and frequently with the edges of the lids puffy, thickened, and excoriated. (For a further account of this form of Iritis, see **TRAUMATIC IRITIS**, p. 90.)

Treatment.—Belladonna to the eye in one form or another to relieve pain and keep the pupil dilated. Tonics of quinine or iron, or both (F. 79, 80, 81), should be given. Counter-irritation in the form of small blisters the size of a shilling to the temple or behind the ear occasionally do good; and if the case is very obstinate, benefit is sometimes derived from a moderate mercurial inunction.

The acute iritis is comparatively rare. It usually follows one or two days after the operation, and unless soon arrested it may lead to the destruction of the eye. Occasionally it will partially subside, and then become chronic.

Treatment.—Leeches to the temple and cold applications to the eye. A fold of linen should be laid over the closed lids, and be moistened with iced water as often as it becomes hot or dry. If the cold ceases to be grateful to the patient, hot fomentations of poppy-heads or belladonna (F. 9, 10) may be substituted. Diffusible stimuli and tonics (F. 67, 77, 79) should be ordered, with a liberal diet, and opiates be given if necessary to relieve pain and produce sleep. Mercury in any form is seldom of use in these cases; it usually depresses the patient, and so does absolute harm. In the acute traumatic iritis which follows the extraction of cataract, there is a strong tendency for the inflammation to spread to the neighbouring tissues, and thus to drift into ophthalmitis or general inflammation of the eye.

3. **Suppuration of the Cornea** may be either partial or complete. It may commence in the line of the incision

and involve more or less of the corneal flap, to which it may be limited; or it may be diffuse, and include the entire cornea.

Symptoms.—Increasing pain in the eye and around the orbit; œdematous swelling and redness of the lids; chemosis of the conjunctiva and a muco-purulent discharge.

If the suppuration is **partial and circumscribed**, the line of the incision will look opaque and yellow, and there will be some purulent infiltration extending into the flap of the cornea, whilst the lower part of the cornea, although perhaps slightly turbid, will still retain some of its transparency and polish. This condition of the eye is sufficient to create great anxiety, but if the suppuration can be confined to the margin of the wound, it is not hopeless. The dangers are—1, That the suppuration will become diffuse; 2, that it will extend itself to the deeper structures and induce a suppurative inflammation of the globe; 3, that although the suppuration of the cornea may be subdued, a secondary iritis or irido-cyclitis may follow, which will in the end produce softening and atrophy of the globe.

When the suppuration of the cornea is **diffuse or complete**, the symptoms are the same but intensified. The suppuration, instead of being confined to the margin of the flap, invades the whole structure of the cornea. The eye must then be considered as irreparably lost.

In old and feeble patients suppuration of the cornea will occasionally occur without the usual inflammatory symptoms of pain with redness and swelling of the lids being manifested. This once happened to a poor old woman, who had long been an inmate of a workhouse, on whom I operated for cataract. With only a sense of grittiness in the eye, and with the slightest trace of swelling of the upper lid, partial suppuration of the cornea followed on the fifth or sixth day after the operation.

Treatment.—An attempt may be made to ward off the early symptoms by the application of two or three leeches to the temple, and iced water to the eye; but as soon as it is ascertained that suppuration of the cornea has commenced, a different treatment should be adopted. Warm fomentations of poppy-heads or belladonna give the most relief, and may be used every two or three hours, and in the intervals a fold of lint should be laid over the eye

and kept moist with warm water or the belladonna lotion. Pain should be relieved by repeated doses of opium, which may be combined with ammonia, quinine, or liq. cinchonæ (F. 76). The patient should be fed up with such food as he can be prevailed on to take, and a moderate allowance of wine be ordered for him. A compress bandage (F. 3) applied to the eye on the first indication of corneal suppuration is often of service, and may be used jointly with the warm applications, the bandage being removed three or four times daily to allow of the fomentations. If the pressure be painful it should not be persevered in.

4. Acute Ophthalmitis and Suppuration of the Globe.—When this happens the eye is lost, and the only course to be pursued is to hasten the suppuration by warm and soothing applications; to give free vent to the pus by an incision through the cornea if necessary; to relieve pain by opiates; and to support the patient by tonics, stimulants, and a good diet.

5. Imperfect Union of the Corneal Wound and consequent Fistula.—From some cause, often difficult if not impossible to explain, the wound of the cornea after the extraction of cataract fails to unite completely, and a small fistula remains through which the aqueous slowly dribbles.

Treatment.—A compress bandage (F. 3) should be placed over the closed lids, and twice a day a few drops of a solution of atropine, gr. 1 ad aquæ $\bar{\text{z}}$ 1, be dropped into the eye. This treatment generally succeeds in closing the fistula, but if after a fair trial it produces no effect, the opening in the cornea may be touched with a fine camel's-hair brush charged with nitrate of silver, as recommended at page 50.

For the symptoms and further treatment of corneal fistula, see FISTULA OF THE CORNEA, page 50.

Cystoid Cicatrix.—This can only occur when the incision has been made in the sclerotic. It is due to the edges of the wound not coming into close contact and to their consequent union through the intervention of cicatricial tissue, which gradually yields before the outward pressure of the parts within the eye, and becomes thinned and bulging. This condition of the cicatrix in the sclerotic will be occasionally met with after iridectomy for glaucoma. It is most liable to happen in eyes in which there is an increased intra-ocular tension.

Treatment.—If the cystoid cicatrix is small or gives no inconvenience, it is best to leave it alone. When large or troublesome, it may be punctured with a broad needle. If the bulging of the cicatrix is on the increase, and the tension of the eye is glaucomatous, an iridectomy should be performed.

CAPSULAR CATARACT is a misnomer. There cannot be an opaque capsule and a transparent lens. There may be an opaque and chalky capsule containing the shrunken remains of a lens, or there may be an opaque capsule filling the pupil after the lens from some cause has gone; but neither of these can be considered as examples of capsular cataract. The class of cases to which the term can be most correctly applied are those in which there are spots or patches of opacity on the capsule with a perfectly transparent lens.

These local opacities may exist under two circumstances:—

1st. Patches of opacity on the lens capsule may be formed from inflammatory exudations during iritis or other inflammations of the eye. They are usually central and correspond to the pupil, but occasionally they are deposited as a white zone around the margin of the lens, and can be only detected when the pupil is dilated.

2nd. In young children one or more white spots are occasionally seen on the lens capsule, the lens itself being clear. On examining the cornea of such eyes, a small nebula will be frequently found to correspond with the speck on the lens capsule; and on inquiry it will be found that these patients have had ophthalmia neonatorum. The inference is that during the attack the swollen cornea and the most prominent part of the lens came together, and that the capsule at the point of contact then became opaque. It should be remembered that in newly-born children the space between the centre of the lens and the cornea is so small as hardly to deserve the name of an anterior chamber. When the central capsular opacity is single and prominent, it has been called **pyramidal cataract**.

CAPSULO-LENTICULAR CATARACT.—In this form of cataract the capsule partakes of the opacity. It may not be absolutely opaque, but its transparency is so affected that it would materially interfere with vision

after the opaque lens has been removed. This opacity is generally confined to the anterior layer of the lens capsule.

Treatment.—In these cases the plan practised by Sir W. Bowman should be adopted. After the section of the cornea has been completed and the piece of iris excised, if an iridectomy has to be performed, instead of tearing through the lens capsule with the ordinary pricker, a pair of fine iris forceps is introduced through the corneal wound, and seizing hold of the anterior layer of the capsule, it is withdrawn from the eye, and the operation of extraction of the lens is then completed in the usual way.

DIABETIC CATARACT.—The only peculiarity in this variety of cataract is its origin. The opaque lens presents no characteristic to distinguish it from cataract arising from other diseases, or from senile decay. As diabetes frequently attacks young people, this disease may be considered as one of the causes of cataract in early life. The cataract is usually soft, but this is due to the age of the patient, who is generally below the period of life at which cataract is common. In diabetic cataract the opacity is probably dependent on impaired nutrition.

Treatment.—The same as for ordinary cataract. The presence of diabetes has been urged as a reason for not operating; but if the patient is apparently in fair health and not much emaciated, an operation is certainly not contra-indicated. I have on several occasions operated myself for diabetic cataract, and have frequently seen my colleagues do so at the Ophthalmic Hospital, and in no case have any unfavourable symptoms followed.

FLUID CATARACT usually occurs in young patients and is sometimes congenital. It has a uniform greyish-white milk-and-water colour without any visible striæ or spots. The fluidity does not always include the whole lens; it occasionally happens that within a fluid cortex there is a small firm nucleus. There is, however, a form of fluid cataract which is met with in elderly people which seems to be an advanced stage of degeneration of the lens. The lenticular matter is converted into a semi-transparent yellowish fluid, which contains oil globules and sometimes plates of cholesterine. In some exceptional cases the fluid is of a dark chocolate or sepia colour. Mr. Haynes

Walton relates the case of a lady, æt. seventy-seven, on whom he operated, in which "the capsule did not contain a particle of lens, but was filled with material like coffee-grounds."*

Treatment.—The same as for other forms of cataract. If after the section has been made in the cornea and the lens capsule opened with the pricker the lenticular matter is found to be fluid, it may be either sucked out with a syringe or allowed to escape along the groove of a curette.

TRAUMATIC CATARACT, or cataract the result of an injury to the eye, may occur either with or without a rupture of the external coats of the eye.

1. Traumatic Cataract with Rupture of the External Coats of the Eye.—One of the most frequent complications of a wound of the cornea is an injury to the lens. Wounds of the lens terminate almost invariably in cataract. The point of injury is within twenty-four hours indicated by an opaque patch, and this opacity gradually increases until the whole lens becomes opaque. The rapidity of the formation of the cataract will depend partly on the extent of the injury inflicted on the lens and its capsule, and partly also on the age of the patient. If the rent in the capsule is large, and the lenticular matter has also been broken into, the aqueous humour will be rapidly brought into contact with the lens substance, and its transparency will be quickly destroyed. In the young, the lens is soft, and becomes more rapidly cataractous from an injury than in the aged, where it is more dense and has a firm nucleus. The immediate effect of a wound of the lens is the admission of the aqueous within its capsule. This is imbibed by the lens tissue, each part of which becomes opaque, and rapidly swells as it is brought under the influence of the aqueous; so that the swelling of the lens increases with the opacity until the whole is opaque. The lens thus swelling frequently presses on the posterior surface of the iris, and excites great irritation: hence it is of the utmost importance that the pupil should be kept fully dilated with atropine, in order to afford space for the swelling lens, and to prevent as far as possible its encroaching on the iris.

* Surgical Diseases of the Eye, 2nd edition, p. 512.

The irritation which is thus excited by a cataractous lens is greater and more apt to occur in the adult and aged person than it is in the child. The most serious symptom which the pressure of a swollen lens on the back of the iris is apt to produce is a glaucomatous hardness of the globe—a condition known as **traumatic glaucoma**. It is ushered in with increased pain and irritation; the anterior chamber is diminished in size from the lens having pushed the iris forwards towards the cornea; the eye has a pinkish tinge from a general fulness of the sclerotic vessels, but especially of those which form the ciliary zone, and the tension of the globe is increased. This state of eye is fraught with danger, and always demands immediate treatment.

Traumatic cataract with rupture of the external coats of the eye is very commonly associated with a prolapse or laceration of the iris, or with both; indeed it is more usual for it to be accompanied with some lesion of the iris, than for the injury to be confined to the lens.

2. Traumatic Cataract without Rupture of the External coats of the Eye.—Sudden violence against the eye, or to the bony parts which surround it, may cause, without any rupture of the external coats of the eye, a rent in the capsule of the lens sufficient to allow the aqueous to permeate its structure and to render it cataractous. Von Graefe noticed that in such cases the rent is generally at the periphery of the lens, or within the area of the thin posterior capsule, but never in the middle of the anterior capsule.

Again, a blow on the eye may, without any apparent injury of the lens capsule, so disarrange the internal structure of the lens that its nutrition will become impaired, and as a result its transparency will be destroyed. This accident is more rare than the preceding, in which the lens capsule is torn. The form of cataract which is usually produced is a diffused opacity; a portion of the lens first becomes nebulous, and this nebulosity increases until the whole lens is opaque.

Treatment of Traumatic Cataract.—1. If the cataract is *uncomplicated with injury to the iris*, and has been caused by some fine sharp-pointed instrument penetrating the cornea, there is good reason to hope for a favourable result. A solution of atropine, gr. 1 ad aquæ ʒ1, should be dropped twice or three times a day into the eye to dilate the pupil fully, and thus to keep the iris out

of the way of the swelling lens. A compress and bandage should be fastened over the closed lids, or, if it is more comfortable, a fold of linen wet with cold water or the belladonna lotion (F. 40) may be laid over the eye. If there is pain in the eye or around the orbit, two leeches should be at once applied to the temple. The patient should be kept in a darkened room. If after all the irritation occasioned by the injury has subsided, a gradual absorption of the lens matter is found to be going on, it is wise not to meddle with the cataract, but to keep a careful watch over the eye, and be prepared to treat symptoms as they arise, being guided by them in the future management of the case.

2. If the wound in the lens is *complicated with injury to, or prolapse of, the iris*, attention must first be directed to the iris, which, if prolapsed, will require to be dealt with in one of the ways suggested under the heading PROLAPSE OF THE IRIS. The general treatment recommended in the preceding section must be also adopted here, and if no untoward symptoms arise, the cataractous lens must be left untreated until the eye has quite recovered from the primary shock of the injury.

Whenever a traumatic cataract excites great irritation or induces symptoms of traumatic glaucoma, the lens should be at once removed. The operation to be selected will depend on the density of the lens, the general condition of the eye, and the age of the patient. As a rule, when the lens is *soft*, a linear extraction should be performed, and an iridectomy may be combined with this operation if circumstances render it advisable.

If, however, the patient is advanced in years, and the lens consequently more or less hard, the best operation will be the extraction operation with iridectomy, see page 152.

SECONDARY CATARACT is when the opacity of the lens is dependent on, and secondary to, disease of the vitreous, choroid, or retina. In these cases the lens not only grows opaque, but frequently undergoes a further degeneration, and earthy salts, the carbonate and phosphate of lime, are deposited both in it and in its capsule. The appearance of such a lens is very characteristic; it is usually somewhat shrunken and flattened, with a peculiar opaque chalky look, and either strikingly white or tinged slightly with yellow.

It is often associated with other degenerative changes within the eye, and occurs conjointly with bony formations on the choroid, and secondary detachments of the retina.

Treatment.—Secondary cataracts, as a rule, are best left alone. In the majority of cases, the eye, when the cataract is complete, is blind, and the extraction of the lens would give no improvement of sight. Even in the most favourable instances, where there is some perception of light, and a moderately active pupil, the fundus of the eye is usually so unsound that it is always doubtful whether the slight chance of benefit is sufficient to justify the risk of an operation. Certainly, when the patient has one eye good, no operation for the extraction of an opaque and chalky lens in the other should be performed.

CAPSULAR OPACITIES.

CAPSULAR OPACITIES FOLLOWING THE LOSS OF THE LENS.—After the lens has been removed, either by absorption or extraction, some density of the capsule which has been left is very apt to occur, and to greatly mar the excellence of vision which the patient would otherwise possess. The degree of opacity varies very much, and is dependent on different circumstances.

The simplest form of Opacity of the Capsule is that which often occurs after an operation for the removal of the lens, especially after linear or suction extraction. Its formation is unaccompanied with any inflammatory action. Examined with the ophthalmoscope, a film of capsule will be found occupying the pupillary space, not actually opaque, but with its transparency sufficiently dulled to interfere with the due passage of the light to the fundus of the eye. Sir W. Bowman has shown that the capsule may cause a serious imperfection of sight *without* becoming opaque, by assuming a wrinkled and folded state, so as to produce an unequal refraction of light in its passage through it, and a consequent confusion of the image on the retina.

The second form of Opacity of the Capsule is where the membrane itself is semi-opaque, but its opacity is considerably increased by bits of soft lenticular matter

having become enclosed between parts of the anterior and posterior layers of the capsule. If the pupil be dilated with atropine, the opacity of the capsule will be seen to vary in density in different points of its area, according to the quantity of lens matter which has been enclosed between its layers. This form of opacity is not necessarily accompanied with any inflammatory action.

The third form of Opacity of the Capsule is always associated with iritis. Lymph is effused on the surface of the capsule, and adhesions more or less extensive between it and the iris close the pupil. The capsule itself becomes opaque, and blending with the lymph upon its surface grows tough, and almost fibrous in its structure, losing all its natural elasticity. This state of the capsule is very frequently combined with some soft opaque lens substance shut in between its layers; indeed, in many cases it is due to the irritation which has been excited from some lenticular matter having been left behind at the time of the operation for the extraction of the lens.

It is this form of membranous opacity which frequently undergoes after a lapse of time a degeneration of structure; in some cases losing the toughness it at first acquired, it becomes brittle and friable, allowing a needle or a pair of iris forceps to pass through it like tinder; or it may in after years become the seat of earthy deposits. The second form of capsular opacity I alluded to, where a portion of lenticular matter is enclosed between the layers of the capsule, is also liable to degenerative changes, and to have earthy salts deposited in the vestiges of the lens between its folds.

TREATMENT OF CAPSULAR OPACITIES.—In treating opacities of the capsule after the lens has been removed, it may be taken as a rule which should never, if possible, be departed from, that no operation should be performed so long as the eye is red or irritable.

Needle Operation for Opaque Capsule.—A single needle is usually sufficient to tear an opening through the semi-opaque or wrinkled capsule which is often found after an ordinary operation for cataract, but two needles should be in readiness in case a second is required.

Before commencing the operation the pupil should be fully dilated with atropine. The needle should penetrate

the cornea obliquely about one or one and a half lines from its circumference, and passing across the pupil to the opposite side, it should puncture the capsule close to the iris, and by then slightly depressing the hand, the needle is made to dip a little into the vitreous, and to cut its way through the capsule. In some eyes one or two dips of the needle will suffice to make a clear opening in the capsule, whilst in other cases they have to be repeated many times.

Occasionally it happens that after the needle has made an opening through the capsule, an adherent film remains stretching across the pupil, which a single needle fails to divide. A second needle should then be used, after the manner first recommended by Sir W. Bowman. It should be introduced by the other hand through the cornea at a point nearly opposite to the first; and passing its point *behind* the band, whilst that of the first needle remains *in front* of it, so that their points cross, the one needle is made to revolve a few turns over the other, until the band of capsule is torn; or if this does not readily follow, the two needles may be then slightly but slowly separated; a proceeding which will seldom fail in breaking it through.

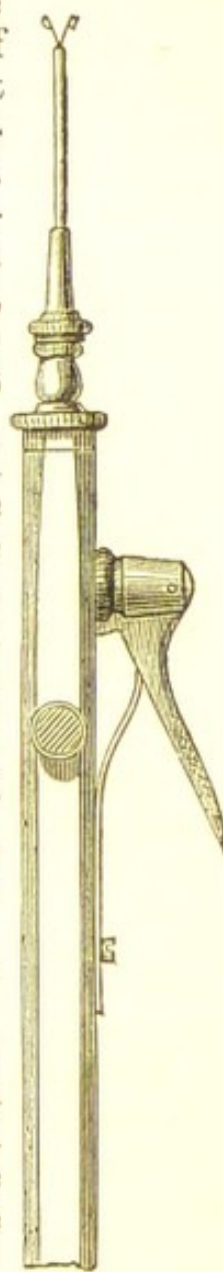
In cases where there is some lens matter enclosed between the anterior and posterior layers of the capsule, a needle operation such as has been already described will generally be sufficient. The breaking up of the capsule will expose the particles of lens matter to the action of the aqueous, and they will usually be quickly absorbed.

When there has been iritis, and the pupil is closed with a dense membrane, a new pupil may be formed and the capsule torn through with two needles; but this will not always suffice, as iritis will often follow the operation, and the pupil will again become closed. It is generally necessary, after the capsule has been torn through, to remove a portion of the iris and make a false pupil. Another very efficient way of dealing with such cases, is to divide the capsule and cut through the lower margin of the pupil with fine scissors, Fig. 21, page 103.

To use Two Needles to Tear through the Opaque Capsule and Open out the Closed Pupil.—One needle is to be introduced through one side of the cornea and be passed into the centre of the capsule upon which the pupil is contracted and adherent. The

second needle is to penetrate the opposite side of the cornea, and to be inserted also into the capsule close to the first. The points of the two needles are now to be dipped downwards a little into the vitreous, and to be drawn slowly in opposite directions, so as to tear through the capsule, and at the same time to pull open the pupil. Having done this, the needles are to be withdrawn, and according to the size of the pupil which has been formed must depend the necessity of making an artificial pupil by removing a piece of the iris. If the new pupil does not open out sufficiently, it will be well at once to make an opening in the cornea with a broad needle, and with a Tyrrell's hook (Fig. 20, p. 102) to draw out a piece of the iris and cut it off.

FIG. 43.



The most difficult cases, however, of all to treat are *those in which there is a piece of tough milky-white looking lens capsule occupying the pupillary area, and to which the iris is adherent at points*. The normal elasticity of such a portion of capsule has been lost, and oftentimes some of the earthy salts are found to be incorporated with it, or with the remains of the little lenticular matter which has been enclosed between its layers. A needle operation here would do no good.

There are two modes of dealing with such cases:—

1. The most safe, and at the same time a very efficient operation, is to cut through the opaque capsule and enlarge the old pupil by a pair of scissors (Fig. 21, page 103). An incision is to be made with the point of an iridectomy knife just within the upper margin of the cornea, sufficiently large to admit easily the closed blades of the scissors. The scissors are then to be introduced within the chamber, and the sharp-pointed blade made to perforate the opaque capsule, and passed downwards some distance behind the pupillary edge of the iris, when with one clip of the scissors the opaque capsule and sphincter

of the iris is divided. If the iris be sufficiently healthy for its cut edges to retract, a good pupil will be thus formed.

2. Having fully dilated the pupil with atropine, detach the opaque capsule from its adhesions to the iris by a fine needle introduced through the cornea. This being done, the fine needle is to be withdrawn and the opening it has made is to be enlarged with a broad needle to allow of the introduction within the anterior chamber of the canular forceps (Fig. 43), with which the piece of capsule is to be seized and drawn out of the eye. If, on drawing out the opaque capsule through the aperture in the cornea, a point of it is found still adherent to the iris, that which has been withdrawn should be snipped off with a pair of scissors, but no attempt should be made to detach it by force. This operation is a *very hazardous one*, though the result, when success follows, is very brilliant. The great danger consists in the dragging upon the iris and the ciliary processes. I have occasionally seen suppuration of the globe follow this operation.

After all operations for capsular opacities, the eye should be kept for at least three or four days with the pupil fully dilated with atropine.

DISLOCATIONS OF THE LENS.

DISLOCATION OF THE LENS INTO THE ANTERIOR CHAMBER may be either congenital, or the result of an injury such as a blow on the eye, or on the head in the vicinity of the eye. Occasionally it is caused by excessive retching or coughing, but in such cases it will generally be found on inquiry that the eyes were unsound, and predisposed to this accident.

Symptoms.—A transparent lens lying in its capsule in the anterior chamber presents a peculiar and characteristic appearance. It looks like a large drop of oil lying at the back of the cornea, the margin of the lens exhibiting a brilliant yellow reflex. The iris is pushed backwards, and the anterior chamber is thus greatly deepened. The pupil is always more or less dilated in proportion to the amount of pressure the lens exerts upon the iris. The lens in this abnormal position acts as a foreign body. It is productive of great irritation, and of severe pain. The inflammation which so frequently follows this accident may be partially due to other parts

of the eye having suffered from the primary injury; but much must also be attributed to the pressure of the lens on the iris.

The pain which accompanies this displacement of the lens is usually severe and neuralgic in character, oftentimes more intense than the state of the eye would lead us to anticipate; but the pressure on the iris, and consequently on the ciliary nerves, is sufficient to account for its severity.

Treatment of Dislocation of the Lens into the Anterior Chamber.—If the lens is giving rise to irritation, it should undoubtedly be removed, and as soon as possible: the irritation will probably continue and increase if it is allowed to remain in its abnormal position. But if the lens, although lying in the anterior chamber, is not acting as an irritant, and the eye, when seen by the surgeon, is perfectly quiet and free from undue vascularity, what course should be pursued? To answer this question, it is necessary first to consider what are the present, and what are likely to be the ultimate effects of such an accident. There are two results which generally follow the long-continued presence of the lens in the anterior chamber—viz., paralysis and atrophy of the iris; both of these are due to the one cause, pressure of the lens on the iris. They are not the immediate results of a dislocated lens, but they are the sequences of the prolonged pressure which is kept up by the lens against the iris, when it has been allowed to remain for many months or years in contact with it. Now, although the eye when first seen may be quiet and free from all vascular excitement, yet it is impossible to say how long this quiescent state may last. An outbreak of acute inflammation may occur at any time without any especial assignable cause beyond the abnormal pressure of the lens on the iris. Again, the presence of the lens in the anterior chamber is very apt to give rise to a glaucomatous state, under which the tension of the globe becomes suddenly increased, and the pain very severe. This condition is always one of peculiar danger to the eye, and calls at once for active treatment.

Considering, then, the many casualties which may happen to an eye with a dislocated lens lying in its anterior chamber, I believe it is advisable in all cases to remove it.

In children a suction operation or a linear extraction may be performed. It is generally judicious in such cases

to complete the extraction of the lens in one sitting, rather than to divide it into two stages, with an interval of some days between them, as in the ordinary mode of performing suction and linear extraction operations.

If the patient be an adult, or a person advanced in years, the dislocated lens should be removed through a section in the margin of the cornea, its exit being assisted with a cataract spoon. Having made the section in the corneo-sclerotic junction with a Graefe's cataract knife, and if possible excised a portion of the iris, the lens should be taken away *in* its capsule, with the aid of one of the traction instruments (Figs. 33, 34), or with the skeleton spoon (Fig. 36, page 150), or with a sharp hook which may be made to seize hold of it and draw it from the eye. During the operation an escape of vitreous will probably occur, as the suspensory ligament must have been torn to allow of the lens being dislocated, and this could hardly have been accomplished without at the same time some rupture of the hyaloid membrane.

DISLOCATION OF THE LENS INTO THE VITREOUS.—This accident may occur either with or without rupture of the external coats of the eye.

The lens is usually dislocated enclosed in its capsule, which may be either entire or partially lacerated. If the capsule has been torn, the lens will soon become cataractous; but even if it is entire, the lens generally after some months becomes opaque, on account of its due nutrition being interfered with.

If the dislocation has been *complete*, the iris, having lost the support of the lens, will fall slightly backwards towards the vitreous, and thus increase the depth of the anterior chamber. The iris will also generally be found tremulous, its whole surface vibrating with the movements of the eye.

If, however, the dislocation has *not been quite complete*, but, as is usually the case, some shreds of the suspensory ligament still connect the lens in its capsule with the upper region of the globe, then the lower surface of the iris against which the lens presses will be bulged towards the cornea, whilst the plane of the upper part will be unaltered. When the lens is thus suspended, it may be sometimes seen by the unaided eye, but always by focal illumination, hanging by filmy shreds from the upper

surface of the globe, and swaying to and fro with the motions of the eye.

State of the Pupil.—There is always more or less dilatation of the pupil. This is probably chiefly due in most cases to the injury which the ciliary nerves have sustained in the accident, although it may also be partly accounted for by the pressure which the displaced lens often exerts on the lower segment of the iris.

The general symptoms are those of great irritation. There is increased vascularity, with dread of light, lachrymation and pain. The eye, from the first effects of the injury, becomes actively inflamed, but this state under treatment may gradually subside. It is, however, generally succeeded by a low form of choroido-iritis or choroido-retinitis, which is kept up by the irritation caused by the abnormal position of the lens. In this stage a glaucomatous state frequently supervenes, and the tension of the eye becomes greatly increased. With the increase of tension all the symptoms become aggravated; and unless the lens, the source of the irritation, is removed, the loss of the eye is certain. This glaucomatous condition is liable to occur in all the dislocations of the lens *within* the eye, but it is more prone to follow those in which the lens is either partially or completely displaced behind the iris, than when it is thrown in front of that structure.

Treatment of Dislocation of the Lens into the Vitreous.—If the dislocation is complete, and the eye is free from irritation, it should be left alone, but the patient should be kept under careful supervision. If, however, the displaced lens is exciting inflammation, it should be removed. This is best done by a traction operation. No speculum should be used, as its pressure on the eye favours the escape of vitreous. The upper lid should be raised with a retractor, or by the index finger of the operator, whilst the section is made in the margin of the cornea with a Graefe's knife, as in the cataract extraction operation, page 152. It is often impossible to seize hold of the iris to draw it out of the wound preparatory to excising a portion of it; for having lost the support of the lens, it will sometimes fall backwards and get so behind the cut edge of the sclerotic that the forceps cannot be made to grasp it. This difficulty is increased by an escape of vitreous, which almost invariably takes place immediately on the withdrawal of

the knife from the eye, and is dependent on a rupture of the hyaloid at the time of the accident, which has allowed the vitreous to fall forwards. If, therefore, the attempt to seize and draw out a piece of iris is unsuccessful, it is better at once to pass the scoop through the pupil to the back of the lens, and to draw it out, if possible, in its capsule.

DISLOCATION OF THE LENS BENEATH THE CONJUNCTIVA can only occur in cases where the sclerotic has been ruptured, whilst the conjunctiva over the rent has remained entire. The lens, separated by the violence of the injury from its ciliary attachment, is forced out of the eye through the wound, and, as the conjunctiva has not been lacerated, it will be seen lying beneath it. The dislocation is almost invariably upwards, or upwards and inwards, as it is in the upper region of the eye, between the insertion of the recti muscles and the margin of the cornea, that the split of the sclerotic coat most frequently occurs.

Symptoms.—The lens will be seen lying beneath the conjunctiva, forming a small, roundish, semi-transparent swelling. If the anterior chamber is clear, the altered shape of the pupil, probably also the tremulous state of the iris, and the presence of a subconjunctival tumour, will be sufficient evidence of the nature of the accident. The lens is nearly always dislocated enclosed in its capsule; but owing to the rough manner in which it is squeezed through the aperture in the sclerotic, the capsule is often lacerated, and the lenticular matter frequently somewhat comminuted.

Treatment.—When the lens is seen lying beneath the conjunctiva, it should be removed; and this may be done by making a small incision through the conjunctiva either with a cataract knife, or with a pair of fine scissors, and then, if the lens is entire in its capsule, by at once lifting it out; or if its capsule has been broken and its substance comminuted, carefully taking it away piecemeal with a small scoop, paying special regard that fragments of it are not left between the lips of the wound in the sclerotic to interfere with its primary union. The lids should be then closed, and a cotton-wool compress with a light bandage be applied to the eye.

It will be well, as a precautionary measure, to apply two or three leeches to the temple, and for a few

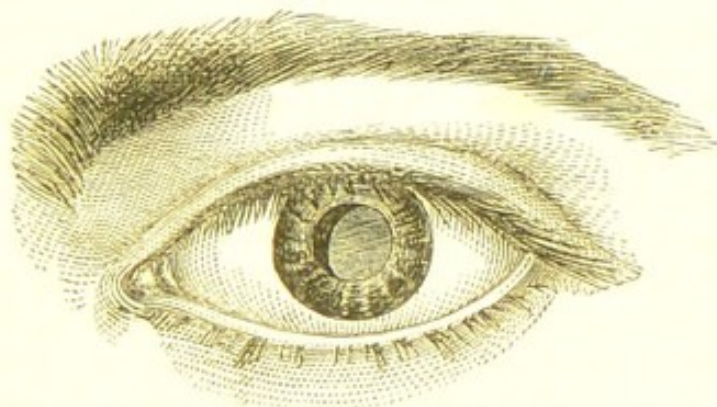
days to keep the patient on a slightly antiphlogistic regimen.

PARTIAL DISLOCATION OF THE LENS may occur from blows on the eye or the side of the head, when a portion only of the suspensory ligament is detached, and consequently a limited or only partial displacement of the lens ensues.

1. The lens may be dislocated either partially upwards or partially downwards, and in either position it may continue permanently fixed. Occasionally the lens is found to be slightly tilted without any absolute displacement; one margin is pressed forwards against the iris, whilst the other is forced back into the vitreous.

2. The suspensory ligament may have been torn or partially detached at one part of its circumference: and

FIG. 44.



The woodcut represents a partial dislocation of the lens. In the patient from whom this drawing was taken the lens was displaced outwards, and a little tilted, so as to present its inner edge slightly forwards. It was already very cloudy, and was rapidly becoming cataractous. With the movements of the head the lens was seen to vibrate.

although no immediate displacement of the lens may have followed, yet, owing to this loosening or partial detachment of its ligament, it may have become what is called a movable or swinging lens, swaying backwards and forwards with the movements of the head or the eye. In certain postures of the head, as in looking downwards or in stooping forwards, a partial dislocation of the lens through the pupil may take place; whilst with the head erect, as in looking directly forwards or upwards, the lens may sink back behind the pupil to apparently its normal position. Independently of the intra-ocular

symptoms which such a swinging lens is liable to excite, a serious defect in vision will be produced by the frequent changes in the position of the lens, such as to render the eye not only comparatively useless, but a source of very considerable annoyance and even danger to the patient, by causing him to misjudge and confuse objects with which he may come in contact in his daily work.

General Symptoms.—Partial displacements of the lens are generally accompanied by grave symptoms. The blow required to produce such an injury must be one of considerable force, and the mere laceration of the suspensory ligament, irrespective of the irritation to which the mal-position of the lens may give rise, is sufficient to place the eye for a time in some danger. But when all the first symptoms which may be attributed to the blow have passed away, there often remain severe neuralgic pains in the eye and around the orbit, which in some instances are persistent, though varying in intensity, whilst in other cases they are recurrent, with intervals of perfect ease. The sight is always materially affected, as in proportion to the tilting forwards of the lens the patient becomes myopic. The lens may continue transparent for a long time after the injury, but the general rule is for it sooner or later to become cataractous.

The most alarming condition which a partially displaced lens is likely to produce is a state of glaucoma, which may come on at any period after the accident. In such cases the glaucomatous symptoms are generally more or less recurrent; for the increased tension of the eye, being dependent on pressure on the back of the iris, is produced whenever the lens falls forward against that structure, and gradually subsides when this pressure is removed by a change of the position of the lens. A frequent repetition of this glaucomatous condition will, however, speedily induce such changes, that unless means are adopted to arrest it, total loss of sight must in the end be the result.

Treatment of Partial Displacements of the Lens.—If the lens from partial detachment of its suspensory ligament is a swinging or movable one, and is frequently dropping partially through the pupil, and thus producing a confusion of the patient's vision, even though there is no pain, its extraction should be advised.

If glaucomatous symptoms come on, the removal of the lens becomes an absolute necessity, and an operation for

its extraction should be performed with as little delay as possible.

The lens is best removed by making a section of the cornea with a Graefe's knife, either upwards or downwards, so as to make the cut correspond with the edge of the lens, which is tilted forwards. A cataract spoon (Figs. 33, 34), or a Taylor's scoop (Fig. 36), is then to be introduced through the wound, and with it the lens is to be drawn out. If the lens is very movable, it may be steadied by transfixing it with a needle passed through the cornea, prior to making the corneal section, and thus it may be held in position until the cataract scoop has been passed behind it. Some vitreous will probably be lost during the operation, owing to a rupture of the hyaloid when the lens was dislocated.

CHAPTER V.

DISEASES OF THE RETINA, CHOROID, AND OPTIC NERVE.

HYPERÆMIA OF THE RETINA.—In estimating the degree of vascularity of the retina, the fundus of the diseased eye should be compared with that of the sound one, as fulness of the vessels, if equally present in both eyes, would clearly not account for a special defect in one of them. Hyperæmia may be caused by overworking the eyes, and especially if they are hypermetropic, or myopic; or it may come on from repeated exposure to bright lights; or it may be associated with inflammation of any part of the eye. The fundus looks too red, and the optic nerve has a decidedly pinkish aspect. The patient complains of occasional flashes of light, and an inability to continue his accustomed work for any length of time, from a sense of fatigue and heat in the eyes. I have seen this condition of the eyes in seamstresses, bootbinders, engravers, and amongst the Spitalfields weavers, who are often engaged for many hours at close work with an insufficient light. It is occasionally associated with hyperæsthesia or undue sensibility of the retina. The eye is thus rendered intolerant of bright light, and frequently during the day the lids are spasmodically closed from

sudden gushes of hot tears accompanied with a sense of grittiness and increased photophobia. These paroxysms usually last only two or three minutes, when the eyes return to the condition they were in before.

A more serious form of hyperæmia is a passive venous congestion due to some impediment in the return flow of blood. It is seen in impairments of sight due to the presence of tumours within the orbit or the skull, or to some local congestion of the brain. It occurs in cases of acute amaurosis dependent on suppressed menstruation, and it will be also found in all glaucomatous affections.

Treatment.—For the first-mentioned form of hyperæmia of the retina, rest of the eyes is imperative. The patient should abstain from all work which requires close application of the eyes or a stooping position of the head, and he should wear blue glasses when exposed to any glare of artificial light. One or two leeches applied to the temple, and repeated at intervals of two or three days, are often of service; and mild counter-irritation behind the ears, or to the temple, by the repeated application of small blisters or a stimulating liniment, will occasionally do good. As the congestion is often due to some impairment of the sympathetic nerve, which from such cause fails to exert its proper influence in maintaining a due tonicity of the vessels, preparations of iron, the mineral acids and bark, are frequently of the greatest benefit. As a local application, the cold douche is the best. It should be applied to the eyes with the lids closed.

For the second form of hyperæmia, the treatment must necessarily be very unsatisfactory. When there is reasonable evidence to suppose that it is caused by a tumour within the skull, medicine can do little if any good. The iodide or bromide of potassium, singly or combined, may be tried; but my own experience is that they are seldom of any benefit.

RETINITIS, OR INFLAMMATION OF THE RETINA, generally arises from some constitutional cause, as syphilis, or disease of the kidneys; but it may also be produced by over-use of the eyes before strong lights. It may occur as a secondary affection from obstruction to the retinal circulation, from orbital tumours, or from embolism, or from an extension of an inflammation of the neighbouring structures. So intimately associated are the retina and choroid in health, that it is difficult

for one to be affected by disease without the other also participating. In speaking therefore of the diseases of the retina, it must not be inferred that the retina only is affected, but that it is the structure primarily involved, and the seat of the principal morbid changes. As in iritis, I will first describe the general symptoms of retinitis, and then briefly refer to the special peculiarities which mark the various forms of this disease.

General Symptoms.—The patient complains that he sees surrounding objects darkly, as though he were looking through a mist. He has to examine closely whatever he wishes to see correctly, and to use a strong light; in fact, from the dulled sensibility of the retina a deep impression is required. As the disease progresses, the field of vision becomes contracted, or portions of it are lost; and the darkness steadily increases until ultimately the eye is blind. The defect of sight is influenced by the part of the retina which is chiefly affected; when the peripheral portions are first attacked, the field of vision is contracted, but the impairment of sight is much less than when the region of the yellow spot is invaded by the disease. The external appearance of the eye is unchanged, there is nothing about it to strike the ordinary observer; it is only by the ophthalmoscope that the symptoms complained of by the patient can be explained.

Examined with the Ophthalmoscope, there is seen a change in the transparency of the retina, which is slightly turbid or milky, from a delicate film of exudation on its surface. There is usually some swelling of the optic disc, its outline is indistinct, and looks blended with the surrounding parts. The veins are generally more or less distended and sometimes tortuous, and parts of them are here and there rendered less distinct, on account of the film which covers them. There may be extravasations of blood, or inflammatory exudation into the retinal tissue, which will appear as greyish-white spots.

The prognosis of retinitis, except when it proceeds from syphilis, is generally unfavourable. The prospect of recovery is diminished in proportion to the extent of the hæmorrhages, and the amount of the inflammatory exudations. Nerve structure once destroyed is never replaced. It is only therefore when the exudations have been chiefly confined to the connective tissue of the retina that a favourable result will follow. When there has

been neither hæmorrhage nor isolated grey spots of exudation, the eye may recover with fair sight. Retinitis may terminate in blindness from atrophy of the retina, or by its detachment from the choroid.

Treatment.—For that form of retinitis which is apparently unconnected either with syphilis or disease of the kidney, small alterative doses of the hydrarg. perchlorid. (F. 101) may be given two or three times a day; or the iodide or bromide of potassium (F. 91, 99) may be prescribed, and at the same time slight counter-irritation may be kept up by rubbing into the temple every night a little of the unguent. hydrarg. iodidi rubri (F. 132). The eyes should be allowed absolute rest, and this can be obtained by the patient abstaining from all close work, and by wearing spectacles with glasses of a rather dark cobalt blue. If the retinitis can be traced to overwork, or has come on after fever or any severe illness, tonics of quinine, iron, or cinchona with the mineral acids should be ordered, with rest to the eyes, and, if possible, change of air.

RETINITIS ALBUMINURICA — *Nephritic Neuro-Retinitis.*—This form of retinitis has received the name of "albuminurica," from being frequently associated with renal disease, when the urine is charged with albumen. It usually occurs in patients who have Bright's disease of the kidney, and, consequent on it, an hypertrophy of the left ventricle of the heart.

Symptoms.—There are three forms in which this nephritic retinitis may occur. 1. It may gradually develop itself with the advance of the kidney disease. For a long time the patient may have complained of a general mistiness, everything appearing as if through a veil; or the impairment of vision may have been confined to one portion of the field, when suddenly the sight is discovered to be markedly worse. The whole field may be thus affected, so that the eye is almost dark; or the blindness may be partial. This sudden loss of sight is probably due to retinal hæmorrhage, and is in proportion to the number, size, and locality of the blood-clots.

2. The second form of nephritic retinitis is dependent on uræmia, and occurs in the later stages of kidney disease, associated with suppression of urine, delirium, and convulsions. The loss of sight is very rapid, and sometimes permanent. If no organic changes have taken

place in the retina from hæmorrhage during the attack of uræmic poisoning, the patient may gradually regain much of his sight after the kidneys have resumed their functions; but the prognosis is always unfavourable.

3. Nephritic retinitis occasionally occurs in women during pregnancy, who are suffering from albuminuria induced by the pregnant state. This form of the disease is frequently accompanied by retinal hæmorrhage, and both eyes may be affected by it. In one case under my care the sight of both eyes was so far destroyed by retinal hæmorrhages that only the perception of large objects remained. The prognosis is very unfavourable. When there is nephritic retinitis in pregnancy, my own feeling is that premature labour should be brought on, with the hope that, in sacrificing the life of an unborn child, we may save the more valuable life of the mother.

Ophthalmoscopic Appearances.—The optic nerve is slightly swollen and œdematous, with its margin indistinct and blurred into the surrounding cloudy retina. Around the disc the retina looks of a greyish-white, and the vessels as they pass to and from the optic nerve are in parts obscured by the exudation. At various points of the retina buff-coloured patches are seen, and in the neighbourhood of the yellow spot, small whitish glistening bodies appear sprinkled. The retinal veins are distended and tortuous, and there are frequently numerous small effusions of blood scattered over the retina. The hæmorrhage is always from the capillaries, and this no doubt is due to the morbid state of the coats of the vessels in advanced Bright's disease, and to the increased force by which an hypertrophied heart sends the blood through them.

In a well-marked case of nephritic retinitis the disease of the kidneys may be diagnosed by the ophthalmoscopic appearance of the eye, but in the early stage of albuminuric retinitis it is impossible to distinguish it from neuritis induced by other causes. In all cases of neuritis the urine should be examined.

Mr. Hulke has had two opportunities of dissecting eyes affected with chronic renal retinitis, an account of which he published in the "Ophthalmic Hospital Reports."* He found there was:—

"1. Œdematous swelling of the optic nerve and retina.

* Royal London Ophthalmic Hospital Reports, vol. v. p. 16.

"2. Large granular corpuscles, more or less abundant, mostly in the intergranule layer.

"3. Botryoidal masses of colloid, also in this layer.

"4. Nests of sclerosed and enlarged ganglionic cells, or moniliformly swollen and sclerosed nerve-fibres in the ganglionic and optic layers.

"5. Hæmorrhages: The shape of the patches of the extravasated blood being determined by the arrangement of the tissues into which the blood escapes."

It has been said that by the presence of retinitis albuminurica, the surgeon may at once diagnose with the ophthalmoscope Bright's disease; but it should be remembered that the affection of the eyes is usually secondary to that of the kidneys; and that it is only in advanced cases of the disease that the symptoms are sufficiently marked to do more than point to the kidneys as the probable source of the mischief.

Treatment.—As the state of the eyes is secondary to and dependent on the disease of the kidneys, the treatment must be constitutional, and those remedies should be selected which are suitable for the renal affection from which the patient is suffering. The bowels should be made to act once daily, the pulv. jalapæ comp., or some hydragogue cathartic being given early in the morning when necessary. The preparations of iron usually do good, and of these the tinct. ferri perchlorid. is perhaps the most useful. The object to be obtained is to relieve the kidneys by promoting the action of the skin and the bowels. Mercury in any form in nephritic retinitis should be strictly avoided. If the eye is painful, a leech applied to the temple will often give ease, and it may be repeated from time to time. The patient should strictly rest the eyes, and protect them from all exposure to glare or artificial light, and for this purpose he should wear spectacles with curved cobalt-blue glasses. He should also avoid stooping, as it favours the flow of blood to the eyes, and thus renders them more liable to retinal hæmorrhages.

RETINITIS SYPHILITICA.—There is one form of retinitis which is undoubtedly due to syphilis. The history of the case and certain ophthalmoscopic appearances mark its specific origin. It usually occurs during the tertiary period of syphilis, when nodes form on the bones, and the patient has pains in his limbs and joints; when, in fact, the constitution has been thoroughly

imbued with the poison. Mr. Hutchinson* has shown that choroido-retinitis may arise also from inherited syphilis.

Symptoms.—A gradual fading of the sight extending over the whole field of vision. The pupil is sluggish and inclined to be dilated. There are no external manifestations to account for the great loss of sight. A past history may reveal syphilis, or there may be local evidences of the disease which will render a searching interrogation unnecessary.

Examined with the Ophthalmoscope.—There is usually turbidity of the vitreous, and a diffused greyish haze of the retina extending from around the optic disc; whilst here and there are seen buff-coloured patches of exudation. The absence of any hæmorrhagic spots are also to some extent characteristic of syphilitic retinitis.

Pure and uncomplicated syphilitic retinitis is a rare disease; it is usually combined with exudative choroiditis, and to the joint affection of the retina and choroid the term "syphilitic choroido-retinitis" has been well applied. ((See EXUDATIVE CHOROIDITIS, page 194.)

The **prognosis** of retinitis syphilitica is more favourable than that of any of the other forms of retinitis. When seen sufficiently early, the disease will generally yield to appropriate treatment, and a great amelioration of the symptoms will usually follow, and in some cases a complete restoration of sight.

Treatment.—The iodide of potassium and the preparations of mercury are the drugs to be relied on for the relief of this disease. I have found the mist. potassii iodidi cum hydrarg. perchlorid. (F. 98) extremely beneficial, and have had patients recover under its influence in a most marked way. This mixture, however, is very apt to disagree with the stomach, and to produce a feeling of discomfort, and, in many instances, to bring out an attack of mercurial erythema, which induces the most intolerable irritation when the patient is warm in bed, and obliges him to desist from the medicine. It is most easily tolerated if it is taken about one or two hours after a meal. When the progress of syphilitic retinitis is very rapid, it is desirable to get the patient quickly under the influence of mercury, and this may be readily accomplished by rubbing half a drachm of the unguent. hydrarg. into the axilla or inner side of the thighs night and morning

* Syphilitic Diseases of the Eye and Ear, p. 130.

until the gums are slightly affected, when its effects may be continued, without being increased, by diminishing the frequency of the inunction. If the patient is feeble, quinine may be given during the exhibition of the mercury; but if not, small doses of the iodide of potassium two or three times a day will be more useful. In some cases I have seen very good results follow the use of Mr. Henry Lee's mercurial vapour bath (F. 4). The patient should commence his fumigations with gr. 10 of calomel and continue them every night, the surgeon keeping a careful watch that he does not become too much affected by them. The baths should be discontinued, or intermitted if the gums become spongy. During the day the patient may take the iodide of potassium (F. 91); or if his strength is failing him, he may be prescribed quinine or cinchona with nitric acid. The mercurial baths are most efficient during the summer months, when the skin acts freely, and when there is the least liability of the patient getting chilled after taking them. I should not order the baths during the cold months unless the patient was able to have them in his own bedroom, and provide himself against all risks of exposure either during or after their administration.

RETINAL APOPLEXY — *Retinitis Apoplectica*.— Retinal hæmorrhage may occur from disease within the eye, as in retinitis or glaucoma; but it may also come on from some extrinsic cause, and it is this form of intraocular hæmorrhage we have now to consider.

Sudden hæmorrhage from the rupture of a retinal or choroidal vessel may arise from a diseased state of the heart, or an atheromatous condition of the coats of the vessels; or from embolism, or from suppressed menstruation. It may happen also in young patients, who without any evidence of disease have a morbid tendency to bleed, and exhibit this predisposition by frequent attacks of epistaxis. In such cases the liability to retinal hæmorrhage is favoured if the daily employment necessitates a stooping position of the head. A well-marked example of this form of retinal hæmorrhage, apparently due only to a peculiar hæmorrhagic tendency, came under my care at the hospital in a young fellow, æt. nineteen, who was by occupation a currier. He was accustomed to work for many hours with his body bent, and his head stooping forwards. About eight weeks previous to my seeing

him he was at his usual employment, and after his day's work went to bed, feeling quite well; but on getting up in the morning he was so blind that he could scarcely find his way to the work yard; and in about two hours he was obliged to return home, as he had only sufficient sight to guide himself about. The boy had suffered from repeated attacks of epistaxis, and only a week before he had lost a large quantity of blood from the nose. Examined with the ophthalmoscope, extensive retinal hæmorrhage was seen in each eye. There were blood clots in the vitreous of both eyes, and in the left a ruptured retinal vessel could be distinctly made out.

Symptoms.—Occasionally there are the premonitory warnings of a disturbed circulation; the patient has attacks of giddiness and dimness of vision which may last from a few seconds to a few minutes; he complains of pain in the head, or has bleeding from the nose; but in many cases the retinal hæmorrhage occurs suddenly, without any previous indication of existing disease. The suddenness of the loss of sight is one of the most characteristic symptoms. The patient may awake in the morning and find himself nearly blind with one or both eyes; or whilst engaged at his usual occupation a dark cloud, or, as some have described it, a red ball may seem to appear before the affected eye, and to gradually increase in size until the vision is either partially or completely lost. The impairment of sight produced by the hæmorrhage depends on the extent of the effusion and the locality in which it has taken place. One large retinal vessel may have given way, and a single clot have formed on the surface of the retina; or there may be several small ecchymoses from ruptured retinal or choroidal capillaries. When it is from a large retinal vessel, the bleeding is often extensive, and the blood breaking through the hyaloid membrane will be extravasated into the vitreous, or it may force its way backwards through the layers of the retina, and form a clot between that structure and the choroid. The blindness may be complete; or it may be central, so that the patient can only see on either side of the object he looks at; or it may be confined to a portion of his field of vision, according to the part of the retina pressed on by the clot.

Ophthalmoscopic Appearances.—If there has been much hæmorrhage, and the blood has been extravasated into the vitreous, the fundus may be so masked that it

will be impossible to make out any details. The history of the case, combined with the detection of blood in the vitreous, will, however, at once explain the cause of the loss of sight. When the hæmorrhage has been of less extent, a retinal vessel may be often seen terminating in a large clot. If there have been many small capillary ecchymoses, these will be clearly made out with the ophthalmoscope. Frequently the remains of old blood-clots may be also seen, there having been previous hæmorrhage; or markings on the retina may indicate the site which some former clots occupied.

The prognosis is always unfavourable, for although some improvement may be gained by the absorption of the clots, yet as the exciting cause remains, the hæmorrhage is very likely to recur. When the blood has been extravasated either into the vitreous, or formed a clot between the retina and the choroid, the prospect of regaining any sight is very slight. In such cases, as the blood is slowly absorbed, the vitreous becomes fluid, the retina detached, and the globe soft. The prognosis is most favourable when there is only one clot, even though it be a large one, providing the surrounding retina be healthy, and there has been no extravasation into the vitreous.

Treatment.—Inquiry must first be made as to the cause of the retinal hæmorrhage, and when this can be ascertained, the endeavour should be to remove it. If the hæmorrhage is due to suppressed menstruation, means should be taken to restore the uterine function. The *mist. potassii iodidi* (F. 91), or the *mist. boracis* (F. 71) is often of service; or, if there is much anæmia, the *mist. ferri comp.*, or some other preparation of iron, should be prescribed. The regular action of the bowels should be maintained by the *pil. aloes et myrrhæ*, or the *pil. aloes Barbadosis*.

When the hæmorrhage apparently arises from heart disease, or a morbid condition of the coats of the vessels, the medical man in attendance must be guided by the symptoms which are present, and prescribe accordingly. In all cases of retinal apoplexy it is well to keep up a slightly increased action of the bowels, and for this purpose the bitter waters of Friedrichshall, Pullna, or Hunyadi Janos are very useful. No local application will benefit the eye; if it is hot or painful, a fold of lint wet with cold water may be laid over it, or one or two leeches may be applied to the temple, and repeated if they afford relief.

RETINITIS PIGMENTOSA has derived its name from the peculiar deposit of the pigment in the retina which characterises this disease. It may occur in persons of all ages. Generally the commencement of this affection may be traced back to early childhood, but, occasionally, "the first symptoms have appeared as late as the age of fifty."* I believe that in most cases it is congenital, and in some hereditary. Both eyes are usually affected, and to a similar extent, although to this there are exceptions. Wells mentions a case in which only one eye suffered. Liebreich has shown that retinitis pigmentosa is frequent amongst deaf-mutes, and also amongst the offspring of marriages between blood relatives. These observations have been confirmed by Mooren in an excellent paper on this subject.†

Symptoms.—The characteristic signs of this disease are, torpidity or diminished sensibility of the retina; a gradually increasing contraction of the field of vision, and a peculiar deposit of pigment in the retina. The first symptom which generally attracts attention is the inability to walk about in a dim light. The patient suffers more or less from nyctalopia or night-blindness; by day his *direct* vision is good, but after dusk it is considerably impaired. The contraction of the field of vision increases almost imperceptibly year by year, but the direct central sight may remain for a long period unchanged. The diminution of the field is from the periphery towards the centre. If, however, the disease continues to progress, the acuteness of the central vision becomes first dimmed, and then gradually darker, until ultimately the patient is blind. In many of the cases recorded by Mooren, commencing cataract in the posterior pole of the lens was observed in the later stages of the disease.

Examined with the Ophthalmoscope, the retina presents a very striking appearance. Sprinkled in an apparently irregular manner, are large deposits of pigment; some of the spots are stellated, or of a spider shape with many small offshoots; others look like mere granules, either congregated together in groups, or scattered about

* Bader, On the Natural and Morbid Conditions of the Human Eye, p. 470.

† Ophthalmic Review, No. 1, p. 4. Translated from Zehender's Klinische Monatsblätter für Augenheilkunde, i. p. 93, by Zacchariah Laurence.

indifferently. This deposit usually commences at the periphery and gradually extends towards the centre.

When more carefully examined, the deposits of pigment seem in places to follow the course of the retinal vessels, parts of which they will overlay. In many cases the choroid is also affected, when, from the wasting of its epithelium and atrophy of its stroma, patches of it are rendered so transparent as to allow the white sclerotic to shine through and render more conspicuous the black patches in the retina. The retinal vessels appear small, but this diminution is said by Schweigger to be due to a thickening of their coats and a consequent lessening of the calibre, which restricts the flow of blood through them, and to this state of anæmia he attributes the defective sensibility of the retina. The optic nerve has a pale anæmic appearance, and when the disease has advanced it exhibits the peculiar dull white of confirmed atrophy.

Treatment.—Little if any benefit is to be derived from medicine. The aim must be to retain the sight the patient has, rather than to endeavour to recover that which has been lost. The use of the eyes must be restricted; he should avoid reading, writing, and all work which requires an effort of the accommodation. Small doses of the iodide or bromide of potassium, or of the perchloride of mercury have been recommended, and may be tried, but they should be given up if they interfere with the general health. Spectacles with curved cobalt-blue glasses should be worn when in the open air or bright sunlight, as they afford rest to the eyes, and protection from the irritating effects of wind.

DETACHMENT OF THE RETINA may be caused—

1. By the extreme elongation of the coats of the eye which occurs in severe cases of myopia, when the retina, being less extensile than the choroid, is in parts separated from it, and the intervening space is occupied by a serous fluid.

2. By a diminution of the bulk of the vitreous, so that the retina, losing its due amount of anterior support, gradually becomes loosened from the choroid, and falling forward is at first partially and ultimately completely detached. This change may be induced by disease, but most frequently it is the result of a penetrating wound of the eye, which has been either accom-

panied with a loss of vitreous, or with hæmorrhage into its substance.

3. **By hæmorrhage between the choroid and retina.**—This may occur in retinitis or glaucoma; or it may be caused by blows on the eye. In most cases the blood-clot is ultimately absorbed, but the retina remains detached.

4. **By serous effusion between the choroid and retina.**—This may occur in a normally-shaped eye without any stretching of the posterior coats as in myopia, or without any previous separation having been effected by hæmorrhage. In some instances it may possibly be due to disease of the vitreous resulting in a change of its structure and a lessening of its bulk; but in many cases no satisfactory cause for the detachment can be detected, and it is therefore ascribed by some to inflammatory action, of which there is little or no evidence.

5. **By the presence of tumours of the choroid.**—As the growth advances the retina is carried in front of it, and the detachment increases with the progress of the disease.

Detachment of the retina may be partial or complete. It generally commences in the lower region of the fundus, and gradually mounts up towards the optic nerve. It usually occurs in one eye only, but both may suffer if the separation has been produced by causes which equally affect the two eyes, as in cases of extreme myopia. The tension of the globe is as a rule slightly diminished when there is a simple detachment with subretinal effusion; but if the displacement is due to a choroidal tumour, the tension is usually increased.

Symptoms.—It is often very difficult to ascertain from a patient the early symptoms of a displaced retina; they have either passed unnoticed, or in the lapse of time have been forgotten. Some indications of retinal irritation are, however, the general precursors of the detachment; the patient is frequently troubled for some weeks previously with the occasional and sudden appearance of bright flashes or scintillations, or of circles of fire, &c.; or with floating muscæ and dimness of vision. The symptoms which may be said to characterize a detachment of the retina are: Loss of vision in one direction, so that a portion of the field may be completely wanting; the patient with the affected eye may be only able to see a portion of the object he looks at, a half or a quarter of

it being quite dark ; or if the loss is central, the point on which he directs his eye is blank, whilst he can see on each side of it. He complains also of a waving up and down with the movements of the head. This is caused by the floating to and fro of the detached portion, and is recognised by the part of the retina still in situ. Another symptom often mentioned is that objects appear bent, twisted, or in some other way distorted, and is no doubt due to some disarrangement of the layers of a portion of the retina which is loosened, though not yet separated from the choroid.

Occasionally an eye with detached retina becomes glaucomatous and very painful. The presence of an intraocular tumour may be then strongly suspected.

Examined with the Ophthalmoscope.—The detachment is best seen by *direct* examination, when if the case is one of partial separation of the retina from the choroid, the detached portion will appear as a bluish-grey film, bounded by a sharp line, on one side of which is the bright expanse of the choroid, shining through the transparent retina, in situ ; and on the other this semi-opaque grey web, which is bulged slightly forwards towards the vitreous. Tracing the course of the retinal vessels from the optic nerve, they seem to be suddenly bent when they arrive at the line of the detachment. A partial, or an entire displacement of the retina, if the separation from the choroid is complete, is easily recognised ; it is when a portion of the retina is rather loosened or wrinkled than absolutely detached that the diagnosis becomes exceedingly difficult. This condition is recognised by a slight opacity of the retina at one spot, and by noting the appearance of the vessels, which seem to stand out at one point and to be lost in the shade at another, as they rise or fall in their passage over the foldings of the loosened retina.

When the lens is cataractous, the detachment of the retina cannot, of course, be seen by the ophthalmoscope, but its presence may be inferred from the following test :—The sound eye being excluded by the patient placing his hand over it, with the mirror of the ophthalmoscope throw a column of light upon the affected eye, moving it in different directions across the eye, transversely and obliquely upwards, downwards, outwards, and inwards, and at the same time question the patient as to whether he can see the light, and can state in what direction the

light comes. In this manner a good estimate may be formed of the perfection of his field of vision; whether portions of it are defective or wanting. If a large portion of the field be wanting, a detachment of the retina may be reasonably suspected.

The prognosis of detached retina is very unfavourable. The tendency is for the disease to extend, and more retina to become detached until at last the eye is blind. The most favourable cases are those in which there is a limited detachment, the result of an injury, probably a small effusion of blood between the choroid and retina. A blind spot in the field of vision will always remain, but the rest of the retina may retain its functions unimpaired. Cases have been recorded where the subretinal fluid has disappeared, and the retina having again fallen back to its place has still retained some power of sight, but they are exceptional.

Treatment.—Detachment of the retina is very intractable, and generally uninfluenced by medicines given for the purpose of procuring absorption of the subretinal fluid. A spontaneous cure or arrest of the disease has occasionally occurred from the accidental laceration of the retina, and the escape of the fluid into the vitreous. The knowledge of this fact induced Graefe and Bowman to endeavour to establish artificially a permanent rent in the detached portion of the retina, through which the fluid could extravasate into the vitreous. This they did by tearing through the displaced retina with either one or two needles introduced through the sclerotic. Von Graefe employed a long cutting needle, "furnished with two very sharp edges, and the neck of which fills the wound, so as to leave no space for the escape externally of the fluid."* Sir W. Bowman uses two rather long needles, which he introduces through the sclerotic, at from a quarter to half an inch from the cornea, and in the space between the recti tendons. The eye should be first examined with the ophthalmoscope, to determine the exact position of the detachment. The operation may be thus performed:—

The patient should be on a couch, and the lids being parted with a spring speculum, one needle should be introduced through the sclerotic at a point where it will

* Graefe, On Perforation of Detached Retina. Translated by George Henry Rogers, R. L. O. H. Reports, vol. iv. p. 222.

perforate the detached portion of the retina at a prominent part. The second needle is then to be inserted at a short distance from the first, and so directed that its point shall penetrate the retina at or close to the same spot. To avoid the risk of wounding the lens in the passage of the needles, they should be thrust through the sclerotic nearly vertically. A rent is now to be torn in the retina by separating the points of the two needles. There is generally an escape of the subretinal fluid by the side of the needles during the operation, and frequently in a sufficient quantity to infiltrate a considerable extent of the subconjunctival tissue. The fluid is generally of a yellowish colour, and when tested yields a large quantity of albumen.

When an eye with detached retina becomes glaucomatous and painful, the only treatment is to excise the globe.

EMBOLISM OF THE CENTRAL ARTERY OF THE RETINA is a cause of blindness, and subsequent atrophy of the optic nerve. The loss of sight is usually sudden and unaccompanied by pain. With the ophthalmoscope the optic disc appears blanched, the arteries reduced to the size of threads, and the veins also much diminished. In some of the cases which have been recorded, there was a loss of transparency of the retina around the optic nerve and in the region of the yellow spot, probably due to a slight serous effusion.

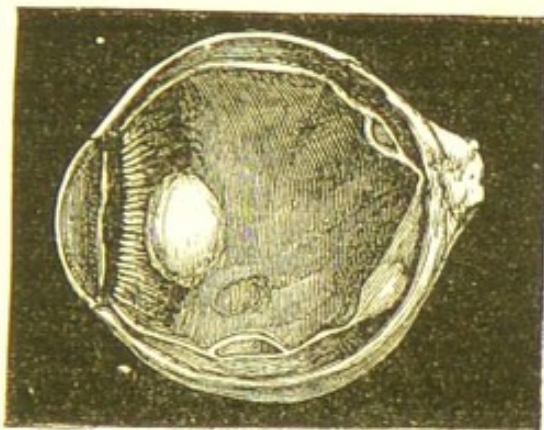
In the case of a young woman under my care, the sight was lost suddenly and without any premonitory symptoms a fortnight after her confinement. She had no pain, but she experienced a sudden sense of darkness over her left eye, which caused her to cover the right with her hand, when she immediately discovered her blindness. When I first saw her, about six weeks afterwards, the optic nerve was of a milky whiteness, and the retinal arteries were dwindled to mere lines, two or three of which were evidently only empty tubes.

The prognosis is unfavourable. No treatment is of any avail. The only consolation to be offered the patient is, that there is no reason to suspect that the other eye will suffer.

GLIOMA OF THE RETINA.—See Intraocular Tumours, page 206.

CYSTS OF THE RETINA are occasionally found in eyes which have been long lost, and appear to be due to degenerative changes. In a paper by M. Iwanoff, on "The different Forms of Inflammation of the Retina,"

FIG. 45.



One half of the eye, showing the chalky lens with the cysts and the retina in situ.

read before the Ophthalmological Congress at Heidelberg, in September, 1864, he alludes to three specimens, containing respectively one, five, and seven cysts. The first example of this disease noticed in this country was in an

FIG. 46.



The other half of the same eye, with the posterior half of the retina turned forwards, to show the position of the cysts on its choroidal surface.

eye which I removed from a patient at the Ophthalmic Hospital. The man had received a penetrating wound of the eye fifteen years previously; after the accident he

only retained perception of light, and in the next eighteen months the eye became totally blind. He came under my care in November, 1867. The lost eye was very painful, its tension was increased, and it was affecting prejudicially the sound one. Under these circumstances I removed the eye. On making a section of it the retina was found slightly detached from the choroid, and its outer aspect was studded with cysts of various sizes, the largest about that of a small pea. They were eleven in number, and each appeared to bulge out from the choroidal aspect of the retina, and to be formed by the separated layers of that structure. The specimen was exhibited at the Pathological Society, and in the "Transactions," vol. xix. p. 362, will be found a full account of the case, with the following report of the examination of the cysts, made by Mr. Vernon, who was then the curator of the museum at the Ophthalmic Hospital:—"The cysts appear to have been formed at the expense of the outer layers of the retina. Their walls consisted of a very fine tissue of delicate fibres, which contained many nuclei of their own, and which were closely interlaced with small nucleated cells, intermingled with round highly refracting bodies, the remnants of the granular layers of the retina. To the outer walls of the cysts which were examined, some of the choroidal epithelium was adherent, while their inner surfaces were lined with squamous epithelium. Many of the cells in the cyst-walls contained fatty granules. With acetic acid the fibres forming the cyst-walls appeared to consist of connective tissue without any elastic element.

DISEASES OF THE CHOROID.

DISSEMINATED OR EXUDATIVE CHOROIDITIS is most frequently the result of syphilis, but it may also occur in patients who are free from all specific taint, and from causes too indefinite or remote to be accurately traced. It is characterized by disseminated buff-coloured exudations on the surface and into the tissue of the choroid. These effusions are generally circumscribed, and between them portions of unclouded choroid are seen through the retina. As the disease progresses, the diffused lymph is absorbed, but a portion of the choroid corresponding to many of the patches becomes atrophied, and frequently to such an extent as to allow the white sclerotic to shine

through its attenuated remains. Around these white patches the choroidal epithelium filled with pigment collects and encircles them with a black rim. Frequently the retina becomes secondarily affected, and choroidoretinitis is established. Without, however, being involved in the inflammatory action, portions of the retina may be so pressed on by the exuded lymph as to cause a temporary suspension of its functions, and, if long continued, atrophy of its structure. A general turbidity of the vitreous with filmy opacities are frequently associated with this form of choroiditis, and especially if it has a syphilitic origin.

General Symptoms.—A gradual failure of sight; surrounding objects appear dark and confused; occasionally the field of vision is contracted, or parts of it are destroyed, so that in certain directions the patient sees only a portion of the object he looks at. The pupil is slightly dilated and sluggish. These symptoms, however, are common to other deep-seated affections of the eye, and it is only by the aid of the ophthalmoscope that the exact locality of the disease can be determined. When thus examined, the patches of exudation will be seen scattered over the fundus of the eye; those that are recent will be recognised as opaque yellowish spots, whilst the site of old effusions will be here and there indicated by the glistening white of the sclerotic shining through the atrophied portions of choroid, which are mapped out by an aggregation of pigment cells. When the inflammatory action is confined to the choroid, the retinal vessels may be clearly traced throughout their course, and in places mounting over the effusion which is beneath them; the retina itself is transparent, and allows the portions of bright choroid unobscured by lymph to shine through the spaces between the exudations; and there are none of the hæmorrhages which are so characteristic of most of the forms of retinitis. If the retina is affected, as very frequently happens when this disease is due to syphilis, a diffused haziness of a part or whole of the fundus, with interruptions in the course of the retinal vessels from inflammatory effusion, will mask many of the ophthalmoscopic signs already mentioned. When in addition to the retinitis there is also a turbidity of the vitreous, it is often impossible to make out the details of the changes which may have taken place, but sufficient information will probably be gained to form a diagnosis of the case.

There are two forms of disseminated choroiditis, the *syphilitic* and the *simple*.

In the **syphilitic** the exudation is very circumscribed, and often in nodules closely resembling those which are so frequently seen in the specific iritis, and there is no tendency for the effusions to run together. This exudative choroiditis sometimes occurs as an extension of the iritis, and it is then associated with, or follows closely upon, the secondary eruption of the skin. It is also met with during the tertiary symptoms of syphilis, but it is then usually complicated with retinitis.

In the **simple** form of disseminated choroiditis there is no history of syphilis, the disease rather resembles the simple iritis in which the effusion of lymph is small in quantity and evenly diffused. The patches on the choroid are less circumscribed, and they have a tendency to coalesce. The disease is more chronic and less amenable to active treatment.

Treatment.—If the disease is due to *syphilis*, the treatment which was recommended for retinitis syphilitica, page 183, should be adopted, but with certain restrictions. When the disseminated choroiditis follows or is associated with the secondary skin eruption, the iodide of potassium (F. 91), with the mercurial bath (F. 4) every night, or with pil. Plummer. gr. 5 every other night, may be ordered; or if the patient has not yet been under the influence of mercury, the unguent. hydrarg. may be rubbed into the axilla or inner side of the thigh every night until the gums are slightly affected. If, however, the disease does not occur until the tertiary period of syphilis, the preparations of the hydrarg. perchlorid. with bark (F. 101); or the mist. potassii iodidi cum hydrarg. perchlorid. (F. 98) will be the most useful.

In the simple disseminated choroiditis, small doses of iodide and bromide of potassium (F. 97) or of the liq. hydrarg. perchlorid. should be prescribed and continued for some weeks, and at the same time a slight mercurial counter-irritation may be kept up by rubbing a little of the unguent. hydrarg. iodidi rubri (F. 132) into the temple every night. If, however, the patient is very feeble and anæmic, the mercurial medicines should not be given internally, but full doses of quinine, or quinine and iron, should be ordered, and the unguent. hydrarg. c. belladonnâ (F. 126) rubbed into the brow and temple every night.

SCLEROTICO-CHOROIDITIS POSTERIOR. — *Posterior Staphyloma*—is a prolongation of the posterior half of the eye, accompanied with atrophy of the choroid, caused by the stretching to which it is subjected by the staphyloma. It is usually found in all cases of severe myopia. When the disease is *stationary*, the myopia remains unchanged, and the patient suffers no inconvenience. If, however, it is *progressive*, the myopia increases, and the acuteness of vision frequently diminishes. The patient also often complains of black muscæ, sometimes like falling soot, and of occasional flashes of light, with other symptoms of retinal irritation. If the eye be now examined with the ophthalmoscope, there will probably be found changes in the choroid, indicative of progressive atrophy: the white crescent on the apparent inner side of the optic nerve will have grown larger, and its outline irregular; and scattered here and there will be white atrophic patches. Occasionally one or more of these spots will coalesce with the myopic arc so as to greatly enlarge its area. Such eyes are liable to become glaucomatous; they are also occasionally subject to detachments of the retina, and to small hæmorrhages from the choroidal capillaries. A further account of sclerotico-choroiditis posterior will be found in the Article MYOPIA, page 249.

Treatment.—Absolute rest to the eyes, and the directions for myopic patients given in the Article MYOPIA should be strictly carried out. If there are rapidly progressing changes in the choroid, small doses of the liq. hydrarg. perchlorid. (F. 101) may be prescribed.

SUPPURATIVE CHOROIDITIS—*Ophthalmitis*—*Panophthalmitis*—is an acute suppurative inflammation involving all the tissues of the eye. It is most frequently induced by an injury such as a penetrating wound, or the lodgment within the globe of a foreign body, or an abrasion or burn of the cornea. It may also follow cataract or other severe operations on the eye, and occasionally it will come on in patients suffering from pyæmia, or exhausted by fever, or by long-continued bad living.

Symptoms.—Great vascularity of the eye, with chemosis of the conjunctiva, and œdematous swelling and redness of the lids.

The aqueous first becomes serous, then turbid from corpuscular lymph and pus; and these sinking to the

bottom of the anterior chamber constitute the state known as hypopion.

The iris loses its striation and brilliancy from inflammatory exudations on its surface and into its substance, and the pupil becomes blocked up with the like materials.

The cornea becomes dull and steamy, and pus may be infiltrated between its laminae, a condition recognised as onyx or corneal abscess, or an irregular sloughing ulcer may appear on its surface.

Such are the visible changes which are rapidly induced by an attack of ophthalmitis; but similar mischief is also going on in the deeper parts of the eye.

The ciliary processes become infiltrated with lymph and pus, and matted to each other.

The vitreous humour grows turbid, and lymph and pus are effused within it. The same exudations also take place on the surface of the retina, and in some cases between the retina and choroid, and between the choroid and sclerotic, all of which tissues may be covered with morbid deposits, and even separated the one from another by them.

The pain of ophthalmitis is always very severe. It is supra-orbital, extending up the side of the head; it is around the orbit and down the side of the nose, and in the eye itself. At first neuralgic in character, sometimes acute, at others dull and aching, but, as the disease advances, hot and throbbing; the pain is usually sufficient to destroy sleep and to produce severe constitutional symptoms.

The prognosis of ophthalmitis is very unfavourable. Occasionally, under judicious treatment, combined with other favourable circumstances, the inflammation may subside, and a useful, although a somewhat damaged, eye be preserved. Generally, however, the activity of the disease continues unabated, and does not expend itself until all the tissues of the eye are involved in one general suppuration. The cornea then gives way, or the pus makes an exit for itself through the sclerotic between the insertions of two of the recti tendons.

Treatment.—The eye should be frequently fomented with the fots belladonnæ (F. 9), or with the decoction of poppy heads. A solution of atropine, gr. 1 ad aquæ ʒ 1, should be dropped into the eye twice or three times a day; but it should be discontinued as useless when suppuration has actually set in. The patient should be

kept in a darkened room, and all use of the eyes should be prohibited. The bowels should be acted on at the commencement of the attack, and if the patient is restless, sleep should be produced, and the pain relieved by opium. In these cases opium is usually of the greatest service; it assuages the pain, tranquillizes the patient, and places him in a more favourable condition for recovery. Whilst there is hot skin and thirst, salines and diaphoretics should be prescribed, but these must soon give place to quinine or bark with the mineral acids. The strength of the patient should be maintained by a liberal strong beef-tea diet, with a moderate allowance of wine or brandy. But if the inflammation goes on, and the cornea becomes ulcerated, or infiltrated with pus; or if there is hypopion with the eye painful, and the anterior chamber deepened by the increased secretion of the aqueous, tapping the anterior chamber with a broad needle will sometimes afford very considerable relief and materially benefit the eye. The activity of the disease is frequently sensibly diminished after one such operation. It is not, however, a proceeding which should be undertaken rashly, as, when it fails to do good, it often seems to irritate the eye and increase the urgency of the symptoms. In some bad cases of ophthalmitis which I have been under my observation, I am satisfied that the ultimate destruction of the eye has been hastened by an injudicious paracentesis of the cornea. When the operation gives ease, it may be repeated at intervals of twenty-four or thirty-six hours if the pain and acute symptoms recur; but if, after once tapping the anterior chamber, the pain in the eye is increased, it should not again be attempted.

If all treatment has failed to arrest the progress of the disease, and suppuration of the globe has actually set in, I would advise the eye to be excised. The patient will thus be quickly restored to health, and be spared much suffering. In my own practice I have never had any unfavourable symptoms follow the excision of a suppurating eye.

DEPOSITS OF BONE ON THE CHOROID are frequently found in eyes which have been long lost. The bony matter is on the anterior surface of the choroid, between it and the retina, which is always detached and usually coarcted. In some cases a mere ossific film is

found lying on the choroid (Fig. 47), whilst in others there is a thick bony cup, sufficient in size to occupy nearly the entire stump (Fig. 48).

FIG. 47.

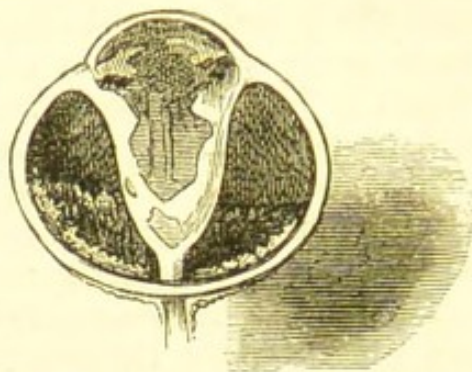


Fig. 47 is the drawing of a section of an eye which I removed from a patient, *æt.* thirty. She had lost all sight in it from an injury eighteen years before coming under my care. The globe was shrunk about one-third; at times it was very painful, and it had lately been subject to frequent recurrences of inflammation, during each of which her sound eye sympathized.

The entire retina was detached and coarcted; the choroid was *in situ* with the sclerotic; but lying on its anterior surface around the optic nerve was a delicate film of bone.

It seems very probable that the formation of these bony plates is due to an inflammatory exudation of lymph on the surface of the choroid, which after a lapse of time becomes organized and converted into fibrous tissue. This afterwards undergoes a further change; osseous granules are deposited within it, and it becomes bone having all the characters, both anatomical and chemical, which distinguish this tissue in other parts of the body. The cup of bone is usually perforated near its centre by a small canal, through which passes a band of the atrophied retina back to the optic nerve.

Whilst bone is thus being developed in the fundus of the eye, earthy salts, such as the phosphate or carbonate of lime, are frequently at the same time being deposited in the lens, if there is one, and between the laminae of the cornea, or, if that has been destroyed, in the cicatricial tissue which has replaced it.

In a report of a specimen of "bone from the inner surface of the choroid," by Mr. Hulke, in the "Patho-

ological Transactions," vol. viii. p. 320, he has given the drawings of the microscopical appearances of the sections he examined. He found in them all the elements of true bone—a complete system of vascular canals, with lacunæ and canaliculi. In the mere scales of bone, however, which he has since examined, he

FIG. 48.

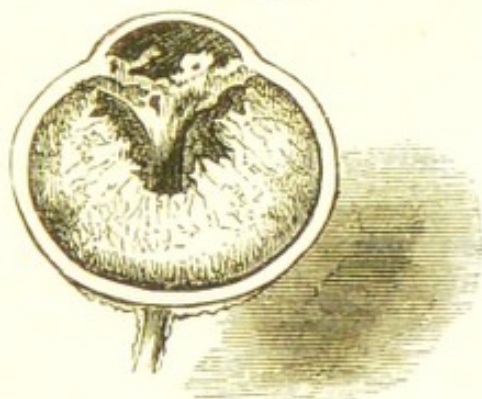


Fig. 48 represents an exceptionally large cup of bone in the stump of an eye which had been lost for more than sixty years. The patient, an old lady, æt. sixty-one, never had any annoyance from it until about four months before coming to the hospital, when it began to give her pain, and since then she has suffered with it severely. The right eye presented all the usual symptoms of sympathetic irritation. I therefore excised the stump of the lost eye, which was shrunk to the size seen in the woodcut.

has told me that he has been unable to detect any vascular canals, but in all he has seen the lacunæ and canaliculi. This is probably simply due to the fact that such delicate films of bone were too thin to admit of vascular canals.

COLLOID DEGENERATION OF THE CHOROID

is one of the changes which are apt to take place in eyes which have been lost from either accident or disease. It may occur at any period of life, and may be met with in eyes which have retained their normal shape, as well as in those which have become shrunken. Colloid globules are seen on making a section of the eye as small white bodies scattered singly or grouped in little masses projecting beyond the surface of the choroid. Examined with the microscope they present a peculiar and characteristic appearance. When fresh they are seen as transparent shining

globules, which refract the light strongly, and somewhat resemble the bright translucent crystals of white sugar candy. In a paper by Mr. Hulke, he says, "Their size varies from the $\frac{1}{1250}$ to $\frac{1}{430}$ of an inch. The largest look like tiny seed pearls strewed over the inner surface of the choroid. They adhere very intimately to the elastic lamina, and indeed appear to be continuous with it." In an eye examined by Mr. Hulke immediately after its removal, in which the choroid was studded with colloid globules, he saw "the blood corpuscles gliding along the capillary vessels in continuous unbroken columns beneath (that is, to the outer side of) the colloid globules, a phenomenon which completely established their respective positions, and one from which we may conclude that these vessels are not primarily affected, although at a later period they may become implicated. Commonly they present no traces of structure, but occasionally they are marked with concentric lines."*

Donders considers that the colloid globules originate in the hexagonal pigment cells, whilst Muller regards them as adventitious thickenings of the elastic lamina behind the hexagonal epithelium. Mr. Hulke further states that "the colloid globules are very prone to calcify. In this state they form stony glandiform masses, with a finely granular surface, or beads of a dull glassy aspect, and the larger concretions are plainly visible to the unaided eye."

Colloid degeneration appears to be most frequent in eyes which have been subject to repeated attacks of inflammation. In one case which came under my notice, these degenerative changes excited sympathetic symptoms in the sound eye, which ceased on the removal of the affected one—a shrunken globe lost from an injury four or five years previously.

TUBERCLES IN THE CHOROID may be frequently found in patients who are suffering from acute tuberculosis. In the cases which have been recorded they produced no defect of sight. With the ophthalmoscope they may be recognised as "small circular circumscribed spots of a pale rose colour, or greyish-white tint, and vary in size from $\frac{1}{3}$ to 2.5 mm. They are chiefly

* Royal London Ophthalmic Hospital Reports, vol. i. [pp. 70 and 180.]

situated in the vicinity of the optic disc, but may extend occasionally to a considerable distance from it."*

Dr. Coupland has related in the "Pathological Transactions," vol. xxv. p. 215, a very interesting case of general tuberculosis in a child, æt. eight, who died of tubercular meningitis. Tubercles were detected in the choroid during life, and verified after death.

Dr. Gowers, in his "Medical Ophthalmoscopy," second edition, p. 148, says, "Tubercles of the choroid may now and then be found in tubercular meningitis, and furnish valuable diagnostic information. But they are less frequent, as Cohnheim pointed out, in tubercular meningitis than in general tuberculosis without meningitis."

HÆMORRHAGE FROM THE CHOROID may occur from injury (see next Section, INJURIES OF THE CHOROID), or it may be occasioned by disease, as in glaucoma, sclerotico-choroiditis posterior, or retinal apoplexy. See the Articles on these subjects. It may also be produced by prolonged and excessive strain of the eyes at close work, and especially if during its continuance the head has to be maintained in a stooping position.

The Treatment must depend on the exciting cause of the hæmorrhage. (See Articles, GLAUCOMA, SCLEROTICO-CHOROIDITIS POSTERIOR, and RETINAL APOPLEXY.)

INJURIES OF THE CHOROID.

INJURIES OF THE CHOROID are usually followed by immediate hæmorrhage, which always seriously affects and often completely destroys sight. A blow on the eye may cause a rent in the choroid, either *with* or *without* rupture of the external coats; or the choroid may be lacerated by a penetrating wound through the sclerotic. Hæmorrhage at once takes place from the torn choroidal vessels, and according to the site and severity of the injury the blood may be extravasated:—

1. Between the choroid and retina.
2. Between the choroid and sclerotic.
3. Into the vitreous humour.

1. Hæmorrhage between the choroid and retina

* Soelberg Wells' Treatise on the Eye, second edition, p. 471.

is generally caused by blows on the eye, and may occur either *with* or *without* rupture of the external coats. The blood is poured out from the anterior surface of the choroid, and a clot is formed between that structure and the retina. When the clot is small, it may be absorbed, and the eye may regain useful vision, but there will always remain a blind spot corresponding with the portion of retina which has been detached. If the hæmorrhage is severe, there will be necessarily an extensive separation of the retina, and the eye for all useful purposes will be destroyed.

2. **Hæmorrhage between the Choroid and Sclerotic**, uncomplicated with hæmorrhage in any other part of the eye, is most commonly produced by an escape of the lens and a sudden loss of vitreous through a wound in an *unhealthy eye*: thus withdrawing unexpectedly the support which the choroid and retina had derived from these structures, when, in their entirety, they occupied their normal position within the globe.

In a healthy eye, the lens and a large amount of vitreous humour may be lost through a wound of its external coats, without exerting any very unfavourable influence on the retina or the choroidal vessels; but in an *unsound eye*, a similar loss would probably produce hæmorrhage between the choroid and sclerotic. It is this form of hæmorrhage which occasionally occurs after an operation for the removal of a cataractous lens from an unsound eye. Indeed, it is almost certain to happen if there be an increased or glaucomatous tension of the eye at the time of operating. In such cases the hæmorrhage takes place from the posterior surface of the choroid, detaching sometimes partially, but generally completely, the choroid from the sclerotic, and forming a large blood clot, it pushes in front of it the choroid and retina, and extrudes more or less of the vitreous from the eye.

When hæmorrhage between the choroid and sclerotic is occasioned by blows on the eye, the bleeding is seldom confined to the space between the choroid and retina, but takes place also in other parts of the eye, and blood is often found on the retina, between it and the choroid, and in the vitreous.

3. **Hæmorrhage into the Vitreous** may occur from an injury of the choroid. If the hæmorrhage is severe, the blood frequently bursts through the retina and hyaloid membrane, and extravasates itself into the vitreous body.

For a further account of hæmorrhage into the vitreous, see the Article in the Chapter on the DISEASES OF THE VITREOUS, page 136.

The Prognosis of choroidal hæmorrhage is always unfavourable. It is only when the bleeding has been slight and limited to a small surface that even a hope can be held out that a certain amount of useful sight will be retained. If in such a case the patient progresses favourably, he will probably recover with some valuable sight, but he will not regain that which was destroyed by the blood clot: one blind spot in his field of vision will indicate the extent of retina which has been detached, and the loss the eye has sustained. When there is extensive choroidal hæmorrhage, the eye for all visual purposes is lost; no matter whether the blood is effused into the vitreous, or between the retina and choroid, or the choroid and sclerotic. If the eye does not suppurate, and as a rule it does not do so if the external coats are entire, it gradually under treatment subsides into a quiet state, becomes soft, and somewhat smaller than the other.

Treatment.—Immediately after the injury a leech or two may be applied to the temple with the hope of preventing any undue inflammatory action; and a fold of lint or linen dipped in cold or iced water should be placed over the eye, and wetted as often as it becomes dry and hot. Two or three drops of a solution of the sulphate of atropia, gr. 1 ad aquæ $\bar{3}$ 1, should be dropped into the eye twice a day. It will exert a sedative influence, and also act beneficially on the pupil if any active inflammation comes on. Complete rest should be given to the sound eye by abstaining from all work, and the exclusion of strong light from the room. There are no special applications or medicines which can be given with the view of favouring absorption of the blood which has been effused.

INTRAOCULAR TUMOURS.

Intraocular tumours may be said to be of two kinds, each of which will admit of certain variations.

1. Glioma which grows from the retina.
2. Sarcomatous tumours which grow from the choroid.

It is very rare to find a carcinomatous growth within the globe, so rare indeed that many pathologists doubt

whether carcinoma or true cancer ever originates within the eye. The tumours which have been described as encephaloid, medullary and melanotic cancers have evidently been either gliomas, or soft sarcomas, and sarcomas deeply coloured with pigment.

GLIOMA OF THE RETINA.—The terrible disease which has received this name was formerly known as encephaloid or medullary cancer, and by some pathologists it is now called encephaloid of the retina. In appearance a glioma resembles very closely brain-substance. It is soft, of a white or yellowish-white colour, and springs from the connective tissue (the neuroglia) of the retina. In structure it consists of a finely granular or amorphous intercellular substance, in which are embedded spherical, roundly oval, and occasionally spindle-shaped cells. As it grows, portions of it frequently undergo fatty degeneration and become so soft as to be almost fluid, whilst other parts become chalky or calcareous. It is usually of rather slow growth, extending over a period of from one to two years before it completely distends the globe and bursts through the sclerotic or cornea. The disease spreads by infection, which travels along the optic nerve, and after death a similar growth is frequently found in the brain in direct communication with the optic tracts. It seldom produces secondary tumours in the abdominal or thoracic viscera; but Knapp has recorded one case in which there were secondary gliomas in the liver, lungs, and diploë of the bones of the cranium.*

Glioma is a disease of early life, and, as far as my experience goes, it is limited to childhood. The youngest patient I have had under my care was an infant six weeks old, in whom the growth was probably congenital, and I have not met with a retinal glioma in a child beyond the age of five years. Knapp mentions two cases in which there was reason to believe that the gliomas were congenital. The disease is very recurrent, and is apt to return in the orbit after the eye has been excised, and also to appear in the other eye. There are, however, occasional exceptions to the recurrence of the glioma after the diseased eye has been removed. In 1872 I excised the right eye of a child, æt. two years and eight months, on account of a glioma of the retina, and

* Knapp, On Intraocular Tumours.

after more than seven years there was no return of the disease.

Symptoms.—A rapid diminution of sight, with more or less dilatation of the pupil. In the early stage of glioma there is no pain, and the disease is usually first discovered by the mother or attendant noticing a bright yellow reflex from the fundus of the globe, and then, on closing the sound eye, it is found that the affected one is almost, if not completely, blind. The refracting media are generally clear, so that the growth of the tumour may be easily watched. As the disease advances there is an increased tension of the globe, and then the eye becomes painful and the child restless, frequently crying and starting in his sleep. The lens and iris are pushed towards the cornea, and the pupil becomes dilated and inactive. At a later stage of the disease the lens becomes cloudy and the cornea dull, and the tumour bursts its way through the globe and appears externally. It now seems to grow with an increased activity, and forms a fungating mass from which there are frequent recurrences of hæmorrhage, and the child dies either worn-out by pain and exhaustion, or from meningitis caused by an extension of the disease to the brain. Examined with the ophthalmoscope, the tumour will be seen occupying a limited portion of the retina, and with blood-vessels on its surface, which clearly belong to the new growth, and indicate its great vascularity. In the immediate locality of the tumour the retina is detached, and this separation increases with the advance of the disease.

Treatment.—The only chance for the patient is an early excision of the globe; and should the two eyes be affected I would excise both, provided the sight has been already destroyed, and the tumour has not burst through the external coats. Such an operation would afford the only hope for recovery, whilst at the same time it would save the patient much ultimate suffering. On several occasions I have been induced to remove the second eye, for the sole purpose of procuring some temporary relief from the excessive pain induced by the over-distended globe, and at a time when there was not the slightest prospect of arresting the disease. In each case the operation gave so much ease, that under similar circumstances I should not hesitate to repeat it.

SARCOMA OF THE CHOROID.—To this affection

has also been applied the terms **medullary sarcoma** and **medullary cancer**. Adopting the definition given by Arnott in his work on cancer, "a sarcoma is almost entirely a cellular growth with more or less of a visible intercellular substance," and the cells may be either round, oval, or spindle-shaped, each containing a nucleus and nucleolus. "In these several varieties, however, the one character remains—viz., that the bulk of the tumour is built up of simple cells, bound together by a scanty homogeneous or granular semi-fluid substance. Hence a marked distinction from carcinoma, in which the cells are as a rule quite free from any visible intercellular material and float in the meshes of a fibrous stroma."*

A sarcoma of the choroid starts from the connective tissue of the choroid; it has a strong tendency to recur in the vicinity from which it originated after it has been removed, and it will frequently give rise at a later period of the disease to secondary tumours in other organs, as the liver, lungs, or kidneys; but, according to Billroth, of Vienna, it rarely infects the lymphatic glands.

Progress of the Disease.—A small nodule first appears on the choroid, which detaches the portion of retina with which it is in contact, and loosens also that which surrounds it. As it grows it pushes forward the retina, displaces the vitreous, and presses the lens and iris towards the cornea. Frequently the globe loses its normal shape, and dark bulgings will be seen in the ciliary region. The cornea grows dull, then ulcerates, and through the opening the tumour crops out; or else it makes an exit for itself posteriorly, and bursting through the sclerotic, it extends itself into the orbit. Having escaped from within the globe, it seems as if it had acquired new vitality, and grows with an increased vigour. If the tumour has burst through the globe anteriorly, its surface after a time ulcerates and bleeds, and it assumes an appearance which has given to it the name of "fungus hæmatodes." The attacks of hæmorrhage increase in frequency with the advance of the disease until the patient at length sinks, worn-out with pain and loss of blood. Such is the history of a case which has been allowed to proceed to its termination unchecked by

* Arnott, On Cancer: its Varieties, their Histology and Diagnosis, page 43.

surgical treatment, but fortunately these examples are now rare.

Symptoms.—The first symptom which generally draws attention to the eye is the loss of sight, which may be either partial or complete according to the size and situation of the tumour. At the commencement of the disease there is usually no pain as a warning of the approaching evil, but as the tumour grows and distends the globe, there is often excessive suffering. The diagnosis of a choroidal tumour in the early stage is frequently very difficult; but with the ophthalmoscope it may be detected at a period when the only symptom is a loss of sight in a portion of the field of vision.

It should be remembered that during the progress of growth of an intraocular tumour, an increased tension of the globe frequently occurs, and that, from overlooking the cause of this glaucomatous symptom, mistakes have occasionally been made by treating such cases with iridectomy.

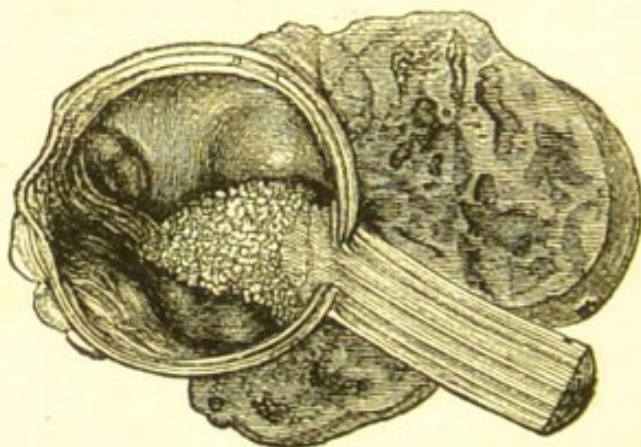
Melanotic Sarcoma of the Choroid, called also **Melanotic Cancer**, is the same disease as the sarcoma of the choroid described in the preceding section, the only difference being the addition of the black pigment which is scattered in varying quantities throughout its structure. I have on two or three occasions seen the identity of sarcoma and melanotic sarcoma well illustrated by the changes which have occurred in the growth of the tumour. Whilst confined within the globe, the sarcoma in each case was deeply coloured with pigment, so as to be in parts absolutely black; but having burst through the sclerotic posteriorly, it grew with an increased rapidity, and the extraocular portion was white. The tumour external to the globe was the same growth and continuous with that which was within the eye; both were sarcomatous, but the addition of pigment made the parts within the globe melanotic.

The Prognosis of choroidal tumours is generally unfavourable. The best chance is afforded the patient when the disease is detected early, and the eye removed before the tumour has attained a large size. It is of the greatest importance that the eye should be excised before the tumour has burst through the external coats, as when the disease has reached this stage there is the probability that the neighbouring tissues have become infected by it.

Treatment.—Excision of the eye. If the tumour has made its way through the sclerotic, the chloride of zinc paste (F. 7) should be applied to the tissues in the orbit, in the manner recommended in the Section TREATMENT OF ORBITAL TUMOURS.

SARCOMA OF THE CHOROID ORIGINATING IN LOST EYES.—Eyes which have been long lost either from injury or disease occasionally become the seat of sarcomatous tumours from the choroid. It is true that such cases are comparatively rare, yet they occur with sufficient frequency to show that the degenerative changes which take place in eyes which have been destroyed by accident or disease are favourable for the production of sarcomatous growths. Fig. 49 represents a section of an eye I removed from a patient, æt. sixty-nine, who had suffered from an acute inflammatory attack twelve years

FIG. 49.



previously, which had completely destroyed the sight. Since that time the eye had been repeatedly inflamed. Four or five months before he last came under my care the eye had begun to bulge, and the pain, which was occasional, had now become constant, and at night the exacerbations were very severe. Under these circumstances the patient wished to have the globe removed, although he had on several previous occasions refused to submit to the operation. From the report of Mr. Nettleship, the curator of the museum at the Royal London Ophthalmic Hospital, the tumour was a spindle-celled sarcoma which took its origin from the choroid, afterwards spread into the retina and optic nerve, and passed either through the nerve or sclerotic into the lax cellular

tissue outside the globe. The conical-shaped tumour which sprang from the optic nerve was probably a secondary formation.*

Mr. Streatfeild has also related a case in which an old man lost the sight of one eye from an inflammatory attack thirteen years before coming under his care. The eye remained shrunken and quiet until within the last three or four months, when it rapidly enlarged. Mr. Streatfeild removed the eye; and after excision the globe was found filled with a sarcomatous growth which had passed outwards, rupturing the sclerotic, and had formed a large extraocular tumour.

DISEASES OF THE OPTIC NERVE.

There are two forms of neuritis or inflammation of the optic nerve.

1. **OPTIC NEURITIS**—*Papillitis*,—*Descending Neuritis*.—The pathological changes originating in structures beyond the eye.

2. **NEURO-RETINITIS**.—The pathological changes originating within the eye.

1. **Optic Neuritis**—*Descending Neuritis*.—The inflammatory changes are mainly confined to the optic nerve. It has been termed *descending* neuritis because it is the result of extraocular disease and the inflammatory process descend along the trunk of the optic nerve to the papilla within the eye. It may be caused by tumours in the brain or in the orbit, or by an intra-cranial syphilitic node, or by meningitis, hydrocephalus, lead-poisoning, or from any irritative disease within the skull. It may also arise from injuries to the head, coming on many months after the patient has apparently recovered from all effects of the accident. Dr. Hughlings Jackson states that descending neuritis may be caused by any "coarse" disease in the cerebrum or cerebellum.

Symptoms of Optic Neuritis.—When seen at an early stage the ophthalmoscopic signs are—1. Change in the appearance of the optic disc, which is swollen and prominent, and oftentimes slightly hazy from a semi-transparent whitish exudation over it. The degree of

* Royal London Ophthalmic Hospital Reports, vol. vii. p. 277.

swelling of the disc is indicated by the abruptness of the bend of the retinal vessels as they pass over its margin on to the retina. 2. Blurring or loss of definite outline of the circumference of the disc, which may be either irregular, confused, or apparently lost, as if the margin of the disc merged into the surrounding retina. 3. Fulness of the retinal veins, which are large, dark coloured, and sometimes tortuous. The arteries may be normal in appearance, but generally they appear small and even thready. If the neuritis increases, the ophthalmoscopic signs are intensified, and portions of the vessels in their course over the papilla will often become obscured by a whitish inflammatory exudation. Occasionally there are small hæmorrhagic spots on the disc and in the adjacent retina, which in some cases is of a dull and whitish colour from inflammatory effusions, whilst the rest of the retina remains perfectly transparent. The disc will sometimes assume a greyish-white colour, with a peculiar "woolly" look, much as if cotton wool had been carded until all its fibrils radiated outwards from a centre.* There is usually a steady diminution of the acuity of vision, often accompanied with a contraction or partial loss of the visual field. The pupil is rather dilated and sluggish. The patient has no pain in the eye, nor are there any external manifestations to account for the increasing loss of sight. Both eyes are generally affected, and the disease is usually symmetrical; but one eye may be attacked a little in advance of the other, or the impairment of sight may be greater in one eye than in the other. After a variable time all the prominent ophthalmoscopic symptoms of neuritis subside; the morbid effusions are absorbed, the disc becomes flattened and of a creamy white, and the arteries are reduced to mere threads, but for a long time the veins continue large and tortuous. With all these changes the sight diminishes until ultimately it is completely lost, or reduced to a mere perception of large objects.

There are, however, cases of neuritis proceeding from intra-cranial causes, and accompanied with great impairment of sight, and from which the patient completely recovers, but I do not know of any means by which these cases can be diagnosed when first seen. There are also

* Hutchinson, On Inflammation of the Optic Nerve: Royal London Ophthalmic Hospital Reports, vol. v. p. 98.

cases of optic neuritis in which the sight of the patient is *not* affected, and yet the neuritis may be due to some local disease of the brain. In a paper by Dr. Hughlings Jackson on the use of the ophthalmoscope in brain disease,* he says, in speaking of double optic neuritis, "it is very common for this condition to exist in a patient who can read the smallest type, and who supposes his sight to be good; there is a marked pathological change without any *obvious* symptom."

When optic neuritis arises from intra-cranial disease, it almost invariably affects both eyes: unilocular neuritis in such cases is very rare. Dr. Hughlings Jackson says: "It is notorious that tumour of but one cerebral hemisphere, nearly always, if it produces optic neuritis, produces *double* optic neuritis, and, what is more to the point, the neuritis begins nearly at the same time on the two sides; it may be unequal in degree."†

The term "choked disc" may still be retained to express that condition of the optic papilla, marked by swelling, increased redness, and distension of the retinal veins; and caused by some mechanical obstruction to the free passage of the blood from the eye to the cavernous sinus. The free communication which exists between the orbital and facial veins certainly does not in all cases prevent venous engorgement and swelling of the optic disc, when the return current of blood from the eye to the cavernous sinus is impeded by the pressure of a tumour within the orbit. This fact was well shown in a case I reported in the Clinical Transactions, vol. ix. p. 134, of a man who had a well-pronounced choked optic disc, due solely to the pressure of an hydatid tumour on the optic nerve, which impeded the return flow of blood from the eye. The tumour was punctured through the upper lid, and a clear fluid escaped; the eye which was protruded, partially receded, and when examined with the ophthalmoscope two days afterwards, the nerve was found to have nearly regained its normal appearance; all the choking of the disc had disappeared.

The **constitutional** symptoms associated with optic neuritis are headache, sometimes continuous, at others paroxysmal, and frequently accompanied by vomiting. In some cases the headache is intense, and it is this

* The Lancet, Oct. 12, 1872.

† Transact. Ophthalmolog. Society, vol. i. p. 68.

symptom which induces the surgeon to examine the state of the optic papilla. With the headache there may be giddiness, which may be occasional or almost constant; or there may be loss of smell, or defect of hearing, or occasional epileptic convulsions, or palsy of one or more of the ocular nerves, or a loss of the proper co-ordinating power over the muscles of the extremities.

Optic neuritis may, however, exist without any other indication of intra-cranial disease, and may yet be due to some gross organic disease in the brain, but which has not manifested constitutional symptoms.

It is difficult to form a prognosis in cases of optic neuritis, but to attempt to do so it is necessary to group together all the symptoms and to estimate them as a whole.

Chronic headache and frequent vomiting with double neuritis point strongly to the presence of an intra-cranial tumour, and this supposition is increased if after a time there be other symptoms manifested, such as giddiness, tinnitus, deafness, or palsy of ocular nerve, or convulsions.

Acute head symptoms in young people with double optic neuritis, suggest tubercular meningitis, and this diagnosis is strengthened, if with the ophthalmoscope tubercles be found in the choroid.

Neuritis in one eye only, generally indicates pressure within the orbit, possibly some form of tumour or an aneurism, or it may be pressure on the cavernous sinus from some growth within the skull but not connected with brain.

Neuritis in both eyes coming on some weeks after a severe head injury is very serious. It indicates some inflammatory action around the seat of brain injury, and such cases often terminate fatally. When neuritis comes on many months after a head injury, it is, I think, due to cicatricial changes taking place at the seat of the brain injury: the patient usually recovers, but the sight is lost.

Neuritis arising from Bright's disease of the kidneys, or from constitutional causes, frequently cannot be diagnosed by the ophthalmoscope from neuritis due to intra-cranial disease. The association of constitutional and local symptoms with the neuritis are essential for a correct diagnosis.

Pathology.—In considering the pathology of neuritis, it is necessary to remember the peculiar arrangement of the external coats of the optic nerve. In Quain's *Anatomy*, 9th edition, vol. ii. p. 377, the author says:—

"The nerves as they pass from the brain and spinal cord receive their perineural covering from the pia mater, and, in addition, two looser sheaths, an outer from the dura mater, and an inner from the arachnoid. Upon the optic nerve these sheaths remain distinct and separate, so that the space which each encloses may be injected, the outer from the subdural, the inner from the subarachnoid space. . . . There thus exists a continuity between the ventricles of the brain, the subarachnoid space, the perivascular canals of the cerebral substance, and the lymphatic spaces within the nerve-sheaths."

In the majority of the cases of neuritis in which there has been a post-mortem examination, the sheaths of the optic nerves have been found more or less distended with fluid which has pressed on the nerve-tissue; and in those cases in which no fluid has been found, there have generally been evidences of inflammatory action either in the nerves or in their sheaths.

There are several theories as to how these optic nerve changes may be induced.

1. That optic neuritis is caused by an extension of an inflammation at the seat of the disease in the brain, which is propagated to the optic papilla either through a direct continuity of nerve tissue; or by an extension of the inflammation through the connective tissue structures and blood-vessels of the optic nerve. Dr. Buzzard has suggested that if this theory be correct, the other cranial nerves may also suffer from neuritis like the optic nerve. This is very probable, as associated with cerebral disease we frequently get in addition to the optic neuritis, deafness, tinnitus, perversion and loss of smell, facial neuralgia, and other symptoms of nerve irritation, all of which may be due to neuritis of the special nerves affected.

2. Another theory is, that the distension of the optic nerve with fluid, so frequently found in optic neuritis, is due either to a rise of intra-cranial pressure, or to an increase of subarachnoid fluid. Certainly the direct communications which exist between the sheaths of the optic nerve and the parts within the head, render the optic nerve peculiarly liable to be affected by any intra-cranial change.

3. It has been suggested that an intra-cranial tumour produces optic neuritis from the irritation it sets up as "a foreign body," and that this irritation is conveyed to the optic nerve, which consequently becomes inflamed.

Treatment.—In optic neuritis the treatment must be

guided by existing symptoms. When there is great pain in the head, the subcutaneous injection of morphia (F. 30) or of morphia with atropia (F. 31), will often give great relief. If morphia alone cannot be borne, it may be tried in smaller doses combined with the bromide of potassium; or the bromide of potassium may be given during the day, and chloral at night. The medicine which seems to do the most good is iodide of potassium, which may be increased up to twenty grains three times a day, and to which may be added five or ten grains of the bromide. If there is reason to believe that the neuritis is due to a syphilitic gumma in the brain, in addition to the iodide of potassium, mercury should be given either in combination with the iodide, or in the form of the green iodide (F. 121), or by inunction. When neuritis is due to a cerebral tumour, not syphilitic, appropriate medicines may relieve symptoms, but they will not cure the disease.

2. NEURO-RETINITIS—*Ascending Optic Neuritis*.—The inflammation is not limited to the optic nerve, but it includes also the retina, from which it originates, and extends to the optic nerve, ascending a short distance along its trunk. It is most frequently induced by syphilis or chronic kidney disease; and it is caused occasionally by derangements of the functions of the uterus, or by fever, diphtheria, or over-lactation.

Symptoms of Neuro-retinitis.—The optic disc is clouded, its outline is indistinct or lost, and the vessels as they pass over its surface are more or less obscured, but there is not the venous distension or the engorgement of the papilla which characterize the pure descending neuritis. The great point of distinction, however, between neuritis and neuro-retinitis is, that in the one the retina is extensively involved, whilst in the other it is either not at all affected, or only for a short distance immediately surrounding the disc.

In neuro-retinitis the whole surface of the retina seems obscured by a diffused haze which renders all the minute vessels indistinct, and gives a peculiar and characteristic washed-out appearance to the fundus. There is also an absence of the head symptoms which were noticed as being generally present in neuritis. In neuro-retinitis the disease is often confined to the one eye, whereas in the descending neuritis both eyes are generally affected.

The prognosis of neuro-retinitis, although unfavourable, is yet more hopeful than that of descending neuritis, and especially if some blood-poisoning, such as syphilis, can be traced as the probable cause of the disease.

Treatment.—In *neuro-retinitis* care must be taken to ascertain the source of the disease, as it may be due to many causes. When it can be ascribed to syphilis, the mist. potass. iodid. (F. 91) may be given during the day, and pil. Plummer. gr. 5 every other night; or the mist. potassii iodidi cum hydrarg. perchlorid. (F. 98) may be prescribed. If the patient is feeble, the unguent. hydrarg. cum belladonnâ (F. 126) may be rubbed into the temple night and morning, and the mist. quinae (F. 79) be taken during the day.

When the disease is apparently due to suppressed menstruation, every endeavour should be used to restore the uterine functions. In some cases I have had excellent results from the iodide of potassium given in 10 gr. doses twice a day in water. It has then acted as a powerful emmenagogue. I must, however, confess that this medicine has occasionally failed to do good, or its administration has been attended with only a partial success. Notice should be taken whether the amenorrhœa is due to anæmia or congestion. If the former, tonics of quinine and iron, or the mist. ferri perchlorid. cum tinct. ergotæ (F. 89) may be ordered, but at the same time some aloetic pill should be prescribed to ensure the regular daily action of the bowels. If the suppression is due to congestion, the bowels should be freely acted on by a brisk purgative. In some cases small doses of podophyllin given every other or third night do good. During the day the iodide and bromide of potassium in a bitter infusion, or the mist. boracis (F. 71) may be given. When the sight is rapidly failing, and there is much pain in the head, I have known the inunction of the unguent. hydrarg. night and morning, so as to get the patient quickly under its influence, productive of great good. As soon as the gums are spongy, the frequency of the rubbing-in must be diminished, but a slight mercurial action should be kept up for two or three weeks.

In cases of neuro-retinitis dependent on or associated with great debility, such as after fever, or diphtheria, or from over-lactation, the mineral acids with cinchona, or some of the preparations of iron, are most likely to do

good. A slight mercurial counter-irritation may be also kept up on the temple of the affected eye, by rubbing in every night a little of the unguent. hydrarg. iodidi rubri (F. 132); or by applying small blisters about the size of a shilling from time to time, and afterwards dressing the vesicated surfaces with the unguent. hydrarg.

ATROPHY OF THE OPTIC NERVE—*White Atrophy*—may be caused by disease of the brain or medulla oblongata; or it may be the unfortunate termination of some deep-seated inflammation of the eye.

Atrophy of the optic nerve may therefore be considered under two headings:—

1. That which proceeds from disease *beyond* the eye.
2. That which arises from *within* the eye.

1. ATROPHY OF THE OPTIC NERVE FROM DISEASE BEYOND THE EYE.—This form is mostly occasioned by cerebral or cerebro-spinal disease, or by tumours within the orbit. Neuritis of one or both eyes may be thus induced, and atrophy of the optic nerves may follow as a consequence. Atrophy may, however, come on without neuritis, dependent no doubt upon cerebral causes, but which are often too obscure to be diagnosed. It is to atrophy of the nerve arising from disease *beyond* the eye that the term “white atrophy” is properly applied. In the other forms of atrophy the papilla is also greyish-white, or white, and especially in their most advanced stages: but the characteristic signs of white atrophy of the optic nerve are best found in cases arising from cerebral disease. (See Article AMAUROSIS, p. 221.)

Symptoms of Atrophy of the Optic Nerve.—An increasing dulness of sight, both for near and distant objects, which is not improved by glasses, excepting those which act as powerful magnifiers, when small objects from being rendered larger are better seen; and contraction or partial loss of the field of vision.

In locomotor ataxy, atrophy of the optic nerves is frequently an early symptom, and the atrophy is often advanced before the unsteadiness of gait manifests itself.

In optic nerve atrophy there is usually some defect in the colour sight, and this becomes very marked as the atrophy advances. Red and green are the colours first

lost, but ultimately there is frequently complete colour-blindness, and everything appears as either white, grey, or black. The loss of colour sight is often very complete in locomotor ataxy.

State of the Pupil.—In the early symptoms of atrophy of the optic nerve dependent on brain disease, the pupil is rather dilated and sluggish; but in the later stages it is widely expanded and fixed, giving to the eyes the peculiar vacant stare which is so characteristic of blindness from cerebral disease. When, however, the atrophy is due to some affection of the spinal cord, the pupil is frequently contracted. See Myosis, p. 96. Dr. Argyll Robertson has shown that in optic nerve atrophy from spinal disease, that although the pupils will not contract to the stimulus of light, yet if an attempt be made to read, or to look at the finger as it is made to approach the eyes, both pupils will contract under the effort of accommodation. This loss of action of the pupils to light is also found in atrophy of the optic nerves proceeding from other causes.

There is a form of atrophy which may be rightly called **senile atrophy of the optic nerve**. It occurs in elderly patients, and the only symptom is a progressive dulness of sight, which may go on to blindness. There are no cerebral or spinal symptoms; the sight fades in the same way as the hearing fails in old people from atrophy of the nerve, and without any evidence of disease.

Ophthalmoscopic Appearances of White Atrophy.—When the disease is fully advanced, the optic disc looks large, flat, and of a bluish or pearly whiteness. The retinal vessels are generally small; the arteries often appear as mere threads, but in some cases, and especially in those which proceed from neuritis, the veins are large and distended. The small blood-vessels, which are usually seen on the disc, have shrunk from view, and the surface of the nerve is blanched and bloodless. There is frequently an excavation of the optic nerve, not from any increased tension of the eye, but from a shrinking from atrophy of the nervous elements, and a falling in of the central portion of the papilla. The peculiarities of this "**atrophic cup**" are, that it is a shallow excavation, shelving from the margin towards the centre of the nerve, quite different from the abrupt edge of the glaucomatous cup. The disc presents the peculiar bluish or milky whiteness of atrophy, its vessels are small, and there is little or no

displacement of them as they pass from the margin of the papilla on to the retina. For a description of the glaucomatous and the physiological excavations of the optic nerve, see Article GLAUCOMA, pp. 120, 121.

2. **Atrophy of the Optic Nerve from Disease within the Eye** may be caused by chronic affections of the choroid or retina by glaucoma, by acute inflammation of the eye, or by an injury producing extensive intraocular hæmorrhage. As the original disease subsides, the cloudiness of the inflamed structures may partially and sometimes completely disappear, but the retina and optic nerve, instead of regaining their functions, undergo a slow process of atrophy, and ultimately all sight is extinguished. The ophthalmoscopic appearances are variable, and depend very much on the nature of the affection which has caused the atrophy. The optic papilla is anæmic, and of a cloudy or greyish-white, but it has not generally the brilliant tendinous whiteness of white atrophy; its outline is often indistinct or irregular, and its vessels are small and withered. In some cases the optic disc looks absolutely smaller than normal, and this is especially so if the eye is soft and somewhat shrunken. A cloudy film often pervades the whole fundus, and blurs the appearance of the structures behind it. Associated with this condition of the eye there are frequently to be seen patches of atrophied choroid with irregular deposits of pigment, and occasionally also a partial detachment of the retina.

The Prognosis and Treatment.—The prognosis of atrophy of the optic nerve is very unfavourable. The only hope is, that if there is any sight remaining, it may be still retained. Our first effort must be to ascertain the cause of the atrophy, and then by appropriate remedies to arrest the progress of the disease. The treatment of the various affections which may cause atrophy of the retina and optic nerve will be found under their respective headings.

For the white atrophy of the optic nerve which proceeds from cerebral disease the subcutaneous injection of strychnine has been recommended, in doses commencing at gr. $\frac{1}{60}$ and increased daily by gr. $\frac{1}{60}$ until the quantity injected reaches gr. $\frac{1}{20}$. It is very doubtful whether this treatment does any good, and it is certainly not free from danger. I know of one case in which violent convulsions followed the injection of $\frac{1}{30}$ of a grain of strychnia, although the patient had previously on several occasions,

at intervals of two or three days, had the same dose administered.

In some cases the use of the constant current of electricity seems to do good. The sponges having been moistened with salt and water, one is to be placed over the closed eyelids of one eye, and the other sponge either at the nape of the neck, or at the back of the ear over the mastoid region, or on the forehead over the supra-orbital nerve, according to the selection of the patient. The point selected is the one which most readily yields flashes or balls of light with the fewest cells. At first, only from three to five cells should be used, but these may be increased to sixteen or eighteen if they can be borne without inconvenience. The position of the positive and negative poles may be changed two or three times during each sitting, which should not last longer than from ten to fifteen minutes daily.

ATROPHY OF THE OPTIC NERVE FROM TOBACCO.—The theory that tobacco in excess will produce a peculiar form of white atrophy of the optic nerve, has received the sanction of the late Drs. Mackenzie and Critchett, and of Messrs. Wordsworth, Hutchinson, and others. My own experience at the Royal London Ophthalmic Hospital, however, leads me to dissent from this doctrine, as I do not remember ever having seen a case in which the loss of sight could be fairly attributed to tobacco *only*. There was always, in addition to the immoderate smoking, some other excess, such as intemperance, dissipation, or an undue mental strain with loss of rest. I have also met with a similar condition of progressive optic atrophy in women who drank spirits largely. The rapid improvement of sight which followed the giving up of the spirits, could leave no doubt but that alcohol was the cause of the nerve atrophy. In these cases there was no tobacco element in the production of the atrophy.

AMAUROSIS AND AMBLYOPIA.

AMAUROSIS.—It is best to restrict this term to those cases of impaired vision and blindness which are due to cerebral or cerebro-spinal causes. Before the discovery of the ophthalmoscope, amaurosis was the generic name of a group of obscure diseases originating either within

or beyond the eye, and characterized by a gradual failure of sight usually terminating in blindness. With increased facility for diagnosis, most of these affections have now been traced to their right source, and have received their own proper name and place in the list of ophthalmic diseases. There still, however, remain a large number of cases, marked by a progressive diminution of sight, dependent on changes in the brain or spinal cord, the exact nature of which we are unable to estimate during life, and which from a want of more precise knowledge may be conveniently classed under the heading of amaurosis.

Although the cause of the blindness is at a distance from the eye, yet secondary changes soon take place in the optic papilla which enable the disease to be recognised by the ophthalmoscope, and its probable progress foretold.

For many useful suggestions in the diagnosis and prognosis of amaurotic affections, I am indebted to the valuable Paper on "Amblyopia and Amaurosis," by the late Von Graefe.*

In the examination of patients suspected to be suffering from amaurosis, we should ascertain—

1. The history of the case.
2. The state of the field, and the acuteness of vision.
3. The condition of the optic papilla.

1. **The History of the Case** always affords important information both as to the diagnosis and prognosis of the disease. By it we determine whether the loss of sight was sudden or gradual; whether it was preceded by head symptoms, or by functional disturbances of other organs, as the kidneys, the liver, or the uterus; or whether there had been any previous constitutional disease, such as gout, rheumatism, or syphilis.

The duration of the impairment of sight is also an important element in forming a prognosis; thus, if the defective vision has been for some months stationary, and all evidence of the disease to which it was apparently due has passed away, a favourable opinion would be given, whereas, if the loss of sight be recent, and there are persistent head symptoms, we should conclude that

* Translated by Mr. J. Zachariah Laurence, from Zehender's *Klin. Monatsbl. für Augenheilkunde*, 1865, p. 129: *Ophthalmic Review*, No. 7, p. 232.

the amaurosis is progressive, and will probably terminate in blindness.

2. **The State of the Field and the Acuteness of Vision.**—The condition of the visual field should be carefully tested by one of the methods described at page 235, so that any imperfection either as regards its periphery or its continuity of surface may be accurately noted, as, according to Von Graefe, the state of the field forms a good basis on which to ground a prognosis. In all cases of amaurosis, the acuteness of central sight should be ascertained and compared with the defects and extent of the field of vision. The following variations may be noticed:—

a. With **diminished** acuity of central vision the field may be entire in its periphery and continuous throughout its area, whilst the visual power is reduced in all directions. Such cases are usually stationary, and so far a hopeful prognosis may be given.

β. With **diminished** acuity of central vision the field may be contracted in one or more directions, or broken by blind patches (scotomata), whilst the visual power throughout the rest of its extent is greatly lowered. With these symptoms the disease may be considered progressive, and the prognosis is blindness.

γ. There may be **complete** loss of central vision, but either with or without impairment of the rest of the field. If with complete loss of central vision the periphery and continuity of the field are good, there is reason to hope that the disease may be stationary, although there is but a slight prospect of recovering the central vision which has been lost. The prognosis is therefore favourable, as the probability is that the patient will not go blind. If, however, in addition to the central scotoma, there are other blind patches in the field, or the periphery is much contracted, so that the eccentric vision is greatly reduced, then the prognosis is most unfavourable, and blindness may be predicted. It must, however, be remembered that the prognosis of this form of central amaurosis does not apply to a similar state of blindness which may be produced by retinal hæmorrhage, or some other disease *within* the eye, the seat of which can be accurately determined by the ophthalmoscope.

δ. There may be **Hemiopia** or complete loss of half the field of vision, in many cases distinctly marked as if by a vertical line, on one side of which all is clear, whilst on

the other all is dark. There are **two** forms of hemiopia to be noticed, the *first*, called **homonymous** from the corresponding halves of the two retinae being affected; thus, the *outer* half in one eye, and the *inner* half in the other may be jointly paralysed, or the reverse. In the *second* form, the **temporal**, which is extremely rare, the *inner* halves of the retinae of the two eyes are blind, but the hemiopia is more diffuse, and the limitation is seldom abruptly marked as in the former.

To understand the distinction between these two classes of hemiopia, it is necessary to refer briefly to the anatomy of the optic tract, commissure, and nerve. The central fibres of each optic tract decussate in the commissure, and are connected with the optic nerve of the opposite side, and supply the *inner* halves of the retinae; whilst the outer fibres of each tract go to the optic nerve of the same side, and supply the *outer* halves of the retinae. Each eye thus receives nerve fibres from both optic tracts, the *outer* half of the retina being provided with filaments from the optic tract of its own side, whilst the *inner* half is furnished from the tract of the opposite side. Hence it is that a clot of blood, or a tumour pressing on the optic tract only of one side—say, the right—will produce paralysis of the outer half of the retina of the right eye, and of the inner half of the retina of the left; the left half of the field of vision of each eye will therefore be blind. If, however, the commissure is the part affected, and only the decussating fibres are involved, there will be paralysis of the inner half of each retina, and the temporal half of the field of vision of each eye will be blind. In testing the field of vision, the student must not forget that the right half of the field corresponds to the left half of the retina, and *vice versa*.

In hemiopia there is usually no neuritis, nor atrophy of the optic disc. In cases of persistent hemiopia, some writers have observed that after the lapse of years there has been a distinct pallor of a portion of the disc.

Hemiopia is often associated with hemiplegia, and Dr. Hughlings Jackson says that in cases of homonymous hemiopia with hemiplegia, "the patient cannot see to his paralysed side."

The prognosis of hemiopia must depend very much on the cause which has produced it. If the half-blindness originated from the pressure of some syphilitic effusion on the optic tract the sight may be regained; or if it be

from the presence of a blood clot, there is reason to hope that even if the vision should not be restored, the defect may remain stationary; but if a cerebral tumour be suspected, the prognosis is most unfavourable.

3. **The Condition of the Optic Papilla** in cases of advanced amaurosis is that of white atrophy, as described at page 219.

The Symptoms which are associated with amaurosis are very variable. In one class of cases there is no pain in the eye or head, and no constitutional disturbance, the only symptom being a gradual fading away of sight.

In another class the blindness is preceded by acute head symptoms, which may last for several days or longer, and then either cease altogether, or greatly diminish. With the cessation or diminution of the pain in the head, the first indications of failing sight are noticed. The patient may regain his health and the full enjoyment of all his mental and physical powers, but his sight steadily fades, until he is in absolute darkness. The loss of vision in these cases is no doubt due to some organic changes in the brain produced during the acute inflammatory attack when the pain in the head was severe. The cause was transitory, but its effects are permanent.

In a third class the pain in the head is continuous; the patient is never free from suffering. Intense headache is the first symptom of the disease, and it precedes the loss of sight. Although at times its severity is lessened, it is never absent. I have had such patients tell me that they would not mind being blind if they could only be free from pain. These are the most distressing of the amaurotic cases; we can do nothing for the *absolute blindness* and but little for the *constant pain*, as the preparations of opium are seldom tolerated.

Amaurosis may be associated with epilepsy, hemiplegia, and locomotor ataxy. It may also occur with paraplegia. Dr. Hughlings Jackson says: "Dr. Brown-Séquard has frequently drawn my attention to cases of paraplegia in which amaurosis has also existed without any other symptoms to suggest disease within the cranium." "The blindness he believes is the result of eccentric irritation. Dr. Wilks also has observed several such cases."*

* On Defects of Sight in Brain Disease: Royal London Ophthalmic Hospital Reports, vol. iv. p. 17.

State of the Pupil.—See ATROPHY OF OPTIC NERVE, page 219.

The Causes of Amaurosis may be chiefly classed under the following headings:—

1. **From Disease of the Cerebrum.**—Amaurosis usually affects *both* eyes; they may be attacked simultaneously, or the blindness may be more advanced in one than the other, but as a rule both are ultimately involved. This can be reasonably anticipated by remembering how intimately the two optic nerves are associated within the brain by commissural fibres. Dr. Hughlings Jackson remarks: “The kind of amaurosis which we most frequently find with disease of the central nervous system is, in my experience, invariably double, although one eye may suffer before the other. I do not say that blindness of one eye does not occur *with other symptoms* of disease of the nervous system, but that it does not occur from disease of the brain-mass.”* Tumours of the brain, cerebral hæmorrhage, softening of the brain, hydrocephalus, meningitis, syphilitic deposits, and embolism, may all be productive of amaurosis.

2. **From Disease of the Cerebellum.**—In some remarks which Dr. Hughlings Jackson kindly gave me on amaurosis from this cause, he says, it has been long known that blindness may coexist with disease of the cerebellum, but it is by no means clear that the blindness depends on the want of that part of the cerebellum which the disease destroys. For as the loss of sight occurs only when the disease is “coarse,” such as from tumours, blood clot, &c., he believes that it is induced by the irritation of the foreign body lying in the brain, and not from the destruction of any centre connected with sight. As a consequence of this irritation the optic nerves become inflamed, and the ultimate loss of sight is due to this cause.

3. **From Disease of the Spinal Cord.**—Amaurosis may occur with paraplegia, and it is frequently met with in locomotor ataxy, and especially when the disease is in an advanced stage. The blindness is usually confined to one eye. Dr. Trousseau† says, “Both eyes may be

* On Defects of Sight in Diseases of the Nervous System: Royal London Ophthalmic Hospital Reports, vol. iv. p. 390.

† Trousseau's Clinical Medicine. Translated by the Sydenham Society vol. i. p. 156.

affected, although this rarely happens." The pupil in spinal amaurosis is frequently contracted, and this is generally the case when the part of the cord affected is in the cervical region.

4. **From Uterine Derangements.**—A very acute form of amaurosis, which will run its course to blindness in a few days or weeks, is occasionally produced by a sudden suppression of the menses. It is usually accompanied by intense headache, with vomiting or a feeling of nausea. In one case which I published,* so rapid was the loss of sight, that in fifteen days from the first symptoms the patient retained but little more than a mere perception of light with either eye. Examined with the ophthalmoscope, the retinal circulation was seen to be interrupted; the return flow of blood was impeded. Although the symptoms were those of pressure on some part of the cerebrum, yet whether the pressure was caused by distension of the vessels, or by an effusion of blood, lymph, or serum, could only be conjectured. Under the influence of 10 gr. doses of the iodide of potassium the functions of the uterus were restored at the next monthly period, and the patient began gradually to recover her sight. In three months she was able with one eye to read No. 1, and with the other No. 10 of Jaeger's test types. The Report concludes by stating that the improvement was still progressing. Amenorrhœa, or irregular and scanty menstruation, may also cause amaurosis; but the symptoms are more chronic than when induced by an acute suppression. (See TREATMENT OF NEURO-RETINITIS, page 217.)

In some obscure manner amaurosis is occasionally connected with pregnancy. A remarkable instance of this form of blindness came under my care at the Ophthalmic Hospital, and will be found related in our Reports.† The amaurosis was recurrent; it commenced during the gestation of the eighth child, and recurred in each succeeding pregnancy. After the birth of her eighth child the patient regained sufficient sight to read No. 10 of Jaeger, and to do needlework; but after the ninth child her recovery was less complete, and in the sixth month of her tenth pregnancy she had become blind with one eye, and could only count fingers with the other.

* *Medical Times and Gazette*, August 1, 1863.

† Royal London Ophthalmic Hospital Reports, vol. iv. p. 65.

5. **From Loss of Blood.**—Amaurosis may occur from a large and rapid loss of blood. I have known it come on suddenly from extensive flooding during parturition, and the blindness has been permanent. Cases have also been reported in which it has followed vomiting of blood. The loss of sight may be immediate, or it may be gradual.

6. **From Reflex Irritation.**—Amaurosis may be induced from injury or disease involving branches of the fifth nerve, at a distance from the eye. Several instances have been quoted by Mr. Hutchinson* which illustrate, as he says, “more or less directly, the influence of the sensitive nerves of the face upon the functions or nutrition of the eyeball.” In some cases the blindness is preceded by intense neuralgia, whilst in others there has been a loss of sensibility on one side of the face. A very interesting case of amaurosis of one eye, consequent on acute abscess of the antrum, produced by a carious tooth, has been recorded by Mr. James Salter.† The loss of sight was permanent.

Monocular Amaurosis may arise from any cause which induces pressure on the optic nerve of one eye only, such as a tumour or some syphilitic exudation, either just within, or immediately external to, the orbit; or it may be produced by embolism, or by disease of the spinal cord.

For the Treatment of Amaurosis no definite course can be laid down; the blindness is secondary to so many diseases. The cause of the defective sight must be sought for by a careful examination into the history and the accompanying symptoms. The most hopeful cases are those which are acute and dependent on some sudden arrest of the function of one of the internal organs, or upon previous syphilitic disease, and where sufficient time has not elapsed for any organic changes to have taken place, either from the pressure of inflammatory exudations, or from atrophy.

AMBLYOPIA (*ἀμβλῦς*, *dull*, *ἄψ*, *the eye*) has the same signification as amaurosis (*ἀμαυρόω*, *to render obscure*), the former meaning dull vision, the latter obscure. These synonymous terms have created great confusion, as they

* Royal London Ophthalmic Hospital Reports, vol. iv. p. 120.

† Medico-Chirurgical Transactions, vol. xlv.

have not only been applied indifferently, but lately they have been used in combination; thus a form of blindness has been described under the title of "Amaurotic Amblyopia." It would be well to restrict the name Amblyopia to those impairments of sight which are apparently due to imperfect perception from defective innervation, or to a loss of the nervous sensibility of one eye from disuse. In this sense the word has been applied by many to denote the dull sight which is so frequently found in one eye in cases of strabismus, where no structural change can be detected by the ophthalmoscope to account for the loss of power. The term amblyopia may be also rightly used to designate the dimmed vision brought on either by the retina being over-wrought, or by its being rendered dull and unimpressible from drink and debauchery.

NYCTALOPIA*—*Night-Blindness* (ὁ τῆς νυκτός ἀλαός—Galen)—is a defect of sight varying in degree from dimness to almost complete darkness after the sun has gone down. It is most frequently met with amongst sailors, soldiers, and others who have been much in the Tropics. It is due to a blunted sensibility of the retina, which fails to appreciate fully the impressions which are produced by a dim light. Night-blindness is frequently met with in retinal affections, and especially in retinitis pigmentosa; but the nyctalopia to which I now refer is a functional disease, and quite independent of any structural change.

Mr. Arthur Benson (Dublin) has noticed a peculiar form of Xerosis of the conjunctiva as occurring very frequently in Epidemic Nyctalopia. It is characterized by a white, frothy-looking patch of variable size on the conjunctiva at each side of the cornea, in that part most constantly uncovered by the lids. It can be easily removed, but reforms rapidly. The patch itself, and the conjunctiva under it, has an oily look, so that the tears form in droplets upon it as on a greasy surface. Under the microscope it is found to consist of degenerated epithelial scales with some oily matter, and a vast quantity of micro-organisms, bacilli and micrococci—(Leber). There is, as a rule, but little increased vascularity of the conjunctiva, and cure generally results in from one to

* See Papers on Nyctalopia and Hemaralopia, by Dr. W. A. Greenhill, Royal London Ophthalmic Hospital Reports, vol. x. p. 284, and by Mr. John Tweedy, *Ibid.* p. 413.

three months. The connection between Conjunctivitis Xerosa and Nyctalopia is not constant, but very frequent. Both seem to occur when the vital energies are below par. The epidemics noted by Mr. Benson all occurred in spring and early summer, and in charity schools; those children being invariably attacked who had some other ailment or delicacy in addition.

Causes.—Although the constant exposure to strong glare exercises a certain influence in producing night-blindness, yet the predisposition to it is given by an impaired and debilitated state of health. In this opinion all who have had much experience of this affection seem to be agreed. During the Crimean War nyctalopia was frequent both amongst the soldiers and sailors, and the evidence of the medical officers coincided in attributing it to either scurvy or debility from exposure and privation.* In a Paper by Dr. Alexander Bryson, "On Night-Blindness in Connection with Scurvy,"† he says that "it most unquestionably occurs much more frequently in scurvy than is generally supposed; but in consequence of the simultaneous existence of some more serious symptoms of a less ambiguous character, it frequently passes unnoticed." He then adduces some forcible examples of nyctalopia occurring with scurvy amongst ships' crews, all of which were successfully treated by giving the eyes rest, and curing the scorbutic symptoms by a proper diet of fresh meat and vegetables; and he concludes by expressing his opinion that the disease is "entirely dependent on an improper or erroneous diet."

Nyctalopia has also been attributed to ague, or to some other form of marsh fever. My own experience, however, of the disease is, that it is peculiarly liable to attack patients whose eyes have been long subjected to excessive glare, and whose constitutions have been debilitated either from scurvy, ague, or from a diet deficient both in quantity and in quality.

Examined with the Ophthalmoscope no change can be detected in the choroid, retina, or optic nerve, to account for the impairment of function.

Treatment.—If there is any evidence of scurvy an anti-scorbutic diet should be prescribed, with two or three

* Royal London Ophthalmic Hospital Reports, vol. ii. p. 35.

† *Ibid.* p. 40.

oranges, or the juice of one or two lemons daily. The citrate of potash, gr. 20, may be also given in water twice or three times a day, and if there is anæmia, the citrate of ammonia and iron combined with citric acid (F. 82) may be ordered.

If ague or remittent fever can be traced as a possible cause of the disease, quinine should be freely given, and continued for at least six or eight weeks. The eyes should be rested, and all exposure to glare or strong light avoided. I have tried keeping the patient in absolute darkness for a week at a time; but the relief was not sufficient to compensate for so long an exclusion from light. Blisters to the temples and behind the ears are perfectly useless; they only serve to irritate the patient, and do no good.

SNOW-BLINDNESS is a temporary loss of sight from the dazzling caused by brilliant whiteness. A similar condition is produced by the excessive glare of artificial light. I have had patients from the light-ships around the coast who have complained that, after trimming the lamps at night, they have been for some minutes absolutely blinded, and that they have not completely recovered from the paralysing effects of the intense glare for some hours.

The Treatment consists in wearing dark neutral-tint glasses to diminish the intensity of the light.

COLOUR - BLINDNESS — *Chromo-pseudopsis* — *Dichromic Vision*—is a defect of sight by which the power of appreciating certain colours is either diminished or lost. The importance of detecting colour-blindness in railway employés, signal-men, and sailors employed in look-out duty is now recognised, and no doubt many future dangers may be averted by using only those who have good colour-sight.

Colour-blindness is more frequent in males than in females.

Professor Donders of Utrecht found amongst 2,300 railroad employés that 152, or 6.60 per cent., were colour-blind.

Professor Holmgren of Sweden found amongst 32,165 males that 1019, or 3.25 per cent., were colour-blind.

Dr. Cohn found amongst 2,429 school-boys of Breslau, 95, or 4 per cent., colour-blind.

Dr. Magnus found amongst 3,273 school-boys of Breslau 3·5 per cent. colour-blind.

Dr. Joy Jeffries of Boston found amongst 10,387 that 431, or 4·149 per cent., were colour-blind.

The testimony of all who have worked at the subject is unanimous that colour-blindness is very infrequent amongst females.

Professor Holmgren of Sweden, out of 3,244 school-girls found only 9, or ·27 per cent., and out of 1,826 factory-girls only 3, or ·16 per cent., of colour-blindness.

Dr. Magnus of Breslau, out of 2,216 girls, only 1, or ·04 per cent., of colour-blindness.

Dr. Joy Jeffries of Boston, out of 7,942 girls, found only 4, or ·052 per cent., colour-blind.

The late Professor Clerk Maxwell, Dr. Thomas Young, and others have shown that for the normal eye there are three, and only three, elements of colour, and that in the colour-blind one of these is absent. These colour perceptions are generally considered to be red, green, and violet (blue, according to Maxwell). The other colours with which we are familiar are produced by combinations in varying proportions of two or more of the three elementary colours. If one of the elementary perceptions be wanting, the patient will be colour-blind so far as that particular colour is concerned, and in looking at a compound colour he will fail to see in it the special colour for which he has no perception.

Professor Pole, who was red blind, in narrating his own experiences of his own sight, says: "A soldier's red coat or a stick of red sealing-wax conveys to me a very positive sensation of colour, by which I am able to identify, in a great number of instances, bodies of this hue. If, therefore, the investigation of my experience ended here, there would be no reason to consider me blind to red. But when I examine more closely what I do see, I am obliged to come to the conclusion that the sensation I perceive is not one that I can identify separately, but is simply a modification of one of my other sensations. It is, in fact, a yellow shaded with black or grey, a darkened yellow, or what I may call yellow-brown. I find that all the most common hues of red correspond to this description; and in proportion as they are more scarlet or more tending towards orange, the yellow I see is more vivid. The explanation I suppose is, that none of such reds are pure—they are combinations of red with yellow;

so that I see the yellow element of the combination, while the true red element of the combination is invisible to me as a colour, and acts only as a darkening shade."

Colour-blindness may be divided into three classes:—

1. **When there is a Deficiency in the Power of Perception of all Colours.** The bright and full colours may be recognised, but the gradation of shades are not appreciated. This may arise from want of education in colours, or it may be due to an inability of the eye to perceive shades of colour as the ear may be incapable of distinguishing gradations of sound. In such cases, training the eyes with sorting and matching coloured worsteds may do good, but it is very doubtful.

The inability to distinguish shades of colour may be congenital, but it may also be induced from over-use, or the constant strain of the eyes in looking at colours. I had a patient under my care at the hospital who had been engaged for many years in a colour warehouse, and whose chief business consisted in sorting and matching colours. For this duty he had acquired a special reputation amongst his fellows. Gradually, however, his powers began to fail him, and when he applied to the hospital for relief, he could only distinguish whole colours, and had lost the faculty of discriminating shades of tint.

2. **When there is a Deficiency in the Power of Perception of particular Colours as Red and Green.** In these cases one of the three elementary colour perceptions is wanting. The patient possesses only dichromic vision and is colour-blind. There are three varieties of this form of colour-blindness named according to the perception which is wanting:

Red-blindness.

Green-blindness.

Violet-blindness.

The red-blindness is by far the most frequent; next comes the green-blindness; whilst violet-blindness is so rare that practically it may be disregarded.

3. **Achromatic Vision**, or the want of power to recognise any colour, everything appearing as either white, black, or grey.

This defect is rare, and is, I believe generally produced by disease. Dr. J. J. Chisholm, of Charleston, S.C. (U.S.A.), has related a case of optic neuritis in which the patient's vision was for a time achromatic. "The

restoration to chromatic vision showed itself," he says, "in a slowly growing perception of blue shades. After some months the shades of yellow could be perceived. Reds cannot yet be detected. All shades of red appear brown."*

Dr. Argyll Robertson has also published a case of spinal disease, in which myosis and colour-blindness existed. The patient lost all perception of colours, although previous to his illness he used to distinguish them readily.†

The best method for examining for defects in colour-sight is by the use of Holmgren's coloured wools. They consist of a collection of small skeins of coloured Berlin wools, each of which is loosely twisted up. In this bundle is included wools of red, orange, yellow, yellow-green, pure-green, blue-green, blue, violet, purple, pink, brown, grey, several shades of each colour, and at least five gradations of each tint from the deepest to the lightest.

These worsteds being placed in a pile on the table, the examiner lays aside a skein of the especial colour desired for the examination. He then requires the patient to select from the wools other skeins which most closely resemble the colour of the sample and to place them by its side. The colour-sight of the patient is decided by the manner in which he performs this task.

TEST 1. Select as the sample skein the palest (lightest) shade of very pure green, which is neither a yellow-green nor a blue-green to the normal eye, but fairly intermediate between the two. (See No. I. in Holmgren's coloured plate facing the title-page.)

If the patient makes mistakes, and matches the sample with light shades of grey, brown, or other light dissimilar colours, he is colour-blind (1—5).

The next test is to ascertain the form of colour-blindness.

TEST 2. A red mauve skein,‡ No. IIa., is chosen for the

* Royal London Ophthalmic Hospital Reports, vol. vi. p. 214.

† Eye Symptoms in Spinal Disease. Oliver and Boyd, Edinburgh. 1869.

‡ This colour is described by Professor Holmgren as purple, "purpur (rosa)," and as containing in tolerably equal proportions the colours of red and violet, which is Holmgren's reason for choosing it as a test. Holmgren "Om Färgblindheten," p. 141.

sample. The colour should be midway between the darkest and the lightest shade. If the patient matches it with blue or violet, 6, 7, or one of them, he is *red blind*.

If he matches the red mauve with green or grey, 8, 9, or one of them, he is *green blind*.

TEST 3 is a confirmatory test and specially useful in examining the colour-sight of those employed in reading signals. Select a vivid red skein, like the red flag used for signals on railways, a bright yellowish-red, a scarlet, No. IIb. The red-blind will match the sample with a dark green or dark brown, 10, 11, with shades which to the normal eye are darker than the scarlet. The green-blind will select light green or light brown, 12, 13, to match the scarlet, shades which are lighter than the sample.*

PERIMETRY.—An estimate of the state of the whole field of vision is an essential aid in the diagnosis, prognosis and treatment of many eye diseases:—thus the loss of a portion of the field would at once suggest detached retina, retinal hæmorrhage, or intraocular tumour, and would lead to a further examination of the eye:—in amaurotic affections the prognosis is mainly determined by the condition of the field—see page 223:—and in cases of chronic, or intermittent glaucoma a progressive contraction of the periphery of the field of vision would indicate that an operation for the relief of tension should not be delayed.

The points to be noted in taking the field of vision are:—

1. The peripheral vision; if it be contracted, and if the contraction be uniform in all directions.
2. If, in addition to the peripheral contraction, there be blind spots or scotomata in portions of the field.
3. If there be loss of central vision, and if with this central loss there be other impairments of the field.
4. If, without loss of peripheral vision, the continuity of the field be broken by blind spots or scotomata.
5. To note the limits of the field of vision for the different colour perceptions. The loss of the red and green are the most frequent.

In taking the field of vision, it must be remembered

* In this Article on Colour-Blindness, the author specially consulted the writings of Professor Pole, Professor Holmgren, of Sweden, and Dr. Joy Jeffries, of Boston, U.S.A.

that the upper and inner portions of the field are often limited by an overhanging brow and a deep bridge to the nose. The fallacy thus occasioned may be obviated by throwing the patient's head to the left when examining the right eye, and *vice versa*.

The variations of the field of vision in amaurotic cases, and their value in forming a prognosis is given at page 223. It is taken from the late Von Graefe's valuable paper on "Amblyopia and Amaurosis."

To ascertain and map out correctly the field of vision a perimeter should be used. The best are McHardy's self-registering perimeter; Priestley Smith's and Berry's.

When no perimeter is at hand the following ready method may be adopted for ascertaining the state of the field of vision:—

The patient should be placed about one and a half feet in front of the surgeon, and having closed his sound eye with his hand, he should be told to look steadily with the affected one at the nose or the eye of the examiner. Whilst the eye is thus fixed, the surgeon should keep one or both of his hands moving gently along the line of the circumference of an imaginary circle which about corresponds with the normal field of vision, carefully noting those points at which the patient says the hand becomes either indistinct or lost. If the patient should be unable to distinguish the movements of the hand at one and a half feet, it may be approximated to the eye, and a smaller circle be described; the parts at which the sight is the most defective or wanting being still accurately observed.

To Map out the Field of Vision without the Aid of a Perimeter, the patient should be directed to stand in front of a black diagram board, placed at twelve inches distance from him. Covering with his hand the eye which is not under examination, he should fix the other on a small white cross which has been drawn in the centre of the board and on a level with his eyes. Whilst his eye is thus fixed by steadily looking on the cross, a small white disc at the end of a piece of wire is to be moved in different directions over the board, and at whatever spot it is *clearly* seen, a + is to be made; when only dimly recognized, a —; and when not visible, an 0. Each series of symbols are now to be connected with lines, and a map will be thus drawn, which will fairly represent the patient's field of vision.

To facilitate the copying and reduction of such a diagram the board should be ruled in three-inch squares, when the drawing can be easily transferred to properly ruled paper.

TUMOURS OF THE OPTIC NERVE are rare.

The late Von Graefe related a case of tumour of the optic nerve, behind the globe, in which the eye was protruded about 9"', and the sight was lost. A microscopic examination showed the tumour to be a myxoma of the optic nerve.*

Mr. Hulke has recorded a case of tumour of the optic nerve in which there was extreme proptosis of the eye, and the vision was reduced to quantitative perception of light.

He removed the eyeball and tumour together, the optic nerve being severed close to the optic foramen. "The tumour was firm, of a spherical outline, in size about one-third less than that of the eyeball, from which it was separated by a portion of seemingly healthy optic nerve, somewhat more than half an inch long." The tumour was examined by Dr. Brailey, who states in his report: "The new growth appears to be a sarcoma, taking its rise in the loose tissue of the intervaginal space, most probably from the nucleated cells found upon its fibres."†

In my own practice I have only met with two cases of retro-ocular tumours of the optic nerve.

The first case‡ was in a man æt. sixty-five. The eye was bulged forwards considerably, and was irremovably fixed in the orbit. I first excised the globe, and then removed a solid tumour which occupied the orbit and completely surrounded the optic nerve. Dr. Brailey, the curator of the Museum, made a section of the globe, and a microscopical examination of the tumour. He stated the parts within the eye were normal, except the optic disc, which was greatly swollen from the pressure of the tumour in the orbit.

The growth was a round-celled sarcoma, and apparently

* Archiv f. Ophthal. x. 1. 194.

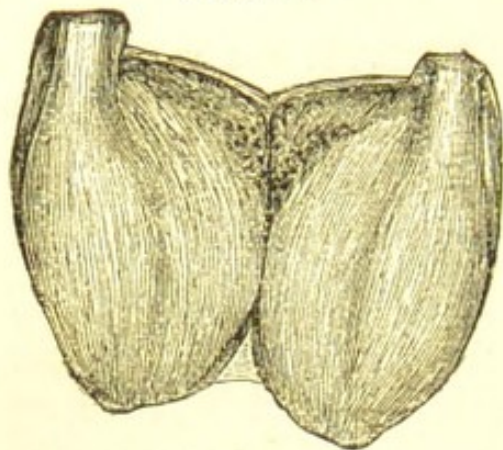
† Royal London Ophthalmic Hospital Reports, vol. x. p. 293.

‡ Ibid. vol. x. p. 296.

originated from the external layers of the dural sheath of the optic nerve.

The second case of tumour of the optic nerve which was

FIG. 50.



Tumour of the optic nerve, resembling a neuroma. The woodcut shows the tumour divided vertically. The upper portion shows the optic nerve where it had been severed from the globe.

under my care was in a girl about seventeen years of age. There was excessive bulging of the eye directly forwards, so that the lids could not close completely over it, and the eye was blind. I removed the eye and the tumour. There was no disease within the eye. The tumour was confined to the optic nerve behind the eye. It was the size represented in Fig. 50, which exactly shows the appearance it presented after it had been divided by a vertical section.

Mr. Milles, the curator of the Museum, examined the growth. He found that the tumour consisted chiefly of fibrous tissue; in places the bundles of fibres were separated, and in the spaces left by the separation there were here and there groups of small round cells. The sections under examination do not show any evidence of nerve-fibres.

INJURIES OF THE OPTIC NERVE.—The optic nerve may be wounded behind the eye, without any injury to its external coats, by the passage of foreign bodies into the orbit, or by stabs into the orbit by some sharp-pointed instrument.

Symptoms.—Sudden loss of sight, the loss being appreciated by the patient immediately on receiving the wound. More or less dilatation of the pupil, which is uninfluenced by light, and no apparent injury to the eye to account for the sudden deprivation of sight. Examined with the ophthalmoscope, there is at first no appreciable change in the appearance of the optic disc, except perhaps it may appear slightly more pink than the nerve in the other eye, but this increased vascularity is very soon followed by pallor, and ultimately the disc becomes quite white, with the arteries small, and pre-

sents all the usual appearances of white atrophy (page 219).

The following case, illustrative of this rather rare accident, was under my care :—

A young man, aged twenty-seven, was engaged in a street fight, when his opponent struck at his head with a clasp-knife. The blade penetrated the rim of the wide-awake hat he was wearing, passed through the upper eyelid, close to the upper edge of the orbit, and onwards to the optic nerve, which it wounded, but without touching the globe. The man declared that he was instantly blinded. He was positive that he could see well with the eye before he received the wound, and on being struck was immediately aware of the loss of sight.

On admission, the pupil was slightly dilated and uninfluenced by light. The globe was uninjured, but on the upper eyelid there was a recent scar indicating the site at which the knife penetrated the orbit, and this scar corresponded to the cut in the rim of the hat through which the knife first passed. The eye was quite blind; it had not even perception of ophthalmoscopic light. Examined with the ophthalmoscope, the optic nerve presented the appearance of commencing atrophy. The optic disc was whiter than that of the other eye, and the arteries were small and thready. The humours of the eye were perfectly clear.

The man has since been several times at the hospital, and when last seen, about three months after the accident, the optic disc had assumed the milky white and flattened appearance of confirmed atrophy.*

Treatment.—No applications nor medicines will restore the wounded optic nerve. The sight which is lost is irreparably gone; but attention must be directed to the wound, and if a foreign body be detected in the orbit, it should be removed. See Article, "Foreign Bodies in the Orbit."

OPAQUE OPTIC NERVE FIBRES.—This congenital anomaly is recognised by the ophthalmoscope as a white patch extending from the optic nerve and terminating in feathery striæ in the retina. In the normal condition the nerve tubes of the optic nerve lose their medullary sheath at and in their passage through the *fascia cribrosa*, but it occasionally happens that in one or more bundles of the optic nerve fibres the white medullary sheath is prolonged on them for some distance into the retina. This congenital peculiarity does not affect the sight. It is, however, generally only detected when the eye is being

* Lancet, Jan. 2, 1875.

examined by the ophthalmoscope for some defect of sight, and is therefore occasionally mistaken for an inflammatory exudation.

THE OPHTHALMOSCOPE.

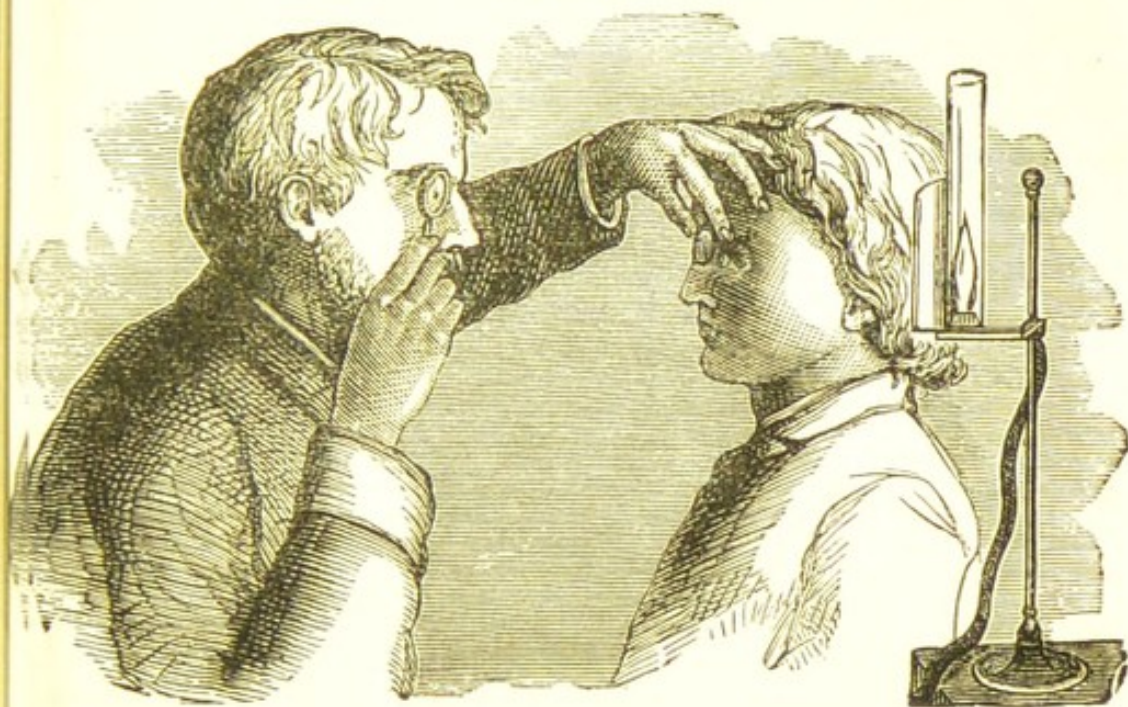OPHTHALMOSCOPES may be divided into two classes, the portable and the fixed. There are a great variety of portable or hand ophthalmoscopes, for each of which the inventor claims certain advantages. The following are a few of the many excellent instruments now in use: Couper's magazine ophthalmoscope, Fox's, Purves's modified by Lang, Loring's, and Landolt's.

FIXED OPHTHALMOSCOPES are too large and heavy to be of much service except for demonstration, or for artistic purposes. When once adjusted to the patient's eye a number of students can look through the instrument in succession; or a sketch of the fundus can be readily taken, as the eye is kept under observation whilst both hands of the surgeon are free for drawing. The best of the fixed ophthalmoscopes is Brudenell Carter's, made by Mr. Hawksley, of 357, Oxford Street.

HOW TO WORK WITH THE OPHTHALMOSCOPE.—To completely explore the whole fundus of the eye, and to ascertain the state of the lens and the vitreous, the pupil should be widely dilated with atropine; but where the desired information can be obtained without such a thorough investigation, it will be unnecessary and undesirable to submit the patient to this annoyance. The examination must be conducted in a darkened room, and with a lamp provided with a bright, steady flame. The most convenient light is a small gas-lamp at the end of a movable arm, which can be turned in all directions, and raised or lowered as may be required. The burner should be a porcelain argand, protected with a piece of wire gauze below to regulate the draught. The chimney should be a tube of plain white glass, of a uniform diameter throughout its length. When gas cannot be obtained, a moderator or a reading-lamp without the shade will answer almost as well. With all ophthalmoscopes, except the binocular, it will be found most convenient to place the lamp on the left-hand side of the patient, and with the flame on a level with, and a little behind the eyes to be examined.

To use a monocular hand ophthalmoscope, the observer sits or stands in front of the patient, so that his eyes are a little above the level of those under examination, and at about eighteen or twenty inches distance from them.

FIG. 51.



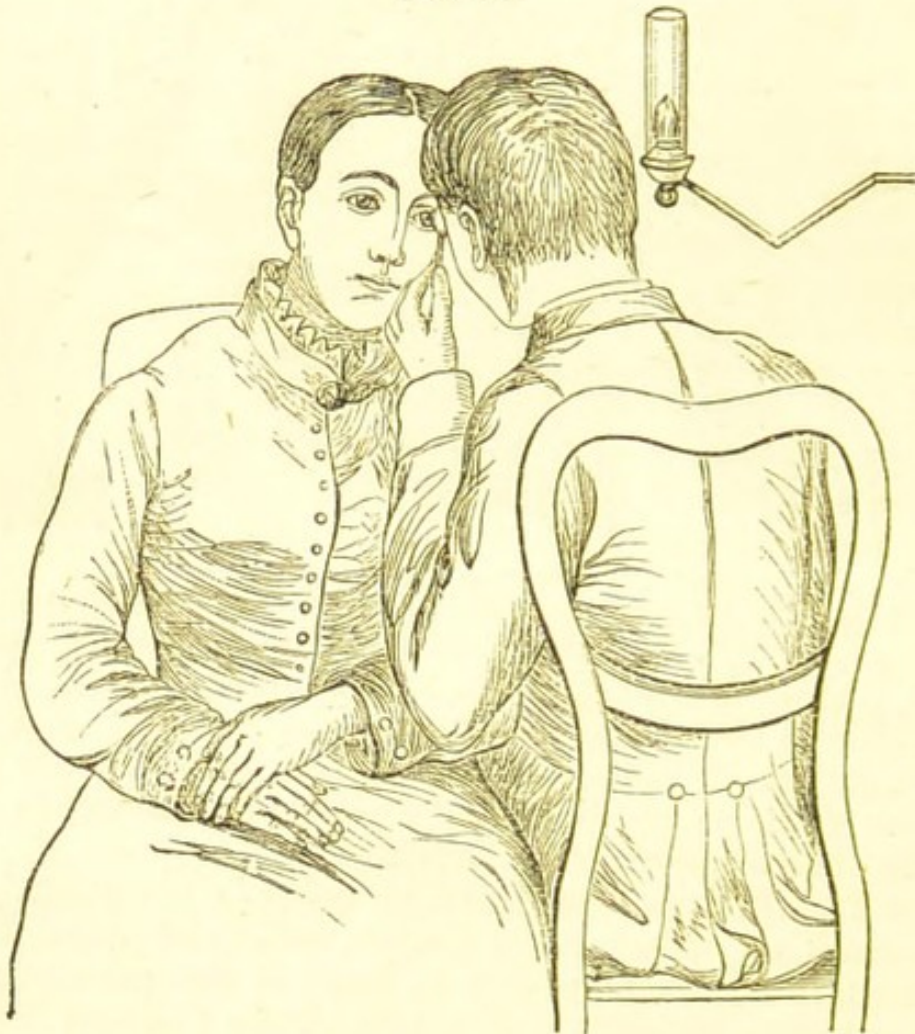
He then with one hand holds the ophthalmoscopic mirror close to his own eye, and at such an angle that he catches upon its polished surface the rays of light from the lamp, and reflects them into the eye of the patient. Looking through the sight-hole of the mirror into the eye thus illuminated, he proceeds to make either an indirect or a direct examination of its fundus.

For the indirect method he holds in his other hand, between his forefinger and thumb, an object-glass of two or two and a half inch focus in front of the patient's eye, and at from one and a half to two inches distance from it, steadying the lens by resting his fingers on the forehead, as represented in the woodcut (Fig. 51). By moving his own head a little backwards or forwards as may be required, he soon succeeds in bringing into view a clearly marked *inverted* aerial image of the fundus of the eye he is examining.

The size of the inverted image may be increased by placing an ocular convex lens of about ten-inch focus behind the sight-hole of the mirror, and using at the same time an object-glass of three-inch focus. With this

combination it will be necessary to approach the head nearer to the patient's eye. In order to obtain a view of the various parts of the fundus in succession, it is requisite to direct the patient to turn his eye in different directions, and for this purpose it is convenient to have fixed objects to which to call his attention. To see the optic nerve, the patient should be told to look at the tip of the observer's ear most distant from him; thus, if the right eye is under examination he should look at the

FIG. 52.



right ear of the surgeon. By this means the globe is slightly inverted, and the optic papilla is brought under observation.

To examine the yellow spot, the patient should be directed to look straight before him at the eye of the surgeon, or through the sight-hole of the mirror.

For the **direct** method, or the examination of the erect image no object-glass is required. The right eye of the patient should be examined with the right eye of the

observer, and the left eye with his left eye. The light should be arranged on the side of the eye to be examined. If the right eye be the one under examination the observer should sit on the side of the patient so that his right eye corresponds with the patient's right. The patient's head should be inclined towards his own right shoulder, whilst the observer bends his head sideways towards that of the patient. In this manner the observer can approximate his eye with the ophthalmoscopic mirror very closely towards the patient's eye. Their eyes may almost meet, but their faces do not touch.

LATERAL OR FOCAL ILLUMINATION of the eye is an extremely useful means for examining the surface of the cornea or the iris, and for ascertaining the state of the lens in cases of suspected cataract. The pupil having been first widely dilated with atropine, the patient is seated on a chair, and the lamp is so placed that its flame is on a level with, and a little in front of, his eye, and at about two feet distance from it. A biconvex lens of two or two and a half inch focus is then held so as to concentrate a cone of light upon the eye, when by a slight movement of the glass in different directions each part of the structure under examination is in turn illumined until the whole of it has been satisfactorily explored. A second lens may be held in front of the eye, to be used as a magnifier if required.

RETINOSCOPY.

By **RETINOSCOPY** we are able to detect and estimate the various errors of refraction *objectively*. It is therefore of great use in determining the refraction of children, as by this method we can measure the degree of myopia, hypermetropia, or astigmatism, and correct the defect with suitable glasses without any assistance on the part of the patient.

For an efficient examination the pupil should be dilated, and the accommodation paralysed with atropine. The patient is to be seated on a chair as for an ordinary ophthalmoscopic examination, and the light placed above the head, so that no direct rays from the lamp fall upon the face. The surgeon in a chair about four feet in front of the patient, with a concave mirror of about nine inches focal length, throws a cone of light on the

corner of the eye to be examined; the patient being told to look straight before him on to the opposite wall. The area of the pupil is illumined, and if the mirror be made to rotate slightly, so that it faces in different directions—first vertically, then horizontally, and next obliquely—a dark shadow will be seen moving with each turn of the mirror across the area of the pupil. It is by the direction in which the shadow moves whilst the mirror is being rotated that the refraction of the eye is determined.

The following are the points to be noticed in retinoscopy:—

1. If the shadow moves **with**, *i.e.*, in the direction in which the face of the mirror is rotated, the eye is **myopic** in that meridian; and if the same result is obtained in all the meridians, both as regards the distinctness and rapidity of movement of the shadow, the case is one of **simple myopia**.

2. If the shadow moves **against**, *i.e.*, opposite to the direction in which the face of the mirror is rotated, and the same result is obtained in all the meridians as regards the distinctness and rapidity of motion of the shadow, then the eye is either **hypermetropic**, **emmetropic**, or **slightly myopic** less than -1 D.

3. If there is a difference in the two opposite meridians, either as regards the direction of the shadow, or of its distinctness and rapidity of motion, then the eye is **astigmatic**.

A rough estimate of the extent of the error of refraction may be made by noticing the brightness of the illumined space, and the distinctness and rapidity of movement of the shadow.

If the illumination be dull, and the movement of the shadow small, there is probably a high degree of ametropia.

If the illumination be bright, and there be a broad shadow with rapid movement, there is probably a low degree of ametropia.

As a rule, the greater the degree of ametropia the less intense is the illumination of the eye.

Having noticed the direction in which the shadow moves, the next step is to correct the defect with glasses; and to do this a spectacle frame is to be fitted on the patient, and glasses placed in succession in front of the eye, and their neutralizing effects noted.

Suppose the shadow is found to move **with** the mirror we have a **myopia** to correct. First place in the spectacle-frame a — glass, say -4 D; if the shadow moves in the same direction, we change the glass for one of a higher power, say -6 D, and if we then find that the shadow moves in the opposite direction, that is, against the motion of the mirror, it shows that the error has been over-corrected, and the refraction made hypermetropic. The patient therefore requires a glass between -4 D and -6 D, and intermediate glasses may be tried in succession until one is found which is just short of over-correction. In myopia the patient will require a glass about 1 D stronger than the one determined by retinoscopy.

If the shadow is found to move **against** the mirror, a trial is to be made, as described in the previous section, but with $+$ glasses placed in front of the eye in succession until one is found which just corrects the error. If a too strong $+$ glass be tried it will be at once detected by noticing that the direction of the shadow is changed, and that it moves with the mirror, showing that the eye has been rendered myopic; lower power glasses must then be substituted in succession until the one is found which is just short of over-correction.

The glass to be ordered for hypermetropic eyes must be 2 D less than the power estimated by retinoscopy; 1 D has to be deducted for the loss of the accommodation produced by the atropine, which has dilated the pupil and paralysed the accommodation; and 1 D for the over-estimate which is made by retinoscopy of the degree of hypermetropia.

In paragraph 2, page 244, it was stated that the shadow moving **against** the mirror may indicate either hypermetropia, slight myopia, or emmetropia.

The following distinguishing tests may be applied:—

If with $+1$ D placed in front of the eye, the shadow continues to move **against** the mirror, the eye is **hypermetropic**.

If with a $+1$ D the direction of the shadow is changed, and now moves **with** the mirror, substitute another glass $+.50$ D, and if the shadow still moves **with** the mirror, the eye is **myopic**.

If with a $+1$ D the shadow moves **with** the mirror, substitute another glass $+.50$ D, and if the shadow now moves **against** the mirror, the eye is **emmetropic**.

To estimate **Astigmatism**, proceed in the same way

as if testing a case of simple myopia or hypermetropia. Determine the refraction of one and then of the other meridian with spherical glasses; thus, take for instance a case of **Hypermetropic astigmatism**.

Suppose in the vertical meridian the degree of hypermetropia = + 2 D; and in the horizontal meridian the hypermetropia = + 4 D.

Deduct 1 D for the error of retinoscopy,

and 1 D for the loss of accommodation from atropine;

And we find the patient would require—
a + 2 D cylinder, axis vertical.

Take next a case of **Myopic astigmatism**.

Suppose in the vertical meridian the degree of myopia = -6 D; and in the horizontal meridian the myopia = -3 D. Add the -1 D for the error in retinoscopy; and we find that the

$$\begin{array}{r} \text{Myopia} = \text{vertical merid. } -7 \text{ D.} \\ \text{horizont. merid. } -4 \text{ D.} \end{array}$$

The correction then would be a glass

$$\begin{array}{r} -4 \text{ D spherical} \\ -3 \text{ D cylindrical, axis horizontal.} \end{array}$$

Mixed Astigmatism is the most difficult error of refraction to diagnose and estimate. The movement of the shadow is different in direction in each of the two principal meridians: thus, in the vertical meridian the shadow may be **with** the mirror, showing myopia: in the horizontal meridian **against** the mirror, indicating hypermetropia. Suppose then we find by retinoscopy that

$$\begin{array}{r} \text{The vertical meridian} = -2 \text{ D,} \\ \text{The horizontal meridian} = +3 \text{ D.} \end{array}$$

According to the rule already mentioned we add -1 D to the myopia, and deduct + 2 D from the hypermetropia; and we have

$$\begin{array}{r} \text{Vertical merid. } -3 \text{ D} \\ \text{Horizontal merid. } +1 \text{ D} \end{array}; \text{ and the correction will be a glass } \begin{array}{r} -3 \text{ D spher.} \\ +4 \text{ D cylind. axis vertical;} \end{array}$$

Or, what is the same, $\begin{array}{r} +1 \text{ D spher.} \\ -4 \text{ D cylind. axis horizontal.} \end{array}$

For an explanation of the theory of retinoscopy, I would refer the reader to the excellent paper on the subject by Mr. Charnley, Royal London Ophthalmic Hospital Reports, vol. x. p. 344.

CHAPTER VI.

ANOMALIES OF REFRACTION AND DISEASES OF ACCOMMODATION.

ANOMALIES OF REFRACTION AND DISEASES OF ACCOMMODATION.—The power which the eye possesses of bringing to a focus on the retina rays of different directions, is termed *accommodation*. By this power the eye is able to distinguish clearly objects at various distances. The fact that we are unable to see distinctly at the same moment near and distant objects is conclusive evidence that there must be a focussing power within the eye. Accommodation is a muscular, although an unconscious, effort, and must not be confounded with *refraction*, which is a faculty possessed by all eyes of bringing certain rays to a focus on the retina *without* any accommodative effort, and is dependent on the shape of the globe and on the media within it. The experiments of Helmholtz with his ophthalmometer proved conclusively that during accommodation for near objects, the lens, and especially its anterior surface, is rendered more convex, and approaches the cornea; and that the pupil contracts and advances whilst the periphery of the iris recedes. The agent through which the change in the lens is effected is the ciliary muscle, but the mechanism by which this is accomplished has not yet been satisfactorily demonstrated. The contraction of the pupil during accommodation Donders considers as probably only an associated movement. That the iris has no share in the process of accommodation was proved in a case under the care of Von Graefe,* where he removed the whole of the iris, and afterwards ascertained by a careful

* Archiv für Ophthalmologie, vii. 2.

examination that the eye still possessed a range of accommodation which corresponded to the age of the patient.

In a normal eye distant objects are seen without any effort of the accommodative power; it is only for near objects that there is active accommodation. This is proved by mydriatics—drugs which dilate the pupil and paralyse the accommodation. If we drop into the eye one or two drops of a solution of atropiæ sulphat. gr. 4 ad aquæ \mathfrak{z} l, we not only dilate the pupil, but in about forty minutes we paralyse the accommodative power, that is, we relax it to its utmost. We then find that the patient is unable to define clearly near objects, but distant vision is unimpaired.

The nearest point of distinct vision for small type No. I. is called the punctum proximum or near point, and is expressed by the letter *p*.

The furthest point of distinct vision for the same type is called the punctum remotum or far point, and is expressed by the letter *r*.

The distance between the near and the far points is termed the range or the amplitude of accommodation.

In the emmetropic eye of a child the near point lies at from $3\frac{1}{2}$ to 4 inches from the eye, and this recedes as age advances. The far point lies at infinite distance.

An eye is said to be normally constructed or *emmetropic* when it is able by virtue of its own refractive power, and without any effort of the accommodation, to unite to a focus on the retina parallel or distant rays.

There are two ways in which the refraction may differ from that of the emmetropic eye. The axis of vision may be too long, so that parallel rays are brought to a focus *in front* of the retina, as in *myopia*; or the axis of vision may be too short, as in *hypermetropia*, where parallel rays are united *behind* the retina. We have now to consider in succession the following conditions of the eye and the treatment which is suited to each:—

Myopia,	Astigmatism,
Hypermetropia,	Presbyopia.

The three first-named are anomalies of refraction, as the impairment of sight they produce may be altogether independent of any faulty state of the accommodation. Presbyopia, however, must be regarded as a normal state

occurring in an emmetropic eye as a natural result of increasing years, and without any necessary defect of its power of refraction.

MYOPIA.

Myopia, or Short Sight, is usually dependent on a too great length in the antero-posterior diameter of the globe, so that the rays of light coming from a distance are brought to a focus in front of the retina, upon which circles of diffusion are formed in the place of a clearly defined image, and the object, therefore, appears confused and indistinct. Myopia may, however, be due to a too great refractive power in the eye, without any abnormal increase in the length of the globe, as in those exceptional cases of spasm of the ciliary muscle in which an undue rotundity is given to the lens. Nearly all the cases of myopia are dependent on the first-mentioned cause, and the extension of the antero-posterior diameter of the globe will be found to arise from a prolongation of the posterior half of the eye. It is seldom that there is any change in the diameter in the anterior or corneal half. This increase in the length of the globe is usually accompanied by a thinning of the sclerotic, and a partial atrophy of the choroid, and is recognised by the names *Posterior staphyloma*, or *Sclerotico-choroiditis posterior*. It is usually found in all cases of severe myopia. Graefe says that it is always present when the myopia exceeds $\frac{1}{5}$, that is, when a stronger concave glass than one of five-inch negative focus is required to correct it; but a posterior staphyloma will be often seen in myopia as low as $\frac{1}{18}$ or $\frac{1}{20}$. The staphyloma may be a uniform prolongation of the posterior coats of the eye, but it is generally a more or less marked ovoid bulging between the yellow spot and the outer margin of the optic disc. The great length of a highly myopic eye may be usually seen by drawing the outer canthus away from the globe with one finger, whilst the patient is made to look as much inwards as possible by directing his attention to an object on the other side of his nose.

Myopic patients can usually see clearly near objects, but they are unable to make out those at a distance, and in endeavouring to do so they instinctively partially close the eyelids, to diminish the palpebral aperture. In this manner they cut off many of the peripheral rays which emanate from the object they are looking at, and by thus

limiting the circles of diffusion they obtain a more sharply defined image.

Myopia may be *hereditary*, *congenital*, or *acquired*. It is generally hereditary, but *not congenital*, in that it does not usually manifest itself until after eight or nine years of age. Myopia will be often found to have existed in families for many past generations. *Acquired* myopia is occasionally seen in watchmakers, steel-plate engravers, and others, who for many years have been in the habit of applying their eyes for several hours daily to fine work, or to literary pursuits. Like all other bodily defects, when once acquired it may be transmitted, and so become hereditary. No doubt to insure this result, it is necessary that the eye should have been specially used throughout several generations. Myopia may be thus regarded as one of the evils of civilization and high mental culture. The great demands which scientific and manufacturing pursuits make on the eyes cause them to gradually attain through successive ages an increased growth and development. Up to a certain point this is productive of improved vision—of sight which is good for both near and distant objects; but beyond a fixed limit the eyes become too large, and myopia is the result.

Ophthalmoscopic Appearances of a Myopic Eye.—By *direct* examination, that is, by aid of the mirror without the use of the object lens, an *inverted* image of the fundus may be seen at some inches from the eye; thus, if the observer move his head in one direction, the retinal vessels will appear to travel in the other. The reverse of this occurs in the *direct* examination of hypermetropic eyes, when the parts of the fundus will seem to move with the head, proving that the image is erect.

To obtain an *erect* image of the fundus of a myopic eye, a concave lens should be placed behind the sight-hole of the mirror. The strength of the concave lens through which the observer can see clearly the details of the fundus of the eye will give an approximate measure of the myopia of the patient; thus, beginning with 1 D concave lens, and trying in succession a series of glasses of higher powers, the lens which shows most distinctly the retinal vessels will indicate nearly the actual degree of myopia.

By an *indirect* ophthalmoscopic examination, that is, by the aid of both the mirror and object lens, the optic nerve and vessels appear rather smaller than in an

emmetropic eye. In most myopic eyes evidence of a posterior staphyloma is seen in a small white band or crescent generally on the *apparent* inner side of the optic nerve. This is known as the *myopic arc* or *crescent*. It is caused by the prolongation backwards of the sclerotic, and consequent stretching of that portion of the choroid which corresponds to the staphyloma. This extension of the choroid induces atrophy and thinning of its texture, so as to render transparent that part of it which is adjacent to the optic nerve, and upon which the greatest pull is exerted, and thus to allow the white shining surface of the subjacent sclerotic to gleam through. Occasionally the choroid is completely detached around a portion of the margin of the optic nerve. The width of the arc is usually proportioned to the degree of the myopia, and in severe cases it will sometimes extend entirely round the optic disc, or instead of a crescent there will be a large white irregular patch, over which the retinal vessels will be seen coursing. (See Article SCLEROTICO-CHOROIDITIS POSTERIOR, page 197.)

By Retinoscopy.—The shadow moves *with* the mirror. (See page 245.)

Treatment of Myopia.—In examining a myopic eye the points to be decided are:—

1. The degree of myopia and the range of accommodation.
2. Whether the myopia is stationary or progressive.
3. Whether it is simple or complicated.

1. **The Degree of Myopia and Range of Accommodation.***—Note the farthest distance from the eye at which the patient can read No. I. This is his *far point*, and represents approximately the degree of the myopia: thus if he can read No. I. at eight inches he has theoretically a myopia of 4.5 D, requiring a concave lens of eight inches focal length for distant objects; if at five inches, a glass of 7 D, or five inches focal length, and so on. In practice, however, it will generally be found that the patient requires a glass of rather lower focal power for distance.

Next determine the *near point*, and this is done by ascertaining how close to the eye the patient can read

* The best types are those prepared by Dr. Snellen, of Utrecht. They may be obtained of Williams and Norgate, Covent Garden, London.

the same type; the space between the near and far points will indicate the range of the accommodation. In low degrees of myopia the range of accommodation is generally good, but less than in emmetropia; whilst in the high degrees of myopia the range is usually very contracted.

Having proceeded so far, find out by trial with successive glasses the weakest concave lens with which the patient can see No. XX. at twenty feet. If no glass will bring his sight up to this standard, his acuteness of vision is impaired, and this defect is due to some other cause than simple myopia. (See COMPLICATIONS OF MYOPIA, page 254.)

Each eye should be tested separately by closing the one which is not under examination, telling the patient to place his hand over it. In testing with glasses, each lens should be placed as close to the eye as it would be worn in the spectacle frame, as its strength is increased if it be held at a distance.

If there be a great difference in the degrees of myopia of the eyes, it is often impossible to provide the more myopic eye with a glass which will enable the patient to use the two eyes together with comfort. In such cases it is better either to give spectacles with both glasses of the same focal power as that which is suited to the least short-sighted eye; or to give to the more myopic eye only a slightly stronger glass than that required for the better eye. In the low degrees of myopia each eye may be furnished with the glass which neutralizes its myopia.

If there be an insufficiency of the internal recti muscles, so that the patient is unable to converge both his eyes on a near object, and this defect is not corrected by the use of concave spherical glasses, and the patient complains of discomfort or pain, much benefit will often be found from adding a prism to the lens with its base inwards. A prism of 1° , 2° , 3° , or 4° may be given to the more defective eye, and if necessary a prism of a lower power to the better eye. In cases where the insufficiency is so marked as to cause a divergent squint, the external rectus of one or both eyes may be divided. The external muscle of the most defective eye should be first divided, and if after an interval of a few days it is found that the effect has not been sufficient, a similar tenotomy should be performed on the other eye. Great judgment must be exercised before dividing the external rectus of even one eye in cases of myopia where the

insufficiency of the internal recti is not very pronounced, as I have frequently seen the most troublesome diplopia follow the division of only the one external rectus muscle.

General Rules for the Selection of Glasses.—

When the myopia is below 2 D or $\frac{1}{18}$, no spectacles should be worn, but the patient should be furnished with glasses in a folding frame, which he can apply to his eyes when looking at objects beyond his range of vision.

In myopia from about 2 D or $\frac{1}{18}$ to 3 D or $\frac{1}{12}$, one pair of spectacles which will enable the patient to read No. XX. at 20 feet will usually be sufficient. If reading glasses are required, and the accommodation is good, the patient may use the same glasses as for distance. If, however, the accommodative power is impaired, the reading glasses must be of a lower power.

In myopia from about 3 D or $\frac{1}{12}$ to 5 D or $\frac{1}{7}$, it will be well to give the patient spectacles with weak lenses for reading, and stronger concaves for wearing in the streets or when looking at things at a distance.

In high degrees of myopia, as from 6 D or $\frac{1}{6}$ upwards, the patient should not, as a rule, be allowed to wear constantly glasses which completely neutralize the myopia, as they will often fatigue the eye, and produce too much dazzling. He should be ordered, for constant use, the concaves which suit him best for reading and enable him to see well eight or ten feet in front of him, and in addition he should be given a pair of glasses in folding frames of a focus which will represent the difference between those he requires for reading and distance. These he may hold in front of his spectacles when looking at objects beyond the power of the glasses he has on; thus, a patient who requires -9 D or $-\frac{1}{4}$ for distance, and -3 D or $-\frac{1}{12}$ for reading, may be ordered spectacles with -3 D or $-\frac{1}{12}$ for constant wear, and a double eye-glass with -6 D or $-\frac{1}{6}$ for occasional use in front of his spectacles; because -3 D with -6 D $= -9$ D. If the glasses dazzle, or if the eyes are irritable, much comfort may be often gained by ordering the lenses to be tinted with cobalt blue; and this is especially beneficial if the eyes have to be much used with artificial light.

In cases of extreme myopia, as from 18 D or $\frac{1}{2}$ to 112 D or $\frac{1}{3}$ or 9 D or $\frac{1}{4}$, I have occasionally found the sight for distant objects greatly improved by a Steinheil's cone.

2. **Whether the Myopia is Stationary or Progressive.**—In most young people the myopia is progressive; it is therefore of the utmost importance that the rules which are given under the heading of GENERAL DIRECTIONS should be strictly followed, in order to retard, if possible, its increase and render it stationary.

In stationary myopia of a low degree, the sight may steadily improve as age advances, and ultimately the patient may be able to discard the use of glasses, but this is rather exceptional. In myopia of a high degree there is always a strong tendency to increase. If the progress is rapid, it is usually accompanied with symptoms of irritation, which require careful management. The patient complains of *muscæ*, flashes of light and globes of fire; the eyes will flush easily when reading, or often without an apparent cause, and they look red and irritable. With such symptoms the use of glasses should be for a time abandoned, or only those of a low power allowed, sufficient to enable the patient to perform the duties absolutely required of him. A leech to each temple, repeated every two or three days for a few times, will sometimes give great relief. A small blister of the size of a shilling may also be applied behind the ears, and repeated from time to time, so as to keep up a little counter-irritation; or some stimulating liniment may be used for a similar purpose. The eyes may be frequently bathed with a cold lotion (F. 43, 51), which may be applied over the closed lids with a fold of linen when the patient is lying down. The most important treatment, however, consists in rest to the eyes, by abstaining from all work, and especially that which induces a stooping position of the head.

3. **Whether the Myopia is Simple or Complicated.**—If suitable concave glasses fail to make the patient read No. XX., Snellen, at 20 feet, there is super-added to the myopia some other defect to account for his impairment of vision. Myopia may be complicated—1, with amblyopia or weak sight, due to defective sensibility of the retina; 2, with astigmatism; 3, with an increasing posterior staphyloma and atrophy of the choroid; 4, with deficiency of power of the internal recti muscles (muscular asthenopia); 5, with opacities of the cornea; 6, with opacities of the vitreous; 7, with choroidal or retinal hæmorrhage; 8, with partial detachment of the retina. For the treatment of all these complications the

reader is referred to the different sections under which they will be found in the index.

General Directions for Myopic Patients.—Avoid all stooping positions of the head, as they tend to cause congestion of the eyes. In reading, sit with the head thrown back, and bring the book to the eyes instead of taking the eyes to the book. Never, if it can be avoided, read books printed in narrow double columns; the having to relax frequently the accommodation, as the eye travels from one short line to the next, tends to induce fatigue. Never read in a moving carriage; the repeated jolts displace the words on which the eye is fixed, and tire the eye by requiring it to keep readjusting itself. If the eyes grow fagged whilst reading, rest awhile, and do not resume work until they are refreshed. Avoid working by an artificial light, and especially gas which flickers. The best lights are wax candles provided with shades which throw their light on the object to be seen, and leave the rest of the room in comparative darkness, into which the eye can roam when feeling fatigued. When the eyes are tired, or hot and irritable, the best application is cold water, with which the eyes, the lids being closed, may be bathed; or a gentle stream of cold water may be carried against the closed lids by means of the siphon eye-douche.

HYPERMETROPIA is the reverse of myopia; for whereas in myopia the optic axis was too long, and parallel rays, or those emanating from distant objects, were brought to a focus in *front* of the retina, in hypermetropia the antero-posterior diameter is too short, and the focal point of parallel rays is *behind* the retina. The result of this defect is that only convergent rays can be brought to a focus on the retina. The hypermetropic eye is consequently unable to receive correct impressions of things at a distance when in a state of repose—that is, with its accommodation relaxed—but it has to bring into action its focussing power, in order to converge sufficiently the parallel rays. The strain on the accommodation is therefore in proportion to the nearness of the object.

Adopting Donders's classification, hypermetropia may be divided into *acquired* and *original*. The **acquired** is occasionally met with in old people, generally above sixty or seventy years of age, when it is associated with presbyopia,

Hypermetropia may thus be often found in an originally emmetropic eye. The patient not only requires convex glasses for reading and looking at near objects, but the refractive power of the eye has become so reduced that he also needs convex glasses for distance. Another form of acquired hypermetropia is found in cases of what Donders calls "aphakia," or absence of the lens from the eye. This may occur from extraction of the lens for cataract, or from a dislocation of the lens out of the field of vision from an accident. In both of these cases convex glasses are required for distance.

Original Hypermetropia may be said to exist in two states, the **manifest** and the **latent**.

The **manifest** is that degree of hypermetropia which the patient exhibits before the accommodation has been paralysed with atropine.

The **latent** is the amount of hypermetropia which is found after the accommodation has been paralysed with atropine, and which was not manifest so long as the patient exerted his focussing power in looking at distant objects.

Donders further divides hypermetropia into **absolute**, **relative**, and **facultative**.

Absolute is when the eye can neither read fine print, nor tell clearly distant objects. With the strongest convergence of the eyes the patient cannot accommodate for parallel rays. This form is seldom met with in the young, as with them there is nearly always a certain amount of accommodative power, which enables them to overcome a portion of the hypermetropia.

Relative Hypermetropia is when, in order to see clearly a near object, say at a distance of sixteen inches, the eyes are obliged to converge as if looking at one at twelve inches. The patient can only accommodate for the real point, by converging the visual lines to another point nearer to the eyes; in fact, by giving to them a periodic convergent squint.

Facultative Hypermetropia is when the patient can see clearly distant objects, either *with* or *without* convex glasses, and he can also, with an effort which is almost unperceived, read and write well, but the eyes are specially liable to suffer from asthenopia when called upon to perform much continuous close work. Such eyes also soon become presbyopic.

Donders has shown that from 50 to 55 years of age the

emmetropic eye becomes hypermetropic; the hypermetropic eye more hypermetropic; and the myopic eye less myopic or emmetropic, or even hypermetropic according to its degree of myopia.*

Treatment of Hypermetropia.—Find out the degree of hypermetropia, and then furnish the patient with such glasses as will best remedy this defect.

To Ascertain the Degree of Hypermetropia.—First direct the patient to look at No. XX. at 20 feet distance, and find out the strongest convex glass with which he can clearly make out that type. The strength of the lens will indicate the degree of *manifest* hypermetropia: thus, if a 2 D or 18-inch focus convex glass be required, the patient is said to have a manifest hypermetropia of 2 D or $\frac{1}{18}$. He should then be directed to read No. I. with this glass, and if he can do so with facility he may be allowed a pair of spectacles with lenses of the same focus for constant use; but if he should be unable to see the type or only to make it out with difficulty, stronger glasses should be tried in succession until the eyes are suited. The spectacles which are thus furnished to the patient will probably, however, only suffice him for a time, as they do not neutralize his *latent* hypermetropia; and this will gradually become manifest as the patient, by the aid of his glasses, ceases to strain his accommodation for distance. After a time he will probably therefore require stronger glasses. In low degrees of hypermetropia, for practical purposes this examination may be sufficient, and suitable glasses may be thus given to the patient; but in all severe cases the amount of latent hypermetropia should also be ascertained. To do this, the accommodation of the eye should be first paralysed by dropping into it a few drops of a solution of atropine, gr. 4 ad aquæ $\bar{3}$ 1; and when the full effect has been gained, try what convex glass will enable the patient to see No. XX. at 20 feet. Now, an ordinary emmetropic eye thus treated would be able to read, unaided by glasses, No. XX. at 20 feet, for without any effort of accommodation it can unite parallel rays on the retina; but the hypermetropic eye will need a convex lens, and one of a greater power than that which was called for before the instillation of the atropine. The focal power of the lens now required will give

* Zehender's Monatsbl. xiii. p. 474.

the degree of *latent* hypermetropia. As a rule the patient cannot wear constantly glasses of the strength necessary to neutralize the latent hypermetropia, as, from having been long accustomed to use unconsciously his accommodation for distance, he is unable to completely relax it, and strong convex glasses would confuse and fatigue the eye. He should therefore first be ordered weaker glasses, and these may be changed from time to time for stronger ones, as may be necessary.

Peculiarities of the Hypermetropic Eye.—It is smaller in all its dimensions than the emmetropic eye, but especially in the antero-posterior diameter, so that the globe has a flattened appearance. This can be distinctly seen if the patient is directed to look as far inwards as possible whilst the outer canthus is drawn outwards with one finger. It will then be noticed that the curve of the eye over which the external rectus curls to its insertion is short and abrupt, and that the globe looks flat and small for the orbit. Donders says: "The hypermetropic eye is in general an *imperfectly developed eye*. If the dimensions of all the axes are less, the expansion of the retina also is less, to which, moreover, a slighter optic nerve and a less number of its fibres correspond." *

Ophthalmoscopic Appearances of a Hypermetropic Eye.—By *direct* examination, that is, by the aid of the mirror without the use of the object lens, an *erect* image of the fundus can be seen at several inches from the eye, and on the observer moving his head the retinal vessels will be seen to travel in the same direction. The highest convex glass placed behind the sight-hole of the mirror through which an erect image of the fundus can be seen will give an approximate estimate of the degree of hypermetropia.

By an *indirect* examination, that is, by the aid of both the mirror and object-glass, the optic nerve and vessels appear larger than in the normal or emmetropic eye.

By **Retinoscopy** the shadow moves *against* the mirror. (See page 244.)

Hypermetropia is very hereditary; many members of a family, of which one or both the parents are hyperme-

* Donders, On the Accommodation and Refraction of the Eye, p. 245.

tropic, are frequently found also to suffer from this defect of the eyes.

Results of Hypermetropia.—It is the most frequent cause of convergent strabismus, and of asthenopia or weak sight.

PRESBYOPIA.

PRESBYOPIA, OR LONG SIGHT, is one of the first of the legion of troubles which advancing years bring upon all of us. In true presbyopia the near point is removed from the eye, but distant vision is unimpaired. The first intimation the patient has of commencing presbyopia is that the type which he could once see clearly at from eight to twelve inches, is now indistinct, and in order to read it, he is obliged to hold the book at a greater distance. As presbyopia advances, the failure of sight for near objects increases, and this is especially noticeable in the evening, when the patient seeks a strong light to work by, because with it the pupil contracts and the circles of diffusion are rendered smaller.

Presbyopia is caused by a diminished power of accommodation, and probably also by senile changes in the structure of the lens. It creeps on imperceptibly, the near point being gradually removed further from the eye as age advances, until the patient is unable to discern any small objects without the aid of convex glasses. Donders says: "The term presbyopia is, therefore, to be restricted to the condition in which, as the result of the increase of years, the range of accommodation is diminished, and the vision of near objects is interfered with." "It is," he remarks, "no more an anomaly than are grey hairs or wrinkling of the skin."*

Donders also states that in the emmetropic eye the near point begins to recede as early as 10 years of age, and from that time the recession continues, until at the age of from 40 to 45 it lies at about eight inches from the eye, when the patient begins to experience inconvenience in reading, and may be considered as presbyopic. The presbyopia continues to increase with advancing years.

From 50 to 55 years of age, the far point begins to recede, and the eye becomes also slightly hypermetropic,

* Donders, On the Accommodation and Refraction of the Eye, pp. 210.

and the sight for distance is improved by low power convex glasses. This hypermetropia increases with age; and at from 70 to 80 years of age the patient will require a glass of from 1 D or $\frac{1}{36}$ to 2 D or $\frac{1}{18}$ to enable him to see clearly distant objects.

Treatment of Presbyopia.—It is a question often asked, When ought convex glasses first to be used? Donders says: "So soon as, by diminution of accommodation, in ordinary work, the required accuracy of vision begins to fail, there is need of convex glasses. The test is, that with weak glasses of from 0.5 D or $\frac{1}{4}$ to 1 D or $\frac{1}{6}$ at the same distance as without glasses, the accuracy of vision is manifestly improved."* It is an error to suppose that presbyopic patients should postpone the use of glasses for as long a period as possible. By so doing they subject themselves to an amount of discomfort which could be avoided, and without any advantage to compensate for the sense of fatigue, heat, and occasional redness of the eyes which an overstrained effort of the accommodation induces.

In selecting glasses for a presbyopic patient, those should be chosen which enable him to read with ease No. I. at about ten or twelve inches from the eye. If stronger glasses are given, they are apt to induce fatigue. When convex glasses are first called for, it will generally only be necessary to wear them in the evening, as by day the patient will be able to perform all his duties without their aid. But soon he will take to his glasses by day, and then a pair of stronger ones will be required for evening use. Whenever, therefore, the patient has to increase the power of his glasses, he should take his evening pair into day use, and obtain stronger ones for his evening's work.

The following is an approximation of the glasses required at the various ages after forty. Every patient should be carefully examined before the glasses are ordered, as age alone will not indicate the glasses required:—

* Donders, On the Accommodation and Refraction of the Eye, p. 217.

Age.	Dioptries.	Numbers in French inches.	Numbers in English inches.
45	1	36	40
50	2	18	20
55	3	12	13
60	4	9	10
65	4.50	8	9
70	5.50	$6\frac{1}{2}$	7
75	6	6	$6\frac{1}{2}$
80	7	$5\frac{1}{2}$	$5\frac{3}{4}$

ASTIGMATISM.

ASTIGMATISM.—"Ametropia," says Donders, "comprising the lesions of refraction, is resolved into two opposite conditions: myopia and hypermetropia. Every lesion of refraction belongs to one of these two. Sometimes, however, it happens that in the several meridians of the same eye the refraction is very different. In one meridian the same eye may be emmetropic, in the other, ametropic; in the several meridians a difference in the degree and even in the form of ametropia may occur."* This defect, dependent on a want of symmetry of the meridians of the eye, has been termed *astigmatism*. The explanation of this anomaly is the following:—The cornea in a normal eye is a segment of an ellipsoid, and as its horizontal and vertical axes are of different lengths, it follows that its curvatures in these directions must also differ; and that vertical and horizontal rays falling upon such a surface must be unevenly refracted, and therefore unite into two separate foci. As a rule the vertical meridian has a shorter focal distance than the horizontal. Hence it is that in most eyes vertical and horizontal lines are not seen with equal clearness from the same point and at the same time.

So far, astigmatism may be considered a natural defect due to a difference of the vertical and horizontal curva-

* Donders, On the Accommodation and Refraction of the Eye, p. 449.

tures of the cornea, and which in a minor degree is common to all eyes. It is only when there is a marked asymmetry between the meridians of the cornea that it attracts notice, and calls for the aid of cylindrical glasses.

There are two distinct forms of astigmatism: the *irregular* and the *regular*.

IRREGULAR ASTIGMATISM.—Donders divides this form into normal and abnormal.

a. Normal Irregular Astigmatism is due to a peculiarity in the structure of the lens. The principal phenomenon, he says, attending this irregularity is monocular polyopia. This multiplication of the object is to be explained by there being from some cause an aberration of the rays as they pass through the different sectors of the lens, and consequently "an imperfect coincidence, even after accommodation, of the images of the different sectors."*

β. Abnormal Irregular Astigmatism may arise from some defect of either the cornea or lens.

From the Cornea.—We have examples of this form of irregular astigmatism in conical cornea; occasionally after the extraction of cataract, and after corneal ulcerations.

From the Lens.—Irregular astigmatism may be caused either by a change in the structure of the lens as is sometimes seen in the early formation of cataract; or by its displacement, as in cases of partial dislocation of the lens into the anterior chamber, or vitreous.

REGULAR ASTIGMATISM is due to a difference in the focal lengths of the meridians of the eye, and is to be corrected by proper cylindrical glasses. It is with this form that we have now to deal.

Regular astigmatism may be *acquired* and *congenital*. The *acquired* may be produced by perforating wounds the eye, and especially those which are near the margin of the cornea; thus, it is occasionally met with after the operations of iridectomy and extraction of cataract. Ulcerations of the cornea usually give rise to *irregular* astigmatism; a case, however, is related by Donders in which, after a perforating ulcer of the cornea, the

* Donders, On the Accommodation and Refraction of the Eye, p. 548.

astigmatism was sufficiently regular to be corrected by a cylindrical glass.

Regular Astigmatism may be divided into—

1. **Simple Astigmatism**, that is, when one meridian is emmetropic, and the other either hypermetropic or myopic.

2. **Compound Astigmatism**, when both meridians are either myopic, or hypermetropic; but the defect in one meridian is greater than in that of the other: thus, if the case is one of compound myopic astigmatism, in the horizontal meridian the myopia may be 2 D or $\frac{1}{8}$, whilst in the vertical it may be 3 D or $\frac{1}{2}$.

3. **Mixed Astigmatism**, that is, where there is hypermetropia in one meridian and myopia in the other. Such cases are comparatively rare.

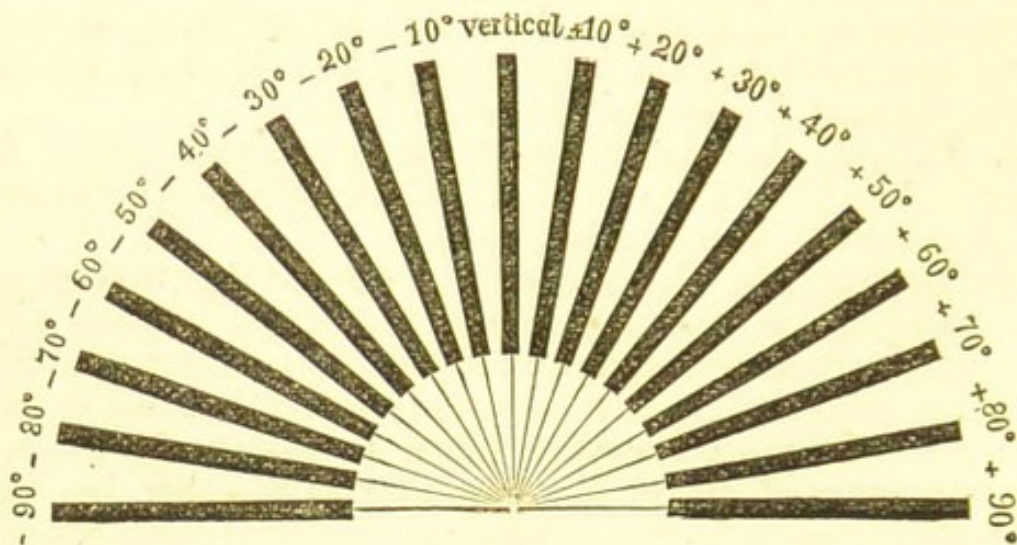
To Ascertain the Presence of Astigmatism.—First test the patient's eyes with spherical glasses, and determine whether they are myopic or hypermetropic, and if either, what glasses most nearly neutralize his defect of sight. Having, however, failed to restore by glasses his acuteness of vision, the question is whether his impairment of sight is due to astigmatism or to other causes. To find this out, place at one end of the room a set of thick vertical and horizontal lines, and let the patient walk towards them, and stop the moment either of them becomes distinct. If he can at a certain point see clearly one set of lines, whilst the others are cloudy and blurred, he is astigmatic. A similar conclusion may be drawn if the patient be made to look at a point of light through a perforation in a metal screen at a distance of 15 feet, when, owing to the astigmatic eye being unable to unite accurately to a focus vertical and horizontal rays, the point will appear drawn out to a vertical or horizontal line, according to whether the eye focuses correctly the horizontal or vertical rays.

The patient should now be directed to look through a slit about $\frac{1}{4}$ of an inch wide in a disc of metal, which is to be slowly rotated in front of the eye, so as to bring the slit opposite each of the different meridians in succession. If in a certain position of the slit he is able to make out No. XX. at 20 feet, the case is one of *simple astigmatism*. The eye is emmetropic in one meridian, and myopic or hypermetropic in the other.

The patient may then be tried with a weak cylindrical convex or concave lens, which he must rotate in front of

the eye, until he places the axis in that direction which gives him the most correct vision. Should the glass first tried not quite answer, others of a slightly higher or lower focal power may be held up in turn, until the eye is suited. Spectacles with similar cylindrical glasses may be then given to the patient; but in ordering them the instructions given at page 269 should be followed.

FIG. 53.



Another very efficient mode of determining the presence and degree of astigmatism is that suggested by Snellen by means of the half circle of radiating lines (Fig. 53), which is a reduced copy of the figure drawn in the last edition of his test types. He marked those lines which deviated from the vertical line with from 10° to 90° . Those to the right of the observer with +; those to the left with —.

With the second eye covered, the patient is told to look at the half circle of lines placed at the end of the room, and to approach it until one at least of the lines can be strongly seen. The direction of this line gives the meridian of greatest refraction, which in regular astigmatism is vertical to the meridian of lowest refraction. A succession of convex or concave spherical glasses are next to be placed in front of the eye, until the highest convex or lowest concave lens is found through which the indistinct lines are rendered clear. The lens which thus corrects the myopia or hypermetropia in the faulty meridian will indicate the strength of the cylindrical glass required, the axis of which will correspond, if it be a convex cylindrical, with the meridian of highest refraction, whilst if

it be a concave cylindrical, it should be placed perpendicular to it.

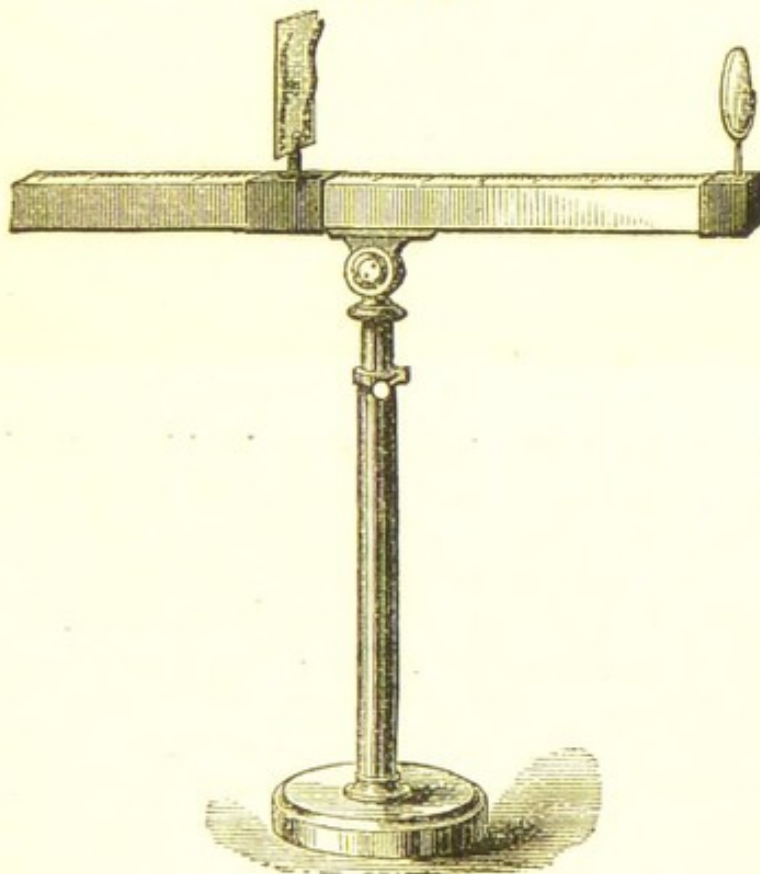
If the astigmatism be associated with myopia or hypermetropia, it is necessary to correct the anomaly of refraction before resorting to the test of Snellen's half circle of lines.

In testing for astigmatism, it is essential that the patient should hold his head straight, and keep his eyelids well open.

Mr. Tweedy has kindly given me the following account of his optometer, which is an extremely useful instrument for measuring astigmatism :—

The optometer, Fig. 54, consists essentially of a ver-

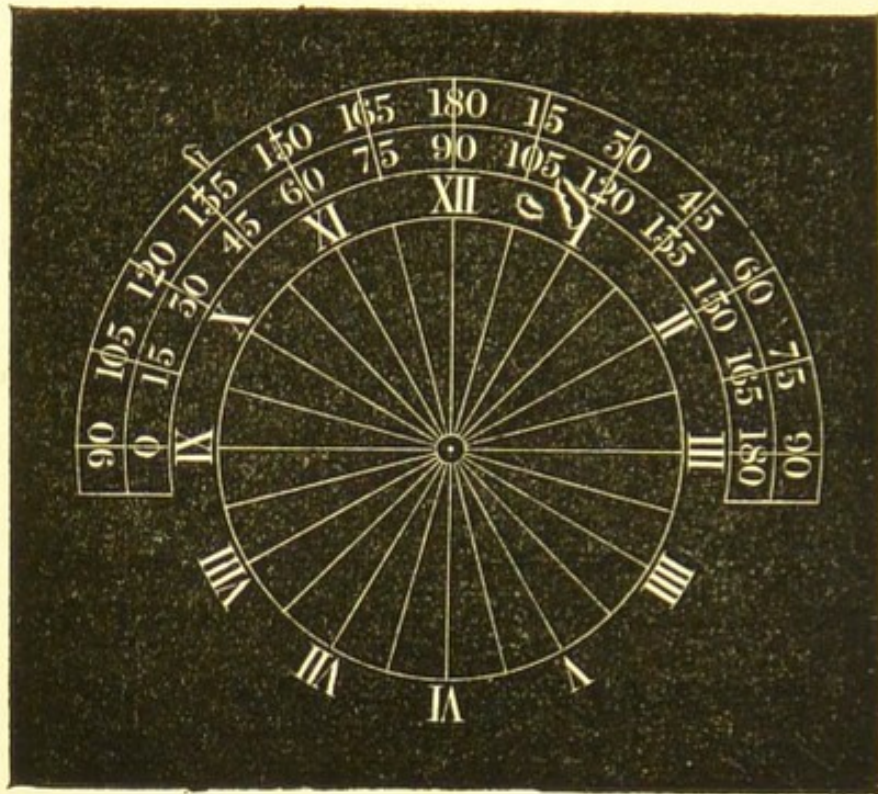
FIG. 54.



tical plate carrying the figure of a dial (Fig. 55) marked with fine radiating lines at angles of 15° with each other. The plate slides on a horizontal bar fourteen inches in length, which is divided on the upper surface into inches and tenths, and into the focal lengths of dioptries and quarters, from three to thirty. At the proximal end of the bar is a clip for holding a convex spherical lens, and to the clip is affixed a semi-circle marked with degrees

corresponding with those on the dial. The radiating lines on the dial are shown not only by the Roman

FIG. 55.



numerals I. to XII., but by a double set of Arabic numbers. The lower set records the angles which the various lines make with the horizontal, while the upper set serves the double purpose of indicating the lines at right angles to those opposite the lower, and of showing the position in which the axis of the correcting cylinder should be placed at the semicircle on the clip. Thus the line at right angles to 30° , lying between X. and IV., is 120° , and this is found to be between I. and VII. As the two principal meridians of the eye in regular astigmatism are at right angles with each other, it follows that if the line 30° lay in one principle meridian the line 120° is in the other principal meridian, and so for every other line. To use the instrument effectually, the following instructions must be strictly followed:—

1. The eye about to be examined having been atropized (or not, according to requirements), is made artificially myopic preferably to about $M = 5\text{ D}$ by means of a convex lens placed in the semicircular clip. The lens required will vary with the degree and kind of ametropia.

If there be much hypermetropia, from 8 D to 12 D should be used; if, on the other hand, there be myopia, only 1 D to 3 D will be needed. The opposite eye being excluded, the patient should sit erect and look through the centre of the myopizing lens at the dial.

2. The dial being at first placed beyond the point of distinct vision is gradually approximated to the eye until at least one of the radiating lines is *seen clearly and distinctly*, without any blurring at the edges, and at the greatest distance. After this, the dial should not be moved, but its distance from the eye should be noted in focal lengths of dioptries.

If *all* the radiating lines come into view with equal clearness at the same maximum distance, there is no astigmatism; but if only *one* line be clearly seen at a maximum distance, there is astigmatism, which may be corrected by placing a suitable concave cylindrical lens close to the semicircular clip and at right angles to this line. The upper set of Arabic numerals on the dial indicates the astigmatic line and the place of the cylinder.

This completes the examination. The deductions are as follows:—

(1) As already stated, if all the lines become distinct at the same maximum distance, there is no astigmatism.

(2) If the maximum distance for all the lines be at the focus of the myopizing lens, there is no ametropia, and the eye is emmetropic.

(3) If the maximum distance be *beyond* the focal length of the myopizing lens, there is hypermetropia equal to the difference between the number of dioptries in the myopizing lens (f) and the distance in focal lengths of dioptries (d), at which the lines are seen, $H = f - d$.

(4) If the maximum distance be *within* the focal length of the myopizing lens there is myopia $M = f - d$.

(5) If only one line be seen clearly at a maximum distance there is astigmatism. The refraction of the meridian of the eye (x) in which the clear line is seen is represented by the difference between the myopizing lens and the distance at which the line is seen $x = f - d$.

(6) The astigmatism is represented by the *weakest concave cylinder*, which placed immediately in front of the myopizing lens, makes the line at right angles to that first seen equally distinct.

(7) The correcting lens for parallel rays will be the

combination of the spherical lens obtained by the formula $x = f - d$, and the weakest concave cylinder ascertained by experiment. If f and d be equal, the concave cylinder alone will suffice; if f be greater than d a convex spherical will be needed in addition; but if f be less than d , then a concave spherical must be combined with the cylinder.

Mr. Couper uses the ophthalmoscope to detect and measure astigmatism, and afterwards confirms the knowledge he has gained with the ophthalmoscope by a trial with glasses. He says: "Although it is obviously inexpedient in ordering glasses to trust to the ophthalmoscope alone, unless, perhaps, when dealing with a young child. . . . Nevertheless an estimate thus made is exact enough to serve as a guide and as a criterion of the patient's accuracy during the final trials with glasses and test types, and to detect errors, whether due to want of acumen or to irregular accommodation on his part, or to any other cause."*

To diagnose and estimate astigmatism by **Retinoscopy**, see page 246.

In the absence of one of the more exact methods, already described, for estimating the degree of astigmatism the following mode of measuring compound astigmatism, by lenses may be used, and an approximately correct result obtained.

Compound Astigmatism.—First ascertain the concave or convex glass, according to whether the patient is myopic or hypermetropic, which most improves vision; and whilst he holds this before his eye, place in front of it a cylindrical glass of similar curvature but of low power, and slowly rotate it, until the axis of the cylinder is in the right direction. If this glass fails to afford the required improvement, try other cylindricals in succession, until the one which gives the greatest benefit has been selected. For convenience of testing the spherical and cylindrical glasses together, a double spectacle-frame should be used, in which the spherical lens should be placed next the eye, and the cylindrical outside, so that it can be easily rotated with the finger. Each eye should be tried separately, the hand being placed over the one which is not under examination. Having selected the combina-

* Report of Fourth International Ophthalmic Congress, p. 109.

tion of spherical and cylindrical glasses, directions should be sent to the optician to furnish the patient with spectacles with the proper spherico-cylindrical lenses. In the written instructions given to the optician, the focal power of each glass should be separately noted, and the direction in which the axis of the cylindrical glass is to be worn, marked by the sign of an arrow; it should be also mentioned that the spherical face of the lens is to be placed next the eye. The glasses should be fitted in frames with circular eye-pieces, so that the axis of each may be accurately adjusted to the eye before the frames are screwed up.

Mixed Astigmatism.—For the relief of this form, bi-cylindrical glasses will be required. Find out the convex plano-cylindrical lens which will neutralize the hypermetropia in the one meridian, and then the concave plano-cylindrical which will correct the myopia in the other meridian. Place now the two lenses in a double spectacle-frame with the axis of the cylinders at right angles to each other, and rotate the two together in front of the eye, so as to ascertain in what direction of the axis the patient has the best sight. Having decided these points, similar lenses may be ordered to be united by Canada balsam, or a similar bi-cylindrical glass may be ground by the optician.

ASTHENOPIA.

ASTHENOPIA OR WEAK SIGHT is a symptom due to several affections of the eye. The patient complains that reading, writing, or the maintenance of fine work which requires a close application of the eyes, induces fatigue: that when thus engaged the object becomes dim and confused, and sometimes suddenly disappears; that if he rests his eyes for a few minutes he is able to resume his work, but in a short time he is again obliged to desist from a recurrence of similar symptoms.

Asthenopia may depend—1, on hypermetropia; 2, on an insufficiency of power of the internal recti, which renders a prolonged convergence of the eyes difficult and sometimes impossible.

1. **ASTHENOPIA DUE TO HYPERMETROPIA** is called also **Accommodative Asthenopia**. It arises from the excessive strain on the accommodation which hypermetropic eyes have to exert to focus the diverging rays of near objects. Fatigue is consequently soon induced,

the accommodative effort is first partially relaxed, and the object under attention being thrown out of focus, becomes confused and dim; in a few minutes all effort of accommodation is suspended, and the impression is lost. After a short rest the patient can resume his work, but the recurrence of the same confusion of sight soon compels him to give up and to cease from his employment.

Treatment.—Properly fitted convex glasses for reading, writing, sewing, or all close work. (See *HYPERMETROPIA*, p. 257). This form of asthenopia is often much increased by anæmia and debility. In such cases tonics, and especially the preparations of iron, are of great service, and should be prescribed (F. 80, 81).

2. **Asthenopia from Insufficiency of the Internal Recti**, so frequently met with in myopia, is called **Muscular Asthenopia**, to distinguish it from the preceding form. It is due to a want of sufficient power in the internal recti to maintain a steady and prolonged convergence of the eyes on a near object. The patient complains that after reading for a short time the letters become confused, and the lines seem to overlap or run into one another. This is caused by a relaxation of one of the internal recti and a consequent eversion of the eye, giving rise to slight diplopia. Even when these symptoms are absent, the great effort which is required to maintain convergence when there is an excess of power in the external recti muscles induces such an amount of fatigue and aching of the eyes as to compel the patient to give up work.

To ascertain if there is an insufficiency of the internal recti, direct the patient to look at the end of your finger, which is to be held at ten or twelve inches from his eyes, and then slowly approach it towards them, telling him to continue looking fixedly at it as it draws nearer. If there is an insufficiency, the eyes will be unable to maintain the necessary convergence as the finger advances to within six inches, and one of them will first waver and then gradually roll outwards. Sometimes this eversion of the eye is almost spasmodic, so quick and sudden is its movement. Often in such cases there is a difference in the focal power of the two eyes, and then the one which deviates is the more myopic, or, in other respects, the more defective of the two. The degree of insufficiency of the internal recti muscles may be accurately

tested by the means of prisms. (See Article on this subject, page 289.) If after a careful examination there is found to be such an insufficiency of the internal recti muscles, that they are unable to maintain a joint and prolonged convergence of the eyes for near objects, the external rectus of one or both eyes should be divided. It is best to divide one at a time, unless the insufficiency is very marked, and the eye to be selected for the first operation should be the one which is the more defective and generally wanders outwards. The external rectus of the other eye can be afterwards divided if the effect gained by the first operation is not sufficient.

THE METRICAL SYSTEM OF NUMBERING GLASSES.*

At the Congress of Ophthalmologists who met at Heidelberg in 1875, and also at the International Medical Congress which met at Brussels the same year, the new metrical system for numbering glasses was adopted. The principles were:—

1. The substitution of the metre for the inch.
2. The choice of a unit sufficiently small so that the numbers of the lenses generally in use may be expressed in whole numbers and not in fractions, the interval between the numbers being as near as possible the same.

The unit of the Dioptric system, the No. 1 of the new series, is a lens with a focal distance of one metre. This unit is called a Dioptre. The metre consists of 37 Paris inches or 39.4 English, but for all practical purposes it may be considered as 40 English inches. As, however, nearly all the English opticians use the Paris inch in the manufacture of their glasses, it will be well to consider the metre as of 37 Paris inches.

The lens of one dioptre corresponds to a glass of one metre focal length, or 37 Paris inches of the old series—

$$\begin{aligned} 2 \text{ dioptres to } \frac{2}{37} &= \frac{1}{18.5} \text{ or 18 of the old series,} \\ 3 \text{ dioptres to } \frac{3}{37} &= \frac{1}{12.3} \text{ or 12 of the old series,} \end{aligned}$$

and so on to 20 dioptres, which is twenty times stronger than No. 1.

* Abstract from the paper, by Dr. Landolt, translated and published in the Royal London Ophthalmic Hospital Reports, vol. vii. p. 632.

By thus following the whole numbers, a series of lenses is obtained which has an interval of one dioptré between each. In practice, however, we often require lenses of less power than one metre focal distance, and also lenses of powers intermediate to the whole numbers. To meet these demands, fractions of a dioptré have been introduced, thus—

$$\begin{array}{lll} \frac{1}{4} \text{ of a dioptré } 0.25 = 148 \text{ of the old series,} \\ \frac{1}{2} \quad \quad \quad \quad \quad \quad 0.5 = 74 \text{ of the old series,} \\ \frac{3}{4} \quad \quad \quad \quad \quad \quad 0.75 = 49 \text{ of the old series.} \end{array}$$

The quarter of a dioptré has also been introduced between the weak numbers of the series up to No. 2.5, and the half of a dioptré from No. 2.5 up to No. 6. A series of thirty-three lenses has been selected. The intervals between the numbers of this series is 1 or $\frac{1}{2}$ or $\frac{1}{4}$ of the dioptré. In every case the interval can be easily reckoned by a simple subtraction of two whole numbers. In this way it can, with facility, be calculated how much one glass is stronger than another, and how much a presbyopia or ametropia has increased or diminished.

To express in dioptries the value of any glass which has been numbered by its focal distance we have only to remember that 1 metre equals 37 Paris inches, and that 1 dioptré (D) corresponds to a lens of 37 inches focal distance.

$$\begin{array}{lll} 2 \text{ D} = \frac{2}{37} = \frac{1}{18.5} \text{ or } 18 \text{ of the old series,} \\ 3 \text{ D} = \frac{3}{37} = \frac{1}{12.3} \text{ or } 12 \text{ of the old series,} \\ 4 \text{ D} = \frac{4}{37} = \frac{1}{9.25} \text{ or } 9 \text{ of the old series,} \end{array}$$

and so on.

We proceed in an inverse manner when we wish to find the dioptré corresponding to a given number of the old system—that is to say, we divide 37 by the number of the glass. Thus, take for example No. 17 of the old system. The number of times $\frac{1}{37}$ is contained in $\frac{1}{17}$ gives us the value of No. 17 in the new system. Now, to divide $\frac{1}{17}$ by $\frac{1}{37}$ is equivalent to dividing 37 by 17, and we have as a result $\frac{37}{17} = 2.25 \text{ D.}$

The following table shows the number of each glass in dioptries, and the corresponding number of the focal distance of the glass in Paris and English inches:—

In ordering glasses it is well to note after the No. of the D specified, "English" or "Paris" inches.

Dioptres.	Focus in Paris inches.	Focus in English inches.
0.25	148	160
0.50	74	80
0.75	49.3	53.3
1.	37	40
1.25	29.6	32
1.5	24.6	26.6
1.75	21.1	22.8
2.	18.5	20
2.25	16.4	17.7
2.5	14.8	16
2.75	13.4	14.5
3.	12.3	13.3
3.5	10.5	11.4
4.	9.25	10.
4.5	8.2	8.8
5.	7.4	8
5.5	6.7	7.2
6.	6.1	6.6
7.	5.2	5.7
8.	4.6	5.
9.	4.1	4.4
10.	3.7	4.
11.	3.3	3.6
12.	3.08	3.3
13.	2.8	3.07
14.	2.6	2.8
15.	2.4	2.6
16.	2.3	2.5
17.	2.1	2.3
18.	2.05	2.2
19.	1.9	2.1
20.	1.8	2.

CHAPTER VII.

STRABISMUS.

DONDERS defines strabismus as "a deviation in the direction of the eyes, in consequence of which the two yellow spots receive images from different objects." *

Strabismus may be either convergent or divergent; it is seldom that the deviation is solely upwards or downwards.

In most cases there is a preponderance of power in either the internal or external rectus muscle, so that the balance between them is destroyed, and the ability to steady the two eyes simultaneously on an object is lost. Whenever an attempt is made to look at a given point, one eye rolls either inwards or outwards according to whether the squint is convergent or divergent; the optic axes are no longer parallel, and the impressions of the image fall on different parts of the two retinae.

Monocular Strabismus is when the deviation is constant in the one eye. It is generally associated with impairment of sight in the squinting eye.

Alternating or Binocular Strabismus is when the deviation occurs alternately, first in one eye and then in the other. The patient can "fix" with either eye, but is unable to direct the two together towards the same point. When one eye is fixed, the other rolls inwards, and *vice versa*. In alternating strabismus the sight of the two eyes is nearly equal.

Strabismus may be either *periodic* or *persistent*.

A **Periodic Squint** comes on only at times, as when the patient is reading or looking fixedly at an object, or after the eyes have been fatigued. It may be caused by some eccentric irritation, as from ascarides, or from dentition, but in the large majority of cases it is due to hypermetropia. A periodic squint may be occasionally benefited by judicious treatment; but more frequently the strabismus increases, and ultimately becomes *persistent*.

(For treatment of PERIODIC SQUINT, see page 278.)

The Movements of the Squinting Eye.—In some

* Donders, On the Accommodation and Refraction of the Eye, p. 291.

cases there is an actual limitation of movement in the squinting eye, and its range outwards if the squint is convergent, or inwards if it is divergent, is impeded. This may be due either to an acquired increase of power in the squinting muscle, as in some cases of hypermetropia; or it may be caused by a loss of power in the antagonistic muscle, as in myopia, where there is frequently an external strabismus consequent on an insufficiency of the internal recti; or as in cases of paralytic squint.

Generally, however, the range of action of the squinting eye is not limited, but displaced, and this is especially noticeable when the sight of the two eyes is equal, and the squint alternates. Thus, before an operation for an internal strabismus, the space over which the eyes move may be three-quarters of an inch; after the operation the range may still be the same, but it will be transposed, and although the eye will travel over no greater distance than before, yet it will be enabled to go more outwards, and consequently less inwards.

STRABISMUS MAY BE INDUCED, 1st, by some anomaly in the refraction of the eyes, as in hypermetropia and myopia; 2nd, from defective sight in one eye—whatever cause prevents binocular vision tends to produce squint, no matter whether it be from great differences in the refraction of the two eyes, as from amblyopia, or from opacities of the cornea; 3rd, strabismus may be produced by paralysis of one or more of the nerves supplying the muscles of the eye.

To ascertain and note the extent of the Strabismus the patient should be first told to look at an object about twenty inches distant, when it will be found that whilst the "fixes" with one eye, the other rolls either inwards or outwards, as the squint may be. A mark is then to be made with a pen on the edge of the lower lid of the squinting eye opposite the centre of the pupil. The sound eye must now be covered with the hand, and the patient directed to look at the object with the squinting eye, and the position of the centre of the pupil is again to be marked on the edge of the lower lid. The space between these lines will indicate the degree of the strabismus, thus, we speak of a strabismus of 1", 2", or more, according to the interval between the markings on the lid. The movement which the squinting eye makes when the sound eye "fixes" upon an object is termed the primary deviation.

The secondary deviation is the extent of movement the sound eye makes when excluded by the hand, whilst the squinting eye fixes itself on the object. The strabismus is said to be *concomitant* when the primary and secondary deviations are equal. The squinting eye is not fixed, but follows the other in its movements.

The degree of strabismus may be carefully estimated by a "Strabismometer," invented by the late Mr. J. Z. Laurence. "It consists of an ivory plate, moulded to the conformation of the lower eyelid, the free border corresponding to that of the lid. This border is graduated in such a manner that, while its centre is designated by 0, Paris lines and half lines are marked off on each side of 0. Attached to the plate is a handle. The application of this strabismometer is obvious. The ivory plate is applied to the lower eyelid, the borders of the two corresponding. If the cornea is central, the vertical diameter of the pupil corresponds to 0; if inverted, to a graduation on the inner side of 0; if everted, to one on the outer side of 0." *

CONVERGENT OR INTERNAL STRABISMUS is usually dependent on hypermetropia. In 77 per cent. of the cases of convergent strabismus, Donders found that there was hypermetropia.† The explanation of this fact is the following:—Owing to the peculiar shape of the hypermetropic eye, the accommodative power is called into constant action, and for near objects the strain is very great. In proportion to the effort to accommodate is the degree of convergence of the eye, so that when a hypermetropic eye is looking at a near object it converges more than a normal or emmetropic eye would do, because the stress on the accommodation is greater. This excessive action of the internal recti muscles causes them to acquire increased strength, and gradually to preponderate over their antagonists the external recti, until ultimately a convergent strabismus is established.

In hypermetropia the strabismus usually first appears at the time the child begins to apply his eyes to close work, as in learning to read, when the efforts of accommodation and convergence are brought into more active

* Optical Defects of the Eye, by J. Z. Laurence, p. 107.

† Donders On the Accommodation and Refraction of the Eye, p. 292.

play. The degree of strabismus is not necessarily proportioned to the extent of the hypermetropia. In very hypermetropic eyes the sight is so defective, and so little benefited by any accommodative effort, that the patient ceases to strain his eyes, and consequently convergent strabismus is less frequent than in eyes with a lower degree of hypermetropia, where, by a strong endeavour to accommodate, the sight is materially improved. In hypermetropic strabismus there is frequently a considerable difference in the refraction of the two eyes. Defective vision in one eye, combined with hypermetropia, but irrespective of it, tends strongly to convergent strabismus.

Another cause of internal strabismus is paralysis of the sixth nerve. (See page 297).

DIVERGENT STRABISMUS is generally associated—
 11, with myopia. According to Donders, about two-thirds of the cases are due to this cause; and if with the myopia there is a large posterior staphyloma, the tendency to divergent strabismus is increased. In myopia there is frequently an insufficiency of power in the internal recti, and a predominance being thus given to the external muscles, divergent squint is produced. This insufficiency may be partly caused by the peculiar lengthened shape of a highly myopic eye, which not only mechanically impedes convergence beyond a certain point, but also diminishes the fulcrum upon which the internal recti act. If a well-marked hypermetropic eye be contrasted with a highly myopic one, this will at once be evident. As the internal recti are inserted in front of the horizontal equator of the eye, the abrupt curve of the almost globular hypermetropic eye, round which the muscles curve to their insertion, gives to them an excess of power and an undue facility of action which favour convergent strabismus; whilst in the highly myopic eye the conditions are reversed, the globe is lengthened, the curve of its equator is diminished, and from its elongated shape its facility of movement is reduced. Under these circumstances the tendency in myopia is for the internal recti to lose power, and for the eye to diverge.

Another explanation of the predominance which the external recti so often acquire over their antagonists in myopia is to be found in the great refractive power of the myopic eye, which diminishes the necessity for extreme

convergence in looking at near objects, and favours divergence in striving to look at those at a distance.

2. Divergent strabismus may be caused by a difference in the refractive powers of the two eyes when both are myopic. For all close work the better eye is used, and the defective eye failing to receive an impression of the object sufficiently strong to stimulate it to convergence rolls outwards.

3. Defect of sight, amounting to, or approximating, blindness, will produce divergent strabismus.

4. Divergent strabismus may follow an improper or ill-advised operation for convergent strabismus.

5. Divergent strabismus may be produced by paralysis of the third nerve (see page 295).

Treatment of Strabismus.—Inquire carefully into the patient's history, and endeavour to ascertain the duration and cause of the squint. Test the vision of both eyes; note their range of action; find out whether the strabismus is periodic or persistent, and measure the extent of the deviation. If there is a faulty state of the refractive powers of the eye, try to neutralize the defect with proper glasses.

When *periodic* squint is suspected to arise from ascariides, dentition, or gastric derangement, the first treatment must be the removal of the source of irritation, and when this is accomplished, the eyes may possibly resume their normal position. If, however, the periodic squint is due to some anomaly in the refraction of the eye, an attempt should be made to rectify the defect by the use of properly fitted glasses, and if the trial is made sufficiently early there is a fair chance of success. In all cases of strabismus which are dependent on a faulty state of the refractive powers of the eye, as in hypermetropia or myopia, the eyes should be provided with proper glasses, which should be worn even if an operation be afterwards performed.

Having decided on an operation, it at once becomes a question whether it will be necessary to divide the tendons of the corresponding muscles in both eyes, or whether a tenotomy in one eye will suffice. Generally it is better to operate on both eyes, and to divide each tendon as close to the globe and with as little disturbance of the adjacent tissues as possible. In this way the effect to be obtained is apportioned between the two eyes, and the result, I think, is better than when by a more free division of the

subconjunctival fascia and a separation of it from the neighbouring parts, the operation is confined to the one eye. In many cases, however, it is prudent to operate first on the one eye only, and then to wait to ascertain the exact effect it has produced before proceeding to divide the tendon in the other eye. This rule should be observed in the treatment of strabismus due to a great defect of sight in one eye, and especially if there is a marked limitation of movement in the squinting eye: it should also be followed in slight cases of alternating strabismus.

The operation for strabismus which I prefer is the one most frequently adopted at the Moorfields Hospital. It is strictly a subconjunctival operation, in the sense that the division of the tendon is accomplished beneath that membrane, the opening in it for the necessary introduction of the instruments being opposite the inferior edge of the tendinous insertion of the muscle.

FIG. 56.



THE MOORFIELDS OPERATION FOR STRABISMUS.—The lids are to be separated by a stop-speculum. The surgeon with a pair of finely-toothed forceps takes hold of the conjunctiva, and often at the same time of the deep fascia over the lower edge of the insertion of the rectus tendon, and with a pair of blunt-pointed scissors makes a small opening through both these structures, the cut being directed towards the globe. If the fascia has escaped the snip of the scissors, it must be seized with the forceps and divided. The blunt hook (Fig. 56) is now passed through the apertures in the conjunctiva and deep fascia, and behind the tendon, which it renders tense by being made to draw it forward and towards the cornea. The points of the scissors are next to be introduced, and slightly separating them, one blade is passed along the hook behind the tendon and the other in front of it, when by a succession of small snips the tendon is divided subconjunctivally on the ocular side of the hook.

The operation is now completed; but, before withdraw-

ing the speculum, Sir W. Bowman usually makes a small counter-puncture in the conjunctiva, by bulging it on the end of the hook in the situation of the upper border of the tendon after its division, and by then snipping it with the scissors; the object being to allow any of the effused blood immediately to escape, instead of diffusing itself over the sclerotic.

This operation is equally applicable to the division of either the internal or external rectus muscle. It must, however, be remembered that the tendon of the external rectus is inserted into the globe in a line much farther back than that of the internal muscle.

GRAEFÉ'S OPERATION FOR STRABISMUS.—The eyelids having been separated by a speculum, the assistant

FIG. 57.



with a pair of forceps draws the eye outwards if the internal rectus is to be divided, and inwards if the operation is to be on the external rectus. The operator then with a pair of finely toothed forceps seizes hold of a fold of the conjunctiva and subjacent tissue close to the cornea, and at a point a little below the centre of the insertion of the muscle. This he cuts through with a pair of scissors slightly curved on the flat, and then burrowing with their points a little distance above and below the opening he has made, he freely detaches with a few snips the subconjunctival tissue from the muscle. The squint hook (Fig. 57) is now passed beneath the lower border of the tendon, which is to be divided with the scissors as close as possible to its insertion into the globe. After the tendon has been cut through, the divided conjunctiva should be raised with one hook, whilst the operator with another hook explores the wound both upwards and downwards to see if any part of the tendon or of its lateral expansion has escaped division. If the whole tendon has been cut through, the exploring hook will glide readily up to the margin of the cornea; but if its progress should be checked by catching behind some undivided part of the tendon, the scissors must be again used to sever that which still remains uncut.

LIEBREICH'S OPERATION FOR STRABISMUS.—

The following is Dr. Liebreich's account of his "Modification of the Operation for Strabismus," which was first published in the "British Medical Journal," December 15, 1866:—"If the internal rectus is to be divided, I raise with a pair of forceps a fold of conjunctiva at the lower edge of the insertion of the muscle; and, incising this with scissors, enter the points of the latter at the opening between the conjunctiva and the capsule of Tenon; then carefully separate these two tissues from each other as far as the semilunar fold, also separating the latter, as well as the caruncle from the parts lying behind. When the portion of the capsule which is of such importance in the tenotomy has been completely separated from the conjunctiva, I divide the insertion of the tendon from the sclerotic in the usual manner, and extend the vertical cut, which is made simultaneously with the tenotomy, upwards and downwards—the more so if a very considerable effect is desired. The wound in the conjunctiva is then closed with a suture."

"The same mode of operating is pursued in dividing the external rectus; and the separation of the conjunctiva is to be continued as far as that portion of the external angle which is drawn sharply back when the eye is turned outwards."

The advantages which he claims for his operation are—

"1. It affords the operator a greater scope in apportioning and dividing the effect of the operation between the two eyes.

"2. The sinking back of the caruncle is avoided, as well as every trace of a cicatrix, which not unfrequently occurs in the common tenotomy.

"3. There is no need for more than two operations on the same individual, and therefore of more than one on the same eye."

Treatment of Strabismus after the Operation.—As a rule no local application is required for the eyes beyond frequently washing them with a little tepid water to clear them from the slight conjunctival discharge which usually follows for a few days after the operation. If the eyes are hot or painful, a fold of linen wet with cold water may be laid over the closed lids, but the eyes should *not* be tied up with a bandage, as it is apt to increase the sense of heat and to add to the dis-

comfort of the patient. When the tendon of one eye only has been divided, the eye which has *not been operated on* should be covered with a single turn of a bandage immediately after the operation, so as to compel the patient to use the squinting eye, and thus to keep it in a central position until the divided tendon has acquired its new insertion. If there is much ecchymosis on the second or third day after the operation, the eye may be frequently washed with a little weak lead lotion (F. 52); or if there should be a muco-purulent discharge a mild astringent lotion (F. 48, 50) may be used three or four times daily.

DIVERGENT STRABISMUS FOLLOWING THE DIVISION OF ONE OR BOTH THE INTERNAL RECTI MUSCLES.—This result may occur from the division of both internal recti when one only was required; or it may follow a too free division of the subconjunctival fascia; or it may arise from the tendon having been divided at too great a distance from its insertion into the globe. In both of the last-mentioned cases the muscle recedes too much, and takes its new insertion into the globe so far back that it loses more of its power than is necessary for the correction of the squint, and consequently gives to the external rectus a predominance which makes the eye diverge.

It is also probable that the extreme divergence which occasionally follows the division of one or both of the internal recti muscles may be due to the tendon of one or both muscles not having contracted a firm union to the globe, but having become united to it through the medium of a thin fibrous tissue which admits of great stretching. In such cases the internal recti lose power, and the eyes gradually fall under the control of the external recti, which draw them completely outwards.

With this form of strabismus there is nearly always associated a sinking back of the caruncle, a defect which gives an unsightly prominence to the globe, and favours its eversion.

Treatment.—If divergence follow shortly after an operation for a convergent strabismus, in which the internal recti of *both eyes* have been divided, a subconjunctival tenotomy should be performed on both the external recti, and this should be done even though the divergence be slight, as when once established the eversion will steadily

increase. If, however, the divergence is the result of a too free division of the internal rectus and adjacent tissues of *one eye*, then the external rectus of that eye only should be divided; and if this fails to correct the outward deviation, the tendon of the internal rectus must be brought forward by an operation at a subsequent period. Whenever the divergence is considerable and the power of inversion limited, the simple subconjunctival division of the external recti will not restore the eyes to position, but the operation which was suggested by the late Mr. Critchett must be performed on one or both eyes according to the circumstances of the case.

STRABISMUS FOLLOWING PARALYSIS OF THE OPPONENT MUSCLE.—There are two ways in which this form of strabismus may be caused:—

1. The paralysed muscle may have regained a certain amount of power, but not sufficient to neutralize its opponent muscle; a strabismus therefore continues.

2. The persistence of the squint after the paralysed muscle has recovered its power may be due to a contraction of the non-paralysed muscle induced by the loss of resistance of its opponent during the period it was paralysed.

Treatment.—If the patient has derived all the benefit that can be reasonably anticipated from a long-continued constitutional treatment and a squint still remains sufficient to cause diplopia or to be unsightly, the tendon of the opponent to the paralysed muscle should be divided. If this fail in rectifying the strabismus the insertion of the paralysed muscle should be brought forward in the manner described in the next section.

CRITCHETT'S OPERATION FOR BRINGING FORWARD THE INSERTION OF THE INTERNAL RECTUS MUSCLE.—The lids are to be separated with the ordinary spring speculum and the eye is to be drawn inwards whilst the operator divides subconjunctivally the tendon of the external rectus. The division of this muscle at the commencement of the operation facilitates the further proceedings. A vertical cut is now to be made with a pair of scissors through the conjunctiva and deep fascia in a line corresponding with the inner margin of the cornea, but at $1\frac{1}{2}$ " or 2" from it, and then with a few successive snips the conjunctiva and subjacent fascia

are to be separated from the inner side of the globe as far back as the inner caruncle. In doing this, care must be taken to divide the new insertion of the internal rectus so that in drawing forwards the tissues which have been thus detached from the globe, the tendon of the internal rectus will be raised with them. A vertical slip of the conjunctiva and fascia is now to be cut away, and the edges of the wound are then to be brought accurately together with sutures. To accomplish this, three stitches of the finest silk will be required: the centre one should be inserted first; it should be passed through the slip of conjunctiva which was left at the edge of the cornea, and through the deep fascia and conjunctiva close to the caruncle, so that when fastened, the eye will be drawn inwards and the caruncle raised. The upper and lower stitches are next to be introduced, and the assistant then gently inverts the eye whilst the threads are being tied. When all is completed the eye should have a decided internal strabismus, as the after-result is always considerably less than that which is obtained at the time of the operation. For the first twenty-four hours after the operation a fold of linen, wet with cold water, should be applied over the closed lids, and it may be continued as long as the eye feels hot or painful. The stitches should be removed about the fourth or sixth day after the operation.

Mr. Tweedy has made a modification of Critchett's operation for bringing forward the internal rectus muscle, which possesses many advantages.*

The following is a summarized description of his operation.

"The operation consists of ten stages, as follows:—

"1. The lids being kept apart with a speculum, a fine silk thread is inserted into the conjunctiva and episcleral tissue, in a line with the horizontal diameter of the cornea, and about one-sixteenth of an inch from the inner margin of the cornea. The ends of the thread are left long with the needle attached (see Fig. 58). (The preliminary insertion of this thread marks, and afterwards indicates, the horizontal meridian of the eyeball, and still later serves as a suture for the middle of the rectus muscle.)

"2. Next, a crescentic incision is made immediately to

* Lancet, March 22, 1884, p. 512.

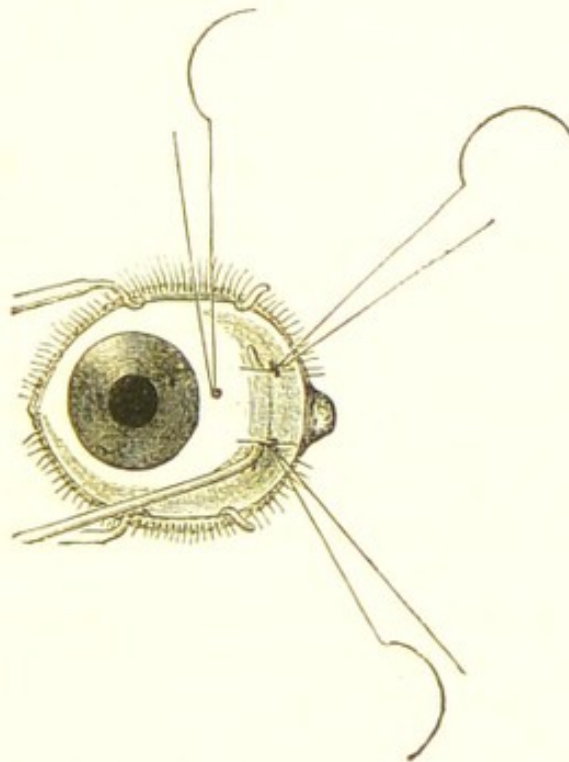
the nasal side of the thread and through the conjunctiva only.

"3. The conjunctiva is then gently detached from the underlying capsule towards the caruncle, but only far enough to expose the insertion of the rectus muscle; not to strip the muscle.

"4. A strabismus hook is then passed under the muscle.

"5. While the hook is in position fine silk threads are attached to the upper and lower borders of the muscle and left long (see Fig. 58).

FIG. 58.



"6. The hold of the threads having been tested by gentle traction, the muscle is divided on the hook. (The operator is now sure that he has secured the tendon.)

"7. The muscle is then carefully raised by means of the threads, and any remaining attachments of the muscle to the globe completely divided.

"8. The needle attached to the thread at the inner border of the cornea is passed through the middle of the divided muscle from within outwards, and in such a way as to penetrate the muscle and its sheath and overlying conjunctiva.

"9. The needles attached to the threads at the upper and lower borders of the muscle are now insinuated into the episcleral tissue, and made to emerge on the surface

of the conjunctiva at about one-eighth of an inch from the upper and lower margins of the cornea respectively. This gives a broad and fan-like attachment to the muscle.

"10. The external rectus is now freely divided subconjunctivally, and then, while an assistant rotates the eyeball inwards, the corresponding ends of the three sutures are closely and firmly tied and cut short.

"Should shortening of the internal rectus muscle or removal of redundant conjunctiva be deemed necessary, it may be done just before the ninth stage. To ensure a complete and permanent result, there should be some convergence of the eye immediately after the operation, and no attempt should be made to exercise the muscle for a week afterwards."

PARALYSIS AND SPASM OF THE CILIARY MUSCLE.

PARALYSIS OF THE CILIARY MUSCLE.—This affection is usually occasioned by some depressing illness, and especially fever and diphtheria. It is generally first noticed during the convalescence, when it is discovered accidentally by the patient. The paralysis varies greatly in its extent, but it is seldom complete. It mostly attacks children, but I have met with it once in an adult, an account of which case I published in the "*Lancet*."*

Paralysis of the ciliary muscle may be induced artificially by frequent instillations into the eye of a strong solution of atropine (F. 16).

Symptoms.—A loss of the accommodative power of the eye in proportion to the degree of the paralysis; things far off are seen clearly, but those which are near are either very misty or quite indistinguishable. The far point of vision is unaltered, but the near point is carried to a distance from the eye. With a convex glass near objects are again rendered distinct; the strength of the lens which an emmetropic eye affected with paresis requires for near vision affords a fair estimate of the loss of power it has sustained. In a severe case the patient may be unable to see distinctly No. XVI. of Jaeger, and yet with proper convex glasses read with facility No. I.

The following account of a child who was under my

* *Lancet*, May 11, 1861.

care suffering from paralysis of the accommodation of the eye is a good example of this disease : *

W. R., æt. eleven, a pale, delicate, but bright and intelligent lad, was brought by his father to the hospital on account of what appeared a sudden great impairment of vision of both eyes. His history was, that up to a fortnight previously he had always had good sight, and could read and write with perfect ease. Six weeks before coming to the hospital he had a low fever, from which he made a fair recovery, but was much reduced by it. One day, shortly after his illness, he discovered on attempting to read that he was unable to do so, but that he could distinguish objects at a distance. Examined with Jaeger's test types, he could only read No. XVI. at fifteen inches from his eyes, but he could with facility tell the hour of the hospital clock at twenty-six feet. With a convex lens of 24" focus he could read at twelve inches No. XII. ; with a lens of 18" focus No. VIII. ; with one of 12" focus No. IV. ; and with a 9" focus lens No. I. This boy was treated with purgatives, iron, and good diet, and perfect rest to the eyes, and within a month he was able to read No. I. perfectly with either eye, and could see as well as ever he did.

The prognosis is favourable. All the cases I have seen have ultimately recovered.

Treatment.—Absolute rest to the eyes ; no convex glasses should be given to allow the patient to read. For children the preparations of bark or iron (F. 138, 139, 144, 146) should be prescribed, with change of air. For adults, the *mist. acidi cum cinchonâ* (F. 75) or the *mist. ferri perchlor.*, either with or without small doses of *strychnia* (F. 84, 86).

As a *local application*, the eyes may be frequently bathed with cold water, or a cold douche may be used with the lids closed.

SPASM OF THE CILIARY MUSCLE is a rare but an occasional complication of hypermetropia, which it masks by rendering the eye temporarily myopic, so that distant vision is improved by concave glasses. It is usually induced from overstraining hypermetropic eyes in repeated endeavours to read or do close work, without the aid of proper convex glasses. It is productive of pain and a feeling of tension of the eyes after using them for a short time at near objects, as in reading, writing, &c. This affection may be diagnosed by the ophthalmoscope, when, in spite of the apparent myopia, the eye exhibits a

* Lancet, October 14, 1862.

hypermetropic refraction. It may also be detected by placing the eye completely under the influence of atropine, so as to paralyse the ciliary muscle, and then testing the refraction with convex glasses. (See Article **HYPERMETROPIA**, p. 257).

Spasm of the ciliary muscle may be caused artificially by applying the Calabar bean to the eye. (See Article **CALABAR BEAN**, p. 98.)

Treatment.—Order the patient to abstain from all work, and use the guttæ atropiæ (F. 16) twice daily for several days. The eye may be then tried with convex glasses, and having ascertained the degree of hypermetropia, suitable spectacles may be ordered, but they should not be worn until the eyes have had at least five or six weeks' complete rest.

DIPLOPIA.

DIPLOPIA, or double vision, is produced by any cause which prevents the optic axes from being directed jointly on the same point, so that the impressions cannot fall on corresponding parts of the two retinæ. Two objects are seen, a true and a false one, the latter varying in position with respect to the former according to the strabismus which is given by the excess of power in one or more of the ocular muscles. The existence of diplopia of course implies that the patient has binocular vision.

There are two forms of diplopia, **homonymous** and **crossed**.

Homonymous or **Direct Diplopia** is met with in convergent strabismus, when the rays from the object fall in one eye on the retina internal to the yellow spot. The false impression is projected outwards, and, if emanating from the right eye, is seen on the right or outer side of the true object.

Crossed diplopia occurs in external or divergent strabismus, when the rays from the object are brought to a focus in one eye on the retina external to the yellow spot. The false image is projected inwards across the nose: thus, if it proceed from the right eye it is seen on the left of the true object.

THE ACTION AND USES OF PRISMS.

The rays of light as they pass through a prism are deflected towards its base; hence it is, that if a prism is

placed in front of the eye with its base towards the nose, the rays being bent inwards will be brought to a focus at a point internal to the yellow spot. The patient would now have diplopia; but in order to unite the two images and bring them on corresponding parts of the two retinae, the squints involuntarily outwards, and if the prism is a weak one, he succeeds in overcoming the displacement. The strabismus which is thus produced is called a *corrective* squint. But if the prism is strong, the patient is unable in this manner to correct the displaced image, and he has diplopia.

Prisms will be found useful—

1. To ascertain the presence of binocular vision.
2. To test the strength of the muscles of the eye.
3. To wear as spectacles to correct diplopia.

1. To Ascertain the Presence of Binocular Vision, that is, to determine whether the patient uses both eyes in looking at an object. Place a prism of about 112° in front of one eye with its base outwards; if there is at once a corrective inward squint, we may be satisfied that the patient enjoys binocular vision. If, however, there is no movement of the eye, and no diplopia, it shows that the patient does not use that eye, but that he is looking with the other, and has not therefore binocular vision. If now the prism is placed before the eye which he does use, it will at once move slightly inwards, but it will not be a corrective squint, for the non-seeing eye will at the same time go an equal distance outwards; this latter, however, is only an associated movement. This mode of examining the eye is often of great service in detecting impostors, who, for some reason known only to themselves, are feigning the loss of sight of one eye—in many cases for the sake of compensation after injury.

2. To Test with Prisms the Relative Strength of the Muscles of the Eye.—A normal eye can overcome a prism of from 16° to 24° with its base turned outwards; but with its base inwards, only one of from 6° to 8° —that is to say, by a corrective squint it can so readjust the displaced image on the retina that there is no diplopia, but binocular vision. In order to determine the degree of insufficiency of power of the internal recti, try what is the strongest prism with its base turned outwards each eye is able to overcome. A lighted candle should be placed seven or eight feet in front of the patient, at which

he is to be directed to look. If he is short-sighted, sufficiently powerful concave glasses should be given to him to enable him to see the light distinctly. Prisms of increasing strengths should now be held in succession with their bases outwards before one eye, until it is decided which is the strongest he can see through without diplopia. The power of the prism which he can thus overcome, compared with that which a normal eye can master, will indicate the degree of insufficiency of the internal rectus of that eye. The other eye must then be tested in a similar manner. It will be thus sometimes found that the strength of the internal muscles has been so reduced, that instead of being able to correct the displaced image produced by a prism of 16° to 24° as in the normal eye, they can only overcome one of from 4° to 6° . Conversely, the strength of the external recti may be ascertained by testing the eyes with prisms with their bases directed inwards.

Another method of measuring the strength of the muscles of the eye is as follows:—

A normal eye can only overcome a prism of from 1° to 2° if the base be turned either upwards or downwards. Place, therefore, in front of the eye a prism of a higher degree, and diplopia will be produced; the false object will be projected either directly above or below the true one. If the prism be held with its base upwards, the false image will appear below; and if the base be placed downwards, the wrong impression will show itself above the true one, but they will both appear in the same line. This, however, is on the supposition that the external and internal recti of the two eyes exactly balance each other. *If they do not*, the false object will not only appear either above or below the true one, but it will be cast either to its outer or inner side, according to the predominance of power of the external or internal recti, and the diplopia will be then either crossed or homonymous. A slip of red glass placed in front of one of the eyes will at once determine the form of the diplopia, by giving a coloured tint to one of the objects, and thus indicating which of the two is the false impression. The extent of the insufficiency may then be ascertained by trying what prism, placed in front of the one with its base upwards, will restore the true and false images to a direct line one above the other. Of course, if the diplopia is found crossed, the prisms must be tried before the eye with their bases

turned inwards; and if homonymous, with their bases placed outwards. If the diplopia is crossed it indicates an excess of power in the external recti, and consequently an insufficiency of the internal muscles; and the reverse if the diplopia is homonymous.

3. To Wear as Spectacles to Correct Diplopia.

—In cases of paralytic strabismus, prisms are often of great service, and especially during the progress of recovery from palsy of the sixth, or partial paralysis of the third nerve, in which the internal rectus is the only muscle, or the one principally affected, and where from special reasons the patient objects to keep the eye covered to avoid the diplopia. The spectacles should be furnished with a piece of plain plate glass for the sound eye, and with a rightly adjusted prism for the paralytic one. Whilst using the prism, the patient should be kept under observation, as, if the case is progressing to a favourable termination, the prism will require to be frequently changed for another of a lower degree as the paralysed muscle gradually regains power, until at last its use may be abandoned.

PARALYTIC AFFECTIONS OF THE MUSCLES OF THE EYE.

The subject of paralysis of the separate nerves which supply the muscles of the eye is involved in considerable obscurity, as although in many cases the diagnosis of the paralysis is clear, yet in a vast number it is difficult to assign any satisfactory explanation for the sudden or gradual loss of power in the structures supplied by one particular nerve. Either the third, fourth, or sixth nerve may become paralysed, without their being evidence of disease in any other portion of the nervous system. The loss of power may be sudden, or it may be gradual, the paralytic symptoms increasing daily until they have reached a certain point, at which, for a time, they usually remain stationary. After a variable interval, the nerve, as a rule, begins to recover its tone, and the parts supplied by it ultimately resume their normal action.

The immediate result of paralysis of one of these nerves is a strabismus, caused by a loss of the balance between the muscles of the affected eye. This is termed a **paralytic strabismus**, to distinguish it from those forms of squint which are due to some anomaly in the refraction of the eye. The paralytic strabismus has this cha-

racteristic, that, whereas in the concomitant squint the primary and secondary deviations are equal, in the paralytic the secondary is greater than the primary. This is easily seen by making the following examination:—If the sound eye be covered with the hand, and the patient be directed to look at a given point, the *primary* deviation or movement of the paralysed eye will be far less than the associated or *secondary* movement of the sound one.

If the patient be directed to cover the sound eye with the hand and then to walk across the room, he will suffer more or less from vertigo, and frequently to such an extent as to cause him to stagger in his gait like a drunken man. This inability to co-ordinate the action of the muscles under the direction of the paralysed eye is most marked when the palsy of the nerve is complete. In cases of diplopia from commencing paralysis of an ocular nerve when there is a difficulty in deciding which is the affected eye, a rapid and correct diagnosis may be often made by telling the patient to walk a short distance with his hand placed first over one eye, and then over the other. The affected eye is the one which when the other is closed, induces vertigo.

Paralysis of one or more of the ocular nerves may be caused by—

- a. Intra-cranial disease.
- β. Intra-orbital disease.
- γ. Blood-poisoning, such as syphilis, rheumatism, and gout.
- δ. Reflex irritation.

a. **From Intra-cranial Disease.**—When paralysis of the ocular muscles proceeds from disease of the brain, it is seldom confined to the structures supplied by one particular nerve; or if during the early symptoms only one nerve is involved, there are usually other indications of cerebral mischief. The patient totters or trips in walking, or has pain or giddiness in the head; or, perhaps, has some loss of power in the muscles of expression, or a diminution of sensibility in the skin of the face.

β. **From Intra-orbital Disease.**—Pressure upon any of the ocular nerves in their course along the orbit to the eye will cause a partial or complete paralysis of their functions. This may be induced by a tumour within the orbit, or by an orbital node, or by some inflammatory

or specific exudation either around the nerve or within its sheath.

γ. From Blood-poisoning.—To either syphilis, rheumatism, or gout many of the cases of paralysis of one of the motor nerves of the eye are to be attributed. A thickening of the fibrous sheath of dura mater, through which the nerve runs in its passage to the orbit, or some inflammatory exudation peculiar to the affection from which the patient suffers, may compress the nerve and paralyse its functions. We have illustrations of analogous forms of local palsy in the paralysis of the muscles of the face, from palsy of the portio dura of the seventh nerve, and in facial anæsthesia from palsy of the fifth. Both of these examples may undoubtedly be due to a pressure on the nerves, either from an inflammatory thickening of neighbouring structures, or from some morbid deposit dependent on a blood poison.

δ. From Reflex Irritation.—It is always difficult to obtain direct evidence to prove that the functional disturbance of a nerve is dependent on distant irritation. I think, however, that there can be no doubt but that many of the forms of local paralysis which are met with both in the child and the adult are due to this cause, and that frequently the palsy of an ocular nerve may also arise from it. The most striking illustrations of this class of disease are to be found in the cases of infantile paralysis, where a single muscle, as the tibialis anticus, or the long extensor of the toes, or a group of muscles, as the flexors or the extensors of the leg, become suddenly deprived of power. Mr. William Adams, in speaking of infantile paralysis, says, "It is frequently neither preceded nor accompanied by any cerebral symptoms, and, even when such symptoms show themselves, they are generally of a transient character;" and further on he remarks, "This form of paralysis generally takes place during the period of first dentition, and would seem to be connected with the irritation attending this process;" and, "that a marked characteristic of this affection is a tendency to spontaneous cure."*

On inquiring into the history of many of the cases of palsy of an ocular nerve, no symptoms of syphilis, rheumatism, or gout are to be detected, and there are no evidences of brain disease or mischief within the orbit,

* Club Foot, by William Adams, pp. 51, 62.

A further investigation, however, will frequently discover as the cause of the palsy, some eccentric irritation in a disorder of the liver, stomach, or some other portion of the intestinal canal.

The analogy between infantile paralysis and some of the cases of palsy of the ocular muscles at once becomes manifest. In both, cerebral symptoms may be wanting or may have been only transient; in both, remote irritation may be the exciting cause of the palsy; in children it is usually dentition, and in adults derangement of the abdominal viscera: and, lastly, in both we have the same tendency to spontaneous cure. The nerve which is, I believe, the most frequently affected from reflex irritation is the sixth.

Before describing the symptoms which indicate paralysis of one or more of the muscles of the eye, I will first briefly refer to the anatomy and functions of each of the motor ocular nerves.

THE THIRD NERVE—*motor oculi*—is the largest of the three motor nerves which supply the muscles of the eye. In its course along the outer wall of the cavernous sinus it divides into two branches, a *superior* and an *inferior*, which enter the orbit through the sphenoidal fissure, passing between the two heads of the external rectus.

a. The superior division supplies

The levator palpebræ.

The superior rectus.

β. The inferior division supplies

The internal rectus.

The inferior rectus.

The inferior oblique, and a branch to the lenticular ganglion (its short root).

In addition to the above-named, the third nerve through its branch to the lenticular ganglion supplies, under the name of the ciliary nerves, the muscular structures within the eye, the ciliary muscle and sphincter pupillæ of the iris.

In the outer wall of the cavernous sinus the third nerve communicates with the ophthalmic division of the fifth, and with the cavernous plexus of the sympathetic.

The functions of the third nerve are: to preside over the action of the muscles to which it sends branches, and under the influence of light upon the retina to effect

the contraction of the pupil. "The motor action of the third nerve may therefore be excited through the optic nerve. There can be no doubt indeed, that this is the ordinary method by which contraction of the pupil is produced during life; the stimulus of light falling upon the retina excites the optic nerve, and through it that portion of the brain in which the third nerve is implanted."*

Paralysis of the third nerve may be either complete or partial.

When the paralysis is *complete*, there is an absolute loss of power in all the structures of the eye supplied by the third nerve. The levator palpebræ being paralysed, the upper lid droops over the eye and cannot be raised by the patient. The superior, inferior, and internal recti, and the inferior oblique muscles, have ceased to exercise any control over the movements of the globe, and the eye is under the dominion of the external rectus and the superior oblique, which, acting together, draw the globe outwards and slightly downwards. A strong divergent strabismus is thus given to the eye, and the patient has crossed diplopia, the false object appearing across the nose on the other side of the true one (see **CROSSED DIPLOPIA**, page 288). But in addition to this, the pupil is widely dilated, and from paralysis of the ciliary muscle the accommodation is destroyed. From the complete relaxation of so many of the ocular muscles there is generally a slight protrusion of the globe. If the patient be directed to close the sound eye, he will generally walk with an unsteady gait, and miss the objects he endeavours to seize. Such are the symptoms of a complete paralysis of the third nerve; but it is seldom, except in cases of cerebral disease, or of tumours in the orbit, that all the branches of the nerve are thus affected.

Partial paralysis of the third nerve may exist in two forms.

a. There may be a diminution rather than an absolute loss of power in all the structures which the nerve supplies, and the patient then exhibits the symptoms already described, but in a modified degree. The ptosis is only partial; the pupil is dilated, but not to its utmost,

* Todd and Bowman's Physiological Anatomy, 1st edit. vol. ii. p. 103.

and the accommodative power of the eye is diminished; there is a divergent strabismus with crossed diplopia, but it is not extreme, and with an extraordinary effort the patient can draw the eye either slightly inwards, upwards, or downwards.

β . In many cases, however, of **partial** paralysis of the third nerve, some of its filaments only are affected. The loss of power may be confined to one or more of the recti muscles, any one of which may be separately paralysed; but the palsy is seldom if ever limited to the inferior oblique. The muscle which is the most frequently involved is the internal rectus; it is rare for the superior or inferior rectus to be paralysed whilst the internal muscle remains intact. The pupil is generally more or less dilated, but I have seen it in exceptional cases of its normal size; the levator palpebræ frequently retains its influence over the upper lid, even when one or more of the muscles of the eye are paralysed. There is always some diplopia, the false object varying in position with respect to the true one, in accordance with the muscle or muscles which have lost their power; thus—

In paralysis of the **internal rectus**, there is a divergent strabismus, but the eye can be turned upwards or downwards. The diplopia is crossed, and the false object is on a level with the true one.

In paralysis of the **superior rectus**, the eye is displaced downwards and outwards by the combined action of the inferior and external recti and superior oblique muscles, whenever an attempt is made to look up. The diplopia is crossed, and the false object is above the level of the true one.

In paralysis of the **inferior rectus**, the eye deviates upwards and outwards by the combined action of the superior and external recti and the inferior oblique muscles, when an effort is made to look down. The diplopia is crossed, and the false object is projected below the level of the true one.

THE FOURTH NERVE—*the trochlear*—the smallest of the cerebral nerves, passes along the outer wall of the cavernous sinus, and enters the orbit by the sphenoidal fissure. It then mounts above the other nerves, and running close to the periosteum of the roof of the orbit, it applies itself to the orbital surface of the superior oblique muscle. As it traverses the wall of the cavernous

sinus, it communicates with the sympathetic through filaments from the carotid plexus, and as it enters the orbit, it occasionally gives a branch to the lachrymal nerve. The function of the fourth nerve is entirely motor.

In paralysis of the fourth nerve, the early symptoms are often obscure and easily overlooked; but when the palsy is complete, they are usually sufficiently marked to be diagnosed by a careful examination of the eye. It should be remembered that the function of the superior oblique in health is to roll the eye downwards and outwards, and, that, therefore, no defect of sight arising from a want of power in this muscle will be noticed by the patient so long as his eyes are fixed on objects above the horizontal mesial line.

Paralysis of the superior oblique is occasionally congenital, and frequently in such cases the patient will instinctively incline his head to the opposite side to enable him to get single vision with the two eyes. In a few instances it is probable that this constant habit of holding the head on one side, to correct the diplopia caused by congenital palsy of the fourth nerve has been the cause of wry-neck.

The symptoms which characterize palsy of this muscle are, that whenever an attempt is made to look downwards the affected eye is drawn slightly upwards and inwards, and the patient has homonymous diplopia, the false object appearing to the outer side and below the level of the true one, and slanting towards it. The interval between the true and false impressions, both in latitude and elevation, are increased as the globe is vertically depressed.

THE SIXTH NERVE—*abducens*—crosses the cavernous sinus, lying close against the outer side of the internal carotid artery. It enters the orbit through the sphenoidal fissure, passing between the two heads of the external rectus to the ocular surface of which muscle it is distributed. In its passage through the cavernous sinus it receives sympathetic filaments from the carotid plexus and a branch from Meckel's ganglion. The function of the sixth nerve is entirely motor.

In paralysis of the sixth nerve there is a marked internal strabismus; the eye, when the palsy is complete, cannot be drawn outwards beyond the mesial line of the

orbit, but it can be turned freely in all other directions. There is homonymous diplopia, the false image being projected to the outer side of the true one. If, with the sound eye closed, the patient endeavours to seize an object, he misses his aim, the hand passing to its outer side. In walking he generally turns his head rather towards the side opposite to that of the affected eye, so as to avoid the diplopia by not looking outwards.

All the ocular muscles may be paralysed from cerebral disease, or from tumours of the orbit; the eye is then rendered prominent and stationary in the centre of the orbit.

The prognosis of the paralytic affections of the muscles of the eye is determined by the following considerations:—

a. The Cause of the Paralysis.—When the loss of power proceeds from some syphilitic, rheumatic, or gouty disease, or from some reflex irritation, the prospect of recovery under suitable remedies is favourable. When, however, the paralysis arises from intra-cranial mischief, and is associated with other cerebral symptoms, the prognosis is bad.

β. The Extent of the Paralysis, whether it is partial or complete, or confined to the muscles supplied by one nerve, is an important point to decide. The prognosis is always most favourable when the paralysis is partial and limited to one ocular nerve, and when there are no other symptoms of disease of the nervous system.

γ. The Length of Time the Paralysis has Lasted.—If the loss of power has been persistent, and no improvement has taken place in spite of judicious treatment, the prognosis is unfavourable. There are, however, many cases in which recovery progresses to a certain point, and then ceases; the paralysed muscle does not completely regain its former tone, and a slight strabismus with diplopia remains. For such patients much may be done by local treatment.

Treatment.—If the paralysis is due to syphilis, rheumatism, or gout, the patient must be treated constitutionally, with the medicines suited to these special diseases. In most cases benefit is gained from small and repeated doses of the iodide, or the iodide and bromide of potassium (F. 91. 97), or of the iodide of potassium combined with iron (F. 92). The bowels should be freely opened by a

purgative, and counter-irritation may be used behind the ear, either by rubbing in a stimulating liniment, or by applying a small blister. In syphilitic cases, pil. hydrarg. subchloridi comp. gr. 5 may be given every other night for a short time, or a little of the unguent. hydrarg. may be rubbed night and morning into the temple of the affected eye. Where reflex irritation may be reasonably expected to be the cause of the paralysis, as in certain cases of palsy of the sixth nerve, the source of the mischief must be sought for in some functional derangement of abdominal viscera. The important connection between the sixth nerve and the sympathetic is, I think, quite sufficient to account for its being prejudicially influenced by visceral irritation.

To relieve the diplopia, which is so distressing to the patient, the affected eye should be excluded, either by being covered with a bandage, or by the use of a pair of spectacles with large curved glasses, one of which has been completely darkened. In certain cases, prisms are of the greatest service in uniting the double images, but it must be remembered in using them, that they will have to be repeatedly changed, as the palsied muscle regains its power. For the internal strabismus, from paralysis of the external rectus, the prism must be placed with its base *outwards*; and for the external strabismus, from paralysis of the internal rectus, the prism must be used with its base *inwards*.

When the paralysis is probably dependent on a local affection of the nerve, as from some rheumatic or gouty effusion, Faradization is often of the greatest service, but it should not be recommended if there is any reason to suspect cerebral disease.

Under one or other of the methods of treatment I have described, the majority of the cases of palsy of one of the ocular nerves will steadily progress to complete recovery. There are, however, occasionally instances when the remedies fail, and the muscle having regained a certain amount of power ceases to improve. When this happens and the strabismus and diplopia have continued stationary for some months, an operation may be performed with advantage, to restore the balance of power between the muscles. If the paralytic strabismus be divergent, the external rectus may be divided; and should this fail, the internal rectus may be brought forward, as recommended in the Article STRABISMUS, page 283. If, however, the

remaining strabismus be convergent, the internal rectus may be divided.

INVOLUNTARY OSCILLATIONS OF THE GLOBES
 —*Nystagmus*—usually indicate an unsound state of the nervous system of the eye. They are frequently associated with congenital cataract, and with defective vision produced from any cause in early childhood; they are also often met with in albinos. These rapid movements of the eyes are quite beyond the patient's control and continue without his knowledge. The oscillations are nearly always horizontal, but I have seen cases in which they were both vertical and rotatory, and I have had one patient in whom the oscillations were rotatory only, the movements being caused by the alternate contractions of the superior and inferior oblique muscles. Occasionally one eye only is affected with nystagmus, and then it is generally horizontal, but in one case in a boy under my care, the one eye affected had vertical nystagmus. Notwithstanding the incessant oscillations of the globes, the power to move the eyes together in all directions is unaffected. The division of the ocular muscles affords no relief to the constant oscillatory motions. In one patient, from whom I had occasion to remove a shrunken globe which oscillated in concert with its fellow, the muscles continued their alternating action, and jerked the conjunctiva to which their cut ends had become attached, in unison with the movements of the remaining eye.

Miners' Nystagmus.—Dr. Oglesby, of Leeds, has drawn attention to a horizontal nystagmus which occurs amongst the miners in coal pits. He says:—"Of the many cases I have now seen, I have never met with any patient who described the origin of the affection differently from his fellows. The statement they make is somewhat as follows:—'I enjoy excellent health, and have never, until the commencement of the present seizure, suffered from any affection of the eyes. One morning after entering the pit, and stooping in the usual manner to get coal, my lamp being placed a few feet away, I was startled to find that the light was rapidly moving to and fro, and believing that something must be very wrong, I at once assumed the erect posture, when I was surprised to find the light from my lamp quite stationary. Thinking that I must be mistaken in the belief that my lamp was moving, I bent again to work, and again found my

lamp moving quickly from side to side; since then this symptom has always occurred when my head and neck are bent when at work, and it has become so much worse with each day's work that now I cannot manage to get coal with safety, and have left the pit.'"

Dr. Oglesby states that "The disease is not preceded by premonitory symptoms, is very constant ever afterwards, is never amenable to treatment, as a rule occurs only in adults, and never except in a miner."*

Dr. Oglesby adds, however, as a postscript to his paper, that he has had a case in which the nystagmus has entirely disappeared under a six weeks' course of strychnia—a drug which he had often prescribed before without benefit.

Dr. Hudson, of Redruth, states:—"That although he had had a very large experience of Cornish miners, he had never met with miners' nystagmus except in men who had acquired it whilst working in coal mines in the north."†

The miners' nystagmus is probably due to the excessive strain of the eyes to see the work at which they are engaged in a dim light.

Voluntary Nystagmus, or the power of inducing nystagmus at will, is rare. In the Royal London (Ophthalmic Hospital Reports, vol. x., p. 203, I reported the two following cases, and I have since heard of others.

CASE I.—A gentleman, after he had consulted me about himself, told me that he possessed the power of shaking both his eyes, and that he had been able all his life to shake them at will. At my request he gave me a performance. First, making both his eyes steady, he then set both into rapid lateral motion, so rapid that the outline of the corneæ was completely lost to view. The movements were really an exaggeration of what is seen in horizontal nystagmus, but they were so rapid that the margins of the corneæ could not be defined.

CASE II.—A former house surgeon in the Royal London (Ophthalmic Hospital possessed the power of voluntary nystagmus, but the lateral movements of his eyes were not nearly so rapid as in the case above related. Before setting his eyes in lateral motion, he had to converge them sufficiently to squint, and then he could simulate horizontal nystagmus. The movements were completely under his control, and could be started and arrested *instantly*.

* Transactions of Ophthalmological Society, vol. ii. p. 243.

† *Ibid.* vol. ii. p. 250.

Treatment.—The only treatment which is likely to diminish the frequency of the oscillations is to improve, if possible, the sight, and this is one of the strongest reasons in favour of an early operation for congenital cataract in those cases where the opacity of the lens is sufficient to prevent the child discerning objects. When the cataract is thus complete, even though there may be no oscillatory movements, they may after a time be acquired, and the good effects of a future operation will be then diminished.

CHAPTER VIII.

SPECIAL INJURIES OF THE EYE.

FOREIGN BODIES WITHIN THE EYE.

THE LODGMENT OF A FOREIGN BODY WITHIN THE EYE is one of the most serious injuries which can happen to that organ, and the importance of ascertaining correctly, as soon as possible after the infliction of an injury, whether there is a foreign body within it, cannot be over-estimated. The prognosis of the case rests entirely on the elucidation of this one point.

Every penetrating wound of the globe should be specially examined with reference to the possibility of there being a foreign body within the eye.

The dangers of a foreign body within the eye are—

1. The risk of the eye being completely destroyed by the inflammation which its presence may excite.

2. If the eye has been destroyed by the inflammatory action which the foreign body has induced, the stump, or that which remains of the eye, will be liable to repeated attacks of inflammation so long as the foreign body continues embedded in it; and with each attack there will be an increased danger of the other eye becoming affected with sympathetic ophthalmia.

All the evidence we can collect may be in favour of there being a foreign body within the eye; yet if we cannot see it, and we have no reason to believe that it is buried within the lens, we must wait for symptoms, and

treat them as they arise. The progress of the case will as a rule quickly determine whether there is a foreign body within the eye, although in some exceptional instances it excites but little if any irritation.

The symptoms which strongly favour the presumption that a foreign body is within the eye when a careful examination fails to detect it, are—

a. An increase or a continuance of the inflammation primarily excited by the injury in spite of all the remedial agents which may have been used to arrest it.

β. If the first inflammatory symptoms have subsided, the continuance of a subacute choroido-iritis or choroido-retinitis uninfluenced by proper local and constitutional treatment.

γ. The non-union of the corneal wound, when the cornea has been the part of the eye involved in the injury; or the only partial closure of the wound, leaving a fistula through which there is a constant drain of the aqueous, causing the iris to lie in contact with the cornea.

δ. Severe and continued pain in the eye, unproportioned to the apparent existing inflammation, and unalleviated by the ordinary local applications and medicines.

Treatment of Foreign Bodies within the Eye.

—In all cases of a foreign body within the eye, the treatment undoubtedly is, if it can be seen and the removal of it is practicable, to take it away. But the object may be so placed that it can be seen, yet from its situation an attempt to remove it will incur a risk of loss of the eye, or from the difficulty of reaching it, the operation will probably fail: how, then, should we act? My answer to this is:—

1. If it is creating irritation, without hesitation endeavour to remove it.

In all cases where the surgeon deems it right to attempt the removal of a foreign body from within the eye, he ought to have a discretionary power, that if he fail to find it, he may remove the globe whilst the patient is still under chloroform, *if circumstances render it advisable.*

2. If the foreign body is creating no irritation, and there is a fair amount of vision, and an attempt to remove it would greatly hazard the eye.—Even in such a case, provided the patient has the

second eye good, I would endeavour to remove the foreign body; but if the injured eye is the only seeing one, no operation should be performed until symptoms of irritation arise.

When the foreign body within the eye is a chip of iron or steel an attempt should be made to remove it with the electro-magnet; small fragments of iron even when lying in the vitreous have been successfully removed by its agency. We are indebted to Dr. McKeown, of Belfast, for having drawn attention to the value of the magnet in diagnosing the presence and for extracting pieces of iron or steel from within the eye;* and to Mr. Simeon Snell, of Sheffield, for having devised a very efficient electro-magnet. One advantage he claims for his electro-magnet is, "that in a case where the portion of metal is visible, the needle may be advanced to it before the magnetic influence is brought into force."† I have used the electro-magnet, and have been much pleased with the results obtained by it.

In every case where the eye is destroyed for visual purposes by the inflammation induced by a penetrating wound, and there is reason to believe that a foreign body is lodged within the globe, the only treatment to be adopted is to excise it. It has ceased to be an organ of vision, and at some future period it may, and very probably will, become a source of much danger to the sound eye.

INJURIES OF THE EYE FROM ESCHAROTICS.

QUICK LIME, or lime before it has been slaked by the addition of water, is the most destructive agent that can come in contact with the surface of the eye. If it is in sufficient quantity and is allowed to remain long enough in apposition, absolute destruction of the part ensues, a slough follows, and complete loss of the eye is a not infrequent result. In the smallest quantity it is a most powerful irritant: a spasmodic contraction of the orbicularis tightly closing the lids upon the globe, and a copious flow of tears follow the introduction of even a particle of lime into the eye. The epithelium is at once whitened and destroyed, and a sharp clear line will indi-

* British Medical Journal, 1874, vol. i. p. 800.

† *Ibid.* 1881, vol. i. p. 843.

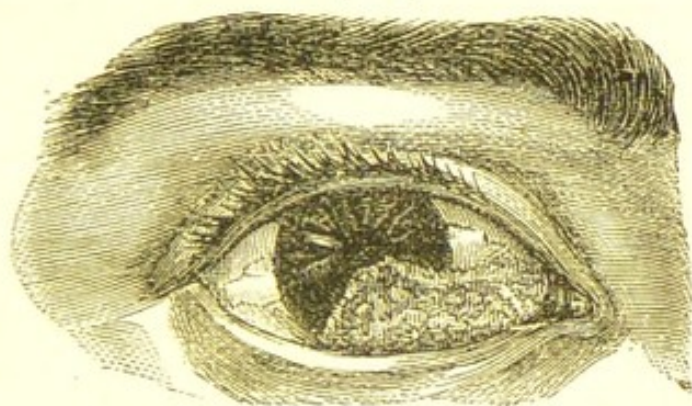
cate the boundary of the part which has been affected by the lime; outside this boundary the conjunctiva is excessively red and more or less chemosed; and the lids, if the injury is severe, are œdematous.

If the epithelium only is destroyed, it will be replaced, and no markings of the injury will remain; but it is seldom, if ever, that the action of unslaked lime is thus limited; the whole thickness of the tissue with which it comes in contact is usually destroyed by it, and dense contracted cicatrices are the result.

MORTAR, PLASTER, and the other combinations of lime used for building purposes differ only in degree from lime in the way in which they affect the eye. Their action is not quite so rapid or so acute as unslaked lime; still, if they are allowed to remain a sufficient time in contact with the eye or with the conjunctiva of the lids, similar results are produced; sloughs may be formed, and suppuration ending in complete destruction of the eye may follow.

Treatment of Injuries from Lime, Mortar, &c.—The first course to be adopted is to remove as

FIG. 59.



The woodcut represents the appearance produced by an injury to the eye from some fresh-made mortar, which was thrown into the eye the day before the boy was brought into the hospital.

As quickly as possible every particle of lime from the eye, and at the same time to arrest the further destructive action of any fragments which may be still sticking to the conjunctival epithelium. For this purpose a little sweet oil should at once be dropped into the eye, and the upper and lower lids being everted in turn, the bits of

lime should be gently lifted away with a fine spatula or spud. Having removed all that can be seen, the upper lid being everted and the lower one drawn down by the finger of an assistant, a stream of tepid water should be gently syringed over the front of the eye and the inner surfaces of the lids, so as to wash away any small pieces which may have escaped notice; but before closing the lids, two or three more drops of oil should be dropped into the eye. If the patient is seen by the surgeon *very early* after the accident, the eye may be syringed out with a little weak vinegar and water, or the dilute acetic acid and water, about the strength of one drachm to one and a half ounces of water. An acetate of lime is thus formed, which is innocuous; but for this treatment to do good it must be resorted to immediately after the introduction of the lime; and as such a chance is rarely afforded the surgeon, the use of olive oil in the first instance will generally be found preferable. For the first two or three days after the injury cold and soothing applications are best suited; cold-water dressings may be applied over the closed lids, or a lotion of belladonna may be substituted if the eye is very painful. Opiates should be given at night if the pain prevents sleep.

BURNS AND SCALDS OF THE EYE.—Hot fluids, according to the intensity of their heat, redden, vesicate, or even destroy the conjunctival surface of the eye or lids with which they come in contact. They produce the same immediate effect on the conjunctiva of the eye as they do on the skin covering the body; but the delicacy of the textures of the eye and the importance of the integrity of each for the well-doing of the whole, render what would be a slight scald elsewhere, a severe injury to the eye.

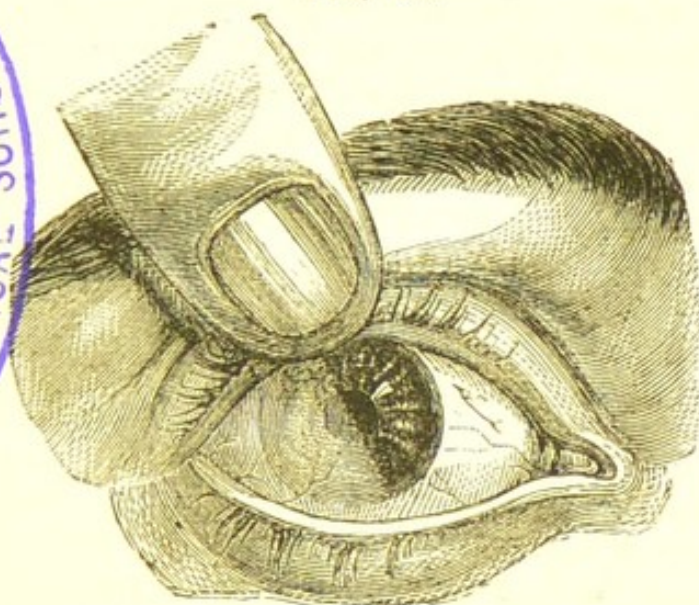
Treatment.—When the patient is first seen, a few drops of olive oil should be dropped into the eye; the lids should be then gently closed, and some cotton wool laid loosely over them, which should be kept in its place by a single turn of a light bandage.

The dropping of oil into the eye may be repeated two or three times during the day, and each time the bandage is removed the eye and lids should be washed with a glycerine lotion (F. 55) free of any discharge which may have accumulated.

If the lids are severely burnt or scalded, previously to

applying the cotton wool, lint soaked in carron oil or equal parts of lime-water and olive oil should be laid over them; but if the burn or scald is only slight, a little ung. cetacei on lint will be sufficient. Opiates should be given internally if the patient is suffering much pain: they not

FIG. 60.



The woodcut represents the effects of a burn of the eye from a splash of molten lead. The man, a plumber, was carrying a pot of melted lead, when his foot slipped over a piece of wood and some of the molten metal splashed up into the eye, and was moulded to the part against which it rested. The patient made a good recovery, and was discharged from the hospital with the eye in the condition shown in the woodcut.

only give ease and procure sleep, but they exercise a specially beneficial control over the suppurative action which has to follow.

STRONG SULPHURIC AND NITRIC ACIDS act chemically on the tissues of the eye, and if in sufficient quantity cause disorganization of the parts with which they are brought in contact, producing superficial or deep sloughs.

The action of a strong acid on the eye, even in the smallest quantity, is that of a powerful irritant; it produces great pain and smarting, more or less œdema of the lids, and a constant flow of tears with intolerance of light, which may last for many days, even though the actual injury inflicted does not extend beneath the epithelium of the ocular conjunctiva.

The rapid flow of tears, however, which the irritation of the acid instantly excites, quickly dilutes it; and if it is only a drop or a small splash which has entered the eye, the injury which it inflicts is comparatively slight and completely remediable.

Treatment of Injuries from Strong Acids.—If the patient is seen very shortly after the accident, the eyes should be gently syringed out with some weak alkaline solution, such as potassæ bicarb. or sodæ sesquicarb. gr. 5, aquæ destillat. ℥i, to neutralize any acid which may yet remain; or if this cannot be at once obtained, tepid water should be used. A little olive oil should be then dropped into the eye, and this may be repeated two or three times a day if it gives ease. The lids being closed, a layer of cotton wool should be laid loosely over them, and a single turn of a bandage passed round the head to keep it in its place.

When the lids are much burnt with a strong acid, an alkaline dressing should be used for the first twenty-four hours, and lint dipped in the liniment. calcis cum cretâ (F. 37), should be laid over them, then a layer of cotton wool, and a turn of a bandage over the whole to keep all *in situ*. The ordinary carron oil or equal parts of lime-water and olive oil may be afterwards substituted for the chalk dressing, and continued until the sloughs begin to separate.

VINEGAR, DILUTE ACETIC ACID, or any of the weak or dilute acids, act as irritants to the eye; and although they do not immediately destroy any of the tissues with which they may be brought into contact, yet they often give rise to an ophthalmia which is the cause of much suffering, and in some instances even of danger to the eye. The primary treatment recommended in the cases of injury from strong acids is equally applicable to those occasioned by the weak or the dilute. If seen early, the alkaline solution should be used, and afterwards either soothing or astringent applications to allay irritation and to check, if necessary, undue secretion from the conjunctiva. In all injuries to the eyes from chemical agents a solution of the antidote should be first used, if the patient is seen sufficiently early to render its application of service. As in the cases of injury from an acid, an alkaline solution was recommended; so in those from a strong alkali, such as caustic potash or soda, an acid

solution of one drachm of vinegar, or of the dilute acetic acid to one and a half ounces of water, should be syringed over the front of the eye and palpebral surfaces of the lids.

INJURIES FROM PERCUSSION CAPS, GUNPOWDER, AND SMALL SHOT.

PERCUSSION CAPS.—One of the most frequent sources of injuries to the eye from the use of guns, which is met with in *civil* practice, is from fragments of percussion caps flying off when they are exploded by the hammer of the gun. This accident very rarely happens when the caps are of the best quality, such as are sold by respectable gunsmiths for ordinary sporting purposes. It is almost invariably occasioned by toy guns, bought as playthings for children, or used by itinerants at fairs and other places of public resort, for firing at a target for nuts. These common percussion caps are sold at a very low price, and are made of a brittle alloy instead of the best copper. In their explosion small scales are detached from them and driven with such velocity that if they strike the eye they usually penetrate it. Unfortunately, the victim of such accidents is more frequently some bystander or passer-by than the person who is shooting. In nearly every case, total loss of the eye is the ultimate result of the injury; and in several which have come under my care, the end has been still more disastrous; the other eye has become affected with sympathetic ophthalmia, and it also has been irreparably destroyed.

Treatment.—See TREATMENT OF FOREIGN BODIES IN THE EYE, page 303.

GUNPOWDER.—The near explosion of gunpowder may affect the eye in four different ways:—

1. By the concussion it produces when exploded in close proximity to the eye.

2. From the burning or scorching of the surface of the eye and the lining membrane of the lids.

3. From depositing in the external tissues of the eye specks of unexploded powder.

4. From grains of powder being driven with sufficient force to penetrate the globe.

Treatment of Gunpowder Injuries.—The first object is to remove all loose powder, if there be any, from

the surface of the eye, and from between the lids and the globe. This may be done by everting the lids and gently squirting a stream of tepid water over the front of the eye and the conjunctiva of the lids with a syringe, or small india-rubber bottle, and afterwards by lifting away with a fine spatula or small scoop, any particles of powder which may be adherent from being entangled with mucus, or with the conjunctival epithelium. The cornea should be then carefully examined, and all the unexploded grains which may be found embedded in it should be removed with a fine needle or spud. Those granules which are lodged deeply in the true corneal tissue and are out of the field of vision, may be left if they cannot be easily lifted away, as more harm will be done by injudiciously picking at them, than their presence can excite.

Specks of unexploded powder which are lying on the sclerotic surface of the eye may be removed, but no great effort should be made to detach them, as, beyond the slightly unseemly appearance, they seldom if ever do harm.

Having taken away all the unexploded powder, a little castor or olive oil should be dropped into the eye and soothing applications used externally. A lotion of belladonna (F. 40) will relieve pain, and by keeping the pupil dilated act beneficially in case any general inflammation of the eye should follow.

INJURIES FROM SMALL SHOT, COMMONLY USED FOR SPORTING PURPOSES.—The velocity and direction of the shot when it strikes the eye determine very much the extent of the injury which it inflicts.

1. **Spent Shots.**—If the shot is *nearly spent*, it may merely produce a slight concussion with ecchymosis of the conjunctiva, from which the eye may quickly recover. If, however, there should be some irritation, it may generally be subdued by the application of two leeches to the temple, the use of the belladonna lotion to the eye, and a few days' absolute rest.

2. **Glancing Shots.**—A shot at full speed may strike the eye in its transit without penetrating it, and leave a deep furrow which may very closely resemble a penetrating wound.

3. **Penetrating Shots.**—The lodgment of a shot within the eye will produce all the severe symptoms which have already been described in the Section on FOREIGN BODIES WITHIN THE EYE. As a rule, the eye

may be considered as lost after such an accident. The passage of the shot into the eye generally inflicts such irreparable damage on the different tissues through which it passes, that all sight is at once extinguished. The eye at first becomes acutely inflamed, and occasionally suppurates; but generally the acute symptoms subside, and a low form of deep-seated inflammation sets in, which ends in softening and shrinking of the globe. So long, however, as the shot remains within the eye, it is a constant source of danger, and may at any time give rise to an attack of sympathetic ophthalmia in the sound eye which may cause its destruction.

Treatment.—If there is a shot within the eye and it cannot be removed, the eye should be excised. (See TREATMENT OF FOREIGN BODIES WITHIN THE EYE, page 303.)

EXCISION OF THE EYE.

The patient should lie on his back on a couch with his face towards the light, and the eyelids be separated by the stop-spring speculum. With a pair of fine single-toothed dissecting forceps a fold of the conjunctiva and subjacent fascia is to be seized close to the cornea, and divided with a pair of blunt-pointed scissors, curved on the flat, as in Fig. 61. Through this opening one blade of the scissors is to be passed, whilst the other remains external to the eye, and then, with a few clips, the conjunctiva and fascia covering the globe are to be cut through in a circle around the cornea. An ordinary strabismus hook (Fig. 56, p. 279) is then to be introduced in turn beneath the tendons of each of the recti muscles, which are to be divided with the scissors close to their insertions in the sclerotic.

Having made certain that the recti muscles are completely divided, one finger of each hand should press back the tissues on either side of the eye, so as to push the globe forwards and partially dislocate it through the opening which was made in the conjunctiva at the commencement of the operation. By this simple manœuvre, the next step, the division of the optic nerve, is facilitated. The cut end of the tendon of either the internal or external rectus muscle should now be seized



with the forceps, and the eye drawn over to one side, whilst the scissors with the blade shut and the curve towards the globe are passed backwards between it and the surrounding tissues. As they round the posterior curve of the eye, the blades should be opened, when, after gently urging them a little further onwards, the optic nerve will come within their grasp, and may be then divided. The eye may now be lifted with the fingers forwards, and the oblique muscles or any other tissues which may be still adherent cut through with the scissors, and the operation will be completed.

When all the bleeding has ceased, the opening in the conjunctiva, through which the eye has been enucleated, may be closed by drawing the edges together with a fine thread which is passed through them at different points and then tied. This is a finish to the operation, and gives an appearance of neatness to it at the time. It is not, however, essential, as the parts are afterwards completely drawn together by cicatrization. In the excision of inflamed eyes it is positively prejudicial, as it prevents the free escape of inflammatory exudations, and thus favours orbital cellulitis.

In all cases where there is no external appearance to distinguish the diseased from the sound eye, it is the duty of the surgeon to indicate the eye which is to be excised by a mark over the brow, before the patient is put under the anæsthetic. To remove the wrong eye is an accident which may occur unless proper precautions are taken.

Treatment after Excision of the Eye.—As a rule, the patient recovers so rapidly from this operation that but little after-treatment is required. A fold of wet lint should be kept over the lids, and all discharge from the wound carefully washed away from time to time with a little warm water gently syringed into the orbit with a glass syringe. The wound usually cicatrizes in from three days to a week, but a slight muco-purulent discharge from the orbit often continues for two or three weeks afterwards. This may be checked by a lotion of alum or tannic acid (F. 47, 58), which should be used with a syringe three or four times daily. It frequently happens that on looking into the orbit the cause of the continuance of the discharge may be seen in a small fungoid granulation sprouting from the cicatrix of the conjunctiva. This should be removed by a single snip with a pair of curved scissors.

If, however, instead of progressing thus favourably, symptoms of orbital cellulitis come on, warmth should be applied to the wound by frequent fomentations of hot water or decoction of poppy-heads, and afterwards by a linseed-meal poultice over the lids and brow. If the opening in the conjunctiva has been closed by a suture, it should be at once removed. It is good practice in such a case to make a free incision through the wound in the conjunctiva into the cellular tissue of the orbit, so as to give free vent to all inflammatory exudations as they are effused. By thus encouraging suppuration and favouring the exit of the pus, the urgent symptoms will probably be at once relieved. The bowels should be freely acted on by a purgative, and the patient should be kept very quiet in a darkened room. It is seldom that any untoward symptoms follow the operation of excision of the eye.

ARTIFICIAL EYES.—In an ordinary case from six weeks to two months after the operation is the best time for commencing the use of a glass eye. Time should be allowed for complete cicatrization to be effected, and for all swelling and discharge to subside before an artificial eye is introduced within the orbit.

One of the most frequent inconveniences produced by too soon wearing an artificial eye is a chronic conjunctivitis with a muco-purulent discharge, which is often very troublesome to arrest. Another and a more serious annoyance is an inflammation of the conjunctiva and sub-mucous tissue in the line on which the edge of the artificial eye rests, sometimes going on to ulceration. As the result of this, cicatrices are often formed, which render the adjustment of another eye very difficult, and sometimes impossible.

When a lost eye has been removed on account of the sound one suffering from sympathetic ophthalmia, an artificial eye should not be allowed until all the sympathetic symptoms have been arrested, and the eye has remained quiet for at least six months.

An artificial eye should be of such a size that the lids can close completely and easily over it, as in sleep, without any squeezing effort on the part of the patient.

It is far better that the glass eye should be rather too small than too large—an artificial eye which is too large leads to many troubles. If the artificial eye is rather small, I frequently advise the patient to wear

spectacles with plane plate glass in front of the seeing eye, and with a convex lens of from 3 to 6 D in front of the artificial eye, so that it may appear to the on-looker as slightly larger than it really is.

I never order an artificial eye for an infant or young child under five years of age, as the necessary daily removal and replacement of it is a source of constant annoyance. As a rule, it is better to wait until the child is nine or ten years of age.

The following excellent rules are given to the patients at the Royal London Ophthalmic Hospital who have had the misfortune to lose an eye :—

INSTRUCTIONS FOR PERSONS WEARING AN ARTIFICIAL EYE.—It should be taken out every night, and replaced in the morning.

To take the Eye out.—The lower eyelid must be drawn downwards with the middle finger of the left hand; and then, with the right hand, the end of a small bodkin must be put beneath the lower edge of the artificial eye, which must be raised gently forwards over the lower eyelid, when it will readily drop out. At this time care must be taken that the eye does not fall on the ground, or other hard place, as it is very brittle, and may easily be broken by a fall.

To put the Eye in.—Place the left hand flat upon the forehead, with the fingers downwards, and with the two middle fingers raise the upper eyelid towards the eyebrow; then, with the right hand, push the upper edge of the artificial eye beneath the upper eyelid, which may now be allowed to drop upon the eye. The eye must then be supported with the middle fingers of the left hand, whilst the lower eyelid is raised over its lower edge with the right hand.

After it has been worn daily for six months, the polished surface of the artificial eye becomes rough; when this happens it should be replaced by a new one. Unless this is done, uneasiness and inflammation may result.

CHAPTER IX.

DISEASES OF THE LACHRYMAL APPARATUS.

EPIPHORA, or a watery eye, is an overflow of the tears. This overflow is not caused by an undue secretion of the lachrymal gland, but by some imperfection in the lachrymal apparatus, through which the escape of the tears is retarded; they consequently accumulate in the lacus at the inner angle of the eye, and from time to time flow over the margins of the lid on to the cheek. The exposure of the eye to cold or wind aggravates the epiphora by stimulating the lachrymal gland to an increased secretion of tears. Epiphora may arise—

1. From a displacement of the punctum *without* any mechanical obstruction in the canaliculus, lachrymal sac, or nasal duct:—

- a. In old people a relaxed orbicularis frequently allows the lower lid to fall from the globe, and become slightly everted, and thus to draw away the punctum from its proper position with respect to the globe.
- β. A similar result is seen in lippitudo, p. 329, and in all cases of ectropion of the lower lid.

2. Obstruction of the canaliculus:—

- a. From closure of its opening into the sac.
- β. From some foreign body (frequently an eyelash) or from a small chalky concretion.
- γ. From a tarsal cyst or styne pressing upon the canaliculus.

3. Obstruction in the lachrymal sac, or nasal duct:—

- a. From blennorrhœa or chronic inflammation of the sac.
- β. From dacryo-cystitis, or acute inflammation of the sac.
- γ. From stricture.
- δ. From mechanical obstruction by tumours.

Treatment.—As epiphora is to be regarded only as a symptom of derangement in some part of the lachrymal

apparatus, the cause must be first detected, and then endeavours made to remove it. When the punctum is displaced, the canaliculus should be slit up, and means should be taken to restore the lid, if diseased, to a healthy state, or if everted, to its normal position.

Foreign bodies or concretions in the canaliculus should be extracted. Sometimes this can be accomplished with the aid of a pair of iris forceps without any cutting operation; but if not, the canaliculus must be laid open, when all difficulty will be removed. The treatment of the other causes of epiphora which have been mentioned, will be found under their respective headings.

CHRONIC INFLAMMATION OF THE LACHRYMAL SAC—*Blennorrhœa*—*Tumour of Sac*—*Mucocèle*— is a disease of slow progress and long duration. The patient generally is unable to say when it commenced, so long has he suffered from a watery eye; but an increase in the severity of the symptoms has induced him to seek advice. This is the tale of a large number of such cases.

Symptoms.—Constant epiphora. The finger placed over the membranous portion of the sac will detect a fulness, sometimes amounting to an absolute protuberance, and a moderate pressure on this will cause a regurgitation of thick viscid mucus or muco-purulent secretion through one or both puncta. The degree of distension of the sac varies with the duration and severity of the disease. In some cases there is a mere thickening and dilatation of the upper extremity of the sac which may be felt with the finger just below the tendo palpebrarum; whilst in severe and long-standing cases the sac is so enlarged as to be expanded along the border of the orbit, and to appear as a tumour the size of a bean, corresponding in position to the inner half of the lower lid. From the constant exudation from the canaliculi, the eye becomes irritable, the caruncle red, and the edges of the lid excoriated. The sight is also frequently dimmed from films of mucus floating in the tears across the cornea, and the patient is troubled by having repeatedly to wipe away the accumulated tears from the inner angle of the eye.

Treatment.—The first course to be pursued is to slit up the canaliculi, and examine with a probe the lachrymal sac and nasal duct, to determine if there is a

stricture or any other change in the mucous track to account for the long-continued obstruction and discharge.

A stricture may exist in three places—

a. At the point where the canaliculus joins the sac.

β. At the line of junction of the lachrymal sac with the nasal duct.

γ. Close to the opening of the nasal duct into the nose.

The first and second are the most frequent sites for stricture.

a. A stricture at the point where the canaliculus joins the sac is recognised by the obstruction the probe meets with as it is passed onwards; instead of entering the sac and striking against the internal bony wall of the canal, its progress is arrested by the outer membranous wall of the sac, which, when pressed upon by the point of the probe, draws inwards the margin of the lid, and imparts a feeling of elastic resilience. For such a case the following course should be adopted:—A guarded knife should be passed as a probe along the slit-up canaliculus until it reaches the sac, when, failing to find the opening of the duct, the guard is to be drawn back, and with a little pressure the point will be made to enter the sac. The point of the knife should now be turned on itself, so that the blade may be passed as if it were a probe down the sac, and the upper portion of the sac with the resisting fascia in front of it be then divided. A free opening having been thus made into the sac, the three probes, Fig. 62, should be passed in succession, beginning with the small end of the smallest

FIG. 62.



probe. No force, beyond a steady even pressure, should be used. In the after-treatment of the case, a probe should be passed between the lips of the wound and into the sac for two or three days following the operation, and afterwards twice in the week to prevent closure of the divided parts during the cicatrizing period.

In such cases I frequently now use a style (Fig. 63) made of soft silver or of pewter wire which can be easily bent to any curve to facilitate its introduction.

FIG. 63. I prefer the pewter style as it can be cut from wire of the gauges No. 16 or 18 as required, and if the end be neatly rounded off with a file, it is easy to introduce and causes little if any discomfort. A probe should be first passed to measure the lachrymal canal, and the style should be then cut to such a length that its end may rest on the floor of the nose whilst its bent extremity lies on the edge of the lid. If the style does not create much irritation, it may be worn continuously for a week or ten days; it should then be removed every two or three days; and left out for a few hours, but again reintroduced; ultimately, before the style is abandoned, it may be worn only at night and removed in the morning. In this manner a callous opening may be formed which will never close.

There is one danger in using a style—if it be cut too short it may slip into the sac. This accident may be avoided by following the directions I have given; but if it should occur and the style cannot be withdrawn through the aperture by which it was introduced, the lachrymal sac must be laid open externally, and the style removed by a pair of forceps. The possibility of the style slipping into the sac is lessened, if its extremity be curved more into the form of a hook than is shown in the woodcut.

β . If the stricture should be at the junction of the lachrymal sac with the nasal duct, the canaliculi should be slit up with Weber's knife (Fig. 65), which should be carried into the sac as described in section *a*, page 317. The three probes should then be passed in succession, so as rapidly to dilate the stricture.

γ . When the constriction is at the lower end of the nasal duct close to its opening into the nose, the stricture should be rapidly dilated at the first intro-

duction of the probe by a steady forcible pressure, and the communication with the nose be at once restored. A probe should be afterwards passed a few times, at intervals of two or three days, to keep the orifice open.

In those cases where there is much distension of, or a constant muco-purulent discharge from, the sac, it will be necessary to wash out the sac with an astringent injection (F. 58) by means of the lachrymal syringe, and to repeat this washing out of the sac at least twice a week until the discharge ceases to be purulent. The patient may also use some slightly stimulating lotion (F. 25, 26), to drop twice a day into the inner angle of the eye. By steadily continuing this treatment the dilated sac will usually shrink to its normal dimensions.

On several occasions where the membranous portion of the canal was so dilated as to form a tumour which extended beyond the centre of the lower lid, I have cut down upon the swelling, and excised the whole of its expanded anterior wall. The patients have made satisfactory recoveries, but the process of cicatrization has generally been rather slow. It is an operation, however, which is never needed except in extreme cases.

ACUTE INFLAMMATION OF THE LACHRYMAL SAC—*Dacryo-cystitis*—usually attacks only one lachrymal sac, although I have seen both involved at the same time. It is generally preceded by epiphora or watery eye, and it will occasionally follow an acute attack of catarrhal ophthalmia, when it appears as if the conjunctival inflammation had spread by an extension along the canaliculi to the mucous membrane of the sac.

The Symptoms are most acute—pain, heat, redness, and swelling over the sac, extending to both the upper and lower eyelids, which are frequently so œdematous as to be closed over the eye. The pain is often excessive; the slightest pressure with the finger on the sac being almost intolerable. These symptoms continue to increase, when suddenly the patient experiences a sense of relief. The inflamed sac distended with pus has given way, and the discharge has escaped into the cellular tissue between the skin and the membranous sac. A superficial abscess is now formed, and the pus gradually makes its way to the

surface, and points a little below the tendo palpebrarum. If the disease be allowed to progress untreated, the purulent contents of the sac are discharged through the ulcerated opening on the face; the inflammation subsides, and the parts slowly regain their normal appearance; but frequently a fistula remains in the site of the wound which communicates directly with the sac, and through which there is a constant flow of tears on to the cheek. The early symptoms of acute inflammation of the sac closely resemble those of a severe attack of catarrhal ophthalmia, as they are often associated with a muco-purulent discharge from the eye; but in all cases of doubt the pressure of the finger over the lachrymal sac will, by the pain it produces, at once remove all obscurity.

Treatment.—During the acute stage when pus is forming, fomentations of hot water, or of decoction of poppy-heads, should be frequently used, and in the intervals a warm linseed-meal poultice may be applied over the part. As soon as there is reason to believe that the sac is distended with pus, an external opening is to be made to give vent to it. An ordinary cataract knife should be made to enter the membranous sac a little below the tendo palpebrarum, and as the blade is withdrawn the incision should be carried downwards and outwards through the skin and deep tissues to the extent of about half an inch. A small strip of lint is then to be placed in the wound to prevent its edges uniting, and a linseed-meal poultice applied. In three or four days' time, when all the swelling has subsided, the canaliculi should be slit up, and one of the probes be passed into the sac. If any stricture is detected, the probes ought to be passed twice a week for a short time. If after a fortnight or three weeks a muco-purulent discharge should continue, the sac must be washed out with an astringent lotion (F. 47, 50, 58), either with an india-rubber bottle with a properly-constructed tubular nozzle, or, what is far better, with one of Wells's lachrymal sac syringes. This operation should be repeated twice a week until all discharge ceases.

FISTULA OF THE LACHRYMAL SAC is one of the results which occasionally follow acute inflammation and abscess of the sac. A small sinuous track exists between the sac and the integument, through which the

tears ooze on to the cheek. I have also seen a lachrymal fistula remain after the patient has given up the wearing of the old-fashioned style, which was introduced by an opening made in the sac through the skin just below the tendo palpebrarum. Lachrymal fistula is occasionally associated with necrosis or caries of the bones forming the lachrymal canal.

Treatment.—In all fistulæ connected with mucous canals the course to be pursued is, first to cure the stricture and restore the mucous track to a healthy state, and the fistula will then generally close of itself. This rule holds good in lachrymal fistulæ, and for this purpose the canaliculi should be laid open, and a probe passed into the sac and nasal duct to ascertain if there is any stricture or disease of the bony walls.

If a stricture be detected it must be dilated with probes, in the manner already directed in page 316. Should there be a chronic thickening of the mucous membrane, with a muco-purulent discharge, the sac must be washed out twice or three times a week with an astringent lotion by means of an india-rubber bottle, or Wells's lachrymal syringe. If this treatment fail, the fistula should be laid freely open into the sac with a cataract knife, the point of which is to be passed through the fistulous opening on the face into the membranous portion of the canal. Into the wound thus made a piece of lint is to be introduced, but it should be removed in twenty-four hours, after which the cut edges may be allowed to unite. This treatment, combined with the use of probes and syringing out the sac, seldom fails to cure the fistula. In those cases, however, where the fistulous opening on the face is large, as when a style has been long worn and afterwards abandoned, it will be often found of service to pare the edges of the opening and unite the raw surfaces with a fine suture.

EPIPHORA FROM MECHANICAL OBSTRUCTION BY TUMOURS.—The cavity of the lachrymal canal may be partially or completely occluded by tumours which either take their origin from within the sac, or by those which grow from the antrum, the nostril, or from the base of the skull. It would be out of place here to discuss the nature and treatment of such growths; they will be found fully described in works on general surgery. It is sufficient to indicate that epiphora may be caused by the

presence of tumours either within, or in the neighbourhood of the lachrymal sac, that the surgeon may not disregard the possibility of their existence in obstinate cases which have persistently resisted all treatment.

FIG. 64.



TO SLIT UP THE CANALICULUS.—There are several ways in which this operation may be performed.

1. The canaliculus may be laid open on Critchett's director (Fig. 64). The patient being seated in a chair, the operator stands behind his head and introduces the point of the instrument, which he holds between his finger and thumb, along the canaliculus, and then drawing the lid outwards with his ring finger to render the parts tense, he with the other hand slits up the duct by passing a cataract knife along the groove of the director.

Care should always be taken to keep the incision external to the caruncle, as if the edge of the knife, as it is run along the director, is turned too much towards the eye, the canaliculus will be divided only up to the caruncle, beneath which the remainder of the duct will tunnel, unless, indeed, the caruncle be divided, which it is always desirable to avoid.

2. The canaliculus may be slit up by Weber's knife, which consists of a fine blade of the shape and size represented in Fig. 65, with a minute button at its extremity. This is introduced into the punctum, and run along the canal, when, by slightly raising the hand and giving to the blade a cutting movement, it is made to divide the canaliculus to the extent required.

3. The canaliculus may be laid open by a pair of fine scissors.

FIG. 65.



OBLITERATION OF THE LACHRYMAL SAC is an operation which has been frequently performed by some

Continental surgeons of eminence in cases of obstinate chronic inflammation which have resisted other modes of treatment. Various means have been adopted for the purpose of destroying the mucous membrane of the lachrymal canal, such as laying open the sac by a free external incision, and applying to its interior either the actual cautery, the galvano-cautery, nitrate of silver, potassa c. calce, chloride of zinc, or some other strong caustic. My own feeling is decidedly averse to this mode of treatment; the few patients who have come under my notice, in whom attempts have been made to obliterate the sac, have prejudiced me unfavourably. They have been illustrations of the difficulty, well known to all practical surgeons, of destroying a mucous canal. In each case the lachrymal sac was *not* obliterated, but the nasal and canalicular openings were completely closed, and as a result there was a quantity of pent-up secretion which distended the sac, and formed a globular tumour below the tendo palpebrarum. There are few cases of chronic lachrymal disease which will not ultimately yield to well-directed and continuous treatment.

REMOVAL OF THE LACHRYMAL GLAND.—When from any cause it has been decided to excise the lachrymal gland, the operation adopted by the late Mr. Zachariah Laurence* may be performed. An incision is to be made immediately below the upper and outer third of the orbital ridge through the skin and the fascia connecting the periosteum of the orbit with the upper edge of the tarsal cartilage. The gland is then to be carefully felt for with the finger, and having made out its exact position, it is to be seized with a pair of hooked forceps and drawn forwards out of the wound, whilst its cellular connections are carefully severed with a knife. Free hæmorrhage often accompanies the operation, but the bleeding may generally be arrested by a stream of cold water from a sponge. The wound should not be finally closed until all bleeding has ceased.

This operation should never be performed for the relief of epiphora arising from disease of the lachrymal sac, as the evils which may result from it are greater than those which it is intended to cure.

* Ophthalmic Review, No. 12, p. 367.

DISEASES OF THE LACHRYMAL GLAND are extremely rare; so seldom, indeed, is the gland affected, that in the Reports of the Royal London Ophthalmic Hospital for ten years, from 1857 to 1867 inclusive, out of a yearly average of over 12,000 new cases only twenty of "diseased lachrymal gland" are recorded. No doubt the lachrymal gland is often secondarily involved in malignant tumours of the orbit, but this is apt to be overlooked from the fact that the gland is either excised unnoticed with the morbid growth, or else it is sloughed out by the action of the caustics which are afterwards used to destroy any portions of the tumour which may have been left behind. Although the lachrymal, like all conglomerate glands, enjoys a special immunity from disease, yet it is not altogether exempt, and to those affections to which it may be subjected I shall now refer.

INFLAMMATION OF THE LACHRYMAL GLAND—*Dacryo-adenitis*—may be either chronic or acute; generally, however, it is the former. It may occur without any apparent cause, or it may arise from injury.

Symptoms.—When chronic there is tenderness and enlargement of the gland, which can be felt by the finger beneath the outer part of the edge of the roof of the orbit, and occasionally a prolongation of the enlarged gland will extend into the upper lid. There will be probably also some œdema of the oculo-palpebral fold of conjunctiva and redness of the lid. If there is much swelling of the gland the eye will be displaced downwards and inwards.

In one case of subacute inflammation of the lachrymal glands which was under my care, both glands were affected symmetrically, and a portion of the enlarged glands could be seen and felt in the outer part of each upper eyelid, causing the lids to droop over the eyes. Under a few weeks' treatment the swelling of the glands completely subsided. The disease in its progress seemed to be very analogous to an attack of mumps or inflammation of the parotid glands.

If the inflammation is acute there will be pain, redness, and swelling in the region of the gland, with œdema of the lid, and chemosis of the conjunctiva. These symptoms may subside under treatment, or they may go on to the formation of pus.

Treatment.—For the *chronic* inflammation of the gland small doses of the iodide of potassium (F. 91), or of the iodide of ammonium, may be given, and an ointment of ammonii iodid. gr. 30, adipis gr. 240, may be gently rubbed night and morning over the swelling, or the eyelid may be painted every or every other day with the tincture of iodine. For the *acute* symptoms one or two leeches may be applied to the temple, and a warm linseed-meal poultice over the eye. If the inflammation should continue, and pus form, an incision should be made in the line of the orbit to give vent to it, as soon as there is sufficient evidence of its presence.

CYSTS OF THE LACHRYMAL GLAND—*Dacryops*—may arise from acute inflammation and abscess, or from injury. Their formation is apparently caused by an obstruction more or less complete of one of the excretory ducts, in which the secretion of the gland accumulates; the walls of the canal become distended, and a small elastic tumour shows itself in the locality of the lachrymal gland, over which the skin is freely moveable. In a Paper by Mr. Hulke on this subject, in vol. i. of the "Ophthalmic Hospital Reports," he says: "The most characteristic and striking sign of dacryops is the sudden enlargement which the tumour undergoes when the patient cries." If the cyst attains a large size, it may seriously interfere with the movements of the eyelid.

Treatment.—The most efficient method of dealing with these cysts is by the establishment of a permanent fistula on their inner or conjunctival surfaces, by which the tears may constantly drain away. For the mode of accomplishing this, see TREATMENT OF FISTULA OF THE LACHRYMAL GLAND, in the next Section. An attempt to dissect the cyst out through an incision of the skin is apt to lead to the formation of a permanent external fistula.

FISTULA OF THE LACHRYMAL GLAND—*Dacryops fistulosus*—may be the result of an abscess of the lachrymal gland which has burst externally, or of a cyst of the gland, or of an incised wound. There is a minute opening in the upper and outer surface of the lid, through which the tears from time to time trickle.

Treatment.—The edges of the fistulous opening may be pared with a fine scalpel, and be then brought together with a single wire suture; or the end of a fine-pointed

cautery, having been made hot, may be introduced into the fistulous orifice; or the galvano-caustic apparatus may be used in a similar manner. The plan of treatment, however, which was adopted by Sir W. Bowman, in a case recorded by Mr. Hulke,* was so successful that I will quote it in detail. "A single thread of silk was armed with a needle at each end, and one of the needles was introduced into the fistulous orifice in the skin on the outer surface of the eyelid, and carried for a short distance upwards; it was then made to pierce the fibro-cartilage of the lid and the conjunctiva, and the thread was drawn out at the inner surface of the lid. A similar manoeuvre was repeated with the other needle, and the thread was drawn out at the inner surface of the lid at the distance of a quarter of an inch from the first, and a little nearer the attached border of the lid. In this way the cyst was pierced at two points by the thread which encircled in a loop the small intervening portion of the tissue. The two ends of the thread were then brought out at the outer commissure, and secured upon the temple with a piece of sticking-plaster. The presence of the thread occasioned very slight annoyance; the conjunctiva lining the upper eyelid became a little swollen and injected, and tears continued to flow from the orifice in the skin, but less abundantly. Ten days afterwards, the thread was replaced by a thicker one, which produced more irritation, and the conjunctiva immediately around it became slightly granular. An attempt was now made to close the aperture in the skin. It was drawn out with forceps and cut off with scissors, together with the little piece of skin immediately around it. The edges of the wound were brought together with two serres fines, which were replaced on the evening of the same day by slips of plaster. When she was next seen, after an interval of four days, the wound had quite healed, and the fistula in the cutaneous surface of the lid had perfectly closed." In another week the thread was withdrawn, and the small bridge of tissue which had been encircled by the loop cut out. "This opening in the conjunctiva continued patent, and there was no further collection of mucus nor tears in the cyst."

SIMPLE HYPERTROPHY, OR CHRONIC ENLARGEMENT OF THE LACHRYMAL GLAND is occasionally met with. The enlarged gland forms an

* Royal London Ophthalmic Hospital Reports, vol. i. p. 288.

unsightly prominence in the upper and outer part of the orbit.

Treatment.—The unguent. ammonii iodid. gr. 30 ad adipis gr. 240, may be rubbed into the swelling night and morning, and small doses of the potass. iodid., or of the

FIG. 66.



Fig. 66 is drawn from a photograph of a patient who was under my care for great enlargement of both lachrymal glands. The right lachrymal gland I completely excised; and from the left I removed only the protruding portion. The result was very satisfactory.

symp. ferri iodid., may be given twice a day. Should this treatment have no effect, the unsightly prominence may be excised; or the whole gland may be removed. In a case lately under the care of my colleague, Mr. Streatfeild, he removed the protruding portion and left the remainder of the gland. The patient made a satisfactory recovery, and has since continued well.

Sarcoma of the Lachrymal Gland is a very rare disease. In the few cases which I have seen, it has occurred as an infiltration into the gland tissue, and formed a distinct tumour growing into the upper eyelid from beneath the upper and outer edge of the orbit. The following case was under my care at the Ophthalmic Hospital:—A poor woman, æt. forty-two, first came to the hospital on December 31st, 1872. There was then distinct proptosis; the eye was bulged forwards and at the same time pressed downwards and inwards. A firm

tumour could be distinctly felt with the finger at the outer margin of the orbit corresponding to the situation of the lachrymal gland. The disease, she believed, commenced about two months before she applied to the hospital. The patient was kept a few weeks under observation, but as the proptosis increased she was in February admitted into the hospital. I then removed the lachrymal gland, with the new growth, by a single incision just below the upper and outer third of the orbital ridge. (See OPERATION FOR REMOVING LACHRYMAL GLAND, p. 323.) The patient soon recovered from the operation and was able to leave the hospital. She was relieved of all the previous suffering; but as the result of the operation she had complete ptosis, and palsy of the sixth nerve, so that she could not evert the eye. These evils were undoubtedly caused by some laceration of the levator palpebræ and sixth nerve in the removal of the tumour, which pressed upon those structures." The following is the Report of the examination of the tumour by Mr. Nettleship, then Curator of the Museum: "The portion removed was a flattish tumour somewhat irregularly divided into about three or four parts or lobes, one of which was very firm, feeling almost like a nodule of scirrhus, while the others had a somewhat firmer consistence than normal lachrymal gland tissue. The entire tumour was about the same shape as the lachrymal gland, and consisted of the whole of that organ. It was, however, considerably larger in area, though not much thicker than the normal gland. A microscopical examination was made after moderate hardening in alcohol, and the growth proved to be a small-celled sarcoma of the lachrymal gland. The proper gland-tissue was sparingly scattered through the tumour, and much of it had probably become atrophied by pressure. The morbid growth appeared to start from the interfollicular connective tissue of the gland, where the normal nuclei became more numerous. A stage later showed these developed into spindle-shaped cells; after this it seems that most of the new elements remained stationary at the round-cell stage, so that, in fact, the bulk of the tumour was composed of small round or roundly oval cells squeezed tightly together, and intersected with more or less strands of elongated cells and threads of normal fibrous tissues."

CHAPTER X.

DISEASES OF THE EYELIDS.

TINEA TARSI is a disease of the follicles of the eyelashes. It is chronic in its progress, difficult to completely subdue, and very recurrent. In the early stage the margins of the lids are red and irritable; there is at first an excessive secretion from the follicles of the cilia, which accumulates during the night, and causes the lids to be gummed together in the morning. As the disease advances, the discharge becomes purulent and cakes into scabs, which adhere to the margins of the lids, and to the lashes. Small pustules then form at the roots of the lashes, and these burst and leave superficial ulcerations, which are generally covered with yellow crusts. The eyelashes gradually fall out, and the edges of the lids lose their sharp outline and become rounded, thickened, and everted. With the eversion of the tarsal borders, the punctum lachrymale is drawn away from the globe, and there is a slight but constant overflow of tears, which excoriates the lids and keeps up the redness and irritation. To this, the extreme stage of *tinea tarsi*, the term *lippitudo* has been applied.

Tinea tarsi is very common amongst all classes, but especially amongst the poor. It is frequently associated with debility and constitutional derangement, and is one of the sequences of scarlatina, measles, and whooping-cough. Patients who have once suffered from it are very apt to have recurrences when from any cause their health fails.

Treatment.—One of the most important elements in the treatment of *tinea tarsi* is strict cleanliness. The lids should be bathed with warm or tepid water night and morning, and all scabs of dried secretion be removed before the application of any of the remedial agents. On going to bed a little of the unguent. hydrarg. nitratis dilut. (F. 129), or of the unguent. hydrarg. oxidi rubri dilut. (F. 130), should be smeared on the tarsal edges; and in the morning after the lids have been thoroughly cleansed from all the discharge which has accumulated on them during the night, they should be bathed with a mild astringent lotion (F. 48, 50). The lotion may be also used

several times during the day. In children, when the eye-lashes are very long, it is often of service to cut them off close to the lids with a pair of scissors, as the lids are more easily kept clean when there are no lashes upon which the discharge can cake. This plan of treatment is usually sufficient to cure a slight case of tinea; but where there are superficial ulcerations or pustules at the roots of the cilia, other means must be adopted. Each morning after the lids have been freed from all discharge, a solution of nitrate of silver, gr. 5 to gr. 10 ad aquæ ʒi, should be applied with a camel's-hair brush to the pustules or ulcerated spaces between the lashes; or they may be touched twice or three times a week with a stronger solution of nitrate of silver, or with the diluted nitrate of silver points (F. 6). In the worst cases, where the edges of the lids are rounded, thickened, and excoriated, with the puncta drawn away from the globe, the canaliculi should be laid open in the manner directed at page 322, so as to form conduits along which the tears may flow into the sac; and a weak solution of nitrate of silver should be painted daily on the red excoriated margins. Where there is great irritability and excoriation of the tarsal edges, I have found much benefit from the use of the lotio boracis (F. 59). Whilst ordering local applications to the lids, attention must also be paid to the state of the patient's health. Tonics of iron and quinine usually do good; but in very chronic cases, accompanied with a thickened and eczematous state of the lids, small doses of the liquor arsenicalis given twice or three times a day will be often of service. It is, however, a medicine which should be seldom prescribed for young children.

HORDEOLUS—*Stye*—is a small boil on or near the margin of the lid. It is closely connected with one or more of the cilia, and in some cases it seems as if the stye was simply a suppurating hair follicle. Generally only one stye appears at a time on the lid, but others are very apt to follow. A succession of them is indicative of an enervated state of health.

Treatment.—In the very early stage, when the patient feels that a stye is coming, and before suppuration has commenced, I have thought that I have on several occasions succeeded in arresting its progress by drawing once across the tender spot on the tarsal edge a point of the mitigated nitrate of silver (F. 6), or a camel's-hair

pencil charged with nitrate of silver, as directed at page 48. It is a remedy worth trying as, if it fails, the patient has in no way suffered. During the advance of the sty, warm applications are best; fomentations with hot water, or the decoction of poppy-heads, and a warm poultice at night covered with a piece of oil-silk. It is seldom necessary to puncture a sty; the pus will select its own site at which to point and make an exit for itself. The bowels should be cleared of all irritating matter by a purgative, and some tonic prescribed; usually the mineral acids with bark (F. 75), or quinine with the perchloride of iron (F. 81), agree very well. In children, the pulv. cinchonæ cum soda (F. 148), or mist. cinchonæ (F. 138, 139), or some preparation of iron (F. 144, 145), may be ordered. When all suppuration has ceased, the lids may be bathed with a slightly stimulating lotion (F. 50), and at bedtime a little of the unguent. hydrarg. nitratis dilut. (F. 129) may be smeared on the tarsal edges.

ECZEMA OF THE EYELIDS frequently accompanies strumous corneitis and phlyctenular ophthalmia in children. It is often associated with eczema behind the ear and sores about the nostrils.

Treatment.—If the child is seen at the commencement of the disease, when the eczematous symptoms are acute, the bowels should be well acted on with a powder (F. 154, 158); and a mixture should be given repeatedly during the day, with small doses of tartarated antimony (F. 136). The diet should be strictly regulated. The best local application will probably be the lotio boracis (F. 59); but if this should fail, a lotion with zinci oxid. (F. 54) may be tried. Ointments generally irritate, and in most cases should be avoided. After three or four days the antimonial mixture should be omitted, and a preparation of bark or iron be ordered (F. 138, 144).

TRICHIASIS is an irregular displacement of the eyelashes, some of which are inverted and often stunted in their growth. By their friction against the globe they cause severe irritation; and when the inverted cilia brush against the cornea, they render it nebulous and vascular. Trichiasis may be partial, that is, limited to a few lashes, or it may affect the whole row. For the causes and treatment of trichiasis, see the next Section.

DISTICHIASIS is when from some cause the bulbs of the cilia have been so shifted that there is a distinct

double row of lashes. The inner row is usually turned inwards, and sometimes so completely, that the lashes cannot be seen without slightly everting the lid with the finger. Distichiasis may be partial, or it may involve the whole of the cilia.

The causes of both trichiasis and distichiasis are purulent and granular ophthalmia. The contraction of the palpebral conjunctiva which takes place during the healing of the granulations, pulls upon the margins of the lid, and causes a displacement of the bulbs of the cilia, and an incurvation of the tarsal cartilage.

FIG. 67.



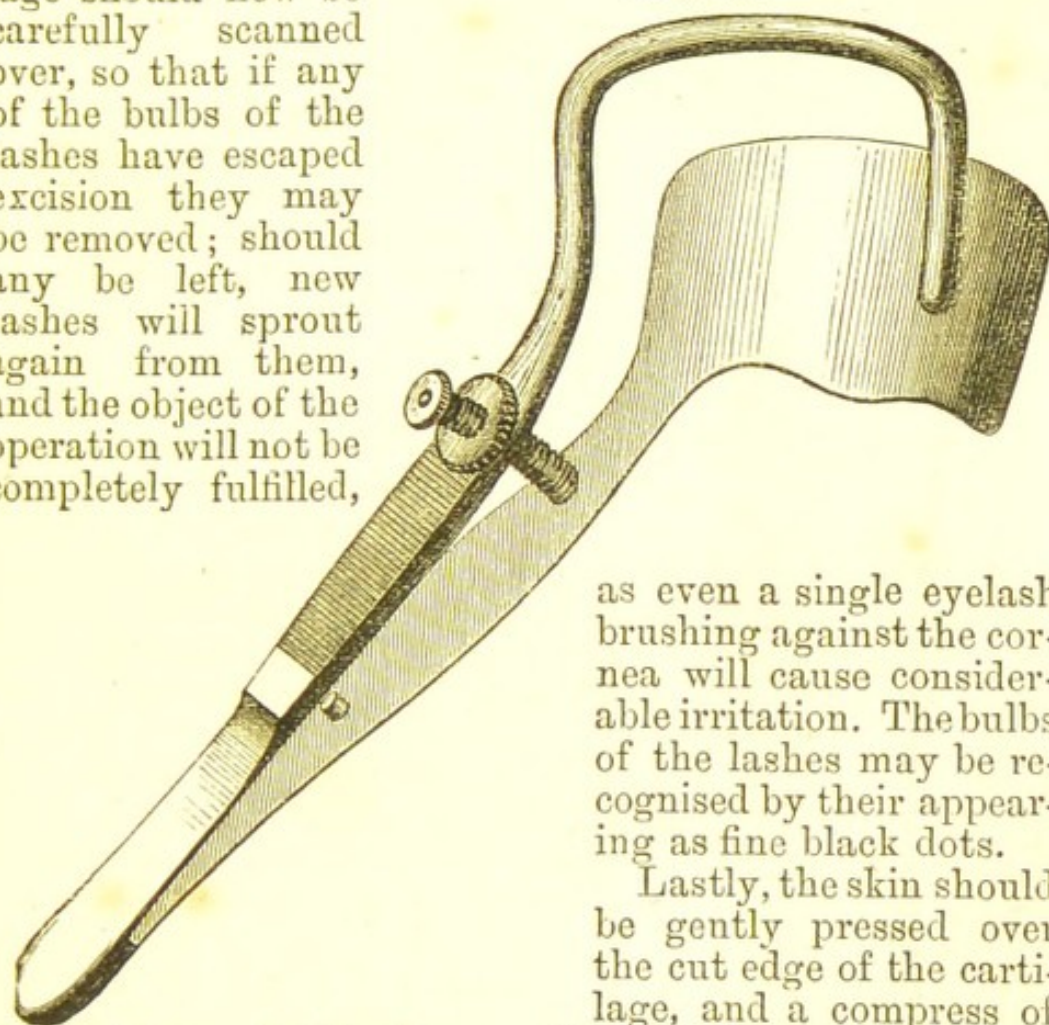
Treatment.—The best operation for severe cases of trichiasis or distichiasis is excision of the whole row of the cilia. The patient is thus rapidly and permanently relieved from a long felt trouble, and the disfigurement is very slight. It is not to be compared with the unsightliness produced by the loss of the oculo-palpebral fold of skin, which is the usual result of those operations which endeavour to rectify the displaced lashes by shortening the integument of the upper lid. It is seldom necessary to excise the cilia of the *lower* lid, as the removal of a fold of skin with the corresponding portion of the orbicularis will usually suffice (see page 337). In slight cases, where only a few of the cilia are affected, the distorted or displaced lashes may be pulled out with a pair of cilia forceps (Fig. 67), or they may be excised. If the inverted lashes involve as much as half the tarsal margin, it is better to excise the entire row, as it is less noticeable than when half the length of the cilia have been removed.

OPERATION FOR THE REMOVAL OF THE EYELASHES.—This consists in first splitting the border of the tarsal cartilage, and then excising the thin wedge of it in which the bulbs of the lashes are embedded.

The lid being drawn tense by one hand of the operator, with the other he makes a long incision with a cataract knife along the inner or ocular edge of the lashes,

and of a sufficient depth for the point of the knife to pass beyond their roots. A second incision is now to be made on the outer surface of the lid just behind, but parallel to, the row of lashes, so as to cut through the integument and the margin of the cartilage just above the bulbs of the cilia: the depths of the two incisions will thus meet, and the whole row of lashes will be excised. The cut surface of the cartilage should now be carefully scanned over, so that if any of the bulbs of the lashes have escaped excision they may be removed; should any be left, new lashes will sprout again from them, and the object of the operation will not be completely fulfilled,

FIG. 68.



as even a single eyelash brushing against the cornea will cause considerable irritation. The bulbs of the lashes may be recognised by their appearing as fine black dots.

Lastly, the skin should be gently pressed over the cut edge of the cartilage, and a compress of

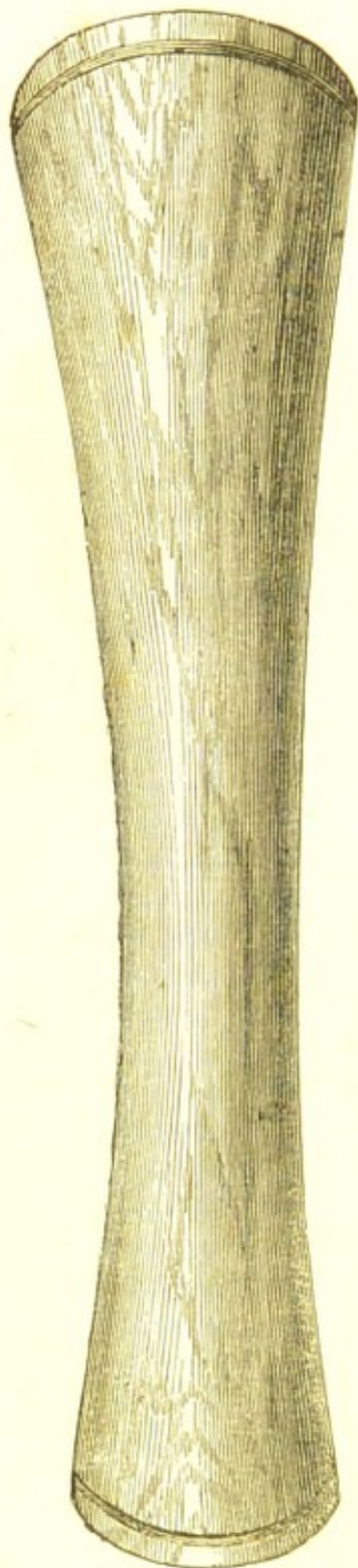wet lint be applied to the eye with a bandage. No sutures should be used.

By this operation the lid is not shortened, for the edge of the cartilage is simply split, and the thin wedge of it removed in which the lashes are implanted.

To facilitate the performance of this operation, either Snellen's eyelid forceps (Fig. 68), or the horn spatula (Fig. 69), may when practicable be used. If Snellen's forceps are selected, the lower blade should be gently insinuated beneath the upper eyelid as far as it will pass, and then with a few turns of the screw, a metallic clamp is made to compress firmly the circumference of the lid

with the exception of its tarsal border, which is left free for the operator.

FIG. 69.



REPOSITIO CILIORUM.—This old operation was first described by Celsus. It was revived by Dr. Snellen, of Utrecht, and has since been advocated by Dr. Argyll Robertson in a Paper in the *Edinburgh Monthly Journal* for May, 1874. The following is his account of the operation:—"The principle of the operation consists essentially in causing the offending eyelashes to be mechanically turned away from the eye, and made to grow more or less in the proper direction by making them pass under a narrow bridge of skin. The following is the method of performing the operation:—A very fine curved needle has the two extremities of a very fine waxed silk ligature (or hair, as Celsus directs) passed through its eye. The needle, being firmly grasped by suitable forceps, is then passed through a narrow fold of skin at the very margin of the lid, close to one of the inverted eyelashes. The point of introduction should be external to the point of emergence of the eyelash, but as close to it as possible: and the needle should be brought out after passing about $\frac{3}{4}$ " or 1" under the skin. The needle and ligature should be drawn through until a small loop alone remains, when, by means of a fine pair of forceps, the eyelash is passed through the loop. Traction is then made on the ligature, and the loop with the entangled eyelash is drawn through the tunnel in the skin. The other misdirected eyelashes are similarly treated.

“Very little irritation follows this operation, and no special after-treatment is necessary. The patient, however, must be warned against touching or rubbing the

FIG. 70.

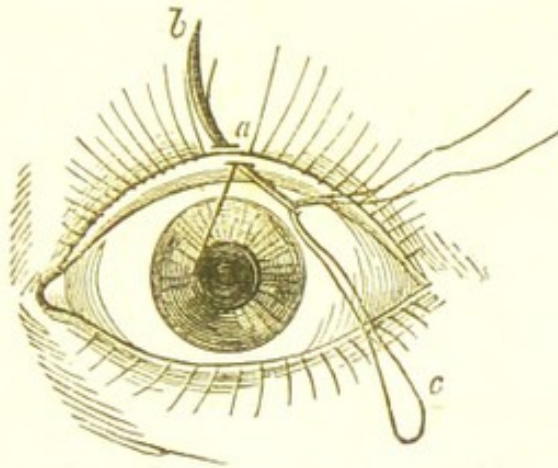


Fig. 70 represents the passage of the needle, armed with the ligature, under a band of skin close to the point of emergence of an inverted eyelash. (The direction of the needle has been represented a little oblique, not to complicate the diagram.)

eyelashes for twenty-four hours after the operation, as he might thus force the eyelashes back out of their new channel.

FIG. 71.

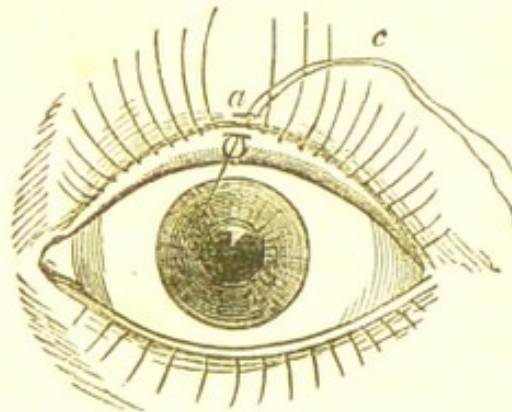


Fig. 71 represents the misdirected eyelash involved in the loop of the ligature.

“This operation is only applicable to those cases of partial trichiasis in which the eyelashes inverted are few in number and of considerable size.”

Various means have been tried for the destruction of the hair follicles by caustics, but the treatment is only applicable to those cases where the displacement of

the lashes is limited, and even then it is not very satisfactory.

FIG. 72.

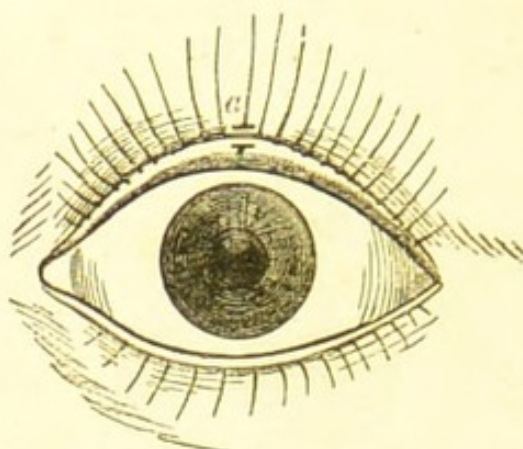


Fig. 72 represents the eyelash in its altered position.

Dr. Herzenstein* has recommended the use of a seton for the destruction of the bulbs of the cilia, and in cases of partial trichiasis it seems applicable. One end of the thread is first introduced by a fine needle through the edge of the tarsal cartilage, and passing it upwards subcutaneously it is brought out at a point beyond the roots of the cilia, and again introduced through the same opening it is carried onwards beneath the skin around the bulbs of the lashes to be destroyed, until finally it emerges on the edge of the lid in a line with the spot at which it first entered. The two ends of the thread are now tied together, and they are allowed to remain until they cut their way out, by which time the hair bulbs are destroyed by suppuration.

ENTROPION, or AN INVERSION OF THE EDGE OF THE EYELIDS.—There are two forms of this disease.

a. The spasmodic entropion.

β. The chronic entropion, which is dependent on structural changes of the conjunctiva of the lid.

a. The **spasmodic entropion** is due to a spasmodic contraction of the orbicularis. It may occur after an injury; or during any affection of the eye, which is accompanied by much photophobia and lachrymation, and particularly if the eye has been for some time closely bandaged up.

* Archiv für Ophthalmologie, Bd. xii. p. 76, 1866.

From the constant overflow of tears the tarsal border becomes red and excoriated; and from the repeated spasmodic contractions of the orbicularis muscle, the edge of the lid becomes curled inwards—sometimes to such an extent that the eyelashes cannot be seen without first everting the tarsal margin by drawing it down with the finger. Spasmodic entropion is frequently seen after the operation for cataract, and especially in old people with the skin of the lids loose and wrinkled. This inversion of the lashes is usually confined to the lower lid.

For the treatment of this form of entropion, it is sufficient to remove a narrow strip of the skin, and of the orbicularis muscle, close up to and nearly the length of the margin of the lid. This is to be done by first pinching up a fold of the skin in a line with the lid by a pair of forceps, and cutting it off with a pair of scissors. A corresponding piece of the orbicularis is then to be seized with the forceps and excised in a similar manner. No sutures will be required; but when all the bleeding has ceased, the edges of the wound should be gently pressed together, and a light pad of wet lint with a bandage fastened over them. Complete union will be effected in two or three days.

β. Chronic Entropion is caused by purulent and granular ophthalmia; by injuries to the conjunctiva of the lids from hot metal, lime, mortar, or any other escharotic which may have caused a destruction of a portion of that membrane. As cicatrization proceeds, the contraction of the conjunctiva causes the margin of the lid with its lashes to become inverted and drawn towards the globe. This folding in of the lashes is a source not only of great discomfort to the patient, but of danger to the eye. The continued brushing of the lashes against the cornea in every movement of the eye is apt to induce a troublesome form of corneitis with ulceration, and will invariably after a time render the cornea nebulous and vascular.

Treatment.—When the entropion is severe, and dependent on a thickened and contracted palpebral conjunctiva, produced by granular ophthalmia; or on cicatrization following an injury to that membrane from some escharotic, the only operation which will afford permanent relief is the removal of the entire row of lashes (see page 332). Associated with the inversion,

there is frequently a considerable contraction of the palpebral aperture. When this exists the external canthus should be first divided with a pair of scissors, and then a fine suture inserted between the divided conjunctiva and the opposite point of skin, in order to prevent the reunion of the edges of the incision. There are, however, many cases of entropion due partly to spasm of the orbicularis, and partly to a contraction of the palpebral conjunctiva. For this class one or other of the numerous operations for everting the infolded tarsal cartilage and rectifying the displaced lashes may be performed.

BUROW'S OPERATION FOR ENTROPION.*—The object of this operation is to restore the inverted tarsal edge to its normal position, and thus to avoid the necessity of removing the row of lashes. In entropion there is an incurving of the tarsal cartilage, so that the cilia brush against the surface of the eye. If such an eyelid be everted, a whitish line will generally be seen running parallel to the margin of the lid, and about one line distant from it: it is upon this line that the tarsal edge is flexed on to the globe. The operation is thus performed:—The lid is everted, and the horn spatula (Fig. 69) having been placed between the globe and lid, an incision is made completely through the tarsal cartilage about one or one and a half lines from its free border along the white line above-mentioned, and extending from the outer to the inner extremity of the tarsal cartilage, taking care to sever thoroughly the cartilage and all the structures of the lid up to the skin, but not to cut the ciliary margin at any point. The lid may be now replaced, and its ciliary border will probably rest against the globe in its proper position, and the operation is completed. If, however, the skin of the lid is very lax, or the tarsal margin is still inclined to curve inwards, a piece of skin may be removed from the lid by pinching a portion of it up with Desmarres's entropion forceps and cutting it off with a pair of scissors. The edges of the wound are then to be brought together with fine sutures.

In dividing the tarsal cartilage the left thumb nail should be inserted into the incision to keep the lid steady, and the blade of the knife should be held parallel with

* Berliner Klinische Wochenschrift, June 23, 1873. Article by Frank Buller, London Medical Record, August 13, 1873.

the tarsal edge so as to avoid making an oblique section of the cartilage.

A simple and very efficacious method of performing this operation is to evert the lid, and having placed the horn spatula (Fig. 69) beneath it to protect the globe, to make at one extremity of the white line which runs parallel with the tarsal margin, a cut with a fine knife through the edge of tarsal cartilage of sufficient size to admit one blade of a pair of scissors. Into this cut one blade of the scissors is inserted, and then with a few decided snips, the tarsal cartilage is divided along the white line from end to end.

Mr. Streatfeild recommends the following operation of "grooving the fibro-cartilage," a full account of which is given in vol. i. of the "Ophthalmic Hospital Reports," p. 125:—"The lid is held with Desmarres's forceps, the flat blade passed under the lid, and the ring fixed upon the skin, so as to make it tense and expose the edge of the lid. An incision, with a scalpel, is made of the desired length, just through the skin, along the palpebral margin, at the distance of a line or less, so as to expose but not to divide the roots of the lashes; and then just beyond them the incision is continued down to the cartilage (the extremities of this wound are inclined towards the edge of the lid): a second incision, farther from the palpebral margin, is made at once down to the cartilage, in a similar direction to the first, and at a distance of a line or more, and joining it at both extremities; these two incisions are then continued deeply into the cartilage in an oblique direction towards each other. With a pair of forceps the strip to be excised is seized and detached with the scalpel."

Another excellent operation is one practised by Arlt. He first splits the tarsal cartilage and severs the entire row of cilia from the subjacent parts as in the operation for excision of the lashes (page 332), but with this difference, that he leaves them still attached at each extremity to the lid. He then removes a fold of skin the length of the lid and adjoining the incision already made, and into the raw surface thus exposed he plants the row of cilia, leaving the skin connection at either end to maintain their vitality until union is effected. A few fine sutures are inserted to keep the parts *in situ*.

Graefe, Pagenstecher, and Snellen have suggested different operations for the relief of entropion. A

detailed account of each will be found in some of the copious Treatises on the Eye which have been lately published.

ECTROPION, OR EVERSION OF THE EYELIDS, may be induced by either injury or disease. The worst and most intractable cases are those which are the result of injury either to the eyelid or to the tissues in its immediate vicinity. When the ectropion is caused by disease, the lower lid is the one most frequently everted; but when it is the result of accident the upper lid suffers equally with its fellow. The deformity which ectropion produces is often very great, and the cause of much annoyance, if not of actual suffering. In all except very slight cases, the eye having lost a part of its natural protection, is liable, from undue exposure, to attacks of recurrent inflammation of its conjunctival surface. It also becomes what is commonly called a watery eye; owing to the eversion of the eyelid the punctum is drawn away from the globe, and some of the tears are constantly flowing over the lid on to the cheek. Lastly, after the lid has been long everted, the conjunctiva is very apt to become changed in appearance and character. In some instances it grows almost cuticular; whilst in others it becomes so hypertrophied and granular as to acquire somewhat the look of a fungoid excrecence.

Ectropion may be produced—

a. By the cicatrization following the destruction of a part or the whole of the skin of the eyelid.

β. By the cicatrization of a wound in the neighbourhood of the eyelids.

γ. By abscesses in the cellular tissue at any point near the margin of the orbit, and especially if associated with diseased bone.

δ. By the cicatrization following lupus. Both the lupus exedens and non-exedens will cause very severe ectropion.

In the cicatrization which follows an absolute destruction of a portion of the integument, the loss is not replaced by a regrowth, but the breach is chiefly repaired by a drawing together of the surrounding parts, borrowing as it were from the abundance of skin in the neighbourhood to close the gap which has been occasioned by the injury. The wound is thus greatly reduced in size, and that which yet remains open is repaired by the develop-

ment of a cicatricial tissue, which closely resembles the true skin, but differs from it in its want of elasticity, softness, and vitality.

If the wound be in the vicinity of the orbit, the contraction which accompanies the healing process draws upon the tarsal edge of the lid, and gradually everts it. This contraction of the neighbouring skin towards the seat of the injury is not confined to the actual period of cicatrization, but continues for many months afterwards, increasing the extent of the ectropion, whilst it diminishes the size of the cicatrix.

When the ectropion is caused by an abscess near the margin of the orbit, very little if any of the skin may have been involved in the suppuration. The ectropion is then dependent on a portion of the cellular tissue having been destroyed by sloughing, and the skin becoming drawn and adherent to the parts beneath, instead of gliding smoothly over them. With the contraction of the skin towards the cicatrix of the subjacent cellular tissue, a pull is exerted upon the eyelid, which will first draw down its tarsal edge, and then gradually evert it.

Two forms of ectropion may be recognised, either of which may be produced by the same cause, the difference being only in degree.

1. Where there is a *partial* eversion of the eyelid, with a thickened and fungoid condition of the conjunctiva.

2. Where the eyelid is *entirely* everted, its conjunctival surface being completely exposed.

The first form is most frequently caused by the cicatrization of a wound in the neighbourhood of the eyelids; whilst the second is generally the result of an absolute destruction of a portion or the whole of the skin of the lid itself.

Treatment of Ectropion.—I will first describe the changes which an ectropion produces in the relative position of the different parts of the eyelid, and then consider the mode of treatment applicable to each. 1. The eyelid is more or less everted. 2. As a consequence of the eversion, the punctum lachrymale is displaced: it is drawn away from the globe, so that it cannot act as a conduit for the tears. 3. The tarsal edge of the lid is more or less elongated, according to the extent of the eversion. 4. In many cases the exposed conjunctiva is hypertrophied and thickened.

In a mild case of ectropion these defects will be only slightly marked, and possibly one or other of them may be absent: but when there is a great eversion of the lid, they will probably be all present and distinctly seen. In treating of each of these defects, I will take them in the order in which it would be wise to proceed in an operation for their relief.

1. If the **punctum lachrymale** be displaced, and drawn away from the globe, the canaliculus should be slit up so as to convert it into a canal along which the tears may flow into the sac. This is readily accomplished by one of the methods recommended at page 322.

2. If the **exposed conjunctiva** is much thickened and hypertrophied, the prominent excrescent-looking portion should be excised. This is most easily done by seizing hold of the piece of conjunctiva which is to be removed, with a pair of fine-toothed forceps, and cutting it off with a pair of small scissors curved on the flat. The contraction which accompanies the cicatrization of the conjunctiva draws the edge of the eyelid inwards, and helps very materially to restore it to its natural position.

3. If the **tarsal edge of the lid** is elongated, it must be shortened before the lid can be restored to its proper position. This lengthening of the tarsal margin is due to the constant pull which has been exerted upon it during the contraction and cicatrization of the wound which have caused the ectropion. To remedy this defect a V-shaped piece of the edge of the lid (as in Fig. 73) may be excised with a fine scalpel. The lips of the wound are then to be brought together with fine pins and twisted sutures, taking care that one of the needles is inserted close to the tarsal edge (as in fig. 74), so that an accurate apposition of the corresponding surfaces is secured. A portion of the tarsal margin may thus be removed from any part of its length; but in most cases it is advisable to make the excision from the extreme end close to the outer canthus. The edges of the wound are brought more easily and accurately together than when the part excised is near the centre of the lid, and the scar which is left is much less noticeable.

4. To relieve the eversion of the eyelid many operations have been suggested and practised. The following is a brief account of some of the operations for ectropion, and the conditions upon which they may be performed:—

a. Where there is complete or partial eversion dependent on a cicatrix at a short distance from the lid.—For convenience of description, I will deal with a case in which the lower lid is the one affected: the same plan of treatment, modified according to circumstances, will be applicable to ectropion of the upper lid. If the ectropion is *partial*, and due to a small cicatrix which is only adherent to a very limited area of the cellular tissue beneath it, while around the scar the skin will glide easily over the subjacent tissues, it will be sufficient first to free the deep adhesions of the cicatrix by subcutaneous division. A tenotomy knife is to be introduced beneath the integument, at a short distance from the scar, and by

FIG. 73.

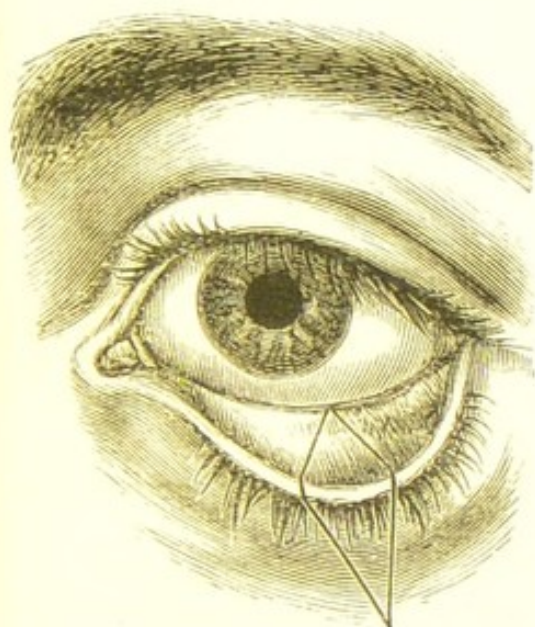
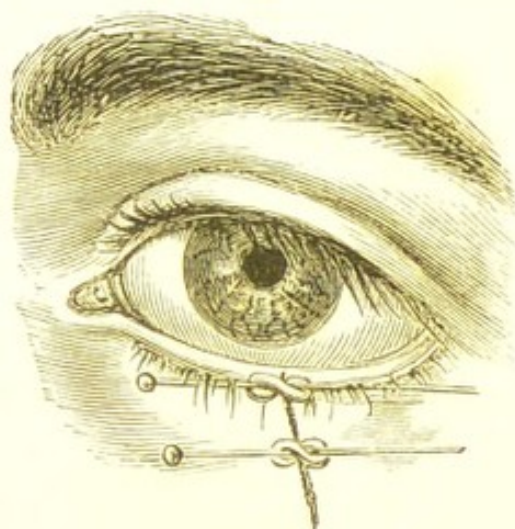


FIG. 74.



a few semicircular sweeps the union between it and the cellular tissue will be parted. If this is satisfactorily accomplished, the skin will glide with freedom over the parts to which it was before adherent. The tarsal edge of the lid should now be shortened in the manner already described; and if the exposed conjunctiva is much thickened, a portion of it also should be excised. By these means the lid will be restored to its normal position, and as the scar will be lifted from its original site, the chance of its reuniting to the parts from which it has been severed will be diminished. In the daily dressing of the wounds, the lids should be well supported with a pad of lint, to prevent the cicatrix being again drawn down to its former position.

β . If the ectropion is *severe*, and the cicatrix which has caused it is dense and firmly attached to the subjacent parts, a different proceeding must be adopted. One very excellent mode of treatment is by including in a V-shaped incision the cicatrix, which is to be separated by a few strokes of the scalpel from all its adhesions to the underlying parts, as is well shown in Fig. 75.

The triangular-shaped piece of skin in which the cicatrix is included is then to be pushed upwards, whilst the lower edges of the V wound are united by two pins and twisted sutures, in the situation marked by the dotted lines in the woodcut, so as to convert the V, when the parts are brought together, into a Y. The everted lid will

FIG. 75.

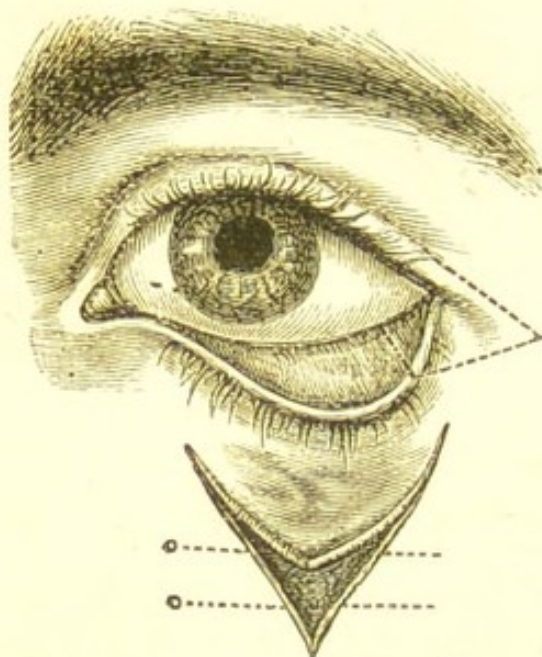
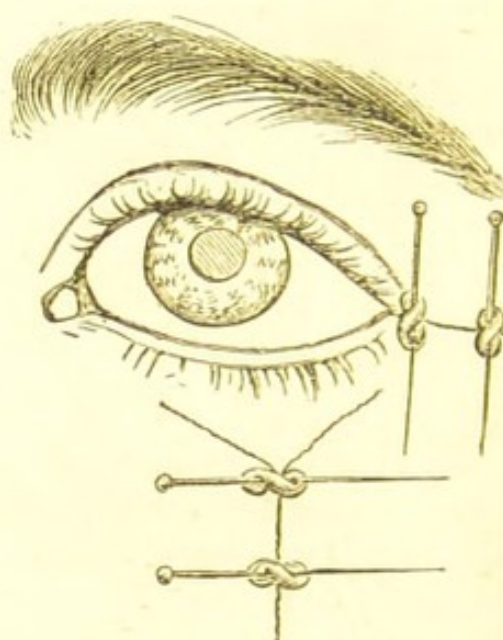


FIG. 76.



thus be raised; but in order to keep it in position, its tarsal edge should be shortened at the outer canthus, removing at the same time a small piece of the margin of the upper lid, to which the lower one should be united by pins and twisted sutures. If the conjunctiva is much thickened, a portion of it may be excised before shortening the lid.

Fig. 76 shows the appearance the eye will present after the operation is completed.

The following operation was the one recommended and performed by Dieffenbach for the relief of ectropion of the lower lid, which had been caused by a cicatrix at a short distance beneath it:—He first dissected out the

cicatrix by including it in a triangular incision (Fig. 77), the base of which corresponded with the tarsal margin of the lid. Having removed this triangular flap of skin, he then extended the cut *cc* to *ca*, *ca*, to allow of the ready approximation of the sides *b*, *b*; which, having been first raised from the subjacent parts by a few strokes of the scalpel, he brought together and united by sutures, as in Fig. 78. The two lateral incisions *ca*, *ca*, he then fastened by sutures to the integument beneath the lower lid in the line *c*, *c*. Fig. 78 represents the appearance after the operation was completed.*

FIG. 77.

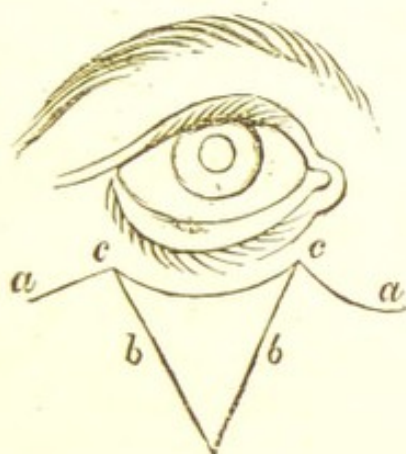
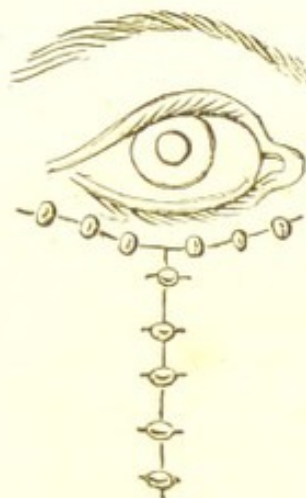


FIG. 78.



In most of the operations for the relief of ectropion the chance of success will be materially increased by adopting the expedient, first suggested and practised by Sir W. Bowman,† of temporarily uniting a portion of the corresponding tarsal edges of the upper and lower lids. This is to be accomplished by paring the thinnest possible shaving from the opposed tarsal margins, and then fastening them together with a single fine suture. Immediate union generally follows, and the lids are allowed to remain closed for some weeks or months, until, indeed, all the contraction and cicatrization consequent on the operation for the ectropion have passed away. When it is desirable to part the lids, the bond of union may be divided on a director with a single stroke of a scalpel.

* Review of Zeis's *Handbuch der plastischen Chirurgie*, British and Foreign Medical Review, vol. vii, p. 406, from which the woodcuts have been copied.

† Royal London Ophthalmic Hospital Reports, vol. vii, p. 1.

γ. In those cases where much of the integument of the eyelid has been destroyed, and complete eversion of it has followed, it is seldom that the lid can be permanently restored to its natural position without some plastic operation. After the lid has been dissected from the adhesions which bind it down, and has been replaced over the eye, a large granulating surface will be left, which, unless covered over by new skin borrowed from a neighbouring part, will cause during cicatrization a return of the ectropion.

I will not attempt to describe the different operations which have been either suggested or performed for the making of a new eyelid. Each case presents peculiarities of its own, for which no special directions can be given. The result of the operation depends very much on the ingenuity of the surgeon in designing one fitted for the case, and on his dexterity in carrying out neatly the details which his mind has conceived.

A few general directions may, however, be useful. If the ectropion be of the upper lid, it is generally most convenient to borrow the skin from the side of the forehead; but when the lower lid is the one affected, it may be most easily obtained from either the side of the cheek or the inner side of the nose.

1. Before attempting a plastic operation for the formation of a new eyelid, sufficient time should be allowed to elapse after the injury for the skin in the neighbourhood of the eye to have recovered as far as possible its healthy elasticity and softness. All thickening and induration of the subjacent cellular tissue should have passed away, and the skin should glide readily over the parts beneath it.

2. After having by dissection restored the lid to its proper position, the size of the surface to be covered with the borrowed skin should be accurately noted; and the piece which has to be taken from the temple, or elsewhere, should be of larger dimensions than is apparently required, as the skin contracts about one-sixth when detached from the part it originally occupied. It must also be remembered that even if it is a little too large, a further contraction of it will take place during the healing process, which will reduce it to its required size.

3. Great care should be taken to leave a good pedicle through which the vascular supply of the new lid may be maintained until it has become united with the parts

beneath it, and a fresh source of nourishment has been established. It is also advisable, in adapting the skin to the lid, to avoid twisting the pedicle on itself more than is absolutely necessary.

4. Before uniting the edges of the new lid to the surrounding skin, all bleeding should be arrested. Nothing tends more to delay primary union than a clot of blood between the opposed surfaces.

In nearly all cases where a plastic operation is required, it will be well to shorten the tarsal margin of the lid in the manner already described, so as to slightly diminish the size of the palpebral aperture.

If the exposed portion of the conjunctiva is much thickened and granular, a portion of it also should be removed with a pair of curved scissors.

Having completed the operation, a layer of wet lint should be laid over the lids, upon which a light compress of cotton wool should be fastened with one or two turns of a roller, for the purpose of keeping the parts in apposition and of maintaining a certain amount of warmth.

When the ectropion is due to an extensive destruction of the skin of the lid and the surrounding integument, so that there is only tight cicatricial tissue around the orbit, I have succeeded in making a new eyelid with a piece of skin taken from the arm. My first case, of which the following is an abstract, is reported in the Transactions of the Clinical Society, 1871, vol. iv. p. 51:—

“On October 15, 1870, I dissected down the lid from its attachments, and in order to keep it in position, I adopted a plan first suggested by Sir W. Bowman, and pared at two points the corresponding tarsal margins of the lids, and united them by two fine sutures, and thus obtained a fixed level surface upon which to transplant some new skin as soon as the granulations were ready to receive it.”

“October 18.—As the whole of the upper eyelid presented a unhealthy granulating surface, and the tarsal margins were firmly united, I transplanted a portion of skin of the size of a silver three-penny-piece, which I removed with a pair of scissors from the inner side of the arm, and placed it on the nasal side of the lid, as at that spot the granulations looked most vascular and healthy. A piece of transparent isinglass plaster was laid across the lid to keep the piece of skin *in situ*, and over this a fold of lint with a compress of cotton wool was placed, and the whole was kept in position by a Liebreich's bandage, which was drawn firmly across both eyes. Before fastening the bandage, a compress of cotton wool on lint was also applied over the sound eye, as it was essential that both eyes should be excluded from light, in order to prevent any disturbance of the lid on which the new skin had been planted, from that

constant rolling of the globes which goes on when one eye is allowed to remain open, and be used by the patient."

"On October 29, the whole of the raw surfaces were completely skinned over."

In my second case, I transplanted a larger portion of skin, and succeeded in obtaining a favourable result.

The following is from the report in the *Lancet*, January 7, 1882:—

"H. E——, aged fifty-one, an engine-driver, was admitted into the hospital on November 25, 1881, on account of a severe ectropion of the right upper eyelid. His history was as follows:—Whilst at work driving an engine at a chemical manufactory, some chemicals near him exploded, and the liquor was blown over the right side of the face, including the temple, brow, and upper eyelid. He was taken to the Poplar Hospital and placed under the care of Mr. Brownfield. Much of the burnt skin sloughed and a large granulating surface was left. The healing of the wound was facilitated by grafts of skin placed on it whilst in the hospital.

On admission into Moorfields Hospital, there was a severe ectropion of the right upper eyelid caused by dense cicatrices. The tarsal edge of the upper eyelid was adherent to a line just below the eyebrow, so that the whole eyelid was completely everted. The cicatrices extended round the temple and brow, so that no healthy skin could be obtained with which to make a new eyelid. An incision was made just above the tarsal edge, and the eyelid dissected from its adhesions was made to fall over the eye. The tarsal edges of the upper and lower eyelid were then united at two points, and an oval-shaped piece of skin half an inch long, and a quarter of an inch wide, was cut from the inner side of the forearm, and laid upon the raw surface, and fastened in position by two fine sutures to the upper edge of the wound. The parts were then covered with a piece of lint smeared with vaseline and a compress of cotton-wool with a bandage applied to keep the whole *in situ*. The patient progressed favourably; the cuticle desquamated from the new skin, which, however, retained its vitality, and completely united to the tissue beneath it. On December 23, the patient was discharged from the hospital, well pleased with the result."

PARALYTIC AND SPASMODIC AFFECTIONS OF THE EYELIDS.

PTOSIS, or a drooping of the upper eyelid over the eye, may be due—

a. To paralysis of the third nerve, or to that branch of it which supplies the levator palpebræ muscle.

β. To injury of the levator palpebræ.

γ. It may be congenital.

δ. Partial ptosis may be occasionally met with in old

people, apparently dependent on a redundancy of wrinkled integument.

Ptosis may be either *complete* or *partial*. In the former the greater part of the cornea and the whole of the pupil is covered by the lid, which cannot be raised by the will of the patient; in the latter the pupil is only partially hidden, and the lid can be slightly uplifted by a strong effort.

The causes which may produce paralysis of the third nerve, or of one or more of its branches, have been already mentioned in the Section on PARALYTIC AFFECTIONS OF THE MUSCLES OF THE EYE, page 292.

Ptosis from injury may be induced by a wound of the upper lid, lacerating the levator palpebræ muscle so as to impair its function.

Treatment.—In recent cases of ptosis arising from paralysis of the third nerve, or of the filament of it which goes to the levator palpebræ, the course of treatment recommended for paralytic affections of the ocular muscles (page 298) must be followed. If, however, medicinal agents fail, relief must be sought from some operative proceeding. For congenital and traumatic ptosis, internal medicines will be of no avail.

In deciding on an operation for ptosis, it is a question what amount of drooping of the lid will render surgical interference advisable. My own feeling is, that if the paralysis is partial, and without any effort on the part of the patient half the pupil is exposed, no operation should be performed. If, however, the palsy is complete, or only a portion of the pupil can be uncovered by a great effort, an attempt should be made to permanently raise the lid, and place it as much as possible under the control of the occipito-frontalis muscle.

The various operations for ptosis are based on the one endeavour to place the upper lid under the action of those fibres of the occipito-frontalis which are mingled with the orbicularis. This end may be accomplished in several ways. The following is, however, the most satisfactory operation:—

A horizontal incision is first made through the skin of the upper lid about 2''' from its tarsal margin and along its entire length; the lips of the wound are then separated by drawing them apart and by a little dissection beneath the integument, until a considerable portion of the orbicularis covering the lid is exposed; this is then seized

with a pair of forceps, and a horizontal strip of the muscle about a quarter of an inch in width is excised. The edges of the wound are then brought together with three sutures, each of which is made to pass through the upper cut portion of the orbicularis. In this manner the lower part of the lid is brought under cover of the upper fibres of the orbicularis, into which the middle and outer fibres of the occipito-frontalis are inserted, and thus a certain amount of control over the upper lid is given to that muscle. In addition to this, the power of closing the lids is diminished by the excision of the broad band of the orbicularis.

An attempt to relieve ptosis by simply excising a piece of the skin of the upper lid is generally unsuccessful.

PARALYSIS OF THE ORBICULARIS MUSCLE—*Lagophthalmos*—is caused by paralysis of the portio dura of the seventh nerve, and is usually associated with palsy of the other facial muscles. It is generally due to some local affection of the portio dura, either as it traverses the bony canal in its passage from within the skull, or after it has emerged from the stylo-mastoid foramen. It may also arise from disease of the brain, as in cases of hemiplegia. According to Dr. Trousseau, it is when the facial palsy is dependent on local causes, and not on brain disease, that the paralysis of the orbicularis is most complete. The knowledge of this fact is used by him as a point in diagnosis; "hence," he says, "if a hemiplegic patient be asked to shut his eye, he does it completely enough to hide the globe of the eye, whilst the eyeball remains uncovered in cases of paralysis of the seventh pair."*

The diseases which lead to the paralysis of the portio dura of the seventh nerve are syphilis, rheumatism, and gout, either of which may cause pressure on the trunk of the nerve from an exudation in its immediate vicinity, or from an inflammatory thickening of the nerve-sheath. Palsy of the facial may also be induced by the nerve being compressed by tumours near the angle of the jaw, by exposure of the side of the face to cold currents of air, and from injury.

The symptoms of palsy of the orbicularis are, an

* Trousseau's Clinical Medicine, translated by the Sydenham Society, vol. i. p. 3.

inability to close the eyelids, and, in exceptional cases, where the paralysis is complete, the patient has not the power even to approximate them. A peculiar stare is thus given to the eye, from which the affection has received the name of *lagophthalmos*, or "hare's eye." The lower lid having lost the support of the orbicularis, falls away from the globe, and the punctum becoming everted the tears flow over the cheek, and the tarsal margins are apt to become excoriated. The most distressing symptoms, however, from a loss of power of the orbicularis arise from the exposure of the eye, from the imperfect closure of its lids, to the contact of foreign particles, and the irritating effects of wind and glare.

The treatment of palsy of the orbicularis is the same as that described for the paralytic affections of the ocular muscles (see page 298). When, however, the paralysis of the facial nerve is due to some local cause, as the presence of a tumour, or an enlarged gland near the exit of the nerve from the stylo-mastoid foramen, special attention must be devoted to its removal.

To protect the eye from exposure, the lids may be kept closed by two strips of plaster placed across their tarsal edges: or a shade, or some other light covering, may be worn by the patient. The most efficient mode, however, of preserving the eye in cases of palsy of the orbicularis is to temporarily unite the margins of the lids at one or two points, after the manner first practised by Sir W. Bowman in his operations for ectropion. (See Article ECTROPION, page 345). In a patient with complete paralysis of the orbicularis, whose eye was inflamed from exposure, I adopted this treatment, and kept the lids closed for two months, when the orbicularis having recovered power, I divided the bands of adhesion, and set the lids again at liberty.* By this simple proceeding, the eye was effectually preserved from all irritation, and the inflammation for which the patient came under my care, rapidly subsided.

BLEPHAROSPASM, or spasmodic contraction of the orbicularis, causing the lids to be tightly grasped upon the globe, occurs in all affections of the eye in which photophobia is a prominent symptom. It is caused by

* Royal London Ophthalmic Hospital Reports, vol. vii. p. 5.

some irritation of the fifth nerve, inducing a reflex contraction of the orbicularis.

a. It is met with in severe cases of the purulent ophthalmia of infants; and in most of the diseases of the cornea, especially those which are marked by ulceration. The continued spasm will sometimes cause entropion, by folding in the tarsal margins of the lids. This spasmodic entropion generally happens to the lower lid.

β. It frequently occurs in granular ophthalmia, when from spasm of the orbicularis it is often difficult to evert the lids to treat the granulations.

γ. It may accompany the simple hyperæsthesia of the retina, which is occasionally seen in anæmia and debility.

δ. It is present in most cases of lodgment of foreign bodies in the eye.

ε. It may also be associated with neuralgia of the fifth nerve, especially of its supra-orbital branch.

The treatment must consist in the endeavour to arrest the spasm by the removal of the source of the irritation. When a foreign body is suspected, the lids should be carefully everted, and the surface of the cornea scanned over, as if a particle of grit or dust can be detected, the taking it away will at once remove all spasm.

For the mode of dealing with the various affections of the cornea, or with granulations of the lid, the reader must refer to the sections under their respective headings. In spasm of the orbicularis arising from anæmia and debility, cinchona with small doses of the tincture of belladonna will be found very useful, or some of the preparations of iron may be ordered. The eyes in all cases should be protected from exposure to glare by dark neutral-tint glasses, and if the intolerance of light is severe, a few drops of the solution of atropine (F. 15) may be dropped twice or three times a day into the eye.

When the blepharospasm is associated with neuralgia of one of the branches of the fifth nerve, quinine should be given in full doses, and the pain be relieved by the subcutaneous injection of from gr. $\frac{1}{6}$ to gr. $\frac{1}{3}$ of the acetate of morphia (F. 30), according to the age and suffering of the patient. If pressure with the finger on the infra- and supra-orbital branches of the fifth nerve will decide which of the two is the cause of the reflex spasm of the orbicularis, that nerve may be subcutaneously divided with a tenotomy knife.

NICTITATION, or a frequent blinking of the lids, is a peculiar nervous affection, in some patients quite involuntary, and in others only to be suppressed by a strong effort of the will. It is sometimes associated with chorea; it then becomes most manifest when the patient is self-conscious. In extreme cases the nictitation may be so frequent and beyond the control of the will, as to interfere with all duties which require a close application of the eyes.

Treatment.—If any source of irritation can be detected to account for this reflex action of the orbicularis, it must be at once removed. Inquiry should be made concerning the functions of the visceral organs, and means be taken to rectify any derangement. If there be chorea, the succus conii may be tried in doses from half a drachm to three drachms twice a day, to be increased according to the age of the patient. During the administration of the drug its effects must be watched carefully.

ULCERATIONS OF THE EYELIDS..

SYPHILITIC ULCERS OF THE LID are generally *secondary*; it is rare to meet with the *primary* sore in this locality. I have, however, seen a chancre on the eyelid; it was in a child under two years of age, and was followed by a copious secondary eruption. No doubt the virus was conveyed to the lid through the finger of the mother or the nurse of the child.

Secondary syphilitic sores on the lid resemble very much in appearance epithelial ulcers, for which they may be easily mistaken. They usually commence close to the tarsal margin, which they partially destroy, leaving a notch which is very characteristic of the disease. The ulcer will often heal at the point where it first commenced, whilst at the same time it extends itself in the opposite direction. In this respect it differs from the rodent or epithelial sore, in which there is no real repair of any portion of the ulcerated surface. The previous history of the patient, when it can be truthfully obtained, is also an important guide in the diagnosis; but in cases of doubt a week or ten days' treatment with anti-syphilitic remedies will usually decide the true origin of the disease.

Treatment.—As an application to the sore, a weak mercurial ointment (F. 129, 130). Internally, a mixture

with iodide of potassium (F. 91); and pil. hydrarg. subchlorid. comp. gr. 5 every other night; or the liq. hydrarg. perchlorid. (F. 101) may be given two or three times daily; or the iodide of potassium and perchloride of mercury may be combined in the same mixture. If the patient be a child, the hydrarg. cum cretâ (F. 151) must be given every night, or night and morning, and during the day small doses of the mist. ferri iodid. or the mist. potassii iodidi cum ferro (F. 142, 143).

RODENT CANCER OF THE EYELID generally commences as a small pimple in the skin, near the tarsal edge, which ulcerates and then scabs over, but does not heal. The granulations of the ulcer are small, the secretion from it is slight, and there is no fetor. It usually gives little or no pain; indeed the attention of the patient is often called to it for the first time only by a sense of itching, which causes him to scratch it with one of his finger-nails; and to this scratch is frequently attributed the after-progress of the disease. Examined between the fingers, the ulcerated surface will be found to have a hard base and margin. It is not simply an ulcer, but it is a new growth or infiltration in the skin, which induces ulceration of the surface as fast as the deposit takes place. In its onward slow creeping progress more skin is involved, and the dimensions of the ulcer are increased; but repair does not follow destruction; there is no true cicatrization in rodent cancer, although here and there parts of the wound may be imperfectly scabbed over.

Rodent cancer does not affect lymphatic glands, and it generally attacks the parts of the face above the mouth. The disease is closely allied to epithelioma, into which, if left, I have seen it converted. I cannot say whether this change is due to a mere progress of the disease, or whether it is that rodent cancer is peculiarly apt to have super-added to it the characters of epithelioma after the same manner that old standing ulcers, unhealed wounds, or scars, become epitheliomatous. For the treatment of rodent cancer, and the diagnosis between it and epithelioma, see the next section.

EPITHELIOMA OF THE EYELID — *Epithelial Cancer*—is rare as a primary affection, but it is occasionally developed from a rodent cancer in this locality. In the early stages, epithelioma resembles rodent cancer,

but in the later periods of the disease there is a marked distinction between them. Epithelioma invades the lymphatics, and involves the neighbouring glands, which subsequently inflame, contract adhesions to the skin and ulcerate, whilst in rodent cancer the glands are not affected.

FIG. 79.

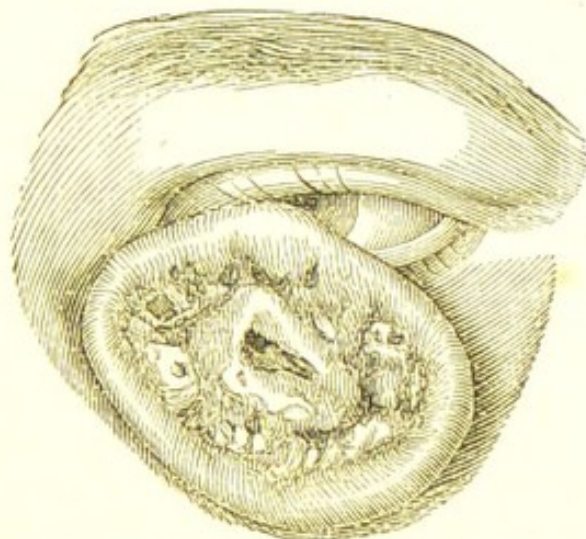


Fig. 79, represents a primary epithelioma of the eyelid in a man æt. sixty-five. The case is reported in the Royal London Ophthalmic Hospital Reports, vol. x. p. 200.

The points of difference between rodent cancer and epithelioma are :—

Rodent cancer does not affect lymphatic glands, whilst epithelioma does, and often at an early stage of the disease.

Rodent cancer is a rather dry ulceration with only little secretion and no fetor, and the granulations are small. In epithelioma the secretion from the ulcerated surface is abundant and fetid, and the granulations large, exuberant, and often in bosses.

Rodent cancer is usually confined to the upper part of the face, and starts *always* in the skin, whilst epithelioma, although it has a preference for certain localities, as where skin joins mucous membrane, may under certain conditions attack any part of the body where there is epithelium.

The points of resemblance between rodent cancer and epithelioma are :—

Both rodent cancer and epithelioma are new growths, composed mainly of epithelial cells; and the new growth

is the only part involved in the ulceration. As the growth increases and includes more of the skin and deeper tissues, so the ulceration continues to extend; but the ulceration does not go beyond the new deposit.

Treatment of Epithelioma and Rodent Cancer.

—Excise the whole of the disease, carrying the incision into the sound skin, so as to be certain that none of the morbid growth is left behind. Arrest all hæmorrhage by means of ligature, and if necessary with the actual cautery; and then thoroughly soak the surface with a solution of chloride of zinc gr. 40 ad aquæ 31, or touch it over with the solid chloride of zinc. A little simple dressing is now to be placed over the wound, which should be allowed to heal by granulation. If in the course of cicatrization any suspicious-looking granulations spring up, they must be at once destroyed by sprinkling on them a little of the chloride of zinc powder (F. 8), or by applying the chloride of zinc paste (F. 7) spread on fine lint or linen. There are other ways of dealing with rodent and epithelial cancer, such as destroying them with the strong nitric acid, or with the liq. hydrarg. nitrat. acid, or with the chloride of zinc; but I much prefer first excising the disease, and then using the chloride of zinc in the way I have described.

TUMOURS OF THE EYELIDS.

TARSAL CYSTS — *Meibomian cysts* — *Chalazion* — usually occur as small isolated tumours in the upper and lower eyelids. There may be two or three of them in the same lid, but they are independent growths, and in no way connected. They generally grow to about the size of a small pea, but they will occasionally attain much larger dimensions. They are developed from the follicles of the Meibomian glands, of which they seem to be a morbid expansion. To the finger they feel like small shot in the lid; and externally they give a nodulated appearance, which makes the patient anxious to be rid of them. They vary in consistence, and in the character of their contents; in some instances they are filled with a solid or thick gelatinous material; whilst in other cases their contents are either a transparent or semi-opaque curdy fluid, or, if the cyst has been inflamed, pus. When first noticed, a tarsal cyst is usually small and firm; as it grows it approaches the inner surface of the lid, its con-

contents undergo degenerative softening, and the conjunctiva immediately covering the tumour becomes thinned and of a bluish colour. In this state the cyst may remain for many months or even years without any apparent change, when from some unexplained cause it may inflame and suppurate.

Treatment.—The best time for operating on a tarsal cyst is when the conjunctiva covering it looks thin and bluish, as its contents are then more easily turned out than at an earlier stage of the disease. The surgeon standing behind the head of the patient, who is seated on a chair, should with one finger evert the lid, and with a cataract knife make an incision through the length of the conjunctival wall of the cyst in a line parallel with the tarsal margin; if the tumour is large, another smaller incision may be also made through it at right angles to the first. With a fine scoop the whole of the contents of the cyst are then to be evacuated, and this is best done by giving to the scoop a slight rotatory movement, which helps to break up the material within the cyst, whilst it also scratches the lining membrane, and sets up sufficient inflammatory action to cause the obliteration of the sac. For two or three days succeeding the operation, a probe should be passed along the line of the incision, to prevent the lips of the wound uniting before the cavity is closed. When the contents of the cyst are so solid that the whole cannot be shelled out, it is a good plan to apply to the interior of the sac a probe charged with nitrate of silver; free suppurative action will be thus induced, and in all probability a cure will be effected.

In small tarsal cysts which have a feeling of solidity like small shot, and especially when they occur in the lower eyelid, the method suggested by the late Mr. Critchett is very useful. The lid being everted, a fine cataract needle is made to transfix the cyst in a line with the tarsal margin, and the piece thus pierced by the needle is excised with a cataract knife.

The contents of the cyst are then turned out as far as possible with the scoop. No attempt should ever be made to dissect out a tarsal cyst by an incision through the skin of the lids.

NÆVUS OF THE EYELID may be limited to the skin, or it may include the whole thickness of the lid, and extend through the palpebral cartilage. Sometimes it is

an extension of a similar but larger growth within the orbit, with which it freely communicates.

Treatment.—In treating nævi of the lid it is of great importance to avoid destruction of healthy skin, lest a bad ectropion should follow the means adopted for the cure of the disease. A small superficial arterial nævus may be often dissected out; or it may be destroyed by the actual cautery, using the finely pointed cautery made specially for eye purposes, with which the nævus may be touched at two or three points. Where the growth extends more deeply, one or two threads soaked in a strong solution of the perchloride of iron may be drawn through it, and be allowed to remain until suppuration has commenced, when they should be removed.

Another very efficient way of treating a nævus of the lid is by electrolysis. From seven to ten cells of the continued current battery will be sufficient. The positive needle is to be introduced into the substance of the nævus at one extremity and the negative at the other, and held in position until a visible change has begun to take place in the nævoid tissue, which is indicated by a change of colour. If the nævus be large, the points of the needles may be shifted to other parts of the growth at the same sitting. Two or more applications at intervals of from one to three weeks may be necessary to completely obliterate the nævus.

When the nævus is too large to be dealt with in either of the ways mentioned, it must be ligatured. The plan recommended by some surgeons of injecting nævi with solutions of iron or of tannin is dangerous to life, and should not be practised. There are several cases on record where this mode of treatment has terminated rapidly in death.

SEBACEOUS OR DERMOID CYSTS occur usually in two localities—at the upper and outer margin, and at the lower and inner edge of the orbit, just over the nasal process of the superior maxillary bone. They are congenital, and although they often appear to the touch to be superficial and loosely attached, they are in reality placed deeply, lying in a depression of the bone, beneath the orbicularis, and very adherent to the surrounding parts. They are filled with sebaceous matter and contain numerous fine hairs.

Treatment.—They should be dissected out through a

single incision, made over the centre of the prominence of the tumour, and in a line corresponding with the curves of the brow or the orbit. Care should be taken to remove the whole of the cyst, as when portions of it are left it will sometimes re-form. The operation, although apparently very slight, is one which often requires considerable neatness and dexterity. In removing the cyst at the lower and inner angle of the orbit, much trouble is frequently experienced from the angular artery or the frontal branch of the ophthalmic being divided, and the consequent brisk hæmorrhage which follows. It is seldom that a ligature is required, pressure with the finger for a few minutes will usually suffice to stop all the bleeding.

XANTHELASMA PALPEBRARUM, called also by the late Dr. Addison and Sir William Gull* *Vitiligoidea plana*. This affection consists of buff or yellow-coloured patches of the skin, which are most frequently seen on the eyelids near their inner angles. These markings are often placed symmetrically on each side of the face, either above or below the inner canthi, and I have met them in a few instances on the upper and lower eyelids of both eyes. The patients who are thus affected are nearly always beyond the middle age, and mostly females, never children. Mr. Hutchinson says that these xanthelasmic patches invariably begin on the left side near the inner canthus. He thinks that that they are evidences of past rather than of coming disease, and are most liable to occur in those who have suffered from severe and frequent sick headaches. The late Dr. Addison believed that they were associated with disease of the liver.

Prognosis.—These yellow patches on the eyelids are perfectly harmless. They may increase in size and in number, but I have never known them produce discomfort, or in any way interfere with the free movement of the lids. When, however, these discolorations of the skin are of large size, they are very unsightly, and on this account they frequently become the source of much mental anxiety.

Treatment.—No local application, nor internal administration of medicine will diminish or eliminate these

* Guy's Hospital Reports for 1850.

buff or yellow-coloured effusions. As a rule it is best to leave them alone. In severe cases or when the yellow patches cause annoyance from the disfigurement they produce I excise them. I have treated several cases in this manner, and the patients have been well pleased with the results.

EPICANTHUS.—This term is applied to a crescentic fold of skin, which slightly overlaps the inner canthus of each eye. By increasing the breadth of the integument between the eyes a peculiar Chinese expression is given to the face, which is sometimes distasteful to the patient or his relatives. Epicanthus is congenital, and usually decreases as the child grows and the bridge of the nose is developed. It is seldom that it interferes with sight.

Treatment.—It is only in extreme epicanthus that any operative proceedings should be adopted. In such cases a vertical ellipse of skin may be excised from the centre of the space between the eyes, and the edges of the wound united with sutures. In this way the crescentic folds of integument will be unravelled, and the canthus of each eye exposed.

INJURIES OF THE EYELIDS.

ECCHYMOSIS OF THE EYELIDS, or, as it is commonly called, “a black eye,” is an effusion of blood into the cellular tissue of the lids and of the parts surrounding them. It may be limited to one or both eyelids, or it may extend to the cellular tissue of the face around the orbit. The blood is generally absorbed in the course of a week or ten days, during which time the discoloration gradually fades away, but, in doing so, passes through a variety of shades which must be familiar to all. It is very rare that any suppuration follows.

A black eye is occasionally complicated with fracture of one or more of the frontal or ethmoidal cells. This casualty is recognised by an emphysematous state of the eyelids and of the cellular tissue around the orbit. When the patient blows his nose, air is forced through the fissured bone into the neighbouring cellular tissue. In no case have I ever seen emphysema of the lids productive of any harm, though the discomfort it occasions is always great. The patient should be cautioned not to blow his nose for some days; the fissured bone will then soon become closed;

and if no fresh air is forced into the cellular tissue, that which is already there will rapidly disappear. Pricking the integument with a fine needle to give vent to the air is seldom if ever necessary, and should not be resorted to except in cases of extreme tension of the skin, a condition which is not likely to occur from a simple fracture of a frontal or an ethmoidal cell.

Treatment.—The application of cold immediately after the blow will limit the effusion of blood, and so diminish the extent of the after-discoloration, and may therefore, shortly after the receipt of the injury, be advantageously used. This is best done by cold evaporating lotions; or by applying ice in an india-rubber bag to the eye; or by a fold of wet linen being laid over the eye, and frequently moistened with iced water. The practice of puncturing the swollen parts, as recommended and frequently adopted by prize-fighters, is essentially wrong. It may, and no doubt does, afford temporary relief to the swelling when it is great, but it renders the part liable to suppuration and erysipelas, neither of which would have been anticipated if the skin had not been cut. A remedy which has for many years received considerable credit is a poultice of the *black bryony root*. It is "made by mixing some of the black bryony root scraped finely with a little crumb of bread. This is placed in a muslin bag over the palpebræ for several hours together; and usually it has an excellent effect in promoting the action of the absorbent vessels."* It is, however, a drug which cannot be always procured; the best place to seek for it is from one of the herbalists in Covent Garden Market. The tincture of *Arnica montana* has also acquired a great repute for the power it is supposed to possess of favouring the absorption of blood in cases of ecchymosis. It may be applied pure over the part with a camel's-hair brush, or it may be used as a lotion (F. 62).

ABSCESS OF THE EYELID.—From contusion or laceration of the integument of the lid, acute inflammation and suppuration of the subjacent cellular tissue may follow. The eyelid becomes red, swollen, and shining, and unmistakable evidence of pus is soon manifested. The treatment is the same as for an abscess in any other

* Tyrrell on Diseases of the Eye, vol. i. p. 200.

part of the body. As soon as it is clear that pus has been formed, an incision should be made to give vent to it, and a warm poultice should be afterwards applied. The only point which requires special notice is the way in which the abscess should be opened. The incision should be made with a fine sharp knife in the horizontal direction, and in a line with the orbital fold of skin just beyond the lid. The cicatrix will then be a mere line, and from its situation it will be scarcely observable.

WOUNDS OF THE EYELIDS may be divided into two classes :—

1. Those which involve only the skin of the lid.
2. Those which have cut through its tarsal border.

1. **Wounds which involve only the skin of the lid** require the same treatment as similar wounds in any other part of the integument of the body; but from the delicacy of the skin in this locality, and the importance of avoiding as far as possible an unseemly scar, more careful manipulation is needed to bring the edges into accurate apposition.

2. **Wounds which have cut through the tarsal border of the lid.**—In lacerations of the eyelid there are two forms of injury to which its tarsal margin is exposed :—

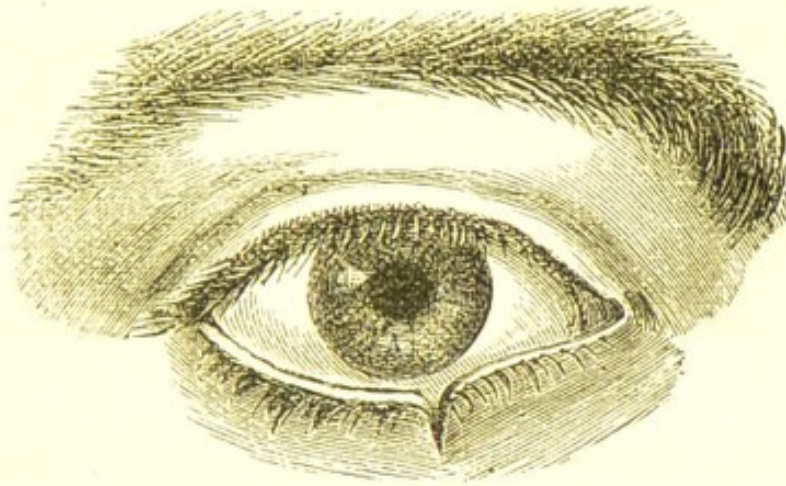
a. The cartilaginous border of the lid may be cut or torn through at any part.

β. The rent may pass through the canaliculus, tearing it away from the punctum lachrymale, which may still remain intact at the extremity of the cartilage.

(a.) **Where the cartilaginous border of the lid has been cut** the edges of the wound become slightly drawn apart, and an unsightly notch is formed, as shown in Fig. 80. If the wound has been a clean incised one, the divided ends of the cartilage should be very accurately fitted together and fastened *in situ* by a pin and twisted suture. The pin should be a very fine one, such as is used by entomologists for pinning the smaller insects. It should be made to pass through the cartilage of the lid so close to its free edge, that the silk when twisted on the pin will slightly overlay the tarsal margin. By attending to these details accurate union will be probably effected, without leaving any notch or irregularity of the border of the lid. When, however, the edges of the

wound of the cartilage are jagged or irregular, as frequently happens when the lid has been torn by some

FIG. 80.

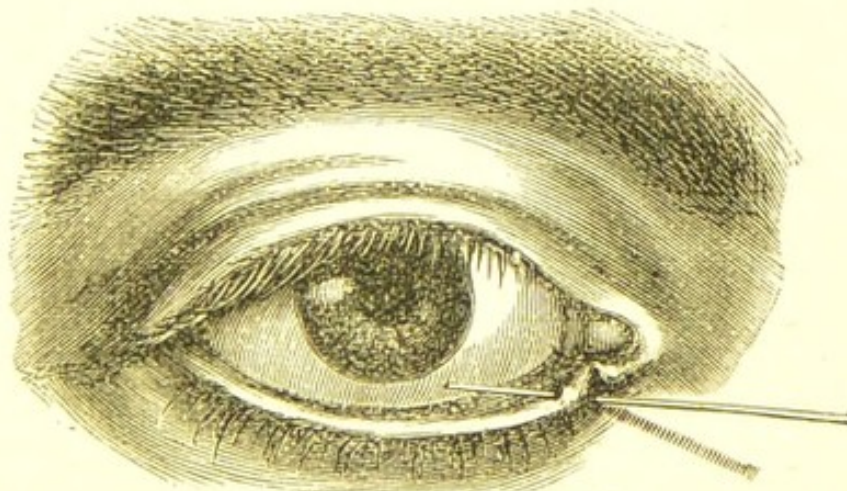


semi-blunt instrument, it is best first to pare them smooth with a sharp scalpel before bringing them together with a pin and twisted suture.

If after a wound of the cartilaginous border of the lid no treatment has been adopted, the edges of the gap are apt to become more widely separated, and occasionally a certain amount of eversion is also produced. The extent of the deformity will necessarily depend very much on the depth of the wound.

(β) When the canaliculus has been torn through and detached from the punctum, as in Fig. 81, a search should be first made for the divided end of the

FIG. 81.



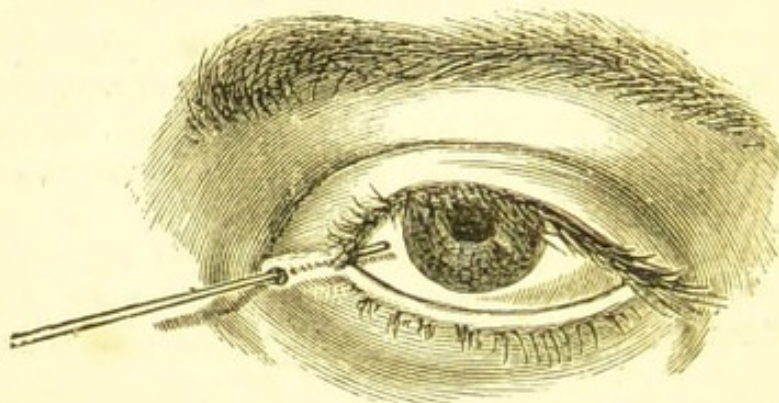
tear-duct. It is of course impossible so to adjust the torn parts that the punctum and the canaliculus can

again be made to communicate with each other. If, therefore, the open end of the divided canaliculus can be detected, a small director (Fig. 64, page 322) should be passed up it, and with a cataract knife it should be slit into the lachrymal sac. The closed tube will thus be converted into an open canal along which the tears will afterwards flow into their proper channel. The torn parts are then to be brought into their normal position and fastened *in situ* with one or two fine silk sutures.

RESULTS OF INJURIES AND ULCERATIONS OF THE EYELIDS.

ANCHYLOBLEPHARON is the union of the margins of the eyelids to each other. They may be either partially or completely united. It is, however, seldom

FIG. 82.



The woodcut is a good illustration of a case of partial ankyloblepharon, and shows very well the position of the fistula which is so frequently met with when the inner portions of the lids are united.

The drawing was taken from a young woman who had met with an accident nine or ten years previously, when she fell down and struck the inner angle of the eye against one of the whalebones of an umbrella. The inner canthus and the inner extremities of both the eyelids were torn, and in the process of repair which followed the injury, the inner margins of the upper and lower lids became united to about one-third of their extent.

that the adhesion extends throughout the entire length of the lids. The inner third of the two lids is more frequently joined than the outer or middle portion. In

nearly all cases of anchyloblepharon, whether partial or complete, a fistulous opening is left at the inner canthus, through which some of the tears find their way on to the face. The union between the lids may be either direct, the two edges being completely adherent, or they may be united by membranous bands passing from the one to the other.

The causes of anchyloblepharon are lacerated wounds, or any accident which produces an abrasion of the corresponding surfaces of the tarsal edges of the eyelids.

Treatment.—When the union between the lids is direct, and a fistula exists at the inner canthus, a small director should be passed behind the adherent margins, and out at the fistulous orifice, and upon it the adhesions may be severed with a pair of scissors; or if this cannot be readily accomplished, the lids may be dissected apart with a sharp scalpel.

If a membranous band is the bond of union between the two lids, it should be divided on a director passed beneath it, and the projecting portions cut off close to the margins of the lids. The chance of success following either of the operations depends very much on the daily dressing of the wound: special care should be taken to keep the lids from reuniting during the progress of cicatrization. This may be generally accomplished by daily separating them, and anointing the granulating surfaces with a little sweet oil.

SYMBLEPHARON is an adhesion of the lids to the globe. It is usually produced by an injury which has caused either a destruction or an ulceration of the opposed conjunctival surfaces of the lid and globe, and their subsequent union by granulation. Lime, mortar, and burns from hot metals, or scalds from hot fluids are the most frequent causes of symblepharon, but it may be produced by any agent which either destroys or abrades the corresponding parts of the lids and globe. Most of the very severe cases of symblepharon which have come under my notice have been due to lime. If the injury it has inflicted is severe, it is absolutely impossible to prevent the union of the lids to the globe. All endeavours to keep the opposed granulating surfaces apart will fail. The contraction which goes on during the process of cicatrization draws the lids and globe into close apposition, and direct union will ensue in spite of all efforts to stop it.

Symblepharon is said to be **complete** when the entire inner surface of one lid is adherent to the globe, and **partial** when the adhesion is limited to only a part of the opposed surfaces. Both eyelids may be often seen partially attached to the globe, or the lower lid may be completely united to it: but it is exceptional to meet with complete symblepharon of both the upper and lower lids of the same eye. The lower eyelid is much more frequently affected by symblepharon than the upper.

Two forms of symblepharon may be recognised:—

1. Membranous bands or frena passing between the lids and the globe.

2. Direct and close adhesions between the opposed surfaces of the eye and lids.

1. **Membranous Bands between the Lids and Globe.**—This is the simplest and most remediable kind of symblepharon. It is due to a less extensive and more superficial injury than that which produces the second form; generally to some *limited* ulceration or abrasion of the corresponding parts of the eye and lids. During the healing process the granulations of the opposed surfaces become united, but the constant pull which is exerted upon them by the movements of the globe will often so stretch the adhesions that they will become elongated into membranous bands.

2. **Direct and Close Adhesions between the Opposed Surfaces of the Eye and Lids.**—These are caused by an absolute destruction of corresponding portions of the conjunctiva of the eye and lids. Deep ulceration or sloughing follows the injury, and opposed granulating surfaces are left, which ultimately become firmly adherent and blended with each other. During the cicatrization, the contraction of the surrounding conjunctiva draws the lids and globe into such close contact, that the movements of the eye cannot stretch the bonds of union, and the lids and globe remain for ever afterwards firmly bound together.

Treatment.—All operations for the cure of symblepharon are as a rule very unsatisfactory: in the severe cases they generally fail to effect any good; and in the milder ones, the relief which is afforded is comparative. It is only in the slight cases that positive good will be found to follow surgical treatment—those in which small membranous bands or tags of adhesion pass between the eyelids and the globe. When these are insulated, so that

a probe can be passed beneath them, and the oculo-palpebral fold of conjunctiva still exists entire, much benefit will be derived from an operation.

There are two ways in which these narrow membranous bands may be treated.

a. They may be simply divided by a scalpel or a pair of fine scissors; and by daily passing the end of a probe dipped in a little sweet oil between their cut ends, reunion may generally be prevented. This mode of treatment is, however, only applicable to the very mild cases, where a simple tag of adhesion ties the lid to the globe.

β. If the bands are small, they may be first cut off close to the globe, and the edges of the wound which is thus made in the conjunctiva may be drawn together and united by one or two fine stitches. The other extremities of the bands are then to be severed from their attachment to the lid. As in the first operation, careful daily dressing will be required to prevent a rejunction of the cut surfaces, for unless the wound in the conjunctiva closes by immediate union, which it may fail to do, the tendency to a return of the symblepharon is very great.

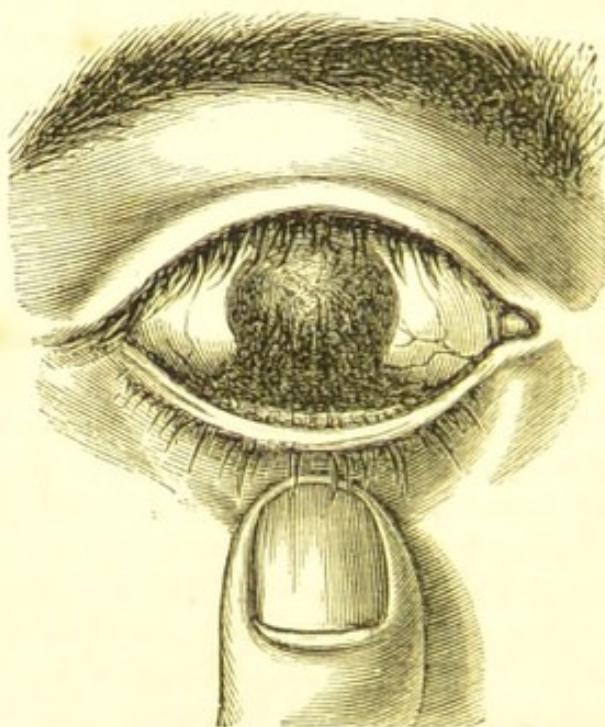
In those cases of symblepharon where there are direct and close adhesions between the eye and the lids, many different plans of treatment have been tried, but most of them without much success. It is only where the extent of the conjunctival surfaces involved is small, that even amelioration can be hoped for. The lid may be generally easily separated from its union with the globe by a careful dissection, but we have no means at our command by which we can prevent their again uniting. Plates of metal and glass shields have been interposed between the granulating surfaces, but with very indifferent success. They have been generally extruded during the contraction which accompanies cicatrization.

Mr. T. Pridgin Teale, of Leeds, has suggested a plastic operation in cases of symblepharon, which he speaks of very favourably. He first described it in the "Royal London Ophthalmic Hospital Reports," vol. iii. p. 253, in which he has cited cases which have been materially benefited by it. In a short note which he has kindly given me he thus describes the operation: "The adherent lid having been dissected off the eyeball, so as to leave the globe perfectly free in its movements, one, or if possible two flaps of the conjunctiva are dissected from the sound part of the eyeball, and transplanted into the

gap. If any portion of the adherent lid is united to the cornea, the separation of the lid is commenced at the *margin* of the cornea, leaving the apex of the lid still *in situ* as an opaque spot on the cornea."

Taylor's Operation for Symblepharon.—Dr. C. Bell Taylor has adopted the following operation for treating cases of symblepharon:—"After the separation of the adherent lid from the eyeball, a thin piece of skin is to be dissected from the lid, passed through an incision in the tarsal cartilage, and its raw surface brought into contact with the denuded portion either of the lid or of the eyeball itself. In this way the two raw surfaces of the lid and eyeball are prevented from coming into contact until the wound is healed, and the eyeball itself is set free. The transplanted skin is nourished through its base in the first instance, which is divided as soon as it has taken root in its new situation. It then gradually dwindles, taking the place and assuming the functions of the lost mucous membrane."*

FIG. 83.



The woodcut represents a case of symblepharon, caused by the action of mortar on the eye.

There are, however, very many cases of symblepharon where no operation should be attempted. The extent of

* British Medical Journal, Feb. 5, 1876.

the adhesions may be so great that it would be worse than useless to endeavour to divide them.

Anchyloblepharon and **Symblepharon** are often associated; indeed, with the union of the margins of the lids it is very general to find also some adhesion between the conjunctival surfaces of the lids and globe. It is, however, rare to find in one eye a complete union of the globe to the lids, and of the lids to each other.

HERPES ZOSTER FRONTALIS.—This form of herpes deserves special attention, as it is occasionally mistaken for erysipelas of the head, and the eye is frequently affected during the attack. It is the source of very great suffering to the patient; severe neuralgia often precedes the herpetic eruption, accompanies it, and continues for an indefinite period after it has passed away.

Herpes frontalis is *always unilateral*. It occurs but once in a lifetime, and the old are more liable to be attacked than the young. I have had, however, under my care a lad only fourteen years of age, who had suffered severely from an attack of this disease.

Symptoms.—The affection commences with small red patches, which appear in succession upon the brow and forehead of one side of the head, and upon which transparent vesicles rise. When the eruption is fully developed, it consists of clusters of vesicles on bright red erythematous patches, with portions of more or less clear skin between them. These patches usually follow the course of the branches of the supra-orbital division of the frontal nerve over the upper eyelid, brow, and one side of the head, but occasionally vesicles will appear in the direction of the terminal branches of the supra-trochlear nerve, and on the side of the nose in the line of the nasal twig from the ophthalmic nerve. After a few days the vesicles begin to wither and collapse, the fluid within them grows turbid, and they become covered with dark crusts, which shortly fall off, leaving scars and pits which are frequently permanent. There is usually some œdema of the side of the face, and the eyelids may be so swollen as to render an examination of the eye impossible. The eye often becomes affected, and generally at about the time when the vesicles are beginning to fade. The inflammation may be only conjunctival, but more frequently there is some ulceration of the cornea with slight iritis. The duration of the disease is from ten to twelve days, but

the inflammation of the eye which it has excited may last for many weeks, and be the source of much anxiety and trouble. The pain is, as a rule, excessive and neuralgic; it is over the brow and forehead, along the inner and upper edge of the orbit, and down the inside of the nose, and occasionally patients complain of very severe pain in the lobe of the ear.

The points of diagnosis between herpes frontalis and erysipelas have been well laid down by Mr. Jonathan Hutchinson. He says: "Herpes frontalis is always limited to one side, never transgresses the median line of the forehead and nose. It never affects the cheek, although there may be some sympathetic œdema of this part (œdema of contiguity). There is less general swelling of the skin than in erysipelas, and in some cases very little. The vesicles of herpes are smaller, more defined, more numerous, and altogether much more conspicuous and pronounced than are the bullæ of erysipelas. There is much more pain and much less constitutional disturbance in herpes than in erysipelas. The strictly unilateral character of the one contrasted with the irregular location of the other is, however, the most reliable feature for the purpose of ready diagnosis." *

Treatment.—The objects to be accomplished during the progress of the disease are to relieve the heat and irritation of the affected parts, to give ease to the neuralgic pains, and to procure sleep. A fold of lint wet with the *lotio zinci oxidi* (F. 54), or with the *lotio conii cum opio* (F. 44), may be laid over the surface, and moistened as often as it becomes hot or dry. Opium should be administered internally, either in small repeated doses, or in one full dose sufficient to procure sleep at bedtime. The subcutaneous injection of morphia (F. 30) is of great service, and may be given in doses of from gr. $\frac{1}{4}$ to gr. $\frac{1}{3}$, and repeated if the suffering is severe. The bowels should be acted on by some mild purgative, and quinine in doses of from gr. 1 to gr. 3 ordered two or three times a day.

For the relief of the neuralgic pains, which are often so persistent after the rash has completely passed away, the painful parts may be gently rubbed with the liniment. *aconiti cum belladonnâ* (F. 34), and the tinct.

* Royal London Ophthalmic Hospital Reports, vol. v. p. 192.

Cannabis Indica, in doses of from \mathfrak{m} 5 to \mathfrak{m} 15, may be prescribed two or three times a day, with an opiate or sub-

FIG. 84.



Fig. 84 was drawn from the photograph of a patient æt. sixty-five, who had suffered from an attack of herpes frontalis, two years before coming under my care. The attack was ushered in and accompanied by pain, and since the cicatrization of the herpetic sores there has been constant pain, never absent, but varying in intensity. The pain was strictly confined to the right side of the head, most acute over the brow, and of a less degree in the course of the infra-orbital branches. One side of the forehead, as represented in the woodcut, was white from dense cicatricial tissue, which had filled up the sores caused by the herpetic eruption. The scars were limited to one-half of the forehead, as if a line had been drawn down the middle line of the forehead and nose. To relieve the excessive pain from which she suffered, I excised about three-quarters of an inch of the supra-orbital nerve, and divided subcutaneously the infra-orbital as it passed out of the foramen. The side of the head was numbed after the operation, but the relief of pain was complete. The subcutaneous division of the infra-orbital nerve had to be repeated, but after each operation she was much relieved.*

cutaneous injection of morphia at bedtime if the neuralgia is sufficient to prevent sleep. Dr. Bazin "gave arsenical

* Medical Times and Gazette, 1878, vol. i. p. 137.

preparations with success in the obstinate neuralgia consecutive to herpes zoster, and so accomplished cures which had resisted narcotics, narcotico-acrids, and cauterization." *

If all remedies fail, the supra-orbital nerve may be divided subcutaneously. The relief, however, from this operation is, unfortunately, frequently only temporary, but it may be repeated, or a piece of the nerve may be excised. The patient should be cautioned that if the operation is successful, there will be numbness in the parts supplied by the nerve.

CHAPTER XI.

DISEASES OF THE ORBIT.

PROTRUSION OF THE GLOBE — *Proptosis* — *Exophthalmos*—is a symptom common to all the diseases within the orbit. The extent and direction of the bulging of the eye is determined by the character of the affection, and the part of the orbit from which it originates. When the proptosis is slight it is often difficult to decide whether the protrusion is real or only apparent, as any oedema of the lids, or of the conjunctiva of the globe will give a prominent appearance to the eye.

To Ascertain or Measure the Degree of Protrusion of an Eye.—The patient should be seated in a chair with his head thrown backwards, whilst the surgeon, standing behind him, raises the two upper eyelids with one finger of each hand, and at the same time directs the patient to look downwards towards his feet. From this position, above and behind the patient, the surgeon can glance down the face and contrast the level of the two eyes with each other, and compare their prominence with the projecting brow, or with the side of the nose.

ABSCESS OF THE ORBIT may be caused by blows on the eye; by penetrating wounds of the orbit; or by

* Trousseau's Clinical Medicine, Sydenham edition, vol. ii. p. 296.

any violence producing fracture of its bony walls; by the lodgment of a foreign body in the orbital cellular tissue; or occasionally by the extension backwards of a suppurative inflammation of the lids, or of the tissues in immediate contiguity with the eye, no matter how induced. Inflammation of the cellular tissue of the orbit (orbital cellulitis) brought on from any cause may terminate in abscess of the orbit. Caries, necrosis, or orbital periostitis may likewise lead to orbital abscess.

Abscess of the orbit may be either *acute* or *chronic*. In the former the inflammatory symptoms generally rapidly follow the injury; they are sharp and quick in their progress, pus is soon formed, and independently of the history of the case, unmistakable evidence of its presence is afforded by the pain, heat, redness, and swelling. Occasionally, however, there is a variable interval of a week or more of perfect quiet and freedom from pain after the injury before any premonitory symptoms show themselves; but when once started, their course is equally acute and rapid.

Symptoms of Acute Abscess of the Orbit.—Deep-seated pain in the orbit extending around the brow, worse at one time, better at another, but never absent, and steadily increasing in severity. Any pressure on the eye, or even moving it, aggravates the pain. The eyelids become red, shining, and œdematous; and the conjunctiva of the lids and globe vascular, swollen, and chemosed. The eye is now observed to protrude slightly beyond the level of the other, and this protrusion increases as the disease advances and the pus makes its way to the surface. The displacement is usually not directly forwards, but more or less downwards and outwards, or downwards and inwards, according to the situation of the abscess within the orbit and the part of the eye on which it presses. With the increasing protrusion of the globe the sight becomes more or less impaired from the strain which is being exerted on the optic nerve. The orbital fold of skin above the lid becomes obliterated, and the upper lid so swollen and stretched in front of the bulging eye that it cannot be raised by the patient. Over the most prominent part of the swelling a careful examination with the fingers will detect fluctuation. The most usual spot for the matter to point is rather to the inner side of the interval between the supra-orbital ridge of the orbit and the upper border of the globe. Occasionally

the suppuration may be more or less confined to one or other side of the orbit, and this will in a great measure determine the site at which the pus will endeavour to make its exit; either the inner, outer, or lower side of the eye may be the part selected. When the abscess is a small and limited one, there may be little or no displacement of the eye.

With all these local symptoms there is always considerable constitutional disturbance. The skin is hot and dry, the patient has occasional rigors, he is restless, and his sleep is broken from pain.

In chronic abscess of the orbit the symptoms are often masked by the very slowness with which they develop themselves, and by the absence of any severe pain. It frequently happens that the patient does not even seek advice until an increasing protrusion of the eye and a somewhat corresponding diminution in vision excite alarm.

Chronic abscess of the orbit is often most difficult to diagnose, and may easily be confounded with a sarcoma, or some soft orbital tumour, the elasticity of which closely resembles fluctuation. The exciting cause of the abscess may have been an injury inflicted at some distant period, which has been forgotten, and from which the patient thought he had completely recovered; or the slow progress of the disease, and the comparative and in many cases complete absence of pain during its early stages may make it difficult, if not impossible, for the patient to give a correct account of how or when it commenced. When doubt exists as to the true nature of the case, an exploratory incision should be made into the tumour, and the surgeon should be prepared to act at once on the information it will afford him. If it is an abscess, the incision should be enlarged sufficiently to give a free exit to the pus; but if, on the other hand, it should prove an orbital tumour, it should, if practicable, be removed without any further delay.

Treatment of Abscess of the Orbit.—As soon as it is clear that pus has formed, and that the protrusion of the eye, if there be any, is due to its presence in the orbit, a free opening should be made for its escape. The site for making the incision should be that spot where there is the most distinct swelling and fluctuation, and where the pus has a tendency to point. After a free vent has been given to the pus within the orbit, a warm lin-

seed-meal poultice should be applied, and care should be taken that the wound is kept open by examining it daily, and, if necessary, by passing a probe along the course of the incision to prevent the cut edges from uniting. It not unfrequently happens after an abscess of the orbit that the wound from the incision only partially closes, and a long sinus remains from which a slight purulent discharge continues to drain. When this is the case, and when no fragment of necrosed bone can be detected by a probe to account for it, the use of a stimulating injection, such as *zinci sulphat. gr. 2 ad aquæ ʒ 1*, thrown into the sinus with a glass syringe twice a day, will often prove of great benefit. If, however, a portion of dead bone is felt with the probe, time must be given to allow of its becoming detached, or at least partially loosened from the living structure; and then, after enlarging the orifice of the sinus, it may be removed with a pair of sequestrum forceps, first using, if necessary, a gouge, or an elevator, or a pair of fine-cutting bone forceps to separate any portion of bone which may be holding it.

FRACTURES OF THE BONES OF THE ORBIT may be caused by blows on the head, or by the impaction within its cavity of a large foreign body, one extremity of which has passed through the orbital walls into the antrum or the posterior nares. When the fracture extends into the frontal or ethmoidal cells, there is generally emphysema of the cellular tissue of the lids and the surrounding parts. This arises from the patient forcibly driving the air through the broken cells when he blows his nose. Fracture of the orbit is often associated with fracture of other portions of the skull, and in such cases it frequently happens that the contusion or laceration of the brain produced by the blow is sufficient to cause death, independently of the injury which the cranial bones have sustained.

There is, however, one form of fracture which is confined to the walls of the orbit, and which is very fatal. It is caused by direct violence, and is commonly produced by a forcible thrust in the eye with a sharp or semi-blunt pointed instrument, such as the points of a pair of scissors, the end of an umbrella, or a foil, or by the stem of a long tobacco-pipe. The orbit is penetrated, and the end of the stick, or whatever it may be, is thrust against its roof or the upper part of its inner wall, which it in

some cases fractures, whilst in others it breaks its way through the bone and penetrates the substance of the brain. From such an injury the patient seldom recovers: even when the bones are broken, but not penetrated, the sharp splinters usually create such irritation of the brain and its membranes that a fatal result ensues. One peculiarity of this accident is, that its severe nature is apt to be often overlooked; the external wound may be small, the immediate symptoms may be trifling, and the patient, if a mechanic, may be able to continue his work for some hours, or it may be for two or three days, before his condition obliges him to desist. Symptoms of inflammation and suppuration may then come on, coupled with those of cerebral or meningeal irritation; the patient may pass rapidly from slight delirium to complete coma, and die in a period varying from a few days to two or three weeks.

Treatment of Fractures of the Orbit.—Fracture of the orbit requires the same treatment as fracture of any other portion of the bones of the skull, with the exception that even if there is reason to believe that a fragment of one of the orbital bones may be pressing injuriously on the brain, no operation can be attempted to dislodge it. Absolute rest, both mental and bodily, should be enjoined in all cases where a fracture of the orbit is suspected. The patient should be kept in bed, and cold water dressings, or an india-rubber bag of ice should be laid over the eye and brow of the injured side; and the bowels should be freely acted on by a brisk purgative. All stimulants should be forbidden, and a limited diet should be ordered. If there is much pain in the head, six or eight leeches should be applied to the temple, and these may be repeated in twenty-four hours if the symptoms become more urgent.

FOREIGN BODIES IN THE ORBIT.—The lodgment of a foreign body within the orbit is one of the most dangerous accidents which can be met with in ophthalmic practice, as it not only always involves a serious risk to the eye, but it places even the life of the patient in considerable jeopardy, and in some instances has caused death. It may prove hurtful to the patient both by the immediate and secondary effects it is liable to produce.

The immediate effects which may arise from the lodgment of a foreign body in the orbit are;—

1. In its passage into the orbit it may either injure the parts within the eye, or rupture its external coats.

2. Although the eye itself may escape injury, the optic nerve may be wounded, and absolute blindness follow.

3. It may injure the walls of the orbit either by penetrating them or by causing fracture.

The secondary effects which a foreign body within the orbit may excite are:—

a. If a foreign body has escaped observation, and has been allowed to remain buried in the orbit, it may excite

FIG. 85.



Fig. 85 represents a piece of stick which I removed from the orbit of a child three years of age. Seven weeks previously, whilst riding in a perambulator, the child fell with his face on to the point of a stick with which he was playing. A piece of it penetrated the orbit, and the grandmother said she believed she had removed the whole of it. On admission into the hospital there was complete ptosis of the left eye, the globe was protruded a quarter of an inch, and fixed in the centre of the orbit, from palsy of all the ocular muscles; the pupil was widely dilated, and as far as could be made out, the eye was blind. At the inner and lower part of the orbit was a small fistulous opening, from which there was a thin discharge. Although I could not detect a foreign body with a probe passed along the sinus, yet the symptoms all pointed to the presence of one in the orbit. I therefore made an incision into the lower part of the orbit, and succeeded in removing a piece of stick exactly corresponding to the woodcut. The child rapidly recovered, and in four days left the hospital. The protrusion of the eye subsided, the levator palpebræ and ocular muscles gradually regained their power, and in three weeks the lid was open, and the movements of the eye almost restored; but the sight was lost.*

orbital cellulitis and abscess. This may lead on to a general inflammation of the globe, which may end in great impairment of vision, or in complete destruction of the eye from suppuration.

β. As a consequence of the orbital inflammation, a portion of the bones of the orbit may become necrosed.

γ. The inflammation may extend backwards along the periosteum lining the orbital walls to the membranes of

* Lancet, Sept. 15, 1877.

the brain, and destroy the patient by meningitis, tetanic convulsions, or abscess of the brain.

A foreign body generally enters the orbit somewhere between the upper or inner side of the eye, and the roof or inner wall of the orbit; but cases are frequently met with where it has passed in at other points around the eye. If small, it usually buries itself in the loose cellular tissue of the orbit; but occasionally it becomes fixed by either penetrating the globe, or by partially entering one of the frontal or ethmoidal sinuses, or the antrum, or by becoming in some way wedged between the globe and its external muscles.

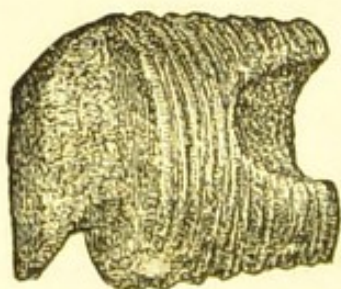
It is very remarkable how often a foreign body has been lodged in the orbit or adjacent cavities without the patient having suffered any great inconvenience from its presence.

In No. 4 of the Ophthalmic Review, page 337, Mr. Brudenell Carter has related a very remarkable case, in which a large piece of an iron hat-peg was impacted in the orbit and antrum of the opposite side, and remained there for a number of days without the patient being aware of its presence. It was then extracted, and the man made a rapid recovery without any impairment of the sight of the eye.

In February, 1869, I extracted from a patient, æt. twenty-eight, the breech of a muzzle-loading gun, which had been impacted for twelve years in the right frontal sinus and upper part of the nose. The following is the history of the case:—

The man stated that twelve years previously his gun burst whilst shooting wild fowl, and produced a severe wound between the eyes, and many smaller ones on his face. He was laid up for four months, during which time both eyes became inflamed and

FIG. 86.



the sight of the left was nearly destroyed. He was attended through his illness by several medical men, but they never found nor did they appear to suspect the presence of a foreign body. He first detected something loose in the nostril about two years and a half before he came under my care. When admitted into the Middlesex Hospital a deep scar was seen between the frontal sinuses, and the upper part of the right side of the nose was swollen. There was an offensive discharge from the right nostril, and the right eye was more prominent than the left. On examination with the finger in the nostril a hard and moveable

body was felt to be lodged beneath the scar and in the upper part of the right nasal cavity, and from the metallic touch it gave to the probe I concluded it to be a portion of the gun-barrel. I first tried to remove this hard mass with a pair of strong forceps introduced through the nostril; but failing to accomplish this, I laid open the right cavity of the nares by an incision carried through the nostril along the fold which forms the line of demarcation between the cartilage of the nose and face. The piece of iron was then seized with the forceps, and, after considerable traction, removed; it weighed an ounce and a quarter, and was covered with a thin layer of rust. The wound was united with two fine sutures. The patient recovered without a bad symptom, and in a week left the hospital.

The woodcut (Fig. 86) represents the actual size and shape of the screw breech of the gun.

Treatment of Foreign Bodies in the Orbit.—

Whenever it can be clearly established that a foreign body is impacted in the orbit, the treatment is to endeavour to remove it as soon as possible. To this rule, however, there are exceptions; and these are when the foreign body is a small shot, or a fine scale of metal which may have flown off from a rivet and passed into the orbit without injury to the eye. The almost impossibility of finding a small object in a mass of cellular tissue forbids the attempt to hunt after it. If it can be easily felt with a probe introduced through the wound it should be removed, but no lengthened exploratory operation should be attempted with the view of seeking for it. Such a proceeding would probably excite more irritation than would arise from the presence of a small metallic body in the orbit. It should also be remembered that small masses of metal may be often embedded in the cellular tissue of any part of the body without producing a symptom of irritation, and that they may remain there for many years without causing any disturbance.

Having ascertained by a careful investigation that a foreign body is in all probability embedded in the orbit, the following operation for its removal may be performed:—

The outer canthus should be freely divided, either by a pair of scissors or with a scalpel, to allow of the upper lid being completely turned up, or the lower one drawn down, according to the locality in which the foreign body is lodged. If it has entered the orbit *above* the globe, the upper lid is to be raised, and the reflection of conjunctiva between the lid and the eye is to be divided over the spot

where the foreign body is suspected to be lying. A probe or the little finger may then be passed through the wound into the orbit by the side of the eye, and having felt the object it may be seized and drawn out with a pair of sequestrum forceps. When the foreign body has entered the orbit *below* the globe, the lower lid must be drawn down and the lower oculo-palpebral fold of conjunctiva must be divided, but the remaining steps of the operation are the same as those already described.

If the foreign body has become entangled with one of the recti muscles, or from any other cause one of them should interfere with its easy withdrawal from the orbit, it is better at once to divide the muscle with a pair of scissors as close as possible to the globe, rather than use any force to overcome the resistance it may be causing.

PENETRATING WOUNDS OF THE ORBIT are always serious. The exact injury which has been inflicted can often be only surmised, and time is required for the manifestation of symptoms before either a correct diagnosis or prognosis of the case can be formed. The instrument which has caused the accident should be examined to see if any fragment of it has been broken off and left behind in the orbital cellular tissue, and the direction in which it penetrated the orbit should be noted. The patient should be kept under careful supervision for some days, so as to enable the surgeon to treat from the onset any unfavourable symptoms that may arise. Even when no injury has been inflicted to the bones of the orbit, orbital cellulitis and abscess are very apt to ensue.

PERIOSTITIS OF THE ORBIT is usually *chronic*, but small portions of the orbital periosteum are occasionally *acutely* inflamed. Acute *diffuse* periostitis rarely if ever affects the orbit.

Chronic Periostitis of the Orbit is nearly always syphilitic. It usually leads to the formation of nodes or the effusion of lymph beneath the periosteum. The most frequent position of the nodes for which the ophthalmic surgeon is consulted is on the frontal bone just over the brow; but they sometimes occur within the orbit and give rise to grave symptoms. The nodes of the flat bones usually differ in their progress from those which are so commonly seen on the tibia and other long bones; for

whereas in the latter they frequently ossify and form bony projections, in the former (the flat bones), and especially in those of the skull, the effused lymph often softens, and pus is formed beneath the periosteum, and a portion of the subjacent bone either exfoliates or becomes carious.

Symptoms.—Dull aching pain, which is worse at nights, when it is usually sufficiently severe to prevent sleep; swelling of the part, evident to the sight and the touch when it occurs over the superciliary ridge; but when the periostitis is within the orbit, the swelling is indicated by the impaired motions of the eyeball, or by paralysis of one or more of its muscles, if the node is in a locality where the ocular nerves can be affected by it; and if the swelling is large, there is some protrusion or displacement of the eye. If the node within the orbit should soften and pus be formed, all the symptoms which characterise orbital abscess will gradually develop themselves, and after the matter has been evacuated a chronic discharge will probably continue until some portion of the orbital bones has exfoliated.

Treatment.—In chronic orbital periostitis there is generally a past history of syphilis, possibly dated back many years; but when this cannot be obtained, the surgeon must use his own judgment as to the patient's veracity, and treat the case accordingly. The most useful medicine is the iodide of potassium, which should be given in the first instance in doses of from gr. 3 to gr. 5 three times a day; but if these fail to do good, they may be increased up to gr. 8 or gr. 10. To relieve pain and favour the absorption of the effused lymph, the unguent. hydrarg. cum belladonnâ (F. 126) may be rubbed into the brow, and left on during the day. When the pain is very severe, a subcutaneous injection of gr. $\frac{1}{6}$ to gr. $\frac{1}{3}$ of the acetate of morphia (F. 30), or gr. 5 of the pil. saponis cum opio, may be given at night. If these remedies fail, a mixture with iodide of potassium and perchloride of mercury (F. 98) may be ordered. If the node within the orbit soften, and pus be formed, an opening should be made to give vent to it; and if a chronic discharge continue, and this be found dependent on a portion of dead bone not yet exfoliated, the sinus should be syringed out twice a day with a little tepid water, or with a very weak solution of carbolic acid, about $\mathfrak{m} 3$ ad aquæ $\mathfrak{z} 1$. As soon as the probe detects that the bone is loosened, the

sinus should be enlarged and the exfoliated piece be removed with a pair of forceps.

ACUTE PERIOSTITIS OF THE ORBIT is an acute inflammation of a portion of the orbital periosteum which may have been detached from the bone or otherwise injured by some penetrating wound of the orbit, or may have become secondarily affected during an attack of orbital cellulitis. It is accompanied by severe pain and by the formation of pus, which will give rise to all the symptoms described in the Section **ABSCESS OF THE ORBIT**. The piece of bone which is subjacent to the inflamed periosteum usually perishes, and a discharge of fetid pus continues to drain through the external wound by which the matter was first evacuated, until the dead bone is detached from the living and removed from the orbit.

Treatment of Acute Periostitis of the Orbit.—When it is traumatic, or is due to orbital cellulitis, the application of linseed-meal poultices and warm fomentations give the most relief during the acute suppurative period. As soon as there is reasonable evidence that pus has formed, an incision should be made into the orbit to give exit to it. For the chronic discharge kept up by the presence of diseased bone, see **TREATMENT OF CHRONIC PERIOSTITIS OF ORBIT**, page 381. The patient should be ordered tonics, stimulants, and a liberal diet. The disease is very depressing, and it is not specific; iodide of potassium and mercurials are therefore contra-indicated.

NECROSIS AND CARIES OF THE ORBIT.—Necrosis of a portion of one or more of the orbital bones generally arises from periostitis induced by an injury, or by an acute orbital abscess; whereas caries is usually produced by some constitutional taint, such as syphilis or struma. In the two preceding sections it is shown that both caries and necrosis may follow inflammation of the periosteum of the orbit. Caries of the malar bone is, however, more frequent than caries of the orbit, and it is a form of the disease which the ophthalmic surgeon is frequently called upon to treat, as it is the cause of a very troublesome ectropion.

Treatment.—For necrosis no permanent cure can be effected until the piece of dead bone has been removed. Time should be given to allow of its being loosened from the living structures, and then guided by a probe passed

through the sinus by which the discharge escapes, an incision should be made down to the necrosed bone, which should be removed with a pair of fine bone forceps. For caries the treatment is different. True caries is strictly ulceration of bone, or, in other words, a degeneration of the bone particles, which are thrown off, and may often be detected in the discharge. As in ulcers of the skin, the object of the treatment is to restore healthy action, and thus produce cicatrization. This may be aimed at by constitutional and local treatment. Where there is a syphilitic taint the iodide of potassium with iron (F. 92), or the iodide and bromide of potassium combined (F. 97), or other anti-syphilitic remedies may be given; but when the disease may be attributed to a strumous diathesis, cod-liver oil, the syrup of the iodide or hypophosphite of iron will generally do good, and especially if at the same time the patient can obtain sea-air and a nutritious diet, of which milk and eggs form a part.

The best local applications are the *lotio rubra* (F. 64); a lotion of carbolic acid (F. 56); or of chloride of zinc gr. 1 ad aquæ ʒ 1. They should be injected up the sinus with a glass syringe twice a day; and if one lotion causes too much irritation, another should be substituted. If, however, all these remedies fail, a cure may be often accomplished by making an incision down to the carious bone, and gouging away the soft and diseased structure.

ANEURISMS OF THE ORBIT.

The aneurisms which are met with in connection with the orbit, and which are commonly described as intra-orbital, are of three kinds—

1. The spontaneous or idiopathic aneurism.
2. The traumatic aneurism.
3. Aneurism by anastomosis, and nævoid growths.

The majority of the supposed aneurisms which have been diagnosed as intra-orbital have really been intracranial, the producing cause of the three prominent symptoms, proptosis, pulsation and bruit having been either some lesion of the carotid artery in or adjoining the cavernous sinus, or some obstruction in the ophthalmic vein, or in the cavernous sinus.

The two following are illustrative cases:—

Mr. Nunneley has reported the post-mortem examination of a patient whose right common carotid he tied for

the relief of a supposed orbital aneurism. The operation was performed in August, 1859, and the woman died of serous apoplexy on February 27, 1864. "On the right side of the sella turcica was found a circumscribed aneurism of the ophthalmic artery, just at its origin, as large as a hazel-nut, which was filled with a dense solid red clot." *

In this case the aneurism was intra-cranial.

In a case in which Sir W. Bowman tied the carotid artery of a woman, æt. forty, in King's College Hospital, on February 27, 1858, all the symptoms plainly pointed to intra-orbital aneurism.

The following abstract is taken from the report of the case and the post-mortem examination made by Mr. Hulke.† "The operation was accomplished without difficulty and with the least possible interference with the adjacent structures. . . . The pulsation and bruit hitherto felt and heard over the front of the eye at once ceased. On the morning of the 10th there was a slight oozing of blood from the wound. On the 11th, thirteen days after the vessel was tied, the ligature came away. On the following morning there was free hæmorrhage, and, after repeated recurrences of the bleeding, she died on the 17th."

At the post-mortem examination by Mr. Hulke, "the double bend of the internal carotid artery resting against the side of the body of the sphenoid bone, together with the carotid and cavernous plexuses of the sympathetic nerve, were bathed in ichorous serum; but the artery itself was not dilated, and its inner surface had a perfectly healthy appearance. The ophthalmic artery and its branches were traced with great care; they were not at all dilated, nor more numerous than usual. . . . The ophthalmic vein seemed much enlarged, and had the appearance of a varix. By comparing it with the vein of the other orbit, the enlargement was seen to be due to thickening of its coats, and not to any dilatation of its calibre. Where the vein opened into the cavernous sinus it was obstructed by a softened, degenerated clot, similar to that in the sinus; this clot stretched along the trunk of the vein into the orbit, but here, and in the tributary branches of the vein, it was evidently of more recent

* Medico-Chirurgical Transactions, vol. xlviii, 1865.

† Royal London Ophthalmic Hospital Reports, vol. ii. p. 6.

date than that which blocked the mouth of the vein at the cavernous sinus.

In some after-remarks, Mr. Hulke says:—"The plugging of the trunk of the ophthalmic vein, where it joins the cavernous sinus, by obstructing the return of blood from the orbit, accounts for the protrusion of the eyeball, and perhaps also for the pulsation which was felt when the fingers were laid on it; because each diastole of the ophthalmic artery must have been attended by a general momentary increase of the whole quantity of blood in the orbit; because its exit through the ophthalmic vein was cut off, and the resisting bony walls of the orbit could permit a distension in front only."

One case of aneurism of the ophthalmic artery of both sides has been recorded by the late Mr. Guthrie. The disease was diagnosed during life and verified after death, when "an aneurism of the ophthalmic artery was discovered on each side, of about the size of a large nut." "The disease existing on both sides, prevented an operation on the carotid being attempted, to which indeed the patient would not have submitted."*

Cases have been recorded of aneurism of the central artery of the retina. In a patient under Dr. G. Sous, of Bordeaux, the disease was diagnosed during life by the ophthalmoscope, the distended vessel appearing as an ovoid tumour on the left optic disc.†

Mr. Rivington, in his valuable paper in the "Medico-Chirurgical Transactions," vol. lviii. p. 213, gives a résumé of the recorded post-mortem examinations of cases of intra-orbital aneurism, of which the following is an abstract. He says, "The only true basis for the pathology of intra-orbital aneurism is the result of post-mortem examinations. Out of the 73 cases adduced in this paper, opportunities for examination of the parts after death have been presented in 12 with the following results:—

1. "In one case only—the case of Guthrie—has there been found any aneurismal affection within the orbit, and in this case an *ordinary circumscribed aneurism* existed on each ophthalmic artery."

2. "In one case—the case of Dr. Cettingen, of Dorpat—

* Lectures on the Operative Surgery of the Eye, p. 158.

† Annales d'Oculistique, 1865.

inflammatory mischief within the orbit leading to plugging of the orbital veins was diagnosed. At the post-mortem, two years later, Dr. Cettingen found no changes in the arteries, but evidences of past inflammation of the orbital tissues and *partial obliteration of the orbital veins.*"

3. "In the remaining ten cases the affection was caused by some disease of the blood-vessels immediately behind the orbit.

4. "In two of these ten cases *no arterial lesion whatever was discoverable. . . .* In both, *obstruction to the passage of blood from the orbit through the intra-cranial sinuses* appeared to be the cause of the affection."

5. "In one idiopathic case which Mr. Nunneley had cured by ligature, post-mortem examination five years afterwards showed *a circumscribed aneurism of the ophthalmic artery at its origin from the internal carotid.*

6. "In three idiopathic cases, *rupture of an aneurismal internal carotid in the cavernous sinus* was discovered."

7. "In one case, the affection appears to have resulted from *simple dilatation and atheromatous degeneration of the internal carotid artery in the cavernous sinus.*"

8. "In three traumatic cases *a direct communication between the carotid artery and the cavernous sinus* was found. In one case, the carotid artery was nearly torn across, in the two others there was a small hole in the artery."

1. The spontaneous or idiopathic aneurism is generally due to disease of the arteries, through which their coats either yield, or one or more of them give way before the pressure of the blood. The spontaneous aneurism may be either *true* or *false*. By the term *true* is understood a simple circumscribed dilatation of the three coats of the artery; whilst the title *false* is improperly applied to the most usual form of aneurism, in which the middle and internal coats have given way, and the sac is composed of the external or cellular coat. The true or false aneurism may become a diffuse aneurism by a rupture of its coats and an extravasation of blood into the surrounding tissues.

2. The traumatic aneurism is the result of an injury, and is a "diffuse aneurism." From a wound in the artery the blood is extravasated, and a sac is formed by a condensation of the surrounding tissues, with which sac the artery communicates.

Traumatic aneurisms in the orbit, or in its close proximity, are usually produced by blows on the orbit, by falls from a height, by punctured wounds of the orbit with a stick, the end of an umbrella, or a foil, or some other form of injury.

The early symptoms of traumatic aneurism in or near the orbit are often masked by the head symptoms, which have immediately followed the injury.

In some of the cases of pulsating exophthalmos which have been supposed to have been intra-orbital aneurisms, the post-mortem examinations have shown that the symptoms were caused by the rupture of an aneurism of the carotid artery into the cavernous sinus.

The symptoms of pulsating exophthalmos or so-called intra-orbital aneurism when well marked are proptosis or protrusion of the eye; pulsations, to be felt with a slight pressure of the fingers on the eye, and which are synchronous with the pulsations at the wrist; a bruit to be heard by placing the stethoscope either over the eye, with the lids closed, or on the side of the temple; pressure on the common carotid at once arrests the pulsations and bruit, and causes a diminution of the proptosis; swelling of the lids, and redness and œdema of the conjunctiva. There is frequently a limitation of the movements of the globe, and in some cases paralysis of one or more of the ocular muscles. There is usually pain, and in addition, noise in the head, compared by one patient to the whirring sound of a steam-engine or thrashing machine, and by another to the blowing of a pair of bellows. In some cases a distinct pulsating tumour may be felt in the upper region of the orbit; but in others there is a marked absence of anything like a circumscribed swelling.

The first symptoms in the majority of the cases are very sudden; but in a few recorded cases they have come on gradually.

The *suddenness* of the first symptoms is well illustrated in the following extracts from four of the reported cases:—Mr. Travers,* in the account of the patient whose carotid he tied successfully, says, “she felt a sudden snap on the left side of her forehead, which was attended with pain.”

Mr. Dalrymple, in citing the history of the case in

* Medico-Chirurgical Transactions, vol. ii. 1811.

which he ligatured the carotid for aneurism of the orbit, uses the patient's own words : "The attack was sudden— instantaneous" "hearing a noise as of the cracking of a whip, and feeling at the same moment an extraordinary kind of pain in the globe of the left eye, she awoke in great alarm and leapt out of bed."*

In the report of another of Mr. Nunneley's cases, in which he tied the carotid, it is stated that "as she stooped down to take off her shoes, she suddenly felt something give way in the left eye, as the crack of a gun."† The poor woman died on the sixteenth day after the operation. On a post-mortem examination "the left carotid on emerging from the bony canal at the origin of the ophthalmic artery, was decidedly enlarged, and filled with, and surrounded by, a nodule of coagulum of the size of a large horse-bean. The right carotid was normal. . . . The ophthalmic artery was considerably dilated, its coats thickened with atheromatous patches; two of its branches, particularly the inner, were distended and filled with coagulum."

Lastly, in the report of "a case of pulsating tumour," in which Sir W. Bowman successfully tied the common carotid artery in a woman æt. forty-one, the patient states "that she had always enjoyed good health until two days after Christmas, 1859, when, as she was in the act of washing some linen, she felt a sudden acute pain on the right side of her head, and from that time she has had an unremitting 'noise in the head, which she says sounds like the puffing of a steam-engine when at work.'"‡

In each of these four cases a series of distressing symptoms followed immediately on the first indication that some vessel had been ruptured.

Treatment of so-called Intra-orbital Aneurism or Pulsating Exophthalmos.—There are only two methods of dealing with such cases—

- (1.) By digital compression of the carotid artery.
- (2.) By ligature of the vessel.

In all cases where it is practicable digital compression should be first tried.

In July, 1856, a female patient with aneurism of the ophthalmic artery, under Professor Gioppi, of Padua, was successfully treated in this manner. "A second case, in

* Medico-Chirurgical Transactions, vol. vi. 1815.

† Ibid., vol. xlii. 1859, pp. 176 and 180.

‡ Royal London Ophthalmic Hospital Reports, vol. iii. p. 324.

which a formidable aneurism of the ophthalmic artery, in a patient the subject of aortic and cardiac disease, was cured by digital compression, was published in 1858 by Drs. Vanzetti and Scaramuzza.* It is not necessary that the compression should be continuous—it may be intermittent, being applied only five or ten minutes at a time, according as the patient can bear it. If this treatment fails to effect a cure, the carotid should be tied. It is an operation which has been frequently performed and with good success.

3. **Aneurism by Anastomosis** is usually congenital, although it may not be detected until by its increased growth it has made itself manifest by extending beyond the orbit. It consists of a morbidly developed network of capillaries in the subcutaneous cellular tissue, forming a prominence beneath the skin, which increases in size, and is rendered turgid by laughing or crying. To the touch it has a tough, doughy feeling, quite distinct from fluctuation.

Treatment.—When the vascular growth is of limited extent, and is only a short distance within the orbit, it may be surrounded subcutaneously with a ligature and tied. The same proceeding may be adopted to a portion of a growth of a larger size which extends beyond the orbit. There are, however, cases to which this plan of treatment is inapplicable, as when the growth pulsates, is of great dimensions, bulges the eye, and is rapidly increasing. For such tumours the effect of temporary pressure with the finger on the carotid should be tried, and if this fails in arresting the pulsations and in reducing the fulness of the growth, the carotid artery should be ligatured. Mr. Haynes Walton succeeded in curing a large aneurism by anastomosis of the orbit in a child four months and three weeks old, by tying the carotid artery. After the operation, the protrusion of the eyeball was sensibly diminished, and the child recovered without a bad symptom.†

Dr. Althaus speaks highly of the success he has obtained from the electrolytic treatment of vascular growths.‡ Although in his book on this subject he has

* Holmes's System of Surgery, vol. iii. pp. 423, 424.

† Haynes Walton, On the Surgical Diseases of the Eye, 2nd edition, p. 230.

‡ On the Electrolytic Treatment of Tumours.

not related any cases of large aneurism by anastomosis in which he has used electrolysis, yet it is a remedy which fairly commends itself for trial before resorting to ligature of the carotid.

The plan of injecting vascular tumours of the orbit with coagulating fluids, such as a solution of tannin or of perchloride or persulphate of iron, is fraught with danger, and has terminated fatally in several cases.

Venous Nævus of the Orbit is a congenital affection. It may not become manifest until many months after birth, when by its increase of size it causes a bulging forwards of the eye. The diagnosis of this rare affection is obscure and difficult. There is protrusion of the eye, which varies in degree, being greater at one time than another, and increased by any strong emotion, such as crying or laughing. An examination with the finger round the orbit may fail to detect any tumour immediately within the orbital edge, the vascular growth being placed directly behind the eye and at the bottom of the orbit. If, however, the nævoid tumour has advanced sufficiently forward to be detected by the finger, it will be felt as a soft, cushiony, elastic mass, and will yield no pulsations.

In some cases the nævus of the orbit extends into the cellular tissue of one or both eyelids, producing a soft, doughy swelling which causes a partial closure of the lids over the eye.

Prognosis.—1. A venous nævus of the orbit may gradually diminish in size as the child advances in years. 2. It may remain stationary, or its increase may be so slow as to occasion no serious inconvenience. 3. It may steadily or rapidly increase in size, so as to cause a protrusion of the globe, and to such a degree as to induce suppuration of the cornea, from the front of the eye being forced beyond the protection of the eyelids.

Treatment.—There are two methods of dealing with a venous nævus of the orbit, when, either from its size or rapid increase, active treatment is rendered necessary:—

1. The superficial portion of the growth which affects the lids may, when practicable, be ligatured subcutaneously; or inflammatory action sufficient to induce coagulation of the blood within the vessels may be excited by pricking the tumour at many points with a needle-pointed cautery, made hot as often as may be required in

the flame of a spirit-lamp. The deeper part of the vascular growth within the orbit may be treated by the actual or galvanic cautery applied at two or three points through the integument close to the margin of the orbit. Mr. Spencer Watson has related in the 6th vol. of the "Transactions of the Clinical Society," a case of extensive venous nævus of the orbit, which he obliterated partly by ligature, and partly by the use of the actual cautery to the tumour within the orbit.

2. The nœvoid tumour within the orbit may be excised. This operation, however, should not be attempted unless the growth is producing great proptosis of the globe, sufficient to render active interference absolutely necessary, and to justify the sacrifice of the eye, as before the venous tumour can be reached, the globe must be enucleated. After the removal of the eye the nœvoid tissue should be drawn forwards with a pair of toothed forceps, and then rapidly cut away with a pair of blunt-pointed scissors curved on the flat. When the greater part of the vascular tissue has been excised, the bleeding will have probably diminished, and all further hæmorrhage may be arrested by plugging the orbit with small pieces of sponge soaked in the liquor ferri persulphatis, and afterwards applying a firm pad of lint with a bandage over the closed lids.

The injecting the vascular growth with astringent solutions is accompanied with great danger to life, as already stated in the preceding section, and should not be attempted.

The following case of venous nævus of the orbit came under my care at the Royal London Ophthalmic Hospital, and was treated by excising the nœvoid growth:—

On November 8, 1870, a little child, aged three years and two months, was brought to the hospital with a great protrusion of the left eye, and evidently suffering considerable pain. The eye was bulged fully half an inch beyond the boundary of the orbit, but the child was still able to close the lids over it. The globe was projected directly forwards, and no tumour could be felt with the finger around any portion of the circumference of the orbit. The cornea was perfectly clear, and the eye otherwise healthy. The mother stated that the eye had begun to protrude about six months previously, but that the bulging had remained almost stationary until ten or twelve days before her application to the hospital, when, without any apparent cause, the protrusion of the eye became rapidly greater, and had since increased daily.

As it was difficult to decide on the nature of the tumour, the

child was kept under observation, and ordered to attend regularly as an out-patient.

On November 18, the child was admitted with the mother into the hospital, as the severity of the symptoms had greatly increased. The eye was much more bulged from the orbit; it had lost the protection of the lids, which could no longer be closed over it, and from the consequent exposure, the cornea was beginning to suppurate; the lower half of it was semi-opaque, and the conjunctiva of the globe was chemosed. The child was evidently in great pain, constantly moaning, and unable to sleep except in short snatches. To relieve the sufferings of the child, and also to obtain a correct knowledge of the growth behind the globe, I decided to remove the eye. On dividing the optic nerve with the scissors, a copious stream of blood followed, and the tumour within the orbit at once collapsed to nearly one-half its former size.

On examination, a vascular growth, composed of large veins, with a cellular matrix, was found to occupy the orbit. Drawing the nævoid tissue out of the orbit with a pair of forceps, so as to keep it on the stretch, I excised the greater portion of it, leaving only a small part of the tumour at the apex of the orbit. The cavity was then plugged with a small piece of sponge soaked in the liquor ferri perchloridi, and a compress to arrest further hæmorrhage was applied over the closed lids with a flannel bandage.

The child recovered without a bad symptom, and has since continued well.

EXOPTHALMIC GOITRE.—GRAVES'S DISEASE.

The three symptoms which characterise this extraordinary affection are; exophthalmos of both eyes, enlargement of the thyroid gland, and palpitation of the heart. To these may be added anæmia, derangement of the functions of one or more of the visceral organs, and a peculiar capriciousness of temper; but these signs are not diagnostic, as they are common to other diseases. Exophthalmic goitre is more frequent among women: thus, "of fifty cases of this complaint collected by Withuisen, only eight occurred in males."* I shall first briefly describe the group of symptoms which mark the disease, and then refer to each in detail.

Symptoms.—The first symptom is usually palpitation of the heart, which steadily increases, and is aggravated by mental emotion or exercise. The eyes seem to grow large, and the friends notice that they begin to protrude, and the thyroid gland expands. The patient suffers from

* Trousseau's Clinical Medicine, Syd. Soc. ed., vol. i. p. 552.

paroxysms of dyspnœa, with violent palpitations, and a sense of fulness of the eyes and throbbing of the carotids. Associated with these symptoms there is usually anæmia, irregular action of the bowels, an uncertain appetite, and if the patient be a female, amenorrhœa. Trousseau lays emphasis on the change of temper, which from being even becomes capricious and irritable, and is often the first indication of there being some constitutional malady.

The **Exophthalmos**, or protrusion of the eyes, is the symptom for which the ophthalmic surgeon is most frequently consulted, and it is the one which often causes the greatest amount of anxiety to the patient. As the disease advances the bulging increases, sometimes to such an extent as to prevent the lids from closing over the globes. When this happens, the eyes suffer from exposure and become liable to frequent attacks of inflammation. In a poor girl, æt. eighteen, who was under my care at the hospital, the eyes continued to protrude more and more, until at last, having lost much of the protection of the lids, both eyes became acutely inflamed, and both corneæ suppurated. I frequently see this patient, and so prominent are the shrunken globes, that although both are contracted to at least one-third of their original size, the lids when shut cannot cover them. Notwithstanding the prominence of the eyes, the sight is generally but little affected. In the case to which I have just referred, the girl could see to read and write well before her eyes became inflamed.

Hypertrophy of the Thyroid.—The whole gland is usually enlarged, but, according to Graves, Stokes, and Trousseau, the right lobe is the more affected of the two. In three out of the four cases of exophthalmic goitre related by Morell Mackenzie,* the right lobe was the larger, and in the fourth both lobes were equal. The increase in the size of the thyroid is at first almost imperceptible, but after it has attained certain dimensions it is productive of distressing symptoms from interfering with respiration when the patient is in the recumbent position. With the hypertrophy of the gland tissue there is dilatation of the vessels of the gland, and this can be easily recognized in severe cases by placing the hand over the thyroid, when

* Transactions of the Clinical Society, vol. i. p. 9.

it will be felt to expand synchronously with the pulsations of the carotids.

Palpitation of the Heart.—This is a very constant symptom, and usually the one which first attracts the patient's attention. Trousseau says: "The valvular sounds are exaggerated, and are generally accompanied by a soft systolic bellows-murmur, audible in the large arteries also. The carotids pulsate more forcibly than natural, and they as well as the jugular veins have a share in the production of the sounds heard over the enlarged thyroid."* The palpitations appear in the early stages of the disease to be due to functional derangement, but in the later there is frequently dilatation of the cavities of the heart.

Derangement of the Visceral Organs.—The appetite is variable—at one time good, at another almost wanting. The bowels are irregular in their action, one patient suffering from repeated attacks of diarrhœa, whilst another is troubled with flatus and constipation. In females there is almost always amenorrhœa. Trousseau remarks: "In the beginning, menstruation is only disturbed, but it is after a time completely suppressed, and hopes of a favourable issue are not to be entertained until this function is perfectly re-established."†

Anæmia generally attends this disease, but it is by no means an essential condition, as exophthalmic goitre may exist in robust and florid-looking patients.

Treatment.—Dr. Trousseau says: "I can from experience recommend you to have recourse in this singular affection to bleeding, digitalis, and hydropathy."‡ The first and last of these remedies I have not tried, but digitalis I have frequently ordered, and always with benefit. The iodide of potassium generally fails to do good in these cases; it depresses too much, and frequently induces iodism. From the usually anæmic state of the patient, iron would naturally be suggested, but with the rapid pulse which mostly accompanies this disease, the drug is badly borne, and aggravates the symptoms. During the paroxysms of dyspnœa ice should be applied over the thyroid and over the præcordial region in an india-rubber ice-bag, and the tincture of digitalis \mathfrak{m} 10 to \mathfrak{m} 15 prescribed every two or three hours, keeping a

* Trousseau's Clinical Medicine, Syd. Soc. ed., vol. i. p. 546.

† Ibid., p. 550.

Ibid., p. 588.

careful watch over the patient during its administration. In the intervals between the paroxysms small doses of the tincture of digitalis, combined either with the mineral acids or with an alkali, according to the special indications of the case, will be found of service. If there is habitual constipation, the bitter waters of Pullna, Friedrichshall, or Kissingen may be also prescribed. In female patients, when there is scanty menstruation or amenorrhœa, means should be taken to restore the uterine functions. In cases which have resisted medicinal remedies, I would certainly try a course of hydropathy, with the hope that by acting freely on the skin the patient may gain that relief which other treatment has failed to afford.

TUMOURS OF THE ORBIT.

TUMOURS OF THE ORBIT may be divided into four classes:—

1. Those which originate within the orbit.
2. Those which commence within the eye, and afterwards extend to the orbit; or reappear in the orbit after the eye has been excised.
3. Those which have their origin at some site beyond the eye or the orbit, but have extended into the orbital cavity.
4. Congenital tumours of the orbit.

It would be out of place to discuss in this manual the nature and progress of all the varieties of tumours which may affect the orbit, as nearly every form of tumour which may grow elsewhere may spring up also in this locality. I shall therefore allude only to those growths which have some special bearing on the treatment to be pursued for their removal.

1. Tumours which Originate Within the Orbit soon manifest their presence by the pressure they exert on the eye. As the growth advances, the globe is protruded in one or other direction, according to the position the tumour occupies in the orbit. All sight may be destroyed by the pressure on the optic nerve, or by the stretching and extension of the nerve from the protrusion of the eye; or, if the exophthalmos is great, the lids may fail to cover the globe, and the cornea may ulcerate and slough from exposure. It is, however, often astonishing to what

an extent the eye may be projected, and the optic nerve consequently stretched, without producing any great impairment of vision; and also how the lost sight will be regained after the eye has been restored to its proper position within the orbit by the removal of the morbid growth. The tumours which originate within the orbit may be benign, recurrent, or malignant; and may be extirpated with more favourable prospects of success than those which first show themselves within the eye.

Of the benign growths we have cysts of the orbit, and fibrous, bony, and cartilaginous tumours.

Cysts of the Orbit are of various kinds. The most frequent are the atheromatous and the steatomatous; but

FIG. 87.



Fig. 87 is drawn from the photograph of a patient from whom I removed a large hydatid cyst of the orbit, which pressed upon the optic nerve and produced a remarkably "choked disc." The case is related in the *Clinical Transactions*, vol. ix. p. 134.

serous, hydatid, and other forms of cysts are also met with in this locality. The most satisfactory method of dealing with cysts is to dissect them out, but this is often extremely difficult, and occasionally impracticable without sacrificing the eye. They sometimes so entwine

themselves amongst the orbital muscles that it is hard to follow them; and their walls are frequently so thin that they either give way, or are punctured during the operation, and their contents having escaped, it becomes almost impossible to identify them from the structures in which they are buried. Unless the cyst is completely excised it is liable to grow again. If the cyst is large, and on making an exploratory incision into it, its contents are found to be fluid, one or two strips of lint may be introduced into its cavity, after it has emptied itself, with the object of exciting sufficient inflammatory action to cause obliteration of the sac. Occasionally an orbital cyst will be found to contain hydatids, which may be either echinococci or cysticerci.

Fibrous Tumours usually grow from the periosteum of the orbit, to which they are attached by either a broad or pedunculated base. They are often situated near the edge of the orbit, from which with care they may be removed without injury to the eye. These tumours, when carefully dissected out with the portion of the periosteum from which they have sprung, do not reappear.

Bony and Cartilaginous Tumours.—The exact nature of these growths can only be ascertained by an exploratory incision, when, if they are attached by a short pedicle, they may be removed. Occasionally, however, their base is so extensive, and their structure so dense, that it is impossible to take them completely away. For the excision of these tumours the operator should be provided with small bone forceps, a bone chisel, a gouge, and an elevator, as even when the pedicle is small, it may be impossible to detach it without the use of some bone instruments. In one case I succeeded in splitting off with a small bone chisel a bony tumour from the inner side of the orbit, which had a base $\frac{3}{4}$ of an inch long and a $\frac{1}{4}$ of an inch wide.

A very instructive case of "a large orbital and intracranial ivory exostosis" is reported by Mr. Tweedy,* in which he succeeded in removing the orbital portion of the growth by a drill worked by a powerful Archimedean screw. He says:—

By means of drills of various sizes I managed to bore a large number of tunnels in various directions through the base of the

* Royal London Ophthalmic Hospital Reports, vol. x. p. 303.

growth, parallel with the upper and inner walls of the orbit. I then cut through the narrow bony septa, between the borings, with a stout carpenter's chisel. When the chisel had made its way deep enough to act as a wedge, I gave a few energetic blows with the mallet, and succeeded in breaking off the whole of the orbital portion of the growth. When this was accomplished the orbital cavity seemed almost normal in size and shape, though it was obvious that a large mass forming the base of the growth still remained behind.

A week after the operation the man got out of bed, and seemed to be in perfect health. The discharge from the wound gradually diminished, and the inflammatory swelling steadily subsided.

The progress of the case continued to all appearance satisfactory, and altogether devoid of anxiety and trouble, till the morning of September 2, or exactly one calendar month from the day of operation.

On September 1 the man had been exercising as usual in the ward and in the out-buildings of the Hospital, seemingly in perfect health and strength. At 8 P.M. he complained of slight pain at the top of his head. This he himself ascribed to cold. He had a disturbed night, and at 10.30 next morning his temperature suddenly rose to 102° F., and the pulse went up to 80. The skin was dry, the tongue was clean, and the bowels were free. The head symptoms rapidly increased, the patient became comatose and died. At the post-mortem examination it was found that the greater part of the exostosis was in the left anterior cranial fossa. It had originally sprung from within the left frontal sinus, and had grown chiefly upwards."

Of the **malignant and recurrent** growths which may originate within the orbit we have the varieties of sarcomas, the scirrhus and occasionally the medullary cancers. Most of the orbital tumours, however, which have been called medullary cancers have been in adults soft sarcomas, and in children gliomas which have extended from the eye into the orbit.

Of the **recurrent** growths the most frequent is the **spindle or round-celled sarcoma**. This tumour usually grows from the greater part of the periosteum lining the orbit, and can only be eradicated by completely extirpating it, and then destroying the whole of the surface from which it springs. This is best done by using the chloride of zinc after the tumour has been excised in the manner described at page 401 in the Section on TREATMENT OF ORBITAL TUMOURS. These recurrent growths differ from the cancerous tumours in that they do not invade the lymphatics or affect the neighbouring organs.

There is another form of fibroid tumour which is recurrent, but in a different sense to the one just alluded

to. It grows from only a limited area of the lining membrane of the orbit, it has a delicate investing capsule, and may be pedunculated. When fairly excised with the portion of the periosteum to which it is attached, it does not return in the same locality; but it reappears in other portions of the body, generally selecting for itself some fibrous expansion from which to sprout. I have had one such case under my care, and as it is an example of a rather rare form of disease I will briefly quote it.

In May, 1866, I removed from the left orbit of a lady a fibroid tumour of six years' growth. It was pedunculated, enclosed in a delicate capsule, and attached to a small portion of the periosteum of the outer wall of the orbit, which I also excised with the tumour. From this operation she rapidly recovered, and the eye, which had been considerably displaced, and impaired in vision, was restored to its normal position, and soon regained much of its lost sight. In March, 1867, the patient returned to me on account of a tumour which occupied the whole of the hard and a portion of the soft palate of the left side. It was irregular in outline, but perfectly smooth and very elastic. It was first noticed about four or five months previously as a small swelling in the upper part of the left hard palate. For the complete removal of the disease I excised the whole of the left side of the hard palate, and as much of the soft palate as was involved in the disease. From this operation also the patient made a good recovery. In October of the same year she again came to me: the disease had recurred on the hard palate of the right side. There was also a fibroid tumour in the parotid region on the same side of the face, which had existed some years, and had now begun to increase in size. I accordingly removed with the gouge the tumour in the palate, scooping away the periosteum and the corresponding portion of bone to which the growth was attached, and excised the parotid tumour. From this operation the patient soon recovered, and up to March, 1880, when I saw her she had continued without a recurrence of the disease.

2. THE TUMOURS WHICH FIRST COMMENCE WITHIN THE EYE, AND AFTERWARDS EXTEND TO THE ORBIT; OR REAPPEAR IN THE ORBIT AFTER THE EYE HAS BEEN EXCISED, are the sarcomas and melanotic sarcomas of the choroid, and the retinal gliomas. (See *INTRA-OCULAR TUMOURS*, page 205. For treatment, see page 401.)

3. TUMOURS WHICH HAVE THEIR ORIGIN AT SOME SITE BEYOND THE EYE OR THE ORBIT, BUT HAVE EXTENDED INTO THE ORBITAL CAVITY.—Such growths may spring from the antrum, the frontal sinuses, the lachrymal canals, or from some of

the bones which help to form the base of the skull, as the pterygoid processes, or the body of the sphenoid. In all cases they should, if practicable, be removed, and at as early a period as possible. Examples of remarkable displacement of the eye from such growths encroaching on the orbit, will be found in Heath's valuable book on "Injuries and Diseases of the Jaws," third edition, pages 270 and 281.

4. **CONGENITAL TUMOURS OF THE ORBIT** are very rare. The following is an abstract of the report of the only case of this kind which has come under my care.* In May, 1882, I excised the eye of a child only two days old, on account of a congenital tumour of the orbit, which had completely extruded the eye from between the lids. The little patient was taken to the Royal London Ophthalmic Hospital, suffering from complete exophthalmos, which was congenital, and evidently due to an orbital tumour. I removed the eye, and for a time the child did well. The child lived until the middle of the August following, and had been in fairly good health until within two days of its death, when convulsions came on, which were followed by coma. The post-mortem and microscopical examinations were made by Mr. Milles, then curator of the museum. The following is an abstract of his report:—A large tumour was found projecting from and filling up the right orbit. On opening the skull, the upper surface of the brain and its membranes were quite healthy. On the under surface there was a distinct impression in the right middle lobe, produced by the projection of several cysts from the sphenoid bone. There was well-marked basic meningitis, confined chiefly to the right side. The tumour seemed to have originated in the body of the sphenoid bone, and to have grown forwards, filling up the cavity of the orbit, and pushing the eye in front of it. The tumour was pretty solid, but contained numerous cysts in its substance. Under the microscope the tumour was found to consist of several varieties of tissue in different stages of development. The most noticeable were patches of hyaline cartilage of a spherical or oblong shape; these were often surrounded by a zone of spindle cells, with a distinct gradation from cartilage cells. Numerous cysts

* Transactions of the Pathological Society, 1884, vol. xxxv.

of all sizes were scattered through the tumour. The walls of the cysts were usually lined by pavement epithelium. In places small cysts were seen to be projecting from the walls of the larger ones. The more solid part of the tumour consisted of masses of round cells like embryonic tissue, spindle cells, and more fully developed fibrous tissue. There was evidence of formation of glandular structure at several parts. The microscopical examination showed that the tumour was evidently one of embryonic origin, with an attempt to develop into the lower forms of connective tissue and gland structure.

Mr. T. Holmes has recorded the successful removal of a congenital tumour of the orbit, from a child aged seven weeks. On examination the tumour was found to consist of "a large mass of substance much resembling udder, of a hard uniform feel, and white colour,—not in any respect resembling malignant disease. Numerous cysts, containing thin serum, had been laid open. Other smaller solid masses lay in the neighbourhood of the principal tumour."*

Treatment of Orbital Tumours.—In all cases which admit of a reasonable hope of success, the morbid growth should be excised, and the eye, if possible, saved. When the tumour is cancerous or recurrent, and occupies the greater part of the cavity of the orbit, the eye must be first enucleated, even though it still retain some sight, in order to afford sufficient space for the complete removal of the growth. The small fibrous, or bony and cartilaginous tumours, or even cysts, may often be taken from the orbit without injury to the eye. The morbid growth may be frequently removed by an incision through the conjunctiva, and especially if the globe has been already excised; but when more room is required, the external canthus must be freely divided, so that the lids may be turned either upwards or downwards, and thus the outer boundary of the orbit be completely exposed. Whenever there is any doubt as to the nature of the tumour, the surgeon should make an incision down to it, but be prepared to act at once upon the information which he thus gains. In bony tumours the base is sometimes found to be so large, and the structure so hard, that it is more

* Transactions of the Pathological Society, vol. xiv. p. 248.

prudent to close the wound than to proceed with the operation. This caution is specially applicable to the broad-based ivory exostoses which are occasionally met with in the orbit. For all the malignant and recurrent growths, the mere excision of the disease is not sufficient, even though the whole mass be apparently taken away, as some germs will certainly be left, which will in all probability cause the tumour to grow again. Having excised as much of the tumour as can with safety be removed

FIG. 88.

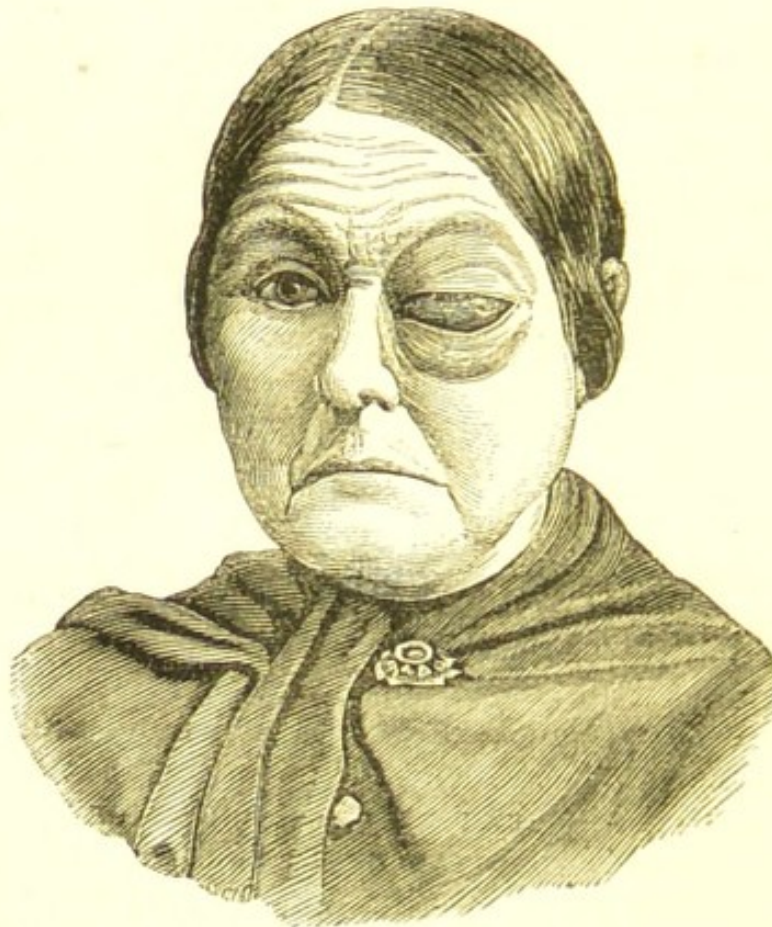

Fig. 88 is drawn from the photograph of a patient with a large melanotic sarcoma of the eye which had burst through the globe and distended both eyelids and filled the orbit. I removed the eye and the tumour from the orbit, and applied the chloride of zinc paste in the way described in the next paragraph, in April, 1875.

with cutting instruments, the actual cautery should be freely applied to those parts of it which still remain, and to all the bleeding points. When all hæmorrhage has been arrested, the chloride of zinc paste (F. 7), spread on small pieces of lint, should be laid evenly over the whole surface from which the growth has sprung. A small

pledget of cotton wool should then be placed in the orbit, and over this a fold of dry lint, which is to be held *in situ* by a bandage tied firmly around the head. Before the patient awakes from the chloroform, from one-sixth to one-third of a grain of the acetate of morphia (F. 30), according to the strength of the patient, should be injected subcutaneously into the arm, and repeated in two hours if the pain be severe.

FIG. 89.



Fig. 89 represents the patient eight months after the operation, July, 1876. When I last heard from this patient she was quite well.*

In cases where I have excised the eye with the orbital tumour, and have been able to preserve the conjunctiva which covered the globe, I have adopted the following method of applying the chloride of zinc paste, in order to avoid the sloughing of the eyelids, which so frequently

* Clinical Soc. Transact., vol. ix. p. 31.

happens from the action of the caustic extending to them :—

After the eye and tumour have been excised, pressure is to be made in the orbit until all bleeding has ceased. The mouth of the conjunctival bag, from which the globe has been enucleated, is now to be held open with two pairs of forceps, whilst the chloride of zinc paste, spread on small strips of lint, is plastered round the sides of the orbit. A small piece of cotton wool is next introduced to keep the strips of lint *in situ*, and the mouth of the conjunctival bag is closed over the whole by a single continued suture. A layer of lint is then placed over the conjunctiva, and upon this the lids are closed and kept in position with a compress of lint and a roller. In this way I have destroyed the greater part of the contents of the orbit without affecting the lids.

In removing tumours from the orbit, it should be remembered that the orbital plate of the frontal bone is frequently thin and soft from the pressure of the growth against it. Special care should therefore be taken during the operation to avoid applying force with any instrument against the roof of the orbit. Twice I have been present when cerebral matter was brought away with portions of the tumour during the operation.

On the day following the operation the bandage may be removed, and if there is much tension of the lids from the stuffing within the orbit, some of the cotton wool may be gently drawn out, and a piece of clean lint being laid over the parts, another bandage should be lightly applied. The remainder of the cotton wool should be taken away on the second day, and a little more laid loosely within the orbit to absorb the discharge as soon as suppuration commences. This dressing may be repeated daily, but the pieces of lint on which the chloride of zinc has been applied should not be removed until suppuration has quite loosened them from the surface against which they were placed. After about ten or twelve days the sloughs will separate from the orbit, and if any suspicious-looking granulations spring up they should be touched with the solid chloride of zinc, or with the potassa cum calce. On three occasions I have seen epileptic convulsions follow within thirty-six hours after the operation, but they have in each instance ceased shortly after the removal of the cotton wool and the chloride of zinc from the

orbit. The fits did not recur, and the patients perfectly recovered.

The success of this mode of treatment has been well proved, and two striking instances of its efficacy have been recorded in the "Pathological Transactions." The first was in a patient under the late Mr. De Morgan, who removed a large encephaloid tumour from the orbit. "It projected nearly four inches forward from the cheek on the outside, and about two inches and three-quarters from the nasal side."* The man died one year and nine months after the operation from paraplegia, but there was no return of the disease in the orbit. The account of the post-mortem examination will be found in the "Pathological Transactions," vol. xviii. p. 220.

The second case (Fig. 90) was a patient under my care

FIG. 90.



Fig. 90 is from a photograph of the patient after she had recovered from the operation.

* Pathological Transactions, vol. xvii. pp. 265-271.

in the Middlesex Hospital, from whom I removed a scirrhus tumour of the orbit,* and at the same time a secondary scirrhus tubercle in the skin in front of the ear and lying over the parotid gland. The whole of the bones of the orbit were detached in one piece (Fig. 91), and are to be seen in the Museum of the Middlesex Hospital. The operation was performed in February, 1866, and up to the present time, July, 1884, the patient has continued quite well and free from any recurrence of the disease.

FIG. 91.

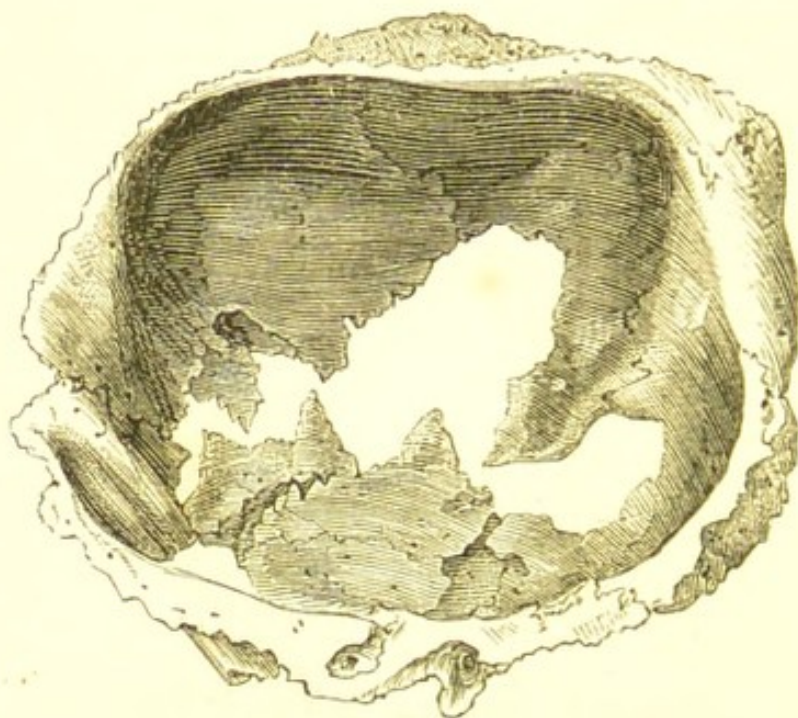


Fig. 91 represents the bones of the orbit as they came away in one piece after the application of the chloride of zinc paste.

ACUTE INFLAMMATORY EXUDATION INTO THE ORBIT.—A case of this nature was under the joint care of Dr. Goodfellow and myself at the Middlesex Hospital. It presented all the symptoms of a rapidly increasing cancerous tumour; but after I had enucleated the eye, and excised the solid growth which filled the orbit, it proved on a microscopical examination to be perfectly structureless, and was probably the product of acute inflammation, most likely specific. The man continued in the hospital until his death five months afterwards, when a post-mortem examination confirmed the diagnosis that

* Pathological Transactions, vol. xviii, pp. 233-235.

syphilis was the cause of the inflammatory exudation. A short account of the case is given in the *Lancet*, April 18, 1868.

Cases of acute inflammatory exudation into the orbit are no doubt rare, but I suspect that they are more frequent than the hospital records would lead us to anticipate. It is only on this supposition that I can account for the occasional instances which one meets with in practice of the gradual subsidence without operative treatment of firm orbital tumours which had considerably displaced the eye, and had been readily felt with the finger in the orbit.

In the treatment of these cases iodide of potassium, given in doses increasing gradually from three to ten grains twice or three times a day, affords the best prospect of success.

DISTENSION OF THE FRONTAL SINUS.

The frontal sinus may be distended with pent-up secretion, or pus, and the tumour thus formed may so closely resemble a growth from within the orbit as to render it difficult to arrive at a correct diagnosis without making an exploratory incision. In order to rightly estimate the displacement of the globe which an expanded frontal sinus may produce, it will be necessary to refer briefly to the anatomy of the dry skull.

The frontal sinuses are two bony cavities placed between the inner and outer tables of the vertical portion of the frontal bone, completely separated from each other by a bony septum. Each of these spaces is subdivided into cells by delicate lamellæ of bone. These cells extend upwards about one inch, gradually becoming narrower as they ascend, until the opposed plates of the frontal bone come almost into contact, a thin layer of diploë only intervening. Forwards and outwards the frontal cells are prolonged between the layers of bone which form the roof of the orbit as far as the mesial line of that cavity, at which part they cease, from the opposed laminae of bone falling together. The half cells which are seen in the dry frontal bone at the nasal notch are completed by corresponding half-cells on each side of the cribriform plate of the ethmoid bone. The frontal cells communicate with the middle meatus of the nose by means of the infundibulum, which is a long and tortuous bony canal connect-

ing the anterior ethmoidal cells with the frontal sinus above, and with the meatus of the nose below.

The situation of the frontal sinuses is indicated on the exterior of the frontal bone by two prominences over the root of the nose, more or less strongly marked in all people, and called the nasal eminences.

Such being the disposition of the frontal cells, it is easy to conceive in what direction a new growth, or an accumulation of fluid, would cause them to distend. Of their boundary walls the weakest is that towards the orbit, where the bony plate which separates that cavity from the frontal sinus is exceedingly thin, and often in the dry skull semi-transparent; so delicate, indeed, in structure is the upper and inner part of the orbit, that the finger, in many of the dry preparations, may be easily pushed through it.

Causes.—In most cases distension of the frontal sinus is due to an injury at some remote period, frequently at a date so far from the symptoms which first attracted the patient's notice, that it seems at first difficult to fairly conclude that the disease is the result of the accident. The extent, however, to which the sinus is often found dilated, and the time which must necessarily be consumed to effect this distension of a bony cavity, together with the oft-told tale of a blow or a fall years ago, can only lead to the conclusion that an injury is the most frequent exciting cause of these accumulations. The explanation is probably to be found in the supposition that at the time of the accident a fracture of some of the anterior ethmoidal or frontal cells produced a closure of the infundibulum, the canal by which the mucus from the frontal sinus escapes into the nose. This channel being closed, there is at once a retention of all mucous secretion, which from that time slowly accumulates and gradually expands the sinus.

Fig. 92 is the drawing of a patient, æt. fifty-eight, who was under my care with an enormous distension of the left frontal sinus. The disease in his case was clearly traceable to a kick he received on the left eyebrow from a horse when four years old, fifty-four years ago. There was still remaining as the result of the injury a depression of the bone over the left eyebrow, and a scar on the inner side of the nose. The left eye was considerably displaced by the tumour; it was half an inch further from the nose, and nearly an inch lower down in the face than its fellow on the opposite side. The eye was projected outwards, and the patient was unable by any effort to draw it inwards. The inner half of the field of vision

was lost, but in the outer half he could count fingers, although he was unable to read any sized type. On the left side of the bridge of the nose there was a smooth, round, elastic swelling about the size of half a large walnut protruding from the inner side of the orbit. It varied in size, being much smaller when he arose in the morning, and larger when he went to bed at night. There was no pain in the tumour, nor in the scar of the old injury.

FIG. 92.



On the patient's admission into the hospital I performed the operation I have described at page 412, and passed an india-rubber drainage-tube through the distended sinus into the left cavity of the nose and out of the corresponding nostril, as is represented in the woodcut, Fig. 94. The contents of the cyst consisted solely of a thick, dark, glairy fluid, evidently the pent-up accumulation of many years' secretion of the lining membrane of the frontal sinus. A very slight amount of irritation followed this operation, and the patient in a few days expressed himself greatly relieved of the sense of weight which had lately oppressed his brow. A free discharge drained through the tube, which was shifted twice a day, and previous to each shifting the cavity of the cyst was thoroughly cleansed with a solution of carbolic acid, $\text{miv ad aquæ } \mathfrak{z}\text{j}$, which was squirted into the sinus through the drainage-tube.

Gradually the discharge diminished in quantity; and as the cyst walls contracted, the eye regained to a great extent its proper position within the orbit. The tube was worn for nearly eight months, when, as all discharge had ceased, it was withdrawn. After the removal of the drainage-tube there was left a fistulous opening at the inner angle of the orbit.

A case also is recorded by Mr. Hulke, of a girl, æt. seventeen, with great expansion of the right frontal sinus, which was evidently caused by an accident when she was five years of age. "She fell from a window and received a cut over the right eyebrow. Her forehead was much bruised and swollen, and she had concussion of the brain."*

There are, however, cases of distended frontal sinus in which no history of an injury can be traced. The only conclusion which can then be drawn is, that from some accidental cause which we cannot detect, the communication between the frontal cells and the nose through the infundibulum has been closed, possibly from some inflammation of the lining mucous membrane. This hypothesis seems the probable explanation of the following case of distension of the frontal sinus in a young girl who had never received an injury. Her mother dated the disease from an attack of erysipelas of the head and face when she was six years old:—

Alice S—, æt. twenty-one, came under my care at the Ophthalmic Hospital, on April 6th, 1869, on account of a tumour on the inner side of the orbit which projected the eye downwards and outwards, as is correctly represented in the woodcut (Fig. 93), taken from a photograph.

History.—The girl states that about six years ago she noticed a swelling at the inner side of the left orbit, close to the bridge of the nose; it was small and soft to the touch, and varied in size, being larger at one time than another; it gradually increased until it attained the dimensions shown in the drawing. The sight of the eye is good. She can read No. I. with ease at 12 inches, and No. XX. Snellen at 20 feet. Her mother thinks that the swelling originated in a severe attack of erysipelas which she had when she was six years old. On two occasions the tumour has been punctured, and each time a thick fluid was evacuated.

After her admission into the hospital, I performed on this patient the operation described at page 412, and succeeded in introducing a drainage-tube through the distended sinus, as is represented in Fig. 94. After cutting into the tumour, my finger passed readily into a large cavity, the dilated frontal sinus, in which I detected a small portion of necrosed bone, which was, however, too firmly adherent to the living structure to be detached. The contents of the cyst consisted partly of the same dark glairy fluid as was found in the first patient, but partly also of pus, with which the dark fluid was freely streaked.

This patient completely recovered, and in the last photograph she sent me, the eye appeared to have regained its normal position.

* Royal London Ophthalmic Hospital Reports, vol. iii. p. 153.

Symptoms.—Distension of the frontal sinus may be *acute* or *chronic*.

When the distension is **acute** it is due to inflammation of the mucous membrane of the sinus, which leads to the

FIG. 93.



formation of pus. There is generally a dull aching pain over the brow and root of the nose, accompanied by considerable constitutional disturbance. The pus gradually accumulates in the frontal sinus, and ultimately discharges itself either by bursting into the nose, or by making an exit for itself through the upper and inner part of the orbit. When the latter site is selected there is usually some bulging of the distended sinus into the orbit, and a slight displacement of the eye downwards and outwards. The upper lid becomes red and swollen, and the tumour examined with the finger is tender, and will, if sufficient thinning of the bone has taken place, impart a sense of fluctuation.

In most cases the distension of the frontal sinus is **chronic**, and the collection of fluid within its walls is the pent-up secretion of many years. Sealed within a bony

cavity, no decomposition ensues, and increasing year by year in quantity it distends the sinus and displaces the eye. There is frequently no pain, not even a sense of weight over the brow. The only symptoms which are manifest to the patient are, the gradual formation of a tumour at the upper and inner portion of the orbit, and a slow but steadily increasing protrusion of the eye downwards, outwards, and forwards. In one patient under my care (Fig. 92), the displacement was so extreme that the upper margin of the cornea of the *left* eye was below the level of the *right* lower lid. Occasionally the early symptoms are chronic, whilst the later ones are sub-acute, and productive of a feeling of constant heaviness and aching across the forehead. The disease is usually confined to the frontal sinus of one side, but I have seen cases in which both frontal sinuses were affected.

Treatment of Distension of the Frontal Sinus.—The objects to be attained are, first to evacuate the pent-up fluid, and then to establish a free communication between the frontal sinus and the nose, through which the secretion may continue to drain as fast as it is secreted. By these means the cavity of the sinus will gradually collapse, and the eye will be restored in a great measure to its normal position. The ends to be desired will be accomplished by the following operation :—

A single curved incision parallel with the fold above the lid is to be made over the most prominent part of the tumour, and having by a little dissection exposed its surface, the scalpel should be plunged into it, and an opening made to the extent of the incision. The index finger of the right hand is now to be pushed into the sinus through the wound to ascertain the size of the cavity and if there is any necrosed or carious bone. Whilst thus exploring the sinus, the little finger of the left hand should be passed up the corresponding nostril and an endeavour made to find out the spot at which the tip of the finger in the sinus will approximate most closely the end of the one in the nose. After a little search it will be found that at one part the fingers will almost meet, there being only a thin plate of bone between them. Having gained this information, the finger in the frontal sinus is to be withdrawn, but that in the nostril is to be retained *in situ* to act as a guide to the gouge or elevator, which is to be passed into the sinus and made to force a passage into the nose through the lamina of bone on

which the tip of the little finger is resting. A communication between the frontal sinus and the nose having been thus established, an india-rubber drainage-tube with holes cut at short distances is to be introduced, one extremity

FIG. 94.

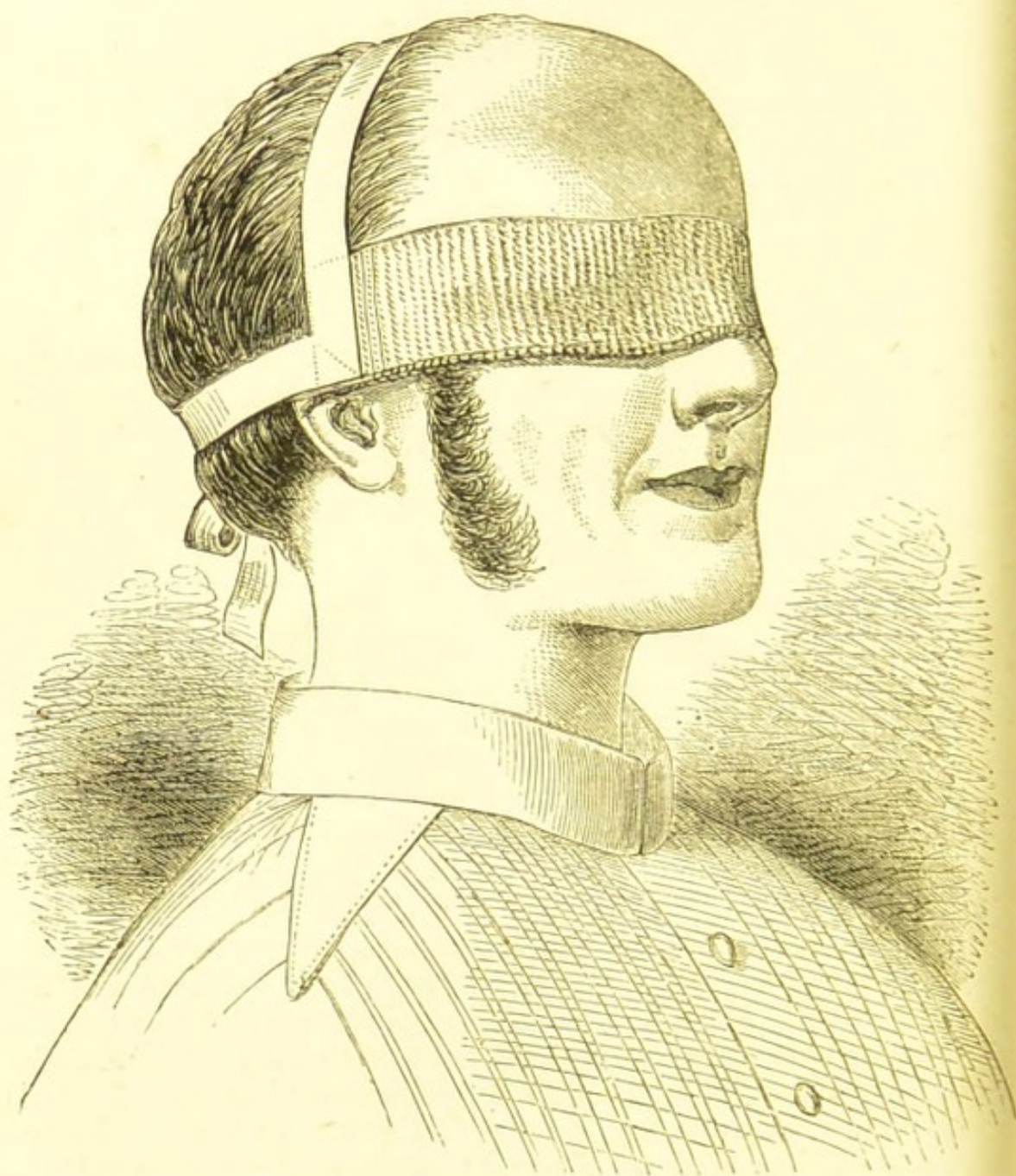


of which is to be afterwards fastened on the forehead, whilst the other end protrudes slightly from the nostril.

The easiest way of introducing the drainage-tube is to pass a probe with an eye up the nostril and out of the wound, and having fastened the tube to it by means of a piece of string, to draw it back again through the nose.

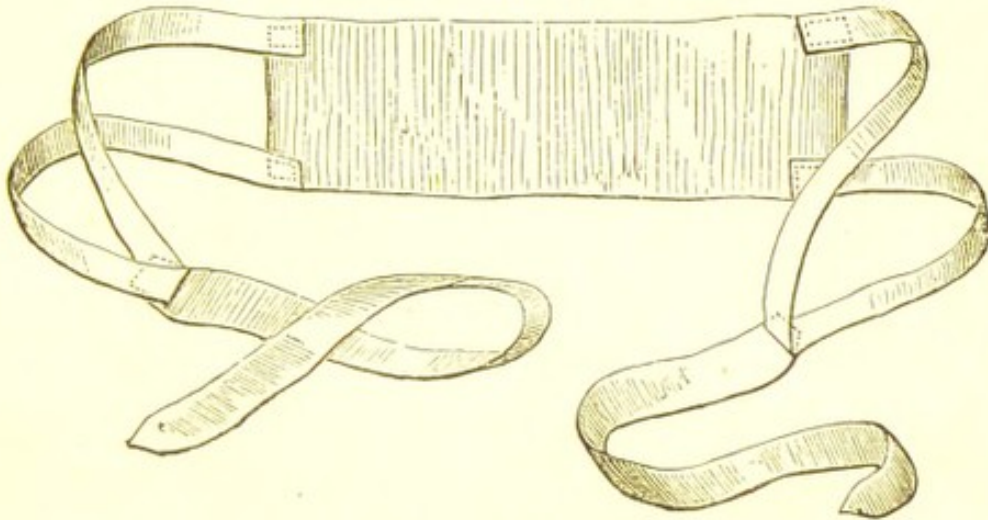
The object of the drainage-tube is to keep the channel between the two cavities from closing, and to enable the attendant to wash out the frontal sinus at least twice a day with some astringent and disinfectant solution. For the latter purpose the *lotio alum. cum zinc. sulph.*, or the *lotio acid. carbolic.* (F. 50, 56) may be injected with a glass syringe through one of the openings at the upper extremity of the tube. The drainage tube should be worn for five or six months, or until all discharge from the nose has ceased. The results of these cases when thus treated are usually most satisfactory.

FIG. 95.



FORMULARY.

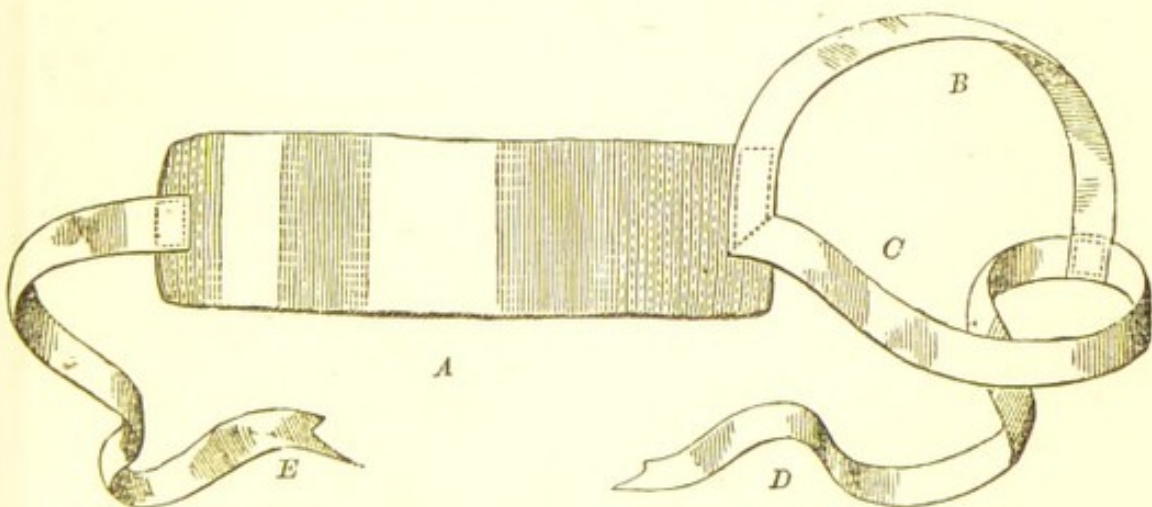
1. The Moorfields Eye Bandage.



This bandage consists of a central band, made of a fold of linen from $9\frac{1}{2}$ to 10 inches in length, and from $2\frac{1}{4}$ to $2\frac{1}{2}$ inches in width. At each end of it are attached tapes, which are

arranged so as to form loops, which include the ears when the bandage is applied. These loops terminate in two tapes, which are tied behind the head.

2. Liebreich's Eye Bandage.



The bandage consists of a linen or a knitted cotton band, *A*, from $9\frac{1}{2}$ to 10 inches in length, and $2\frac{1}{4}$ inches in width;

at either end of which are attached tapes to keep it in position on the head. The tapes should be one inch in width.

One tape, *B*, $11\frac{1}{2}$ to 12 inches in length, extends across the top of the head from ear to ear and terminates in a loop, through which the second tape, *C D*, passes, as in the woodcut.

To apply the bandage:—

The patient having been told to gently close the lids of both eyes, a small square of linen is laid over each, upon which are placed small pads of cotton wool or charpie. The bandage, which had been previously fitted to the head, is now drawn across the eyes and fastened on the temple, *opposite* to the eye which has undergone the operation. (See Fig. 95.)

3. The Compress Bandage.

"This bandage should be about $1\frac{3}{4}$ yards in length, and $1\frac{1}{2}$ inches in width; the outer two-thirds should consist of fine and very elastic flannel, the central third of knitted cotton. The eye having been padded, the bandage is to be adjusted in the following manner:—One end is to be applied to the forehead just above the affected eye, and is then to be passed to the opposite side of the forehead, above the ear, to the back of the head; the knitted portion is then to be carried on below the ear, and brought upwards over the compress, the bandage being passed across the forehead, and its end firmly pinned. The opposite eye may be closed with sticking plaster, or if it also requires a compress, a separate bandage is to be applied to it."*

* "Observations on Compressive Bandages," by Prof. Von Graefe,

In the place of the flannel and knitted cotton bandage above described, a fine linen one will answer equally well.

4. Mercurial Vapour Bath.

The following is Mr. Henry Lee's description of his mercurial vapour bath:—"The most convenient calomel vapour-bath, and that which is now generally



used, is one which was made at my request by Mr. Blaise. In this apparatus the lamp which sublimes the calomel boils the water at the same time. In the centre of the top, immediately over the wick of the lamp, is a small, separate, circular tin plate, upon which the calomel is placed. Around this is a circular depression, which may be one-third filled with boiling water. The apparatus is then placed on the ground, and the lamp is lighted. The patient sits over it with an American cloth cloak, or a Mackintosh, or a moleskin cloak fastened round his neck. He thus becomes surrounded by calomel vapour, which he is generally directed to inhale for two or three separate minutes during each bath. In doing

abridged and translated by Soelberg Wells, *R.L.O.H. Rep.*, vol. iv. p. 206.

this the patient should not put his head under the cloak, but simply allow some of the vapour to escape from its upper part, and breathe it mixed with a large proportion of common air. At the expiration of a quarter of an hour or twenty minutes the calomel is volatilized and the water has boiled away. A portion of the calomel is deposited, together with the condensed vapour of the steam, on the patient's body, and is there to be left. The quantity of spirits of wine used upon each occasion is so regulated that the lamp goes out of its own accord about the same time as the calomel disappears. The patient then gradually unfastens the cloak, and in about a minute he is sufficiently cool to put his night-dress on without much interfering with the very fine layer of calomel which covers his body. He must be particularly told not to wipe his skin, as by so doing he would necessarily interfere with the action of the medicine. Should there be no objection on the part of the patient, he may go to bed in the cloak and sleep in it either for a part or the whole of the night."*

5. Lapis Divinus.

Sulphate of Copper, Nitrate of Potash, and Alum, of each equal parts, in powder, fused in a glazed earthen crucible, powdered Camphor, to the extent of $\frac{1}{10}$ part of the whole, being added near the end of the process. When cold, break in

* Article "Syphilis," Holmes's System of Surgery, by Henry Lee, 2nd edit. vol. i. p. 491.

pieces and keep in a closely stoppered bottle.*

6. Diluted Nitrate of Silver Points.

These are made by fusing Nitrate of Potash in various proportions with Nitrate of Silver; thus:†

No. 1 consists of 1 Nitrate of Silver and 2 of Nitrate of Potash.

No. 2 consists of 1 Nitrate of Silver and 3 of Nitrate of Potash.

No. 3 consists of 1 Nitrate of Silver and $3\frac{1}{2}$ of Nitrate of Potash.

No. 4 consists of 1 Nitrate of Silver and 4 of Nitrate of Potash.

7. Pasta Zinci Chloridi. (*Ph. Middlesex Hospital.*)

This paste is prepared by first making the Liquor Zinci Chloridi cum Opio,‡ and then adding Flour to render it of a proper consistence, as follows:

℞ Liquoris Zinci Chloridi
cum Opio . . . fl.oz. 1
Farinæ Tritici . . . gr. 120

Mix smoothly in a mortar and heat over a water-bath until of a proper consistence.

* Squire's Comp. to Brit. Pharmacop., 5th edit. p. 96.

† Squire's Comp. to British Pharmacop., 5th edit. p. 40.

‡ *Liquor Zinci Chloridi cum Opio.*

℞ Zinci Chloridi . . . oz. 16

Pulveris Opii . . . oz. $1\frac{1}{2}$

Acidi Hydrochlorici . . . fl.dr. 6

Aquam Bullientem . . . ad O 1

Macerate the Opium in twelve ounces of the boiling water for twelve hours, add the acid and filter, then dissolve the Chloride of Zinc in the filtered liquid and make up to twenty ounces with distilled water.

8. Pulvis Caustica.

R Zinci Chloridi . . } Partes
 Zinci Oxidi . . . } æquales.
 Mix them intimately with
 pestle and mortar. Preserve
 in a well-stoppered bottle.

9. Fetus Belladonnæ.

Extract. Belladonnæ . . gr.60
 To be dissolved in one pint
 of boiling water and used as a
 fomentation.

10. Fetus Papaveris.

R Capsul. Papav. contus. oz.1
 Aquæ destillat. . . fl.oz.20
 Mix, and boil for a quarter
 of an hour; then strain through
 muslin.

11. Gargarisma Acidi Hydrochlorici.

R Acidi Hydrochlorici
 diluti. . . . fl.dr.2
 Decoct. Quercûs. . fl.oz.20
 Misce.

12. Gargarisma Aluminis.

R Aluminis . . . gr.120
 Tinct. Myrrhæ . . fl.dr.4
 Aquæ destillat. . ad fl.oz.20
 Misce.

13. Gargarisma Potassæ Chloratis.

R Potassæ Chloratis . gr.90
 Acidi Hydrochlorici . min.40
 Glycerini . . . fl.oz.1
 Aquæ Destillat. . ad fl.oz.20
 Mix the acid and chlorate in
 a bottle; cork and let it stand
 for three minutes; then add
 the water gradually with much
 shaking. Lastly, add the gly-
 cerine.

14. Gargarisma Sodæ Chloratæ.

R Liq. Sodæ Chloratæ . fl.dr.4
 Aquæ destillat. . ad fl.oz.8
 Misce.

15. Guttæ Atropiæ Sulphatis.

R Atropiæ Sulphatis . gr.1 ad
 gr.2
 Aquæ destillat. . . fl.oz.1
 Misce.

16. Guttæ Atropiæ Sulphatis Fortiores.

R Atropiæ Sulphatis . gr.4
 Aquæ destillat. . . fl.oz.1
 Misce.

17. Guttæ Daturiæ.

R Daturiæ Sulphat. . . gr.2
 Aquæ destillat. . . fl.oz.1
 Misce.

18. Guttæ Eseriæ.

R Eseriæ Sulphatis gr.2 ad gr.4
 Aquæ destillat. . . fl.oz.1
 Misce.—To be dropped into
 the eye to produce contraction
 of the pupil. It is the most
 active of the Calabar Bean pre-
 parations.

19. Guttæ Homatropin. Hydrobromat.

R Homatropin. Hydrobromat.
 gr.2
 Aquæ destillat. . . fl.oz.1
 Misce.

20. Guttæ Physostigmatis Fabæ (Calabar Bean).

R Extract. Physostigmatis
 Fabæ . . . gr.1 ad gr.4
 Aquæ destillat. . . fl.dr.1
 Misce.

21. Guttæ Pilocarpiae.

R Pilocarpiae Nitratis . . gr.2
 Aquæ destillat. . . fl.oz.1
 Misce.

22. Guttæ Argenti Nitratis.

R Argenti Nitratis . . gr.1
 Aquæ destillat. . . fl.oz.1
 Misce.

23. Guttæ Argenti Nitratis Fortiores.

R Argenti Nitratis . . gr.2
 Aquæ destillat. . . fl.oz.1
 Misce.

24. Guttæ Potassii Iodidi.

R Potassii Iodidi . . gr.3
 Aquæ destillat. . . fl.oz.1
 Misce.

25. Guttæ Zinci Chloridi.

R Zinci Chloridi . . gr.1
 Aquæ destillat. . . fl.oz.1
 Misce.

26. Guttæ Zinci Sulphatis.

R Zinci Sulphatis gr.1 ad gr.2
 Aquæ destillat. . . fl.oz.1
 Misce.

27. Guttæ Cupri Sulphatis.

R Cupri Sulphatis . . gr.2
 Aquæ destillat. . . fl.oz.1
 Misce.

28. Guttæ Opii.

R Vini Opii . . fl.dr.2
 Aquæ destillat. . . fl.dr.6
 Misce.

29. Guttæ Terebinthinæ.

R Ol. Terebinthinæ . fl.dr.1
 Ol. Olivæ . . fl.dr.7
 Misce.

30. Injectio Morphiae Hypodermica P.B.

A solution of Acetate of Morphia containing one grain of the acetate in twelve minims of the injection.

Dose, 1 to 6 minims.

31. Injectio Morphiae et Atropiæ.

R Atropiæ Sulphatis . . gr.1
 Inject. Morphiae Hypodermicæ P.B. . . fl.dr.6
 Misce.

Dose, 1 to 4 minims.

Three minims contain $\frac{1}{4}$ th of a grain of acetate of morphia and $\frac{1}{120}$ th of sulphate of atropia.

32. Liniment. Aconiti.

R Linimenti Aconiti . fl.dr.4
 Linimenti Saponis . . fl.dr.6
 Misce.

33. Liniment. Ammoniae.

R Liq. Ammoniae . . fl.dr.4
 Ol. Olivæ . . fl.dr.4
 Misce.

34. Liniment. Aconiti cum Belladonna.

R Tinct. Aconiti (Fleming's) fl.dr.4
 Liniment. Belladonnæ fl.oz.1½
 Misce.

35. Linimentum Belladonnæ cum Glycerino.

R Extracti Belladonnæ gr.240
 Glycerini . . fl.oz.½
 Misce.

36. Linimentum Chloroformi.

R Chloroformi . . fl.dr.4
 Ol. Olivæ . . fl.dr.4
 Misce.

37. Linimentum Calcis cum Creta.

R Olei Lini,
Liquoris Calcis . . . āā fl.oz.4
Cretæ Preparatæ . . . oz.2
Misce.

38. Linctus.

R Theriacæ oz.1
Pulv. Tragacanthæ . . . gr.25
Syrupi Papaveris . . . fl.dr.6
Tinct. Scillæ fl.dr.2
Acid. Sulphuric. dilut. min.30
Aquæ fl.oz.2
Misce.

Dose, from a half to two tea-
spoonfuls.

39. Lotio Atropiæ.

R Atropiæ Sulphatis . . . gr.1
Aquæ Sambuci . . . fl.oz.2
Aquæ destillat. . . ad fl.oz.8
Misce.

40. Lotio Belladonnæ.

R Extracti Belladonnæ . gr.40
Aquæ destillat. . . fl.oz.8
Misce.

41. Lotio Belladonnæ cum Alumine.

R Liquor. Belladonnæ
(Battley's) . . . fl.dr.1
Aluminis gr.24
Aquæ Sambuci . . . fl.oz.2
Aquæ destillat. . . ad fl.oz.8
Misce.

42. Lotio Stramonii.

R Extracti Stramonii . . gr.4
Aquæ Lauro-Cerasi . . fl.dr.4
Aquæ destillat. . . ad fl.oz.8
Misce.

43. Lotio Opii.

R Extracti Opii liquidi fl.dr.2
Acid. Hydrocyanici dilut. m30
Aquæ destillat. . . ad fl.oz.8
Misce.

44. Lotio Conii cum Opio.

R Extracti Conii . . . gr.30
Extracti Opii Liquidi fl.dr.1
Aquæ ferventis . . . fl.oz.8
Misce.

45. Lotio Acidi Boracici.

R Acid. Boracici . . . gr.4 to gr.6
Aquæ destillat. . . fl.oz.1
Misce.

46. Lotio Resorcini.

R Resorcini gr.36
Aquæ destillat. . . fl.oz.8
Misce.

47. Lotio Aluminis.

R Aluminis gr.6
Aquæ destillat. . . fl.oz.1
Misce.

48. Lotio Aluminis Mit.

R Aluminis gr.4
Aquæ destillat. . . fl.oz.1
Misce.

49. Lotio Aluminis cum Atropia.

R Aluminis gr.24
Atropiæ Sulphatis . . . gr.1
Aquæ destillat. . . fl.oz.8
Misce.

50. Lotio Alum. cum Zinci Sulph.

R Aluminis gr.3
Zinci Sulphatis . . . gr.1
Aquæ destillat. . . fl.oz.1
Misce.

51. Lotio Evaporans.

R Sp. Ætheris Nitrosi fl.dr.2
Aceti Aromatici . . . min.6
Aquæ destillat. . . ad fl.oz.1
Misce.

52. Lotio Plumbi.

R Plumbi Acetatis . . . gr.2
 Acidi Acetici dilut. . . min.2
 Aquæ destillat. . . . fl.oz.1
 Misce.

53. Lotio Quiniæ Sulphatis.

R Quiniæ Sulphatis . . . gr.4
 Acid. Sulphuric. dilut. . .
 m $\frac{1}{2}$ vel q. s.
 Aquæ destillat. . . . fl.oz.1
 Misce.

Useful as a local application
 in some cases of Diphtheritic
 Ophthalmia.

54. Lotio Zinci Oxidi.

R Zinci Oxidi gr.90
 Glycerini fl.dr.4
 Aquæ Sambuci fl.oz.2
 Aquæ destillat. . . . ad fl.oz.8
 Misce.

55. Lotio Glycerini.

R Glycerini fl.dr.4
 Aquæ Flor. Aurantii . fl.oz.2
 Aquæ destillat. . . . ad fl.oz.8
 Misce.

56. Lotio Acid. Carbolie.

R Acid. Carbolie. pur. . .
 min. 2 to min.8
 Aquæ destillat. . . . fl.oz.1
 Misce.

57. Lotio Hydrarg. Perchloridi.

R Hydrarg. Perchloridi . gr. $\frac{1}{8}$
 Aquæ destillat. . . . fl.oz.1
 Misce.

58. Lotio Acidi Tannici.

R Acidi Tannici gr.30
 Sp. Vini rectificati . . fl.dr.4
 Aquæ Rosæ fl.oz.2
 Aquæ destillat. . . . ad fl.oz.8
 Misce.

59. Lotio Boracis cum Glycerino.

R Boracis gr.120
 Glycerini fl.oz. $\frac{1}{2}$
 Aquæ Sambuci fl.oz.2
 Aquæ destillat. . . . ad fl.oz.8
 Misce.

Very useful in eczema of the
 face and eyelids.

60. Lotio Boracis cum Plumbo.

R Liquor. Plumbi Subacetatis
 min.30
 Boracis gr.60
 Glycerini fl.dr.2
 Aquæ destillat. . . . ad fl.oz.8
 Misce.

Useful in eczema of the face
 and eyelids.

61. Lotio Boracis cum Soda.

R Sodæ Bicarb. gr.60
 Boracis gr.60
 Acid. Hydrocyanici diluti
 min.40
 Aquæ Sambuci fl.oz.2
 Aquæ destillat. . . . ad fl.oz.8
 Misce.

Useful in eczema of the face
 and eyelids.

62. Lotio Arnicæ.

R Tincturæ Arnicæ . . . min.30
 Aquæ destillat. . . . fl.oz.1
 Misce.

63. Lotio Nigra.

R Calomelanos gr.60
 Mucilag. Acaciæ . . . fl.dr.4
 Liquor. Calcis ad fl.oz.8
 Misce.

64. Lotio Rubra.

R Zinci Sulphatis . . gr.1
 Sp. Rosmarini,
 Tinct. Lavandulæ comp.
 āā min.15
 Aquæ destillat. . . fl.oz.1
 Misce.

65. Mistura Antimonii Tartarati.

R Vin. Antimonialis . fl.dr.½
 Liq. Ammon. Acetatis fl.dr.1
 Tinct. Hyoscyami . min 20
 Aquæ destillat. . ad fl.oz.1
 Misce.

66. Mistura Potassæ Citratis.

R Potassæ Bicarb. . . gr.20
 Sp. Ammon. Aromat. fl.dr.½
 Tinc. Aurantii . . fl.dr.½
 Aquæ destillat. . . fl.oz.1½
 To be taken in effervescence
 with

Acid. Citric. gr. 14.
 dissolved in one tablespoonful
 of water.

The Sp. Ammon. Aromat.
 may be omitted if desired.

67. Mistura Chloroformi cum Ammonia.

R Ammoniæ Carb. . . gr.3
 Sp. Chloroformi . . min.15
 Tinct. Aurantii . . fl.dr.½
 Aquæ destillat. . . fl.oz.1½
 Misce.

68. Mistura Salinæ.

R Potassæ Bicarb. . . gr.10
 Spirit. Ætheris Nitrosi fl.dr.½
 Liq. Ammoniæ Acetatis fl.dr.1
 Aquæ destillat. . . ad fl.oz.1
 Misce.

69. Mistura Cinnamomi.

R Tinct. Cinnamomi . fl.dr.1
 Aquæ destillat. . . fl.oz.1
 Misce.

70. Mistura Cinnamomi cum Acido.

R Tinct. Cinnamomi . fl.dr.½
 Acid. Nitro-Muriatic dilut.
 min.10
 Aquæ destillat. . . ad fl.oz.1
 Misce.

71. Mistura Boracis.

R Boracis . . . gr.60
 Sp. Ætheris Nitrosi . fl.dr.4
 Syrup. Aurantii . . fl.dr.4
 Aquæ destillat. . . ad fl.oz.8
 Misce.
 Dose, 1 ounce.

72. Mistura Ergotæ.

R Extracti Ergotæ liquidi
 min.30
 Tinct. Aurantii . . min.30
 Aquæ destillat. . . ad fl.oz.1
 Misce.
 To be taken twice a day.

73. Mistura Nucis Vomicæ.

R Tinct. Nucis Vomicæ min.15
 Infus. Gentian. comp. fl.oz.1
 Misce.

74. Mistura Acidi cum Tinct. Nucis Vomicæ.

R Acidi Nitro-Muriatici dilut.
 min.10
 Tinct. Nucis Vomicæ min.15
 Tinct. Chiratae . . min.15
 Aquæ destillat. . . fl.oz.1
 Misce.

75. Mistura Acidi cum Cinchona.

R Acidi Nitro-Muriatici dilut.
 min.10
 Tinct. Cinchonæ . . fl.dr.½
 Decoct. Cinchonæ . . fl.oz.1
 Misce.

76. Mistura Cinchonæ cum Opio.

R Extract. Cinchonæ Flav.
 liquid. min.15
 Acidi Nitrici dilut. . . min.10
 Tinct. Opii . . . min.5 to 10
 Aquæ destillat. . . . fl.oz.1
 Misce.

77. Mistura Cinchoniæ.

R Cinchoniæ Sulphatis gr.3
 Acidi Sulphurici dilut. min.10
 Aquæ destillat. . . . fl.oz.1
 Misce.

78. Mistura Croton Chloral.

R Croton Chloral . . . gr.2
 Tinct. Aurantii . . . fl.dr.½
 Pulv. Gum Tragacanth. gr.3
 Aquæ destillat. . . . fl.oz.1
 Misce.

To be taken every one or two hours for three doses *only*, until relieved.

79. Mistura Quiniæ.

R Quiniæ Sulphatis . . gr.1
 Acid. Sulphuric. dilut. min.10
 Tinct. Aurantii . . . fl.dr.½
 Aquæ destillat. . . . fl.oz.1
 Misce.

80. Mistura Quiniæ cum Ferro.

R Quiniæ Sulphatis,
 Ferri Sulphatis . . . āā gr.1
 Acidi Sulphurici diluti min.5
 Aquæ destillat. . . . fl.oz.1
 Misce.

81. Mistura Ferri Perchloridi cum Quinia.

R Quiniæ Sulphatis . . gr.1
 Tinct. Ferri Perchlorid. min.5
 Acidi Nitrici diluti . . min.5
 Aquæ destillat. . . . ad fl.oz.1
 Misce.

82. Mistura Ferri et Ammoniae Citratis.

R Ferri et Ammoniae Citratis
 gr.5
 Acidi Citrici . . . gr.5
 Syrup. Aurantii . . . fl.dr.½
 Aquæ destillat. . . . fl.oz.1
 Misce.

83. Mistura Ferri Sulphatis.

R Ferri Sulphatis . . . gr.1
 Acidi Sulphurici diluti min.10
 Aquæ destillat. . . . fl.oz.1½
 Misce.

84. Mistura Ferri Perchloridi.

R Tinct. Ferri Perchloridi
 min.10
 Aquæ destillat. . . . fl.oz.1
 Misce.

85. Mistura Ferri Perchloridi cum Acido.

R Tinct. Ferri Perchloridi
 min.10
 Acid. Hydrochloric. dilut.
 min.10
 Aquæ destillat. . . . fl.oz.1½
 Misce.
 To be taken in water twice a day.

86. Mistura Ferri Perchloridi cum Strychnia.

R Tinct. Ferri Perchloridi
 min.10
 Liquor Strychniæ . . . min.5
 Aquæ destillat. . . . fl.oz.1
 Misce.

87. Mistura Ferri cum Tinct. Digitalis.

R Tinct. Ferri Perchloridi
 min.10
 Tinct. Digitalis . . . min.5
 Infus. Quassiae . . . ad fl.oz.1
 Misce.

88. Mistura Ferri Peroxidi et Ammon. Sulphat.

R Ferri Peroxid. et Ammon.
Sulph. (Iron Alum). . . gr.5
Tinct. Calumbæ . . min.30
Aquæ destillat. . . fl.oz.1½
Misce.

89. Mistura Ferri cum Ergota.

R Tinct. Ferri Perchloridi
min.10
Tinct. Ergotæ . . min.15
Aquæ destillat. . . fl.oz.1
Misce.

90. Mistura Guaiaci cum Cinchona.

R Tinct. Guaiaci Ammon. fl.dr.4
Extracti Cinchonæ Flavæ
liquidi . . . fl.dr.2
Mucilag. Acaciæ . . fl.dr.6
Aquæ destillat. . . ad fl.oz.8
Misce.

Dose, two tablespoonfuls in half a glass of water two or three times a day.

91. Mistura Potassii Iodidi.

R Potassii Iodidi . . gr.4
Potass. Bicarbonat. . gr.5
Tinct. Cinchonæ Flav. fl.dr.½
Aquæ destillat. . . fl.oz.1
Misce.

92. Mistura Potassii Iodidi cum Ferro.

R Potassii Iodidi . . gr.3
Potassæ Bicarb. . . gr.5
Ferri et Ammoniac Citratis
gr.5
Aquæ distillat. . . fl.oz.1
Misce.

93. Mistura Potassii Iodidi et Bromidi cum Ferro.

R Potassii Iodidi . . gr.4
Potassii Bromidi . . gr.5
Ferri et Ammoniac Citratis
gr.5
Aquæ destillat. . . fl.oz.1
Misce.

94. Mistura Potass. Iodidi cum Ammonia.

R Potassii Iodidi . . gr.3
Potassæ Bicarb. . . gr.5
Ammon. Carbonat. . gr.3
Tinct. Calumbæ . . fl.dr.½
Aquæ destillat. . . ad fl.oz.1
Misce.

95. Mistura Potassii Iodidi cum Colchico.

R Potassii Iodidi . . gr.2
Potassæ Bicarb. . . gr.10
Tinct. Colchici . . min.10
Aquæ destillat. . . fl.oz.1
Misce.

96. Mistura Potassii Iodidi cum Guaiaco.

R Potassii Iodidi . . gr.2
Tinct. Guaiaci Ammon. fl.dr.½
Tinct. Cinchonæ Flav. fl.dr.½
Mucilag. Acaciæ . . fl.dr.½
Aquæ destillat. . . ad fl.oz.1
Misce.

To be taken in half a glass of water twice a day.

97. Mistura Potassii Iodidi et Bromidi.

R Potass. Iodidi . . gr.3
Potass. Bromidi . . gr.5
Potass. Bicarb. . . gr.5
Tinct. Calumbæ . . fl.dr.½
Aquæ destillat. . . ad fl.oz.1
Misce.

98. Mistura Potassii Iodidi cum Hydrarg. Perchloridi.

R Hydrarg. Perchloridi gr.1
 Potassii Iodidi . . . gr.60
 Tinct. Calumbæ . . . fl.oz.2
 Aquæ destillat. . . ad fl.oz.6
 Misce.

Dose, two teaspoonfuls in a glass of water two or three times a day.

99. Mistura Potassii Bromidi.

R Potass. Bromidi gr.5 to gr.10
 Potass. Bicarb. . . . gr.5
 Tinct. Calumbæ . . . fl.dr.½
 Infus. Calumbæ . . . fl.oz.1
 Misce.

100. Mistura Potassii Bromidi cum Ferro.

R Potass. Bromidi gr.5 to gr.10
 Ferri et Ammoniae Citrat. . . . gr.5
 Tinct. Calumbæ . . . fl.dr.½
 Aquæ destillat. . . ad fl.oz.1

101. Mistura Hydrarg. Perchloridi.

R Liquor Hydrarg. Perchloridi . . . fl.dr.1
 Tinct. Cinchonæ comp. fl.dr.½
 Aquæ destillat. . . . fl.oz.1
 Misce.

102. Mistura Terebinthinæ.

R Olei Terebinthinæ min.15
 Mucilaginis Acaciæ fl.dr.1
 Aquæ Pimentæ . . ad fl.oz.1½
 Misce.

103. Mistura Gentianæ cum Aloes.

R Decoct. Aloës comp. fl.dr.12
 Tinct. Gentianæ comp. fl.dr.3
 Infus. Gentianæ comp. ad fl.oz.8
 Misce.
 Take a sixth part twice a day.

104. Mistura Magnesiae Composita.

R Magnesiae Carbonatis pond. . . . gr.10
 Magnesiae Sulphatis . gr.60
 Aquæ Menthæ Piperitæ fl.oz.1½
 Misce.

105. Mistura Rhei Comp.

R Rhei Pulveris . . . gr.15
 Magnesiae Carbonatis. gr.10
 Sp. Ammon. Aromat. fl.dr.½
 Tinct. Rhei . . . fl.dr.1
 Aquæ destillat. . . ad fl.oz.1½
 Misce.

106. Pilula Aloes cum Ferro.

R Extracti Aloës Socotrinæ,
 Ferri Sulphatis,
 Pulv. Zingiberis . . āā gr. 1
 Theriacæ q.s.
 Misce.

107. Pilula Aloes cum Jalapa.

R Extract. Aloës Socotrinæ gr.1½
 Jalapæ Resinæ . . . gr.1½
 Pulv. Gum. Scammonii gr.2
 Saponis Mollis . . . gr.2
 Mix and divide into two pills.
 Dose, 1 or 2.

108. Pilula Aloes cum Nuce Vomica.

R Extracti Nucis Vomicae gr.¼
 Extracti Aloës Socotrinæ gr.1
 Extracti Hyoscyami . gr.2
 Misce.
 Dose, 1, when necessary.

109. Pilula Belladonnæ cum Zinci Sulphate.

R Extracti Belladonnæ. gr.½
 Zinci Sulphatis . . . gr.1
 Sacchari Lactis . . . gr.1
 Theriacæ q.s.
 Misce.

110. Pilula Croton-Chloral.

R Croton-Chloral Hydrat. gr.3
 Glycerini Tragacanth. vel
 Mucilag. Acaciæ . q.s.
 Misce.

To be taken every one, two
 or three hours for three doses
only until relieved.

111. Pilula Cinchonix cum Ferro.

R Cinchonix Sulphatis,
 Ferri Sulphatis āā gr.1
 Confectionis Rosæ Caninæ q.s.
 Misce.

112. Pilula Quiniæ cum Opio.

R Quiniæ Sulphatis gr.1
 Pulv. Opii gr.½
 Misce.

113. Pilula Colocynthis cum Hydrargyro.

R Pilulæ Hydrargyri,
 Extracti Colocynthis
 compositi. āā gr.2
 Extracti Hyoscyami . gr.1
 Misce.

114. Pilula Colocynthis cum Rheo.

R Pilulæ Colocynthis
 comp. gr.3
 Pilulæ Rhei comp. gr.3
 Extracti Hyoscyami . gr.2
 Mix and divide into two pills.
 Dose, 1 or 2.

115. Pilula Calomelanos cum Colocynthis.

R Hydrargyri Subchloridi gr.1
 Extracti Colocynthis
 compositi. gr.3
 Pulveris Ipecacuanhæ . gr.½
 Misce.
 Dose, 1 or 2.

116. Pilula Elaterii Composita.

R Elaterii. gr.½
 Extract. Aloës Socotrinæ
 gr.1½
 Extracti Hyoscyami . gr.3
 Misce.

117. Pilula Colchici Comp.

R Extract. Colchici Acetici gr.1
 Pulv. Ipecacuanhæ comp. gr.4
 Extracti Hyoscyami . gr.1
 Misce.

118. Pil. Cannabis Comp.

R Extract. Cannabis Indicæ
 gr.¼
 Extract. Belladonnæ . gr.¼
 Pulv. Glycyrrhizæ . gr.2
 Misce.
 One pill at night, or when in
 great pain.

119. Pil. Calomel. cum Opio.

R Hydrarg. Subchloridi
 gr.1 ad gr.2
 Pulv. Opii gr.¼ ad gr.½
 Confect. Rosæ Caninæ q.s.
 Misce.

120. Pil. Hydrarg. cum Opio.

R Pil. Hydrarg. gr.4
 Pulv. Opii gr.½
 Misce.

121. Pil. Hydrarg. Iodidi Virid.

R Hydrarg. Iodidi Virid.
 gr.½ ad gr.1
 Extracti Lactuæ gr.2
 Misce.

122. Pil. Sodæ Arseniatis.

R Sodæ Arseniatis gr. 1/16
 Sacchari Lactis gr.1
 Extract. Lupuli gr.3
 Misce.

123. Unguentum Belladonnæ.

R Extracti Belladonnæ. oz. $\frac{1}{2}$
 Glycerini . . . fl.dr.1
 Adipis or Vaseline . oz. $\frac{1}{2}$
 Misce.

**124. Unguent. Belladonnæ
Comp.**

R Hydrarg. Ammoniati. gr.5
 Extract. Belladonnæ . gr.10
 Adipis or Vaseline . oz.1
 Misce.

To be rubbed on the forehead and temple. The surface may be then covered with a piece of tissue paper to prevent the hair getting into it.

**125. Unguent. Hydrarg. cum
Atropia.**

R Atropiæ Sulphatis . gr.1
 Unguent. Hydrarg. . gr.120
 Unguent. Cetacei . gr. 240
 Misce.

**126. Unguent. Hydrarg. cum
Belladonna.**

R Extract. Belladonnæ. gr.60
 Unguent. Hydrarg. . gr.420
 Misce.

To be rubbed into the temple and around the brow.

**127. Unguentum Hydrargyri
cum Opio.**

R Opii. gr.60
 Unguenti Hydrargyri gr.420
 Misce.

128. Unguentum Opii.

R Opii. gr.60
 Adipis gr.420
 Misce.

**129. Unguent. Hydrarg.
Nitratis dilut.**

R Unguent. Hydrarg.
 Nitratis gr.20
 Unguent. Cetacei or
 Vaseline gr.120
 Misce.

**130. Unguent. Hydrarg.
Oxidi Rubri Dilut.**

R Unguent. Hydrarg. Oxidi
 rubri gr.20
 Unguent. Cetacei or Vase-
 line gr.120
 Misce.

**131. Unguent. Hydrarg.
Oxid. Flav.**

R Hydrarg. Oxid. Flav.
 gr. $\frac{1}{2}$ ad gr.1
 Unguent. Cetacei or Vase-
 line gr.120
 Misce.

**132. Unguent. Hydrarg.
Iodidi Rubri.**

R Hydrarg. Iodidi Rubri
 gr. 10 to gr. 15
 Unguent. Cetacei or Vase-
 line oz.1
 Misce.

A mercurial counter-irritant.
 To be rubbed into the temple at night. In applying this ointment the fingers should be covered with a glove.

133. Unguent. Iodoform.

R Iodoformi præcipitati
 gr. 1 ad gr. 2
 Vaseline dr. 1
 Misce.

**134. Unguentum Stramonii.
(Middlesex Hospital.)**

R Foliorum Stramonii re-
 centium lb. $\frac{1}{2}$
 Adipis lb.2
 Mix the bruised leaves with the fat and expose to a mild heat until the leaves become friable, then strain through linen.

FORMULARY FOR CHILDREN.

135. Mistura Salina.

℞ Liquor Ammonię Citratis . . . fl.dr.4
 Sp. Ætheris Nitrosi . . . fl.dr.3
 Syrup. Tolutani . . . fl.dr.4
 Aquę destillat. . . ad fl.oz.4
 Misce.—Dose, one dessert-
 spoonful every four hours.

136. Mistura Antimonii
Tartarati.

℞ Vini Antimonialis . fl.dr.2
Liq. Ammoniae Citratis fl.dr.4
Syrup. Althææ . . . fl.dr.3
Aquæ destillat. . . ad fl.oz.4
Misce.—Dose, one dessert-
spoonful between 2 and 4 years
of age ; one tablespoonful be-
tween 4 and 8.

137. **Mistura Potassæ Chloratis.**

℞ Potassæ Chloratis . gr.24
Acid. Hydrochloric. dilut. min.24
Syrupi Aurantii . . fl.dr.4
Aquæ destillat. . . fl.oz.4
Misce.—One tablespoonful
three times a day.

138. Mistura Cinchonæ cum
 Acido.

℞ Extract. Cinchonæ flav.
liquid. . . . min.40
Acidi Nitrici diluti . min.40
Syrupi Aurantii . . . fl.dr.3
Aquæ destillat. . . ad fl.oz.4
Misce.—Dose, one table-
spoonful.

139. *Mistura Cinchonæ cum*
Infus. Rosæ.

℞ Extract. Cinchonæ flav.
liquid. fl.dr.1
Syrup. Aurantii . . . fl.dr.4
Infusi Rosæ Acidi . . ad fl.oz.6
Misce.—One tablespoonful
twice a day.

140. Mistura Cinchonæ cum
Tinct. Belladonnæ.

℞ Extract. Cinchonæ flav.
liquid. min.5
Acid. Nitric. dilut. . min.3
Tinct. Belladonnæ
min.3 to min.5
Aquæ destillat. . ad fl. oz.½
Misce.—For a child from 4
to 7 years of age.

141. Mistura Potassii Bromid.
cum Tinct. Belladonnæ.

R Potassii Bromid. . . gr.2
Tinct. Belladonnæ . . . min.3 to min.5
Aquæ destillat. . . fl.oz.½
Misce.—For a child from 4
to 7 years of age.

142. *Mistura Ferri Iodidi.*

R Syrup. Ferri Iodidi
min. 10 to 20
Glycerini fl. dr. $\frac{1}{2}$
Aquæ destillat. . . . ad fl. oz. $\frac{1}{2}$
Misce.

143. Mistura Potassii Iodidi cum Ferro.

℞ Potassii Iodidi . . . gr.8
 Ferri et Ammoniae Citratis . . . gr.24
 Sacchari albi . . . gr.60
 Aquæ destillat. . . ad fl.oz.4
 Misce.—One dessertspoonful for a dose.

144. Mistura Ferri Citratis.

℞ Ferri et Ammoniae Citratis . . . gr.30
 Sacchari albi . . . gr.60
 Aquæ destillat. . . fl.oz.4
 Misce.—One dessert to a tablespoonful twice a day.

145. Mistura Ferri Hypophosphitis.

℞ Syrup. Ferri Hypophosphitis . . min.15 to 30
 Aquæ destillat. . . fl.oz.½
 Misce.

146. Mistura Ferri Phosphatis Comp.

℞ Syrup. Ferri Phosphatis comp. (Parrish) min. 30 to 60
 Aquæ destillat. . . fl.oz.½
 Misce.—To be taken twice a day between the meals.

147. Mistura Arsenicalis.

℞ Liquor Arsenicalis min. 1 to 2
 Syrup. Aurantii . . min.20
 Aquæ destillat. . . fl.oz.½
 Misce.—To be given twice a day, immediately after a meal. For a child from 4 to 7 years of age.

148. Pulvis Cinchonæ cum Soda.

℞ Pulveris Cinchonæ flavæ,
 Soda Bicarbonatis,
 partes æquales.
 Misce.—Dose, gr. 5 to gr. 10.

149. Pulv. Ferri Carbonat. Saccharat.

Dose, gr. 3 to gr. 6, once or twice a day.

150. Pulv. Ipecac. Comp. cum Potass. Nitrat.

℞ Pulvis Ipecac. comp. . . gr.1
 Potassæ Nitratis . . . gr.2
 Misce.

151. Pulvis Hydrarg. cum Creta cum Saccharo.

℞ Pulvis Hydrarg. cum Cretâ . . . gr.1
 Pulvis Sacchari albi . . gr.2
 Misce.

152. Pulvis Alterativus.

℞ Hydrarg. cum Cretâ . . gr.1
 Sodæ Bicarbonatis . . gr.2
 Pulvis Rhei . . . gr.3
 Misce.—Dose, gr. 6 to gr. 12

153. Pulv. Hydrarg. cum Creta cum Rheo.

℞ Hydrarg. cum Cretâ . . gr.1
 Pulv. Rhei . . . gr.2
 Misce.—Dose, gr. 3 to gr. 8

154. Pulvis Scammonii cum Jalapa.

℞ Pulv. Scammonii . . gr.1
 Pulv. Jalapæ . . . gr.3
 Misce.

155. Pulvis Calomel cum
Rheo.

R Pulv. Rhei gr.4
Hydrargyri Subchloridi,
Pulv. Cretæ Aromaticæ,
āā gr. 1
Misce.—Dose, gr. 3 to gr. 8

156. Pulvis Calomel cum
Jalapa.

R Pulv. Jalapæ gr.4
Hydrargyri Subchloridi,
Zingiberis āā gr. 1.
Misce.—Dose, gr. 3 to gr. 6

157. Pulvis Calomel cum
Scammonio.

R Pulv. Scammonii . . . gr.4
Hydrargyri Subchloridi,
Sacchari purificati . āā gr.1
Misce.—Dose, gr. 3 to gr. 6.

158. Pulvis Calomel et Scam-
mon. cum Jalapa.

R Hydrargyri Subchloridi gr.1
Scammonii gr.2
Pulv. Jalapæ gr.4
Misce.—Dose, gr. 3 to gr. 7.

TEST-TYPES

IN USE AT THE

Royal London Ophthalmic Hospital, MOORFIELDS,

*Corresponding to the "Schrift-Scalen" of Prof. Edw. Jaeger,
of Vienna.*

No. 1.—Gem.

I had now been in the isle twelve months, and I thought it was time to go all round it, in search of its woods, springs, and creeks. So I set off, and brought back with me limes and grapes in their prime, large and ripe. I had hung the grapes in the sun to dry, and in a few days' time went to fetch them, that I might lay up a store. The vale, on the banks of which they grew, was fresh and green, and a clear, bright stream ran through it, which gave so great a charm to the spot, as to make me wish to live there. But

No. 2.—Pearl.

there was no view of the sea from this vale, while from my house, no ships could come on my side of the isle, and not be seen by me; yet the cool, soft banks were so sweet and new to me that much of my time was spent there. In the first of the three years in which I had grown corn, I had sown it too late; in the next, it was spoilt by the drought; but the third year's crop had sprung up well. I found that the hares would lie in it night and day, for which there was no cure but to plant a thick hedge all round it; and this took me more than three weeks to do. I shot

No. 4.—Minion.

the hares in the day time; and when it grew dark, I made fast the dog's chain to the gate, and there he stood to bark all night. In a short time the corn grew strong, and at last ripe; but, just as the hares had hurt it in the blade, so now the birds ate it in the ear. At the noise of my gun, whole flocks of them would fly up; and at this rate I saw that there would be no corn left; so I made up my mind to keep a look out night and day. I hid by the side of a hedge, and could

No. 15.—2-line English.

would fall out
here, and in
there, in all sorts

No. 16.—2-line Great Primer.

of ways; while
some when
they were put

No. 18.—2-line Double Pica.

out in the
sun to bake

INDEX.

- ABRASIONS of cornea, 75
Abscess of cornea, 37
 ,, eyelid, 361
 ,, orbit, 372
Abscession of staphyloma of the cornea, 64
Acids, injuries from, 307
Accommodation, diseases of, 247
Acute inflammatory glaucoma, 119
Alternating strabismus, 274
Amaurosis, 221
 ,, causes of, 226
 ,, from disease of cerebrum, 226
 ,, ,, ,, cerebellum, 226
 ,, ,, ,, spinal cord, 226
 ,, ,, loss of blood, 228
 ,, ,, reflex irritation, 228
 ,, ,, tobacco, 221
 ,, ,, uterine derangements, 227
 ,, monocular, 228
 ,, signification of, 221
Amblyopia, 228
 ,, signification of, 228
Anatomy of external coats of optic nerve, 215
 ,, fourth nerve, 296
 ,, frontal sinus, 407
 ,, optic tract, commissure and nerve, 224
 ,, parts concerned in glaucoma, 126
 ,, sixth nerve, 297
 ,, third nerve, 294
Anchyloblepharon, 364
Aneurisms of orbit, 383
 ,, by anastomosis, 389
 ,, diffuse, 386
 ,, spontaneous, 386
 ,, traumatic, 386

- Aneurisms, true and false, 386
 ,, treatment of, 388
 Anomalies of refraction, 247
 Anterior chamber, dislocation of lens into, 170
 ,, ,, hæmorrhage into, 103
 ,, staphyloma of the sclerotic, 65
 Aquo-capsulitis, 89
 Arcus senilis, 71
 Arlt, Dr., operation for entropion, 339
 Artificial pupil, 101
 ,, with a broad needle and Tyrrell's hook, 101
 ,, by iridectomy, 102
 ,, by iridodesis, 103
 ,, division of iris with a pair of scissors, 102
 ,, eyes, 313
 Ascending optic neuritis, 216
 Asthenopia, 269
 ,, from hypermetropia, 269
 ,, ,, insufficiency of the internal recti, 270
 Astigmatism, 261
 ,, compound, 263, 268
 ,, irregular, 262
 ,, mixed, 263, 269
 ,, regular, 263
 ,, simple, 263
 ,, to ascertain the presence of, 263
 ,, ,, Couper's method, with ophthalmoscope, 268
 ,, ,, Snellen's method, 264
 ,, ,, Tweedy's method, with optometer, 265
 ,, treatment of, 263-269
 Atropia, sulphate of, 94
 Atrophic cup of optic nerve, 219
 Atrophy of optic nerve, 218
 ,, ,, ,, senile, 219
 ,, ,, ,, from tobacco, 221

BLACK cataracts, 145

- Blennorrhœa, 316
 Blepharospasm, 351
 Bone on the choroid, 199
 Bowman, Sir W., operation for conical cornea, 60
 ,, ,, capsulo-lenticular cataract, 162
 ,, ,, ectropion, 345
 ,, spoon for traction operation, 150
 Broad needle, 143
 Buller's eye shield, 9
 Burns and scalds of eye, 306
 Burow's operation for entropion, 338

- CALABAR bean, 98
 Calcareous film of cornea, 54
 Canaliculus, to slit up the, 322
 Canular forceps, 169
 Capsular cataract, 161, 166
 " opacities, 166
 " " varieties of, 161, 166
 " " treatment of, 167
 Capsule, opaque, needle operation for, 167
 " " operation with two needles for, 168
 " " " " canular forceps for, 169
 Capsulo-lenticular cataract, 161, 166
 Carter's fixed ophthalmoscope, 240
 Caries of orbit, 382
 Casualties after an extraction of cataract, 157
 Cataract, 137
 " black, 145
 " capsular, 161, 166
 " capsulo-lenticular, 161, 166
 " causes of, 137
 " congenital, 138
 " " operations for, 139-144
 " cortical, 139
 " diabetic, 137, 162
 " fluid, 162
 " hard, 138, 145
 " " treatment of, 146
 " " operations for, 147-156
 " " casualties after an operation for, 157
 " " treatment after extraction of, 156
 " infantile, 138
 " lamellar, 138
 " nuclear, 145
 " pyramidal, 161
 " secondary, 165
 " senile, 137, 146
 " soft, 138
 " striated, 145
 " traumatic, 138, 163
 " treatment by flap extraction, 147
 " " Graefe's modified linear extraction, 15
 " " linear extraction, Gibson's, 141
 " " Liebreich's operation, 154
 " " Macnamara's operation, 155
 " " Pagenstecher's extraction, 155
 " " solution, 140
 " " suction, 144
 " " traction operation, 149
 Catarrhal ophthalmia, 1

- Chalazion, 356
- Chloride of zinc, use of, in removal of orbital tumours, 402-406
- Choked disc, 213
- Choroid, colloid degeneration of, 201
 - „ deposits of bone on, 199
 - „ diseases of, 194
 - „ hæmorrhage from, 203
 - „ injuries of, 203
- Choroid, melanotic cancer of, 209
 - „ sarcoma of, 207
 - „ „ „ originating in lost eyes, 210
 - „ „ „ melanotic, 209
 - „ tubercles in, 202
 - „ tumours of, 207
- Choroiditis, disseminated, 194
 - „ suppurative, 197
- Choroido-iritis, 107, 108
- Chromo-pseudopsis, 231
- Chronic glaucoma, 122
 - „ interstitial corneitis, 32
 - „ ophthalmia, 3
- Cilia forceps, 332
- Ciliary muscle, paralysis of, 286
 - „ „ spasm of, 287
 - „ staphyloma, 65
- Colour blindness, 231
- Coloboma of iris, 131
- Colloid degeneration of choroid, 201
- Concomitant strabismus, 276
- Congenital cataract, 138, 139
 - „ tumour of orbit, 400
- Conical cornea, 56
 - „ „ operations for, 59
- Conjunctivitis, acute, 1
 - „ follicular, 22
- Conjunctiva, diseases of, 1
 - „ fibro-fatty tumours of, 28
 - „ foreign bodies on, 72
 - „ cysts of, 29
 - „ cuticular, 24
 - „ dislocation of lens beneath, 174
 - „ ecchymosis of, 29
 - „ injuries of, 29
 - „ lacerations of, 30
 - „ pemphigus of, 25
 - „ warts of, 29
- Consecutive or secondary glaucoma, 124
- Convergent strabismus, 276
- Coredialysis, 104

- Cornea, diseases of, 31
 - „ abrasions of, 75
 - „ calcareous film of, 54
 - „ conical, 56
 - „ fistula of, 50
 - „ nebula of, 51
 - „ leucoma of, 52
 - „ opacity of, from lead, 53
 - „ staphyloma of, 61
 - „ „ partial, 61
 - „ „ complete, 63
 - „ ulcers of, 43
 - „ „ chronic vascular, 49
 - „ „ superficial, 44
 - „ „ „ nebulous, 44
 - „ „ „ transparent, 45
 - „ „ deep, 45
 - „ „ „ crescentic or chiselled, 47
 - „ „ „ sloughing, 46
 - „ injuries of, 72
 - „ abscess of, 37
 - „ foreign bodies on, 72
 - „ paracentesis of, 38
 - „ penetrating wounds of, 76
 - „ tattooing the, 53
- Corneitis, 31
 - „ chronic interstitial, 32
 - „ diffuse suppurative, 36
 - „ general treatment of, 34
 - „ marginal, 39
 - „ strumous, 34
- Corneo-iritis, 43
- Cortical cataract, 139
- Couper, Mr., on astigmatism, 268
- Critchett's canaliculus director, 322
 - „ operation for iridodesis, 103
 - „ „ divergent strabismus, 283
 - „ spoon for traction operation, 150
- Crossed diplopia, 288
- Cup, atrophic, 219
 - „ glaucomatous, 120
 - „ physiological, 121
- Curette, 143
- Cuticular conjunctiva, 24
- Cyclitis, 66
- Cysticercus on iris, 93
- Cystoid cicatrix, 160
- Cystotome, Graefe's, 148
- Cysts of conjunctiva, 29

- Cysts of iris, 92
- „ lachrymal gland, 325
- „ retina, 193
- „ eyelid, 356
- „ sebaceous, 358

DACRYO-ADENITIS, 324

Dacryo-cystitis, 319

Dacryops, 325

„ fistulosus, 325

Daturine, sulphate of, 95

Deposits of bone on choroid, 199

Dermoid tumours of cornea, 28

„ cysts, 358

Descending optic neuritis, 211

Detachment of retina, 188

Diabetic cataract, 137, 162

Dichromic vision, 231

Dieffenbach's operation for ectropion, 344

Diffuse suppurative corneitis, 36

Diplopia, 288

„ crossed, 288

„ homonymous, 288

Diphtheritic ophthalmia, 13

Direct examination with ophthalmoscope, 242

Diseases of accommodation, 247

„ choroid, 194

„ conjunctiva, 1

„ cornea and sclerotic, 31

„ crystalline lens, 137

„ eyelids, 329

„ frontal sinus, 407

„ iris, 82

„ lachrymal apparatus, 315

„ optic nerve, 211

„ orbit, 372

„ retina, 177

„ vitreous, 131

Dislocation of lens into anterior chamber, 170

„ „ vitreous, 172

„ „ beneath conjunctiva, 174

„ „ partial, 175

Disseminated choroiditis, 194

Distension of frontal sinus, 407

Distichiasis, 331

Divergent strabismus, 277

Dixon, Mr., on granular lids, 19

Duboisine, sulphate of, 96

- ECCHYMOSIS** of conjunctiva, 29
 „ eyelids, 360
- Ectropion**, 340
 „ from purulent ophthalmia, 6
 „ treatment of, 341-348
- Eczema** of eyelids, 331
- Embolism** of central artery of retina, 192
- Entropion**, 336
 „ chronic, 337
 „ spasmodic, 336
 „ treatment, 337-340
 „ Burow's operation for, 338
- Epicanthus**, 360
- Epiphora**, 315
 „ causes of, 315
 „ from obstruction by tumours, 321
- Episcleritis**, 71
- Epithelioma** of eyelid, 354
- Eserine**, sulphate of, 99
- Excision** of eye, 311
- Exophthalmic** goitre, 392
- Exophthalmos**, 372
- Extraction** of cataract. *See* Cataract, Treatment of
- Exudative choroiditis**, 194
- Eye**, excision of, 311
 „ rupture of, through sclerotic, 78
- Eyelashes**, operation for the removal of, 332
- Eyelids**, diseases of, 329
 „ abscess of, 361
 „ blepharospasm, 351
 „ distichiasis, 331
 „ ecchymosis of, 360
 „ ectropion, 340
 „ „ operations for relief of, 341-348
 „ eczema of, 331
 „ entropion, 336
 „ „ operations for relief of, 337-340
 „ epicanthus, 360
 „ epithelioma of, 354
 „ hordeolus, 330
 „ nictitation, 353
 „ paralysis of orbicularis, 350
 „ ptosis, 348
 „ rodent cancer of, 354
 „ syphilitic ulcers of, 353
 „ tinea tarsi, 329
 „ trichiasis, 331
 „ tumours of, 356
 „ nævus of, 357

Eyelids, tarsal cysts of, 356

„ wounds of, 362

„ xanthelasma palpebrarum, 359

FIBRO-FATTY tumours of conjunctiva, 28

Field of vision, to ascertain the, 235

„ „ map out the, without a perimeter, 236

Fine needle, 141

Fistula of cornea, 50

„ lachrymal gland, 325

„ „ sac, 320

Flap extraction of cataract, 147

„ „ accidents during, 149

Fluid cataract, 162

Fluidity of vitreous, 134

Focal illumination of eye, 243

Forceps, canular, 169

„ cilia, 332

„ iris, 100

„ Snellen's eyelid, 333

Foreign bodies on conjunctiva, 72

„ cornea, 72

„ in orbit, 376

„ in vitreous, 135

„ within the eye, 302

Formulary, 415

Fourth nerve, paralysis of, 296

„ anatomy of, 296

Fractures of orbit, 375

Frontal sinus, distension of, 407

„ „ causes of, 408

„ „ symptoms of, 411

„ „ treatment of, 412

„ sinuses, anatomy of, 407

GLAUCOMA, 118

„ acute inflammatory, 119

„ chronic or simple, 122

„ consecutive or secondary, 124

„ intermittent, 123

„ occasional complications of, 125

„ pathology of, 126

„ premonitory symptoms of, 119

„ traumatic, 125, 164

Glaucomatous cup, characteristics of, 120

Glioma of the retina, 206

Globe, to ascertain tension of, 129

„ involuntary oscillations of, 300

„ protrusion of, 372

Goitre, exophthalmic, 392

- Gonorrhœal ophthalmia, 8
 Gouty iritis, 88
 Graefe's operation for strabismus, 280
 „ knife for cataract, 151
 „ modified linear extraction operation, 151
 Granular lids, 15
 „ ophthalmia, acute, 17
 Granulations, trachomatous, 15
 „ follicular, 22
 „ papilliform, 22
 Graves's disease, 392
 Gunpowder, injuries from, 309

- H**ARD cataract, 138, 145
 „ Hæmorrhage into anterior chamber, 103
 „ between choroid and retina, 203
 „ „ „ sclerotic, 204
 „ into the vitreous, 136, 204
 Hemiopia, 223
 Herpes zoster frontalis, 369
 Homatropine, hydrobromate of, 95
 Homonymous diplopia, 288
 Hooks for strabismus, 279, 280
 Hook, Tyrrell's, 102
 Hordeolus, 330
 Horn spatula for excision of eyelashes, 334
 Hyalitis, 131
 „ simple, 131
 „ suppurative, 132
 Hydrophthalmia, 60
 Hyperæmia of retina, 177
 Hypermetropia, 255
 „ absolute, 256
 „ acquired, 255
 „ facultative, 256
 „ latent, 256
 „ manifest, 256
 „ ophthalmoscopic appearances in, 258
 „ original, 256
 „ peculiarities of eye in, 258
 „ results of, 259
 „ relative, 256
 „ to ascertain the degree of, 257
 „ treatment of, 257
 Hypopion, 37

- I**NDIRECT examination with ophthalmoscope, 241
 „ Infantile cataract, 138, 140
 Inflammation of choroid, 194

- Inflammation of ciliary body, 66
 - „ cornea, 31
 - „ iris, 82
 - „ lachrymal gland, 324
 - „ „ „ sac, acute, 319
 - „ „ „ „ chronic, 316
 - „ optic nerve, 211
 - „ retina, 178
 - „ vitreous, 131
- Injuries of eyelids, 360
 - „ eye from burns and scalds, 306
 - „ „ gunpowder, 309
 - „ „ lime, 304
 - „ „ mortar and plaster, 305
 - „ „ percussion caps, 309
 - „ „ small shot, 310
 - „ „ strong sulphuric and nitric acids, 307
 - „ „ vinegar or weak acids, 308
 - „ choroid, 203
 - „ conjunctiva, 29
 - „ cornea and sclerotic, 72
 - „ iris, 103
 - „ lens, 163, 170
 - „ optic nerve, 238
- Inoculation for cure of granular lids, 20
- Intermittent glaucoma, 123
- Interstitial corneitis, 32
- Intra-ocular tumours, 205
- Involuntary oscillations of globe, 300
- Iridectomy, operation of, 99
 - „ „ knife, 99
- Irido-choroiditis, 107
- Iridodesis, 103
- Iridodonesis, 130
- Iris forceps, 100
 - „ diseases of, 82
 - „ coloboma of, 131
 - „ cysticercus on, 93
 - „ cysts of, 92
 - „ functional derangements of,
 - „ injuries to, 103
 - „ melanotic sarcoma of, 93
 - „ operations on, 99
 - „ prolapse of, 105
 - „ tremulous, 130
- Iritis, 82
 - „ general symptoms of, 83
 - „ gouty, 88
 - „ primary, 82

- Iritis, rheumatic, 86
 „ secondary, 83
 „ serous, 89
 „ suppurative, 90
 „ syphilitic, 85
 „ traumatic, 90

JEQUIRITY seeds, 21

KERATITIS, 31

- „ punctata, 89
 Kerato-globus, 60
 Keratome, 99
 Keratonyxis, 140
 Knife, cataract, for flap extraction, 147
 „ Graefe's, for cataract, 151
 „ secondary, for cataract, 148
 „ Weber's, for slitting up canaliculus, 322

LACERATIONS of conjunctiva, 30

- Lachrymal apparatus, diseases of, 315
 „ gland, diseases of, 324
 „ „ chronic enlargement of, 326
 „ „ cysts of, 325
 „ „ hypertrophy of, 326
 „ „ inflammation of, 324
 „ „ fistula of, 325
 „ „ removal of, 323
 „ „ sarcoma of, 327
 „ sac, acute inflammation of, 319
 „ „ chronic inflammation of, 316
 „ „ fistula of, 320
 „ „ stricture of, 316, 317
 „ „ obliteration of, 322

Lagophthalmos, 350

Lamellar cataract, 138

Lateral illumination of eye, 243

Lens, crystalline, diseases, of, 137

- „ „ dislocation of, into anterior chamber, 170
 „ „ „ „ vitreous, 172
 „ „ „ „ beneath conjunctiva, 174
 „ „ partial dislocations of, 175

Lenses, metrical system of numbering, 271

Leucoma of cornea, 52

Levator-palpebræ, paralysis of, 348

Liebreich's operation for strabismus, 281

„ „ cataract, 154

Lime, injuries from, 304

Linear extraction of cataract, 141
 Lippitudo, 329
 Lodgment of foreign bodies in the eye, 302

MACNAMARA'S operation for cataract, 155
 Marginal corneitis, 39
 Meibomian cysts, 356
 Melanotic sarcoma of choroid, 209
 „ „ iris, 93
 Metrical system of numbering glasses, 271
 Miners' nystagmus, 300
 Modified linear extraction, 151
 Moorfields' operation for strabismus, 279
 Mortar, injuries from, 305
 Mucocele, 316
 Muscæ volitantes, 132
 Mydriasis, 93
 Mydriatics, 94
 Myotics, 98
 Myopia, 249
 „ complications of, 254
 „ general directions for, 255
 „ „ rules for selection of glasses in, 253
 „ ophthalmoscopic appearances in, 250
 „ treatment of, 251
 Myosis, 96

NÆVUS of eyelid, 357
 „ venous, of orbit, 390
 Necrosis of orbit, 382
 Nebula of cornea, 51
 Needle, broad, 143
 „ fine, 141
 „ operation for capsular opacities, 167
 Nephritic retinitis, 180
 Neuritis, pathology of, 214
 Neuro-retinitis, 216
 Nictitation, 353
 Night-blindness, 229
 Nuclear cataract, 145
 Nyctalopia, 229
 Nystagmus, 300
 „ miners', 300
 „ voluntary, 301

OBLITERATION of lachrymal sac, 322
 Onyx, 37
 „ Samesch's operation for, 39

- Opacity of cornea from lead, 53
- Opacities of capsule of lens, 166
 - „ vitreous, 133
- Opaque optic nerve fibres, 239
- Operations. *See* Separate Headings
- Ophthalmia, catarrhal, 1
 - „ chronic, 3
 - „ diphtheritic, 13
 - „ gonorrhœal, 8
 - „ granular, 15
 - „ neonatorum, 4
 - „ phlyctenular, 40
 - „ purulent, 7
 - „ „ of newly born infants, 4
 - „ „ contagious, 7
 - „ scrofulous, 40
 - „ sympathetic, 110, 111
- Ophthalmitis, 197
- Ophthalmoscope, the, 240
 - „ fixed, 240
 - „ how to work with the, 240
 - „ direct examination with, 242
 - „ indirect examination with, 241
- Optic nerve, diseases of, 211
 - „ atrophy of, 218
 - „ „ from tobacco, 221
 - „ fibres, opaque, 239
 - „ injuries of, 238
 - „ senile atrophy of, 219
 - „ tumours of, 237
- Optic neuritis, ascending, 216
 - „ descending, 211
- Orbicularis, paralysis of, 350
- Orbit, abscess of, 372
 - „ acute inflammatory exudation into, 406
 - „ aneurisms of, 383
 - „ caries of, 382
 - „ congenital tumours of, 400
 - „ foreign bodies in, 376
 - „ fractures of the bones of, 375
 - „ nævus, venous, of, 390
 - „ necrosis of, 382
 - „ penetrating wounds of, 380
 - „ periostitis of, 380
 - „ tumours of, 395
 - „ „ 1. Those which originate within orbit, 395
 - „ „ 2. Those which commence within eye, 399
 - „ „ 3. Those which originate beyond eye or orbit, 399
 - „ „ bony and cartilaginous, 397

- Orbit, cysts of, 396
- „ fibrous tumours of, 397
- „ recurrent fibroid tumours of, 398
- Orbital tumours, treatment of, 401
- Oscillations, involuntary, of globe, 300

PAGENSTECHER'S operation for cataract, 155

Panophthalmitis, 197

Papillitis, 211

Paracentesis of cornea, 38

Paralysis of ciliary muscle, 286

- „ all the ocular muscles, 298
- „ fourth nerve, 296
- „ sixth nerve, 297
- „ third nerve, 294
- „ portio dura of seventh nerve, 350
- „ external rectus, 297
- „ inferior rectus, 296
- „ internal rectus, 296
- „ superior rectus, 296
- „ „ oblique, 296
- „ levator palpebræ, 348
- „ orbicularis, 350

Paralytic affections of muscles of eye, 291

- „ „ „ from intra-cranial disease, 292
- „ „ „ „ intra-orbital disease, 292
- „ „ „ „ blood-poisoning, 293
- „ „ „ „ reflex irritation, 293
- „ „ „ treatment of, 298
- „ „ „ the eyelids, 348

Pathology of conical cornea, 57

- „ glaucoma, 126
- „ neuritis, 214

Pemphigus conjunctivæ, 25

Penetrating wounds of cornea and sclerotic, 76

- „ „ orbit, 380

Percussion caps, injuries from, 309

Perimetry, 235

Periodic strabismus, 274

Periostitis of orbit, 380

- „ „ acute, 382
- „ „ chronic, 380

Peritomy, 23

Physiological cup of optic nerve, 121

Phlyctenular ophthalmia, 40

Pilocarpine, nitrate of, 99

Pinguecula, 28

Plaster, injuries from, 305

Posterior staphyloma of sclerotic, 197, 249

- Presbyopia, 259
 " treatment of, 260
 Pricker for cataract operations, 148
 Primary iritis, 82
 Prisms, action and uses of, 288
 " to ascertain the presence of binocular vision, 289
 " to test the strength of the muscles of the eye, 289
 " to wear as spectacles to correct diplopia, 291
 Prolapse of iris, 105
 Proptosis, 372
 Pterygium, 26
 Ptosis, 348
 Pulsating exophthalmos, 387
 Pupil, artificial, 101
 Purulent ophthalmia of newly born infants, 4
 Purulent or contagious ophthalmia, 7
 Pyramidal cataract, 161

REFRACTION, anomalies of, 247

- Repositio ciliorum, 334
 Retina, diseases of, 177
 " cysts of, 193
 " detachment of, 188
 " embolism of central artery of, 192
 " glioma of, 206
 " hyperæmia of, 177
 " tumours of, 206
 Retinitis, 178
 " albuminurica, 180
 " " in pregnancy, 181
 " apoplectica, 184
 " pigmentosa, 187
 " syphilitica, 182
 Retinal apoplexy, 184
 Retinoscopy, 243
 Rheumatic iritis, 86
 Rodent cancer of eyelid, 354
 Rupture of eye through sclerotic, 78

SÄMESCH'S operation for ulcer of cornea, 39

- Sarcoma of cornea and sclerotic, 81
 " choroid, 207
 " " originating in lost eyes, 210
 " lachrymal gland, 327
 Scissors for making artificial pupil, 103
 Sclerotico-choroiditis, posterior, 197, 249
 Sclerotic, diseases of, 31
 " anterior staphyloma of, 65
 " posterior staphyloma of, 197, 249
 " penetrating wounds of, 76

- Sclerotic, rupture of, 78
 Sclerotomy, 128
 Scotomata, 223, 235
 Scrofulous ophthalmia, 40
 Sebaceous cysts, 358
 Secondary cataract, 165
 " " knife, 148
 " glaucoma, 124
 " iritis, 83
 Senile atrophy of optic nerve, 219
 " cataract, 137, 146
 Serous iritis, 89
 Seton, in vascular ulcer of cornea, 49
 Shield for protecting eye in purulent ophthalmia, 9
 Short sight. See Myopia.
 Sichel's knife, 147
 Silver style, 318
 Simple glaucoma, 122
 Sixth nerve, paralysis of, 297
 " anatomy of, 297
 Small shot, injuries from, 310
 Snellen on astigmatism, 264
 " eyelid forceps, 333
 Snow-blindness, 231
 Soft cataract, 138
 " operations for, 140-144
 " solution operation for, 140
 " suction operation for, 144
 Sparkling synchysis, 134
 Spasm of ciliary muscle, 287
 Speculum, spring-stop, 101
 Spoons for traction operation for cataract, 150
 Spud for removal of foreign bodies, 73
 Squint. See Strabismus.
 Staphyloma, anterior, of sclerotic, 65
 " posterior, of sclerotic, 197, 249
 " ciliary, 65
 " of cornea, 61
 " " operations for, 64
 Strabismus, 274
 " alternating or binocular, 274
 " causes of, 275
 " concomitant, 276
 " convergent or internal, 276
 " Critchett's operation for divergent, 283
 " Tweedy's " 284
 " divergent or external, 277
 " " following division of internal recti, 282
 " " following paralysis of opponent muscle, 283
 " Graefe's operation for, 280

- Strabismus, hooks used in operation for, 279, 280
 „ monocular, 274
 „ Liebreich's operation for, 281
 „ Moorfields' operation for, 279
 „ paralytic, 291
 „ periodic, 274
 „ primary deviation in, 275
 „ secondary deviation in, 276
 „ to note the extent of the, 275
 „ treatment of, 278
 Streatfeild's operation for entropion, 339
 Striated cataract, 145
 Stricture of nasal duct, 317
 Strong acids, injuries from, 307
 Strumous corneitis, 34
 Suction operation for cataract, 144
 Suppurative corneitis, 36
 „ choroiditis, 197
 „ iritis, 90
 Symblepharon, 365
 Sympathetic irritation, 110
 „ ophthalmia, 110, 111
 Synchysis, 134
 „ scintillans, 134
 Syndectomy, 23
 Syphilitic iritis, 85
 „ ulcers of eyelid, 353
 Syringe for soft cataract, 145

TARSAL cysts, 356

- Tattooing the cornea, 53
 Taylor's spoon for cataract operation, 150
 „ operation for symblepharon, 368
 Teale's, Mr. T. P., operation for symblepharon, 367
 „ „ suction operation, 144
 Tension of globe, to ascertain, 129
 Test-types, 431
 Third nerve, paralysis of, 294
 „ „ anatomy of, 294
 Tinea tarsi, 329
 Tobacco amaurosis, 221
 Trachoma, 15
 Traction operation for cataract, 149
 Traumatic cataract, 163
 „ treatment of, 164
 Traumatic iritis, 90
 Tremulous iris, 130
 Trephining cornea, operation of, 60
 Trichiasis, 331

- Tubercles in choroid, 202
 Tumours of choroid, 207
 „ conjunctiva, 28
 „ cornea and sclerotic, dermoid, 28
 „ eyelids, 356
 „ frontal sinus, 407
 „ iris, 93
 „ optic nerve, 237
 „ orbit, 395
 „ retina, 206
 „ sebaceous or dermoid, near orbit, 358
 Tweedy's optometer for astigmatism, 265
 „ operation for divergent squint, 284
 Tyrrell's hook, 102

- ULCERS of eyelid, 353
 „ „ epithelial, 354
 „ „ rodent, 354
 „ „ syphilitic, 353
 „ cornea, 43
 „ „ chronic vascular, 49
 „ „ superficial, 44
 „ „ „ nebulous, 44
 „ „ „ transparent, 45
 „ „ deep, 45
 „ „ „ crescentic or chiselled, 47
 „ „ „ sloughing, 46

- VENOUS nævus of orbit, 390
 Vinegar, injuries from, 308
 Vitreous humour, diseases of, 131
 „ „ dislocation of lens into, 172
 „ „ fluidity of, 134
 „ „ foreign bodies in, 135
 „ „ hæmorrhage into, 136, 204
 „ „ inflammation of, 131
 „ „ opacities of, 132-133
 Voluntary nystagmus, 301

- WARTS on conjunctiva, 29
 Weak acids, injuries from, 308
 Weber's canaliculus knife, 322
 White atrophy of optic nerve, 218
 Wounds of eyelids, 362
 „ cornea and sclerotic, 76
 XANTHELASMA palpebrarum, 359
 Xerophthalmia, 24
 Xerosis, 24





