

Researches into the anatomy and pathology of the eye / by E. Treacher Collins.

Contributors

Collins, E. Treacher 1862-1932.

Publication/Creation

London : H.K. Lewis, 1896.

Persistent URL

<https://wellcomecollection.org/works/mjgzjur2>


License and attribution

This work has been identified as being free of known restrictions under copyright law, including all related and neighbouring rights and is being made available under the Creative Commons, Public Domain Mark.

You can copy, modify, distribute and perform the work, even for commercial purposes, without asking permission.





Wellcome Collection
183 Euston Road
London NW1 2BE UK
T +44 (0)20 7611 8722
E library@wellcomecollection.org
<https://wellcomecollection.org>







22101011329









RESEARCHES
INTO THE
ANATOMY AND PATHOLOGY OF THE EYE

Edward

87508

RESEARCHES
INTO THE
ANATOMY AND PATHOLOGY
OF THE
EYE

BY

E. TREACHER COLLINS, F.R.C.S.

ASSISTANT SURGEON TO THE ROYAL LONDON OPHTHALMIC HOSPITAL, MOORFIELDS
HUNTERIAN PROFESSOR, ROYAL COLLEGE OF SURGEONS, ENGLAND, 1893-94

WITH 10 PLATES AND 28 FIGURES IN THE TEXT


LONDON
H. K. LEWIS, 136 GOWER STREET,
1896

PRINTED BY
H. K. LEWIS, 136 GOWER STREET,
LONDON, W.C.

M20507

WELLCOME INSTITUTE LIBRARY	
Coll.	wel10mee
Call	
No.	WW100
	1896
	C711

I DEDICATE THIS BOOK
TO
GEORGE LAWSON, F.R.C.S.
SURGEON OCULIST TO HER MAJESTY THE QUEEN
IN
ADMIRATION OF HIS CHARACTER
AND AS A MARK OF
GRATITUDE FOR HIS UNFAILING KINDNESS TO ME
THROUGHOUT MY MEDICAL CAREER



PREFACE.

DURING the six years I held the post of Curator of the Museum at the Royal London Ophthalmic Hospital, I contributed several articles containing new facts and opinions on the Anatomy and Pathology of the Eye to the ophthalmological publications of this country.

At the Royal College of Surgeons in 1894, I gave in three lectures a summary of my researches.

This book is composed of those lectures, together with a few additions which the time at my disposal did not permit of my including in them.

These additions are the last part of Chapter II., the first half of Chapter IV., and the whole of Chapter VIII.


I have not attempted to treat of the subjects dealt with in a systematic way, but have written on those points only on which I felt I had something new, that was worth saying, to fellow workers in my profession.

I am greatly indebted to the Ophthalmological Society and to the Staff of the Moorfields Hospital for permission to reproduce several illustrations, which had already appeared in articles of mine in their publications, and which help considerably to elucidate the subjects discussed.

E. TREACHER COLLINS.

84 WIMPOLE STREET, W.

February, 1896.



CONTENTS.

CHAPTER I.

THE DEVELOPMENT OF THE SUSPENSORY LIGAMENT OF THE LENS. MODE OF FORMATION OF THE CONDITIONS TERMED *Coloboma Lentis* AND *Ectopia Lentis*. CHANGES IN THE SHAPE OF THE LENS IN DEVELOPMENT AND DISEASE. HOW CELLS COME TO LINE THE POSTERIOR CAPSULE IN CATARACTOUS LENSES. THE DEVELOPMENT OF THE LENS CAPSULE. ANTERIOR POLAR CATARACT, ITS MINUTE ANATOMY AND MODE OF FORMATION pages 1-24

CHAPTER II.

ZONULAR CATARACT, ITS HISTOLOGICAL APPEARANCES, MODE OF FORMATION, AND CONNEXION WITH RICKETS. CONGENITAL CATARACTS. CONGENITAL FORMATION OF FIBROUS TISSUE IN THE VITREOUS. THE DEVELOPMENT OF THE VITREOUS HUMOUR. MUSCÆ VOLITANTES pages 25-48

CHAPTER III.

METHOD OF BLEACHING SECTIONS OF THE EYE. ARRANGEMENT OF PIGMENT EPITHELIUM ON THE POSTERIOR SURFACE OF THE IRIS. CYSTS OF THE IRIS DUE TO SEPARATION OF ITS TWO PIGMENT EPITHELIAL LAYERS. ECTROPION OF THE UVEAL PIGMENT OF THE IRIS. ARRANGEMENT OF THE PIGMENT EPITHELIUM OF THE CILIARY BODY IN MEN AND ANIMALS. EXPERIMENTAL EVIDENCE ON THE SOURCE OF THE AQUEOUS HUMOUR AND NUTRIENT FLUID OF THE VITREOUS. CATARRHAL, SUPPURATIVE, AND PLASTIC INFLAMMATION OF THE SECRETING AREA OF THE CILIARY BODY. CYSTS OF THE GLANDS OF THE CILIARY BODY. ADENOMA AND CARCINOMA OF THE CILIARY BODY pages 49-71

CHAPTER IV.

IMPLANTATION OF EYELASHES INTO THE EYE. IMPLANTATION EPITHELIAL CYSTS OF THE EYE. ENDOTHELIAL CYSTS OF THE IRIS. GLIOMA OF THE RETINA NOT SARCOMA. DEVELOPMENT OF THE CHOROID AND ORIGIN OF THE MEMBRANE OF BRUCH. EXTRAPAPILLARY COLOBOMATA pages 72-91

CHAPTER V.

CASES OF GLAUCOMA IN WHICH THE INCREASE OF TENSION IS DIFFICULT TO EXPLAIN. THE DEVELOPMENT OF THE IRIS. GLAUCOMA AND CONGENITAL ABSENCE OF THE IRIS. CONGENITAL ANTERIOR SYNECHIE OF THE PUPILLARY MEMBRANE AND IRIS. CONGENITAL GLAUCOMA OR BUPHTHALMOS pages 92-106

CHAPTER VI.

GLAUCOMA AFTER EXTRACTION OF CATARACT. GLAUCOMA IN CASES OF TRAUMATIC ANIRIDIA. THE *Modus Operandi* OF IRIDECTOMY IN THE RELIEF OF TENSION IN PRIMARY GLAUCOMA. THE MODE OF FORMATION OF A CYSTOID CICATRIX. THE CAUSES OF FAILURE OF IRIDECTOMY IN THE RELIEF OF TENSION pages 107-121

CHAPTER VII.

THE IMMEDIATE EFFECTS OF CONCUSSION OF THE EYE. CHANGES FOUND IN EYES INJURED BY CONCUSSION. DEPRESSION BACKWARDS OF THE PERIPHERY OF THE IRIS. IRIDODIALYSIS. RUPTURE OF THE PILLARS OF THE IRIS AND SPLITTING OF THE CILIARY MUSCLE. RUPTURE OF THE WHOLE LIGAMENTUM PECTINATUM AND RETRACTION OF A PORTION OF THE IRIS. RUPTURE OF THE SUSPENSORY LIGAMENT. DISLOCATION OF THE LENS INTO THE ANTERIOR CHAMBER. CONCUSSION CATARACT. BLOOD STAINING OF THE CORNEA pages 122-133

LIST OF AUTHORS QUOTED page 135

INDEX page 137

LIST OF ILLUSTRATIONS.

PLATE I.

- Fig. a.*—Bleached section of the ciliary body of a normal eye, showing glands.
,, *b.*—Glands of the ciliary body; bleached section. [Facing page 56.]

PLATE II.

- Fig. a.*—Overgrowth of the glands of the ciliary body in a cyclitic membrane.
,, *b.*—Bleached section of a melanotic carcinoma originating in the glands of the ciliary body. [Facing page 64.]

PLATE III.

- Fig. a.*—Implantation epithelial cyst of the iris.
,, *b.*—Lining membrane of the cyst. [Facing page 74.]

PLATE IV.

- Fig. a.*—Shrunken eyeball with implantation cyst.
,, *b.*—Lining epithelium of cyst.
,, *c.*—Congenitally ill-developed iris.
,, *d.*—Coloboma of the iris. [Facing page 96.]

PLATE V.

- Fig. a.*—Congenital aniridia and glaucoma.
,, *b.*—Glaucoma after extraction of cataract.
,, *c.*—Traumatic aniridia and glaucoma. [Facing page 108.]

PLATE VI.

Figs. a, b, c.—Sections of eyes in which iridectomy was successful in relieving tension in glaucoma.

[Facing page 112.]

PLATE VII.

Figs. a, b, c.—Sections of eyes illustrating the formation of a cystoid cicatrix.

[Facing page 116.]

PLATE VIII.

Figs. a, b, c.—Sections of eyes in which iridectomy was unsuccessful in glaucoma

[Facing page 118.]

PLATE IX.

Figs. a, b, c, d, e.—Sections from a series of eyes injured by concussion.

[Facing page 124.]

PLATE X.

Section of an eye with concussion cataract.

[Facing page 128.]

WOODCUTS IN TEXT.

FIG.	PAGE
1. Diagrammatic section of an eye with a persistent and patent central hyaloid artery and an ill-developed lens	2
2. Section of eye represented diagrammatically in figure 1, showing developing fibres of the suspensory ligament	3
3. Section of eye represented diagrammatically in figure 1, showing developing fibres of the suspensory ligament more advanced than in figure 2	4
4. Anterior polar cataract of less than six weeks' formation	14
5. Anterior polar cataract of seven months' formation	15
6. Anterior polar cataract of eleven years' formation	16
7. Anterior polar cataract of 21 years' formation	17
8. Microscopical appearances of lens with a congenital defect at its posterior pole	39
9. Semi-diagrammatic section of a microphthalmic eye with a band of fibrous tissue in the vitreous	42
10. Branching fibres with small round bodies on them seen in the foetal vitreous	45
11. Transverse section of the central artery of the vitreous from a foetus of between the fifth and sixth month	46
12. Transverse section of the same artery, shown in figure 11, further forwards in the vitreous, after it has lost its cellular sheath	46
13. An eyeball with persistence of the sheath of the central hyaloid artery	48
14. Small cyst situated between the two layers of pigment epithelium on the back of the iris	52
15. Anterior half of an eye, with a cyst situated between the two layers of pigment epithelium on the back of the iris	52
16. Cyst of the iris, with uveal pigment on its anterior surface	53
17. Section of a horse's iris	55
18. Epithelial implantation cyst forming in the anterior chamber after extraction of cataract	76

	PAGE
19. Lining epithelium of the cyst shown in figure 18	77
20. Epithelial implantation cysts of the cornea following a perforating wound with a shot	78
21. Epithelial implantation cyst of the cornea, in a shrunken eye, after extraction of cataract	79
22. Section of eyeball shewing epithelial implantation cyst of the cornea following a wound with a piece of wood	80
23. Laminated epithelium lining cyst shown in figure 22	80
24. Microscopical appearances of glioma of the retina	85
25. Microscopical appearances of the retina from a human fœtus be- tween the third and fourth month	85
26. The anterior half of an eye with apparent aniridia, from which the sclerotic and cornea have been removed	95
27. Congenital anterior synechia of a persistent pupillary membrane and of the iris	102
28. Eye from which the lens had been extracted, in which a mem- brane had been subsequently needled, and in which the tension had become increased	109

RESEARCHES INTO THE ANATOMY AND PATHOLOGY OF THE EYE.

CHAPTER I.

THE DEVELOPMENT OF THE SUSPENSORY LIGAMENT OF THE LENS.
MODE OF FORMATION OF THE CONDITIONS TERMED *Coloboma Lentis*
AND *Ectopia Lentis*. CHANGES IN THE SHAPE OF THE LENS IN
DEVELOPMENT AND DISEASE. HOW CELLS COME TO LINE THE POS-
TERIOR CAPSULE IN CATARACTOUS LENSES. THE DEVELOPMENT OF
THE LENS CAPSULE. ANTERIOR POLAR CATARACT, ITS MINUTE
ANATOMY AND MODE OF FORMATION.

THE DEVELOPMENT OF THE SUSPENSORY LIGAMENT OF THE LENS.

IN studying the pathology of the eye I soon became aware how largely a knowledge of the embryology of that organ helped to interpret the changes met with. Not only does embryology help to elucidate morbid processes, but I think I shall be able to show that very valuable suggestions as to doubtful points in the development of tissues may be obtained from the changes which occur in disease. The way in which these two subjects, embryology and pathology, mutually help to explain one another is the keynote of much that is to follow.

Taking first the suspensory ligament of the lens, which was at one time supposed to consist of two layers of membrane, but which is now known to consist of bundles of fibres, its mode of development has been left by em-

bryologists but very imperfectly explained. According to Kölliker, it is formed in man during the fourth month. Lieberkühn remarks that the zonule is distinctly recognisable in eyes which have attained half their definite size. Angelucci and Löwe believe that the suspensory ligament is derived from the anterior part of the vitreous. My attention was first directed to the matter by the examination of an eye of which I published a full description in the Royal London Ophthalmic Hospital Reports.* It

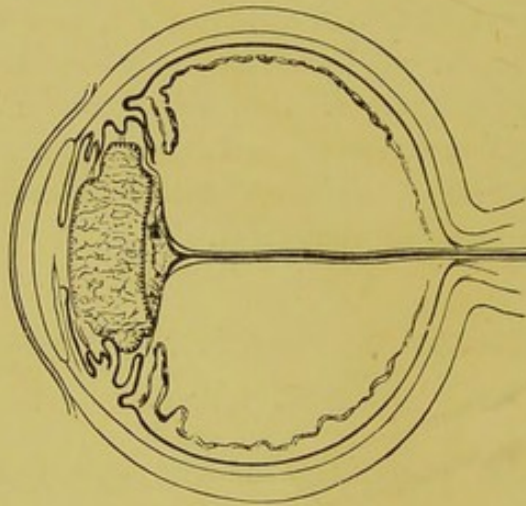


FIG. 1.—Diagrammatic section of an eye with a persistent and patent central hyaloid artery and an ill-developed lens.

had been enucleated from an infant aged three months, under the supposition that it contained a new growth. Pathological examination revealed that the opaque mass behind the lens, which had been taken for the growth, was really a collection of cells and fibres, into which a persistent hyaloid artery, still patent and carrying blood, passed and broke up (fig. 1). The chief interest of the specimen, however, centred in the fact that it exhibited the fibres of the suspensory ligament in all stages of their de-

* Vol. xiii., part 1.

velopment. The fibres of the lens, instead of developing in the normal way, filling and rendering tense the capsule in which they are contained, had undergone retrogressive changes, and had left the capsule lax and wrinkled. Whether this was the result of the persistence of the hyaloid artery, or whether it had persisted as a result of changes in the lens, I am unable to determine. Anyhow,

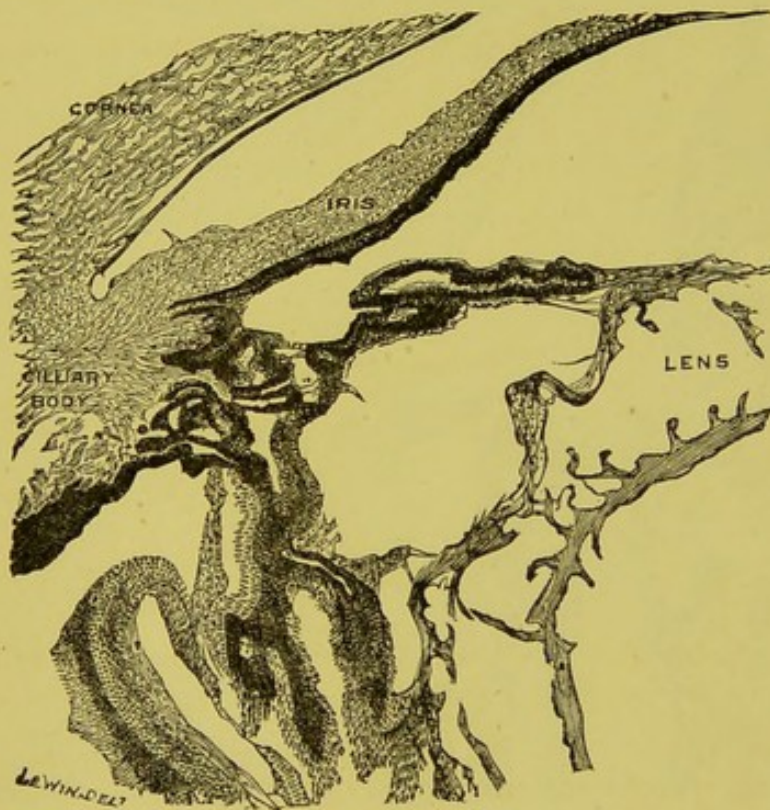


FIG. 2.—Section of eye represented diagrammatically in fig. 1. The developing fibres of the suspensory ligament are shown stretching between the ciliary processes and the lens capsule.

as the result of the lax condition of the capsule, the fibres of the suspensory ligament do not appear to have become stretched to their usual extent, and hence exhibited all stages of delayed development. The ciliary processes were in places nearly in contact with the sides of the lens; adhesions stretched between them composed of

spindle-shaped cells (fig. 2), and in other parts of fibres like those of the suspensory ligament with nuclei lying on them (fig. 3). These fibres, as they approached their insertion into the ciliary processes, became thicker, and some of them were there composed of several layers of elongated cells, which gradually merged into the unpigmented cells covering the ciliary processes.

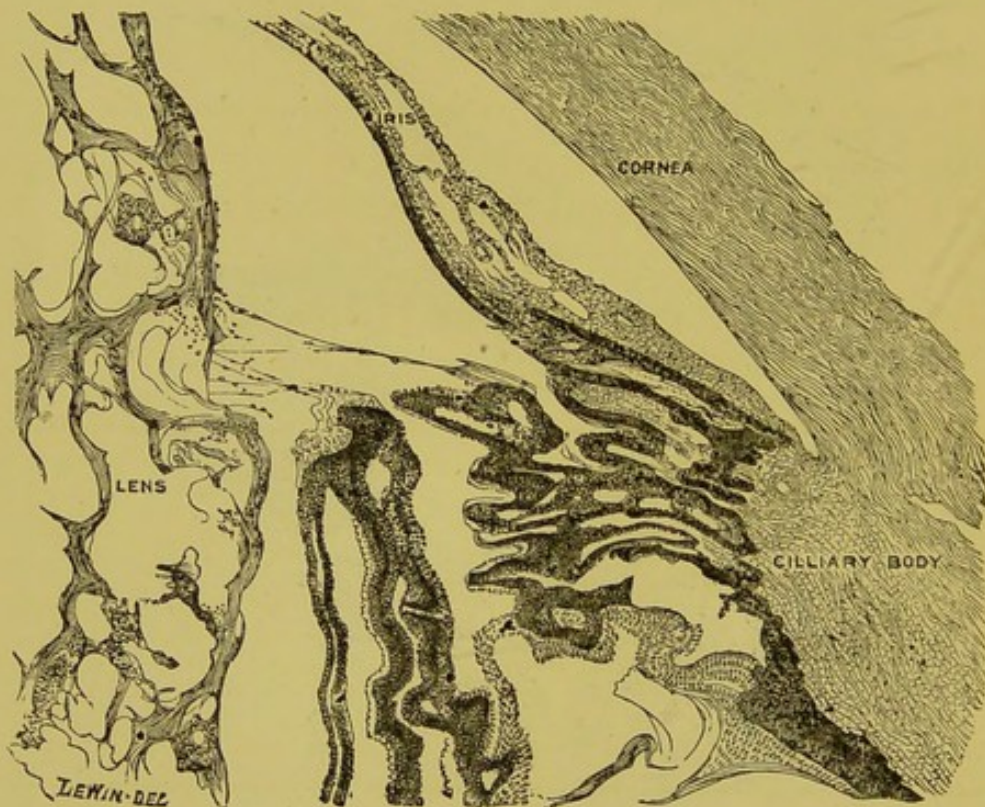


FIG. 3.—Section of eye represented diagrammatically in fig. 1. The fibres of the suspensory ligament are shown in a more advanced stage of development than in fig. 2.

The appearances shown in these specimens suggested that the fibres of the suspensory ligament were originally cellular adhesions passing between the sides of the lens and the ciliary processes; that as the eye grew these adhesions became stretched, and lengthened out into fibres with nuclei on them; and that ultimately the nuclei

disappeared and left the suspensory ligament as we see it in the adult eye. To test the truth of this theory I measured the diameters of a series of foetal eyes and the diameters of the lenses contained in them. The result of these measurements I have embodied in Table I. There is a possible source of error in the fact that all the measurements were made after the eyes had been hardened in Müller's fluid. On account of there being necessarily some delay in my obtaining the eyes after their removal this was the only course open to me. In every case an antero-posterior vertical section was made of the eyeball and the lens measured *in situ*.

TABLE I.—*Showing the Diameters of a Series of Foetal Eyes and of their Lenses.*

AGE.	NO. OF EYES EXAMINED.	DIAMETERS OF EYEBALL.			DIAMETERS OF LENS.	
		ANTERO-POSTERIOR.	LATERAL.	VERTICAL.	ANTERO-POSTERIOR.	TRANSVERSE.
4th month	3	8·1 mm.	7·8 mm.	7·5 mm.	2·8 mm.	3·3 mm.
5th month	1	11·75 mm.	11·5 mm.	10·5 mm.	3·5 mm.	4 mm.
6th month	4	12·5 mm.	12 mm.	11·1 mm.	3·8 mm.	4·5 mm.
7th month	8	14·3 mm.	13·2 mm.	12·6 mm.	4 mm.	5 mm.
9th month	3	16·75 mm.	16 mm.	15·3 mm.	4·3 mm.	5·75 mm.
Adult . .	Merkel	24·3 mm.	23·6 mm.	23·4 mm.	3·7 mm.	9 mm.

This table shows that the diameters of the globe at the ninth month are just double what they are at the fourth month, and in the adult treble that size; that the transverse diameter of the lens is likewise double at the ninth month, and treble in the adult what it is at the fourth month. So supposing, as is the case, that the ciliary body touches the sides of the lens at the fourth month—in that the eyeball is much larger than the lens, to begin with, and both increase to double and treble their size—then, unless

the thickness of the coats of the eyeball also become double the thickness they were (which they do not), there must be a gradual growing away of the ciliary body from the sides of the lens, and stretching of any adhesions which had formed between them. I have recently examined microscopically a human foetal eye of between the third and fourth months, in which cellular adhesions passing between the ciliary processes and the fibrovascular sheath of the lens are distinctly shown. I think that there can be little doubt these are the commencing fibres of the suspensory ligament. The hindermost fibre of the suspensory ligament is inserted into the retina in the region of the ora serrata. The retina, as was long ago pointed out by von Ammon, and as I have had abundant opportunities of confirming, is in the foetal eye thrown into numerous creases; apparently the inner layer of the secondary optic vesicle grows at a greater rate than the outer. The most pronounced of these folds and the last to disappear is in the region of the ora serrata. In fact, folds of retina at this part are at one time in contact with the back of the lens, and while there are quite capable of acquiring adhesions to the fibrovascular sheath. On the growth of the globe, the enlargement of the vitreous, and the flattening out of the retina these adhesions become stretched and elongated into fibres.

COLOBOMA LENTIS.

The above description of the way in which the zonule of Zinn develops, not only throws light on some of the congenital abnormalities met with in connexion with the

lens, but also receives considerable support from its mode of explaining them. Taking first the condition known as coloboma lentis. An excellent *résumé* of the literature of which malformation, together with two new cases, has been published by Dr. Heyl,* I cannot do better than quote the passage in which he sums up: "From the preceding it may then be seen that coloboma of the lens is a condition which presents at the place of defect an edge, not rounded as in the normal condition, but either straight in the horizontal direction or incurved; that the amount of deficiency varies from a slight indentation to about one-quarter of the lens substance, the centre of the lens, its poles, and the lens substance in the immediate vicinity being uninvolved; that the lens sometimes, in addition to the defect, is imperfectly developed in all its meridians; that the deficiency is always in the inferior half, and, almost without exception, entirely so; and, finally, that coloboma of the other ocular structures frequently co-exists, but very frequently no trace of it can be found."

Now, supposing the pars ciliaris retinae failed to acquire adhesions to the lens capsule in one part of its circumference, it follows that the suspensory ligament would be absent in that position; and that as the eyeball enlarged that portion of the capsule to which no suspensory ligament was attached would not be held taut, and made to expand like the remainder. Consequently there would be a depression in the lens in that situation. The amount and shape of the deficiency would depend on the extent of the defect in the suspensory ligament. There would not, of course, be any alteration in the nucleus or poles

* "Transactions of the Fifth International Ophthalmological Congress," p. 16.

of the lens, for these are formed before the influence of the suspensory ligament comes into play. The most likely cause for the non-adhesion, and so for the defect in the suspensory ligament, would be the absence of the ciliary body or pars ciliaris retinæ—in fact, coloboma of the ciliary body. Dr. Heyl says that this condition does frequently coexist with a defect in the lens, the defect being in the situation of the foetal cleft. Mr. Marcus Gunn,* regarding the condition of coloboma lentis from the clinical side, has arrived at a similar conclusion as to its mode of formation. He says: “The notch in the lower border of the lens may be accounted for by the imperfect development of the ciliary processes and suspensory ligament, so that the soft lens is not here drawn outwards into the normal comparatively sharp curve at its equator.” The same observer† has pictured and described a case of congenitally misplaced and notched lens, in which a distinct gap in the suspensory ligament was visible corresponding to the notch. I have recently examined pathologically an eyeball in which there was a congenital coloboma in the outer margin of the lens. The ciliary processes opposite the notch in the lens, instead of being directed inwards towards the sides of the lens, as they were in the rest of the circumference of the globe, sloped backwards (Plate IV., Fig. *d*). This might be explained by the suspensory ligament being absent in this position, the ciliary processes not having been drawn forwards by it, as was the case elsewhere. Whether or not there was a gap in the suspensory ligament I was unable definitely to determine, owing to the way in which the eyeball was opened.

* “Ophthalmic Review,” vol. viii., p. 234.

† “Transactions of the Ophthalmological Society,” vol. ix., p. 166.

ECTOPIA LENTIS.

Ectopia lentis, or congenital displacement of the lens, has been attributed by Becker to irregular development of the suspensory ligament. I think the explanation I have given of the mode of formation of the latter helps us to understand how this comes about. The literature of the subject has been carefully worked up by Dr. D'Ench,* and he ends his article with the following conclusions:—"1. Ectopia of the lens is a malformation, the causes of which thus far remain unknown. 2. It always affects both eyes, generally in a symmetrical manner. 3. The direction of the displacement is almost always either upwards and inwards or upwards and outwards. 4. The lenses are generally transparent; sometimes their size is below the mean. 5. The suspensory ligament is sometimes found and sometimes it is not. 6. In about one-fourth of all cases there is myopia. 7. The position of the lenses may remain unchanged throughout life but spontaneous dislocation may also result. 8. Heredity has been proven." Supposing the adhesions, which take place between the capsule of the lens and pars ciliaris retinæ to form the fibres of the suspensory ligament, be absent over a large area, then on the expansion of the globe there would be no counteracting force on one side to hold the lens in position, and it would be drawn towards that side to which the adhesions had formed. The determining cause as to whether a coloboma of the lens is formed or an ectopia would depend on the extent of the deficiency in

* "Archives of Ophthalmology," vol. x., p. 89.

the suspensory ligament. In some cases, as would be expected, both are present. When the deficiency is very great indeed the lens would be mobile, and might become dislocated. Abnormal density or frailty of the adhesions in part of the circumference would also be likely causes of displacement of the lens, and would account for those cases in which some of the fibres of the suspensory ligament can be seen passing (in a case of displacement upwards) from the lower margin of the lens to the ciliary body. Delay in the closure of the foetal cleft, though it did not lead to permanent coloboma of the ciliary body, could yet lead to ectopia of the lens, for the eye might have expanded to such an extent that the lens would have been drawn away from the lower part of the globe before the ciliary processes had sufficiently developed to have acquired adhesions to its capsule. Mr. Nettleship, in his "Textbook on Diseases of the Eye,"* says: "Congenital dislocation of the lens is often accompanied by other defects of development, such as coloboma." It is noteworthy that the lens is almost invariably displaced upwards, either directly, or with some inclination inwards or outwards; that is to say, it is almost always displaced in the opposite direction to the foetal cleft, which we know is generally downwards, or downwards with a slight inclination inwards or outwards.

* Fifth edition, p. 181.

CHANGES IN THE SHAPE OF THE LENS IN DEVELOPMENT AND DISEASE.

The table of measurements of lenses, which I have given above, shows that the transverse diameter of the lens is at the fourth month only a little more than the antero-posterior diameter, and in the adult lens is nearly three times as much. This globular condition of the foetal lens is well known, and the alteration in its shape is due to the laying on of fresh lens fibres at the sides. The cells lining the anterior capsule proliferate and shift round it until they reach a position a little behind its equator, where they commence to lengthen out. The traction which is exerted on the sides of the lens, through the fibres of the suspensory ligament, by the growth of the ciliary processes away from it, apparently influences the position in which new lens fibres are laid on.

In two congenitally misplaced lenses which I have examined microscopically, and in which the lateral traction did not come into play; the cells lining the capsule instead of lengthening out into lens fibres at the equator, had spread round the posterior capsule for some distance, and had some of them swollen up and become large and globular.

The traction on the sides of the lens helps to produce bowing of its fibres; in the early foetal lens they are some of them quite straight and others only slightly bent. My table of measurements seems to show, though the number of eyes examined is too few to make it certain, that the antero-posterior diameter of the foetal lens is somewhat greater than that of the adult. If after birth the ciliary

area becomes abnormally enlarged, as in the condition known as bupthalmos, then the lens becomes flattened antero-posteriorly and lengthened transversely. This decrease in the antero-posterior diameter of the lens must be due to the increase in the curvature of its fibres.

HOW CELLS COME TO LINE THE POSTERIOR CAPSULE IN CATARACTOUS LENSES.

The cells which line the capsule of the lens end normally a little behind its equator, so that the posterior capsule has no cells lining it. In cataractous lenses, both senile and inflammatory, not uncommonly a row of cells is found lining the posterior as well as the anterior capsule. The explanation of this change is, I think, as follows:—The cells which line the lens capsule are epithelial cells and tend to go on proliferating throughout life, the only thing which checks this proliferation is the tension to which they become exposed. As they proliferate, they shift round the capsule until they reach the equator of the lens, where they lengthen out into lens fibres. Should anything occur in the lens to lessen the tension of its capsule, the cells will at once begin to multiply at a greater rate. In cataractous lenses the tension becomes lessened by degeneration or shrinking of the lens fibres. Should some degeneration occur in the nucleated zone, then instead of the cells lengthening into lens fibres there, they might continue to spread round the posterior capsule and line it. In several cataractous lenses which I have examined with cells lining the posterior capsule, I have found lens fibres in the nucleated zone breaking down into hyaline globules.

THE DEVELOPMENT OF THE CAPSULE OF THE LENS,
AND ANTERIOR POLAR CATARACT.

The way in which the capsule of the lens develops has not yet been definitely determined. There are two views respecting it which are thus referred to in the ninth edition of Quain's "Anatomy": "The origin of the capsule of the lens appears to be still somewhat doubtful. Lieberkühn, Arnold, and Löwe profess to trace it to a thin pellicle of mesoblast, which at an early period passes in between the lens and the secondary ocular vesicle; but Kölliker and Kessler are of opinion that it is a cuticular deposit on the surface of the lens cells. Balfour is inclined to adopt the latter view, on the ground that the capsule seems to make its appearance before the introduction of the mesoblast has occurred." The examination of the histological changes in anterior polar or pyramidal cataracts, throws, I think, some light on this matter. I have had the opportunity of examining pathologically a large number of lenses with this form of cataract, and I will discuss in detail the changes observed in them and enter somewhat fully into the views which have been put forward as to their mode of origin. I have examined microscopically thirteen lenses with anterior polar cataracts, which have varied from one month up to twenty-one years in the length of time which had elapsed since their formation.

I may here mention that I only regard as anterior polar cataracts opacities which are situated within the capsule; these are opacities of the lens itself—that is, true cataracts; and to them the name should be confined.

It is possible that there may be opacities at the anterior pole of the lens, due either to inflammatory deposit or to the persistence of a portion of the anterior fibro-vascular sheath; these would be external to the capsule, and therefore not true cataracts. It is well not to confound these latter with the former, but to speak of them as what

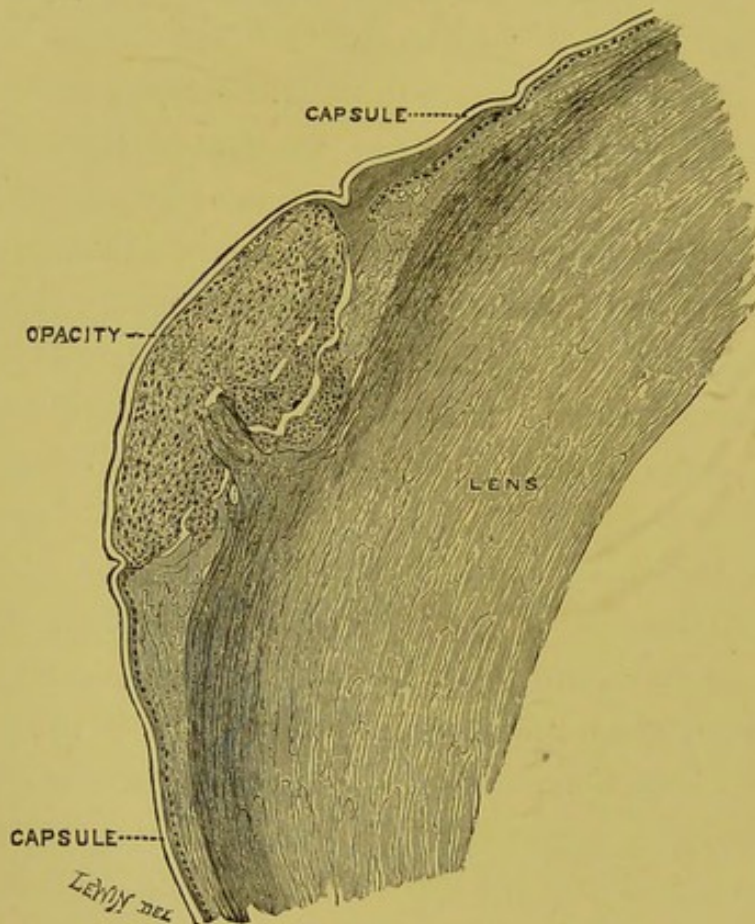


FIG. 4.—An anterior polar cataract of less than six weeks' formation. The changes are shown to be entirely beneath the hyaline capsule.

they really are—viz., pupillary membranes, either inflammatory or congenital.

The first change to occur in the formation of an anterior polar cataract is a localised proliferation of the cells lining the anterior capsule and some disturbance

and breaking up of the lens fibres in the neighbourhood. As a consequence of the proliferation of the capsule cells, elevation of the hyaline capsule over them is brought about, and from the breaking up of the lens fibres some excavation of the lens substance beneath them occurs (fig. 4). Later the mass of cells and débris of the

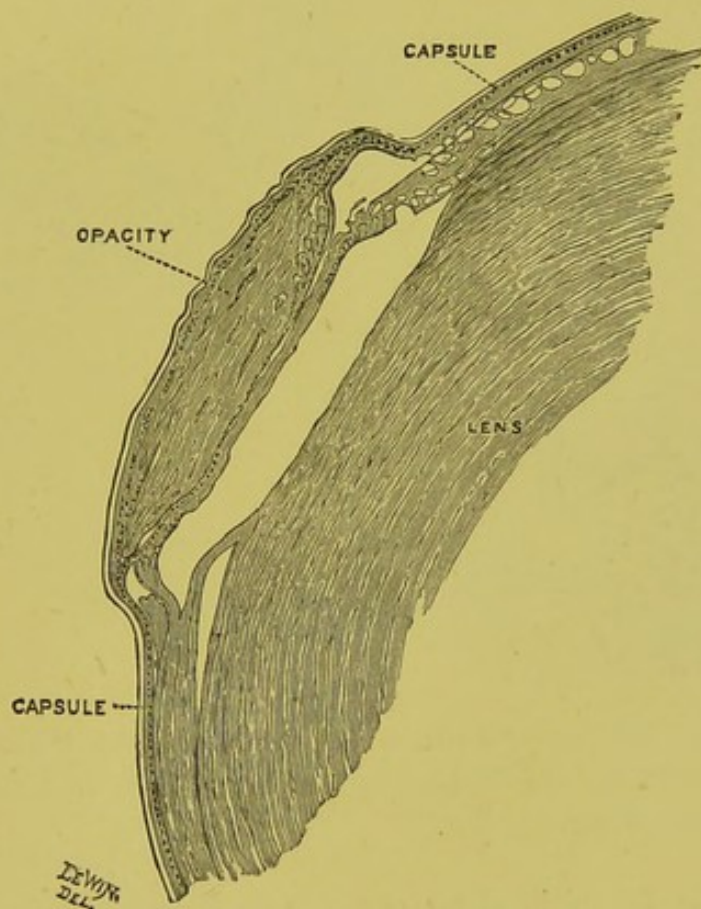


FIG. 5.—An anterior polar cataract of seven month formation. A layer of cells is shown beneath the opacity, continuous with those lining the capsule elsewhere, and a hyaline layer in front of it.

broken-up lens fibres become condensed into an almost structureless substance, showing a slight lamination and having a few flattened epithelial cells stranded here and there in it. When the mass which constitutes the opacity has reached this condition the cells which line

the capsule at its margin spread in between the opaque part and the unaltered lens substance, so that in an anterior polar cataract which has existed for more than seven months, a layer of cells is seen between the opacity and the lens substance continuous with those lining the capsule elsewhere (fig. 5). Later still—that is, after several

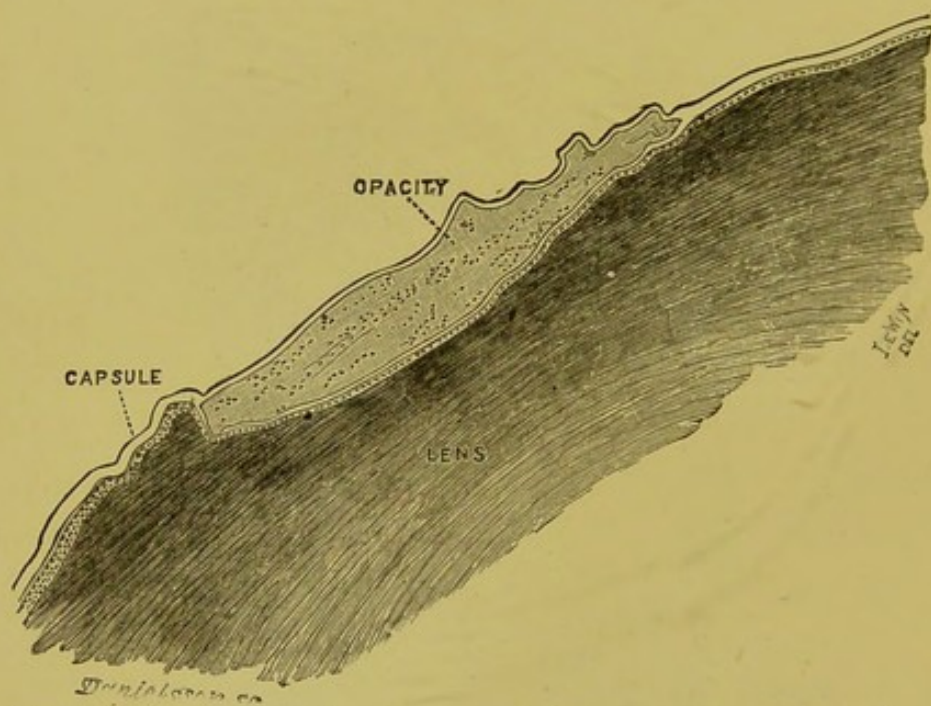


FIG. 6.—An anterior polar cataract of eleven years formation. A complete layer of hyaline capsule lined by cells is shown behind the opacity, and a hyaline layer in front of it.

years—a layer of hyaline capsule is found separating the opacity from the lens substance in addition to the layer of cells, so that at the margin of the opacity the hyaline capsule seems to split into two divisions—one going in front of it and the other, with a layer of cells lining it, behind it (figs. 6 and 7).

Presumably the newly formed layer of capsule is a deposition from the cells; and if the capsule cells are in a pathological condition capable of producing a layer of

hyaline capsule, it seems reasonable to suppose that that structure is originally formed by them. That the changes which give rise to pyramidal cataract are situated beneath the hyaline capsule was long ago pointed out by Stellwag von Carion, Müller, Rucke, Bauer, Dixon, and Hulke. That occasionally a hyaline layer is met with

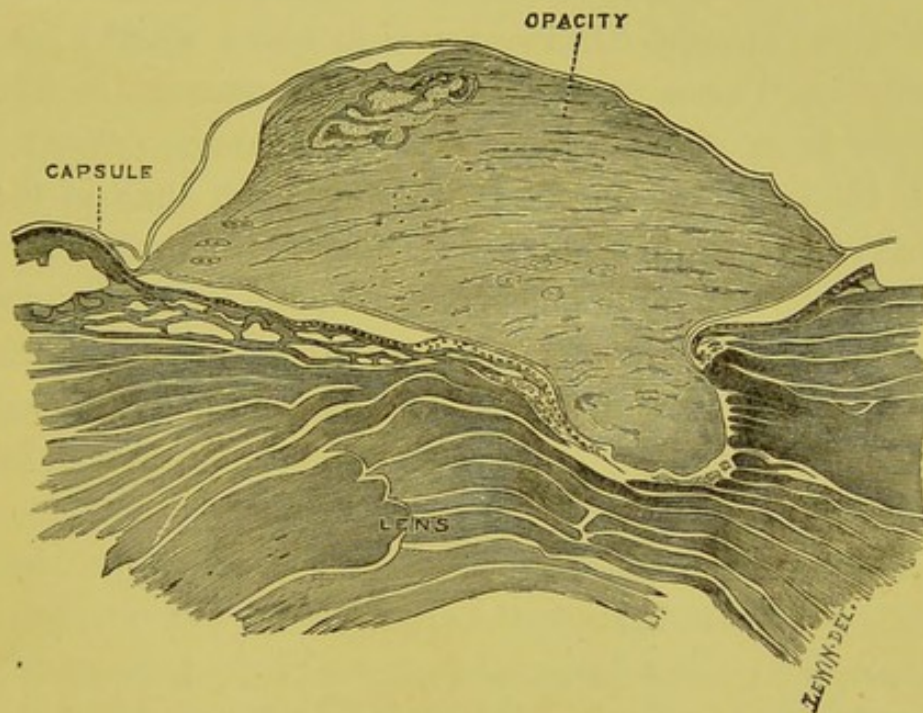


FIG. 7.—An anterior polar cataract of twenty-one years formation. A layer of hyaline capsule lined by cells is shown behind the opacity and a hyaline layer of equal thickness in front of it.

behind the opacity as well as in front of it was mentioned by Becker, who considered that it had become split off by the intrusion of new material into the substance of the capsule. More recently B. Gepner, jun.,* as the result of the examination of two cataractous lenses from fishes' eyes, came to the conclusion that these hyaline layers were not split off the original capsule, but freshly secreted by the

* "Archiv für Ophthalmologie," Bd. xxxvi., Ab. 4, S. 255.

epithelial cells. This latter view of their origin I am inclined, as I have said, to believe to be correct, because:— in all the more recent anterior polar cataracts which I have examined I find there is no distinct layer separating the opaque part from the lens fibres. In those of longer duration a layer of cells is observed between them, which look as if they had spread in from the unaltered cells lining the capsule. In two lenses in which several years had elapsed since the formation of the cataract, in front of the layer of cells was a layer of hyaline capsule; it was thicker in the one of twenty-one years than in that of eleven years' duration. Also, because the hyaline layer behind the opacity in one of the cases is a complete layer (fig. 6). I have examined numerous sections of it, but have been unable to find any gap in its continuity through which the intrusion of new material could have taken place.

Very similar conclusions as to the origin of these hyaline layers behind the opacity in anterior polar cataracts, and as to the development of the lens capsule, have been arrived at by Otto Schirmer.* He found that after wounds of the anterior capsule, the gap was first closed by some rows of cells resulting from proliferation of the capsular epithelium beneath a layer of fibrine, and that afterwards a new hyaline layer made its appearance, across the space left by the retraction of the two extremities of the wounded capsule. This new layer was evidently the product of the epithelial cells on its inner surface.

It is sometimes observed that when there is an opacity at the anterior pole of the lens there is also a second

* "Archiv für Ophthalmologie," Bd. xxxv., Ab. 1, S. 220.

opacity, a little depth in the lens substance, separated from the anterior one by some clear lens matter. I have notes of three such cases.

The first case was that of a man aged twenty-four years, who in infancy had had inflammation of the eye, which left a nebula of the cornea. There was a raised opacity at the anterior pole of the lens opposite the nebula, and further back in the lens another opacity. The second case was that of a girl aged nineteen years. She stated that both her eyes were bad when she was born; they were swollen and discharged; they remained bad for about three months and had been in their present condition as long as she could remember. She had slight lateral nystagmus, faint *nebulæ* of both *corneæ*, a small central opacity at the anterior pole of each lens, and a second opacity in each lens at a little depth in it, clear lens substance intervening. The third case was that of a man aged twenty years; his left eye was inflamed when he was three years old; he never remembered seeing properly with it. There was a faint nebula of the cornea, and in a position corresponding to it an opacity at the anterior pole of the lens; posterior to this was a layer of clear substance, and then a second opacity.

It will be seen that in all these three cases several years had elapsed between the inflammatory attack, which presumably caused the anterior polar opacity, and the time at which the patient came under observation. These lenses had therefore considerably increased in size, due to the laying on of fresh cortical fibres, since the anterior polar cataracts were first formed. These fresh fibres would have separated the opaque part, produced by the mass of proliferated epithelium, from the part of the

lens which was in contact with them when the disturbance originally occurred, and which was also probably broken up and opaque. In this way two opacities were formed separated by clear lens substance, the posterior of which appeared to sink deeper and deeper as the lens increased in size.

It is well known that anterior polar opacities in the lens are frequently produced by ulceration of the cornea, and frequently follow that very common cause of ulceration of the cornea—viz., purulent ophthalmia of infancy. Though most often originating in early life, they may occur at any age. I have examined one of recent formation from a man aged fifty-one years, who one month previous to excision had had ulceration of the cornea, with hypopyon, for which a Saemisch's section had been performed. I have another specimen from a man aged forty-six years, whose eye was affected with a traumatic ulcer of the cornea one month previous to its enucleation. True anterior polar cataract—that is, where the opacity is situated beneath the capsule, and which in every respect resembles those which follow on ulceration of the cornea—may be congenital and occur in eyes with perfectly clear corneæ. I have two specimens which demonstrate this, and I wish to lay particular stress on it, because it is very tempting to attribute any congenital opacity at the anterior surface of the lens to the persistence of a portion of the anterior fibro-vascular sheath, especially if tags of it are adherent to the anterior surface of the iris in the same eye. The first of the two cases of congenital anterior polar cataract I examined was associated with such tags, and in addition with almost complete congenital absence of the iris in both

eyes. The patient died when three years old as a result of a burn, and both eyes were obtained for pathological examination; one has been mounted as a macroscopical specimen (fig. 26), and sections have been cut of the other. I shall have to refer again to this eye in speaking of congenital abnormalities of the iris. My second specimen of congenital anterior polar cataract is a very remarkable one. The eye was excised when the child was seven years old; it had, in addition to the opacity of the lens, congenital anterior synechia of the iris and hydrophthalmos. The anterior polar opacity was very large and the rest of the lens imperfectly developed. As I have said, it is quite possible to have congenital anterior polar cataracts without any opacity of the cornea. Often in those in which anterior polar cataracts exist, and in which there is a distinct history of purulent ophthalmia in infancy, only a faint nebula of the cornea is found; so faint, indeed, sometimes that it seems impossible to believe that it is all the damage that has resulted from a perforating ulcer of the cornea. Though these cataracts are most often seen clinically in cases where there are slight corneal changes, from the great frequency with which I have met with them pathologically in eyes where the cornea is completely opaque, and where there can be no doubt that perforation has occurred, I feel convinced that a perforating ulcer is the commonest cause of them.

Such, then, being the facts with regard to anterior polar cataracts, how can their formation be explained? Mr. Hulke,* writing on this subject, says: "When we remember the small size of the anterior chamber of an infant's eye and the spherical shape of the lens at this

* "Royal London Ophthalmic Hospital Reports," vol. i., p. 190.

period of life, it becomes apparent that the distance between the front of the lens and the posterior surface of the cornea must be very small, for a large segment of the lens projects through the pupil and the zenith is considerably in advance of the plane of the iris; in these respects the infant's eye presents a striking similarity to that of the fish. In ophthalmia neonatorum, when the cornea has become inflamed and swollen its posterior surface may actually come into contact with the front of the lens, and then a dot of lymph poured out upon the latter by the inflamed cornea, or even the mere pressure contact, may give rise to opacity by preventing the proper nutritional osmose through the capsule; the little white cones which seem to project forward through the pupil in cataracta pyramidata, have their origin in this way."

Mr. Hutchinson* says on this matter: "The theory which I would venture to support is this, that the mere proximity of the inflammatory action on the surface of the conjunctiva and cornea suffices to disturb the nutrition of the lens capsule and to produce deposits. It is of course admitted that the lens surface is, during infancy, in very close proximity with the posterior surface of the cornea, so that such disturbance of nutrition may be more easily possible than it would in adult life. Still, if this hypothesis be tenable, we have in the occurrence a most interesting example of the pathological possibility that diseased action, may by a sort of vital catalysis, disturb a structure with which it is not in continuity, and that even when there exists between the disturbing and disturbed tissues a structure (cornea) which is wholly unaffected, and a layer of fluid of greater or less depth."

* *Ibid.*, vol. vi., p. 138.

Mr. Hutchinson,† in criticising the views of Mr. Hulke on the mode of formation of pyramidal cataracts, says : “ I cannot but suspect that we adopt hypotheses which are too mechanical when we attribute these little opacities either to corneal perforation or to prevention, by pressure, of nutritional osmose. As regards the latter, we must remember that there is excess, not deficiency, of growth.”

My own observations of these cataracts lead me to incline to the view put forward by Mr. Hulke, and to attribute their formation to contact of the cornea with the anterior pole of the lens, and so an arrest in the osmose of the nutritional fluids to it in that position. The contact when the opacity is congenital is due to delay in the formation of the anterior chamber which prolongs the apposition of these structures, normally existing during part of foetal life, after the fibro-vascular sheath has disappeared. In infancy, when the anterior chamber is very shallow, contact may be brought about by the swelling of the cornea, which is the accompaniment of inflammation of it, and need not necessarily be due to its perforation. Later in life the formation of anterior polar cataract is less common, and it would then seem that perforation of the cornea must occur before the lens can come into apposition with it. Mr. Hutchinson's objection to this theory may, I think, be met in this way. The immediate result of the arrest of the osmose of nutrient fluids through the capsule at the anterior pole, is to cause the lens fibres in that region to shrink, and to break up into hyaline globules and granular detritus; as a consequence of their shrinking

† *Ibid.*, p. 140.

and degeneration, the tension of the capsule at the anterior pole is lessened. There is evidence to show that the only thing which keeps the epithelial cells that line the capsule from proliferating more quickly than they do, is the tension to which they are exposed; therefore, directly the tension at the anterior pole is lessened they commence to multiply at an increased rate, and form the mass of cells which is the earliest stage of these opacities.

CHAPTER II.

ZONULAR CATARACT, ITS HISTOLOGICAL APPEARANCES, MODE OF FORMATION, AND CONNEXION WITH RICKETS. CONGENITAL CATARACTS. CONGENITAL FORMATION OF FIBROUS TISSUE IN THE VITREOUS. THE DEVELOPMENT OF THE VITREOUS HUMOUR. MUSCÆ VOLITANTES.

HISTOLOGICAL APPEARANCES OF ZONULAR CATARACTS.

DURING the last few years the results of several investigations of the minute anatomy of zonular cataract have been published. I have myself had seven lenses presenting this form of cataract for microscopical examination. Before entering into the changes I have found, I will briefly review what has been written on the subject. Von Gräfe* and Jäger† found from section of lenses with zonular cataract which had been removed by extraction, that there was an opaque whitish line separating a clear nucleus from a clear cortex. Deutschmann‡ was the first to examine a zonular cataract microscopically. He found the nucleus and cortex clear and unchanged, but that they were separated by a zone in which the lens fibres were altered by the presence of numerous vacuoles and small drops of myeline; also that there were fissures between the fibres filled with granular detritus. The next observations into the microscopical characters of zonular cataract were made, almost simultaneously, by

* "Archiv für Ophthalmologie," Band i., Ab. 2, S. 236.

† "Staar und Staar-operationen," 1854, p. 17.

‡ "Archiv für Ophthalmologie," Band xxxii., Ab. 2, S. 295.

Beselin* in Germany and by Lawford† in this country. Beselin summarises the changes he found as follows: "Scattered throughout the nucleus of the cataract examined we find numerous small masses, which are apparently post-mortem coagulation products. This nucleus is surrounded by two oval zones of cataractous substance, neither complete nor continuous, which are separated by a layer of normal lens tissue. These are, however, united here and there; both zones consist in greater part of large and small fissures, which are filled with detritus. In their immediate vicinity lens fibres are found, which are in process of cataractous degeneration. The cortex is composed of normal lens tissue; it presents a number of small fissures apparently accidental, which are filled with detritus, and at the periphery a number of small fissures may be seen, which were apparently produced artificially." Lawford, in the three specimens he examined, found in the cortical layers no changes of importance. The line of demarcation between the cortical and nuclear areas was abrupt, and between them he found a thin layer with breaks in it of granular substance; this he regarded as probably constituting the essential part of zonular cataract. In the nuclear area of all three specimens were a large number of small irregular dots or particles arranged more or less in layers, and which seemed to run concentrically, as if following the laminæ. He was inclined to regard these latter as coagulation masses, the result of the fluids employed in preserving the specimens. Otto Schirmer‡ found a similar dotted—

* "Archiv für Augenheilkunde," Band xviii., Heft 1.

† "Royal London Ophthalmic Hospital Reports," vol. xii., p. 184.

‡ "Archiv für Ophthalmologie," Band xxxv., Ab. 3, S. 747.

or, as he termed it, "vacuolated"—condition of the nucleus to that discovered by Beselin and Lawford. He found, however, that the vacuoles were more numerous in what he regards as the zone of opacity than in its central portion. He does not agree with Beselin and Lawford that these vacuoles were produced by the hardening reagents, but considers that they are the essential cause of the opacity. Such a band of vacuoles, he points out, is just the very thing to produce an opacity in a lens, as the coefficient of refraction differs in the vacuoles and in the lens fibres; the fact that this layer was not sharply differentiated from the nucleus is no argument against his position, for there is nothing to prove that zonular cataracts have any such sharp line of demarcation. He subsequently* brought forward a specimen to show that vacuoles existed in a lens in the recent state; also that the layer of vacuoles corresponded exactly in size and position with the opaque zone seen before and after extraction. The clefts described by Beselin and Lawford he thinks are probably the striæ often seen in connexion with these opacities. Schirmer has further shown that central cataract is due to vacuoles or drops similar to those seen in zonular cataracts. Hess, who has examined five zonular cataracts, confirms Schirmer's results.

The seven lenses which I have examined with what were described clinically as zonular or lamellar cataracts were all prepared in the same way. They were all hardened in Müller's fluid, passed through spirit and embedded in celloidin, after which sections were cut of them. They were all lenses which had been removed by

* *Ibid.*, Band xxxvi., Ab. 1, S. 185.

the operation of extraction, after the capsule had been opened, from patients over the age of twenty-four years. In all of them some laceration of the extreme cortical layers had occurred. In three only was the transverse diameter of the opacity measured, in two of these it was 3.5 mm. across and in the other 5.5 mm. Microscopically three different kinds of changes are met with in these lenses; all three are not present in each lens, and the amount of change in each lens varies considerably. These changes are:—First, fissures between the lens fibres, which may or may not contain a granular substance, they run concentrically to the nucleus separating it from the cortex. Secondly, small vacuoles, mostly round or oval, but in places (where they seem to have run into one another), elongated and beaded. Some of them contain a hyaline substance, which, after prolonged immersion in logwood, stains deeper with it than the surrounding lens fibres. The average size of the vacuoles is about 0.005 mm. across. Thirdly, spaces larger than the so-called vacuoles measuring on an average about 0.02 mm. across, mostly circular, with very irregular margins and containing a granular substance which stains deeply with logwood; apparently some degeneration of lens substance occurred in their formation. These three changes correspond to the appearances seen clinically in these cataracts—viz., the radiating spokes or striæ, the uniform haze, and the denser dots. None of the specimens showed any changes in the cortical layers, which were not readily accounted for by laceration of them in the removal of the lens. In several of the specimens there was a great tendency for the nucleus to separate from the cortex and to drop out. In these it was impossible to say

to what extent fissures, between the nucleus and cortex, existed prior to extraction. In some, fissures existed containing no granular substance. In one the amount of granular substance was very great; it formed a band 0.15 mm. wide encircling the nucleus. The lens fibres bordering on this band were degenerate and had some of the small vacuoles amongst them. This specimen differed from all the others I have examined in that the nucleus showed no changes and was completely free from any vacuoles. In the appearances of the band of granular substance, and in the absence of changes in the nucleus, it is very similar to that described by Deutschmann. In all the other six lenses small vacuoles were present in the nucleus; in most they were more numerous and closer together in a zone around the nucleus than in the nucleus itself; in two, however, they were distributed uniformly throughout the whole nucleus. If these vacuoles or bodies, as Schirmer suggests, are what give rise to the opacity, then these last two specimens were really central and not zonular cataracts. They were probably incorrectly classed clinically. It would seem that no very sharp line can be drawn between zonular and central cataracts—the same changes are met with in both, differing only in locality and degree. In the two lenses in which in addition to the zonular haze white dots of opacity were seen are the ones, and the only ones, in which I have found the third change mentioned, the larger circular spaces with granular contents. The position of these spaces, outside the zone of small vacuoles, corresponds to that in which the white dots appear to be situated.

THEORIES AS TO THE MODE OF FORMATION OF
ZONULAR CATARACTS.

Such, then, being the anatomical changes met with in zonular cataract, how are they brought about? Horner's view was that a pathological layer of lens substance is deposited about a normal nucleus. This he attributed to rickets, the convulsions met with in connection with it being due to cranio-tabes, and the changes in the enamel of the teeth being also of rachitic origin. This view of the rachitic origin of zonular cataract has been widely accepted by writers on the Continent, but none of the text-books in this country mention it.

Leber thought that a normally formed layer of lens substance became subsequently changed. Beselin and Schirmer differ from these authorities. The former asserts that alterations in the nutrition affect the whole nucleus, and that this change takes place when the subsequent nucleus constitutes the whole lens, the general contraction of the affected part causes the formation of fissures between it and the cortical layers of normally formed lens substance which are developed later, and that a granular substance subsequently collects in these fissures. Schirmer's theory is as follows: "Some unknown disturbance—probably in its nutrition—affects the lens so as to produce vacuoles in its substance. These may be at first in the fibres, perhaps, but later on between them, certainly. Only the newest lens fibres and those formed during the action of the noxious agent contain enough vacuoles to exhibit a visible opacity. The vacuoles in the nucleus are not enough to produce this

appearance; but, though the nucleus remains transparent, it has altered in its physical properties so that it shrinks more rapidly than the subsequently formed cortical portion is able to do, and clefts are thus produced in the lens."

Many regard zonular cataracts as really congenital, and a recent paper by Bernard Dub* brings forward evidence in favour of this view. The table of measurements of foetal lenses I have given in chapter I. has been used by him, together with measurements of adult lenses by Priestley Smith, and a series of measurements of lenses from the ages of ten months to twelve years made by himself, for the purpose of determining the time of life at which zonular cataracts originate. To do this he has compared the measurements of the lens at different ages with those of the opaque zones in a series of zonular cataracts. His method of effecting the measurement of these latter is very ingenious. It is described as follows: "If the left eye be the one affected, a millimetre scale is placed about the patient's left temple behind the outer canthus. The observer illuminates the fundus of the eye by an ophthalmoscope held before his own right eye, and keeps his left eye closed; then, opening his left eye, he squints inwards, so as to fix the scale with the left eye, while the right still observes the cataract against the red background of the illuminated fundus. The position of the scale is such that the homonymous diplopia thus invoked makes the image of the cataract seen by the right eye coincide with that of the scale seen by the left, and the only thing further required is to make the correction necessary to neutralise the enlargement produced by the

* *Ibid.*, Band xxxvii., Ab. 4, S. 26.

magnifying power of the patient's cornea. Dub assumes this to be one-seventh (on Helmholtz's authority), and corrects his figures accordingly." As the result of his measurements, he concludes that the commonly received views that zonular cataracts begin in the first two years or so of extra-uterine life, and that the peripheral fibres are the parts affected, cannot both of them be true. This paper gives in figures drawn from a series of cases the views which were expressed by Mr. Hulke* in his Presidential Address to the Ophthalmological Society in 1886. He then said: "With reference to cataract in early life, it is a question with some at what age the lamellar form makes its appearance, or rather some excellent observers have formed the opinion that it is infantile, not congenital. I am not convinced by the arguments used by the supporters of infantile origin. The opaque zones are clearly laid down during the development of the lens, and instances of zonular cataract occur where the diameter of the opaque zone is certainly less than that of the entire lens at birth." He further goes on to say that the first recognition of lamellar and zonular cataract based on dissection was, so far as he knew, made by Mr. Bowman, the subject being a kitten a few days old.

A number of direct measurements have now been made of the opaque areas in zonular cataract. The following table gives the transverse diameters of ten such, together with the measurements in Dub's ten cases.

The average transverse diameter of three lenses at the ninth month of foetal life I found to be 5.75 mm., and Dub found the average of three lenses under a year old to be 7.46 mm. So it would seem from these direct

* "Transactions of the Ophthalmological Society," vol. vii., p. 27.

Table II.—Showing direct measurements of the Transverse Diameters of the Opaque Areas in Ten Zonular Cataracts, with Dub's measurements in ten cases.

	Direct Measurements.	Dub's Measurements.
	mm.	mm.
Beselin . . .	6	1. 4'4
Lawford (1) . .	5'25	2. 4'6
Lawford (2) . .	4'5	3. 4'7
Lawford (3) . .	4'5	4. 4'8
Schirmer (1) . .	5'75	5. 4'8
Schirmer (2) . .	3'25	6. 5
Schirmer (3) . .	6	7. 5'2
Collins (1) . . .	3'5	8. 5'2
Collins (2) . . .	3'5	9. 5'5
Collins (3) . . .	5'5	10. 5'6

measurements that the zone of opacity in zonular cataract is probably never larger than the lens at birth, that it may be about the size of it at that time, but is more often smaller, and sometimes very much smaller. The direct measurements differ slightly from Dub's and show a greater variety in size, in three the zone being larger than his largest, and in three smaller than his smallest. In the smallest there is so much difference between the size of the zone, and that of the lens at birth, that I think it hardly possible to believe that the opaque area was the extreme cortex at the time of birth, and that the diminution in size is the result of shrinking. We must, then, either conclude that zonular cataract may be produced before birth or that the part affected, at the time the change occurs, is not the most peripheral, as has generally been supposed.

It is, I think, conceivable that as the result of some

general disturbance of nutrition the lens might become affected after birth, so that the nucleus, which is furthest removed from the nutrient supply, would shrink. Shrinking of the nucleus is what seems to occur first in the formation of zonular cataract, fissures, vacuolation, and degeneration following, between it and the cortical layers from which it contracts.

In support of such a view of the origin of zonular cataract are the cases in which they are found to arise as the result of what may be called purely intraocular causes. Gräfe had one caused by iritis and synechiæ; Becker one following a perforating ulcer of the cornea, and Schirmer describes the case of a woman aged 27 who had ulcerative keratitis ending in staphyloma and increased tension; the lens in whose eye had an anterior polar cataract separated by some clear fibres from a second opacity near the anterior pole, and within this again a zone of opacity enclosing a clear nucleus. I have met with a case very similar to this last. It was that of a boy aged eight months who had had ophthalmia neonatorum and ulceration of the left cornea, which subsequently became leucomatous and staphylomatous. His right eye at the time of excision was quite healthy. In the left after excision some white fibrous tissue was seen to stretch between one side of the lens and the ciliary processes; there was an opacity at the anterior pole of the lens and also a zone of opacity in it, enclosing a clear nucleus; at the posterior part of the zone of opacity, there was a white streak.

There seems no evidence of any connexion between zonular cataract and congenital syphilis. The defective condition of the enamel of the teeth so frequently asso-

ciated with the former is, as Mr. Hutchinson pointed out, quite different from the notched screwdriver condition found in the latter disease. Mr. Hutchinson* differs from Horner, who attributes zonular cataract and defect of the enamel of the teeth to rickets; he considers the latter more probably due to a stomatitis from the administration of mercurial powders given for fits. He says: "In reference to the suggestion of the Zurich investigators that the peculiarities of the teeth, in the skull bones and in the general development, are all due to rickets, I must be allowed to say that it is as yet wholly unproved. I am not aware that any author has described what are so freely spoken of as "rachitic teeth," if that term be applied, as it is by Dr. Davidson, to the permanent set. Professor Vogel of Dorpat, in reference to the effects of rickets on the teeth, says that, "as the disease disappears before the second dentition commences, these phenomena are not observed in the permanent teeth." Yet it is upon the state of the permanent teeth almost solely that the diagnosis of rickets in the Zurich clinique is based; for in only four per cent. did Professor Horner find evidence of rachitic malformation in the extremities. The irregular formation of the skull, defects in symmetry of the face, and mental peculiarities when present are perhaps quite as easily explained by reference to the attacks of convulsions as by the hypothesis of rickets."

Though, as Mr. Hutchinson says, it is not proved that rickets affects the permanent teeth, still it is very possible that it may do so. The germ of all the enamel organs of the permanent set are present at birth, and just those teeth which are most frequently affected—

* "Brit. Med. Jour.," vol. i., p. 308.

namely, the first molars, the incisors, and the canines—are the ones in which calcification commences during the first two years of life—*i.e.*, at the time of the initiatory stage of rickets.

It occurred to me that possibly some evidence as to the etiological relation of rickets and lamellar cataract might be obtained from our Australian colonies, where I was informed rickets was a rare disease. I wrote, therefore, to my friends, Dr. Barrett of Melbourne and Dr. Symons of Adelaide, asking them for any information they could obtain for me on the subject. The result of these inquiries I recently communicated to the Ophthalmological Society. It may be briefly summed up as follows:—In Adelaide rickets is a rare disease, and lamellar cataract very infrequent. In Melbourne rickets was until recently comparatively rare, that it is more common now, but that the severity of the affection is much less than in the Old World; lamellar cataract is exceedingly rare, and the honeycombed condition of the enamel of the teeth is not often met with. In Sydney, the oldest city in Australia, rickets is said to be as common as in England, but I have no statement as to its comparative severity. Lamellar cataract is less frequent than in this country. In Persia, a country I have recently visited, I found both rickets and lamellar cataract very rare diseases.

CONGENITAL CATARACTS AND CONGENITAL FIBROUS MEMBRANES BEHIND THE LENS.

Although it is very doubtful if zonular cataracts can be classed as congenital, there are other forms of opacity of

the lens which are undoubtedly so, and with regard to these I have a few observations to record.

The following is a case which demonstrates a point of considerable practical importance in connection with operations for congenital cataract. An infant four weeks old was brought by his mother to the hospital because she noticed a white appearance in his right eye. On examination a greyish white opacity with a somewhat metallic lustre was seen apparently behind the lens, fine blood-vessels coursed over it, and in the centre was a small, dark, round, slightly depressed spot. The lens in front of the opacity was quite clear, and a red reflex could be obtained round the extreme margin of the opacity in all directions. The diagnosis seemed to lie between glioma of the retina and a congenital membrane behind the lens with a persistent hyaloid artery. It was decided not to advise any immediate operation, but to keep the case under observation. Four months later the whole lens had become of a milky white colour, and the opacity originally seen behind the lens was no longer visible. The anterior chamber was shallower than it had been but the tension was normal.

The symptoms now exhibited seemed to indicate something of a progressive nature. The probabilities of the case being one of glioma were thought to be such, as to make it advisable that the eye should be removed and it was accordingly excised.

Pathological examination of the eye showed that the opacity first seen was due to a white membrane behind the posterior capsule of the lens, which was composed of a dense mass of fibres and cells; there were a few small blood-vessels in it derived from a persistent and patent

hyaloid artery. All the ciliary processes were adherent to this membrane, being directed towards the posterior surface of the lens and not to its sides.

Supposing in this case the lens had become opaque before birth instead of shortly after, or that it had become opaque before the patient was brought for examination. Then it would have been diagnosed as one of congenital cataract and a discission operation would have been performed. The lens matter liberated to the action of the aqueous humour would have become absorbed, but still a dense opacity would have remained, viz., the fibrous membrane in the anterior part of the vitreous immediately behind the posterior capsule of the lens. No amount of needling would have caused any absorption of it, and very probably the surgeon would have been tempted to have withdrawn the membrane from the eye with forceps; which seeing that it was adherent to, and practically part of, the vitreous, must necessarily have led to a considerable escape of that humour.

It is well known that in many of the cases of undoubted congenital cataract, the lens is shrunken, and that after needle operations there remains an opaque and often very tough membrane which it is exceedingly difficult to deal with. In the light of the above case and of others presenting similar characters which I have examined, it seems probable that in congenital cataract the opacity and ill-development of the lens is secondary to the formation of a fibrous membrane behind it, which is usually associated with a persistence of the central hyaloid artery. Also, that some of the opacities which do not yield to the usual operative procedures for soft

cataracts, are due to the existence of these fibrous membranes, the possibility of the presence of which should be borne in mind in advising any operation for their removal by forceps.

The next case which I shall briefly relate is somewhat similar to the last. The patient when aged nine months

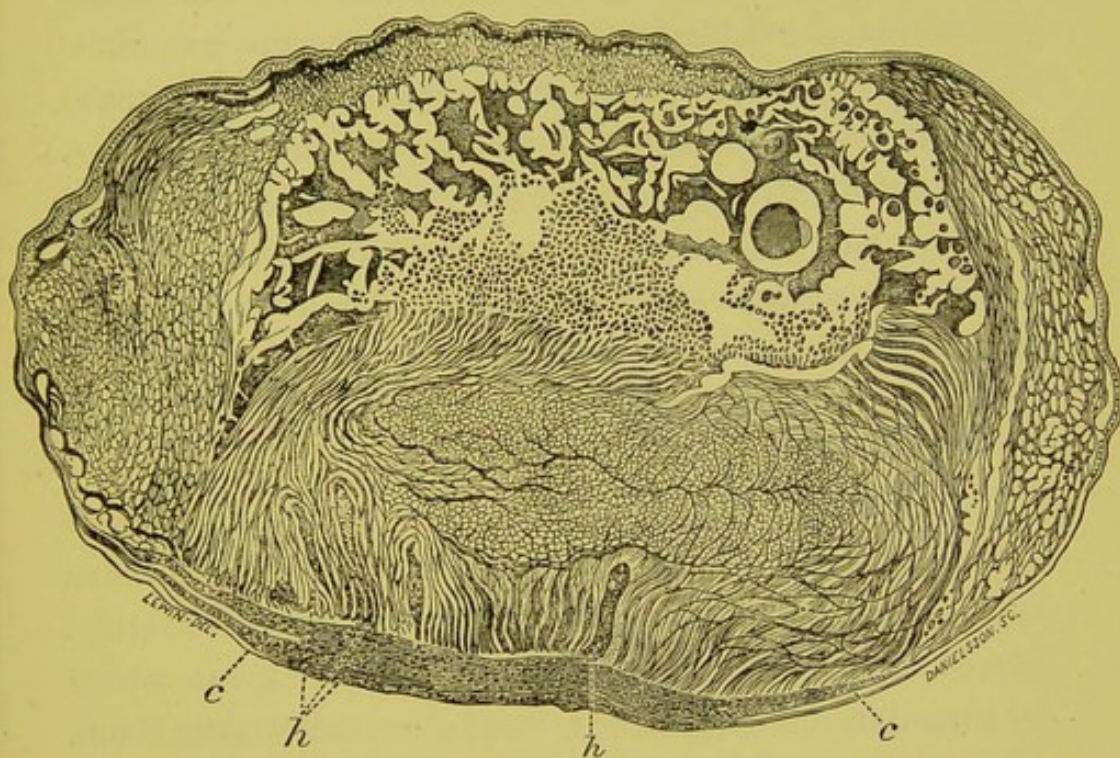


FIG. 8.—Microscopical appearance of a lens with a congenital defect at its posterior pole. (*c*) points to the capsule which is absent for some distance posteriorly, the gap being filled with a mass of nucleated fibres. (*h*) points to hæmorrhages in the lens substance, in front of the nucleated fibres.

was brought by her parents to the hospital, because they had noticed since she was three weeks old a peculiar appearance in her right eye. On examination a grey reflex was seen at the posterior part of the lens with a large hæmorrhage on its surface; the eye was thought to contain a gliomatous growth of the retina and was accord-

ingly excised. Pathological examination revealed at the back of the lens a thick membrane composed of elongated cells and fibres. The hyaline capsule could be traced on each side passing into the membrane, but there was a wide gap left in its continuity at the posterior pole (fig. 8, *c*).

In the posterior and outer part of the lens were some collections of red blood corpuscles between the lens fibres (fig. 8, *h*); no blood-vessels could be seen in their vicinity or amongst the fibres of the membrane behind the lens. The central hyaloid artery of the vitreous was not present, but it is most probable that the hæmorrhage into the lens came from some of its branches before it disappeared; the blood gaining access to the lens substance owing to a defect in the development of its posterior capsule.

Hæmorrhages into the lens must necessarily be of extremely rare occurrence. Alt says: "Hæmorrhagic cataract has been once examined and described by Gräfe. He found the lens fibres brown, which colour was caused by granular and crystallized blood-pigment within them, while their shape was unaltered. The capsular epithelial cells, too, were filled with the pigment. It could not be ascertained, in this case, whether the lens capsule was intact or ruptured."

MODE OF FORMATION OF CONGENITAL FIBROUS MEMBRANES IN THE VITREOUS.

It becomes now a matter of interest to enquire how these fibro-cellular membranes, which form behind the lens, simulate the clinical appearances of a glioma of the

retina, and complicate the treatment of congenital cataract, are produced.

I may at first state that tissue of a similar fibro-cellular character is found congenitally, not only as a membrane behind the lens, but also in other parts of the vitreous humour, around a central hyaloid artery, or in the neighbourhood of the foetal cleft. Thus in a microphthalmic eye which I examined, I found a considerable band of fibrous tissue with small blood-vessels in it stretching between the posterior wall of the globe and the back of the lens. It was attached posteriorly to the sclerotic just below the optic nerve, there being a coloboma of the choroid. The lens was situated abnormally far back in the eye; having apparently been held back by the fibrous tissue while the other parts of the eye had grown forwards; the ciliary processes becoming very much elongated (fig. 9).

In a patient aged six weeks, who was brought to the hospital because her right eye seemed larger than her left, and because a white speck had been noticed in it; the lens was found partly opaque and displaced outwards, while behind it was an opaque looking pinkish mass with blood-vessels visible on its surface. The mass was thought, probably, to be a gliomatous growth of the retina, and the eye was excised. Pathological examination showed a white membrane 1 mm. wide stretching across the ciliary region behind the lens. Passing backwards from this membrane through the vitreous chamber were three white cords, two large and one small; these gave off branches and a transverse band connected the two larger ones posteriorly. At the inner and lower part of the globe, extending from the margin of the optic disc to the equator was a thick lens-shaped mass. This mass

and the wall of the globe, which seemed continuous, measured 4 mm. across; the retina and choroid in the region of the mass could not be traced; the smaller white cord was inserted into the mass. The membrane behind the lens, the white cords and the mass attached to the

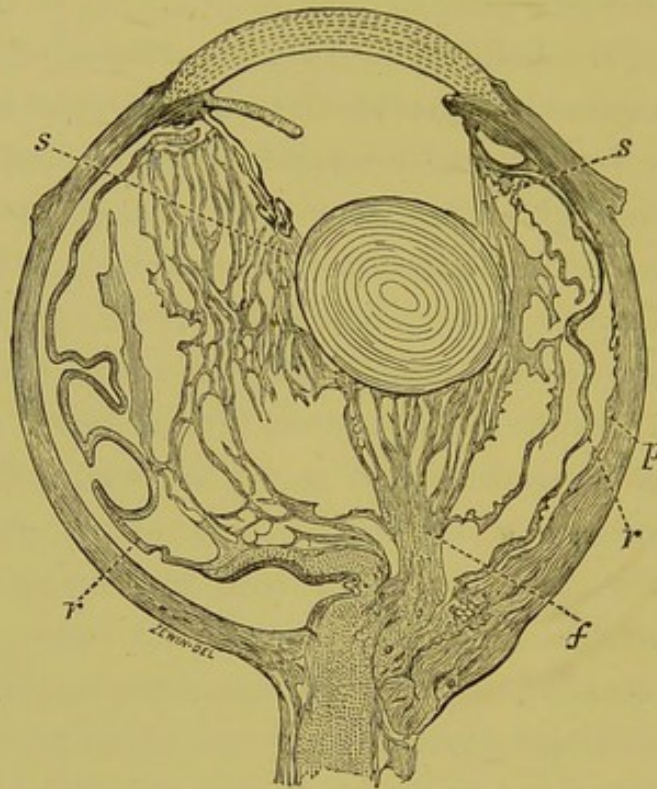


FIG. 9.—Semi-diagrammatic section of a microphthalmic eye with a band of fibrous tissue in the vitreous, stretching from the posterior pole, below the optic nerve, to the back of the lens, which latter is held back by it, the anterior parts of the eye having grown forwards, the ciliary processes being much elongated.

s. Suspensory ligament. *r.* Retina. *f.* Fibrous tissue in vitreous. *p.* Coloboma of choroid.

inner wall of the globe, were all composed of a network of closely packed fibres and cells; some of the latter were like ordinary leucocytes, others had the nucleus displaced much to one side like the signet-ring shaped cells of the vitreous.

Blood-vessels coursed through the membrane behind the lens and the mass at the side of the globe, and each white cord had a blood-vessel in the centre of it.

This abnormal formation of fibro-cellular tissue in the vitreous chamber cannot, I think, be the result of changes in inflammatory products, because, it is quite unlike what is produced in inflammation of the eye later in life; and because the other structures of the eye, in the specimens I have examined, show no changes which can be attributed to past inflammation. It is unlikely that such extensive new formations could occur in the vitreous as the result of inflammation without some signs of it, past or present, in the vascular tunics of the globe.

The changes in these cases amount to more than a mere persistence of foetal structures which normally disappear before birth. The membranes met with behind the lens are not simply a persistence of the posterior fibro-vascular sheath of the lens, which is a thin, delicate structure, scarcely more than a fine network of blood-vessels.

The stout thick cords passing through the vitreous, though they each contain an artery continuous with that of the optic nerve, are more than a simple persistency of the cellular sheath which normally surrounds the posterior part of the central artery of the vitreous. This congenital defect is I believe due to some irregular development of the mesoblast tissue, which normally passes in at the ocular cleft to form the vitreous humour.

Hess, who has met with fibrous tissue of a similar character in different parts of the vitreous in microphthalmic eyes, states that he cannot regard it as an inflammatory product, but considers it to be the result of

an atypical embryonic development of the intruded mesodermic layer which goes to form the vitreous.

In nearly all the cases which I have examined presenting this abnormality, the blood-vessels of the vitreous have persisted and remained patent, it is difficult to decide whether the abnormal tissue is due to the persistence of the blood-vessels, or whether they persist as the result of the abnormally developed tissue.

In some of the eyes in which a membrane was present behind the lens and in which there was a persistent and patent hyaloid artery, I was unable to determine the venous channel by which the blood circulating in the artery and the membrane, left the eye. The ciliary processes were connected with the membrane by bundles of delicate fibres, like those of the suspensory ligament of the lens, but I was unable to trace any connection between the blood-vessels in the membrane and those of the ciliary body.

THE DEVELOPMENT OF THE VITREOUS HUMOUR.

In examining the vitreous humour in sections of a series of human foetal eyes of different ages, I find, in the youngest specimen, which was stated to be from a foetus of about the tenth week, the vitreous consists of but a thin layer separating the posterior surface of the lens from the inner layer of the secondary optic vesicle; it is bounded by a very definite hyaline membrane, and is mainly composed of a network of exceedingly fine fibrils with numerous little granules lying on them (fig. 10). Small blood-vessels course through it, the walls of which

are composed of cells only one layer thick. Scattered throughout on the hyaloid membrane at fairly regular intervals but widely separated from one another are nucleated cells, resembling leucocytes.

In sections of an eye from a foetus of the fourth month, the posterior fibro-vascular sheath of the lens is more defined. The granules on the fibrils show up very plainly, they stain with logwood or eosine, and are about one eighth the size of the nucleus of a cell. Three or four granules one after another are sometimes located on the

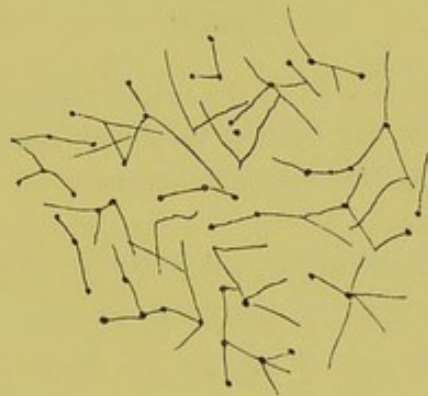


FIG. 10.—Branching fibres with small round bodies on them, seen in the foetal vitreous $\times 300$.

same fibril; the fibrils frequently branch and at the point of separation a granule is often met with, occasionally there is a star-like arrangement of granules and fibrils (fig. 10).

The space left between the fibrils is filled by a homogeneous material.

From a foetal eye of between the fourth and fifth months, I obtained a section across the central artery of the vitreous as it emerged from the optic nerve. It is seen to be encircled by a distinct cellular sheath which

together with the artery lies in a space lined by a definite hyaline membrane.

Transverse sections of the central artery of the vitreous in a fifth to sixth month foetus shows first a hyaline membrane, then a cellular sheath with the cells close together, next some spaces and fibres and then in the centre the artery (fig. 11). Further forward in the vitreous, the cellular sheath ceases and the artery lies bare in the

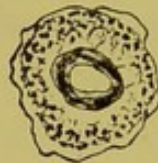

FIG. 11.—Transverse section of the central artery of the vitreous, showing the cellular sheath and hyaloid membrane surrounding it. From a foetal eye of between the fifth and sixth months.

canal bounded by hyaline membrane (fig. 12). On approaching the posterior surface of the lens this canal expands and the artery splits up into branches which are distributed to the posterior fibro-vascular sheath of the lens.

The first to describe the granules and fibres in the

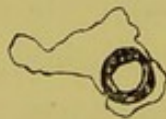

FIG. 12.—Transverse section of the same artery, shown in figure 11, further forwards in the vitreous. The cellular sheath has ceased, but the artery is still surrounded by a hyaloid membrane.

foetal vitreous was, I believe, Sir William Bowman;* he says, in speaking of a human foetal eye:—"With a power of 300 diameters these specimens of the vitreous show a

* Collected Papers of Sir W. Bowman, vol. ii., p. 189.

very well marked but peculiar fibrous texture not at all unlike that of the enamel pulp described by Dr. Todd and myself. The fibres join in numerous points, at which are minute nuclear granules resembling oil-particles, but not soluble in ether." The nature of the granules seems to me at present very uncertain, they take on a nuclear stain but are many times smaller than the nucleus of any cell, and are more the size of a nucleoli than of a nucleus.

I have met with them in the vitreous of adults, but in it they do not stain so deeply or form nearly such conspicuous structures as in foetal eyes.

Their arrangement like beads on a fine thread or as the central point of a star-like figure, their size and general appearance, all make me think, that it is the persistence of some of them which give rise to the *musca volitantes*, so frequently seen by some persons with perfectly healthy eyes on looking at a white cloud.

PERSISTENCE OF THE SHEATH OF THE CENTRAL HYALOID ARTERY.

It is quite common to see ophthalmoscopically in otherwise perfectly healthy eyes, a tag or membrane of grayish-white tissue attached to the optic disc filling up the depression which normally exists in the nerve head, or protruding somewhat forwards beyond the level of the rest of the disc. I have had the opportunity of examining microscopically two such membranes, and have found them to consist of cells and fibres similar to those which form the sheath of the central hyaloid artery, which in

these cases has remained persistent though the artery itself has become obliterated (fig. 13).

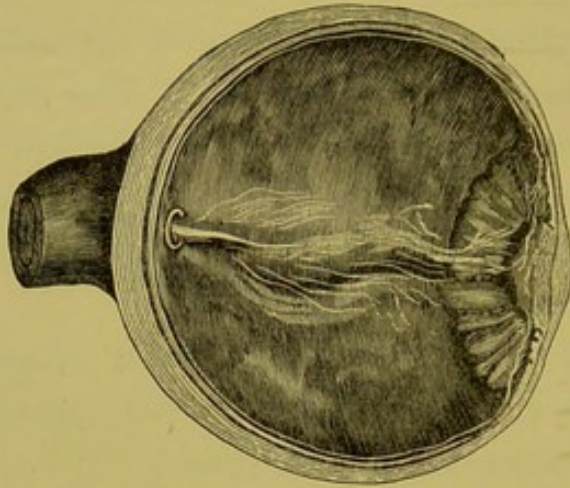



Fig. 13.—An eyeball the sight of which was destroyed by ulceration of the cornea.

Prolonged forwards into the vitreous from the optic nerve is a tag of white membrane, which microscopically is seen to be composed of fibres and cells, and which is probably a persistence of the sheath of the central hyaloid artery.



DESCRIPTION OF PLATE II.

Fig. a. Overgrowth of the glands of the ciliary body in a cyclitic membrane. × 300.

Fig. b. Bleached section of a melanotic carcinoma originating in the glands of the ciliary body. × 300.

PLATE II

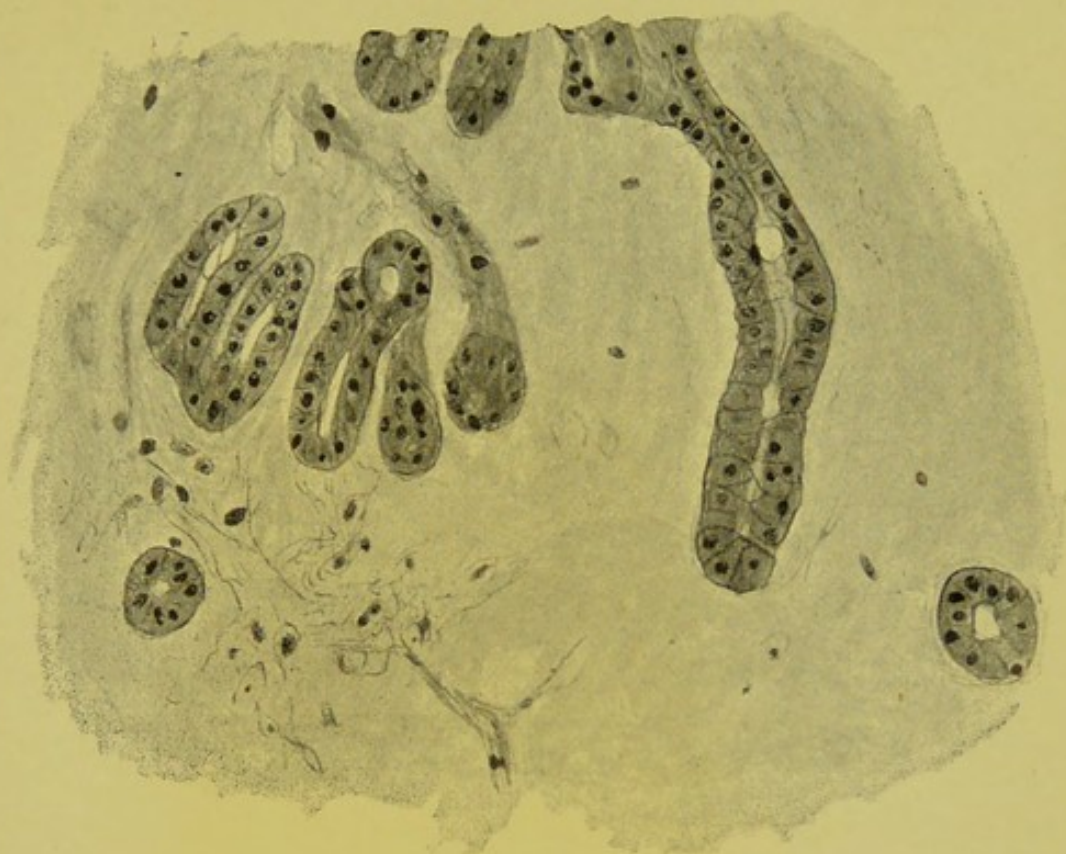


Fig. a.

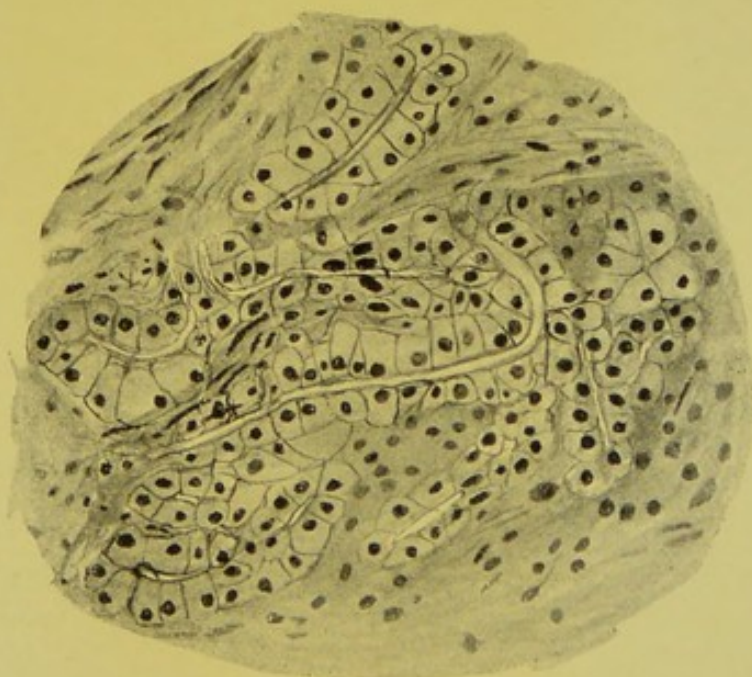


Fig. b.



CHAPTER III.

METHOD OF BLEACHING SECTIONS OF THE EYE. ARRANGEMENT OF PIGMENT EPITHELIUM ON THE POSTERIOR SURFACE OF THE IRIS. CYSTS OF THE IRIS DUE TO SEPARATION OF ITS TWO PIGMENT EPITHELIAL LAYERS. ECTROPION OF THE UVEAL PIGMENT OF THE IRIS. ARRANGEMENT OF THE PIGMENT EPITHELIUM OF THE CILIARY BODY IN MEN AND ANIMALS. EXPERIMENTAL EVIDENCE ON THE SOURCE OF THE AQUEOUS HUMOUR AND NUTRIENT FLUID OF THE VITREOUS. CATARRHAL, SUPPURATIVE, AND PLASTIC INFLAMMATION OF THE SECRETING AREA OF THE CILIARY BODY. CYSTS OF THE GLANDS OF THE CILIARY BODY. ADENOMA AND CARCINOMA OF THE CILIARY BODY.

METHOD OF BLEACHING SECTIONS OF THE EYE.

THE late Lord Sherbrooke was an albino. During the latter part of his life he became affected with cataract, and an operation of extraction with iridectomy was performed on one of his eyes. The surgeon who performed the operation brought the piece of iris to the laboratory at the Moorfields' Hospital for examination. It was thought it might show well the arrangement of the epithelium on the posterior surface of the iris, which in the normal eye is densely pigmented. The specimen was a mere fragment, and its preparation was not satisfactory; but its examination suggested to me the possibility of depriving sections of the eye of their pigment, and so allowing of a more accurate examination of the pigmented epithelium. The best way I found to effect this was to

place the section from an eye which had been previously embedded in celloidin, first, into chlorine water, which can be readily made as required by soaking chloride of lime in water and filtering, then into water acidulated with hydrochloric acid (one minim to one drachm). The sections should be passed backwards and forwards between these two solutions until the pigment quite disappears, then after thoroughly washing in several changes of water they can be stained with logwood. The manipulation of the sections requires considerable care, as, after exposure for some time to the chlorine and acid, they have a great tendency to come to pieces—the substance of the cornea peeling off Descemet's membrane, the choroid separating from the uveal pigment layer, and so forth, in spite of the embedding celloidin. Mr. Griffith has recently improved on this method, and has succeeded in bleaching portions of the eye *en masse*.

ARRANGEMENT OF THE PIGMENT EPITHELIUM ON THE BACK OF THE IRIS.

A section of the iris which has been bleached shows quite distinctly, as I first pointed out in 1890, that there are two layers of epithelium on its posterior surface. The anterior of these is continuous with the pigmented layer on the inner surface of the ciliary body, and the posterior with the unpigmented layer or pars ciliaris retinae. At the pupillary border of the iris these two layers unite, this union corresponding developmentally with the junction of the inner and outer layers of the secondary optic vesicle. The anterior layer consists of a single row of

flattened nucleated cells. The posterior layer is the most deeply pigmented portion of the whole eye and the last to lose its pigment in the bleaching process; the cells in it at the root of the iris are elongated and wedge-shaped, the bases of the wedges being directed backwards; the result being that the posterior surface of the outermost part of the iris has a convoluted outline, the cells being arranged in little groups with depressions between them. On tracing the iris inwards these depressions become much shallower and separated further apart. From about its centre to the pupillary border it presents a smooth surface, the cells here being of a regular columnar shape. Throughout this layer the nuclei of the cells are situated in their posterior halves. At the pupillary border the cells in the anterior layer are not so flattened and are more quadrate in shape. It is this increase in the size of the cells in the anterior layer which makes the pigment on the posterior surface of the iris thicker at the tip than in the centre.

CYSTS OF IRIS DUE TO SEPARATION OF ITS TWO PIGMENT EPITHELIAL LAYERS.

The posterior layer of cells may be termed the *pars iridis retinæ*; and as in the hinder parts of the eye the two layers of the secondary optic vesicle become separated in detachment of the retina, so in the anterior part they may become separated and a space be formed between the two layers of pigment on the back of the iris. Slight detachments of this sort are seen frequently in various pathological states, especially in eyes of youthful patients

(fig. 14). It is of more frequent occurrence than detachment of the whole of the pigment epithelium from the stroma of the iris, for the anterior layer, like the pigment epithelium in the posterior parts of the eye, has firm

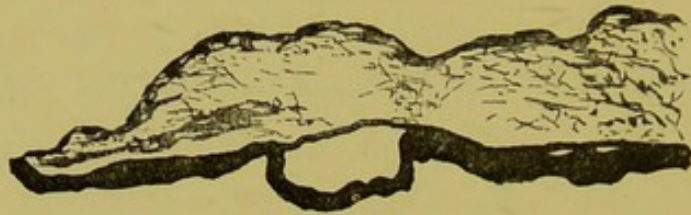


FIG. 14.—Small cyst situated between the two layers of pigment epithelium on the back of the iris, from an eye which contained a melanotic sarcoma of the ciliary body, and in which the iris was swollen and œdematous.

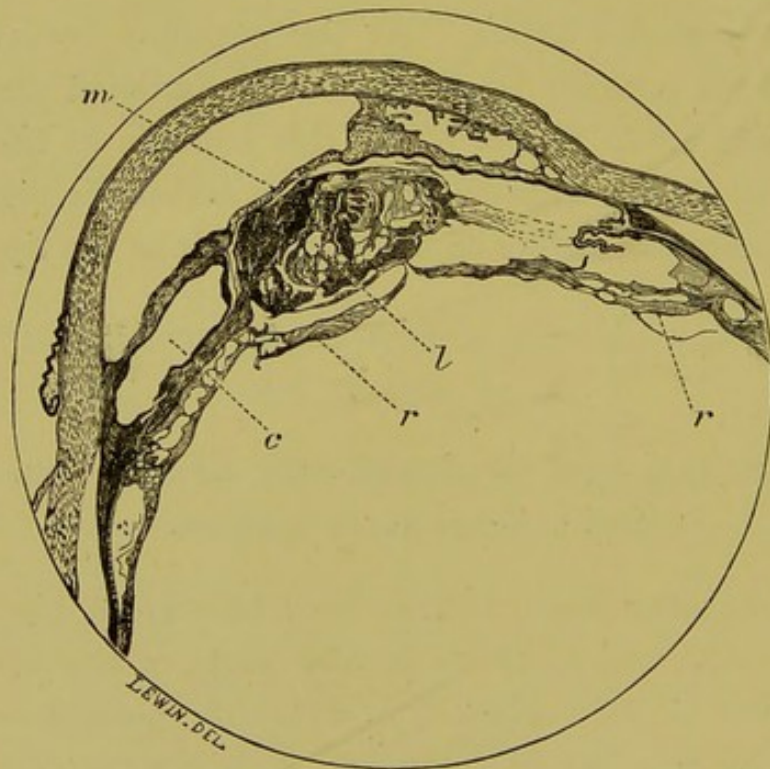


FIG. 15.—Microscopical appearance of the anterior half of an eye with a cyst situated between the two layers of pigment epithelium on the posterior surface of the iris.

c. Cyst. *m.* Inflammatory membrane in pupil. *l.* Lens. *r.* Detached retina.

connexions to the mesoblastic structures overlying it. An effusion between the two pigment epithelium layers, when extensive and localised, will produce a cyst-like tumour of the iris (figs. 15 and 16). When not localised, extensive and following iritis, with occlusion of the pupil, a condition indistinguishable clinically from what is known

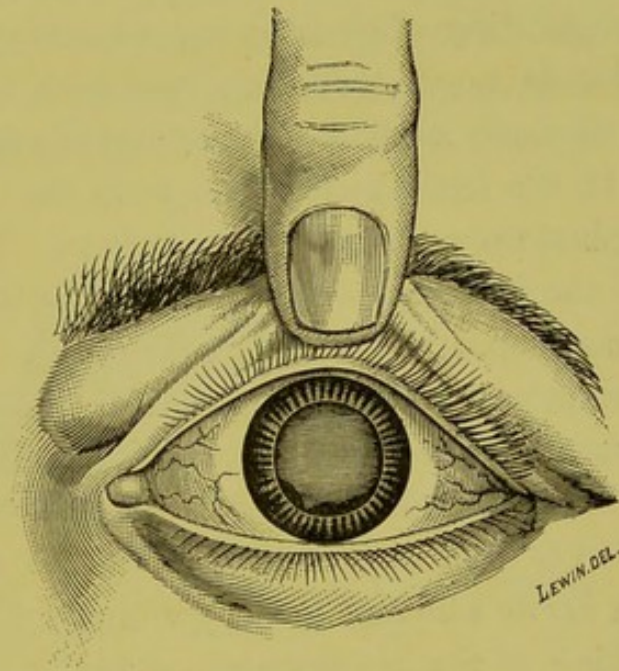


FIG. 16.—Cyst of iris with uveal pigment on its anterior surface.

as "iris bombé," is produced. The surgeon in performing an iridectomy in such a case removes the stroma of the iris and anterior layer of pigment, and then is probably surprised to find the coloboma still filled up with a layer of pigment, the posterior pigment epithelial layer.

ECTROPION OF THE UVEAL PIGMENT OF THE IRIS.

The pigment epithelium terminates usually at the pupillary margin of the iris; in certain pathological conditions it is continued round it on to the anterior surface, constituting what is known as ectropion of the uvea. This is most commonly met with in cases of glaucoma of some standing, and appears to be due to a shrinking of the iris, which ensues from the pressure of its root against the periphery of the cornea. The shrinking affects the anterior part of the iris more than the posterior, consequently the latter gets drawn round. It is not uncommon to find the ectropion of the uvea more in one part of the circumference of the pupil than in another. In such cases the iris is most shrunken where the ectropion is most marked, and where the root of the iris is most firmly adherent to the periphery of the cornea. The shrinking of the iris more in one part than another is rendered evident by an eccentric position of the pupil. As the result of these observations we may formulate the following rule, which is of some practical utility in operating for glaucoma—that when in a case of glaucoma the pupil is eccentric, and there is ectropion of the uvea, the iris is likely to be less adherent to the periphery of the cornea, in the position opposite to that to which the pupil is displaced, and where the ectropion of the uvea is most marked, than elsewhere. This is, therefore, the most favourable position in which to do an iridectomy in order to remove the iris up to its extreme periphery.

Ectropion of the uveal pigment, besides occurring as

the result of glaucoma, is sometimes also a congenital condition, and may give rise to a raised pigment nodule at the pupillary border. The arrangement of the pigment epithelium at the pupillary margin of the iris of a horse is very peculiar.

The pupil of the horse is oval in shape, and projecting from its margin on one side is an irregular, nodulated, deeply pigmented mass, continuous with the uveal pigment layers on its posterior surface. In the eyes I have dissected this mass measured on an average 8 mm. in

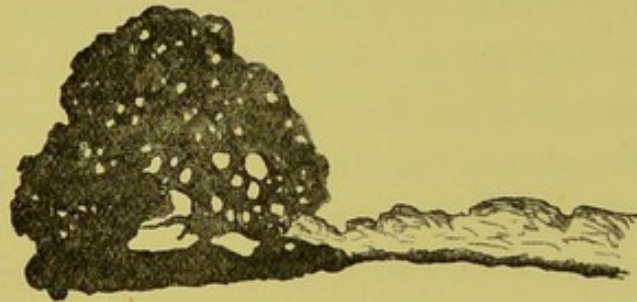


FIG. 17.—Section of a horse's iris, showing the prominent mass of pigmented epithelial tissue at its pupillary border.

length, 3 mm. in width, and 3.5 mm. in height. In unbleached sections of it, little can be made out of the arrangement or shape of the cells of which it is composed. It is very cavernous, and blood-vessels are seen coursing through it, continued on from those in the stroma of the iris (fig. 17). Bleached sections show the mass to be made up of flattened epithelial cells, which line and form columns between numerous, variously sized, circular spaces.

ARRANGEMENT OF THE PIGMENT EPITHELIUM OF THE
CILIARY BODY IN MEN AND ANIMALS.

Bleached sections of the human eye show that the pigment epithelial layer from the optic disc up to the ora serrata consists of but a single row of cells. In the ciliary body, protruding from this layer towards the ciliary muscle, are numerous little processes or down-growths, each consisting of a group of cells (Plate I., figs. *a* and *b*). These down-growths vary in number and shape in different portions of the ciliary body. The two parts where they are most numerous, are just in front of the ora serrata and at the junction of the plicated and non-plicated parts. In the plicated part there are but very few of them, and those that exist are met with in the recesses between the ciliary processes. Most of the down-growths at the junction of the plicated and non-plicated portions are pear-shaped, the bulbous end of the pear projecting towards the ciliary muscle. Those in front of the ora serrata project outwards and slightly backwards; they are shorter and broader than the others, and some of them can be distinctly seen to consist of two rows of cells. By the examination and comparison of a number of bleached and unbleached sections of the ciliary region cut on the flat, I have been able to distinctly make out that the cells of these projecting processes are arranged in rings with a central lumen.

I have attempted to make out how far an arrangement of the pigment epithelium of the ciliary body similar to that which exists in man, is present also in animals.



DESCRIPTION OF PLATE I.

Fig. a. Bleached section of the ciliary body of a normal eye, showing glands. $\times 120$.

Fig. b. Glands of the ciliary body; bleached section.
 $\times 300$.

PLATE I.

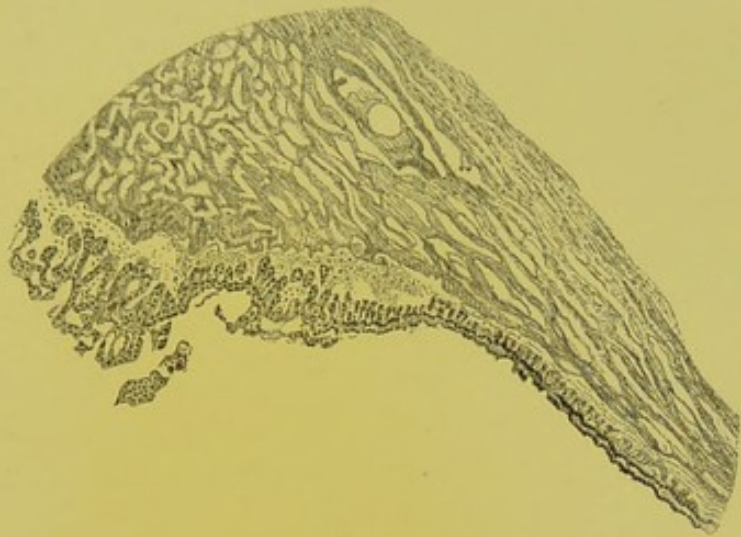


Fig. a.

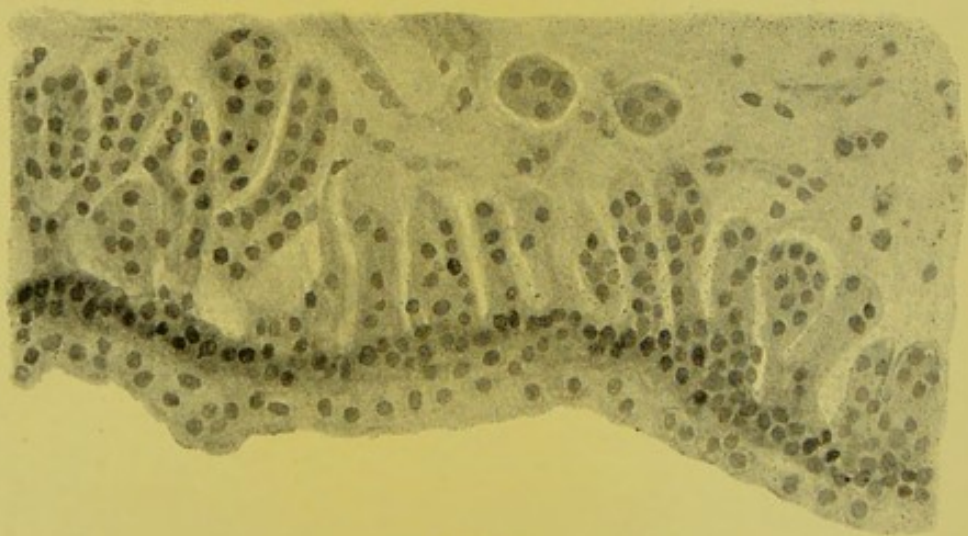

Fig. b.



For this purpose I have cut and bleached sections of eyes of the following animals:—pig, ox, rabbit, cat, fox, sheep, horse, and chimpanzee. Sections of animals, eyes take much longer to bleach than those of the human eye, in fact in some I found it impossible to get them completely devoid of pigment. The prolonged time which they have to remain in the solutions renders them very friable. It is not, therefore, at all an easy matter to obtain good bleached specimens of animals eyes for examination.

The shape and character of the ciliary processes in animals vary considerably in the different species. All those mentioned, except the chimpanzee, have much longer and thinner processes with more numerous and complicated folds than are met with in man. The non-plicated part, too, in all these animals is much shorter. In the rabbit I have been unable to find any arrangement of the pigment epithelium corresponding to the down-growths met with in man. The cells are arranged throughout the ciliary region in this animal in one uniform single row. In the ox, horse and chimpanzee, there are certainly down-growths from the pigment epithelial layer in the hindermost part of the plicated portion and at its junction with the non-plicated part, which are comparable to those I have described in the human eye. With regard to the other animals I am unable to make any definite statement.

EXPERIMENTAL EVIDENCE AS TO THE SOURCE OF THE
AQUEOUS HUMOUR AND NUTRIENT FLUID OF THE
VITREOUS.

Many ingenious experiments have during the last few years been performed for the purpose of determining the source of the aqueous humour, and of the nutrient fluids of the lens and vitreous. That the aqueous was secreted by some part of the walls of the posterior chamber seemed likely, by its accumulation behind the iris when the pupil became closed either by a complete ring of posterior or anterior synechiæ. It seemed improbable that it came from the iris, for in cases of aniridia, either congenital or traumatic, no alteration in its constituents or in its amount was noticed. Deutschmann* excised the iris and ciliary body from the eye of a rabbit, and found that the secretion of the aqueous was arrested, and that the vitreous shrank. Schoeler and Uthhoff,† adopting a method of subcutaneous injection of a solution of fluoresceine originally suggested by Ehrlich, found that from four to ten minutes after such an injection the coloration could be detected coming through the pupil into the anterior chamber. On dissection of eyes excised at various periods after subcutaneous injection they found that simultaneously with, or immediately after the coloration of the pupil, some of the furrows between the ciliary processes were tinged with green. These green lines grew narrower in the di-

* "Archiv für Ophthalmologie," Band xxvi., Ab. 3., S. 117.

† "Jahresbericht über die Wirksamkeit der Augenklippen," S. 52. Von Prof. Schoeler.

rection of the equator of the eye, and ended at the posterior limit of the processes; there was also a gradual coloration of the vitreous body proceeding from the ciliary processes and passing backwards. In an eye in which the ciliary processes had become atrophied or destroyed in consequence of previous cyclitis, no colour entered the anterior chamber through the pupil, and on section the atrophied processes were almost entirely destitute of coloration. These experiments seem to prove that the aqueous and nutrient fluid of the vitreous are secreted in the ciliary region. They are confirmed by those of Leplat* who injected iodide of potassium subcutaneously, and after enucleation cut up the frozen eyeballs into zones, testing each zone quantitatively for iodine with starch.

In the *Archives d'Ophthalmologie* for 1891 there appeared a series of articles by M. Nicati, in which he claims to have established on histological, physiological, and pathological grounds, the existence of a glandular apparatus for the elaboration of the aqueous humour. His histological researches refer to rabbits' eyes, and he speaks of the pars ciliaris retinæ as the gland of the aqueous humour.

These experimental researches go to show that it is in that part of the eye in which these little tubular down-growths of cells exist, that the aqueous humour and the fluid which gives nutriment to the vitreous are secreted. These are the only fluids which are known to be poured into the eye. These tubular down-growths open towards its interior, and are only separated from the close vascular plexus of the ciliary region

* "Annales d'Oculistique," vol. xcvi., p. 89.

by a basement membrane. The inference that they are glands concerned in the elaboration of the aqueous humour and nutrient fluid of the vitreous seems to me irresistible. There is no evidence at present to show to what extent they are concerned in it; that they are the sole source of these fluids seems improbable, from their absence in rabbits' eyes and from the fact that epithelium similar to that lining the glands covers the rest of the ciliary processes. I first pointed out the existence of these gland-like processes of the pigment epithelium of the ciliary body in March, 1891. Greef,* who has since written on the subject, seems to think I referred to the recesses between the ciliary processes in speaking of glands, but can only have done so by failing to have read carefully the description I gave of them. Mr. Griffith,† in a criticism of my work read before the British Medical Association in 1894, agrees that the anterior group of processes are glandular in character, but considers that the posterior—those situated in the non-plicated portion of the ciliary body, which he finds are not always present—are really only rucks in the pigment epithelial layer due to alterations in the state of contraction of the ciliary muscle. The objections to this view of their nature are: (1) that when present they are distinctly tubular; (2) that there are no half stages between a distinct tube and a single row of cells; and (3) that I have found them present in some and absent in other perfectly healthy eyes, hardened and prepared in precisely similar ways. I am at a loss to explain their absence in some eyes and presence in others. The anterior group of pear-

* "Report of Heidelberg Ophthalmoscopical Society," 1893.

† "Ophthalmic Review," vol. xiii., p. 247.

shaped processes is always present. If they be glands we should expect to find them subject to the same diseases as secreting tubular glands in other parts of the body. We should expect to find them subject to catarrhal and suppurative inflammation; we should expect to find overgrowth of them in cases of chronic inflammation; we should expect them to be subject to cystic formation, and for them to be the starting points of tumours presenting a glandular character, either adenomata or carcinomata. I will now proceed to show that these expectations are actually fulfilled.

CATARRHAL INFLAMMATION OF THE SECRETING AREA
OF THE CILIARY BODY.

The disease, which was originally described by Wardrop in 1808 as aquo-capsulitis, and which is now generally spoken of as serous iritis, is, I believe, primarily catarrhal inflammation of the ciliary body and of these glands. The whole course of the disease points, I think, in this direction. I would interpret its symptoms as follows:—It commences with congestion of the blood-vessels around the glands, which manifests itself as circumcorneal injection. This is not associated with pain and photophobia, which symptoms usually occur in iritis. The secretion from the glands becomes augmented, causing increase in the aqueous humour and deepening of the anterior chamber. It also becomes altered in character, more albuminous than usual, and contains a few leucocytes, some pigmented epithelial cells which have desquamated from the surfaces of the glands, and some shreds of fibrin. These formed

elements tend to gravitate to the lower part of the anterior chamber and to be deposited on the posterior surface of the cornea, forming the spots of "keratitis punctata," some of which are often pigmented, the pigment being derived from the desquamated cells above mentioned. Some of the leucocytes also collect in the mesh of the ligamentum pectinatum; this, together with the alteration in the character of the fluid, tends to hinder its exit from the eye, and, combined with the excessive secretion, readily leads to increase of tension, which is only temporarily relieved by iridectomy or paracentesis. As a result of these changes in the composition of the aqueous it becomes slightly turbid, which turbidity produces an alteration in the colour of the iris. This latter structure is not at first affected, and there is no tendency to the formation of synechiæ until in the later stages, when it has become secondarily involved. The vitreous is early noticed to contain flocculi. The course of the disease, as in all catarrhs, is very variable, and there is great tendency to relapses. Severe cases end in disorganisation of the structures which receive their nutrient fluid from these glands. Thus the vitreous shrinks, the lens becomes cataractous, and a condition of phthisis bulbi results.

The histological appearances of sections from eyes affected with so-called serous iritis are quite in keeping with this theory of its pathology. There is some increase in the size of the glands, some irregularity and proliferation of their epithelium, enlargement of the blood-vessels in their vicinity, and a variable amount of round-celled infiltration about them. At the stage in the disease at which eyes are usually obtained for histological examination inflammation is not confined to the ciliary body, but has spread

throughout the uveal tract. In the eye of a boy aged nine years, in whom the symptoms of this disease followed a wound from a knife, which was excised eighteen days after the injury, I found considerable cell accumulation between the ciliary muscle, and the pigment epithelium, just in the region where these glands are situated.

The dotted opacities on the back of the cornea are frequently spoken of as "keratitis punctata," a term which is of course inappropriate if this theory of their formation be correct, for they are not caused by an inflammation of the cornea but are deposits of inflammatory products on its posterior surface. In teased specimens of these deposits, besides round cells, pigment epithelial cells similar to those in the tubular down-growths of the ciliary body are occasionally found. The term "Descemetitis" for the condition in which these opacities are found is also inaccurate. I have a section of cornea with dotted opacities on its posterior surface in which the endothelium lining Descemet's membrane can be traced continuous and unaltered in front of the accumulations of round cells.

It is interesting to notice how a supposed analogy between the aqueous chamber and the large serous sacs of the body, such as the peritoneum and pleura, led to what for the patient must have been a very disagreeable form of treatment—viz., the internal administration of the oil of turpentine. Wardrop, Jacob of Dublin, and others thought the aqueous chamber to be a closed sac lined throughout with endothelium; this of course it is not, for posteriorly it communicates through the circumlental space with the vitreous, and the anterior surface of the lens capsule has no endothelial cells on it. Moreover,

the lining membrane on the back of the cornea is unlike that of a serous cavity, which consists essentially of a layer of endothelial cells with blood-vessels external to them. Perhaps the most striking difference between the aqueous chamber and the serous sacs is that the former is a cavity containing fluid, while the latter in the normal state are only potential cavities whose walls are lubricated with fluid. Dr. Carmichael of Dublin, relying on this supposed analogy and on the apparently beneficial effect which turpentine administered internally had on cases of peritoneal inflammation, recommended the administration of the same drug when the supposed lining serous membrane of the aqueous chamber was the seat of disease. This treatment is still prescribed by some surgeons even at the present day.

Besides the glands and secreting area of the ciliary body being primarily affected by a catarrhal inflammation, they may also become secondarily involved by inflammation starting in other structures of the eye; or in the course of a general disease in which the uveal tract is implicated the ciliary body may be the first part to be inflamed. In sympathetic ophthalmitis the early symptoms are similar to those described as typical of "aquo-capsulitis" or "serous iritis." The most striking and constant change revealed by the microscope in eyes affected with sympathetic ophthalmitis is the presence of groups of round cells scattered throughout the uveal tract. It can be easily understood that such an inflammatory nodule occurring in the situation of the glands of the ciliary body would cause the exudation of inflammatory products from them, which would be partly carried forwards into the anterior chamber and partly effused into

the vitreous. In eyes affected with sympathetic ophthalmitis I have frequently found nodules of cells of this character thus situated. In the same way, should one of the nodules of round cells which occur in syphilitic uveitis be located in the glandular region of the ciliary body a like effusion would be expected and similar symptoms. Dots on the back of the cornea, deepening of the anterior chamber, and opacities in the vitreous are often met with in syphilitic affections of the eye.

SUPPURATIVE AND PLASTIC INFLAMMATION OF THE
SECRETING AREA OF THE CILIARY BODY.

In suppurative inflammation of the eye it is quite common to find purulent infiltrations of the vitreous obviously starting from the ciliary body, and pus cells can be traced forwards from the latter, between the iris and lens, into the anterior chamber, where an accumulation is seen at the lower part, constituting a hypopyon. When inflammation of the ciliary body is of a plastic character the inflammatory bodies infused into the vitreous organise into fibrous tissue, and a band of fibrous tissue forms behind the lens across the ciliary region. This is spoken of as a cyclitic membrane; to it the detached retina is frequently adherent. In such cases there is often considerable overgrowth of the pigment epithelium of the ciliary body. This overgrowth presents a characteristic arrangement of its cells in the form of cylindrical gland-like tubes (Plate II., fig. *a*). Just as in chronic inflammation of other glandular surfaces hyperplasia of the glandular structure occurs, so here. I cannot do

better than quote a description of this condition which has been given by Alt,* and with which my own observations quite coincide. Speaking of plastic cyclitis and cyclitic membranes, he says:—"Meanwhile the cells of the uveal layer have also undergone proliferation. The whole layer appears very much thickened, and grows into the cyclitic membrane in an irregular way. We also observe, however, frequently a more typical kind of proliferation of the cells of the uveal layer in the shape of cylindrical tubes, which grow into the cyclitic membrane and give off branches. In longitudinal and transverse sections these tubes appear like the glandulæ tubulosæ, or the epithelial cylinders of epithelioma. The cells of these tubes are either free of pigment or pigmented. Their shape and arrangement with their branches have given some writers (Schieff-Gemusens) the idea that they were blood-vessels whose walls were filled with pigment. Specimens in which the blood-vessels have been injected with a coloured fluid, however, plainly show that they are different from blood-vessels. They appear, as stated, just like glands or epithelioma cylinders. Not all the cells originating by proliferation from the uveal layer are pigmented, and I am even convinced that the young cells of this layer are at first always unpigmented and form their pigment only later on. For this reason we find in cyclitic membranes the same tubular formations without any pigment at all, which can nearly always be traced backwards to a pigmented cell tube or the uveal layer itself." He gives woodcuts showing these cylindrical tubes.

* "Lectures on the Human Eye," p. 106.

CYSTS OF THE GLANDS OF THE CILIARY BODY.

It is by no means uncommon to meet with cystic spaces in the region of the ciliary body in eyes affected with very different diseases. Many of these spaces are due to the detachment of the pars ciliaris retinæ from the pigment epithelium. Brailey,* writing on this subject, says:—"I have found even in the course of my usual microscopic examination the pars ciliaris retinæ detached from the subjacent pigment layer in about 10 per cent. of the cases of primary glaucoma. These detachments are frequently so localised as to give the appearance of little fluid-containing cysts, but sometimes they are of considerable extent. Very similar changes are found in association with the cyclitis which accompanies the disease, known clinically as iritis serosa. In this condition, however, the cysts contain some corpuscular elements." Kuhnt† mentions that he has frequently found cysts in the ciliary body due to the detachment of the pars ciliaris retinæ from the pigment epithelium as a senile change in eyes which have been altered by atrophic processes. Cysts due to the distension of the small tubular glands which I have found to exist in the ciliary body, should they occur, would differ from those due to the detachment of the pars ciliaris retinæ from the pigment epithelium in being bounded entirely by pigment cells. I have one specimen from an eye which had had cyclitis showing such cysts.

* "Royal London Ophthalmic Hospital Reports," vol. x., p. 384.

† "Klinisches Monatsblatt," 1881, p. 48.

ADENOMA AND CARCINOMA OF THE CILIARY BODY.

Alt, in his book entitled "Lectures on the Human Eye,"* mentions and pictures what he calls "a tumour-like new formation of pigmented and unpigmented cell cylinders, starting from the uveal layer of the ciliary body and neighbouring choroid." The woodcut shows very distinctly tubules lined by epithelial cells, cut transversely and longitudinally. This tumour-like new formation growing in the region where I find these tubular glands, I regard as an adenoma.

Professor Michelt† removed the right eye of a woman, aged forty-one years, who had always enjoyed good health, for what was supposed to be a melanotic sarcoma growing from the posterior surface of the iris and invading the ciliary body. Pathological examination of the eyeball showed that the growth, which was gray in colour, sprang from the ciliary processes. Microscopically the iris and ciliary muscle were seen to be quite free from any pathological formation, and the growth was found to consist of a mesh of connective tissue, in some of the spaces of which there were rows of cylindrical cells, arranged, he says, so as to present the appearance of a tubular gland.

He concluded by describing the growth as endothelial and epithelial cancer.

Amongst the specimens preserved in the laboratory of the Royal London Ophthalmic Hospital, Moorfields, I found an eye removed from a woman aged sixty-

* *Ibid.*, p. 123.

† "Archiv für Ophthalmologie," B. xxiv., Ab. 1, S. 140.

three years, who twenty-five years previously had had a severe blow on it from a fist, and two years subsequently had found that it was blind. It gave her no trouble until nine weeks previous to enucleation, when pain and inflammation set in. Except for the eye trouble she was in good health, and continued so for twenty-three months after its removal; since that time she has changed her address, and I have been unable to trace her. The eye contained a growth which was partially deeply pigmented, and sprang from the ciliary processes, invading the ciliary muscle and root of the iris. It was originally described as a sarcoma which had undergone mucoid degeneration. It was afterwards re-examined and shown by Mr. Solly at a meeting of the Pathological Society of London on April 15th, 1891, as "a melanotic growth from the eye which appeared to be epithelial." I have cut some more specimens from this tumour and bleached them; there can be no doubt of the epithelial character of the cells (Plate II., fig. *b*). In some parts of the tumour they have undergone colloid degeneration: while in others, especially towards its base, which is the most pigmented part, they are grouped in parallel columns, cut in various directions. This growth I regard as a melanotic glandular carcinoma. As melanotic carcinoma is practically unknown in other parts of the body and it is extremely unlikely that a primary non-pigmented growth would give rise to a secondary deeply pigmented one, and as the patient made no complaint of any other growth during the two years she was under observation, I think there can be no doubt that the tumour was a primary one of the ciliary body.

In March, 1893, Messrs. Badal and Lagrange* recorded a case which they described as a primary carcinoma of the ciliary body. The patient under their care was a boy aged eight years. A peculiar appearance was noticed in his left eye soon after birth. When about five years old it became quite blind, and shortly afterwards commenced to enlarge. At the time of excision it was injected, there was a staphylomatous condition in the ciliary region, and by oblique illumination a rose-coloured reflex was obtained. A year after excision the child was in good health, and there was no sign of recurrence. Pathological examination revealed a new growth confined to the ciliary region, and consisting of two unequal whitish nodules placed alongside each other. Microscopically the growth was seen to be composed of (1) regular tubules with a central lumen lined by a single layer of cylindrical epithelium; (2) similar tubules, filled with proliferating epithelial cells; and (3) collections of atypical and deformed epithelial cells grouped and separated by thin strands of connective tissue.

At the December meeting of the Ophthalmological Society in 1893 I showed a primary tumour of the ciliary body exhibiting glandular structure. It was removed by Mr. Rockliffe, who sent it to me for examination. The patient was a woman aged twenty-eight years; for six months she had noticed failure of vision in the eye, but it had only recently become inflamed and painful. Her health otherwise was quite good, and she had no symptoms of growths in any other part of the body. On section of the tumour the anterior part of it was seen to be deeply pigmented; the posterior part was devoid of

* "Archives d'Ophthalmologie," 1892, p. 143.

pigment. Microscopically, the cells composing the central portions of the growth appeared very degenerate; they were much swollen and their outlines ill-defined. The more peripheral parts were less degenerated; the cells here were of epithelial character, and arranged in a way suggestive of a glandular structure.

To sum up, then, I find that there are situated in the region which experiments have proved to be the part from which this aqueous humour and nutrient fluid of the vitreous are secreted numerous little tubular processes of epithelial cells, which I can imagine to be nothing else than glands concerned in their elaboration: that the nature of these processes has been hidden by their pigment, and is only rendered evident in bleached sections; that these glands and other secreting cells of the ciliary body are, like secreting structures elsewhere, subject to attacks of catarrhal inflammation, which gives rise to the group of symptoms generally included under the term "serous iritis"; that as the result of chronic inflammation there may be considerable overgrowth of their tissue, which overgrowth preserves a glandular type; that they may become distended into little cysts, and that they may be the seat of tumours, either adenoma or glandular carcinoma.

CHAPTER IV.

IMPLANTATION OF EYELASHES INTO THE EYE. IMPLANTATION EPITHELIAL CYSTS OF THE EYE. ENDOTHELIAL CYSTS OF THE IRIS. GLIOMA OF THE RETINA NOT SARCOMA. DEVELOPMENT OF THE CHOROID AND ORIGIN OF THE MEMBRANE OF BRUCH. EXTRAPAPILLARY COLOBOMATA.

IMPLANTATION OF EYELASHES INTO THE EYE.

TOWARDS the termination of Shakespeare's play of "Richard the Third," the king rushes in shouting the well known words, "A horse! A horse! my kingdom for a horse," he meets Richmond, they fight and Richard is slain. That celebrated tragedian the late Barry Sullivan was once acting the part of Richard, when Richmond during the fight accidentally injured Mr. Sullivan's eye with his sword. Mr. Critchett, who has recorded the incident* saw Mr. Sullivan about six weeks after the accident and found that an eyelash had been driven into the anterior chamber.

It might be thought that the implantation of an eyelash into the anterior chamber is a very unusual form of accident. A number of cases have, however, been recorded in which it has occurred.

A punctured wound with such an instrument as a rapier or a knife seems the most likely sort of injury to bring it about.

In a case recorded by Sweiggert† as many as six eye-

* "Trans. Ophth. Soc.," vol. xi., p. 125.

† "Ophth. Soc. of Heidelberg," 1871.

lashes were found in the anterior chamber after a wound with a rapier. I have examined an eye which was wounded with a knife in which three eyelashes were implanted through a wound of the cornea three millimeters from its margin, into the vitreous chamber.

When an eyelash has been lying in the eye for a considerable time, it may become partially surrounded by or connected with an epithelial pearl-like tumour, the starting point of which seems to be the root-sheath of the hair.

This is what had occurred in a case described by Mr. Richardson Cross and myself* and also in those recorded by Rockliffe†, Stoeber‡, Pamard§, Monoyer||, Rothmund,¶ Sweigger,** and Masse.†† That the origin of the growths is that suggested was conclusively proved by the last named observer, who produced some of a similar character by planting eyelashes into the anterior chamber of rabbits' eyes.

In Rockliffe's, Stoeber's, Pamard's, and Cross's cases one eyelash only was carried into the eye and one tumour only grew. In Monoyer's case there was one eyelash but two tumours, one apparently unconnected with the hair.

In Rothmund's, Sweigger's, and Masse's cases several lashes were seen in the anterior chamber, in the first two only two growths appeared, and in the last three; Masse's

* "Transactions of the Ophthalmological Society," vol. xiii., p. 199.

† "Transactions of the Ophthalmological Society," vol. iii., p. 26.

‡ "Klin. Monatsbl. f. Augenheilk.," B. ii., Sept., 1864.

§ "Annales d'Oculistique," t. v., p. 157.

|| "Gaz. Méd. de Strasbourg," 1872.

¶ "Klin. Monatsbl. f. Augenheilk.," B. x., S. 189.

** Ibid.

†† "Kystes, tumeurs perlées et tumeurs dermoïdes de l'iris," p. 48.

case is of considerable interest because it is the only one in which the growth or the eye was not removed. At the end of five years one of the tumours is said to have grown to the size of a large bean and to have become adherent to the cornea, the other two had remained stationary as small white points.

The essential pathological characters of the tumours in all the cases would appear to be the same.


All of them were composed of epithelial cells, and all of them presented a white mother of pearl like appearance on section, due to cholesterine crystals contained in them.

The one I examined microscopically demonstrated well that these tumours are essentially cystic, having a lining of well developed laminated epithelium, and a semi-solid contents of degenerate epithelial cells and fat globules (Plate III., figs. *a* and *b*). In some of the cases the growth has been found free in the anterior chamber and in others it has developed in the iris.

IMPLANTATION EPITHELIAL CYSTS OF THE EYE.

It being proved then, that tumours of the iris may develop from the root sheath of a hair, when it is implanted together with the hair into the anterior chamber, it seemed probable that portions of the surface epithelium unconnected with hairs, implanted into the interior of the eye might similarly proliferate and develop into cystic growths.

A large majority of the cysts of the iris which are met with, occur in eyes in which there have been perforating wounds.



DESCRIPTION OF PLATE III.

Fig. a. Section of the anterior half of an eye with a cyst in the iris, following on the implantation of an eyelash into the eye. The square to which (*a*) points, is the part shown in *Fig. b* more highly magnified. $\times 10$.

Fig. b. $\times 300$.

- A. Contents of cyst.
- B. Epithelial lining of cyst.
- C. Iris.
- D. Lens capsule.
- E. Lens.

PLATE III.

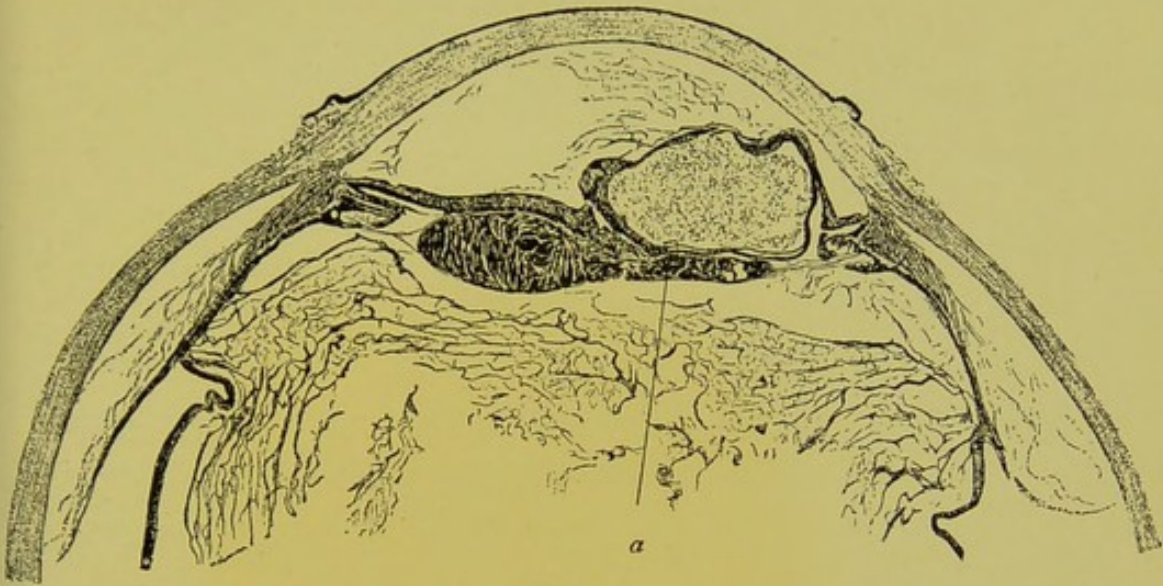


Fig. a.

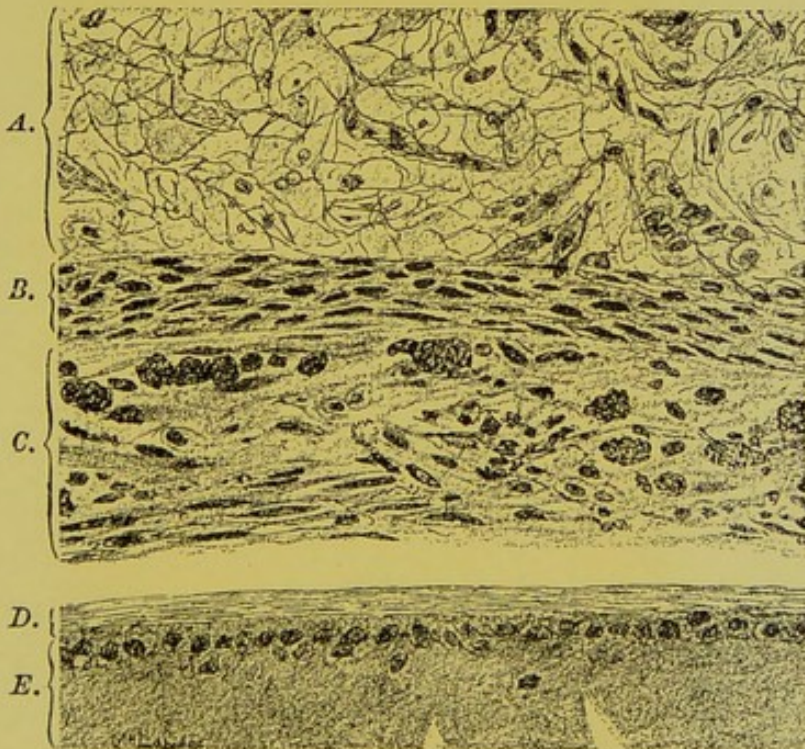


Fig. b.



Mr. Hulke* suggested in 1867, "that in some instances, perhaps, the cyst may originate out of a portion of Descemet's membrane, which may have been torn away from the back of the cornea by the penetrating foreign body and carried before it into the iris." Cysts of the iris which follow wounds of the eye, are as a rule found to be lined by laminated epithelium, and it seems more probable that it is the surface epithelium which is implanted and which forms the starting point of the cyst, rather than the endothelium on Descemet's membrane.

Masse† in 1881 introduced into the anterior chamber and grafted on the iris of rabbits' eyes small pieces of conjunctiva and skin, and subsequently in 1883 bits removed from the surface of the cornea, from these grafts he found develop both epithelial pearl-like tumours and true cysts.

In the shrunken eye of a man aged 40, which had been injured 28 years previously by a "tip-cat," and which was excised for recurrent attacks of pain, I found a large cavity measuring in its greatest lateral diameter 12 mm. and in its greatest antero-posterior diameter 11.5 mm. (Plate IV., fig. *a*). Microscopical examination of this eye showed, the whole of the interior of the cavity to be lined by laminated epithelium exactly resembling that on the anterior surface of the cornea (Plate IV., fig. *b*). It also showed near the corneal margin on one side a cicatrix leading down to the cyst, embedded in which was a second small cyst lined by laminated epithelium. The structures in the interior of the globe were barely recognisable. Here and there some remnants of iris tissue could be made out between the cornea and the

* "Ophthalmological Hospital Reports," vol. vi., p. 12.

† Ibid.

lining epithelium of the large cyst. The lens was absent. The atrophied retina and shrunken remains of the vitreous were much displaced backwards. I think that in this case there can be little doubt that the cyst was the result of implantation of a piece of the surface epithelium into the interior of the eye, at the time of the wound 28 years previously. The cyst probably commenced in the iris, and by its gradual expansion displaced all the structures in the interior of the globe. It is, I believe, the largest implantation cyst of which a description has been published.

In July, 1889, Mr. Richardson Cross extracted a catar-

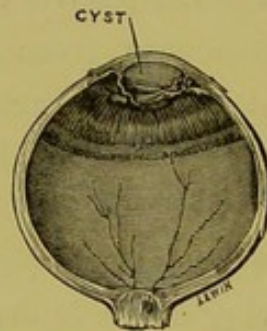


FIG. 18.—Epithelial implantation cyst forming in the anterior chamber after extraction of cataract.

act with iridectomy, from the left eye of a lady aged 64; the operation was performed without any complications. Three months later the patient with glasses was able to see $\frac{20}{80}$ and J. 2. Seven months after the operation an acute attack of glaucoma set in and the sight rapidly failed. The eye was excised one year and eight months after the extraction of the cataract. On pathological examination of the eye I found a large cyst lined by laminated epithelium filling the anterior chamber and coloboma (figs. 18 and 19). The iris partly embraced the lower margin and sides of the cyst and where it was not in contact with

the cyst it lay against the posterior surface of the cornea. The epithelium from which this cyst originated was implanted probably at the time of the operation. I have met with another very similar case, in which the way the epithelium was probably carried into the eye is more obvious. On the conclusion of the operation the anterior chamber was irrigated out with a solution of bin-iodide of mercury 1 in 25,000. A striated haze of the cornea followed and persisted. An opaque membrane filling the coloboma was subsequently needled, after which the eye for a long time remained injected and irritable. The vision became reduced to hand reflex, and two years after

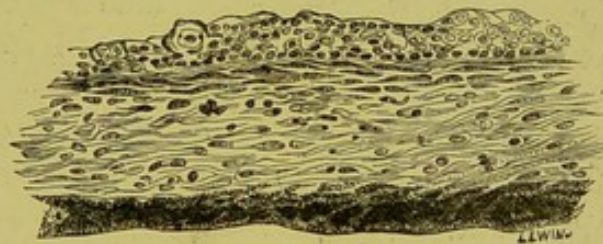

FIG. 19.—Microscopical section showing the lining epithelium, on the surface of the iris, of the cyst in figure 18.

the extraction of the cataract the eye was excised. A cyst was then found lined by laminated epithelium filling the anterior chamber.

Cysts lined by laminated epithelium are sometimes met with in the substance of the cornea as well as in the iris and anterior chamber.

The first of these, I found, was in the eye of a man aged 27, who 18 months previous to excision had had a wound of it, and of the lower eyelid, from a shot. The shot had apparently carried before it into the corneal wound portions of the surface epithelium, microscopical examination of the scar formed in its track, revealed seve-

ral separate clumps of epithelial cells deep in the fibrous tissue of the cornea (fig. 20). In the larger patches there were spaces in the centre containing a hyaline substance, probably the coagulated remains of the fluid contents of the cyst.

My next specimen of corneal cyst was in an eye the sight of which had been destroyed after extraction of

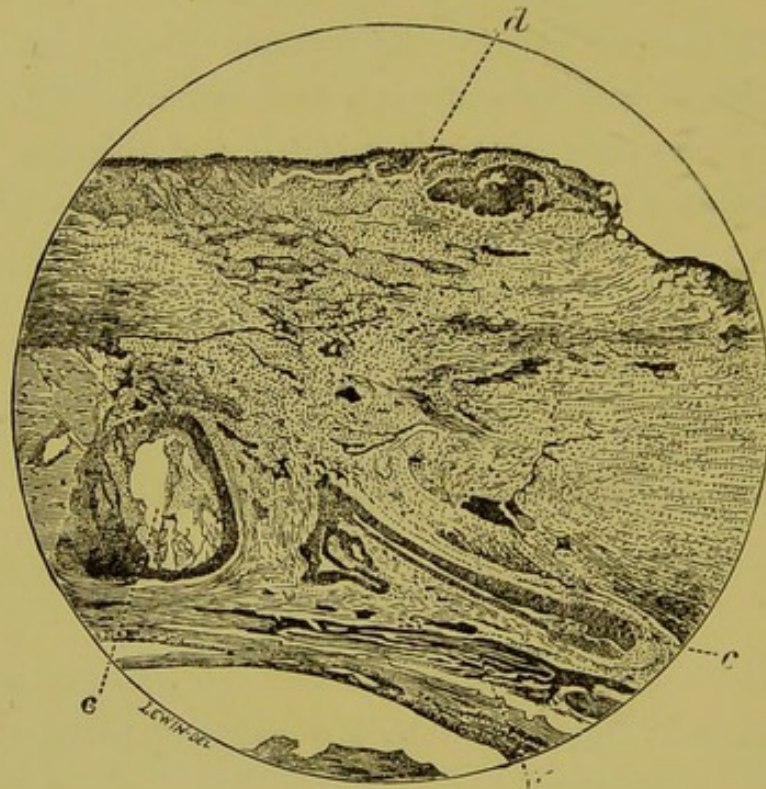


FIG. 20.—Epithelial implantation cysts of the cornea following a perforating wound with a shot.

c. Cysts. *d.* Bowman's membrane. *u.* Uveal pigment of iris.

cataract by the patient vomiting. It was excised twelve months after the operation when it had become somewhat shrunken, in the centre of the cornea was a large cavity lined by several layers of epithelial cells (fig. 21).

In the above two cases the cysts were only discovered on microscopical examination. In the next case the im-

plantation cyst of the cornea had grown to such dimensions that it was easily visible to the naked eye. The boy had run a stick into his eye, wounding the centre of the lower half of the cornea, two years and nine months previous to its excision. The iris adhered to the cornea at the seat of the wound, the tension became increased and the lower part of the cornea commenced to bulge

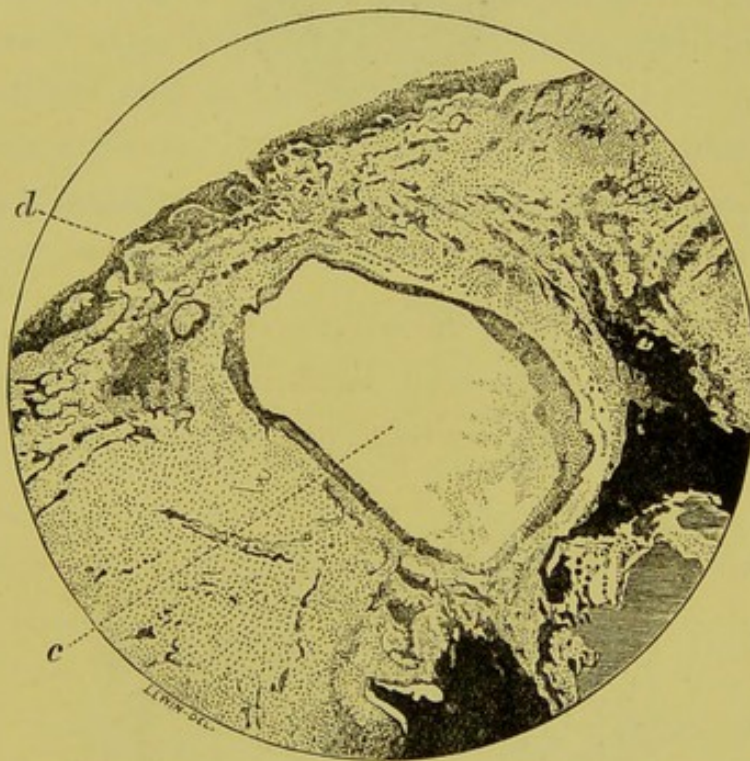


FIG. 21.—Epithelial implantation cyst of the cornea, in a shrunken eye after extraction of cataract.

d. Bowman's membrane. *c.* Cyst.

forwards. Two iridectomies were performed with the hope of relieving tension but were unsuccessful. The prominence of the lower part of the cornea continued to increase.

After removal of the eye a large cyst was found situated partly in the cornea and partly in the sclerotic

at the lower part (fig. 22). It measured 9.5 mm. laterally, and 5 mm. antero-posteriorly.

Microscopical examination showed the cyst to be lined by epithelial cells, several layers thick, those towards its

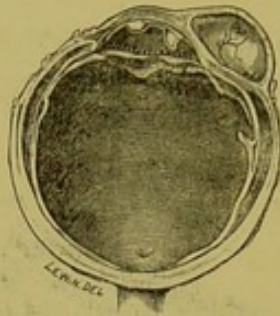


FIG. 22.—Section of eyeball showing epithelial implantation cyst of the cornea following a wound with a piece of wood.

interior being the most flattened and scaly (fig. 23). Here and there cells were seen swollen with large globules in them, as though undergoing mucoid degeneration.

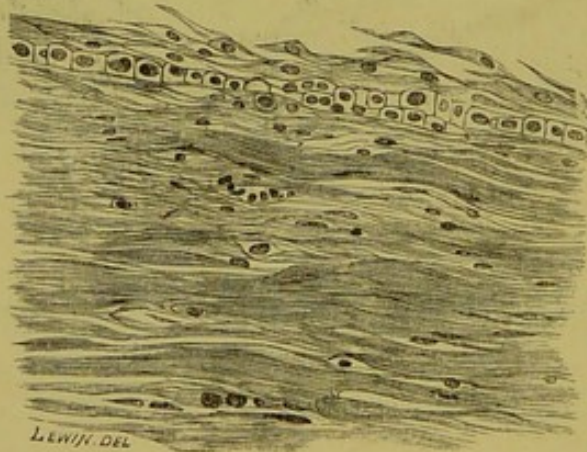


FIG. 23.—Laminated epithelium lining cyst shown in figure 22.

There was laminated fibrous tissue in front of the cyst and behind it. There was a gap in Descemet's membrane on the posterior surface of the cornea in the region of the cyst, where the iris was adherent, and had in its

substance a second smaller cyst, also lined by laminated epithelium, which was thicker than that in the corneal cyst, and exactly resembled the surface epithelium of the cornea.

I will now conclude this record of implantation cysts of the eye by mentioning one which I found situated between the conjunctiva and sclerotic. It occurred in a boy whose eye was removed when he was nine years old; when nine months old he had wounded it with a screw-driver and it had been blind ever since. A scar was seen extending vertically across the inner part of the cornea, and there was, what appeared to be, a cystoid condition of its lower part just beyond the corneal margin. Section of the eye, however, revealed a cyst with semi-translucent walls containing a clear watery fluid, lying between the conjunctiva and sclerotic, and not communicating with the anterior chamber. Microscopically the cyst was seen to be lined by laminated epithelium, and to overlie a band of dense cicatricial tissue which passed into the interior of the eye through the anterior part of the ciliary body.

The contents of implantation cysts in the eye vary. In most of mine they were gelatinous or watery. In the one which grew around an eyelash, the contents consisted of degenerate epithelial cells, cholesterine crystals and fat globules. Gräfe* has described a case in which the cyst was found to contain short hairs and sebaceous matter. One recorded by Strawbridget† "was lined with a layer of squamous epithelial cells, swollen, and in an advanced stage of fatty degeneration. These cells were

* "Archiv für Ophthalmologie," B. iii., Ab. 2, S. 412.

† "Trans. Amer. Ophth. Soc.," 1878, p. 385.

free from each other, and were surrounded by granular matter, fat, and cholesterine crystals." In Snell's case* the contents of the cyst are described as consisting of "a number of very large, clear, closely packed cells, like fat cells, in which no nucleus was discernible, of cholesterine crystals in great numbers, of a large quantity of fatty matter, both in the purely granular and oily forms, of pigment cells and granules in small quantity, of sparsely scattered tessellated epithelium, and of a homogeneous finely granular material."

This difference in contents probably depends on a difference in the character of the epithelium implanted. A portion of the epidermis or the root sheath of a hair, may give rise to a cyst with sebaceous contents; while a portion of the epithelium of the cornea or conjunctiva may give rise to one containing a mucous fluid.

ENDOTHELIAL CYSTS OF THE IRIS.

Besides the cysts of the iris due to separation of the two layers of pigment on the posterior surface of the cornea, and those due to implantation of the surface epithelium; there are others which appear to arise spontaneously, though they may follow on an injury, not necessarily a perforating wound. They are distinguished from the implantation cysts, by being lined by a single layer of endothelial cells, and not by laminated epithelium. I have proposed that these should be termed *endothelial cysts*, and the implantation cysts *epithelial cysts*, because the former I believe arise entirely from mesoblastic struc-

* ' Ophth. Hosp. Reports,' vol. x., p. 208.

tures, while the latter are produced by implantation of epiblastic tissue into subjacent mesoblast.

In a case of Mr. Nettleship's in which I had the opportunity of examining the cyst microscopically, it had commenced to grow without any apparent cause at the ciliary border of the iris, and ten months after it was first noticed measured 4.5 mm. in length, and 4 mm. in breadth.

Microscopically it was seen to be situated nearer the anterior than the posterior surface of the iris, and was lined by a single layer of flattened endothelial cells resting on a distinct basement membrane.

Schmidt-Rimpler* has offered a most reasonable explanation of the mode of formation of this class of cysts:—

“He considers that such cysts originate in the closure of one of the crypts always present in the iris. These crypts, according to Fuchs, dip into the iris tissue as deeply as the position of the vessels, and from the latter the lymph streams pass through them to the anterior chamber. These lymph streams have been demonstrated by experiments with fluorescin injection in rabbits (Schick). Anatomical researches, and especially the examination of the anterior surface of the iris by Zehender's binocular lens, have shown that these pits in the iris are frequently bridged over in front by bands, or completely by a thin membrane. In one instance, Fuchs observed (microscopically) a fine non-nucleated membrane closing the opening of a crypt.

“It seems legitimate to assume that such a membrane might become thickened as a result of disease, and thus

* “Archiv für Ophthalmologie,” B. xxxv., S. 1.

the anterior outlet of the crypt be occluded; the same pathological conditions might block any lateral communications between the crypt in question and adjoining ones, and the lymph would then be unable to escape into the aqueous. The gradual accumulation of this secretion would soon lead to dilatation of the cavity so formed, and its encroachment on the surrounding iris tissue. The endothelial lining membrane of the cyst, Schmidt-Rimpler thinks is derived from the endothelium which dips into the crypts from the anterior surface of the iris. Under the irritation of the enclosed lymph, growth of this normally existing endothelial layer occurs; and this lining membrane is thickest on the posterior wall of the cyst.*

GLIOMA OF THE RETINA NOT SARCOMA.

The development of the retina is a subject of great intricacy and one which requires further investigation. I have not myself made any special study of it, but in the examination of microscopical sections of human foetal eyes I have been struck by the fact that in those about the third month its layers are quite undifferentiated, that it is then composed entirely of a mass of round cells with large nuclei and scarcely any cell protoplasm, some of them, however, having little spicules projecting from them (fig. 25). These cells closely resemble those which are met with in gliomatous tumours of the retina (fig. 24). So close, indeed, is this resemblance that I feel sure that if a pathologist was shown a piece of foetal retina in which the layers were undifferentiated under the micro-

* Abstract in "Ophthalmological Review," vol. viii., p. 372.

scope, and was told that it was a piece of a tumour, he would have no hesitation in pronouncing it a glioma of the retina.

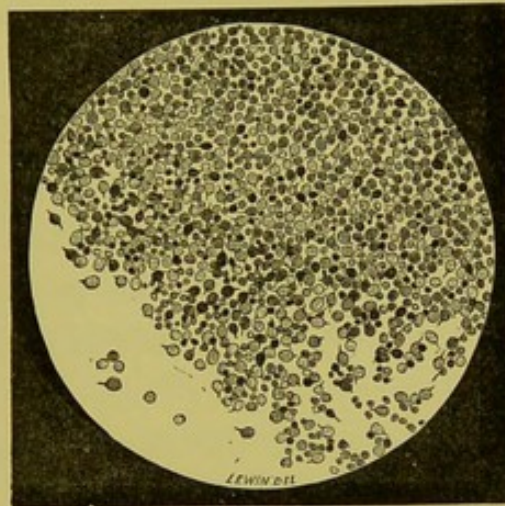


FIG. 24.—Microscopical appearances of glioma of the retina.

Glioma of the retina is usually classified in text-books amongst the sarcomata, and yet there are most striking

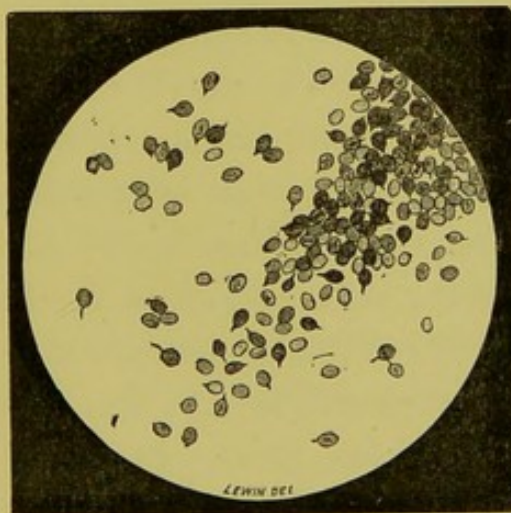


FIG. 25.—Microscopical appearances of the retina from a human fœtus between the third and fourth month.

differences between it and them. These differences may be divided into clinical, histological, and embryological.

The chief clinical difference relates to the age at which

the growths appear. Sarcoma in whatever part of the body it originates, may occur at any age: glioma of the retina on the other hand is confined to childhood, being usually noticed during the first two years of life and never occurring after eleven.

Secondary growths of sarcoma are more frequently met with in the internal organs and especially in the liver, than are secondary growths of glioma, the seats of predilection of which seem to be the periosteum of the cranial or facial bones, the glands about the jaw and the brain.

In about 20 per cent. of the cases of glioma of the retina both eyes are affected; sarcoma occurring in the eye is never bilateral.

Glioma of the retina is more malignant than sarcoma, but recurrence never takes place after three years immunity from the date of its removal. In a case of sarcoma of the choroid, on the other hand, a patient may after the removal of the eye, have an interval of ten years of good health, and then die with melanotic growths in the liver, which being pigmented must necessarily have been secondary to that in the choroid.

Histologically the cells of glioma of the retina differ from those of any round-celled sarcoma in having larger nuclei, less cell-protoplasm around the nucleus and little spicules projecting from them. In glioma of the retina there is a much greater tendency for the cells composing it to undergo degenerative changes than in a sarcoma. This tendency to degeneration is the cause of the patchy staining which sections of glioma always display; the nuclei of the surrounding parts staining less readily with logwood than the others. The cells in glioma of

the retina are always grouped around blood-vessels, those nearest the vessel walls staining the best; they are always round, with the exception of some which are occasionally met with arranged in rings one cell thick which are cylindrical in shape. None of the cells in glioma are ever spindle-shaped. In this again it differs from sarcoma, for wherever a round-celled sarcoma occurs there also a spindle-celled growth may occasionally be met with.

What may be termed the embryological difference between glioma and sarcoma is also very great. All sarcomata take origin in tissue which is derived from the mesoblastic layer of the blastoderm. The nervous elements of the retina and its neuroglia are formed from neural epiblast; the blood-vessels of the retina being the only parts of it developed from mesoblast. Sections of glioma of the retina in its early stages seem to show that it starts from the granular layers which are entirely epiblastic.

The resemblance, which exists between embryonic retina before its layers are differentiated and gliomatous tissue, suggests that just as sarcoma represents the foetal condition of the tissue in which it primarily grows, so glioma of the retina represents the foetal condition of the retina from which it starts, it being really a growth of neural epiblast.

DEVELOPMENT OF THE CHOROID AND ORIGIN OF THE MEMBRANE OF BRUCH.

In an early stage in the development of the eye the mesoblastic tissue which surrounds the secondary optic

vesicle consists of a mass of cells, there being no differentiation between the sclerotic and choroid coats. Later, in the part which is to become choroid the nuclei stain deeper and blood-vessels commence to appear. The cells of the part, which is to form the sclerotic, are gradually lengthened out and differentiated into fibres. The tissue between the two coats early becomes spaced out to form the lamina supra-choroidea and lamina fusca. The pigment in the branched cells of the choroid can be detected about the seventh month, but does not reach its maximum until after birth.* It is exceedingly difficult to determine the exact date of the commencement of the elastic lamina or membrane of Bruch. I have certainly been able to make it out as a very thin layer as early as the sixth month. Its origin and mode of formation cannot be determined by the examination of embryological specimens alone. As in the case of the lens capsule, I think some valuable suggestions may be drawn with regard to its origin from a study of some of the pathological processes which occur in connexion with it.

It is exceedingly common to meet in pathological specimens of the eye with little nodules of a hyaline substance on the inner surface of the elastic lamina, which present all the physical characters of that membrane. These hyaline or colloid bodies were originally described as a senile change, but they are met with in eyes which have been blind for some time from patients

* A. Rieke, in the "Archiv für Ophthalmologie," B. xxxvii., Ab. 1, 1891, gives the results of the examination of several fœtal eyes with reference to this point, and in conclusion says, that the first sign of the choroidal pigment is not seen till the seventh month, and that great variability exists as to when it makes its appearance.

of any age, and often quite apart from any signs of inflammation. Various opinions have been expressed as to their origin; these may be grouped under three heads, viz., (1) that they are thickenings of the hyaline membrane (Müller and De Wecker); (2) that they are due to a hyaline degeneration of the pigment epithelial cells lining the elastic lamina (Donders, De Vicenten, and Dimmer); and (3) that they are an excretion from the pigment epithelial cells (Leber and Meyer). *A priori*, it would seem more probable for these hyaline nodules to be the product of epithelial cells, rather than outgrowths from an inert basement membrane like the elastic lamina. Dimmer has pointed out that if they were only thickenings of the elastic lamina we should expect to find them extending outwards towards the choroid as well as inwards towards the retina, which we do not. Their presence always on the inner surface of the elastic lamina is readily understood if they are regarded as products of the pigment epithelium. That they are not outgrowths of the elastic lamina seems to me conclusively proved by the fact that they may be found where no elastic lamina is present. Thus, in a specimen I have examined of a microphthalmic eye which had a cyst connected with it, ill-developed retina was found lining the cyst, but no choroid; in the retina, however, there were hyaline bodies presenting all the characters of those under consideration. Hess* also found bodies of a similar character in the lining membrane of cystic protrusions of the sclerotic, where no choroid was present, in two pigs' eyes. That they are the product of epithelial cells I think there can be no doubt; whether they are formed

* "Archiv für Ophthalmologie," Band xxxviii., Ab. 3.

within the cells themselves or are an excretion from them cannot be so conclusively determined.

I have bleached several sections of eyes containing these hyaline nodules, thinking that when the cells were deprived of their pigment it would be easy to detect the presence of degenerative changes in them. The cells, which are often much flattened, are always outside the hyaline nodules, several of them often completely encircling the latter. The usual form of these hyaline or colloid bodies is that of little globules, the largest not so big as a pin's head. Occasionally, however, on the inner surface of the choroid much larger masses are met with, which are composed of layers of hyaline substance, with here and there flattened pigment epithelial cells between them. The appearance presented suggests that of numerous layers of the membrane of Bruch closely packed together. Such masses may occasionally be seen ophthalmoscopically as raised white elevations over which the retinal vessels course. I have known them diagnosed as sarcoma and tubercle of the choroid, the eyeball being enucleated accordingly. Their extreme chronicity is usually sufficient to distinguish them from these affections. Their position between the retina and choroid, the disturbance of the pigment epithelial cells around them, and the presence of some of these cells between the layers, all seem to point to the hyaline substance being the product of the pigment epithelium. Now, if it is possible for the pigment epithelium under the influence of a morbid stimulus, to produce a substance which stains and reacts to reagents in precisely a similar way to the elastic lamina itself, it is reasonable to suppose that that membrane is originally produced from them,

just as the hyaline capsule of the lens appears to be the product of the cells which line it. Additional evidence of this view of the origin of the elastic lamina is afforded by a case of cyst connected with a microphthalmic eye recorded by Rindfleisch,* in which the lining membrane of the cyst consisted of retina with well developed layers, pigment epithelium, and an elastic lamina, but no choroid. If the elastic lamina is derived from the pigment epithelium it is epiblastic in origin, and should, strictly speaking, be classed as a layer of the retina and not of the choroid.

EXTRA-PAPILLARY COLOBOMATA.

The choroid in places sometimes fails to develop, *i.e.*, the mesoblastic tissue which surrounds the secondary optic vesicle fails to become differentiated into choroid and sclerotic. The inner layers fail to become vascularised or only a few large vessels form. It would seem that when this failure in vascularisation occurs, the outer layer of the secondary optic vesicle in the part non-vascularised does not become pigmented, and at the margin of the patch there is often an excess of pigmentation. These patches of failure in the differentiation of the choroid give rise to what are known as colobomata. They occur, of course, most frequently in the region of the foetal ocular cleft, but may be met with, as pointed out by Lindsay Johnson†, in any part of the fundus.

* *Ibid.*, Band xxxvii., Ab. 3, p. 192.

† "Archives of Ophthalmology," vol. xix.

CHAPTER V.

CASES OF GLAUCOMA IN WHICH THE INCREASE OF TENSION IS DIFFICULT TO EXPLAIN. THE DEVELOPMENT OF THE IRIS. GLAUCOMA AND CONGENITAL ABSENCE OF THE IRIS. CONGENITAL ANTERIOR SYNECHIE OF THE PUPILLARY MEMBRANE AND IRIS. CONGENITAL GLAUCOMA OR BUPHTHALMOS.

CASES OF GLAUCOMA IN WHICH THE INCREASE OF TENSION IS DIFFICULT TO EXPLAIN.

THE pathology of glaucoma may not inaptly be compared to a large child's puzzle with many pieces of various and irregular shapes. Its framework has by the united efforts of many earnest workers been pieced together. Several important centre pieces, however, have yet to be added to make the picture complete. Some of these have probably been placed wrongly; every additional bit, however small, rightly inserted may, by forming some fresh curve or notch, suggest how the centre pieces should lie. I propose now to deal with some of these small bits, the shape and situation of which I have carefully studied. Of all the theories which have been put forward to explain the increase of tension in glaucoma, that which attributes it to the obstruction to the exit of the aqueous humour from the eye, and which has been so ably expounded and supported by Mr. Priestley Smith, is the most fascinating and apparently explains best the phenomena met with. There are, however, several classes of cases which at first seem to offer considerable difficulties

to its acceptance. If these at first sight exceptional cases can be shown really to be consistent with it, then great additional support will be afforded to the theory. These classes of glaucoma with which I now propose to deal are—(1) glaucoma occurring in eyes in which part or the whole of the iris is apparently congenitally absent; (2) congenital glaucoma, otherwise known as buphthalmos or hydrophthalmos; (3) glaucoma occurring after extraction of cataract; (4) glaucoma in cases in which the whole iris has escaped through a wound—*i.e.*, cases of traumatic aniridia; and (5) cases of primary glaucoma in which the operation of iridectomy has been preformed and in which the tension has returned.

THE DEVELOPMENT OF THE IRIS.

For the consideration of the first two of these classes it is necessary to refer to the development of the iris. Before the iris is formed there exists between the posterior surface of the cornea and the anterior capsule of the lens, the anterior portion of the fibro-vascular sheath. This receives its blood-supply partly from the ciliary arteries and partly from those in the posterior fibro-vascular sheath, which is prolonged forwards around the sides of the lens to join it. The anterior fibro-vascular sheath is developed by a differentiation and vascularisation of the posterior part of the mesoblast which grows in to separate the cuticular epiblast from the lens; the more anterior portion of this mesoblast developing into the substantia propria of the cornea and Descemet's membrane. The cornea, anterior fibro-vascular sheath and lens lie, then, at one time in close contact with one

another. Until the separation occurs of the anterior fibro-vascular sheath from the back of Descemet's membrane there is not even a potential anterior chamber. The iris, as it grows out of the ciliary body, consists of some mesoblastic cells and of the two layers of the secondary optic vesicle, the posterior of which is at first only slightly pigmented. It has to insinuate itself between the cornea and the anterior fibro-vascular sheath on the one side, and the lens on the other, pushing the prolongation from the posterior fibro-vascular sheath in front of it. The anterior fibro-vascular sheath, when the iris has grown in, becomes raised from the surface of the lens capsule, and forms the pupillary membrane, which subsequently disappears as far as the small circle or corona of the iris. Tags of it when persistent can be seen proceeding from the toothed edge of this corona.

GLAUCOMA AND CONGENITAL ABSENCE OF IRIS.

It is not at first evident, if primary glaucoma is due to an obstruction to the exit of the aqueous humour from the eye by the apposition of the root of the iris to the periphery of the cornea, how, when the iris is apparently absent in part of or in its entire circumference, glaucoma can develop.

I have been fortunate in having three specimens which help to explain these cases, for two of which I am indebted to Mr. Nettleship. The first is from the patient I have already referred to in speaking of anterior polar cataract, who had apparent complete congenital absence of both irides. The second is from the mother of this patient, who also had apparent complete congenital

absence of both irides, and in one eye a leucomatous staphylomatous cornea, with increased tension, secondary to ulceration of the cornea. The third was from a man aged thirty-six years, who had congenital coloboma of the iris outwards and absolute primary glaucoma. In the first case, though no iris could be detected clinically, on peeling off the sclerotic and cornea a small rudimentary iris was exposed in its entire circumference; it was broadest on the outer side, where it measured 2 mm. in length, above it measured 0.75 mm., it was slightly

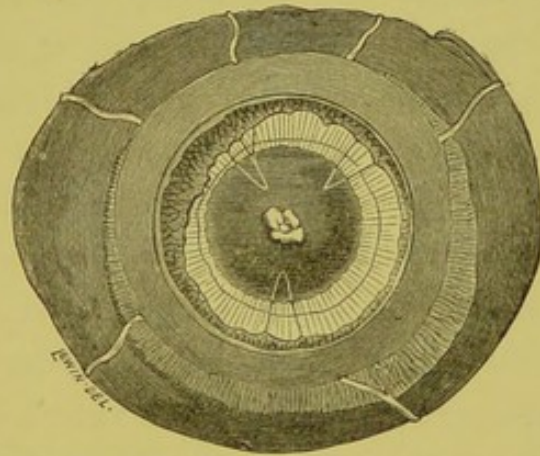



FIG. 26.—Anterior half of the right eye of a patient with apparent aniridia from which the cornea and sclerotic have been removed, exposing a rudimentary iris, tags of pupillary membrane, lens with an anterior polar opacity, and fibres of the suspensory ligament.

broader above than below, and was narrowest of all on the inner side (fig. 26). In removing the cornea it was noticed that the iris was abnormally adherent at its periphery. Throughout the entire circumference of this rudimentary iris the uveal pigment showed at what corresponded to its pupillary border. Some delicate tags, remnants of the pupillary membrane, could be seen passing from the anterior surface of the iris to the lens capsule.

Of the left eye microscopical sections were made; in these the cornea appears perfectly healthy. The ciliary body on each side of the section is seen to end in the rudimentary iris, above measuring 1 mm., but much smaller below; the whole of the iris tissue appears more condensed than usual (Plate IV., fig. c). Above, the free margin extends just beyond a line drawn backwards on a level with the termination of Bowman's membrane. This line corresponds to the apparent sclero-corneal margin clinically, the real corneal margin being an oblique line extending posteriorly, to the angle of the chamber. Below, the tip of the iris does not extend beyond the termination of Descemet's membrane in the ligamentum pectinatum. A small rudiment of the sphincter muscle is distinguishable in the upper part of the iris, but not below. The uveal pigment ends on both sides in a double fold; above, it extends a short distance beyond the stroma. One section shows a tag of membrane prolonged from the anterior surface and floating free, a remnant of the pupillary membrane. In some sections delicate bands of adhesion are seen to pass from the anterior surface of the iris to the ligamentum pectinatum; these do not, however, go up into the extreme periphery of the anterior chamber. In this case, then, though clinically apparently no iris was present, there was really a rudimentary one, which if pushed forwards, would be quite sufficient to block the whole of the posterior surface of the ligamentum pectinatum. Owing to the obliquity of the sclero-corneal margin the periphery of the iris is hid from view, and when it is very small, as in this case, none of it may be visible.

In the left eye of the second case, the mother of the



DESCRIPTION OF PLATE IV.

- Fig. a.* Section of a shrunken eyeball showing the extent of a large epithelial implantation cyst in its interior.
- Fig. b.* The lining laminated epithelium of the cyst shown in *Fig. a.*
- Fig. c.* Section of an eye, showing a rudimentary iris, in which clinically no iris was visible. A persistent tag of pupillary membrane is attached to the tip of the iris, and an adhesion stretches between its root and the ligamentum pectinatum.
- Fig. d.* Section of an eye which had congenital coloboma of iris and lens, and in which glaucoma occurred. The iris is seen to be absent, but the filtration area of cornea is blocked by a fold in which the ciliary body terminates; the ciliary processes slope backwards.

PLATE IV.

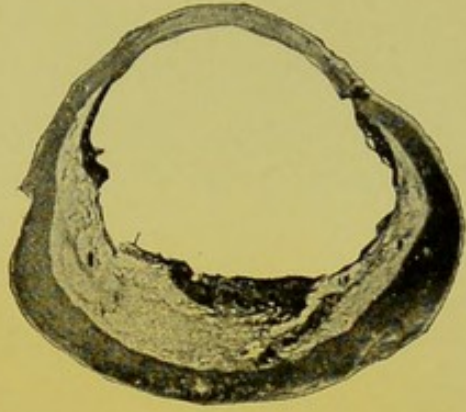


Fig. a.



Fig. b.

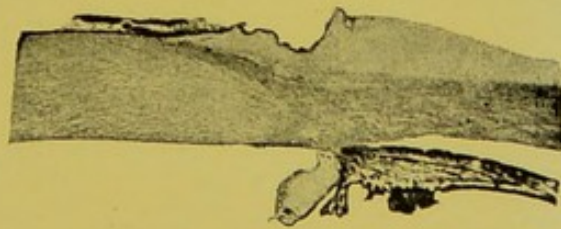


Fig. c.

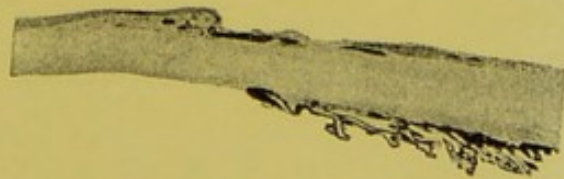

Fig. d.



first, there was increased tension; a rudimentary iris, similar to that in her daughter, had become pushed forwards into contact with the periphery of the cornea and was intimately adherent to it (Plate V., fig. *a*). Why it should have become thus pressed forwards from a perforating ulcer of the cornea was not evident; possibly the extensive hæmorrhage which there had been between the choroid and sclerotic may have had something to do with it. In the third case, the one with congenital coloboma of the iris outwards and primary glaucoma, the ciliary body in the region of the coloboma ends in a rounded knob, which is in contact with the back of the cornea (Plate IV., fig. *d*). The termination of this knob, however, does not reach as far as the end of Descemet's membrane, so that the whole of the posterior surface of the ligamentum pectinatum is not blocked by it. The uveal pigment on the back of this knob-like termination of the ciliary body is composed of two layers united at the tip, the posterior being much thicker than the anterior.

Just where these end on the posterior surface of the ligamentum pectinatum there is a little accumulation of fibres and cells; from it the endothelial lining of Descemet's membrane passes inwards, and a layer of cells outwards beneath the pigment on the termination of the ciliary body; this layer of cells may possibly be a persistence of the prolongation forwards from the posterior fibro-vascular sheath which joins the anterior. From the arrangement of this knob at the termination of the ciliary body, with a layer of unpigmented cells behind it, I should think that it had never become separated from the cornea rather than that it had recently become pushed

forwards into contact with it; so that probably there had always been obstruction to the exit of fluids in this situation, and the onset of the glaucoma was determined by the root of the iris in the rest of its circumference becoming displaced forwards. In a case like this, then, there would be a congenital predisposition to glaucoma. In the first case, although no increase of tension was ever established, there would seem to have been a predisposition to it, for, as I have said, tags of adhesion, not sufficient to block the angle of the chamber, passed across between the rudimentary iris and the ligamentum pectinatum.

Several cases have now been published in which the iris was entirely or in part absent, and in which the eye became glaucomatous. Brailey* showed at the Ophthalmological Society a girl eighteen years of age with double microphthalmos and glaucoma; the iris was absent in her right eye except for a narrow crescentic piece on the inner side which occupied about two-fifths of the circle, and absent in the left except for three small isolated bits, also on the nasal side. Armaignac† reports a case of glaucoma secondary to dislocation of the lens in a patient with nearly complete aniridia.

I recorded in the "Ophthalmic Review,"‡ 1891, the notes of a patient under the care of Mr. Tay who had apparent complete absence of the irides in both eyes and increased tension of both. De Schweinitz§ read before the American Ophthalmological Society the description

* "Transactions of the Ophthalmological Society," vol. x., p. 139.

† "Memoires et Observations d'Ophthalmologie Pratique," p. 239.

‡ Vol. x., p. 101.

§ "Transactions of the American Ophthalmological Society," 1891.

of a case with coloboma of the iris, polycoria, and primary glaucoma in a woman aged fifty-two years.

There is a practical point in connexion with these cases which follows as the outcome of my observations—that is, that the apparent complete congenital absence of the iris or the presence of a congenital coloboma of the iris, does not diminish the likelihood of relief of tension being obtained by a sclerotomy in the former case, or an iridectomy in the latter.

It is but seldom that an opportunity offers itself for the microscopical examination of an eyeball with apparent aniridia. I have only been able to discover two in which the result of such an examination is recorded. H. Pagenstecher* in 1871 was the first to give a description of the microscopical characters of a case of irideremia. In his case the ciliary body ended in the region of the ligamentum pectinatum in a small, pointed, pigmented, and vascular process; and a prolongation of Descemet's membrane with the endothelium lining it passed beneath this process to the ciliary body. G. Rindfleisch† has given an excellent microscopical description of a case, together with a *résumé* of the literature of the subject. His case was that of a woman aged fifty-one years, who presented the typical symptoms of irideremia in both eyes. She had nystagmus, some amblyopia, and some opacities of the corneæ and lenses, the latter being displaced upwards. Microscopically he found, considerable encroachment of the episcleral tissue on the cornea, some hyaline excrescences on Bowman's membrane, and a triradiate deposit of pigment

* "Klinik für Augenheilkunde," Band ix., S. 425.

† "Archiv für Ophthalmologie," Bd. xxxvii., Ab. 3, S. 192.

on Descemet's membrane. At the lower sclero-corneal margin there was the scar of a perforation. A rudimentary iris was present, but its sphincter muscle was completely absent. It was closely approximated to the cornea, the angle of the chamber appearing pointed. The ciliary body was badly developed, and its processes were directed backwards.

Manz suggested that the arrest in the development of the iris in cases of aniridia is due to the contact of lens and cornea mechanically preventing its growth inwards. Rindfleisch agrees with Manz, and attributes the contact of lens and cornea in his case to intra-uterine inflammation, beginning in the choroid, extending forwards, and causing perforation near the sclero-corneal margin with escape of aqueous. In my specimens no sign of a perforation is to be seen either in this region or in the cornea. The sclero-corneal margin is a very unusual position for a perforation to occur in, and it seems unlikely that a bilateral affection, as irideremia usually is, would be caused in this way. It is, moreover, unnecessary to have a perforation for the lens to come in contact with the cornea, for at the time the iris is developing these structures are in apposition, the anterior fibro-vascular sheath alone intervening; there is, then, no anterior chamber or aqueous. We have only to imagine an abnormal adhesion or late separation of these structures to understand how the iris may be prevented from growing in. The adhesions between the front of the rudimentary iris and the ligamentum pectinatum, the folded condition of the uveal pigment at tip of the iris, and the presence of an anterior polar cataract in the case I have examined, are all in

keeping with such a theory. If arrest of development of the whole iris can be explained in this way it follows that, supposing the late separation or abnormal adhesion of lens and cornea to be localised, a localised arrest of development of the iris would be occasioned. In this way might be explained cases in which a coloboma of the iris is situated in a position in which it is inconceivable that the fœtal cleft could ever have existed, and also the rare cases in which two colobomata of the iris have been seen to exist in the same eye.

CONGENITAL ANTERIOR SYNECHIÆ OF THE PUPILLARY MEMBRANE AND IRIS.

The anterior fibro-vascular sheath is, as I have said developed from the posterior part of the mesoblast, which grows in to separate the lens from the cuticular epiblast, the anterior part forming the cornea. It can be easily understood that a portion of the anterior fibro-vascular sheath might remain after birth adherent to the cornea. The iris grows beneath the peripheral portion of the anterior fibro-vascular sheath, which comes to form its anterior layer; an adhesion of the anterior fibro-vascular sheath in this region to the back of the cornea would form an anterior synechia of the iris. The central portion of the anterior fibro-vascular sheath forms the pupillary membrane, which usually disappears before birth; occasionally a portion of it persists, and may be attached to the back of the cornea. Cases of adhesion of persistent pupillary membranes to the back of the cornea have

been recorded by Beck,* Samelson,† Makrocki,‡ and Zinn,§ In these cases there seems to have been a possibility that the adhesions were caused by intra-uterine perforation of the cornea. I have a specimen of this sort in which no such possibility was at all likely. It occurred in an eye to which I have already referred. In it the central artery of the vitreous was persistent and patent, ending behind the lens in a fibro-cellular mem-

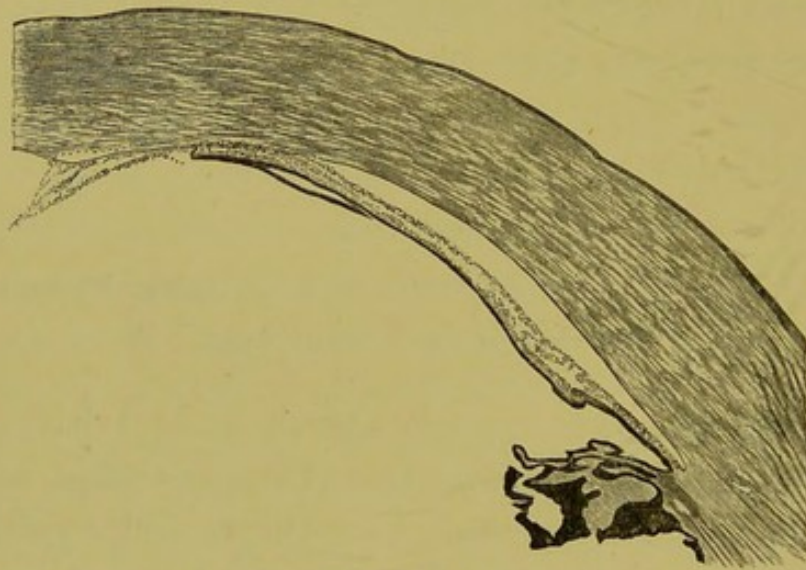


FIG. 27.—Congenital anterior synechia of a persistent pupillary membrane and of the iris.

brane, which was seen through the lens as a grey reflex, which led to the diagnosis of glioma of the retina, and excision of the globe. The cornea in this eye was quite clear and microscopically appeared perfectly healthy, but adherent to its posterior surface was a large piece of a persistent pupillary membrane, and also the pupillary border of the iris (fig. 27).

* "Ammon's Zeitschrit," Band i., Heft. 1.

† "Centralblatt für Augenheilkunde," 1880, S. 215.

‡ "Archiv für Augenheilkunde," Band xiv., S. 83.

§ "Klinisches Monatsblatt für Augenheilkunde," Band xxviii., S. 290.

The case already quoted, in which the iris appeared clinically to be absent, but where really a rudimentary one was present from the anterior surface of which adhesions passed to the ligamentum pectinatum, is another example of congenital anterior synechiæ of the iris (Plate IV., fig. *c*). I have met with two others. In one the adhesions were situated rather nearer the periphery of the iris than its pupillary margin in its outer half; they were about twelve in number, and appeared as little whitish elevations of the iris tissue coming forwards to the back of the cornea, which latter was perfectly clear. In this eye, besides the anterior synechiæ, there were some slit-like openings right through the substance of the iris, just external to the sphincter muscle. The other case was that of a girl aged seven years, whose mother stated she had noticed that the girl's right eye when she was born was larger than the left, that it had a slight cast, and since then that it had gradually increased in size. At the time of excision it appeared about as large again as the left. The cornea measured 12.5 mm. across, it was quite clear, and the iris at the upper part was adherent to it, elsewhere being in its normal position. The eye had no perception of light and its tension was increased. Microscopically the laminæ of the cornea everywhere appear normal. Bowman's membrane in the region of the anterior synechia is replaced by fibrous tissue and Descemet's membrane is thickened. The endothelium lining the latter membrane turns round at the edge of the synechia to the anterior surface of the iris. The periphery of the iris is very thin and on both sides of the section is intimately adherent to the cornea. There are

also some posterior synechiæ, but no round-celled infiltration in any part of the uveal tract. In this last case it would appear, that the portion of the anterior fibrovascular sheath which becomes incorporated with the iris, had not only failed to separate from the back of the cornea in the region of the pupil, but also at its extreme periphery, so that there was a congenital block to the exit of the aqueous humour, which gave rise to an increased tension and expansion of the elastic tunics of the child's eye.

CONGENITAL GLAUCOMA OR BUPHTHALMOS.

Failure in the separation of the iris from the back of the cornea at its extreme periphery might occur unassociated with anterior synechiæ elsewhere; such a condition of things would offer an easy explanation of cases of congenital glaucoma known under the names of "hydrophthalmos" and "bupthalmos." In an eye from a case of this sort sent to me by Mr. Papillon I have found extensive peripheral adhesion of the root of the iris to the cornea. The patient from whom it was removed was a boy aged fourteen years. When he was six weeks old his medical man first noticed his left eye to be larger than his right; it had gradually increased in size since then. The cornea at the time of excision measured 15 mm. across.

I have examined microscopically several other eyes affected with congenital glaucoma in which the operation of iridectomy had been unsuccessfully performed, and in all these the angle of the anterior chamber was closed by adhesion of the root of the iris to the

cornea, both in the region of the coloboma and elsewhere. The anterior chamber in cases of congenital glaucoma is usually abnormally deep, and I should like to point out that it is quite possible to have a deep anterior chamber and at the same time for its angle to be closed, the iris being considerably bent at the point where the adhesion ceases. In an eye in which the primary obstruction to the circulation of the intra-ocular fluid occurred at the angle of the anterior chamber, the fluid would be expected to collect in the anterior chamber and distend it. If, however, the primary seat of obstruction was further back, at the circumferential space, as it probably is in the primary glaucoma of adults, then the accumulation of fluid would occur in the vitreous chamber, which would be enlarged and the anterior chamber shallowed. I think the difference in the condition of the anterior chamber in the primary glaucoma of adults and in that of children can be thus explained, by a difference in the seat of primary obstruction.

Cases of buphthalmos or congenital glaucoma sometimes go on to a spontaneous cure. Thus a child may be born with increased tension of the eye which may as the result of the tension expand to a certain size; then the tension may become normal, and, though the eye remains large and the sight defective, still no further enlargement or deterioration of vision occurs. I have sections of the eye of one such case, which was excised when the child was four years old on account of pain following a blow. In them the iris is much displaced backwards and the angle of the chamber is open, but stretching across from the ligamentum pectinatum to the root of the iris, fine delicate fibrils are seen. The appearances suggest

that originally congenital adhesions existed between the root of the iris and cornea, which checked the exit of aqueous humour from the eye, and that as this accumulated in the anterior chamber and distended it these adhesions became stretched, some of them giving way, so that ultimately normal tension became established.

CHAPTER VI.

GLAUCOMA AFTER EXTRACTION OF CATARACT. GLAUCOMA IN CASES OF TRAUMATIC ANIRIDIA. THE *Modus Operandi* OF IRIDECTOMY IN THE RELIEF OF TENSION IN PRIMARY GLAUCOMA. THE MODE OF FORMATION OF A CYSTOID CICATRIX. THE CAUSES OF FAILURE OF IRIDECTOMY IN THE RELIEF OF TENSION.

GLAUCOMA AFTER EXTRACTION OF CATARACT.

GLAUCOMA coming on after extraction of cataract is a subject which presents many points of interest, not only to the pathologist, but also to the practical surgeon. In 1888, I published the clinical history of four such cases, and in 1890, I read before the Ophthalmological Society a paper based on the pathological examination of ten eyes in which sight had been destroyed by increased tension supervening on extraction. Since then I have examined pathologically eleven more eyes similarly affected. From the commencement of 1885 to the middle of 1889 there were extracted at the Royal London Ophthalmic Hospital, Moorfields, 1405 senile cataracts; in nine of which cases the eye was subsequently lost from the results of increased tension, giving an average of 0.64 per cent. It can be easily understood that the fact of the lens and a portion of the iris being absent would not materially affect the course of a serous cyclitis. Supposing such an attack to occur in an aphakic eye, there would be the same tendency to the accumulation of cells in the mesh of the ligamentum pectinatum as the fluid

containing them filtered through it, and there would be the same excess of fluid thrown into the eye. There would be the same increase in the albumen in the fluid, which hinders its power of diffusion through animal membranes. I have found many cases of increased tension after extraction to be due to the onset of such inflammatory trouble; it is not these I particularly wish to deal with now, but those cases in which the operation apparently goes perfectly smoothly and in which the wound heals well, the eye recovering from the operation without any or with only slight inflammation, and in which increase of tension subsequently ensues. In such cases there can be no obstruction of the circumlental space, for the lens is absent; the pupil is not blocked and it might be imagined that, as iridectomy had been done, the angle of the anterior chamber in the region of the coloboma would be open. In these cases the time at which the increase of tension comes on after the extraction varies. It may be noted as soon as the wound is sufficiently healed to permit of its estimation, or it may not occur until a year or more after. Often the operation of discission seems the exciting cause of the glaucomatous attack. How can all these cases be explained? From the examination of my specimens I believe as follows:—In all eyes in which glaucoma comes on after extraction of cataract there is adhesion to, or entanglement of the lens capsule in, the extraction scar (Plate V., fig. *b*, and fig. 28). This adhesion or entanglement holds the root of the iris, or the anterior of the ciliary processes if the iris has been removed up to the periphery, into close contact with the back of the cornea in the region of the coloboma, and so keeps the angle of the cham-



DESCRIPTION OF PLATE V.

- Fig. a.* Section of an eye supposed to have congenital aniridia and in which increase of tension came on, the angle of the anterior chamber is shown to be blocked by a rudimentary iris. The ciliary body has become somewhat detached from the sclerotic in the preparation of the specimen.
- Fig. b.* Section of an eye which had glaucoma, coming on after extraction of cataract. Adhesion of lens capsule to extraction scar shown.
- Fig. c.* Section of an eye in which the whole iris escaped through a wound in the cornea, and in which there was afterwards increase of tension. The angle of the anterior chamber is shown to be blocked by the anterior of the ciliary processes, which is displaced forwards.

PLATE V

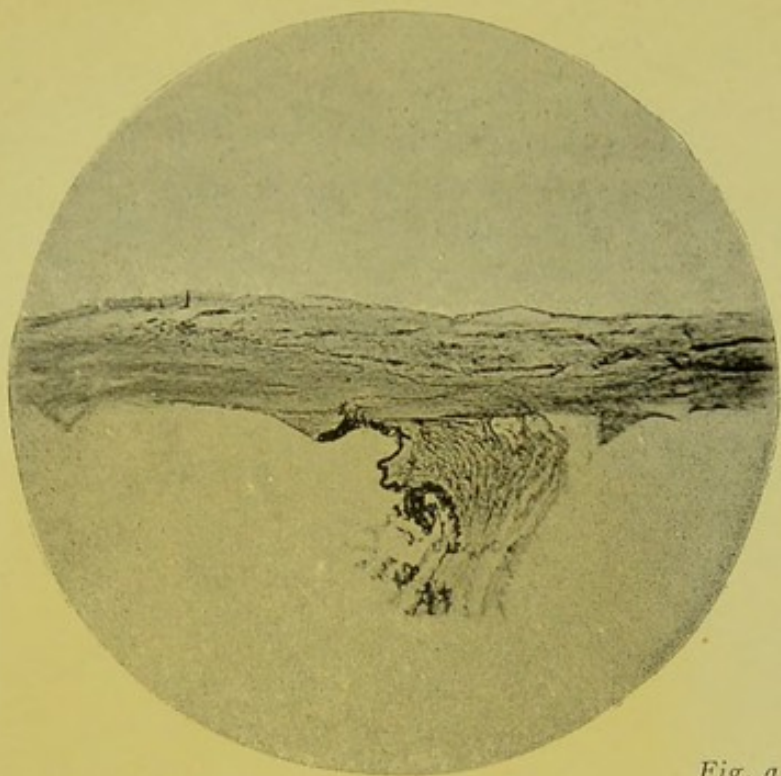


Fig. a.

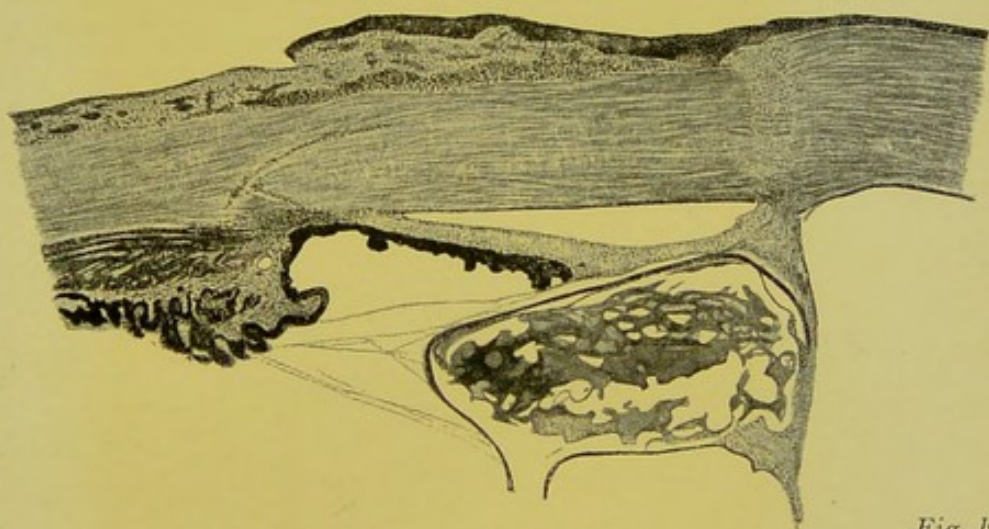


Fig. b.

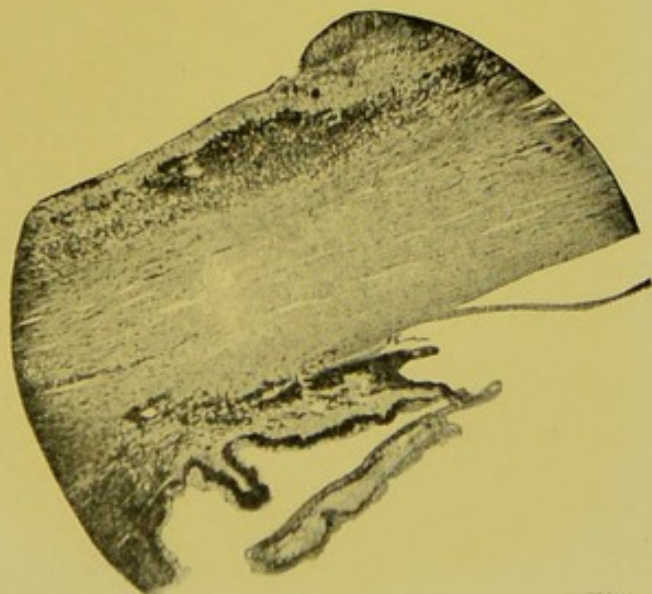


Fig. c.



ber blocked in that situation. The advanced position which the capsule takes, by reason of its attachment to the cornea, draws forwards the iris lying in front of it, and in this way approximates the root of the iris elsewhere than in the region of the coloboma, to the periphery of the cornea. In some cases, especially those in which the extraction scar is very corneal, the advance in the position of the capsule is so great that the apposition of the cornea

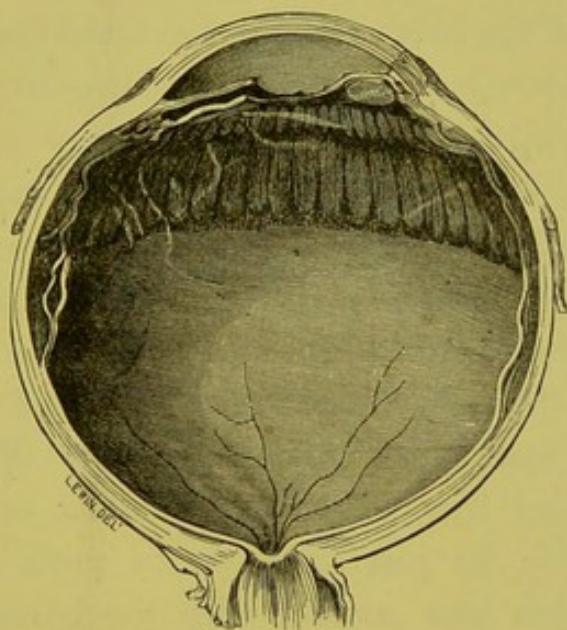


FIG. 28.—The lateral half of an eye from which a cataract had been extracted and in which a membrane had been subsequently needed. The lens capsule with a hole in its centre is shown adherent to the extraction cicatrix, dragging forwards the iris in front of it.

and iris is actually occasioned. In such cases the increased tension follows directly the wound has closed after the operation. The adhesion of the lens capsule to the extraction scar is sometimes composed of inflammatory exudation (Plate V., fig. *b*); this on organising and contracting tends gradually to advance more and more the position of the capsule and cor-

sequently that of the iris. Such a gradual advance would explain those cases in which the increased tension does not make its appearance until some time after the cataract has been removed. In an aphakic eye in which glaucoma followed the operation of needling an opaque membrane I found, besides an adhesion of the capsule to the extraction scar, a second adhesion at the needle puncture. This second adhesion had caused a further advance in the position of the capsule, which led to apposition of the root of the iris and the cornea, and so to increased tension. A needle operation after extraction of cataract leads sometimes to the onset of increased tension without any second adhesion of the capsule to the cornea, probably either by the swelling of the cortical lens matter so often left in the periphery of the capsule, through the action of the aqueous humour on it, or by the swelling of the ciliary processes occasioned by dragging on them in tearing through the capsule. This swelling of the cortical lens matter, or swelling of the ciliary processes may be just sufficient to push forward the root of the iris into contact with the cornea, to which it is already abnormally close by reason of the advanced position of the lens capsule. I have one specimen of glaucoma occurring in an eye from which a traumatic cataract had been extracted in its capsule; in it the anterior hyaloid of the vitreous is clearly shown adherent to the cicatrix in the cornea. An adhesion of the hyaloid of the vitreous to the cornea would tend to cause a greater advance in the position of the iris than an adhesion of the lens capsule, because normally it is further back.

GLAUCOMA IN CASES OF TRAUMATIC ANIRIDIA.

I have met with two eyes in which the whole iris had escaped through a wound near the centre of the cornea, and which afterwards became glaucomatous. Until I examined sections of them microscopically the cause of the increased tension seemed to me quite inexplicable.

In both these eyes the lens had been wounded, some portion of it escaping and a broad adhesion of its capsule to the corneal scar remaining. In the escape of the iris through the wound the anterior part of the ciliary body had become drawn forwards, the advance in the position of which had been maintained by the adhesion of the lens capsule to the wound. In both specimens I find the most anterior of the ciliary processes in contact with the posterior surface of the ligamentum pectinatum (Plate V., fig. *c*).


THE MODUS OPERANDI OF IRIDECTOMY IN THE RELIEF
OF TENSION IN PRIMARY GLAUCOMA.

Since Gräfe, by what must be described as a lucky chance, discovered that the removal of a portion of the iris would relieve the tension in primary glaucoma, numerous speculations have been made and theories suggested as to its *modus operandi*. Obviously the only way to obtain any accurate data upon which to form an opinion on this subject, is to examine sections of eyes on which the operation has been performed, and to compare those in which it has proved successful with those in which it

has failed. Eyes in which iridectomy has relieved tension are not often obtained for pathological examination; I have, however, had four such specimens. Those in which the operation has failed—unfortunately, only too frequently—come into the pathologist's hands. A careful study of these offers many points of practical interest. As with so many subjects, when they come to be investigated closely the issue is found not to be a simple one. Iridectomy does not relieve tension always in precisely the same way—failure in relief of tension by iridectomy is not always due to the same cause.

First I should like to point out that iridectomy is performed in two very different ways. So different are these two modes of performing the operation in their possible results as regards the relief of tension, that I think it would be well to designate them by two different names. The term "iridectomy" might be retained for those cases in which an incision is made and the iris simply drawn out and snipped off. The old name of "iridectomediales" might be revived for those in which after the incision is made the iris is drawn out, snipped on one side, then torn away from its insertion along the whole length of the wound, and finally cut off.

Before proceeding to the ways in which I have found iridectomy to relieve tension, I will dispose of two of the theories which have been put forward with regard to it. It is held by some that in making the incision for iridectomy for glaucoma the knife is passed into the extreme angle of the anterior chamber, and made to open up the blocked spaces of Fontana and the canal of Schlemm. In order to be able to determine the exact relative position of a cicatrix to the sclero-corneal margin I have, in



DESCRIPTION OF PLATE VI.

Sections of eyes upon which iridectomy had been performed for glaucoma. Illustrations reproduced from photomicrographs of the parts about the seat of operation.

Fig. a. Acute glaucoma. Tension relieved by operation. Eye excised ten years later for corneal ulcer and hypopyon. A small portion of the root of the iris has been left after the iridectomy, but the angle of the anterior chamber is open.

Fig. b. Recent glaucoma. Keratome used for incision. Section very oblique, and not very peripheral. Iris removed quite up to the ciliary body.

Fig. c. Glaucoma of two months standing. Tension relieved by operation. Eye excised five weeks later for ulceration of cornea. Iris removed quite up to the ciliary body.

PLATE VI

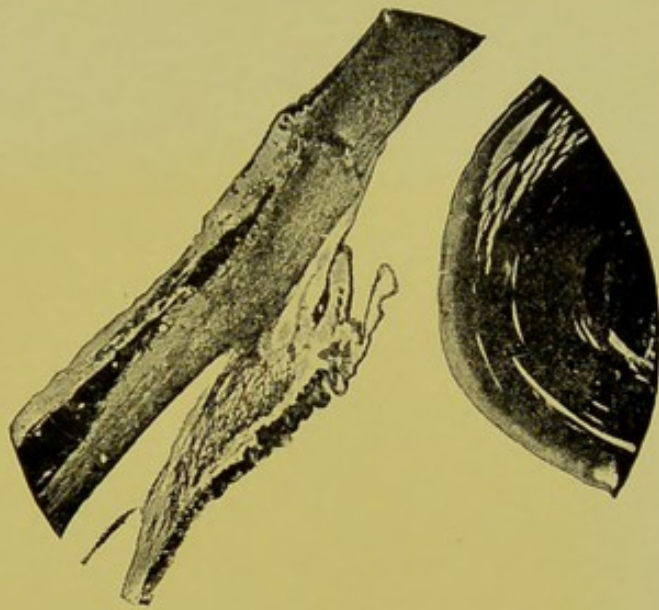


Fig. a.

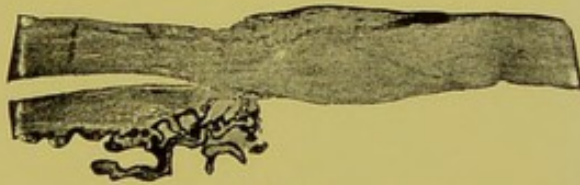


Fig. b.




Fig. c.



several recently excised eyes with healthy corneæ, made a scratch with a needle through the epithelium at what appeared to be the exact junction of the clear cornea with the opaque sclerotic. I then hardened the eyes and cut sections of them, and found that my scratch corresponded to the usually well-defined termination of Bowman's membrane. The distance of this landmark to a point on the surface of the globe on a level with Schlemm's canal is 1.61 mm., and to a point level with the commencement of the ligamentum pectinatum—*i.e.*, where Descemet's membrane begins to split up—1 mm. On account of the obliquity of the line of junction of the cornea and sclerotic it follows, that an incision which passed external to the termination of Bowman's membrane and internal to the commencement of the ligamentum pectinatum, would be partly corneal and partly scleral. One which passed internal to the termination of Bowman's membrane would be purely corneal, and one passing through the ligamentum pectinatum almost entirely in the sclerotic.

The iridectomy cicatrices in the eyes which I have examined microscopically are nearly all oblique, the gap left in Descemet's membrane on the posterior surface of the cornea being more internal than the commencement of the cicatrix on the surface of the globe. The amount of obliquity varies considerably, and, speaking generally, it is more in those cases in which a keratome was used (Plate VI., fig. *b*) than in those in which the incision was made with a Gräfe's knife (Plate VI., fig. *c*). In only two of the eyes I have examined had the incision been made sufficiently peripheral to penetrate the ligamentum pectinatum. In one of these the lens escaped, and the

ciliary body prolapsed the day following the operation (Plate VIII., fig. *c*). In none had the canal of Schlemm been reached. In one eye the cicatrix was entirely corneal. In the remainder, including those cases where the glaucoma was cured, it was partly corneal and partly scleral.

Another theory is that the removal of the iris has little or nothing to do with the relief of tension, but that it is occasioned by the formation of a band of scar tissue, which, being situated at the sclero-corneal margin, allows of the filtration of the aqueous humour through it. *A priori*, it is unlikely that the fibrous tissue of a cicatrix would be more permeable by fluid than the fibrous tissue of the cornea or sclerotic.

Experimentally, Schœler* has shown that in rabbits' eyes upon which sclerotomies have been performed, filtration is retarded, not promoted, and that when he increased the pressure in these eyes the cicatrices remained dry.

Pathologically, I find in several eyes iridectomised for glaucoma, good bands of cicatricial tissue, well at the periphery of the chamber free for some part of their extent from any entanglement of the iris, in which the tension returned and persisted.

Starting now with the known fact, that whatever is the first factor in the causation of primary glaucoma, the tension is kept up by the apposition of the root of the iris to the posterior surface of the cornea, preventing the exit of the aqueous humour through the spaces of Fontana. I find that in the four speci-

* "Transactions of the International Medical Congress," 1881, vol. iii., p. 100.

mens I have examined, in which normal tension was re-established (three of them being subsequently excised for some intercurrent malady and the other removed post-mortem) the arrest in the exit of fluid from the eye was relieved in somewhat different ways.


The first case was that of a woman aged fifty-seven years, in whom iridectomy was performed for acute glaucoma of four days standing; tension was relieved and the eye excised ten years later on account of an ulcer of the cornea with hypopyon. In this eye the angle of the anterior chamber was round and open, both in the region of the coloboma and elsewhere. The iris had not been removed to its extreme periphery, a portion of its root had been left (Plate VI., fig. *a*). It would seem that in this case the apposition of the root of the iris to the cornea having only been of recent origin, slight means were sufficient to dislodge it from its faulty position, that the escape of the aqueous and the drag on the iris incident to the iridectomy, had effected this.

The second case was that of a man aged sixty-nine years, who had an iridectomy performed on his right eye for a glaucoma of two months' standing. The eye was excised five weeks afterwards on account of ulceration of the cornea; during the time which had elapsed since the operation tension had remained normal or slightly sub-normal. Microscopical examination of this eye showed that the iris had been removed quite up to its point of junction with the ciliary body—that is, in this eye the iris had torn through at its thinnest part, as it usually does when drawn upon in the normal state (Plate VI., fig. *c*). The filtration area in the region of the coloboma had thus been opened up through which the

aqueous humour could escape. A similar result had been obtained in the third case; that of a woman aged eighty-eight years, who had had repeated attacks of increased tension. An iridectomy was performed and the tension remained normal up to the time of her death. The angle of the anterior chamber elsewhere than at the seat of the iridectomy in this eye remained closed.

THE MODE OF FORMATION OF A CYSTOID CICATRIX.

The fourth case was a private patient under the care of Mr. Tweedy, to whom I am indebted for the specimen. The patient was a woman who had chronic glaucoma in both eyes. In each an iridectomy was performed, and in each the tension was relieved. In the left the cicatrix became cystoid. Eleven months later, while out driving, she caught cold in the eye, and an attack of iritis ensued. Thirteen months after the iridectomy the left eye was excised for the relief of pain. In the region of the iridectomy scar of this eye there was a gap in the sclero-corneal tissue, over which the conjunctiva stretched, and around which the conjunctival tissue was swollen and œdematous. Around the outer part of the gap in the sclero-corneal tissue the anterior part of the ciliary body turned, lining the outer wall of the gap, while remnants of the atrophied root of the iris were found lining the rest of it (Plate VII., fig. *b*). Relief of tension in this case had evidently been occasioned, not by the opening up of the normal passages for the exit of fluid from the eye, but by the formation of a fresh one in the shape of a fistula in the fibrous tunic of the globe, through which aqueous humour passed into the sub-conjunctival tissue.



DESCRIPTION OF PLATE VII.

Sections of eyes showing the formation of a cystoid cicatrix.
Illustrations reproduced from photo-micrographs.

Fig. a. Prolapse of a fold of iris into iridectomy cicatrix at the margin of the coloboma. The first stage in the formation of a cystoid cicatrix.

Fig. b. Chronic glaucoma. Tension normal for a year after operation. Eye then excised on account of iritis and pain. Cystoid cicatrix partly lined by atrophied iris, partly by ciliary processes. Sub-conjunctival tissue near cicatrix swollen.

Fig. c. Cystoid cicatrix lined by atrophied iris tissue, in an eye in which glaucoma came on after extraction of cataract. Sub-conjunctival tissue around cicatrix swollen.

PLATE VII.

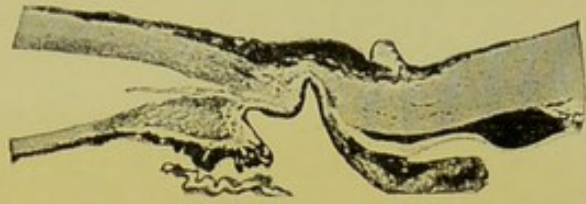

Fig. a.

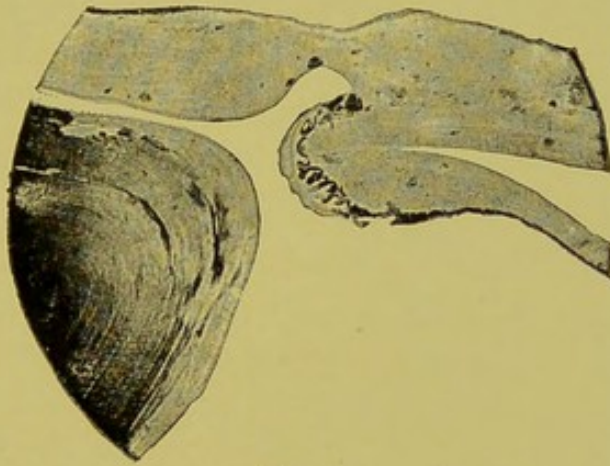


Fig. b.

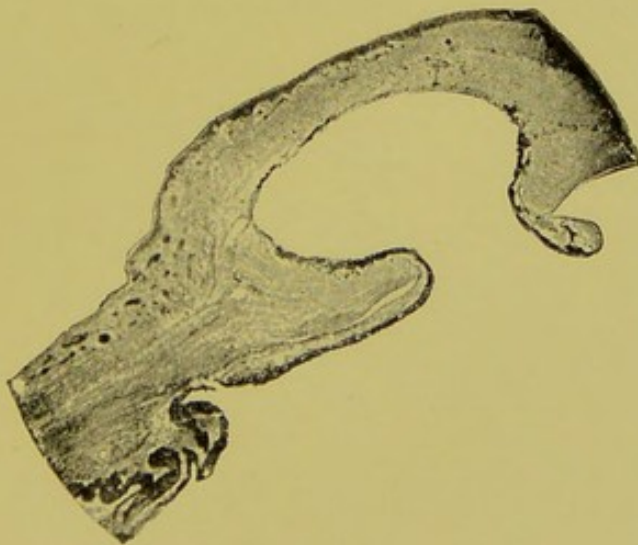


Fig. c.




I have examined microscopically several cystoid cicatrices and find they are always lined by more or less atrophied iris tissue. If the cut end of a piece of iris becomes entangled in a wound, the wound in closing incorporates the iris in the cicatrix. If, however, a fold of iris tissue becomes involved (Plate VII., fig. *a*), the anterior surface of the iris unites to the cut edges of the sclero-corneal tissue, the conjunctiva heals over it, and thus a gap is left lined by iris tissue in the walls of the eyeball. It is known that the iris tissue is impermeable by the intra-ocular fluids, for when the pupil becomes closed by total posterior synechiæ they accumulate behind it and bow it forwards, instead of passing through it. Hence it follows that an eyeball may have a gap in its coats, through which no escape of fluids will occur into the sub-conjunctival tissue as long as it is lined by impermeable iris tissue. Should, however, there be any tendency to accumulation of fluids in such an eye, the gap, being a weak spot, will yield and expand, the iris tissue lining it will become atrophied and stretched, and breaks will occur in the continuity of its uveal pigment layer, which is probably the chief obstacle to the passage of fluid through it. There would then be formed a thin bulging or cystoid cicatrix lined by very atrophied iris tissue, through which any excess of intra-ocular fluid would be able to pass into the sub-conjunctival tissue (Plate VII., fig. *c*). It is not uncommonly observed, and was pointed out by Gräfe, that these cystoid cicatrices periodically discharge themselves sub-conjunctively, the explanation being that when the accumulation of fluid has reached a certain stage a rent occurs in the iris tissue which allows of its escape. Mr.

Bader, in the form of sclerotomy which he advocates, seeks to produce a condition such as the above. He says:* "To secure success it is desirable to obtain, and to maintain, a staphyloma of the conjunctiva, with or without prolapse of the iris." De Wecker and most other operators endeavour to avoid a prolapse of any kind.

THE CAUSES OF FAILURE OF IRIDECTOMY IN THE RELIEF OF TENSION.

Such, then, being the ways in which I have found iridectomy to relieve the increase of tension in glaucoma, I will now describe what I have found to be the causes of failure in the operation. By far the commonest would seem to be the non-removal of the iris up to its extreme periphery, so that a portion of it is left blocking up the filtration area, sometimes rendered additionally secure in its faulty position by the healing of the cut end of the iris in the corneal cicatrix (Plate VIII., fig. *a*). In cases where glaucoma has been of long standing the root of the iris becomes absolutely adherent to the cornea, and when drawn upon, instead of tearing at its junction with the ciliary body, tears at the point where it ceases to be adherent, so that the filtration area never becomes opened up. Sometimes the adhesion of the iris is so firm that its separation is an absolute physical impossibility. In acute glaucoma, when the root of the iris only lies in apposition with the cornea and is not adherent to it, it tears away from its extreme

* "Transactions of the International Medical Congress," 1881, vol. iii., p. 98.



DESCRIPTION OF PLATE VIII.

Sections of eyes upon which iridectomy had been performed for glaucoma. Illustrations reproduced from photographs of the parts about the seat of operation.

Fig. a. Subacute glaucoma. Return of tension after operation. Excision two months later. A large portion of the periphery of the iris has been left blocking the filtration area, its cut end is adherent to the iridectomy cicatrix.

Fig. b. Absolute glaucoma. Return of tension after operation. Excision a year later. Lens capsule adherent to iridectomy cicatrix. The lens has become somewhat displaced backwards from the position in which it was in the recent state. The filtration area is blocked by ciliary processes.

Fig. c. Glaucoma of two months standing. Section very peripheral. Prolapse of ciliary body. Escape of lens the day after operation.

PLATE VIII

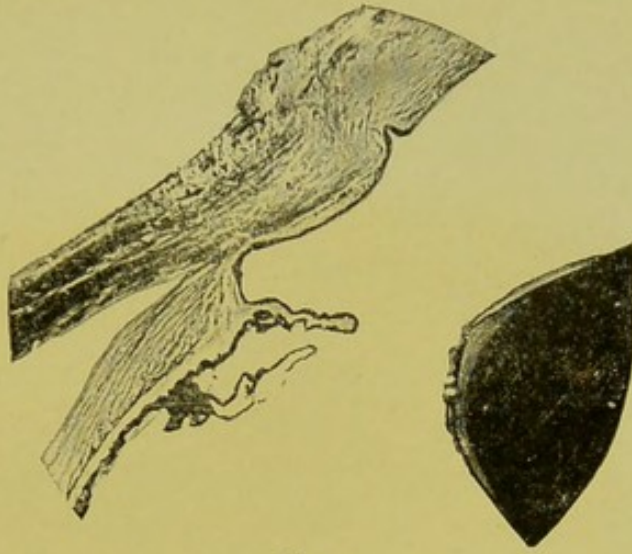


Fig. a.

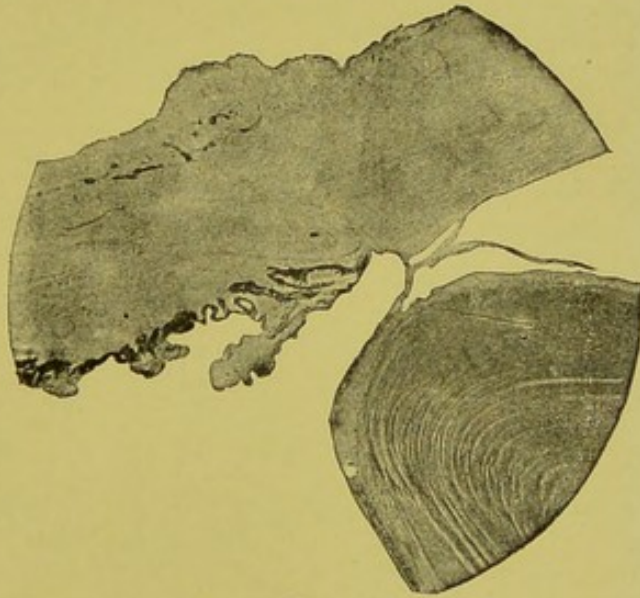


Fig. b.

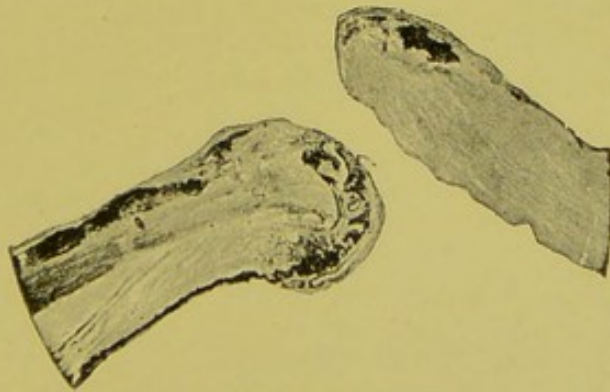


Fig. c.



periphery. This is the difference between acute and chronic glaucoma, which renders the operation of iridectomy such a very satisfactory proceeding in the former and so very unsatisfactory in the latter.

Another cause of failure in the removal of the iris up to its periphery is the way in which the operation is performed; thus a simple withdrawal of the iris and snipping it off are not so well calculated to effect this as what I would term, as I have already explained, an "iridectomedialysis." Sometimes after an iridectomy for glaucoma the anterior chamber is very slow in re-forming. In such cases the plastic exudation thrown out to effect the closure of the sclero-corneal wound may unite the lens capsule lying in contact with the wound to it. Then when the anterior chamber does re-form, the part of the lens in the region of the wound will remain adherent to it, become drawn forwards, and hold the anterior of the ciliary processes or the root of the iris, if a piece of it is left, in contact with the ligamentum pectinatum in the situation of the coloboma (Plate VIII., fig. *b*). In such cases, it is needless to say, tension is not relieved.

It has been suggested that where the lens is very much pushed forwards in cases of glaucoma, or where it seems unlikely that the anterior chamber will readily re-form, a scleral puncture should be performed as a preliminary procedure, and in some cases this has apparently seemed to answer its purpose well. I should like to point out, however, a possible danger which I have met with in connexion with scleral puncture. In a case in which it was performed suppuration in the vitreous subsequently ensued, and the eye had to be

excised. Sections across the line of puncture show a prolapse of vitreous much infiltrated with pus cells lying in it. It must have been along this prolapse of vitreous that the suppurative infection had gained access to the interior of the eye.

Prolapse or adhesion of the ciliary processes to the sclero-corneal cicatrix after the iris has been removed not infrequently occurs when the incision is a very peripheral one (Plate VIII., fig. *c*). A study of the anatomical relation of the anterior part of the ciliary body and iris shows at once that this is what might be expected. The anterior part of the ciliary processes extends for some distance behind the periphery of the iris, so that if the sclero-corneal incision is a very peripheral one, and the iris is drawn out, the anterior part of the ciliary body is drawn forwards with it; in one specimen I have it was cut off with the iris. An adhesion of the anterior part of the ciliary body to the iridectomy cicatrix I have found to block the filtration area, even after the iris has been removed up to its extreme periphery. In acute glaucoma I do not think there is any necessity, provided an iridectomediaalysis be done, to make the incision very peripheral. The iris tears away naturally at its root when drawn upon, wherever the incision is (Plate VI., fig. *b*), and a peripheral incision certainly increases the risks of the operation.

I should like to urge, as the result of my observations, the necessity of performing an iridectomy early in cases of chronic glaucoma. I think in some cases, even, it would be well to perform what might be termed a preventive iridectomy for this disease—that is, to perform an iridectomy when only the subjective symptoms are

present and when no deterioration of vision has occurred. The risks of an iridectomy in such an eye are very small—they can hardly be considered greater than the risks of a preliminary iridectomy for extraction of cataract. The chances of success, in preventing or relieving increased tension, of an iridectomy performed before adhesion of its root to the cornea has occurred are infinitely greater than after such adhesion is established.

CHAPTER VII.

THE IMMEDIATE EFFECTS OF CONCUSSION OF THE EYE. CHANGES FOUND IN EYES INJURED BY CONCUSSION. DEPRESSION BACKWARDS OF THE PERIPHERY OF THE IRIS. IRIDODIALYSIS. RUPTURE OF THE PILLARS OF THE IRIS AND SPLITTING OF THE CILIARY MUSCLE. RUPTURE OF THE WHOLE LIGAMENTUM PECTINATUM AND RETRACTION OF A PORTION OF THE IRIS. RUPTURE OF THE SUSPENSORY LIGAMENT. DISLOCATION OF THE LENS INTO THE ANTERIOR CHAMBER. CONCUSSION CATARACT. BLOOD STAINING OF THE CORNEA.

THE IMMEDIATE EFFECTS OF CONCUSSION OF THE EYE.

A blow from a blunt object on the front of the eye which does not cause a perforating wound may give rise to several different lesions, some of which are well known, and others I believe I was the first to describe. I propose now to discuss these changes which are produced in an eye as the result of concussion. The one with which perhaps ophthalmic surgeons are most familiar is what is termed iridodialysis, that is a detachment of a portion of the periphery of the iris from the ciliary body.

Arlt* describes its mode of formation as follows:—
“The cornea being momentarily flattened the circle described by the corneo-scleral border and the ciliary body, with which it is firmly united is extended, whilst the sphincter iridis is contracted, the serrated connection of the iris with the ciliary body is torn to a greater or less

* Von Arlt's "Diseases of the Eye." Translated by Ware, p. 315.

extent and a second communication is formed between the anterior and posterior chambers."

Fuchst has shown that there is another important factor in these cases, he says:—"the blow which strikes the cornea and flattens it out also pushes the aqueous backward. The latter tends to recede and pushes against the posterior wall of the anterior chamber, which in the area of the pupil is formed by the lens and in the rest of its extent by the iris. The latter when pushed backwards, finds a support in the lens except at its marginal portion which lies outside the margin of the lens. Here the posterior chamber is deepest and is bounded only by the feeble zonula of Zinn. The periphery of the iris, therefore, forms the most yielding spot in the posterior wall of the anterior chamber and the one which is the first to give way before the pressure of the receding aqueous."

CHANGES FOUND IN EYES INJURED BY CONCUSSION.

In the eye of a man aged 42, which three months before excision had received a severe blow on it but no perforating wound, and which previously had very defective vision from high myopia and a detachment of the retina; I found the periphery of the iris in its entire circumference forced backwards between the margin of the lens and the ciliary body, the anterior chamber much deepened, and its angle widely opened out (Plate IX., fig. a).

In this eye there had been no tearing of any tissue, but it can be easily understood that the forcing of the iris


* "Text-book of Ophthalmology," English translation, p. 302.

back in this way, readily causes it to tear at its weakest point, *i.e.*, its point of union with the ciliary body, and for an iridodialysis to result.

In other cases instead of the iris tearing away from the ciliary body, those fibres of the ligamentum pectinatum which curve round the angle of the chamber and go to the root of the iris, forming the so-called pillars of the iris, give way, and the ciliary muscle becomes split, so that the angle of the anterior chamber is prolonged outwards; a wide gap being left between the circular and longitudinal muscle fibres.

In one case in which I met with this condition the boy had been struck on his eye by a stone shot from a catapult (Plate IX., fig. *c*); in another case a boy aged 16 had struck his eye with the end of a stick which he was throwing over his shoulder.

In a third case a boy aged ten struck his eye with the stick of his catapult and I found that on one side there was an iridodialysis and on the opposite side a tearing through of the pillars of the iris and a splitting of the ciliary muscle; this shows conclusively that it is the same sort of injury which gives rise to the two different lesions (Plate IX., fig. *b*). In the case of a boy aged eleven who was looking up at some fireworks and received a blow on his right eye by the descending stick of a rocket. I found that not only had those fibres of the ligamentum pectinatum which go to the root of the iris been torn through, but also those which give origin to the ciliary muscle, and that the whole ciliary body had become separated from the sclerotic and displaced to one side (Plate IX., fig. *d*). The displacement of the ciliary body and iris beyond the sclero-cor-



DESCRIPTION OF PLATE IX.

Photo-micrographs of front halves of a series of eyes injured by concussion.

Fig. a. Periphery of iris depressed backwards between lens and ciliary body.

Fig. b. Irido-dialysis, and rupture of suspensory ligament and capsule of lens on one side. Rupture of the fibres of the ligamentum pectinatum going to the root of the iris, and splitting of the ciliary muscle, on the other.

Fig. c. Rupture of the fibres of the ligamentum pectinatum going to the root of the iris and splitting of the ciliary muscle, on both sides.

Fig. d. Rupture of the whole ligamentum pectinatum, and separation of the iris and the ciliary body from the sclerotic. Iris on one side much shrunken. Blood-clots in the anterior chamber. Suspensory ligament and capsule of lens on one side ruptured; vitreous protruding forwards between the ciliary body and lens.

Fig. e. Dislocation of lens into the anterior chamber, secondary glaucoma.

PLATE IX.

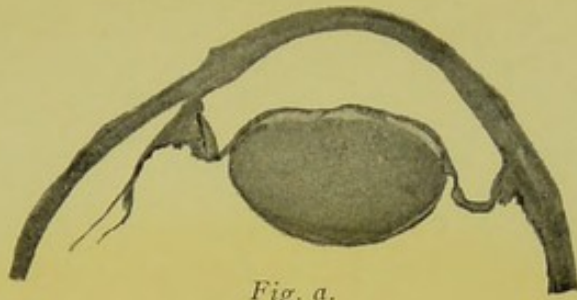


Fig. a.

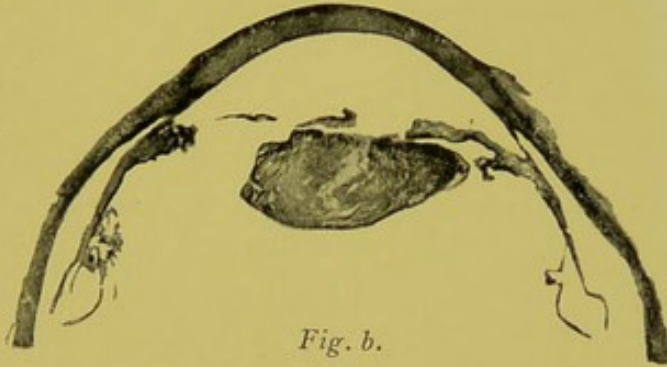


Fig. b.

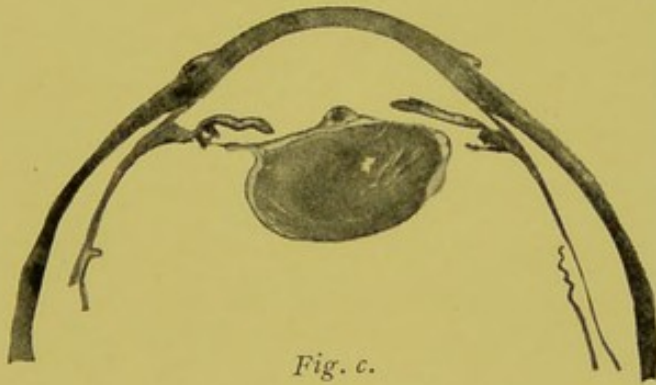


Fig. c.

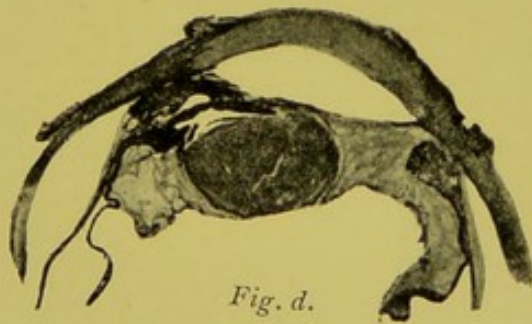


Fig. d.

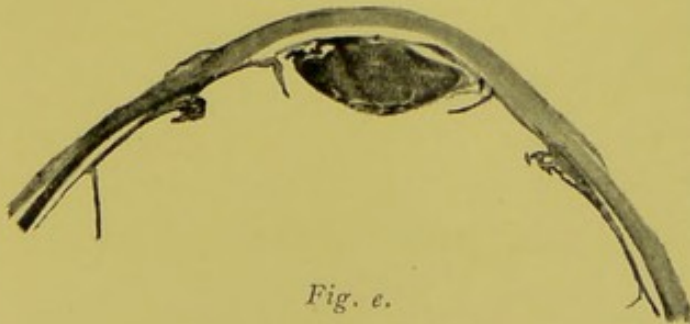


Fig. e.



neal margin, together with some shrinking of the latter, had caused the whole of the upper part of the iris to disappear clinically, and as there was a large blood-clot in the lower part of the anterior chamber, the whole of it was out of sight. The lens in this case was also displaced to one side and there was a commencing opacity in it.

A case presenting itself in which, after a blow on the eye, the iris was found to have in part disappeared, the anterior chamber to have become deepened, and the lens displaced, would be diagnosed as one of retroflexion of the iris. The following description of this condition is given by Soelberg Wells :*

“A very peculiar and rare condition is that of retraction or depression of a portion of the iris, which is sometimes produced by blows upon the eye. The portion of the iris which is depressed is folded back upon itself, and the inner pupillary circle disappears at the point where this folding occurs ; the peripheral portion of the iris is quite invisible, having sunk back out of sight, so that the eye at this point presents the appearance as if an iridectomy had been made quite up to the ciliary attachment. On examining the eye with the oblique illumination, or with the ophthalmoscope, we cannot, however, detect a trace of the ciliary processes, as would be the case if the iris had been removed. In such cases the lens has generally been found partially dislocated or much diminished in size.”

The often-quoted case of von Ammon's† is the one upon which the description of the pathological condition

* “Treatise on Diseases of the Eye,” 3rd edition, p. 183.

† “Archiv für Ophthal.,” Bd. i., Ab. 2, S. 119.

in this class of cases is based. A young soldier, wishing to commit suicide, loaded his musket with powder, and then, pouring a quantity of water into the barrel, placed the muzzle in his mouth, discharged the piece, and fell dead. In his right eye the only visible portion of the iris was a small crescentic piece on the outer side. The point where this portion disappeared was neither torn nor abruptly folded inwards, but disappeared without its being possible to discern what had become of it. Dissection showed that the upper, inner, and lower borders of the iris were pushed back; the vitreous body was displaced; the lens, with its capsule entire, touched the upper border of the middle of the superior ciliary processes, whilst the inferior border was found near the centre of the unnaturally large pupil. The lens and vitreous body had displaced the iris; when they were removed under water the iris slowly returned to its position.

My case shows that the same symptoms as those which I have quoted from Soelberg Wells may be produced by a rupture of the fibres of the ligamentum pectinatum, which allows of the retraction of the iris and ciliary body to such an extent that a portion may be completely withdrawn beyond the sclero-corneal margin, and consequently invisible by oblique illumination.

The wide and sudden dilatation of the pupil which results from the depression backwards of the periphery of the iris, in concussion of the eye, may cause a rupture of the fibres of the sphincter muscle, or even a tear in the pupillary border of the iris, persistent dilatation and inactivity of the pupil resulting. Sometimes the forcing back of the periphery of the iris between the ciliary body

and margin of the lens leads to rupture of the fibres of the suspensory ligament, if this takes place in its entire circumference, then it is easy to understand that the expanded pupil of the displaced iris is very likely to slip round the lens, and for the latter to become dislocated into the anterior chamber.

In some of the eyes I have examined the suspensory ligament was torn through only on one side, in these the vitreous had protruded forwards between the ciliary body and the side of the lens in the region of the rupture.

CONCUSSION CATARACT.

The almost complete absence of records of pathological examinations of concussion cataract was drawn attention to by Lawford in the "Ophthalmic Review," for 1887. He gave a *résumé* of the opinions of different authors with regard to it, and recorded two cases, in both of which he found a rupture of the capsule.

I have now examined microscopically five other specimens of concussion cataract, all of which proved to have rents in the lens capsule, and so far as I know no case has been recorded of a concussion cataract in which the capsule was found to be definitely intact. The most frequent position in which the lens capsule ruptures is at or a little behind its equator; the two ends of the ruptured capsule retract and tend to coil outwards. A rupture occasionally occurs in the posterior part of the capsule, as is shown by a case recorded by Lawford and also by one which I examined myself, in which the ends of the divided capsule were widely separated by lens matter protruding backwards into the vitreous, which had re-

mained clear up to the time of excision, a week after the injury (Plate X.).

BLOOD STAINING OF THE CORNEA.


Sometimes as the result of injuries to the eye, either concussion or wounds, and sometimes spontaneously in blind eyes, extensive hæmorrhage occurs into the anterior chamber; the blood completely distending it, forcing back the iris and lens, and even occasionally giving rise to increased tension.

In cases where this has occurred it has been observed that the cornea may become stained either a greenish or rusty-brown colour. The discoloration at first extends throughout the whole cornea, later on it disappears from the periphery and a narrow ring of clear cornea is seen in its entire circumference, the central stained portion ending by an abrupt well-defined margin.

It is when the peripheral ring of cornea has become cleared, that it first becomes possible to diagnose the case as one of staining of the cornea. When the whole cornea is stained, it is not possible to distinguish it from a simple distension of the anterior chamber with blood, the condition with which it is always associated.

The appearances presented when a large circular area of the cornea is stained a rusty brown colour, around which there is a ring of clear cornea, closely simulate those of an amber-coloured lens dislocated into the anterior chamber; so close is the resemblance, that I have seen some of the best observers mistaken in diagnosing this affection.

The disappearance of the discoloration of the cornea

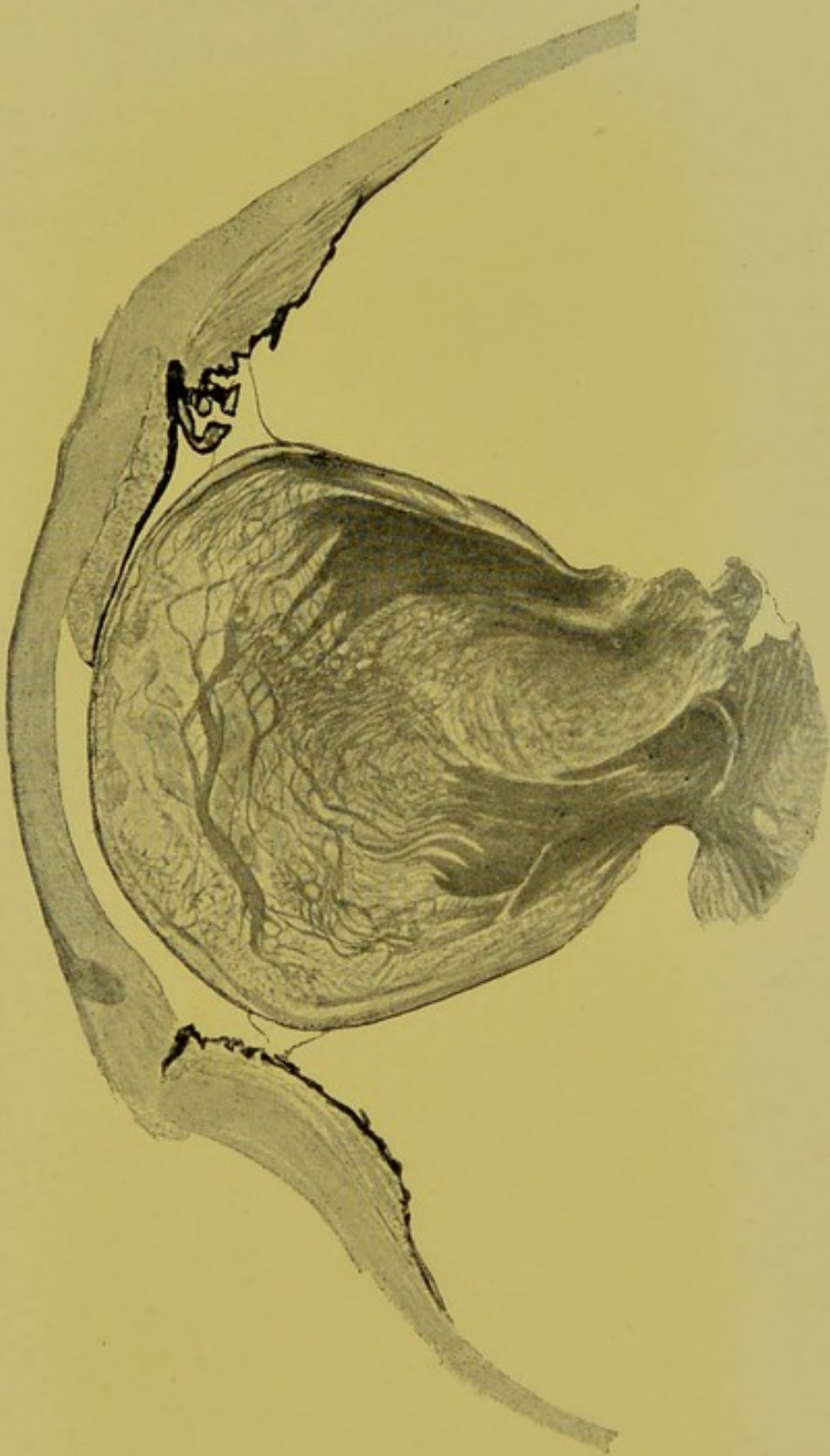


DESCRIPTION OF PLATE X.

Section of the front half of an eye injured by a blow from a stone.

Rupture of the posterior capsule of the lens and extrusion of lens substance backwards through it.

PLATE X





goes on slowly from the periphery towards the centre, becoming slower and slower the further removed the stained area is from the sclero-corneal margin. In one case I was able to watch the discoloration of the cornea from its onset until it had completely disappeared. The hæmorrhage into the anterior chamber in this case occurred on the removal of a prolapsed iris, the staining of the cornea could first definitely be noted eight days after the operation. Fifteen days after, the extreme periphery of the cornea in its entire circumference was quite clear. Twenty-five days after, the lower margin of the pupil dilated with atropine, was just visible below the staining. Two months after, there was still a large central opaque area. Nine months after, the centre of the cornea was still pigmented but much less densely so. A year after, the central patch was of a gray colour and measured 4 mm. in diameter. I did not see the patient again until two years and three months after, when the cornea was quite clear. This discoloration of the cornea may occur at any age. I have met with it in patients varying from 14 months to 56 years old.

It is not a very rare condition, as the complete absence of any mention of it in textbooks on diseases of the eye would seem to imply. During three years at the Moorfields Hospital I met with nine cases of the affection.

Microscopical examination of corneæ with this form of discoloration, show scattered throughout its substance a number of little granules, or highly refracting particles, or crystals. This substance cannot be made out to bear any definite relationship to the spaces between the fibres of the cornea, some of the granules extend as far forwards as Bowman's membrane; they are strictly limited to the

stained area and are seen to end abruptly where the stained area joins the clear peripheral zone.

With regard to the nature of this pigment I may point out that Virchow has taught us that in old blood-clots retained in the interior of the body, such as are found in aneurisms or in the brain after cerebral hæmorrhages, small crystals of a rhomboidal shape and bright red colour are often met with, also an amorphous deposit of the same colour and nature; this substance he has termed hæmatoidine.

The size of these hæmatoidine crystals varies considerably and I have found the size of the highly refracting particles met with in the discoloured corneæ to vary in different cases.

Dr. Halliburton in his "Textbook of Chemical Physiology and Pathology" describes hæmatoidine as insoluble in water, alcohol, ether, acetic acid, dilute mineral acids and alkalies. I have found that sections of the cornea with this peculiar form of staining, after having been immersed in these different solutions, still contain the highly refracting granules as before.

He goes on to state that hæmatoidine is soluble in concentrated acids and caustic alkalies, and that when treated with fuming nitric acid the crystals give the same colour reaction as the bile pigment does (Gmelin's reaction). Salkowski found hæmatoidine to be identical chemically with bilirubin.

I have not been able to determine if the particles in the discoloured corneæ are present after treatment with strong acids and alkalies, because these reagents cause such changes of the tissue as to prevent any further satisfactory examination. With pieces of cornea from

two cases and a drop of fuming nitric acid, I obtained a beautiful play of colours passing from green to blue, to red, and then to a bright yellow.

The varying colour of the bile pigment or hæmatoidin in Gmelin's test, depends on the different degrees of its oxidation. Supposing this staining of the cornea to be due to the presence of hæmatoidine, then we have a satisfactory explanation of the difference in the colour of the stain which has been observed in different cases; it sometimes being greenish and sometimes rusty brown or red.

Halliburton reports that neither hæmatoidine nor bilirubin shows bands spectroscopically, but that both possess a strong absorption power for the violet end of the spectrum.

I have examined with the micro-spectroscope the stained portion of the cornea from two cases and there were no absorption bands whatever to be seen, only absorption of the violet end of the spectrum.

Hæmatoidine is a derivative of hæmoglobin and is free from iron. I have tested sections of the cornea from four cases with ferrocyanide of potassium and hydrochloric acid, and also with ammonium sulphide; the highly refracting granules were not stained black with the former or dark green with the latter test. In two of them, however, though the granules were not stained green, a substance which seemed to be confined to the interspaces between the laminæ of the corneæ was. In the logwood and eosine stained sections of these two corneæ, this substance did not show up very definitely but seemed to stain rather more with eosine and less with logwood than the surrounding fibrous tissue of the cornea.

Vossius,* in one of the cases he recorded, got a reaction with ammonium sulphate, and in the other with cyanide of potash indicating the presence of iron.

Weeks† applied to the sections of the cornea of the case he reported, the ferrocyanide test, and states that there appeared to be a faint reaction.

There occurs often, Halliburton says, in connection with blood extravasations and associated with hæmatoidine, a substance containing iron, to which Newmann has given the name Hæmosiderin.

I conclude then from microscopical, chemical and spectroscopical examination of these discoloured corneæ, that the discoloration is mainly due to hæmatoidine, but that in some of them it is associated with hæmosiderin.

Having determined the nature of the pigment the next thing to consider is its mode of entrance into the cornea. Vossius was of opinion that there was direct hæmorrhage into its substance, the blood coming from the vessels at the sclero-corneal margin. If this was the case red blood corpuscles would be found in the cornea, and the discoloration would occur from the periphery towards the centre.

In none of the seven cases I have examined microscopically have I found any blood corpuscles in the cornea, and in two cases which were under observation while the discoloration came on, it was noticed as soon in the centre as anywhere else. The fact of the discoloration always being associated with blood in the anterior chamber, makes it highly probable that it is the source from which the pigment is derived. Weeks says


* "Archiv für Ophthal.," B. xxxv., Ab. 2, S. 207.

† "New York Eye and Ear Infirmary Reports," Vol. i., Part 1, p. 37.

that it is probable that the pigment entered the substance of the cornea in the soluble form of hæmoglobin, and was there transformed into a salt not soluble in the fluids of the cornea. With this I quite agree, for it is obvious that there is no circulation of fluid in the cornea with sufficient force to disseminate the particles of hæmatoidine, which are insoluble in water and weak alkalies, throughout its substance.

Weeks is further of opinion that this hæmoglobin containing fluid entered the cornea through the spaces of Fontana. Seeing, however, that there is generally increase of tension in these eyes, due to the exit of fluids at the angle of the anterior chamber, being obstructed, and also as I have just mentioned that the discoloration appears as soon in the centre of the cornea as elsewhere ; I think it is more probable that the hæmoglobin enters the cornea by a process of diffusion through Descemet's membrane.

It can be easily realized that the process of clearing in the cornea after this discoloration is a slow one, when we consider that the substance which has to be removed—hæmatoidine—is insoluble in the fluid of the cornea, and that every particle has to be taken up by migratory leucocytes.



LIST OF AUTHORS QUOTED.

- Alt, 40, 66, 68
Ammon, von, 6, 125
Angelucci, 2
Arlt, 122
Armaignac, 98
Arnold, 13
- Badal, 70
Bader, 118
Balfour, 13
Bauer, 17
Beck, 102
Becker, 9, 17, 34
Bowman, Sir W., 46
Brailey, 67, 98
- Carion, Stellwag von, 17
Carmichael, 64
Critchett, Anderson, 72
Cross, Richardson, 73
- D'Ench, 9
Davidson, 35
Deutschmann, 25, 58
Dimmer, 89
Dixon, 17
Donders, 89
Dub, 31
- Ehrlich, 58
- Fuchs, 83, 123
- Gepner, jun., 17
Gräfe, von, 25, 34, 40, 117
Greef, 60
Griffith, John, 50, 60
Gunn, Marcus, 8
- Halliburton, 130, 132
Hess, 27, 43, 89
Heyl, 7
Horner, 30
Hulke, 17, 21, 23, 32, 75
Hutchinson, 22, 35
- Jacob, 63
Jäger, 25
Johnson, Lindsay, 91
- Kessler, 13
Kölliker, 2, 13
Kuhnt, 67
- Lagrange, 70
Lawford, 26, 127
Leber, 30, 89
Leplat, 59
Lieberkühn, 2, 13
Löwe, 2, 13
- Makrocki, 102
Manz, 100
Masse, 73, 75
Meyer, 89

- Michel, 68
Monoyer, 73
Müller, 17, 89

Nettleship, 10
Nicati, 59

Pagenstecher, H., 99
Pamard, 73

Rieke, 88
Rindfleisch, 91, 99, 100
Rockliffe, 73
Rothmund, 73
Rucke, 17

Salkowski, 130
Samelson, 102
Schœler, 58, 114
Schieff-Gemusens, 66
Schirmer, 18, 26, 27, 30, 34

Schmidt-Rimpler, 83
Schweinitz, de, 98
Smith, Priestley, 31, 92
Solly, 69
Stœber, 73
Sweigger, 72, 73

Uhthoff, 58

Vincenten, de, 89
Virchow, 130
Vogel, 35
Vossius, 132

Wardrop, 61, 63
Wecker, de, 89, 118
Weeks, 132, 133
Wells, Soelberg, 125

Zinn, 102

INDEX.

	PAGE
Aniridia, congenital	94, 99, 100
traumatic	111
Anterior synechiæ, congenital	101
Aqueous chamber, supposed analogy with serous sacs	63
humour, sources of	58
Bleaching sections of the eye	49
Bowman's membrane, distance of termination of, from Schlemm's canal	113
Bruch's membrane, development of	88, 91
Buphthalmos	104
Capsule of lens, adherent to extraction scar	108
cells lining it	12
development of	13
wounds of	18
Cataracts, anterior polar, how formed	21
structure of	14
when formed	20
with second deep opacity	19
concussion	127
congenital	37
hæmorrhagic	40
zonular, condition of teeth in connection with	35
due to intraocular causes	34
histological appearances of	25
in connection with rickets	36
measurements of opacity in	31, 33
theories as to formation	30
Choroid, colobomata of	91
development of	87
Cicatricial tissue, bands of, at periphery of cornea	114

Ciliary body, adenoma of	68
arrangement of pigment-epithelium of	56
carcinoma of	68
catarrhal inflammation of	61
cysts of	67
glands of	56, 60
overgrowth of gland tissue from	66
plastic inflammation of	65
prolapse of, after iridectomy	120
suppurative inflammation of	65
muscle, split by concussion	124
Concussion, changes produced by	123
effects of, on eye	122
Cornea, blood staining of	128
cysts of	78
Cystoid cicatrices	116
Eyelashes implanted into eye	72
Fœtal eyes, diameters of	5
Fibro-vascular sheath of lens, anterior, development of	93
persistence of	14
posterior	43
Glaucoma, after extraction of cataract	107
after needling opaque membranes	110
and congenital absence of iris	94
and traumatic aniridia	111
cases of, difficult to explain	93
congenital	104
failure of iridectomy in	118
iridectomy, successful in	115
how performed	112
theories regarding its action	112
scleral puncture for	119
Glioma of retina, cells in	84
how it differs from sarcoma	86
Hæmatoidine	130

Hæmosiderin	132
Hyaline membrane beneath anterior polar cataract	16
nodules on inner surface of choroid	88
Implantation epithelial cysts	74
Iridectomedialysis	112, 119
Iridodialysis	124
Iris, arrangement of pigment-epithelium of	50
coloboma of	97
congenital absence of	94, 99
cysts due to separation of pigment epithelial layers	51
endothelial	83
epithelial	74
development of	93
disappearance of portion of, after concussion	125
ectropion of pigment-epithelium	54
of the horse	55
Keratitis punctata	63
Lens, coloboma of	7
congenital dislocation of	9
dislocation of, into anterior chamber	127
appearances simulated	128
foetal diameters of	5
opacities of (<i>see</i> Cataract).	
Ligamentum pectinatum, rupture of, from concussion	124
Muscæ volitantes	47
Pupillary membranes	14, 94, 101
Retina in foetal eyes	6, 84
Rickets in connection with zonular cataracts	36
Scleral puncture for glaucoma	119
Sphincter muscle of iris, rupture of	126
Suspensory ligament of lens, development of	2, 4
torn after concussion	127

Sympathetic ophthalmitis	64
Synechiæ, anterior, congenital	101
Syphilitic uveitis	65
Teeth, condition of, in connection with zonular cataract	35
Vitreous, central artery of, in foetal eyes	46
persistence of	2, 37, 43, 44
of sheath of	47
congenital fibrous membranes in	40
development of	44
fibrils in	45
nutrient fluid of	58



December, 1895.

CATALOGUE OF WORKS

PUBLISHED BY

H. K. LEWIS

136 GOWER STREET, LONDON, W.C.

Established 1844.

A. C. ABBOTT, M.D.

First Assistant, Laboratory of Hygiene, University of Pennsylvania.

THE PRINCIPLES OF BACTERIOLOGY: A Practical
Manual for Students and Physicians. With Illustrations, post 8vo, 7s. 6d.

H. ALDERSMITH, M.B. LOND., F.R.C.S.

Resident Medical Officer, Christ's Hospital, London.

RINGWORM: Its Diagnosis and Treatment. Fourth Edition, enlarged, with Illustrations, fcap. 8vo. [In preparation.]

HARRISON ALLEN, M.D.

Consulting Physician to Rush Hospital for Consumption.

A HANDBOOK OF LOCAL THERAPEUTICS. General Surgery by R. H. HARTE, M.D., Surgeon to the Episcopal and St. Mary's Hospitals; Diseases of the Skin by A. VAN HARLINGEN, M.D., Professor of Diseases of the Skin in the Philadelphia Polyclinic; Diseases of the Ear and Air Passages by H. ALLEN, M.D.; Diseases of the Eye by G. C. HARLAN, M.D., Surgeon to Wills Eye Hospital. Edited by H. ALLEN, M.D. Large 8vo, 14s. nett.

JAMES ANDERSON, M.D., F.R.C.P.

Late Assistant Physician to the London Hospital, &c.

NOTES ON MEDICAL NURSING from the Lectures given to the Probationers at the London Hospital. Edited by E. F. LAMPORT, Associate of the Sanitary Institute. With an Introductory Biographical Notice by the late SIR ANDREW CLARK, BART. Second edition, crown 8vo, 2s. 6d.

E. CRESSWELL BABER, M.B. LOND.

Surgeon to the Brighton and Sussex Throat and Ear Hospital.

A GUIDE TO THE EXAMINATION OF THE NOSE,
WITH REMARKS ON THE DIAGNOSIS OF DISEASES OF
THE NASAL CAVITIES. With Illustrations, small 8vo, 5s. 6d.

JAMES B. BALL, M.D. LOND., M.R.C.P.

Physician to the Department for Diseases of the Throat and Nose, and Senior Assistant Physician, West London Hospital.

INTUBATION OF THE LARYNX. With Illustrations, demy 8vo, 2s. 6d.

G. GRANVILLE BANTOCK, M.D., F.R.C.S. EDIN.
Surgeon to the Samaritan Free Hospital for Women and Children.

I.

ON THE USE AND ABUSE OF PESSARIES. Second Edition, with Illustrations, 8vo, 5s.

II.

ON THE TREATMENT OF RUPTURE OF THE FEMALE PERINEUM IMMEDIATE AND REMOTE. Second Edition, with Illustrations, 8vo, 3s. 6d.

III.

A PLEA FOR EARLY OVARIOTOMY. Demy 8vo, 2s.

FANCOURT BARNES, M.D., M.R.C.P.

Physician to the Chelsea Hospital for Women; Obstetric Physician to the Great Northern Hospital, &c.

A GERMAN-ENGLISH DICTIONARY OF WORDS AND TERMS USED IN MEDICINE AND ITS COGNATE SCIENCES. Square 12mo, Roxburgh binding, 9s.

JAMES BARR, M.D.

Physician to the Northern Hospital, Liverpool; Medical Officer of Her Majesty's Prison, Kirkdale, &c.

THE TREATMENT OF TYPHOID FEVER, and reports of fifty-five consecutive cases with only one death. With Introduction by W. T. GAIRDNER, M.D., LL.D., Professor of Medicine in the University of Glasgow. With Illustrations, demy 8vo, 6s.

ASHLEY W. BARRETT, M.B. LOND., M.R.C.S., L.D.S.E.
Dental Surgeon to, and Lecturer on Dental Surgery in the Medical School of, the London Hospital.

DENTAL SURGERY FOR MEDICAL PRACTITIONERS AND STUDENTS OF MEDICINE. Second Edition, with Illustrations, cr. 8vo, 3s. 6d. [LEWIS'S PRACTICAL SERIES.]

ROBERTS BARTHOLOW, M.A., M.D., LL.D.

Professor Emeritus of Materia Medica, General Therapeutics, and Hygiene in the Jefferson Medical College of Philadelphia, &c., &c.

I.

A PRACTICAL TREATISE ON MATERIA MEDICA AND THERAPEUTICS. Eighth Edition, revised and enlarged, large 8vo, 21s.

II.

A TREATISE ON THE PRACTICE OF MEDICINE, FOR THE USE OF STUDENTS AND PRACTITIONERS. Fifth Edition, with Illustrations, large 8vo, 21s.

H. CHARLTON BASTIAN, M.A., M.D., F.R.S., F.R.C.P.
Professor of the Principles and Practice of Medicine in University College, London; Physician to University College Hospital, &c.

I.

PARALYSES: CEREBRAL, BULBAR, AND SPINAL. A MANUAL OF DIAGNOSIS FOR STUDENTS AND PRACTITIONERS. With numerous Illustrations, 8vo, 12s. 6d.

II.

VARIOUS FORMS OF HYSTERICAL OR FUNCTIONAL PARALYSIS. Demy 8vo, 7s. 6d.

GEO. M. BEARD, A.M., M.D.

AND
A. D. ROCKWELL, A.M., M.D.

*Formerly Professor of Electro-Therapeutics in the New York Post Graduate Medical School ;
Fellow of the New York Academy of Medicine, &c.*

I
ON THE MEDICAL AND SURGICAL USES OF ELECTRICITY. Eighth Edition. With over 200 Illustrations, roy. 8vo, 28s.

II
NERVOUS EXHAUSTION (NEURASTHENIA) ITS HYGIENE, CAUSES, SYMPTOMS AND TREATMENT. Second Edition, 8vo, 7s. 6d.

W. M. BEAUMONT.

Surgeon to the Bath Eye Infirmary.

THE SHADOW-TEST IN THE DIAGNOSIS AND ESTIMATION OF AMETROPIA. Post 8vo, 2s. 6d.

F. E. BEDDARD, M.A., F.R.S.

[See Cambridge Natural Science Manuals, page 5.]

E. H. BENNETT, M.D., F.R.C.S.I.

Professor of Surgery, University of Dublin,

AND
D. J. CUNNINGHAM, M.D., F.R.C.S.I.

Professor of Anatomy and Chirurgery, University of Dublin.

THE SECTIONAL ANATOMY OF CONGENITAL CÆCAL HERNIA. With coloured plates, sm. folio, 5s. 6d.

A. HUGHES BENNETT, M.D., M.R.C.P.

Physician to the Hospital for Epilepsy and Paralysis, Regent's Park, &c.

I
A PRACTICAL TREATISE ON ELECTRO-DIAGNOSIS IN DISEASES OF THE NERVOUS-SYSTEM. With Illustrations, 8vo, 8s. 6d.

II
ILLUSTRATIONS OF THE SUPERFICIAL NERVES AND MUSCLES, WITH THEIR MOTOR POINTS; a knowledge of which is essential in the Art of Electro-Diagnosis. 8vo, cloth, 2s.

HORATIO R. BIGELOW, M.D.

Permanent Member of the American Medical Association, &c.

PLAIN TALKS ON ELECTRICITY AND BATTERIES, WITH THERAPEUTIC INDEX, FOR GENERAL PRACTITIONERS AND STUDENTS OF MEDICINE. With Illustrations, crown 8vo, 4s. 6d.

DRS. BOURNEVILLE AND BRICON.

MANUAL OF HYPODERMIC MEDICATION.

Translated from the Second Edition, and Edited, with Therapeutic Index of Diseases, by ANDREW S. CURRIE, M.D. Edin., &c. With Illustrations, crown 8vo, 3s. 6d.

ROBERT BOXALL, M.D. CANTAB., M.R.C.P. LOND.
Assistant Obstetric Physician at the Middlesex Hospital, &c.

ANTISEPTICS IN MIDWIFERY. 8vo. 1s.

RUBERT BOYCE, M.B., M.R.C.S.
Professor of Pathology in University College, Liverpool.

A TEXT-BOOK OF MORBID HISTOLOGY for Students
and Practitioners. With 130 coloured Illustrations, royal 8vo, 31s. 6d.

GURDON BUCK, M.D.

CONTRIBUTIONS TO REPARATIVE SURGERY:
Showing its Application to the Treatment of Deformities, produced by
Destructive Disease or Injury; Congenital Defects from Arrest or Excess
of Development; and Cicatricial Contractions from Burns. Large 8vo, 9s.

MARY BULLAR & J. F. BULLAR, M.B. CANTAB., F.R.C.S.
RECIPTS FOR FLUID FOODS. 16mo, 1s.

CHARLES H. BURNETT, A.M., M.D.
*Emeritus Professor of Otology in the Philadelphia Polyclinic; Clinical Professor of Otology
in the Woman's Medical College of Pennsylvania; Aural Surgeon
to the Presbyterian Hospital, Philadelphia.*

**SYSTEM OF DISEASES OF THE EAR, NOSE AND
THROAT.** By 45 Eminent American, British, Canadian and Spanish
Authors. Edited by CHARLES H. BURNETT. With Illustrations, in
two imperial 8vo vols., half morocco, 48s. *nett.*

STEPHEN SMITH BURT, M.D.
*Professor of Clinical Medicine and Physical Diagnosis in the New York Post-graduate
School and Hospital.*

**EXPLORATION OF THE CHEST IN HEALTH AND
DISEASE.** With Illustrations, crown 8vo, 6s.

DUDLEY W. BUXTON, M.D., B.S., M.R.C.P.
*Administrator of Anæsthetics and Lecturer in University College Hospital, the National
Hospital for Paralysis and Epilepsy, Queen's Square, and the Dental Hospital of London.*

ANÆSTHETICS THEIR USES AND ADMINISTRATION. Second Edition, with Illustrations, crown 8vo, 5s.

[LEWIS'S PRACTICAL SERIES.]

CAMBRIDGE NATURAL SCIENCE MANUALS.

BIOLOGICAL SERIES.

(General Editor: A. E. SHIPLEY, M.A., Fellow and Tutor of Christ's College).

ELEMENTARY PALÆONTOLOGY—INVERTEBRATE.

By HENRY WOODS, B.A., F.G.S. Crown 8vo, 6s.

PRACTICAL PHYSIOLOGY OF PLANTS.

By F. DARWIN, M.A., F.R.S. and E. H. ACTON, M.A. Second Edition, crown 8vo, 6s.

PRACTICAL MORBID ANATOMY.

By H. D. ROLLESTON, M.D., F.R.C.P., Fellow of St. John's College, Cambridge; Assistant Physician and Lecturer on Pathology, St. George's Hospital, London; and A. A. KANTHACK, M.D., M.R.C.P., Lecturer on Pathology, St. Bartholomew's Hospital, London. Crown 8vo, 6s.

ZOOGEOGRAPHY.

By F. E. BEDDARD, M.A., F.R.S. Crown 8vo, 6s.

ELEMENTS OF BOTANY.

By F. DARWIN, M.A., F.R.S. Crown 8vo, 6s.

FOSSIL PLANTS. A Manual for Students of Botany and Geology.

By A. C. SEWARD, M.A., F.G.S. [In Preparation.]

PHYSICAL SERIES.

(General Editor: R. T. GLAZEBROOK, M.A., F.R.S., Fellow of Trinity College; Assistant Director of the Cavendish Laboratory).

HEAT AND LIGHT.

By R. T. GLAZEBROOK. Crown 8vo, 5s. (The two parts are also published separately). HEAT, 3s. LIGHT, 3s.

MECHANICS AND HYDROSTATICS.

By the same Author. Crown 8vo, 8s. 6d. Part I.—DYNAMICS, 4s. Part II.—STATICS, 3s. Part III.—HYDROSTATICS, 3s.

ELECTRICITY AND MAGNETISM.

By the same Author.

[In preparation.]

SOLUTION AND ELECTROLYSIS.

By W. C. D. WHETHAM, M.A., Fellow of Trinity College. Crown 8vo, 7s. 6d.

ELEMENTS OF PETROLOGY.

By A. HARKER, M.A., F.G.S., Fellow of St. John's College; University Demonstrator of Petrology. Crown 8vo, 7s. 6d.

HARRY CAMPBELL, M.D., B.S. LOND., M.R.C.P.
Physician to the North-West London Hospital.

I.
THE CAUSATION OF DISEASE: An exposition of the ultimate factors which induce it. Demy 8vo, 12s. 6d.

II.
FLUSHING AND MORBID BLUSHING: THEIR PATHOLOGY AND TREATMENT. With plates and wood engravings, royal 8vo, 10s. 6d.

III.
DIFFERENCES IN THE NERVOUS ORGANISATION OF MAN AND WOMAN, PHYSIOLOGICAL AND PATHOLOGICAL. Royal 8vo, 15s.

IV.
HEADACHE AND OTHER MORBID CEPHALIC SENSATIONS. Royal 8vo, 12s. 6d. [*Just published.*]

R. E. CARRINGTON, M.D., F.R.C.P.
Late Assistant Physician and Senior Demonstrator of Morbid Anatomy at Guy's Hospital.
NOTES ON PATHOLOGY. With an Introductory Chapter by J. F. GOODHART, M.D. (ABERD.), F.R.C.P., Physician to Guy's Hospital, Edited by H. EVELYN CROOK, M.D. LOND., F.R.C.S. ENG., and GUY MACKESON, L.R.C.P., M.R.C.S. Crown 8vo, 3s. 6d.

ALFRED H. CARTER, M.D. LOND.
Fellow of the Royal College of Physicians; Senior Physician to the Queen's Hospital, Birmingham; Professor of Therapeutics in Mason College, Birmingham.
ELEMENTS OF PRACTICAL MEDICINE. Seventh Edition, crown 8vo, 10s. [*Now ready.*]

F. H. CHAMPNEYS, M.A., M.D. OXON., F.R.C.P.
Physician-Accoucheur and Lecturer on Obstetric Medicine at St. Bartholomew's Hospital; Examiner in Obstetric Medicine in the University of Oxford, &c.

I.
LECTURES ON PAINFUL MENSTRUATION. THE HARVEIAN LECTURES, 1890. Roy. 8vo, 7s. 6d.

II.
EXPERIMENTAL RESEARCHES IN ARTIFICIAL RESPIRATION IN STILLBORN CHILDREN, AND ALLIED SUBJECTS. Crown 8vo, 3s. 6d.

W. BRUCE CLARKE, M.A., M.B. OXON., F.R.C.S.
Assistant Surgeon to, and Senior Demonstrator of Anatomy and Operative Surgery at St. Bartholomew's Hospital; Surgeon to the West London Hospital, &c.
THE DIAGNOSIS AND TREATMENT OF DISEASES OF THE KIDNEY AMENABLE TO DIRECT SURGICAL INTERFERENCE. With Illustrations, demy 8vo, 7s. 6d.

JOHN COCKLE, M.A., M.D.
Physician to the Royal Free Hospital.
ON INTRA-THORACIC CANCER. 8vo, 4s. 6d.

ALEXANDER COLLIE, M.D. ABERD., M.R.C.P. LOND.
Secretary of the Epidemiological Society for Germany and Russia, &c.
ON FEVERS: THEIR HISTORY, ETIOLOGY, DIAGNOSIS, PROGNOSIS, AND TREATMENT. Illustrated with Coloured Plates, crown 8vo, 8s. 6d. [LEWIS'S PRACTICAL SERIES.]

M. P. MAYO COLLIER, M.B., M.S. LOND., F.R.C.S. ENG.
*Professor of Comparative Anatomy and Physiology at the Royal College of Surgeons,
England, &c.*

THE PHYSIOLOGY OF THE VASCULAR SYSTEM.
Illustrations, 8vo, 3s. 6d.

WALTER S. COLMAN, M.B., M.R.C.P. LOND.
Pathologist and Registrar to the National Hospital for the Paralysed and Epileptic.

SECTION CUTTING AND STAINING: A Practical
Guide to the Preparation of Normal and Morbid Histological Specimens.
Crown 8vo, 3s.

W. H. CORFIELD, M.A., M.D. OXON., F.R.C.P. LOND.
*Professor of Hygiene and Public Health in University College, London; Medical Officer
of Health for St. George's, Hanover Square, &c.*

DWELLING HOUSES: their Sanitary Construction and
Arrangements. Third Edition, with Illustrations, crown 8vo, 3s. 6d.

J. LEONARD CORNING, M.A., M.D.
Consultant in Nervous Diseases to St. Francis Hospital.

A PRACTICAL TREATISE ON HEADACHE, NEU-
RALGIA, SLEEP AND ITS DERANGEMENTS, AND SPINAL
IRRITATION. With an Appendix—Eye Strain, a Cause of Headache
By **DAVID WEBSTER**, M.D. Second Edition, demy 8vo, 7s. 6d.

EDWARD COTTERELL, F.R.C.S. ENG., L.R.C.P. LOND.
Late House Surgeon, University College Hospital.

ON SOME COMMON INJURIES TO LIMBS; their
Treatment and After-treatment, including Bone-setting (so-called).
With Illustrations, small 8vo, 3s. 6d.

SIDNEY COUPLAND, M.D., F.R.C.P.
*Physician to the Middlesex Hospital, and Lecturer on Practical Medicine in the Medical
School; late Examiner in Medicine at the Examining Board for England.*

NOTES ON THE CLINICAL EXAMINATION OF THE
BLOOD AND EXCRETA. Third Edition, 12mo, 1s. 6d.

CHARLES CREIGHTON, M.A., M.D.
Formerly Demonstrator of Anatomy in the University of Cambridge.

I.
A HISTORY OF EPIDEMICS IN BRITAIN, Vol. I.
FROM A.D. 664 TO THE EXTINCTION OF THE PLAGUE.
Demy 8vo, 18s. Vol. II. FROM THE EXTINCTION OF THE
PLAGUE TO THE PRESENT TIME. Demy 8vo, 20s.

II.
ILLUSTRATIONS OF UNCONSCIOUS MEMORY IN
DISEASE, including a Theory of Alteratives. Post 8vo, 6s.

III.
CONTRIBUTIONS TO THE PHYSIOLOGY AND
PATHOLOGY OF THE BREAST AND LYMPHATIC GLANDS.
New Edition with additional chapter, with wood-cuts and plate, 8vo, 9s.

IV.
BOVINE TUBERCULOSIS IN MAN: An Account of the
Pathology of Suspected Cases. With Chromo-lithographs and other
Illustrations, 8vo, 8s. 6d.

H. RADCLIFFE CROCKER, M.D. LOND., B.S., F.R.C.P.

Physician for Diseases of the Skin in University College Hospital, &c.

DISEASES OF THE SKIN; THEIR DESCRIPTION, PATHOLOGY, DIAGNOSIS, AND TREATMENT. Second Edition, with 92 Illustrations, 8vo, 24s.

EDGAR M. CROOKSHANK, M.B. LOND.

Professor of Comparative Pathology and Bacteriology in, and Fellow of, King's College London.

I.

MANUAL OF BACTERIOLOGY: Illustrated with Coloured Plates from original drawings, and with other Illustrations in the text. Third Edition, 8vo, 21s.

II.

HISTORY AND PATHOLOGY OF VACCINATION. Vol. I., A Critical Inquiry. Vol. II., Selected Essays, (Edited) including works by Jenner, Pearson, Woodville, Henry Jenner, Loy, Rogers, Birch, Bousquet, Estlin, Ceely, Badcock, Auzias-Turenne, Dubreuilh and Layet. Two volumes, illustrated with 22 coloured plates. Royal 8vo, 20s. *nett.*

J. BRENDON CURGENVEN, M.R.C.S., L.S.A.

Formerly House Surgeon to the Royal Free Hospital; Honorary Secretary of the Harveian Society, the Infant Life Protection Society, &c.

THE DISINFECTION OF SCARLET FEVER AND OTHER DISEASES BY ANTISEPTIC INUNCTION. 8vo, 1s. 6d.

F. DARWIN, M.A., F.R.S.

[See Cambridge Natural Science Manuals, page 5.]

HERBERT DAVIES, M.D., F.R.C.P.

Late Consulting Physician to the London Hospital.

THE MECHANISM OF THE CIRCULATION OF THE BLOOD THROUGH ORGANICALLY DISEASED HEARTS. Edited by ARTHUR TEMPLER DAVIES, B.A. (Nat. Science Honours), M.D. Cantab., M.R.C.P.; Physician to the Royal Hospital for Diseases of the Chest. Crown 8vo, 3s. 6d.

HENRY DAVIS, M.R.C.S.

Teacher and Administrator of Anæsthetics at St. Mary's Hospital, and Assistant Anæsthetist to the Dental Hospital of London.

GUIDE TO THE ADMINISTRATION OF ANÆSTHETICS. Second Edition, fcap. 8vo, 2s. 6d.

J. THOMPSON DICKSON, M.A., M.B. CANTAB.

Late Lecturer on Mental Diseases at Guy's Hospital.

THE SCIENCE AND PRACTICE OF MEDICINE IN RELATION TO MIND, the Pathology of the Nerve Centres, and the Jurisprudence of Insanity, being a course of Lectures delivered at Guy's Hospital. Illustrated by Chromo-lithographic Drawings and Physiological Portraits. 8vo, 14s.

F. A. DIXEY, M.A., D.M.

Fellow of Wadham College, Oxford.

EPIDEMIC INFLUENZA: A Study in Comparative Statistics. With Diagrams and Tables. 8vo, 7s. 6d.

HORACE DOBELL, M.D.

Consulting Physician to the Royal Hospital for Diseases of the Chest, &c.

ON DIET AND REGIMEN IN SICKNESS AND Health, and on the Interdependence and Prevention of Diseases and the Diminution of their Fatality. Seventh Edition, 8vo, 5s. *nett.*

DR. A. DUHRSEN.

Privat Docent in Midwifery and Gynæcology in the University of Berlin.

A MANUAL OF GYNÆCOLOGICAL PRACTICE FOR STUDENTS AND PRACTITIONERS. Translated and Edited from the Fourth German edition, by JOHN W. TAYLOR, F.R.C.S., Surgeon to the Birmingham and Midland Hospital for Women, &c.; and FREDERICK EDGE, M.D. LOND., M.R.C.P., F.R.C.S., Surgeon to the Wolverhampton and District Hospital for Women. With 120 Illustration, crown 8vo, 6s. [Now ready.]

JOHN EAGLE.

Member of the Pharmaceutical Society.

A NOTE-BOOK OF SOLUBILITIES. Arranged chiefly for the use of Prescribers and Dispensers. 12mo, 2s. 6d.

ARTHUR W. EDIS, M.D. LOND., F.R.C.P.

Senior Physician to the Chelsea Hospital for Women; Late Obstetric Physician to the Middlesex Hospital.

STERILITY IN WOMEN: including its Causation and Treatment. With 33 Illustrations, demy 8vo, 6s.

ALEXANDER S. FAULKNER.

Surgeon-Major, Indian Medical Service.

A GUIDE TO THE PUBLIC MEDICAL SERVICES. Compiled from Official Sources. 8vo, 2s.

W. SOLTAU FENWICK, M.D., B.S. LOND.

Member of the Royal College of Physicians; Assistant Physician to the Evelina Hospital for Sick Children, &c.

THE DYSPEPSIA OF PHTHISIS: Its Varieties and Treatment, including a Description of Certain Forms of Dyspepsia associated with the Tubercular Diathesis. Demy 8vo, 6s. [Now ready.]

DR. FERBER.

MODEL DIAGRAM OF THE ORGANS IN THE THORAX AND UPPER PART OF THE ABDOMEN. With Letter-press Description. In 4to, coloured, 5s.

J. MAGEE FINNY, M.D. DUBL.

King's Professor of Practice of Medicine in School of Physic, Ireland, &c.

NOTES ON THE PHYSICAL DIAGNOSIS OF LUNG DISEASES. 32mo, 1s. 6d.

AUSTIN FLINT, M.D., LL.D.

Professor of Physiology and Physiological Anatomy in the Bellevue Hospital Medical College, New York; Visiting Physician to the Bellevue Hospital, &c.

A TEXT-BOOK OF HUMAN PHYSIOLOGY. Fourth Edition, Illustrated by plates, and 316 wood engravings, large 8vo, 25s.

W. H. RUSSELL FORSBROOK, M.D. LOND., M.R.C.S.

Consulting Medical Officer to the Government of the Cape of Good Hope; formerly Surgical Registrar to Westminster Hospital.

A DISSERTATION ON OSTEO-ARTHRITIS. Demy 8vo, 5s.

J. MILNER FOTHERGILL, M.D., M.R.C.P.

Late Physician to the City of London Hospital for Diseases of the Chest, Victoria Park, &c.

I.

INDIGESTION AND BILIOUSNESS. Second Edition, post 8vo, 7s. 6d.

II.

GOUT IN ITS PROTEAN ASPECTS. Post 8vo, 7s. 6d.

III.

THE TOWN DWELLER: His Needs and His Wants.
With an Introduction by SIR B. W. RICHARDSON, M.D., LL.D., F.R.S.
Post 8vo, 3s. 6d.

PROFESSOR E. FUCHS.

Professor of Ophthalmology in the University of Vienna.

TEXTBOOK OF OPHTHALMOLOGY.

Translated from the German by A. DUANE, M.D., Assistant Surgeon, Ophthalmic and Aural Institute, New York. Second Edition, with 190 Illustrations, large octavo, 21s.

PROFESSOR DR. PAUL FÜRBRINGER.

Director of the Friedrichshain Hospital, Berlin, &c.

TEXT-BOOK OF DISEASES OF THE KIDNEYS AND GENITO-URINARY ORGANS. Translated by W. H. GILBERT, M.D., Physician in Baden-Baden, &c. Vol. I., demy 8vo, 7s. 6d.

SIR DOUGLAS GALTON.

Late Royal Engineers, K.C.B., Hon. D.C.L., LL.D., F.R.S., Assoc. Inst. C.E., M.I.Mech.E., F.S.A., F.G.S., F.L.S., F.C.S., F.R.G.S., &c.

HEALTHY HOSPITALS. Observations on some points connected with Hospital Construction. With Illustrations, 8vo, 10s. 6d.

JOHN HENRY GARRETT, M.D.

Licentiate in Sanitary Science and Diplomate in Public Health, Universities of Durham and Cambridge, &c.

THE ACTION OF WATER ON LEAD; being an inquiry into the Cause and Mode of the Action and its Prevention. Crown 8vo, 4s. 6d.

ALFRED W. GERRARD, F.C.S.

Examiner to the Pharmaceutical Society, &c.

ELEMENTS OF MATERIA MEDICA AND PHARMACY. Crown 8vo, 8s. 6d.

II.

NEW OFFICIAL REMEDIES, B.P., 1890. Supplement to the above. Crown 8vo, 1s.

HENEAGE GIBBES, M.D.

Lecturer on Physiology in the Medical School of Westminster Hospital, &c.

PRACTICAL HISTOLOGY AND PATHOLOGY.

Third Edition, revised and enlarged, crown 8vo, 6s.

R. T. GLAZEBROOK, M.A., F.R.S.

[See Cambridge Natural Science Manuals, page 5.]

JAMES F. GOODHART, M.D. ABERD., F.R.C.P.

Physician to Guy's Hospital, and Consulting Physician to the Evelina Hospital for Sick Children.

ON COMMON NEUROSES: or the Neurotic Element in Disease and its Rational Treatment. Second Edition, crown 8vo, 3s. 6d.

C. A. GORDON, M.D., C.B.

Deputy Inspector General of Hospitals, Army Medical Department.

REMARKS ON ARMY SURGEONS AND THEIR WORKS. Demy 8vo, 5s.

JOHN GORHAM, M.R.C.S.

TOOTH EXTRACTION: a Manual on the proper mode of extracting Teeth. Fourth Edition, fcap. 8vo, 1s. 6d.

GEORGE M. GOULD, A.M., M.D.

Ophthalmic Surgeon to the Philadelphia Hospital, &c.

I.

A NEW MEDICAL DICTIONARY: including all the words and phrases used in Medicine, with their proper pronunciation and definitions. 8vo, 12s. 6d.

II.

A POCKET MEDICAL DICTIONARY, Giving the Pronunciation and Definition of about 12000 of the Principal Words used in Medicine and the Collateral Sciences. 32mo, 4s. nett.

W. R. GOWERS, M.D., F.R.C.P., M.R.C.S.

Physician to University College Hospital, &c.

DIAGRAMS FOR THE RECORD OF PHYSICAL SIGNS.
In books of 12 sets of figures, 1s.

SURGEON-CAPTAIN A. E. GRANT, M.B.

Indian Medical Service; Professor of Hygiene, Madras Medical College.

THE INDIAN MANUAL OF HYGIENE.

Vol. I., 8vo, 10s. 6d. nett.

LANDON C. GRAY, M.D.

Professor of Nervous and Mental Diseases in the New York Polyclinic; Visiting Physician to St. Mary's Hospital, &c.

A TREATISE ON NERVOUS AND MENTAL DISEASES FOR STUDENTS AND PRACTITIONERS OF MEDICINE. With 168 illustrations, 8vo, 21s.

J. B. GRESSWELL, M.R.C.V.S.

Provincial Veterinary Surgeon to the Royal Agricultural Society.

VETERINARY PHARMACOLOGY AND THERAPEUTICS. With an Index of Diseases and Remedies. Fcap. 8vo, 5s.

A. HILL GRIFFITH, M.D.

Surgeon, Manchester Royal Eye Hospital.

THE DIAGNOSIS OF INTRA-OCULAR GROWTHS.

With 8 woodcuts, 8vo, 1s. 6d.

SAMUEL D. GROSS, M.D., LL.D., D.C.L. OXON.

Professor of Surgery in the Jefferson Medical College of Philadelphia.

A PRACTICAL TREATISE ON THE DISEASES, INJURIES, AND MALFORMATIONS OF THE URINARY BLADDER, THE PROSTATE GLAND, AND THE URETHRA. Third Edition, revised and edited by S. W. GROSS, A.M., M.D., Surgeon to the Philadelphia Hospital. Illustrated by 170 engravings, 8vo, 18s.

SAMUEL W. GROSS, A.M., M.D.

Surgeon to, and Lecturer on Clinical Surgery in, the Jefferson Medical College Hospital and the Philadelphia Hospital, &c.

A PRACTICAL TREATISE ON TUMOURS OF THE MAMMARY GLAND: embracing their Histology, Pathology, Diagnosis, and Treatment. With Illustrations, 8vo, 10s. 6d.

DR. JOSEF GRUBER.

Professor of Otology in the University of Vienna, etc.

A TEXT-BOOK OF THE DISEASES OF THE EAR. Translated from the Second German edition, and Edited, with additions, by EDWARD LAW, M.D., C.M. EDIN., M.R.C.S. ENG., Surgeon to the London Throat Hospital for Diseases of the Throat, Nose and Ear; and COLEMAN JEWELL, M.B. LOND., M.R.C.S. ENG., late Surgeon and Pathologist to the London Throat Hospital. Second English Edition, with 165 Illustrations, and 70 coloured figures on 2 lithographic plates, royal 8vo, 28s.

F. DE HAVILLAND HALL, M.D., F.R.C.P. LOND.

Physician to Out-patients, and in charge of the Throat Department at the Westminster Hospital, &c.

DISEASES OF THE NOSE AND THROAT. Crown 8vo, with 2 coloured plates and 59 illustrations, 10s. 6d. [Now ready.]
[LEWIS'S PRACTICAL SERIES.]

WILLIAM A. HAMMOND, M.D.

Professor of Mental and Nervous Diseases in the Medical Department of the University of the City of New York, &c.

SPIRITUALISM AND ALLIED CAUSES AND CONDITIONS OF NERVOUS DERANGEMENT. With Illustrations, post 8vo, 8s. 6d.

A. HARKER, M.A., F.G.S.

[See Cambridge Natural Science Manuals, page 5.]

VINCENT DORMER HARRIS, M.D. LOND., F.R.C.P.

Physician to the City of London Hospital for Diseases of the Chest, Victoria Park; Examining Physician to the Royal National Hospital for Consumption and Diseases of the Chest, Ventnor, &c.

AND

EDWIN CLIFFORD BEALE, M.A., M.B. CANTAB., F.R.C.P.
Physician to the City of London Hospital for Diseases of the Chest, Victoria Park, and to the Great Northern Central Hospital, &c.

THE TREATMENT OF PULMONARY CONSUMPTION.
A Practical Manual. Crown 8vo, 10s. 6d. [Now ready.]
[LEWIS'S PRACTICAL SERIES.]

ALEXANDER HARVEY, M.D.

Late Emeritus Professor of Materia Medica in the University of Aberdeen, &c.,

AND

ALEXANDER DYCE DAVIDSON, M.D., F.R.S. EDIN.

Late Regius Professor of Materia Medica in the University of Aberdeen.

SYLLABUS OF MATERIA MEDICA FOR THE USE OF STUDENTS, TEACHERS AND PRACTITIONERS. Based on the relative values of articles and preparations in the British Pharmacopœia. Ninth Edition, 32mo, 1s. 6d.

H. HELBING, F.C.S.

MODERN MATERIA MEDICA: FOR MEDICAL MEN, PHARMACISTS, AND STUDENTS. Fourth Edition, 8vo, 8s. nett.
[Just published.]

C. HIGGENS, F.R.C.S.

Ophthalmic Surgeon to Guy's Hospital; Lecturer on Ophthalmology at Guy's Hospital Medical School.

MANUAL OF OPHTHALMIC PRACTICE.

Illustrations, crown 8vo, 6s.

[LEWIS'S PRACTICAL SERIES.]

BERKELEY HILL, M.B. LOND., F.R.C.S.

Professor of Clinical Surgery in University College; Surgeon to University College Hospital and to the Lock Hospital.

THE ESSENTIALS OF BANDAGING. With directions for Managing Fractures and Dislocations; for administering Ether and Chloroform; and for using other Surgical Apparatus; with a Chapter on Surgical Landmarks. Sixth Edition, revised and enlarged, Illustrated by 144 Wood Engravings, crown 8vo, 5s.

BERKELEY HILL, M.B. LOND., F.R.C.S.

Professor of Clinical Surgery in University College; Surgeon to University College Hospital and to the Lock Hospital;

AND

ARTHUR COOPER, L.R.C.P., M.R.C.S.

Surgeon to the Westminster General Dispensary.

SYPHILIS AND LOCAL CONTAGIOUS DISORDERS.

Second Edition, entirely re-written, royal 8vo, 18s.

FROM HOSPITAL WARD TO CONSULTING ROOM, with Notes by the Way; a Medical Autobiography. By a Graduate of the London University. Post 8vo, 3s. 6d.

PROCTER S. HUTCHINSON, M.R.C.S.

Assistant Surgeon to the Hospital for Diseases of the Throat.

A MANUAL OF DISEASES OF THE NOSE AND THROAT; including the Nose, Naso-pharynx, Pharynx, and Larynx. With Illustrations, crown 8vo, 3s. 6d.

SIR W. JENNER, Bart., M.D.

Physician in Ordinary to H.M. the Queen, and to H.R.H. the Prince of Wales.

THE PRACTICAL MEDICINE OF TO-DAY: Two Addresses delivered before the British Medical Association, and the Epidemiological Society, (1869). Small 8vo, 1s. 6d.

GEORGE LINDSAY JOHNSON, M.A., M.B., B.C. CANTAB.
Clinical Assistant, late House Surgeon and Chloroformist, Royal Westminster Ophthalmic Hospital, &c.

A NEW METHOD OF TREATING CHRONIC GLAUCOMA, based on Recent Researches into its Pathology. With Illustrations and coloured frontispiece, demy 8vo, 3s. 6d.

H. LEWIS JONES, M.A., M.D., F.R.C.P.

Medical Officer in charge of the Electrical Department in St. Bartholomew's Hospital.

MEDICAL ELECTRICITY. A Practical Handbook for Students and Practitioners. Second Edition, with Illustrations, crown 8vo, 10s. 6d.

[Now ready.]

[LEWIS'S PRACTICAL SERIES.]

T. N. KELYNACK, M.D.

Pathologist to the Manchester Royal Infirmary; Demonstrator and Lecturer on Pathology in the Owen's College.

A CONTRIBUTION TO THE PATHOLOGY OF THE VERMIFORM APPENDIX. With Illustrations, large 8vo, 10s. 6d.

HENRY R. KENWOOD, M.B., D.P.H., F.C.S.

Instructor in the Hygienic Laboratory, University College, and Assistant to Professor Corfield in the Public Health Department, University College.

PUBLIC HEALTH LABORATORY WORK, including Methods employed in Bacteriological Research, with special reference to the Examination of Air, Water and Food, contributed by RUBERT BOYCE, M.B., Assistant Professor of Pathology, University College. With Illustrations, cr. 8vo, 10s. 6d. [LEWIS'S PRACTICAL SERIES.]

NORMAN KERR, M.D., F.L.S.

President of the Society for the Study of Inebriety; Consulting Physician, Dalrymple Home for Inebriates, etc.

INEBRIETY OR NARCOMANIA: its Etiology, Pathology, Treatment, and Jurisprudence. Third Edition, 8vo, 21s. [Now ready.]

NORMAN W. KINGSLEY, M.D.S., D.D.S.

President of the Board of Censors of the State of New York; Member of the American Academy of Dental Science, &c.

A TREATISE ON ORAL DEFORMITIES AS A BRANCH OF MECHANICAL SURGERY. With over 350 Illustrations, 8vo, 16s.

F. CHARLES LARKIN, F.R.C.S. ENG.*

Surgeon to the Stanley Hospital; late Assistant Lecturer in Physiology in University College, Liverpool,

AND

RANDLE LEIGH, M.B., B.SC. LOND.

Senior Demonstrator of Physiology in University College, Liverpool.

OUTLINES OF PRACTICAL PHYSIOLOGICAL CHEMISTRY. Second Edition, with Illustrations, crown 8vo, paper 2s. 6d. nett, or cloth 3s. nett.

J. WICKHAM LEGG, F.R.C.P.

Formerly Assistant Physician to Saint Bartholomew's Hospital, and Lecturer on Pathological Anatomy in the Medical School.

I.

ON THE BILE, JAUNDICE, AND BILIOUS DISEASES. With Illustrations in chromo-lithography, 719 pages, roy. 8vo, 25s.

II.

A GUIDE TO THE EXAMINATION OF THE URINE. Seventh Edition, edited and revised, by H. LEWIS JONES, M.D., M.A., F.R.C.P., Medical Officer in charge of the Electrical Department in St. Bartholomew's Hospital. With Illustrations, fcap. 8vo, 3s. 6d.

ARTHUR H. N. LEWERS, M.D. LOND., M.R.C.P. LOND.
Obstetric Physician to the London Hospital.

A PRACTICAL TEXTBOOK OF THE DISEASES OF WOMEN. Fourth Edition, Illustrations, crown 8vo, 10s. 6d. [LEWIS'S PRACTICAL SERIES.]

LEWIS'S POCKET MEDICAL VOCABULARY.

Second Edition, thoroughly revised, 32mo, roan, 3s. 6d.

T. R. LEWIS, M.B., F.R.S. ELECT, ETC.

Late Fellow of the Calcutta University, Surgeon-Major Army Medical Staff, &c.

PHYSIOLOGICAL & PATHOLOGICAL RESEARCHES.

Arranged and edited by SIR WM. AITKEN, M.D., F.R.S., G. E. DOBSON, M.B., F.R.S., and A. E. BROWN, B.Sc. Crown 4to, portrait, 5 maps, 43 plates and 67 wood engravings, 30s. *nett*.

. A few copies only of this work remain for sale.

ROBERT LINDSAY, A.M., M.B., F.R.C.S.E.

Retired Surgeon, Army Medical Department.

AN ESSAY ON MALARIA AND ITS CONSEQUENCES.

Crown 8vo, 4s.

C. B. LOCKWOOD, F.R.C.S.

Hunterian Professor, Royal College of Surgeons of England; Surgeon to the Great Northern Hospital; Senior Demonstrator of Anatomy and Operative Surgery in St. Bartholomew's Hospital.

HUNTERIAN LECTURES ON THE MORBID ANATOMY, PATHOLOGY AND TREATMENT OF HERNIA.

36 Illustrations, demy 8vo, 5s.

WILLIAM THOMPSON LUSK, A.M., M.D.

Professor of Obstetrics and Diseases of Women in the Bellevue Hospital Medical College, &c.

THE SCIENCE AND ART OF MIDWIFERY.

Fourth Edition, with numerous Illustrations, 8vo, 18s.

A. W. MACFARLANE, M.D., F.R.C.P. EDIN.

Examiner in Medical Jurisprudence in the University of Glasgow; Honorary Consulting Physician (late Physician) Kilmarnock Infirmary.

INSOMNIA AND ITS THERAPEUTICS.

Medium 8vo, 12s. 6d.

RAWDON MACNAMARA.

Professor of Materia Medica, Royal College of Surgeons, Ireland; Senior Surgeon to the Westmoreland (Lock) Government Hospital; Surgeon to the Meath Hospital, &c.

AN INTRODUCTION TO THE STUDY OF THE BRITISH PHARMACOPŒIA. Demy 32mo, 1s. 6d. [*Just published.*]

JOHN MACPHERSON, M.D.

Inspector-General of Hospitals H.M. Bengal Army (Retired).

ANNALS OF CHOLERA FROM THE EARLIEST PERIODS TO THE YEAR 1817. With a map. Demy 8vo, 7s. 6d.

A. COWLEY MALLEY, B.A., M.B., B.CH., T.C.D.

PHOTO-MICROGRAPHY; including a description of the Wet Collodion and Gelatino-Bromide Processes, together with the best methods of Mounting and Preparing Microscopic Objects for Photo-Micrography. Second Edition, with Photographs and Illustrations, crown 8vo, 7s. 6d.

PATRICK MANSON, M.D., C.M.

THE FILARIA SANGUINIS HOMINIS; AND CERTAIN NEW FORMS OF PARASITIC DISEASE IN INDIA, CHINA, AND WARM COUNTRIES. Illustrated with Plates and Charts. 8vo, 10s. 6d.

JEFFERY A. MARSTON, M.D., C.B., F.R.C.S., M.R.C.P. LOND.
Surgeon General Medical Staff (Retired).

NOTES ON TYPHOID FEVER: Tropical Life and its Sequelæ. Crown 8vo, 3s. 6d.

EDWARD MARTIN, A.M., M.D.

MINOR SURGERY AND BANDAGING WITH AN APPENDIX ON VENEREAL DISEASES. 82 Illustrations, crown 8vo, 4s.

WILLIAM MARTINDALE, F.C.S.

Late Examiner of the Pharmaceutical Society, and late Teacher of Pharmacy and Demonstrator of Materia Medica at University College,

AND

W. WYNN WESTCOTT, M.B. LOND.

Coroner for North-East London.

THE EXTRA PHARMACOPŒIA, with Medical References, and a Therapeutic Index of Diseases and Symptoms. Eighth Edition, limp roan, med. 24mo, 9s. [Just published.]

WILLIAM MARTINDALE, F.C.S.

Late Examiner of the Pharmaceutical Society, &c.

I.

COCA, AND COCAINE. Their History, Medical and Economic Uses, and Medicinal Preparations. Third Edition, fcap. 8vo, 2s. [Now ready.]

II.

ANALYSES OF TWELVE THOUSAND PRESCRIPTIONS: being Statistics of the Frequency of Use therein of all Official and Unofficial Preparations. Fcap. 4to, 2s. 6d. nett. [Now ready.]

MATERIA MEDICA LABELS.

Adapted for Public and Private Collections. Compiled from the British Pharmacopœia of 1885, with the additions of 1890. The Labels are arranged in Two Divisions:—

Division I.—Comprises, with few exceptions, Substances of Organized Structure, obtained from the Vegetable and Animal Kingdoms.

Division II.—Comprises Chemical Materia Medica, including Alcohols, Alkaloids, Sugars, and Neutral Bodies.

On plain paper, 10s. 6d. nett. On gummed paper, 12s. 6d. nett.

The 24 additional Labels of 1890 only, 1s. nett.

, Specimens of the Labels, of which there are over 470, will be sent on application.

S. E. MAUNSELL, L.R.C.S.I.
Surgeon-Major, Medical Staff.

NOTES OF MEDICAL EXPERIENCES IN INDIA
PRINCIPALLY WITH REFERENCE TO DISEASES OF THE
EYE. With Map, post 8vo, 3s. 6d.

ANGEL MONEY, M.D. LOND., F.R.C.P.
*Late Assistant Physician to University College Hospital, and to the Hospital for Sick
Children Great Ormond Street.*

I.
TREATMENT OF DISEASE IN CHILDREN: EM-
BODYING THE OUTLINES OF DIAGNOSIS AND THE
CHIEF PATHOLOGICAL DIFFERENCES BETWEEN CHILD-
REN AND ADULTS. Second Edition, with plates, crown 8vo, 10s. 6d.
[LEWIS'S PRACTICAL SERIES.]

II.
THE STUDENT'S TEXTBOOK OF THE PRACTICE
OF MEDICINE. Fcap. 8vo, 6s. 6d.

A. STANFORD MORTON, M.B., F.R.C.S. ENG.
*Assistant Surgeon to the Moorfields Ophthalmic Hospital; Ophthalmic Surgeon to the
Great Northern Central Hospital.*

REFRACTION OF THE EYE: Its Diagnosis, and the
Correction of its Errors. Fifth Edition, with Illustrations, small 8vo,
3s. 6d. [Now ready.]

C. W. MANSELL MOULLIN, M.A., M.D. OXON., F.R.C.S.
*Surgeon to and Lecturer on Physiology at the London Hospital; late Radcliffe's
Travelling Fellow and Fellow of Pembroke College, Oxford, &c.*

I.
ENLARGEMENT OF THE PROSTATE: its Treatment
and Radical Cure. With plates, 8vo, 6s. [Now ready.]

II.
SPRAINS; THEIR CONSEQUENCES AND TREAT-
MENT. Second Edition, crown 8vo, 4s. 6d.

PAUL F. MUNDE, M.D.
*Professor of Gynecology at the New York Polyclinic; President of the New York Obstetrical
Society and Vice-President of the British Gynecological Society, &c.*

THE MANAGEMENT OF PREGNANCY, PARTURI-
TION, AND THE PUERPERAL STATE. Second Edition, square
8vo, 3s. 6d.

WILLIAM MURRAY, M.D., F.R.C.P. LOND.
Consulting Physician to the Children's Hospital, Newcastle-on-Tyne, &c.

ILLUSTRATIONS OF THE INDUCTIVE METHOD IN
MEDICINE. Crown 8vo, 3s. 6d.

WILLIAM MURRELL, M.D., F.R.C.P.
*Physician to, and Lecturer on Pharmacology and Therapeutics at Westminster Hospital;
late Examiner in Materia Medica to the Royal College of Physicians of London, &c.*

I.
WHAT TO DO IN CASES OF POISONING.
Seventh Edition, royal 32mo, 3s. 6d.

II.
MASSOTHERAPEUTICS, OR MASSAGE AS A MODE
OF TREATMENT. Fifth Edition, with Illustrations, crown 8vo, 4s. 6d.

III.
CHRONIC BRONCHITIS AND ITS TREATMENT.
Crown 8vo, 3s. 6d.

HENRY D. NOYES, A.M., M.D.

Professor of Ophthalmology and Otology in Bellevue Hospital Medical College; Executive Surgeon to the New York Eye and Ear Infirmary, &c.

A TEXTBOOK ON DISEASES OF THE EYE.

Second and revised Edition, Illustrated by 5 chromo-lithographic plates, 10 plates in black and colours and 269 wood engravings, 28s. *nett.*

GEORGE OLIVER, M.D., F.R.C.P.

PULSE-GAUGING: A Clinical Study of Radial Measurement and Pulse Pressure. With Illustrations, fcap. 8vo, 3s. 6d.

[*Now ready.*]

THE HARROGATE WATERS: Data Chemical and Therapeutical, with notes on the Climate of Harrogate. Addressed to the Medical Profession. With Map of the Wells, crown 8vo, 3s. 6d.

ON BEDSIDE URINE TESTING: a Clinical Guide to the Observation of Urine in the course of Work. Fourth Edition, fcap. 8vo, 3s. 6d.

DR. A. ONODI.

Lecturer on Rhino-Laryngology in the University of Budapest.

THE ANATOMY OF THE NASAL CAVITY, AND ITS ACCESSORY SINUSES. An Atlas for Practitioners and Students, translated by ST CLAIR THOMSON, M.D. LOND., F.R.C.S. ENG., M.R.C.P. LOND. Plates, small 4to, 6s. *nett.* [*Now ready.*]

SAM. OSBORN, F.R.C.S.

Chief Surgeon to the Metropolitan Corps of the St. John Ambulance Brigade; Surgeon to the Hospital for Women, Soho Square, &c.

AMBULANCE LECTURES: FIRST AID TO THE INJURED. Third Edition, with Illustrations, fcap. 8vo, 2s.

[*Just published.*]

AMBULANCE LECTURES: HOME NURSING AND HYGIENE. Second Edition, with Illustrations, fcap. 8vo, 2s.

WILLIAM OSLER, M.D., F.R.C.P. LOND.

President of the Association of American Physicians; Professor of Medicine, Johns Hopkins University, and Physician-in-Chief Johns Hopkins Hospital, Baltimore.

ON CHOREA AND CHOREIFORM AFFECTIONS.

Large 8vo, 5s.

THE CEREBRAL PALSIES OF CHILDREN. A Clinical Study from the Infirmary for Nervous Diseases, Philadelphia. Demy 8vo, 5s.

KURRE W. OSTROM.

Instructor in Massage and Swedish Movements in the Philadelphia Polyclinic and College for Graduates in Medicine.

MASSAGE AND THE ORIGINAL SWEDISH MOVEMENTS; their application to various diseases of the body. Third Edition, with Illustrations, 12mo, 3s. 6d. *nett.*

CHARLES A. PARKER, F.R.C.S. EDIN.

Assistant Surgeon to the Hospital for Diseases of the Throat, Golden Square, London.

POST-NASAL GROWTHS. Demy 8vo, 4s. 6d. [*Just published.*]

ROBERT W. PARKER.

Senior Surgeon to the East London Hospital for Children; Surgeon to the German Hospital.

DIPHTHERIA: ITS NATURE AND TREATMENT,
WITH SPECIAL REFERENCE TO THE OPERATION, AFTER-
TREATMENT AND COMPLICATIONS OF TRACHEOTOMY.

Third Edition, with Illustrations, 8vo, 6s.

**CONGENITAL CLUB-FOOT; ITS NATURE AND
TREATMENT.** With special reference to the subcutaneous division

of Tarsal Ligaments. 8vo, 7s. 6d.

LOUIS C. PARKES, M.D., D.P.H. LOND. UNIV.

Lecturer on Public Health at St. George's Hospital Medical School; Medical Officer of Health for Chelsea.

HYGIENE AND PUBLIC HEALTH. Fourth Edition, with
numerous Illustrations, crown 8vo, 10s. 6d. [Now ready.]

[LEWIS'S PRACTICAL SERIES.]

**INFECTIOUS DISEASES, NOTIFICATION AND PRE-
VENTION.** Fcap. 8vo, cloth, 2s. 6d; roan, 4s. 6d.

JOHN S. PARRY, M.D.

Obstetrician to the Philadelphia Hospital, Vice-President of the Obstetrical and Pathological Societies of Philadelphia, &c.

EXTRA-UTERINE PREGNANCY; Its Causes, Species,
Pathological Anatomy, Clinical History, Diagnosis, Prognosis and
Treatment. 8vo, 8s.

E. RANDOLPH PEASLEE, M.D., LL.D.

Late Professor of Gynæcology in the Medical Department of Dartmouth College; President of New York Academy of Medicine, &c., &c.

**OVARIAN TUMOURS: Their Pathology, Diagnosis, and
Treatment,** especially by Ovariectomy. Illustrations, roy. 8vo, 16s.

LESLIE PHILLIPS, M.D.

Surgeon to the Birmingham and Midland Skin and Lock Hospital.

**MEDICATED BATHS IN THE TREATMENT OF SKIN
DISEASES.** Crown 8vo, 4s. 6d.

HENRY G. PIFFARD, A.M., M.D.

Clinical Professor of Dermatology, University of the City of New York; Surgeon in Charge of the New York Dispensary for Diseases of the Skin, &c.

**A PRACTICAL TREATISE ON DISEASES OF THE
SKIN.** With 50 full page Original Plates and 33 Illustrations in the
Text, 4to, £2 12s. 6d. nett.

G. V. POORE, M.D., F.R.C.P.

Professor of Medical Jurisprudence, University College; Assistant Physician to, and Physician in charge of the Throat Department of, University College Hospital.

**LECTURES ON THE PHYSICAL EXAMINATION OF
THE MOUTH AND THROAT.** With an Appendix of Cases. 8vo,
3s. 6d.

R. DOUGLAS POWELL, M.D., F.R.C.P.

Physician Extra-ordinary to H.M. the Queen; Physician to the Middlesex Hospital; Consulting Physician to the Hospital for Consumption and Diseases of the Chest at Brompton.

DISEASES OF THE LUNGS AND PLEURÆ, INCLUDING CONSUMPTION. Fourth Edition, with coloured plates and wood engravings, 8vo, 18s.

TABLE OF PHYSICAL EXAMINATION OF THE LUNGS: with Note on International Nomenclature of Physical Signs (reprinted from DR. POWELL'S "Diseases of the Lungs,"). On one sheet, 6d.

HERBERT A. POWELL, M.A., M.D., M.CH. OXON., F.R.C.S.E.

THE SURGICAL ASPECT OF TRAUMATIC INSANITY. Medium 8vo, 2s. 6d.

D'ARCY POWER, M.A., M.B. OXON., F.R.C.S. ENG.

Demonstrator of Operative Surgery at St. Bartholomew's Hospital; Surgeon to the Victoria Hospital for Children, Chelsea; Examiner in the University of Durham; Member of the Conjoint Examining Board of the Royal College of Physicians (Lond.) and of Surgeons (Eng.)

THE SURGICAL DISEASES OF CHILDREN AND THEIR TREATMENT BY MODERN METHODS. With Illustrations, crown 8vo, 10s. 6d.

[Now ready.]

[LEWIS'S PRACTICAL SERIES.]

URBAN PRITCHARD, M.D. EDIN., F.R.C.S. ENG.

Professor of Aural Surgery at King's College, London; Aural Surgeon to King's College Hospital; Senior Surgeon to the Royal Ear Hospital.

HANDBOOK OF DISEASES OF THE EAR FOR THE USE OF STUDENTS AND PRACTITIONERS. Third Edition, With Illustrations, crown 8vo.

[In preparation.]

[LEWIS'S PRACTICAL SERIES.]

CHARLES W. PURDY, M.D. (QUEEN'S UNIV.)

Professor of Genito-Urinary and Renal Diseases in the Chicago Polyclinic, &c., &c.

BRIGHT'S DISEASE AND THE ALLIED AFFECTIONS OF THE KIDNEYS. With Illustrations, large 8vo, 8s. 6d.

DR. THEODOR PUSCHMANN.

Public Professor in Ordinary at the University of Vienna.

A HISTORY OF MEDICAL EDUCATION FROM THE MOST REMOTE TO THE MOST RECENT TIMES. Translated and edited by EVAN H. HARE, M.A. OXON., F.R.C.S. ENG., L.S.A. Demy 8vo, 21s.

C. H. RALFE, M.A., M.D. CANTAB., F.R.C.P. LOND.

Assistant Physician to the London Hospital; Examiner in Medicine to the University of Durham, &c., &c.

A PRACTICAL TREATISE ON DISEASES OF THE KIDNEYS AND URINARY DERANGEMENTS. With Illustrations, crown 8vo, 10s. 6d.

[LEWIS'S PRACTICAL SERIES.]

FRANCIS H. RANKIN, M.D.
President of the New York Medical Society.

HYGIENE OF CHILDHOOD. Suggestions for the care of Children after the Period of Infancy to the completion of Puberty. Crown 8vo, 3s.

AMBROSE L. RANNEY, A.M., M.D.
Professor of the Anatomy and Physiology of the Nervous System in the New York Post-Graduate Medical School and Hospital, &c.

THE APPLIED ANATOMY OF THE NERVOUS SYSTEM. Second Edition, 238 Illustrations, large 8vo, 21s.

H. A. REEVES, F.R.C.S. EDIN.
Senior Assistant Surgeon and Teacher of Practical Surgery at the London Hospital; Surgeon to the Royal Orthopædic Hospital.

BODILY DEFORMITIES AND THEIR TREATMENT:
A HANDBOOK OF PRACTICAL ORTHOPÆDICS. Illustrations, crown 8vo, 8s. 6d. [LEWIS'S PRACTICAL SERIES.]

RALPH RICHARDSON, M.A., M.D.
Fellow of the College of Physicians, Edinburgh.

ON THE NATURE OF LIFE: An Introductory Chapter to Pathology. Second edition, revised and enlarged. Fcap. 4to, 10s. 6d.

W. RICHARDSON, M.A., M.D., M.R.C.P.

REMARKS ON DIABETES, ESPECIALLY IN REFERENCE TO TREATMENT. Demy 8vo, 4s. 6d.

SAMUEL RIDEAL, D.SC. (LOND.), F.I.C., F.C.S., F.G.S.
Fellow of University College, London.

I.

PRACTICAL ORGANIC CHEMISTRY; The Detection and Properties of some of the more important Organic Compounds. 12mo, 2s. 6d.

II.

PRACTICAL CHEMISTRY FOR MEDICAL STUDENTS, required at the First Examination of the Conjoint Examining Board in England. Fcap 8vo, 2s.

J. JAMES RIDGE, M.D.
Medical Officer of Health, Enfield.

ALCOHOL AND PUBLIC HEALTH. Second Edition, crown 8vo, 2s.

E. A. RIDSDALE.
Associate of the Royal School of Mines.

COSMIC EVOLUTION; being Speculations on the Origin of our Environment. Fcap. 8vo, 3s.

SYDNEY RINGER, M.D., F.R.S.

Holme Professor of Clinical Medicine in University College; Physician to University College Hospital.

I.

A HANDBOOK OF THERAPEUTICS.

Twelfth Edition thoroughly revised, 8vo, 15s.

II.

**ON THE TEMPERATURE OF THE BODY AS
A MEANS OF DIAGNOSIS AND PROGNOSIS IN PHTHISIS.**

Second Edition, small 8vo, 2s. 6d.

R. LAWTON ROBERTS, M.D. LOND., D.P.H. CAMB., M.R.C.S. ENG.

Honorary Life Member of, and Lecturer and Examiner to, the St. John Ambulance Association.

I.

ILLUSTRATED LECTURES ON AMBULANCE WORK.

Fifth Edition, copiously Illustrated, crown 8vo, 2s. 6d.

[Just published.]

II.

**ILLUSTRATED LECTURES ON NURSING AND HY-
GIENE.** Second Edition, with Illustrations, crown 8vo, 2s. 6d.

FREDERICK T. ROBERTS, M.D., B.SC., F.R.C.P.

Professor of the Principles and Practice of Medicine in University College; Physician to University College Hospital; Consulting Physician to Brompton Consumption Hospital, &c.

I.

THE THEORY AND PRACTICE OF MEDICINE.

Ninth Edition, with Illustrations, large 8vo, 21s.

[Just Published.]

II.

THE OFFICINAL MATERIA MEDICA.

Second Edition, entirely rewritten in accordance with the latest British Pharmacopœia, fcap. 8vo, 7s. 6d.

III.

**NOTES ON THE ADDITIONS MADE TO THE BRITISH
PHARMACOPŒIA, 1890.** Fcap. 8vo, 1s.

H. D. ROLLESTON, M.D., F.R.C.P.

[See Cambridge Natural Science Manuals, page 5.]

D. B. ST. JOHN ROOSA, M.D.

Consulting Surgeon to the Brocklyn Eye and Ear Hospital, &c.

**A PRACTICAL TREATISE ON THE DISEASES OF
THE EAR:** Including a Sketch of Aural Anatomy and Physiology.

Seventh Edition, Illustrated, large 8vo, 25s.

ROBSON ROOSE, M.D., LL.D., F.C.S.

Fellow of the Royal College of Physicians in Edinburgh, &c.

I.

**GOUT, AND ITS RELATIONS TO DISEASES OF
THE LIVER AND KIDNEYS.** Seventh Edition, crown 8vo, 4s. 6d.

[Now ready.]

II.

**NERVE PROSTRATION AND OTHER FUNCTIONAL
DISORDERS OF DAILY LIFE.** Second Edition, demy 8vo, 18s.

III.

LEPROSY AND ITS PREVENTION: as Illustrated by
Norwegian Experience. Crown 8vo, 3s. 6d.

WILLIAM ROSE, M.B., B.S. LOND., F.R.C.S.

Professor of Surgery in King's College, London, and Surgeon to King's College Hospital.

HARELIP AND CLEFT PALATE. With Illustrations, demy 8vo, 6s.

BERNARD ROTH, F.R.C.S.

Fellow of the Medical Society of London; Member of the Clinical and Pathological Societies and of the Medical Officers of Schools' Association.

THE TREATMENT OF LATERAL CURVATURE OF THE SPINE. With Photographic and other Illustrations, demy 8vo, 5s.

J. BURDON SANDERSON, M.D., LL.D., F.R.S.

Jodrell Professor of Physiology in University College, London.

UNIVERSITY COLLEGE COURSE OF PRACTICAL EXERCISES IN PHYSIOLOGY. With the co-operation of F. J. M. PAGE, B.Sc., F.C.S.; W. NORTH, B.A., F.C.S., and AUG. WALLER, M.D. Demy 8vo, 3s. 6d.

W. H. O. SANKEY, M.D. LOND., F.R.C.P.

Late Lecturer on Mental Diseases, University College, London, etc.

LECTURES ON MENTAL DISEASE. Second Edition, with coloured Plates, 8vo, 12s. 6d.

JOHN SAVORY.

Member of the Society of Apothecaries, London.

A COMPENDIUM OF DOMESTIC MEDICINE AND COMPANION TO THE MEDICINE CHEST: Intended as a source of easy reference for Clergymen, Master Mariners, and Travellers; and for Families resident at a distance from professional assistance. Tenth Edition, sm. 8vo, 5s.

DR. C. SCHIMMELBUSCH.

Privat-docent and Assistant Surgeon in Prof. v. Bergmann's University Clinic at Berlin.

THE ASEPTIC TREATMENT OF WOUNDS.

With a Preface by Professor BERGMANN. Translated from the Second German Edition by A. T. RAKE, M.B., B.S. LOND., F.R.C.S. ENG., Registrar and Pathologist to the East London Hospital for Children. With Illustrations, crown 8vo, 5s. [Now ready.]

E. SCHMIEGELOW, M.D.

Consulting Physician in Laryngology to the Municipal Hospital and Director of the Oto-Laryngological Department in the Polyclinic at Copenhagen.

ASTHMA: Especially in its Relation to Nasal Disease. Demy 8vo, 4s. 6d.

DR. B. S. SCHULTZE.

Professor of Gynecology; Director of the Lying-in Hospital, and of the Gynecological Clinic at Jena.

THE PATHOLOGY AND TREATMENT OF DISPLACEMENTS OF THE UTERUS. Translated by J. J. MACAN, M.A., M.R.C.S. and edited by A. V. MACAN, M.B., M.Ch., Master of the Rotunda Lying-in Hospital, Dublin. With 120 Illustrations, medium 8vo, 12s. 6d.

A. C. SEWARD, M.A., F.G.S.

[See Cambridge Natural Science Manuals, page 5.]

JOHN SHAW, M.D. LOND., M.R.C.P.

Obstetric Physician to the North-West London Hospital.

ANTISEPTICS IN OBSTETRIC NURSING. A Text-book for Nurses on the Application of Antiseptics to Gynæcology and Midwifery. Coloured plate and woodcuts, 8vo, 3s. 6d.

G. E. SHUTTLEWORTH, B.A., M.D.

Late Medical Superintendent, Royal Albert Asylum for Idiots and Imbeciles of the Northern Counties, Lancaster; formerly Assistant Medical Officer, Earlswood Asylum.

MENTALLY-DEFICIENT CHILDREN THEIR TREATMENT AND TRAINING. With Illustrations, crown 8vo, 4s.

[Now ready.]

A. J. C. SKENE, M.D.

Professor of Gynecology in the Long Island College Hospital, Brooklyn, New York.

TREATISE ON THE DISEASES OF WOMEN, FOR THE USE OF STUDENTS AND PRACTITIONERS. Second Edition, with coloured plates and 251 engravings, large 8vo, 28s.

J. LEWIS SMITH, M.D.

Physician to the New York Foundling Asylum; Clinical Professor of Diseases of Children in Bellevue Hospital Medical College.

A TREATISE ON THE DISEASES OF INFANCY AND CHILDHOOD. Seventh Edition, with Illustrations, large 8vo, 21s.

FRANCIS W. SMITH, M.B., B.S.

THE SALINE WATERS OF LEAMINGTON. Second Edit., with Illustrations, crown 8vo, 1s. nett.

JOHN KENT SPENDER, M.D. LOND.

Physician to the Royal Mineral Water Hospital, Bath.

THE EARLY SYMPTOMS AND THE EARLY TREATMENT OF OSTEO-ARTHRITIS, commonly called Rheumatoid Arthritis, with special reference to the Bath Thermal Waters. Sm. 8vo, 2s. 6d.

LOUIS STARR, M.D.

Physician to the Children's Hospital, Philadelphia; late Clinical Professor of Diseases of Children in the Hospital of the University of Pennsylvania.

HYGIENE OF THE NURSERY. Including the General Regimen and Feeding of Infants and Children; Massage, and the Domestic Management of the Ordinary Emergencies of Early Life. Fourth Edition, with Illustrations, crown 8vo, 3s. 6d.

JAMES STARTIN, M.B., M.R.C.S.

Senior Surgeon to the London Skin Hospital.

LECTURES ON THE PARASITIC DISEASES OF THE SKIN. VEGETOID AND ANIMAL. With Illustrations, crown 8vo, 2s. 6d.

JOHN LINDSAY STEVEN, M.D.

Assistant Physician and Pathologist, Glasgow Royal Infirmary; Physician for Out-patients, Royal Hospital for Sick Children, Glasgow; Lecturer on Pathology, St. Mungo's and Queen Margaret Colleges, Glasgow, &c.

THE PATHOLOGY OF MEDIASTINAL TUMOURS. With special reference to Diagnosis. With Plates, 8vo, 4s. 6d.

LEWIS A. STIMSON, B.A., M.D.

Surgeon to the Presbyterian and Bellevue Hospitals; Professor of Clinical Surgery in the Medical Faculty of the University of the City of New York, &c.

A MANUAL OF OPERATIVE SURGERY.

Second Edition, with three hundred and forty-two Illustrations, post 8vo, 10s. 6d.

JAMES STOCKEN, L.D.S. ENG.

Pereira Prizeman for Materia Medica; Late Dental Surgeon to the National Dental Hospital.

DENTAL MATERIA MEDICA AND THERAPEUTICS.

Fourth edition, revised by LESLIE M. STOCKEN, L.R.C.P., M.R.C.S., L.D.S., and J. O. BUTCHER, L.D.S. ENG., Assistant Dental Surgeon to Guy's Hospital. Fcap. 8vo, 4s. [Now ready.]

ADOLF STRÜMPELL.

Professor and Director of the Medical Clinique at Erlangen.

A TEXT-BOOK OF MEDICINE FOR STUDENTS AND PRACTITIONERS. Second Edition translated from the German by Dr. H. F. VICKERY and Dr. P. C. KNAPP, with Editorial Notes by Dr. F. C. SHATTUCK, Visiting Physician to the Massachusetts General Hospital, etc. Complete in one large vol., with 119 Illustrations, imp. 8vo, 28s.

JUKES DE STYRAP, M.R.C.P.I., ETC.

Physician-Extraordinary, late Physician in Ordinary, to the Salop Infirmary; Consulting Physician to the South Salop and Montgomeryshire Infirmaries, etc.

I.

THE YOUNG PRACTITIONER: WITH PRACTICAL HINTS AND INSTRUCTIVE SUGGESTIONS, AS SUBSIDIARY AIDS, FOR HIS GUIDANCE ON ENTERING INTO PRIVATE PRACTICE. Demy 8vo, 7s. 6d. *nett.*

II.

A CODE OF MEDICAL ETHICS: WITH GENERAL AND SPECIAL RULES FOR THE GUIDANCE OF THE FACULTY AND THE PUBLIC IN THE COMPLEX RELATIONS OF PROFESSIONAL LIFE. Fourth Edition, demy 8vo, 3s. 6d. *nett.*

III.

MEDICO-CHIRURGICAL TARIFFS.

Fifth Edition, revised and enlarged, fcap. 4to, 2s. *nett.*

IV.

THE YOUNG PRACTITIONER: HIS CODE AND TARIFF. Being the above three works in one volume. Demy 8vo, 10s. 6d. *nett.*

C. W. SUCKLING, M.D. LOND., M.R.C.P.

Professor of Materia Medica and Therapeutics at the Queen's College, Physician to the Queen's Hospital, Birmingham, etc.

I.

ON THE DIAGNOSIS OF DISEASES OF THE BRAIN, SPINAL CORD, AND NERVES. With Illustrations, crown 8vo, 8s. 6d.

II.

ON THE TREATMENT OF DISEASES OF THE NERVOUS SYSTEM. Crown 8vo, 7s. 6d.

JOHN BLAND SUTTON, F.R.C.S.

Lecturer on Comparative Anatomy, Senior Demonstrator of Anatomy, and Assistant Surgeon to the Middlesex Hospital; Erasmus Wilson Lecturer, Royal College of Surgeons, England.

LIGAMENTS: THEIR NATURE AND MORPHOLOGY.

With numerous Illustrations, post 8vo, 4s. 6d.

HENRY R. SWANZY, A.M., M.B., F.R.C.S.I.

Surgeon to the National Eye and Ear Infirmary, and Ophthalmic Surgeon to the Adelaide Hospital, Dublin.

A HANDBOOK OF THE DISEASES OF THE EYE

AND THEIR TREATMENT. Fifth Edition, edited under supervision of the Author by LOUIS WERNER, M.B., B.CH., Examiner in Ophthalmic Surgery in the University of Dublin, and in the Royal University of Ireland. Illustrated with wood-engravings, colour tests, etc., small 8vo, 10s. 6d. [Now ready.]

EUGENE S. TALBOT, M.D., D.D.S.

Professor of Dental Surgery in the Woman's Medical College; Lecturer on Dental Pathology and Surgery in Rush Medical College, Chicago.

IRREGULARITIES OF THE TEETH AND THEIR TREATMENT. With 152 Illustrations, royal 8vo, 10s. 6d.

ALBERT TAYLOR.

*Associate Sanitary Institute; Chief Sanitary Inspector to the Vestry of St. George,
Hanover Square, etc.*

THE SANITARY INSPECTOR'S HANDBOOK.

With Illustrations, cr. 8vo., 5s.

H. COUPLAND TAYLOR, M.D.

Fellow of the Royal Meteorological Society.

**WANDERINGS IN SEARCH OF HEALTH, OR
MEDICAL AND METEOROLOGICAL NOTES ON VARIOUS
FOREIGN HEALTH RESORTS.** With Illustrations, crown 8vo, 6s.

J. C. THOROWGOOD, M.D.

Assistant Physician to the City of London Hospital for Diseases of the Chest.

**THE CLIMATIC TREATMENT OF CONSUMPTION
AND CHRONIC LUNG DISEASES.** Third Edition, post 8vo, 3s. 6d.

D. HACK TUKE, M.D., LL.D.

Fellow of the Royal College of Physicians, London.

**THE INSANE IN THE UNITED STATES AND
CANADA.** Demy 8vo, 7s. 6d.

DR. R. ULZMANN.

ON STERILITY AND IMPOTENCE IN MAN. Translated
from the German with notes and additions by ARTHUR COOPER, L.R.C.P.,
M.R.C.S., Surgeon to the Westminster General Dispensary. With
Illustrations, fcap. 8vo, 2s. 6d.

W. H. VAN BUREN, M.D., LL.D.

Professor of Surgery in the Bellevue Hospital Medical College.

**DISEASES OF THE RECTUM: And the Surgery of the
Lower Bowel.** Second Edition, with Illustrations, 8vo, 14s.

ALFRED VOGEL, M.D.

Professor of Clinical Medicine in the University of Dorpat, Russia.

**A PRACTICAL TREATISE ON THE DISEASES OF
CHILDREN.** Third Edition, translated and edited by H. RAPHAEL,
M.D., from the Eighth German Edition, illustrated by six lithographic
plates, part coloured, royal 8vo, 18s.

A. DUNBAR WALKER, M.D., C.M.

THE PARENT'S MEDICAL NOTE BOOK.

Oblong post 8vo, cloth, 1s. 6d.

A. J. WALL, M.D. LOND.

Fellow of the Royal College of Surgeons of England; of the Medical Staff of H. M. Indian Army (Retired List).

ASIATIC CHOLERA: ITS HISTORY, PATHOLOGY, AND MODERN TREATMENT. Demy 8vo, 6s.

JOHN RICHARD WARDELL, M.D. EDIN., F.R.C.P. LOND.
Late Consulting Physician to the General Hospital Tunbridge Wells.

CONTRIBUTIONS TO PATHOLOGY AND THE PRACTICE OF MEDICINE. Medium 8vo, 2rs.

W. SPENCER WATSON, B.M. LOND., F.R.C.S. ENG.
Surgeon to the Throat Department of the Great Northern Hospital; Senior Surgeon to the Royal South London Ophthalmic Hospital.

I.

DISEASES OF THE NOSE AND ITS ACCESSORY CAVITIES. Second Edition, with Illustrations, demy 8vo, 12s. 6d.

II.

THE ANATOMY AND DISEASES OF THE LACHRYMAL PASSAGES. With Illustrations, demy 8vo, 2s. 6d.

III.

EYEBALL-TENSION: Its Effects on the Sight and its Treatment. With woodcuts, p. 8vo, 2s. 6d.

IV.

ON ABSCESS AND TUMOURS OF THE ORBIT. Post 8vo, 2s. 6d.

FRANCIS H. WELCH, F.R.C.S.

Surgeon Major, A.M.D.

ENTERIC FEVER: as Illustrated by Army Data at Home and Abroad, its Prevalence and Modifications, Ætiology, Pathology and Treatment. 8vo, 5s. 6d.

W. WYNN WESTCOTT, M.B.

Deputy Coroner for Central Middlesex.

SUICIDE; its History, Literature, Jurisprudence, and Prevention. Crown 8vo, 6s.

FRANK J. WETHERED, M.D.

Medical Registrar to the Middlesex Hospital, and Demonstrator of Practical Medicine in the Middlesex Hospital Medical School; late Assistant Physician to the City of London Chest Hospital, Victoria Park.

MEDICAL MICROSCOPY. A Guide to the Use of the Microscope in Medical Practice. With Illustrations, crown 8vo, 9s.
[LEWIS'S PRACTICAL SERIES.]

W. C. D. WHETHAM, M.A.

[See Cambridge Natural Science Manuals, page 5.]

E. G. WHITTLE, M.D. LOND., F.R.C.S. ENG.

Senior Surgeon to the Royal Alexandra Hospital for Sick Children, Brighton.

CONGESTIVE NEURASTHENIA, OR INSOMNIA AND NERVE DEPRESSION. Crown 8vo, 3s. 6d.

SIR JOHN WILLIAMS, BART., M.D., F.R.C.P.

Consulting Physician to University College Hospital; Physician Accoucheur to H.R.H. Princess Beatrice, &c.

CANCER OF THE UTERUS: Being the Harveian Lectures for 1886. Illustrated with Lithographic Plates, royal 8vo, 10s. 6d.

R. T. WILLIAMSON, M.D. LOND., M.R.C.P.

Medical Registrar, Royal Infirmary, and Assistant in Medicine, Owen's College, Manchester.

ON THE RELATION OF DISEASES OF THE SPINAL CORD TO THE DISTRIBUTION AND LESIONS OF THE SPINAL BLOOD VESSELS. Royal 8vo, 2s.

E. T. WILSON, M.B. OXON., F.R.C.P. LOND.

Physician to the Cheltenham General Hospital; Associate Metropolitan Association of Medical Officers of Health.

DISINFECTANTS AND ANTISEPTICS: HOW TO USE THEM. In Packets of one doz. price 1s., by post 1s. 1d.

[Just thoroughly revised.]

DR. F. WINCKEL.

Formerly Professor and Director of the Gynaecological Clinic at the University of Rostock.

THE PATHOLOGY AND TREATMENT OF CHILD-BED: A Treatise for Physicians and Students. Translated from the Second German Edition, with many additional notes by the Author, by J. R. CHADWICK, M.D. 8vo, 14s.

BERTRAM C. A. WINDLE, M.A., M.D. DUBL.

Professor of Anatomy in the Queen's College, Birmingham; Examiner in Anatomy in the Universities of Cambridge and Durham.

A HANDBOOK OF SURFACE ANATOMY AND LAND-MARKS. Illustrated, post 8vo, 3s. 6d.

EDWARD WOAKES, M.D. LOND.

Senior Aural Surgeon and Lecturer on Aural Surgery at the London Hospital; Surgeon to the London Throat Hospital.

I.
ON DEAFNESS, GIDDINESS AND NOISES IN THE HEAD. Third Edition, with Illustrations, 8vo. *[In preparation.]*

II.
POST-NASAL CATARRH, AND DISEASES OF THE NOSE CAUSING DEAFNESS. With Illustrations, cr. 8vo, 6s. 6d.

III.
NASAL POLYPUS: WITH NEURALGIA, HAY-FEVER, AND ASTHMA, IN RELATION TO ETHMOIDITIS. With Illustrations, cr. 8vo, 4s. 6d.

HENRY WOODS, B.A., F.G.S.

[See Cambridge Natural Science Manuals, page 5.]

HERMANN VON ZEISSL, M.D.

Late Professor at the Imperial Royal University of Vienna.

OUTLINES OF THE PATHOLOGY AND TREATMENT OF SYPHILIS AND ALLIED VENEREAL DISEASES.
 Second Edition, revised by M. VON ZEISSL, M.D., Privat-Dozent for Diseases of the Skin and Syphilis at the Imperial Royal University of Vienna. Translated, with Notes, by H. RAPHAEL, M.D., Attending Physician for Diseases of Genito-Urinary Organs and Syphilis, Bellevue Hospital, Out-Patient Department. Large 8vo, 18s.

OSWALD ZIEMSEN, M.D.

Knight of the Iron Cross, and of the Prussian Order of the Crown.

THE TREATMENT OF CONSTITUTIONAL SYPHILIS. Post 8vo, 3s. 6d.

Lewis's Diet Charts.

Price 6s. 6d. per packet of 100 charts, by post 6s. 10½d.

A suggestive set of diet tables for the use of Physicians, for handing to patients after consultation, modified to suit individual requirements, for Albuminuria, Alcoholism, Anæmia and Debility, Constipation, Diabetes, Diarrhœa, Dyspepsia, Fevers, Gout, Nervous Diseases, Obesity, Phthisis, Rheumatism (chronic), with blank chart for other diseases.

Lewis's Four-Hour Temperature Charts.

25s. per 1000, 14s. per 500, 3s. 6d. per 100, 2s. per 50, 1s. per 20, carriage free.

This form has been drawn up to meet the requirements of a chart on which the temperature and other observations can be recorded at intervals of four hours. They will be found most convenient in hospital and private practice. Each chart will last a week.

Clinical Charts for Temperature Observations, etc.

Arranged by W. RIGDEN, M.R.C.S. 50s. per 1000, 28s. per 500, 15s. per 250, 7s. per 100, or 1s. per dozen.

Each Chart is arranged for four weeks, and is ruled at the back for making notes of Cases; they are convenient in size, and are suitable both for hospital and private practice.

Lewis's Clinical Chart, specially designed for use with the

Visiting List. This Temperature Chart is arranged for four weeks and measures 6 × 3 inches. 30s. per 1000, 16s. 6d. per 500, 3s. 6d. per 100, 1s. per 25, 6d. per 12.

Lewis's Nursing Chart.

25s. per 1000, 14s. per 500, 3s. 6d. per 100, 2s. per 50, or 1s. per 20.

These Charts afford a ready method of recording the progress of the case from day to day.

Boards to hold the Charts, price 1s.

Chart for Recording the Examination of Urine.

40s. per 1000; 25s. per 500; 15s. per 250; 7s. 6d. per 100; 1s. per 10.

These Charts are designed for the use of Medical Men, Analysts, and others making examinations of the urine of patients, and afford a very ready and convenient method of recording the results of the examination.

LEWIS'S PRACTICAL SERIES.

Under this title a Series of Monographs is published, embracing the various branches of Medicine and Surgery. The volumes are written by well-known Hospital Physicians and Surgeons, recognized as authorities in the subjects of which they treat. The works are of a THOROUGHLY PRACTICAL nature, calculated to meet the requirements of the practitioner and student, and to present the most recent information in a compact form.

THE TREATMENT OF PULMONARY CONSUMPTION.

By VINCENT D. HARRIS, M.D. LOND., F.R.C.P., Physician to the City of London Hospital for Diseases of the Chest, Victoria Park, etc., and E. CLIFFORD BEALE, M.A., M.B. CANTAB., F.R.C.P., Physician to the City of London Hospital for Diseases of the Chest, Victoria Park, etc. Crown 8vo. 10s. 6d. [Now ready.]

THE SURGICAL DISEASES OF CHILDREN AND THEIR TREATMENT

BY MODERN METHODS. By D'ARCY POWER, M.A., M.B. Oxon., F.R.C.S. Eng., Demonstrator of Operative Surgery at St. Bartholomew's Hospital, etc. With Illustrations, crown 8vo, 10s. 6d. [Now ready.]

DISEASES OF THE NOSE AND THROAT.

By F. de HAVILLAND HALL, M.D., F.R.C.P. Lond., Physician to Out-patients, and in charge of the Throat Department at the Westminster Hospital. With coloured plates and wood engravings, crown 8vo. 10s. 6d.

PUBLIC HEALTH LABORATORY WORK.

By HENRY R. KENWOOD, M.B., D.P.H., F.C.S., Instructor in the Hygienic Laboratory, University College, etc. With Illustrations, cr. 8vo, 10s. 6d.

MEDICAL MICROSCOPY: A GUIDE TO THE USE OF THE MICROSCOPE IN MEDICAL PRACTICE. By FRANK J. WETHERED, M.D., M.R.C.P., Demonstrator of Practical Medicine in the Middlesex Hospital Medical School, &c. With Illustrations, crown 8vo, 9s.

MEDICAL ELECTRICITY. A PRACTICAL HANDBOOK FOR STUDENTS AND PRACTITIONERS. By H. LEWIS JONES, M.A., M.D., F.R.C.P. Second edition, with Illustrations, crown 8vo, 10s. 6d.

HYGIENE AND PUBLIC HEALTH.

By LOUIS C. PARKES, M.D., D.P.H. LOND. UNIV., Fellow of the Sanitary Institute, and Member of the Board of Examiners. Fourth edition, with numerous Illustrations, cr. 8vo, 10s. 6d. [Now ready.]

MANUAL OF OPHTHALMIC PRACTICE.

By C. HIGGINS, F.R.C.S., Ophthalmic Surgeon to Guy's Hospital; Lecturer on Ophthalmology at Guy's Hospital Medical School. Illustrations, cr. 8vo, 6s.

A PRACTICAL TEXTBOOK OF THE DISEASES OF WOMEN.

By A. H. N. LEWERS, M.D. Lond., M.R.C.P., Obstetric Physician to the London Hospital, etc. Fourth Edition, with Illustrations, crown 8vo, 10s. 6d.

ANÆSTHETICS THEIR USES AND ADMINISTRATION.

By DUDLEY W. BUXTON, M.D., B.S., M.R.C.P., Administrator of Anæsthetics and Lecturer in University College Hospital, etc. Second Edition, with Illustrations, crown 8vo, 5s.

TREATMENT OF DISEASE IN CHILDREN.

By ANGEL MONEY, M.D., F.R.C.P., late Assistant Physician to the Hospital for Sick Children, Great Ormond Street. Second edition, cr. 8vo, 10s. 6d.

ON FEVERS: THEIR HISTORY, ETIOLOGY, DIAGNOSIS, PROGNOSIS, AND TREATMENT. By ALEXANDER COLLIE, M.D. Aberd., M.R.C.P. Illustrated with Coloured Plates, crown 8vo, 8s. 6d.

HANDBOOK OF DISEASES OF THE EAR FOR THE USE OF STUDENTS AND PRACTITIONERS. By URBAN PRITCHARD, M.D. Edin., F.R.C.S. Eng., Professor of Aural Surgery at King's College, London. Third Edition, with Illustrations, crown 8vo. [In preparation.]

A PRACTICAL TREATISE ON DISEASES OF THE KIDNEYS AND URINARY DERANGEMENTS. By C. H. RALFE, M.A., M.D., F.R.C.P., Assistant Physician to the London Hospital, etc. Illustrations, cr. 8vo, 10s. 6d.

DENTAL SURGERY FOR MEDICAL PRACTITIONERS AND STUDENTS OF MEDICINE. By ASHLEY W. BARRETT, M.B. Lond., M.R.C.S., L.D.S., Dental Surgeon to, and Lecturer on Dental Surgery in the Medical School of, the London Hospital. Second edition, with Illustrations, cr. 8vo, 3s. 6d.

BODILY DEFORMITIES AND THEIR TREATMENT: A HANDBOOK OF PRACTICAL ORTHOPÆDICS. By H. A. REEVES, F.R.C.S. Edin., Senior Assistant Surgeon and Teacher of Practical Surgery at the London Hospital, etc. With numerous Illustrations, cr. 8vo, 8s. 6d.

 THE NEW SYDENHAM SOCIETY'S PUBLICATIONS.

President:—T. BRYANT, ESQ., F.R.C.S.

Honorary Secretary:—JONATHAN HUTCHINSON, ESQ., F.R.S.

Treasurer:—W. SEDGWICK SAUNDERS, M.D., F.S.A.

 Annual Subscription, One Guinea.

The Society issues translations of recent standard works by continental authors on subjects of general interest to the profession.

Amongst works recently issued are "Sir William Gull's Collected Works," "Laveran's Paludism," "Pozzi's Gynecology," "Flügge's Micro-Organisms," "Cohnheim's Pathology," "Hench's Children," "Spiegelberg's Midwifery," "Hirsch's Historical and Geographical Pathology," "Ewald's Disorders of Digestion," works by Charcot, Duchenne, Begbie, Billroth, Graves, Koch, Hebra, Guttmann, etc.

The Society also has in hand an Atlas of Pathology with Coloured Plates, and a valuable and exhaustive "Lexicon of Medicine and the Allied Sciences."

The Annual Report, with full list of works published, and all further information will be sent on application.

 PERIODICAL WORKS PUBLISHED BY H. K. LEWIS.

THE BRITISH JOURNAL OF DERMATOLOGY. Edited by William Anderson, H. G. Brooke, H. Radcliffe Crocker, T. Colcott Fox, Stephen Mackenzie, Malcolm Morris, J. F. Payne and J. J. Pringle. Published monthly, 1s. Annual Subscription, 12s. post free.

TRANSACTIONS OF THE DERMATOLOGICAL SOCIETY OF GREAT BRITAIN AND IRELAND. Vol. I., royal 8vo, 5s.

THE THERAPEUTIC GAZETTE. A Monthly Journal, devoted to the Science of Pharmacology, and to the introduction of New Therapeutic Agents. Edited by Dr. R. M. Smith. Annual Subscription, 10s., post free.

THE GLASGOW MEDICAL JOURNAL. Published Monthly. Annual Subscription, 20s., post free. Single numbers, 2s. each.

LIVERPOOL MEDICO-CHIRURGICAL JOURNAL, including the Proceedings of the Liverpool Medical Institution. Published twice yearly, 3s. 6d. each number.

TRANSACTIONS OF THE COLLEGE OF PHYSICIANS OF PHILADELPHIA. Volumes I. to VI., 8vo, 10s. 6d. each.

MIDDLESEX HOSPITAL, REPORTS OF THE MEDICAL, SURGICAL, AND Pathological Registrars for 1883 to 1892. Demy 8vo, 2s. 6d. *nett* each volume.

ARCHIVES OF PEDIATRICS. A Monthly Journal, devoted to the Diseases of Infants and Children. Edited by Dr. W. P. Watson. Annual Subscription, 12s. 6d., post free.

* * MR. LEWIS is in constant communication with the leading publishing firms in America, and has transactions with them for the sale of his publications in that country. Advantageous arrangements are made in the interests of Authors for the publishing of their works in the United States.

Mr. Lewis's publications can be procured of all Booksellers in any part of the world.



1



