

The rapid cure of aneurism by pressure : illustrated by the case of Mark Wilson, who was cured of aneurism of the abdominal aorta in the year 1864 / by William Murray.

Contributors

Murray, William, 1839-1920.

Publication/Creation

London : J. & A. Churchill, 1871.

Persistent URL

<https://wellcomecollection.org/works/g46j87bk>

License and attribution

This work has been identified as being free of known restrictions under copyright law, including all related and neighbouring rights and is being made available under the Creative Commons, Public Domain Mark.

You can copy, modify, distribute and perform the work, even for commercial purposes, without asking permission.

**wellcome
collection**

Wellcome Collection
183 Euston Road
London NW1 2BE UK
T +44 (0)20 7611 8722
E library@wellcomecollection.org
<https://wellcomecollection.org>

THE RAPID CURE OF ANEURISM


BY PRESSURE

BY

W. MURRAY, M.D., M.R.C.P. Lond.

NEWCASTLE-ON-TYNE.

M18547



22101727869

W. J. W.
A. MacLachlan
Comp.

7

3/-

#

17

55487

LAI

THE
RAPID CURE OF ANEURISM BY PRESSURE,
ILLUSTRATED BY THE CASE OF
MARK WILSON,
WHO WAS CURED OF
ANEURISM OF THE ABDOMINAL AORTA
IN THE YEAR 1864.

BY
WILLIAM MURRAY, M.D., M.R.C.P. LOND.,
LECTURER ON PHYSIOLOGY IN THE UNIVERSITY OF DURHAM; LATE PHYSICIAN TO THE
DISPENSARY, AND CONSULTING PHYSICIAN TO THE CHILDREN'S
HOSPITAL, ETC., NEWCASTLE-ON-TYNE.



LONDON:
J. & A. CHURCHILL, NEW BURLINGTON STREET.
1871.

10965

M18547

WELLCOME INSTITUTE LIBRARY	
Coll.	welMOmec
Call	
No.	WG500
	1871
	M98r

9.4.75

Dedicated

TO THE MEMORY OF THE LATE

CHARLES MOORE, Esq.,

WHO, BY HIS UNWEARIED EXERTIONS, CONTRIBUTED MUCH TO OUR

KNOWLEDGE OF THE PATHOLOGY AND TREATMENT


OF ANEURISM,

AND, BY HIS EARLY APPRECIATION OF THE MERITS OF THE

RAPID METHOD,

MATERIALLY PROMOTED ITS INTRODUCTION AS A NEW MEANS OF

TREATING THAT DISEASE.



P R E F A C E.

I HAVE much hesitation in contributing so meagre an addition to the voluminous literature we now possess on the subject of aneurism, but my reasons for publishing are, I think, so substantial that I deem a little better than none at all. The extreme importance of developing a plan of treatment which shall reach the aneurisms of large and internal vessels, and the equal importance of rendering that treatment short, safe, and endurable by the patient, prompt me to bring the subject before the profession, in the expectation that the treatment herein described will ere long be adopted in all appropriate cases. Brilliant and effectual as the ligature and the knife may be in the hands of distinguished operators, we must not forget that their use is surrounded by dangers, while Rapid Pressure no less surely, scarcely less speedily, and much more safely, may lead to similar results in much less experienced hands.



Digitized by the Internet Archive
in 2014

<https://archive.org/details/b20388706>

CONTENTS.

CHAPTER I.

	PAGE
INTRODUCTION	9

CHAPTER II.

HISTORY OF CASE	13
---------------------------	----

CHAPTER III.

POST-MORTEM EXAMINATION	26
-----------------------------------	----

CHAPTER IV.

PROGRESS OF THE RAPID METHOD	32
--	----

CHAPTER V.

CONCLUDING REMARKS	40
------------------------------	----

CHAPTER I.

Introduction.

As an introduction to the subject of my essay, I shall endeavour to recall as correctly as possible the steps by which I was led to adopt the Rapid Method in the case of Aneurism of the Abdominal Aorta which is fully detailed in the following pages. I shall also add a few remarks on the origin and nature of the Rapid Method, in the hope of establishing it as an accepted and improved mode of curing aneurism by pressure.

When Wilson presented himself as a patient at the Newcastle Dispensary, I made several careful examinations of the pulsating tumour from which he suffered, and in doing so I discovered that by firm pressure with my own hand I could to a great extent command the pulsations of his aneurism. It then occurred to me that pressure which had been successful in other parts might be applied to the abdominal aorta. Then came the idea that to render the necessary amount of pressure tolerable,

chloroform might be used, and further, that chloroform would enable me so completely to command the vessel, that *coagulation of blood* in the aneurism might occur if the current were thus completely arrested.

After repeatedly considering these points, the whole subject assumed a new phase in my mind. Here was a case which had suggested a treatment that seemed to involve an entirely new view of the application of pressure in the treatment of aneurism; a treatment which would not only be more speedy in its action, but also cure the disease by an entirely new process. So strongly was I influenced by these considerations, that I at once proceeded to test their accuracy. The results which followed were more than could be expected, for the rapid manner in which the aneurism was cured bore the most direct testimony to the nature of the curative process, and that which before had been a mere surmise now became a settled conviction.

As my object in detailing the following case is not only to establish the possibility of compressing so large a vessel as the aorta for the cure of aneurism, but more particularly to point out the *nature of the curative process*, I call special attention to that part of the report where I describe the manner in which the aneurism ceased to beat. The sudden and complete consolidation of an *internal* aneurism was, as far as I know, an entirely new fact in medical science; and the repetition of the same phenomenon in other cases which have since been treated by the same means tends strongly to show that all

aneurisms may be treated on the same principle. I think it is not too sanguine to expect that in future, wherever pressure is used for the cure of aneurism, the administration of chloroform will be considered an essential part of the treatment, and that sudden and rapid cure by the coagulation of blood will be no uncommon result, in place of the slow and gradual change which is brought about by the lamination of fibrin when the older method is pursued. I would further remark that the *principle* on which the rapid method rests is clearly "the complete stagnation of a mass of blood in the aneurism until it coagulates." Whether this is to be done under chloroform or without it; whether by pressure both above and below or only above the sac; and whether the pressure is to be made by the hand, by flexion, by a weight, or by a tourniquet, are questions which in no way touch the principle on which the treatment is based. The importance of the following case is greatly enhanced by the post-mortem evidence of its reality which has been now obtained. Until this was procured, I hesitated to press its claims on the notice of the profession, lest there should have been any error of diagnosis in the case. Now that all fear on that account is removed, I would claim for the case great importance, because it involves in itself not one but several facts new to anatomy, physiology, and practical medicine. It establishes,

1st. The possibility of suddenly blocking up the aorta below the renal arteries without injury to the patient.

2nd. It reveals the channels by which blood finds its

way to the lower part of the body when the aorta is thus occluded.

3rd. It shows the vast importance of giving chloroform in using pressure for the cure of aneurism; and

4th. It proves that aneurism can be cured in a few hours by coagulation of blood, while the old method, which cured the disease by fibrinous lamination, lasted on an average five and twenty days.

CHAPTER II.

History of the Case.

FIVE weeks after the treatment had been employed, Wilson was well enough to travel to London. I therefore took him to the meeting of the Royal Medico-Chirurgical Society, held on May 24th, where he was carefully examined by many eminent members of that Society, and they unanimously confirmed the observations related in the paper which was read by the late Mr. Moore. The following extract from the Medico-Chirurgical Society's *Transactions* contains a full history of the case up to the time when my paper was read:—

An Account of a Case of Aneurism of the Abdominal Aorta, which was cured by Compression of that Artery immediately above the Tumour, by the Rapid Method. Communicated by the late Charles H. Moore, F.R.C.S. Received April 26th.—Read May 24th, 1864. (Med. Chir. Soc. Trans., 1864.)

History.—The patient (Mark Wilson) is a spare man, twenty-six years old. His occupation as a paviour has

compelled him to use a large wooden rammer for driving paving stones into the ground. Often, in making strenuous efforts, he has overreached himself, and subjected the trunk of his body to severe straining. Eleven months ago, after a hard day's work, he was seized somewhat suddenly with a very severe pain in the back, of a gnawing character, and preventing movement. Two months later the same pain began to be felt very severely in the abdomen, catching his breath during inspiration. He was treated for these pains by several medical attendants, with leeches, blisters, &c. About two months ago he began to feel a slight pulsation in the belly, and shortly after that time he became my patient at the Newcastle Dispensary, where, after a few examinations, I became convinced that he had an aneurism of the abdominal aorta. This opinion was shared by the resident medical officer of the dispensary.

The following is the condition of the patient as noted previous to treatment:—"His abdomen is somewhat spare, so that a distinct pulsation can be seen to the left of and slightly above the umbilicus; the pulsation is most distinct during expiration. On applying the hand, a hard, slightly moveable pulsating mass, of a distinct globular form, is to be felt extending from about two inches to the left to about one inch to the right of the umbilicus, and upwards to within three inches of the margin of the left lower ribs. The pulsations in it are very strong and impinge upon the hand with a sudden stroke, and the expansion of the tumour very distinctly separates the hands when applied

to it. The tumour is about the size of a very large orange. The impulse conveyed to the hand, when laid on the upper part of the tumour, is almost as strong upwards as it is downwards when felt by the hand applied below the tumour. When pressure is made on the aorta above it, all pulsation ceases, and when the pressure is removed a distinct thrill is felt to accompany the rush of blood into the tumour. (A line drawn across the abdomen over the umbilicus touches at either end the margins of the last ribs, and encloses between the free borders of the ribs a triangular space (the epigastric region); over the left half of this space there is room enough to compress the aorta against the spine.) The aorta below the tumour can be felt, and its pulsations seem in no way to vary from their normal character. By auscultation a feeble bruit can be heard over the tumour. The patient is in good general health; his bowels are subject to occasional attacks of constipation, sometimes being open every day, at others only once in two or three days, which may to a certain extent be accounted for by the large quantity of opiates he has taken to relieve the acute pain which he has suffered. His arterial system is free from evidence of degeneration."

All palliative treatment having failed to relieve him, after much thought and careful consideration, I proposed to apply a tourniquet above the aneurism, and thus attempt to cure it by compression. It happened, as I have before shown, that between the aneurism and the free borders of the ribs on the left side there was space

enough to permit one blade of a tourniquet to press down on the spinal column, and on tightening the tourniquet I found that, by a very nice adaptation, the pulsation in the aneurism could be completely commanded. The instrument used was the ordinary horse-shoe tourniquet, made so as to open rather wider than usual, and thus to grasp the trunk of the body.

I took the patient to the Northumberland and Durham Medical Society, to have my diagnosis verified, and to propose my plan of treatment. Several members examined the tumour, and it was admitted by all who did so that the case was unquestionably one of aneurism of the aorta. The president, Dr. Heath, expressed the same opinion in very decided terms. The following is an extract from the Report of the Monthly Meeting of the Northumberland and Durham Medical Society, April 14th, 1864 :—

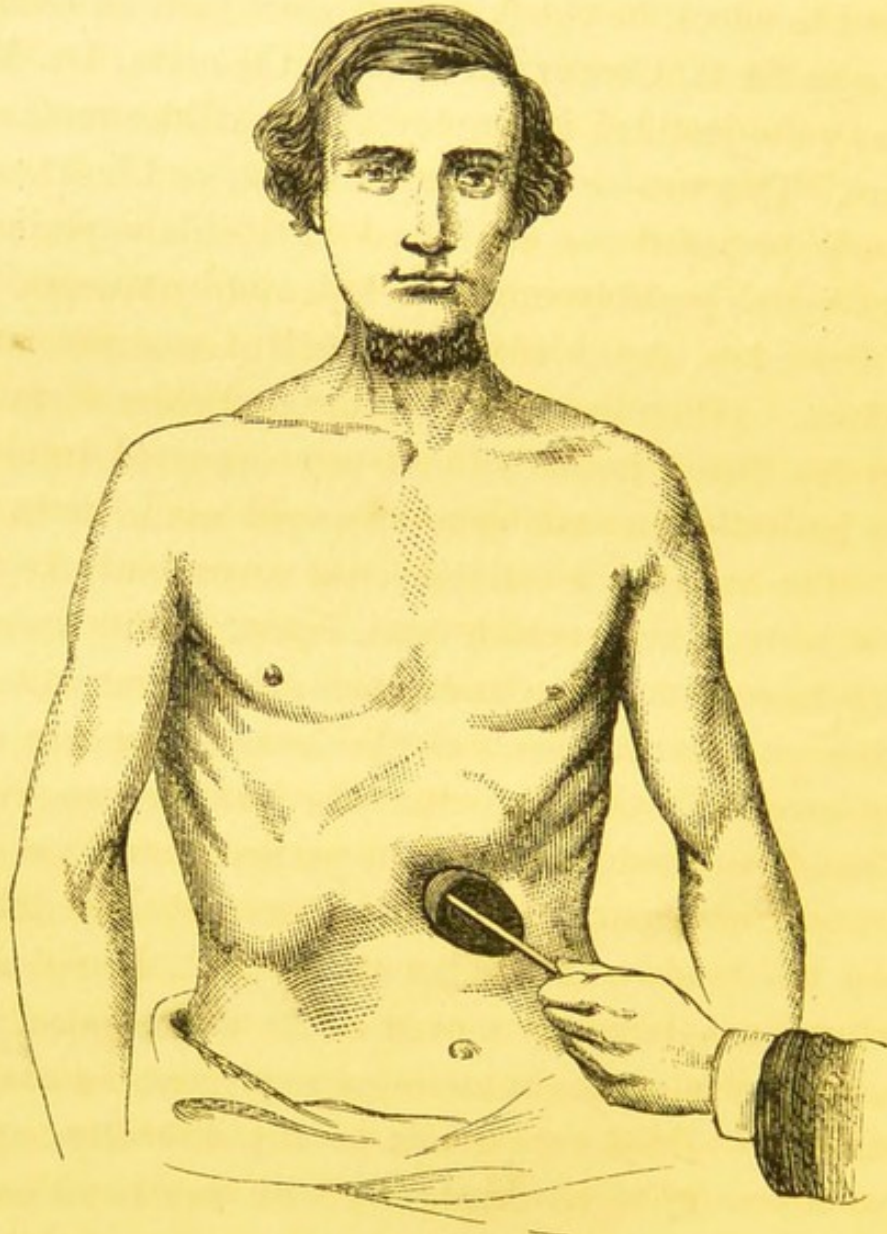
“Dr. Murray introduced a patient suffering from aneurism of the abdominal aorta. That it was an aneurism was clear from the fact that when a tourniquet was applied above it, pulsation ceased; and on removing the pressure a distinct thrilling rasping sensation was communicated to the hand as the tumour recommenced beating, as if produced by the rush of blood into its interior. As the patient was young, Dr. Murray proposed to operate on the aneurism by pressure. He thought that treatment fully justified, because the disease was otherwise necessarily fatal. Several gentlemen having asked questions and made remarks, Dr. Heath, the president of the society, said, “this was a very interesting case; they

sometimes met with instances of pulsation of the abdominal aorta, which closely resembled aneurism, but he thought there was no doubt this was truly a case of aneurism. With respect to the treatment which Dr. Murray proposed to adopt, he thought that since such an eminent surgeon as Sir A. Cooper did once tie the aorta, Dr. Murray was quite justified in employing the milder method of pressure. This was an age of experiment, and he thought the course proposed was a fair and justifiable experiment, and one which possibly might be followed by success."

On Saturday, April 16th, the patient was put under chloroform. (Having lately administered chloroform to a patient for fifteen hours without any apparent injury, I had no hesitation in making a prolonged use of it in this case.) The anæsthetic influence was accordingly kept up for two hours, during which time, except during momentary displacements of the instrument, the pulsation in the aneurism and in the vessels of the lower limbs was completely arrested. On removing the pressure no visible effect had been produced; but the patient passed no urine for nearly thirty hours. It was found exceedingly difficult to keep up steady pressure, as the patient, being under chloroform, unconsciously moved about a good deal; the irregular action of the muscles of expiration in the abdominal wall added very much to the difficulty, and it became necessary to sit constantly with one hand on the screw of the tourniquet, and the other on its anterior or applied blade, and thus to secure the constant pressure required. On neither occasion when the pressure was

applied did we escape a considerable number of recurrences of the pulsation from displacements of the instrument. This statement, however, does not apply to the

PLATE I.



last hour of the second and successful attempt, during which all movement and pulsation were completely arrested.

On Tuesday, April 19th, after much entreaty on my part, the patient again submitted to be put under chloroform. Dr. Heath having carefully re-examined the tumour, and expressed his conviction of the nature of the disease, the tourniquet was applied, and pulsation in the tumour completely arrested. With the assistance of Drs. Nesham and Spencer, and Messrs. Armstrong and Powell, the pressure and the insensibility were kept up for about five hours. Until the last hour the slightest movement in the tourniquet showed that pulsation in the tumour had not ceased, and that the disease was unaltered. During the last hour the existence of pulsation became less obvious. It was then deemed prudent, lest the patient's strength should be exhausted, to remove the pressure and see what had been accomplished. On finally removing the pressure very slight pulsations were felt, and hopes were entertained that some advantage had been gained. As the femorals did not beat during the application of pressure, the extremities had become cold; and when the patient recovered from the chloroform a fit of shivering occurred. Hot bottles were applied to the feet, and hot brandy and water was given, followed in a short time by a large dose of a mixture of chlorodyne, opium, and belladonna, containing about ʒjss. of the tincture of the last drug, which I find is a perfectly safe dose as an anodyne when combined with an ordinary dose of opium. In the evening he was found restless, and "sore all over," with tenderness at the seat of the aneurism and of the pressure, and numbness of the extremities. To my

astonishment the tumour had now become perfectly pulseless, and every indication of pulsation in the aorta below it had disappeared.

Wednesday, April 20th.—Patient feels restless and slightly feverish, with thirst and hot skin, but the pulse is only 72 and feeble. Bowels open, passes water freely; can stand, although the legs are still numb, and he feels “pins and needles” in his feet. In consultation with Dr. Heath, a most careful examination was made, and the following observations were confirmed by that gentleman. There is no pulsation in the tumour, which is now perfectly stationary, hard, resistant, and lessened in size. Nor are any pulsations to be felt in the aorta below the tumour, in the iliacs, or in the femoral arteries.

Thursday, April 21st.—Patient looks well and feels much better; says he is more free from pain than he has been for several months. There is a very slight movement in the tumour, which is now a hard globular mass, easily felt, and slightly moveable, but evidently smaller than before. At one or two points on the abdominal wall pulsating vessels can be felt, but there is no pulsation in the femorals.

Friday, 22nd.—With Mr. Lightfoot, who carefully examined the case, the following points were made out and verified by that gentleman:—A solid hard tumour, of about the size of an apple, lying to the left of the umbilicus, can be felt, and during deep expiration can be seen. It is motionless to the eye, and by the hand the slightest possible forward movement can be distin-

guished at its upper border, as if communicated from the aorta pulsating above. No expansion, thrill, or bruit, can be made out. Running over the right border of the tumour a vessel can be felt pulsating, which, from its position and size, is probably the superior mesenteric artery. The femorals are pulseless. All numbness is gone from the legs, and the patient declares he feels quite well.

Saturday, 23rd.—Observation of the tumour corresponds with the notes of yesterday in every particular. The pulsation of small arteries in the abdominal wall is now pretty distinct. The patient is sitting up and out of bed, feels better than he has done for months past, and is free from pain. Eats well and sleeps well.

Sunday, 24th.—Going on well.

Monday, 25th.—Still improving, and is moving about freely. The tumour is now much diminished in size, and no pulsation can be distinguished. (Observation confirmed by Dr. Spencer.)

Tuesday, 26th.—The patient has been out this morning, and walked about a quarter of a mile. On ceasing to walk he felt as if a cord was tied around his waist, and was quite numb below that level. He feels his legs numb and weak, but in other respects is quite well and in good spirits, declaring himself to be better than he has been "for eleven months past." After careful examinations, the observations previously made were this morning confirmed by Messrs. Fife and Armstrong. Mr. Rayne, after a very careful examination, also expressed his con-

viction "that there is now no blood passing through the tumour." Dr. Gibb and many other medical gentlemen in the town, after examining the parts, came to a similar conclusion.

May 1st.—Patient still improving. Legs warm and stronger, but still numb when he walks far. Had an attack of diarrhoea, which ceased on taking a few doses of chalk mixture. No pulsation in the tumour or arteries below it.

5th.—Still improving. Took a long walk two days ago, and, except a feeling of numbness and weakness in the legs, was no worse for it. Tumour carefully examined this morning in the presence of several medical men, when the following points were observed and verified:—
"The tumour is stationary, harder than before, and lessened in size. Its periphery lies seven inches from the sternum (the patient having a long chest) and five inches above the pubes, four inches from the anterior superior spine of ilium on the left side, and five inches from the same point on the right side. It lies a little more to the left than to the right of the umbilicus." No bruit can be heard, and the aorta above can be felt beating in the epigastrium.

11th.—Patient still improving, tumour pulseless, and diminishing in size.

(The following remarks were appended to the Report.)

I need offer little comment on this case, especially as the patient will be introduced at the meeting of the

Society. I would note, in the first place, that we have in it a most complete triumph for the advocates of "compression" in the treatment of aneurism. The disease, though one which has baffled all attempts to cure it, has in this instance disappeared by means of treatment lasting but a few hours, and involving the use of a known and simple expedient.

Secondly, here is actual proof that a sudden occlusion of the aorta can take place without violent symptoms or great inconvenience ensuing.

Again, the case shows that in compression, as has been noted by an eminent surgeon in the North, "the actual cure takes place very rapidly, probably in less than an hour;" for, till within the last hour of the treatment, the slightest movement in the tourniquet was followed by most violent beating in the aneurism.

As an instance of the dependence of a curative process on the influence of chloroform, this case is most striking; for no man, exhausted with pain and weary of life, could have borne for five hours, without an anæsthetic, such tremendous pressure as was here employed, even though that pressure were to save his life.

Postscript, July 7th, 1864.—The patient has obtained a situation as a "fitter," and feels equal to the work. The only unfavourable symptom now present is a numb pain in the knees after walking, which disappears after resting a few minutes. The lower limbs are plump, but flabby; the rest of the body is well nourished. The

tumour is now scarcely to be felt, and the aorta, iliacs, and femoral arteries, are still quite pulseless.

Postscript, September 26th, 1864.—I have seen the patient this morning, and he looks well. He only complains of slight weakness and pain in his back and legs. The numbness no longer exists. He works as an engine-fitter from 6 a.m. till 8, and sometimes 10 p.m.; in addition to which he has to walk nearly two miles to and from his work. The abdomen and limbs are now plump and fat. Only slight hardness, which is evident on *deep pressure only*, is perceptible at the site of the aneurismal tumour. There is no pulsation in the aorta below the site of the tumour, but above it a very distinct thud can be felt to strike dead against the applied hand. There is now distinct pulsation in the right femoral artery, but no certain evidence of it in the left. The patient says “he now feels as well as ever he did in his life.” Five months have now elapsed since pulsation was felt in the tumour.

Report continued up to 1870.

The patient continued to enjoy good health until the commencement of the year 1870, having during the intervening six years followed a variety of laborious occupations, and having also on several occasions undergone no small amount of privation through the prevailing scarcity of work. During this period the aneurismal swelling gradually disappeared, the termination of the aorta could be very easily distinguished by its thud

against the hand when applied about three inches above the umbilicus, and its course below the thudding point remained absolutely pulseless.

By far the most notable change during this period was the appearance of numerous large pulsating vessels on the front and sides of the abdominal parietes; one on either side of the rectus muscle on the site of the epigastric arteries equalled the femoral artery in size, while those on the upper part and lateral aspects of the abdomen varied from the size of the brachial artery to that of the ulnar. The course of these vessels was, for the most part, extremely tortuous and difficult to trace.

About the commencement of the present year (1870) the patient was compelled to resume his old occupation as a paviour, and the strenuous efforts required of him once more brought on violent pain in the epigastrium, which was speedily followed by other symptoms of an aneurism in that region. This latter disease, when fully developed, was found to lie so close to the diaphragm that pressing the aorta above it was out of the question. The aorta below this new aneurism was very carefully examined, and found to be perfectly free from pulsation; in fact, it was evident that the aorta above the occluded point had given way and become dilated into an aneurism. The usual symptoms of aneurism of the aorta near the cæliac axis were terminated by the sudden death of the patient on June 1st, 1870.

CHAPTER III.

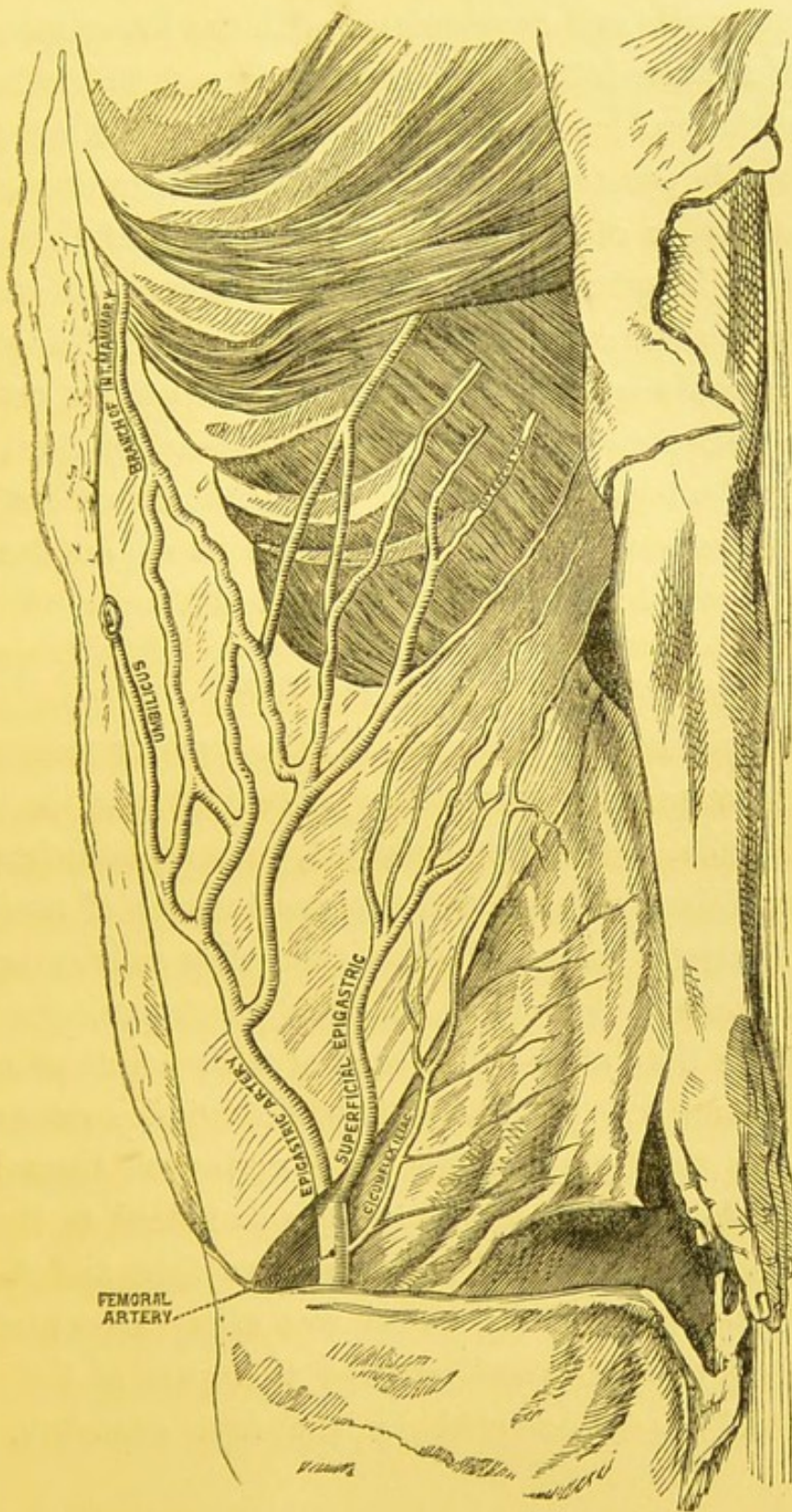
*Report of the Post-mortem Examination held on the 2nd of
June, 1870.*

THIS examination was conducted by Dr. Maclachlan and Mr. Davidson, assisted by Mr. Johnson, in the presence of Mr. Russell, one of the surgeons to the Newcastle Infirmary, and several other gentlemen. To all these gentlemen I am much indebted for the assistance they afforded, but more especially to Dr. Maclachlan, who carefully dissected the aneurism after its removal from the body.

Vessels in Abdominal Walls.

On removing the skin from the front of the abdomen a numerous array of tortuous blood-vessels was found ramifying in every direction; the tortuous branches of neighbouring trunks were seen to anastomose directly with each other, and the terminations of the trunks themselves were observed to be continuous with each other. (1) The deep epigastric artery (as large as the axillary) ran up along the outer border of the rectus muscle, giving

PLATE II.



off lateral branches; (2) other branches of the epigastric passed outwards and anastomosed with the lower intercostal arteries, these latter being much enlarged and tortuous. (3) One lateral branch of the epigastric given off from its inner side penetrated the umbilicus, and running along the free border of the suspensory ligament of the liver, entered the longitudinal fissure of that organ and anastomosed with a branch of the hepatic artery. (4) The superficial epigastric artery, enlarged and very tortuous, entered a plexus of vessels formed by it and branches of the lower intercostal arteries. (5) The superficial circumflex iliac followed the same course, and joined in an anastomosis with the lower intercostals. (*See Plate II.*)

Vessels inside Abdomen.

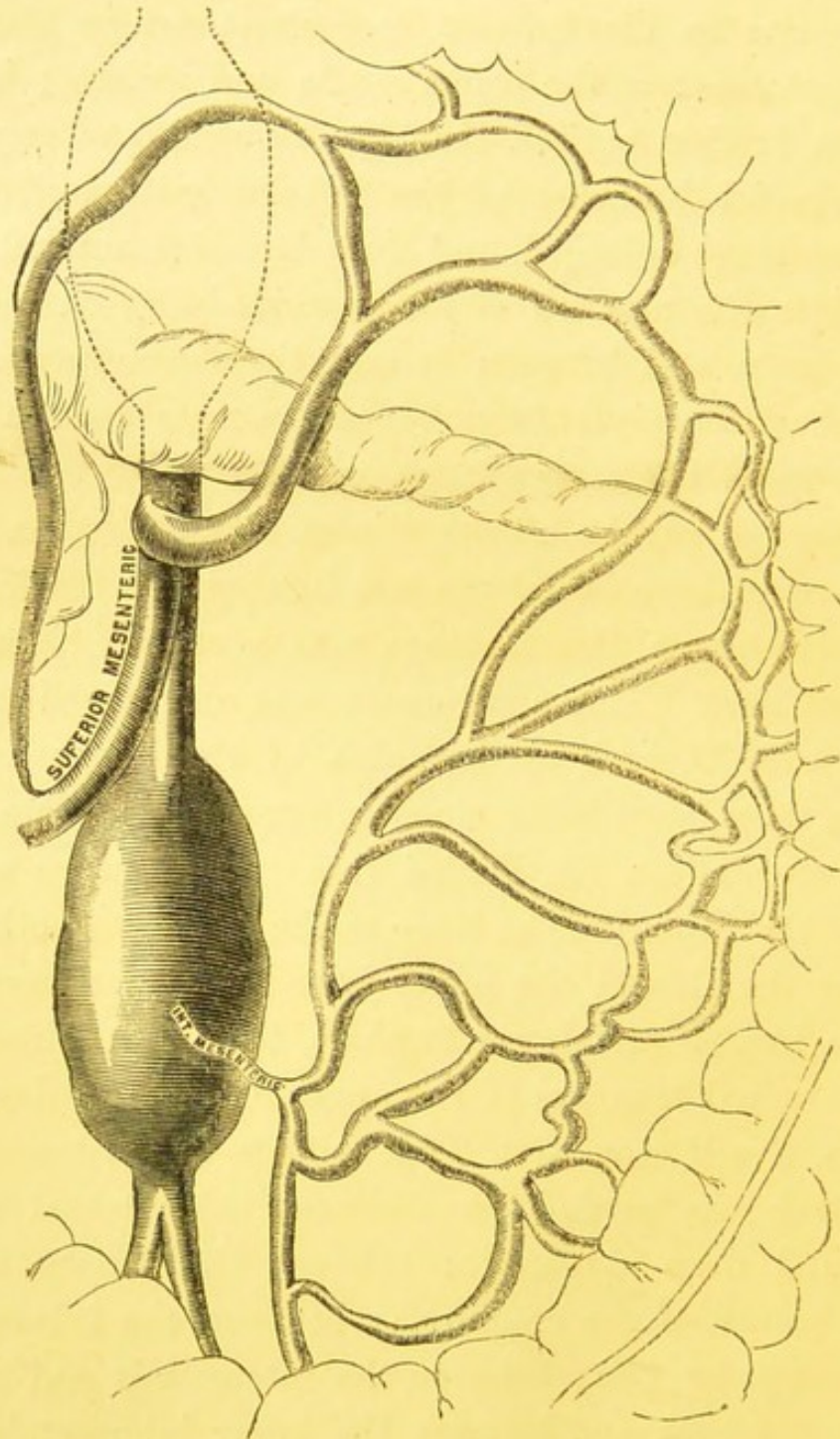
After opening the abdomen, (1) the superior mesenteric artery, as large as the aorta, was apparent, (2) and the colica media branch, enormously enlarged, gave off branches of a very large size, which joined the anastomosis of similarly enlarged vessels given off from the colica sinistra branch of the inferior mesenteric. All these anastomosing vessels were larger than crow-quills even at their points of union with each other. (3) The state of the inferior mesenteric artery was most peculiar, for while giving off these large branches the trunk of the vessel was dwindled to the size of the radial artery, and its coats were thin and flaccid. This wasted state of the vessel was easily accounted for by finding that the vessel entered that part of the aorta which had been occupied by the first aneurism, and

which was now a mere fibrous mass. It was evident, therefore, that a very free current had been sent from the superior to the inferior mesenteric artery through this anastomosis of the colica media and sinistra; but it must be further noticed that the sigmoid and superior hæmorrhoidal branches of the inferior mesenteric were also very much enlarged, and their branches entered very freely into the network of anastomosis lying on the left of the aorta and between it and the descending colon. The rest of the *visceral* branches of the aorta were in their natural state, but a very large and free anastomosis was found on the surface of the iliacus and quadratus muscles, between branches of the last lumbar and ilio-lumbar artery (which in this instance was given off from the common iliac). This anastomosis was also joined by the circumflexa ilii and by branches of the upper lumbar arteries, these latter being much enlarged. (See Plate III.)

The circumflexa ilii divided into two branches at the crest of the ilium (one as large as the radial, the other as large as the ulnar); the upper joined the anastomosis of the ilio lumbar and lower lumbar, the other joined the large terminal branches of the upper lumbar arteries.

Thus, it will seen—1st. That outside the abdomen the circulation was carried on—between the internal mammary and deep epigastric; between the *hepatic* artery and a branch of the epigastric; between the intercostals and deep epigastric; between the intercostals and superficial epigastric; and between the lower intercostals with the superficial circumflex iliac.

PLATE III.



2nd. Within the abdomen the circulation was carried on,—between the colica media of the superior mesenteric artery and the colica sinistra branch of the inferior mesenteric, including its sigmoid and hæmorrhoidal branches; between the upper lumbar arteries and the ilio lumbar; and between the lower lumbar arteries and the circumflexa ilii.

As regards the state of the aorta itself, it was observed to be largely dilated up to the new aneurism, which had become “diffuse” before death, and rendered any careful dissection impossible, as the whole of the precincts of the aorta were completely occupied by large coagula and masses of semi-coagulated blood. The aorta below this was completely occluded, and its walls in an atrophied condition.

CHAPTER IV.

On the Progress of the Rapid Method.

It is impossible to leave the history of this case without remarking on the results which have followed, since the treatment therein introduced has been adopted by other surgeons.

Dr. Mapother's Cases.

In the hands of Dr. Mapother, of Dublin, two cases have been cured, Dr. Mapother having strictly followed the plan I pursued, and having tried with it the suggestion made by Dr. O'Ferrall, of applying pressure on the distal as well as on the cardiac side of the aneurism. His first case was pressed without chloroform at first, and afterwards under chloroform, and at the last effort under chloroform the aneurism was cured in four and a half hours. Dr. Mapother's second case was scarcely so successful, the pressure having lasted ninety-seven hours before coagulation occurred. Dr. Mapother holds the same views as I have repeatedly expressed, and concludes "that

the blood should be detained in the sac as completely as possible, by compression on the artery above and below it." Holding that the cure is effected by coagulation of the blood *en masse* and not by laminated fibrin, Dr. Mapother also dwells on the desirability of giving chloroform, and on applying pressure both above and below the sac.

Dr. Heath's Cases.

Dr. Heath, of Newcastle, has also been successful in curing at least two cases by the same method. The first of his cases was a striking and brilliant example of the treatment; for the aneurism was distinctly consolidated in the short space of twenty minutes. I am glad to know that Dr. Heath holds strongly to the idea that complete pressure under chloroform leads to rapid cure by coagulation. The following is an extract from his address on "Surgery," delivered at the annual meeting of the British Medical Association, 1870:—

"The old or slow pressure method was an advance upon the ligature; but what I believe was first named by myself the 'rapid pressure treatment,' must be considered to be in some respects even a greater improvement upon the older plan.

"The rapid pressure treatment may be considered but the natural development of the older method, and, like many other triumphs of modern surgery, owes its practicability to chloroform.

“I should rather leave to those who best know what dangers encompass him who is submitted to the knife and the ligature—the shock, the suppuration, the erysipelas, the pyæmia, the gangrene, and the secondary hæmorrhage—the appraisalment of a measure which, after a few hours’ sleep, leaves the awakened patient free from his disease, with no wound to heal, no further risk to run, and to say whether any surgical proceeding ever more truly deserved the application of the old maxim—*Cito, tuto, et jucunde.*”

Mr. Holden’s Case.

A very striking case is reported in the Bartholomew’s Hospital Report, Vol. II., by Mr. Eck. The patient was under Mr. Holden’s care, and the pressure was kept up for five hours (during the first hour without chloroform), and it resulted in a remarkable diminution of the pulsations, which finally disappeared in three weeks. In this case some decided change was effected by the pressure, which eventuated in cure. This point, though not favourable to the rapidity of the cure, is highly important as a confirmation of what occurred in most of the other cases, viz., a decided consolidation without absolute cessation of pulsation, the very faintest degree of pulsation being in some cases continued for a short time after the removal of the pressure.

Mr. Lawson Tait’s Case.

In November, 1867, Mr. Lawson Tait wrote an inte-

resting paper in the *Medical Times and Gazette*, pointing out the desirability of completely arresting the current in the aneurism, but he does not mention the use of chloroform. He refers there to the opinions of Mr. Henry Lee and Mr. Bryant, both of whom evidently hold that the rapid method is a great advance on the older and slower mode of treatment. Mr. Lawson Tait was successful in his case without the use of chloroform, and, as far as I can see, the instrument he used may prove highly serviceable when chloroform is inadmissible.

The next case was cured by Mr. Lawson in the Middlesex Hospital, and *it* affords the most striking example of the rapid cure. In this case the pressure was applied for twenty-three minutes only.

Mr. Lawson's Case.

“Inguinal aneurism cured by compression of the abdominal aorta.—The patient, a man, æt. 36, was under Mr. Lawson's care in Middlesex Hospital. The treatment was commenced, on August 21, by the application of Carte's compressor to the femoral artery in the groin, just above the aneurism, which was so applied as to shut off all but a wave of impulse from the sac. The pressure was very badly borne, from the pain it produced; still the man took great interest in the treatment, and bore it as well as he could. He soon learned to regulate it for himself, screwing it up firmly as long as he could bear it, and only relaxing it every hour or so for a short time,

when he could endure it no longer. The tumour, however, altered very little during six weeks of this treatment, the tourniquet being apparently used during the daytime, as described, and left off at night.

“On October 9 and 10 there was a very decided improvement in the condition of the tumour; its density had further increased, and the pulsations considerably lessened in force. Notwithstanding these changes, Mr. Lawson decided to adopt the treatment pursued by Dr. Murray, of Newcastle, and to compress the abdominal aorta so as to completely arrest the flow of any blood through the aneurismal sac.

“On October 10, at three o'clock p.m. (the bowels having been completely emptied by an enema), the man was placed thoroughly under the influence of chloroform. A Lister's tourniquet was applied over the abdominal aorta, just above the umbilicus, and another tourniquet was placed firmly over the femoral artery, just below the aneurism. The tourniquets were kept on for twenty-three minutes. Only once at the end of the fourth minute did a wave of blood pass into the sac of the aneurism, when the tourniquet over the aorta was at once tightened; but for the remaining nineteen minutes absolute compression of the vessel was maintained, and no blood entered the tumour. The man now became somewhat collapsed, and began to retch. The tourniquets were then removed, and the administration of the chloroform stopped. The pulsations in the tumour were diminished, but they were perfectly regular. It was,

however, impossible to say whether the diminution of the pulsations were not due to the collapsed state of the patient. The man was returned to his bed, and the Carte's compressor readjusted over the artery. When the effects of the chloroform had completely passed off he complained of coldness and numbness of the legs, with soreness in the belly. At seven o'clock in the evening, finding that all pulsation had ceased in the aneurism, the man himself removed the compressor. The house-surgeon was at once sent for, and he found that there was no longer any pulsation in the tumour. Since that time the man has continued to improve. With the exception of some feeling of soreness in the belly, which lasted for about thirty-six hours, the patient suffered no inconvenience from the treatment.

“October 17.—The aneurismal sac is now felt as a hard oval mass; the artery which leads to it pulsates strongly, but all impulse ceases at the upper edge of the tumour.”

Nothing could better illustrate the difference between the slow and rapid method than this case. Contrast the six weeks' application of Carte's compressor (without chloroform) to the femoral artery, with the application of Lister's tourniquet (with chloroform) to the abdominal aorta—the difference between six weeks of imperfect pressure, and twenty minutes of an absolutely stagnated current.

Mr. Russell's Case.

The last case was cured by Mr. Russell, of Newcastle-on-Tyne. I had the pleasure of seeing that in his case the treatment was carried out most carefully, and terminated successfully after a few hours' trial.

There is one point established by these cases which strongly confirms the above theory of the process by which the cure is effected. I refer to the apparently unchanged condition of the aneurism until the last hour, half hour, or twenty minutes of the pressure. The value of this fact is still further enhanced when we remember that more than one surgeon has observed that while treating their cases by the old method, they had been surprised to find, after long and anxious waiting, that a sudden and unexpected change had taken place, by which the cure was at once completed. Dr. Banon's case related below was in all probability one of this class. The truth is, that in this case, as soon as the current was sufficiently arrested, the new method was unconsciously being tried instead of the old.

Dr. Banon's Case.

Dr. Banon states "that the man had suffered from popliteal aneurism, and compression was used for some time ineffectually. He was worn out by want of rest.

He got a large opiate, which produced great somnolence. When in this state the resident pupil screwed down the instrument so as to stop all pulsation, and in six hours the tumour was solid. The man was in as favourable a condition for the adoption of pressure as if he had got chloroform." This remarkable case occurred in 1849.

I may further state that Sir William Fergusson, Mr. Erichsen, and many other eminent surgeons, have expressed to me the opinion that complete pressure under chloroform leads to rapid cure by coagulation; and the late Mr. Charles Moore was a most enthusiastic supporter of the same view.

CHAPTER V.

Concluding Remarks.

As I am not professing to write a complete history of the rise and progress of the rapid cure of aneurism by pressure, I do not enter into the many interesting steps by which the minds of several eminent men were led to foreshadow the possibility of its introduction. Were I to do this I should have to revert to the late Professor Porter's suggestions and to Banon's case as very early indications of what was to come; and, later than these, I should have to speak of the work done by Porter and O'Ferrall and many other Dublin surgeons, of Lee, Ernest Hart, Bryant, and Heath in this country, and possibly of authorities in France and elsewhere. I write, however, as having been the first to put the treatment within the pale of accepted practice by introducing chloroform as an essential part of the treatment. Before this was done, the possibility of completely arresting the current in an aneurism was a matter of great doubt and difficulty, whereas now it is a matter of certainty and *not* difficult. I would add that, as yet, the advocates of the new method do not seem to have grasped the idea that in all aneurisms, of and below the aorta, pressure ought to be made on that

vessel, both because of the ease with which it is commanded, and because by pressing it you ensure a complete arrest of current in any of the aneurisms of the lower part of the body. It is for this reason that I fail to see the value attached by Dublin surgeons to Dr. O'Ferrall's suggestion of applying distal pressure. The value of his suggestion is great if the circulation be not completely stopped in all vessels which by anastomosis may throw blood into the aneurism; but this seems to me to be impossible where the aorta itself is fully commanded. The application of distal pressure is therefore unnecessary where the proximal pressure can be applied above the division of the aorta.

The foregoing case, together with the experience derived from the cases treated since the year 1864, and the inferences that can be legitimately drawn therefrom, have, I trust, been sufficient to establish the following points:—

1st. That it is possible to cure aneurisms by pressure more rapidly than has hitherto been supposed.

2nd. That this is to be done by completely arresting the flow of blood through the aneurism for a period of time which is only a fractional part of that required by the old method.

3rd. That chloroform is a necessary adjunct to the treatment in most cases.

I will conclude my remarks by a reference to the following propositions, which contain a statement of the basis on which the new method rests.

First Proposition.—The introduction of chloroform in the treatment by compression in no way interferes with the coagulation of blood or the deposition of fibrin; by *it* this treatment is applicable to arteries in the most sensitive and delicate situations, and it may be used for several hours continuously without danger to the patient. Its use will add greatly to the ease with which the treatment can be carried out, and therefore to its efficacy. It ought to be used in treating aneurism in *other* parts, as well as those in the abdomen.

Second Proposition.—From the cases now on record it is evident that consolidation of fibrin alone does not cure the aneurism; *this is due mainly to coagulation of blood.* This is proved, 1st, by the clear indications in several cases that the tumour ceases to beat and becomes solid within the space of *one hour* (see report of the cases) when once the conditions of coagulation are established; 2ndly, by the rapid disappearance of the tumour after it becomes solid. In the Newcastle cases the diminution in the size of the tumours was a surprise to us all. The rapid formation and removal of the clot argues powerfully *for* its sanguineous and *against* its fibrinous nature.

Third Proposition.—It is now established that the cure of an aneurism by pressure need not be a tedious process lasting many hours or extending over many days. The question may be stated thus:—Are we to have cure by coagulation of blood in *five hours* by completely arresting the current through the aneurism, or cure by lami-

nation of fibrin in *twenty-five days* by frequently and imperfectly arresting the circulation? The answer of course depends upon the safety and efficacy of the *former* process. That it is as *safe* as the other I have no doubt, for in none of these cases has suppuration of the sac after treatment, or injury to the patient while being compressed, resulted. All that we can say with regard to the permanent efficacy of the treatment is, *that it has not failed in any one instance.*

Fourth Proposition.—The experience derived from the treatment of the cases of iliac confirms an opinion I had previously formed, that in all cases of aneurism of the larger arteries springing from the abdominal aorta it is best and perfectly safe to press on the aorta itself. To command the channel of the aorta and to arrest its pulsation seems to me after numerous trials to be a most feasible operation.

Fifth Proposition.—I would compare the process of *coagulation* in an aneurism to those instances of crystallisation which occur when the slightest disturbance of the conditions of solution determines the immediate solidification of dissolved matter, where a sudden movement, a rough surface, &c., are enough to induce the formation of crystals—in like manner, the completely arrested current seems to assume the solid form *at once and decidedly* as soon as the conditions of the solution of fibrin are disturbed. We are still uncertain as to the exact nature of those conditions, but we can disturb them in an aneurism by the rapid compression treatment.



LONDON :
PARDON AND SON, PRINTERS,
PATERNOSTER ROW.

2

