

**A manual of dissections of the human body : for the use of students and more particularly for those preparing for the higher examinations in anatomy / by R.E. Carrington.**

**Contributors**

Carrington, R. E.

**Publication/Creation**

London : George Bell, 1881.

**Persistent URL**

<https://wellcomecollection.org/works/d8b29225>


**License and attribution**

This work has been identified as being free of known restrictions under copyright law, including all related and neighbouring rights and is being made available under the Creative Commons, Public Domain Mark.

You can copy, modify, distribute and perform the work, even for commercial purposes, without asking permission.



Wellcome Collection  
183 Euston Road  
London NW1 2BE UK  
T +44 (0)20 7611 8722  
E [library@wellcomecollection.org](mailto:library@wellcomecollection.org)  
<https://wellcomecollection.org>





~~Robert H. Wren~~  
~~Amherst College~~



22101420280

~~Robert E. Lord~~

~~Owens College .~~


3/9

0/11

4



A MANUAL OF DISSECTIONS OF THE  
HUMAN BODY.



*W. R. Cooper*  
*owns copy.*  
*1889.*

A MANUAL OF

# DISSECTIONS OF THE HUMAN BODY,

FOR THE

USE OF STUDENTS, AND MORE PARTICULARLY

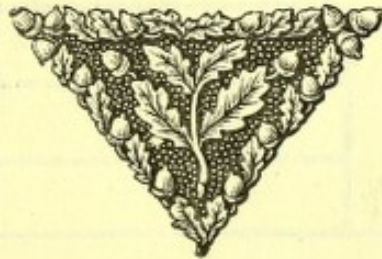FOR THOSE PREPARING FOR THE HIGHER

EXAMINATIONS IN ANATOMY.

BY

R. E. CARRINGTON, M.D. LOND., M.R.C.P.,

SENIOR DEMONSTRATOR OF ANATOMY, GUY'S HOSPITAL.



LONDON:

GEORGE BELL AND SONS, YORK STREET,  
COVENT GARDEN.

1881.





WELLCOME INSTITUTE LIBRARY	
Coll.	weIMOmec
Call	
No.	Q54
	1881
	C31m

M15163

## PREFACE.

It has not been found possible in the arrangement of these dissections to classify them under the usual headings of Head and Neck, Upper extremity, Abdomen, and Lower extremity, because many of them would have been included under two or even more of these: in fact, they have often been specially planned with this object, so as to include the border lines of parts which, as they belong strictly neither to one nor the other dissector, are often neglected entirely. Nevertheless, this order has been followed for the most part, and in cases where a dissection involves partly one part and partly another, it has as far as possible been used as an intermediate link between the two. It is taken for granted that the student should have carefully dissected the whole body through before he turns his attention to special dissections. The steps outside the usual routine that are necessary to be taken to expose different structures, form a special feature of the higher anatomical examinations, and, indeed, are not absent from the more ordinary ones, and my experience of the past four years has shown me that students are often non-plussed as to the mode in which questions of this sort should be answered: it is to meet this difficulty, and also to assist those who may wish to carry their anatomical



knowledge further than the usual dissecting-room course would allow them, that this work has been published.

I am thoroughly convinced that it is well nigh impossible to accurately answer many of the questions that are asked in the higher examinations, except they have previously been worked out practically, and am strongly of opinion that special arrangements should be made to meet the requirements of candidates for these tests. If a subject were allotted to four instead of eight dissectors, I think, by mutual arrangement and consultation between themselves, they might each of them perform many special dissections, and might collectively work out many others.

The present manual is the result of special work during the conduct for the past two years of the anatomical class for the first M.B. examination of the University of London. I have been greatly assisted by Messrs. W. A. Lane and J. A. P. Price, Assistant Demonstrators at Guy's Hospital, and to them I desire to express my great obligations for thorough and painstaking work in the prosecution for this class.

The principle that has been followed throughout, has been to perform the dissection with the *least possible destruction of surrounding parts compatible with the full exposure of the structure under consideration*. The skin incisions have been carefully planned with this object, and I may incidentally remark that this is often one of the most difficult steps of the dissection, and that further, owing to the retraction of the divided skin, the surface exposed will always be greater than that strictly included between the lines of incision. It will frequently happen that there are several preliminary steps to be taken before the actual point of the question is reached. Thus in a dissection to expose the Thoracic duct, the opening of the



Thoracic and Abdominal cavities may fairly be considered as not an essential part of the dissection, whilst in one to display the Internal Mammary Artery, a detailed account of the Thoracic and Abdominal parietes is evidently required. Students are often puzzled to know whether they are to consider such cavities as opened, or whether they are to write down every separate structure they divide in the course of the dissection. It is difficult to give an absolute answer, but in the absence of specific information from the examiner himself, much will depend upon the amount of time allowed them to write their paper. It may, however, be taken for granted that nothing but naked-eye anatomy is required.

The plan that has been followed in arranging and writing out the various dissections is this:—

1. The position of the body, or part, is indicated.
2. The requisite skin incisions have then been stated carefully.
3. The dissection has been divided into stages numbered I., II., III., &c., and the different steps of each stage have been indicated by the small letters *a, b, c, d, &c.*
4. After each stage short accounts numbered 1, 2, 3, 4, &c., of the structures exposed have been given, following as far as possible some definite direction, as from above downwards, or from side to side, and taking them in the order of bones, muscles, arteries, veins, nerves, &c. The student should avoid giving a bare list: he is not required to *describe* each structure that may be exposed, but he should indicate the *relative positions* of parts succinctly and distinctly.
5. When a structure to be exposed lies in two or

more distinct regions each has, in some cases, been taken separately and indicated by the capitals A, B, C.

I am painfully aware of the imperfections of this work, but trust that as each dissection has been actually performed, want of accuracy will not be one of them. No doubt the absence of plates is a striking deficiency, but in the presence of the beautiful atlases of Professor Ellis, and more recently that of Mr. Godlee, I am strongly of opinion that these will not be found necessary. My object, however, has been mainly to supply a little manual within the reach of all, which may be a guide to actual dissecting-room work.

ST. THOMAS'S STREET, S.E.



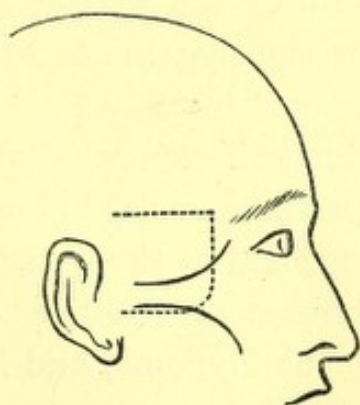
## A MANUAL OF DISSECTIONS.

### A DISSECTION TO EXPOSE THE STRUCTURES THAT ARE SEEN ON THE REMOVAL OF THE OUTER WALL OF THE ORBIT.

POSITION.—The body lying upon its back, and the face rotated to the opposite side.

#### I. SKIN INCISIONS.

1. From the external angular process of the Frontal bone horizontally backwards an inch above the Zygoma, and parallel with it to a point one inch above its root.



No., 1.

2. From just outside the outer canthus, obliquely downwards and backwards, over the Malar process, to a quarter of an inch below the lower



border of the Zygoma, and horizontally backwards to its root.

3. A vertical incision joining the anterior extremities of Nos. 1 and 2.

Reflect the flap backwards, and expose the superficial fascia; clear this away, and the deep fascia over the muscles, and expose—

1. The Zygoma at the lower part of the surface exposed.
2. The lateral prolongation of the aponeurosis of the Occipito-frontalis muscle running down to be attached to the preceding. On the removal of this, the Temporal fascia is displayed.
3. The outer part of the Orbicularis palpebrarum muscle at the outer canthus.
4. The upper fibres of the Masseter muscle attached to the lower border of the Zygoma.
5. The anterior part of the Attrahens aurem muscle above the Zygoma, at the posterior part of the dissection.
6. A small portion of the Parotid gland, covered by its fascia below the Zygoma at the posterior part.
7. Cutaneous arteries from—
  - a. The Anterior Temporal above the Zygoma.
  - b. The Transverse Facial below the Zygoma.
  - c. The Lachrymal at the outer canthus.
8. Temporal branches of the Facial nerve passing upwards over the Zygoma, and Malar branches running over the Malar process.
9. The Temporal branch of the Temporo-malar nerve becoming cutaneous a finger's breadth above the Zygoma, and its communication with a Temporal branch of the Facial nerve.

Subcutan<sup>s</sup>  
Bone  
Fascia

muscle

gland

arty.

nerve

main says nearly  
an inch.



- Nerves* {
10. The **Malar branch of the Temporo-malar nerve**, cutaneous over the Malar process, and communicating with a **Malar branch of the Facial nerve**.
  11. A small twig of the **Lachrymal nerve** at the outer canthus.

## II.

- a. Remove the part of the **Attrahens aurem muscle** exposed.
- b. Raise the fibres of the **Orbicularis palpebrarum muscle** and turn it forwards, dissecting out more fully the **Malar branch of the Temporo-malar nerve**.
- c. Detach the **Masseter muscle** from the lower border of the **Zygomatic** and the **Malar processes**.
- d. Cut through the **Temporal fascia** from the upper border of the **Zygoma**. It will be found to consist of two layers, and between them will be found some fat, the **Temporal branch of the Temporo-malar nerve** behind the **Frontal process** of the **Malar bone**, and a small twig of the **Middle Temporal artery**.
- \* e. Saw through the **Zygoma** in front and behind and remove it, and clear away the fat beneath it in front of the **Temporal muscle**, extending down upon the **Superior Maxilla**.

There will now come into view—

1. The part of the **Malar bone** previously covered by the **Orbicularis muscle**.
2. The tendon of the **Temporal muscle** attached to the **Coronoid process** of the lower jaw.
3. The **Masseteric artery, vein, and nerve** behind the **Coronoid process**, passing out through the Sigmoid notch, seen entering the muscle or divided.

\* From Temporo-malar angle to ant. end of masseteric attachment.



III. Remove completely the **Temporal** muscle from its origin and insertion as far as it is displayed. The **Middle Temporal** artery will be taken away with it, and there will then be exposed—

1. The posterior surface of the **Orbital** process of the **Malar** bone, the outer surface of the **Ala** major of the **Sphenoid** bone as low down as the **Pterygoid** ridge, the anterior part of the **Squamous** portion of the **Temporal** bone, and a small portion of the outer surface of the **Superior Maxilla**.
2. The upper head of the **External Pterygoid** muscle.
3. The end of the second portion of the **Internal Maxillary** artery, and the **Alveolar** branch of the third portion upon the **Superior Maxilla**.
4. Twigs of the **Lachrymal** artery, passing through foramina in the **Malar** bone anastomosing with the **Deep Temporal**.
5. The anterior and posterior **Deep Temporal** arteries at the front and back parts of the **Temporal** fossa, and their veins running into
6. A portion of the **Pterygoid** plexus of veins upon the **External Pterygoid** muscle, joining in front with the **Alveolar** plexus.
7. The anterior and posterior **Deep Temporal** nerves with the corresponding arteries.
8. Oftentimes a small twig of the **Masseteric** nerve to the **Temporal** muscle behind the posterior **Deep Temporal** nerve.
9. The two **Posterior Dental** branches of the second division of the **Fifth** nerve lying upon the **Superior Maxilla**.
10. The temporal branch of the **Temporo-malar** nerve is again seen piercing the Malar bone.



## IV.

- a. Draw forwards the **Orbicularis palpebrarum** muscle, cut through the **External Tarsal** ligament, and, with the handle of the scalpel, separate the **Dura mater** of the Orbit from the outer wall, to prevent injuring it in the removal of the bone.
- b. Chip away with the chisel the Malar bone at the exit of the **Malar** branch of the **Temporo-malar** nerve, and follow this nerve through the bone. Its division into **Temporal** and **Malar** branches may thus be traced, and the nerve itself followed, into the inferior and outer angle of the Orbit. *vide*
- c. Now proceed to remove the portions of bone forming the outer wall of the Orbit with the chisel. This will be done piecemeal, but the following may be taken as the requisite incisions:—
  1. A horizontal one at the upper part of the exposed surface, commencing in front at the suture between the **External Angular** process and the **Malar** bone, and ending behind at the articulation between the **Squamous** part of the **Temporal** bone and the **Ala major** of the **Sphenoid** bone. This is carried onwards until it reaches the **Sphenoidal fissure** behind.
  2. A second horizontal one at the lower part of the dissection, commencing in front at the anterior part of the **Malar** process, passing through it, running parallel with No. 1, and ending behind at a point corresponding to the upper. This opens up the **Spheno-maxillary fissure**.
  3. A vertical incision joining the hinder extremities of Nos. 1 and 2.The **middle fossa** of the skull is opened up slightly.



There will now be exposed—

1. The **Dura mater** of the Orbit.
2. The **Infra-orbital** branch of the third part of the **Internal Maxillary** artery entering the **Infra-orbital** foramen, and the commencement of the **Descending Palatine** branches.
3. The second division of the **Fifth** nerve with the **Infra-orbital** artery, entering the same foramen, and the following branches ; the whole of the **Temporo-malar** and the upper portions of the two **Posterior Dental**.
4. Two or three twigs from **Meckel's** ganglion to the periosteum of the Orbit. Their source, however, is not seen.

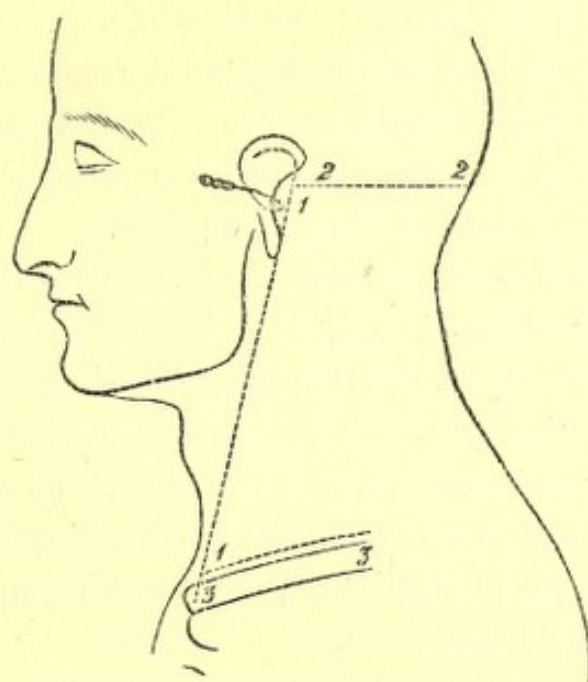
V. Remove the periosteum of the Orbit as far back as the **Sphenoidal** fissure ; here it will be seen to be continuous with the **Dura mater** of the skull. Clear away fat.

There will now be exposed—

1. The **Eye-ball**.
2. The **External** and **Inferior Recti** muscles outside and below the eye-ball respectively, and the **Inferior Oblique** muscle passing below the **Inferior**, and internal to the **External Rectus** muscle.
3. The **Lachrymal** gland at the upper and outer part of the orbit.
4. The **Lachrymal** nerve and artery above, the nerve joining with the **Temporo-malar**.
5. The nerve from the **Third** to the **Inferior Oblique** muscle entering its posterior border.

## A DISSECTION TO EXPOSE THE VERTEBRAL ARTERY.

**POSITION.**—A block should be placed under the shoulders, the head allowed to hang supported by a smaller one, and the face rotated to the opposite side on which the dissection is to be made.



No. 2.

### I. SKIN INCISIONS.

1. From immediately in front of the Mastoid process to the Sterno-clavicular articulation.
2. Transversely from the upper end of No. 1 to the Occipital tuberosity.
3. Transversely from the lower end of No. 1 along the upper border of the Clavicle for the inner half.

Reflect the flap backwards and expose the superficial fascia containing—



1. The **Platysma myoides** muscle at the lower and front part.
2. **Cutaneous arteries** from:—The **Posterior Auricular** behind the ear. The **Occipital** upon the Occiput. The **Ascending Cervical** at the lower part through the **Sterno-mastoid** muscle. At the upper part of the same muscle from the **Sterno-mastoid** branch of the **Occipital** or **External Carotid**. From the **Superficial Cervical** over the **Trapezius** muscle. From the **Suprascapular** over the **Clavicle**.
3. The upper part of the **External Jugular vein**.
4. The **Great Auricular** nerve at its distribution over the **Mastoid** process, and the commencement of the branches to the **Pinna** and face.
5. The **Small Occipital** nerve perforating the deep fascia near the skull.
6. The **Great Occipital** nerve perforating the fascia lata about half an inch from the anterior border of the **Trapezius** muscle, close to the Occiput.
7. The **Third Occipital** nerve perforating behind the distribution of the Great, and running up to the **Occipital protuberance**.
8. **Cutaneous filaments** from the **third and fourth Cervical** nerves ramifying over the lower part of the **Trapezius** muscle.
9. **Filaments** of the **Superficial Cervical** nerve perforating the **Platysma** muscle over the centre of the **Sterno-mastoid** muscle.

II. Remove the **Platysma** muscle, dissecting out at the same time the **Sternal** and **Clavicular** branches of the **third and fourth Cervical** nerves. The **External Jugular Vein** will now be displayed as far as the point of its perforation of the deep fascia at the lower part of the posterior triangle.



III. Clean away the **fascia lata**, preserving and dissecting further the preceding vessels and nerves to the extent that this is possible without removal of muscles. There will now be exposed—

1. The **Sterno-mastoid** muscle in front.
2. The anterior portion of the **Trapezius** muscle behind.
3. In the angular interval between the preceding muscle at the skull, either a dense fascia or the **Complexus** muscle.
4. The **Splenius capitis** muscle, and the slip of the **Splenius colli** to the transverse process of the Atlas. This muscle runs downwards and backwards highest of those forming the floor of the posterior triangle.
5. The attachments of the **Levator anguli scapulæ** muscle to the upper three or four Cervical transverse processes.
6. The **Scalenus medius** muscle immediately below the preceding, and behind the Sterno-mastoid muscle.
7. The posterior edge of the **Scalenus anticus** muscle, in the case of a narrow Sterno-mastoid muscle.
8. The posterior belly of the **Omo-hyoid** muscle crossing the **Scalenus medius** obliquely at the lower part.
9. Branches of the **Superficial** and **Ascending Cervical** arteries in the upper part of the posterior triangular space.
10. The **Transverse Cervical** artery crossing from beneath the lower part of the Sterno-mastoid muscle and passing under the Omo-hyoid muscle.
11. The third part of the **Subclavian** artery turning over the first rib, and the **Posterior Scapular** artery when it is a branch of this part of the vessel.



12. The whole length of the **External Jugular vein** and its sinus joined below by the **Transverse Cervical**, **Suprascapular** and **Posterior Jugular** branches, and communicating over the **Clavicle** with the **Cephalic vein**, and over the **Sterno-mastoid muscle** with the **Anterior Jugular vein**
13. The **Posterior Auricular nerve**, artery, and vein behind the **Pinna**.
14. The **Great Auricular nerve** turning round the posterior border of the **Sterno-mastoid muscle** at its upper part and dividing into branches for the skin over the **Mastoid process**, **Pinna**, and the **Parotid gland**.
15. The **Small Occipital nerve** running up the posterior border of the **Sterno-mastoid muscle**.
16. The **Great Occipital nerve** now seen perforating the **Trapezius muscle** near its anterior border and ramifying over the **Occiput** accompanied by the **Occipital artery and vein**.
17. The **Third Occipital nerve** perforating the **Trapezius** internal to the preceding.
18. The **Superficial Cervical nerve** turning over the **Sterno-mastoid muscle**, and running transversely across beneath the **External Jugular vein**.
19. The superficial descending **Sternal** and **Clavicular** branches of the **Cervical plexus**.
20. The **Spinal-accessory nerve** crossing transversely from the upper third of the **Sterno-mastoid muscle** downwards and backwards to the **Trapezius muscle**.
21. A branch of the **Cervical plexus** from the third nerve to the **Levator anguli scapulæ muscle**.
22. Branches from the third and fourth **Cervical nerves** to the **Trapezius muscle**. They accompany the



Spinal-accessory nerve and communicate with it, and some perforate the Trapezius muscle and supply the skin over it. These have been mentioned with the superficial fascia.

23. The **Phrenic nerve** in case the **Scalenus anticus** muscle is exposed.
24. The **fifth, sixth, and seventh Cervical nerves** forming part of the **Brachial plexus**.
25. The nerve to the **Rhomboid** muscle perforating the outer border of the **Scalenus medius** muscle at the upper part.
26. The **Posterior Thoracic nerve** perforating the same muscle lower down, and running down behind the **Brachial plexus**.
27. The **Suprascapular nerve** arising from the cord formed by the junction of the fifth and sixth nerves, and crossing the space transversely a little above the **Clavicle**.
28. The nerve to the **Subclavius** muscle running down over the third part of the **Subclavian artery**.
29. The branch from the **Descendens noni** nerve to the posterior belly of the **Omo-hyoid** muscle, passing from beneath the **Sterno-mastoid** to the lower border of the muscle it supplies.
30. The **Glandulæ concatenatæ** along the posterior border of the **Sterno-mastoid** muscle, and a small piece of the **Parotid gland** immediately in front of the **Mastoid process**.

#### IV. Remove now—

- a. The **External Jugular vein** and its branches.
- b. The **Great Auricular**, the **Superficial Cervical**, the **Sternal and Clavicular**, the **Muscular to the Trapezius** and the **Spinal-accessory nerves**.



- c. Take away the posterior portion of the **Sternomastoid** muscle by cutting through the mastoid and clavicular attachments and removing the piece. The branches of the second nerve to the muscle will be cut through.
- d. Detach the **Trapezius** muscle from its occipital attachment, and hook it well back.
- e. Cut through the **Omo-hyoid** and **Splenius capitis** muscles, and remove the attachments to the transverse process of the **Atlas**, of the **Splenius colli**, **Levator anguli scapulæ**, and **Scalenus medius** muscles.

There will now be exposed—

- 1. The transverse process of the **Atlas**.
- 2. The posterior belly of the **Digastric** muscle running downwards and forwards from the deep surface of the **Mastoid** process.
- 3. The **Stylo-hyoid** muscle parallel with its anterior border.
- 4. The **Trachelo-mastoid** muscle at the upper part inserted into the outer surface of the **Mastoid** process.
- 5. The **Complexus** muscle, behind the immediately preceding muscle.
- 6. A small piece of the **Superior Oblique** muscle is seen running up from the transverse process of the **Atlas** between the **Trachelo-mastoid** and **Complexus** muscles.
- 7. The **Rectus capitis anticus major** muscle is seen in front arising and running upwards from the anterior tubercles of the transverse processes of the third, fourth, fifth, and sixth **Cervical** vertebræ.
- 8. The **Scalenus anticus** muscle is seen below the **Rectus** muscle inserted into the same points.



9. A further piece of the **Splenius colli** muscle is seen by the removal of the **Sterno-mastoid** muscle.
10. The **Longus colli** muscle is seen on the front of the vertebral column anterior to the **Rectus anticus major**, and **Scalenus anticus** muscles.
11. Above the **Manubrium** the outer margin of the **Sterno-hyoid** muscle is displayed.
12. The **Common Carotid** artery, its **Internal** and **External** branches, and the **Occipital** offset of the latter.
13. The first part of the **Subclavian** artery and the following branches :—**Thyroid** axis giving off **Transverse Cervical** and **Suprascapular** offsets, which run backwards over the **Scalenus anticus** muscle, and the **Inferior Thyroid** running upwards beneath the **Common Carotid**, having given off previously the **Ascending Cervical** branch which passes upwards in the interval between the **Scalenus anticus** and **Rectus anticus major** muscles, and sends numerous offsets to the posterior triangle. The commencement of the **Internal Mammary** branch of the first part of the **Subclavian**, but the **Vertebral** offset is not seen, as it lies under cover of its vein.
14. Branches of the **Princeps Cervicis** branch of the **Occipital** artery are seen superficial to the **Complexus** muscle.
15. The **Internal Jugular** vein parallel with and outside the **Common Carotid** artery, and its **Occipital** branch.
16. The part of the **Anterior Jugular** vein which lies below the **Sterno-mastoid** muscle.
17. The upper part of the **Subclavian** vein and its **Vertebral** branch.
18. The **Thoracic** and right lymphatic ducts opening into



the junction of the Internal Jugular and Subclavian veins.

19. The first four Cervical nerves and their loops. Only, however, the lower part of the first loop is seen. The communications of the loop of the Atlas with the Hypoglossal nerve, and the Superior Cervical ganglion. Branches of all the loops to the anterior Recti muscles.
20. The Hypoglossal nerve, the Descendens noni branch. The Communicans noni branches of the second and third Cervical nerves pass over or under the Internal Jugular vein, and join the Descendens in a loop. The branch from this loop to the Sternohyoid muscle is seen.
21. The lower two ganglia of the Sympathetic nerve, their connecting cord, and the lower part of the connection with the superior ganglion, the upper part of this trunk being overlapped by the Internal Jugular vein. The communication of the middle ganglion with the fifth and sixth nerves, and of the inferior with the seventh and eighth.
22. The Phrenic nerve, and its communication with the nerve to the Subclavius muscle, lying upon the Scalenus anticus muscle.
23. The fifth, sixth, seventh, and eighth Cervical nerves, and the cord from the first Dorsal nerve to the Brachial plexus.

V. Remove now—

- a. The upper part of the Complexus muscle with its nerves from the Suboccipital, and Great Occipital, and small arteries from the Vertebral entering its deep surface, and from the Princeps Cervicis overlying it.



- b.* Detach the posterior belly of the **Digastric** muscle from its origin and turn it forwards, its nerve from the **Facial** will be divided.
- c.* Cut through the origin of the **Trachelo-mastoid** muscle, its nerve from the **Great Occipital** will be cut.
- d.* Detach the **Scalenus anticus** muscle from its origin and turn it back, the following structures will be cut through with it:—The **Phrenic** nerve and its communication with the **Subclavian** nerve. The **Transverse Cervical**, the **Suprascapular**, and **Ascending Cervical** arteries.
- e.* Divide the **Internal Jugular** vein above and below, and remove the intermediate piece.
- f.* Remove the **Thoracic duct** which crosses superficial to the **Vertebral** artery and vein.

There will now be exposed—

1. The **Occipital** bone. The **Mastoid** process of the **Temporal** bone, and the transverse processes of the **Cervical** vertebræ. The posterior arch of the **Atlas** is seen in the floor of
2. The **Suboccipital** triangle bounded internally by the **Rectus capitis anticus major**, below by the **Inferior Oblique**, and above by the **Superior Oblique** muscles.
3. The **Rectus capitis lateralis** muscle is seen running up from the transverse process of the **Atlas**, and the **Intertransverse** muscles and ligaments between the transverse processes.
4. The **Longus colli** muscle is seen more fully in front of the vertebræ.
5. The whole of the **Subclavian** artery is displayed below. Its **Vertebral** branch overlapped by the vein,



and surrounded by branches of the inferior Cervical ganglion, is seen passing from the first part of the Subclavian artery to the foramen in the sixth Cervical transverse process; and is again exposed in its upper part above, lying upon the posterior arch of the Atlas in the floor of the Suboccipital triangle.

6. A further part of the Occipital artery is seen above, and superficial to the same triangle a general anastomosis between the **Princeps** and **Profunda Cervicis** arteries, and other twigs from the Vertebral. Muscular branches, and the occasional Mastoid branch of the Occipital may be seen.
7. The radicles of the Vertebral vein are exposed overlying the Suboccipital triangle.

The following are also exposed—

1. The Suboccipital nerve between the Vertebral artery and the posterior arch of the Atlas giving branches to both the Oblique and posterior Recti muscles.
2. The Great Occipital nerve (the internal branch of the posterior primary division of the second) turning round the lower border of the Obliquus inferior muscle. The anterior primary branch of the second nerve upon the transverse process of the Axis external to the Vertebral artery.
3. A further portion of the Hypoglossal nerve closely united with the Vagus.
4. The Vagus nerve.
5. The Spinal-accessory nerve.
6. The Superior Cervical ganglion.
7. The loop of the Atlas and its communications with the Hypoglossal and Vagus nerves and the superior ganglion of the Sympathetic nerve.



## VI.

- a. Cut away the **Superior Oblique** muscle entirely, and detach the **Inferior Oblique** muscle from the transverse process of the **Atlas** and turn it down.
- b. Remove the **Rectus lateralis**, the **Recti antici major** and **minor** muscles, and detach the **Longus colli** muscle from the third, fourth, fifth, and sixth transverse processes.
- c. Chip away with the chisel the anterior tubercles of the **Cervical** transverse processes and small portions of the bone behind, leaving the posterior tubercles; in this way the vertebral foramina will be opened up.
- d. Remove with the chisel and small saw a piece of the **Occipital** bone by the following incisions:—
  1. From the **Occipital** tuberosity vertically to the foramen magnum, behind.
  2. From the **Occipital** tuberosity transversely to the articulation of the **Mastoid** portion of the **Temporal** bone with the **Occipital**.
  3. Vertically down from the anterior end of No. 2, through the middle of the **Occipital Condyle**, to the foramen magnum.
- e. Divide the **Capsular**, **Posterior Occipito-atloid** and **Check** ligaments of the same side, and the first process of the **Denticulate** ligament.
- f. Take away a small piece of the lower part of the lateral lobe of the **Cerebellum**.
- g. Remove the **Vertebral vein**, which conceals the artery both below and in the foramina of the transverse processes.

The **Vertebral artery** is now exposed in its whole course,



with its **Anterior and Posterior Spinal, Meningeal, and the commencement of the Posterior inferior Cerebellar branches.**

It is seen lying in the foramina in the transverse processes of the Cervical vertebræ surrounded by branches of the **Sympathetic nerve** derived from the **Inferior Cervical ganglion**, and having the **Anterior primary branches of the Cervical nerves** behind it, except the first, which is internal, and the second, which is external to it. Within the skull the eighth and ninth nerves pass over it, and the **Spinal-accessory** is separated from it by the first process of the **Ligamentum Denticulatum.**

### A DISSECTION TO EXPOSE THE OTIC GANGLION AND THE CARTILAGINOUS PORTION OF THE EUSTACHIAN TUBE.

**POSITION.**—The body lying upon the back, and the face rotated to the opposite side.

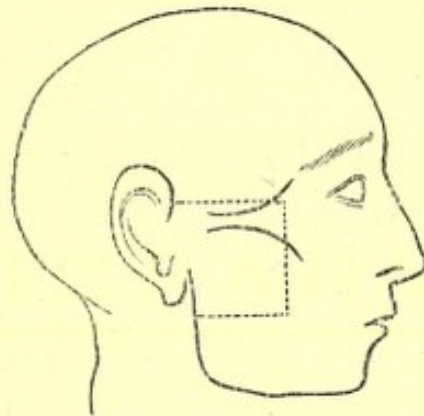
#### I. SKIN INCISIONS.

1. Along the upper margin of the Zygoma, from the anterior extremity of the origin of the Masseter muscle to the posterior part of the Condyle of the jaw.
2. Vertically along the anterior margin of the Masseter muscle to a point midway between the origin and the lower margin of insertion.
3. From the lower end of No. 2 transversely backwards to the posterior margin of the Ramus of the jaw.

Reflect the flap backwards, and expose the superficial fascia.

## II. Clear this away and expose—

1. The Zygoma.
2. The Temporal fascia just at its attachment to the Zygoma.
3. The Parotid fascia, that covering the Masseter muscle, and a small piece of the Buccal fascia in front.
4. The Temporal, Malar, and Infraorbital branches of the Facial nerve emerging from the Parotid gland.
5. The Transverse Facial artery and vein parallel with and below the Zygoma.



No. 3.

6. The duct of the Parotid Gland below the artery, with branches of the nerve above and below it.

## III. Remove the preceding structures and expose—

1. A portion of the neck of the jaw, the Capsular and the External lateral ligaments of the articulation.
2. The Masseter muscle running downwards and backwards from the Zygoma.
3. A small piece of the Buccinator muscle at the anterior margin of the preceding.
4. Emerging from the front border of the Masseter, the Buccal branch of the fifth nerve.
5. The Buccal branch of the Internal Maxillary artery accompanying it.



6. The **Anterior Internal Maxillary vein** also issuing from beneath the **Masseter muscle**.
7. The **Parotid gland** upon the **Masseter muscle**.

## IV.

- a. Divide both layers of the **Temporal fascia** at their attachment to the **Zygoma**.
- b. Remove the anterior part of the **Parotid gland**, the **Socia parotidis**, and the included part of the **Facial nerve**.
- c. Remove the **Masseter muscle** within the limits of the skin incision. In doing this its nerve from the third division of the **Fifth**, with its artery from the **Internal Maxillary**, and its vein to the **Pterygoid plexus** will be divided.
- d. Saw through the **Zygoma** in front and behind, and remove the included piece of bone.

The following structures are now exposed—

1. The upper half of the **Ramus**, and the **Coronoid process** of the jaw, a portion of the upper **Alveolus**, and the tuberosity of the **Superior Maxilla**.
2. The **Posterior Dental nerve and artery**, and the **Alveolar plexus of veins** lying upon the **Superior Maxilla**.
3. Part of the fleshy fibres and the insertion of the **Temporal muscle** into the **Coronoid process**.
4. The **Buccal nerve, artery, and vein** in front of the **Temporal tendon**.
5. The divided end of the **Masseteric nerve, artery, and vein** behind the tendon emerging from the **Sigmoid notch**.
6. The **Auriculo-temporal nerve** at the posterior part, running vertically upwards.
7. The **Temporal artery and vein** with the preceding.



## V.

- a. Divide the jaw through its neck, and again transversely across the Ramus halfway down.
- b. Cut through the Temporal muscle parallel with the upper skin incision.
- c. Remove the piece of bone with the muscle attached. Branches of the Buccal nerve and occasionally others from the Masseteric nerve to the Temporal muscle will be divided, and the Middle Temporal artery removed in its substance.

There will now be exposed—

1. The External Pterygoid muscle lying transversely.
2. The Internal lateral ligament passing vertically down beneath the Ramus.
3. The Internal Maxillary artery,<sup>1</sup> at first crossing the ligament, then lying upon the muscle, and passing between its two heads in front. Whilst the artery is lying upon the External Pterygoid muscle, it is seen giving off the anterior and posterior Deep Temporal, the Masseteric, Buccal, and Pterygoid branches; and whilst upon the ligament the Inferior Dental offset.
4. Lying upon the muscle the superficial part of the Pterygoid plexus of veins, joining in front with the Alveolar, receiving branches corresponding to those of the artery, and forming behind the Internal Maxillary vein which joins the Temporal.
5. Issuing above the upper border of the muscle, the anterior and posterior Deep Temporal nerves. Passing between the two heads, the Buccal nerve and the anterior part of the Internal Maxillary artery;

<sup>1</sup> When it occupies the normal position superficial to the External Pterygoid Muscle, otherwise it is beneath it.



and emerging from the lower border the Dental and Gustatory nerves, the latter being anterior. The Buccal nerve is frequently seen to join the anterior Deep Temporal, and the posterior Deep Temporal may be derived from the Masseteric nerve.

## VI.

- a. Divide the Internal Maxillary artery in front and behind, cut through its branches, and remove it.
- b. Disarticulate the jaw. Remove the External Pterygoid muscle from its origin, and take it away; dividing at the same time the Buccal nerve.
- c. Divide carefully with the chisel the External Pterygoid plate and remove it, cutting the fibres of origin of the Internal Pterygoid muscle from its deep surface.

There will now be exposed—

1. The Internal Pterygoid muscle passing obliquely downwards and backwards.
2. The ascending branches of the first part of the Internal Maxillary artery, before hidden by the jaw; viz., Middle Meningeal, running up to the Foramen Spinosum, the Small Meningeal, often a branch of the preceding to the Foramen Ovale, the Tympanic branch backwards to the Glasserian fissure.
3. The deep part of the Pterygoid plexus of veins.
4. The Third division of the Fifth nerve issuing from the Foramen Ovale and dividing into an *anterior or motor part* from which the anterior and posterior Temporal, the divided Masseteric and Buccal nerves, and the branch to the External Pterygoid muscle may be traced; and a *posterior or motor-sensory part* from which the Auriculo-temporal with its two roots embracing the Middle Meningeal artery, and



the Dental and Gustatory branches may be followed. A communication between the Auriculo-temporal and the Facial nerves may be seen.

5. The Chorda Tympani nerve issuing from the canal of Huguier and joining the Gustatory nerve.

VII. Divide the Internal lateral ligament. Cut through the Dental and Gustatory nerves, and reflect them carefully upwards. There will now be seen—

1. The nerve to the Internal Pterygoid entering the posterior border of the muscle.
2. The Otic ganglion lying upon the muscle, closely connected with its nerve.
3. The Tensor palati muscle lying beneath it.
4. The branch of the Otic Ganglion to the Tensor palati, and that to the Tensor tympani muscle passing backwards.
5. The Lesser Petrosal nerve coming through the spine of the Sphenoid, and the communication with the Sympathetic nerve on the Middle Meningeal artery may be traced to the ganglion.

VIII. Divide—

- a. The Internal Pterygoid muscle, at its attachment to the Ramus, and remove it. Its nerve will be cut through.
- b. The Great and Small Meningeal arteries, and the Pterygoid veins, and clear them away.
- c. The Third division of the Fifth Nerve, and remove it entirely. The Chorda Tympani nerve will be destroyed.
- d. Cut through the Tensor palati muscle from its origin, and at the point where it turns round the Hamular process, and take it away.

The outer surface of the cartilaginous portion of the



Eustachian tube is now fully exposed, from the retiring angle between the Squamous and Petrous portions of the Temporal bone, to its attachment to the Internal Pterygoid plate.

The following structures are also seen—

1. The Levator palati muscle arising from its lower membranous part, and passing over
2. The arched upper border of the Superior Constrictor, which muscle arises from the lower third of the Internal Pterygoid plate.
3. Lying upon the preceding the Ascending Pharyngeal artery, dividing into the following branches:—one following the tendon of the Tensor palati muscle, one passing over the upper border of the Superior Constrictor muscle, another to the Middle Lacerated foramen, and sometimes one to the Anterior Condylloid.

### A DISSECTION TO EXPOSE THE HYPOGLOSSAL NERVE IN THE EXTRA-CRANIAL PART OF ITS COURSE.

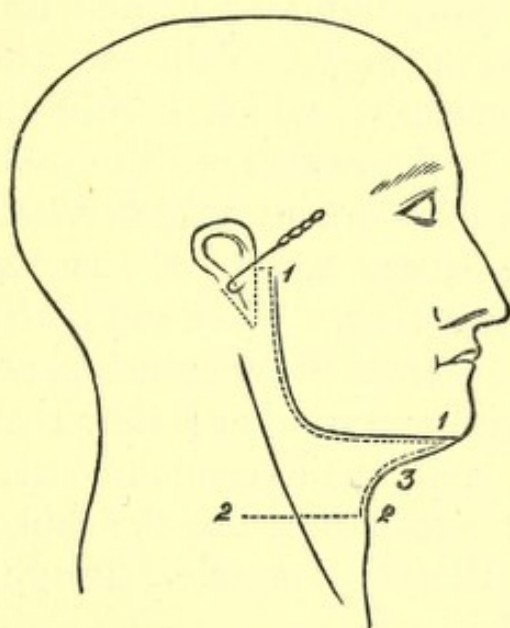
POSITION.—The body lying upon its back, the face rotated to the opposite side to that upon which the dissection is to be made, the jaw pulled well upwards, so as to extend the head, and the Hyoid bone drawn downwards by hooks.

#### I. SKIN INCISIONS.

1. From the middle line in front along the base of the jaw, and the posterior border of the Ramus as high as the Zygoma, then backwards, winding round

the attachment of the Pinna, to the Mastoid process.

2. Transversely from the middle line opposite the Hyoid bone, outwards to a point vertically below the hinder end of No. 1.



No. 4.

3. Join the anterior ends of Nos. 1 and 2 by a vertical incision along the median line.

Reflect the flap backwards, and there will be exposed the superficial fascia, containing—

1. Twigs of the Posterior Auricular artery behind the Pinna.
2. An Anterior Auricular artery to the front of the Pinna.
3. Cutaneous offsets of the Submental branch of the Facial artery below the jaw.
4. The Great Auricular nerve crossing the Sternomastoid muscle obliquely towards the Pinna, and dividing into Mastoid, Auricular, and Facial branches.



5. Cutaneous twigs of the upper branch of the Superficial Cervical nerve beneath the jaw.

## II.

- a. Remove the superficial fascia, and expose the *Platysma myoides* muscle running up to the base of the jaw, from the middle line nearly as far back as the angle. Take this away, and expose the *fascia lata*, which should then be cleaned away. In the course of this dissection, the upper branch of the Superficial Cervical nerve, and the Infra-maxillary branch of the Facial nerve will come into view. They will both be found to lie at first, *beneath* the deep fascia, and to communicate with one another; they then perforate the fascia, and again communicate, and then the former is distributed to the skin, and the latter to the *Platysma* muscle. They may now be removed.

When this is done, the Parotid and Submaxillary glands will come into view, with many other structures. It will be convenient to take the glands away at once, to avoid enumerating the same parts twice over.

- b. In removing the Parotid gland, the following structures will be found in its substance from the surface inwards:—

1. The commencement of the Facial nerve, and its division into Cervico-facial and Temporo-facial offsets. When the gland is completely removed the exit from the Stylo-mastoid foramen will be seen, and the Posterior Auricular, and the branches to the Digastric



and Stylo-hyoid muscles observed coming off close to the point of exit. The nerve should be removed.

2. The External Jugular vein and the commencement of its communications with the Internal Jugular and Facial veins. These and the Internal Maxillary vein should be divided, and the External Jugular removed.
3. The External Carotid artery, its Anterior and Posterior Auricular, Temporal, and Internal Maxillary branches, and the Transverse Facial offset of the Temporal. All these should be divided, and the trunks removed.

c. In removing the Submaxillary gland, the Facial vein will be found passing over it, and should be cut away; the Facial artery traversing it, or grooving its deep surface and giving off in its substance the Submental and Submaxillary offsets. It also should be divided above and below, and these branches taken away.

The following structures will now be exposed—

1. The body of the Hyoid bone and the greater Cornu, at the lower part of the dissection.
2. Part of the Sterno-Mastoid muscle behind, running up to the Mastoid process.
3. Both bellies and the tendon of the Digastric muscle. The posterior belly running downwards and forwards from beneath the Sterno-mastoid muscle, the tendon attached by areolar tissue to the body of the Hyoid bone, and the anterior belly running thence,



upwards and forwards, to the lower jaw close to the Symphysis.

4. The **Stylo-hyoid** muscle parallel with, and in front of the posterior belly of the **Digastric** muscle, seen splitting below for the tendon of the latter to be attached to the body of the **Hyoid** bone.
5. The **Mylo-hyoid** muscle, running up from the body of the **Hyoid** bone to the lower jaw.
6. The **Hyoglossus** muscle, seen in small part behind the **Mylo-hyoid**, and running up beneath it.
7. The under surface of the angle of the jaw can be seen, and the **Internal Pterygoid** muscle lying upon it.
8. The **External Carotid** artery, and the following branches: the commencement of the **Occipital** and **Lingual**: the origins of the divided **Temporal**, **Posterior Auricular**, and **Facial**. The last may be seen giving off the **Tonsillar** and **Inferior Palatine** offsets.
9. Owing to the retraction of the **Sterno-mastoid** muscle on the division of the process of fascia, extending from the angle of the jaw to its anterior border, the **Internal Carotid** artery, and the
10. **Internal Jugular** vein behind it.
11. The **Mylo-hyoid** branch of the **Inferior Dental** artery lying upon its muscle.
12. Radicles of the **Anterior Jugular** vein beneath the chin.
13. The **Vagus** nerve between the **Internal Carotid** artery and the **Internal Jugular** vein.
14. The branch of the **Inferior Dental** nerve, to the **Mylo-hyoid** and **Digastric** muscles. The small twig supplying the latter, however, being traceable before the removal of the **Submaxillary** gland.
15. The **Hypoglossal** nerve winding round the **Occipital**



artery, and then running transversely forwards beneath the posterior belly of the Digastric muscle. The Descendens noni branch upon the External Carotid artery and the commencement of the twig to the Thyro-hyoid muscle.

16. Lymphatic glands of the Submaxillary region.

### III.

- a. Cut through the Mylo-hyoid muscle at its attachment to the jaw and the median raphé, and turn it downwards.
- b. Remove the exposed portion of the Sterno-mastoid muscle.
- c. Remove the whole of the Digastric and the Stylo-hyoid muscles. The nerves to these and the preceding muscles will be divided.
- d. Divide the External Carotid artery below the point at which it is crossed by the Hypoglossal nerve. Cut through its Occipital offset, and the Inferior Palatine and Tonsillar branches of the Facial artery. Remove the upper portion and pull down the lower.

The Styloid process will now come into view, and the different structures attached to it.

1. The Stylo-glossus muscle, and Stylo-hyoid and Stylo-maxillary ligaments to the tip.
  2. The origin of the Stylo-hyoid muscle from the centre of the outer surface, and
  3. The Stylo-pharyngeus muscle from the inner side of the base.
- e. Cut the process through at the base with the forceps, and pull it down with the structures attached to it, having previously detached the Stylo-glossus muscle.



*f.* Divide the Internal Jugular vein above and below, and remove it.

The following structures will now come into view—

1. Above, the transverse process of the Atlas, and a small portion of the Rectus capitis lateralis muscle.
2. The Hyoglossus muscle running upwards from the body, and greater and lesser Cornua of the Hyoid bone to the side of the tongue.
3. The Stylo-glossus muscle at the upper border of the preceding muscle, divided posteriorly.
4. The Genio-hyoid muscle in front, running up from the body of the Hyoid bone to the lower jaw.
5. The Genio-hyo-glossus muscle in front of the Hyoglossus, and above the Genio-hyoid muscle.
6. The Middle Constrictor muscle, posteriorly.
7. Lying upon the Hyoglossus from above downwards :
  - a.* The Gustatory nerve, and the Submaxillary ganglion.
  - b.* The deep part of the Submaxillary gland, with Wharton's duct running upwards and forwards from it, and passing beneath the preceding nerve.
  - c.* The Hypoglossal nerve lower down. It may now be seen in the whole of its course. At its commencement it is closely conjoined with the Vagus nerve, it then descends vertically, next turns forward on the Hyoglossus, and is finally distributed to the Hyoglossus, Stylo-glossus, Genio-hyoid, and Genio-hyo-glossus muscles. The commencement of the Descendens noni and Thyro-hyoid branches may also be seen, as well as the loops of communication with



the Gustatory nerve, at the anterior border of the Hyoglossus muscle.

8. Issuing from the anterior border of the Hyoglossus muscle is the **Ranine branch of the Lingual artery**, with its vein.
9. Passing under the posterior border of the same muscle are from above downwards—
  - a. The **Glosso-pharyngeal nerve**, which may also be seen from the base of the skull downwards.
  - b. The **Stylo-hyoid ligament**, in the centre.
  - c. The **Lingual artery**, lowest of all.
10. The **Internal Carotid artery** will be seen running up to the base of the skull, deep down in the hollow behind the **Ramus of the jaw**.
11. The **Ascending Pharyngeal artery** in front of, but parallel with the Carotid.
12. The **Vagus nerve** is seen passing down behind the artery, and giving off the **Superior Laryngeal nerve** beneath it, and the **Pharyngeal branch** either over or under the vessel.
13. The **Spinal-accessory nerve** is seen with the Vagus. It will probably be cut below by the removal of part of the **Sterno-mastoid muscle**.
14. The **Superior Cervical ganglion of the Sympathetic nerve** will be displayed.
15. The loop of the anterior primary branches of the first and second Cervical nerves in front of the transverse process of the Atlas.
16. Communications between this loop and the Vagus, Hypoglossal, and Sympathetic nerves are traceable.

The preceding structures of the **Submaxillary region** may all be displayed if the preceding directions have been followed; a more satisfactory view, may, however, be



obtained if, after the reflection of the Mylo-hyoid muscle (Stage III.), the following steps be taken:—

- a. Sew the tip of the tongue to the Septum nasi.
- b. Divide the lower jaw and investing soft parts, in front near the Symphysis, and behind at the junction of the body and Ramus, and turn the included piece upwards.

In the anterior incision the following structures will be divided:—

1. Skin.
2. Superficial and deep fasciæ.
3. The Orbicularis oris muscle, and Inferior Coronary artery.
4. Depressor labii inferioris muscle.
5. Levator menti muscle.
6. The bone.
7. The mucous membrane of the mouth.

In the posterior incision—

1. Skin.
2. Superficial and deep fasciæ.
3. Facial vessels lying upon the bone.
4. Supra-maxillary, and Buccal branches of the Facial nerve.
5. Buccinator muscle.
6. Depressor anguli oris muscle.
7. Bone, and Inferior Dental nerve and artery in its substance.
8. The mucous membrane of the mouth, which should also be detached from the bone between the two incisions.

If the bone be turned up in this way, the Sublingual gland and the Sublingual branch of the Facial artery will in addition come into view, above the anterior border of the

Genio-hyo-glossus muscle. The Hypoglossal nerve may also be more fully traced into the substance of the tongue.

## A DISSECTION TO EXPOSE FULLY THE FIRST DORSAL NERVE.

POSITION.—The body is to be supported by blocks upon the opposite shoulder to that on which the dissection is to be made. The shoulder to be well pulled down.

### I. SKIN INCISIONS.

A semilunar flap of skin, following the course of the first rib, is to be removed by the following incisions:—

1. From the seventh Cervical spinous process, to the lower border of the inner end of the Clavicle at its articulation with the Sternum.
2. From the second Dorsal spinous process, to the upper border of the second Costal cartilage at the Sternum.
3. Vertical incisions joining the anterior and posterior ends of the preceding.

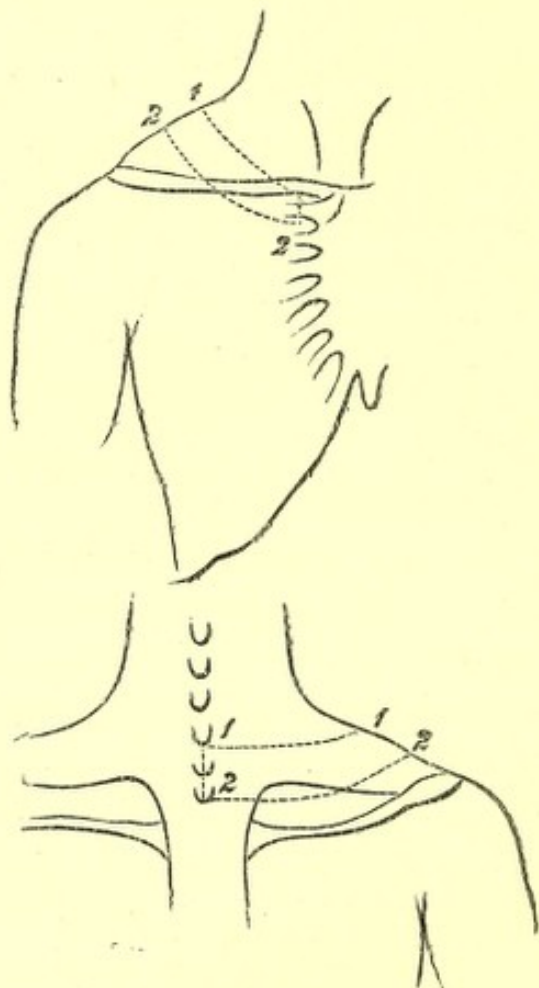
The flap thus removed will cross in front the middle third of the Clavicle.

There will now be exposed the superficial fascia, containing, passing from before backwards—

1. The *Platysma myoides* muscle over the Clavicle.
2. Arterial twigs over the Clavicle from the Suprascapular. In the body dissected a branch from the Acromio-thoracic artery ascended over the bone.
3. A communication over the Clavicle between the Cephalic and the External Jugular veins.



4. The descending cutaneous branches of the Cervical plexus. The **Supra-sternal** branch over the inner end, and the **Supra-clavicular** over the middle of the Clavicle. The upper part of the **Supra-acromial** branches.



No. 5.

5. The first **Anterior Cutaneous** nerve, artery, and vein.  
 6. The branch of communication from the **Supra-clavicular** to the second **Anterior Cutaneous** nerve. In this case it was with the first, and therefore the junction was seen.  
 7. By the side of the first **Dorsal spine**, the **internal branch** of the posterior primary division of the first

Dorsal nerve, with its corresponding artery and a radicle of the Dorsi-spinal veins.

II. Remove the preceding structures and the fascia lata, and expose—

1. The Sterno-mastoideus muscle passing down to the inner third of the Clavicle, only a small portion of the outer border being seen.
2. Below this the Pectoralis major muscle, corresponding to the inner half of the same bone.
3. Posteriorly, and also at the outer side of the front aspect, the Trapezius muscle.

III.

- a. Within the limits of the skin incisions divide and remove the Pectoralis major muscle in front, and with it, branches of the External Anterior Thoracic nerve.
- b. Take away the portion of the Trapezius muscle exposed in the dissection. With it will be divided—
  1. Branches of the Superficial Cervical artery and vein.
  2. The Posterior Jugular vein.
  3. Portions of the Spinal-accessory, and third and fourth Cervical nerves.

There will now be exposed, passing from before backwards—

1. A further portion of the inner end of the Clavicle.
2. Below this the fascia prolonged from the Pectoralis minor muscle, and the Costo-coracoid membrane and the structures perforating it, viz. :—

The Acromio-Thoracic artery.

The Cephalic vein.

The External Anterior Thoracic nerve.



Perhaps a small branch of the Superior Thoracic artery.

3. Above the Clavicle the third part of the Subclavian artery.
4. The Transverse Cervical branch of the first portion of the same artery is seen higher up, but the Supra-scapular offset is hidden by the Clavicle. Both these arteries have their veins with them.
5. Above the Subclavian artery are seen the cords of the Brachial plexus, and the following branches: The Supra-scapular, Posterior Thoracic, and the nerve to the Subclavius muscle.
6. Beneath the plexus and the Subclavian artery, the Scalenus medius and posticus muscles, the latter most external.
7. Still further back is seen the upper and inner angle of the Scapula, covered by the Supra-Spinatus muscle.
8. Ascending from the Scapula, and running upwards and forwards above the Brachial plexus, the posterior belly of the Omo-hyoid muscle.
9. The first digitation of the Serratus magnus muscle is seen, internal and posterior to this, above the upper border of the Scapula.
10. Still further back is the Levator anguli scapulæ muscle ascending from the angle.
11. Internal to it, and nearer the spine, the upper part of the Rhomboideus minor muscle.
12. The upper edge of the Serratus posticus superior muscle seen just above the Rhomboideus.
13. The Posterior Scapular artery, accompanied by its vein, is seen passing beneath the Levator anguli scapulæ muscle, having previously given a branch over the dorsum Scapulæ. Its continuity with the



Transverse Cervical artery beneath the Omo-hyoid muscle is traceable.

14. The nerve to the Rhomboid muscles lies between the Rhomboideus minor and Levator anguli scapulæ muscles, and may be found if they are separated from one another.

IV. The dissection should now be commenced behind, and carried forwards.

- a. Remove the exposed part of the Rhomboideus minor muscle. The Serratus posticus superior muscle is seen beneath it, and the Posterior Scapular artery and vein between the two.
- b. Remove the Levator anguli scapulæ muscle within the limits of the dissection. The nerve to the Rhomboidei muscles will be seen beneath it.
- c. Take away the exposed part of the Serratus posticus superior muscle, and remove at the same time the Posterior Scapular vessels, and the nerve to the Rhomboidei muscles.

There will now be exposed, passing from the spinous processes outwards—

1. The tubercle of the first, and a considerable portion of the second rib.
2. The Splenius muscle in part, most internally.
3. The Transversalis colli muscle in part.
4. The Cervicalis ascendens muscle in part, seen passing upwards.
5. The second Levator costæ muscle passing from the transverse process of the first Dorsal vertebra downwards and outwards to the second rib, the external<sup>1</sup> branch of the posterior primary division of

<sup>1</sup> In two dissections I have found this to be the case. Both branches may however, be internal to the Levator costæ muscle.



the first Dorsal nerve passing out external to it, and the internal division internally.

6. Still more externally the *Scalenus posticus* muscle.

Passing from below are—

7. The upper tendon of the *Musculus accessorius* into the first rib.

8. The highest tendon of the *Longissimus dorsi* muscle when attached to the first rib.

## V.

a. Remove the preceding muscles as far as they are exposed in the dissection. In detaching the *Transversalis colli* muscle the *Trachelo-mastoid* will be found beneath it, and should be taken away at the same time. The second *Levator costæ* muscle may be retained in order to follow out more fully the nerves in relation with it.

There will now be exposed—

A portion of the *Complexus* muscle along the median line.

b. Remove this and there will be seen—

The *Semispinalis* muscle.

c. Take away this and there will come into view—

1. The *Multifidus spinæ* muscle.

2. Lying upon it the internal branches of the posterior primary divisions of the eighth Cervical and first Dorsal nerves.

d. Clear away the *Multifidus spinæ* muscle, and there will be seen—

1. The first rib at its inner part, the transverse process of the first Dorsal vertebra, and part of the second rib.

2. The posterior *Costo-transverse* ligament, be-



tween the first Dorsal transverse process and its rib.

3. The posterior part of the **External Intercostal muscle**.
- e. Divide the first Dorsal transverse process at its root with the chisel. Cut through the first rib at its neck, and again external to its tubercle. Cut through the first anterior Costo-transverse ligament which runs downwards from the first Dorsal transverse process to the second rib. Remove the included portions of bone. The posterior and middle Costo-transverse ligaments of the first rib will be taken away at the same time. The **Superior Intercostal artery**, which lies upon the neck of the first rib, will be divided; but the **Inferior Cervical ganglion of the Sympathetic**, which is internal to it, will not come into view.
- f. Remove now the exposed **External Intercostal muscle**, and

The trunk of the first Dorsal nerve and its division into anterior and posterior primary branches will come into view.

VI. Continue now the dissection forwards in order to trace out fully the anterior primary branch.

- a. Divide and remove the exposed portions of the **Scalenus posticus**, and **Scalenus medius** muscles. The latter muscle is taken away to trace the branch of the first Dorsal nerve which joins the eighth Cervical.
- b. Cut through the **Clavicle** in two places and remove its middle third with the **Costo-coracoid membrane** and the **Subclavius muscle**.
- c. Divide the **Transversalis colli artery and vein**, and the **Supra-scapular artery and vein**.



- d.* Cut through the cords of the Brachial plexus, and the Supra-scapular branch.
- e.* Remove the first digitation of the Serratus magnus muscle, the fascia over the External Intercostal muscle, and the remaining portion of the muscle itself.

The anterior primary branch of the nerve may now be fully traced.

N.B.—The nerve in the posterior part of its course lies underneath the first rib, and this must be lifted up, or better, the outer border may be chipped away to the necessary extent.

## A DISSECTION OF THE POSTERIOR SURFACE OF THE CORD IN THE CERVICAL REGION.

POSITION.—The body lying on its face, the shoulders supported by blocks, and the head hanging forwards.

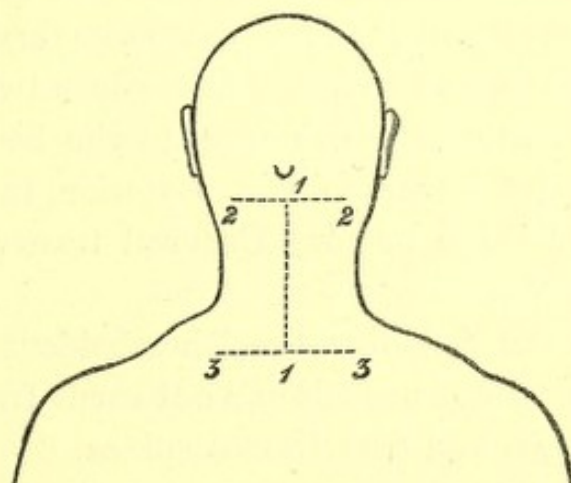
### I. SKIN INCISIONS.

1. A vertical one along the middle line, the upper limit of which is the central point of a line encircling the neck at the level of the apices of the Mastoid processes, and the lower the first Dorsal spinous process.
2. Transverse incisions above and below for two inches on each side.

Reflect the flaps to the sides and expose the superficial fascia containing—

1. Small cutaneous branches from the Superficial Cervical artery on the outer side, and from the Profunda Cervical artery with the nerves described under No. 4.

2. Veins corresponding to the preceding arteries, and others along the spines connected with the Dorsispinal.
3. At the outer parts of the surface exposed cutaneous twigs from the third and fourth Cervical nerves supplying the skin over the Trapezius muscles.
4. Along the Spinous processes the inner branches of the posterior primary divisions of the third, fourth, and fifth Cervical nerves, the third sending a branch up to the Occiput.



No. 6.

II. Remove the preceding and the fascia lata, and expose—

1. The Trapezii muscles running up above to the inner third of the superior curved lines, each attached to all the Cervical spines by means of the ligamentum nuchæ.
2. Small portions of the Sterno-mastoidei muscles at the extreme upper and outer parts.
3. A small portion of the Splenius capitis muscle between the two preceding on either side.

III. Cut through and remove the Trapezius muscle on each side as far as it is exposed. With it there will be re-



moved the **Spinal-accessory** nerve and branches from the third and fourth **Cervical** nerves, together with offsets of the **Superficial Cervical** artery.

The following structures will now be seen on both sides:—

1. The **Complexus** muscle highest of all, inserted into the space between the curved lines of the **Occipital** bone.
2. Below this, the **Splenius** muscle, arising as far as it is possible to make out in this dissection, from the spines of the first **Dorsal** and the seventh **Cervical** vertebræ and the **ligamentum nuchæ** up to the third vertebra, and splitting above into two portions, the upper one of which goes to the head (**S. capitis**), and the lower to the posterior tubercles of the upper three or four **Cervical** transverse processes (**S. colli**).
3. Below the **Splenius** the **Rhomboideus minor** muscle, running downwards and outwards from the seventh **Cervical** and first **Dorsal** spines.
4. The **Serratus posticus superior** muscle has the same origin as the preceding, and lies beneath it; its superior border showing above it however.
5. The origin of the **Levator anguli scapulæ** muscle, from the upper three or four posterior tubercles of the **Cervical** transverse processes is seen on the outer side of the **Splenius**.
6. Between the **Levator anguli scapulæ** and the **Rhomboideus minor**, and below the **Splenius** muscles is a triangular interval, in which some tendinous slips of the **Cervicalis ascendens** and **Transversalis colli** muscles appear, the latter being internal.
7. Lying upon the **Complexus** muscles at their extreme



upper and outer parts are the Occipital artery and vein, and lower down on the Splenius muscle branches of the Superficial Cervical artery and vein, and the Posterior External Jugular vein.

8. Lying upon the Complexus above the Splenius muscle, the internal branches of the posterior primary divisions of the second and third Cervical nerves and their communications (Great and Third Occipital nerves).

#### IV.

- a. Detach the Rhomboideus minor and the Serratus posticus superior muscles of both sides and take them away. The nerves to the Rhomboid, and also those supplying the Serrati muscles, will be divided.
- b. Hook well aside the following muscles of each side:—Levator anguli scapulæ, Cervicalis ascendens, and Transversalis colli.
- c. Remove the Splenii muscles as far as they are exposed in the space dissected. Their nerves from the external branches of the posterior primary divisions of the Cervical nerves will be seen and divided on their deep surface.

There will now be exposed—

1. The tubercle of the first rib, internal to the retracted Transversalis and Cervicalis muscles on each side.
2. The Complexus muscles lying in the vertebral groove, and reaching above from the Occiput to the lower extremity of the space. The inner division called Biventer cervicis is apparent.
3. The Transversales and Cervicales muscles of both sides more fully.
4. The Trachelo-mastoid muscles on either side, inside



the two immediately preceding muscles, arising from the Cervical articular processes from the fourth to the seventh inclusive, and inserted into the Mastoid processes. All their origin however, is not seen.

5. The Occipital vessels, lying upon the Complexus muscle of each side at its extreme upper part, and offsets of the Princeps Cervicis branch running down superficial to the muscle.
6. The same branches of the second and third Cervical nerves already mentioned.
7. The nerves to the Splenii muscles from the posterior primary branches of the Cervical are seen entering their deep surface.

#### V.

- a. Cut through and remove the Complexus muscles from their origins and insertions. The former; as is displayed in this dissection is from the transverse processes of the first Dorsal and seventh Cervical vertebræ, the spine of the seventh, and the articular processes of the fourth, fifth, and sixth Cervical vertebræ; the latter; is into the space between the two curved lines of the Occipital bone. The nerves to the Complexus from the Suboccipital, and internal branches of the posterior primary divisions of the second and third Cervical nerves, will be divided on removing the muscle.

There will now be exposed—

1. The articular processes of the second, third, fourth, fifth, and sixth Cervical vertebræ.
2. The ligamentum nuchæ now displayed by the removal of the various muscles.



3. The Suboccipital triangle, bounded internally by the Rectus capitis posticus major muscle, below and externally by the Inferior Oblique muscle, and above and externally by the Superior Oblique muscle. In its floor is the posterior arch of the Atlas.
4. The Semispinales muscles, running from the transverse processes to the spines as high as the second vertebra.
5. Above and external to the processes of the Semispinalis muscle, passing to the second and third spinous processes, is seen a small piece of the Multifidus spinæ muscle on either side.
6. Lying upon the arch of the Atlas in the floor of the triangle is seen the Vertebral artery.
7. Upon the Semispinales, beneath the nerves to be mentioned, the Profunda Cervicis branch of the Superior Intercostal artery running up to join in a general anastomosis over the Suboccipital triangle, with branches of the Vertebral and Princeps Cervicis arteries.
8. The origins of the Vertebral vein, and sometimes the Posterior Condylloid vein in the triangle. The Profunda Cervicis vein with the corresponding artery.
9. The Suboccipital nerve, and the internal divisions of the posterior primary branches of the second, third, fourth, and fifth Cervical nerves. The first, second, and third communicate and form Cruveilhier's plexus. The Suboccipital nerve lies *beneath* the Vertebral artery *upon* the arch of the Atlas and supplies both the Recti postici and Oblique muscles and the Complexus muscle. The great Occipital nerve turns round the lower border of the Inferior Oblique



muscle. The third, fourth, and fifth nerves course inward *over the Semispinalis* to become cutaneous by the Spines; these are seen at their junction with the external branches.

10. The external branches of the second, third, fourth, fifth, sixth, seventh, and eighth nerves, emerging externally to the line of the articular processes of the Cervical vertebræ. These enter the following muscles:—Complexus, Transversalis colli, Trachelomastoid, and Cervicalis ascendens.
11. Branches from the Vertebral artery are seen with the last-mentioned nerves.

## VI.

- a. Remove now the Semispinales muscles, with the inner branches of the posterior primary divisions of the third, fourth, and fifth Cervical nerves lying upon them.

This brings into view—

1. The seventh Cervical articular processes.
2. The inner branches of the posterior primary divisions of the sixth, seventh, and eighth Cervical nerves. In the dissection made, the corresponding branch of the fifth nerve passed beneath the Semispinalis muscle.
- b. Clear away the Multifidus spinæ, the Rectus capitis posticus major and minor, the Superior and Inferior Oblique muscles of both sides.
- c. The anastomosis of Vertebral, Princeps, and Profunda Cervicis arteries.
- d. The origin of the Vertebral veins.
- e. Cruveilhier's plexus and the nerves forming it.
- f. The inner branches of the posterior primary divisions of the sixth, seventh, and eighth Cervical nerves.



This will expose—

1. The laminae, articular, and spinous processes of the vertebrae as far as the first Dorsal, and the posterior arch of the Atlas.
2. The posterior Occipito-atloid and Atlo-axoid ligaments and the Capsular ligaments of the articular processes.
3. The Dorsi-spinal venous plexus lying upon the vertebral laminae.

## VII.

Saw through the posterior arch of the Atlas, and the laminae of the exposed vertebrae internal to the articular processes on each side, and remove the pieces of bone together with the following structures:

- a. The Ligamentum nuchae.
- b. The Interspinales muscles. (There are none between the Axis and Atlas.)
- c. The Interspinous ligaments. (Very slightly marked in the neck.)
- d. The Posterior Occipito-atloid, Atlo-axoid, and Ligamenta Subflava below the first two vertebrae.
- e. The Vertebral artery, and the Suboccipital nerve.
- f. The Venae Dorsi-spinales.

This opens up the Spinal canal and exposes—

1. The Dura-mater surrounded by loose areolar tissue.
2. The Posterior Longitudinal venous plexus lying upon the Dura-mater.

## VIII.

Slit up the Dura-mater, with the parietal layer of the Arachnoid along the median line.

This brings into view—

1. The visceral layer of Arachnoid with the Sub-arachnoid space and Pia-mater.



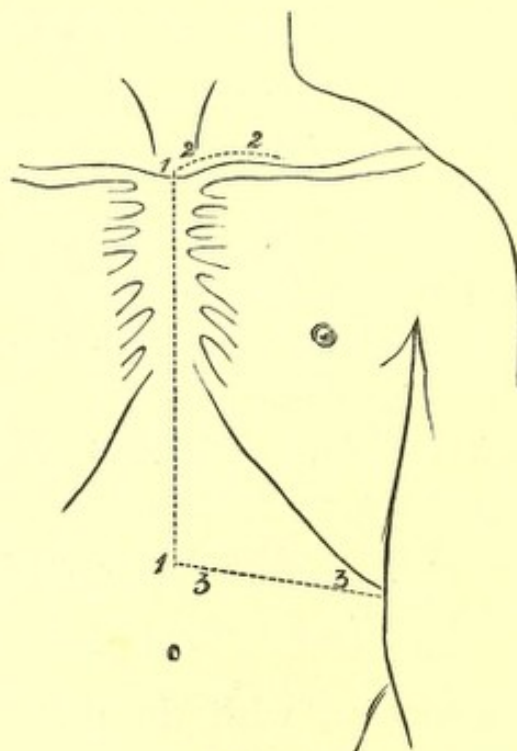
2. The posterior surface of the Spinal Cord.
3. The Posterior Spinal arteries, one in each side.
4. The Medulli Spinal veins, which are in the main two venous trunks, one on each side, united into a close plexus by intercommunicating branches.

## A DISSECTION OF THE INTERNAL MAMMARY ARTERY.

POSITION.—The body lying supine.

### I. SKIN INCISIONS—

1. From the centre of the supra-sternal notch to midway between the umbilicus and Ensiform Cartilage.



No. 7.

2. A transverse one parallel with and half an inch above the upper border of the Sternum and Clavicle,

to the junction of the inner with the middle third of the latter.

3. Another transversely from the lower border of No. 1 to the tip of the tenth rib.

Reflect the flap outwards and expose the superficial fascia containing—

1. The *Platysma myoides* muscle over the Clavicle.
2. The Supra-sternal and Supra-clavicular nerves passing over the Clavicle, and branches of the Supra-scapular artery with them.
3. The upper eight Anterior Cutaneous branches of the Intercostal nerves along the median line. The corresponding vessels from the Internal Mammary and Superior Epigastric trunks accompanying them.
4. A communication between the Supra-clavicular and second Anterior Cutaneous nerves.
- 5.<sup>1</sup> The anterior branches of the third, fourth, fifth, and sixth Lateral Cutaneous nerves.
6. Small cutaneous vessels are found in the wall of the abdomen, derived from the anterior portions of the Intercostals.

## II.

Remove the *Platysma* muscle and the fascia lata, and expose—

1. The *Sterno-mastoideus* muscle, arising from the Manubrium Sterni and inner end of the Clavicle.
2. The *Pectoralis major* muscle, arising from the Clavicle and the true ribs from the first to the sixth inclusive. The interlaced aponeurosis of the muscles of opposite sides is also seen over the Sternum.
3. The aponeurosis of the *Obliquus Externus* muscle, and

<sup>1</sup> The second Lateral Cutaneous nerve usually wants the anterior branch (Ellis). It is, however, figured by Henle.



the fleshy fibres attached to the ninth and tenth ribs.

4. Anterior branches of the Internal Mammary artery ramifying over the Sternum.

### III.

- a. Cut through the exposed attachment of the Sternomastoid muscle and turn it upwards.
- b. Remove the fleshy portion of the Pectoralis major muscle within the limits of the skin incisions, preserving the Anterior Cutaneous arteries and nerves, and observing additional muscular branches of the Internal Mammary artery in the intercostal spaces from the second to the sixth inclusive.
- c. Take away the anterior layer of the sheath of the Rectus muscle made up of the aponeuroses of the Obliquus Externus and Internus muscles, and further take away the aponeurosis and exposed fleshy portion of the Obliquus Externus muscle external to this.
- d. Remove the upper part of the Rectus muscle, dissecting out the Superior Epigastric branch of the Internal Mammary artery which lies beneath it, with its vein. This artery is seen to enter the sheath of the muscle beneath the cartilage of the seventh rib.

There will now be exposed—

1. The inner portion of the Clavicle, the side of the Sternum, and the Costal cartilages as far as the tenth.
2. The Sterno-hyoid and Sterno-thyroid muscles above the Manubrium and Clavicle.
3. The inner border of the Scalenus anticus muscle external to the preceding muscles.



4. The fascia over the Internal Intercostals, these muscles showing plainly through it; and the anterior portions of the External Intercostal muscles.
5. A portion of the Obliquus Internus muscle outside the sheath of the Rectus muscle.
6. The Anterior Jugular vein crossing transversely above the Clavicle.

The following structures between the Sterno-thyroid and Scalenus anticus muscles:—

7. A small portion of the first part of the Subclavian artery and the following branches. The Thyroid axis, the commencement of its Inferior Thyroid, and the Transverse Cervical and Supra-scapular offsets. The origin of the Internal Mammary branch is also seen.
8. The Phrenic nerve is seen on the Scalenus anticus muscle if the left artery is dissected; on the right side this nerve is too far out.
9. The Vagus nerve, the commencement of its Recurrent Laryngeal and Inferior Cardiac branches, are to be seen upon the Subclavian Artery, if the right side is dissected; on the left side this nerve is too deep.
10. The Ansæ Vieussenii are seen crossing the first part of the right Subclavian artery.

#### IV.

- a. Cut through the Sterno-hyoid muscle, and hook inwards the Sterno-thyroid muscle.
- b. Saw through the Clavicle at the junction of the inner with the middle third, and disarticulate the inner end from the Sternum by dividing the anterior and posterior Sterno-clavicular and Interclavicular ligaments. The interarticular fibro-cartilage will be removed, the Rhomboid ligament, the inner



end of the Costo-Coracoid membrane, and a small piece of the internal portion of the Subclavius muscle cut through. Remove the upper and outer projecting angle of the Manubrium.

- c. Remove the fascia over the Internal Intercostal muscles, the anterior portions of the External and of the Internal Intercostal muscles. When this is done, the Internal Mammary artery will be seen in the intervals of the Costal cartilages about half an inch from the Sternum. It will be found to be giving off the Anterior Intercostal branches of the upper five or six spaces, two in each space, one running along the upper border of the rib, the other along the lower border of the rib above. These will be found to anastomose behind with the bifurcated Intercostal branches of the Aorta, similarly disposed as regards the rib. In the first or first two spaces, the Superior Intercostal artery will take the place of the Aortic Intercostal. In the lower spaces Anterior Intercostal arteries will be traced, but they will subsequently be found to arise from the Musculo-phrenic branch of the Internal Mammary artery, but this offset in its course outwards and downwards to the ninth cartilage is hidden by the approximation of the seventh, eighth, and ninth cartilages. The Internal Mammary artery will be seen to lie upon the pleura above and the Triangularis sterni muscle below. The Intercostal nerves will also be seen in the spaces crossing superficial to it. Veins corresponding to all the arteries mentioned are seen.



*d.* Having thus traced the artery between the cartilages, now remove the inner portions of the upper nine by cutting them through, externally in a line extending obliquely from the inner end of the divided **Clavicle** (one and a half inches from the **Sternum**) to the tip of the tenth rib; and internally, disarticulate them from the breast-bone dividing the following: **Anterior and Posterior Costo-sternal, Capsular, Interarticular** of second joint and of third when present, and **Costo-xiphoid** ligaments. The last is between the **Ensiform** and seventh cartilages. The **synovial membranes** will be of course destroyed.

*e.* Now raise this portion of the chest-wall from above downwards, dividing on its under surface (1) the slips of the **Triangularis sterni** muscle to the **Ensiform**, and second, third, fourth, fifth, sixth, and seventh cartilages; (2) the attachments of the **Diaphragm** and **Transversalis** muscle from the sixth to the ninth, and still lower (3) the insertion of the **Obliquus Internus** muscle into the ninth rib, that part attached to the seventh and eighth being already removed. The upper part of the last muscle should now be reflected downwards. This dissection should be done carefully, keeping the knife close to the inner surface of the chest-wall, to avoid a division of the artery.

There will now be exposed, commencing from above—

1. The process of deep **Cervical fascia** beneath the **Sterno-thyroid** muscle, which should be cleared away.

IF THE DISSECTION IS DONE ON THE LEFT SIDE.

2. The **Internal Jugular** and **Subclavian** veins joining



and forming the **Innominate**, only the beginning of which is exposed. The **Vertebral** and **Internal Mammary** veins will be seen joining the **Innominate**, and the **Thoracic** duct entering at the junction of the **Jugular** and **Subclavian** veins.

3. The lower part of the **Common Carotid** artery beneath the preceding trunks.
4. The first part of the **Subclavian** artery, the **Thyroid axis**, and the commencement of its branches, and the origin of the **Internal Mammary** branch.
5. The **Phrenic** nerve crossing the **Internal Mammary** artery.

Owing to the veins overlapping the arteries the **Vagus** nerve is not seen.

IF THE DISSECTION IS MADE ON THE RIGHT SIDE.

2. The veins as on the left, but they are more external and separated from the artery by an angular interval. The right **Lymphatic** duct is seen instead of the **Thoracic**.
3. The bifurcation of the **Innominate** artery into **Subclavian** and **Carotid** branches.
4. The right **Vagus** nerve, its **Recurrent** and **Inferior Cardiac** branches.
5. The **Ansæ Vieusénii**.

The **Phrenic** nerve lies too far out to be displayed on this side.

6. **Lymphatic** glands are seen at the root of the neck above the **Manubrium**.

IN THE THORACIC REGION.

7. The **parietal Pleura** is seen above, and the **Triangularis sterni** muscle below.
8. The **Diaphragm** is seen below.



9. The seventh, eighth, and ninth Intercostal nerves are seen on the portion of the Transversalis muscle remaining, passing behind the Musculo-phrenic branch of the artery.
10. The whole of the Internal Mammary artery except the upper part is now seen, and this may be exposed by dividing the Subclavian vein and hooking inwards, the Innominate and Internal Jugular veins. This will expose in addition, if the dissection is done on the left side, the Vagus nerve and the Ansæ Vieusenii, which were not previously seen.

#### A DISSECTION TO EXPOSE THE ANTERIOR SURFACE OF THE TRACHEA.

POSITION.—Body supine, a block under the shoulders, and the head hanging back.

##### I. SKIN INCISIONS.

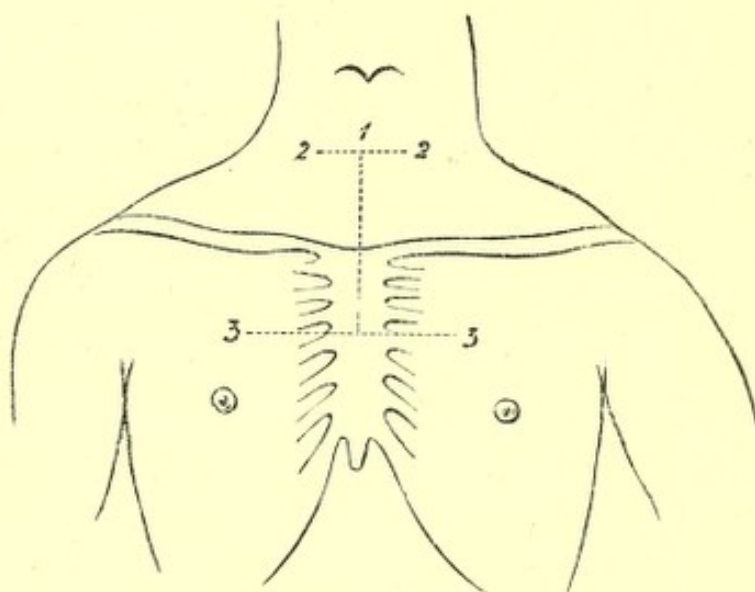
- (1.) Along the median line from the Cricoid cartilage to the level of the lower border of the third Costal cartilages at their junction with the Sternum.
- (2.) A transverse incision at the upper end for one inch on either side.
- (3.) A transverse incision at the lower end for three inches on either side.

Reflect the flaps outwards and expose—

1. The superficial fascia.
2. The Platysma muscles over the inner ends of the Clavicles.
3. Branches of the Anterior Jugular veins perforating at a variable distance down the neck.



4. The inferior branch of the **Superficial Cervical** nerve at the lower part of the neck.
5. Twigs of the **Supra-sternal** and **Supra-clavicular** branches of the **Cervical Plexus**.
6. The communication of the **Supra-clavicular** with the second **Anterior Cutaneous** nerve.
7. Branches of the **Supra-scapular** artery passing over the **Clavicle** with them.



No. 8.

8. Cutaneous branches from the **Inferior Thyroid** artery at the lower part of the neck.
  9. The first **Anterior Cutaneous** artery from the **Internal Mammary** sending small filaments to join them.
  10. The **Anterior Cutaneous** arteries, veins, and nerves of the upper two spaces.
  11. The anterior branch of the second **Lateral Cutaneous** nerve, when present.
  12. Its corresponding artery.
- II. Remove all the preceding structures and expose the **fascia lata** of the neck and chest.

In taking away the *Platysma*, the *Supra-clavicular* and *Supra-sternal* nerves will be found *beneath* it above the *Clavicle*.

### III. Remove the *fascia lata*.

In the middle line in front this will be found to present two layers, one between the anterior borders of the *Sterno-mastoidei*, and one between the corresponding borders of the *Sterno-hyoidei*. Some fat is found between these layers.

There will now be exposed—

1. The inner portions of the *Clavicles* on either side, and the first two pieces of the *Sternum*; the latter covered by the aponeurotic expansion of the *Pectorales* muscles.
2. The *Sterno-mastoidei* muscles attached to the *Clavicles*.
3. The *Sterno-hyoidei* muscles.
4. Small portions of the *Sterno-thyroidei* muscles outside the preceding.
5. Small portions of the *Omo-hyoidei* muscles at the upper and outer parts.
6. Small branches of the *Supra-scapular* arteries over the inner parts of the *Clavicles*.
7. Small branches of the *Inferior Thyroid* arteries above the *Sternal* notch.
8. Further portions of the *Anterior Jugular* veins, and a transverse branch of communication between the two, above the *Sternal* notch.
9. The *Pectorales majores* muscles.
10. *Lymphatics*.

### IV. Remove now—

- a. The *Sterno-mastoidei* muscles within the limits of the skin incisions.



b. The **Sterno-hyoidei** muscles.

c. The **Sterno-thyroidei** muscles.

In doing this there will be seen immediately beneath the first muscle on each side—

1. A further portion of the **Anterior Jugular vein**.
2. The nerves to the **Sterno-hyoidei** and **Sterno-thyroidei** from the **Ansa Hypoglossi** entering the outer borders.

d. Cut away the **Pectorales** muscles within the limits of the dissection.

There will now be exposed from above downwards—

1. Processes of deep **Cervical** fascia beneath the **Sterno-thyroidei** muscles running to the **Pericardium**.
2. The lobes and isthmus of the **Thyroid** body.
3. The **Trachea** in the median line.
4. The **Œsophagus** at the root of the neck on the left side.
5. The **Inferior Thyroid** plexus of veins.
6. Branches of the **Inferior Thyroid** arteries.
7. The **arteria Thyroidea ima** when present.
8. The inner margins of the **Scaleni antici** muscles on either side.
9. The **Omo-hyoidei** muscles, crossing the **Scalenus** muscle at the upper part.
10. The **Phrenic** nerve on the left **Scalenus anticus**.
11. Small portions of the first part of the **Subclavian** artery on both sides with the **Thyroid** axis, and the commencement of the **Inferior Thyroid**, **Transverse Cervical**, and **Supra-scapular** branches.
12. On the left side, the **Carotid** sheath, and this being opened, the **Internal Jugular vein**, covering this part of the **Common Carotid** artery. The **Vertebral vein** is also seen.



13. On the right side, the Common Carotid artery and Internal Jugular and Vertebral veins will be both exposed.
  14. The Thoracic and right Lymphatic ducts, and lymphatic vessels and glands.
  15. The right Vagus nerve, between the Carotid artery and Jugular vein, next crossing the Subclavian artery.
  16. The right Ansa Vieusensii.
  17. The first three ribs, and Costal cartilages.
  18. The inner portions of the Subclavii muscles, between the first rib and the Clavicles, covered by the Costo-coracoid membranes.
  19. The fascia of the External Intercostales.
  20. The Internal Intercostales muscles showing through it.
  21. The anterior ends of the External Intercostales.
  22. The Anterior Sterno-clavicular and Inter-clavicular ligaments, and Anterior Costo-sternal ligaments.
- V. Saw through the Clavicles, divide the upper three ribs at the outer limit of the skin incisions, and saw through the Sternum at the lower level of the third cartilages. Remove the included piece of chest-wall, with the following structures—
- a. The origins of the Sterno-hyoidei and Thyroidei muscles.
  - b. The External and Internal Intercostal muscles.
  - c. The Triangulares sterni muscles.
  - d. The Internal Mammary arteries and veins.
  - e. The Intercostal nerves, arteries, and veins of the upper two spaces.
  - f. The Subclavii muscles will be divided at their inner portions.



*g.* The parietal layers of the Pleuræ.

*h.* A few lymphatic glands between the Pleuræ and Sternum.

The Lungs will be found to be retracted on either side, and there will be now exposed—

1. Areolar tissue, fat, and lymphatics of the anterior Mediastinum, which should be cleared away.
2. The Trachea in the median line.
3. The right and left Internal Jugular veins, forming the right and left Innominates, and a small portion of the Superior Vena Cava, if distended. Entering the right and left Innominates are the Inferior Thyroid and Vertebral veins coming from above. The Superior Intercostal veins from below, and the cut ends of the Internal Mammary branches.

These veins should now be removed, and there will then be exposed—

4. The arch of the Aorta giving off the Innominate branch on the right, which crosses over the Trachea, and bifurcates above into right Subclavian, and Common Carotid branches. The left Common Carotid and left Subclavian branches passing upwards and to the left. The Vertebral artery will be seen leaving the latter on the removal of its vein.
5. Crossing the arch of the Aorta are, from within outwards—
  - a.* The left Phrenic nerve.
  - b.* The Inferior Cardiac branch of the left Vagus.
  - c.* The Cardiac branch of the left superior Cervical ganglion.
  - d.* The left Vagus giving off its Recurrent branch.
  - e.* The left Superior Intercostal vein.



6. The left Pulmonary artery and the Ductus Arteriosus.
7. The right Vagus nerve passing beneath the Innominate artery. Its Recurrent branch is seen turning round the Subclavian artery, and its Inferior Cardiac branch lying on the outer side, and then passing beneath the Innominate.
8. The left Vagus is seen above, between the Common Carotid and Subclavian arteries, and below passing beneath the left branch of the Pulmonary artery.
9. The right and left Ansæ Vieusenii crossing the first parts of the Subclavian arteries.
10. Part of the superficial Cardiac plexus.
11. The right and left Phrenic nerves in front of the corresponding roots of the Lungs, and the Comes nervi Phrenici arteries with them.
12. The anterior surface of the Pericardium, with some small arteries from the Internal Mammary, and small veins running to the left Superior Intercostal and Innominate veins.

VI. Remove now—

- a. The isthmus and exposed parts of the lobes of the Thyroid gland. In doing this there will be taken away—
  1. The Superior and Inferior Thyroid arteries.
  2. The Middle and the remaining portions of the Inferior Thyroid veins.
  3. Branches of nerves from the middle Cervical ganglion.
- b. Open the Pericardium.
- c. Divide the Aorta between Innominate and left Carotid branches, turn the ends right and left, and fix them.



There will now be exposed—

The whole length of the **Trachea** from its origin to its bifurcation.

And the following additional structures—

1. Further portions of the **Common Carotid** arteries in the neck.
2. The **Œsophagus** more clearly at the root of the neck on the left side.
3. The whole of both **Recurrent Laryngeal** nerves.
4. A further portion of the **Aortic arch**.
5. The **Pulmonary** artery and its bifurcation.
6. The right **Auricle** and appendix, the tip of the left **Auricular appendix**, the **Auriculo-ventricular groove**, the upper part of the right **Ventricle**, and the commencement of the right and left **Coronary** arteries.
7. A further portion of the superficial **Cardiac plexus** of nerves.
8. The deep **Cardiac plexus** lying upon the bifurcation of the **Trachea**, with its radicles entering it from above.

## A DISSECTION TO EXPOSE THE VENA AZYGOS MAJOR.

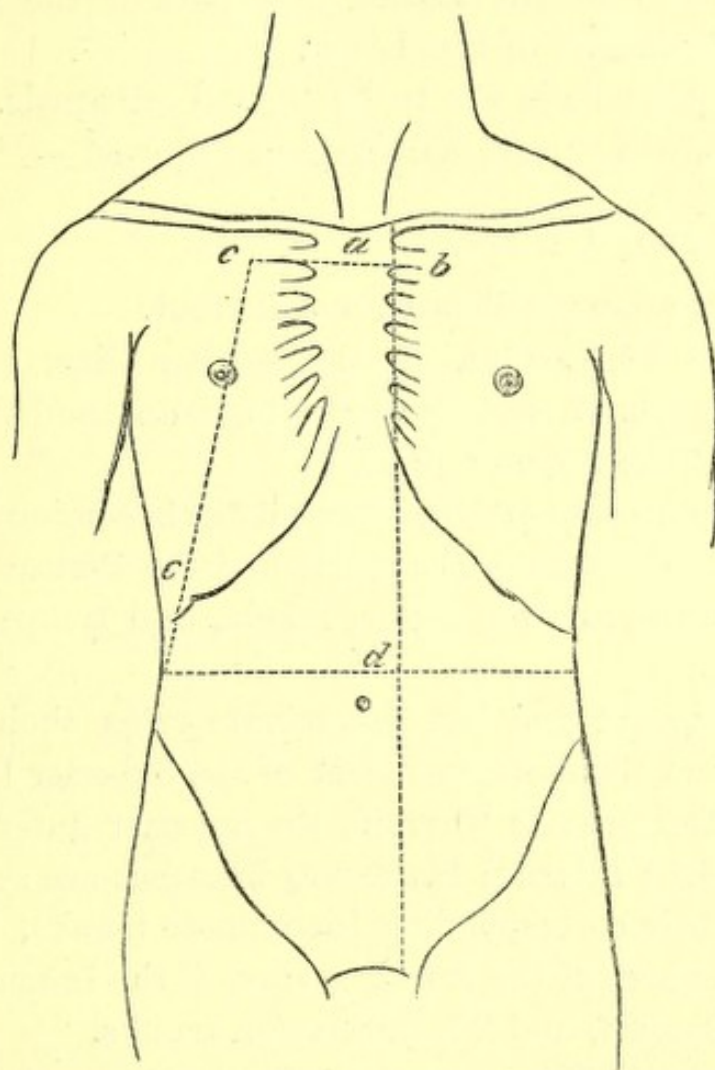
**POSITION.**—The body lying on its back.

I. The **Thorax**<sup>1</sup> is opened, and the anterior part of its bony wall taken away, with the soft parts attached, by the following dissection—

- a.* Cut through the **Manubrium** just below the line of junction of the first **Costal cartilages** with it.

<sup>1</sup> For an account of the structures divided, see the dissections of the **Trachea** and **Internal Mammary** arteries.

- b.* Divide through the junctions of the left Costal cartilages with the Sternum, from the second to the seventh inclusive.
- c.* Cut through the ribs on the right side, in a line



No. 9.

leading from a point four inches from the middle line above to the tip of the tenth rib below.

- d.* Open the **Abdomen** by a crucial incision, the transverse one of which should reach between the tips of the tenth ribs and the vertical to the left of the **Xiphoid** cartilage.



- e. Remove the piece of chest wall included between the above incisions, and the right upper flap of the Abdominal wall, cutting through the attachments of the **Diaphragm** to the inner surface of the ribs, the **Round**, and part of the **Suspensory ligaments** of the **Liver**.

The other flaps are to be turned outwards.

The following parts will be now exposed—

#### A. IN THE CHEST.

1. **Right Lung** collapsed, and its root.
2. The **Pericardium** in the median line, covered by areolar tissue, fat, and lymphatics, and the remains of the **Thymus gland**.
3. The process of deep **Cervical fascia** coming from above to the arch of the **Aorta** and the **Pericardium**.

Remove the areolar tissue, fascia, and lymphatics, and expose—

4. The right and left **Innominate veins**, their junction, and the commencement of the **Superior Vena Cava**. The **Inferior Thyroid**, the **Superior Intercostal**, the **right Internal Mammary** branches are seen joining their corresponding **Innominate trunks**.
5. The arch of the **Aorta**, giving off the **Innominate**, left **Carotid**, and left **Subclavian trunks**.
6. The right **Phrenic nerve** in front of the root of the lung, and the left **Phrenic** crossing the **Aortic arch**. The **Comes nervi Phrenici** artery with each.
7. On the **Pericardium** small **arteries** from the **Internal Mammary**, and **veins** entering the left **Innominate trunk**.

#### II.

- a. Dissect out the **Vena Azygos major**, as it arches up



and over the root of the right Lung, and enters the Cava; divide the root, and remove the viscus, taking away the *ligamentum latum Pulmonis* at the same time. The following structures will be cut through—

1. Right Bronchus.
2. Right Pulmonary artery.
3. Right Pulmonary veins.

In this order from before backwards, and above downwards.

4. Right Bronchial artery and veins.

At the back of the root.

5. Parts of the anterior and posterior Pulmonary plexuses of nerves.

In front and behind respectively.

6. Lymphatics and glands.

b. Hook the divided root well over to the left side, and with it the Heart, contained in the Pericardium.

c. Remove the Pleura, as it is reflected from the posterior wall of the chest, over the bodies of the vertebræ, to the back of the root of the Lung. The *Œsophagus* will be found to be drawn to the left by the traction on the root of the Lung and Pericardium.

There will now be exposed—

1. The *Vena Azygos major*, as it lies on the right side of the bodies of the vertebræ; the right Intercostal veins, except those of the first two spaces, will be found joining it, the right Bronchial vein opens into it near its termination. The *Vena Azygos minor inferior* crosses the body of the seventh or



eighth Dorsal vertebræ to join it, and the Vena Azygos minor superior may be found joining the Azygos major above, when present. Both these structures pass beneath the Aorta.

2. The Thoracic Aorta is seen lying to the left side of the Azygos major and the Intercostal arteries, except those of the first and a part of the second spaces passing behind the vein.
3. The Thoracic duct in the interval between the Vein and the Aorta.
4. The Œsophagus to the left, with the Vagi nerves in front and behind.
5. The right gangliated Sympathetic cord lies externally on the heads of the ribs, giving from the second, third, and fourth ganglia (Quain), or third and fourth (Ellis) branches to the posterior Pulmonary plexus. The ganglia are also seen giving off the Splanchnic nerves which run down outside the Vena Azygos. The great Splanchnic arising by roots from the fifth or sixth to the ninth or tenth ganglia inclusive. The small from the tenth or eleventh, and the smallest from the twelfth. These are seen perforating the Diaphragm close to one another. Externally the ganglia are seen to send two branches to each Intercostal nerve.
6. The posterior wall of the chest will be seen formed by the ribs and Intercostal muscles. The internal muscles as far as the angles, and a thin fascia prolonged inwards to the vertebræ from them. On removal of this fascia, the Intercostal nerve, artery, and vein will be seen having the following relations to each other in the lower spaces, *i.e.* vein, artery, nerve from above downwards; in the upper spaces the



nerve is at first highest. The **External Intercostal muscles** are seen underneath the vessels and nerves extending as far inwards as the tubercles of the ribs.

### B. IN THE ABDOMEN.

On opening the Abdomen as described above, the following structures are exposed—

1. The **Liver** with the **Round** and **Suspensory ligaments** in the middle line, and the tip of the **Gall bladder** on the right.
2. The **Stomach** on the left.
3. The **great Omentum**.
4. The **Cæcum** and **ascending Colon**, if distended.

### III.

- a. Raise the **Liver**, and dissect out in the small **Omentum** the **Bile duct** on the right, the **Hepatic artery** and its branches on the left, and the **Portal vein** behind. Divide these structures.
- b. Raise the **great Omentum** on to the ribs, and fix it there. Turn the **small Intestine** over to the left, and dissect out the **Superior Mesenteric vessels** as they pass over the third part of the **Duodenum**.
- c. **Ligature** and divide the **Hepatic flexure** of the **Colon**, cut through the **conjoined transverse Mesocolon** and **great Omentum** from before backwards, dividing the **middle Colic artery** and **vein**; turn the ends of the **Colon** right and left.
- d. Remove the **Peritoneum** between the **Duodenum**, and **ascending Colon** above, and the **median line** and **ascending Colon** below, and with it the **Ileo** and **right Colic arteries, veins, and nerves**, and



take away the ascending layer of the transverse Meso-colon, in front of the Duodenum and Pancreas.

- e. The Stomach is already pulled up, and fixed to the left ribs by the portion of great Omentum remaining. Divide now the Duodenum at its junction with the Pylorus, and again below on the right side of the Superior Mesenteric vein. Cut through the head of the Pancreas, and take it away with the piece of Duodenum included between the two incisions. The Pancreatico-duodenalis arteries, superior and inferior, will be divided and taken away, and the duct of the gland with the arteria Pancreatica magna cut through. The Bile duct will be removed, being already cut above. The Portal vein must be again divided just after the junction of the Splenic with the Superior Mesenteric, and taken away.

There will now be exposed—

1. The Abdominal Aorta and the following branches, the Phrenics, the Cœliac axis, the Gastric, Splenic, the divided Hepatic and its Gastro-duodenal branch, the right, Supra-renal, Renal, Spermatic, and Lumbar branches.
2. The Inferior Vena Cava on its right side joined by the following veins, right Phrenic, Supra-renals, which however may enter the Renals (also seen), the right Spermatic, the Lumbar of both sides, and the Ascending Lumbar when present.<sup>1</sup>
3. The right Crus of the Diaphragm on the right of the Aorta.

<sup>1</sup> Vide Quain, vol. i. p. 473.



4. The right Psoas muscle, with the Genito-crural nerve, Spermatic artery, and Ureter lying upon it.
5. The Kidney, the upper end concealed by the Liver.
6. The Solar plexus and its prolongations along the vessels, viz.:—The Cœliac, Renal, Supra-renal, Phrenic plexuses.
7. The Splanchnic nerves perforating the right Crus of the Diaphragm. The endings of the small and lesser in the Cœliac and Renal plexuses respectively. The Semilunar ganglion and the ending of the greater, are hidden by the Inferior Cava on this side.

## IV.

- a. Cut through the Coronary and left Lateral ligaments of the Liver as far as the Inferior Cava.
- b. Divide the Diaphragm from before backwards, passing between the foramen Quadratum and opening for the Œsophagus down through the decussation of the Crura into the Aortic opening, cutting through the right Phrenic Artery; now pull the halves of the Diaphragm to the right and left.
- c. Divide the Inferior Cava at its entrance into the right Auricle.
- d. Pull the Liver and with it the lower portion of the Inferior Cava well over to the right side, and fix it there.
- e. Divide the Supra-renal, Renal, and Spermatic arteries.
- f. Pull the upper part of the Aorta to the left.
- g. Remove the right Semilunar ganglion, which will be displayed by the removal of the Inferior Vena Cava, and the right side of the Solar plexus.



There will now be exposed—

1. The whole length of the *Vena Azygos Major*.
2. The right *Lumbar Sympathetic cord*.
3. The *Receptaculum chyli* and the *Thoracic duct*.

## A DISSECTION TO EXPOSE THE ANTERIOR AND POSTERIOR CIRCUMFLEX ARTERIES.

**POSITION.**—The body supported by blocks upon the opposite shoulder to that to be dissected. The arm is to be moved backwards and forwards, and rotated outwards and inwards according as the front or back is being dissected. In making the skin incisions the shoulder is to be drawn well down.

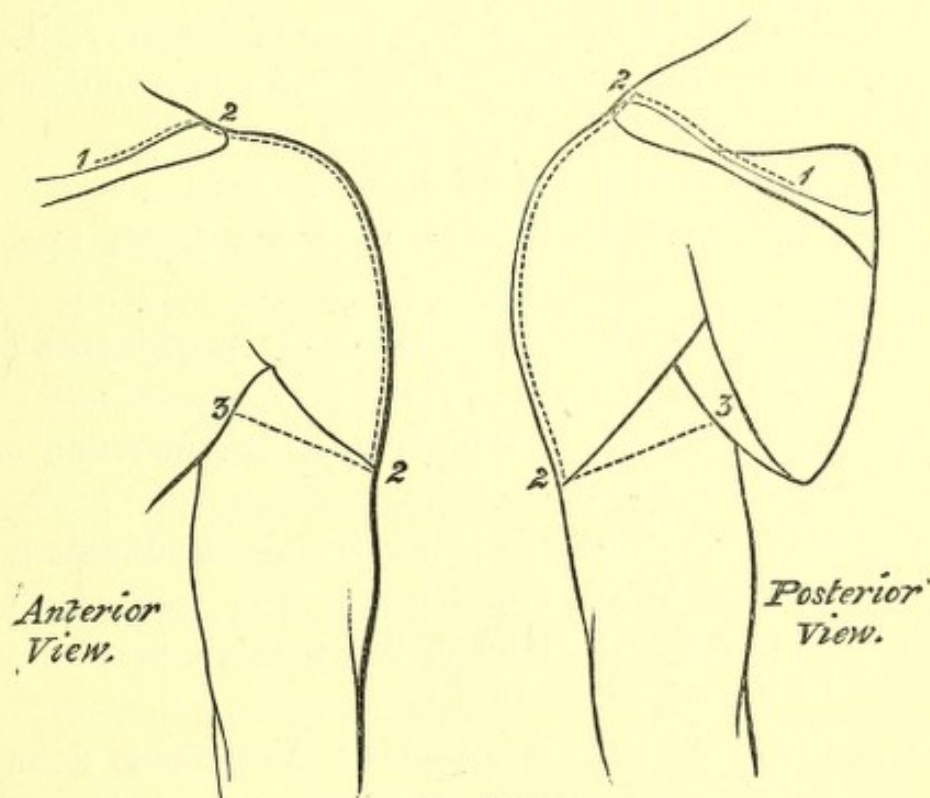
### I. SKIN INCISIONS.

1. Along the outer third of the posterior border of the *Clavicle*, the inner border of the *Acromion* process, and the upper border of the *Spine of the Scapula*, for two-thirds of its extent.
2. A vertical incision from the centre of the inner border of the *Acromion* above, over the middle of the prominence of the shoulder to the insertion of the *Deltoid* muscle.
3. From the lower end of No. 2, obliquely upwards and forwards to the middle of the anterior fold of the *Axilla*, and upwards and backwards to the centre of the posterior fold.

Reflect the flaps forwards and backwards and expose the superficial fascia, and—

1. The upper surface, of the outer third of the *Clavicle*, and of the *Acromion* process.

2. The anastomosis on the Acromion between the Suprascapular, Acromio-thoracic, and Posterior Circumflex arteries.
3. A cutaneous branch of the Posterior Circumflex artery at the lower part of the posterior border of the Deltoid muscle, sending a twig downwards to the skin over the long head of the Triceps muscle.



No. 10.

4. A descending branch of the Acromio-thoracic artery between the Pectoralis major and the Deltoid muscles.
5. The Cephalic Vein also between these two muscles. Its branch of communication over the Clavicle with the External Jugular vein may be seen at its upper part.
6. Lymphatic vessels along the Cephalic vein.



7. Passing over the Acromion process, the Supra-acromial branches of the descending cutaneous nerves of the Cervical plexus.
8. The lower branch of the Circumflex nerve passing round the posterior border of the Deltoid below the middle, and supplying the skin over the lower two-thirds of the muscle, and further giving off a twig to the skin over the long head of the Triceps muscle. Offsets of the upper branch of the nerve pass between the muscular fibres, and also turn down over the lower part of the muscle.

9. The bursa over the Acromion process.

II. Remove these structures, and the fascia lata, and expose—

1. The Deltoid muscle forming the prominence of the shoulder.
2. In front of this the outer part and insertion of the Pectoralis major muscle.
3. Below the Pectoralis major muscle the Biceps muscle is seen at its upper part. The part exposed is mainly the short head, but a small portion of the long head comes into view.
4. Behind the Deltoid muscle the Latissimus dorsi and Teres major and minor muscles are seen in part, and the Inspinatus muscle above them covered by its fascia.
5. The upper part of the external head of the Triceps muscle is exposed behind the Deltoid muscle at its lower part, running up beneath it.
6. A small twig of the Dorsalis Scapulæ artery is seen posteriorly between the Teres muscles.

III. Detach the Deltoid muscle from its origin and reflect it downwards. The branches of the Posterior Circumflex



artery and the accompanying nerve to its substance and on its cutaneous surface may be preserved.

There will now be seen—

1. A further portion of the **Acromion**, and the **Coracoid** process of the **Scapula**. The head, and greater and lesser **Tuberosities** of the **Humerus**.
2. The **Coraco-acromial** ligament, and the **Coraco-humeral** portion of the **Capsule**.
3. The insertions of the **Supra-spinatus**, **Infra-spinatus**, and **Teres minor** muscles from above downwards into the great **Tuberosity**.
4. A small portion of the insertion of the **Subscapularis** muscle into the lesser **Tuberosity**, especially seen in the adducted position of the arm.
5. The origin of the **Coraco-brachialis** and short head of the **Biceps** muscles from the **Coracoid** process, and the tendon of the long head of the latter perforating the **Capsular** ligament.
6. A further part of the tendon of the **Pectoralis major** muscle passing in front of the **Coraco-brachialis** and short head of the **Biceps** muscles, and inserted into the outer **Bicipital** ridge.
7. A further portion of the **Teres major** muscle is seen behind, covering in this position the **Latissimus dorsi** muscle.
8. The long head of the **Triceps** muscle is seen posteriorly passing between the **Teres major** and **minor** muscles, the former being in front of it. The **Teres major** and **minor** muscles diverge from one another as they pass to the **Humerus** so as to form a **triangle**, of which the bone forms the base, the **Teres minor** muscle the upper and internal, and the **Teres major** muscle the lower and external boundaries. The



long head of the **Triceps** muscle passing to the **Scapula** divides this triangle into two parts, an upper or external part quadrilateral in shape, and a lower or internal triangular.

9. The **Posterior Circumflex** artery and vein, passing through the quadrilateral space.
10. The **Anterior Circumflex** artery with its vein, passing beneath the **Coraco-brachialis** and **Biceps** muscles, winding round the neck of the **Humerus** and anastomosing with the posterior artery.
11. The **Circumflex** nerve accompanying the **Posterior Circumflex** artery.
12. The bursa between the **Subscapularis** muscle and the **Acromion**.

#### IV.

- a. Cut through the **Pectoralis major** in front at the point of its appearance from beneath the reflected skin, and turn it outwards.
- b. Divide the **Coraco-brachialis** and short head of the **Biceps** muscles, and turn them downwards. The **Musculo-cutaneous** nerve will be carried with the former muscle.
- c. Divide the long tendon of the **Biceps** muscle, and with it the aponeurotic process from the tendon of the **Pectoralis major** muscle to the great **Tuberosity**. Open up the sheath of the tendon.
- d. Remove the fascia and fat and glands from the upper part of the **Axillary** space, dissecting out the various structures met with.

There will now be exposed—

1. The **Pectoralis minor** muscle in front, attached to the **Coracoid** process.
2. The **Subscapularis** muscle more fully. It is seen to



hide the *Teres minor* muscle when looked at from the front, and to take the place of this muscle in the boundaries of the quadrilateral and triangular spaces on the anterior aspect.

3. The insertions of the *Latissimus dorsi* and *Teres major* muscles, the former attached to the floor and the latter to the inner ridge of the Bicipital groove.
4. The upper part of the internal head of the *Triceps* muscle below the *Teres major* muscle.
5. The third portion of the *Axillary* artery, and its branches—viz., the *Subscapular*, which is seen running downwards on the *Subscapular* muscle, giving the *Dorsalis Scapulæ* branch through the triangular space. The *Anterior Circumflex* is hidden by the *Median* nerve at its origin, and also by the *Musculo-cutaneous* nerve, but this has been pulled down with the *Coraco-brachialis* muscle; the artery is seen in all the rest of its course, and a branch running up the Bicipital groove to the joint, may be traced. The *Posterior Circumflex* branch is hidden at its origin by the nerves on the inner side of the artery to be mentioned immediately, and by the *Axillary* vein, but it may be seen passing backwards through the quadrilateral space. The *Long Thoracic* branch of the second portion of the *Axillary* trunk may be seen descending along the outer border of the *Pectoralis minor* muscle. An *External Mammary* branch may be seen sometimes crossing the centre of the space, arising from the third part of the main trunk.
6. The *Axillary* vein is seen internal to the artery, receiving radicles corresponding to the above-named branches of the latter.



7. The Median and Musculo-cutaneous nerves are outside the artery, the latter gives branches to the Coracobrachialis muscle before piercing it.
8. The Internal Cutaneous nerve is superficial to it.
9. The Ulnar, inner head of Median, and lesser Internal Cutaneous nerves are internal to the artery.
10. The Intercosto-humeral nerve passes out from the second intercostal space lower down, and communicates by a cross branch with the lesser Internal Cutaneous nerve.
11. The Musculo-spiral nerve is behind the artery. The origin of its Internal Cutaneous branch is seen.
12. The Circumflex nerve is also behind the artery, accompanying the Posterior Circumflex artery.
13. The Subscapular nerves to the Teres major and Latissimus dorsi muscles may be seen passing down to their respective muscles.

## V.

- a. Divide the Axillary vein, and turn the ends inwards and outwards.
- b. Hook upwards the Median nerve. This exposes the origin of the Anterior Circumflex artery.
- c. Hook downwards the Ulnar, both Internal Cutaneous and the Musculo-spiral nerves. The origin of the Posterior Circumflex artery will now be uncovered.

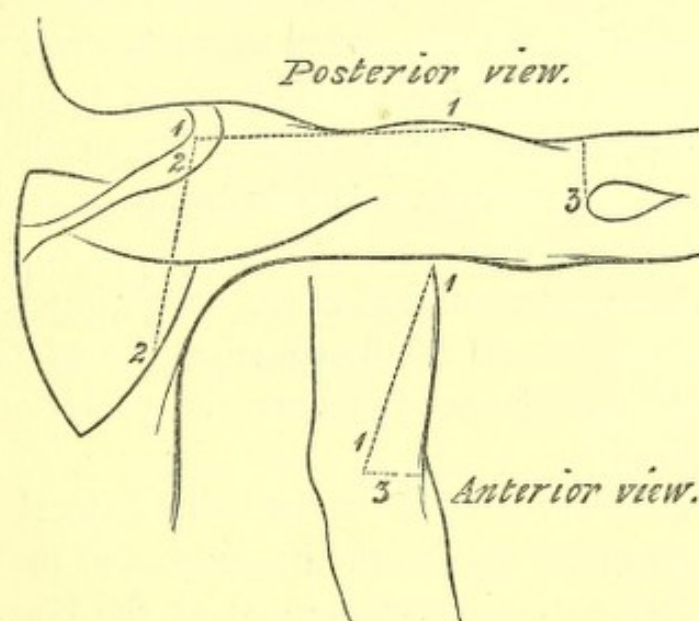
Both the Circumflex arteries may now be seen in their entire distribution.

## A DISSECTION TO EXPOSE THE MUSCULO-SPIRAL NERVE.

**POSITION.**—The body lying upon its face, the arm extended at right angles to the trunk, and rotated inwards.

### I. SKIN INCISIONS.

1. From the tip of the Acromion process down the outer border of the arm for about half its extent, and then forwards to the centre of the bend of the elbow half an inch below the external Condyle.



No. 11.

2. From the upper end of No. 1 downwards and backwards to the centre of the Axillary border of the Scapula.
3. From the lower end of No. 1, transversely outwards below the external Condyle to the Olecranon process.



Reflect the flap inwards and expose the superficial fascia and the following cutaneous structures—

1. Branches of the **Posterior Circumflex** artery, turning round the posterior border of the Deltoid muscle below the middle, and supplying the skin over it. An offset is also given to the integument over the Triceps muscle.
2. Twigs of the **Superior Profunda** artery in front of and behind the external Condyle.
3. In front of the elbow, the **Median-cephalic** vein joined below by the **Radial**; the **Cephalic** vein is also seen in the lower half of the arm.
4. The **Supra-acromial** branches of the **Cervical** plexus over the upper part of the Deltoid muscle.
5. Branches of the **Circumflex** nerve turning round the posterior border of the Deltoid at the lower part, and having a similar distribution to the **Posterior Circumflex** artery. Other branches of the nerve perforate the muscle.
6. The **Intercosto-humeral** nerve supplying the skin of the upper half of the inner aspect of the arm; a few filaments passing over the posterior Axillary fold.
7. The posterior branch of the third **Lateral Cutaneous** nerve often reaches the upper part of the arm.
8. The **Internal Cutaneous** branch of the **Musculo-spiral** nerve passing back beneath the **Intercosto-humeral** and supplying the skin nearly as far as the Olecranon.
9. The superior **External Cutaneous** branch of the **Musculo-spiral** nerve lies with the **Cephalic** vein. The inferior **External Cutaneous** branch over the posterior aspect of the arm.



10. In front of the elbow beneath the Median-cephalic vein, the Musculo-cutaneous nerve.

11. The upper part of the Olecranon bursa.

II. Remove the preceding and expose the fascia lata.

Above the elbow it will be found to form the external intermuscular septum. Clear it away except this process.

The following structures will be displayed—

1. The posterior portion of the Deltoid muscle.
2. The Latissimus dorsi muscle passing beneath it at the lower part, but separated by the long head of the Triceps muscle.
3. The Teres major muscle, taking a similar course to the Latissimus, but above it.
4. A small portion of the lower border of the Teres minor above the major muscle. It may, however, not come into view.
5. The long head of the Triceps muscle below the posterior border of the Deltoid and superficial to the Latissimus dorsi, and Teres major muscles. The outer head of the Triceps lower down the arm, and above the long head in the abducted position. Still lower, the outer portion of the inner head and the tendon.
6. In front of the elbow the outer border of the Biceps muscle, and beneath it the
7. Brachialis anticus muscle.
8. Descending from the external Condylod ridge the Supinator longus, and Extensor carpi radialis longior muscles.
9. Still lower down the upper part of the Anconeus muscle, behind and below the external Condyle.
10. Between the Brachialis anticus and Supinator longus



muscles a further portion of the **External Cutaneous** nerve will be seen.

11. On pulling outwards the **Supinator longus** and **Extensor carpi radialis longior** muscles, the **Musculo-spiral** nerve may be seen perforating the external intermuscular septum, running down beneath them, and dividing at the level of the external Condyle into **Radial** and **Posterior Interosseous** branches. The offsets to these muscles and the **Brachialis anticus** may also be traced.
12. Running down with the **Musculo-spiral** nerve the anterior branch of the **Superior Profunda** artery will be seen inosculating below with the **Radial Recurrent** branch.

### III.

- a. Hook the posterior border of the **Deltoid** muscle well forwards.
- b. Cut through the long, and outer heads of the **Triceps** muscle.
- c. Divide the **Latissimus dorsi** and **Teres major** muscles.
- d. Divide the **Supinator longus** and **Extensor carpi radialis longior** muscles.

There will now be exposed—

1. The head of the **Humerus** and the upper part of the shaft.
2. The **Subscapularis** muscle along the **Axillary** border of the **Scapula**.
3. The **Teres minor** muscle parallel with and behind the preceding.
4. Lower down at the elbow the **Supinator brevis** muscle.
5. Most of the second, and all the third part of the **Axillary** artery, and the commencement of the **Bra-**



chial, in front of the Subscapularis and along the inner border of the arm.

6. The **Subscapular branch**, running down the Axillary border of the Scapula, crossing behind the Musculo-spiral nerve, and giving off its **Dorsalis Scapulæ branch** below the Teres minor muscle, this branch then passes beneath the muscle.
7. The **Posterior Circumflex artery** is seen at its origin and in the rest of its course.
8. The origin and upper part of the **Superior Profunda branch** of the Brachial artery.
9. The **Axillary vein**, internal to and in front of its artery, the **venæ comites** of the Brachial artery, and veins corresponding to all the arterial branches above enumerated.
10. The **Circumflex nerve** is seen with the **Posterior Circumflex artery**.
11. The **Musculo-spiral nerve** above and below, and the origin of its **Internal Cutaneous branch** at its upper part.
12. Deep down in the dissection above, the **Musculo-cutaneous nerve** may be seen entering the **Coracobrachialis muscle** and also the **Ulnar nerve**, but it is not necessary to find them, for the nerve in course of dissection is superficial to them in this position.

#### IV.

- a. Remove a portion of the lower border of the **Subscapularis muscle** near the Humerus. Then the bifurcation of the posterior cord of the Brachial plexus into the **Circumflex** and **Musculo-spiral nerves** can be seen. This division takes place internal to the Axillary border of the Scapula, and if necessary a portion of the bone may be



chipped away; nevertheless this is not absolutely requisite.

- b. Divide the **Subscapular vessels**.
- c. Trace the **Musculo-spiral nerve** through the substance of that portion of the **Triceps** not yet divided, along the **Musculo-spiral groove**. In this situation the **Superior Profunda artery** will be found lying upon it, and must be removed. The upper part of the external intermuscular septum must also be taken away.

The nerve and its offsets may now be completely traced to its bifurcation. The **Internal branches**, viz., to the inner and middle heads of the **Triceps**, the **Ulnar Collateral**, and the **Internal Cutaneous**. The **Posterior branches**, viz., to the outer head, and the **Anconeus muscle**; the latter a long slender offset passing through the substance of the muscle with a branch of the **Superior Profunda artery**. The **External branches**, viz., the two **External Cutaneous**, and to the **Supinator longus** and **Extensor carpi radialis longior**, may all be followed out; some of them, however, have been previously dissected. A branch to the **Brachialis anticus muscle** from the outer set may be sometimes traced.

## A DISSECTION OF THE ANASTOMOSES ABOUT THE ELBOW-JOINT.

**POSITION.**—It will be necessary to move the arm about, and it should at first lie on its posterior, and next on its anterior surface.

### I. SKIN INCISIONS.

1. A circular one around the arm two inches above the **Condyles of the Humerus**.



2. A circular one around the forearm, two inches below the same points.
3. A longitudinal one along the median line in front, between the two circular incisions.

Reflect and remove the included portion of skin, and expose the superficial fascia containing—

IN FRONT—

1. The **Cutaneous veins**. The **Radial**, on the outer side. The **Anterior** and **Posterior Ulnar**, the latter coming from the posterior surface of the forearm, and the two uniting into one trunk. The **Median**, along the centre of the forearm, dividing into two branches, **Median-cephalic** externally and **Median-basilic** internally, and receiving at its bifurcation a deep vein from the venæ comites of the Brachial artery. The **Radial** vein joins the **Median-cephalic**, and the two form the **Cephalic vein** which runs up on the outer side of the arm. The united trunk of the **Ulnar** veins joins the **Median-basilic**, and the result is the **Basilic vein** passing upwards on the inner side of the arm.
2. With the **Cephalic vein** is the superior **External Cutaneous** branch of the **Musculo-spiral nerve**.
3. Behind the **Median-cephalic vein** the **External Cutaneous nerve** running down to the forearm.
4. The **Internal Cutaneous nerve** at the inner side of the arm dividing into numerous branches. One of these passes to the back of the forearm over the internal Condyle; the others pass some superficial to, and some beneath the **Median-basilic vein**, to the front of the forearm.
5. **Cutaneous branches** of the **Radial Recurrent artery** are found in front of the outer Condyle.



6. **Lymphatics**, and a gland in front of the elbow, and one above the inner Condyle.

BEHIND will be found—

7. The **Olecranon** process covered by a bursa.
8. The nerve of **Wrisberg** between the internal Condyle and Olecranon, sending filaments inwards over the lower part of the arm, the inner Condyle, and the Olecranon. A communication may be traced with the Internal Cutaneous nerve.
9. The inferior **External Cutaneous** branch of the **Musculo-spiral** nerve giving twigs over the posterior surface of the arm and forearm.
10. **Cutaneous twigs** of the following arteries are seen: of the **Interosseous Recurrent** behind the outer Condyle; of the **Posterior Ulnar Recurrent** and **Inferior Profunda** behind the inner Condyle.

II. Remove and expose the **fascia lata** which dips down to the external and internal Condylloid ridges to form the corresponding intermuscular septa, and is joined in front by the semilunar process of fascia derived from the tendon of the **Biceps** muscle.

III. Remove the preceding except the septa, and there will be now exposed—

IN FRONT—

1. The **Supinator longus** and **Extensor carpi radialis longior** muscles running down from the external Condylloid ridge.
2. The **Brachialis anticus** muscle and the lower part of the fleshy belly and tendon of the **Biceps** muscle in the centre, superficial to the preceding. These pass from the arm, the former to the Coronoid process of the Ulna, the latter to the Tuberosity of the Radius.



3. The origin of the **Pronator radii teres** muscle from the internal Condylloid ridge, and the common tendon of the **Pronator radii teres**, **Palmaris longus**, **Flexor sublimis digitorum**, and **Flexor carpi ulnaris** muscles from the internal Condyle.
4. A small piece of the **Supinator brevis** muscle in the floor of the triangular space.

## BEHIND—

5. The tendon of the **Triceps** muscle inserted into the Olecranon process.
6. The **Anconeus** muscle passing from the outer Condyle to the outer surface of the Olecranon process.
7. The common tendon of the following muscles from the external Condyle: **Extensor carpi radialis brevior**, **Extensor communis digitorum**, **Extensor minimi digiti**, **Extensor carpi ulnaris**. The origin of the **Supinator brevis** muscle from the same bony point.
8. The origin of the **Flexor carpi ulnaris** muscle from the inner surface of the Olecranon process, and the posterior margin of the Ulna.
9. The external and internal intermuscular septa.

## IN FRONT—

10. A further portion of the **External Cutaneous nerve**, emerging on the outer side between the **Biceps** and **Brachialis anticus** muscles.
11. The **Musculo-spiral nerve** lying deeply between the **Supinator longus** and **Brachialis anticus** muscles, and dividing on a level with the external Condyle into **Radial** and **Posterior Interosseous** branches. **Offsets** from the trunk are traceable to the **Supinator longus** and **Extensor carpi radialis longior** muscles, and occasionally one supplying the **Brachialis an-**



ticus muscle. With the nerve a branch of the **Superior Profunda** artery is seen.

12. The **Brachial** artery with its **venæ comites** is seen internal to the **Biceps** tendon dividing opposite the head of the **Radius** into **Radial** and **Ulnar** branches. The **Anastomotica Magna** branch is found above the elbow, sending a small branch down beneath the **Pronator radii teres** muscle, and perforating the internal intermuscular septum.
13. The **Median** nerve lies internal to the **Brachial** artery, and gives off a branch above the elbow to the **Pronator radii teres** muscle.

BEHIND—

14. The **Anastomotica Magna** and **Inferior Profunda** arteries are found in the space between the internal **Condyle** and **Olecranon** process.
15. The **Ulnar** nerve with the preceding.

IV. Divide now—

- a. The origin of the **Pronator radii teres** muscle from the internal **Condylloid** ridge, and its inner tendinous head (which overlaps the **Anterior Ulnar Recurrent** artery) from the inner surface of the **Coronoid** process.
- b. The common **Flexor** tendon from the internal **Condyle**.
- c. The outer head of the **Flexor carpi ulnaris** muscle from the **Olecranon** process and posterior border of the **Ulna**.

Turn all the preceding muscles downwards.

- d. Detach the **Supinator longus**, and **Extensor carpi radialis longior** muscles from the external **Condylloid** ridge and pull them down.
- e. Remove the **Anconeus** muscle.



*f.* Take away the **Triceps** muscle. Do this piecemeal, dissecting out in its substance the **Superior Profunda** artery. A branch will be found running to the back of the external Condyle between the muscle and the bone, and an arch across the back of the bone immediately above the Olecranon fossa to the inner side, joining with the **Anastomotica Magna** artery.

There will now be exposed—

IN FRONT of the outer Condyle—

The **Radial Recurrent** artery, joining with the anterior branch of the **Superior Profunda**.

BEHIND the outer Condyle—

The **Interosseous Recurrent** artery anastomosing with the posterior branch of the **Superior Profunda**, and a branch from the **Anastomotica Magna** coming from the inner side. It sends a branch over the Olecranon to join the **Posterior Ulnar Recurrent** artery.

IN FRONT of the internal Condyle—

A slender branch from the **Anastomotica Magna** artery, uniting with the **Anterior Recurrent** branch of the **Ulnar** artery.

BEHIND the internal Condyle—

The general anastomosis of the **Superior** and **Inferior Profunda** and **Anastomotica** branches of the **Brachial** artery with one another, and with the **Posterior Recurrent** branch of the **Ulnar** artery running up from the forearm.



## A DISSECTION TO EXPOSE THE SUPINATOR BREVIS MUSCLE.

**POSITION.**—During the dissection the forearm should be pronated and supinated as occasion arises. The muscle will be best displayed with the forearm strongly pronated and resting upon its inner border.

### I. SKIN INCISIONS.

1. Transversely from the upper border of the **Olecranon** process of the **Ulna** outwards over the **external Condyle** of the **Humerus** to the centre of the bend of the elbow in front.
2. Transversely from the posterior border of the **Ulna** at its centre round the outer border of the forearm to the **median line** in front.
3. Join the anterior extremities of the preceding by a longitudinal incision along the median line.

Reflect the flap backwards and outwards, and expose the superficial fascia containing—

1. The **Median vein**, its deep communicating branch with the *venæ comites* of the **Brachial artery** at its point of bifurcation, and the lower part of the **Median-cephalic** branch. The **Radial vein** joining the latter.
2. Cutaneous offsets of the **Radial** and **Interosseous Recurrent** arteries in front of and behind the external Condyle respectively. A transverse branch of the latter is found behind the **Olecranon**, and cutaneous twigs of the **Superior Profunda** artery behind the external Condyle.
3. A few of the lowest twigs of the superior **External**



Cutaneous branch of the Musculo-spiral nerve in front of the elbow, and the inferior **External Cutaneous** branch of the same nerve behind the elbow and the forearm.

4. The **External Cutaneous** nerve beneath the Median-Cephalic vein running down the front of the forearm, giving off its posterior branch at the lower part of the dissection.
5. Part of the **Olecranon** process, and the **external Condyle**. The former covered by its bursa.

II. Remove the preceding cutaneous structures and expose the **fascia lata**. Clean this away, and the following structures will be displayed, commencing from the front and passing backwards—

1. The outer part of the insertion of the **Brachialis anticus** muscle.
2. The tendon of the **Biceps** muscle running down to the **Tuberosity** of the **Radius**.
3. The lower part of the **Pronator radii teres** muscle in its whole width below, but only its outer border above.
4. The **Supinator longus** muscle descending from the arm, on the outer side of the forearm. This should be hooked outwards.
5. A small portion of the **Supinator brevis** muscle deep down between the two immediately preceding muscles.
6. The **Extensor carpi radialis longior** muscle outside the **Supinator longus** muscle.
7. The common tendon and upper fleshy portions of the following muscles in their order from without inwards—viz., **Extensor carpi radialis brevior**, **Extensor communis digitorum**, **Extensor minimi di-**



giti, **Extensor carpi ulnaris**, and a portion of the origin of the latter from the posterior border of the Ulna.

8. The **Anconeus** muscle running from the outer Condyle to the outer side of the Olecranon.
9. In front, internal to the Biceps tendon, the lower part of the **Brachial artery** and its division into **Radial** and **Ulnar** branches. The **Radial Recurrent** branch passing up beneath the **Supinator longus** muscle. These arteries are accompanied by their veins.
10. The anterior terminal branch of the **Superior Profunda** artery above, beneath the **Supinator longus** muscle, anastomosing with the **Radial Recurrent**.
11. The **Median nerve** internal to the **Brachial artery**, and its branch to the **Pronator radii teres** muscle.
12. Beneath the **Supinator longus** muscle, but seen by pulling it outwards, the **Musculo-spiral** nerve dividing opposite the external Condyle into **Radial** and **Posterior Interosseous** branches.

### III. Divide now—

- a. The **Supinator longus** and **Extensor carpi radialis longior** muscles, and throw the ends upwards and downwards.
- b. The common **Extensor** tendon, and pull the fleshy bellies of the muscles taking origin from it downwards. Their nerves from the **Posterior Interosseous** will be cut.
- c. The **Pronator teres** muscle, and hook the ends upwards and downwards. The upper portion will carry with it the **Median nerve**.

There will now be exposed—

1. The upper and outer portion of the **Flexor profundus digitorum** muscle.



2. The **Radial** artery, its **Recurrent** branch, and the anterior branch of the **Superior Profunda** artery more fully.
3. Posteriorly, the upper part of the **Posterior Interosseous** artery at its point of emergence below the **Supinator brevis** muscle. The **Recurrent** branch will be seen passing up upon this muscle and beneath the **Anconeus**. Sometimes this offset pierces the **Supinator brevis**.
4. The **Posterior Interosseous** nerve, emerging from the **Supinator brevis** is seen, giving branches to the **Extensor** muscles, which however are divided now, and should have been traced when these muscles were reflected.

## IV.

- a. Remove now the **Radial** vessels and nerve, the **Interosseous Recurrent** artery, and the **Posterior Interosseous** nerve.
- b. Pull inwards or remove some of the outer fibres of the **Anconeus** muscle which slightly overlap the **Supinator brevis** muscle.
- c. Take away that portion of the **Flexor profundus digitorum** muscle which runs up to the **Coronoid** process externally to the **Brachialis anticus** insertion.

The **Supinator brevis** muscle will now be fully exposed.

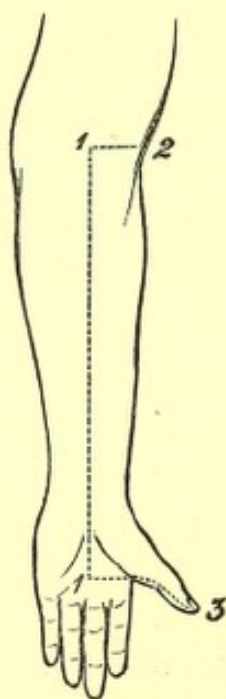


## A DISSECTION TO EXPOSE THE FLEXOR LONGUS POLLICIS MANUS MUSCLES.

**POSITION.**—The forearm supinated, the wrist and thumb extended.

### I. SKIN INCISIONS.

1. Longitudinally along the median line, commencing above at the centre of the forearm opposite to the head of the Radius, and ending below at the middle of the palm of the hand on a level with the upper border of the abducted thumb.



No. 12.<sup>1</sup>

2. Transversely above from the upper end of No. 1 to the outer border of the forearm.
3. Transversely from the lower end of No. 1, along the inner border of the thumb to the tip.

<sup>1</sup> The dotted line is carried a little too far upwards.

Reflect the flap outwards, and expose the superficial fascia containing—

1. Branches of the **Princeps Pollicis** artery on either side of the thumb.
2. The **Radial vein** along the outer border of the forearm.
3. The **Median vein** along the centre, with the deep communicating branch above.
4. The anterior branch of the **External Cutaneous nerve** along the outer border of the forearm.
5. Twigs from the anterior branch of the **Internal cutaneous nerve**.
6. The **Cutaneous Palmar branch** of the **Median nerve** in the middle line just above the **Annular ligament** and passing over it into the palm.
7. **Digital branches** of the **Median nerve** to either side of the thumb.

II. Remove the preceding structures, and expose the **fascia lata**. At the wrist this is seen to be strengthened by transverse fibres, and to constitute in that situation the **Anterior Annular ligament**,<sup>1</sup> being attached internally to the **Unciform** and **Pisiform bones**, and externally to the **Scaphoid** and **Os Trapezium**. On the palm of the hand is seen the posterior part of the **Palmar fascia**, thick in the centre, but thin over the **Thenar eminence**.

III. Remove now the **fascia lata**, except that part forming the **Anterior Annular ligament**. Detach the lateral part of the **Palmar fascia** from the ball of the thumb. There will now be exposed—

1. The **Extensor carpi radialis longior muscle** most externally.
2. Internal to the preceding the **Supinator longus muscle**.

<sup>1</sup> Only the outer part is uncovered.



3. Next the **Pronator radii teres** muscle.
4. Then the **Flexor carpi radialis** muscle.
5. Still more internally the **Palmaris longus**, its tendon passing over the Annular ligament, to be inserted into the Palmar fascia.
6. The outermost tendon of the **Flexor sublimis digitorum** will probably be seen at the lower part.
7. Forming the ball of the thumb are the following muscles: the **Abductor pollicis**, most superficial, running from the lower border of the Annular ligament to the outer side of the base of the proximal Phalanx. The **Opponens** muscle is beneath it, but a small portion is seen at its outer border. The outer head of the **Flexor brevis pollicis** is seen inserted, with the Abductor muscle, into the outer side of the base of the proximal Phalanx. The insertion of the **Adductor** and inner head of the **Flexor brevis pollicis** muscles is seen at the inner side of the base of the proximal Phalanx.
8. Some of the fleshy fibres of the **Flexor longus pollicis** muscle are seen between the tendons of the **Supinator longus** and **Flexor carpi radialis** muscles, and its tendon emerging from between the two heads of the **Flexor brevis pollicis** to its insertion into the ungual Phalanx of the thumb.
9. A small piece of the **Pronator quadratus** muscle internal to the **Supinator longus** tendon, on the lower two inches of the Radius.
10. The **Radial artery** is seen to be overlapped above by the **Supinator longus**, and to be superficial below between the tendon of that muscle and that of the **Flexor carpi radialis longior**. It is found to give off muscular offsets, and the **Superficial Volar** branch, over



or between the muscles of the Thenar eminence, and to be accompanied by two *venæ comites*.

11. The **Radial nerve** is seen to lie on the outer side of the artery as far as about three inches above the wrist.
12. A small piece of the **Median nerve** is seen just above the wrist, between the **Flexor carpi radialis** and outermost **Flexor sublimis** tendons.

#### IV.

- a. Remove the outer part of the **Anterior Annular ligament**, and take away the central thick portion of the **Palmar fascia** as far as it is exposed, having previously divided the insertion of the **Palmaris longus** muscle into it.
- b. Remove the exposed portion of the **Pronator radii teres** muscle.
- c. Cut through the **Flexor carpi radialis** above and below, and remove it. Its nerve from the **Median** will be divided.
- d. Cut the **Palmaris longus** above and remove it.

There will now be exposed—

1. The outer portion of the **Flexor sublimis digitorum** muscle, its origin from the oblique line and upper three fourths of the anterior border of the **Radius**; its four tendons passing over the **Carpal bones** in pairs (the tendons of the middle and ring fingers being in front), and spreading out in the palm to the fingers. The two innermost are not seen.
2. A further portion of the **Flexor longus pollicis** muscle above the wrist.
3. The **Pronator quadratus** muscle more fully.
4. In the palm, the tendons of the **Flexor profundus** muscle<sup>1</sup> beneath those of the **Flexor sublimis**, and

<sup>1</sup> The two outermost only are seen.



the two outer **Lumbricales** muscles arising from the outer side of those going to the index and middle fingers. These tendons, as well as those of the superficial **Flexor** muscle, are surrounded by synovial membrane.

5. The outer portion of the **Superficial Palmar arch** is seen, and just the commencement of the branch to the contiguous sides of the index and middle fingers.
6. The **Median nerve** is seen in the palm, somewhat enlarged and divided into two parts. The outer division supplies branches to the **Abductor**, **Opponens**, and outer head of **Flexor brevis pollicis** muscles, and two **Digital** branches to the outer and inner borders of the thumb, and a single branch to the outer side of the index. This last branch is only seen at its origin. The commencement of the branch of the inner division, which divides for the contiguous sides of the index and middle fingers, also comes into view. The twigs to the exposed **Lumbricales** muscles from the two last-mentioned branches may be traced. The nerves here lie beneath the artery.

## V.

- a. Divide now the outer division of the **Median nerve**, and the **Superficial Palmar arch**.
- b. Clean away the synovial membrane from the **Flexor** tendons.
- c. Divide the **Flexor sublimis** muscle longitudinally along its whole length. Cut through the index and middle tendons, and reflect the **Radial** origin of the muscle outwards.

The **Flexor longus pollicis** muscle will now be fully ex-

posed by opening up the Palmar sheath of its tendon ; and the occasional slip from the inner part of the Coronoid process of the Ulna may be traced.

In addition there will be seen—

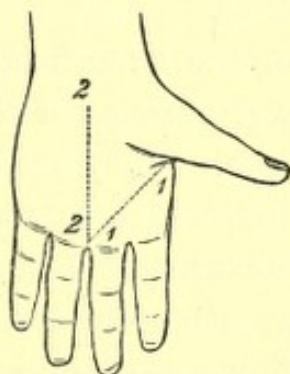
1. The outer part of the *Flexor profundus digitorum* muscle in the forearm.
2. The *Median nerve* in the forearm with its branches to the *Flexor sublimis* muscle.

### A DISSECTION OF THE ANTERIOR SURFACE OF THE ADDUCTOR POLLICIS MANUS MUSCLE.

POSITION.—The hand lying upon its dorsal surface, the thumb strongly abducted and rotated outwards.

#### I. SKIN INCISIONS.

1. From the inner border of the base of the proximal Phalanx of the thumb to the inner border of the root of the middle finger.



No. 13.

2. Along the median line from the inner end of the preceding to a point half an inch in front of the wrist.

Reflect the flap backwards and expose the superficial fascia containing granular fat, and—



1. Cutaneous branches of artery from the Superficial Palmar arch.
2. Branches of the Musculo-cutaneous nerve over the ball of the thumb.
3. The Cutaneous Palmar branch of the Median nerve at the centre of the wrist.

II. Remove and expose the central thick, and the outer thin portions of the Palmar fascia, and the digitations of the former to the second and third fingers.

III. Remove the preceding and expose—

1. The inner tendon of insertion of the Flexor brevis pollicis muscle, and conjoined with it on its inner side the insertion of the Adductor pollicis muscle.
2. The tendon of the Flexor longus pollicis muscle will be seen on the outer side of the preceding, owing to the retraction of the skin.
3. A small piece of the Abductor indicis muscle in front of the Adductor pollicis muscle on the outer side of the index finger.
4. The tendons of the superficial and beneath them of the deep Flexor muscles of the fingers to the second and third digits. They are seen passing into their special sheaths, which extend half an inch into the palm. The Lumbricales muscles of the index and middle fingers are seen, and on the removal of the superficial Flexor tendons are found to arise each from two tendons of the deep. ?
5. The Princeps Pollicis artery is seen on the thumb, and also its bifurcation.
6. The Radialis Indicis artery on the outer side of the index finger.
7. The outer portion of the Superficial Palmar arch,



formed by the Superficial part of the Ulnar artery, joining with the Superficialis Volæ branch of the Radial, and a very constant communication with the Radialis Indicis artery. A branch of the arch is seen bifurcating for the contiguous sides of the index and middle fingers.

8. Single branches of the Median nerve to the inner side of the thumb and the outer side of the index finger; and one which bifurcates for the contiguous sides of the index and middle digits. The two inner of these branches are found to supply the two outer Lumbrical muscles.

The arteries in the palm are superficial to the nerves.

#### IV. Remove—

- a. The Superficial Palmar arch and its branches.
- b. The branches of the Median nerve to the index and middle fingers.
- c. Divide the Flexor tendons of the fingers and pull them forwards.

There will now be exposed—

1. The Adductor pollicis muscle arising from the anterior two thirds of the Metacarpal bone of the middle finger, and inserted into the inner side of the base of the proximal Phalanx of the thumb.
2. In front of this, the Abductor indicis muscle on the outer side of the index finger, and the lower part of the Palmar and Dorsal Interossei muscles of the second space; arching over their lower parts the piece of the Transverse Metacarpal ligament between the heads of the second and third Metacarpal bones.
3. The inner fleshy head of the Flexor brevis pollicis, and its tendinous insertion (often containing a sesa-



moid bone), conjoined with the insertion of the Adductor pollicis muscle.

4. A very small piece of the outer part of the Deep Palmar arch between the Flexor brevis and Adductor pollicis muscles at their inner parts.
5. The Deep branch of the Ulnar nerve supplying the inner head of the Flexor brevis and Adductor pollicis muscles.

### A DISSECTION TO EXPOSE THE DEEP PALMAR ARCH AND ITS BRANCHES.

POSITION.—The hand lying upon its dorsal aspect with the thumb strongly abducted, and the fingers extended.

#### I. SKIN INCISIONS.

1. Along the median line of the palm from the line marking the junction of the wrist with the forearm, to the centre of the root of the middle finger.
2. Transverse incisions from the upper end of No. 1, to the inner and outer borders of the forearm respectively.
3. Transverse incisions from the lower end of No. 1, along the roots of the fingers to the inner and outer borders of the hand.

Reflect the flaps inwards and outwards, and expose the superficial fascia, containing granular fat, and—

1. The Superficial Transverse ligament across the roots of the fingers.
2. The Palmaris brevis muscle, along the inner border of the hand.



3. The filaments of the Musculo-cutaneous nerve over the ball of the thumb.
4. The Cutaneous Palmar branch of the Median nerve, passing down over the centre of the Annular ligament and along the centre of the palm, and communicating with
5. The Cutaneous Palmar branch of the Ulnar nerve, which lies over the Ulnar artery and supplies the skin of the inner border of the hand.
6. Unnamed twigs of the Median and Ulnar nerves to the skin of the palm, and small branches of artery from the Superficial Palmar arch.

II. Remove the superficial fascia, the cutaneous nerves, and the Palmaris brevis muscle. The branch of nerve to the muscle from the Ulnar will be divided.

There will now be exposed—

1. The Anterior Annular ligament across the wrist.
2. The Palmar fascia. This will be seen to be made up of three divisions, a central thick triangular portion, and two lateral parts covering the Thenar and Hypothenar eminences. The central portion has its apex at the Annular ligament, and its base is cut into four processes, one for each of the fingers. These are connected together by the Superficial Transverse ligament which crosses them at the roots of the fingers.
3. The commencements of the sheaths of the Flexor tendons are seen, and these are found to be joined by the Digital processes of the Palmar fascia.
4. The tendon of the Palmaris longus muscle is seen passing over the Annular ligament to join the apex of the central triangular division of the Palmar fascia.



5. In the intervals of the four Digital processes of the Palmar fascia, the following structures are seen:—

*a.* Small portions of the **Lumbricales** muscles in each space.

*b.* The **Digital** vessels, and nerves. Those supplying the outer side of the index and the inner side of the little fingers emerge from the Palmar fascia further back than the others. The nerves are superficial to the arteries at the clefts of the fingers. The origins of the vessels and nerves are not traceable at this stage.

6. The **Ulnar** artery and nerve are found beneath the **Palmaris brevis** muscle, lying at first upon the **Annular** ligament, and then passing beneath the Palmar fascia. The nerve is on the **Ulnar** side of the artery.

III. Remove now the three portions of the **Palmar fascia** and the **Superficial Transverse ligament**. This must be done carefully, so as to avoid cutting the various vessels and nerves, which are now to be traced to their several origins. There will now be exposed—

1. The small muscles of the thumb. The **Abductor** most superficial. The outer head of the **Flexor brevis** along its inner border. A small piece of the **Opponens** along its outer border, close to the **Annular** ligament. A small portion of the **Adductor** running transversely in the cleft between the thumb and index finger, internal to the **Flexor brevis pollicis**.

2. The small muscles of the little finger. The **Abductor** most internal. The **Flexor brevis** along the outer side of the preceding.



3. A small piece of the **Abductor indicis** muscle along the Radial side of the index finger, emerging from beneath the **Adductor pollicis** muscle.
4. The tendons of the **Flexor sublimis digitorum** muscle, entering their sheaths on the four fingers.
5. The four **Lumbricales** muscles, the first on the Radial side of the index tendon of the **Flexor sublimis digitorum** muscle, and the others in the intervals between the tendons.
6. The **Superficial Palmar arch** and its **venæ comites** crossing transversely the **Flexor** tendons on a level with the upper border of the abducted thumb. It is formed for the most part by the **Ulnar artery**, and is completed internally by the **Superficialis** *Externally* **Volæ** branch of the **Radial artery**, and by a communication with the **Radialis Indicis** artery. The first of these two last vessels is usually very small and even inconstant, when present it passes over or through the short muscles of the thumb. From the convexity of the arch, which is directed towards the fingers, the **Digital branches** arise. These are four in number, a single one to the inner side of the little finger, and three others which bifurcate for the contiguous sides of the ring and little, and two next digits. From the concavity of the arch arise small branches to the palm, which have been divided. Close to the lower border of the **Annular ligament** the **Profunda** branch of the **Ulnar artery** arises, and is seen passing between the **Flexor brevis** and **Abductor minimi digiti** muscles.
7. Issuing from beneath the **Flexor brevis** and **Adductor pollicis** muscles, and lying upon the **Abductor indicis** muscle is seen the **Radialis Indicis** branch



of the Radial artery, along the outer side of the first finger. The commencement of the *Princeps Pollicis* branch of the same artery may be seen just at the cleft of the thumb and index finger.

8. The Ulnar nerve is seen to divide close to the lower border of the Annular ligament into a Superficial and Deep branch. The Deep branch passes, with the corresponding branch of the Ulnar artery, between the Flexor brevis and Abductor minimi digiti muscles. The Superficial branch supplies an undivided offset to the inner side of the little finger, and a bifurcated branch to the contiguous sides of this digit, and the next. This last branch also sends an offset of communication beneath the Ulnar artery to the Median nerve. The branches from the Superficial division of the Ulnar nerve to the Palmaris brevis, and integument of the inner border of the palm are, of course, divided.
9. The Median nerve is seen passing from beneath the lower border of the Annular ligament lying upon the Flexor tendons. Just at this point it is found to be flattened out, and divided into two parts of nearly equal size. From the outer part filaments are traceable to the Abductor, Opponens, and outer head of the Flexor brevis pollicis muscles, and the following Digital branches,—viz., two undivided, one for each border of the thumb, and a third also single, for the Radial border of the index finger. This last also supplies the outermost Lumbrical muscle. The inner division supplies two branches which bifurcate for the contiguous sides of the index and middle, and middle and ring fingers; the outermost of these two supplies the next



Lumbrical muscle, the innermost communicates with the Ulnar nerve, as mentioned above.

The branches of the Median nerve lie beneath the Superficial Palmar arch.

#### IV.

- a. Divide now the **Superficial Palmar arch**, both internally and externally, raise the included piece, draw it with the Digital branches toward the fingers, and fix it there.
- b. Cut through the **Superficial branch of the Ulnar nerve**, and throw it towards the fingers.
- c. Divide the **Median nerve** at the lower border of the **Annular ligament**, and bring it also over the fingers, cutting through its branches to the muscles of the thumb and two outer Lumbrical muscles.
- d. Cut through the origin of the **Flexor brevis minimi digiti** muscle from the **Annular ligament** and **Unciform process**, and throw it forwards. Its nerve from the **Deep branch of the Ulnar** will be divided.
- e. Remove the central portion of the **Anterior Annular ligament** with the portion of the tendon of the **Palmaris longus** muscle which passes over it.
- f. Cut through the tendons of the **Flexor sublimis digitorum** muscle, and throw them towards their respective fingers. Beneath the **Annular ligament** they will be found to be arranged in pairs, the two to the middle and ring fingers being superficial to the other two.

There will now be exposed—

1. The **Adductor minimi digiti** muscle, beneath the **Flexor brevis minimi digiti** muscle.
2. The tendons of the **Flexor profundus digitorum** muscle,



passing into the Digital sheaths beneath the Flexor sublimis tendons.

3. The **Lumbricales** muscles more fully. The two innermost will be found arising from the contiguous sides of the tendons of the little, ring, and middle fingers. The two outermost from the Radial sides of the tendons of the middle and index fingers respectively.
4. Further portions of the **Profunda** branches of the **Ulnar** artery and nerve. Two slender twigs from this portion of the nerve are traceable to the two innermost **Lumbricales** muscles.

## V.

- a. Divide the tendons of the **Flexor profundus digitorum** muscle, and throw them towards the fingers with the **Lumbricales** muscles attached. The nerves to the two innermost of these latter muscles from the Deep branch of the **Ulnar** will be torn through.
- b. Divide the origin of the **Adductor minimi digiti** from the **Unciform** process and **Annular** ligament, and turn the muscle inwards. Its nerve from the Deep branch of the **Ulnar** will be divided.

There will now be exposed—

1. The **Interossei** muscles of the third and fourth spaces, a **Palmar** and **Dorsal** in each, the former on the Radial side of the latter. These muscles are covered by their fascia.
2. The **Adductor pollicis** muscle more fully, arising from the anterior two thirds of the **Metacarpal** bone of the middle finger, and passing outwards to the thumb. It hides the **Palmar** and **Dorsal Interossei** of the second space, except at their anterior ends.



3. The inner head of the *Flexor brevis pollicis* muscle, arising from the Trapezoid bone, the *Os Magnum*, the base of the third Metacarpal bone, and the sheath of the *Flexor carpi radialis* tendon. It passes outwards to the thumb parallel with the upper border of the immediately preceding muscle.
4. The tendon of the *Flexor longus pollicis* muscle between the two heads of the short *Flexor*.
5. The greater part of the Deep Palmar arch, *i.e.*, the Deep branch of the Ulnar artery, is seen to join the Radial.
6. The Deep branch of the Ulnar nerve is seen accompanying the corresponding branch of the artery, and ending in branches to the *Adductor pollicis* and the inner head of the *Flexor brevis pollicis*. Its twig to the *Abductor minimi digiti* muscle may be traced, but those to the *Flexor brevis* and the *Adductor minimi digiti* muscles are divided. Offsets to all the *Interossei* muscles may be found.

#### VI. To complete the dissection—

Remove the inner head of the *Flexor brevis pollicis* muscle from its origin, and throw it towards the thumb. Its nerves will be divided.

This will expose—

1. The upper portions of the Palmar and Dorsal *Interossei* of the second space.
2. A further portion of the *Abductor indicis* muscle, previously covered by the inner head of the *Flexor brevis pollicis* muscle.
3. The whole of the Deep Palmar arch, which will be found to be formed in this way. The Radial artery is seen entering the palm at the back of the first interosseous space, between the two heads of origin



of the Abductor indicis muscle. It runs transversely across the palm, lying upon the bases of the Metacarpal bones and the Interossei muscles, above the upper border of the Adductor pollicis muscle; and joins at the inner part the Deep branch of the Ulnar artery. It forms an arch about half an inch nearer the wrist than the superficial one. From its concavity Recurrent branches are traceable up to the wrist to join the Anterior Carpal arch. From its convexity proceed three arteries which occupy the three inner interosseous spaces, and run forwards to the clefts of the fingers to join the Digital branches of the superficial arch. From these Interosseous branches three Perforating offsets to the Interosseous arteries of the back of the hand are traceable.

4. Further portions of the Radialis Indicis and Princeps Pollicis arteries, previously covered by the inner head of the Flexor brevis pollicis, are displayed.

### A DISSECTION TO EXPOSE THE INTEROSSEOUS ARTERY, ITS BRANCHES AND THEIR ANASTOMOSES.

POSITION.—Both surfaces of the forearm will be dissected, so that it must be pronated or supinated as occasion arises.

#### I. SKIN INCISIONS.

1. A circular incision round the arm, at the level of the external Condyle of the Humerus.
2. An incision more or less circular, which corre-



sponds in front to the line between the forearm and palm, but posteriorly runs a little lower down along the bases of the Metacarpal bones.

3. A median incision, joining the two preceding above and below, running down the anterior surface of the forearm.

Remove the whole of the skin of the forearm between these limits, and expose the superficial fascia, containing—

IN FRONT—

1. The Median vein, its bifurcation into Median-cephalic and Median-basilic branches, and its junction at the division with the Deep Median branch communicating with the venæ comites of the Brachial artery.
2. The Radial vein commencing below at the back of the forearm, but soon winding round the outer border and joining above the Median-cephalic vein.
3. The Anterior Ulnar vein running up the inner border of the forearm, receiving above the Posterior Ulnar vein, which lower down is placed on the posterior surface, but above winds round to the front to join the Anterior Ulnar vessel. The vein resulting from this junction is seen entering the Median-basilic.
4. The anterior branches of the Internal Cutaneous nerve, some of which usually pass over, and some beneath the Median-basilic vein to supply the skin of the inner border of the forearm as far as the wrist.
5. The anterior branch of the External Cutaneous nerve, usually passing beneath the Median-cephalic vein and supplying the skin of the outer part of the forearm, within the whole limits of the surface exposed.
6. Twigs of the upper External Cutaneous branch of the Musculo-spiral nerve reach the upper and outer



part of the anterior surface of the bend of the elbow.

7. The **Palmar Cutaneous branch of the Median nerve** is seen piercing the fascia about the centre of the forearm just above the wrist.
8. The **Palmar Cutaneous branch of the Ulnar nerve** lies over the line of the Ulnar artery, and pierces the fascia lata just above the wrist. Sometimes a second branch is cutaneous higher up, and joins the anterior branch of the Internal Cutaneous nerve.

BEHIND—

9. The lower portions of the **Radial and Posterior Ulnar veins**, as mentioned above.
10. The posterior branch of the **Internal Cutaneous nerve**, supplying about the upper half of the internal portion of the forearm.
11. The posterior branch of the **External Cutaneous nerve** supplying about the lower third of the outer border of the forearm.
12. Twigs of the lesser **Internal Cutaneous nerve**, between the internal Condyle and the Olecranon process, and a junction with the posterior branch of the Internal Cutaneous nerve.
13. The lower **External Cutaneous branch of the Musculo-spiral nerve**, supplying the skin of the back of the forearm, between the Internal and External Cutaneous nerves as far as the wrist, and communicating with the latter.
14. The **Radial nerve**, cutaneous between from two to three inches above the wrist, and its points of division into branches for the thumb, the next two, and half the ring fingers.



15. The Dorsal branch of the Ulnar nerve, perforating on the inner side at a lower point than the Radial, and its points of division into branches for the remaining finger and a half.

## II.

- a. Remove the preceding, and expose the fascia lata, joined above in front of the bend of the elbow, by the semilunar process from the tendon of the Biceps muscle. Behind the wrist it is seen to be strengthened by transverse fibres, and to constitute the Posterior Annular ligament.
- b. Clear away the deep and Bicipital fascia, and expose—

## IN FRONT—

1. Above, the lower part of the triangular space of the bend of the elbow, bounded: *externally*, by the Supinator longus muscle; *internally*, by the Pronator radii teres muscle; and having the *floor* formed by the lower part of the Brachialis anticus muscle and a small portion of the Supinator brevis muscle. It contains—
2. The tendon of the Biceps muscle running down to the Tuberosity of the Radius, most externally.
3. The Brachial artery, surrounded by its *venæ comites*, placed internal to the Biceps tendon. The division of the artery into Radial and Ulnar branches is seen, and the commencement of the Radial Recurrent branch.
4. The Median nerve is exposed inside the artery, and its branch to the Pronator radii teres muscle may be traced.
5. Internal to the Pronator radii teres muscle is seen the Flexor carpi radialis muscle, as far as the wrist.



6. The *Palmaris longus* muscle, next internally, and
7. The *Flexor carpi ulnaris* muscle, innermost of all.
8. At the wrist between the tendons of the two preceding muscles, those of the *Flexor sublimis digitorum* muscle come into view.
9. Small portions of the *Pronator quadratus* muscle are seen below on the *Radius* and *Ulna*.
10. The *Radial* artery and its *venæ comites* are exposed farther than has been indicated above,—viz., as low down as the wrist. At first it lies in the triangular space, then crosses over the insertion of the *Pronator teres* muscle, and finally lies between the *Supinator longus* and *Flexor carpi radialis* tendons.
11. The *Ulnar* artery with its veins is seen for about its lower third, below and internally, passing from beneath the fleshy portion of the *Flexor carpi ulnaris* muscle, and running on the outer side of its tendon as far as the wrist.
12. The *Radial* nerve is seen external to its artery, as far as about three inches above the wrist. It is overlapped above by the fleshy part of the *Supinator longus* muscle.
13. The *Ulnar* nerve lies on the inner side of the lower exposed portion of the corresponding artery, as far as the wrist.
14. A further small portion of the *Median* nerve is seen, just above the wrist, between the *Flexor carpi radialis* and outermost tendon of the *Flexor sublimis digitorum*.

BEHIND—

15. The *Anconeus* muscle, passing between the external Condyle, and the outer surfaces of the *Olecranon*



process and the upper part of the shaft of the Ulna.

The following muscles from without inwards—

16. The **Supinator longus**.
17. The **Extensor carpi radialis longior**.
18. The **Extensor carpi radialis brevior**.
19. The **Extensor communis digitorum**.
20. The **Extensor minimi digiti**.
21. The **Extensor carpi ulnaris**.

At the lower part, passing out between the **Extensor communis digitorum** and **Extensor carpi radialis brevior** tendons, are—

22. The **Extensor ossis metacarpi and primi internodii pollicis** muscles.
23. The **Posterior Interosseous artery** is seen on the outer side of the **Extensor carpi ulnaris** tendon for about the lower third of the forearm, accompanied by its vein.

### III.

IN FRONT—

- a. Divide the **Pronator radii teres** muscle at its insertion, and at its origin from the Coronoid process, and pull it upwards, cutting through at the same time the **Anterior Ulnar Recurrent artery** and the **Median nerve**.
- b. Cut through the tendons of the **Palmaris longus** and **Flexor carpi radialis** muscles at the wrist, and pull these muscles upwards. Their nerves from the **Median** will be divided, and arterial twigs from the **Radial** and **Ulnar**.

There will now be exposed—

1. The **Flexor sublimis digitorum** muscle, its origin above from the internal Condyle, the inner side of the



Olecranon, the oblique line and upper three fourths of the anterior border of the Radius; and its tendons below as far as the wrist.

2. A small portion of the tendon of the **Flexor longus pollicis** muscle below, lying upon the lower part of the Radius.

IV. Divide the fleshy belly of the **Flexor sublimis digitorum** muscle by a longitudinal incision along the middle line, and hook the halves inwards and outwards. The **Median** nerve has already been cut, but branches from it to this muscle and arterial twigs from the **Ulnar** will be divided.

There will now be exposed—

1. The **Flexor profundus digitorum** muscle, lying upon the **Ulna** and the corresponding half of the **Interosseous** membrane.
2. The **Flexor longus pollicis** muscle, concealing the anterior surface of the **Radius** and the outer part of the **Interosseous** membrane. Its occasional head from the inner part of the **Coronoid** process will be seen if present.
3. A further portion of the **Ulnar** artery is now seen lying upon the **Brachialis anticus** and **Flexor profundus digitorum** muscles, and the following branches: the **Anterior** and **Posterior Ulnar Recurrent** branches, the former being cut, the **Common Interosseous** trunk giving off **Anterior** and **Posterior Interosseous** branches, the former seen passing between the **Flexor profundus** and **longus pollicis** muscles, and the latter going to the back of the forearm.
4. All these arteries have corresponding veins.
5. The **Median** nerve lying upon the **Flexor profundus** muscle, accompanied by the
6. **Comes nervi Mediani** artery at the lower part.



V. Separate now the **Flexor longus pollicis** muscle from the **Flexor profundus digitorum** muscle, dissect off their origins from the Interosseous membrane, and pull the former well outwards and the latter inwards. The occasional head of origin of the **Flexor longus pollicis** must be cut through if present.

There will now be exposed—

1. The **Interosseous membrane**.
2. The **Pronator quadratus** muscle in the greater part of its extent.
3. The **Anterior Interosseous artery** lying upon the membrane, and disappearing below beneath the **Pronator quadratus** muscle. Its twigs to the muscles between which it lies, the origin of the **Comes nervi Mediani** artery, and the nutrient arteries to the **Radius** and **Ulna** may now be traced from it. The **Posterior Interosseous artery** may be traced above, passing to the back of the forearm between the **Oblique ligament** and the upper margin of the **Interosseous membrane**.
4. The **Anterior Interosseous nerve** is found with the artery of the same name, and its several branches to the **Flexor profundus** and **longus pollicis** muscles are traceable, if they have not been torn through in separating these muscles.

VI. To expose the artery beneath the **Pronator quadratus** muscle, one of two courses may be taken, viz., A or B.

- (A) *a.* Separate the tendons of the **Flexor profundus** muscle well from that of the **Flexor longus pollicis** muscle as far as the upper border of the **Anterior Annular ligament**, and draw them by hooks on either side.
- b.* Divide the **Pronator quadratus** muscle longitudi-



nally, and reflect the halves inwards and outwards.

In this way there will be exposed—

1. The anterior surface of the wrist-joint and its ligaments.
  2. The **Anterior Carpal arch**, derived from the Radial and Ulnar arteries.
  3. The **Anterior Interosseous artery** passing to the back of the forearm beneath the Interosseous membrane, but sending down a branch to anastomose with the Anterior Carpal arch.
- (B) *a.* Divide the tendons of the superficial and deep **Flexor muscles** of the fingers at the Annular ligament, dissect them up for some distance and hook them inwards.

The same parts enumerated under A will be exposed, but more completely.

The **Anterior Interosseous artery** is now fully exposed except at its ending. To see this, and to trace the **Posterior artery**, the forearm should now be supinated. The structures exposed by the removal of the fascia lata have been enumerated under Section II.

BEHIND—

## VII.

- a.* Remove the **Posterior Annular ligament**.
- b.* Separate the **Extensor communis digitorum** muscle from the **Extensor carpi radialis brevis** muscle as high as the external Condyle, cut through its Condylod origin and reflect the muscle downwards as far as the bases of the Metacarpal bones.
- c.* Cut through the origin of the **Extensor minimi digiti**, and reflect it down to the same extent.



- d.* Divide the origin of the **Extensor carpi ulnaris** from the external Condyle and the deep fascia as low down as its attachment to the posterior margin of the Ulna, and hook the muscle inwards. **Branches** of the **Posterior Interosseous** nerve will be cut through in the division of these muscles, together with twigs from the artery of the same name.
- e.* Remove the **Anconeus** muscle, taking care of the artery which will be found beneath it.

There will now be exposed—

1. The posterior surface of the **Supinator brevis** muscle, highest of all.
2. Next below, the **Extensor ossis metacarpi pollicis** muscle, arising from the Radius and Ulna.
3. Next, the **Extensor primi internodii pollicis** muscle, arising from the Radius.
4. Still lower, the **Extensor secundi internodii pollicis** muscle, arising from the Ulna.
5. Lowest of all, the **Extensor indicis** muscle, from the Ulna.
6. The **Posterior Interosseous** artery, passing from the front, between the **Supinator brevis** and **Extensor ossis metacarpi pollicis** muscles, and running down the forearm along the outer side of the tendon of the **Extensor carpi ulnaris**, lying upon the other **Extensors** of the thumb, and that of the index finger. The **Recurrent branch** uncovered by the removal of the **Anconeus** muscle is seen passing upwards, lying first upon the **Supinator brevis** muscle and then upon the Ulna, anastomosing above with the posterior branch of the **Superior Profunda** artery, and communicating across the **Olecranon** with the **Pos-**



terior Ulnar Recurrent artery. The corresponding veins are seen.

7. The **Posterior Interosseous nerve** is displayed, coming through the **Supinator brevis** muscle, dividing into branches for the **Extensor** muscles, and disappearing below beneath the **Extensor secundi internodii pollicis**.

VIII. Divide now the **Extensor secundi internodii pollicis** and **Extensor indicis** muscles. Remove the fleshy portions and pull the tendons outwards. This will expose—

1. The termination of the **Anterior Interosseous artery**.
2. The **Posterior Carpal arch**.
3. The communication between the two preceding, and the branch from the **Posterior Interosseous artery**, which joins the **Anterior**, and the **Carpal arch**.
4. The further portion of the **Posterior Interosseous nerve**, and its gangliform enlargement.

IX. To see the origin of the **Posterior Interosseous artery** from the common trunk, remove, if necessary, a portion of the lower margin of the **Supinator brevis** muscle.

### A DISSECTION TO EXPOSE THE OBTURATOR NERVE COMPLETELY.

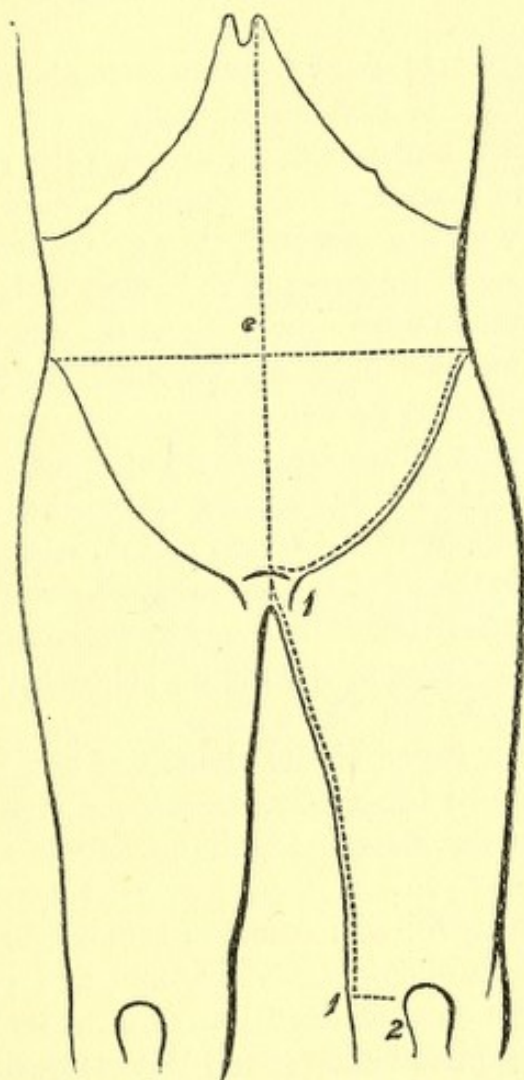
POSITION.—The body supine, the thigh of the side dissected to be abducted, rotated out, and slightly flexed.

I. The **Abdomen** is to be opened by a crucial incision, and the lower flap on the side to be dissected removed by an incision parallel with and a little above the line of Pou-



part's ligament, then inwards to the median line, the other flaps to be turned outwards and fixed.

In the flap cut away there will be removed the following structures in layers, lettered A, B, C, D, E, F, G, H, K.<sup>1</sup>



No. 14.

A. Skin.

B. **Superficial fascia** in two layers at the lower part.

<sup>1</sup> Paragraphs A, B, C, D, E, F, G, H, K have been printed in smaller type because the anatomy of this flap is not an essential part of the dissection: nevertheless, it is a good plan to mention every structure divided or removed which is visible to the naked eye.



**Superficial Pudic artery and vein** passing inwards over the cord.

**Superficial Epigastric artery and vein** passing upwards over the centre of Poupart's ligament.

**Superficial Circumflex Iliac artery and vein**, sending twigs over the lower part of the Abdomen at the outer part.

**Ilio-hypogastric nerve**, cutaneous about one inch above the external Abdominal ring.

**Ilio-inguinal nerve** coming through the ring.

**Lymphatic glands** along Poupart's ligament.

One or two of the **lower Anterior Cutaneous nerves** accompanied by twigs of the **Deep Epigastric artery**.

The **Spermatic cord** emerging at the ring.

C. The **aponeurosis of the External Oblique muscle**, with the following parts:—

**External ring** above and outside the spine of the Pubes.

**Intercolumnar fibres** crossing transversely the lower fibres of the aponeurosis, which run downwards and inwards, and the fascia of the same name covering in the ring.

The **Triangular fascia** belongs to this muscle, but is seen in the next layer as it runs up beneath the inner pillar of the ring to the Linea alba.

The **anterior layer of the sheath of the Rectus muscle** is seen more internally, consisting partly of the aponeurosis of the External Oblique muscle and partly of the next.

D. The **Internal Oblique muscle** in its origin from about the outer half of Poupart's ligament and part of its origin from the crest of the Ilium, and in its insertion to the Linea alba and crest of the Pubes forming the rest of the anterior layer of the sheath of the Rectus muscle as far as half way between the Umbilicus and Pubic crest, but reinforced by the **aponeurosis of the Transversalis muscle** below that point. Above this the aponeurosis splits into two layers, one of which passes in front and one behind the Rectus muscle. The **Conjoined tendon** of this and the next succeeding muscle at its insertion into the Ilio-pectineal line.



The **Cremaster muscle** in front of the cord.

Further portions of the **Ilio-hypogastric and Ilio-inguinal nerves** which lie between the Oblique muscles.

A further portion of the cord.

- E. The **Transversalis muscle**, in its origin from the outer third of Poupart's ligament, and part of its origin from the Iliac crest, and its insertion into the Linea alba and Pubic crest, forming the rest of the anterior layer of the sheath of the Rectus muscle below the point indicated, but above that extending into the Linea alba behind the muscle.

The **fascia Transversalis** outside the Conjoined tendon and its Infundibuliform process hiding the internal ring.

- F. The Rectus and Pyramidalis muscles, the latter in front of the lower part of the former.

- G. The **fascia Transversalis**.

The **Deep Epigastric vessels** running up internal to the ring and behind the Rectus muscle, giving off and receiving the Pubic branches.

The **Deep Circumflex Iliac vessels**, running out parallel with Poupart's ligament.

The **obliterated Hypogastric artery**, corresponding in its position with the Epigastric, but on its deep surface.

- H. **Subperitoneal fat**.

- K. **Peritoneum**.

## II. NOW DISSECT THE PART OF THE NERVE IN THE THIGH.

### SKIN INCISIONS.

1. From the crest of the Pubes at the centre, down the Symphysis and along the inner part of the thigh to the posterior part of the internal Condyle of the Femur.
2. Transversely from the lower end of the preceding to the fore part of the Condyle.

Reflect the flap outwards as far as the line of the Femoral artery.



This exposes the superficial fascia which below Poupart's ligament internal to the Saphenous vein, is found to consist of two layers. At this point it conceals the Saphenous opening, and being perforated by lymphatics is called the Cribiform fascia.<sup>1</sup> This fascia contains the following—

1. The Long Saphenous vein, running up along the inner and front part of the thigh, and receiving at the upper part the Superficial Pudic, Epigastric, and Circumflex Iliac branches, and the cutaneous veins of the inner and back part of the thigh united into one trunk, which enters the Saphenous near the opening of that name. Sometimes the veins of the outer part of the thigh unite in a similar manner and join it near the same spot.
2. The cut ends of the Superficial Pudic, Epigastric, and Circumflex Iliac arteries, and a cutaneous twig of the Anastomotica Magna artery in front of the inner Condyle.
3. The branch of the Ilio-inguinal nerve to the skin of the upper and inner third of the thigh.
4. The Internal Cutaneous nerve perforating the fascia lata at the junction of the lower with the middle third. Smaller twigs of the nerve are cutaneous above this along the Saphenous vein, one or two about the Saphenous opening, and another half-way down.
5. Numerous lymphatic vessels in the front of the thigh, and a chain of glands along Poupart's ligament.

### III. Remove and expose—

1. Poupart's and Gimbernat's ligaments.
2. The fascia lata of the thigh, presenting at the upper

<sup>1</sup> This is the deeper of the two layers.



and inner part, immediately below Poupart's ligament, the Saphenous opening.

IV. Clear these structures away and expose—

1. The Pectineus muscle at the upper and outer part of the dissection.
2. If this muscle be separated from the next succeeding, the Adductor brevis muscle is seen in small part, and lying upon it the three muscular branches of the Superficial division of the Obturator nerve.
3. The Adductor longus muscle below and internal to the preceding. A branch of the Superficial division of the Obturator nerve is found lying along its inner \* border.
4. The Gracilis muscle most internal, descending from the Ramus of the Pubes and flattened against the Adductor muscles.
5. The Adductor magnus muscle, the lower fleshy fibres and tendon, below the Adductor longus muscle.
6. The Sartorius muscle at the lower part of the thigh, external to the Adductors longus and magnus muscles.
7. A small piece of the Vastus internus muscle, external to the Adductors longus and magnus, and overlapped below by the Sartorius muscle.
8. The special funnel-shaped sheath of the Femoral vessels is seen above, reaching for two inches below Poupart's ligament. This may now be cleaned away at once, and then the Femoral artery with the vein internal to it may be seen until they are covered by the Sartorius muscle. The Inferior External Pudic branch is seen passing inwards over the Pectineus, and the ending of the Deep



branch of the *Anastomotica Magna* artery lying with the tendon of the *Adductor magnus* muscle. The vein corresponding to the *Inferior Pudic* branch is cut inasmuch as it joins the *Saphenous*.

9. The *Deep Crural* arch will be removed as it crosses the upper part of the *Femoral* sheath.

## V.

- a. Divide the *Sartorius* muscle now where it appears beneath the skin at the outer part. The branch of the *Obturator* nerve which runs along the *Adductor longus* muscle may now be traced to its junction with the inner branch of the *Internal Cutaneous* nerve which is now exposed. The aponeurotic covering of *Hunter's Canal* will now be seen, and may be at once removed. When this is done, the *Femoral* artery may be traced to the opening in the *Adductor magnus* muscle. At this point it is seen to give off the *Anastomotica Magna* branch. The *Femoral* vein will be found now lying external to the artery. The *Long Saphenous* nerve will also be seen usually lying externally to the artery, but it may be crossing to the inner side. A communication between the inner branch of the *Internal Cutaneous* and *Long Saphenous* nerves may now be traced, thus completing the *Obturator* plexus.
- b. Detach the *Pectineus* muscle from its origin and pull it outwards.
- c. Cut through the *Adductor longus* muscle at its origin and pull it outwards, taking care of its nerve from the *Superficial* division of the *Obturator*.

There will now be exposed—



1. The upper part of the **Obturator externus** muscle below the horizontal **Ramus** of the **Pubes**.
2. The **Adductor brevis** muscle, below this and overlapping it internally.
3. A further portion of the **Adductor magnus** muscle still lower.
4. The lesser **Trochanter** of the **Femur**, above the upper border of the **Adductor brevis** muscle.
5. The portion of the **Profunda Femoral artery** which lies beneath the **Adductor longus**. Its **Perforating branches** are seen, the first and second piercing the **Adductor brevis** muscle, the third and the terminal branch of the artery, the **Adductor magnus** muscle.
6. Branches of the **Internal Circumflex artery**, superficial to the **Adductor brevis** muscle.
7. The corresponding veins with the preceding arteries.
8. The **Superficial division** of the **Obturator nerve**, running down over the **Obturator** and **Adductor brevis** muscles, and sending branches to the **Gracilis**, **Adductor longus** and **brevis** muscles, and the **Obturator plexus**; all of which are now displayed. A terminal twig to the **Femoral artery** may also be traced.

VI. Divide the **Adductor brevis** muscle at its insertion. Remove the branches of the **Internal Circumflex vessels** superficial to it. Pull the muscle inwards and fix it. In this way the branches of the **Superficial division** may be preserved. There will now be exposed—

1. A further portion of the **Adductor magnus** muscle.
2. Other branches of the **Internal Circumflex vessels** beneath the **Adductor brevis** muscle.
3. The **Deep division** of the **Obturator nerve** may be traced. Branches may be followed to the **Obtu-**



rator externus and Adductor magnus muscles, and to the Adductor brevis muscle, when it is not supplied by the Superficial division. A branch may be traced through the fibres of the Adductor magnus muscle to the Popliteal artery by removing a portion of the muscle and pulling internally the Semimembranosus tendon. It may in this way be followed to the Posterior ligament of the knee-joint.

## VII. THE ABDOMINAL PORTION OF THE DISSECTION SHOULD NOW BE RESUMED.

- a. The great Omentum and transverse Colon should be placed upon the ribs, and the Intestines turned to the opposite side of the body on which the dissection is made.
- b. Clear away the Peritoneum from the brim of the Pelvis, and that over the posterior wall of the Abdomen from near the median line to the right or left Colon, as the case may be.
- c. Divide the junction of the Rectum with the Sigmoid flexure, or the Ileum with the Cæcum, according to the side dissected.
- d. Cut through the constituents of the cord at the internal Abdominal ring if this has not already been done, viz., the Vas Deferens, the Spermatic vessels, and Sympathetic nerves. The artery to the Vas from the Superior Vesical.

There will now be exposed—

1. The Psoas magnus muscle, and parvus if present.
2. The Iliacus muscle in the Venter Ilii, covered by its fascia.
3. The Common Iliac artery and its bifurcation, the upper part of the Internal, and the whole of the



**External Iliac branch** running along the brim of the Pelvis and continuous with the Femoral.

4. The corresponding veins.
5. The **Sigmoid branch** of the **Inferior Mesenteric artery** or the **Ileo-colic** of the **Superior** will be seen, according to the side dissected, crossing the **Psoas muscle**, with their veins.
6. The **Ureter** and **Spermatic vessels** will be found descending over the **Psoas muscle**.
7. The **Genito-crural nerve** lying upon the **Psoas muscle**, and traceable below to the **Femoral artery** and the internal ring.
8. The **Anterior Crural nerve** between the **Psoas** and **Iliacus**.
9. The **External Cutaneous nerve** crossing the **Iliacus muscle**.

### VIII.

- a. Remove the **Sigmoid** or **Ileo-colic vessels**, as the case may be.
- b. Cut through the **External Iliac vessels** at their upper ends, and pull the lower outwards.
- c. Separate the **Pelvic fascia** from the brim and upper part of the **Pelvic wall**. The **Obturator nerve**, **artery**, and **vein**, in this order, from above downwards, will be found running along the outer wall of the **Pelvis** to the opening in the **Thyroid foramen**; parallel and internal to its upper part will be found the large cord passing from the fourth to the fifth **Lumbar nerves**, and between this and the **Obturator** the **Ilio-lumbar artery** and **vein**.
- d. Pull the **Ureter** inwards, and the **Spermatic vessels** outwards from off the **Psoas**, and remove the inner part of this muscle from its origin as far up-



wards as the lower border of the second Lumbar vertebra downwards to the Pelvic brim.

- e. Remove a piece of the **horizontal Ramus of the Pubes**, from just outside the Pubic spine for an inch and a half, opening in this way the canal at the upper part of the Thyroid foramen, dividing and removing a portion of the **Obturator externus muscle and membrane**.

There will now be exposed—

1. The origin, course, and distribution of the **Obturator nerve**. The branch from the Superficial division to the hip-joint which comes off near to the Thyroid membrane being now traceable. In the dissection made the **Obturator trunk** arose from the second, third, and fourth Lumbar nerves.
2. The origin and commencement of the **Anterior Crural nerve**.
3. The bodies of the third, fourth, and fifth Lumbar **vertebræ**, and the intervertebral disc between the second and third.
4. The **Aorta**, and second, third, and fourth Lumbar **arteries**.
5. The **Renal vessels** of the side dissected, at the upper part.
6. Further portions of the **Ilio-lumbar vessels**.
7. The **gangliated cord** of the Sympathetic nerve lying on the side of the **vertebræ**, and the communications between the ganglia and Lumbar nerves.
8. The communication between the fourth and fifth Lumbar nerves, and the commencement of the **Lumbo-sacral cord**.
9. The remaining portion of the **Psoas muscle**.
10. The **Iliacus muscle** covered by its fascia.



11. Lying upon the Psoas muscle the Genito-crural, and upon the Iliacus muscle the External Cutaneous nerves.

## A DISSECTION OF THE PORTAL VEIN, AND ITS BRANCHES.

POSITION.—The body lying on its back.

I. The Abdomen being opened by a crucial incision, the parts exposed will be—

1. The Stomach.
2. The Liver and Gall-bladder.
3. The great Omentum descending from the Stomach and hiding the small Intestines; frequently, however, it is more or less puckered up, and exposes them to a variable extent.
4. The Cæcum and the lower end of the ascending Colon when distended.

II. Fix the Liver to the ribs by stitches passed through its substance. Pull down the Pylorus and dissect out the structures in the lesser Omentum, viz.—

1. The Bile duct to the right, above joined by the Cystic and Common Hepatic branches.
2. The Hepatic artery to the left, giving off the Superior Pyloric, Cystic, and Gastro-duodenal branches, the last running down behind the Pylorus, and giving off the Inferior Pyloric branch.
3. The Portal vein behind the preceding, dividing into right and left branches, and the right receiving the Cystic vein. The Gastric vein should be traced into it at the Pylorus. The Gastro-epiploic vein, running along the greater curva-



ture of the Stomach, may be traced into the Gastro-duodenal by pulling down the Pylorus, and the junction of this with the Portal after being joined by the Pancreatico-duodenal vein may be seen.

III. Place the great Omentum on the ribs, and dissect out—

1. The Superior Mesenteric vein by placing the Intestines over on the left side and removing the anterior layer of the Mesentery. The branches from small Intestines, the Ileo-colic, and right Colic branches may be found, and the middle Colic by removing the lower layer of the transverse Meso-colon.
2. The Inferior Mesenteric vein, by placing the Intestines on the right side and removing the Peritoneum covering the left side of the posterior Abdominal wall, whence it passes over the Colon. The left Colic, Sigmoid, and beginning of the Superior Hæmorrhoidal branches will be seen.

In this dissection the corresponding arterial branches, the Superior and Inferior Mesenteric plexuses of the Sympathetic nerve and the Mesenteric glands will be seen, and the arteries and veins occupying the following relative positions:—

- a. Superior Mesenteric vein to the right.
- b. Superior Mesenteric artery to the left of preceding.
- c. Next the Inferior Mesenteric artery.
- d. The Inferior Mesenteric vein, most to the left.

IV. Remove any remaining parts of the posterior layer of the transverse Meso-colon. Divide a small piece of the upper end of the Mesentery opposite the second Lumbar



vertebra, in order to get the beginning of the Jejunum to the right, as it overlaps the upper end of the Inferior Mesenteric vein.

V. Divide the Hepatic flexure of the Colon, and, pulling the divided ends to the right and left sides, pin them there.

This exposes—

1. The Pylorus and Duodenum encircling the Pancreas.
2. The Superior and Inferior Mesenteric arteries and veins passing over the third piece of the Duodenum and beneath the Pancreatic gland.

VI.

- a. Divide now the head of the Pancreas, and the Duodenum at the junction of its first and second portions. The arteria Pancreatic Magna will be divided as well as the duct.
- b. Pull the Stomach and Pancreas over to the left, and place them on the ribs.
- c. Remove the Hepatic artery and Bile duct.

The Portal vein and its branches will now be fully seen.

## A DISSECTION OF THE POSTERIOR SURFACE OF THE KIDNEY.

POSITION.—The body lying upon its face.

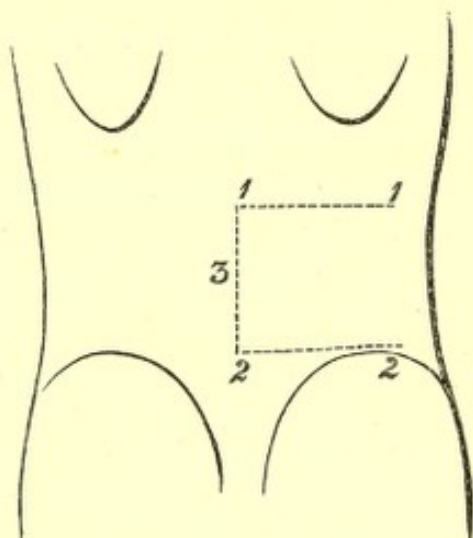
### I. SKIN INCISIONS.<sup>1</sup>

1. From the spine of the twelfth Dorsal vertebra, transversely outwards to the tip of the last rib.

<sup>1</sup> It may be objected that these incisions will not uncover a sufficient surface to expose the Kidney. The writer has always proceeded on the principle of the least possible destruction of surround-



2. From the spine of the fourth Lumbar vertebra transversely outwards to the crest of the Ilium, and along it to a point midway between the anterior and posterior Iliac spines.
3. A longitudinal incision along the median line from the spine of the twelfth Dorsal to the fourth Lumbar vertebra.



No. 15.

Reflect the flap outwards and expose the superficial fascia, containing—

1. The external branches of the posterior primary divisions of the eleventh and twelfth Dorsal nerves at the upper part, about one inch from the median line. The branch from the twelfth nerve external to the other.
2. The posterior branches of the Lateral Cutaneous offsets of the tenth and the eleventh Dorsal nerves extending backwards at the anterior and upper part.
3. The external branches of the posterior primary dividing parts, compatible with a full view of the structure to be displayed, and he has found from repeated dissections of the Kidney that these incisions are ample.



sions of the first, second, and third Lumbar nerves passing over the crest of the Ilium, the upper ones supplying filaments to the skin over the lower part of the space between the last rib and the crest of the Ilium.

4. Small cutaneous branches from the Intercostal arteries with the posterior and lateral cutaneous nerves, and from the Lumbar arteries with the Lumbar nerves.

II. Remove the preceding and the fascia lata, and expose—

The aponeurosis of the *Latissimus dorsi* muscle attached to the Lumbar spines and about the posterior half of the crest of the Ilium. Fleshy fibres of the muscle are seen for an inch or more in front of the aponeurotic Iliac attachment of the muscle, and also at the upper part.

III. Cut through the *Latissimus dorsi* muscle at its attachment to the Iliac crest, and again along the upper border of the twelfth rib. Join these transverse cuts by a longitudinal one through the muscle between their outer extremities. Reflect the muscle inwards as far as possible towards the median line behind.

There will now be exposed—

1. The *Serratus posticus inferior* muscle running from the spines of the last Dorsal and upper two or three Lumbar vertebræ upwards and outwards, and its attachment to the last rib will be seen.
2. The posterior layer of the aponeurosis of the *Transversalis* muscle will be seen below.

These three aponeurotic structures, viz., the origins of the *Latissimus dorsi* and *Serratus posticus inferior*



muscles, and the posterior lamella of the aponeurosis of the Transversalis are all more or less conjoined with one another at their attachments to the Lumbar spines. The united aponeurosis constitutes the **Fascia lumborum**.

3. The outer edge of the **Fascia lumborum** will be found to be marked by a definite vertical line, which later on is seen to correspond to the external border of the **Erector spinæ** muscle. Outside this, the fleshy origin of the **Internal Oblique** muscle, from the middle layer of the posterior aponeurosis will be seen.
4. More externally still, the posterior free edge of the **External Oblique** muscle will be seen, extending from the last rib to the Iliac crest, having internal to it the cut edge of the **Latissimus dorsi** muscle.
5. The outer portion of the last rib will be seen above, and probably, owing to the retraction of the skin, the lower fibres of the last **External Intercostal** muscle.

#### IV.

- a.* Clear away completely the **Lumbar fascia**.
- b.* Detach the **Internal Oblique** muscle from its origin, and turn it outwards.

There will now be exposed—

1. Nearest to the median line the **Erector spinæ** muscle, dividing above into **Sacro-lumbalis** externally, and **Longissimus dorsi** muscles internally, at about the level of the last rib.
2. Internal to the **Longissimus dorsi** muscle, from the twelfth Dorsal and upper two Lumbar spines, the **Spinalis dorsi** muscle passing upwards.
3. External to the **Erector spinæ** muscle, the cut edge of the posterior layer of the aponeurosis of the **Trans-**



versalis muscle. Outside this the middle layer, and, still more externally, the undivided aponeurosis and the fleshy fibres of the muscle.

4. Still more externally, the divided *Latissimus dorsi* and the *External Oblique* muscles, as before.
5. Resting upon the upper part of the *Erector spinæ* the external branches of the posterior primary divisions of the eleventh and twelfth Dorsal nerves, and, piercing its outer border, the corresponding branches of the upper three Lumbar nerves.
6. The anterior branch of the last Dorsal nerve with its accompanying vessels piercing the aponeurosis of the *Transversalis* muscle at the outer part.

V. The further progress of the dissection will depend upon the width of the *Erector spinæ* muscle. Usually it will be necessary to remove it, or at least the outer part, but the muscle may be narrow, and then it may be cut transversely at the level of the last rib, and drawn inwards sufficiently. It will be well to proceed as follows:—

- a. Make a transverse cut into the upper part of the *Erector spinæ* muscle, and draw the muscle well inwards towards the spines of the vertebræ.
- b. Remove the middle layer of the *Transversalis* aponeurosis and the fleshy fibres of the muscle by vertical cuts, externally and internally. The last Dorsal vessels and nerve may be dissected out and left.

There will now be exposed, in addition to the structures enumerated under Stage IV.—

1. The tips of the transverse processes of the four upper Lumbar vertebræ.
2. The *Quadratus lumborum* muscle.
3. Resting upon the posterior surface of the *Quadratus*



lumborum muscle the anterior branches of the four Lumbar arteries, but the lowest may pass in front. With the arteries are the corresponding veins.

VI. Take away now the Quadratus lumborum muscle completely, with the vessels lying upon it. There will now be exposed, in addition to the structures already enumerated—

1. The anterior layer of the aponeurosis of the Transversalis muscle.
2. Further portions of the last Dorsal vessels and nerve; \* lying immediately below the last rib.

VII. Remove the anterior lamella of the aponeurosis of the Transversalis muscle and a quantity of adipose tissue, and there will be displayed—

1. The posterior surface of the Kidney. This organ is very movable, and enveloped by fat. The writer has found as the result of several dissections that, putting for the moment on one side the question of the removal of the Erector spinæ muscle, the Kidney will now fall forwards, and the whole of its posterior surface may be now cleaned and exposed, and that the removal of the eleventh and twelfth ribs is entirely unnecessary.

Besides the Kidney there will be displayed—

2. The Pelvis of the Kidney and the commencement of the Ureter.
3. The Colon ascending or descending according to the side dissected. On the left side it lies below and external to the Kidney, on the right more immediately below. Arteries and veins from and to the Superior or Inferior Mesenteric vessels, as the case may be, can also be traced to the Intestine.

\* Last dorsal nerve. Passes below 12th, anteriorly. Then over surf of quad ren, betw. it and lamella lumborum. At this point quad ren fibres, conjunct with middle lamellæ and h. in right - to descend wall - betw. midway betw. middle - phrenic. Dorsal br. fibres betw. oblique & goes to buttock.



4. The Peritoneum and subperitoneal fat will be seen outside the preceding viscera.

5. Crossing the Kidney transversely from above downwards will be seen—

The anterior branches of the last Dorsal vessels and nerve.

The Ilio-hypogastric nerve.

The Ilio-inguinal nerve.

6. Internally the outer part of the Psoas magnus muscle.

7. Above, the origin of the Diaphragm from the ligamentum Arcuatum externum.

VIII. The dissection has been given from Stage V. on the supposition that the Erector spinæ muscle was sufficiently narrow to allow of its being drawn inwards after making a transverse cut at the upper part. This the writer knows from experience to be the case sometimes. Nevertheless, it more often happens that the muscle is too wide to admit of this mode of treatment, and when this is the case the following correction must be made for Stage V.:—

Remove the Erector spinæ muscle as far as it is exposed in the dissection. In addition to the structures already enumerated, there will now be displayed—

1. The inner half of the twelfth rib, and the transverse processes of the four upper Lumbar vertebræ.

2. The attachment to the last rib of the twelfth Levator costæ muscle between the tubercle and the angle.

3. The Multifidus spinæ muscle, arising from the mammillary processes of the Lumbar vertebræ and passing upwards and inwards to the spinous processes.



4. The posterior Inter-transverse muscles between the transverse processes.
5. The posterior primary division of the last Dorsal nerve and the accompanying vessels.

### A DISSECTION TO EXPOSE THE POSTERIOR SURFACE OF THE SACRAL PLEXUS.

POSITION.—The body lying on the face, the Abdomen and Pelvis raised on blocks, allowing the legs to hang down to a moderate extent.

#### I. SKIN INCISIONS.

1. An incision running horizontally outwards for four inches from the median line, at a level of one inch above the posterior superior Iliac spine.
2. From the inner end of (1) along the median line, three-fourths of the distance to the tip of the Coccyx.
3. From the lower end of (2) obliquely downwards and outwards to the Tuber Ischii.

Reflect the flap outwards and expose—

1. The loose areolar tissue of the buttock, and in it,
2. The external branches of the posterior primary divisions of the upper two Sacral nerves, the superior near the top of the Sacrum, the inferior at the lower part of the dissection.
2. Accompanying the preceding nerves cutaneous branches of the Lateral Sacral arteries.
4. Cutaneous branches of the Gluteal and Sciatic arteries over the Sacrum, and the Coccygeal branch of the latter at the lower part of the bone, also branches

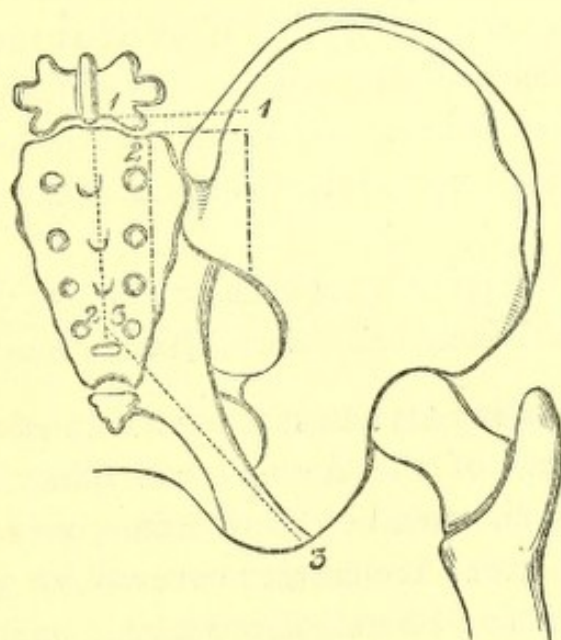


of the Gluteal artery perforating the Gluteus maximus muscle.

5. Small filaments of the external branches of the posterior primary divisions of the upper three Lumbar nerves run back over the upper part of the surface exposed.

II. Remove the preceding structures and expose—

1. The conjoined aponeuroses of the Latissimus dorsi and Multifidus spinæ muscles.



No. 16.<sup>1</sup>

2. The fascia lata over the Gluteus maximus muscle.

III. Remove the preceding and expose the Erector and Multifidus spinæ muscles, and the Gluteus maximus muscle.

IV. Detach the preceding muscles, dividing branches of the Gluteal artery and vein to the Gluteus maximus muscle,

<sup>1</sup> The dotted lines (1, 2, 3) indicate the skin incisions, and the others the piece of bone removed.



and noticing branches of the Sacral plexus and Small Sciatic nerve entering its deep surface.

There will now be exposed—

On the Sacrum :

1. The upper three fourths of the posterior surface of this bone and the upper four foramina.
2. The superior and oblique Sacro-iliac and the Supra-spinous ligaments.
3. The posterior primary divisions of the upper four Sacral nerves. The inner branches will be divided on the removal of the Multifidus muscle; the outer branches will be seen to unite in loops on the back of the Sacrum with one another, and a branch running up to the last Lumbar nerve will be seen.
4. The corresponding arteries and veins from and to the Lateral Sacral and Sacra Media vessels.

Under the Gluteus maximus muscle will be seen—

5. The parts of the Sacrum and Ilium from which it arises, the spine of the Ischium, and the upper part of the great Trochanter covered by a bursa.
6. The Great and Small Sacro-sciatic ligaments.

The following muscles from above downwards—

7. The posterior part of the Gluteus medius.
8. The Piriformis.
9. The Gemelli with the intervening tendon of the Obturator internus muscle.
10. The cut Superficial branch of the Gluteal artery and vein above the Piriformis.
11. The Sciatic artery and vein below this muscle.
12. The Pudic artery and vein crossing the Ischial spine.
13. A second series of loops of the external branches of



the upper three Sacral nerves lying upon the Great Sacro-sciatic ligament.

14. The Great Sciatic nerve below the Piriformis.
15. The Small Sciatic nerve, also below this muscle, branches to the Gluteus maximus muscle divided.
16. Branches of the Sacral plexus to the Gluteus maximus muscle, also divided.
17. The nerve to the Obturator internus muscle, usually outside, and the Pudic nerve, inside the Pudic artery.
18. The nerve to the Gemellus superior muscle.
19. The upper part of the nerve to the Gemellus inferior and Quadratus femoris muscles, if the Great Sciatic nerve is pulled outwards.

#### V.

- a. Remove the Gluteus medius muscle from the posterior part of the Iliac attachment.
- b. Cut through the Piriformis muscle as it emerges from the Pelvis, and turn it outwards.
- c. Cut through and remove the Sacro-sciatic ligaments.
- d. Clear away fat and fascia from the posterior part of the Ischio-rectal fossa.
- e. Chisel through the Ilium from the centre of the great Sacro-sciatic foramen vertically upwards to the crest; and through the Sacrum just outside the posterior foramina, as far down as the fourth; connect these incisions above, and remove the included portions of the bones. The incision into the Sacrum should not be carried high enough to remove the upper part of the lateral mass, which is left. All but the upper part of the Sacro-iliac articulation is taken away and with it



The oblique and transverse fasciculi of the  
Posterior Sacro-iliac ligaments.

The Auricular cartilage.

The Anterior Sacro-iliac ligaments.

*f.* Remove the pieces of origin of the **Pyriformis** muscle, between the second, third, and fourth Sacral foramina.

*g.* Take away the loose areolar tissue about the vessels and nerves.

There will now be exposed—

- |                                  |                      |
|----------------------------------|----------------------|
| 1. The Lumbo-sacral cord,        | } forming the Sacral |
| 2. The first four Sacral Nerves, |                      |

The following branches of the plexus will be seen—

3. The Gluteal from the Lumbo-sacral cord, and first, or first two Sacral nerves.
4. The Great Sciatic, a direct continuation of the plexus.
5. The Small Sciatic branch arising by two cords from the lower part of the plexus, and traceable to the part formed by the first two Sacral nerves.
6. Nerves to the Gluteus maximus muscle from the same part of the plexus as the preceding, in front of it.
7. The Pudic branch derived from the third nerve, and involving the whole of the portion of the fourth which joins the plexus.
8. Usually two branches to the **Pyriformis** muscle arising from the upper part of the posterior surface of the plexus, or the first two nerves before they join it.
9. The nerve to the **Obturator internus** muscle will be seen below, but not at its origin from the union of the Lumbo-sacral cord and the first Sacral nerve on the anterior surface. The nerves to the **Gemelli**



muscles will now be seen at their origin from the front and lower part.

10. The fourth Sacral nerve is seen perforating and running along the upper part of the Coccygeus muscle.
11. The Gluteal artery and vein seen between the Lumbo-sacral cord and the first Sacral nerve.
12. The Sciatic artery and vein below the Sacral plexus.
13. The Pudic artery and vein.
14. Branches of the Lateral Sacral arteries accompany the Sacral nerves.
15. The Coccygeus muscle passes from the spine of the Ischium to the Sacrum and Coccyx.
16. A small piece of the Gluteus minimus muscle is seen at the margin of the Sacro-sciatic foramen.
17. A small piece of the Obturator internus muscle at the outer margin of this foramen.
18. The posterior part of the Levator ani muscle where the Ischio-rectal fossa is cleaned.
19. The Pelvic fascia is seen beneath the deep surface of the plexus, separating the nerves from the branches of the Internal Iliac artery.

A DISSECTION TO EXPOSE THE ANTERIOR SURFACE OF THE SACRAL PLEXUS IN THE MALE SUBJECT. THE LEG BEING REMOVED, THE BUTTOCK AND PERINÆUM DISSECTED, THE ABDOMEN OPENED, AND THE VISCERA REMOVED.

POSITION.—The body lying on its back.

- I. The first step will be to make a side view of the Pelvis, and to do this the following steps are necessary on the



side on which the section is to be made. The plexus of the opposite side is the one that is to be exposed.

- a.* Remove the **Psoas** muscle and the **External Iliac** vessels along the brim, and part of the **Iliacus** muscle from the **Venter Ilii**.
- b.* Dissect off the **Pelvic fascia** from the brim of the **Pelvis**. This is to be done carefully keeping close to the bone, and thus taking away the **Obturator internus** muscle, and the dissection should be carried nearly as far forwards as the **Symphysis**, backwards to the fascia of the **Pyri-formis**, and as low down as possible.
- c.* Separate the **Obturator fascia**, with the falciform process of the **Great Sciatic ligament**, and the **Obturator** muscle, from the outer wall of the **Ischio-rectal fossa**. This incision will meet the above.
- d.* Saw off the spine of the **Ischium**.
- e.* Saw through the **Rami of the Pubis and Ischium**, an inch external to the **Symphysis Pubis**.
- f.* Saw through the **Innominate bone** behind, the incision extending from the outer margin of the **Quadratus lumborum** above, vertically downwards to the great **Sacro-sciatic foramen**. Or the bone may be disarticulated behind, by removing the **Multifidus** and **Erector spinæ** muscles from the **Sacro-vertebral groove**, dividing the **Anterior and Posterior Sacro-iliac**, the **Ilio-lumbar**, **Lumbo-sacral**, and **Great Sciatic ligaments**, and forcibly separating the bones. In this way the **Auricular cartilage** which adheres to the **Sacrum** mostly, may be displayed.
- g.* When the bone is removed, the spine of the **Ischium**



should be fixed down, and the **Obturator internus muscle** gently peeled off the outer surface of the **Pelvic fascia**, when the following will be exposed—

1. The **Pelvic fascia**, and **white line** extending from the lower part of the **Symphysis** to the **Ischial spine**.
2. The **Obturator fascia** below this line.
3. The **Obturator nerve, artery, and vein**, running transversely above, in this order from above downwards, and passing out in front through the opening above the **Obturator membrane**. They lie in the substance of the **Pelvic fascia**.

The **Pudic vessels, and nerve**, are seen lying in the substance of the **Obturator fascia**, or rather in a sheath derived from its inner surface. They may be traced backwards round the **Ischial spine**, and as far forwards as the **Triangular ligament**.<sup>1</sup>

II. Remove now the **Obturator fascia** at the **white line**. Divide the **Anal fascia** along this line; cut through the origin of the **Levator ani muscle** from it, and expose the **Recto-vesical fascia**<sup>2</sup> running downwards and inwards to

<sup>1</sup> A good dissection of the **Pudic artery** may be made in this way, but the anterior section of the bone would have to be modified.

<sup>2</sup> The above is the account of the arrangement of the **Pelvic fascia** as usually given. It is, however, frequently found, that the **Pelvic fascia** is directly continuous with the **Recto-vesical**, and the **white line** is formed by the upper edge of the **Obturator**, which is loosely connected with the **Pelvic** by areolar tissue. The origin of the **Levator ani muscle** often extends considerably above the **white line**.



the viscera. Below it are the following parts closing the Pelvic outlet from before backwards:—

1. The Triangular ligament.
2. The Levator ani muscle.
3. The Coccygeus muscle, and the smaller Sacro-sciatic ligament.
4. The Great and Small Sciatic nerves, the Pudic nerve, the nerve to the Obturator internus muscle.
5. The Sciatic vessels, piercing the fascia of the Piriformis.

The preceding vessels and nerves leave the Pelvis below the Piriformis muscle.

6. The Piriformis muscle.
7. The Sacral plexus lying upon it, and giving off the above-named branches.
8. The Gluteal vessels and nerve, above the Piriformis muscle, and piercing the fascia over it.

### III.

- a. Cut away the Recto-vesical fascia and its prolongations to the viscera on the side of the Pelvic section, the Pubo-prostatic ligament, and Ellis's ligament of the Rectum.
- b. Remove the piece of Peritoneum passing to the viscera from the side of the Pelvis on which the section has been made, and display in this way a side view of the Pelvic viscera.<sup>1</sup>

The following are the parts now seen—

1. The divided portions of the Innominate bone.
2. The Rectum in the concavity of the Sacrum and Coccyx; most posteriorly branches of the Superior Hæmorrhoidal artery may be seen in removing the

<sup>1</sup> To show the parts more clearly, the Bladder should be inflated through the Ureter, and the Rectum filled with tow.



sheath of Recto-vesical fascia. Owing to the curvature of this viscus to the left, a better view is obtained by making the section on this side.

3. The **Bladder** in front of the preceding.
4. The **Recto-vesical pouch** of Peritoneum between the Bladder and Rectum.
5. The **Prostate gland** surrounding the neck of the Bladder, and enveloped by the **Prostatic plexus** of veins, the sheath of the Recto-vesical fascia being removed.
6. In front of the preceding the **two layers of the Triangular ligament** perforated by the **Membranous Urethra**, and in front of the ligament the **Bulb**.
7. Between the Fundus of the Bladder and the Rectum the **Vesicula Seminalis** of the side dissected.
8. The **Ureter** is seen descending internally to the Internal Iliac vessels, and entering the posterior and external part of the Fundus of the Bladder.
9. The obliterated **Hypogastric artery** is seen running transversely on the upper part of the side of the Bladder to the apex, and continuous behind with the **Internal Iliac artery**.
10. Crossing over the immediately preceding structure, and running vertically down internally to it and the Ureter, is the **Vas Deferens**, accompanied by its artery.
11. Extending from the apex of the Bladder on to the Abdominal wall are the **Urachus**, and both obliterated **Hypogastric arteries**.
12. Extending from the Abdomen over the **Sacro-iliac Synchrondrosis** the **Internal Iliac artery**. Its **Obturator, Sciatic, and Pudic** branches are divided, as well as the **Gluteal**, but the **Superior, Middle, and**



**Inferior Vesical offsets** are seen, the former giving the branch to the Vas, and the Middle very inconstant. The **Middle Hæmorrhoidal artery** is also displayed, commonly arising from the Inferior Vesical or the Pudic branches.

13. The **corresponding veins**. These are plexiform at their origin, and form the **Prostatic, Vesical, and Hæmorrhoidal plexuses**, which are found on the sides of the corresponding viscera. The **Dorsal vein of the Penis** is seen entering the Prostatic plexus.
14. The **Pelvic plexus of the Sympathetic nerve** of the side dissected is seen surrounding the Iliac vessels, and sending prolongations to the viscera along the vessels.
15. **Lymphatic glands** along the Iliac vessels.
16. Below these structures are seen the parts closing the outlet of the Pelvis already enumerated above.

#### IV.

Divide now the following structures—

- a. The **Spermatic cord** at the internal Abdominal ring of the side on which the section has been made.
- b. The obliterated **Hypogastric artery**.
- c. The **Ureter**.
- d. The **Vesical and Middle Hæmorrhoidal arteries and veins** of the side dissected.
- e. Cut through the **Meso-rectum**, containing the **Superior Hæmorrhoidal artery and vein**, and the accompanying **Sympathetic plexus**, and draw the **Rectum** well over to the side from which the bone has been removed.
- f. Strip off the **Peritoneum** passing from the Blad-



der and Rectum to the opposite side of the Pelvis.

- g.* Divide the obliterated Hypogastric artery, the Spermatic cord, the Vesical and Hæmorrhoidal vessels, and the Ureter of the opposite side.
  - h.* Cut through the Recto-vesical fascia of the opposite side at its visceral attachments, and pull the Bladder over to the same side as the Rectum.
  - i.* Dissect out the Internal Iliac vessels and their branches, and remove them; except the Obturator, which may remain on the Pelvic wall. These branches have already been enumerated. In cleaning these the other Pelvic Sympathetic plexus will be destroyed.
  - j.* Remove the fascia of the Pyriformis.
- There will now be exposed—

1. The anterior surfaces of the Sacrum and the Coccyx and the posterior surface of the Symphysis Pubis.
2. Lying on the Sacrum, the Sacra Media and Lateral Sacral arteries and veins. The Hypogastric Sympathetic plexus, and the gangliated cords of the Sympathetic, one on each side, are seen uniting below in the ganglion impar. The Coccygeal gland may be found below this, receiving branches from the ganglion impar and the Sacra Media artery.
3. The Psoas muscle, External Iliac vessels, and Pelvic wall of the opposite side, and covering the wall:—
4. The Pelvic fascia lining the Obturator internus muscle; below is the white line, and below this the Recto-vesical fascia covering the Levator ani muscle. The Recto-vesical fascia may be seen closing the Pelvis in front, leaving in the median line a little triangular interval between the Pubic



attachments of the Levatores ani; here it is very thin, and dips down to join the Prostatic capsule. *This fascia is seen to be separated from the Triangular ligament by the Levatores ani muscles.*

5. The **Obturator nerve, artery, and vein** are seen running across the Pelvic wall in this order from above downwards. Behind the Symphysis are the **Pubic branches of the Obturator, and Deep Epigastric arteries.**
6. The **Coccygeus muscle** behind the Levator ani muscle, passing from the sides of the Sacrum and Coccyx to the Ischial spine.
7. The **Sacral plexus** consisting of the Lumbo-sacral cord, and the first, second, third, and part of the fourth nerves, their communications with the Sympathetic ganglia and the following branches. The **Gluteal**, arising from the posterior part of the Lumbo-sacral cord, and the first or first two Sacral nerves. The nerve to the **Obturator internus muscle** derived from the front of the plexus at the union of the Lumbo-sacral cord, with the first Sacral nerve. **Visceral branches** to the Bladder and Vagina, from the second, third, and fourth nerves (Godlee). Ellis describes them as coming from the fourth nerve, and sometimes from the third. In this dissection they came from the second, third, and fourth.
8. The remainder of the fourth nerve, its **Hæmorrhoidal branch**, which is seen passing over the Coccygeus muscle and turning to the back of the Coccyx, between that muscle and the Levator ani, or perforating the former. The branch to the visceral surface of the **Levator ani muscle**, which also sup-



plies the **Coccygeus**. This is internal to the preceding, and is seen by dissecting off the Rectovesical fascia from the Levator ani muscle.

9. The nerve formed by the united anterior primary branches of the fourth, fifth, and the Coccygeal, perforating the Coccygeus muscle to be distributed to its posterior surface.

## A DISSECTION TO EXPOSE THE PUDIC ARTERY.

**POSITION.**—The body in the lithotomy position, but the buttocks raised higher than usual by blocks beneath the Lumbar region. The side on which the dissection is to be made tilted higher than the opposite. The Scrotum should be hooked forwards on to the Abdomen. In this way, the side of the buttock, the Ischio-rectal fossa, and the Perinæum may be seen in one view.

### I. SKIN INCISIONS.

1. From the posterior superior Iliac spine vertically downwards to the tip of the Coccyx, then forwards encircling the anus and along the median raphe of the Perinæum to the base of the Scrotum.
2. A transverse incision outwards for three inches from the upper and posterior end of No. 1.
3. A transverse incision outwards for two inches from the anterior end of No. 1.

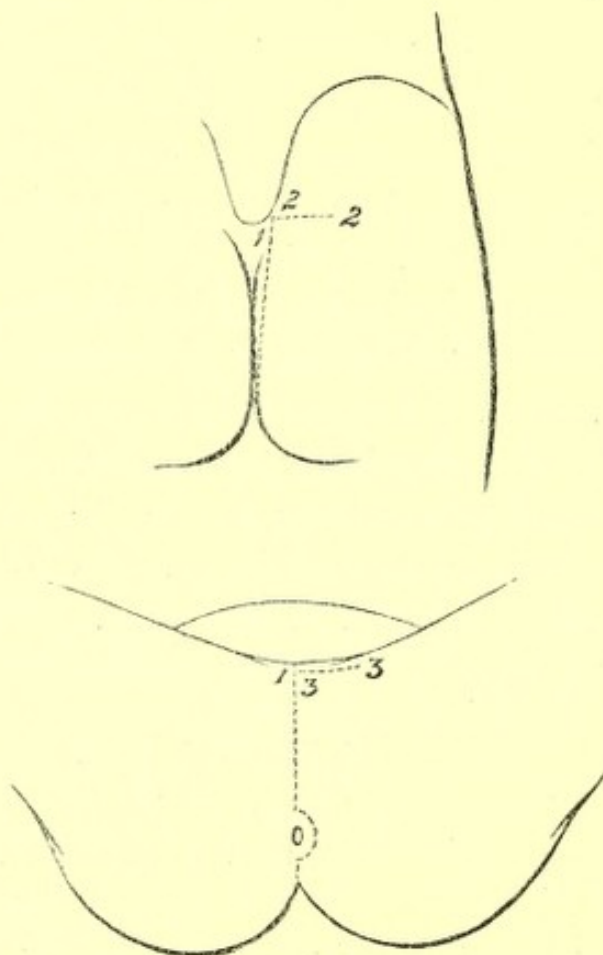
Reflect the flap outwards and expose the superficial fascia. Over the Perinæum this consists of two layers, of which the superficial is now seen.

The following structures in their order, from before backwards, are also displayed.



## 1. Cutaneous arteries from—

- a.* The **Superficial Perinæal** branch of the Pudic.
- b.* The **Inferior Hæmorrhoidal** over the Ischio-rectal fossa, and a branch turning round the edge of the Gluteus maximus muscle.



No. 17.

- c.* The **Sciatic** artery over the Gluteus maximus muscle, some offsets turning round the lower border, others perforating the muscle. The ending of the **Coccygeal** branch.
  - d.* The **Gluteal** passing through the Gluteus maximus muscle.
2. At the back of the Ischio-rectal fossa, an offset of



- the Inferior Hæmorrhoidal branch of the Pudic nerve, turning round the Gluteus muscle ; and
3. Branches of the Small Sciatic nerve external to it, and having a similar distribution.
  4. The Hæmorrhoidal branch of the fourth Sacral nerve in the angle between the Gluteus maximus and External Sphincter ani muscles.
  5. The Coccygeal nerve close to the Coccyx.
  6. The external branches of the posterior primary divisions of the upper three Sacral nerves, the smallest near the Iliac crest, the largest opposite the lower end of the Sacrum, the other by the side of the Coccyx.
  7. Twigs passing backwards over the upper and posterior part of the space dissected, from the external branches of the posterior primary divisions of the upper three Lumbar nerves as they pass over the Iliac crest.

## II.

- a. Take away in front the superficial layer of the superficial fascia of the Perinæum.
- b. Clean out the fat from the Ischio-rectal fossa, and remove the sheath of the Obturator fascia enclosing the Pudic vessels and nerve.
- c. Remove the fascia lata from the Gluteus maximus muscle behind. While these steps are being taken, the following structures will be seen:—

## IN FRONT OVER THE PERINÆUM.

1. The Rami of the Pubes and Ischium.
2. The Superficial Perinæal vessels running up to the Scrotum.
3. The Anterior and Posterior Superficial Perinæal nerves,



the latter *external* to the other. These nerves communicate freely with one another.

4. More externally the **Inferior Pudendal branch** of the **Small Sciatic nerve**. It communicates with the **Posterior, or External Superficial Perinæal nerve**.

BOUNDING THE ISCHIO-RECTAL FOSSA THE FOLLOWING STRUCTURES WILL BE FOUND—

5. INTERNALLY.—The **External Sphincter ani muscle**, below it the **Levator ani muscle** covered by the **Anal fascia**, and the **Coccygeus muscle**. The latter posterior to the **Levator ani**.
6. EXTERNALLY.—The **Tuber Ischii** and below it the **Obturator fascia** covering in the **Obturator internus muscle**, forming the outer wall.
7. POSTERIORLY.—The inferior border of the **Gluteus maximus muscle**.

CONTAINED IN THE ISCHIO-RECTAL FOSSA THE FOLLOWING STRUCTURES WILL BE DISSECTED—

8. In a sheath of the **Obturator fascia**, one and a half inches deep on the outer wall, the **Pudic vessels**. The **Inferior Hæmorrhoidal branches** are traceable transversely across the space to the lower end of the **Rectum**, and the **Superficial Perinæal vessels** backwards to their origin from the **Pudic**. Crossing the front of the fossa is the small **Transverse Perinæal artery**, which may be a branch of the main trunk, but more commonly arises from the **Superficial Perinæal branch**.
9. The **Pudic nerve** will be found in the outer wall of the fossa deeper than the artery, but its **Perinæal branch**, which is considerably larger than the nerve



itself, is *superficial* to the vessel. This branch will be found to be dividing in front into offsets, which may be better traced in a subsequent dissection. Opposite the Tuber Ischii the **Inferior Hæmorrhoidal branches** of the main nerve pass inwards to the lower end of the Rectum, and communications with the **Posterior Superficial Perinæal** and **Inferior Pudendal** nerves may now be followed forwards.

10. The **Hæmorrhoidal branch** of the fourth Sacral nerve may be seen passing between the Levator ani and Coccygeus muscles, or perforating the latter to be distributed to the External Sphincter muscle.

#### ON THE BUTTOCK—

11. The **Gluteus maximus** muscle will be cleaned, and the previously mentioned branches of the **Sacral nerves** will be found perforating it.

#### III.

- a. Remove now in front the **deep layer** of the **superficial fascia** of the Perinæum, detaching it from the Pubic arch externally, and from the **Triangular ligament** behind.

In doing this the distribution of the **Perinæal branch** of the **Pudic nerve** may be with advantage traced. The fascia is seen to pass over the **Transversus perinæi** muscle to join the **Triangular ligament**. The nerve will be found to divide into the following branches:—

1. The **Posterior Superficial Perinæal**, which passes on the cutaneous surface of the **Transversus muscle**.
2. The **Anterior Superficial Perinæal**, running beneath the **Transversus muscle**, and giving a



transverse offset to the fore part of the Levator ani muscle.

3. Muscular branches, which may be traced to the Erector penis, Accelerator urinæ, and Transversus perinæi muscles at once, and later on to the deep Transverse, and Constrictor urethræ muscles.

4. Slender twigs to the Corpus Spongiosum.

The fascia investing the three superficial muscles may be now cleaned away.

- b.* Remove the Gluteus maximus muscle from its attachments internally to the Sacrum and Coccyx, and cut it through externally in a line parallel with the reflected skin.

There will now be exposed—

IN FRONT, THE ANTERIOR TRIANGLE OF THE PERINÆUM, bounded

EXTERNALLY, by the Crus Penis with the Erector muscle lying upon it.

INTERNALLY, by the Bulb of the Corpus Spongiosum Urethræ covered by the Accelerator urinæ muscle.

POSTERIORLY, by the Transversus perinæi muscle.

THE FLOOR, formed by the Anterior layer of the Triangular ligament of the Perinæum.

UNDER THE GLUTEUS MAXIMUS MUSCLE.

1. The Great Sacro-sciatic ligament passing between the sides of the Sacrum and Coccyx and the inner border of the Tuber Ischii. The Small Sacro-sciatic ligament crosses transversely beneath this from the side of the lower part of the Sacrum and the Coccyx to the Ischial spine.



2. The upper and posterior part of the **Gluteus medius** muscle is the highest of the structures displayed.
3. The **Pyriformis** muscle is next below, emerging from the great Sacro-sciatic foramen.
4. Next, the tendon of the **Obturator internus** muscle passing out from the lesser Sacro-sciatic foramen. It is overlapped here by the **Gemelli** muscles, the origins only of which are seen.
5. The **Superficial branch of the Gluteal artery** is seen between the **Gluteus medius** and **Pyriformis** muscle with its accompanying vein, both however are divided at their point of entrance into the **Gluteus maximus** muscle.
6. The **Sciatic vessels** pass from the Pelvis below the **Pyriformis** muscle, and the **Coccygeal branch** is seen perforating the Great Sacro-sciatic ligament.
7. The **Pudic vessels** are seen upon the spine of the **Ischium**, with the **Pudic nerve** inside and the nerve to the **Obturator internus** muscle outside them.
8. The **Great and Small Sciatic nerves**, the **Pudic nerve**, the nerve to the **Obturator internus** muscle, the nerve to the **Gemellus superior** muscle, and the nerve to the **Gemellus inferior** and **Quadratus femoris** muscles are exposed passing from the Pelvis below the **Pyriformis**. The latter two, however, are here beneath the Great Sciatic nerve. Branches to the **Gluteus maximus** muscle from the Small Sciatic and Sacral plexus are also seen.
9. On the surface of the **Great Sacro-sciatic ligament**, the second series of loops between the external branches of the posterior primary divisions of the upper three Sacral nerves is seen.
10. A bursa over the **Tuber Ischii** is opened.



## IV.

- a. Cut through in front the **Superficial Perinæal nerves** and turn them forwards.
- b. Detach the **Crus Penis** and **Erector** muscle from the **Ramus** of the **Ischium** and turn it inwards. This must be done carefully, to avoid injuring the **Pudic artery**, which lies between the **Crus** and the bone, but a branch which enters the **Corpus Cavernosum** at this point is unavoidably divided. The **Pudic nerve** is found here with the artery, and a similar branch from it to the **Corpus Cavernosum** is cut through.
- c. Remove the **Superficial Transversus perinæi** muscle.
- d. Take away the **Great Sacro-sciatic ligament**, with the **Coccygeal branch** of the **Sciatic artery**, and the **Sacral nerves**.
- e. Cut through the **Pyriformis** muscle at its point of emergence and turn it outwards.
- f. Remove with the chisel the bone forming the inner portion of the upper part of the great **Sacro-sciatic foramen**, and the lower part of the **Sacro-iliac articular surfaces**, with the cartilage and ligaments in part. This is done to display the origin of the **Pudic artery** from the **Internal Iliac trunk**.

There will now be exposed—

## IN THE PERINÆAL REGION.

1. The Anterior layer of the **Triangular ligament**.
2. The **Pudic artery and nerve** piercing it, and dividing into the branches for the **Corpus Cavernosum**, which are now cut, and the branches for the **Dorsum** of the **Penis**, which pass forwards to



pierce the **Suspensory ligament**, the nerve lying outside.

The **Anterior layer** of the **Triangular ligament** may now be cleaned away, and the **Pudic artery and nerve** traced between the two layers. It will be found to give off a small transverse artery to the **Bulb** of the **Corpus Spongiosum**, which reaches that structure by perforating the **Anterior layer** of the ligament. There will now be exposed—

3. The **Deep Transversus perinæi muscle**.

4. The **Constrictor urethræ muscle** in front of the preceding, but usually continuous with it.

The branches of nerve from the **Perinæal branch** of the **Pudic** may now be traced to the preceding muscles.

#### IN THE ISCHIO-RECTAL REGION—

The **Pudic artery** may be traced in the outer wall of the fossa.

#### IN THE GLUTEAL REGION—

The **Pudic artery** may be followed from the **Internal Iliac trunk** in front of the lower end of the **Sacral plexus**, over the spine of the **Ischium** to the **Ischio-rectal fossa**. The **Sciatic and Pudic veins** must be removed to do this.

By the removal of the **Pyriformis muscle**, the following structures, in addition to those mentioned under **Stage III.**, will be exposed—

1. Further portions of the **Gluteal, and Sciatic arteries**.

2. The first, second, third, and fourth **Sacral nerves** forming the plexus.

3. The first portion of the **Gluteal nerve**.

4. The nerves to the **Pyriformis muscle** from the upper and posterior part of the plexus.



5. The origin of the **Pudic nerve**, mainly from the third and fourth Sacral nerves.
6. The origin of the **Small Sciatic nerve** by two roots from the lower part of the plexus.

#### NOTE<sup>1</sup> ON THE TRIANGULAR LIGAMENT OF THE URETHRA.

The anatomy of the Triangular ligament of the Urethra has in the experience of the writer often proved to be somewhat of a stumbling block to students. This note is written with the view of endeavouring to make the connections of this structure clearer. The difficulty arises, I believe, from two causes: *firstly*, that *identical* parts of the Pelvic fascia have received a different nomenclature; and, *secondly*, that incorrect or at all events inexplicit accounts are given in most of the text books in ordinary use.

To obviate the first difficulty, I shall take that account of the Pelvic fascia which is now commonly received, and indeed followed by the authors usually read; but the connections of the various parts of which with the structure under consideration are either not stated explicitly, or are else erroneously given. I mean that description which states that the **Pelvic fascia** divides at some point in a line extending from the **Symphysis of the Pubes to the spine of the Ischium**, into two parts, one of which extends in to the various Pelvic viscera, and the other of which is continued down on the inner surface of the **Obturator internus muscle** to the outlet of the Pelvis. The line of bifurcation is called the **white line**, the part of

<sup>1</sup> Reprinted from the "Guy's Hospital Reports."



the fascia above this line is named **Pelvic**, the portion below, **Obturator**, and the piece extending in to the viscera **Recto-vesical**. Further, there is a thin fascia derived from the Obturator, which lines the under surface of the Levator ani muscle, to which the name **Anal** is applied.

But whilst laying down these hard and fast lines, I will quote here a passage from "Quain's Anatomy" (vol. i., page 327), because whilst I have been repeatedly convinced of its accuracy, I do not think that any other of the authors ordinarily read, mention the facts stated therein. It is as follows:—

"The Obturator fascia is sometimes included in the description of the Pelvic fascia, while the Recto-vesical is considered as an offset from it. It will be found however on dissection, that the Recto-vesical fascia is always most directly continuous with the Pelvic fascia, and that the Obturator fascia is only loosely connected with it. Indeed the fibres of the Levator ani muscle in most cases pass upwards to some extent beyond the white line, and thus separate the Obturator from the Pelvic fascia."

We will now take the various descriptions<sup>1</sup> given of the anatomy of the Triangular ligament. We shall find that there is no difficulty about the **Anterior or Superficial lamella**, for this is described by all as a *special layer of fascia closing the upper part of the Pubic arch*. It is in the connections of the **Deep layer**, that the discordant accounts, real or apparent, are given. Thus in "Gray's Anatomy" (page 751) it is stated "the Posterior layer is derived from the Pelvic fascia," and again (pp. 755-56) the Pelvic fascia "is continuous below the Pubes with

<sup>1</sup> The italics are my own, in all the succeeding quotations.



the fascia of the opposite side, so as to close the front part of the outlet of the Pelvis, blending with the Posterior layer of the Triangular ligament ;” and, further, the Obturator fascia “is a direct continuation of the Pelvic fascia below the white line, and is *attached to the Pubic arch.*” The inference from this account is, I take it, that the Posterior layer is formed by the *Pelvic fascia*, closing the Pelvis in front and beneath the Symphysis, and that the Obturator division takes no part in the formation of the Triangular ligament, but stops short at the Pubic arch.

In “Quain’s Anatomy” (vol. i., page 326), we find “this layer (*i.e.* Deep layer of Triangular ligament) is superficial to the anterior fibres of the Levator ani, which lie between it and the *Pelvic fascia*,<sup>1</sup> and is *connected with a thin web of areolar tissue which extends backwards on the surface of the Levator ani muscle, and is distinguished as the Anal fascia.*” The Obturator division is described as being attached to the Rami of the Pubes and Ischium.

There is nothing said as to the connection of the Triangular ligament with the Pelvic fascia, or with any part of it, and I think that we must either infer that both layers of the ligament are to be looked upon as *special fasciæ*, or that else the Deep layer is derived from the *Anal fascia*.

In Heath’s account of the Triangular ligament, no mention is made of its connection with any part of the Pelvic fascia, but in describing the *Recto-vesical layer* (page 261), the following is stated, “it is seen to dip down to the Prostate, and is thus continued from one

<sup>1</sup> The word *Pelvic* must here be read in connection with the passage quoted above (vol. i., page 327). *Recto-vesical* is probably meant as being a direct continuation of the *Pelvic fascia*.



side to the other of the Pelvis, of which it closes the outlet."

In "Ellis's Anatomy" (eighth edition, page 546), no distinction is made between Pelvic and Obturator fasciæ, but the *whole membrane lining the inner surface of the Obturator muscle is called Pelvic*, and the following statement is made:—"Inferiorly the fascia is attached to the hip bone along the side of the Pubic arch." He is here speaking of the part *below the white line, i.e., the Obturator division of other writers*. On page 549, it is stated that the Recto-vesical fascia between the Pubo-prostatic ligaments of opposite sides "dips down to reach the Triangular ligament of the Perinæum, and closes the Pelvis between the Levatores ani." On page 429 we find, "The Posterior layer (of the Triangular ligament) is *derived from the Recto-vesical fascia*." Here, then, we have another account of the origin of this layer.

I may here note that in the sixth edition of this writer's work (page 587), the account given of the Pelvic fascia differs substantially from the later one just quoted; in that, it (the Pelvic fascia) is stated to be "continued from the one hip bone to the other, so as to close the cavity of the Pelvis in front for a short distance," and that, on page 458, it is said that "the Posterior layer (*i.e., of the Triangular ligament*) is derived from the Pelvic fascia;" we must, however, of course, take the later description, which gives the origin from the Recto-vesical fascia.

I think I have quoted enough to justify the statement that the connections of the Posterior layer of the Triangular ligament may well be a stumbling block, for we have the following different accounts given:—

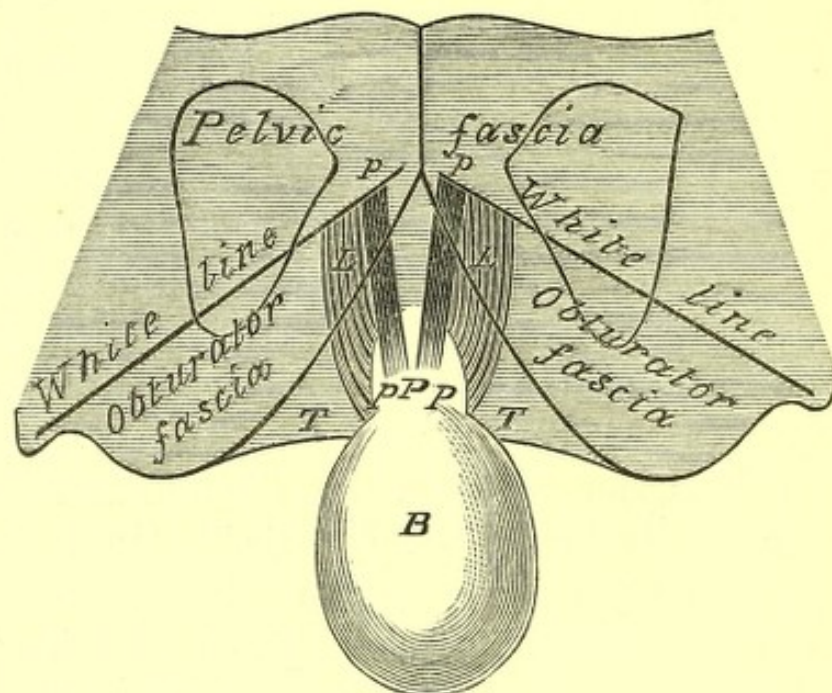
1. From the Pelvic fascia (Gray).
2. A special structure, or from the Anal fascia (Quain).



### 3. From the Recto-vesical fascia (Ellis).

It seems to me that the following considerations may make the matter clearer.

1. The Pubic arch is of course below the level of the Symphysis.



No. 18.

DIAGRAM OF THE POSTERIOR SURFACE OF THE SYMPHYSIS PUBIS, showing the divisions of the Pelvic fascia and the connections of the Posterior layer of the Triangular ligament.

P. Prostate.

B. Bladder, drawn backwards.

p. p. Pubo-prostatic ligaments.

L. L. Anterior fibres of Levatores ani, arising from the lower part of the Symphysis.

T. T. The Posterior layer of the Triangular ligament.

The white line corresponds to the cut edge of the Recto-vesical fascia. The Pubo-prostatic ligaments to the anterior edges of the same; between these there is an interval in which the Recto-vesical fascia dips down in the median line to join the Posterior layer of the Triangular ligament and the Capsule of the Prostate. The Pubo-prostatic ligaments are above the Levatores ani muscles.



2. The white line extends from the *lower part* of the Symphysis Pubis.

Therefore the *Triangular ligament must be below the level of the Pelvic fascia*, which only extends as far down as the white line.

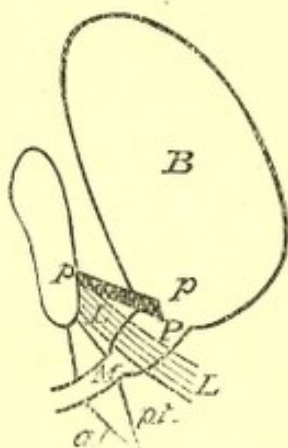
I believe the true account, and it is one which I have verified by dissection, to be as follows:—

The **Superficial layer** is a *special fascia*. All accounts here agree. The **Deep layer** is formed by the **Obturator fascia**, which anteriorly is found to stretch across the Pubic arch and close it; or perhaps a little more exactly, the Obturator fascia may be described as running down to be fixed to the margin of the Pubic arch, and a little above its attachment to give off a process which passes across the upper part of the arch, and which, joining with a like process from the fascia of the opposite side, forms the Deep layer of the Triangular ligament. If, therefore, in Gray's account for *Pelvic* we write *Obturator*, it would be correct. The Triangular ligament is continuous behind with the Anal fascia, but I do not think that the second alternative of Quain's description is correct, viz., that the Posterior layer is derived from the Anal fascia, for this would be tracing a comparatively thick membrane from a very thin one, and as to the first, that it is a special structure not connected with any division of the Pelvic fascia, I would say that I have often made out the continuity with the Obturator piece.

Finally, we have Ellis's derivation from the Recto-vesical layer. This to my mind cannot be the case, for, as is indeed expressly stated by Quain, the fibres of origin of the Levator ani muscle from the Symphysis Pubis, are found distinctly, between the Recto-vesical fascia and the Posterior layer of the Triangular ligament.



It is, however, a fact that the Recto-vesical fascia closes the Pelvis *above* these attachments of the Levatores ani, "between the Pubo-prostatic ligaments of opposite sides," except in the centre, where it dips down to join the Prostate, leaving a small interval ; but this makes another layer closing the Pelvis just below the Symphysis, and we have indeed from without inwards—



No. 19.

ANTERO-POSTERO VERTICAL SECTION THROUGH THE BLADDER AND  
SYMPHYSIS PUBIS.

B. Bladder.

P. Prostate.

M. Membranous Urethra.

p. p. Pubo-prostatic ligament.

L. L. Levator ani, arising from the Symphysis, and placed between the Pubo-prostatic ligament (*i. e.*, Recto-vesical fascia) and the Posterior layer of the Triangular ligament.

p. t. Posterior layer, and

a. t. Anterior layer of the Triangular ligament.

1. The Superficial layer of the Triangular ligament.

2. The Deep layer of the same, derived from the Obturator fasciæ.

3. The Recto-vesical fascia.

And between the Recto-vesical fascia and the



Triangular ligament, a median septum is formed by the former dipping down in the centre to join the latter. On either side of this there is a little space bounded above by the Recto-vesical fascia, below by the Deep layer of the Triangular ligament, and internally by the median septum, externally by the Pubic bone, and in this the anterior fibres of the Levator ani muscle run up to the Symphysis.

The above statement is pretty nearly a reprint of my note in the "Guy's Gazette." Since it was written I have consulted Henle, and I gather that allowing for his difference of description, the connections are much the same as given above. "Handbook of Anatomy," vol. ii., part 1, pp. 406-8, p. 525, and fig. 402, and pp. 541-42.

I find also that Godlee in the text to Part VI. of his Plates makes the following statements (page 220):—"It (Obturator fascia) is to some extent continuous, along the arch of the Pubes, with the Posterior layer of the Triangular ligament." And again (page 221):—"The Posterior layer of the Triangular ligament \* \* \* at its attachment to the Pubic arch may be said to be continuous with the Obturator fascia."

## A DISSECTION TO EXPOSE THE PROFUNDA FEMORIS ARTERY.

POSITION.—The subject lying upon its back, the thigh abducted, and rotated out, the knee flexed, so that the foot of the side to be dissected rests upon the opposite thigh.

### I. SKIN INCISIONS.

1. From immediately below the centre of Poupart's



ligament along the upper two thirds of a line leading to the **internal Condyle** of the Femur.

2. An oblique incision at the upper end of No. 1, reaching for one and a half inches on either side, parallel with Poupart's ligament.
3. A transverse cut at the lower end of No. 1, for one and a half inches on either side.

Reflect the flaps inwards and outwards, and expose the **superficial fascia**.

This will be found at the upper part of the thigh to consist of **two layers**, which are most easily separable on the inner side of the Saphenous vein.

Dissect out in it—

1. The **Superficial External Pudic** artery, at the upper and inner part.
2. The **Superficial Epigastric** artery, passing upwards over the centre of Poupart's ligament.
3. The **Superficial Circumflex Iliac** artery at the upper and outer part.
4. Small arteries derived from the **Femoral** trunk will be seen, with the several cutaneous nerves to be mentioned below.
5. The **Long Saphenous** vein receiving branches corresponding to the three above-named arteries, and at the upper part a large branch which collects the blood from the inner and back parts of the thigh; sometimes there is a corresponding branch on the outer side.
6. Cutaneous twigs of the **Internal Cutaneous** nerve, one perforating near the Saphenous opening, and one or more lower down the thigh.
7. The **Middle cutaneous** nerve perforating the deep fascia at about the centre of the thigh, about three



inches below Poupart's ligament. There are two branches, of which the outer is only seen to a small extent.

8. The **Crural branch of the Genito-crural nerve** cutaneous, near the middle line, about one inch below Poupart's ligament. It is seen to **communicate** below with the **Middle Cutaneous nerve**.
9. Numerous **lymphatic vessels** in front of the thigh running upwards to **lymphatic glands**, which are found arranged in a row along the **Long Saphenous vein**.

II. Remove the preceding structures, and expose the **deep fascia**.

At the upper and inner part of the thigh, immediately below Poupart's ligament, the **Saphenous opening** will be displayed: and the deep layer of the superficial fascia (**Cribri-form fascia**) which is attached to its margins being removed, a portion of the **Femoral sheath** will appear at its outer part.

### III.

- a. Clear away the **deep fascia**. In doing this the attachment of the **superior Cornu** of the **Saphenous opening** to Poupart's ligament must be divided. The cutaneous nerves should be preserved.
- b. Remove fat, fascia and lymphatics, from **Scarpa's triangle**.

There will now be exposed—

1. The lower portions of the **Sartorius** and **Adductor longus** muscles.
2. The **Psoas** and a portion of the **Iliacus** muscles at the upper and outer part, most external of those forming the floor of **Scarpa's triangle**; the **Iliacus** being outermost.



3. The lower part of the **Pectineus** muscle.
4. A small piece of the **Adductor brevis** muscle, between the **Pectineus** and the **Adductor longus** muscles.
5. A portion of the **Vastus internus** muscle below.
6. The **Crural sheath** covering in about the upper two inches of the **Femoral** vessels, and the ordinary areolar sheath below it. This, however, will most probably be taken away in cleaning the triangle, if not, it should now be removed. It will then be seen that the sheath is divided into three compartments by two fascial septa, the outermost one of which contains the **Femoral artery**, the middle the **Femoral vein**, and the innermost, which is only half an inch in length, contains a lymphatic gland.
7. The **Femoral artery** is seen giving off the **Superficial Pudic**, **Epigastric**, and **Circumflex Iliac** arteries, at the upper part, and lower down the **Inferior External Pudic** twig, which crosses inwards over the **Pectineus** muscle. The **Profunda** branch arises from one to two inches below **Poupart's** ligament on the outer side, but is exceedingly variable in its place of origin, and may come off at any point between **Poupart's** ligament and four inches below it. The **Internal** and **External Circumflex** branches of the **Profunda** artery may be seen at their origins, the former passing backwards between the **Psoas** and **Pectineus** muscles, the latter running out between the **Superficial** and **Deep** divisions of the **Anterior Crural** nerve. These last two branches, however, are also very variable in origin, and are often found arising from the **Common Femoral** trunk. **Muscular** branches of the **Femoral** artery are also displayed.



8. The **Femoral vein** is seen receiving branches similar to those of the main artery, except that the twigs corresponding to the **Superficial Pudic**, **Epigastric**, and **Circumflex Iliac** arteries run into the **Long Saphenous vein**, which also is seen to join the **Femoral vein** quite at its upper part. The **Femoral vein** at **Poupart's ligament** lies internal to the artery, but at the apex of **Scarpa's triangle** is beneath it; the **Profunda vein** is superficial to its artery, so that in **Scarpa's triangle** these two large veins lie between the **Superficial** and **Deep Femoral arteries**.
9. The **Anterior Crural nerve** is displayed lying between the **Psoas** and **Iliacus** muscles, about half an inch to the outer side of the **Femoral artery**. The **Middle** and **Internal Cutaneous**, and the **Internal Saphenous** offsets are traceable from it. Parallel with the last nerve, but external to it, a large nerve to the **Vastus internus** muscle may be seen. The **Middle Cutaneous** branch is found supplying the **Sartorius** muscle, and the two small nerves to the **Pectineus** muscle, which pass beneath the **Femoral artery**, may be followed. The distribution of the other muscular branches to the **Rectus** and **Vastus externus** muscles cannot be traced, but they are seen at their origins.
10. By separating slightly the **Pectineus** from the **Adductor longus** muscles, the **Superficial division** of the **Obturator nerve** is seen lying upon the small portion of the **Adductor brevis** muscle which is exposed. A slender twig of this nerve which runs along the inner border of the **Adductor longus** muscle may now be found. It is distributed to



the Obturator plexus, but the ending cannot now be traced.

IV. Divide now the **Sartorius muscle** at the lower part of the dissection, and turn it outwards and inwards. Beneath it is found the aponeurotic covering of **Hunter's canal**, which should be taken away. In addition there will now be seen—

1. Further portions of the **Femoral artery and vein**, the latter passing to the outer side of the artery. The **Anastomotica Magna branch** of the artery, coming off at the lower part of the canal.
2. More of the **Long Saphenous nerve**. It may lie on the outer side of the artery throughout the extent of the canal, or it may cross from the outer to the inner side, over it.
3. The branch of the **Obturator nerve** to the plexus of the same name may now be traced to its communication with the Inner branch of the **Internal Cutaneous nerve**.
4. Both **Anterior and Inner branches** of the **Internal Cutaneous nerve** will be seen, the former lying upon the artery, the latter to its inner side. A communication between the **Inner branch** and the **Saphenous nerve** is traceable, thus completing the so-called **Obturator plexus**.

V.

- a. Hook outwards the **Anterior Crural nerve** dividing the **Internal Cutaneous** and **Long Saphenous branches**.
- b. Cut through the **Femoral artery** at its lowest part, and hook the ends upwards and downwards, dividing at the same time its muscular offsets.
- c. Remove the **Femoral and Profunda veins**.



- d. Divide the tendinous insertion of the **Adductor longus muscle**, and pull the muscle inwards.

There will now be exposed—

1. The lower part of the **Adductor magnus muscle**, at its attachment to the Femur.
2. The whole length of the **Profunda Femoris artery**, and the origin of its branches, viz., the **Internal** and **External Circumflex**, and the four **Perforating**; the upper two of which pierce the **Adductor brevis muscle**, the third and fourth (which last is the termination of the artery) passing to the back of the thigh through the **Adductor magnus muscle**.

VI. The **Adductor magnus muscle** must be divided at its Femoral attachment, behind the opening for the Femoral artery, to follow out the terminal or fourth Perforating twig.

## A DISSECTION TO EXPOSE THE GLUTEUS MINIMUS MUSCLE.

POSITION.—The body lying on its face, the Abdomen and the Pelvis raised on blocks, and the legs hanging down to a moderate degree.

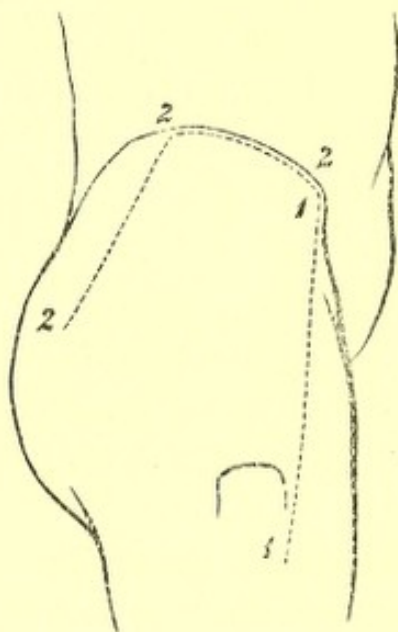
### I. SKIN INCISIONS.

1. From the anterior-superior Iliac spine to the anterior-inferior angle of the great Trochanter.
2. From the upper end of No. 1, along the anterior two thirds of the Iliac crest, and then downwards and backwards to a point three inches below the posterior-superior Iliac spine.



Reflect the flap downwards, and expose the loose fascia of the buttock, containing—

1. The posterior branches of the **External Cutaneous** nerve most anteriorly.
2. The **Lateral Cutaneous** branch<sup>1</sup> of the last **Dorsal** nerve, crossing the **Iliac crest**, and running as far as the **Trochanter major**.



No. 20.

3. The **Iliac** branch of the **Ilio-hypogastric** nerve<sup>1</sup> posterior to this.
4. The external branches of the posterior primary divisions of the first three **Lumbar** nerves, crossing the **Iliac crest** still further inwards.
5. The external branches of the posterior primary divisions of the first two **Sacral** nerves,—the upper one near the **Iliac crest**, the lower giving filaments over the lower part of the surface exposed.

<sup>1</sup> These nerves bear an inverse ratio to one another as to their size.



## II. Remove the preceding structures and expose—

The fascia lata forming externally the Ilio-tibial band, above covering the Gluteus medius muscle, and dividing to enclose the Gluteus maximus muscle.

## III. Remove the fascia covering the Gluteus maximus, and reflect this muscle inwards, by dividing the upper part of its fascial insertion and the fleshy fibres, in a line corresponding to the lower margin of the reflected skin. In doing this—

- a. The Superficial branch of the Gluteal artery will be divided.
- b. The Inferior Gluteal branches of the Small Sciatic nerve will be cut, with arteries from the Sciatic.
- c. Branches to the reflected muscle from the part of the Sacral plexus formed by the first and second nerves will be seen.
- c. The bursæ over the great Trochanter, and the Vastus externus muscle will be opened.

Divide the Tensor vaginae femoris muscle at its origin, and hook it well forwards, cutting the branches supplying it from the Gluteal artery and nerve.

There will now be exposed, from above downwards:—

1. The Gluteus medius muscle.
2. The Piriformis muscle.
3. The Gemellus superior muscle.
4. The Obturator internus muscle.
5. The Gemellus inferior muscle, at its insertion.
6. The Vastus externus muscle on the outer side.
7. The Trochanter major, below and externally.
8. Beneath the Tensor vaginae muscle is an anastomosis



between the Gluteal, External Circumflex, and Circumflex Iliac arteries.

9. The divided **Superficial** branch of the Gluteal artery and vein above the Piriformis muscle.
10. The **Sciatic** artery and vein emerging below the Piriformis muscle.
11. The **Pudic** artery, vein, and nerve, leaving the Pelvis at the same spot; the artery giving a branch to the Digital fossa.
12. The **Great and Small Sciatic** nerves are seen below the muscle.
13. The nerve to the **Obturator internus** muscle is seen crossing the spine of Ischium, usually having the Pudic artery to its inner side and the Pudic nerve still more internal.
14. The small nerve to the **Gemellus superior** muscle may be seen by pulling outwards the Great Sciatic nerve.

IV. Cut through at their origins and insertions, the **Gluteus medius**, and **Piriformis** muscles, and remove them. Branches of the Gluteal artery and nerve will be divided in taking away the former muscle.

1. The **Gluteus minimus** muscle will now be fully exposed, and lying upon it the **Gluteal** nerve and **Deep branch of the artery** of the same name. Each divides into an **upper** and **lower** branch, the former of which runs along the upper margin of the muscle, the latter crosses it, passing downwards and outwards; the nerve to supply the **Tensor vaginæ femoris** muscle, and the artery to join in the anastomosis previously mentioned.

The Great Sciatic nerve may be required to be pulled inwards a little from off the muscle.



2. All the structures previously mentioned as leaving the Pelvis below the Piriformis muscle will be more fully seen, and in addition
3. The Pelvic fascia on the deep surface of the Piriformis muscle.

### A DISSECTION TO EXPOSE THE POPLITEUS MUSCLE.

POSITION.—The leg lying on its anterior surface.

#### I. SKIN INCISIONS.

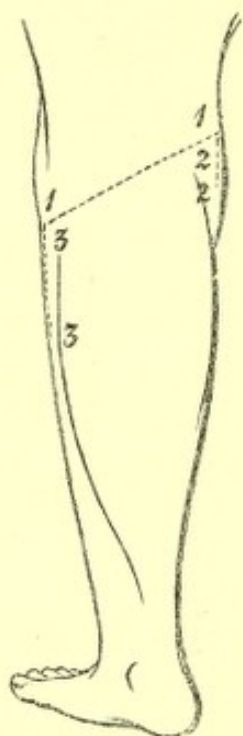
1. From the middle of the outer surface of the external Condyle of the Femur obliquely downwards and inwards across the back of the joint to the upper margin of the inner Tuberosity of the Tibia at its centre.
2. From the outer end of (1) vertically downwards for one inch.
3. From the inner end of (1) vertically downwards for the upper third of the leg.

Reflect the flap downwards, and expose the superficial fascia, containing—

1. Branches of the Internal Saphenous nerve running backwards over the Tibia at its inner part.
2. The Inner branch of the Internal Cutaneous nerve posterior to this.
3. Branches of the Small Sciatic nerve perforating the fascia over the Popliteal space, and the nerve itself coming through just below it.
4. Branches of the External Popliteal nerve supplying the skin at the outer part.



5. On the inner side a cutaneous artery from the *Anastomotica Magna*.
6. The termination of the **Sciatic artery** with the Small Sciatic nerve, but here reinforced by a branch from the **Popliteal**.
7. A cutaneous artery on the outer side from the **Popliteal**, which accompanies the **External Popliteal nerve**.



No. 21.

8. The **Internal Saphenous vein** along the inner border of the Tibia.
  9. The **External Saphenous vein** along the centre of the space, and usually perforating the fascia lata opposite the centre of the articulation, but sometimes running up higher.
  10. **Lymphatics.**
- II. Remove the preceding structures including the **Internal Saphenous vein**. This exposes the **fascia lata**,



strengthened over the Popliteal space by transverse fibres. This must be taken away, and then the following are exposed—

1. Above and externally, the tendon of the **Biceps** muscle inserted into the head of the Fibula and split by the **Long External Lateral ligament**.
2. Below, externally and internally, portions of the heads of the **Gastrocnemius** muscle, the greater part of the inner being visible.
3. A part of the origin of the **Plantaris** muscle, above the outer head of the **Gastrocnemius** muscle.
4. On the inner side and below, the tendons of the **Semi-membranosus** and the **Semitendinosus** muscles, the prolongation of the latter to the fascia lata is divided.
5. Along the median line, the **Internal Popliteal** nerve giving off branches below, to both heads of the **Gastrocnemius**, to the **Plantaris**, **Soleus**, and **Popliteus** muscles, the commencement of the **Inferior Internal Articular** nerve, and a cutaneous branch running downwards to the integument of the calf, and called the **ramus Communicans Tibialis**,<sup>1</sup> or sometimes the **External Saphenous** nerve.
6. The **External Popliteal** nerve following the tendon of the **Biceps** muscle. A slender branch of this, or of the **Great Sciatic** nerve, which comes off above the limits of the dissection, may be seen lying on its outer side; it gives off, above, the **Superior External Articular**, and below, the **Inferior External Articular** branches, the latter of which passes beneath the

<sup>1</sup> For simplicity's sake these branches should be called the **Communicans Tibialis** and **Communicans Fibularis**, and the nerve which results from their junction the **External Saphenous**.



outer head of the Gastrocnemius muscle. The **External Popliteal** nerve gives off the ramus **Communicans Peronei**<sup>1</sup> or **Fibularis**, which perforates the fascia lata considerably above the ramus **Communicans Tibialis**.

7. The **Popliteal vein** below and internal to the **Internal nerve**, receiving the **External Saphenous** branch, and other veins corresponding to the offsets of the artery to be next enumerated.
8. The **Popliteal artery** below and internal to the vein, and almost hidden by it and the **Internal nerve**. Branches running up to the **Ham-string** muscles and others descending to the calf are seen (**Sural**), the **Superior External Articular** artery with the corresponding nerve, the **Inferior Internal and External Articular** offsets, with the nerves of the same name, and the **Azygos** branch. There is also a cutaneous branch previously seen accompanying the **External Popliteal nerve**.
9. Four or five lymphatic glands or fewer along the **Popliteal vessels**.

### III.

- a. Hook the **Semitendinosus**, and **Semimembranosus** muscles internally.
- b. Divide the **Gastrocnemius** muscle above and below, and remove it within the limits of the skin incisions. Its nerves and arteries will be divided, and there will now be exposed—
  1. The **Popliteus** muscle at the upper part of the **Tibia**,

<sup>1</sup> For simplicity's sake these branches should be called the **Communicans Tibialis** and **Communicans Fibularis**, and the nerve which results from their junction the **External Saphenous**.



covered by its special fascia derived from the tendon of the Semimembranosus muscle.

2. The Soleus muscle below it.
3. The Plantaris muscle crossing it, passing over the vessels and the Internal nerve.

The Plantaris should be taken away, inasmuch as it crosses the next-mentioned structures.

4. More of the Internal Popliteal nerve and the branches more fully—viz., to the Soleus muscle, to the Popliteus muscle. The nerve to this latter muscle is seen turning round the lower border. The Inferior Internal Articular branch running along the upper border of the Popliteus muscle, and beneath the expansion of the Semimembranosus muscle with the corresponding artery.
5. A further portion of the Popliteal artery, and its branches enumerated above, more fully.
6. More of the Popliteal vein.

#### IV.

- a. Divide now and remove the Popliteal artery and vein, and the Internal Popliteal nerve.
- b. Cut through the Biceps tendon. Open the Capsule of the joint by removing its outer part, and divide the Long and Short External Lateral ligaments.
- c. Remove the fascia over the Popliteus muscle, and trace out the tendinous origin of the muscle from the external Condyle.

The whole of the Popliteus muscle will be now exposed, and in addition—

1. The ligament of Winslow.
2. More of the Inferior External Articular nerve, and vessels.

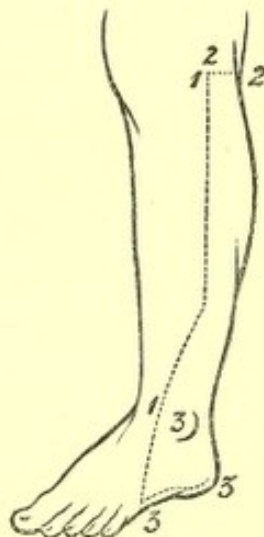


## A DISSECTION TO EXPOSE THE PERONEAL ARTERY AND ITS BRANCHES.

**POSITION.**—The body supine, the leg rotated outwards and lying upon its inner aspect.

### I. SKIN INCISIONS.

1. From the head of the Fibula along the upper two thirds of the bone, to the centre of the anterior surface of the ankle-joint.



No. 22.

2. A transverse incision from the upper end of No. 1 backwards, to a little beyond the middle of the posterior surface of the leg.
3. A third from the lower end of No. 1 downwards and forwards to the base of the fifth Metatarsal bone, then backwards along the inner border of the foot to the centre of the heel.

Reflect the flap backwards, and expose the superficial fascia and the following parts—



1. The triangular subcutaneous surface and the external Malleolus of the Fibula.
2. The **External Saphenous vein**, from its commencement at the outer side of the Dorsum of the foot, upwards behind the outer ankle and along the median line of the leg through the whole extent of the dissection.
3. **Cutaneous arteries.**
  - a. From the **Popliteal** above and externally, with branches of the **External Popliteal nerve**.
  - b. From the **Sciatic** along the median line, with the **Small Sciatic nerve**, reinforced by twigs from the **Popliteal artery**.
  - c. Numerous branches from the **Peroneal** along the outer border of the Fibula, and others behind the external Malleolus.
  - d. From the **Anterior Tibial** artery in front of the Fibula, with branches of the **Musculo-cutaneous nerve**; and the **External Malleolar** arterial branch in front of the ankle.
  - e. Twigs from the **External Plantar** and **Tarsal arteries** at the outer side of the Dorsum of the foot.
4. Cutaneous branches of the **External Popliteal nerve** at the upper and outer part; one larger than the rest, called **ramus Communicans Fibularis**, running downwards and inwards to the middle of the calf.
5. The small portion of the **Communicans Tibialis nerve** seen superficial to the deep fascia, a little above the centre of the calf.
6. The nerve called **External Saphenous** resulting from



the junction of the preceding, and accompanying the vein of the same name behind the external Malleolus to the outer border of the foot.

7. The **Small Sciatic nerve** perforating the fascia lata just below the Popliteal space, running down the middle of the leg, and joining the **Communicantes Tibialis** and **Fibularis** nerves just at their union. Branches of this nerve are cutaneous at the upper part.
8. In front of the Fibula branches of the **Musculo-cutaneous nerve**, which run to the fourth and fifth toes, and other filaments supplying the skin on the outer side of the Dorsum of the foot.

II. Remove the preceding structures and expose the fascia lata, which will be seen forming the upper and lower divisions of the **Anterior Annular ligament** in front of the ankle, and the **External Annular ligament** between the Malleolus and Os Calcis. In front of the exposed portion of the Fibula the fascia is very strong, and joined to the outer border of the bone.

III. Remove the above fascial structures and expose—

1. The **Gastrocnemius muscle** and tendo Achillis.
2. The outer border of the **Soleus muscle**, seen beneath the preceding.
3. The **Peroneus longus muscle** lying on the Fibula, and covering in the **Peroneus brevis muscle** except for the anterior part of the lower third.
4. The lower part of the **Peroneus tertius muscle** in front of the Fibula.
5. The upper part of the origin of the **Extensor brevis digitorum muscle** on the Dorsum of the foot.



6. The **Anterior Peroneal** artery and vein in front of the lower end of the Fibula, and on the outer side of the Dorsum of the foot.
7. The small portion of the lesser **Sciatic nerve**, which, in this dissection, lies beneath the fascia lata.
8. The greater part of the **Communicans Tibialis** nerve, which is beneath the deep fascia.
9. The **External Popliteal** nerve at the upper part of the head of the Fibula.

IV. Divide the **Gastrocnemius** and **Soleus** muscles above as far as the centre, and pull them well inwards. In doing this, the nerve to the latter will be probably cut through.

Remove the aponeurotic arch over the upper part of the **Posterior Tibial** vessels and nerve.

There will now be exposed—

1. The **Popliteus** muscle covered by its fascia at the upper part, with its nerve lying on the posterior surface, and turning round the lower border.
2. The aponeurosis stretching over the **Tibialis posticus** muscle, between the bones of the leg, immediately below it. The fibres of the muscle are visible through the aponeurosis.
3. The **Flexor longus pollicis** muscle, lying on the lower two thirds of the inner surface of the Fibula.
4. The **Popliteal** artery and its bifurcation. The **Anterior Tibial** branch passing between the lower border of the **Popliteus** muscle and the **Tibialis posticus** muscle. The **Posterior Tibial** branch lying on the aponeurosis of the **Tibialis posticus** muscle, and giving off the **Peroneal** artery, which runs downwards and outwards for a short distance to enter the substance of the **Flexor longus pollicis** muscle.



5. The *venæ comites* of the preceding, uniting to form the Popliteal vein.
6. The Posterior Tibial nerve at first to the inner side of the artery of the same name, but soon crossing it to the outer side. The branches to the *Tibialis posticus* and *Flexor longus pollicis* muscles are seen, the latter running with the Peroneal artery.

## V.

- a. Trace down the Peroneal artery in the substance of the *Flexor longus pollicis* muscle, divide the muscle below and pull its lower end downwards. The nutrient and muscular branches will be now seen.
- b. Divide the External Annular ligament if not done previously, and open up the sheath of the *Peroneus longus* muscle at the outer border of the foot.
- c. Cut through the *Peronei longus* and *brevis* muscles, and turn the ends upwards and downwards.
- d. Saw through the Fibula at the junction of the lower with the upper three fourths, and again two inches lower down, above the external Malleolus. Remove this piece of bone by dividing the attached fibres of the *Tibialis posticus* and *Peroneus tertius* muscles and the Interosseous and Inferior Interosseous ligaments. The Peroneal artery may now be followed in its whole course. Below, it is seen lying on the posterior Tibio-fibular ligament, and receiving the communicating branch from the Posterior Tibial artery, which may come over or under the tendon of the *Flexor longus pollicis* muscle. The artery may be traced down behind the



external Malleolus to its anastomoses, with twigs of the Tarsal and External Plantar arteries. The Anterior Peroneal branch may be followed round the front of the outer ankle to its anastomoses with the External Malleolar and Tarsal arteries.

## A DISSECTION TO EXPOSE THE PLANTAR ARCH.

POSITION.—The foot must be arranged with the Plantar surface uppermost. In an entire body this will best be done by turning the subject on the face, flexing the knee, and supporting the leg with blocks.

### I. SKIN INCISIONS.

1. Along the median line of the foot from the Os Calcis to the root of the third toe.
2. Transverse incisions from the anterior and posterior ends of this, to the inner and outer borders of the foot and heel respectively.

Reflect the flaps inwards and outwards, and expose the superficial fascia. Clear it away, dissecting out at the same time—

1. The Superficial Transverse ligament, across the roots of the toes in the rudimentary web of the foot.
2. The Lumbricales muscles, with the Digital vessels and nerves in the intervals of the Plantar fascia.
3. The Plantar Cutaneous branches of the Posterior Tibial artery, vein, and nerve, in the hollow of the heel.
4. At short distances from the inner and outer borders of the foot along the furrows of the internal and external intermuscular septa, some small unnamed



arteries and nerves derived from the **Internal and External Plantar**, respectively.

5. At the clefts of the toes, the **Digital vessels and nerves** will be found issuing from between the processes of the **Plantar fascia** and passing beneath the **Superficial Transverse ligament**; those to the inner side of the first and the outer side of the fifth toes, however, perforate further back than the rest. The origin of these vessels and nerves is not now traceable.
6. When the superficial fascia or fat is completely removed, the preceding vessels and nerves will be displayed, and the **Plantar fascia**. This will be found to be made up of three portions: a central, thick and triangular, with its apex at the heel, and its base cut into five processes, one for each toe; and two lateral portions which are thin and unimportant, except that there is a strong process on the outer side between the **Os Calcis** and the base of the fifth **Metatarsal bone**.

II. Remove now the **Plantar fascia**, by a longitudinal incision along the median line, and a transverse one at the **Os Calcis**. Reflect it forwards; in doing this two septal processes, one on each side of the **Flexor brevis digitorum** muscle, will be found. The **Digital vessels and nerves** and the **Lumbricales** muscles are to be preserved, the rest of the above-mentioned structures will be removed. There will now be displayed—

1. The **Abductor pollicis** muscle, along the inner border of the foot.
2. The **Flexor brevis digitorum** muscle, along the centre of the foot. It is found to be giving off four tendons, one to each of the four outer toes, these



are seen entering their corresponding sheaths, which reach for a short distance into the foot.

3. The **Lumbricales** muscles are seen in the intervals of the tendons of the **Flexor brevis digitorum** muscle. The innermost one is on the Tibial side of the tendon to the first toe, the others are in the intervals of the tendons; they pass to the Tibial side of the first Phalanges.
4. The **Abductor minimi digiti** muscle, along the outer border of the foot.
5. The tendon of the **Flexor longus pollicis** muscle in part, on the outer side of the **Abductor pollicis** muscle.
6. Small portions of the insertions of the **Flexor brevis pollicis** muscle, into the inner and outer sides of the base of the Metatarsal Phalanx of the great toe.
7. A small part of the **Flexor brevis minimi digiti** muscle at its insertion into the first Phalanx, lying on the inner side of the **Abductor minimi digiti** muscle.
8. The **Internal Plantar artery and vein**, in the anterior part of its course emerging from beneath the **Abductor pollicis**. Different accounts of the ending of this artery are given. According to Gray and Quain, it terminates by running along the inner side of the great toe. Ellis's description is that it gives off four branches, the innermost of which runs to the inner side of the great toe, the outer three dip down in the first, second, and third interosseous spaces to join the Digital branches of the Deep Plantar arch. I believe that both accounts are true in different cases.



9. The **External Plantar artery and vein**, in a small part of their course. They are seen at the anterior and outer part of the foot, between the *Abductor minimi digiti* muscle and the outer border of the *Flexor brevis digitorum* muscle. The branch to the outer surface of the little toe is visible.
10. The **Internal Plantar nerve**, emerging with the corresponding artery from beneath the *Abductor pollicis*, and dividing in front into four **Digital branches** which lie upon the tendons of the *Flexor brevis digitorum*, one undivided for the inner side of the great toe, the others bifurcating at the clefts of the toes to supply the contiguous sides of the first and second, second and third, and third and fourth. In this dissection they are only seen as far as the bifurcation. By separating the *Abductor pollicis* from the *Flexor brevis digitorum* posteriorly, branches may be traced from the trunk of the **Internal Plantar nerve** to these muscles. The innermost **Digital** offset will be found supplying the *Flexor brevis pollicis* muscle, the next two the two innermost **Lumbricales** muscles, and the outermost communicates with the inner of the two **Digital** branches from the **Superficial** division of the **External Plantar nerve**.
11. The **Superficial branch of the External Plantar nerve**, appearing between the *Abductor minimi digiti* and the *Flexor brevis digitorum* muscles, a little anterior to the base of the fifth **Metatarsal** bone. It is seen dividing into two **Digital** branches, one undivided for the outer side of the little toe, the other bifurcated for the contiguous sides of this toe and the next.



## III.

- a. Cut through the **Internal Plantar nerve** behind, and throw it over the toes. The branches of the **artery of the same name**, to the second, third, and fourth interosseous spaces, must be divided if present.
- b. Divide the **Flexor brevis digitorum** muscle, and throw it towards the toes. Its nerve from the **Internal Plantar** will be torn through.

There will now be exposed—

1. The tendon of the **Flexor longus digitorum** muscle. This is seen to be dividing into four slips, one for each of the four outer toes. They each enter the corresponding **Digital sheath** beneath the **Flexor brevis** tendon. The following are also seen connected with this muscle, viz.—
  - a. The **Accessorius** muscle, passing from the **Os Calcis** to the hinder border of the tendon of the **Flexor longus digitorum**, but from which tendinous slips are traceable to those tendons of the long **Flexor** which run to the second, third, and fourth toes (Turner). A portion of the **Inferior Calcaneo-cuboid** or **Long Plantar ligament** is seen behind close to the **Os Calcis**, between its two heads of origin.
  - b. The **Lumbricales** muscles. The innermost arising from the **Tibial** side of the innermost tendon, the other three from the contiguous sides of the first and second, second and third, and third and fourth tendons.
2. The tendon of the **Flexor longus pollicis** muscle, lying beneath (in this position) the **Flexor longus digitorum** muscle. A tendinous slip passes from the



former to the latter at the hinder part of the foot, and is said to be traceable to the slips of the Flexor longus digitorum, running to the second and third toes (Turner).

3. A further portion of the **Flexor brevis pollicis** muscle, running to each side of the base of the first Phalanx of the great toe, with the tendon of the Flexor longus pollicis lying between these two heads.
4. The **Flexor brevis minimi digiti** muscle, lying upon the Metatarsal bone of the little toe.
5. The **Plantar and Dorsal Interossei** muscles of the fourth space, the former lying externally.
6. The **External Plantar** artery, with its accompanying vein. The vessel is seen behind, emerging from beneath the Abductor pollicis muscle, and running obliquely forwards and outwards over the Accessorius muscle to a point opposite the base of the fifth Metatarsal bone. It then turns transversely inwards, and passes beneath the tendon of the Flexor longus digitorum muscle; just as it makes this bend it gives off the branch to the outer side of the little toe, which has been previously seen.
7. The **External Plantar** nerve, taking the same course as the artery as far as the base of the fifth Metatarsal bone. At that point it is divided into a **Superficial** and a **Deep** branch. The former has been already seen dividing into two **Digital** branches for the little, and the opposed side of the fourth toe; besides this, the outermost of the two is now seen to be supplying the **Flexor brevis minimi digiti** muscle, and often the **Interossei** muscles of the fourth space; the inner has been found to communicate with the fourth Digital branch of



the Internal Plantar nerve. The Deep division passes, with the External Plantar artery, beneath the tendons of the Flexor longus digitorum. The trunk of the External Plantar nerve may be now found supplying branches to the Accessorius and Abductor minimi digiti muscles, in the posterior part of its course which was previously covered by the Flexor brevis digitorum.

## IV.

- a. Divide the tendon of the Flexor longus digitorum and the Accessorius muscle transversely at their junction. This point is taken in order to leave the Accessorius muscle with the External Plantar vessels and nerve lying upon it. The tendons of the long Flexor muscle, with the attached Lumbricales, should now be reflected over the toes. As this is done two slender nerves to the two outermost Lumbricales will be found coming from the Deep branch of the External Plantar nerve. There will now be exposed—
1. The Flexor brevis pollicis muscle, most internally.
  2. The Adductor pollicis muscle, external to this parallel with its outer border.
  3. The Flexor brevis minimi digiti muscle, lying upon the fifth Metatarsal bone.
  4. The Transversalis pedis muscle, lying transversely across the Metatarso-phalangeal articulations.
  5. The Plantar and Dorsal Interossei muscles, of the third and fourth spaces, and just the anterior end of the Plantar of the second, lying in the triangular interval formed by the Adductor pollicis, Flexor brevis minimi digiti, and Transversalis pedis mus-



cles. The Adductor pollicis may, however, conceal the Interossei of the second space completely.

6. Further portions of the **External Plantar vessels**. The portion of the artery which extends beyond the base of the fifth Metatarsal bone is called the **Plantar arch**. The **Digital branches** of the arch which run forwards in the fourth and third spaces, and the anterior part of the one in the second space, will be seen. They pass in front beneath the **Transversalis pedis** muscle. The **Posterior Perforating offsets** of the two outer Digital branches, which pass through the heads of the Dorsal Interossei to the Interosseous arteries of the Dorsum may be traced, but only the anterior part of the Digital branch of the second space will be seen, as the posterior part is concealed by the Adductor pollicis muscle. Each of these Digital branches is seen to bifurcate at the cleft of the toes, and from the point of bifurcation other slender offsets (**Anterior Perforating**) also to the Dorsal Interosseous arteries, are traceable.
7. The **Deep branch of the External Plantar nerve** may be followed to its ending in the Adductor pollicis muscle. Branches are traceable to the **Transversalis pedis**, and at this stage only to the Interossei of the third space, and the fourth when not supplied by the Superficial division. The offsets to the two outer **Lumbricales** have been already seen.

#### V.

- a. Remove now the **Adductor pollicis** muscle and the outer portion of the **Flexor brevis pollicis** muscle. The nerves to the former from the Deep division of the **External Plantar** will be divided.



There will now be exposed—

1. The **Interossei** muscles of the first and second spaces.
2. The remaining portion of the **Plantar arch** and its junction at the back of the first interosseous space, with the communicating branch from the **Dorsalis Pedis** artery. The **Digital** branch of the second space is now displayed, and its **Posterior Perforating** offset is now traceable.
3. The **arteria Magna Pollicis** is seen arising from the **Dorsalis Pedis** artery, where it dips into the sole of the foot. This divides into two branches, the outer of which runs forwards in the first space, and bifurcates for the contiguous sides of the great toe and the next, and the inner of which passes beneath the tendon of the **Flexor longus pollicis** and innermost head of the **Flexor brevis pollicis**, to the inner side of the great toe.
4. The nerves to the **Interossei** muscles of the first and second spaces are now traceable from the **Deep division of the External Plantar nerve**.

The **Plantar arch** is now fully exposed. If the whole of the **External Plantar artery** is to be uncovered, it will be necessary to remove the posterior part of the **Abductor pollicis** muscle and the lower portion of the **Internal Annular ligament**.







## INDEX.

### ABDOMEN.

Structures exposed on opening,  
129, § 1-4.

Layers of wall of, in pubic and  
inguinal regions, 119, § A-K.

### ANASTOMOSIS.

On the Acromion process, 71, § 2.

Beneath the Complexus muscle,  
16, § 6.

About the elbow-joint, 87.

Beneath the Tensor vaginae femoris  
muscle, 175, § 8.

### ARCH.

Aortic, structures crossing, 60,  
§ a-e.

Palmar, deep, formation and  
branches of, 107, § 3.

Palmar, superficial, formation and  
branches of, 103, § 6.

Plantar, formation and branches  
of, 194, § 6.

### ARTERY.

Femoral, branches of, 170, § 7.

Intercostal, anterior, sources of,  
52, c.

Plantar, external, distribution of,  
190, § 9; 192, § 6; 194, § 6;  
195, § 2.

Plantar, internal, distribution of,  
189, § 8.

### ARTERY (*continued*).

Profunda femoris, branches of,  
173, § 2.

Sciatic, termination of, 178, § 6.

Thyroid axis, distribution of, 13,  
§ 13.

Vertebral, relations in interverte-  
bral foramina of, 18.

### AXILLA.

Position of arteries in, 75, § 5.

### CANAL.

Hunter's, structures contained in,  
124, § V. a.

### CORD.

Spermatic, constituents of, at in-  
ternal ring, 126, § d.

### DISSECTION OF

Adductor pollicis muscle, 97.

Anastomoses about elbow, 82.

Arch, deep palmar, 100; plantar,  
187.

Azygos major vein, 62.

Circumflex arteries, anterior and  
posterior, 70.

Cord, spinal, in cervical region,  
40.

Dorsal nerve, first, 33.

Eustachian tube, 18.



DISSECTION OF (*continued*)

- Flexor longus pollicis manus muscle, 92.
- Gluteus minimus muscle, 173.
- Hypoglossal nerve, 24.
- Interosseous arteries, 108.
- Kidney, posterior surface of, 131.
- Mammary, internal, artery, 48.
- Musculo-spiral nerve, 77.
- Obturator nerve, 118.
- Orbit, through outer wall, 1.
- Otic ganglion, 18.
- Peroneal artery, 182.
- Popliteus muscle, 177.
- Portal vein, 129.
- Profunda femoris artery, 167.
- Pudic artery, 151; another mode, 145 (foot-note).
- Sacral plexus, anterior surface of, 143; posterior surface of, 138.
- Supinator brevis muscle, 88.
- Trachea, anterior surface of, 55.
- Vertebral artery, 7.

## FASCIA.

- Cervical, deep, arrangement at root of neck, 57, § III.; 58, § 1.
- Lumborum, formation of, 133.
- Palmar, description of, 101, § 2; structures between the processes of, 102, § 5.
- Pelvic, description of, 160; dissection of, 144, § *a-g*.
- Plantar, description of, 188, § 6; structures between processes of, 187, § 2.
- Popliteus muscle, of, 180, § 1.
- Recto-vesical, dissection of, 145; § II.
- Temporal, structures between the layers of, 3, § *d*.

## FOSSA.

- Ischio-rectal, boundaries of, 154, § 5, 6, 7; contents of, 154, § 8, 9, 10.

## GLAND.

- Parotid, structures contained in, 26, § 1-3.
- Submaxillary, structures contained in, 27, § *c*.

## LIGAMENT.

- Annular, anterior of wrist, attachment of, 93, § II.
- Triangular, of urethra, note on, 160.

## MEDIASTINUM.

- Structures contained in posterior. Add Trachea and omit Sympathetic cord, 65, § 1-5.

## MEMBRANE.

- Costo-coracoid, structures perforating, 35, § 2.

## MUSCLE.

- Accessory pedis, insertion of, 191, § *a*.
- Complexus, parts beneath, 44.
- Deltoid, parts beneath, 73, § 1-12.
- Extensor tendon, muscles arising by common, 85, § 7.
- Extensors, deep layer of, at back of forearm, 117, § 1-5.
- Flexor longus pollicis pedis, insertion of, 191, § 2.
- Flexor tendon, muscles arising by common, 85, § 3.
- Flexor sublimis digitorum, arrangement of tendons beneath Annular ligament, 95, § 1.
- Gluteus maximus, parts beneath, 140, § 5-19; 156, § 1-10.



**MUSCLE** (*continued*).

Hyoglossus, structures in relation with, 30, § 7-9.

Lumbricales of hand, origins of, 105, § 3.

Lumbricales of foot, origins of, 191, § *b*.

Pterygoid, external, structures in relation with, 21, § 3-5.

**NERVE.**

Buttock, cutaneous nerves of, 174, § 1-5.

Crural, anterior, distribution of, 179, § 9.

Median, in hand, distribution of, 104, § 9.

Obturator, distribution of, superficial division, 125, § 8; deep division, 125, § 26.

Occipital, third, distribution of, 8, § 7.

Plantar, external, 190, § 11; 192, § 7; 194, § 7; 195, § 4; internal, 190, § 10.

Pudic, distribution of Perinæal branch, 155-8, § 1-4.

Sacral plexus, *vide* PLEXUS.

Sacral nerves, loops of posterior primary branches of, 140, § 3, 13.

Saphenous, external, formation of, 179 (foot-note).

Splanchnics, origin of, 66, § 5; endings of, 69, § 7.

Ulnar in palm, 104, § 8; 107, § 6.

**PALM OF HAND.**

Cutaneous vessels and nerves of, 101, § 3-6.

**PALM OF HAND** (*continued*).

Median nerve, distribution in, 104, § 9.

Ulnar nerve, distribution in, 104, § 8; 107, § 6.

**PELVIS.**

Outlet of, parts closing, 146, § 1-8.

Side view of, dissection of, 144, § *a-g*; structures seen in, 146, § 1-16.

**PERINÆUM.**

Anterior triangle of, 156.

**PLEXUS.**

Obturator, formation of, 124, § V. *a*; 72, § 3, 4.

Sacral, formation and origin of branches of, 142, § 1-10; 150, § 7; 159, § 4-6.

**RELATIONS OF**

External and Internal Cutaneous nerves to veins of bend of elbow, 83, § 3, 4.

Intercostal nerve, artery, and vein to one another, 66, § 6.

Median nerve to superficial Palmar arch, 105, § 9.

Mesenteric arteries and veins to one another, 130, § *a, b, c, d*.

Obturator nerve, artery, and vein at wall of pelvis, 145, § 3.

Omentum, lesser, structures contained in, 129, § 1-3.

Posterior Interosseous artery to tendon of Extensor carpi ulnaris, 113, § 22.

Pudic nerve and Perinæal branch to artery in Ischio-rectal fossa, 154, § 9.



RELATIONS OF (*continued*).

Root of lung (right), structures contained in, 65, *vide* ERRATA.

Spine of Ischium, structures crossing, 157, § 7.

## SHEATH.

Of Rectus, formation of, 120, § D, E.

Crural, 170, § 6.

## SOLE OF FOOT.

Cutaneous vessels and nerves of, 187, § 3, 4, 5.

External and Internal Plantar arteries, *vide* ARTERY.

External and Internal Plantar nerves, *vide* NERVE.

## SPACE.

Mediastinal, posterior, *vide* MEDIASTINUM.

Sub-occipital triangular, boundaries of, 15, § 2; contents of, 15, § 5; 16, § 1.

SPACE (*continued*).

Triangular, of neck, posterior, structures contained in, 9-11, § 1-30, omitting § 13, 16, 17.

Triangular, at bend of elbow, 84-5, § 1-4; 85-6, 10-13.

Triangular, of Perinæum, anterior, *vide* PERINÆUM.

Triangular and quadrilateral, of Scapula, from behind, 73; from the front, 75, § 2.

## SPINE OF ISCHIUM.

Structures crossing, 157, § 7.

## STYLOID PROCESS.

Structures attached to, 29, § 1-3.

## VEIN.

Arm and forearm, cutaneous of, 83, § 1.

Saphenous, long, radicles of, in thigh, 122, § 1; 168, § 5.

## ERRATA.

Page 23, § VII. 2, *for* "muscle," *read* "nerve to the Internal Pterygoid muscle."

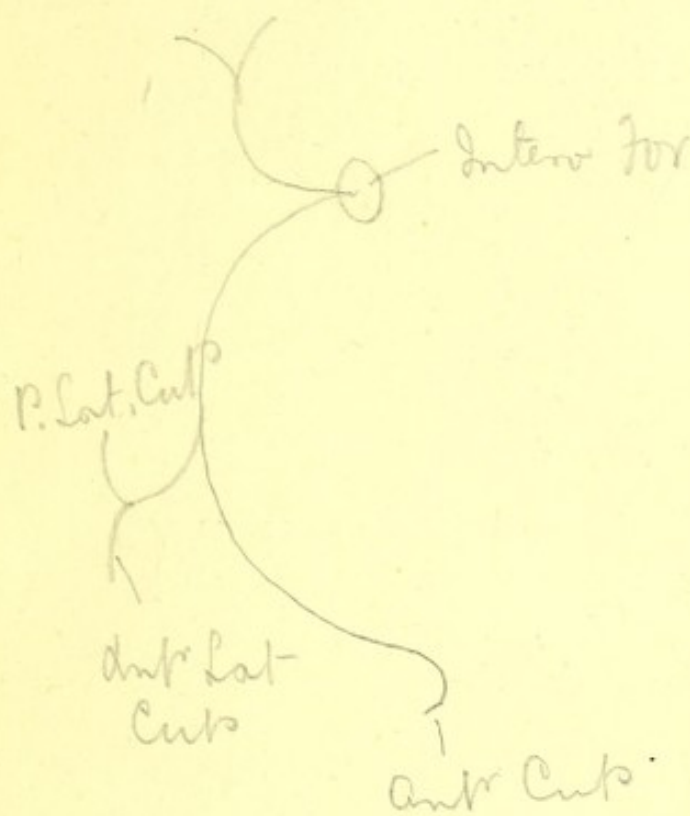
Page 32, two lines from bottom, *for* "Facial," *read* "Lingual."

Page 65, nine lines from top, *for* "from before backwards," *read* "from behind forwards."





par. cornu - covers ~~trunk~~ whole of Animals  
 oc. front  
 platysma & Mus. of Expression } p.c.  
 Muscles of face } represented  
 retrogressive evolution } in man.



Post Cut Branches of last six Dorsal nerves  
 come out in a line with outer border of  
 Erector Spinae and divide into two

First three Lumbar are Cut of Buttocks

Fourth Lumbar Muscular

Fifth Lumbar joins 1<sup>st</sup> Sacral which joins 2<sup>nd</sup>  
 which joins 3<sup>rd</sup>, which joins 4<sup>th</sup> which joins  
 5<sup>th</sup> wh. joins Coccyge

Fifth Lumbar is only Muscular

From the loops of Post. Sacral Plexus } Post.  
 as far as 3<sup>rd</sup>. Supply Intest over Sacro Sci Lig. } Sac.  
 Plexus



The lateral cut piece the Lat. boss in a  
line with the digitations of Est. oblique





















































Post-4<sup>th</sup> Neck ————— p. 7.

