

Ellis's demonstrations of anatomy : being a guide to the knowledge of the human body by dissection / by George Viner Ellis.

Contributors

Ellis, George Viner, 1812-1900.
Thane, George Dancer, Sir, 1850-1930.

Publication/Creation

London : Smith, Elder & Co., 1887.

Persistent URL

<https://wellcomecollection.org/works/dzmjbt9h>


License and attribution

This work has been identified as being free of known restrictions under copyright law, including all related and neighbouring rights and is being made available under the Creative Commons, Public Domain Mark.

You can copy, modify, distribute and perform the work, even for commercial purposes, without asking permission.



Wellcome Collection
183 Euston Road
London NW1 2BE UK
T +44 (0)20 7611 8722
E library@wellcomecollection.org
<https://wellcomecollection.org>



The Library of the
Wellcome Institute for
the History of Medicine

MEDICAL SOCIETY
OF LONDON

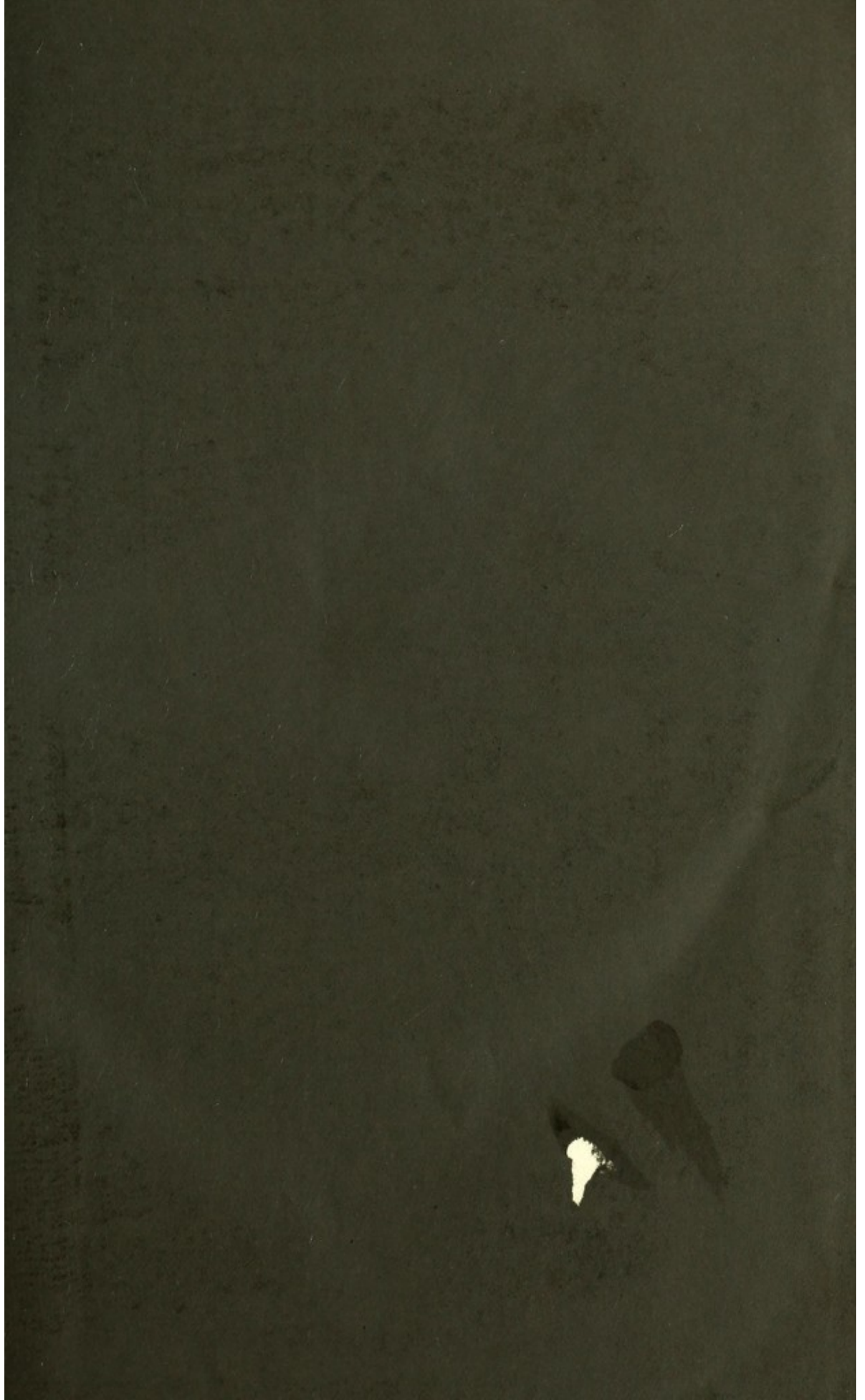
Accession Number

Press Mark

ELLIS, George Viner



22101448634



$$0 \frac{5}{18}$$



DEMONSTRATIONS
OF
ANATOMY.

EXHIBITION

Y. M. O. T. A.

ELLIS'S
DEMONSTRATIONS OF
ANATOMY:

BEING A
GUIDE TO THE KNOWLEDGE OF THE HUMAN BODY
BY
DISSECTION.

TENTH EDITION,

REVISED AND EDITED BY

GEORGE DANCER THANE,

PROFESSOR OF ANATOMY IN UNIVERSITY COLLEGE, LONDON.

ILLUSTRATED BY 241 ENGRAVINGS ON WOOD.

LONDON:
SMITH, ELDER, & CO., 15, WATERLOO PLACE.
1887.

[All rights reserved.]

20

LONDON :
BRADBURY, AGNEW, & CO., PRINTERS, WHITEFRIARS.

M15186

WELLCOME INSTITUTE LIBRARY	
Coll.	welMOmec
Call	
No.	Q54
	1887
	E47e

PREFACE.

IN this edition of the Demonstrations of Anatomy, the plan and arrangement of the work, as explained in former editions, have not been altered; but the description of the minute structure of the viscera and sense-organs has been omitted, in view of the increased facilities which exist at the present day for the study of microscopic Anatomy.

The figures illustrating the text have been added to by the introduction of thirteen new woodcuts.

In carrying out the revision of the text, I have endeavoured to maintain the efficiency of the work as a guide to the acquisition of knowledge by practical study.

G. D. THANE.

September, 1887.

Digitized by the Internet Archive
in 2014

<https://archive.org/details/b20387234>

CONTENTS.

CHAPTER I.

DISSECTION OF THE HEAD AND NECK.

	PAGE
SECTION 1. External Parts of the Head	1
2. Internal Parts of the Head	9
3. The Face	20
4. The Orbit	38
5. The Neck, right side	51
Posterior triangular space	53
Front of the Neck	58
Anterior triangular space	60
6. Pterygo-maxillary Region	81
7. Submaxillary Region	92
8. Right Orbit and Superior Maxillary Nerve	99
9. Deep Vessels and Nerves of the Neck	102
10. Left side of the Neck	115
11. The Pharynx	120
12. The Mouth	132
13. Cavity of the Nose	133
14. Spheno-palatine and Otic Ganglia, Nasal and Facial Nerves, and Internal Maxillary Artery	138
15. The Tongue	147
16. The Larynx	153
17. Hyoid Bone, Cartilages and Ligaments of the Larynx, Struc- ture of the Trachea	163
18. Prevertebral Muscles and the Vertebral Vessels	169
19. Ligaments of the first two Cervical Vertebrae, and of the Clavicle	172

CHAPTER II.

DISSECTION OF THE BRAIN.

SECTION 1. Membranes and Vessels	180
2. Origin of the Cranial Nerves	186

	PAGE
SECTION 3. Medulla Oblongata and Pons Varolii	191
4. The Cerebrum, or Great Brain	200
The under Surface, or the Base	200
The upper Surface, Lobes, and Convolutions	204
The Interior	212
Ventricles and Central Parts.	213
Fibres of the Cerebrum	226
5. The Cerebellum, or Little Brain	228
Surfaces and Lobes	228
Structure of the Mass	231
Fourth Ventricle and Nuclei of Cranial Nerves.	233

CHAPTER III.

DISSECTION OF THE UPPER LIMB.

SECTION 1. The Wall of the Thorax	242
The Axillary Space	246
2. Scapular Muscles, Vessels, Nerves, and Ligaments	261
3. The Front of the Arm	270
Back of the Arm	279
4. The Front of the Forearm	282
5. The Palm of the Hand	295
6. The Back of the Forearm	306
7. Ligaments of the Shoulder, Elbow, Wrist, and Hand	314

CHAPTER IV.

DISSECTION OF THE THORAX.

SECTION 1. Cavity of the Thorax	330
The Pleuræ	332
Relations of the Lungs	334
The Pericardium	336
The Heart and its large Vessels	338
Nerves of the Thorax	356
The Trachea, and the Characters and Structure of the Lung	359
Parts in Front of the Spine, and the Cord of the Sympathetic	363
Parietes of the Thorax	369
2. Ligaments of the Trunk	371
Articulation of the Ribs to the Vertebrae	372
Articulation of the Ribs to the Sternum	373
Articulations of the Sternum	374
Articulations of the Vertebrae	374

CHAPTER V.

DISSECTION OF THE BACK.

	PAGE
First Layer of Muscles	382
Second Layer of Muscles	386
Third Layer of Muscles	388
Fourth Layer of Muscles, with Vessels and Nerves	390
Fifth Muscular Layer, and the Sacral Nerves	398

CHAPTER VI.

DISSECTION OF THE SPINAL CORD.

Membranes of the Cord	404
Roots of the Spinal Nerves	408
Vessels of the Cord	410
Form and Divisions of the Cord	410
Composition of the Cord	412
Intraspinal Vessels	414

CHAPTER VII.

DISSECTION OF THE PERINEUM.

SECTION 1. Perineum of the Male	416
Posterior Half of the Space	417
Anterior Half of the Space	422
Lateral Operation of Lithotomy	430
2. Perineum of the Female	431

CHAPTER VIII.

DISSECTION OF THE ABDOMEN.

SECTION 1. Wall of the Abdomen	435
2. Hernia of the Abdomen	454
3. Cavity of the Abdomen	465
Relations of the Viscera	467
Peritoneum and its Folds	473
Mesenteric Vessels, and Part of the Sympathetic Nerve	478
Relations of the Aorta and Vena Cava	484
Relations of the Duodenum and Pancreas	485
Cœliac Axis and Portal Vein	486
Sympathetic and Vagus Nerves	491
4. Anatomy of the Abdominal Viscera	493
The Stomach	493
The Small Intestine	496
The Large Intestine	500
The Pancreas	503

SECTION	4— <i>continued.</i>	PAGE
	The Spleen	504
	The Liver	506
	The Gall-Bladder	512
	The Kidney and the Ureter	513
	The Suprarenal Body	516
	The Testis and the Vas Deferens	517
5.	Diaphragm, with Aorta and Vena Cava	522
	Deep Muscles of the Abdomen	531
6.	Lumbar Plexus and the Cord of the Sympathetic Nerve	534

DISSECTION OF THE PELVIS.

SECTION	1. Fascia of the Cavity, and the Muscles of the Pelvic Outlet	539
	2. Relations of the Viscera in the Male	545
	3. Relations of the Viscera in the Female	552
	4. Vessels and Nerves of the Pelvis	556
	5. Anatomy of the Viscera of the Male	565
	The Prostate Gland and the Seminal Vesicles	566
	The Urinary Bladder	569
	The Urethra and the Penis	572
	The Rectum	578
	6. Anatomy of the Viscera of the Female.	579
	Genital Organs	579
	The Vagina	581
	The Uterus	582
	Ovaries and Fallopian Tubes	585
	Bladder, Urethra, and Rectum	587
	7. Internal Muscles of the Pelvis	588
	Ligaments of the Pelvis	589

CHAPTER IX.

DISSECTION OF THE LOWER LIMB.

SECTION	1. The Front of the Thigh	598
	Femoral Hernia	606
	Scarpa's Space	610
	Deep Muscles, Vessels, and Nerves on the Front of the Thigh	613
	Deep parts on the inner Side of the Thigh	623
	2. The Buttock, or the Gluteal Region	631
	3. The Back of the Thigh	644
	The Popliteal Space	645
	Hamstring Muscles and Vessels	650
	The Hip-Joint	653
	4. The Back of the Leg	659
	5. The Sole of the Foot	669
	6. The Front of the Leg and the Dorsum of the Foot	682
	7. Ligaments of the Knee, Ankle, and Foot	691

CHAPTER X.

DISSECTION OF THE EYE.

	PAGE
Sclerotic Coat and Cornea	717
Choroid Coat and Ciliary Processes	719
Ciliary Muscle	721
The Iris	721
Ciliary Vessels and Nerves	723
Chamber of the Aqueous Humour	724
The Retina	724
Vitreous Body, and Hyaloid Membrane, with the Suspensory Ligament, and the Canal of Petit	725
Crystalline Lens and its Capsule	727

CHAPTER XI.

DISSECTION OF THE EAR.

The Auditory Canal	729
The Tympanum, with its Vessels and Nerves	731
Ossicles of the Tympanum, and their Muscles and Ligaments	735
The Osseous Labyrinth of the Inner Ear	740
Vestibule	740
Semicircular Canals	741
Cochlea, its Septum and Passages	742
The Membranous Sacs, or Labyrinth	745
Nerve of the Labyrinth	747
Blood-vessels of the Labyrinth	748

INDEX	749
-----------------	-----

DEMONSTRATIONS OF ANATOMY.

CHAPTER I.

DISSECTION OF THE HEAD AND NECK.

SECTION I.

EXTERNAL PARTS OF THE HEAD.

Directions. In the dissection of the head and neck, the student should endeavour to learn the parts described in the first fifty-seven pages, before the position of the body is changed ; but if want of time necessitates the omission of some part, the examination of the facial nerve (p. 35) can be best deferred till a subsequent stage. The exterior and the interior of the head, the orbit on one side, and the posterior triangular space on both sides of the neck should be examined while the body lies in its first position on the back.

Parts to be
learnt before
the body is
turned.

The student begins with the dissection of the muscles of the scalp and ear. On the left side the muscles are to be seen, and on the opposite half the vessels and nerves are to be displayed.

Position. The body lying on the back, raise the head to a suitable height, and turn the face to the right side.

Position of
the body.

EXTRINSIC MUSCLES OF THE EAR. Three muscles pass to the auricle from the side of the head. Two are above it,—one elevating, the other drawing it forwards ; and the third, a retrahent muscle, is behind the ear. There are other special or intrinsic muscles of the cartilage of the ear, which will be afterwards noticed (p. 34).

Muscles of
the ear.

Dissection. When the auricle has been drawn down by hooks, the position of the upper muscle will be indicated by a slight prominence between it and the head. A horizontal incision, about three inches in length, is to be made through the skin close above the ear, and from the centre of this another cut is to be carried upwards along the cutaneous ridge above mentioned for a similar distance. By carefully raising the flaps of skin between these cuts from below upwards, and removing a little areolar tissue, a thin fan-shaped layer of pale muscular fibres will come into view, the

Dissection
of upper
muscles,

anterior portion of which is the *attrahens*, while the posterior is the *attollens aurem* muscle.

of posterior
muscle.

On drawing forwards the ear, a ridge marks the situation of the posterior muscle. To remove the integuments, let the scalpel be carried downwards about an inch behind the ear, from the transverse cut above as far as to a level with the lobule of the ear, and then forwards below the lobule. After the piece of skin included by those cuts has been reflected towards the ear, the *retrahent* muscle must be sought beneath the subcutaneous tissue; it consists of rounded bundles of fibres, and is stronger and deeper than the others.

Attrahens
aurem
muscle.

The *ATTRAHENS AUREM* (fig. 1, ¹⁶) is a small fan-shaped muscle, and *arises* from the fore part of the aponeurosis of the occipito-frontalis. Its fibres are directed downwards and backwards, and are *inserted* into a projection on the front of the rim of the ear. Beneath it are the superficial temporal vessels and nerve.

Attollens
aurem
muscle.

The *ATTOLLENS AUREM* (fig. 1, ¹⁵) has the same form as the preceding, though its fibres are longer and better marked. *Arising* also from the tendon of the occipito-frontalis, the fibres converge to their *insertion* into the inner or cranial surface of the pinna of the ear,—into an eminence corresponding with a fossa (that of the *antihelix*) on the opposite aspect.

Retrahens
aurem con-
sists of two
or three
bundles.

The *RETRAHENS AUREM* (fig. 1, ¹⁷) consists of two or three roundish but separate bundles of fibres, which are stronger than those of the other muscles. The bundles *arise* from the root of the mastoid process, and pass almost horizontally forwards to be *inserted* by tendinous fibres into the lower part of the ear (*concha*) at its cranial aspect. The auricular branches of the posterior auricular artery and nerve are in contact with this muscle.

Use of ear
muscles.

Action. The three preceding muscles will move the outer ear slightly in the directions indicated by their names: the anterior drawing it upwards and forwards, the middle one upwards, and the posterior backwards.

Occipito-
frontalis,

The *OCCIPITO-FRONTALIS MUSCLE* (fig. 1, ^{1, 4}), covers the greater part of the vault of the skull, and consists of anterior and posterior fleshy parts with an intervening aponeurotic tendon.

how seen :

Dissection. To expose the occipito-frontalis, the transverse incision already made on the side of the head is to be prolonged above the eyebrow to the root of the nose, and from the latter spot a cut is to be carried backwards along the middle line of the head to the external occipital protuberance. The flap of skin, thus marked out, is to be raised from before back with the subjacent fat; while doing this the dissector will meet first with the anterior fleshy part of the muscle, next with a white shining thin aponeurosis, and lastly with the posterior fleshy belly towards the lateral aspect of the cranium. The aponeurosis of the muscle is easily taken away with the granular fat superficial to it; and if the under surface of the flap presents a white instead of a yellow appearance, the student may suspect he is removing that membrane.

take care
not to cut
away apo-
neurosis.

The *posterior* or *occipital part* (⁴) *arises* from the outer half or two-

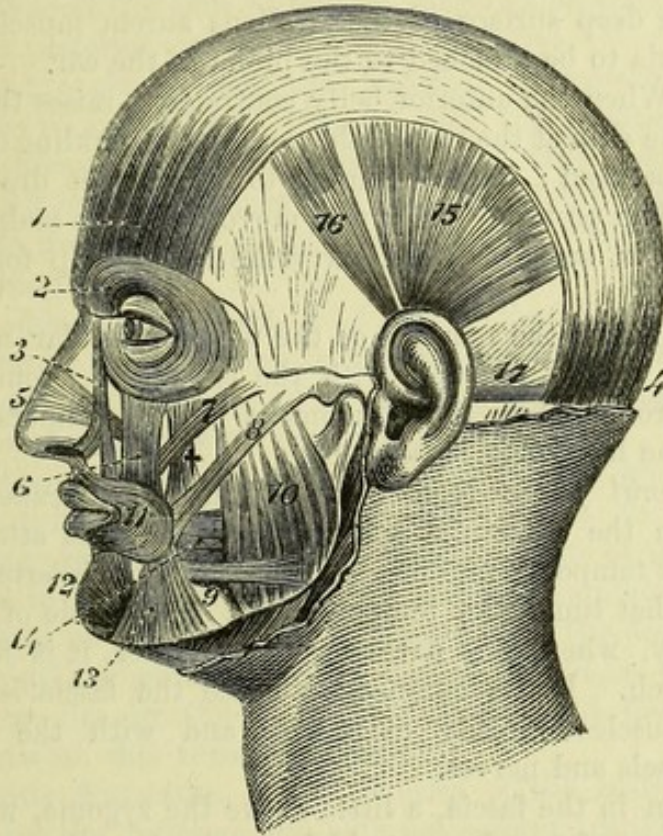
thirds of the upper curved line of the occipital bone, and from the mastoid portion of the temporal bone. The fibres are about one inch and a half in length, and ascend to the aponeurosis.

The *anterior* or *frontal part* (¹) forms a thin layer which covers about the lower two-thirds of the frontal bone. Its fibres are paler than those of the occipital part, and spring from the aponeurosis

Occipital
part, origin
and ending.

Frontal
part:
how at-
tached.

Fig. 1.*



some distance below the line of the coronal suture. They descend to the eyebrow and root of the nose, where they interlace with the fibres of the orbicularis palpebrarum, corrugator supercilii and pyramidalis nasi muscles, and terminate in the subcutaneous tissue. Some fasciculi are frequently attached to the nasal bone internally, and to the external angular process of the frontal bone on the outer side. The right and left muscular portions meet at the lower part of the forehead.

The *tendon* or *epicranial aponeurosis* covers the upper part of the cranium, and is continuous across the middle line with the like structure of the opposite half of the head. In front, it sends a pointed process downwards for some distance between the two muscular portions; and behind, it is prolonged between the posterior bellies, to be attached to the occipital bone above the superior curved line. From its lateral margin the upper auricular muscles arise. Superficial to the aponeurosis are the vessels and nerves

Aponeu-
rosis

its attach-
ment,
and rela-
tions.

* Muscles of the scalp and ear. 1. Anterior, and 4, posterior belly of the occipito-frontalis. 15. Attollens aurem. 16. Attrahens aurem. 17. Retrahens aurem only partly seen.

of the scalp and a small quantity of fat, which is traversed by numerous short fibrous bands uniting it closely to the skin. Its deep surface is connected to the pericranium only by a loose areolar tissue devoid of fat, so that the scalp moves freely over the skull.

Prolongation to ear.

By making a transverse incision through the aponeurosis above the ear and separating it from the pericranium towards the side of the head, it will be seen to be joined by a thin membrane, which springs from the skull above the temporal line, and descends, closely united to the deep surface of the *attollens aurem* muscle, over the temporal fascia to be attached to the pinna of the ear.

Use of anterior and

Action. When the anterior belly contracts it raises the eyebrow, smoothing the skin at the root of the nose, and wrinkling transversely that of the forehead; and continuing to contract, it draws forward the scalp. The posterior belly will move back the scalp; and the bellies acting in succession can carry the hairy scalp forwards and backwards.

posterior belly.

How to see temporal fascia.

Dissection. After the removal of the upper auricular muscles and the temporal vessels, together with the epicranial aponeurosis and its lateral prolongation, the attachment of the temporal fascia on the side of the head may be seen.

Temporal fascia.

The *temporal fascia* is a white shining membrane, which is stronger than the epicranial aponeurosis, and gives attachment to the subjacent temporal muscle. Superiorly it is inserted into the curved line that limits the temporal fossa on the side of the skull; and inferiorly, where it is narrower and thicker, it is fixed to the zygomatic arch. By its cutaneous surface the fascia is in contact with the muscles already examined, and with the superficial temporal vessels and nerves.

Attachments,

relations,

and layers.

An incision in the fascia, a little above the zygoma, will show it to consist there of two layers, which are fixed to the edges of the upper border of the zygomatic arch. Between the layers is some fatty tissue, with a small branch of the superficial temporal artery, and a slender twig of the orbital branch of the superior maxillary nerve with an accompanying artery.

To see temporal muscle.

Dissection. The temporal fascia is now to be detached from the skull, and to be thrown down to the zygomatic arch, in order that the origin of the underlying temporal muscle may be examined. A soft areolar tissue which lies beneath it near the zygoma is to be taken away. The difference in thickness of parts of the fascia will be evident.

Temporal muscle.

Origin,

insertion, and

relations.

The **TEMPORAL MUSCLE** is laid bare only in part. Wide and thin above, it becomes narrower and thicker at the lower end. The muscle *arises* from the temporal fascia, and from the surface of the impression on the side of the skull, which is named the temporal fossa. From this origin the fibres descend, converging to a tendon, which is *inserted* into the margins and inner surface of the coronoid process of the lower jaw (p. 82).

On the cutaneous surface is the temporal fascia, with the parts superficial to that membrane; and concealed by the muscle are the deep temporal vessels and nerves which ramify in it. The insertion

of the muscle will be seen, and its action explained, in the dissection of the pterygoid region.

Dissection. For the dissection of the vessels and nerves, let the face be now turned to the left side, and let an incision be carried along the eyebrow and the zygomatic arch to a little behind the ear, so as to allow the skin on the right half of the head to be reflected. The flap of the skin is to be raised from before backwards, but the subcutaneous fat should be left till the nerves are found. How to reflect skin on right side.

Behind the ear the skin should be raised as on the other side, to uncover the posterior auricular vessels and nerve.

Along the eyebrow seek the branches of vessels and nerves which come from the orbit (fig. 2), viz., the supraorbital vessels and nerve about the middle, and the supratrochlear nerve and frontal vessels near the inner angle of the orbit; they lie at first beneath the muscular fibres of the frontalis, which must be cut through to find them. Seek nerves and vessels on the forehead,

On the side of the head, in front of the ear, the superficial temporal vessels and nerve are to be traced upwards; and above the zygomatic arch the branches of the facial which join an offset (¹⁰) of the superior maxillary nerve are to be sought. on the side of the head,

Behind the ear the posterior auricular vessels and nerve, and below it branches from the great auricular nerve to the tip and back of the pinna are to be found; one or more offsets of the last should be followed to the junction with the posterior auricular nerve. behind ear,

At the back of the head the ramifications of the occipital vessels, and the large and small occipital nerves should be denuded; the former nerve lies by the side of the artery, and the latter about midway between this vessel and the ear. at the back of the head.

CUTANEOUS ARTERIES. The arteries of the scalp (fig. 2) are furnished by the internal and external carotid trunks, and anastomose freely over the side of the head. Only two small branches, the supraorbital and frontal, come from the former; while three, viz., the temporal, occipital, and posterior auricular, are derived from the latter. Vessels of the scalp.

The **SUPRAORBITAL ARTERY** (*c*) leaves the orbit through the notch in the margin of the orbit, and is distributed on the forehead. Some of its branches are superficial to the frontalis and supply the skin; while others lie beneath the muscle, and supply it, the pericranium, and the bone. Supraorbital artery.

The **FRONTAL ARTERY** (*b*) is close to the inner angle of the orbit, and is much smaller than the preceding. It ends in branches for the supply of the muscles, integuments, and pericranium. Frontal artery.

The **SUPERFICIAL TEMPORAL ARTERY** (*d*) is one of the terminal branches of the external carotid. After crossing the zygoma immediately in front of the ear, the vessel divides on the temporal fascia into anterior and posterior branches. Superficial temporal has

The *anterior branch* runs forwards with a serpentine course to the forehead, supplying muscular, cutaneous, and pericranial offsets, and anastomoses with the supraorbital artery; this is the branch that is opened when blood is taken from the temporal artery. anterior and

posterior
branches.

The *posterior branch* is larger than the other, and ascends to the top of the head, over which it anastomoses with the artery of the opposite side. Its offsets are similar to those of the anterior division, and communicate behind with the occipital and posterior auricular arteries.

Occipital
artery.

OCCIPITAL ARTERY (a). The terminal part of this artery, appearing between the trapezius and sterno-mastoid muscles, divides into large and tortuous branches, which spread over the back of the head. Communications take place with the artery of the opposite side, with the posterior part of the temporal, and with the following artery. Some offsets pass deeply to supply the occipitalis muscle, the pericranium, and the bone.

Posterior
auricular
artery

The **POSTERIOR AURICULAR ARTERY (f)** appears in front of the mastoid process, and divides into two branches. One (*mastoid*) is directed backwards to supply the occipitalis, and anastomose with the occipital artery. The other (*auricular*) supplies the retrahent muscle, the back of the pinna, and the superficial structures above the ear: offsets from this also pierce the pinna to be distributed on the opposite surface.

Veins of the
scalp.

The **VEINS** of the exterior of the head generally correspond to the arteries in their course, and communicate freely together, as well as with the sinuses in the interior of the skull by means of small branches named *emissary*, and with the veins of the diploë of the cranial bones. The *frontal vein* is of large size, and descends to the inner end of the eyebrow, beneath which it is joined by the smaller *supraorbital vein*: the resulting vessel is known as the *angular vein*, and forms the commencement of the facial trunk. The *temporal vein* descends to the temporo-maxillary trunk; the *posterior auricular vein* to the external jugular; and the *occipital veins* join the deep veins of the back of the neck.

Nerves of
the scalp.

CUTANEOUS NERVES (fig. 2). The nerves of the scalp are furnished from cutaneous offsets of both cranial and spinal nerves. The half of the head in front of the ear receives branches from the three trunks of the fifth cranial nerve, and a few twigs from the facial nerve. The hinder part of the head is supplied by spinal nerves (anterior and posterior primary branches), except close behind the ear, where there is an offset of the facial or seventh cranial nerve.

Supraorbital
nerve;

The **SUPRAORBITAL NERVE (fig. 2,⁶)** comes from the first trunk of the fifth nerve, and escapes from the orbit with its companion artery. It is placed at first beneath the orbicularis palpebrarum and frontalis muscles, and here gives offsets to these as well as to the pericranium. In the orbicularis a communication is established between this and the facial nerve. Finally the nerve ends in two cutaneous branches.

its two cuta-
neous and

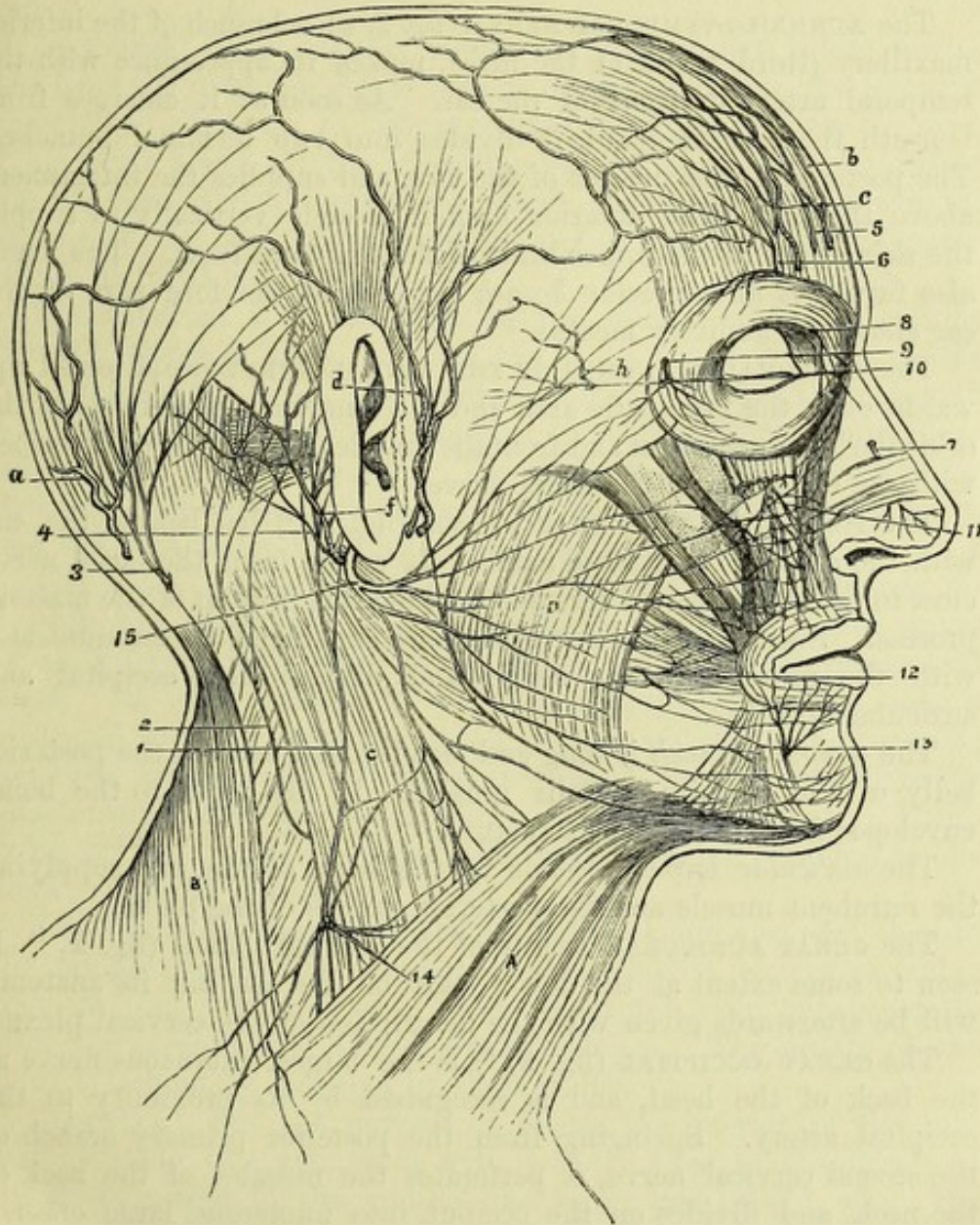
The inner of these soon pierces the frontalis, and reaches upwards as high as the parietal bone. The outer branch is of larger size, and perforating the muscle higher up, extends over the head as far as the ear.

palpebral
branches.

As the nerve escapes from the supraorbital notch it furnishes some *palpebral* filaments to the upper eyelid.

At the inner angle of the orbit is the small SUPRATROCHLEAR NERVE (fig. 2, ⁵) from the same trunk. It ascends to the forehead close to the bone, and piercing the muscular fibres ends in the

Fig. 2.*



integument. Branches are given from it to the orbicularis and corrugator supercilii, and some *palpebral* twigs enter the upper eyelid. The SUPERFICIAL TEMPORAL NERVES are derived from the second and third trunks of the fifth nerve, and from the facial nerve.

* Nerves and arteries of the scalp. *Nerves*: 1. Great auricular. 2. Small occipital. 3. Great occipital. 4. Posterior auricular of the facial. Auriculo-temporal (not numbered) in front of the ear, by the side of the temporal artery, *d*. 5. Supratrochlear. 6. Supraorbital. 10. Temporal of the superior maxillary, and crossing it are the temporal branches of the facial nerve. *Arteries*: *a*. Occipital. *b*. Frontal. *c*. Supraorbital. *d*. Superficial temporal. *f*. Posterior auricular. *h*. Orbital branch of superficial temporal.

- of superior maxillary; The TEMPORAL BRANCH OF THE SUPERIOR MAXILLARY NERVE (second trunk of the fifth) is a slender twig (fig. 2, ¹⁰), which perforates the temporal aponeurosis about a finger's breadth above the zygomatic arch. When cutaneous, the nerve is distributed on the fore part of the temple, and communicates with the facial nerve, also sometimes with the next.
- of inferior maxillary, The AURICULO-TEMPORAL NERVE (fig. 2, *d*), a branch of the inferior maxillary (third trunk of the fifth), makes its appearance with the temporal artery in front of the ear. As soon as it emerges from beneath the parotid gland, it divides into two terminal branches. The posterior is the smaller of the two, and supplies the integument above the ear. The anterior branch ascends vertically to supply the skin as far as the upper limit of the temporal fossa. The nerve also furnishes an *auricular branch* (upper) to the fore part of the ear above the auditory meatus.
- its auricular branch; and of facial nerve. The TEMPORAL BRANCHES OF THE FACIAL NERVE are directed upwards over the zygomatic arch and the temporal aponeurosis to the orbicularis palpebrarum and frontalis muscles: they will be described with the dissection of the facial nerve.
- Posterior auricular nerve has The POSTERIOR AURICULAR NERVE (fig. 2, ⁴) lies behind the ear with the artery of the same name. It arises from the facial nerve close to the stylo-mastoid foramen, and ascends in front of the mastoid process. Soon after the nerve becomes superficial it communicates with the great auricular nerve, and divides into occipital and auricular branches.
- occipital branch, The *occipital branch* is long and slender, and ends in the posterior belly of the occipito-frontalis muscle. It lies close to the bone, enveloped in dense fibrous structure.
- and auricular. The *auricular branch* ascends to the back of the ear, supplying the retrahent muscle and the posterior surface of the pinna.
- Great auricular nerve. The GREAT AURICULAR NERVE of the cervical plexus (fig. 2, ¹) is seen to some extent at the lower part of the ear, but its anatomy will be afterwards given with the description of the cervical plexus.
- Great occipital nerve: The GREAT OCCIPITAL (fig. 2, ³) is the largest cutaneous nerve at the back of the head, and is recognised by its proximity to the occipital artery. Springing from the posterior primary branch of the second cervical nerve, it perforates the muscles of the back of the neck, and divides on the occiput into numerous large offsets; these spread over the posterior part of the occipito-frontalis muscle, and terminate in the integument. As soon as the nerve pierces the trapezius, it is joined by an offset from the third cervical nerve; and on the back of the head it communicates with the small occipital nerve.
- junctions. The SMALL OCCIPITAL NERVE of the cervical plexus (fig. 2, ²) lies midway between the ear and the preceding nerve, and is continued upwards in the integuments higher than the level of the ear. It communicates with the nerve on each side, viz., the posterior auricular and the great occipital. Usually this nerve furnishes an *auricular branch* to the upper part of the pinna on its cranial aspect.
- Small occipital nerve has an auricular branch.

SECTION II.

INTERNAL PARTS OF THE HEAD.

Dissection. The skull is now to be opened, but before sawing the bone the dissector should detach, on the right side, the temporal muscle nearly down to the zygoma, without separating the overlying fascia; and all the remaining soft parts are to be divided by an incision carried around the skull, about one inch above the margin of the orbit at the forehead, and as low as the protuberance of the occipital bone behind.

Dissection
to open the
skull.

The cranium is to be sawn in the same line as the incision through the soft parts, but the saw is to cut only through the outer table of the bone. The inner table is to be broken through with a chisel, in order that the subjacent membrane of the brain (dura mater) may not be injured. The skullcap is next to be forcibly detached by inserting the fingers between the cut surfaces in front, and the dura mater will then come into view.

Precautions
in cutting
through the
bone.

The DURA MATER is the most external of the membranes investing the brain. It is a strong, fibrous structure, which serves as an internal periosteum to the bones, and supports the cerebral mass. Its outer surface is rough, and presents, now the bone is separated from it, numerous small fibrous and vascular processes; but these are most marked along the line of the sutures, where the attachment of the dura mater to the bone is more intimate. Ramifying on the exposed part of the membrane are branches of the large meningeal vessels.

Dura mater.

Appearance
of outer
surface.

Small granular masses, Pacchionian bodies, are also seen close to the middle line. The number of these bodies is very variable; they are but seldom found before the third year, but generally after the seventh, and they increase with age. The surface of the skull is frequently indented by these bodies.

Pacchionian
bodies.

Dissection. For the purpose of seeing the interior of the dura mater, divide this membrane with scissors close to the margin of the skull, except in the middle line before and behind, where the superior longitudinal sinus lies. The cut membrane is then to be raised on the right side towards the top of the head; and the veins connecting it with the brain may be broken through.

Cut through
dura mater.

The inner surface of the dura mater is free and smooth, being separated from the arachnoid, the second of the coverings of the brain, by the cavity known as the *subdural space*, although the two membranes are in the natural condition closely applied to one another. The fibrous tissue of which the dura mater is composed is so arranged as to give rise to two strata, an external which adheres to the bones, and an internal which is lined by an epithelium similar to that on serous membranes. At certain spots these layers are slightly separated, and form thereby the spaces or sinuses for

Inner
surface,

and struc-
ture.

Processes.	the passage of the venous blood. Moreover, the innermost layer sends processes between different parts of the brain, forming the falx, tentorium, &c.
Falx.	The <i>falx cerebri</i> (fig. 3) is the median sickle-shaped process of the dura mater, which dips in between the hemispheres of the large brain. Its form and extent will be evident if the right half of the brain is gently separated from it. Narrow and pointed in front, where it is attached to the crista galli of the ethmoid bone, it widens posteriorly, and joins a horizontal piece of the dura mater named the tentorium cerebelli. Its upper border is convex, and is fixed to the middle line of the skull as far backwards as the internal occipital protuberance; and the lower or free border, concave, is turned towards the central portion of the brain (<i>corpus callosum</i>), with which it is in contact posteriorly.
Form and attachments.	
Borders.	
Sinuses in it.	In this fold of the dura mater are contained the following sinuses:—the superior longitudinal along the convex border, the inferior longitudinal in the hinder part of the lower edge, and the straight sinus at the line of junction between it and the tentorium.
Superior longitudinal sinus.	The SUPERIOR LONGITUDINAL SINUS (fig. 3, <i>b</i>) extends from the ethmoid bone to the internal occipital protuberance. Its position in the convex border of the falx will be made manifest by the escape of blood through numerous small veins, when pressure is made from before back with the finger along the middle line of the dura mater.
Situation and ending;	When the sinus is opened it is seen to be narrow in front, and to widen behind, where it ends in a dilatation termed the <i>torcular Herophili</i> on one side (more frequently the right) of the internal occipital protuberance. Its cavity is triangular in form, with the apex of the space turned to the falx; and across it are stretched small tendinous cords— <i>chordæ Willisii</i> —near the openings of some of the cerebral veins. Occasionally small Pacchionian bodies project into the sinus.
its interior.	
Veins opening into it.	The sinus receives small veins from the substance of the skull and dura mater, and larger ones from the brain; and the blood flows backwards in it. The cerebral veins open chiefly at the posterior part of the canal, and they lie for some distance against the wall of the sinus before they perforate the dura mater; their course is directed from behind forwards, so that the current of the blood in them is evidently opposed to that in the sinus: this disposition of the veins may be seen on the left side of the brain, where the parts are undisturbed.
Current of blood in it.	
Directions for removal of brain.	<i>Directions.</i> Before the rest of the dura mater can be examined, the brain must be taken from the head. To facilitate its removal, let the head incline backwards, while the shoulders are raised on a block, so that the brain may be separated somewhat from the base of the skull. For the division of the cranial nerves a sharp scalpel will be necessary; and the nerves are to be cut longer on the one side than the other.
Mode of proceeding, and parts cut in succession.	<i>Removal of the Brain.</i> As a first step cut across the anterior part of the falx cerebri, and the different cerebral veins entering the

longitudinal sinus; raise and throw backwards the falx, but leave it uncut behind. Gently lift up the frontal lobes and the olfactory bulbs of the large brain. Next cut through the internal carotid artery and the second and third nerves, which then appear, together with some veins descending from the brain; the large second nerve is placed on the inner, and the round third nerve on the outer side of the artery.

Anterior
vessels and
nerves,

The brain is now to be supported in the left hand, and the pituitary body to be dislodged with the knife from the hollow in the centre of the sphenoid bone. A strong horizontal process of the dura mater (tentorium cerebelli) comes into view at the back of the cranium. Along its free margin lies the small fourth nerve, which is to be cut at this stage of the proceeding. Make an incision through the tentorium on each side, close to its attachment to the temporal bone, without injuring the parts underneath: the following nerves, which will be then visible, are to be divided in succession. Near the inner margin of the tentorium is the fifth nerve, consisting of a large and small root; while nearer the middle line of the skull is the slender sixth nerve. Below the fifth, and somewhat external to it, are the seventh and eighth nerves entering the internal auditory meatus, the former being anterior and the smaller of the two. Directly below the foregoing are the ninth, tenth and eleventh nerves in one line:—of these the upper small piece is the ninth or the glosso-pharyngeal; the flat band next below, the tenth or pneumo-gastric; and the long round nerve ascending from the spinal canal, the eleventh or spinal accessory. The remaining nerve nearer the middle line is the twelfth, which consists of two small pieces.

next the
tent,

posterior
nerves and

After dividing the nerves, cut through the vertebral arteries as they wind round the medulla oblongata. Lastly, cut across the spinal cord as low as possible, as well as the roots of the spinal nerves that are attached on each side. Then on placing the first two fingers of the right hand in the spinal canal, the cord may be raised, and the whole brain may be taken readily from the skull in the left hand. In doing this some large veins, passing from the hinder part of the cerebral hemisphere to the attached margin of the tentorium, will be broken through, as well as small ones from the portions of the brain in the posterior fossa of the base of the skull.

vessels, and

lastly, the
spinal cord.

Preservation of the brain. After removing some of the membranes from the upper part, and making a few apertures through them on the under surface, the brain may be immersed in spirit to harden it. Wrap the brain up in a piece of calico, and then place it upside down in a suitable vessel, on the bottom of which some cotton-wool or tow has been spread, and let it be quite covered with spirit.

How to pre-
serve the
brain.

Examination of the brain. At the end of two or three days the dissector should examine the other membranes and the vessels. As soon as the vessels have been learnt, the membranes are to be carefully removed from the surface of the brain, without detaching the different cranial nerves at the under surface. The brain may

Examina-
tion of it.

remain in the spirit till the dissection of the head and neck has been completed, but it should be turned over occasionally to allow the spirit to penetrate its substance.

The description of the brain and its vessels will be found after that of the head and neck.

Directions. *Directions.* After setting aside the brain, the anatomy of the dura mater, and the vessels and nerves in the base of the skull should be proceeded with. For this purpose raise the head to a convenient height, and fasten the tentorium in its natural position with a few stitches. The dissector should be furnished with the base of a skull while studying the following parts.

Dura mater in base of skull; *Dura mater.* At the base of the cranium the dura mater is much more closely united to the bones than it is at the top of the skull. Here it follows the different inequalities of the osseous surfaces; and it sends processes through the several foramina, which join for the most part the pericranium, and furnish sheaths to the nerves.

its prolongations, Beginning the examination in front, the membrane will be found to send a prolongation into the foramen cæcum, as well as a series of tubes through the apertures in the cribriform plate of the ethmoid bone. Through the sphenoidal fissure it joins the periosteum of the orbit; and through the optic foramen a sheath is continued on the optic nerve to the eyeball. In the sella turcica the dura mater forms a recess which lodges the pituitary body, and behind the dorsum sellæ it adheres closely to the basilar process of the occipital bone. From the latter part it may be traced into the spinal canal through the foramen magnum, to the margin of which it is very firmly united.

Tentorium cerebelli; The *tentorium cerebelli* is the process of the dura mater which is interposed in a somewhat horizontal position between the small brain (cerebellum) and the posterior part of the large brain (cerebrum).

surfaces, Its upper surface is raised along the middle, where it is joined by the falx cerebri, and is sloped laterally for the support of the back part of the cerebral hemispheres. Its under surface touches the small brain, and is joined by the falx cerebelli.

edges, The anterior concave margin is free, except at the ends where it is fixed by a narrow slip to each anterior clinoid process. The posterior or convex edge is connected to the following bones:—occipital (transverse groove), posterior inferior angle of the parietal, petrous portion of the temporal (upper border), and posterior clinoid process of the sphenoid.

and the sinuses in it. Along the centre of the tentorium is the straight sinus: and in the attached edge are the lateral and superior petrosal sinuses on each side.

Falx cerebelli The *falx cerebelli* has a corresponding position below the tentorium to the falx cerebri above that fold. It is much smaller than the falx of the cerebrum, and will appear on detaching the tentorium. Triangular in form, this fold is adherent to the internal occipital crest, and projects between the hemispheres of the small brain. Its

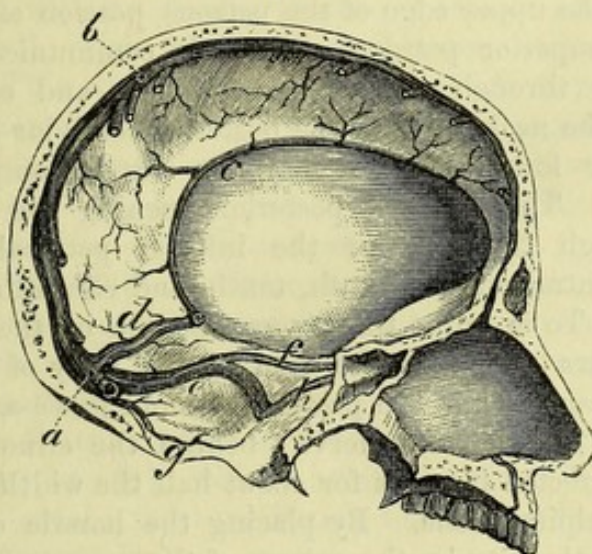
base is directed to the tentorium ; and the apex reaches the foramen magnum, on each side of which it gives a small slip. In it is contained the occipital sinus. contains occipital sinus.

The SINUSES are channels for venous blood between the layers of the dura mater. They are arranged in two groups, the one comprising the sinuses that converge towards the internal occipital protuberance, while the other is formed by the cavernous sinuses on the sides of the body of the sphenoid bone and the canals opening into these. Sinuses of the skull.

A. The *superior longitudinal sinus* has been described at p. 10. Superior and

The INFERIOR LONGITUDINAL SINUS (fig. 3, c) resembles a small vein, and is contained in the lower border of the falx cerebri at the inferior longitudinal.

Fig. 3.*



posterior part. This vein receives blood from the falx and the large brain, and ends in the straight sinus (d) at the edge of the tentorium.

The STRAIGHT SINUS (fig. 3, d) lies along the junction of the falx with the tentorium, extending from the termination of the preceding sinus to the internal occipital protuberance, where it is continued into one of the lateral sinuses, generally the left. Its form is triangular, like the superior longitudinal. Joining it are the inferior longitudinal sinus, the veins of Galen from the interior of the large brain, and some small veins from the upper surface of the cerebellum. Straight sinus.

The OCCIPITAL SINUS (fig. 3, g) is a small canal in the falx cerebelli, which reaches from the torcular Herophili to the foramen magnum, and collects the blood from the occipital fossæ. This sinus may be double. Occipital sinus.

The LATERAL SINUSES, right and left, are the channels by which most of the blood passes from the skull. Each extends from the Lateral sinuses,

* Some of the venous sinuses of the skull. a. Torcular Herophili. b. Superior, c. Inferior longitudinal sinus. d. Straight sinus. e. Lateral sinus. g. Occipital sinus. f. Superior, and h. Inferior petrosal sinus.

occipital protuberance, along the winding groove on the occipital, parietal and temporal bones, to the jugular foramen, where it ends in the internal jugular vein. The sinus of the right side is generally larger than the left, and begins at the torcular Herophili (p. 10), forming the continuation of the superior longitudinal sinus. The left lateral sinus is mainly prolonged from the ending of the straight sinus, but it is also joined by a branch from the lower end of the superior longitudinal sinus, which crosses obliquely in front of the occipital protuberance. In some cases this arrangement is reversed, so that the torcular Herophili and the larger lateral sinus are placed on the left side; and occasionally the torcular Herophili forms a common place of meeting (confluence) of the superior longitudinal, the straight and the two lateral sinuses.

The lateral sinus is joined by some cerebral and cerebellar veins, and, opposite the upper edge of the petrous portion of the temporal bone, by the superior petrosal sinus. It communicates with the occipital veins through the mastoid foramen, and often with the deep veins of the neck through the posterior condylar foramen.

The jugular foramen is divided into three compartments by fibrous bands. Through the posterior opening the lateral sinus passes; through the anterior the inferior petrosal sinus; and through the central one the ninth, tenth, and eleventh nerves.

Dissection. To examine the cavernous sinus on the left side, cut through the dura mater by the side of the body of the sphenoid bone from the anterior to the posterior clinoid process, and internal to the position of the third nerve; behind the clinoid process, let the knife be directed inwards for about half the width of the basilar part of the occipital bone. By placing the handle of the scalpel in the opening thus made, the extent of the space will be defined. A probe or a blow-pipe will be required, in order that it may be passed into the different sinuses joining the cavernous centre.

B. The CAVERNOUS SINUS, which has been so named from the reticulate structure in its interior, is situate on the side of the body of the sphenoid bone. This space, resulting from the separation of the two layers of the dura mater, is of an irregular shape, and extends from the sphenoidal fissure to the tip of the petrous portion of the temporal bone.

The layer of dura mater bounding the sinus externally is of some thickness, and contains in its substance the third and fourth nerves, with the ophthalmic trunk of the fifth nerve; these lie in their numerical order from above down.

The cavity of the sinus is larger behind than before, and is traversed by a network of slender fibrous cords. Through the space winds the trunk of the internal carotid artery surrounded by the sympathetic, with the sixth nerve on the outer side of the vessel; but all these are separated from the blood in the space by a thin lining membrane.

The cavernous sinus receives the ophthalmic veins from the orbit through the sphenoidal fissure, and some inferior cerebral veins. It communicates with its fellow of the opposite side by the inter-

cavernous sinuses, and with the pterygoid plexus outside the skull through the foramen ovale and the foramen lacerum. The blood leaves the cavity by the superior and inferior petrosal sinuses.

The INTERCAVERNOUS SINUSES are two vessels which pass transversely in the sella turcica between the right and left cavernous sinuses, being placed one in front of, and the other behind the pituitary body. To the venous ring thus formed around the pituitary body the name of *circular sinus* has been given.

Intercavernous or circular sinus.

The SUPERIOR PETROSAL SINUS (fig. 3, *f*) lies in a groove in the upper edge of the petrous part of the temporal bone, and extends between the cavernous and lateral sinuses. Small veins from the cerebellum are received into it.

Superior petrosal.

The INFERIOR PETROSAL SINUS (fig. 3, *h*) is larger than the superior, and lies in a groove along the line of junction of the petrous part of the temporal with the basilar process of the occipital bone; it is joined by small veins from the cerebellum, and one from the internal ear. This sinus passes through the anterior compartment of the jugular foramen, and ends in the internal jugular vein.

Inferior petrosal.

The TRANSVERSE SINUS OR BASILAR PLEXUS is a venous network in the substance of the dura mater over the basilar process of the occipital bone, uniting the inferior petrosal sinuses.

Transverse or basilar sinus.

MENINGEAL ARTERIES. These arteries supplying the cranium and the dura mater come through the base of the skull; they have been named from their situation in the three fossæ, anterior, middle, and posterior meningeal.

Arteries of dura mater are:—

The ANTERIOR MENINGEAL are small branches of the anterior ethmoidal artery (p. 46), which enters the skull by the anterior internal orbital canal: they are distributed to the dura mater over and near the ethmoid bone.

Anterior meningeal.

The MIDDLE MENINGEAL ARTERIES are three in number: two, named large and small, are derived from the internal maxillary trunk; and the third is an offset of the ascending pharyngeal artery.

Middle meningeal.

a. The *large meningeal branch* of the internal maxillary artery appears through the foramen spinosum of the sphenoid bone, and divides into two principal branches. The larger of these enters the deep groove on the anterior inferior angle of the parietal bone, and ends in ramifications which extend upwards to the top of the head and forwards over the frontal bone. The posterior branch is distributed over the hinder part of the parietal and the upper part of the occipital bones. Two *veins* accompany this artery.

Large from internal maxillary

As soon as the artery comes into the cranial cavity, it furnishes branches to the dura mater and to the ganglion of the fifth nerve. One small offset, *petrosal*, enters the hiatus Fallopii, and supplies the surrounding bone (Hyrtl). One or two branches pass through the sphenoidal fissure into the orbit, and anastomose with the ophthalmic artery.

gives branches to dura mater

b. The *small meningeal branch* is an offset of the large one outside the skull, and is transmitted through the foramen ovale to the membrane lining the middle cranial fossa.

Small meningeal.

c. Another *meningeal branch* from the ascending pharyngeal

One from

ascending pharyngeal. artery comes through the foramen lacerum (basis cranii). This is seldom injected, and is not often visible.

Posterior meningeal. The POSTERIOR MENINGEAL ARTERIES are small twigs of the ascending pharyngeal which enter the skull by the anterior condylar and jugular foramina, and supply the dura mater in the neighbourhood, and a branch of the vertebral artery which is distributed over the lower part of the occipital bone. The branch coming through the jugular foramen is sometimes derived from the occipital artery.

Nerves of dura mater. MENINGEAL NERVES. Offsets to the dura mater are said to be derived from the fourth, fifth, ninth and tenth cranial nerves; and from the sympathetic nerve.

Cranial nerves in the base of the skull: CRANIAL NERVES (fig. 4). As the cranial nerves pass through their apertures in the base of the skull they are invested by processes of the membranes of the brain, which are thus disposed:—those of the dura mater and pia mater are continued into the sheath of the nerve; while that of the arachnoid, except in the case of the second nerve, terminates as the nerve enters the dura mater. Some of the nerves, those in the middle fossa of the skull for instance, receive sheaths of the dura mater before they reach the foramina of transmission. The nerves are arranged in twelve pairs, which are enumerated from before backwards in the order in which they perforate the dura mater. Only part of the intracranial course of each nerve will be seen at this stage, the rest will be learnt in the dissection of the base of the brain.

only partly seen. The FIRST OR OLFATORY NERVES are about twenty small filaments which arise from the olfactory bulb of the brain (fig. 33) as it lies in the groove at the side of the crista galli, and descend to the nose through the foramina in the cribriform plate of the ethmoid bone.

Olfactory nerves end in the nose. The SECOND OR OPTIC NERVE (fig. 4, ²), diverging to the eyeball from its commissure, enters the orbit through the optic foramen: accompanying the nerve is the ophthalmic artery.

Second nerve passes to the eye. *Dissection.* The third and fourth nerves, and the ophthalmic trunk of the fifth nerve, lie in the outer wall of the cavernous sinus; and to see them, it will be necessary to trace them through the dura mater towards the orbit.

Dissection of third and fourth nerves; Afterwards the student should follow outwards the roots of the fifth nerve into the middle fossa of the skull, as in fig. 4, taking away the dura mater from them, and from the surface of the large Gasserian ganglion which lies on the fore part of the petrous portion of the temporal bone. From the front of the ganglion arise two other large trunks besides the ophthalmic, viz., superior and inferior maxillary, and these should also be traced to their apertures of exit from the skull. If the dura mater is removed entirely from the bone near the nerves a better view will be obtained.

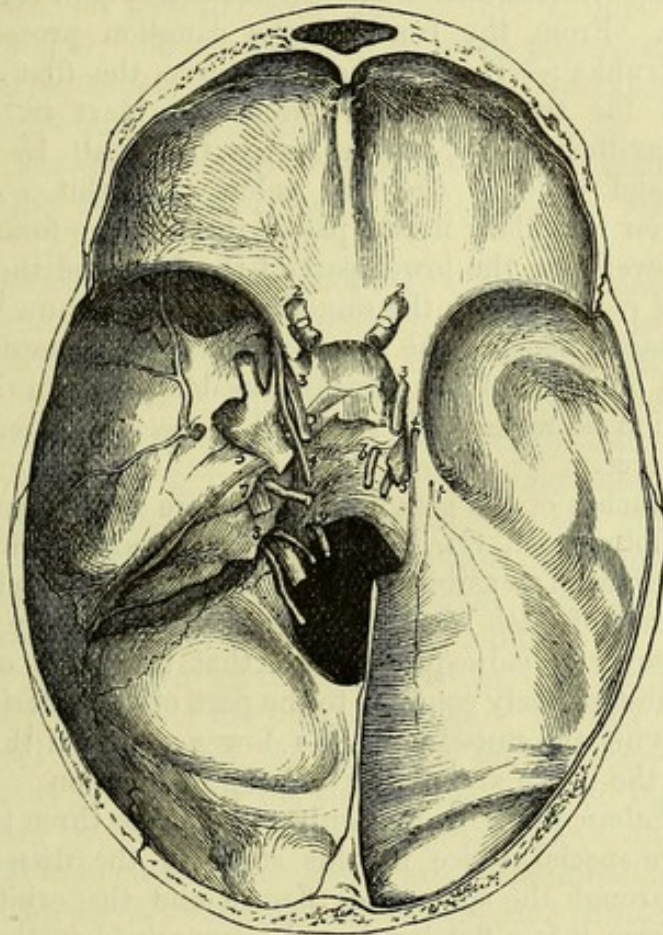
of fifth nerve. The THIRD OR OCULOMOTOR NERVE (fig. 4, ³) is destined for the muscles of the orbit. It enters the wall of the cavernous sinus near the anterior clinoid process, and is placed at first above the other nerves; but when it is about to enter the orbit through the

sphenoidal fissure, it sinks below the fourth and a part of the fifth, and divides into two branches.

Near the orbit the nerve is joined by one or two delicate filaments from the cavernous plexus (p. 20). passes to orbit.

The **FOURTH OR TROCHLEAR NERVE** (fig. 4, ⁴) courses forwards to one muscle in the orbit. It is the smallest of the cranial nerves, and Fourth nerve

Fig. 4.*



pierces the dura mater at the free edge of the tentorium, close behind the posterior clinoid process. In the wall of the sinus it lies below the third; but as it is about to pass through the sphenoidal fissure it rises higher than all the other nerves. in the wall of sinus.

While in the wall of the sinus the fourth nerve is joined by twigs of the sympathetic; and it is sometimes connected with the ophthalmic trunk of the fifth.

FIFTH OR TRIFACIAL NERVE (fig. 4, ⁵). This nerve is distributed to the face and head, and consists of two parts or roots—a large or sensory, and a small or motor. Fifth nerve has two roots.

The *large root* of the nerve passes through an aperture in the Large root

* Cranial nerves in the base of the skull. On the left side the dura mater has been removed from the middle fossa to show the nerves in the wall of the cavernous sinus, the Gasserian ganglion, and the three trunks of the fifth nerve. 2, 3, 4, 5, 6. Second to sixth nerves. 7. Facial and auditory. 8. Glosso-pharyngeal, vagus and spinal accessory. 9. Hypoglossal. On the right side the dura mater is untouched. † Offset to the tentorium from the ophthalmic nerve.

dura mater into the middle fossa of the base of the skull, where it immediately enters the Gasserian ganglion.

and Gasserian ganglion on it;

The *Gasserian ganglion*, placed in a depression close to the point of the petrous part of the temporal bone, is flattened, and about half an inch wide. The upper surface of the ganglion is closely united to the dura mater, and presents a semilunar elevation, the convexity of which looks forwards. Some filaments from the plexus of the sympathetic on the carotid artery join its inner side.

gives three branches.

Branches. From the front of the ganglion proceed the three following trunks:—The ophthalmic nerve, the first and highest, is destined for the orbit and forehead. Next in order is the superior maxillary nerve, which leaves the skull by the foramen rotundum, and ends in the face below the orbit. And the last, or the inferior maxillary nerve, passes through the foramen ovale to reach the lower jaw, the lower part of the face, and the tongue.

Small root.

The *small root*, lying in the same tube of the dura mater as the large one, passes beneath the ganglion without communicating with it, and joins only one of the three trunks derived from the ganglion: if the ganglion be raised, this root will be seen to enter the inferior maxillary nerve.

Difference in the use of the roots.

Those branches of the ganglion which are unconnected with the small or motor root, viz., the ophthalmic and superior maxillary, are solely nerves of sensibility; but the inferior maxillary, which is compounded of both roots, is a nerve of sensibility and motion. It will moreover be subsequently seen that the fibres of the motor root are almost entirely confined to the part of the inferior maxillary nerve supplying the muscles of the lower jaw, and that the larger branches of the nerve are wholly sensory in function.

Ophthalmic nerve enters orbit,

The *ophthalmic nerve* is the only one of the three trunks which needs a more special notice in this stage of the dissection. It is continued through the sphenoidal fissure and the orbit to the forehead. In form it is a flat band, and is contained in the wall of the cavernous sinus below the third and fourth nerves. Near the orbit it divides into three branches (p. 40).

supplies dura mater in its course.

In this situation it is joined by filaments of the cavernous plexus of the sympathetic, and gives a small *recurrent* filament (fig. 4, †) to the tentorium cerebelli.

Sixth nerve is in cavernous sinus;

The *SIXTH OR ABDUCENT NERVE* (fig. 4, ⁶) enters the orbit through the sphenoidal fissure, and supplies one of the orbital muscles. It pierces the dura mater behind the body of the sphenoid bone, and crosses the space of the cavernous sinus, instead of lying in the outer wall with the other nerves.

joins sympathetic.

In the sinus the nerve is placed close against the outer side of the carotid artery; and it is joined by one or two large branches of the sympathetic nerve surrounding that vessel.

Seventh and eighth nerves leave skull together.

The *SEVENTH OR FACIAL* and the *EIGHTH OR AUDITORY NERVES* (fig. 4, ⁷) pass together into the internal auditory meatus, the facial being the smaller and higher of the two. At the bottom of the meatus they separate; the facial nerve courses through the aqueduct of Fallopius to the face, and the auditory nerve is distributed to the internal ear.

The NINTH or GLOSSO-PHARYNGEAL, the TENTH, PNEUMO-GASTRIC or VAGUS, and the ELEVENTH or SPINAL ACCESSORY NERVES (fig. 4, ⁸) pass through the middle compartment of the jugular foramen. The glosso-pharyngeal is external to the other two, and has a distinct opening in the dura mater. The spinal accessory nerve ascends through the foramen magnum and, together with the vagus, enters an aperture in the dura mater close to the occipital bone. Ninth, tenth and eleventh nerves pass through jugular foramen.

The TWELFTH or HYPOGLOSSAL NERVE (fig. 4, ⁹) is the motor nerve of the tongue, and consists of two small pieces, which pierce the dura mater separately opposite the anterior condylar foramen; these unite at the outer part of that aperture. Twelfth nerve.

Dissection. The dissector may now return to the examination of the trunk of the carotid artery as it winds through the cavernous sinus. Dissection of carotid,

On the opposite side of the head, on which the nerves in the wall of the cavernous sinus are untouched, an attempt may be made to find two small plexuses of the sympathetic on the carotid artery, though in an injected body this dissection is scarcely possible. of sympathetic plexuses:

One of these (cavernous) is near the root of the anterior clinoid process; and to bring it into view it will be necessary to cut off that piece of bone, and to dissect out with care the third, fourth, fifth, and sixth nerves, looking for filaments between them and the plexus. Another plexus (carotid), joining the fifth and sixth nerves, surrounds the artery as it enters the sinus. cavernous, and carotid.

The INTERNAL CAROTID ARTERY appears in the cranium at the apex of the petrous part of the temporal bone. In this part of its course the vessel lies between the layers of the dura mater bounding the cavernous sinus along the side of the body of the sphenoid bone, and makes two bends so as to have the form of the letter S reclined. It first ascends in the inner part of the foramen lacerum, and then runs forwards to the root of the anterior clinoid process; finally it turns upwards in the groove on the inner side of this process, perforates the dura mater forming the roof of the sinus, and divides into cerebral arteries at the base of the brain. In this course the artery is enveloped by nerves derived from the sympathetic in the neck (p. 114). Internal carotid artery winds through cavernous sinus.

The *branches* of the artery here are few. In the sinus there are some small arteries (*arteriæ receptaculi*) for the supply of the dura mater and the bone, the nerves, and the pituitary body; and opposite the anterior clinoid process the ophthalmic branch arises. Branches.

The terminal branches of the carotid will be seen in the dissection of the base of the brain (p. 184).

SYMPATHETIC NERVE. Accompanying the carotid artery is a prolongation of the sympathetic nerve of the neck, which forms the following plexuses:— Sympathetic forms

The *carotid plexus* is situate on the outer side of the vessel, at its entrance into the cavernous sinus, and communicates with the sixth nerve and the Gasserian ganglion. carotid plexus,

The small *cavernous plexus* is placed below the bend of the artery which is close to the anterior clinoid process, and is mainly derived cavernous plexus;

- from that offset of the upper cervical ganglion which courses along the inner side of the carotid artery. Filaments from the plexus unite with the third, fourth, and ophthalmic nerves. One filament is also furnished to the lenticular ganglion in the orbit, either separately from, or in conjunction with the nasal nerve.
- unio with cranial nerves.**
- Distribu- tion.** After forming these plexuses, the nerves surround the trunk of the carotid, and are continued on the cerebral and ophthalmic branches of that vessel: one offset enters the eyeball with the central artery of the retina.
- Two super- ficial petro- sal nerves.** PETROSAL NERVES. Beneath the Gasserian ganglion is the *large superficial petrosal nerve* (fig. 35, ²) entering the hiatus Fallopii to join the facial nerve. External to this is sometimes seen the *small superficial petrosal nerve* (fig. 35, ³), but this is frequently concealed in the substance of the temporal bone. The source, and the destination of these small nerves will be afterwards learnt. It will suffice now for the student to notice their position, and to see that they are kept moist and fit for examination at a future time.
- Directions for preserv- ing parts.** *Directions.* Now that the study of the base of the skull has been completed a preservative fluid or salt should be applied, and the flaps of skin should be stitched together over all.

SECTION III.

DISSECTION OF THE FACE.

- Directions.** *Directions.* The muscles and vessels are to be dissected together on the left side of the face, and the right side is to be kept for the nerves.
- Position of head.** *Position.* The head is to be lowered from the position in which it was placed for the examination of the base of the skull, and turned so that the side of the face to be dissected is upwards: fix it in this position with hooks.
- Dissection.** *Dissection.* As a preparatory step, the muscular fibres of the apertures may be made slightly tense by inserting a small quantity of tow or cotton wool between the eyelids and the eyeball, and between the lips and the teeth.
- How to raise the skin from muscle of eyelids,** First lay bare the sphincter muscle of the eyelids by making a skin-deep incision over the margin of the orbit, and raising the skin of the lids towards the aperture of the eye. Much care must be taken in detaching the skin from the thin and pale fibres of the orbicular muscle in the lids, else they will be cut away in consequence of the little areolar tissue between the two.
- from the face,** Next the integument is to be removed from the side of the face by one incision in front of the ear from above the zygomatic arch to the angle of the jaw, and another along the base of the jaw to the chin: a cut should also be made along the free margin of each lip from the centre to the angle of the mouth, and another round

the edge of the nostril. The flap of skin is to be raised from behind forwards, and left adherent along the middle line.

On the side of the nose the skin is closely united to the subjacent parts, and must be detached with caution. Around the mouth is the orbicular muscle of the lips, and from this many fleshy slips extend both upwards and downwards, but they are all marked so distinctly as to escape injury, with the exception of the small risorius muscle which goes from the corner of the mouth towards the ramus of the lower jaw. While removing the fat from the muscles, each fleshy slip may be tightened with hooks.

The facial vessels and their branches will come into view as the muscles are cleaned; but the nerves may be disregarded on this side.

In front of the ear is the parotid gland, the duct of which is to be preserved; this is on a level with the meatus auditorius, and pierces the middle of the cheek.

MUSCLES OF THE FACE (fig. 6). The superficial muscles of the face are disposed in three groups: one of the nose, another of the eyelids and eyebrow, and a third of the aperture of the mouth. One of the muscles of mastication, viz., the masseter, is partly displayed at the hinder part of the face, covering the ramus of the lower jaw.

MUSCLES OF THE NOSE (fig. 5). These muscles are the following: pyramidalis nasi, compressor naris, levator labii superioris alæque nasi, dilatator naris, and depressor alæ nasi.

The **PYRAMIDALIS NASI** (fig. 5,¹) is a small fleshy slip that covers the nasal bone, and appears to be a continuation of the innermost part of the frontalis muscle. Its fibres are attached above to the skin of the forehead; below, they end in the aponeurosis of the compressor muscles over the cartilaginous part of the nose. Its inner border meets the muscle of the opposite side.

Action. This muscle draws down the skin of the centre of the forehead, and produces transverse wrinkles at the root of the nose.

COMPRESSOR NARIS. This muscle (fig. 5,³) is not well seen till after the examination of the following one, by which it is partly concealed. Triangular in shape, it arises by its apex from the upper maxillary bone near the anterior nasal aperture. The fibres are directed inwards, spreading out at the same time, and end in an aponeurosis, which covers the cartilaginous part of the nose, and is continued into the opposite muscle.

Action. It stretches the skin over the cartilaginous part of the nose.

The **LEVATOR LABII SUPERIORIS ALÆQUE NASI** (fig. 5,²) is placed by the side of the nose, and arises from the nasal process of the upper maxillary bone, in front of the attachment of the orbicularis. The fibres pass downwards, and the most internal are attached by a narrow slip to the wing of the nose, while the rest are blended with the orbicularis oris. Near its origin the muscle is partly concealed by the orbicularis palpebrarum, but in the rest of its extent it is subcutaneous. Its outer border joins the elevator of the upper lip.

Use. *Action.* This muscle raises the upper lip and wing of the nose, forming wrinkles in the overlying skin.

Dilator of nostril; *Dilatator naris.* In the dense tissue on the outer side of the nostril are a few muscular fibres, both at

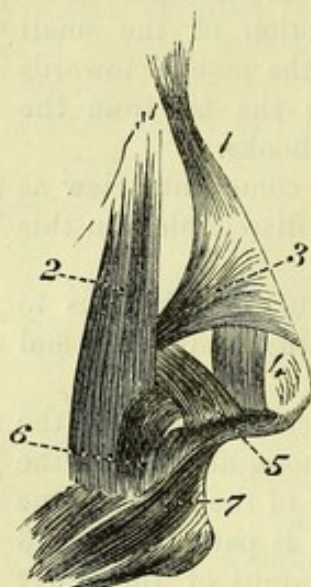
Fig. 5.*

anterior and

posterior
parts.

Use.

**Depressor of
wing.**



the fore and back part of that aperture (fig. 5, ⁴ and ⁵), to which the above name has been given by Theile: they are seldom visible without a lens. The *anterior* slip (⁴) passes from the cartilage of the aperture to the integument of the margin of the nostril; and the *posterior* (⁵) arising from the upper jawbone and the small sesamoid cartilages, ends also in the integuments of the nostril.

Action. The fibres enlarge the nasal opening by raising and everting the outer edge.

The **DEPRESSOR ALÆ NASI** (fig. 5, ⁶) will be seen if the upper lip is everted, and the mucous membrane is removed by the side of the frænum of the lip. It arises below the nose from the incisor fossa of the superior maxilla, and ascends to be inserted

into the septum narium and the posterior part of the ala of the nose.

Use. *Action.* By drawing down and turning in the edge of the dilated nostril, it restores the aperture to its usual size.

Four muscles of eyelids and brow. **MUSCLES OF THE EYELIDS.** The muscles of the eyelids and eyebrow are four in number, viz., orbicularis palpebrarum, corrugator supercilii, levator palpebræ superioris, and tensor tarsi†: the two latter are dissected in the orbit, and will be described with it.

Orbicularis palpebrarum: The **ORBICULARIS PALPEBRARUM** (fig. 6, ²) is the sphincter muscle closing the opening between the eyelids. It is a flat and thin layer, which extends from the margin of the lids beyond the circumference of the orbit. From a difference in the characters of the fibres, a division has been made of them into two parts—outer and inner.

two parts.

Orbital or
external,
attached
internally.

The *external fibres* (orbital part), the best marked, are fixed only at the inner side of the orbit. This attachment (origin) is connected with the borders of the internal tarsal ligament; above the ligament with the nasal process of the superior maxillary, and the internal angular process of the frontal bone; and below the ligament with the orbital margin of the superior maxillary bone. From this origin the fibres are directed outwards, giving rise to ovals, which lie side by side, and increase in size towards the outer edge of the muscle, where they project beyond the margin of the orbit. Some of the peripheral fibres spread upwards to the skin of the forehead, and others downwards to that of the cheek.

* Muscles of the nose. 1. Pyramidalis nasi. 2. Common elevator of the nose and lip. 3. Compressor naris. 4 and 5. The two slips of the dilatator naris. 6. Depressor alæ nasi. 7. Orbicularis oris.

† The tensor tarsi muscle (p. 49) is sometimes described as a part of the orbicularis.

The *internal fibres* (palpebral part), paler and finer than the outer, occupy the eyelids, and are fixed at both the outer and inner sides of the orbit. Internally they *arise* from the internal tarsal ligament: externally they end in the external tarsal ligament, by means of which they are attached to the malar bone, and a few may blend with the orbital part. Close to the cilia or eyelashes the fibres form a small pale bundle, which is sometimes called *ciliary*.

Internal or palpebral part,

attached at both ends.

Ciliary bundle.

The muscle is subcutaneous; and its circumference is blended above with the frontalis. Beneath the upper half of the orbicularis, as it lies on the margin of the orbit, is the corrugator supercillii muscle with the supraorbital vessels and nerve; and beneath the lower half is part of the elevator of the upper lip. The outer fibres are joined occasionally by slips to other contiguous muscles below the orbit.

Relations.

Action. The inner fibres cause the lids to approach each other, shutting the eye; and in forced contraction the outer commissure is drawn inwards. In closing the eye the lids move unequally—the upper being much depressed, and the lower slightly elevated and moved horizontally inwards.

Use of inner and

When the outer fibres contract, the eyebrow is depressed, and the skin over the edge of the orbit is raised around the eye, so as to protect the ball. Elevation of the upper lip accompanies contraction of the outer part of the orbicularis, owing to the associated action of the levator labii superioris and zygomatic muscles.

outer fibres.

The CORRUGATOR SUPERCILII is beneath the orbicularis, near the inner angle of the orbit. Its fibres *arise* from the inner part of the superciliary ridge of the frontal bone, and are directed outwards between the bundles of the orbicularis to be inserted into the skin above the inner half of the eyebrow. It is a short muscle, and is distinguished by the closeness of its fibres.

Corrugator supercillii

inserted into skin.

Action. It draws inwards and downwards the mid-part of the eyebrow, wrinkling vertically the skin near the nose, and stretching that outside its place of insertion.

Use.

MUSCLES OF THE MOUTH. The muscles of the aperture of the mouth consist of a sphincter; an elevator of the upper lip and angle of the mouth; an elevator and depressor of the lower lip and angle of the mouth; and retractors of the corner. Lastly, a wide muscle of the cheek closes the space between the jaws.

Muscles of the mouth.

The ORBICULARIS ORIS MUSCLE (fig. 6, ¹¹) surrounds the opening of the mouth, and is united with the several muscles converging to that aperture. It consists of two parts, inner and outer, which differ in the appearance and arrangement of the fibres, like the sphincter muscle of the eyelids.

Sphincter of the mouth

consists of two parts:

The *inner part*, the fibres of which are pale in colour and fine in texture, forms a rounded thick fasciculus, which corresponds with the red margin of the lip. The fibres of this portion of the muscle, unattached to bone, blend with the buccinator at the corner of the mouth, and some pass from lip to lip.

inner or labial,

not fixed to bone;

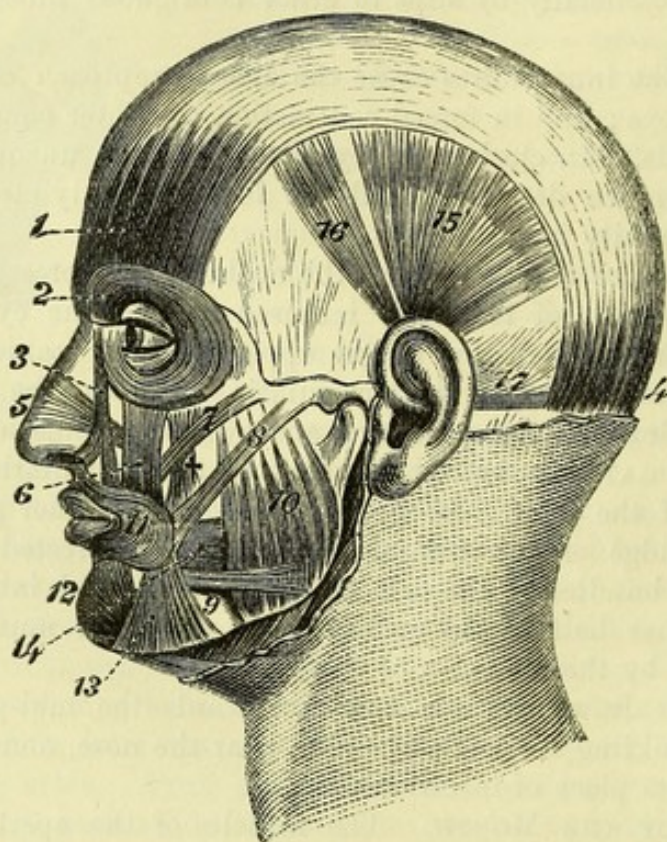
The *outer part* is thin, wide, and more irregular in form, and is connected with the subjacent bone, besides its union with the

outer or facial,

adjoining muscles. In the upper lip it is attached, on each side of the middle line, by one slip (nasolabial) to the back of the septum of the nostrils (fig. 5, 7); and by a thin stratum to the outer surface of the upper jaw, opposite the canine tooth, and external to the depressor of the wing of the nose. In the lower lip it is fixed on each side to the inferior jawbone, opposite the canine tooth, external to the levator menti muscle. To see these attachments the lip must be everted, and the mucous membrane carefully raised.

Relations. The inner margin of the muscle is free, and bounds the aperture of the mouth; while the outer edge blends with the different muscles

Fig. 6.*



that elevate or depress the lips and the angle of the mouth. Beneath the orbicularis in each lip is the coronary artery, with the mucous membrane and the labial glands.

Use of both parts. *Action.* Both parts of the muscle contracting, the lips are pressed together and projected forwards, and the aperture of the mouth is diminished transversely by the approximation of the corners.

Inner alone. The inner fibres acting alone will turn inwards the red part of the lip, and diminish the width of the oral opening.

Outer alone. The outer fibres press the lips against the dental arches, the free edges being protruded and somewhat everted. At the same time

* 1. Frontalis muscle. 4. Occipitalis. 2. Orbicularis palpebrarum. 3. Levator labii superioris alæque nasi. 5. Compressor naris. 6. Levator labii superioris. 7. Zygomaticus minor (too large). 8. Zygomaticus major. 9. Risorius. 10. Masseter. 11. Orbicularis oris. 12. Depressor labii inferioris. 13. Depressor anguli oris. 14. Buccinator. † Levator anguli oris.

the central part of the nose is depressed and the chin raised by means of the fleshy slips connected with those parts.

The **LEVATOR LABII SUPERIORIS** (fig. 6, ⁶) extends vertically from the lower margin of the orbit to the orbicularis oris. It *arises* from the upper maxillary and malar bones above the infraorbital foramen, and blends inferiorly with the orbicularis oris. Near the orbit the muscle is overlapped by the orbicularis palpebrarum, but below that spot it is subcutaneous. By its inner side it joins the common elevator of the ala of the nose and upper lip; and to its outer side lie the zygomatic muscles, the small one joining it. Beneath it are the infraorbital vessels and nerve. Elevator of upper lip.
Relations.

Action. By the action of this muscle the upper lip is raised, and the skin of the cheek is bulged below the eye. Use.

The **DEPRESSOR LABII INFERIORIS** (fig. 6, ¹²) is opposite the elevator of the upper lip, and has much yellow fat mixed with its fibres. The muscle has a wide *origin* from a depression on the front of the lower jaw, reaching outwards from near the symphysis to a little beyond the mental foramen; ascending thence it is united with the orbicularis in the lower lip. Its inner border joins in the lip the muscle of the opposite side; and its outer is overlapped by the depressor anguli oris. Depressor of lower lip.

Action. If one muscle contracts, the half of the lip of the same side is depressed and everted; but by the use of both muscles, the whole lip is lowered and turned outwards, and rendered tense at the centre. Use.

The **LEVATOR MENTI** (levator labii inferioris) is a small muscle on the side of the frænum of the lower lip, which is opposite the depressor of the ala of the nose in the upper lip. When the lip has been everted and the mucous membrane removed, the muscle will be seen to *arise* from the incisor fossa of the lower jaw, and to descend to its *insertion* into the integument of the chin. Its position is internal to the depressor of the lip and the attachment of the orbicularis. Elevator of chin.

Action. It indents the skin of the chin opposite its insertion, and assists in raising the lower lip. Use.

The **LEVATOR ANGULI ORIS** (fig. 6, †) has well-marked fibres, and is partly concealed by the levator labii superioris. *Arising* from the canine fossa below the infraorbital foramen, its fibres spread out towards the angle of the mouth, where they are superficial to the buccinator, and mix with the rest of the muscles, but the greater number are continued into the depressor anguli oris and the lower lip. Elevator of the angle
joins depressor.

Action. This muscle elevates the corner of the mouth, and acts as an antagonist to the depressor. Use.

The **DEPRESSOR ANGULI ORIS** (fig. 6, ¹³) is triangular in shape. It *arises* from the oblique line on the outer surface of the lower jaw; and ascending to the angle of the mouth, its fibres join those of the elevator muscle. The depressor conceals the mental branches of the inferior dental vessels and nerve. It is united at its origin with the platysma myoides, and near its insertion with the risorius muscle. Depressor of angle.

- Use.** *Action.* The angle of the mouth is drawn downwards and backwards by it, as is exemplified in a sorrowful countenance.
- Zygomatic muscles;** The ZYGOMATIC MUSCLES (fig. 6, ⁷ and ⁸) are directed obliquely from the malar bone towards the angle of the mouth and the upper lip. One is longer and larger than the other; they are therefore named major and minor.
- large and** The *zygomaticus major* (⁸) arises from the outer part of the malar bone, and is inserted into the angle of the mouth.
- small.** The *zygomaticus minor* (⁷) is attached to the malar bone in front of the other, and blends with the fibres of the special elevator of the upper lip.
- Use.** *Action.* The large muscle draws upwards and backwards the corner of the mouth, as in laughing; and the small one assists the levator labii superioris in raising the upper lip.
- Risorius muscle.** The RISORIOUS MUSCLE (Santorini) (fig. 6, ⁹) is a thin and narrow bundle of fibres, sometimes divided into two or more parts, which arises externally from the fascia over the masseter muscle, and is connected internally with the apex of the depressor anguli oris.
- Use.** *Action.* The use of this muscle is indicated by its name, as it retracts the corner of the mouth in smiling.
- Buccinator muscle.** The BUCCINATOR (fig. 6, ¹⁴) is the flat and thin muscle of the cheek, and occupies the interval between the jaws. The muscle arises from the outer surface of the alveolar borders of the upper and lower maxillæ, as far forwards in each as the first molar tooth; and in the interval between the jaws behind it is attached to a tendinous band known as the pterygo-maxillary ligament. From this origin the fibres are directed forwards to the angle of the mouth, where they mix with the other muscles and with both parts of the orbicularis; and as some of the central fibres descend to the lower lip while others ascend to the upper lip, a decussation takes place at the corner of the mouth.
- Insertion at corner of the mouth.**
- Parts in contact with it.** On the cutaneous surface of the buccinator are the different muscles converging to the angle of the mouth; and crossing the upper part is the duct of the parotid gland, which perforates the muscle opposite the second upper molar tooth. Internally the muscle is lined by the mucous membrane of the mouth, and externally it is covered by a fascia (bucco-pharyngeal) that is continued to the pharynx. By its intermaxillary origin the buccinator corresponds with the attachment of the superior constrictor of the pharynx.
- Use on aperture,** *Action.* By one muscle the corner of the mouth is retracted, and by the action of both the aperture of the mouth is widened transversely.
- on cheek,** In mastication the cheek is pressed by the muscular contraction against the dental arches, while the corner of the mouth is fixed by the orbicularis.
- in expelling air.** In the expulsion of air from the mouth, as in whistling, the muscle is contracted so as to prevent bulging of the cheek; but in the use of a blow-pipe it is distended over the volume of air contained in the mouth, and drives out a continuous stream by its contraction.

The principal VESSELS OF THE FACE (fig. 18) are the facial and transverse facial arteries with their accompanying veins. The arteries are branches of the external carotid; and the facial vein is received into the internal jugular trunk. Arteries of the face.

The FACIAL ARTERY (fig. 18, *g*), a branch of the carotid, emerges from the neck, and crosses the base of the lower jaw immediately in front of the masseter muscle. From this point the artery ascends in a tortuous manner, near the angle of the mouth and the side of the nose, to the inner margin of the orbit, where it anastomoses with the ophthalmic artery. The course of the vessel is comparatively superficial in the mass of fat of the inner part of the cheek. At first it is concealed by the platysma while crossing the jaw, but this thin muscle does not prevent pulsation being recognised during life; and near the mouth the large zygomatic muscle is superficial to it. The vessel rests successively on the lower jaw, buccinator muscle, elevator of the angle of the mouth, and elevator of the upper lip. Accompanying the artery is the facial vein, which takes nearly a straight course, and lies to its outer side. Facial artery; course and relations.

Branches. From the outer side of the vessel unnamed branches are furnished to the muscles and integuments, some of which anastomose with the transverse facial artery. From the inner side are given the following branches:— Plan of the branches.

The *inferior labial branch* (*t*) runs inwards beneath the depressor anguli oris muscle, and is distributed between the lower lip and chin; it communicates with the inferior coronary, and with the mental branch of the inferior dental artery. Inferior labial.

Coronary branches (*r* and *s*). These are one for each lip (superior and inferior), which arise together or separately from the facial, and are directed inwards between the orbicular muscle and the mucous membrane of the lip, till they inosculate with the corresponding branches of the opposite side. From the arterial arches thus formed offsets are supplied to the lips and labial glands. From the arch in the upper lip a branch is given to each side of the septum narium,—*artery of the septum*. Two coronary form an arch in each lip. Branch to septum.

The *lateral nasal branch* (*p*) arises opposite the ala nasi, and passes beneath the levator labii superioris alæque nasi to the side of the nose, where it anastomoses with the nasal branch of the ophthalmic artery. Lateral nasal branch.

The *angular branch* (*o*) is the terminal twig of the facial artery at the inner angle of the orbit, and joins the nasal branch of the ophthalmic artery. Angular branch.

The *facial vein* commences at the root of the nose in a vein named angular (*p*. 6). It then crosses over the elevator of the upper lip, and, separating from the artery, courses beneath the large zygomatic muscle to the side of the jaw. Afterwards it has a short course in the neck to join the internal jugular vein. Facial vein away from artery;

Branches. At the inner side of the orbit the angular vein receives veins from the upper eyelid (*superior palpebral*) and from the side of the nose. Below the orbit the facial trunk is joined by veins from the lower eyelid (*inferior palpebral*), as well as by a large joined by branches.

branch, *anterior internal maxillary* or *deep facial vein*, that comes from the plexus in the pterygoid region (p. 89); and thence to its termination by veins corresponding with the branches of the artery in the face and neck.

Transverse
facial artery.

The TRANSVERSE FACIAL ARTERY (fig. 18) is a branch of the superficial temporal, and appears in the face at the anterior border of the parotid gland. It lies by the side of the parotid duct, with branches of the facial nerve, and distributes offsets to the muscles and integuments; some branches anastomose with the facial artery.

Lay bare the
parotid.

Dissection. The parotid gland in front of the ear may be next displayed. To see the gland, raise the skin from the surface towards the ear by means of a cut from the base of the jaw to the anterior border of the sterno-mastoid muscle; this cut may be united with that made for the dissection of the posterior muscle of the ear. A strong fascia covers the gland, and is connected above and behind to the zygomatic arch and the cartilage of the ear, but is continued in front over the face; this is to be removed, so that the gland may be detached slightly from the parts around. The great auricular nerve will be seen ascending to the lobule of the ear; and three or four small lymphatic glands rest on the surface of the parotid.

Parotid
lymphatic
glands.
Parotid
gland.

The PAROTID (fig. 16,¹⁰) is the largest of the salivary glands. It occupies the space between the ear and the lower jaw, and is named from its position. Its excretory duct enters the mouth through the middle of the cheek.

Irregular in
shape:

The shape of the gland is irregular, and is determined by the surrounding parts. Thus inferiorly, where there is not any resisting structure, the parotid projects into the neck, and comes into close proximity with the submaxillary gland, though separated from it by a process of the cervical fascia; a line from the angle of the jaw to the sterno-mastoid muscle marks usually the extent of the gland in this direction. Above, the parotid is limited by the zygomatic arch and the temporal bone. Along the posterior part the sterno-mastoid muscle extends; but anteriorly, the gland projects somewhat into the face over the masseter muscle, and has connected with it in this situation a small accessory part, known as the *socia parotidis*.

relations;

accessory
part.

The duct
reaches
mouth:

Issuing from the anterior border is the excretory duct—*duct of Stenson* (ductus Stenonis, fig. 17), which crosses the masseter below the socia parotidis, and perforates the buccinator and the mucous membrane of the cheek obliquely opposite the second molar tooth of the upper jaw. The duct lies between the transverse facial artery and some branches of the facial nerve, the latter being below it. A line drawn from the meatus auditorius to a little below the nostril would mark the level of the duct in the face; and the central point of the line would be opposite the opening into the mouth. The length of the duct is about two inches and a half; and its capacity is large enough to allow a small probe to pass, but the opening into the mouth is much less.

its length
and size.

Surface of
gland.

The cutaneous surface of the parotid is smooth, and three or four

lymphatic glands are seated on it ; but from the deep part processes are sent into the inequalities of the space between the jaw and the mastoid process.

Dissection. By removing with caution the parotid gland, the hollows that it fills will come into view : at the same time the dissector will see the vessels and nerves that pass through it. An examination of the processes of the gland, and of the number of important vessels and nerves in relation with it, will demonstrate the dangers attending any operation on it. The duct may be opened, and a pin may be passed along it to the mouth, to show the position and the diminished size of the aperture.

Dissection
to see deep
parts.

Two large processes of the gland extend deeply into the neck. One dips behind the styloid process, and projects beneath the mastoid process and sterno-mastoid muscle, where it reaches also the deep vessels and nerves of the neck. The other piece is situate in front of the styloid process ; it passes into the glenoid hollow behind the articulation of the lower jaw, and sinks beneath the ramus of that bone along the internal maxillary artery.

Deep part
sinks behind
jaw.

Coursing through the middle of the gland is the external carotid artery, which ascends behind the ramus of the jaw, and furnishes the posterior auricular, superficial temporal, and internal maxillary branches. Superficially to the artery lies the trunk formed by the junction of the temporal and internal maxillary veins ; and this common trunk, receiving some veins from the parotid, divides near the angle of the jaw into two branches, the anterior of which passes downwards to join the facial vein, while the posterior inclines backwards over the border of the sterno-mastoid muscle and is continued into the external jugular vein (fig. 15). Crossing the vessels in the gland from behind forwards is the trunk of the facial nerve, which divides here into its primary branches. The superficial temporal branch of the inferior maxillary nerve lies above the upper part of the glandular mass ; and offsets of the great auricular nerve pierce the gland at the lower part, and join the facial.

Vessels and

nerves in
the gland.

In dissecting out the gland it has been seen to consist of a number of lobules separated by connective tissue septa. From the lobules small ducts arise, and these join together so as to give rise to two large tubes, which are placed superficially to the branches of the facial nerve in the gland, and by their union opposite the hinder margin of the ramus of the jaw form the beginning of Stenson's duct. As it crosses the masseter the main duct receives one or more small branches from the socia parotidis.

Obvious
structure of
gland.

The parotid receives its *arteries* from the external carotid ; and its *nerves* from the sympathetic, auriculo-temporal of the fifth, facial, and great auricular. Its *lymphatics* join those of the neck.

Vessels and
nerves.

Two or three small *molar glands* lie on the surface of the buccinator, and open into the mouth near the last molar teeth by separate ducts.

Molar
glands.

The NOSE has the form of a three-sided pyramid, which is attached to the face by one of its surfaces, while the base is free. The lateral surfaces meet anteriorly in a rounded edge termed the

External
nose : its
parts,

dorsum, the upper part of which is known also as the *bridge*. The lower and posterior part of each lateral surface is convex and marked off by a curved groove, constituting the *ala*. The base presents the oval apertures of the *nostrils* or *anterior nares*, separated by a short thick partition, the *septum narium* or *columna nasi*.

and frame-
work.

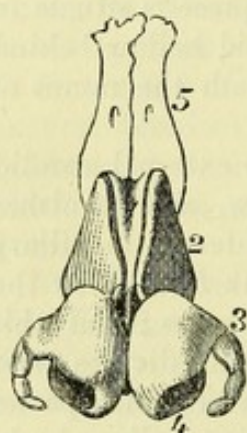
The shape of the nose is maintained by a framework consisting of the nasal bones and the nasal processes of the superior maxillary bones above, and of the cartilages of the nose below, in the part corresponding to the anterior nasal aperture of the skull.

Nasal
cartilages.

CARTILAGES OF THE NOSE (fig. 7). These are five in number, one in the centre, the *cartilage of the septum*, and two on each side, the *lateral cartilage* and the *cartilage of the aperture*. They are all hyaline cartilage, but do not show any tendency to become ossified. Only the lateral cartilages are learnt in this stage of the dissection.

Fig. 7.*

Take away
tissue from
surface.



The upper
cartilage
joins the
septal.

Dissection. The lateral cartilages will be seen when the muscular and fibrous structures of the left side of the nose have been taken away. By turning aside the lateral cartilages the septal one will appear in the middle line.

The *lateral cartilage* (upper lat. cart., fig. 7, ²) is flattened, and triangular in form. Posteriorly it is attached to the nasal and upper maxillary bones; and anteriorly it joins the cartilage of the septum above, but is separated from it by a narrow cleft below. Inferiorly, the lateral cartilage is con-

tiguous to the cartilage of the aperture, and is connected to it by fibrous tissue.

The lower
surrounds
aperture;
not inserted
into bone.

The *cartilage of the aperture* (lower lat. cart., fig. 7) forms a ring around the opening of the nose except behind. It has not any attachment directly to bone; but it is united above to the lateral cartilage by fibrous tissue, and below with the dense teguments forming the *ala* of the nose and the margin of the nostril.

One part
outside;

The part of the cartilage (³) which bounds the opening externally is narrow and pointed behind, where it forms two or three vertical folds, and sometimes becomes divided into as many small pieces—*cartilaginee minores vel sesamoides*; but it swells out in front where it touches its fellow, and forms the apex of the nose.

accessory
cartilages;

another in-
side nostril.

The inner part (⁴) is shorter and narrower. It projects backwards in the *columna nasi* below the level of the anterior end of the septal cartilage, being attached to this and to its fellow of the opposite side by fibrous tissue, and reaches nearly to the superior maxillary bone.

Appendages
of the eye.

The **APPENDAGES OF THE EYE** include the eyebrow, the eyelid, and the lachrymal apparatus. Some of these can be examined now on the opposite side of the face. The apparatus for the tears will be dissected after the orbit has been completed.

Eyebrow.

The *eyebrow* (*supercilium*) is a curved eminence just above the

* Cartilages of the nose. 1. Septal cartilage. 2. Lateral cartilage. 3. Cartilage of the aperture, its outer part, and 4, its inner part. 5. Nasal bone.

eye which is placed over the orbital arch of the frontal bone. It consists of thickened integuments, and its prominence is in part due to the subjacent orbicularis palpebrarum and corrugator supercilii muscles. It is furnished with long coarse hairs, which are directed outwards, and towards one another.

The *eyelids* (palpebræ) are two moveable semilunar folds in front of the eye, which can be approached or separated over the eyeball. The upper lid is the larger and more moveable, and descends below the middle of the eyeball when the two meet; it is also provided with a special muscle to raise it. The interval between the open lids is named the *palpebral fissure*. Externally and internally they are united by a commissure or *canthus*. Eyelids
Upper
larger.

The free border of each lid is somewhat thickened, and presents a narrow surface which meets the opposite lid when the aperture is closed, and is bounded towards the eyeball by a sharp smooth edge; but at the inner end, for about a quarter of an inch from the commissure, it is somewhat thinner and more rounded. At the spot where the two parts join is a small white eminence (fig. 13, ¹), the *papilla lachrymalis*; and in this is the *punctum lachrymale*, or the opening of the canal for the tears. Shape of
margin.

Papilla.
Punctum.

This margin is provided anteriorly with the eyelashes, and near the posterior edge with a row of small openings of the Meibomian glands: but both the cilia and the glands are absent from the part of the lid which is internal to the opening of the punctum lachrymale. Hairs and
apertures.

The *eyelashes* (cilia) are two or more rows of curved hairs, which are fixed into the anterior edge of the free border of the lid; they are largest in the upper lid, and diminish in length from the centre to the sides. The cilia of the two lids are convex towards one another, and cross when the lids are shut. Eyelashes.

STRUCTURE OF THE EYELIDS. Each lid consists fundamentally of a fibrous plate attached to the bone by ligaments. Superficial to this framework are the integuments with a layer of fibres of the orbicularis palpebrarum, and beneath it the mucous lining of the conjunctiva. The upper lid includes also the tendon of the levator palpebræ. Vessels and nerves are contained in the lids. Different
parts in
eyelids.

Dissection. The student may examine the structure of the lids on the left side, on which the muscles are dissected. The bit of tow or wool may remain beneath the lids; and the palpebral part of the orbicularis muscle is to be thrown inwards by an incision around the margin of the orbit. In raising the muscle care must be taken of the thin membranous palpebral ligament beneath, and of vessels and nerves of the lid. Dissect lids.

Orbicularis palpebrarum. The palpebral fibres of this muscle form a pale layer which reaches the free edge of the eyelids (p. 23). A thin stratum of areolar issue without fat unites the muscle with the skin. Layer of
orbicularis.

The *palpebral ligament* or *fascia* is a thin fibrous layer, which is continued from the margin of the orbit to join the anterior surface of the fibrous tarsal plate. At the inner part of the orbit the A fibrous
layer.

ligament is thin and loose, but at the outer part it is somewhat thicker and stronger.

A fibrous plate forms part of the lid :

The *fibrous plates* (tarsi), one for each eyelid, are elongated transversely, and give strength to the lids. Each is fixed internally and externally by fibrous bands—the *tarsal ligaments*, to the margin of the orbit. The border corresponding with the edge of the lid is free, and thicker than the rest of the plate. On the deep surface each tarsus is lined by the mucous membrane or conjunctiva.

difference in the two lids.

The tarsi are not alike in the two lids. In the upper eyelid, where the fibrous plate is larger, it is crescentic in shape, and is nearly half an inch wide in the centre; and to its fore part the tendon of the levator palpebræ is attached. In the lower lid the tarsus is a narrow band, about two lines broad, with nearly straight borders.

Ligaments of eyelids attach tarsi.

The *internal tarsal ligament* (tendo palpebrarum) is a small fibrous band at the inner side of the orbit, which serves to fix the lids, and is attached to the anterior margin of the lachrymal groove in the upper jaw. It is about a quarter of an inch long, and divides into two processes, which are united with the tarsal plates, one to each. This ligament crosses the lachrymal sac, behind which it sends a fibrous expansion; and the fleshy fibres of the orbicularis palpebrarum arise from it. The *external tarsal ligament* is a much weaker band uniting the tarsi to the malar bone.

Sebaceous tubes in lid :

The *Meibomian* or *tarsal glands* are embedded in the substance of the tarsal plates, and can be readily seen through the conjunctiva on the posterior surface of the lids. They extend, parallel to one another, from the free towards the opposite margin of the tarsus; and their number is about thirty in the upper, and twenty in the lower lid. The apertures of the glands open in a line at the free border of the lid near the posterior edge.

their structure.

Each gland is a small yellowish tube, closed at one end, and having minute lateral cæcal appendages connected with it. The secretion is similar to that of the sebaceous glands of the skin.

Tendon of levator palpebræ.

If the palpebral ligament be cut through in the upper lid, the *tendon* of the *levator palpebræ* will be seen to be inserted into the fore part of the tarsus by a wide aponeurotic expansion.

Mucous lining of lid.

The *conjunctiva*, or mucous membrane, lines the interior of the lids, from which it is reflected to the front of the eyeball. The line of reflection is known as the *fornix conjunctivæ*, and is placed, above and below, some distance beyond the convex margin of the tarsus. Inside the lids the conjunctiva is inseparably united to the tarsi, and has numerous fine papillæ. At the free margin of the lids it joins the skin, and through the lachrymal canals and nasal duct it is continuous with the pituitary membrane of the nose.

Caruncle

Between the eyeball and the inner commissure of the lids is seen a prominent and fleshy-looking body—*caruncula lachrymalis* (fig. 13, 4), which contains a group of glands, and has a few minute hairs on its surface. External to the caruncle is a small vertical fold of the mucous membrane—*plica semilunaris*, resting on the inner part of the eyeball.

and contiguous fold.

Blood-vessels of the eyelids. The *arteries* of the eyelids are furnished by the palpebral and lachrymal branches of the ophthalmic artery :— Arteries of lids.

The *palpebral arteries*, one for each eyelid, run outwards from the inner canthus, lying between the tarsus and the orbicular muscle; and they anastomose externally with the lachrymal artery. From each arch branches are distributed to the structures of the lid. Palpebral

The terminal portion of the *lachrymal artery* perforates the palpebral ligament at the outer part of the orbit, and, after having given small offsets to the upper eyelid, divides into two branches which complete the palpebral arches. and lachrymal.

The *veins* of the lids open into the angular, facial and temporal veins. Veins.

The *nerves* of the eyelids are supplied from the ophthalmic and superior maxillary divisions of the fifth and the facial nerves. Nerves of lids,

The branches of the ophthalmic nerve which give offsets to the upper lid are the following: *lachrymal*, near the outer part; *supra-orbital*, about the middle; and *supratrochlear* and *infratrochlear* at the inner side. In the lower eyelid there are usually two *palpebral branches*, inner and outer, of the *superior maxillary nerve*. from fifth,

Branches of the facial nerve enter both lids at the outer side, and supply the orbicularis muscle; they communicate with the offsets of the fifth nerve. and seventh nerve.

EXTERNAL EAR. The outer ear consists of a broad, projecting part, named *pinna* or *auricle*, and of a tube—*meatus auditorius externus*, leading inwards to the middle ear, from which it is separated by the tympanic membrane. The *pinna* may be now examined on the left side of the head; but the *meatus* will be described with the anatomy of the ear. Parts of external ear.

The **PINNA** or **AURICLE** is an uneven piece of yellow fibro-cartilage, which is covered with integument, and is fixed to the margin of the *meatus auditorius externus*. It is of a somewhat oval form, with the margin folded and the upper end larger than the lower. Texture and form of pinna.

The surface next the head is generally convex; and the opposite excavated, but presenting the following elevations and depressions. In the centre is a deep hollow named *concha*, which is wide above but narrow below; it conducts to the *meatus auditorius*. In front of the narrowed part of the hollow is a projection of a triangular shape—the *tragus*, which has some hairs on the inner surface; and on the opposite side of the same narrow end, rather below the level of the *tragus*, is placed another projection—the *antitragus*. Surface marked by fossæ and eminences.

The prominent rim-like margin of the ear, which extends into the *concha*, is called the *helix*; and the depression internal to it is the *groove* or *fossa of the helix*. Within the *helix*, forming the hinder and upper boundary of the *concha*, is the large eminence of the *antihelix*, which presents at its upper part a triangular depression, the *fossa of the antihelix*. Margin.

Inferiorly the auricle ends in a soft pendulous part, the *lobule*. Lobule.

The *special muscles of the pinna*, which extend from one part of Intrinsic

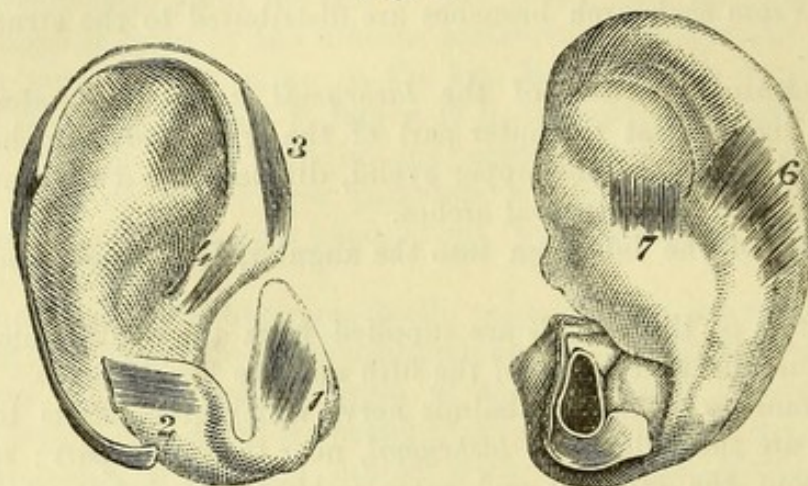
muscles of
auricle.

the cartilage to another, are very thin and pale. Five small muscles are to be recognised; and these receive their names for the most part from the several eminences of the external ear.

How to find
the muscles.

Dissection. In seeking the small auricular muscles, let the skin be removed only over the spot where each muscle is said to

Fig. 8.*



be placed. A sharp knife and a good light are necessary for the display of the muscular fibres. Occasionally the dissector will not find one or more of the number described below.

One muscle
on tragus.

The *muscle of the tragus* (fig. 8, ¹) is always found on the external aspect of the process from which it takes its name. The fibres are short, oblique, or transverse, and extend from the outer to the inner part of the tragus.

One on
antitragus.

The *muscle of the antitragus* (fig. 8, ²) is the best marked of all. It arises from the outer part of the antitragus, and the fibres are directed upwards to be inserted into the pointed extremity of the antihelix.

One on root
of helix.

The *small muscle of the helix* (fig. 8, ⁴) is often indistinct or absent. It is placed on the part of the rim of the ear that extends into the concha.

Another on
helix.

The *large muscle of the helix* (fig. 8, ³) arises above the small muscle of the same part, and is inserted into the front of the helix, where this is about to curve backwards. It is usually present.

And one at
back of
concha.

The *transverse muscle of the auricle* (fig. 8, ⁶) forms a wide layer, which is situate at the back of the ear in the depression between the helix and the convexity of the concha. It arises from the convexity of the cartilage forming the concha, and is inserted into the back of the helix. The muscle is mixed with much fibrous tissue, but it is well seen when that tissue is removed.

Use.

Actions. These muscles are said to alter slightly the condition of the outer ear; the muscles of the helix assisting, and those of the

* Muscles on the outer surface of the ear-cartilage. 1. Muscle of the tragus. 2. Muscle of the antitragus. 3. Large muscle of the helix. 4. Small muscle of the helix.

Muscles on the inner surface of the ear-cartilage. 6. Transverse muscle. 7. Oblique muscle (Tod) sometimes seen.

tragus and antitragus retarding the passage of sonorous undulations to the meatus.

Dissection. The remaining skin should now be removed from the pinna, and the muscles cleaned off to expose the cartilage: in doing this the lobule of the ear, which consists only of skin and fat, will disappear as in fig. 8. Clean the cartilage.

The *cartilage of the pinna* (fig. 8) resembles much the external ear in form, and presents nearly the same parts. The rim of the helix subsides posteriorly about the middle of the pinna; while anteriorly a small process projects from it, and there is a fissure near the projection. The part of the cartilage forming the fossa of the helix ends on a level with the lowest part of the concha in a pointed process which is separated from the antitragus by a deep notch. The antihelix is continued below into the antitragus. On the posterior aspect of the concha is a strong vertical ridge of cartilage. Cartilage forms part of external ear.

Deficient inferiorly,

Inferiorly the cartilage is fixed to the margin of the external auditory aperture in the temporal bone, and forms a portion of the meatus auditorius; but it does not give rise to a complete tube, for at the upper and hinder part that canal is closed by fibrous tissue. and at upper part of meatus.

In the piece of cartilage forming the outer end of the meatus are two *fissures* (of Santorini): one is directed vertically beneath the base of the tragus; the other passes from before backwards in the floor of the meatus. Its fissures.

Some *ligaments* connect the pinna with the head, and others pass from one point to another of the cartilage. Ligaments;

The *external* ligaments are two bands of fibrous tissue, anterior and posterior. The anterior fixes the fore part of the helix to the root of the zygoma. The posterior passes from the back of the concha to the mastoid process. The chief *special* ligament crosses the interval between the tragus and the helix, and completes the opening of the auditory meatus. extrinsic.

intrinsic.

Vessels and nerves of the auricle. The *arteries* of the auricle are derived from the *superficial temporal* (ant. *auricular* branches) and the *posterior auricular* branches of the external carotid. The *veins* have a corresponding termination. The skin of the pinna is supplied on the outer surface mainly by the *auriculo-temporal* branch of the inferior maxillary nerve, on the inner surface in the upper part by the *small occipital*, and in the lower part, together with the outer aspect of the lobule, by the *great auricular nerve*. The *auricular branch of the vagus* also reaches the back of the concha. The muscles are supplied by the *posterior auricular branch* of the facial nerve.

The **FACIAL NERVE** (fig. 9), or the seventh cranial nerve, is the motor nerve of the superficial muscles of the head and face. Numerous communications take place between it and the fifth nerve; the chief of these are found above and below the orbit, and over the side of the lower jaw. Outline of facial nerve.

Dissection. The facial nerve is to be displayed on the right side of the face if there is sufficient time before the body is turned; otherwise it is to be omitted for the present (see p. 1). The trunk Dissection of nerve

of the nerve is concealed by the parotid gland, but its ramifications are mostly in front of the glandular mass.

beyond
parotid,

To expose the branches of the nerve beyond the parotid gland, raise the skin from the face in the same manner as on the left side. The different branches are then to be sought as they escape from beneath the anterior border of the gland, and are to be followed forwards to their termination.

on temple,

The highest branches to the temple have already been partly dissected above the zygomatic arch; and their junction with the temporal branch of the superior maxillary, and with the supraorbital nerve has been seen. Some still smaller branches are to be traced to the outer part of the orbit, where they enter the eyelids and communicate with the other palpebral nerves; as these cross the malar bone, a junction is to be found with the subcutaneous malar branch of the fifth nerve.

in eyelids,

in the face,

With the duct of the parotid are two or more large branches, which are to be followed below the orbit to their junction with the infraorbital, nasal, and infratrochlear nerves.

on lower
jaw.

The remaining branches to the lower part of the face are smaller in size. One joins with the buccal nerve over the lower part of the buccinator muscle; and one or two others are to be traced forwards to the lower lip, and to the mental branch of the inferior dental nerve.

The nerve
in the
parotid,

To follow backwards the trunk of the nerve through the gland, the integuments should be taken from the surface of the parotid as on the other side, and the gland should be removed piece by piece. In this proceeding its small branches of communication with the great auricular nerve, and the deep branches joining it from the auriculo-temporal nerve (of the fifth) are to be sought.

and muscu-
lar branches.

Lastly, the first small branches of the facial to the ear and to the digastric and stylo-hyoid muscles are to be looked for close to the base of the skull before the nerve enters the parotid.

Branches
outside the
skull.

THE FACIAL NERVE OUTSIDE THE SKULL (fig. 9,¹⁵). The nerve issues from the stylo-mastoid foramen, after traversing the aqueduct of Fallopius, and furnishes immediately the three following small branches:—

Posterior
auricular
branch.

The *posterior auricular branch* (fig. 9,⁴) turns upwards in front of the mastoid process, where it communicates with an offset of the great auricular, and is also joined by a branch to the ear from the pneumo-gastric nerve; it ends in auricular and mastoid offsets (p. 8).

Branch to
digastric.

The *branch to the digastric muscle* arises generally in common with the next. It is distributed by several offsets to the posterior belly of the muscle near the skull.

Branch to
stylo-hyoid.

The *branch to the stylo-hyoid* is a long slender nerve, which is directed inwards, and enters its muscle about the middle. This branch communicates with the sympathetic nerve on the external carotid artery.

Division
into two.

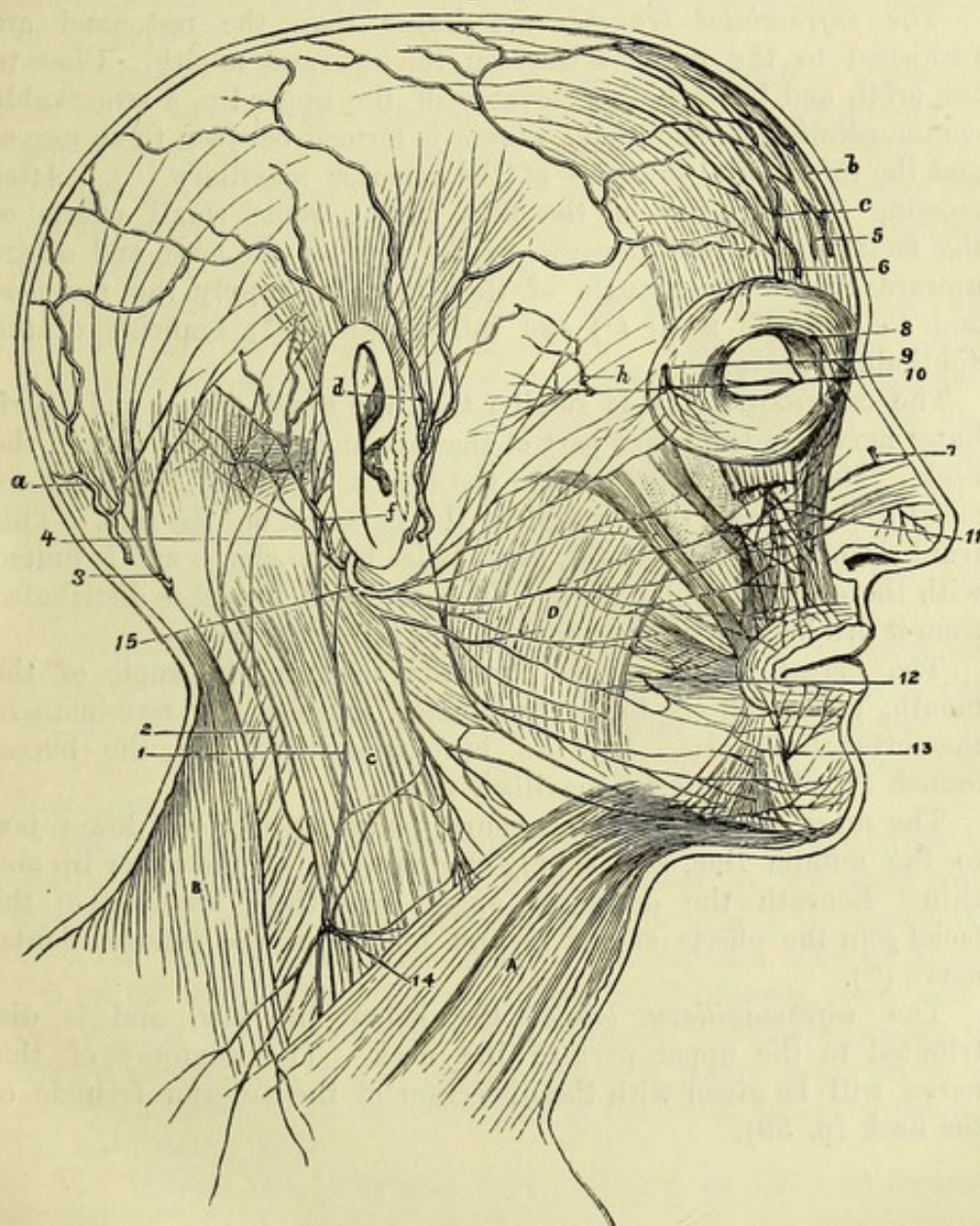
As soon as the facial nerve has given off these branches, it is directed forwards through the gland, and divides near the ramus of the jaw into two large trunks—temporo-facial and cervico-facial.

The TEMPORO-FACIAL TRUNK furnishes offsets to the side of the head and face, which extend downwards to the level of the mouth. As this trunk crosses over the external carotid artery, it receives one or two large branches from the auriculo-temporal portion of the inferior maxillary nerve, and then divides into three sets of terminal branches—temporal, malar, and infraorbital, which have

The upper division of the nerve

has three sets of branches.

Fig. 9.*



frequent communications with one another as they pass forwards in the face.

The *temporal branches* ascend obliquely over the zygomatic arch to enter the orbicularis palpebrarum, the corrugator supercilii, and the frontalis muscles; they are united with offsets of the supra-

Temporal branches to side of head.

* Superficial nerves of the face. 7. Nasal nerve. 8. Infratrochlear. 9. Subcutaneous malar. 11. Infraorbital. 12. Buccal. 13. Mental. 15. Facial nerve, sending back the posterior auricular branch, 4, and forwards its numerous offsets to join the branches of the fifth nerve above enumerated.

orbital nerve (⁶). The *attrahens* and *attollens aurem* muscles are supplied from this set ; and a junction takes place above the zygoma with the temporal branch of the superior maxillary nerve (¹⁰).

Malar
branches
to eyelids.

The *malar branches* are directed to the outer side of the orbit, and are distributed to the orbicularis muscle. Communications take place in the eyelids with the palpebral filaments of the fifth nerve, and over the malar bone with the small subcutaneous malar branch of the superior maxillary nerve (⁹).

Infraorbital
branches
between eye
and mouth.

The *infraorbital branches* are larger than the rest, and are furnished to the muscles between the eye and mouth. Close to the orbit, and beneath the elevator of the upper lip, a remarkable communication—*infraorbital plexus*, is formed between these nerves and the infraorbital branches of the superior maxillary (¹¹). After crossing the branches of the fifth nerve, some small offsets of the facial nerve pass inwards to the side of the nose, and others upwards to the inner angle of the orbit, to supply the muscles, and to join the nasal (⁷) and infratrochlear (⁸) branches of the ophthalmic nerve.

Lower
division of
the nerve
has also

The CERVICO-FACIAL is smaller than the upper trunk, and distributes nerves to the lower part of the face and the upper part of the neck. Its highest branches join the lowest offsets of the temporo-facial division, and thus complete the network on the face. This trunk, while in the parotid, gives twigs to the gland, and is united with the great auricular nerve. The terminal branches distributed from it are buccal, supramaxillary, and inframaxillary.

three sets of
branches.

Buccal to
corner of
mouth.

The *buccal branches* pass forwards towards the angle of the mouth, giving offsets to the buccinator muscle, and terminate in the orbicularis oris. On the buccinator they join the buccal branch (¹²) of the inferior maxillary nerve.

Supra-
maxillary
between
mouth and
chin.

The *supramaxillary branches* course forwards over the lower jaw to the middle line, and supply the muscles of the lower lip and chin. Beneath the depressor anguli oris these branches of the facial join the offsets of the mental branch of the inferior dental nerve (¹³).

Infra-
maxillary
to neck.

The *inframaxillary branch* lies below the jaw, and is distributed to the upper part of the neck. The anatomy of this nerve will be given with the dissection of the anterior triangle of the neck (p. 59).

SECTION IV.

DISSECTION OF THE ORBIT.

Directions. The orbit should be dissected on the side on which the muscles of the face have been learnt.

Position of
the head.

Position. In the examination of this cavity the head is to be placed in the same position as for the dissection of the sinuses of the base of the skull.

Dissection. The cotton wool beneath the eyelids should be taken away, and the bone forming the roof of the orbit may be removed in the following manner. Two vertical cuts are to be made with a saw through the frontal bone opposite the inner and outer edges respectively of the anterior opening of the orbit; and then with a chisel these are to be continued backwards along the roof of the orbit, so as to meet near the optic foramen. The piece of bone included between the incisions is now to be tilted forwards, but is not to be taken away.

How to open
the orbit
with saw,

chisel,

Afterwards the rest of the roof of the orbit, which is formed by the small wing of the sphenoid bone, is to be cut away with the bone forceps, except a narrow ring around the optic foramen; and any overhanging bone on the outer side, which may interfere with the dissection, should be likewise removed. During the examination of the cavity the eye is to be pulled gently forwards.

and bone
forceps.

The *periosteum* of the orbit is now seen where it has been detached from the bone in the dissection. This membrane forms a sac around the contents of the orbit, which is continuous posteriorly with the dura mater through the sphenoidal fissure and the optic foramen, and is closed in front by the palpebral fascia passing from it to the lids (p. 31). It adheres but loosely to the bones, and is perforated behind by apertures for the passage of the vessels and nerves entering the orbit. On the sides, prolongations of the membrane accompany the vessels and nerves leaving the cavity.

Periosteum
of orbit.

Dissection. The periosteum is next to be divided along the middle of the orbit, and to be taken away. After the removal of a little fat, the following nerves, vessels, and muscles come into view; but it is not needful to remove much of the fat at this stage of the dissection.

Open
periosteum.

The frontal nerve and the supraorbital artery are placed in the centre; the lachrymal nerve and vessels close to the outer wall; and the small fourth nerve at the back of the orbit: all these nerves are above the muscles in the cavity. The superior oblique muscle lies on the inner side, and is recognised by the fourth nerve entering it; the levator palpebræ and superior rectus are beneath the frontal nerve; and the external rectus is partly seen below the lachrymal nerve. At the outer part of the orbit, near the front, is the lachrymal gland.

Position of
parts
exposed.

The frontal and lachrymal nerves should be followed forwards to their exit from the orbit, and backwards, with the fourth nerve, through the sphenoidal fissure, to the wall of the cavernous sinus. In tracing them back, it will be expedient to remove the projecting anterior clinoid process, should this still remain; and some care will be required to follow the lachrymal nerve to its commencement.

Trace super-
ficial nerves.

Contents of the orbit. The eyeball and the lachrymal gland, and a great quantity of granular fat, are lodged in the orbit. Connected with the eye are six muscles—four straight and two oblique; and there is also an elevator of the upper eyelid in the cavity.

Orbit has
seven
muscles;

several cranial nerves; The nerves in the cavity are numerous, viz., the second, third, fourth, ophthalmic of the fifth, and the sixth, together with the small temporo-malar branch of the superior maxillary nerve, and offsets of the sympathetic; their general distribution is as follows:—

their distribution; The second nerve enters the eyeball; the third supplies all the muscles of the cavity but two; the fourth enters the superior oblique; and the sixth is spent in the external rectus muscle. The fifth nerve supplies some filaments to the eyeball with the sympathetic, but the greater number of its branches pass through the orbital cavity to the face. The ophthalmic vessels are also contained in the orbit.

and some vessels.

Lachrymal gland at outer part of orbit. The LACHRYMAL GLAND (fig. 10, F) secretes the tears, and is situated in the hollow on the inner side of the external angular process of the frontal bone. It is of an oval form, something like a small almond, and measures about three-quarters of an inch in its longest diameter, which is directed transversely. From its fore part a thin accessory piece projects beneath the upper eyelid. The upper surface is convex, and in contact with the periosteum, to which it is connected by fibrous bands that constitute a ligament for the gland; the lower surface rests on the eyeball and the external rectus muscle.

Ducts open behind upper eyelid. The gland has from eight to twelve very fine ducts, which open on the surface of the conjunctiva in a curved line above the outer part of the upper eyelid, and a little in front of the fornix.

Fourth nerve. The FOURTH NERVE (fig. 10, ¹) is the most internal of the three nerves entering the orbit above the muscles. In the cavity, it is directed inwards above the levator palpebræ to the superior oblique muscle, which it pierces on the orbital surface.

Ophthalmic gives three branches. The OPHTHALMIC TRUNK of the fifth nerve (fig. 10), as it approaches the sphenoidal fissure, furnishes from its inner side the nasal branch, and then divides into the frontal and lachrymal branches; the first passes into the orbit between the heads of the external rectus, but the other two lie, as before said, above the muscles.

Frontal. The *frontal nerve* (fig. 10, ²) is close to the outer side of the fourth as it enters the orbit, and is much larger than the lachrymal branch. In its course to the forehead the nerve lies along the middle of the orbit; and after giving off from its inner side the supratrochlear branch (⁴), it leaves the cavity by the supraorbital notch. Taking the name *supraorbital*, it ascends on the forehead, where it is distributed. This nerve frequently divides into its two main branches (p. 6) while still within the orbit.

Palpebral filaments. While in the notch the supraorbital nerve gives one or two *palpebral* filaments to the upper lid.

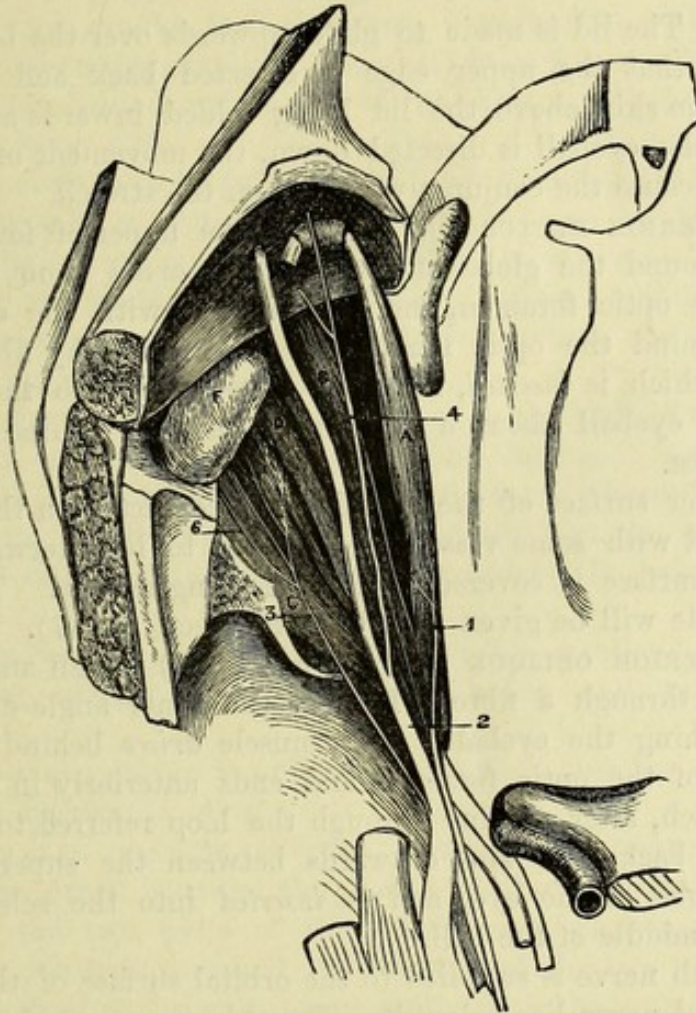
Supratrochlear branch. The *supratrochlear nerve* (⁴) passes inwards above the pulley of the upper oblique muscle, and leaves the orbit to end in the eyelid and forehead (p. 7). Before the nerve turns round the margin of the frontal bone, it sends downwards a twig of communication to the infratrochlear branch of the nasal nerve.

Lachrymal nerve. The *lachrymal nerve* (fig. 10, ³) after entering the orbit in a

separate canal of the dura mater, is directed forwards in the outer part of the cavity, and beneath the lachrymal gland to the upper eyelid, where it pierces the palpebral fascia, and is distributed to the structures of the lid. ends in eyelid:

The nerve furnishes branches to the lachrymal gland: and near offset joins superior maxillary.

Fig. 10.*



the gland it sends downwards one or two small filaments (6) to join the temporo-malar branch of the superior maxillary nerve.

The *nasal nerve* is not fully seen at this stage of the dissection, and will be noticed later (p. 43). Nasal, afterwards.

Dissection. Divide the frontal nerve about its middle, and throw the ends forwards and backwards: by raising the posterior piece of the nerve, the separate origin of the nasal branch from the ophthalmic trunk will appear. The lachrymal nerve may remain uncut. Dissection.

The *LEVATOR PALPEBRÆ SUPERIORIS* (fig. 10, B) is the most superficial muscle, and is attached posteriorly to the roof of the orbit in front of the optic foramen. The muscle widens in front, Elevator of upper eyelid,

* First view of the orbit (Illustrations of Dissections). *Muscles*:—A. Superior oblique. B. Levator palpebræ. C. External rectus. D. Superior rectus. F. Lachrymal gland. *Nerves*:—1. Fourth. 2. Frontal. 3. Lachrymal. 4. Supratrochlear. 6. Offset of lachrymal to join temporo-malar.

- attached to tarsus. and bends downwards in the upper eyelid to be *inserted* by a broad tendon into the front of the tarsal plate.
- Relations. By one surface the muscle is in contact with the frontal nerve and the periosteum; and by the other with the superior rectus muscle. If it is cut across about the middle, a small branch of the third nerve will be seen entering the posterior half on the under surface.
- Use. *Action.* The lid is made to glide upwards over the ball by this muscle, so that the upper edge is directed back and the lower forwards, the skin above the lid being folded inwards at the same time. If the eyeball is directed down, the movement of the lid is less free, because the conjunctiva is put on the stretch.
- Upper rectus muscle. The SUPERIOR RECTUS (fig. 10, D) is the upper of four muscles that lie around the globe of the eye. It *arises* from the upper part of the optic foramen, and is connected with the other recti muscles around the optic nerve. In front the fleshy fibres end in a tendon, which is *inserted*, like the other recti, into the sclerotic coat of the eyeball about a quarter of an inch behind the transparent cornea.
- Origin. Insertion.
- Position to other parts. The under surface of the muscle is in contact with the globe of the eye, and with some vessels and nerves to be afterwards seen; the upper surface is covered by the preceding muscle. The action of the muscle will be given with the other recti (p. 47).
- Use. The SUPERIOR OBLIQUE MUSCLE (fig. 10, A) is thin and narrow, and passes through a fibrous loop at the inner angle of the orbit before reaching the eyeball. The muscle *arises* behind from the inner part of the optic foramen, and ends anteriorly in a rounded tendon, which, after passing through the loop referred to (fig. 11), is reflected backwards and outwards between the superior rectus and the globe of the eye, and is *inserted* into the sclerotic coat behind the middle of the ball.
- Upper oblique muscle. enters a loop. Insertion.
- Relations. The fourth nerve is supplied to the orbital surface of the muscle and the nasal nerve lies below it. The thin insertion of the muscle lies between the superior and the external recti, and near the tendon of the inferior oblique.
- Pulley of the muscle. The *pulley*, or *trochlea* (fig. 11), is a fibro-cartilaginous ring nearly a quarter of an inch wide, which is attached by fibrous tissue to the depression of the frontal bone at the inner angle of the orbit. A fibrous layer is prolonged from the margins of the pulley on the tendon; and a synovial sheath lines the ring, to facilitate the movement of the tendon through it. To see the synovial sheath and the free motion of the tendon, this prolongation may be cut away.
- Use. For the use of the muscle, see the description of the inferior oblique (p. 49).
- Dissection. *Dissection.* The superior rectus muscle is next to be divided about the middle and turned backwards (fig. 11), when a branch of the third nerve to its under surface will be found. At the same time the nasal nerve and the ophthalmic vessels will come into view as they cross inwards above the optic nerve: these should be traced

forwards to the inner angle, and backwards to the posterior part of the orbit.

By taking away the fat between the optic nerve and the external rectus, at the back of the orbit, the student will find easily fine nerves (ciliary) with small arteries lying along the side of the optic nerve; and by tracing these ciliary nerves backwards, he will be guided to the small lenticular ganglion (the size of a pin's head). The dissector should find then two branches from the nasal and third nerves to the ganglion: the nasal branch is slender, and enters the ganglion behind; while that of the third nerve, short and thick, joins the lower part.

Find lenticular ganglion,

and roots.

The eyeball is to be fully exposed by dissecting off its investing fascia (capsule of Tenon), which will be seen to send processes around the several muscles inserted into the sclerotic.

Clean eyeball.

Lastly, the student should separate from one another the nasal, third, and sixth nerves, as they pass between the heads of the external rectus muscle into the orbit.

Separate nerves.

The THIRD NERVE is placed highest in the wall of the cavernous sinus (fig. 4, ³); but at the sphenoidal fissure it descends below the fourth, and the two superficial branches (frontal and lachrymal) of the ophthalmic nerve. It comes into the orbit between the heads of the outer rectus, having previously divided into two parts.

Third nerve

as it enters orbit;

The *upper division* (fig. 11, ⁸) is the smaller, and ends in the under surface of the levator palpebræ and superior rectus muscles.

its upper branch,

The *lower division* supplies three other muscles, and will be dissected afterwards (p. 47).

lower branch.

The NASAL BRANCH OF THE OPHTHALMIC NERVE (fig. 11, ¹) enters the orbit between the heads of the external rectus, lying between the two parts of the third nerve, and is then directed obliquely inwards to reach the anterior of the two internal orbital canals. Passing through this aperture with the anterior ethmoidal (nasal) artery, the nerve appears in the cranium at the outer margin of the cribriform plate of the ethmoid bone. Finally, it enters the nasal cavity by an aperture at the front of the cribriform plate; and after passing behind the nasal bone, it issues between that bone and the cartilage, to end on the outer side of the nose.

Nasal nerve.

General course to the face.

In the orbit the nasal crosses over the optic nerve, but beneath the superior rectus and levator palpebræ muscles, and lies afterwards below the superior oblique; in this part of its course it furnishes the following branches:—

In the orbit.

The *branch to the lenticular ganglion* (⁵) is about half an inch long and very slender, and arises as soon as the nerve comes into the orbit: this is the *long root* of the lenticular ganglion.

Branches.

Long root of lenticular ganglion.

Long ciliary nerves. As the nasal crosses the optic nerve, it supplies two or more ciliary branches (fig. 11) to the eyeball. These lie on the inner side of the optic nerve, and join the ciliary branches of the lenticular ganglion.

Long ciliary branches.

The *infratrochlear branch* (²) arises as the nasal nerve is about

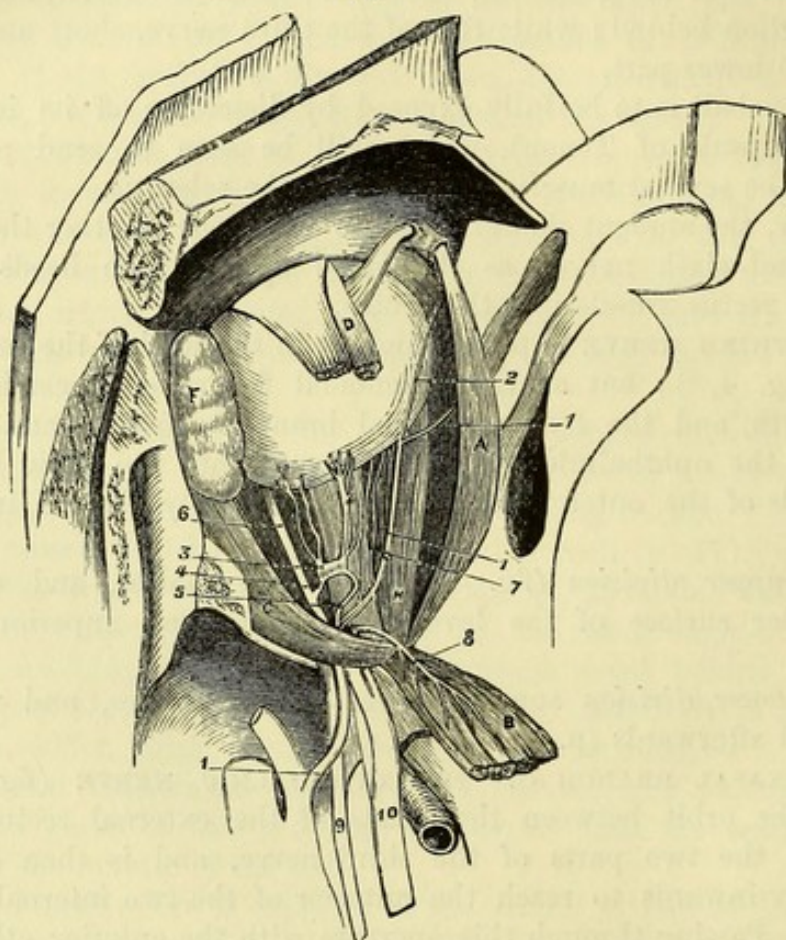
Infratrochlear branch.

to leave the cavity, and is directed forwards below the pulley of the superior oblique muscle, to end in the upper eyelid, the conjunctiva, and the side of the nose. Before this branch leaves the orbit it receives an offset of communication from the supratrochlear nerve.

Nasal nerve
in the nose,

In the nose (fig. 34). While in the nasal cavity the nerve furnishes branches to the lining membrane of the septum and outer

Fig. 11.*



wall; these will be subsequently referred to with the nerves of the nose (p. 142).

and in the
face.

Termination of the nasal nerve (fig. 9). After the nerve becomes cutaneous on the side of the nose, as seen in the dissection of the facial nerve (p. 36), it descends beneath the compressor naris muscle, and ends in the integuments of the tip of the nose.

Lenticular
ganglion.

The OPTHALMIC OR LENTICULAR GANGLION (fig. 11,³) is a small round body, about the size of a pin's head, and of a reddish colour.

Situation.

It is placed at the back of the orbit between the optic nerve and

* Second view of the orbit (Illustrations of Dissections). *Muscles* :—A. Superior oblique. B. Levator palpebrae and upper rectus thrown back together. C. External rectus. D. Fore part of upper rectus. F. Lachrymal gland. *Nerves* :—1. Nasal nerve beginning outside the orbit. 2. Its infra-trochlear branch. 3. Lenticular ganglion :—4, its short root; 5, its long root (too large). 6. Branch of third to inferior oblique muscle. 7. Ciliary branches of the nasal nerve. 8. Upper branch of the third. 9. Sixth nerve. 10. Third nerve, outside the orbit.

the external rectus, and commonly on the outer side of, and close to the ophthalmic artery. By its posterior part the ganglion has branches of communication with other nerves (its roots); and from the anterior part proceed ciliary branches to the eyeball. The ganglion receives roots from sensory, motor, and sympathetic nerves.

The *branches of communication* are three in number. One, the *long root* (⁵), is the branch of the nasal nerve before noticed, which joins the superior angle. A second branch of considerable thickness, the *short root* (⁴), passes to the inferior angle from the branch of the third nerve that supplies the inferior oblique muscle. And the *sympathetic root* is derived from the cavernous plexus, either in union with the long root, or as a distinct branch to the posterior border of the ganglion.

Branches. The *short ciliary nerves* (fig. 11) are ten or twelve in number, and are collected into two bundles, which leave the upper and lower angles at the front of the ganglion. In the upper bundle are four or five, and in the lower, six or seven nerves. In their course to the eyeball they lie along the outer and under parts of the optic nerve, and communicate with the long ciliary branches of the nasal nerve.

The **OPHTHALMIC ARTERY**, a branch of the internal carotid, enters the orbit through the optic foramen. At first the vessel is outside the optic nerve, but it then courses inwards over (or occasionally under) the nerve to the inner side of the orbit, and finally perforates the palpebral fascia above the internal tarsal ligament to end by dividing into frontal and nasal branches.

The *branches* of the artery are numerous, though inconsiderable in size, and may be arranged in three sets:—one arising outside the optic nerve, another above it, and a third set on the inner side.

The *lachrymal artery* accompanies the nerve of the same name to the upper eyelid, where it ends by supplying that part, and joining in the palpebral arches (p. 33). It supplies branches, like the nerve, to the lachrymal gland and the conjunctiva; and it anastomoses with the large meningeal artery by an offset through the sphenoidal fissure.

The lachrymal artery also sends a small branch with each of the divisions of the temporo-malar nerve; and these join the temporal and transverse facial arteries.

The *central artery of the retina* is a very small branch which pierces the optic nerve about half an inch behind the eyeball.

The *supraorbital branch* arises beneath the levator palpebræ and superior rectus muscles; it then takes the course of the nerve of the same name through the notch in the margin of the orbit, and ends in branches on the forehead (p. 5).

The *ciliary branches* are uncertain in their place of origin and enter the eyeball at the front and back:—

The *posterior ciliary*, four or five in number, run to the eyeball around the optic nerve, and divide into a number of branches (from fifteen to twenty), which perforate the sclerotic coat at the posterior

Connections.

Three roots:

long,

short,

and sympathetic

Ciliary branches to eyeball.

Ophthalmic artery,

in the orbit

Branches.

Lachrymal branch

to gland and eyelids:

offsets through malar bone

Branch to retina.

Supraorbital branch.

Ciliary arteries are

posterior—

- two named long ciliary, part. Two of this set (one on each side of the optic nerve), named *long ciliary*, pierce the sclerotic farther out than the others, and lie along the middle of the eyeball.
- and anterior. The *anterior ciliary arteries* arise from muscular branches of the ophthalmic, and perforate the sclerotic coat near the cornea : in the eyeball they anastomose with the long ciliary. For the ending of these vessels, see the dissection of the eyeball.
- Muscular. The *muscular branches* are uncertain in their place of origin ; and those to the lower muscles often arise together as one trunk.
- Ethmoidal branches, The *ethmoidal branches* are two, anterior and posterior, and are directed through the canals in the inner wall of the orbit :—
- posterior The *posterior* is the smaller of the two, and ends in offsets to the mucous membrane of the upper part of the nose and the ethmoidal cells.
- and anterior. The *anterior branch* (internal nasal) accompanies the nasal nerve to the cavity of the nose (Section XIV.), and gives meningeal offsets to the fore part of the falx cerebri and the dura mater of the anterior fossa of the skull.
- Branches to eyelids. The *palpebral branches*, one for each eyelid, generally arise together opposite the pulley of the superior oblique muscle, and then separate from one another. The arches they form have been dissected with the eyelids (p. 33).
- Frontal branch. The *frontal branch* turns round the margin of the orbit, and is distributed on the forehead (p. 5).
- Nasal branch. The *nasal branch* (external) supplies the skin and muscles of the upper part of the nose, and anastomoses with the angular and lateral nasal branches of the facial artery.
- Ophthalmic veins : The *ophthalmic veins* are two in number, superior and inferior, and leave the orbit by the sphenoidal fissure, between the heads of the external rectus, to end in the cavernous sinus. The *superior vein* is the larger and accompanies the artery : it begins in front by a wide communication with the angular vein, and on its way backwards it receives tributaries corresponding to most of the offsets of the artery. The *inferior vein* lies below the optic nerve, and is formed by the lower ciliary and muscular branches ; it communicates through the sphenomaxillary fissure with the pterygoid plexus. The supraorbital, frontal and palpebral veins do not join the ophthalmic, but pass to the veins of the face (pp. 6 and 33).
- superior and inferior. The *optic nerve* in the orbit extends from the optic foramen to the back of the eyeball. As the nerve leaves the foramen it is surrounded by the recti muscles ; and beyond that spot the ciliary arteries and nerves entwine around it. It terminates in the retinal expansion of the eye.
- Optic nerve
- ends in retina.
- Dissection. *Dissection* (fig. 12). Take away the ophthalmic vessels, and divide the optic nerve about its middle, together with the small ciliary vessels and nerves. Turn forwards the eyeball, and fasten it in that position with hooks. On removing some fat the three recti muscles—inner, inferior, and outer, will appear ; and lying on the first two are the offsets of the lower division of the third nerve.

The LOWER DIVISION OF THE THIRD NERVE (fig. 12) supplies three muscles in the orbit. As it enters this space, between the heads of the external rectus, it lies below the nasal, and rather above the sixth nerve. Almost immediately the nerve divides into three branches. One ⁽⁵⁾ passes to the internal, another ⁽⁴⁾ to the inferior rectus, both entering the muscles on their ocular surfaces; the third ⁽³⁾, the longest and most external, is continued forwards to the inferior oblique muscle, which it pierces at the hinder border.

Lower
division of
third nerve

supplies
muscles,

Soon after its origin the last branch communicates with the lenticular ganglion, forming the short root (fig. 11, ⁴) of that body; and it furnishes two or more filaments to the inferior rectus muscle.

and joins
ganglion.

The SIXTH NERVE (fig. 12, ²) lies below the other nerves, and above the ophthalmic veins, in the interval between the heads of the external rectus. In the orbit it first lies against, and then penetrates the inner surface of the external rectus muscle.

Sixth nerve.

RECTI MUSCLES. The *internal* (fig. 12, D), *inferior* (C), and *external recti* (B), are placed with reference to the eyeball as their names express. They arise posteriorly from the circumference of the optic foramen by a common attachment, which partly surrounds the optic nerve. The external rectus differs from the others in having two heads: the upper one joins the superior rectus in the common origin: the lower and larger head blends on the one side with the inferior rectus in the common origin, and on the other side is attached to a bony point on the lower border of the sphenoidal fissure, near the inner end, while some of its muscular fibres are also connected with a tendinous band between the heads. All the muscles are directed forwards, the lower also obliquely outwards, and have a tendinous *insertion* into the ball of the eye about a quarter of an inch from the cornea, and in front of the greatest transverse diameter of the ball.

Straight
muscles of
eyeball.

Origin.

Insertion.

Between the heads of origin of the external rectus, the different nerves before mentioned are transmitted into the orbit, viz., the third, the nasal branch of the fifth, and the sixth, together with the ophthalmic veins.

Between
heads of
outer rectus.

Action. The four recti muscles, attached to the eyeball at opposite sides in front of the greatest transverse diameter, are able to turn the pupil in opposite directions.

Use of all.

The inner and the outer muscles move the ball horizontally around a vertical axis, the former directing the pupil towards the nose and the latter towards the temple.

Inner and
outer,

The upper and lower recti elevate and depress the fore part of the ball around a transverse axis; but as the muscles are directed obliquely outwards, the upper muscle turns the pupil up and in, and the lower muscle turns it down and in.

upper and
lower,

By the simultaneous action of two contiguous recti, the ball will be moved to a point intermediate to that to which it would be directed by either muscle singly.

and two
contiguous.

Dissection. By opening the optic foramen, the attachment of the recti muscles will be more fully laid bare. To dissect out the

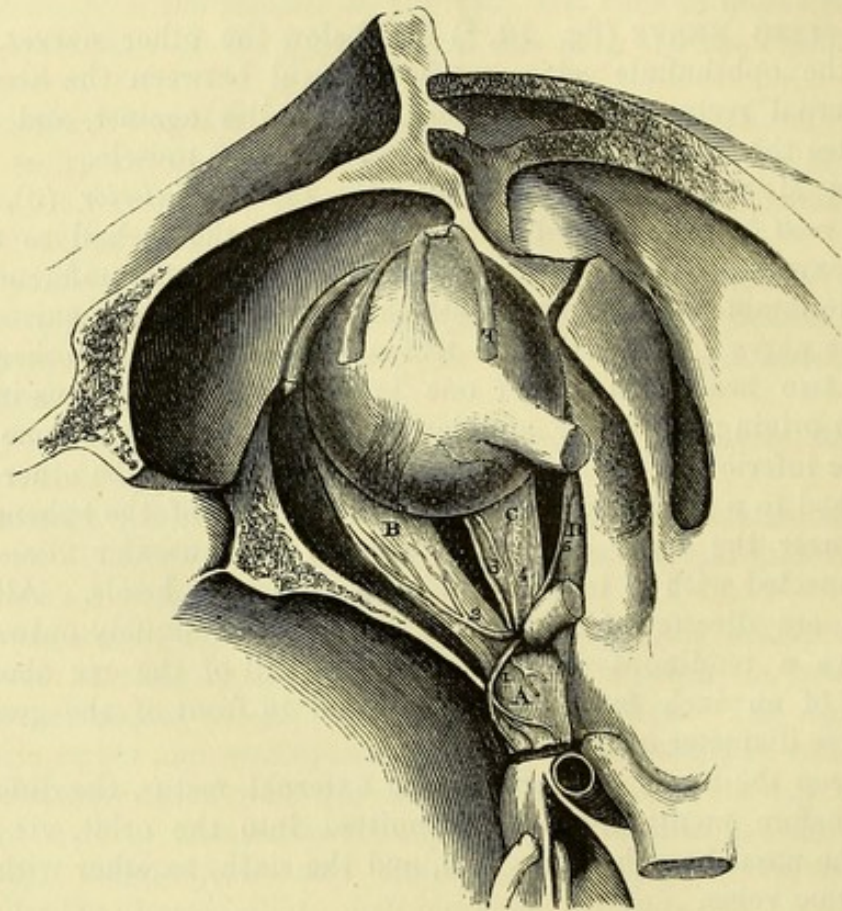
Dissect infe-
rior oblique.

inferior oblique muscle, let the eyeball be replaced in its natural position ; then by separating the lower eyelid from the margin of the orbit, and removing some fat, the muscle will appear beneath the eyeball, arching from the inner to the outer side : if the external tarsal ligament be divided it may be followed upwards to its insertion into the ball.

Lower
oblique
muscle.

The INFERIOR OBLIQUE MUSCLE (fig. 12, H) is placed near the anterior margin of the orbit, and differs from the other muscles in being directed across, instead of parallel to the axis of the orbit.

Fig. 12.*



Origin. It arises from the superior maxillary bone immediately outside the opening of the nasal duct. From this spot the muscle passes outwards between the inferior rectus and the bone, then between the eyeball and the external rectus, to be inserted into the sclerotic coat between the outer and upper recti.

Course.

Insertion.

Relations. The borders of the muscle look forwards and backwards, and the posterior receives its branch of the third nerve. The insertion of the tendon is near that of the superior oblique muscle, but rather closer to the optic nerve.

* Third view of the orbit (Illustrations of Dissections). *Muscles*:—A. Upper rectus and levator palpebrae thrown back together. B. External rectus. C. Inferior rectus. D. Internal rectus. E. Upper oblique cut, showing the insertion. H. Insertion of inferior oblique. *Nerves*:—1. Upper branch of the third. 2. Sixth nerve. 3. Branch of third to inferior oblique. 4. Branch of third to inferior rectus. 5. Branch of third to internal rectus.

Action of the oblique muscles. The superior oblique acting alone would draw the back of the eyeball upwards and inwards, and therefore cause the front of the eye to be directed downwards and outwards. The inferior oblique would similarly turn the eye upwards and outwards. In consequence of their transverse direction, these muscles would also tend to rotate the eyeball around its antero-posterior axis, the superior oblique depressing, and the inferior oblique elevating the inner end of the horizontal meridian of the eye, but movements of this nature take place only to a very limited extent during life.

Action of oblique muscles : alone,

The oblique muscles are believed to act mainly in controlling the tendency of the superior and inferior recti to rotate the eyeball and turn it inwards. Thus, to move the eye directly upwards, the superior rectus and the inferior oblique are used, while the inferior rectus and superior oblique co-operate in directing the eye downwards.

and with superior and inferior recti.

Dissection. To expose the small tensor tarsi muscle, the remaining portion of the palpebral fascia is to be separated from the margin of the orbit ; but the lids must be left attached at the inner side by means of the internal tarsal ligament. On clearing away a little areolar tissue in the neighbourhood of the inner commissure, after the lids have been placed across the nose, the pale fibres of the tensor tarsi will be seen.

Seek tensor tarsi.

The TENSOR TARSI MUSCLE arises from the crest of the lachrymal bone, and slightly from the bone behind the crest. Its fibres are pale, and form a very small flat band, behind the internal tarsal ligament, which divides like that structure into a slip for each eyelid. In the lid the slip lies by the side of the lachrymal canal, and blends with the fibres of the orbicularis along the free margin of the tarsus.

Tensor tarsi muscle.

Insertion.

Action. The tensor tarsi draws backwards the inner canthus of the eye and compresses the lachrymal sac, after it has been dilated by the orbicularis palpebrarum in the act of winking.

Use.

Dissection. A small nerve, the orbital branch of the superior maxillary trunk, lies along the lower part of the outer wall of the orbit, and may be brought into view after the removal of the eyeball and its muscles. This nerve is very soft and easily broken, and is covered, as it enters the orbit through the spheno-maxillary fissure, by pale fleshy fibres (orbitalis muscle). Two branches, temporal and malar, are to be traced forwards from it ; and the junction of a filament of the lachrymal nerve with the former is to be sought close to the bone. The outer wall of the orbit may be cut away bit by bit, to follow the temporal branch to the surface of the head.

Trace offset of superior maxillary nerve.

The TEMPORO-MALAR OR ORBITAL BRANCH of the superior maxillary nerve arises in the spheno-maxillary fossa, and divides at the back of the orbit into malar and temporal branches, which ramify on the face and the side of the head with companion vessels.

Orbital branch of superior maxillary nerve :

The malar branch is directed forwards through the canal of the same name in the malar bone to supply the skin of the upper and

its malar

outer part of the cheek : it communicates here with the facial nerve (p. 38).

and tempo-
ral offsets.

The *temporal branch* ascends in a groove in the bone on the outer wall of the orbit, and after being joined by a filament from the lachrymal nerve, passes into the temporal fossa through the temporal canal in the malar bone : it is then directed upwards between the temporal muscle and the skull, and perforates the temporal fascia near the orbit (p. 8).

Orbitalis
muscle.

Orbitalis muscle. At the lower and outer angle of the orbit this thin layer of unstriped muscle is sometimes well seen. The fibres cross the speno-maxillary fissure, being attached to the edges, and are pierced by the temporo-malar nerve.

Apparatus
for the tears.

LACHRYMAL APPARATUS (fig. 13). The lachrymal gland, puncta, canals, and sac, with the nasal duct, constitute the apparatus by which the tears are formed and conveyed to the nose. The gland has been already described (p. 40).

Dissection.

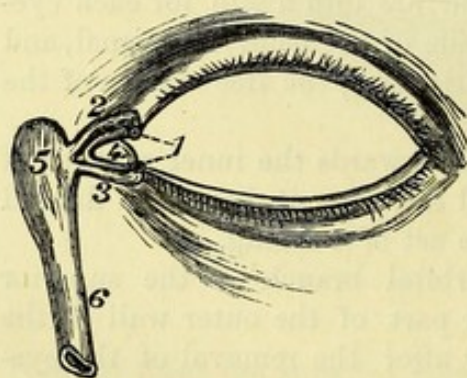
Dissection. A bristle or blunted pin should be introduced into each lachrymal canal through the punctum of the eyelid. The lachrymal sac will appear on removing the tensor tarsi and the areolar tissue from its surface, as it lies on the lachrymal bone. The prolongation from the internal tarsal ligament over the sac should be defined.

Apertures
in eyelids.

The *puncta lachrymalia* (¹), one in each lid, are the openings of the lachrymal canals. Each is situate on the free margin of the lid, about a quarter of an inch from the inner canthus, and at the summit of the papilla lachrymalis.

Fig. 13.*

Canals for
the tears.



The *lachrymal canals* (canaliculi, fig. 13, ² and ³) lead from the puncta, and convey the tears to the lachrymal sac. From the margin of the lid, each canal is directed vertically for about half a line, and then bends inwards, following the course of the internal tarsal ligament. Internally the two canals converge, and they

open into the lachrymal sac, rather above its middle, either separately or by a common orifice.

Receptacle
of the tears.

The *lachrymal sac* and *nasal duct* extend from the inner side of the orbit to the nose, and convey the tears into the latter cavity. They form one tube, of which the upper dilated end is the sac, and the lower part the duct.

Situation of
the sac, or
dilated part.

The *sac* (⁵) is placed in the hollow formed by the nasal process of the superior maxillary and the lachrymal bones. In front, it is crossed by the ligament of the eyelids ; and behind, it is covered by

* The eyelids and lachrymal apparatus. 1. Puncta lachrymalia. 2. Upper, and 3, lower lachrymal canal. 4. Caruncula lachrymalis. 5. Lachrymal sac. 6. Nasal duct.

an expansion derived from that band, which is fixed to the lachrymal crest. If the aponeurotic covering be removed, the mucous lining will appear. Into the outer side of the sac the lachrymal canals open.

The *duct* ⁽⁶⁾ is the narrower part of the tube, and is about half an inch long. It is entirely surrounded by bone, and inclines slightly outwards and backwards as it descends. In the nasal cavity it opens into the fore part of the inferior meatus, where its opening is guarded by a small fold of the mucous membrane.

Canal leading to the nose.

Its opening.

Within the bone, the duct has a fibrous coat lined by mucous membrane, which is continuous with that of the nose below, and through the canals with the conjunctiva above.

Structure of the duct.

Directions. The examination of the eyeball may be omitted with more advantage till the dissection of the head and neck has been completed. The description of the eye will be found in Chapter X.

Anatomy of eyeball afterwards.

SECTION V.

DISSECTION OF THE NECK.

Position. For the dissection of the right side of the neck let the head be supported on a block of a moderate height, and let the face be turned to the left side and fastened in that position with hooks. To obtain a good view of the region, the right arm may be drawn tightly under the body, with the object of depressing the point of the shoulder, and putting the neck on the stretch. In some bodies, owing to a difference in the form of the neck, the best position will be obtained by placing the upper limb over, instead of under the chest.

Position of the part.

Surface-marking. The side of the neck has a somewhat irregularly quadrilateral outline, and is limited in the following way :—Below is the prominence of the clavicle ; and above is the base of the lower jaw with the skull. In front, the boundary is the middle line of the neck between the chin and sternum ; and behind, a line from the occiput to the acromial end of the clavicle. The part thus included is divided into two triangular spaces (anterior and posterior) by the diagonal prominence of the sterno-mastoid muscle. And in consequence of the position of that muscle the base of the anterior space is at the jaw, and the apex at the sternum ; while the base of the posterior one is at the clavicle, and the apex at the head.

Boundaries of the side of the neck.

Division into two triangles by sterno-mastoid.

The surface in front of the sterno-mastoid is depressed at the upper part of the neck, near the position of the carotid vessels ; and behind the muscle, just above the clavicle, is another hollow which indicates the situation of the subclavian artery.

Hollows.

Along the front of the neck the following parts can be recognised through the skin :—About two inches and a half from the chin, in the retiring angle formed by the outline of the front of the neck,

Objects in middle line of neck,

hyoid bone the body of the hyoid bone may be felt, with its large cornu extending backwards on each side. Below this is the prominence of the thyroid cartilage, called *pomum Adami*, which is more marked in the male sex; and between the cartilage and the hyoid bone is a slight interval, corresponding with the thyro-hyoid membrane.

thyroid, Below the thyroid is the narrow prominent ring of the cricoid cartilage; and between the two the finger may distinguish another interval, which is opposite the crico-thyroid membrane.

cricoid cartilage, Immediately above the sternum, and bounded on each side by the prominent sterno-mastoid muscle, is a narrow depression, the depth of which is much increased in emaciated persons, and in which the tube of the trachea can be recognised. In some bodies, especially in women, the swelling of the thyroid gland may be felt by the side of the air tube.

and supra-sternal depression. *Directions.* As the time for turning the body will not allow the examination of the whole side of the neck, the student should lay bare now only the part behind the sterno-mastoid muscle.

Dissection of the platysma. *Dissection.* To raise the skin from the posterior triangle of the neck, make an incision along the sterno-mastoid muscle from the tip of the mastoid process to the clavicle one inch external to its articulation with the sternum; from the upper end of this carry a cut backwards two-thirds of the distance to the external occipital protuberance, and from the lower end another cut outwards along the clavicle as far as the acromion. The skin is to be reflected from before back towards the trapezius muscle. The superficial fascia, which will then be brought into view, contains the platysma; and to see that muscle, it will be necessary to take the subcutaneous layer from the surface of the fibres.

Platysma muscle The PLATYSMA MYOIDES is a thin subcutaneous muscular layer, which is now seen only in its posterior half. The muscle is placed across the side of the neck, and extends from the top of the shoulder to the face. Its fleshy fibres take *origin* from the subcutaneous tissue over the clavicle and acromion, as well as from that covering the highest parts of the pectoral and deltoid muscles; ascending through the neck, the fibres are *inserted* into the jaw and the angle of the mouth.

arises at shoulder; inserted into jaw; The lower part of the muscle is more closely united to the skin than the upper, and covers the external jugular vein as well as the lower part of the posterior triangle. At first the fibres of the muscle are thin and scattered, but they increase in strength as they ascend. The oblique direction of the fibres should be noted, because in venesection in the external jugular vein the incision is to be so made as to divide them transversely.

covers triangle. *Use.* The action will be found with the description of the remainder of the muscle (p. 58).

Dissection. *Dissection.* The platysma is to be cut across near the clavicle, and to be reflected forwards as far as the incision over the sterno-mastoid muscle, but it is to be left attached at that spot. In raising the muscle the student must be careful of the deep fascia of the neck; and he should dissect out the external jugular vein, with the

superficial descending branches of the cervical plexus, which are close beneath the platysma.

The EXTERNAL JUGULAR VEIN (fig. 14, ^s) begins just behind the angle of the jaw by the union of the posterior division of the temporo-maxillary with the posterior auricular vein (fig. 15). Descending beneath the platysma to the lower part of the neck, it there pierces the deep cervical fascia to open into the subclavian vein. Its course down the neck will be marked by a line from the angle of the jaw to the middle of the clavicle. Beyond the sterno-mastoid muscle the vein is dilated, and the swollen part (*sinus*) is limited by two pairs of valves,—one being situate below at the mouth of the vein, and the other near the muscle. Small superficial branches join the vein, and an offset connects it with the anterior jugular vein. Its size and the height at which it crosses the sterno-mastoid muscle, are very uncertain.

External
jugular
vein

crosses side
of neck to
subclavian.

The DEEP CERVICAL FASCIA, like the aponeuroses in other regions of the body, consists of a superficial layer which surrounds the neck continuously, and of processes that are prolonged inwards between the muscles. In some bodies this fascia is thin and indistinct.

Cervical
fascia.

In its extent round the neck the membrane encases the sterno-mastoid, and has a different disposition before and behind that muscle. As now seen passing backwards from the muscle, the fascia continues over the posterior triangular space, and encloses the trapezius in its progress to the spines of the vertebræ. At the lower part of the neck it is attached to the clavicle, and is perforated by the external jugular vein and the cutaneous nerves.

Part behind
sterno-mas-
toid muscle

After the superficial layer has been removed near the clavicle, a deep process may be observed surrounding the omo-hyoid muscle, and passing downwards behind the clavicle, to be fixed to the back of that bone, and the anterior end of the first rib.

sends a pro-
cess around
omo-hyoid.

POSTERIOR TRIANGULAR SPACE.

This space (fig. 14), having the form and position before noted, is about eight inches in length. It contains the cervical and brachial plexuses, with the portion of the subclavian artery on which a ligature is usually placed, and some offsets of the vessel and the nerves.

Posterior
triangular
space of
the neck.

Dissection. By the removal of the cervical fascia and the fat between the sterno-mastoid and trapezius muscles, the posterior triangle of the neck will be displayed. In the execution of this somewhat difficult task the student should proceed cautiously, to avoid injuring the numerous nerves and vessels in the space.

Dissection
of the space.

Seek first the small omo-hyoid muscle (fig. 14, ³), which crosses the space obliquely about an inch above the clavicle, and divides it into two. Close to or beneath the upper border of the muscle lie the slender nerve and vessels to it: the nerve is derived from the descendens noni, and the artery from the suprascapular.

Find omo-
hyoid.

Above the omo-hyoid muscle will be found the branches of the

Nerves

above omo-hyoid ; cervical plexus, together with the spinal accessory nerve ; the latter will be recognised by its piercing the sterno-mastoid muscle. The greater number of the branches of the cervical plexus descend to the shoulder ; but the small occipital and great auricular nerves ascend to the head, and the superficial cervical branch is directed forwards over the sterno-mastoid muscle.

vessels below, Below the omo-hyoid find the large subclavian artery and the brachial plexus, which have a deep position, and run downwards and outwards. Also the following vessels and nerve are to be sought, viz., the suprascapular vessels behind the clavicle ; the transverse cervical vessels, which are higher in the neck, taking an outward direction beneath the omo-hyoid muscle ; and, lastly, the small branch of nerve to the subclavius muscle, which lies about the middle of the space between the clavicle and the omo-hyoid.

and a small nerve.

Define serratus, Underneath the trapezius, where it is attached to the clavicle, define the serratus magnus muscle ; and behind the brachial plexus, towards the lower part of the space, the middle scalenus muscle appears. Through the scalenus issue two muscular nerves ; one, formed by two or three roots, for the serratus magnus ; the other smaller, and higher up, for the rhomboidei.

and nerves piercing scalenus.

Boundaries. *Limits of the space.* The space is bounded in front by the sterno-mastoid muscle ⁽¹⁾ ; and behind by the trapezius ⁽²⁾. Its base corresponds with the middle third of the clavicle, and its apex is at the skull. In its area are several muscles, which are placed in the following order from above down, viz., splenius capitis, levator anguli scapulæ ⁽⁶⁾, and middle scalenus ⁽⁵⁾ ; and at the lower and outer angle, somewhat beneath the trapezius, lies the upper part of the serratus magnus. Covering the space are the structures already examined, viz., the skin and superficial fascia, the platysma over the lower half or two-thirds, and the deep fascia.

Is divided by omo-hyoid. The small omo-hyoid muscle ⁽³⁾ crosses the space near the clavicle, so as to divide it into two, a lower or claviclar, and an upper or occipital part.

Part near clavicle. The *claviclar part* is the smaller, and contains the subclavian artery. It is triangular in form, with its base directed forwards, and is bounded in front by the sterno-mastoid ⁽¹⁾, above by the omo-hyoid ⁽³⁾, and below by the clavicle. This space measures commonly about two inches from before backwards, and about one inch from above down at its base.

Extent of the space.

Trunks of vessels and nerves, Crossing the area of this space, rather above the level of the clavicle, is the trunk of the subclavian artery ⁽⁷⁾, which issues from beneath the anterior scalenus muscle, and is directed over the first rib to the axilla. In the ordinary condition of the vessel the companion subclavian vein is seldom seen, owing to its being placed lower down behind the clavicle. Above the artery are the large cords of the brachial plexus ⁽⁹⁾, which accompany the vessel, and become closely applied to it beneath the clavicle. Behind the artery and the nerves is the middle scalenus muscle ⁽⁵⁾. And below the vessel is the first rib.

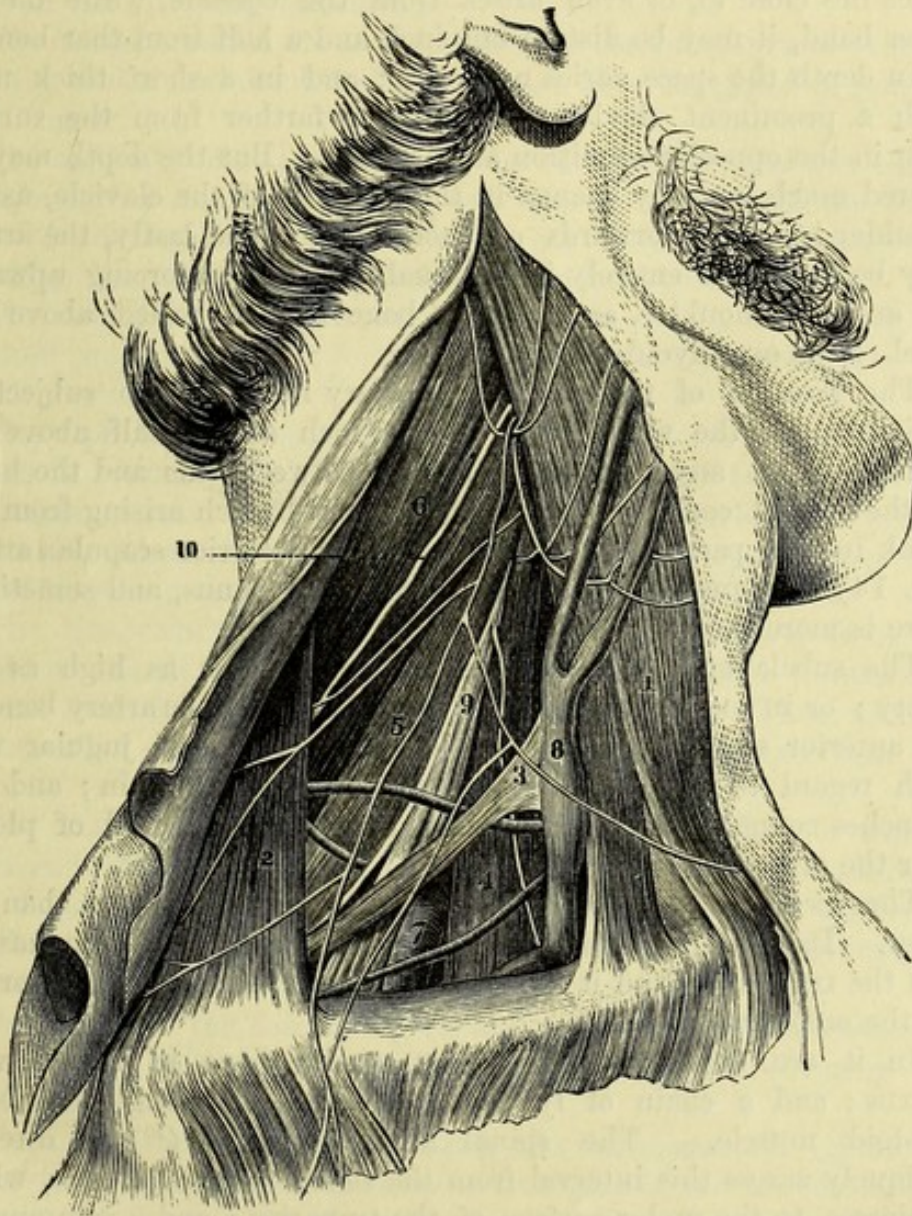
and their relative position.

Branches of vessels.

Along the lower boundary of the space, and rather beneath the

clavicle, lie the suprascapular vessels; and crossing the upper angle, at the meeting of the omo-hyoid and sterno-mastoid muscles, are the transverse cervical vessels. Entering the space from above is the external jugular vein (8), which descends over (seldom under) the omo-hyoid, and opens into the subclavian vein; in this region

Fig. 14.*



the vein receives the suprascapular and transverse cervical branches, and sometimes a small vein over the clavicle, from the cephalic vein of the arm.

* Part of the posterior triangle of the neck is here displayed, but the student should carry the dissection as high as the head, so as to lay bare the whole of that space. 1. Sterno-mastoid. 2. Trapezius. 3. Posterior belly of omo-hyoid. 4. Anterior scalenus, with the phrenic nerve on it, exposed by the shrinking of the sterno-mastoid. 5. Middle scalenus. 6. Levator anguli scapulæ. 7. Third part of subclavian artery. 8. External jugular vein joining the subclavian below. 9. Brachial plexus. 10. Spinal accessory nerve. (Blandin's Surgical Anatomy).

Variations
in the size
of the space,

The length of the clavicular part of the space depends mainly upon the extent of the attachment of the trapezius and sterno-mastoid muscles to the clavicle: in some bodies these muscles occupy nearly the whole length of that bone, leaving but a small interval between them; and occasionally they meet, so as to cover the subclavian artery altogether. The space also varies in height according to the position of the omo-hyoid, for this muscle sometimes lies close to, or even arises from the clavicle, while on the other hand, it may be distant one inch and a half from that bone.

also in the
depth, both
natural

In depth the space varies naturally; and in a short thick neck with a prominent clavicle, the artery is farther from the surface than in the opposite condition of the parts. But the depth may be altered much more by change in the position of the clavicle, as the shoulder is carried forwards or backwards. And lastly, the artery may be concealed entirely in its usual position by forcing upwards the arm and shoulder, as the collar bone can be raised above the level of the omo-hyoid muscle.

and arti-
ficial.

Departure
from the
ordinary
state of the
artery,
and its
branches.

The position of the subclavian artery itself is also subject to variation, for the vessel may be one inch and a half above the clavicle, or at any point intermediate between this and the bone. In the typical condition there is not any branch arising from the trunk in this part of its course; but the posterior scapular artery (fig. 14) is frequently given off beyond the scalenus, and sometimes there is more than one branch.

Position
of veins.

The subclavian vein occasionally rises upwards as high as the artery; or in some rare instances, it even lies with the artery beneath the anterior scalenus. The position of the external jugular vein with regard to the subclavian artery is very uncertain; and the branches connected with its lower end often form a kind of plexus over the arterial trunk.

Occipital
part of
space

The *occipital part* of the posterior triangle is larger than the other. Its boundaries in front and behind are the sterno-mastoid and the trapezius; and it is separated from the clavicular portion by the omo-hyoid muscle.

contains
nerves and
lymphatics;
also spinal
accessory
nerve.

In it are contained chiefly the ramifications of the cervical plexus; and a chain of lymphatic glands lies along the sterno-mastoid muscle. The spinal accessory nerve⁽¹⁰⁾ is directed obliquely across this interval from the sterno-mastoid muscle, which it pierces, to the under surface of the trapezius; and a communication takes place between it and the spinal nerves in the space.

Nerves of
the cervical
plexus

SUPERFICIAL BRANCHES OF THE CERVICAL PLEXUS. These nerves emerge from beneath the sterno-mastoid muscle about the middle of its hinder border, and are thence directed both upwards and downwards.

that ascend,
viz.—

The **ASCENDING SET** (fig. 14) are three in number, viz., small occipital, great auricular, and superficial cervical.

Small
occipital.

The *small occipital branch* (fig. 2, ²) comes from the second, and in most cases also from the third cervical nerves, and is directed upwards to the head along the posterior border of the sterno-mastoid muscle. It perforates the fascia near the skull, and is dis-

tributed between the ear and the great occipital nerve (p. 8). Occasionally there is a second cutaneous nerve to the back of the head.

The *great auricular nerve* (fig. 2, ¹) is derived from the second and third cervical nerves. Perforating the deep fascia at the posterior border of the sterno-mastoid muscle, the nerve is directed upwards beneath the platysma towards the lobule of the ear, and ends in the following branches :—

Great auricular,

The *facial branches* are sent forwards to the integuments over the parotid, and a few slender filaments pass into the gland to join the facial nerve.

supplies facial,

The *auricular branches* ascend to the external ear, and are chiefly distributed on its cranial aspect, but one or more reach the lower part of the outer surface. On the ear they communicate with branches furnished from the facial and pneumo-gastric nerves.

auricular,

The *mastoid branch* is directed backwards to the skin over the mastoid process, where it joins the posterior auricular branch of the facial nerve (p. 36).

and mastoid branches.

The *superficial cervical nerve* (fig. 2, ¹⁴) arises from the cervical plexus in common with the preceding, and turns forwards round the sterno-mastoid muscle about the middle. Afterwards it pierces the fascia, and ramifies over the anterior triangular space (see p. 59). There may be more than one branch to represent this nerve.

Superficial cervical nerve.

The DESCENDING SET of branches (fig. 2) are derived from the third and fourth nerves of the plexus, and are directed towards the clavicle over the lower part of the triangular space. Their number is somewhat uncertain, but usually there are about three near the clavicle.

Nerves that descend are

The most internal branch (sternal) crosses the clavicle near its inner end; the middle branch (clavicular) lies about the middle of that bone; and the external (acromial) turns over the clavicular attachment of the trapezius to the acromion. All are distributed to the skin of the chest and shoulder.

supraclavicular.

Derived from the descending set are one or two *posterior cutaneous nerves of the neck*, which ramify in the integument covering the trapezius above the scapula.

Posterior cervical cutaneous.

The *lymphatic glands* lying along the sterno-mastoid (*glandulae concatenatae*) are some of the *deep cervical glands*, and are continuous through the lower part of the posterior triangular space with the glands of the axilla. A chain of *superficial cervical glands* accompanies the external jugular vein; and close to the skull, over the apex of the posterior triangular space, are one or two small *sub-occipital glands*; while farther forwards, resting on the insertion of the sterno-mastoid, there are two or three small *mastoid glands*.

Lymphatic glands of neck.

Directions. The dissection of the posterior triangle should be repeated on the left side of the neck, in order that the difference in the vessels may be observed. Afterwards, the reflected parts are to be replaced and carefully fastened in their natural position with a few stitches, preservative fluid or salt having been previously applied.

Directions.

The body is now to be turned for the examination of the back; The back to

be examined now. and during the time allotted for this position the dissector of the head is to learn the posterior part of the neck. (See the DISSECTION OF THE BACK.)

Remove spinal cord. After the completion of the back, the student should take out the spinal cord, and then return to the dissection of the front of the neck, which is described below.

FRONT OF THE NECK.

Detach the head. *Directions.* After the thorax and back are finished, the head and neck may be detached from the trunk by dividing the spinal column between the second and third dorsal vertebræ, and cutting through the arch of the aorta beyond its large branches (if this is not done), so as to take that piece of the vessel with the head. The dissector continues his work on the remainder of the right side of the neck; but if the facial nerve has been omitted, it should be first learnt (p. 35).

Examine right side of neck. *Position.* Supposing the facial nerve completed, a small narrow block is to be placed beneath the left side of the neck, and the face is to be turned from the dissector. Farther, the neck is to be made tense by means of hooks, the chin being well raised at the same time.

Position of part. *Dissection.* An incision along the base of the jaw on the right side (if it has not been made already) will allow the piece of integument in front of the sterno-mastoid to be raised towards the middle line. Beneath the skin is the superficial fat, containing very fine offsets of the superficial cervical nerve.

Dissection to raise skin, to show platysma. To define the platysma muscle, remove the fat which covers it, carrying the knife down and back in the direction of the fleshy fibres.

Anterior part of platysma. *PLATYSMA MYOIDES.* The anterior part of the platysma, viz., from the sterno-mastoid muscle to the lower jaw, covers the greater portion of the anterior triangular space. At the base of the jaw it is inserted between the symphysis and the masseter muscle; while other and more posterior fibres are continued over the face, joining the depressor anguli oris and risorius, as far as the fascia covering the parotid gland, or even to the cheek-bone.

Insertion into jaw. *Crossing of the fibres.* The fibres have the same appearance in this as in the posterior half of the muscle (p. 52), but they are rather stronger. Below the chin the inner fibres of opposite muscles cross for about an inch, but those which are superficial do not always belong to the same side in different bodies.

Use on mouth, in swallowing. *Action.* The hinder part of this muscle draws the corner of the mouth downwards and outwards; the fore part is used in swallowing, and carries forwards the skin of the upper part of the neck, thus facilitating the upward movement of the larynx. When the muscle contracts forcibly, the skin of the upper part of the chest and shoulder is also raised.

Dissection. *Dissection.* Raise the platysma to the base of the jaw, and dissect out beneath it the branches of the superficial cervical nerve, and the cervical branch of the facial nerve. Clean also the deep

fascia of the neck, and the anterior jugular vein which is placed near the middle line.

The **SUPERFICIAL CERVICAL NERVE** has been traced from its origin in the cervical plexus to its position on the deep fascia of the neck (p. 57). Beneath the platysma it divides into an upper and a lower branch :—

The *upper branch* perforates the platysma, and ends in the skin over the anterior triangle, extending about half way down the neck. While beneath the platysma this branch joins the facial nerve.

The *lower branch* likewise passes through the platysma, and is distributed to the integuments below the preceding, reaching as low as the sternum.

The **INFRAMAXILLARY BRANCH OF THE FACIAL NERVE** (p. 38) pierces the deep cervical fascia, and divides into slender offsets which pass forwards beneath the platysma, and form arches across the side of the neck (fig. 9), reaching as low as the hyoid bone. Most of the branches end in the platysma, but a few filaments perforate it, and reach the integuments. Beneath the muscle there is a communication between this branch of the facial and the upper division of the superficial cervical nerve.

Dissection. Cut across the external jugular vein about the middle, and throw the ends up and down. Afterwards the superficial nerves of the front of the neck may be divided in a line with the angle of the jaw, the anterior ends being removed, and the posterior reflected. The great auricular nerve may be cut through and the ends reflected.

The part of the **DEEP CERVICAL FASCIA** in front of the sterno-mastoid is stronger than that over the posterior triangle (p. 53), and has the following arrangement. Above, it is fixed to the base of the lower jaw, and is continued over the parotid gland to the zygoma. A thickened band passes backwards from the angle of the jaw to the sheath of the sterno-mastoid, and holds forwards the anterior border of that muscle. Above this, a deep process is sent inwards from the hinder margin of the ramus of the jaw, between the parotid and submaxillary glands, to the styloid process, giving rise to the *stylo-maxillary ligament*. In front, the fascia is attached to the body of the hyoid bone; and below, to the sternum. Its lower part forms a dense white membrane, which near the manubrium becomes divided into two layers, one in front and the other behind, so as to enclose a small space containing a little fat and the transverse branch of communication between the anterior jugular veins.

Layers of the membrane are prolonged between the muscles; and that beneath the sterno-mastoid is continuous with the sheath of the cervical vessels. One of these, beneath the sterno-thyroid muscles, descends in front of the great vessels at the root of the neck to the arch of the aorta and the pericardium.

ANTERIOR TRIANGULAR SPACE.

Anterior
triangular
space.

This space (fig. 15) contains the carotid vessels and their branches, with many nerves; and it corresponds with the hollow on the surface of the neck in front of the sterno-mastoid muscle.

Dissection
of anterior
triangle.

Dissection. To define the anterior triangular space and its contents, take away the deep fascia of the neck and the subjacent fat, but without injuring or displacing the several parts. First clean the surface of the muscles below the hyoid bone, leaving untouched the anterior jugular vein.

Trace
arteries.

The trunks into which the large carotid artery bifurcates are to be followed upwards, especially the more superficial one (external carotid), the branches of which are to be traced as far as they lie in the space. In removing the sheath from the vessels, as these appear from beneath the muscles at the lower part of the neck, the dissector should be careful of the small descending branch of the hypoglossal nerve on the surface of the artery. In the sheath between the vessels (carotid artery and jugular vein) will be found the pneumo-gastric nerve, and behind the sheath lies the sympathetic nerve.

Seek longi-
tudinal
nerves,

and trans-
verse
nerves.

Clean the digastric and stylo-hyoid muscles, which cross the space in the direction of a line from the mastoid process to the hyoid bone, and beneath them look for several nerves. Thus, crossing the carotid arteries just below the digastric is the hypoglossal nerve, which gives one branch (*descendens noni*) in front of the artery, and another smaller one to the thyro-hyoid muscle. Under cover of the muscles, and taking a similar direction between the two carotid arteries, are the glosso-pharyngeal nerve and the stylo-pharyngeus muscle. Directed downwards and backwards from beneath the same muscles to the sterno-mastoid is the spinal accessory nerve.

Spinal
accessory.

Laryngeal
nerves.

On the inner side of the vessels, between the hyoid bone and the thyroid cartilage, the dissector will find the superior laryngeal nerve; and by the side of the larynx, with the descending part of the superior thyroid artery, the small external laryngeal branch.

Clean gland,
seek nerve
to mylo-
hyoid.

Clean then the submaxillary gland close to the base of the jaw; and on partly displacing it from the surface of the mylo-hyoid muscle, the student will expose the small branch of nerve to that muscle with the submental artery.

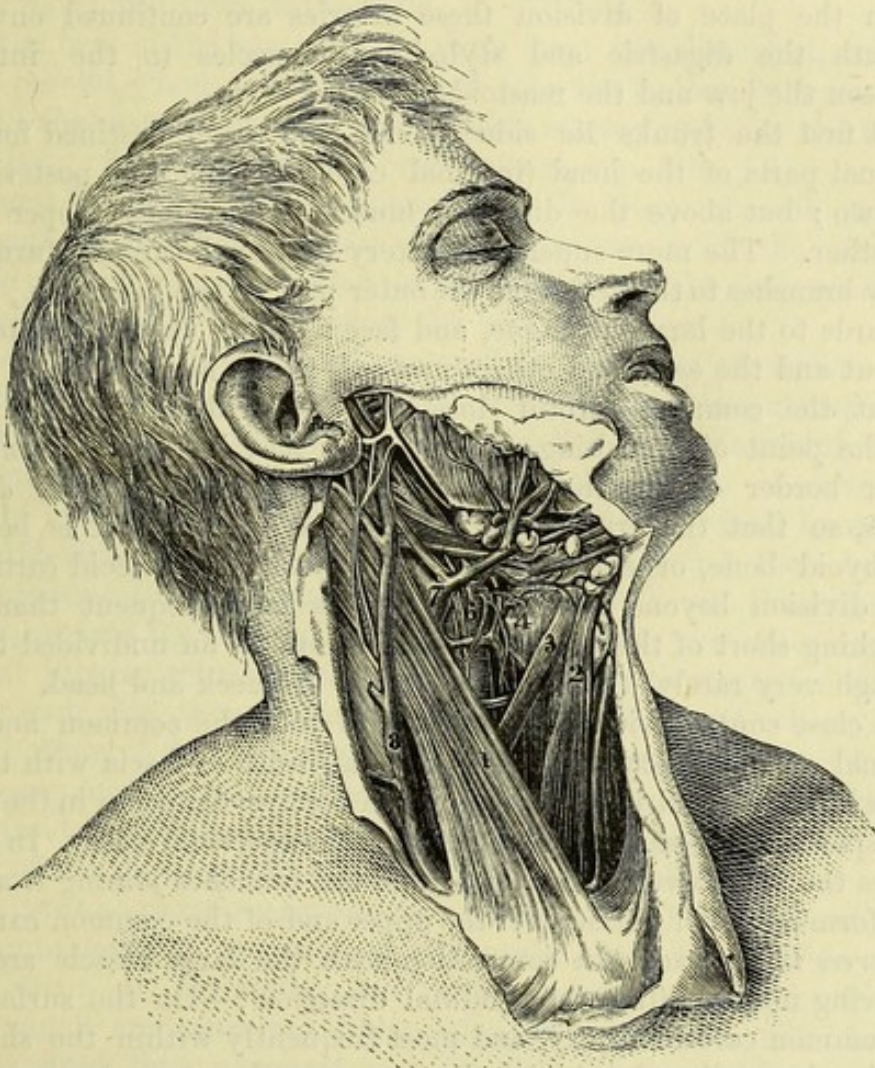
The interval between the jaw and the mastoid process has been already cleaned by the removal of the parotid gland in the dissection of the facial nerve.

Boundaries.

Limits of the space. Behind, is the sterno-mastoid muscle (¹); and in front, the boundary is formed by a line from the chin to the sternum, along the middle of the neck. Above, at the base of the space, are the lower jaw, the skull, and the ear; and below, at the apex, is the sternum. Over this space are placed the skin, the superficial fascia with the platysma, the deep fascia, and the ramifications of the facial and superficial cervical nerves, together with the anterior jugular vein.

Muscles in the space. In the area of the triangular interval, as it is above defined, are seen the larynx and pharynx in part, and many muscles converging towards the hyoid bone, some being above and some below it. Below are the depressors of that bone, viz., omo-hyoid, sterno-hyoid, and sterno-thyroid, (² to ⁴); and above are the elevator muscles, viz., mylo-hyoid, digastric, and stylo-hyoid.

Fig. 15.*



Connected with the back of the hyoid bone and the larynx are some of the constrictor muscles of the pharynx.

Vessels in the triangular space. The carotid blood vessels (⁶ and ⁷) occupy the hinder and deeper part of the space along the side of the sterno-mastoid muscle; and their course would be marked on the surface by a line from the sterno-clavicular articulation to a point midway between the angle of the jaw and the mastoid process. As high as the level of the cricoid cartilage they are buried beneath

* Anterior triangular space of the neck (Quain's "Arteries"). 1. Sterno-mastoid. 2. Sterno-hyoid. 3. Anterior belly of omo-hyoid. 4. Thyro-hyoid. 6. Common carotid artery dividing. 7. Internal jugular vein. 8. External jugular vein.—In the original drawing the sterno-mastoid is partly cut through.

the depressor muscles of the hyoid bone ; but beyond that spot they are covered by the superficial layers over the space, and by the sterno-mastoid muscle which, before it is displaced, conceals the vessels as far as the parotid gland.

Bifurcation. For a short distance after its exit from beneath the depressor muscles of the hyoid bone, the common carotid artery remains a single trunk ; but opposite the upper border of the thyroid cartilage it divides into two large vessels, external and internal carotid. From the place of division these arteries are continued onwards beneath the digastric and stylo-hyoid muscles to the interval between the jaw and the mastoid process.

Position of two trunks to one another. At first the trunks lie side by side, the vessel destined for the internal parts of the head (internal carotid) being the posterior of the two ; but above the digastric muscle it becomes deeper than the other. The more superficial artery (external carotid) furnishes

Branches. many branches to the neck and the outer part of the head, viz., some forwards to the larynx, tongue, and face ; others backwards to the occiput and the ear ; and others upwards to the head.

Changes in the place of division of carotid. But the common carotid does not always divide as here said. For the point of branching of the vessel may be moved from the upper border of the thyroid cartilage, either upwards or downwards, so that the trunk may remain undivided till it is beyond the hyoid bone, or end in branches opposite the cricoid cartilage. The division beyond the usual place is more frequent than the branching short of that spot. It may ascend as an undivided trunk (though very rarely) furnishing offsets to the neck and head.

Jugular vein ; In close contact with the outer side of both the common and the internal carotid artery, and encased in a sheath of fascia with them, is the large internal jugular vein, which receives branches in the neck corresponding to some of the branches of the superficial artery. In some bodies the vein covers the artery ; and the branches joining it above may form a kind of plexus over the upper end of the common carotid.

position varies.

Nerves with the arteries,

lying along

and crossing them.

Nerves in the space. In connection with the large vessels are the following nerves with a longitudinal direction :—On the surface of the common carotid artery, and most frequently within the sheath, lies the descending branch of the hypoglossal nerve ; between the artery and jugular vein is the pneumo-gastric nerve ; and behind the sheath is the sympathetic nerve. Along the outer side of the vessels the spinal accessory nerve extends for a short distance, until it pierces the sterno-mastoid muscle.

Several nerves are placed across the vessels :—thus, directed transversely over the two carotids, so as to form an arch below the digastric muscle, is the hypoglossal nerve giving off its descending branch (*descendens noni*). Appearing on the inner side of the carotid arteries, close to the base of the space, is the glosso-pharyngeal nerve, which courses forwards between them. To the inner side of the internal carotid artery, opposite the hyoid bone, the superior laryngeal nerve comes into sight ; while a little lower down, with the descending branches of the thyroid artery, is the external laryngeal branch of that nerve.

Glands in the space. Two large glandular bodies, the sub-maxillary (fig. 16, ¹¹) and thyroid (¹²), have their seat in this triangular space of the neck. The submaxillary gland is placed altogether in front of the vessels, and is partly concealed by the jaw: beneath it, on the surface of the mylo-hyoid, is the small nerve to that muscle, with the submental artery. By the side of the thyroid cartilage, between it and the common carotid artery, lies the thyroid body beneath the sterno-thyroid muscle: in the female this body is more largely developed than in the male.

Glands;
submaxillary,

and thyroid
body.

At the base of the space, if the parts were not disturbed, would be the parotid gland, which is wedged into the hollow between the jaw and the mastoid process, and projects somewhat below the level of the jaw. Its relations have been noticed at p. 28.

Parotid
gland.

Several lymphatic glands, belonging to the deep cervical group, lie along the internal jugular vein, under cover of the sterno-mastoid muscle; and another set of smaller glands (*submaxillary lymphatic glands*) is placed below the base of the jaw.

Lymphatic
glands.

Directions. The student has to proceed next with the examination of the individual parts that have been referred to in the triangular spaces.

ANTERIOR JUGULAR VEIN. This vein lies near the middle line of the neck, and its size is dependent upon the degree of development of the external jugular. Beginning in some small branches below the chin, the vein descends to the sternum, and then bends outwards beneath the sterno-mastoid muscle, to open into the external jugular, or into the subclavian vein. In the neck the anterior and external jugular veins communicate. There are two anterior veins, one for each side, though one is usually larger than the other; and at the bottom of the neck they are joined by a transverse branch.

Anterior
jugular vein

joins external
jugular
vein.

In many subjects the lower part of the anterior jugular vein is joined by a considerable branch which runs downwards, along the anterior border of the sterno-mastoid muscle, from the facial vein.

The **STERNO-CLEIDO-MASTOID MUSCLE** (fig. 15, ¹) forms the superficial prominence of the side of the neck. It is narrower in the centre than at the ends, and *arises* below by two heads of origin which are separated by an elongated interval. The inner head is fixed by a narrow tendon to the anterior surface of the first piece of the sternum; and the outer head has a wide fleshy attachment to the sternal third of the clavicle. From this origin the heads are directed upwards, the internal passing backwards, and the external almost vertically, and join about the middle of the neck in a flattened belly. Near the skull the muscle ends in a broad tendon, which is *inserted* into the mastoid process at the outer aspect from tip to base, and by a thin aponeurosis into a rough surface behind that process, and into the outer part of the upper curved line of the occipital bone.

Sterno-mas-
toid muscle

has its
origin at
sternum
and clavicle,

and inser-
tion at skull.

The muscle divides the lateral surface of the neck into two triangular spaces. On its cutaneous aspect the sterno-mastoid is covered by the integuments, the platysma and the deep fascia, and is crossed by the external jugular vein, and by the great auricular and superficial cervical nerves. If the muscle be cut through

Position to
other parts.

below and raised, it will be seen to lie on the following parts:—The clavicular origin is superficial to the anterior scalenus and omo-hyoid muscles; and the sternal head conceals the depressors of the hyoid bone, and the common carotid artery with its vein and nerves. After the union of the heads, the muscle is placed over the cervical plexus, the middle scalenus, and the elevator of the angle of the scapula; and near the skull on the digastric and splenius muscles, the occipital artery, and part of the parotid gland. The spinal accessory nerve perforates the muscular fibres about the junction of the upper and middle thirds.

Use. *Action.* Both muscles acting bend the cervical part of the spine, carrying the head forwards; but one muscle will turn the face to the opposite side. In conjunction with other muscles attached to the mastoid process, one sterno-mastoid will incline the head towards the shoulder of the same side.

In laborious respiration the two muscles will assist in elevating the sternum.

Omo-hyoid muscle begins at the scapula, and ends at hyoid bone. The OMO-HYOID MUSCLE crosses beneath the sterno-mastoid, and consists of two fleshy bellies united by a small intermediate tendon (fig. 14, ³). The *origin* of the muscle from the scapula, and the relations of the posterior belly are to be studied in the dissection of the back. From the intervening tendon the anterior fleshy belly (fig. 15, ³) is directed upwards along the outer border of the sterno-hyoid muscle, and is *inserted* into the lower border of the body of the hyoid bone, close to the great cornu.

Relations. The anterior belly is in contact with the fascia, after escaping from beneath the sterno-mastoid, and rests on the sterno-thyroid and thyro-hyoid. This part of the muscle crosses the carotid vessels on a level with the cricoid cartilage.

Use. *Action.* The omo-hyoid muscle depresses and tends to draw backwards the hyoid bone.

Sterno-hyoid muscle. The STERNO-HYOID MUSCLE (fig. 15, ²) is a flat thin band nearer the middle line than the preceding. It *arises* from the inner end of the clavicle at its posterior aspect, from the back of the manubrium and the cartilage of the first rib. From this origin it ascends to be *inserted* into the lower border of the body of the hyoid bone, internal to the preceding muscle. Its fibres are often interrupted near the clavicle by a tendinous intersection.

Relations. One surface is covered by the sterno-mastoid and the fascia. When the muscle is divided and turned aside, the deep surface will be found to touch the sterno-thyroid, the thyro-hyoid, and the thyroid cartilage. The right and left muscles are separated by an interval which is wider below.

Use. *Action.* It draws the hyoid bone downwards after swallowing; and in laborious respiration it will aid in raising the sternum.

Sterno-thyroid muscle. The STERNO-THYROID MUSCLE is broader and shorter than the sterno-hyoid, beneath which it lies. It *arises* from the posterior surface of the sternum and cartilage of the first rib below the sterno-hyoid, and is *inserted* into the oblique line on the side of the thyroid cartilage, where it meets the thyro-hyoid muscle.

The inner border touches its fellow below, while the outer reaches over the carotid artery. The superficial surface is for the most part covered by the preceding hyoid muscles; and the opposite surface is in contact with the lower part of the common carotid artery, the trachea, the larynx, and the thyroid body. A transverse tendinous line frequently crosses the muscle near the sternum. Relations.

Action. Its chief use is to draw downwards the larynx after deglutition, but in conjunction with the following muscle it can also act on the hyoid bone. Use.

Like the sterno-hyoid it participates in the movement of the chest in laborious breathing.

The THYRO-HYOID MUSCLE (fig. 15, 4) forms a continuation of the sterno-thyroid. *Arising* from the oblique line of the thyroid cartilage, the fibres ascend to the anterior half of the great cornu, and to the outer part of the body of the hyoid bone. Thyro-hyoid muscle.

On the muscle lie the omo-hyoid and the sterno-hyoid; and beneath it are the superior laryngeal nerve and vessels.

Action. It draws up the larynx towards the hyoid bone, as in swallowing. The sterno-thyroid and thyro-hyoid together fix the thyroid cartilage for the action of the intrinsic muscles of the larynx. Use.

Directions. The remaining parts included in this section are the scaleni muscles and the subclavian blood-vessels, with the cervical nerves and the carotid blood-vessels. The student may examine them in the order here given.

Dissection (fig. 16). Supposing the sterno-mastoid cut, the fat and fascia are to be taken away from the lower part of the neck, so as to prepare the scaleni muscles with the subclavian vessels and their branches. By means of a little dissection the anterior scalenus muscle will be seen ascending from the first rib to the lower cervical vertebræ, having the phrenic nerve and subclavian vein in front of it, the latter crossing it near the rib. Dissection

The part of the subclavian artery on the inner side of the scalenus is then to be cleaned, care being taken not only of its branches, but of the branches of the sympathetic nerve which course over and along it from the neck to the chest. This dissection will be facilitated by the removal of the remaining part of the clavicle. of the subclavian artery

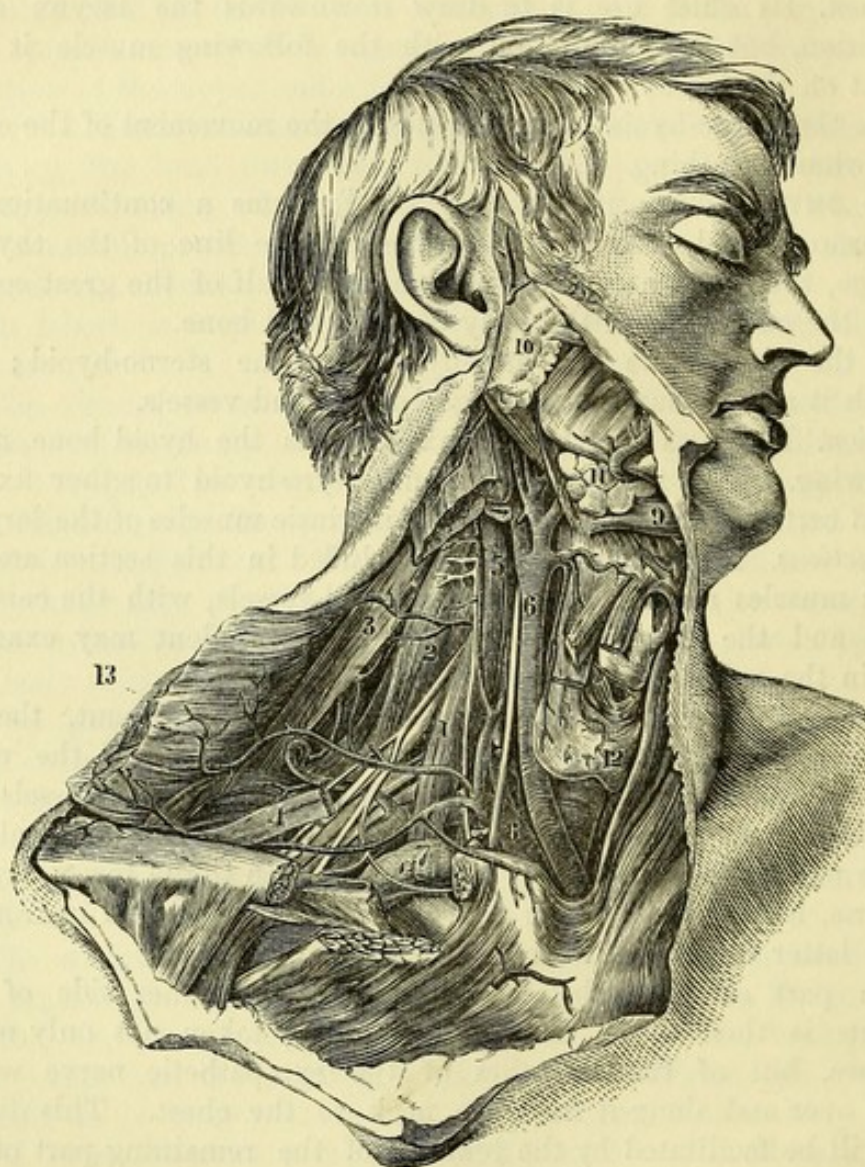
All the branches of the artery are in general easily found, except the superior intercostal, which is to be sought in the thorax in front of the neck of the first rib. On the branch (inferior thyroid) ascending to the thyroid body, or near it, is the middle cervical ganglion of the sympathetic; and the dissector should follow downwards from it a small cardiac nerve to the thorax. Only the origin and first part of the arterial branches can be now seen; their termination is met with in other stages of this dissection, or in the dissection of other parts of the body. and its branches;

Next the student should seek the small right lymphatic duct that opens into the subclavian vein at its junction with the internal jugular. A notice of it will be given with the lymphatics of the thorax. of right lymphatic duct;

of brachial
plexus ;

The outer part of the subclavian artery having been already prepared, let the dissector remove more completely the fibrous tissue from the nerves of the brachial plexus. From the plexus trace the small branch to the subclavius muscle, and the branches to the rhomboid and serratus muscles, which pierce the middle scalenus.

Fig. 16.*



If it is thought necessary, the anterior scalenus may be cut through after the artery has been studied.

of cervical
plexus.

Clean the cervical plexus, and seek its muscular branches, the small twigs to join the descendens noni, and the roots of the phrenic nerve. Lastly, let the middle scalenus muscle be defined, as it lies beneath the cervical nerves.

* A view of the common carotid and subclavian arteries (Quain's "Arteries").
1. Anterior scalenus, with the phrenic nerve on it. 2. Middle scalenus.
3. Levator anguli scapulae. 4. Omo-hyoid. 5. Rectus capitis anticus major.
6. Common carotid artery. 7. Subclavian vein. 8. Subclavian artery.
9. Digastric muscle. 10. Parotid gland. 11. Submaxillary gland. 12.
Thyroid body. 13. Trapezius muscle, reflected.

The SCALENI MUSCLES are usually described as three in number, and are named from their relative position, anterior, middle, and posterior; they extend from the transverse processes of the cervical vertebræ to the first and second ribs.

Number of
scaleni
muscles.

The SCALENUS ANTICUS (fig. 16, ¹) is somewhat conical in shape, and *arises* from the anterior tubercles of the transverse processes of the third, fourth, fifth, and sixth cervical vertebræ. It is *inserted* into the upper surface and inner border of the first rib, surrounding the rough mark or projection on this part of the bone known as the scalene tubercle.

Scalenus
anticus.
Origin;
insertion.

More deeply seated below than above, the muscle is concealed by the clavicle and the clavicular part of the sterno-mastoid: the phrenic nerve lies along its anterior surface, and the subclavian vein crosses over it near the rib. Along the inner border is the internal jugular vein. Beneath it are the pleura, the subclavian artery, and the nerves of the brachial plexus. The attachment to the vertebræ corresponds with the origin of the rectus capitis anticus major muscle.

Relations,
with vessels,
and nerves.

Action. The anterior muscle raises strongly the first rib, in consequence of its forward attachment. If the rib is fixed, it bends forwards the lower part of the neck.

Use.

The SCALENUS MEDIUS MUSCLE (fig. 16, ²) is larger than the anterior, and extends highest of all on the vertebræ. Its *origin* is from the posterior tubercles of the transverse processes of all the cervical vertebræ (fig. 45, D); and it is *inserted* into an impression on the upper surface of the first rib, extending from the tuberosity behind to the groove for the subclavian artery in front.

Scalenus
medius.
Origin;
insertion.

In contact with the anterior surface are the subclavian artery and the cervical nerves, together with the sterno-mastoid muscle; the posterior surface touches the posterior scalenus, and the deep lateral muscles of the back of the neck. The fibres are perforated by the nerves of the rhomboid and serratus muscles.

Parts in
contact
with it.

Action. Usually it elevates the first rib. With the rib fixed, the cervical part of the spine can be inclined laterally by one muscle.

Use.

The SCALENUS POSTICUS (fig. 45, F) is inconsiderable in size, and appears to be part of the preceding muscle. *Arising* from two or three of the lower cervical transverse processes, it is *inserted* below, by a thin tendon about half an inch wide, into the second rib in front of the serratus posticus superior.

Scalenus
posticus.
Attach-
ments.

Action. It acts as an elevator of the second rib; and its fibres having the same direction as those of the medius, it will help to incline the neck in the same way.

Use.

The SUBCLAVIAN ARTERY (fig. 16) is the first portion of the large trunk supplying the upper limb with blood, and is thus designated from its position beneath the clavicle. On the right side, this vessel (⁸) is derived from the bifurcation of the innominate artery behind the sterno-clavicular articulation, and the part of it named subclavian extends as far as the outer border of the first rib. To reach the limb the artery crosses the lower part of the neck, taking an arched course over the top of the lung and the first rib,

Subclavian
artery
extends to
upper limb,

is divided
into three
parts.

and between the scaleni muscles. For the purpose of describing its numerous connections the vessel is divided into three parts; the first extending from the sterno-clavicular articulation to the inner border of the anterior scalenus; the second, beneath the scalenus; and the third, from the outer border of that muscle to the outer edge of the first rib.

First part,
internal to
scalenus,
is deep.

First part. Internal to the anterior scalenus the artery lies deeply in the neck, and ascends somewhat from its origin. Between the vessel and the surface will be found the common tegumentary coverings with the platysma and the deep fascia; the sterno-mastoid, sterno-hyoid, and sterno-thyroid muscles; and a strong deep process of fascia from the inner border of the scalenus muscle.

In front,
behind, and
below it.

Behind and below, it rests against the pleura, which ascends into the arch formed by the vessel; and the apex of the lung separates the artery from the vertebræ and the first and second ribs.

Veins with
the artery.

Veins. The innominate vein lies below and rather in front of this part of the artery. The internal jugular vein crosses the arterial trunk close to the scalenus; and underneath this vein, with the same direction, lies the vertebral vein. Much more superficial, and separated from the artery by muscles, is the deep part of the anterior jugular vein.

Position of
nerves.

Nerves. In front of the artery lies the pneumo-gastric nerve, near to the internal jugular vein; and inside this, the lower cardiac branch of the same nerve trunk. Beneath the subclavian artery winds the recurrent branch of the pneumo-gastric; and one or two branches of the sympathetic nerve form loops around the vessel.

Second part
beneath
scalenus.

Second part. Beneath the scalenus the vessel is not so deep as in the first part of its course, and at this spot it rises highest above the clavicle. It is covered by the integuments, platysma, and deep fascia; then by the clavicular origin of the sterno-mastoid; and lastly by the anterior scalenus. Behind and below the artery are the pleura and lung.

In front,
behind, and
below.

Position of
vein;

Veins. Below the level of the artery, and separated from it by the anterior scalenus muscle, lies the arch of the subclavian vein.

of nerves to
the artery.

Nerves. In front of the scalenus descends the phrenic nerve. Above the vessel, in the interval between the scaleni, are placed the large cervical nerves; and the trunk formed by the last cervical and first dorsal nerves is behind the artery.

Third part

Third part. Beyond the scalenus the artery traverses the clavicular part of the posterior triangular space (fig. 14), and is nearer the surface than in the rest of its course: this part of the vessel is enclosed in a sheath of the deep cervical fascia, which it receives as it passes from between the scaleni. It is comparatively superficial while in the space before mentioned, for it is covered only by the integuments, the platysma, and deep fascia; but near its termination the vessel gets under cover of the clavicle and subclavius muscle, and the suprascapular vessels cross in front of it. In this part of its course the artery rests on the surface of the first rib, which is interposed between it and the pleura; and the insertion of the scalenus medius is behind it.

is super-
ficial.

Parts cover-
ing it;

and beneath.

Veins. The subclavian vein approaches the artery, not being separated by muscle, but lies commonly at a lower level. The external jugular vein crosses it near the scalenus muscle; and the suprascapular and transverse cervical branches, which enter the jugular, sometimes form a plexus over this part of the artery.

Position of
veins;

Nerves. The large nerves of the brachial plexus are mostly above the artery, but the lowest trunk is still behind and close to the vessel; and the small nerve to the subclavius crosses it about the middle. Superficial to the cervical fascia lie the descending cutaneous branches of the cervical plexus.

of nerves to
artery.

Peculiarities. The artery may spring as a separate trunk from the arch of the aorta, in which case it takes a deeper course than usual to reach the interval between the scaleni muscles.

Peculiarities
of origin,

The level of the arch formed by the subclavian artery in the neck varies in different subjects (see p. 56); and occasionally the vessel pierces, or even passes in front of the scalenus anticus muscle.

level and
course.

Branches. The chief branches of the subclavian artery are four in number. Three of these arise from the first part of the arterial trunk:—one (vertebral) ascends to the head; another (internal mammary) descends to the chest; and the remaining one (thyroid axis) is a short thick trunk, which furnishes branches inwards and outwards to the thyroid body and the shoulder. These arise commonly near the scalenus muscle, so as to leave an interval at the beginning of the trunk free from offsets. This interval varies in length from half an inch to an inch in the greater number of cases; and its extremes range from less than a quarter of an inch to an inch and three quarters. In some instances the branches are scattered over the first part of the artery.*

Branches of
subclavian.

From first,

The fourth branch (superior intercostal) arises beneath the anterior scalenus from the second part of the artery, and gives off the deep cervical branch: a small spinal artery frequently comes from this part of the trunk.

second,

If there is a branch present on the third part of the artery, it is commonly the posterior scapular: if more than one, the internal mammary, the suprascapular, or the thyroid axis may be added.

and third
part.

The *vertebral artery* is generally the first and largest branch of the subclavian, and arises from the upper and posterior part of the trunk. Ascending between the contiguous borders of the scalenus anticus and longus colli muscles, this branch enters the foramen in the transverse process of the sixth cervical vertebra, and is continued upwards to the skull through the foramina in the other cervical vertebræ. Before the artery enters its aperture it lies behind the internal jugular vein, and is crossed by the inferior thyroid artery; it is accompanied by branches of the sympathetic nerve, and supplies small muscular offsets. Its farther course and distribution will be given afterwards.

Vertebral
artery in the
neck.

Small
branches.

* The student is referred for fuller information respecting the peculiarities of the vessels, and the practical applications to be deduced from them, to the original and valuable work on the *Anatomy of the Arteries of the Human Body* by Richard Quain, F.R.S.

Vertebral
vein, and
branches.

The *vertebral vein* issues with its accompanying artery, to which it is here superficial, and descends over the subclavian artery to join the innominate vein; it receives the *deep cervical vein*, and the branch (*anterior vertebral vein*) that accompanies the ascending cervical artery.

Internal
mammary
artery in
the neck.

The *internal mammary branch* leaves the lower part of the subclavian artery, and coursing downwards beneath the clavicle, and on the outer side of the innominate vein, enters the thorax between the cartilage of the first rib and the pleura. As the artery disappears in the chest, it is crossed superficially by the phrenic nerve. The vessel is distributed to the walls of the chest and abdomen; and its anatomy will be learnt with the dissection of those parts.

Thyroid axis

Thyroid axis. This is a short thick trunk (fig. 16) which arises from the front of the subclavian artery near the anterior scalenus muscle, and soon divides into three branches—one to the thyroid body, and two to the back of the shoulder.

divides into
three.

Supra-
scapular
artery:

The *suprascapular branch* courses outwards across the lower part of the neck, behind the clavicle and subclavius muscle, to the superior border of the scapula, and entering the supraspinous fossa is distributed on the dorsum of that bone. The connections of this artery are more fully seen in the dissection of the back.

Transverse
cervical
artery.

The *transverse cervical branch*, usually larger than the preceding, takes a similar direction, though higher in the neck, and ends beneath the border of the trapezius muscle in the superficial cervical and posterior scapular arteries. (See the dissection of the back.) In its course outwards through the posterior triangular space, this branch crosses in front of the anterior scalenus, the phrenic nerve, and the brachial plexus, but usually behind the omo-hyoid. Some small offsets are supplied by it to the parts in the posterior triangle.

offsets:

size and
ending vary.

In many bodies the transverse branch arising from the thyroid axis is of small size, and ends as the superficial cervical artery, while the posterior scapular branch arises separately from the third, or even the second part of the subclavian trunk (fig. 16).

Inferior
thyroid
artery

The *inferior thyroid branch* is the largest offset of the thyroid axis. Directed inwards with a flexuous course to the thyroid body, this branch passes beneath the common carotid artery and the accompanying vein and nerves, and in front of the longus colli muscle and the recurrent nerve. Behind the lower part of the thyroid body it divides into branches which ramify in that organ, and communicate with the superior thyroid and its fellow.

gives laryn-
geal offset,

Near the larynx an *inferior laryngeal branch* is directed upwards with the nerve of the same name, and other offsets are furnished to the trachea and the neighbouring muscles.

and ascend-
ing cervical
branch.

The *ascending cervical branch* of the thyroid is directed upwards between the scalenus anticus and rectus capitis anticus major, and ends in branches to those muscles and the posterior triangle of the neck. Some small spinal offsets are conveyed along the spinal nerves to the cord and its membranes.

Veins cor-
responding
to arteries.

The *veins* corresponding with the branches of the thyroid axis have the following destination:—those with the suprascapular and

transverse cervical arteries open into the external jugular vein. But the inferior thyroid vein, beginning in the thyroid body, descends on the front of the trachea to the innominate vein.

The *superior intercostal artery* arises from the posterior part of the subclavian, and arching over the apex of the lung, passes downwards in front of the neck of the first rib: its distribution to the first two intercostal spaces will be seen in the thorax. Superior intercostal branch.

Arising in common with this branch is the *deep cervical artery*, which passes backwards between the transverse process of the last cervical vertebra and the first rib, lying internal to the two hinder scaleni muscles and the fleshy slips continued upwards from the erector spinæ, to end beneath the complexus muscle at the posterior part of the neck. Deep cervical branch.

A *spinal branch* is frequently given from the second part of the artery; its offsets are continued into the spinal canal through the intervertebral foramina. Spinal branch.

The SUBCLAVIAN VEIN is much shorter than the companion artery, reaching only from the outer edge of the first rib to the inner border of the anterior scalenus. It is a continuation of the axillary vein, and ends by joining the internal jugular in the innominate trunk. Its course is arched below the level of the artery, from which it is separated by the scalenus anticus. Subclavian vein.

Branches. The subclavian vein is joined at the outer edge of the anterior scalenus by the external jugular vein, and sometimes also by the anterior jugular. Into the angle of union of the subclavian and internal jugular veins the right lymphatic duct opens (fig. 28, ⁹); and at the like spot on the left side, the large lymphatic or thoracic duct ends (fig. 28, ⁸). The highest pair of valves in the subclavian trunk is placed outside the opening of the external jugular vein.* Its branches; opening of lymphatic ducts. Valves.

It should be borne in mind that occasionally the vein is as high in the neck as the third part of its companion artery; and that it has been seen in a few instances with the artery beneath the anterior scalenus. Position may vary.

The ANTERIOR PRIMARY BRANCHES OF THE CERVICAL NERVES spring from the common trunks in the intervertebral foramina, and appear on the side of the neck between the intertransverse muscles. These nerves are eight in number, and are equally divided between the cervical and brachial plexuses; the upper four being combined in the former, and the remaining nerves in the latter plexus. Close to their origin they are joined by offsets of communication from the sympathetic cord. Cervical nerves. Position and number.

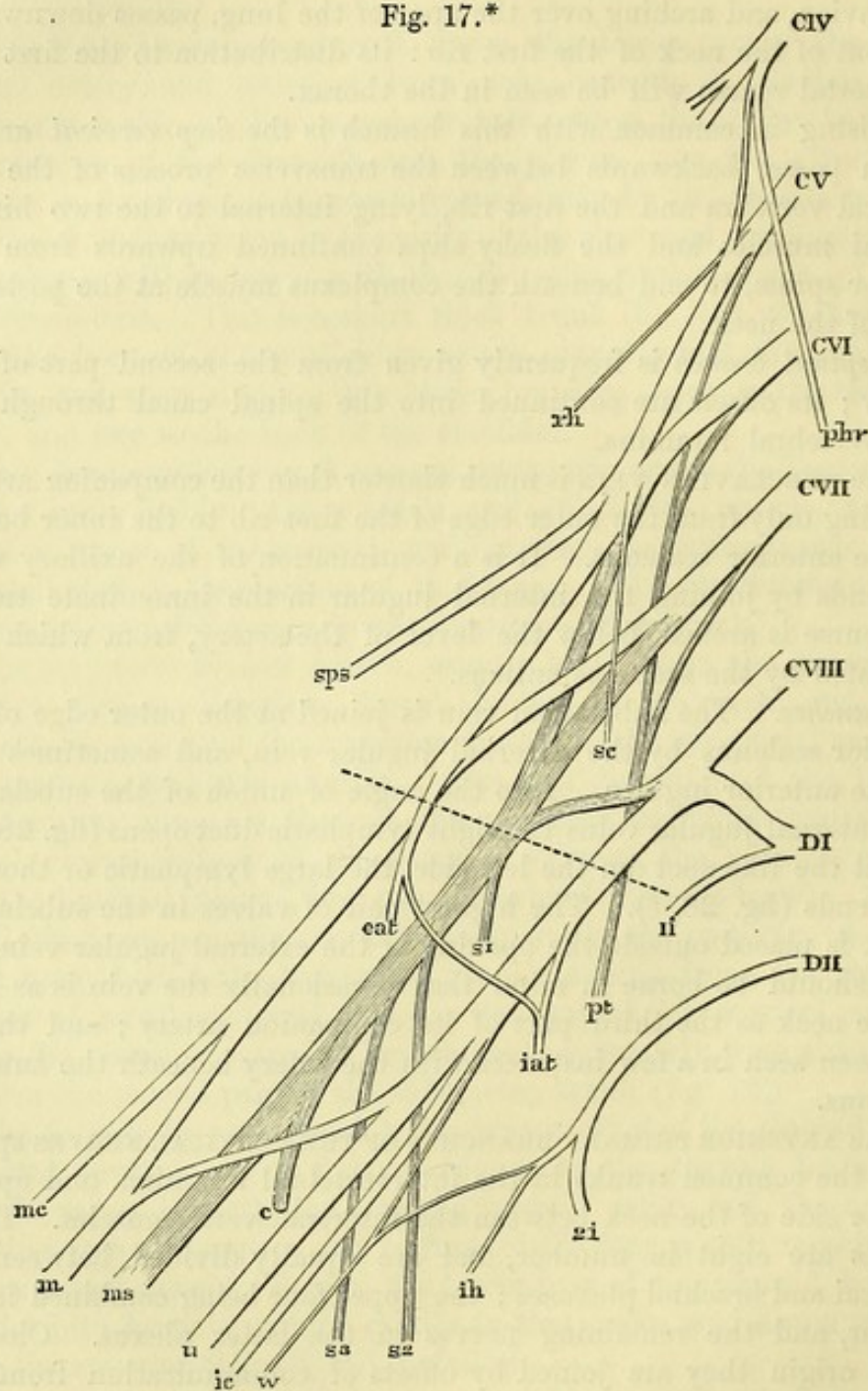
To this general statement some addition is needed for the first two nerves, the peculiarities of which are noticed in SECTION XVIII. First two differ from rest.

BRACHIAL PLEXUS (fig. 17). The lower four cervical nerves and the larger part of the first dorsal are blended in this plexus; and a fasciculus is added to them from the lowest nerve entering the cervical plexus. Thus formed, the plexus reaches from the neck to Brachial plexus, formed by five nerves.

* See a paper on the Valves in the Veins of the Neck in the Edin. Med. Journal of Nov., 1856, by Dr. Struthers.

the axilla, where it ends in nerves for the upper limb. Only the part of it above the clavicle can now be seen. In the neck the nerves lie at first between the scaleni muscles, opposite the four

Fig. 17.*



lower cervical vertebræ, and afterwards in the posterior triangular space. The arrangement of the nerves in the plexus is as follows:—

The fifth and sixth nerves unite near the vertebræ, forming an

Disposition
of nerves in
the plexus.

* Diagram of the brachial plexus. The dotted line indicates the level at which the cords are crossed by the clavicle. CIV. to CVIII. Fourth to eighth cervical nerves. DI, and DII. First and second dorsal nerves. Ii, and 2i. First and second intercostal nerves. phr. Phrenic nerve. rh. Nerve to rhomboids. pt. Posterior thoracic nerve. sc. Branch to subclavius. sps. Suprascapular nerve.

upper trunk; the seventh remains distinct and constitutes a middle trunk; and the eight cervical and first dorsal join beneath the anterior scalenus in a lower trunk. Near the outer border of the middle scalenus these three trunks bifurcate, each giving off an anterior and a posterior division. As they pass beneath the clavicle the anterior divisions of the upper and middle trunks join to form the *outer cord* of the plexus; the posterior divisions of the three trunks by their union give rise to the *posterior cord*; while the large anterior division of the lower trunk is continued as the *inner cord*. The three cords accompany the subclavian artery, lying to its acromial side, and are continued to the axilla where the nerves of the limb arise.

Branches. The branches of the plexus may be classed into those above the clavicle, and those below that bone. Those of the upper set end mostly in muscles of the lower part of the neck and of the scapula; while the lower set consists of the branches to the upper limb, with which they will be described.

BRANCHES ABOVE THE CLAVICLE. *Branches for the scaleni and longus colli muscles.* These small twigs arise from the nerves close to the intervertebral foramina, and are seen when the anterior scalenus is divided.

The *branch for the rhomboid muscles* springs from the fifth nerve, and perforates the fibres of the scalenus medius; it is directed backwards beneath the levator anguli scapulæ to its destination. Branches are given usually from this nerve to the levator anguli scapulæ.

The *nerve of the serratus* (posterior thoracic nerve) arises from the fifth, sixth, and generally also the seventh, nerves near the intervertebral foramina. Piercing the fibres of the scalenus lower than the preceding branch, the nerve is continued downwards behind the brachial plexus, and enters the serratus magnus muscle on its axillary surface.

The *branch for the subclavius muscle* is a slender twig, which arises from the trunk formed by the fifth and sixth nerves, and is directed downwards over the subclavian artery to the deep surface of the muscle; it is often united with the phrenic nerve at the lower part of the neck.

The *suprascapular nerve* is the largest of these branches, and arises from the trunk of the plexus formed by the fifth and sixth nerves. It is destined for the muscles on the dorsum of the scapula, and it will be dissected with the arm.

Occasionally an offset from the fifth cervical trunk joins the phrenic nerve on the anterior scalenus muscle.

The **CERVICAL PLEXUS**, formed by the upper four cervical nerves, lies beneath the upper half of the sterno-mastoid muscle, and on the middle scalenus and the levator anguli scapulæ. Each nerve entering the plexus, except the first, divides into an ascending and a descending branch, and these unite with corresponding parts of the adjacent nerves, so as to give rise to a series of arches. From these arches or loops the different branches arise:—

Its offsets
are super-
ficial ;

and deep,
which are:—

Phrenic
nerve.

Nerves to
join descen-
dens noni.

Branches
to recti.

Branches
to other
nerves.

Branches to
muscles.

Branches
joining
spinal ac-
cessory.

Common
carotid
artery.

Origin.

Course.

The *branches* are superficial and deep. Those of the superficial set are again subdivided into ascending and descending, and have been described with the posterior triangular space of the neck (p. 56). The ascending branches may be now seen to spring from the union of the second and third nerves; and the descending, to take origin from the loop between the third and fourth nerves. The deep set of branches remains to be examined: they are muscular and communicating, and may be arranged in an internal and an external series.

INTERNAL SERIES. The *phrenic* or muscular nerve of the diaphragm (fig. 16) is derived from the fourth, or third and fourth nerves of the plexus; and it may be joined by a fasciculus from the fifth cervical nerve. Descending obliquely on the surface of the anterior scalenus from the outer to the inner edge, it enters the chest in front of the internal mammary artery, but behind the subclavian vein, and traverses that cavity to reach the diaphragm. At the lower part of the neck the phrenic nerve is joined by a filament of the sympathetic, and sometimes by an offset of the nerve to the subclavius muscle.

On the left side the nerve crosses over the first part of the subclavian artery.

The *branches communicating with the descendens noni* are two in number. One arises from the second, and the other from the third cervical nerve; they are directed inwards over or under the internal jugular vein to join the descending muscular branch (*descendens noni*) of the hypoglossal nerve in front of the common carotid artery.

Muscular branches are furnished to the anterior recti muscles; they arise from the loop between the first two nerves, and from the trunks of the other nerves close to the intervertebral foramina.

Some *connecting branches* pass from the loop between the first two nerves to the vagus, hypoglossal and sympathetic nerves near the skull: these will be afterwards seen.

EXTERNAL SERIES. *Muscular branches* are supplied from the second nerve to the sterno-mastoid; from the third and fourth nerves to the levator anguli scapulæ and middle scalenus; and from the loop between the same nerves to the trapezius.

Connecting branches with the spinal accessory nerve exist in three places. First, in the sterno-mastoid muscle; next, in the posterior triangular space; and lastly, beneath the trapezius. The union with the branches distributed to the trapezius has the appearance of a plexus.

The **COMMON CAROTID ARTERY** is the chief vessel for the supply of blood to the neck and head (fig. 16, 6). The origin of the vessel differs on the two sides, being at the lower part of the neck on the right side, and in the thorax on the left side.

The right vessel commences opposite the sterno-clavicular articulation at the bifurcation of the innominate artery, and ends at the upper border of the thyroid cartilage by dividing into external and internal carotids. The course of the artery is along the side of the

trachea and larynx, gradually diverging from the vessel on the opposite side in consequence of the increasing size of the larynx; and its position will be marked by a line from the sterno-clavicular articulation to a point midway between the angle of the jaw and the mastoid process. Situation.

Contained in a sheath of cervical fascia with the internal jugular vein and the pneumo-gastric nerve, the carotid artery has the following connections with the surrounding parts:—As high as the cricoid cartilage the vessel is deeply placed, and is concealed by the common coverings of the skin, platysma, and fasciæ; and by the muscles at the lower part of the neck, viz., sterno-mastoid (sternal origin), sterno-hyoid, omo-hyoid, and sterno-thyroid. But from the cricoid cartilage to its termination the artery is more superficial, being covered only by the sterno-mastoid with the common investments of the neck. The vessel rests mostly on the longus colli and scalenus anticus muscles, but close to its ending on the rectus capitis anticus major. To the inner side of the carotid lie the trachea and larynx, the œsophagus and pharynx, and the thyroid body, the last overlapping the vessel by the side of the larynx. Along the outer side of the carotid sheath is a chain of lymphatic glands. Parts covering it,
beneath it,
and on its sides.

Veins. The large internal jugular vein lies on the outer side of the artery, being closely applied to it in the upper part of its course, but separated from it below by an interval about half an inch wide: on the left side the vein is nearer to the artery below, as will be afterwards seen. One or two superior thyroid veins cross the upper end of the arterial trunk; and opposite the thyroid body another small vein (middle thyroid) is directed backwards over the vessel. Near the clavicle the anterior jugular vein passes outwards in front of the artery, but is separated from it by the sterno-hyoid and sterno-thyroid muscles. Position of veins,

Arteries. Offsets of the superior thyroid artery descend over the upper part of the sheath; and the inferior thyroid crosses behind it near the lower border of the cricoid cartilage. of arteries,

Nerves. The descendens noni lies in front of the artery, crossing from the outer to the inner side, and is joined there by the communicating branches from the cervical plexus. The pneumo-gastric lies within the sheath, behind and between the artery and the vein. The sympathetic cord and branches rest on the spine behind the sheath. All the nerves above mentioned have a longitudinal direction; but the inferior laryngeal or recurrent crosses obliquely inwards beneath the sheath, towards the lower end of the artery. of nerves to carotid.

Branches of carotid. As a rule, the common carotid artery does not furnish any collateral branch, though it is very common for the superior thyroid to spring from its upper end. At the terminal bifurcation into the two carotids the artery is slightly bulged. Branches none.

The INTERNAL JUGULAR VEIN extends upwards to the base of the skull, but only the part of it that accompanies the common carotid artery is now seen. Placed on the outer side of the artery, the vein ends below by uniting with the subclavian to form the innominate trunk. Its proximity to the carotid is not equally close throughout, for at Internal jugular vein

is close to side of artery, except below.

the lower part of the neck there is a space between the two, in which the vagus nerve is seen crossing (on the right side only) the subclavian artery. Sometimes the vein overlaps the artery to a considerable extent.

The lower part of the vein is marked by a dilatation or sinus. Near its ending it becomes contracted, and is provided with a single or double valve.

Branches.

In this part of its course the vein receives the superior and middle thyroid branches.

Differences in origin of artery,

Peculiarities of the carotid. The origin of the artery on the right side may be above or below the point stated. Mention has been made of the difference in the place of bifurcation, and of the fact that the common carotid may not be divided into two (p. 62). As a very rare occurrence, instead of one there may be two trunks issuing from beneath the hyoid muscles.

in division.

Dissection.

Dissection. The dissector may next trace out completely the trunk of the external carotid (fig. 18), and follow its branches until they disappear beneath different parts. Afterwards he may separate from one another the digastric and stylo-hyoid muscles, which cross the carotid, and define their origin and insertion.

Digastric muscle has two bellies,

The DIGASTRIC MUSCLE (fig. 16, ⁹) consists of two fleshy bellies, united by an intervening tendon. The posterior, the larger of the two, *arises* from the digastric fossa on the inner side of the mastoid process; while the anterior belly is fixed to the depression by the side of the symphysis of the lower jaw. From these attachments the fibres are directed to the intervening tendon, which is surrounded by fibres of the stylo-hyoid, and is united by an aponeurotic expansion to its fellow, and to the body and part of the great cornu of the hyoid bone.

which are joined by a tendon.

Position to other parts.

The arch formed by the digastric is superficial, except at the posterior end, where it is beneath the sterno-mastoid and splenius muscles. The posterior belly covers the carotid vessels and the accompanying veins and nerves; and is placed across the anterior triangular space of the neck in the position of a line from the mastoid process to the fore part of the hyoid bone. Along its lower border lie the occipital artery and the hypoglossal nerve, the former passing backwards, the latter forwards. The anterior belly rests on the mylo-hyoid muscle.

The muscle bounds a space containing glands.

The muscle forms the lower boundary of a space between it, the jaw, and the base of the skull, which is subdivided into two by the stylo-maxillary ligament. In the posterior portion are contained the parotid gland (¹⁰), and the vessels and nerves in connection with it (p. 29); in the anterior, are the submaxillary gland (¹¹), with the facial and submental vessels, and deeper still, the muscles between the chin and the hyoid bone.

Use.

Action. The lower jaw being moveable, the muscle depresses that bone and opens the mouth. If the jaw is fixed, the two bellies acting will elevate the hyoid bone.

Stylo-hyoid muscle.

The STYLO-HYOID MUSCLE is thin and slender, and lies immediately above the posterior belly of the digastric. It *arises* from

the posterior surface of the styloid process near the base, and is inserted into the outer part of the body of the hyoid bone.

Insertion.

The muscle has the same relations as the posterior belly of the digastric; and its fleshy fibres are usually perforated by the tendon of that muscle. In some bodies the stylo-hyoid is absent.

Surrounds digastric tendon.

Action. This muscle elevates the hyoid bone in swallowing, and with the posterior belly of the digastric, prevents the bone being carried forwards by the other elevators.

Use.

The HYPOGLOSSAL NERVE (twelfth cranial) appears in the anterior triangle at the lower edge of the digastric muscle, where it hooks round the occipital artery; it is then directed forwards to the tongue beneath the tendon of that muscle, and disappears in front under the mylo-hyoid. In this course the nerve passes over the two carotids; and near the great cornu of the hyoid bone it also crosses the lingual artery. From this part arise the descending branch, and a small muscular offset to the thyro-hyoid.

Twelfth nerve in the anterior triangle.

Branches:

The *descending branch* (ram. descendens noni) leaves the trunk of the hypoglossal as it turns round the occipital artery, and descends on the front of, or more frequently within, the carotid sheath to below the middle of the neck, where it is joined by the communicating branches of the cervical nerves so as to form a single or double loop (*ansa hypoglossi*) with the concavity turned upwards. The descending branch gives an offset to the anterior belly of the omo-hyoid, and from the loop branches proceed to the posterior belly of the omo-hyoid, to the sterno-hyoid and sterno-thyroid muscles: sometimes another offset is continued to the thorax, where it joins the phrenic and cardiac nerves.

one to hyoid muscles

is joined with cervical nerves.

The EXTERNAL CAROTID ARTERY (fig. 18, *d*) springs from the bifurcation of the common carotid at the upper border of the thyroid cartilage, and furnishes branches to the neck, the face, and the outer part of the head.

External carotid artery.

From the place of origin it ascends in front of the mastoid process, and ends opposite the neck of the lower jaw in the internal maxillary and temporal branches. The artery lies at first in front of the internal carotid, but it afterwards inclines somewhat backwards and becomes superficial to that vessel. Its position would be marked with sufficient accuracy by a line from the front of the meatus of the ear to the cricoid cartilage.

Extent.

Course and direction.

At first the external carotid is overlaid by the sterno-mastoid, and by the common coverings of the anterior triangular space, viz., the skin, and the superficial and deep fasciæ with the platysma. But above the level of a line from the mastoid process to the hyoid bone, the artery is crossed by the digastric and stylo-hyoid muscles; and higher still it is concealed by the parotid gland. At its beginning the artery rests against the pharynx; but above the angle of the jaw it is placed over the styloid process and stylo-pharyngeus muscle, which separate it from the internal carotid. In front of the upper part of the vessel are the ramus of the jaw and the stylo-maxillary ligament.

Parts superficial to it,

beneath it,

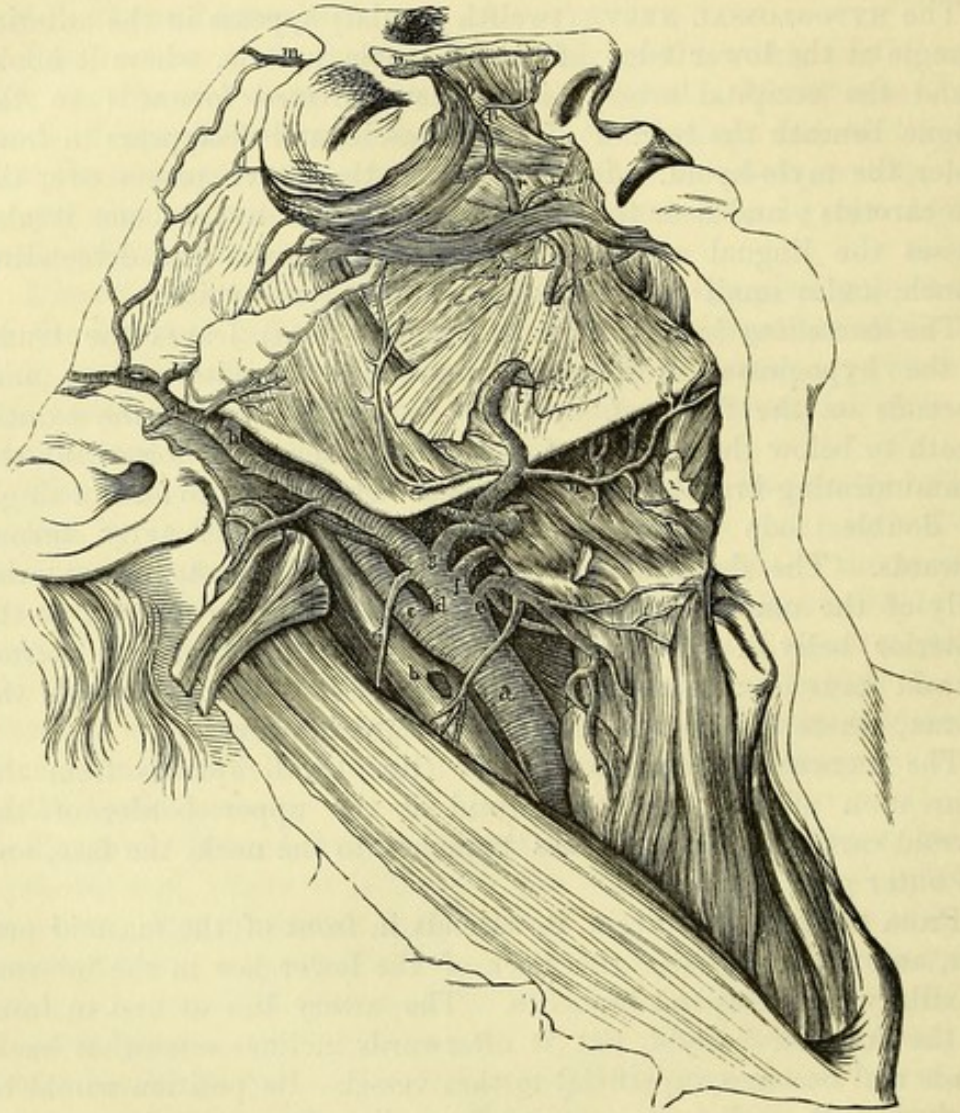
and in front.

Veins. There is not any companion vein with the external carotid, Veins in

contact with the artery ; as with most arteries ; but in the parotid gland the temporo-maxillary vein lies on it, and the anterior division of this trunk frequently runs with the artery beneath the digastric muscle. Near the beginning it is crossed by the facial and lingual branches joining the internal jugular vein.

and nerves. *Nerves* are directed from behind forwards over and under the

Fig. 18.*



artery. At the lower border of the digastric the hypoglossal lies over the vessel, and above that muscle it is crossed by the two trunks of the facial nerve. Three nerves lie beneath it—beginning below, the small external laryngeal; a little higher, the superior laryngeal; and near the angle of the jaw, the glosso-pharyngeal.

Its branches
are anterior,

The *branches* of the external carotid are numerous, and are

* External carotid and its superficial branches ("Anatomy of the Arteries," Quain). *a.* Common carotid. *b.* Internal jugular vein. *c.* Internal carotid. *d.* External carotid. *e.* Superior thyroid. *f.* Lingual. *g.* Facial. *h.* Internal maxillary. *i.* Superficial temporal. *m.* Supraorbital. *n.* External nasal. *o.* Angular branch of facial. *p.* Lateral nasal. *r.* Superior coronary. *s.* Inferior coronary. *t.* Inferior labial. *u.* Submental artery.

classed into an anterior, posterior, and ascending set. The anterior set comprises branches to the thyroid body, the tongue, and the face, viz., superior thyroid, lingual, and facial arteries. In the posterior set are the occipital and posterior auricular branches. And the ascending set includes the ascending pharyngeal, temporal, and internal maxillary arteries. Besides these, the external carotid gives other branches to the neighbouring muscles and the parotid gland.

The arrangement of the branches of the carotid may be altered by their closer aggregation on the trunk. The usual number may be diminished by two or more uniting into one; or it may be increased by some of the secondary offsets being transferred to the parent trunk.

Directions. All the branches, except the ascending pharyngeal, lingual and internal maxillary, may be now examined; but those three will be described afterwards with the regions they occupy.

The *superior thyroid artery (e)* arises near the great cornu of the hyoid bone, and passes beneath the omo-hyoid, sterno-hyoid and sterno-thyroid muscles to the thyroid body, to which it is distributed on the anterior aspect. This artery is superficial in the anterior triangle, and furnishes offsets to the lowest constrictor and the muscles beneath which it lies, in addition to the following named branches:—

a. The *hyoid branch* is very small, and runs inwards below the hyoid bone: it supplies the muscles attached to that bone, and anastomoses with the vessel of the opposite side.

b. A *sterno-mastoid branch* descends in front of the sheath of the common carotid artery, and is distributed chiefly to the muscle from which it takes its name.

c. The *superior laryngeal artery* pierces the membrane between the hyoid bone and the thyroid cartilage, with the superior laryngeal nerve, and ends in the interior of the larynx.

d. A small *crico-thyroid branch* is placed on the membrane between the cricoid and thyroid cartilages, and communicates with the corresponding artery of the opposite side, forming an arch.

The *superior thyroid vein* commences in the larynx and the thyroid body, and crosses the end of the common carotid artery to open into the internal jugular vein.

The *facial artery (g)* arises above the lingual, and is directed upwards over the lower jaw to the face. In the neck the artery passes under the digastric and stylo-hyoid muscles, and then beneath the submaxillary gland, under cover of which it makes a sigmoid turn. Its anatomy in the face has been referred to (p. 27). From the cervical part branches are given to the pharynx, and to the structures below the jaw, viz.:—

a. The *inferior or ascending palatine branch* ascends to the pharynx beneath the jaw, passing between the stylo-glossus and stylo-pharyngeus muscles, and is distributed to the soft palate, which it reaches by turning over the upper border of the superior constrictor muscle. Its place in the palate is frequently supplied by an offset of the ascending pharyngeal artery.

- tonsil, *b.* The *tonsillar branch* is smaller than the preceding, and passes between the internal pterygoid and stylo-glossus muscles. Opposite the tonsil it perforates the constrictor muscle, and ends in offsets to that body.
- submaxillary gland, *c.* *Glandular branches* are supplied to the submaxillary gland from the part of the artery in contact with it.
- and mylo-hyoid muscle, *d.* The *submental branch* arises near the inferior maxilla, and courses forwards on the mylo-hyoid muscle to the anterior belly of the digastric, where it ends in offsets: some of these turn over the jaw to the chin and lower lip; and the rest supply the muscles between the jaw and the hyoid bone, one or two perforating the mylo-hyoid and anastomosing with the sublingual artery.
- Facial vein. The *facial vein* (p. 27) joins the internal jugular. In the cervical part of its course it receives branches corresponding to the offsets of the artery; and it frequently sends a considerable branch downwards to join the anterior jugular vein (p. 63).
- Occipital artery The *occipital artery* springs from the carotid opposite the facial branch, near the lower border of the digastric muscle, and ascends to the inner side of the mastoid process. Here it turns backwards in the occipital groove of the temporal bone, passing above the transverse process of the atlas, and then runs between the muscles attached to the occipital bone, to become cutaneous and ramify over the back of the head (p. 6). In the part of its course now exposed the artery lies beneath the digastric muscle and the parotid gland, and crosses over the internal carotid artery, the jugular vein, and the spinal accessory and hypoglossal nerves.
- ends on occiput; The occipital artery gives small branches to the surrounding muscles, and one larger branch to the sterno-mastoid, which bends downwards over the hypoglossal and enters the muscle in company with the spinal accessory nerve: this branch frequently arises directly from the external carotid. In some bodies there is also a small *meningeal branch* entering the skull by the jugular foramen. The offsets at the back of the neck are seen in the dissection of that region.
- a sterno-mastoid branch; The *occipital veins* are two or three in number, and pass downwards between the muscles of the back of the neck to enter the deep cervical vein. They communicate through the mastoid foramen with the lateral sinus in the interior of the skull.
- sometimes a posterior meningeal. The *posterior auricular artery* is smaller than the preceding branch, and takes origin above the digastric muscle. Between the ear and the mastoid process, it divides into two branches for the ear and occiput (p. 6).
- Occipital veins. A small branch, *stylo-mastoid*, enters the foramen of the same name, and supplies the middle ear.
- Posterior auricular; The *posterior auricular vein* is of considerable size, and descends over the upper end of the sterno-mastoid muscle to join the beginning of the external jugular.
- a branch to tympanum. The *superficial temporal artery* (*i*) is one of the terminal branches of the external carotid, and in direction forms the continuation of that trunk. Ascending in the parotid gland and over
- Posterior auricular vein. The *superficial temporal artery* (*i*) is one of the terminal branches of the external carotid, and in direction forms the continuation of that trunk. Ascending in the parotid gland and over
- Temporal artery; The *superficial temporal artery* (*i*) is one of the terminal branches of the external carotid, and in direction forms the continuation of that trunk. Ascending in the parotid gland and over

the posterior root of the zygoma, it divides on the temporal fascia into anterior and posterior branches which are distributed over the front and side of the head (p. 5). Before dividing the artery gives off the following branches :—

a. *Parotid branches* are furnished to the gland of the same name ; *articular* twigs to the articulation of the lower jaw ; and *muscular* branches to the masseter. Branches to parotid, to articulation,

b. Some *anterior auricular offsets* are distributed to the pinna and meatus of the external ear. and to ear.

c. The *transverse facial branch* leaves the temporal artery close to its origin, and is directed forwards over the masseter muscle (p. 28) ; on the side of the face it supplies the muscles and integuments, and anastomoses with the facial artery. Branch to face.

d. The *middle temporal branch* arises just above the zygoma, and pierces the temporal aponeurosis to enter the substance of the temporal muscle : it anastomoses with the temporal branches of the internal maxillary artery. Branch to temporal muscle

e. A small *orbital branch* runs forwards between the layers of the temporal fascia, and is distributed to the superficial structures near the eye (fig. 2, *h*) ; this anastomoses with an offset of the lachrymal artery (p. 45). and fascia.

The *temporal vein* begins on the side of the head (p. 6) and lies with its artery in front of the ear. Near the zygoma it is joined by the middle temporal vein ; it then receives branches corresponding to the other offsets of the artery ; and it ends by uniting with the internal maxillary vein. Temporal vein.

Directions. The lower part of the neck will now be left for some days, so that the dissector may stitch together the flaps of skin, when he has applied salt to preserve it.

SECTION VI.

PTERYGO-MAXILLARY REGION.

In this region are included the muscles superficial to and beneath the ramus of the lower jaw, together with the temporo-maxillary articulation. In contact with the muscles (pterygoid) beneath the jaw, are the internal maxillary blood-vessels, and the inferior maxillary trunk of the fifth nerve. Contents of the region.

Dissection. The masseter muscle, which is superficial to the bone, has been partly laid bare in the dissection of the facial nerve. To see it more fully, the branches of the facial nerve and the transverse facial artery should be cut through and turned backwards, and the fascia cleaned off the surface of the muscle. Dissection.

Should there be any tow or cotton-wool left in the mouth let it be removed.

The **MASSETER** (fig. 6,¹⁰) arises by a flattened tendon from the lower border of the zygomatic arch, including a small portion of the Masseter muscle ; origin,

malar process of the superior maxilla, and by fine fleshy fibres from the deep surface of the zygomatic process and the malar bone. It is *inserted* into the outer surface of the coronoid process and ramus of the lower jaw, extending from the angle behind to the level of the second molar tooth in front. The superficial fibres are inclined downwards and backwards, and form a layer that can be readily separated from the deeper portion of the muscle, in which the fibres run nearly vertically.

The lower part of the masseter is covered only by the integuments, with the platysma and fascia; but the upper is partly concealed by the parotid gland, and is crossed by Stenson's duct, and by the transverse facial vessels and branches of the facial nerve. The anterior border projects over the buccinator muscle, and a quantity of loose fat resembling that in the orbit is found beneath it. The muscle covers the ramus of the jaw, and the masseteric branches of nerve and artery entering its deep surface.

Action. It raises the lower jaw with the internal pterygoid in the mastication of the food.

Dissection. To lay bare the temporal muscle to its insertion, the following dissection may be made:—The temporal fascia is to be detached from the upper border of the zygomatic arch and removed from the surface of the muscle. Next, the arch is to be sawn through in front and behind, so as to include all its length; and is to be thrown down (without being cut off) with the masseter still attached to it, by separating the fibres of that muscle from the ramus of the jaw. In detaching the masseter its nerve and vessels, which pass through the sigmoid notch, will come into view, and should be dissected out of the muscle.

The surface of the temporal muscle may be then cleaned. And to expose its termination, let the coronoid process be sawn off by a cut passing from the centre of the sigmoid notch to the last molar tooth, so as to include the whole insertion of the muscle. Before sawing the bone let the student find and separate from the muscle the buccal vessels and nerve issuing from beneath it. Lastly, the coronoid process should be raised and the fat removed, in order that the lower fibres of the temporal muscle, and their contiguity to the external pterygoid beneath them, may be seen.

The TEMPORAL MUSCLE (fig. 19,¹) *arises* from the fascia covering it, and from the bones forming the temporal fossa (p. 4), reaching upwards to the semicircular line on the side of the skull, and downwards to the infratemporal crest on the great wing of the sphenoid bone. From this extensive origin the fibres converge to a tendon, which appears on the outer surface of the muscle, and is *inserted* into the borders and inner surface of the coronoid process, as well as into a groove on the front of the ramus of the lower jaw, extending downwards nearly to the last molar tooth.

Behind the posterior border of the tendon are the masseteric vessels and nerve, and in front of it the buccal vessels and nerve: the last nerve occasionally perforates some of the fibres of the muscle.

Action. All the fibres contracting, the muscle will raise the

mandible and press it forcibly against the upper jaw. The hinder fibres acting alone can retract the lower jaw after it has been moved forwards by the external pterygoid.

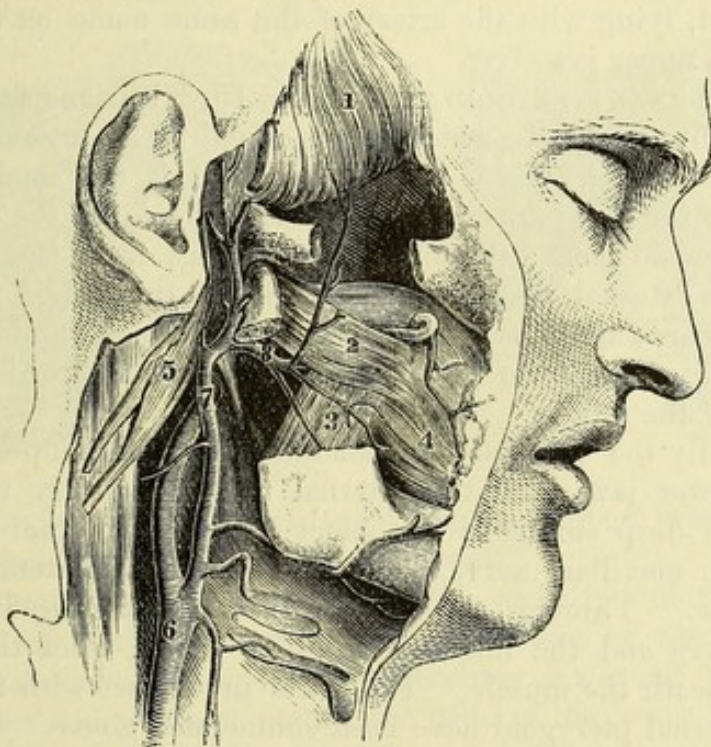
Dissection. For the display of the pterygoid muscles (fig. 19), it will be necessary to remove a piece of the ramus of the jaw. But the greater part of the temporal muscle is to be first detached from the subjacent bone with the handle of the scalpel, and the deep temporal vessels and nerves are to be sought in its fibres.

A piece of the ramus is next to be taken away by sawing across the bone below the condyle, and again close above the dental foramen; and to protect the dental vessels and nerve in contact

To dissect
pterygoid
muscles,

saw through
ramus of
the jaw;

Fig. 19.*



with its inner surface while doing this, the handle of the scalpel may be inserted between them and the bone, and carried downwards to their entrance into the foramen.

After the loose piece of bone has been removed, and the subjacent parts freed from much fat, the pterygoid muscles will appear,—the external (2) being directed backwards and outwards to the condyle, while the internal (3), which is parallel in direction to the masseter, descends to the angle of the jaw. In removing the fatty tissue, the student must be careful not to take away the thin internal lateral ligament, which lies on the internal pterygoid muscle beneath the ramus.

take it away
and the fat.

* Superficial view of the pterygoid region (Quain's "Arteries"). 1. Temporal muscle. 2. External pterygoid. 3. Internal pterygoid. 4. Buccinator. 5. Digastric and stylo-hyoid muscles, cut and thrown back. 6. Common carotid. 7. External carotid. 8. Internal maxillary artery (beneath the pterygoid instead of over it).—The nerves are omitted in this woodcut.

Position of vessels.	<i>Position of vessels.</i> Running forwards over the external pterygoid muscle is the internal maxillary artery, which distributes offsets upwards and downwards: sometimes the artery is placed beneath the muscle. The veins, which form a large plexus between the muscles, may be taken away.
Nerves.	<i>Position of nerves.</i> Most of the branches of the inferior maxillary nerve are seen in this dissection. Thus, the masseteric and deep temporal nerves appear between the upper border of the external pterygoid and the skull, while the buccal nerve perforates the fore part of the muscle. Issuing from beneath the lower border of the same muscle are the large inferior dental and lingual nerves, the latter being the anterior of the two; and coming out behind the condyle of the jaw is the auriculo-temporal nerve. The small posterior dental branch of the superior maxillary nerve is also to be found, lying with the artery of the same name on the hinder part of the upper jaw.
External pterygoid. Origin.	The EXTERNAL PTERYGOID MUSCLE (fig. 19, ²) is triangular in shape, and <i>arises</i> by two heads, which are separated by an interval opposite the sphenomaxillary fossa. The upper head is the smaller, and is attached to the fore part of the zygomatic surface of the great wing of the sphenoid bone; the lower head springs from the outer surface of the external pterygoid plate. From this origin the muscle
Insertion.	runs backwards and outwards to be <i>inserted</i> into the hollow in front of the neck of the lower jaw-bone, and into the interarticular fibrocartilage of the joint.
Relations.	Externally the pterygoid is concealed by the temporal muscle and the lower jaw; and the internal maxillary artery usually lies on it. Its deep surface is in contact with the internal pterygoid, the inferior maxillary nerve, and with the internal lateral ligament of the jaw. Through the interval between the heads pass the buccal nerve and the internal maxillary artery, when the latter is placed beneath the muscle. The parts in contact with the borders of the external pterygoid have been enumerated above.
Use of both muscles, of one muscle.	<i>Action.</i> If both muscles contract, the jaw is moved directly forwards, so that the lower dental arch is placed in front of the upper; but if one muscle act alone (say the right), the condyle of the same side is drawn forwards, and the grinding teeth of the lower jaw are moved obliquely to the left across those of the upper. By the alternate action of the two muscles the trituration of the food is mainly effected.
Internal pterygoid. Origin.	The INTERNAL PTERYGOID MUSCLE (fig. 19, ³) crosses the direction of the external, and is nearly parallel to the ramus of the jaw. It <i>arises</i> in the pterygoid fossa, mainly from the inner surface of the external pterygoid plate, and by a small slip from the outer surface of the tuberosity of the palate bone and the superior maxilla in front
Insertion.	of the pterygoid process. The fibres descend to be inserted into a rough mark on the inner side of the ramus of the lower jaw, extending from the inferior dental foramen to the angle.
Contiguous parts.	On the muscle are placed the dental and lingual nerves, the dental vessels, and the internal lateral ligament of the jaw. Its deep

surface is in relation with the superior constrictor below, and the tensor palati above. The origin of this muscle embraces the lower part of that of the external pterygoid.

Action. It acts with the masseter in raising the jaw.

Use.

TEMPORO-MAXILLARY ARTICULATION (figs. 20 and 21). This articulation is a compound joint, being formed by the condyle of the lower jaw and the fore part of the glenoid cavity of the temporal bone, with an interposed disc of fibro-cartilage. The bones are united by the following ligaments:—

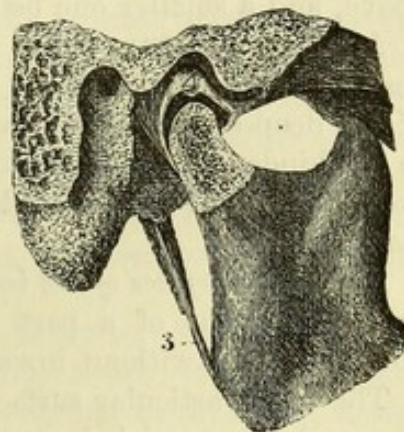
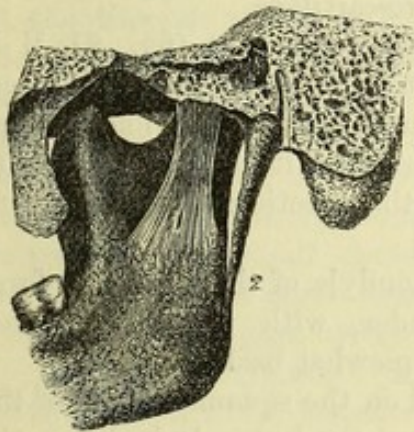
Joint of lower jaw.

The *capsule* is a thin membranous tube which is attached above to the temporal bone around the articular surface, and below to the condyle of the lower jaw, reaching farther down behind than in front. The cavity in the interior is divided into two parts, upper

Capsule of the joint.

Fig. 20.*

Fig. 21.†



and lower, by the fibro-cartilage; and the upper portion of the capsule is wider and looser than the lower.

The *external lateral ligament* is a thickened band of the capsule, composed of fibres passing from the tubercle at the root of the zygoma and the adjoining part of the outer surface of that process to the outer and posterior part of the neck of the lower jaw.

External lateral,

The *internal lateral ligament* (fig. 20, ¹) is a long, thin, membranous band, which is not in contact with the joint. Superiorly it is connected to a ridge on the inner side of the glenoid fossa, formed by the spinous process of the sphenoid and the vaginal process of the temporal bone; and inferiorly it is inserted into the inner margin of the dental foramen in the lower jaw. The ligament lies between the jaw and the internal pterygoid; and its origin is concealed by the external pterygoid muscle. The internal maxillary vessels, with the auriculo-temporal and inferior dental nerves, pass between the band and the ramus of the jaw.

and internal lateral ligament.

Dissection. After the external lateral ligament and the capsule

Dissection.

* Ligaments of the jaw—inner view (Bourguery and Jacob). 1. Internal lateral ligament. 2. Stylo-maxillary.

† A view of the interior of the temporo-maxillary joint (Bourguery and Jacob). 3. Stylo-maxillary ligament. 4. Interarticular fibro-cartilage: the dark intervals above and below the disc are the synovial cavities.

	have been examined, the interarticular fibro-cartilage will be exposed by taking away the capsule on the outer side (fig. 21).
Fibro-cartilage ; shape,	The <i>interarticular fibro-cartilage</i> (fig. 21, ⁴) is an oval plate, elongated transversely, and thinner in the centre, where it is sometimes perforated, than at the margins. The upper surface fits the articular hollow and eminence of the temporal bone, being convex behind and concave in front ; and the lower is moulded to the convexity of the condyle of the jaw. By the circumference it is connected with the capsule ; and in front the external pterygoid muscle is attached to it.
and attach- ments.	
Use.	This interarticular disc allows a double movement to take place in the articulation, the condyle of the jaw revolving in the socket formed by the fibro-cartilage, while the latter glides forwards and backwards over the temporal articular surface.
Two syno- vial sacs.	Two <i>synovial sacs</i> are present in the articulation—a larger one above, and a smaller one below the fibro-cartilage.
Stylo-maxil- lary liga- ment.	Another structure—the <i>stylo-maxillary ligament</i> (fig. 21, ³) is described as a uniting band to the articulation. This is a process of the deep cervical fascia, which extends from the styloid process to the hinder border of the ramus of the jaw ; it gives attachment to the stylo-glossus muscle, and separates the parotid and submaxillary glands.
Surface of jaw	<i>Articular surfaces of the bones.</i> The condyle of the jaw has a form resembling that of a part of a cylinder, with its axis directed obliquely from without inwards and somewhat backwards.
and tem- poral bone.	The upper articular surface is placed on the squamous part of the temporal bone, and is larger than that on the jaw. It includes the deep oval hollow formed by the part of the glenoid fossa in front of the Glaserian fissure, and the convex surface, known as the articular eminence, which forms the anterior boundary of the hollow.
Kinds of movement.	<i>Movements of the joint.</i> The lower jaw has up and down, forward and backward, and oblique movements.
In opening the mouth, how condyle moves.	In <i>depressing</i> the jaw, as in opening the mouth, the condyle moves forwards till it is placed under the convexity of the articular eminence ; but the interposed concave fibro-cartilage gives security to the joint. Even with this provision, a slight degree more of sudden motion may throw the condyle off the prominence of the temporal bone into the zygomatic fossa, and give rise to dislocation.
Dislocation. State of ligaments.	In this movement the fore and lateral parts of the capsule are tightened ; and the fibro-cartilage is drawn forwards with the condyle by the external pterygoid muscle.
Shutting mouth.	When the jaw is <i>elevated</i> and the mouth closed, the condyle and the fibro-cartilage glide back into the glenoid fossa ; and the posterior part of the capsule is stretched.
Forward and backward movement.	During the <i>horizontal movements forwards and backwards</i> of the jaw the condyle is placed successively opposite the front and back of the temporal articular surface ; and the fibro-cartilage always follows the condyle of the jaw, even in dislocation.
	Excessive motion forwards would be prevented by the coronoid process of the jaw striking against the zygomatic arch ; and the

backward movement is checked by the external lateral ligament and by the meeting of the condyle with the postglenoid process of the temporal bone.

The *oblique movement* is produced by the condyle of one side advancing on the articular eminence, while the other remains in the glenoid fossa. If the right condyle advances, the chin moves to the left side, and the grinding teeth of the lower jaw are carried obliquely to the left and forwards across the upper set. By the alternate action to opposite sides the food is triturated.

Oblique movement how produced.

Dissection. The condyle of the jaw is next to be disarticulated and drawn forwards with the attached external pterygoid muscle, so as to allow the inferior maxillary nerve to be seen (fig. 22). While cutting through the joint-capsule, the dissector must be careful of the auriculo-temporal nerve close beneath.

Dissection of inferior maxillary nerve,

On turning forwards the pterygoid muscle, and removing some fat, the dissector will find the trunk of the inferior maxillary nerve. The masseteric, temporal, and buccal branches of the nerve should be traced to a common origin close below the foramen ovale of the sphenoid bone. The dental and lingual nerves should be cleaned beneath the muscle; and the auriculo-temporal nerve followed forwards with care from the back of the articulation to its origin from the trunk. The small chorda tympani is to be found joining the back of the lingual nerve near the skull.

its trunk and branches;

of chorda tympani,

The large meningeal artery and its offsets are to be sought beneath the external pterygoid. Sometimes the trunk of the internal maxillary artery lies beneath that muscle, and in that case, it and its branches are now to be cleaned.

and arteries.

The INTERNAL MAXILLARY ARTERY (fig. 19, ⁸) is one of the terminal branches of the external carotid, and takes a winding course beneath the lower jaw and the temporal muscle to the sphenomaxillary fossa, where it ends in branches for the face, the interior of the nose, and the palate and pharynx.

Internal maxillary artery,

At first the artery is directed forwards between the ramus of the jaw and the internal lateral ligament of the joint, and crosses the dental nerve; it then ascends over the lower portion of the external pterygoid, being placed between it and the temporal muscle; and finally, it turns inwards opposite the interval between the heads of the external pterygoid to gain the sphenomaxillary fossa. The course of the artery is sometimes beneath, instead of over the external pterygoid; and when that is the case, the artery reaches the sphenomaxillary fossa by passing between the heads of the muscle, as in the figure.

course and relations,

varies in its position.

The *branches* of this artery are numerous, and are classed in three sets: the first set arises beneath the jaw; the second between the muscles; and the third in the sphenomaxillary fossa.

Branches are in three sets.

Two chief branches, viz., the inferior dental and the great meningeal, leave the internal maxillary artery while it is in contact with the ramus of the jaw.

Those beneath jaw.

The *inferior dental artery* descends between the internal lateral ligament and the jaw, and enters the foramen on the inner surface

Inferior dental

of the ramus, along with the dental nerve ; it supplies the teeth, and ends in the lower part of the face (p. 91).

has a
branch to
mylo-hyoid
muscle.

As the artery is about to enter the foramen it furnishes a small *mylo-hyoid branch* to the muscle of that name ; this is conducted by a groove on the inner surface of the bone, in company with a branch from the dental nerve, to the superficial surface of its muscle, where it anastomoses with the submental artery.

Great
meningeal
artery

ends in
skull,

but gives

The *great meningeal artery* is the largest branch of the internal maxillary, and arises opposite the preceding. It ascends beneath the external pterygoid muscle, and between the roots of the auriculo-temporal nerve to the foramen spinosum of the sphenoid bone, through which it passes into the skull. Its course and distribution within the cranial cavity have been already seen (p. 15). Before the artery reaches the foramen, it usually furnishes the following small branches ; but one or more of them may arise directly from the internal maxillary trunk :—

branch to
tympanum,

a. The *tympanic branch* passes into the tympanum through the Glaserian fissure, and is distributed to the tympanic membrane and parts within the cavity.

to meatus,

b. A *deep auricular branch* arises with the former or separately, enters the meatus through the cartilage, or between this and the bone, and ramifies in the meatus and on the tympanic membrane.

to dura
mater.

c. The *small meningeal branch* begins near the skull, and courses through the foramen ovale with the inferior maxillary nerve ; it ramifies in the dura mater in the middle fossa of the skull.

Branch with
lingual
nerve.

Another small branch springs from the dental artery or the internal maxillary trunk, and accompanying the lingual nerve, ends in the cheek and the mucous membrane of the mouth.

Branches of
second part
are—

The branches from the second part of the artery (between the temporal and external pterygoid) are distributed to the temporal, masseter, buccinator, and pterygoid muscles.

to the
temporal
muscle ;

The *deep temporal arteries* are two in number, anterior and posterior, and ascend on the side of the skull beneath the temporal muscle. The posterior anastomoses with the middle temporal branch of the superficial temporal artery ; the anterior communicates, through the malar bone, with branches of the lachrymal artery (p. 45).

to the
masseter ;

The *masseteric artery* is directed outwards with the nerve of the same name behind the tendon of the temporal muscle, and passing through the sigmoid notch, enters the deep surface of the masseter muscle. Its branches anastomose with the other offsets to the muscle from the external carotid trunk.

to the
cheek ;

The *buccal branch* quits the artery near the upper jaw, and descends beneath the insertion of the temporal muscle with its companion nerve : it is distributed to the buccinator muscle and other structures of the cheek, joining branches of the facial artery.

to pterygoid
muscles.

The *pterygoid branches* are uncertain in their position and number ; whether derived from the trunk or some of the branches of the internal maxillary, they enter the two pterygoid muscles.

Branches of
third part :

Of the branches that arise from the artery in the sphenomaxillary

fossa, only one, the posterior dental, will be now described. The remainder will be examined with the superior maxillary nerve and Meckel's ganglion; they are infraorbital (p. 101), superior palatine, naso-palatine, vidian, and pterygo-palatine (SECTION XIV).

The *posterior dental branch* arises as the artery enters the sphenomaxillary fossa, and descends with a tortuous course on the zygomatic surface of the upper jaw, along with a small branch of the superior maxillary nerve. Its branches mostly enter the canals of the bone and supply the upper molar and bicuspid teeth, as well as the lining membrane of the antrum; but some external offsets are furnished to the gum.

The INTERNAL MAXILLARY VEIN is a short trunk, often double, which leaves the hinder part of the pterygoid plexus, and runs backwards beneath the jaw with the first part of the internal maxillary artery, to join the temporal vein in the parotid gland.

The *pterygoid plexus* is an extensive network of veins surrounding the internal maxillary artery and the pterygoid muscles. Into it the veins corresponding to the branches of the artery empty themselves, and it communicates with the cavernous sinus in the interior of the skull through the foramen ovale and foramen lacerum. From the plexus the large internal maxillary vein leads backwards, and another considerable branch, the *anterior internal maxillary* or *deep facial vein*, descends to the face to join the facial vein. A prolongation of the plexus into the sphenomaxillary fossa is often distinguished as the *alveolar plexus*.

The INFERIOR MAXILLARY NERVE (fig. 22) is the largest of the three trunks arising from the Gasserian ganglion (p. 18). It leaves the skull by the foramen ovale in the sphenoid bone, and divides immediately below that opening into two principal pieces, viz., an anterior smaller part, which is distributed mainly to muscles, and a larger posterior part, ending in branches which are, with one exception, altogether sensory. In addition to these, the nerve of the internal pterygoid muscle arises from the inner side of the primary trunk.

Directions. Should the internal maxillary artery obstruct the view of the nerve, it may be cut through.

The SMALLER PART receives nearly all the fibres of the motor root of the nerve, and furnishes branches to three of the muscles of the jaw, viz., temporal, masseter, and external pterygoid, and the buccal branch to the cheek.

The *deep temporal branches* (3) are three in number, and enter the deep surface of the temporal muscle; the *middle*, which is the largest and supplies the greater part of the muscle, leaves the anterior division of the trunk and ascends close to the bone, above the upper border of the external pterygoid; the *posterior* is usually conjoined with the masseteric nerve, and enters the hinder part of the muscle; and the *anterior* is given off from the buccal nerve in front of the external pterygoid.

The *masseteric branch* (2) takes an outward course above the external pterygoid muscle, and through the sigmoid notch, to the

only one
now seen

is the
posterior
dental.

Internal
maxillary
vein arises
from

pterygoid
plexus:

tributaries

and outlets

Inferior
maxillary
nerve.

Anterior
part

supplies
temporal
branches,
middle

posterior,
and
anterior.

Masseteric.

under surface of the masseter muscle, in which it can be followed to near the anterior border. As this branch passes by the articulation of the jaw it gives one or more twigs to that joint.

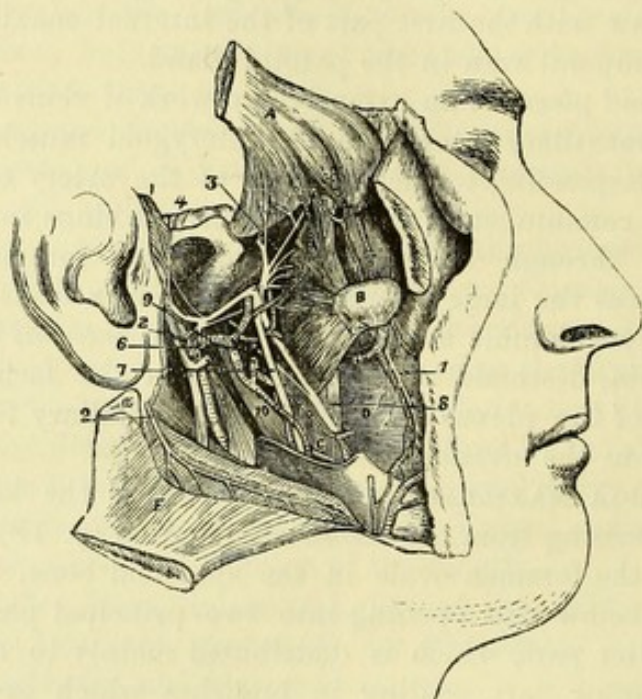
Branch to
external
pterygoid.

The *nerve to the external pterygoid* generally arises in common with the buccal nerve, and enters the deep surface of its muscle: it is often represented by two or three branches.

Buccal
nerve is
sensory;

The *buccal branch* (¹), longer and larger than the others, is mainly a sensory nerve to the cheek. It is first directed forwards between the heads of the external pterygoid muscle, and then descends beneath the coronoid process and insertion of the temporal muscle towards the angle of the mouth. After perforating the pterygoid, it

Fig. 22.*



gives off
deep
temporal.

gives off the anterior deep temporal nerve; and on the surface of the buccinator it divides into branches which form a plexus with the buccal branches of the facial nerve, and are finally distributed to the skin and mucous membrane of the cheek.

Posterior
part of
inferior
maxillary.

The **LARGER PART** of the inferior maxillary nerve divides into three branches—auriculo-temporal, inferior dental, and lingual. A few of the fibres of the motor root join the dental nerve, and are conveyed to the mylo-hyoid and digastric muscles.

Auriculo-
temporal

The **AURICULO-TEMPORAL NERVE** (⁴) arises from the trunk near the base of the skull, usually by two roots which embrace the middle meningeal artery. In its course to the surface of the head, it is first directed backwards beneath the external pterygoid muscle

* Deep view of the pterygoid region (Illustrations of Dissections). *Muscles*: A. Temporal reflected. B. Condyle of the jaw disarticulated, with the external pterygoid attached to it. C. Internal pterygoid. D. Buccinator. F. Masseter thrown down. *Nerves*: 1. Buccal. 2. Masseteric, cut. 3. Deep temporal. 4. Auriculo-temporal. 6. Chorda tympani. 7. Inferior dental. 8. Lingual. 10. Internal lateral ligament of the lower jaw. The arteries are not numbered with the exception of the internal maxillary trunk, which is marked with 9.

as far as the neck of the jaw, and then upwards with the temporal artery in front of the ear. Its ramifications on the head are described at page 8. In the part now dissected its branches are the following :—

a. Branches of the meatus auditorius. Two offsets are given to the meatus from the nerve beneath the neck of the jaw, and enter that tube between the cartilage and bone.

b. Articular branch. The branch to the joint of the jaw arises near the same spot as the preceding, or from the branches to the meatus.

c. The inferior auricular branch supplies the tragus and adjacent part of the pinna.

d. Parotid branches. These small filaments ramify in the gland.

e. Communicating branches with the otic ganglion. One or two filaments pass between the otic ganglion and the beginning of the auriculo-temporal nerve (p. 146).

f. Branches to the facial nerve. Two considerable branches pass forwards round the superficial temporal artery to join the upper trunk of the facial nerve.

The INFERIOR DENTAL (⁷) is the largest of the branches of the inferior maxillary nerve. In its course to the canal in the lower jaw, the dental nerve is placed behind and external to the lingual, and lies at first beneath the external pterygoid muscle; it afterwards rests on the internal pterygoid, and near the dental foramen on the internal lateral ligament. After the nerve enters the bone, it is continued forwards beneath the teeth to the foramen in the side of the jaw, and ends at that spot by dividing into an incisor and a mental branch. Only one offset (to the mylo-hyoid muscle) leaves the dental nerve before it enters the bone. Its branches are :—

a. The mylo-hyoid nerve arises near the dental foramen, and is continued along a groove on the inner aspect of the ramus of the jaw to the cutaneous surface of the mylo-hyoid, and to the anterior belly of the digastric muscle.

b. The dental branches arise in the bone, and supply the molar and bicuspid teeth. If the bone is soft, the canal containing the nerve may be laid open so as to expose these branches.

c. The incisor branch is small and continues the direction of the nerve onwards to the middle line, furnishing offsets to the canine and incisor teeth, below which it lies.

d. The mental or labial branch (fig. 9, ¹³) is in size the continuation of the dental trunk, and issues on the face beneath the depressor of the angle of the mouth. It gives one offset downwards to the integument of the chin; but the greater part of the nerve is directed upwards beneath the depressor labii inferioris, to be distributed on the inner and outer surfaces of the lower lip. Its branches communicate with the supramaxillary portion of the facial nerve.

The *inferior dental artery*, after entering the lower jaw, has a similar course and distribution to the nerve. Thus it supplies off-

lies beneath jaw,
and supplies branches

to the meatus,

joint of jaw,

the ear, and part of the pinna.

parotid;

to join otic ganglion

and facial nerve.

Inferior dental

is between pterygoid muscles,

then in the jaw,

and supplies

branch to mylo-hyoid,

dental branches to grinding

and cutting teeth,

branch to lower lip.

Dental artery

- has an sets to the bone, dental branches to the molar and bicuspid teeth, and ends anteriorly in an incisor and a mental branch.
- incisor and The *incisor branch* is continued to the symphysis of the jaw, where it ends in the bone; it furnishes twigs to the canine and incisor teeth.
- labial branch. The *mental branch*, issuing by the mental foramen, ramifies in the structures covering the lower jaw, and anastomoses with the branches of the facial artery.
- Lingual nerve The LINGUAL OR GUSTATORY NERVE (⁸) is concealed at first, like the others, by the external pterygoid muscle. It is then inclined forwards with a small artery over the internal pterygoid, and under cover of the side of the jaw to the tongue. The remainder of the nerve will be seen in the dissection of the submaxillary region (p. 97).
- courses to the tongue ;
- no branch here. In its course beneath the jaw the nerve does not give off any branches, but the following communicating nerve is received by it.
- Chorda tympani The *chorda tympani* (⁶) is a branch of the facial nerve, and leaves the tympanum by a special aperture close to the inner end of the Glaserian fissure. Appearing from beneath the upper attachment of the internal lateral ligament of the jaw, this small nerve joins the lingual at an acute angle, about three-quarters of an inch below the skull. At the point of meeting a communication takes place with the lingual, but the greater part of the chorda tympani is merely conducted along that nerve to the tongue.
- joins lingual,
- ends in tongue. The origin of this nerve, and its course across the tympanum, are described in SECTION XIV.
- Branch to internal pterygoid. The *nerve to the internal pterygoid* can now be seen as it passes beneath the hinder border to the inner surface of its muscle, but it will be more fully shown in the dissection of the otic ganglion (SECTION XIV).

SECTION VII.

SUBMAXILLARY REGION.

- Parts in it. The submaxillary region is situate between the lower jaw and the hyoid bone. In it are contained some of the muscles of the hyoid bone and tongue, the vessels and nerves of the tongue, and the sublingual and submaxillary glands.
- Position of the neck. *Position.* In this dissection the position of the neck is the same as for the examination of the anterior triangle.
- Dissection. *Dissection.* If any fatty tissue has been left on the submaxillary gland, or on the mylo-hyoid muscle, when the anterior triangular space was dissected, let it be taken away.
- Situation The SUBMAXILLARY GLAND (fig. 16, ¹¹) lies below the jaw in the anterior part of the space limited by that bone and the digastric muscle. Somewhat oval in shape, it rests on the mylo-hyoid, and

sends a deep process round the posterior or free border of that muscle. In front of it is the anterior belly of the digastric; and behind is the stylo-maxillary ligament separating it from the parotid. The gland is covered only by the integuments, platysma, and deep fascia; and the facial artery winds forwards on its deep surface.

and relations
of submaxillary gland.

In structure the submaxillary resembles the parotid gland (p. 29); and its duct—duct of Wharton—issuing from the deep process, extends beneath the mylo-hyoid muscle to the mouth.

Structure.

Dissection. To see the mylo-hyoid muscle, detach the anterior belly of the digastric from the jaw, and dislodge without injury the submaxillary gland from beneath the bone.

Dissection

The MYLO-HYOID MUSCLE is triangular in shape, with the base at the jaw and the apex at the hyoid bone, and unites along the middle line with its fellow of the opposite side. It arises from the mylo-hyoid ridge on the inner surface of the lower jaw as far back as the last molar tooth; and its fibres are inserted partly into the front of the body of the hyoid bone, but the greater number end, with those of the muscle of the opposite side, in a median raphe between that bone and the jaw.

Mylo-hyoid

arises from jaw

inserted into hyoid bone and raphe.

On the cutaneous surface lie the anterior belly of the digastric and the submaxillary gland, the facial artery with its submental offset, and the mylo-hyoid nerve and artery. The fibres of the muscle are frequently deficient near the jaw, and allow the genio-hyoid to be seen. Only the posterior border is unattached, and round it a piece of the submaxillary gland winds. The parts in contact with the deep surface of the muscle will be shown after the undermentioned dissection has been made.

Parts around it.

Action. The mylo-hyoid assists the digastric and genio-hyoid in depressing the lower jaw or elevating the hyoid bone; but its principal action is to raise the floor of the mouth and press the tongue against the palate, as in the first stage of deglutition.

Use.

Dissection. To bring into view the muscles beneath the mylo-hyoid, and to trace the vessels and nerves to the substance of the tongue, the student should first divide the facial vessels on the jaw, and remove them with the superficial part of the submaxillary gland; but he should be careful to leave the deep part of the gland which turns beneath the mylo-hyoid, because the small submaxillary ganglion is in contact with it. Next he should cut through the small branches of vessels and nerve on the surface of the mylo-hyoid; and detaching that muscle from the jaw, should turn it down (as in fig. 24), but without injuring the genio-hyoid muscle beneath it.

Dissection to detach mylo-hyoid.

Afterwards the bone is to be sawn through on the right of, but close to the muscles attached to the symphysis, the soft parts covering the jaw having been first cut. The loose side of the jaw (for the ramus of the bone has been sawn before) is to be raised to see the parts beneath, and it may be fastened up with a stitch; but it should not be detached from the mucous membrane of the mouth.

To see deep muscles saw the jaw,

fasten
tongue,

The apex of the tongue is to be now pulled well out of the mouth over the upper teeth, and fastened with a stitch to the septum of the nose, while the left half of the jaw is to be drawn down forcibly with hooks. The scalpel should be then passed from below upwards between the sawn surfaces of the bone, for the purpose of dividing a strong band of the mucous membrane of the mouth; and it should be carried onwards along the middle line of the tongue to the tip.

and cut
mucous
membrane.

Define
ner

By means of a stitch the hyoid bone may be fastened down, to make tight the muscular fibres. All the fat and areolar tissue are to be removed, and in doing this the student is to take care of the Whartonian duct, of the hypoglossal nerve and its branches, which lie on the hyo-glossus muscle, and especially of its small offset ascending to the stylo-glossus muscle; also of the lingual nerve nearer the jaw. Between the lingual nerve and the deep part of the submaxillary gland the dissector should seek the small submaxillary ganglion with its offsets; and he should endeavour to separate from the trunk of the lingual the small chorda tympani nerve (p. 92), and to define the offset from it to the submaxillary ganglion.

vessels,

At the hinder border of the hyo-glossus clean the lingual vessels, the stylo-hyoid ligament, and the glosso-pharyngeal nerve, all passing beneath that muscle; and at the anterior border find the issuing ranine artery, which, with the companion vein and lingual nerve, is to be traced on the under surface of the tongue to the tip.

and
sublingual
gland.

Adhering to the mucous membrane of the mouth is the sublingual gland, and this is to be defined, together with the sublingual artery which supplies it.

Parts be-
neath mylo-
hyoid;

Parts beneath the mylo-hyoid (fig. 24). The relative position of the objects covered by the mylo-hyoid is now apparent:—Extending from the hyoid bone to the side of the tongue is the hyo-glossus muscle, the fibres of which are crossed superiorly by those of the stylo-glossus. On the hyo-glossus are placed, from below upwards, the hypoglossal nerve, Wharton's duct, and the lingual nerve, the latter crossing the duct; and near the anterior border of the muscle the two nerves are united by branches. Beneath the same muscle lie, from below upwards, the lingual artery, the stylo-hyoid ligament, and the glosso-pharyngeal nerve. Above the hyo-glossus is the mucous membrane of the mouth, with the sublingual gland attached to it in front, and some fibres of the superior constrictor muscle covering it behind near the jaw.

above hyoid
bone,

in front of
hyo-glossus.

Between the chin and the hyoid bone, close to the middle line, is situate the genio-hyoid muscle; above this is a larger fan-shaped muscle, the genio-glossus. Along the outer side of the last muscle lie the ranine vessels; and a sublingual branch for the gland of the same name springs from the lingual artery at the anterior border of the hyo-glossus. On the under surface of the tongue, near the margin, lies the lingual nerve; and the hypoglossal nerve enters the fibres of the genio-glossus.

The HYO-GLOSSUS MUSCLE (fig. 23, ¹) is thin and somewhat square in shape. It arises from the lateral part of the body, and from all the great cornu, of the hyoid bone. The fibres ascend and enter the side of the tongue; they will be seen afterwards to mingle with those of the palato- and stylo-glossus.*

The parts lying on the outer surface of the hyo-glossus, as well as those passing beneath its anterior and posterior borders, have already been enumerated; and under the muscle there are also portions of the genio-glossus and middle constrictor.

Action. This muscle depresses the tongue, drawing down the sides and giving a rounded form to the dorsum; and if the tongue is protruded from the mouth, the fibres will draw it backwards into that cavity.

The STYLO-GLOSSUS (fig. 23, ²) is a slender muscle, which arises from the styloid process near the apex, and from the stylo-maxillary ligament, and is directed

downwards and forwards to the hinder part of the lateral margin of the tongue. Here it gives some fibres to the dorsum, but the greater part of the muscle turns to the under surface, and is continued forwards to the tip of the tongue. Beneath the jaw this muscle is crossed by the lingual nerve.

Action. Both muscles will raise the back of the tongue against the roof of the mouth; and if the tongue is protruded they will restore it to the cavity.

One muscle can direct the point of the tongue towards its own side of the mouth.

The GENIO-HYOID MUSCLE (fig. 23, ⁴) arises from the lower of the mental spines on the inner aspect of the symphysis of the jaw, and is inserted into the front of the body of the hyoid bone.

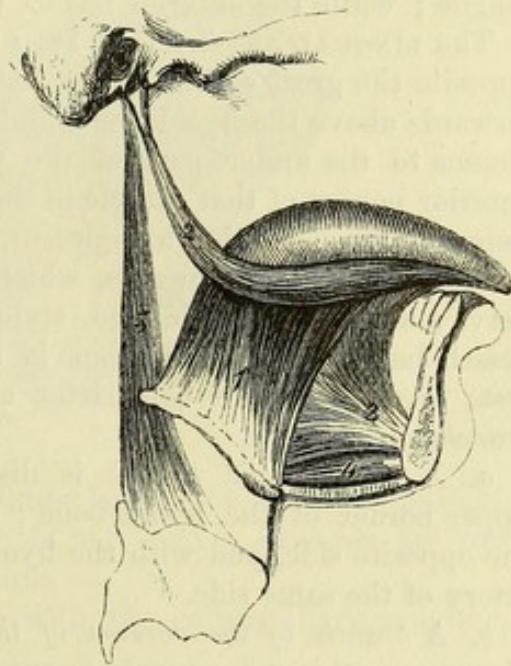
The lower surface of this muscle is covered by the mylo-hyoid, and the upper is in contact with the genio-glossus (³). The inner border touches the muscle of the opposite side, and the two are often united.

Action. The genio-hyoid either depresses the lower jaw or

* A distinct muscular slip (chondro-glossus), arising from the small cornu of the hyoid bone, is sometimes regarded as a part of the hyo-glossus. For farther details respecting the anatomy of this and the other lingual muscles, reference is made to the dissection of the tongue, SECTION XV.

† Muscles of the tongue. 1. Hyo-glossus. 2. Stylo-glossus. 3. Genio-glossus. 4. Genio-hyoid. 5. Stylo-pharyngeus.

Fig. 23.†



comes to side of tongue.

Use of both

of one.

Relations.

Use

raises the hyoid bone, according to which end is fixed by other muscles.

Genio-glossus.

The GENIO-GLOSSUS (genio-hyo-glossus, fig. 23, ³) is a thick, fan-shaped muscle, having its apex at the jaw, and its base at the tongue. It takes *origin* from the upper of the mental spines behind the symphysis of the jaw. From this spot the fibres radiate, the posterior passing backwards to their *insertion* into the body of the hyoid bone, the anterior forwards to the tip of the tongue, and the intermediate ones to the tongue from base to point.

Origin.

Insertion.

Contiguous parts.

Lying close to the median plane, the inner surface of the muscle is in contact with its fellow. Its lower border corresponds to the genio-hyoid, and the upper to the frænum linguæ. On its outer side are the ranine vessels, and the hyo-glossus muscle; and the hypoglossal nerve perforates the hinder fibres.

Use.

Action. By the simultaneous action of the whole muscle the tongue is depressed, and hollowed along the middle. The hinder fibres acting alone raise the hyoid bone and protrude the tongue; while the anterior retract the tip of the tongue.

Lingual artery ascends to the tongue beneath hyo-glossus.

The LINGUAL ARTERY (fig. 18, *f*) arises from the external carotid opposite the great cornu of the hyoid bone. At first it is directed forwards above the hyoid bone, and then upwards beneath the hyo-glossus to the under part of the tongue (fig. 24); it ends at the anterior border of that muscle in the sublingual and ranine branches. Before it reaches the hyo-glossus, the artery forms a small loop, with its convexity upwards, which is crossed by the hypoglossal nerve; and the digastric and stylo-hyoid muscles also lie over the vessel, but are separated from it by the hyo-glossus. The trunk rests on the middle constrictor and genio-glossus muscles. Its *branches* are:—

Its branches are—
to hyoid bone;

a. A small *hyoid branch* is distributed to the muscles at the upper border of the hyoid bone; it anastomoses with its fellow of the opposite side, and with the hyoid branch of the superior thyroid artery of the same side.

to back of the tongue;

b. A *branch to the dorsum of the tongue* arises beneath the hyo-glossus muscle, and ascends to supply the substance of the tongue and the tonsil. The fibres of the hyo-glossus must be divided to see it.

to the sublingual gland;

c. The *sublingual branch* springs from the final division of the artery at the edge of the hyo-glossus, and is directed outwards to the gland of the same name. Some offsets supply the gums and the contiguous muscles, and one continues behind the incisor teeth to join a similar artery from the other side.

to the substance of tongue.

d. The *ranine branch* (fig. 24, ⁹) is the terminal part of the lingual artery, and extends forwards along the outer side of the genio-glossus to the tip of the tongue where it ends. Muscular offsets are furnished to the substance of the tongue of the same side. This artery is very tortuous, and is embedded in the muscular fibres of the tongue.

Lingual veins.

The lingual artery is accompanied by two small *venæ comites*, but the largest vein of the tongue is the *ranine*, which lies external to

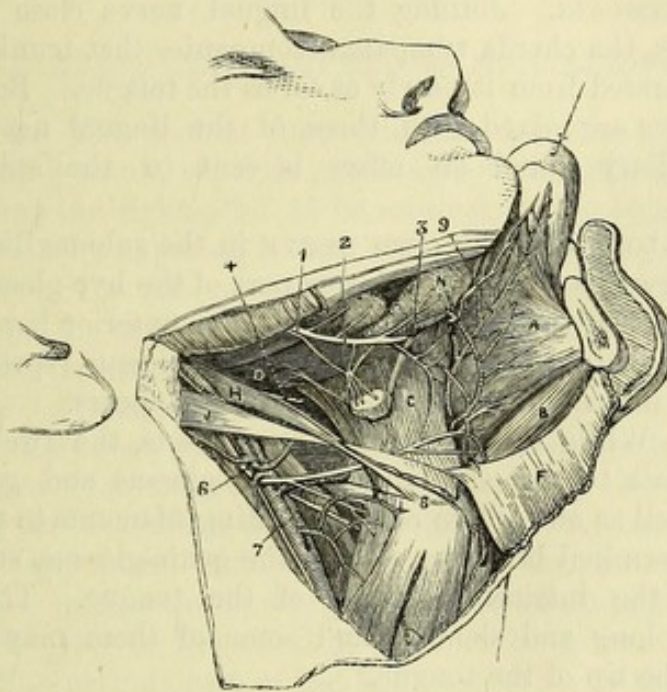
the artery of the same name, and, after being joined by *sublingual branches*, passes backwards over the hyo-glossus muscle with the hypoglossal nerve. These veins end in the internal jugular.

The LINGUAL NERVE (fig. 24,¹) has been followed in the pterygo-maxillary region to its passage between the ramus of the lower jaw and the internal pterygoid muscle (p. 92). In the submaxillary region the nerve is inclined inwards to the side of the tongue, across the mucous membrane of the mouth and the origin of the superior constrictor muscle, and above the deep part of the submaxillary

Lingual
nerve

along side
of tongue

Fig. 24.*



gland. Lastly, it is directed forwards below the Whartonian duct, and along the side of the tongue to the apex. *Branches* are furnished to the surrounding parts, thus :—

gives
branches

Two or more offsets connect it with the submaxillary ganglion, near the gland of that name.

to the gan-
glion,

Farther forwards one or more branches descend on the hyo-glossus to unite in a loop with twigs of the hypoglossal nerve.

to twelfth
nerve,

Other filaments are supplied to the mucous membrane of the mouth, the gums, and the sublingual gland.

to mucous
membrane,

Lastly, the *branches for the tongue* ascend through the muscular substance, and are distributed to the conical and fungiform papillæ.

to the
papillæ.

The SUBMAXILLARY GANGLION (fig. 24,²) resembles the other ganglia connected with the three trunks of the fifth nerve, and communicates with motor, sensory, and sympathetic nerves. It lies

Submaxil-
lary
ganglion

* Deep view of the submaxillary region (Illustrations of Dissections).
Muscles : A. Genio-glossus. B. Genio-hyoid. C. Hyo-glossus. D. Stylo-glossus. F. Mylo-hyoid reflected. H. Stylo-hyoid. J. Posterior belly of digastric.
Nerves : 1. Lingual. 2. Submaxillary ganglion. 4. Glosso-pharyngeal. 6. Hypoglossal. 7. Upper laryngeal. The lingual artery is seen dividing, close to the hypoglossal nerve : the ranine offset is marked with 9. 3. Wharton's duct.

on the hyo-glossus muscle immediately above the deep part of the submaxillary gland, and is attached by two or three filaments to the lingual nerve.

has roots
from the
fifth, facial
and sym-
pathetic,

Connections with nerves—roots. The fibres of the sensory root are derived from the lingual, and of the motor root from the chorda tympani nerves, both joining the upper part of the ganglion. The sympathetic root comes from the plexus on the facial artery.

gives
branches to
gland.

Branches. From the lower part of the ganglion five or six small offsets descend to the submaxillary gland; and from the fore part other filaments are given to the mucous membrane of the mouth and Wharton's duct.

Chorda tym-
pani;
destination.

CHORDA TYMPANI. Joining the lingual nerve close below its origin (p. 92), the chorda tympani accompanies that trunk, but can be easily separated from it nearly as far as the tongue. Beyond that point its fibres are mixed with those of the lingual nerve. Near the submaxillary gland an offset is sent to the submaxillary ganglion.

Twelfth
nerve above
hyoid bone.

The HYPOGLOSSAL OR TWELFTH NERVE in the submaxillary region is directed forwards across the lower part of the hyo-glossus muscle and under cover of the mylo-hyoid. At the anterior border of the hyo-glossus it enters the fibres of the genio-glossus, spreading out and dividing into numerous branches as it disappears.

Its branches
supply mus-
cles of
tongue.

Branches. While resting on the hyo-glossus, the twelfth nerve furnishes offsets to the stylo-glossus, hyo-glossus and genio-hyoid muscles, as well as one or two communicating filaments to the lingual nerve. Its terminal branches, within the genio-glossus, supply that muscle and the intrinsic muscles of the tongue. The lingual branches are long and slender, and some of them may be traced forwards to the tip of the tongue.

The GLOSSO-PHARYNGEAL nerve (fig. 24,⁴), appearing between the two carotid arteries, courses forwards over the stylo-pharyngeus, and ends under the hyo-glossus in branches for the tongue. (See the DISSECTION OF THE TONGUE.)

Wharton's
duct

The *duct of the submaxillary gland* (fig. 24,³), Wharton's duct, issues from the deep part of the glandular mass turning round the border of the mylo-hyoid muscle. About two inches in length, it is directed upwards and forwards on the hyo-glossus muscle, and over the lingual nerve, to open on the centre of an eminence by the side of the frænum linguæ: the opening in the mouth will be seen if a bristle be passed along the duct. The deep part of the submaxillary gland extends along the side of the duct, reaching, in some instances, the sublingual gland.

opens by
frænum
linguæ.

Sublingual
gland

The **SUBLINGUAL GLAND** (fig. 24, N) is an almond-shaped body with its longest diameter, which measures about an inch and a half, directed from before backwards. It lies beneath the fore part of the tongue, between the genio-glossus muscle and the lower jaw, and resting on the mylo-hyoid. Its upper border is covered by the mucous membrane, which is raised into a fold along the floor of the mouth over the gland; and its inner end touches the one of the opposite side behind the symphysis of the jaw.

forms a pro-
minence be-
low tongue,

The gland consists of from ten to twenty small masses, each of which has a separate duct. The ducts (ducts of Rivinus) open for the most part on the sublingual mucous fold, but some of them join the submaxillary duct, and one larger tube (duct of Bartholin), which is however frequently wanting, springs from the deeper part of the gland and runs forwards to end either in common with, or close to the duct of Wharton.

and is a composite structure.

SECTION VIII.

RIGHT ORBIT AND SUPERIOR MAXILLARY NERVE.

Directions. The student may examine next the right orbit, and the remaining trunk, superior maxillary, of the fifth nerve.

Directions.

Supposing the right orbit to be untouched, the student may vary the dissection by exposing it from the outer side.

Learn right orbit.

Dissection. For this purpose, first detach the eyelids from the outer half of the orbital margin, and with the handle of the scalpel separate the periosteum from the corresponding part of the wall of the cavity. Then saw vertically through the centre of the upper margin of the orbit, and continue the cut backwards with a chisel to the sphenoidal fissure. Make a farther cut, also with a chisel, (from the inside) along the middle fossa of the base of the skull from the sphenoidal fissure in front to the foramen spinosum behind, and outside the line of the foramen rotundum and foramen ovale. The side of the skull is next to be sawn transversely in front of the petrous part of the temporal bone, so that the incision shall end at the posterior extremity of the cut made in the base. Afterwards the malar bone is to be sawn through into the sphenomaxillary fissure. The piece of the skull, including parts of the frontal, malar, sphenoid, and temporal bones, is now loose, and can be removed with the temporal muscle. If the portion of the roof of the orbit which is left should interfere with the view of the contents of the cavity in the later stages of the dissection, let it be taken away with the bone-forceps.

Open orbit from the outer side.

The description that has been given of the contents of the left orbit (pp. 39, *et seq.*) may be used also for the right side. The following will serve as a guide to the steps of the dissection :—

On removing the periosteum, the external rectus muscle will be at once seen, and its two heads should be defined, with the nerves entering the cavity above and between them. Along the upper border of the muscle the lachrymal nerve and artery are to be followed to the lachrymal gland, and beyond these the levator palpebræ superioris and superior rectus muscles are exposed, as well as the frontal and fourth nerves. When these have been studied, the external rectus, with the lachrymal vessels and nerve, are to be divided in the middle, and the parts thrown forwards and backwards. Then take away the fat from the lenticular ganglion, the

Order of the dissection.

nasal, third and sixth nerves, and the ophthalmic artery at the back of the orbit, and clean the inferior oblique muscle in front as it arches round the eyeball. To see fully the remaining muscles, the course of the ophthalmic artery and nasal nerve, and the lower division of the third nerve, it will be necessary to divide the frontal nerve, the levator palpebræ and superior rectus muscles, and the optic nerve.

Superior
maxillary
nerve.

The superior maxillary division of the fifth nerve, in its course to the face, is placed successively in the skull, the speno-maxillary fossa, and the infraorbital canal.

The beginning of the nerve in the cranium has been already demonstrated (p. 18).

Dissection
in speno-
maxillary
fossa ;

Dissection. In the speno-maxillary fossa the nerve can be partly seen by the dissection already made for the orbit, and its exposure here will be completed by removing the fat, and cutting away more of the great wing of the sphenoid bone, so as to leave only an osseous ring round the nerve at its exit from the skull. In the fossa the student seeks the following offsets,—the orbital branch entering the cavity of the orbit, branches to Meckel's ganglion which descend in the fossa, and the posterior dental branch along the back of the upper jaw.

in floor of
orbit.

To follow onwards the nerve in the floor of the orbit, the contents of the cavity having been taken away, the bony canal in which it lies must be opened to its termination on the face. From the infraorbital canal the anterior and middle dental branches are to be traced downwards for some distance in the bone. The infra-orbital vessels are prepared with the nerve.

Infraorbital
vessels.

Upper max-
illary nerve

passes to
face

through
infraorbital
canal.

The SUPERIOR MAXILLARY NERVE (fig. 25) commences at the Gasserian ganglion (p. 18), and leaves the cranium by the foramen rotundum. The course of the nerve is almost straight to the face, across the speno-maxillary fossa, and along the orbital plate of the upper maxilla through the infraorbital canal. Issuing from the canal by the infraorbital foramen, where it is concealed by the elevator of the upper lip, it ends in infraorbital or facial branches which radiate to the eyelid, nose, and upper lip.

Its branches
are—to
orbit ;

Branches.—*a.* The *orbital* or *temporo-malar branch* ⁽⁴⁾ has already been described (p. 49). Its two divisions have been destroyed on the right side in opening the orbit.

to the nose
and palate ;

b. The *spheno-palatine branches* ⁽³⁾ descend from the nerve in the fossa, and supply the nose and the palate ; they are connected with Meckel's ganglion, and will be dissected with it (SECTION XIV).

to the hinder
teeth and
cheek ;

c. The *posterior dental branch* ⁽⁵⁾ leaves the nerve near the upper jaw. It enters a canal in the maxilla, and supplies branches to the molar teeth and the lining membrane of the antrum ; near the teeth it joins the middle dental branch. Before entering the canal it furnishes one or more offsets to the gum and the mucous membrane of the cheek.

to fore teeth ;

d and *e.* The *middle* and *anterior dental branches* arise together or separately from the trunk in the floor of the orbit, and descend in special canals in the wall of the antrum to end in branches to

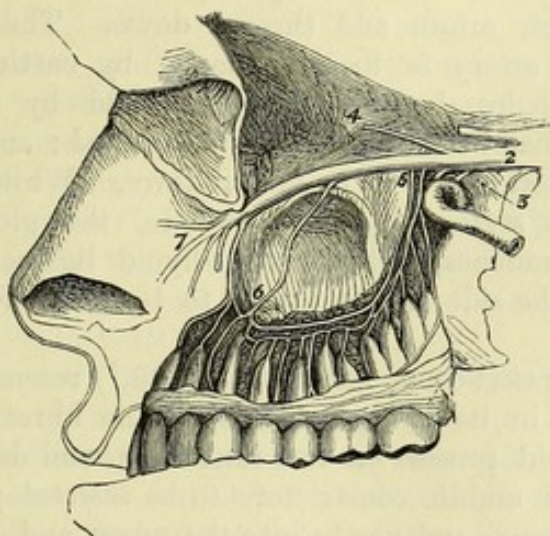
the teeth, after forming loops of communication with one another, and with the posterior dental nerve. From the middle branch filaments are given to the bicuspid teeth; and from the anterior to the canine and incisors, as well as a twig or two to the inferior meatus of the nose.

f. The *palpebral branches* are usually two small twigs which turn upwards round the margin of the infraorbital foramen to reach the lower lid; to lower eyelid;

g. The *lateral nasal branches* are directed inwards, and supply the skin of the side of the nose; to side of nose;

h. The *labial branches*, three or four in number, are larger than the others, and descend to the lip, supplying the skin of the face and to upper lip,

Fig. 25.*



between the orbit and the mouth, as well as the mucous membrane of the upper lip. Their ramifications are crossed by, and communicate with the infraorbital branches of the facial nerve, the whole forming the *infraorbital plexus* (p. 38). joining facial.

The INFRAORBITAL ARTERY is a branch of the internal maxillary (p. 89). Taking the course of the nerve through the infraorbital canal, the vessel appears on the face beneath the elevator muscle of the upper lip; and it ends in branches which are distributed, like those of the nerve, between the eye and mouth. On the face its branches anastomose with offsets of the facial and buccal arteries. In the canal in the maxilla the artery furnishes small twigs to the orbit, and a larger *anterior dental branch* which runs with the nerve of the same name to the incisor and canine teeth: the dental branch also gives offsets to the antrum, and near the teeth it anastomoses with the posterior dental artery. ends in face: branches to orbit, and one to anterior teeth.

The *vein* accompanying the artery communicates in front with the facial vein, and terminates behind in the alveolar plexus (p. 89). Infraorbital vein.

* Diagram of the superior maxillary nerve. 2. Trunk of the nerve leaving the Gasserian ganglion. 3. Spheno-palatine branches. 4. Temporo-malar branch. 5. Posterior dental nerves. 6. Middle and anterior dental. 7. Facial branches.

SECTION IX.

DEEP VESSELS AND NERVES OF THE NECK.

Parts in this section.	In this SECTION are included the deepest styloid muscle, the internal carotid and ascending pharyngeal arteries, and some cranial and sympathetic nerves.
Position of head.	<i>Position.</i> The position of the part is to remain as before, viz., the neck is to be fixed over a small block.
Dissection of the stylo-pharyngeus,	<i>Dissection.</i> To see the stylo-pharyngeus muscle, the posterior belly of the digastric and the stylo-hyoid muscle should be detached from their origin and thrown down. The trunk of the external carotid artery is to be removed by cutting it through where the hypoglossal nerve crosses it, and by dividing those branches of it that have been already examined; any veins accompanying the arteries are to be taken away. While cleaning the surface of the stylo-pharyngeus muscle, the glosso-pharyngeal nerve and its branches, and the stylo-hyoid ligament are also to be prepared. The side of the jaw is to be drawn forwards on the face.
and glosso-pharyngeal nerve.	
Stylo-pharyngeus. Origin.	The STYLO-PHARYNGEUS MUSCLE (fig. 23, ⁵) resembles the other styloid muscles in its elongated form. The fibres <i>arise</i> from the root of the styloid process on the inner side, and descend between the superior and middle constrictors to be <i>inserted</i> partly into the wall of the pharynx, and partly into the upper and hinder borders of the thyroid cartilage.
Insertion.	
Is between carotid arteries.	The muscle lies below the stylo-glossus, and between the carotid arteries; and the glosso-pharyngeal nerve turns over the lower end of its fleshy belly.
Use.	<i>Action.</i> It raises the pharynx, and tends to dilate the part of the cavity above the hyoid bone. From its attachment to the thyroid cartilage it will assist in elevating and drawing backwards the larynx.
Stylo-hyoid ligament	The <i>stylo-hyoid ligament</i> is a fibrous band, which extends from the tip of the styloid process to the small cornu of the hyoid bone.
lies by side of preceding.	Its position is between the stylo-glossus and stylo-pharyngeus muscles, and over the internal carotid artery; while the lower end is placed beneath the hyo-glossus muscle. To its posterior border, the middle constrictor muscle is attached below. It is frequently cartilaginous or osseous in part of, or occasionally in all its extent. Sometimes a slip of fleshy fibres is continued along it.
Internal carotid artery.	The INTERNAL CAROTID ARTERY supplies the deep parts of the head, viz., the brain, the contents of the orbit, and the nose; and takes a circuitous course through and along the base of the skull before it ends in branches to the cerebrum.
Part already seen.	The arterial trunk in the cranium, and its offset to the orbit, have been already learnt; but the portions in the neck and the temporal

bone remain to be dissected. The terminal branches of the carotid are examined with the brain.

Dissection. For the display of the cervical part of the artery (fig. 26) there is now but little dissection required. By detaching the styloid process at the root, and throwing it forwards with its muscles, the internal carotid artery and the jugular vein may be followed upwards to the skull. Only a dense fascia conceals them; and this is to be taken away carefully, so that the branches of the nerves may not be injured.

Dissection
of carotid in
the neck;

In the fascia, and directed forwards over the artery, seek the glosso-pharyngeal nerve and its branches near the skull, and the small pharyngeal branch of the vagus lower down; still lower, the superior laryngeal branch of the vagus, with its external laryngeal offset, crossing beneath the carotid. Between the vein and artery, close to the skull, will be found the vagus, hypoglossal, and sympathetic nerves; and crossing backwards, over or under the vein, the spinal accessory nerve. External to the vessels the loop of the first and second cervical nerves over the transverse process of the atlas is to be defined; and from it branches of communication are to be traced to the large ganglion of the sympathetic beneath the artery, and to the vagus and hypoglossal nerves. Ascending to the cranium, on the inner side of the carotid, the ascending pharyngeal artery will be met with.

and crania
nerves;

To open the carotid canal in the temporal bone, and to follow the contained artery into the cranium, make a cut along the side of the skull in the following manner:—the saw being placed behind the mastoid process, cut forwards to the foramen spinosum in the wing of the sphenoid bone (to which spot the side of the skull has been already taken away), and let the instrument be directed through the stylo-mastoid foramen and the root of the styloid process, but rather external to the jugular foramen and the carotid canal. When the piece of bone has been detached, the carotid canal may be opened with the bone forceps.

in the tem-
poral bone.

In cleaning the artery in the canal, large and rather red branches of the superior cervical ganglion of the sympathetic will be found on it; and in a fresh part two small filaments may be recognised with care,—one from Jacobson's nerve, joining the sympathetic at the posterior part of the canal; the other from the Vidian nerve, at the front of the canal.

Nerves on it.

On the piece of bone that has been cut off, the dissector may obtain a view of the outer part of the tympanum with its membrane and chain of bones, and the chorda tympani nerve.

Tympanum
obtained.

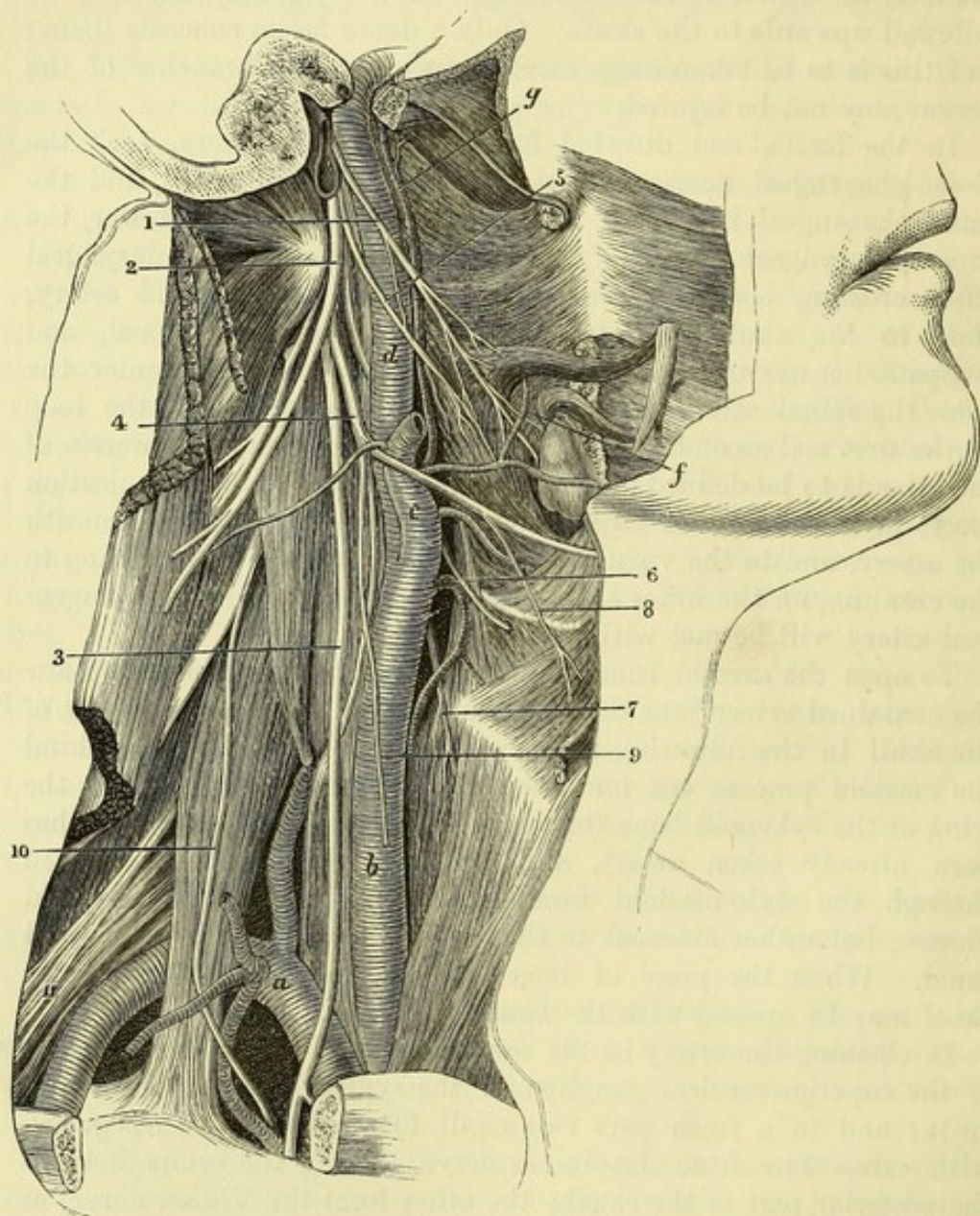
The *internal carotid artery* (fig. 26, *d*) springs from the bifurcation of the common carotid trunk. It extends from the upper border of the thyroid cartilage to the base of the skull; then through the petrous portion of the temporal bone; and lastly along the base of the skull to the anterior clinoid process, where it ends in branches for the brain. This winding course of the artery may be divided into three portions—one in the neck, another in the temporal bone, and a third in the cranium.

Internal
carotid
enters the
skull.

Its course is
first

through the neck; *Cervical part.* In the neck the artery ascends almost vertically from its origin to the carotid canal, and is in contact with the pharynx on the inner side. The line of the common carotid artery

Fig. 26.*



would mark its position in the neck. Its depth from the surface varies like that of the external carotid; and the digastric muscle may be taken as the index of this difference. Thus, below that

less deep
below.

* Deep vessels and nerves of the neck (Illustrations of Dissections).
Arteries: *a.* Subclavian. *b.* Common carotid. *c.* External carotid, cut. *d.* Internal carotid. *f.* Inferior palatine branch of facial. *g.* Ascending pharyngeal.
Nerves: 1. Glossopharyngeal. 2. Spinal accessory. 3. Pneumo-gastric or vagus. 4. Hypoglossal. 5. Pharyngeal branch of vagus. 6. Upper laryngeal branch of vagus. 7. External laryngeal branch of the last. 8. Thyro-hyoid branch of hypoglossal. 9. Descendens noni, cut. 10. Phrenic. 11. Brachial plexus. Recurrent of the vagus winds round the subclavian artery, *a.*

muscle, the internal carotid is overlapped by the sterno-mastoid and covered by the common integuments, fascia, and platysma, and is on the same level as the external carotid, though farther back. But above that muscle, the vessel is placed deeply beneath the external carotid artery and the parotid gland, and is crossed by the styloid process and the stylo-pharyngeus muscle. While in the neck, the internal carotid lies on the rectus capitis anticus major muscle, which separates it from the vertebræ.

but very deep above;

rests on rectus.

Vein. The internal jugular vein accompanies the artery, being contained in a sheath with it, and placed on the outer side.

Position of vein,

Small vessels. Below the digastric muscle the occipital artery is directed back over the carotid; and the offset from it to the sterno-mastoid may run down on the carotid trunk. Above the digastric the posterior auricular artery crosses the internal carotid.

of vessels,

Nerves. The pneumo-gastric is contained in the sheath between the artery and vein, being parallel to them; and the sympathetic, also running longitudinally, lies behind the sheath of the vessels. Crossing the artery superficially, from below up, are the hypoglossal, which sends the descendens noni downwards along the vessel; next the pharyngeal branch of the vagus; and lastly the glosso-pharyngeal. Directed inwards beneath the carotid is the superior laryngeal nerve, furnishing the external laryngeal branch, together with pharyngeal offsets of the upper ganglion of the sympathetic. Close to the skull, the cranial nerves of the neck are interposed between the artery and the vein. Around the carotid entwine branches of the sympathetic, and offsets of the glosso-pharyngeal nerve.

of nerves.

The cervical portion of the artery remains much the same in size to the end, though it is sometimes very tortuous; and it usually does not furnish any branch.

Part in the temporal bone. In the carotid canal the winding course of the vessel commences. The artery first ascends in front of the cochlea and tympanum; next it is directed forwards almost horizontally; and lastly it turns upwards into the cranium through the foramen lacerum. Branches of the sympathetic nerve surround the carotid in the bone.

Part in temporal bone.

While in the canal the artery supplies a small branch to the cavity of the tympanum.

Offset to the tympanum.

The *cranial part* of the artery is described with the base of the skull (p. 19).

Cranial part.

The INTERNAL JUGULAR VEIN is continuous with the lateral sinus of the skull, and extends from the jugular foramen nearly to the first rib. Behind the inner end of the clavicle it joins the subclavian to form the innominate vein (p. 71).

Internal jugular vein joins subclavian;

As far as the thyroid cartilage the vein accompanies the internal carotid, but below that point it is the companion to the common carotid artery; and it lies on the outer side of each. Its contiguity to the artery is not equally close throughout, for near the skull there is a small interval between them, containing the cranial nerves; and at the lower part of the neck there is a larger intervening space (p. 76), in which the pneumo-gastric nerve, with its cardiac branch, is found.

is outside carotids.

Size.	The size of the vein remains much the same from the skull to the
Enlarged below hyoid bone.	hyoid bone, where it is suddenly increased owing to the junction of a number of tributaries corresponding to branches of the external carotid artery. Its lower dilatation and its valve have been before referred to (p. 76).
Branches.	The following <i>branches</i> open into the internal jugular, viz., the inferior petrosal sinus close below the skull, the pharyngeal, lingual, facial and superior thyroid veins near the hyoid bone, and the middle thyroid vein opposite the lower part of the larynx.
Ascending pharyngeal artery	The ASCENDING PHARYNGEAL ARTERY (fig. 26, <i>g</i>) is a long slender branch of the external carotid, which arises near the beginning of that vessel. It runs upwards between the internal carotid artery and the pharynx to near the base of the skull, where it ends in pharyngeal and meningeal branches. Its offsets are numerous, but small :—
ends at skull.	
Branches are prevertebral,	<i>a.</i> One or more <i>prevertebral branches</i> pass to the longus colli and recti antici muscles, supplying also the nerves and lymphatic glands of this region.
pharyngeal,	<i>b.</i> <i>Pharyngeal branches</i> supply the wall of the pharynx, the soft palate and the tonsil. The highest of these, one of the terminal branches of the artery, ramifies in the superior constrictor, the Eustachian tube, and the levator and tensor palati muscles: this branch is sometimes large and furnishes the inferior palatine artery instead of the facial (p. 79).
and meningeal.	<i>c.</i> The <i>meningeal branches</i> enter the skull through the foramen lacerum, the jugular foramen and the anterior condylar foramen (p. 16). These arteries are seldom injected.
	The <i>pharyngeal veins</i> form a plexus which empties itself into the internal jugular trunk.
Directions concerning small branches of the nerves.	<i>Dissection of the cranial nerves in the neck.</i> By the time this stage of the dissection has been arrived at, the condition of the parts will not permit the tracing of the very minute filaments of the cranial nerves in the jugular foramen, and all the paragraphs marked with an asterisk are therefore to be omitted for the present. Afterwards, if a fresh piece of the skull can be obtained, in which the bone has been softened by acid and the nerves hardened in spirit, the examination of the branches now passed over may be made.
Dissection to open jugular foramen.	* <i>In the jugular foramen.</i> Supposing the dissection of the internal carotid to be carried out as it is described at page 103, let the student cut across with care the jugular vein near the skull. Let him then remove bit by bit with the bone forceps, or with a scalpel if the part has been softened, the ring of bone which bounds externally the jugular foramen, proceeding as far forwards as the osseous crest between that foramen and the carotid canal. Between the bone and the coat of the jugular vein, the small auricular branch of the pneumo-gastric nerve is to be found; it is directed backwards to an aperture near the styloid process.
Follow spinal accessory and pneumo-gastric;	* Trace then the spinal accessory and pneumo-gastric nerves through the aperture, by opening the fibrous sheath around them. Two parts, large and small, of the spinal accessory nerve should

be defined ; the latter is to be shown joining a ganglion on the vagus, and applying itself to the trunk of that nerve. A communication between the two pieces of the spinal accessory is to be found. On the pneumo-gastric is a small well-marked ganglion, from which the auricular branch before referred to takes origin ; and from the ganglion filaments are to be sought passing to the smaller portion of the spinal accessory nerve, and to the ascending branch of the upper cervical ganglion of the sympathetic.

* Next follow the glosso-pharyngeal nerve through the fore part of the foramen, and take away any bone that overhangs it. This nerve presents two ganglia as it passes from the skull (fig. 27) : one jugular), which is scarcely to be perceived, near the upper part of the tube of membrane containing it ; the other, much larger (petrous), is situate at the hinder border of the petrous portion of the temporal bone. From the lower one, seek the small nerve of Jacobson, which enters an aperture in the crest of bone between the jugular foramen and the carotid canal, and another filament of communication with the ganglion of the sympathetic. Sometimes the dissector will be able to find a filament from the lower ganglion to join the auricular branch of the pneumo-gastric, and another to end in the upper ganglion of the pneumo-gastric nerve.

Below the foramen of exit from the skull, the cranial nerves have been for the most part denuded by the dissection of the internal carotid ; but the intercommunications of the vagus, hypoglossal, sympathetic, and first two spinal nerves, near the skull, are to be traced out more completely.

The larger part of the spinal accessory has been sufficiently laid bare already ; but its small piece is to be traced to the vagus close to the skull, and onwards along that trunk.

The chief part of the glosso-pharyngeal has also been dissected ; but the offsets on the carotid, and others to the pharynx in front of the artery are to be defined.

On the pneumo-gastric trunk the student will find an enlargement close to the skull (ganglion of the trunk), to which the hypoglossal nerve is intimately united. From the ganglion proceed two branches (pharyngeal and laryngeal), which are to be traced to the parts indicated by their names, especially the first which enters the pharyngeal plexus. The task of exposing the ramifications of the branch of the vagus, and those of the glosso-pharyngeal and sympathetic in the plexus, is by no means easy, in consequence of the dense tissue in which they are contained. Two or more cardiac offsets of the vagus, one at the upper and another at the lower part of the neck, may be recognised readily. Lastly, the dissector may prepare more fully the recurrent branch coursing up beneath the lower end of the common carotid : by removing the fat around it, offsets may be seen passing to the chest and the windpipe.

Only the first, or the deep part of the hypoglossal nerve remains to be made ready for learning ; its communications with the vagus, sympathetic, and the spinal nerves are to be shown.

A dissection for the sympathetic will be given farther on

afterwards
glosso-pharyngeal

and its
branches.

Dissection
of the nerves
in the neck :

of spinal
accessory ;

of glosso-pharyngeal ;

of vagus ;

pharyngeal
plexus,

cardiac
offsets,

and recur-
rent ;

of hypo-
glossal ;

of sympa-
thetic in
part.

(p. 113); but its large ganglion near the skull (upper cervical) should be cleaned, and the branches from it to the pharyngeal plexus should be pursued beneath the carotid artery.

Ninth, tenth
and eleventh
nerves.

The *ninth, tenth, and eleventh cranial nerves* (glosso-pharyngeal, pneumo-gastric, and spinal accessory) leave the cranium together by the jugular foramen (p. 19), from which circumstance they were formerly grouped together as one nerve—the eighth nerve of Willis. Outside the skull the nerves take different directions to their destination; thus the glosso-pharyngeal is inclined forwards to the tongue and pharynx; the spinal accessory backwards to the sterno-mastoid and trapezius muscles; and the pneumo-gastric nerve descends to the viscera of the thorax and abdomen.

Glosso-pharyngeal
nerve

The GLOSSO-PHARYNGEAL NERVE (fig. 27,¹) is the smallest of the three trunks. In the jugular foramen it is placed somewhat in front of the other two, and lies in a groove in the hinder border of the petrous part of the temporal bone. In the aperture of exit the nerve is marked by two ganglionic swellings, the upper one being the jugular, and the lower the petrous ganglion.

has two
ganglia in
foramen.

Its upper

The *jugular ganglion* (⁴) is very small, and is situate at the upper end of the osseous groove containing the nerve. It includes only the outer fibres of the nerve, and is not always to be recognised.

and lower
ganglion.

The *petrous ganglion* (⁵) is much larger, and encloses all the fibrils of the nerve. Ovalish in form, it is placed in a hollow in the posterior border of the temporal bone; and from it spring the branches that unite the glosso-pharyngeal with other nerves.

In the neck

After the nerve has quitted the foramen, it comes forwards between the jugular vein and the carotid artery (fig. 26,¹), and descends over the artery until it reaches the hinder border of the stylo-pharyngeus muscle. Then curving forwards, it becomes almost transverse in direction, crosses the stylo-pharyngeus, and finally passes beneath the hyo-glossus muscle, where it ends in branches to the tongue.

courses to
the tongue.

Branches to
join

The *branches* of the glosso-pharyngeal may be classed into those connecting it with other nerves at the base of the skull, and those distributed in the neck.

with others,
viz.,

The *connecting branches* arise from the petrous ganglion; and in this set is the tympanic nerve.

sympathetic
and vagus,

* A filament ascends from the sympathetic nerve in the neck to join the petrous ganglion. Sometimes there is an offset from the ganglion to the auricular branch of the vagus, and another to the upper ganglion of this nerve.

facial and
sympa-
thetic.

* The *tympanic branch* (nerve of Jacobson—fig. 27,⁶) enters the aperture in the ridge of bone between the jugular and the carotid foramina, and ascends by a special canal to the inner wall of the tympanum: its distribution is given with the anatomy of the middle ear (CHAPTER XI).

Distributed
to

Branches for distribution. In the neck the branches are furnished chiefly to the pharynx and the tongue.

pharynx,

a. Pharyngeal branches. Two or three branches, arising from the glosso-pharyngeal nerve as it lies over the carotid artery, descend

to join the pharyngeal branch of the vagus and take part in the formation of the pharyngeal plexus; and one or two smaller twigs penetrate the superior constrictor muscle.

b. A muscular branch enters the stylo-pharyngeus while the nerve is in contact with the muscle. stylo-pharyngeus,

c. The tonsillitic branches supply the tonsil and the arches of the soft palate. On the former they end in a kind of plexus—*circulus tonsillaris*. tonsil,

d. Lingual branches. The terminal branches of the nerve supply the hinder part of the tongue, in connection with which they are described (SECTION XV).

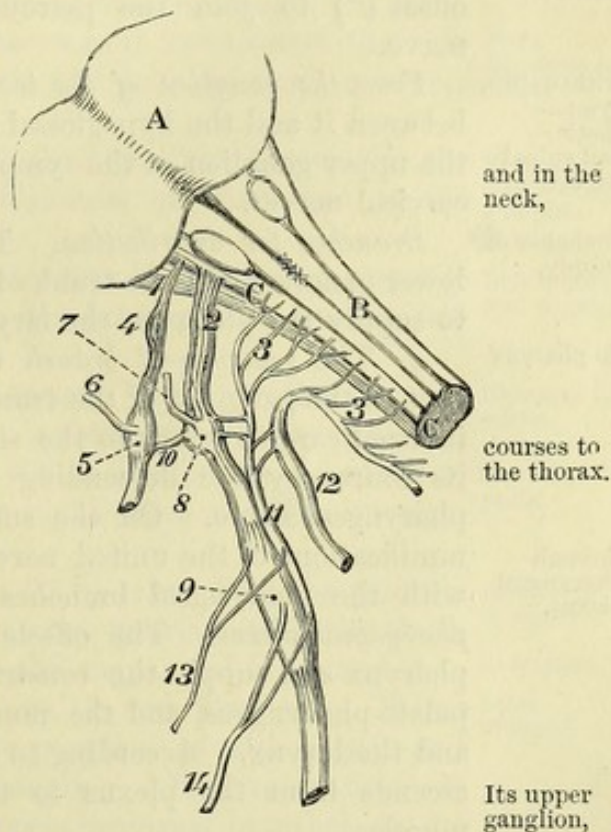
The PNEUMO-GASTRIC OR VAGUS NERVE (fig. 27,²) is the largest Vagus nerve of the cranial nerves in the neck, and escapes through the jugular foramen in the same sheath of dura mater as the spinal accessory. In the foramen it has a distinct ganglion (gang. of the root), to which the smaller part of the spinal accessory nerve is connected.

When the nerve has left the foramen, it receives the small part of the spinal accessory, and swells into a ganglion nearly an inch long (gang. of the trunk). This ganglion lies between the internal carotid artery and jugular vein, and communicates with several nerves. To reach the thorax, the vagus descends almost vertically (fig. 26,³) between the internal jugular vein and the internal and common carotid arteries; and it enters that cavity, on the right side, by crossing over the subclavian artery, but beneath the innominate vein.

* The *ganglion of the root* (fig. 27,⁵) is of a greyish colour, and in texture is like the ganglion on the large root of the fifth nerve. Small branches in the jugular foramen come from this ganglion.

The *ganglion of the trunk* (⁹) is cylindrical in form, reddish in colour, and nearly an inch in length; it communicates with the hypoglossal, spinal, and sympathetic nerves. All the intrinsic fibres of the trunk of the nerve enter the ganglion, but those

Fig. 27.*



* Diagram of the ninth, tenth, and eleventh nerves. A. Pons. B. Medulla oblongata. 1. Glosso-pharyngeal nerve. 2. Vagus. 3, 3. Spinal accessory. 4. Jugular ganglion. 5. Petrous ganglion. 6. Tympanic nerve. 7. Auricular branch. 8. Root-ganglion, and 9. Trunk-ganglion of vagus. 10. Branch joining the petrous and upper ganglion of the vagus. 11. Small part of spinal accessory. 12. Large part of spinal accessory. 13. Pharyngeal, and 14. Superior laryngeal branch of vagus.

derived from the spinal accessory nerve (¹¹) pass over the ganglion without being connected to it.

Branches

The *branches* of the pneumo-gastric nerve arising in the neck may be divided into those uniting it with other nerves, and those distributed to the several organs.

to unite
with others ;

* *Connecting branches* (fig. 27) arise from the ganglia of the root and trunk of the vagus.

auricular
branch ;

* *From the ganglion of the root.* The *auricular branch* (Arnold's nerve,⁷) is the chief offset, and crosses the jugular fossa to enter an aperture near the root of the styloid process : it traverses the substance of the temporal bone, and is distributed to the outer ear. Its farther course will be described with the anatomy of the ear.

with
eleventh,
sympa-
thetic,
ninth ;

* One or two short filaments unite this ganglion with the small part of the spinal accessory nerve ; and a branch from the upper ganglion of the sympathetic enters it. Occasionally there is an offset (¹⁰) to join the petrous ganglion of the glosso-pharyngeal nerve.

with twelfth,
sympa-
thetic,
and spinal
nerves.

From the ganglion of the trunk. Communicating filaments pass between it and the hypoglossal nerve. Other branches connect it to the upper ganglion of the sympathetic and the loop of the first two cervical nerves.

Branches of
supply.

Branches for distribution. The cervical branches arise from the lower ganglion and the trunk of the nerve, and are directed inwards, to supply the pharynx, the larynx, and the heart.

To pharynx

a. The *pharyngeal branch* (fig. 27,¹³) springs from the upper part of the ganglion of the trunk, and is directed inwards over the internal carotid artery to the side of the pharynx, being joined in its course by the descending pharyngeal branches of the glosso-pharyngeal nerve. On the surface of the middle constrictor, the ramifications of the united nerves communicate freely together, and with the pharyngeal branches of the sympathetic, to form the *pharyngeal plexus*. The offsets of the plexus enter the wall of the pharynx and supply the constrictor muscles, the palato-glossus and palato-pharyngeus, and the mucous membrane between the mouth and the larynx. According to Luschka, Henle, and others, a branch ascends from the plexus to the levator palati and azygos uvulæ muscles.

through
pharyngeal
plexus.

Upper
branch to
larynx,

b. The *superior laryngeal nerve* (fig. 27,¹⁴) is much larger than the preceding branch, and comes from the middle of the ganglion of the trunk. It runs obliquely downwards and forwards, passing on the inner side of the internal and external carotids (fig. 26,⁶), to the interval between the hyoid bone and the thyroid cartilage. Here it perforates the thyro-hyoid membrane, and divides into branches for the supply of the mucous membrane of the larynx (SECTION XVI). While beneath the internal carotid artery it furnishes the following offset :—

its external
offset.

The *external laryngeal branch* (fig. 26,⁷) descends on the inferior constrictor muscle to the side of the larynx, and then beneath the sterno-thyroid to the crico-thyroid muscle in which it ends. Near its origin it gives off a filament to join the upper cardiac branch of

the sympathetic ; and lower down it supplies twigs to the inferior constrictor.

c. Cardiac branches. One or two small cardiac nerves spring from the pneumo-gastric at the upper part of the neck, and join cardiac branches of the sympathetic. At the lower part of the neck, on each side, there is a larger cardiac nerve which descends into the thorax :—the right one joins the deep nerves to the heart from the sympathetic ; and the left terminates in the superficial cardiac plexus.

Branches to the heart, upper and lower.

d. The inferior or recurrent laryngeal nerve leaves the pneumo-gastric trunk on the right side opposite the subclavian artery, and winding round that vessel, takes an upward course in the neck to the larynx, ascending beneath the common carotid and inferior thyroid arteries, along the groove between the trachea and the œsophagus. At the larynx it enters beneath the ala of the thyroid cartilage, where it will be afterwards traced. The following branches arise from it :—

Lower branch to larynx

Some *cardiac branches* leave the nerve as it turns round the subclavian artery ; these enter the thorax, and join the cardiac nerves of the sympathetic.

gives branches to heart,

Tracheal and œsophageal branches spring from it as it ascends in the neck ; and near the larynx some filaments are furnished to the inferior constrictor muscle.

to trachea, œsophagus, and pharynx.

On the left side the recurrent nerve arises in the thorax, opposite the arch of the aorta ; in the neck it lies between the trachea and œsophagus, as on the right side.

Left recurrent nerve.

The SPINAL ACCESSORY NERVE courses through the jugular foramen with the pneumo-gastric, but is not marked by any ganglion. The nerve is composed of two parts, viz., a smaller one, accessory to the vagus, and a larger, spinal part, which have a different origin and distribution.

Eleventh nerve

has two parts.

The *part accessory to the vagus* (fig. 27,¹¹) arises from the medulla oblongata, and ends by joining the pneumo-gastric outside the skull. In the foramen of exit it lies close to the vagus, and is connected to the upper ganglion of that nerve by one or two filaments. Below the foramen it passes over the lower ganglion of the vagus, and blends with the trunk beyond that ganglion. It gives distinct offsets to join the pharyngeal and upper laryngeal branches of the pneumo-gastric ; and other fibres are continued into the cardiac and inferior laryngeal branches.

Accessory to vagus

in foramen : below foramen.

The *spinal part* (fig. 27,¹²), which takes its origin from the spinal cord, is much larger, and is connected with the smaller piece while passing through the jugular foramen. Beyond the foramen the nerve (fig. 26,²) takes a backward course through the sterno-mastoid, and across the side of the neck to end in the trapezius : at first it is concealed by the jugular vein, but it then passes either over or under that vessel. The connections of the nerve beyond the sterno-mastoid have been already examined (p. 56).

Spinal part in foramen :

in the neck

crosses to trapezius,

The nerve furnishes muscular offsets to the sterno-mastoid and the trapezius.

supplies muscles.

The HYPOGLOSSAL NERVE, issuing from the cranium by the

Twelfth nerve :

anterior condylar foramen, is at first deeply placed between the internal carotid artery and the jugular vein (fig. 26⁴). It next comes forwards between the vein and artery, turning round the outer side of the vagus to which it is closely united. The nerve now descends in the neck, and becomes superficial below the digastric muscle in the anterior triangular space (p. 77) ; from this spot it is directed forwards to the tongue and its muscles (p. 98).

branches
join it to
vagus,

Connecting branches. Near the skull the hypoglossal is united to the lower ganglion of the vagus by filaments crossing between the two nerves as they are in contact.

sympa-
thetic, and
spinal
nerves,
and supply
muscles.

A little lower down the nerve is joined by offsets from the sympathetic and the loop of the first two spinal nerves.

The *branches for distribution* have been met with in the foregoing dissections. Thus, in the neck it supplies, in common with the spinal nerves, the depressors of the hyoid bone. In the sub-maxillary region it furnishes branches to one elevator (genio-hyoid) of the hyoid bone, to the extrinsic muscles of the tongue except the palato-glossus, and to all the intrinsic muscles of the tongue.

Dissection
of rectus
lateralis.

Dissection. The small rectus capitis lateralis muscle, between the transverse process of the atlas and the base of the skull, is now to be cleaned and learnt. At its inner border the anterior branch of the first cervical nerve, which forms a loop in front of the atlas, is to be found.

Rectus
lateralis.

The RECTUS CAPITIS LATERALIS (fig. 26) is very short, and represents a posterior intertransverse muscle. It *arises* from the fore and upper part of the transverse process of the atlas, and is *inserted* into the jugular process of the occipital bone.

Parts
around.

On the anterior surface rests the jugular vein ; and in contact with the posterior are the obliquus superior and the vertebral artery. To the inner side lie the anterior primary branch of the first cervical nerve and the rectus anticus minor muscle.

Use.

Action. It assists the muscles attached to the mastoid process in inclining the head laterally.

Dissection
of first
nerve.

Dissection. For the purpose of tracing backwards the anterior branch of the first cervical nerve, divide the rectus lateralis muscle, observing the offset to it ; then cut off the end of the transverse process of the atlas, and remove the vertebral artery, so as to bring into view the nerve as it lies on the first vertebra.

Anterior
division of
suboccipital
nerve
lies on atlas,

The ANTERIOR PRIMARY BRANCH OF THE FIRST CERVICAL OR SUB-OCCIPITAL NERVE is rather smaller than the posterior, and arises from the common trunk on the neural arch of the atlas. From that spot it is directed forwards above the transverse process, and on the inner side of the vertebral artery, to the interval between the rectus lateralis and rectus anticus minor muscles. Emerging here it bends

forms a loop
with second.

down in front of the transverse process of the atlas and forms a loop with the second cervical nerve. As the nerve passes forwards it supplies the rectus lateralis and anticus minor muscles, and branches connect the loop with the vagus, hypoglossal, and sympathetic nerves.

Branches.

Sympathetic

SYMPATHETIC NERVE. In the neck the sympathetic nerve con-

sists, on each side, of a gangliated cord, which lies close to the vertebral column, and is continued into the thorax. On this portion of the nerve are three ganglia—the superior near the skull, the middle towards the lower part of the neck, and the inferior close to the first rib. From the ganglia proceed connecting branches to the spinal and most of the cranial nerves in the neck, and branches for distribution to viscera and blood-vessels.

nerve in neck
has three ganglia.

Besides the ganglia above mentioned, there are other ganglia in the head and neck, where the sympathetic enters into connection with the three divisions of the fifth nerve.

Other ganglia on fifth nerve.

Dissection. To display the branches of the sympathetic nerve requires greater care than is necessary in tracing the white-fibred nerves, for they are softer, more easily torn, and generally of smaller size. In the neck the ganglia and their branches have been partly prepared, and only the following additional dissection will be required to bring them into view:—The jugular vein having been cut through, the upper ganglion will be seen by raising the carotid artery, and the trunks of the vagus and hypoglossal nerves, and by cutting through the branches that unite these two to the loop between the first and second spinal nerves. The several branches of the ganglion are to be traced upwards on the carotid artery, inwards to the pharynx, down along the neck, and outwards to other nerves.

Dissection of upper ganglion;

The dissector has already seen the middle ganglion on or near the inferior thyroid artery; and its branches to spinal nerves, and along the neck, are now to be traced.

of middle;

To obtain a view of the inferior ganglion the greater part of the first rib is to be taken away, and the subclavian artery is to be cut through, internal to the scalenus, and drawn aside, without however destroying the fine nerves that pass over it. It is supposed that the clavicle has been removed. The ganglion is placed close above the neck of the first rib; its branches are large, and are easily followed outwards to the vertebral artery and the spinal nerves, and downwards to the thorax.

and inferior ganglion.

The SUPERIOR CERVICAL GANGLION is the largest of the three, and is of a reddish-grey colour. Fusiform in shape, it is as long as the second and third cervical vertebræ, and is placed on the rectus capitis anticus major muscle, beneath the internal carotid artery and the contiguous cranial nerves. Branches connect the ganglion with other nerves; and some are distributed to the blood-vessels, the pharynx, and the heart.

Superior ganglion is near skull,

beneath carotid.

Connecting branches unite the sympathetic with both the spinal and the cranial nerves.

Connecting branches

With the spinal nerves. The four highest spinal nerves have branches of communication with the upper ganglion of the sympathetic; but the offset to the fourth nerve may come from the cord connecting the upper to the next ganglion.

with spinal nerves;

With the cranial nerves. Near the skull the lower ganglion of the vagus and the hypoglossal nerve are joined by branches of the sympathetic. Another offset from the upper part of the ganglion

with cranial below skull,

- and in jugular foramen ; ascends to the jugular foramen, and divides into two filaments which join the petrous ganglion of the glosso-pharyngeal and the root-ganglion of the vagus.
- and with some in the skull. Communications are formed with several other cranial nerves by means of the ascending offset from the ganglion into the carotid canal (p. 19).
- Branches. *Branches for distribution.* The branches of this set are more numerous than the preceding, and the nerves are generally of larger size.
- To internal carotid, The *ascending branch*, prolonged from the upper part of the ganglion, accompanies the internal carotid artery and its branches. Near the skull it divides into two pieces which enter the canal for the carotid, one on each side of that vessel, and are continued to the eyeball and the pia mater of the brain, forming secondary plexuses on the ophthalmic and cerebral arteries. In the carotid canal communications are formed with the tympanic nerve (p. 108), and with the sphenopalatine ganglion (p. 142) ; with the former near the lower end, and with the latter near the upper opening of the canal. The communications and plexuses which these nerves form in their course to the brain are described at p. 19.
- which join cranial nerves ;
- to external carotid, *Branches for blood-vessels* (nervi molles). These nerves surround the external carotid trunk, and ramify on its branches so as to form plexuses on the arteries with the same names as the vessels : some small ganglia are occasionally found on these slender nerves. By means of the plexus on the facial artery the submaxillary ganglion communicates with the sympathetic ; and through the plexus on the internal maxillary artery the otic ganglion obtains a similar communication.
- forming plexuses and ganglia ;
- to pharyngeal plexus ; The *pharyngeal nerves* pass inwards to the side of the pharynx, where they join with the branches of the glosso-pharyngeal and pneumo-gastric nerves in the pharyngeal plexus (p. 110).
- to cardiac plexuses ; *Cardiac nerves* enter the thorax to join in the plexuses of the heart. There are three cardiac nerves on each side, viz., superior, middle, and inferior, each taking its name from the ganglion of which it is an offset.
- superficial cardiac nerve. The *superior* or *superficial cardiac nerve* of the right side courses behind the sheath of the carotid vessels, and enters the thorax along the innominate artery. In the neck the nerve is connected with the cardiac branch of the vagus, with the external laryngeal, and with the recurrent nerve. In some bodies it ends by joining one of the other cardiac nerves.
- Middle ganglion. The MIDDLE CERVICAL or THYROID GANGLION is of small size, and is situate beneath the great vessels, usually opposite the sixth cervical vertebra, on or near the inferior thyroid artery. Its branches are the following :—
- joined to spinal nerves *Connecting branches* with the spinal nerves sink between the borders of the longus colli and anterior scalenus, to join the fifth and sixth cervical nerves.
- loop to lower ganglion ; A considerable branch passes between the middle and inferior cervical ganglia, forming a loop (ansa Vieussensii) over the front of the subclavian artery, and supplying it with filaments.

Branches for distribution. These consist of nerves to the thyroid body, together with the middle cardiac nerve. branches of distribution,

The *thyroid branches* ramify around the inferior thyroid artery, and end in the thyroid body; they join the external and recurrent laryngeal nerves. thyroid branches,

The *middle or great cardiac nerve* descends to the thorax across the subclavian artery; its termination in the cardiac plexus will be learnt in the chest. In the neck it communicates with the upper cardiac and recurrent laryngeal nerves. middle cardiac nerve.

The INFERIOR CERVICAL GANGLION is of large size but irregular in shape, and lies over the interval between the first rib and the transverse process of the last cervical vertebra, its position being internal to the superior intercostal artery. Oftentimes it extends in front of the neck of the rib, and joins the first swelling of the knotted cord in the thorax. Its branches are similar to those of the other two ganglia. Inferior ganglion
on neck of first rib.

Connecting branches join the last two cervical nerves. Other nerves accompany the vertebral artery, forming the *vertebral plexus* around it, and communicating with the cervical nerves. Branches to spinal nerves and vertebral artery; and inferior cardiac.

Only one branch for distribution, the *inferior cardiac nerve*, issues from the lower ganglion. It lies beneath the subclavian artery, joining in that position the recurrent laryngeal nerve, and enters the thorax to terminate in the deep cardiac plexus behind the arch of the aorta.

Directions. The student now proceeds to dissect the left side of the neck, but the remains of the right half should be carefully preserved during the time occupied in the examination of the left half. Directions.

SECTION X.

DISSECTION OF THE LEFT SIDE OF THE NECK.

Directions. In the dissection of the left half of the neck, the differences between it and the right side are specially to be studied. When the description of the right side will suffice, reference will be only made to it. Directions.

After the neck has been made tense over a narrow block, the anterior part of it is to be prepared as on the opposite side. The description of the right side (pp. 58 to 65) is to be used for the anterior triangular space, the sterno-mastoid, and the depressor muscles of the hyoid bone. Dissection of anterior triangle of neck;

Next the scaleni muscles and the subclavian vessels are to be learnt. The dissection and description of the muscles on the right side (pp. 65 to 67) will serve for those on the left, except that the student will meet on the left side with the thoracic duct. of scaleni, and subclavian artery;

The thoracic duct arches over the part of the subclavian artery internal to the scalenus muscle. If it is uninjected it looks like a of thoracic duct.

vein, rather flattened, and smaller than a crow-quill ; and it will be found about half an inch above the clavicle, crossing behind the internal jugular vein, and then bending downwards to end in the angle between the latter and the subclavian vein.

On this side the clavicle is to remain articulated, in order that the joint may afterwards be studied.

Left
subclavian
artery
differs much
from right
subclavian

The LEFT SUBCLAVIAN ARTERY arises from the arch of the aorta, instead of from an innominate trunk, and ascends thence over the first rib in its course to the upper limb. With this difference on the two sides in the origin of the subclavian—the one vessel beginning opposite the sterno-clavicular articulation, the other in the thorax—it is evident that the length and relations of the part of the artery on the inner side of the scalenus anticus must also differ on the two sides.

in the first
part.

First part. The part of the artery internal to the anterior scalenus is much longer on the left than the right side. It ascends nearly vertically from its origin to the level of the first rib, and then bends somewhat abruptly outwards over the top of the lung. On leaving the chest it is deeply placed in the neck, near the spine and the œsophagus, and does not rise usually so high above the first rib as the right subclavian.

Relations
to sur-
rounding
parts.

Between the artery and the surface are structures like those on the right side, viz., the integuments with the platysma and deep fascia, and the sterno-mastoid, hyoid, and thyroid muscles. To the inner side are the œsophagus and the thoracic duct ; and the pleura is in contact with the outer and posterior surfaces. Its relations lower in the chest are described in the dissection of the thorax.

Veins.

Veins. The internal jugular and vertebral veins, as well as the beginning of the innominate, are in front of this part of the artery.

Position of
nerves.

Nerves. The pneumo-gastric nerve lies parallel to the vessel instead of across it as on the right side ; and the phrenic nerve crosses over it close to the scalenus. Accompanying the artery are the cardiac branches of the sympathetic, which course along its inner side to the chest.

Rest of
artery.

The *second* and *third parts* of the artery, viz., beneath and beyond the scalenus, are essentially the same as on the right side (p. 68).

Branches
resemble
those of
right vessel.

The *branches* of this artery resemble so closely those of the right trunk, that one description will serve for both (pp. 69 to 71). It may be remarked that the superior intercostal of the left side is usually internal to, instead of beneath the scalenus as on the right side ; in other words, this branch arises sooner.

Thoracic
duct

The THORACIC DUCT (fig. 28,^s) conveys the chyle and lymph of the greater part of the body into the venous circulation. Escaping from the thorax on the left side of the œsophagus, the duct ascends in the neck as high as the seventh cervical vertebra. At the spot mentioned it issues from beneath the carotid artery and the internal jugular vein, arching outwards and downwards above or over the subclavian artery, and in front of the anterior scalenus muscle and phrenic nerve, to open into the angle of junction of the subclavian

comes from
the thorax

and joins
veins.

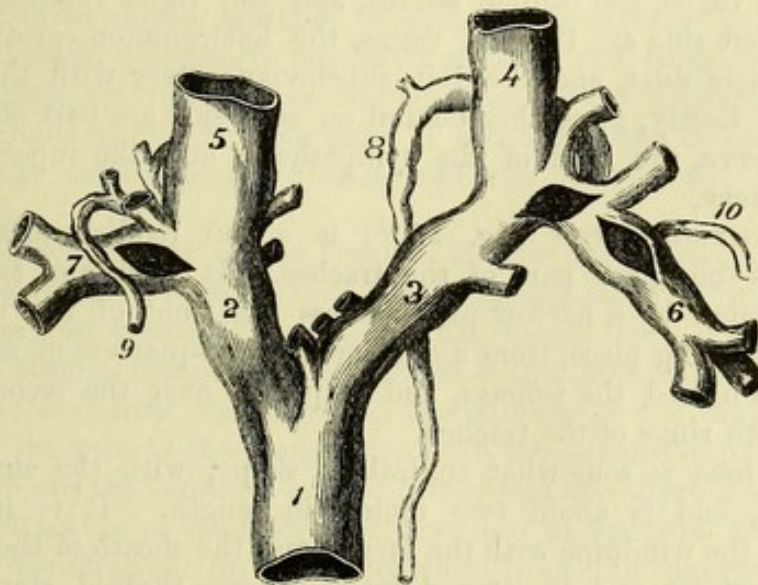
with the internal jugular vein. Double valves, like those of the Valves.
veins, are present in the interior of the tube; and a pair guards
the opening into the posterior part of the vein. Frequently the Frequent
upper part of the duct is divided; and there may be separate variety.
openings into the large veins corresponding with those divisions.

Large lymphatic vessels from the left side of the head and neck, Branches.
and from the left upper limb, open into the upper part of the duct,
and sometimes separately into the veins ⁽¹⁰⁾.

Examine next the brachial and cervical plexuses, using the de- Spinal
scription of the right side (pp. 71 to 74). nerves.

COMMON CAROTIDS. On opposite sides these vessels have differ- Difference in
ences like those between the right and left subclavian arteries; for origin of
right and
left carotids.

Fig. 28.*



the left vessel arises from the arch of the aorta, and is therefore longer than the right, and contained partly in the chest. The description of the artery between its origin and the top of the sternum will be included in the dissection of the thorax.

Beyond the sterno-clavicular articulation, the vessels on both In the neck
sides so nearly resemble one another that the same description
may serve for the two (p. 74). On the left side, however, the difference
jugular vein and the pneumo-gastric nerve are nearer to the carotid in vein and
than on the right side, and are sometimes placed over the artery, nerve.
in the lower third of the neck.†

PARTS IN THE UPPER APERTURE OF THE THORAX. The relative Parts in the
aperture of
thorax.

* Diagram of the ending of the right lymphatic duct and the thoracic duct in the veins. 1. Upper vena cava. 2. Right, and 3. Left innominate vein. 4. Left, and 5. Right internal jugular. 6. Left, and 7. Right subclavian vein. 8. Thoracic duct. 9. A lymphatic trunk joining the right lymphatic duct, as this is about to end in the subclavian vein. 10. A lymphatic trunk opening separately into the left subclavian vein.

† Occasionally these differences will be reversed—the vein and nerve being close to the artery on the right side, and away from it on the left.

position of the several parts entering or leaving the thorax by the upper opening may be now observed.

In middle line.

In the middle line lie the remains of the thymus gland, and the trachea and œsophagus. In front of the trachea are the lower ends of the sterno-hyoid and sterno-thyroid muscles with layers of the cervical fascia, and the inferior thyroid veins; and behind the gullet and windpipe are the longi colli muscles. Between the two tubes is the recurrent nerve on the left side.

On each side:

partly the same on both sides, and partly different.

On each side the dome of the pleura and the apex of the lung project into the neck; and in the interval between the pleura and the trachea and œsophagus, are placed the vessels and nerves passing between the thorax and the neck. Most anteriorly on both sides lie the innominate vein, the phrenic nerve, and the internal mammary artery; but the vessels and nerves next met with are different on the two sides:—On the right side come the innominate artery, with the vagus, the cardiac nerves, and the right lymphatic duct. On the left side are the left vagus, the left common carotid artery, the thoracic duct, and the left subclavian artery with the cardiac nerves. Lastly, altogether behind on each side are part of the first dorsal nerve, the cord of the sympathetic, and the superior intercostal artery.

Thyroid body consists of two lobes and a cross piece.

The THYROID BODY (fig. 16,¹²) is a soft reddish mass, which embraces the upper part of the trachea. It consists of two lateral lobes, united by a narrow piece across the front of the windpipe. The connecting piece, from a quarter to three-quarters of an inch in depth, is named the *isthmus*, and is placed over the second, third, and fourth rings of the trachea.

Relations and

extent of lobes.

Each lobe is somewhat conical in shape, with the smaller end upwards, and is about two inches in length. It is interposed between the windpipe with the larynx and the sheath of the common carotid artery, and is covered by the sterno-thyroid, sterno-hyoid, and omo-hyoid muscles. The extent of the lobe varies; but usually it reaches as high as the middle of the thyroid cartilage, and as low as the sixth ring of the trachea.

Middle lobe or pyramid.

From the upper border of the thyroid body, a conical process, known as the *pyramid*, often ascends towards the hyoid bone, to which it is attached by a fibrous band. The pyramid generally springs from the inner part of one of the lateral lobes, seldom from the isthmus; and it is sometimes connected to the hyoid bone by a slip of muscle, the *levator glandulæ thyroideæ* of Sæmmerring.

Accessory glands.

Detached portions of glandular substance, or *accessory thyroid glands*, are not unfrequently found between the main body and the hyoid bone.

Weight and size.

The thyroid body is of a brownish red or purple hue, is granular in texture, and weighs from one to two ounces. It is larger in the woman than in the man. On cutting into the gland a viscid yellowish fluid escapes. It has not any excretory tube or duct.

No duct.

Arteries,

superior,

The *arteries* of the thyroid body are two on each side—superior and inferior thyroid. The branches of the external carotids (superior thyroid) ramify chiefly on the anterior aspect: while those from

the subclavians (inferior thyroid) pierce the deep surface of the inferior, mass.

Occasionally there is a third branch (*art. thyroidea ima*) which arises from the innominate artery in the thorax, and ascending in front of the trachea assists in supplying the thyroid body. and sometimes lowest thyroid.

The *veins* are large and numerous; they are superior, middle, and inferior thyroid on each side. The first two enter the internal jugular vein (p. 76). The *inferior thyroid veins* issue from the lower part of the thyroid body, and descend on the trachea, forming a plexus on that tube beneath the sterno-thyroid muscles; they enter finally the innominate veins. Veins. Inferior, form a plexus on trachea.

The TRACHEA, or windpipe, is continued from the larynx to the thorax, and ends by dividing into two tubes (bronchi), one for each lung. It occupies the middle line of the body, and extends commonly from the lower part of the sixth cervical to the lower border of the fourth dorsal vertebra, measuring about four inches and a half in length, and nearly one in breadth. The front and sides of the trachea are rounded in consequence of the existence of firm cartilaginous bands in those parts of the wall; but at the posterior aspect the cartilages are absent, and the wall is flat and membranous. Trachea lies in neck and thorax. Size. Form.

The cervical part of the trachea is very moveable, and has the following relative position to the surrounding parts. Covering it in front are the depressor muscles of the hyoid bone, with the deep cervical fascia: beneath those muscles is the inferior thyroid plexus of veins; and near the larynx is the isthmus of the thyroid body. Behind the tube is the œsophagus, with the recurrent nerves. On each side are the common carotid artery and the thyroid body. Cervical part is amongst muscles and vessels.

The structure of the trachea is described in SECTION XVII.

The ŒSOPHAGUS, or gullet, reaches from the pharynx to the stomach. It commences, like the trachea, opposite the lower part of the sixth cervical vertebra, and ends opposite the tenth dorsal vertebra. The tube reaches through part of the neck, and through the whole of the thorax. Its length is about nine inches. Œsophagus occupies neck and thorax. Length.

In the neck its position is behind the trachea till near the thorax where it projects to the left side of the airtube, and touches the thyroid body and the thoracic duct. Behind the œsophagus are the longi colli muscles. On each side is the common carotid artery, the proximity of the left being greater, in consequence of the projection of the œsophagus towards that side. Position in neck, and relations.

The structure of the œsophagus will be examined in the dissection of the thorax.

Directions. The dissector may learn next the digastric and stylohyoid muscles, with the hypoglossal nerve (p. 76). Afterwards he may take the trunk of the external carotid, with the following branches,—superior thyroid, facial, occipital, posterior auricular, and superficial temporal (pp. 77 to 81). Muscles and vessels in anterior triangle.

The dissector is not to examine now the pterygo-maxillary or submaxillary regions on the left side, because such a proceeding would interfere with the subsequent dissections. Before learning the Regions to be omitted.

pharynx he should lay bare, on this side, the middle and inferior ganglia of the sympathetic with their branches.

Dissection
of sympa-
thetic,

Dissection. For the display of the two lower ganglia of the sympathetic and their branches, it will be necessary to take away the great blood-vessels by cutting them across at the lower part of the neck, and near the digastric muscle. In removing the vessels, care must be taken of the sympathetic beneath them.

viz., middle
and lower
ganglia.

The middle ganglion must be sought in the fat and areolar tissue near the inferior thyroid artery; and the inferior one will be seen above the neck of the first rib, after the subclavian artery has been divided. The upper cardiac nerve may be found descending beneath the carotid sheath.

Reserve
sterno-
clavicular
joint.

The upper end of the sternum with the attached clavicle is to be taken away next, by cutting through the middle of the first rib; and the piece of bone is to be put aside for the subsequent examination of the sterno-clavicular articulation.

Ganglia of
sympathetic
nerve.

The *middle* and *inferior cervical ganglia* of the sympathetic nerve are so similar to the corresponding ganglia of the right side, that the same description will suffice (p. 114).

Cardiac
nerves.

The *cardiac nerves* are three in number on the left as on the right side, viz., superior, middle, and inferior, but they present some differences.

Upper.

The *superior cardiac nerve* has a similar course in the neck on both sides; but the left in entering the chest lies between and parallel to the carotid and subclavian arteries, and it ends in the superficial cardiac plexus.

Middle.

The *middle cardiac nerve* unites frequently with the next, and passes beneath the subclavian artery to the deep cardiac plexus.

Lower

The *inferior cardiac nerve* is generally a small branch, which enters the thorax conjoined with the preceding, to end in the deep cardiac plexus.

SECTION XI.

DISSECTION OF THE PHARYNX.

Directions.

The pharynx can be examined only when it has been separated from the back of the head and the spinal column; and it will therefore be necessary to cut through the base of the skull in the manner indicated below, so as to have the anterior half, with the pharynx connected to it, detached from the posterior half.

Detach
pharynx
from spine,

Dissection. The block being removed from beneath the neck, the head is to be placed downwards, so that it may stand on the cut edge of the skull. Next the trachea and œsophagus, together with the vagus and sympathetic nerves, are to be cut near the first rib, and all are to be separated from the spine as high as the basilar process of the occipital bone, but without injuring, on the left side, the vessels and nerves near the skull.

For the division of the skull turn upwards the inner surface of

the base, and make the following incisions in the posterior fossa. On the right side a cut, with the chisel, is to be carried along the line of union of the petrous part of the temporal with the occipital bone. On the left side another cut with the chisel is to be made in the same direction, but through the occipital bone internal to the jugular foramen and the inferior petrosal sinus; this is to begin rather behind that foramen, and to end opposite the one on the other side. The skull is then to be sawn through vertically on the left side close behind the mastoid process, so that the incision shall meet the posterior end of the cut made with the chisel.

cut base of skull partly from inside,

saw left side of skull,

Finally, placing the skull again upside down, let the student cut through the basilar process of the occipital bone between the attachments of the pharynx and the muscles of the spinal column, the chisel being directed backwards. The base of the skull is now divided into two parts (one having the pharynx attached to it, the other articulating with the spine), which can be readily separated with a scalpel.

and chisel through the basilar process;

then cut soft parts.

The spinal column with the piece of the occipital bone connected with it should be set aside, and kept for after examination.

Preserve piece of spine.

Dissection of the pharynx (fig. 29). Let the student take the anterior part of the divided skull, and, after moderately filling the pharynx with tow, fasten it with hooks on a block, so that the œsophagus may be pendent and towards him.

Fasten pharynx.

On the left side of the pharynx a different view from that of the right side may be obtained of the cranial and sympathetic nerves near the skull (p. 108), when some loose areolar tissue and the styloid process with its muscles have been removed: if the lower ends of the nerves are fixed with pieces of thread, they can be more easily displayed.

Dissect nerves on left side,

Afterwards the dissector may proceed to remove the fascia from the constrictor muscles of the right side (fig. 29), in the direction of the fibres,—these radiating from the side to the middle line. The margins of the two lower constrictor muscles (middle and inferior) are to be defined. Beneath the lower one, near the larynx, will be found the recurrent nerve with vessels; between the inferior and middle are the superior laryngeal nerve and vessels; and the stylo-pharyngeus muscle disappears beneath the upper border of the middle constrictor.

then muscles, viz.,

lower and middle constrictor,

To see the attachment of the superior constrictor to the lower jaw and the pterygo-maxillary ligament, it will be necessary to cut through the internal pterygoid muscle of the right side. Above the upper fibres of this constrictor, and near the base of the skull, are two small muscles of the palate (F and H) entering the pharynx: one, tensor palati, lies close inside the internal pterygoid muscle; and the other, levator palati, is deeper and larger.

upper constrictor.

The PHARYNX is a portion of the alimentary canal which gives passage to both food and air. It is placed behind the nose, mouth, and larynx, and extends from the base of the skull to the lower border of the cricoid cartilage of the larynx, where it ends in the œsophagus, on a level with the lower part of the sixth cervical

Pharynx

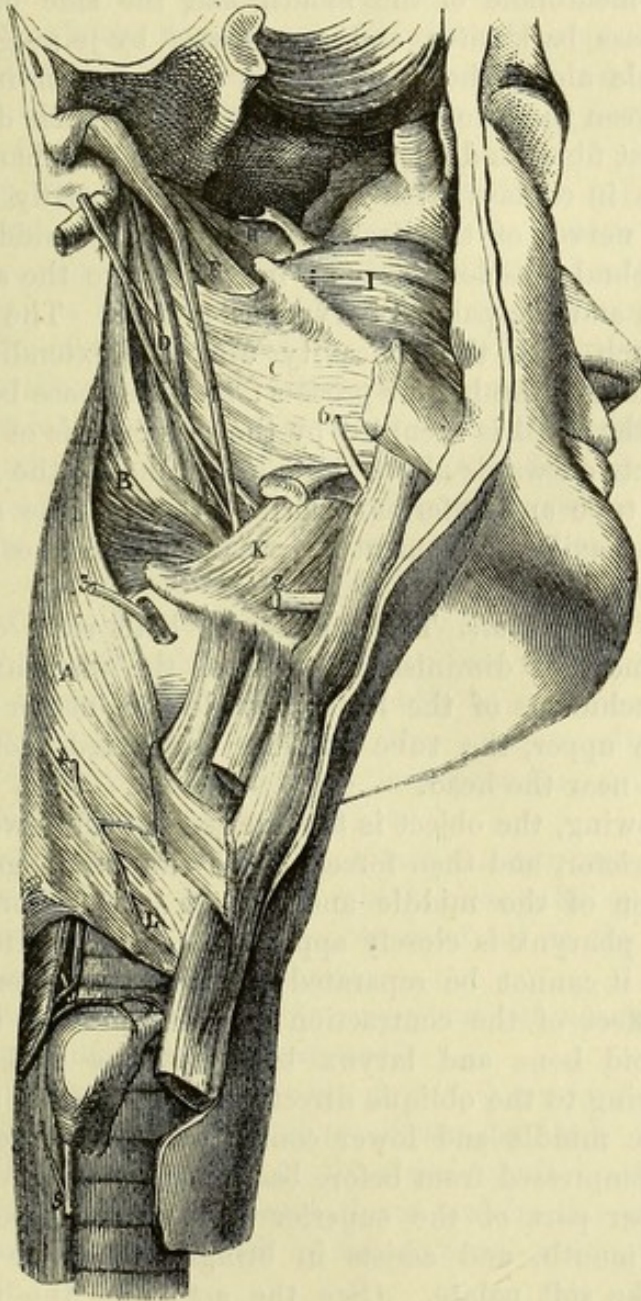
Extent

- form, vertebra. In form it is somewhat conical, with the dilated part upwards; and its length averages about four and a half inches, but varies according to the position of the head and the degree of elevation of the larynx.
- length.
- Is an incomplete bag. The tube of the pharynx is incomplete in front, where it communicates with the cavities above mentioned, but is quite closed above, behind, and at the sides. Below, it opens into the gullet.
- Relations. On each side of it are placed the trunks of the carotid arteries, with the internal jugular vein, and the accompanying cranial and sympathetic nerves. Behind it is the spinal column, covered by muscles, viz., *longi colli* and *recti capitis antici*.
- Attachments, In front, the pharynx is united to the larynx, the hyoid bone, the tongue, and the bony framework of the nasal fossæ, which form the boundaries of its cavity in this direction. Behind and at the sides, it has a special muscular wall, and is only united by very loose connective tissue to surrounding parts. At the upper end the bag is completed by a fibrous aponeurosis which fixes it to the base of the skull; and the whole is lined by mucous membrane.
- and construction.
- Aponeurosis of pharynx. The *aponeurosis* of attachment is seen at the upper part of the pharynx, where the muscular fibres are absent, to connect the tube to the base of the skull, and to complete the posterior boundary. Superiorly it is fixed to the basilar process of the occipital, and the petrous part of the temporal bone; but inferiorly it becomes thin, and is lost in the layer of connective tissue between the muscular and mucous strata. On this membrane some of the fibres of the superior constrictor muscle terminate.
- Muscles in two layers. The MUSCLES of the pharyngeal wall are arranged in two layers—an outer comprising the three constrictors, the fibres of which run more or less transversely to the direction of the tube, and an inner of longitudinal fibres derived from the stylo-pharyngeus and palato-pharyngeus. Externally the constrictor muscles are covered by a fascia, which is continued forwards above, beneath the internal pterygoid muscle, to the surface of the buccinator (bucco-pharyngeal fascia, p. 26).
- Pharyngeal fascia.
- Lower constrictor arises from larynx and ends in the middle line. The INFERIOR CONSTRICTOR (fig. 29,A), the most superficial, arises from the side of the cricoid cartilage, and from the inferior cornu, oblique line, and upper border of the thyroid cartilage. The origin is small when compared with the insertion, for the fibres radiate as they pass backwards, to be *inserted* along the middle line, where the muscles of opposite sides join.
- Parts in contact with it. The outer surface of the muscle is in contact with the sheath of the carotid vessels, and with the muscles covering the spinal column. The lower border is nearly horizontal, and beneath it the inferior laryngeal nerve and vessels (5) pass; while the upper border ascends very obliquely and overlaps the middle constrictor. A few of the lowest fibres of the muscle turn downwards, and are continued into the longitudinal fibres of the œsophagus.
- Middle constrictor arises from hyoid bone. The MIDDLE CONSTRICTOR (fig. 29,B) has a similar shape to the preceding, that is to say, it is narrowed in front and expanded behind. Its fibres *arise* from the great and small cornua of the hyoid bone,

and from the stylo-hyoid ligament. From this origin the fibres radiate, and are blended along the middle line with those of the opposite muscle.

The posterior surface of this muscle is to a great extent concealed Relations. by the inferior constrictor. Laterally, it touches the carotid sheath;

Fig. 29. *



and its origin is beneath the hyo-glossus muscle, the lingual artery passing between the two. Its upper border is separated from the superior constrictor by the stylo-pharyngeus; and in the interval

* External view of the pharynx (Illustrations of Dissections). *Muscles*: A. Inferior constrictor. B. Middle constrictor. C. Upper constrictor. D. Stylo-pharyngeus. F. Levator palati. H. Tensor palati. I. Buccinator. K. Hyoglossus. *Nerves*: 1. Glosso-pharyngeal. 2. Hypoglossal. 3. Superior laryngeal. 4. External laryngeal. 5. Inferior laryngeal. 6. Lingual.

between the origins of the middle and inferior constrictors are the superior laryngeal nerve and vessels.

Upper con-
strictor
arises from
pterygoid
process,
jaw and
tongue.

The SUPERIOR CONSTRICTOR is thinner than the others, and of a quadrilateral form. It has a broad *origin* from the following parts in succession, commencing above,—the lower end of the internal pterygoid plate and the hamular process, the pterygo-maxillary ligament, the hinder part of the mylo-hyoid ridge of the lower jaw, the mucous membrane of the mouth, and the side of the tongue.

Inserted
partly into
a raphé.

The fibres pass backwards, and are *inserted* by joining those of the fellow muscle along the middle line, where a tendinous raphé is formed between the two for the upper half of their depth. Some of the highest fibres end on the aponeurosis of the pharynx.

Relations.

The parts in contact with this muscle externally are the deep vessels and nerves of the neck at the side, the middle constrictor and prevertebral muscles behind: internally are the aponeurosis of the pharynx and the palato-pharyngeus muscle. The upper border forms an arch with the concavity upwards extending from the pterygoid plate to the basilar process; and the space between it and the base of the skull is occupied by the aponeurosis of the pharynx, which projects outwards above the muscle, and by the levator palati, Eustachian tube and inferior palatine artery. The attachment to the pterygo-maxillary ligament corresponds with the origin of the buccinator muscle (1).

Interval
between
muscle and
skull.

Use of
constrictors

Action of constrictors. The muscles of both sides contracting at the same time will diminish the size of the pharynx; and as the anterior attachments of the lower muscles are nearer together than those of the upper, the tube will be contracted more behind the larynx than near the head.

in swallow-
ing

In swallowing, the object is first seized by the lower part of the upper constrictor, and then forced on to the œsophagus by the successive action of the middle and inferior constrictors. Since the back of the pharynx is closely applied to the prevertebral muscles, from which it cannot be separated in the natural condition of the parts, the effect of the contraction of these muscles is to draw the tongue, hyoid bone and larynx backwards, as well as somewhat upwards owing to the oblique direction of the greater number of the fibres of the middle and lower constrictors; and the cavity, when empty, is compressed from before backwards.

of
constrictor.

The upper part of the superior constrictor narrows the space above the mouth, and assists in bringing together the posterior pillars of the soft palate. (See the action of the palato-pharyngeus.)

Dissection
to show

Dissection. By dividing the middle and inferior constrictors midway between their origin and insertion, and reflecting the parts forwards and backwards, the longitudinal fibres of the pharyngeal wall will be exposed.

longitudinal
muscles.

The LONGITUDINAL OR ELEVATOR MUSCLES of the pharynx are the stylo-pharyngeus and palato-pharyngeus. The *stylo-pharyngeus* has already been described, but it may now be followed to its insertion (p. 102). The *palato-pharyngeus* is only partially seen, and will be

described with the muscles of the soft palate. Its fibres appear behind those of the stylo-pharyngeus, and descend to the lower part of the pharynx, reaching backwards to the middle line.

Dissection (fig. 30). Open the pharynx by an incision along the middle, and, after removing the tow from the interior, keep it open with hooks : a better view of the cavity will be obtained by partly dividing the occipital attachment on each side. Dissection.

The INTERIOR OF THE PHARYNX (fig. 30) is wider from side to side than from before back, and its greatest width is opposite the hyoid bone ; from that spot it diminishes both upwards and downwards, but much more rapidly in the latter direction. In it the following objects are to be noticed. Interior of pharynx

At the top are situate the posterior apertures (G) of the nasal fossæ, which are separated by the septum nasi. Below them hangs the soft palate, partly closing the opening into the mouth ; and from its free margin a prominent fold of the mucous membrane, the posterior pillar of the soft palate (L), is continued downwards and backwards on the side of the pharynx. Immediately behind each nasal aperture is the trumpet-shaped end of the Eustachian tube ; and from the anterior extremity of the prominence formed by the tube, a ridge descends to join the posterior pillar of the palate. Behind the opening of the Eustachian tube the mucous membrane is prolonged into a deep recess, which corresponds to the projection of the aponeurosis of the pharynx seen externally (p. 124). Objects to be noted

On raising the soft palate, the opening into the mouth—isthmus faucium (H), is exposed, bounded laterally by a mucous fold which descends to the tongue and is named the anterior pillar of the soft palate ; while between the anterior and posterior pillars on each side is a hollow containing the tonsil (K).

Next in order, below the mouth, comes the aperture of the larynx (N) with the epiglottis, the valve which closes the opening during deglutition, projecting above it. Lowest of all is the opening (O) from the pharynx into the œsophagus.

The *apertures* into the pharynx are seven in number, and have the following position and boundaries :— Seven apertures, viz.—

The *posterior openings of the nasal fossæ* (G) are oval in form, and measure about an inch from above down, but only half an inch across. Each is constructed in the dried skull by the sphenoid, with the vomer and palate bones above, and by the palate below ; by the vomer internally, and by the internal pterygoid plate on the outer side. Posterior nares.

The *Eustachian tube* (F) is a canal, partly osseous, partly cartilaginous, by which the tympanic cavity of the ear communicates with the external air. Eustachian tube ;

If the mucous membrane be removed from the tube on the right side, the cartilaginous part is seen to be nearly an inch long. It is fixed above to a groove between the petrous part of the temporal and the sphenoid bones, and ends in front by a wide opening on the inner side of the internal pterygoid plate on a level with the posterior extremity of the inferior spongy bone of the nose. Its cartilaginous part

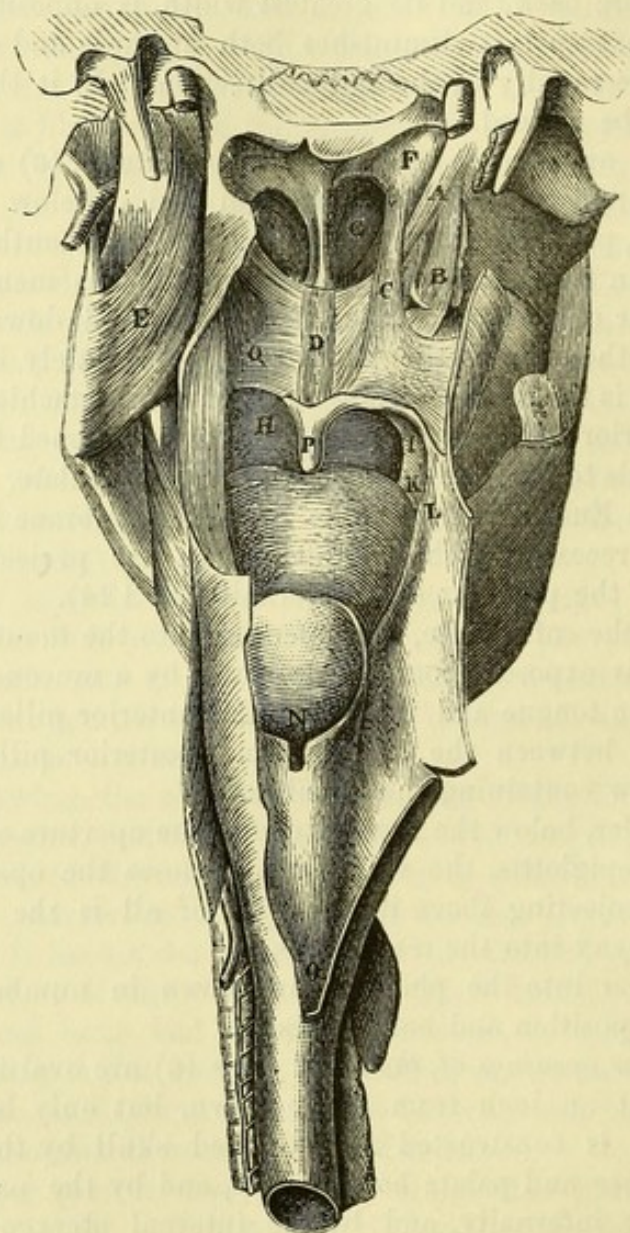
pharyngeal
opening ;

construc-
tion.

opening in the pharynx is oval in form, and the inner margin projects forwards, giving rise to a trumpet-shaped mouth.

This part of the tube is constructed of a triangular piece of yellow fibro-cartilage, which is bent downwards on each side so as to enclose a narrow space. The inner portion is larger than the outer, and increases in breadth from behind forwards. On its outer side

Fig. 30.*



the tube is completed by fibrous tissue. The cartilage is covered on its inner side by mucous membrane, and through the tube the

* Internal view of the pharynx (Illustrations of Dissections). Muscles of the palate, and named parts : A. Levator palati. B. Tensor palati. C. Salpingo-pharyngeus. D. Azygos uvulae. E. Internal pterygoid, F. End of the Eustachian tube. G. Posterior naris. H. Mouth cavity. I. Anterior pillar of fauces. K. Position of tonsil. L. Posterior pillar of fauces. N. Opening of larynx. O. Opening of oesophagus. P. Uvula. Q. Superficial part of palato-pharyngeus.

mucous lining of the cavity of the tympanum is continuous with that of the pharynx.

The space included between the root of the tongue and the soft palate is called the *fauces*. It is wider below than above ; and on each side lies the tonsil.

The *isthmus faucium* (H) is the narrowed aperture of communication between the mouth and the pharynx. It is bounded above by the soft palate, below by the tongue, and on the sides by the anterior pillars of the soft palate. Its size varies with the movements of these parts, and it can be closed by the meeting of the soft palate and the tongue. Isthmus of the fauces.

The *aperture of the larynx* (N) is wide in front, where it is bounded by the epiglottis, and pointed behind between the arytenoid cartilages. The sides are sloped from before back, and are formed by folds (aryteno-epiglottidean) of the mucous membrane extending between the arytenoid cartilages and the epiglottis. Behind it is limited by the cornicula laryngis, and by the arytenoid muscle covered by mucous membrane. During respiration this aperture is unobstructed, but in the act of deglutition it is closed by the epiglottis. Upper opening of larynx.

The *opening into the œsophagus* (O) is the narrowest part of the pharynx, and is opposite the cricoid cartilage and the sixth cervical vertebra. At this spot the mucous membrane in the œsophagus becomes paler than in the pharynx ; and the point at which the pharynx ends is marked externally by a slight contraction, and by a change in the direction of the muscular fibres. Beginning of œsophagus.

The cavity of the pharynx is divided into three parts, which differ in their function with regard to the transmission of the food and air. The upper or *nasal portion* is limited below by the soft palate and its posterior pillars ; it gives passage only to air, and is always open. The middle or *oral portion* extends downwards to the aperture of the larynx, and is traversed by both food and air ; it is open when breathing through the mouth, but closed when breathing solely through the nose, the aperture of the larynx then corresponding to the interval between the posterior pillars. The third part being behind the larynx is termed *laryngeal*, and only transmits food ; its walls are naturally in contact, except during the act of deglutition. Subdivision of cavity of pharynx into nasal, oral, and laryngeal portions.

The **SOFT PALATE** (*velum pendulum palati*, Q) is a moveable structure between the mouth and the pharynx, which can either close the opening of the mouth, or cut off the communication with the nose, according as it is depressed or elevated. In the usual position of the soft palate (the state of relaxation) its anterior surface is concave, and is continuous with the roof of the mouth ; while the opposite surface is convex and turned to the pharynx. The upper border is fixed to the posterior margin of the hard palate ; and on each side it joins the pharynx. The lower border is free, and is produced in the centre into a conical pendulous part—the *uvula* (P). Along its middle is a slight ridge, indicative of the original separation into two halves. Soft palate at back of mouth ; surfaces, borders ; from it hangs uvula.

Arches or pillars,	<p>Descending from the soft palate on each side of the fauces are the two folds of mucous membrane before referred to, containing muscular fibres, and named the <i>arches</i> or <i>pillars of the soft palate</i> or <i>fauces</i>. The <i>anterior pillar</i> (1) springs from the anterior surface of the soft palate near the base of the uvula, and reaches to the side of the tongue rather behind the middle; and the <i>posterior</i> (1), longer than the other, is continued from the lower border of the velum to the side of the pharynx. As they diverge from their origin to their termination, they limit a triangular space in which the tonsil lies.</p>
anterior,	
posterior.	
Constituents of velum.	<p>The soft palate consists of an aponeurosis, with muscles, vessels, nerves, and mucous glands; and the whole is enveloped by the mucous membrane.</p>
Dissect	<p><i>Dissection.</i> Some of the muscles of the palate are readily displayed, but others require care in their dissection.</p>
levator and tensor on right half.	<p>On the right side the two principal muscles of the soft palate—the elevator and tensor, are very plain. These have already been partly dissected; but to follow them to their termination, let the upper attachment of the pharynx on the right side, and the part of the superior constrictor which arises from the internal pterygoid plate be cut through. The levator will be fully laid bare by the removal of the mucous membrane and a few muscular fibres covering its lower end. The tendon of the tensor palati should be followed round the hamular process of the internal pterygoid plate; and its situation in the palate beneath the levator should be made evident. The position of the Eustachian tube with respect to those muscles should also be ascertained.</p>
On left, palato-pharyngeus,	<p>On the left side, the mucous membrane is to be raised with great care from the posterior surface of the soft palate, to obtain a view of the superficial muscular fibres. Immediately beneath the mucous covering are some fine transverse fibres of the palato-pharyngeus muscle; and beneath them, close to the middle line, are the longitudinal fibres of the azygos uvulæ. A slender muscular bundle contained in the ridge of mucous membrane descending from the extremity of the Eustachian tube is to be exposed and traced to its junction with the palato-pharyngeus. On the right side, a deeper set of fibres of the palato-pharyngeus is to be followed beneath the levator and azygos muscles.</p>
azygos uvulæ,	
and palato-glossus.	<p>The student should remove next the mucous membrane from the muscular fibres contained in the arches of the palate, and should follow these upwards and downwards. In order to see those in the anterior fold, it will be necessary to take the membrane from the anterior surface of the palate. If the part is not tolerably fresh, some of the paler fibres may not be visible.</p>
Aponeurosis of palate.	<p><i>Aponeurosis of the soft palate.</i> Giving strength to the velum is a thin but firm aponeurosis, which is attached to the hard palate. This membrane becomes thinner as it descends in the velum; and it is joined by the tendon of the tensor palati muscle.</p>
Nine muscles in it.	<p>The MUSCLES OF THE SOFT PALATE are, on each side, an elevator and tensor, which descend from the skull, with the palato-glossus</p>

and palato-pharyngeus, which act as depressors, and a small median azygos muscle.

The LEVATOR PALATI (fig. 30, A; 31,³) is a thick roundish muscle which is partly situate outside the pharynx. It arises from the under surface of the petrous portion of the temporal bone close in front of the carotid foramen, and from the lower border of the adjacent cartilaginous part of the Eustachian tube. Entering the pharynx above the superior constrictor, the fibres of the muscle spread out in the soft palate, where they join along the middle line with those of the muscle of the opposite side.

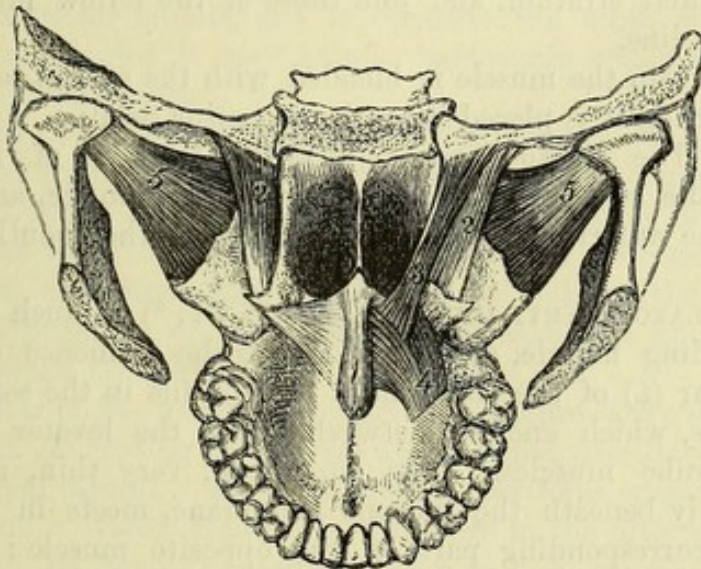
Elevator muscle arises outside pharynx, and is lost in velum.

The belly of the muscle rests against the lower border of the Eustachian tube; and the expanded part is embraced by two layers of fibres of the palato-pharyngeus (⁴).

Relations.

Action. It raises the soft palate from the tongue, so as to

Fig. 31.*



enlarge the fauces; and by bringing the hinder part of the velum into contact with the posterior wall of the pharynx, it can shut off the upper part of that cavity, as in vocalization, when the air is prevented from passing through the nose.

The TENSOR OR CIRCUMFLEXUS PALATI (fig. 30, B; 31,²) is a thin flattened muscle, lying immediately behind the internal pterygoid plate. About an inch wide at its *origin*, it is attached to the scaphoid fossa at the root of the internal pterygoid plate, to the outer side of the Eustachian tube, and to the spinous process of the sphenoid. The fleshy fibres end below in a tendon, which turns round the hamular process, and is inserted into a ridge close to the posterior border of the hard palate, and blends inferiorly with the aponeurosis of the velum.

Tensor muscle arises outside pharynx, inserted into aponeurosis of soft palate.

The fleshy part of the tensor palati is placed between the internal pterygoid muscle externally and the Eustachian tube and levator

Relations.

* 1. Azygos uvulæ. 2. Tensor palati. 3. Levator palati. 4. Palato-pharyngeus—upper end. 5. External pterygoid.

palati internally. The tendon enters the pharynx between the attachments of the buccinator muscle, and is thrown into folds as it winds round the hamular process, a bursa being placed between the two. In the soft palate it lies between the palato-pharyngeus and palato-glossus.

Use on
palate,

Action. Acting from the skull the muscle will fix and make tense the soft palate; but its movements will be very limited, seeing that the tendon is inserted partly into the palate bone.

on tube.

The soft palate being fixed by its depressor muscles, the tensor, taking its fixed point below, opens the Eustachian tube in swallowing.

Palato-
glossus.

Attach-
ments.

The PALATO-GLOSSUS MUSCLE (constrictor isthmi faucium) is a small, pale band of fibres, which is contained in the anterior pillar (fig. 30, 1) of the soft palate. It is connected below with the side of the tongue; from this spot the fibres ascend in front of the tonsil to the anterior aspect of the soft palate, where they form a thin muscular stratum, and join those of the fellow muscle along the middle line.

Relations.

At its origin the muscle is blended with the glossal muscles, and at its insertion it is placed beneath the tensor palati.

Use.

Action. The palato-glossus closes the isthmus of the fauces, bringing the soft palate into contact with the tongue, and approximating the anterior pillars, thus shutting off the mouth from the pharynx.

Palato-
pharyngeus

forms two
layers in
velum;

posterior
layer is
joined by
salpingo-
pharyngeus;
anterior
layer is
larger;

The PALATO-PHARYNGEUS (fig. 30, q; 31, ⁴) is much larger than the preceding muscle, and gives rise to the eminence of the posterior pillar (L) of the soft palate. It begins in the soft palate in two layers, which enclose between them the levator palati and azygos uvulae muscles. The superficial, very thin, and situate immediately beneath the mucous membrane, meets in the middle line the corresponding part of the opposite muscle; it is also joined by a slender fasciculus, which descends from the anterior extremity of the cartilage of the Eustachian tube (*salpingo-pharyngeus*—Santorini, fig. 30, c). The deep or anterior layer is much stronger, and lies between the levator and tensor palati muscles; its upper fibres spring from the hinder margin of the hard palate and the aponeurosis of the velum, while the lower ones join those of the opposite side. The two layers meet at the outer part of the soft palate, and the muscle descends behind the tonsil on the side wall of the pharynx. Spreading out below, the anterior fibres are inserted into the hinder border of the thyroid cartilage, but the greater number end in the submucous tissue of the pharynx beneath the inferior constrictor, the hinder ones meeting the fellow muscle in the middle line.

inserted
into thyroid
cartilage
and wall of
pharynx.

Use;

Action. The palato-pharyngeus depresses and tightens the soft palate, raises the larynx and lower part of the pharynx, and at the same time brings together the posterior pillars of the fauces, thus acting as a sphincter by which the nasal portion is separated from the oral portion of the pharynx. In swallowing, the hinder pillars of the soft palate, being approximated by the action of this muscle, form,

in swallow-
ing;

together with the uvula, an inclined plane, beneath which the food is directed downwards. The contraction of the salpingo-pharyngeus at the same time assists in opening the Eustachian tube, by drawing inwards and backwards the cartilage bounding its orifice.

of salpingo-pharyngeus.

The AZYGOS UVULÆ (fig. 30, D ; 31,¹) is situated along the middle line of the velum near the posterior surface. The muscle consists of two narrow slips of pale fibres, which arise from the spine at the posterior border of the hard palate, or from the contiguous aponeurosis, and end below in the base of the uvula. Behind this muscle, separating it from the mucous membrane, is the thin stratum of the palato-pharyngeus.

Azygos muscle is in two slips.

Action. Its fibres shorten the mid-part of the soft palate, and elevate the uvula, directing that process backwards.

Use.

The TONSIL is an oval prominent body, of variable size, placed above the root of the tongue, in a recess between the anterior and posterior pillars of the soft palate. Externally it is covered by the superior constrictor muscle, and is opposite the angle of the lower jaw. When enlarged it may extend backwards and press against the internal carotid artery.

Tonsil is between pillars of fauces, and opposite angle of jaw.

The surface of the tonsil is marked by apertures, which lead into recesses lined by mucous membrane. Its substance consists mainly of lymphoid tissue, partly diffused, and partly collected into follicles set round the walls of these recesses. A similar collection of lymphoid tissue stretches across the posterior wall of the pharynx, between the openings of the Eustachian tubes, and is known as the *pharyngeal tonsil* (Luschka).

Structure.

Pharyngeal tonsil.

The *arteries* of the tonsil are numerous, and are derived from the facial, lingual, ascending pharyngeal and internal maxillary branches of the external carotid. Its *veins* have a plexiform arrangement on the outer side. *Nerves* are furnished to it from the fifth and glossopharyngeal. Its *lymphatics* join the deep cervical glands.

Vessels,

and nerves.

The *mucous membrane of the pharynx* is continuous in front with the lining of the nose, mouth and larynx. A fold encloses the muscles and glands of the soft palate, from which the membrane descends on each side over the tonsil to the tongue. It is also prolonged by the Eustachian tube to the tympanum ; and below, it is continued into the œsophagus. It is provided with numerous mucous glands in the upper part of the pharynx, and on both surfaces, but especially the upper, of the soft palate. Another collection of glands (arytenoid) is enclosed in the fold of mucous membrane bounding the opening of the larynx on each side. The epithelium is columnar and ciliated above the soft palate, but scaly and stratified below that part.

Mucous membrane of pharynx.

Glands.

Epithelium.

Beginning of the œsophagus. This tube is much smaller than the pharynx, and the walls are flaccid. For its commencement, and its relations in the neck, see p. 119.

Beginning of œsophagus.

The gullet consists of two layers of muscular fibres, with a lining of mucous membrane. The *external layer* is formed of longitudinal fibres, which begin opposite the cricoid cartilage by three bundles, an anterior and two lateral ; the former is attached to the ridge at

Two layers of muscular fibres ; outer longitudinal,

and inner
circular.

the back of the cartilage, and the others join the inferior constrictor. The *internal layer* is formed of circular fibres, which are continuous with those of the inferior constrictor. The structure of the œsophagus is described more fully in the dissection of the thorax.

SECTION XII.

CAVITY OF THE MOUTH.

The cheeks, the lips, and the teeth are to be examined with the mouth, as all may be considered accessory parts.

Mouth.

MOUTH. The cavity of the mouth extends from the lips in front to the anterior pillars of the fauces behind. Its boundaries are partly osseous and partly muscular, and its size depends upon the position of the lower jaw-bone. When the lower jaw is moderately removed from the upper, the mouth is an oval cavity with the

Form,

and bounda-
ries,

following boundaries. The *roof*, concave, is constituted by the hard and soft palate, and is limited in front and on the sides by the arch of the teeth. In the *floor* is the tongue, surrounded by the arch of the lower teeth; and beneath that body is the sublingual gland on each side. Each *lateral boundary* consists of the cheek and the ramus of the lower jaw; and in it, near the second molar tooth in the upper jaw, is the opening of the parotid duct. The anterior opening of the mouth is bounded by the lips; and the posterior is the isthmus faucium (p. 127), leading into the pharynx. The space between the lips and the teeth is often distinguished from the rest of the cavity as the *vestibule of the mouth*.

Vestibule.

Lining of
the mouth

The *mucous membrane* is less sensitive on the hard than the soft boundaries of the mouth; it lines the interior of the cavity, and is reflected over the tongue. In front it is continuous with the skin, and behind with the lining of the pharynx. The epithelium covering the membrane is scaly and stratified.

differs in
parts:
on roof,

Between each lip and the front of the corresponding jaw the membrane forms a small fold—*frænulum*. Over the bony part of the roof it blends with the dense tissue enclosing the vessels and nerves; on the soft palate it is smooth, and thinner. Along the middle of the roof is a slightly raised *raphé*, which ends in front opposite the anterior palatine fossa in a small papilla; and on each side of this, at the fore part of the hard palate, there are two or three irregular transverse ridges. In the floor of the mouth the membrane forms the *frænum linguæ* beneath the tip of the tongue, and on each side of the *frænum* it is raised into a ridge by the sublingual gland, at the fore part of which is a small papilla, perforated by the opening of Wharton's duct. On the interior of the cheek and lips the mucous lining is smooth, and is separated from the muscles by small buccal and labial glands.

floor,

cheek, and
lips.

Over the whole cavity, but especially on the lips and tongue, are Papillæ. papillæ for the purpose of touch.

The CHEEK extends from the commissure of the lips to the ramus of the lower jaw, and is attached above and below to the alveolar process of the jaw on the outer aspect. The chief constituent of the cheek is the fleshy buccinator muscle : on the inner surface of this is the mucous membrane ; and on the outer the integuments, with some muscles, vessels, and nerves. The parotid duct perforates the cheek obliquely near the second molar tooth of the upper jaw.

The LIPS surround the opening of the mouth ; they are formed mainly by the orbicularis oris muscle, covered externally by integument, and internally by mucous membrane. The lower lip is the larger and more moveable of the two. Between the muscular structure and the mucous covering lie the labial glands ; and in the substance of each lip, internal to the muscular structure, and at the line of junction of the two portions of the orbicularis, is placed the arch of the coronary arteries.

TEETH. In the adult there are sixteen teeth in each jaw, which are set in the alveolar borders in the form of an arch, and are surrounded by the gums. Each dental arch has its convexity turned forwards ; and, commonly, the arch in the maxilla overhangs that in the mandible when the jaws are in contact. The teeth are similar in the half of each jaw, and have received the following names :—the most anterior two are incisors, and the one next behind is the canine tooth ; two, still farther back, are the bicuspid ; and the last three are molar teeth. For details as to the form and structure of the teeth reference must be made to a work on systematic or general anatomy.

SECTION XIII.

DISSECTION OF THE NOSE.

To obtain a view of the interior of the nose, it will be necessary to make a vertical longitudinal section through the nasal cavity. While the student is examining the boundaries of the nose he will derive advantage from the use of a vertical section of a macerated skull.

Dissection. Before sawing the bone, the loose part of the lower jaw on the right side should be taken away, and the tongue, hyoid bone, and larynx, all united, are to be detached from the opposite half of the lower jaw, and laid aside till the dissector is ready to use them.

On the right side of the middle line saw carefully through the frontal and nasal bones, the cribriform plate of the ethmoid, and the body of the sphenoid bone, without letting the saw descend into the nasal cavity.

Cut soft parts, and saw bone in roof of mouth.

Next the roof of the mouth is to be turned upwards, and the soft parts are to be divided on the right side opposite the cut in the roof of the nose. Then by sawing through the hard palate and the alveolar process of the upper jaw along the same line, the piece of the skull will be separated into two parts, right and left; the right half will serve for the examination of the meatuses, and the left will show the septum nasi, after the mucous membrane has been removed.

Situation of nose.

The CAVITY OF THE NOSE is placed in the centre of the bones of the face, being situate above the mouth, below the cranium, and between the orbits. This space is divided into two nasal fossæ by a vertical partition.

Division into two.

Form.

Each fossa is larger below than above, and is compressed laterally, so that its diameter from before back or from above down much exceeds that from within out. It communicates with both the face and the pharynx by openings named nares; and it has also apertures of communication with the sinuses in the surrounding bones, viz., frontal, ethmoid, sphenoid, and superior maxillary. Each fossa presents for examination a roof and floor, an inner and outer wall, and an anterior and posterior opening.

Openings.

Roof.

The *roof* is strongly arched from before back, and is formed by the cribriform plate of the ethmoid bone in the centre; by the frontal and nasal bones, and the cartilages in front; and by the body of the sphenoid, with the sphenoidal spongy bone, and the palate bone, at the posterior part. In the dried skull many apertures exist in it; most are in the ethmoid bone for the branches of the olfactory nerve with vessels, and one for the nasal nerve and vessels; on the front of the body of the sphenoid is the opening of its sinus.

Floor.

The *floor* is slightly hollowed from side to side, and is formed by the palate processes of the superior maxillary and palate bones. Near the front in the dry skull is the incisor foramen leading to the anterior palatine fossa.

Inner boundary

partly osseous,

partly cartilaginous.

The *inner wall* (septum nasi) is partly osseous and partly cartilaginous. The osseous part is constructed by the vomer, by the perpendicular plate of the ethmoid bone, and by those parts of the frontal and nasal with which this last bone articulates. The angular space in front in the prepared skull is filled in the recent state by the *cartilage of the septum*, which forms part of the partition between the nostrils, and supports the lateral cartilages. Fixed between the vomer, the ethmoid, and the nasal bones, this cartilage rests in front on the incisor crest of the superior maxillæ, and projects between the cartilages of the nostrils. The septum nasi is commonly bent to one side.

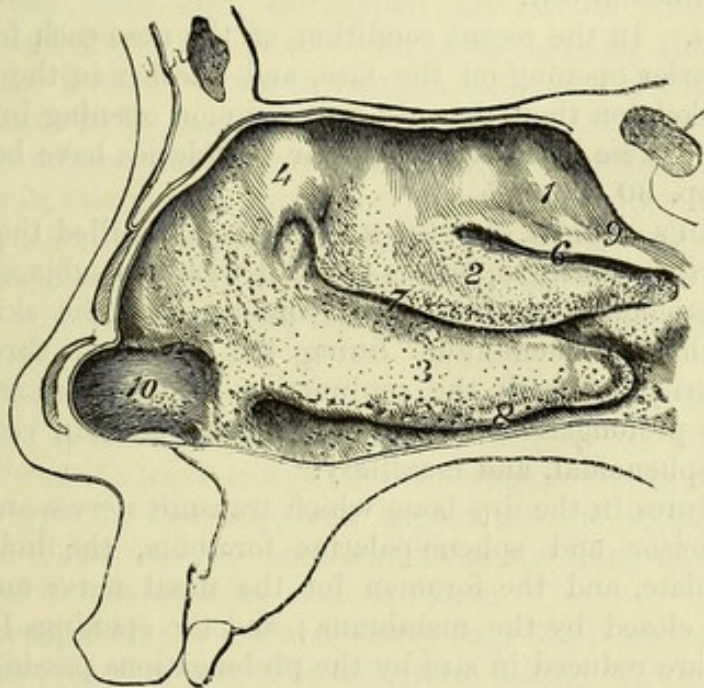
Outer boundary,

The *outer wall* has the greatest extent and the most irregular surface. Seven bones enter into its formation, and they come in the following order from before backwards:—the nasal and superior maxillary; the small lachrymal bone and the lateral mass of the ethmoid, with the inferior turbinate bone below these; and posteriorly the ascending part of the palate bone, with the internal

pterygoid plate of the sphenoid ; of these, the nasal, lachrymal, and ethmoid reach only about half way from roof to floor, and the inferior turbinate is confined to the lower half, while the others extend the whole depth. In front of the bones, the lateral cartilages complete this boundary.

From this wall three slightly convoluted osseous plates, named *turbinate* or *spongy bones* (fig. 32), project into the cavity :—the upper (1) and middle (2) are processes of the ethmoid, but the lower one (3) is a separate bone. The turbinate bones are confined to that portion of the outer wall which is situate above the hard palate. Between each turbinate bone and the wall of the nose is a longitudinal hollow or meatus ; and into these hollows the nasal duct and the sinuses of the surrounding bones open.

Fig. 32.*



The *meatuses* are the spaces arched over by the spongy bones ; and as the bones are limited to a certain part of the outer wall, so are the spaces beneath them.

The *upper meatus* (fig. 32,⁶) is the smallest and straightest of the three, and is limited to the posterior half of the space above the hard palate. Into its fore part the posterior ethmoidal cells open ; and at its posterior end, in the dried skull, is the sphenopalatine foramen by which nerves and vessels enter the nose.

The *middle meatus* (fig. 32,⁷) is longer than the upper, reaching from the posterior opening of the nasal fossa, nearly as far forwards

* Outer wall of the nasal cavity. 1. Upper turbinate bone. 2. Middle turbinate bone. 3. Inferior turbinate bone. 4. Flat part of the ethmoid bone. 6. Upper meatus. 7. Middle meatus. 8. Lower meatus. 9. Rudimentary fourth meatus. 10. Vestibule. The cut also shows the apertures of the glands of the nose.

as the hard palate. The free border of the middle turbinate bone being curved upwards anteriorly, this meatus is open in front as well as below. On raising the overhanging turbinate bone, a deep groove will be seen in the fore part of the lateral wall of the meatus, bounded below by the uncinat process of the ethmoid, and leading upwards through the infundibulum of the latter bone to the frontal sinus. Into the groove lower down the anterior ethmoidal cells open, and at its hindmost part is a small aperture leading into the antrum of the superior maxilla. In some cases there is a second opening into the antrum close above the lower turbinate bone.

Lower
meatus.

The *inferior meatus* (fig. 32,⁸) is wider than the middle one, and extends the whole length of the hard palate. Near its anterior extremity is the opening of the nasal duct.

A fourth
meatus
sometimes.

Occasionally there is a small rudimentary or fourth meatus above the superior turbinate bone (fig. 32,⁹), which communicates with a posterior ethmoidal cell.

Nares.

The *nares*. In the recent condition of the nose each fossa has a distinct anterior opening on the face, and another in the pharynx ; but in the skeleton there is only one common opening in front for both sides. These apertures and their boundaries have been before described (pp. 30 and 125).

Mucous
lining of the
nose.

The MUCOUS LINING OF THE NASAL FOSSA is called the *pituitary* or *Schneiderian membrane*, and is blended with the subjacent periosteum or perichondrium. It is continuous with the skin at the nostril, with the membrane lining the pharynx through the posterior naris, and with the conjunctiva through the nasal duct ; and it sends prolongations to line the different sinuses, viz., frontal, ethmoidal, sphenoidal, and maxillary.

Some foramina closed,

The apertures in the dry bone which transmit nerves and vessels, viz., the incisor and sphenopalatine foramina, the holes in the cribriform plate, and the foramen for the nasal nerve and vessels, are entirely closed by the membrane ; and the openings leading to the sinuses are reduced in size by the prolongations passing through them. At the termination of the nasal duct the mucous membrane forms a single or double fold, which is sometimes sufficient to close the opening and prevent air entering the canal from the nose.

others
diminished
by it.

Folds on
spongy
bones.

Over the middle and lower turbinate bones, and to a greater extent on the latter, the mucous membrane is thickened and projected beyond the edges of the bones by the large submucous vessels, so that the meatuses are deeper and longer in the recent state than in the dried skull.

Three
regions of
nasal fossa.

The appearance and structure of the lining membrane differ in the upper and lower parts of the nasal fossa, and near the anterior opening, whence a division of the cavity is made into three portions, which are termed respectively the olfactory region, the respiratory region, and the vestibule.

Vestibule.

The *vestibule* (fig. 32,¹⁰) is the slightly dilated portion of the cavity immediately within the nostril. It is bounded by the cartilage of the aperture and the ala of the nose ; and its wall is

more flexible than that of the part above. The lining membrane of the vestibule has the characters of the outer skin, being furnished with papillæ and hairs (vibrissæ), and lined by a stratified scaly epithelium.

The *respiratory region* is the part below the level of the middle turbinate bone. Its mucous membrane is thick, of a red colour, very vascular, and has numerous mucous glands, the openings of which are readily seen on the surface. The glands are largest and most abundant on the inferior turbinate bone, and at the lower and back part of the cavity. The epithelium of this region is columnar and ciliated. Respiratory region.

The *olfactory region* is the narrowed upper part of the nasal fossa, which is enclosed by the ethmoid bone. It comprises the part of the roof formed by the cribriform plate, the part of the septum (about one-third) formed by the perpendicular plate of the ethmoid, and, on the outer wall, the upper and middle turbinate bones, together with the flat surface of the lateral mass of the ethmoid in front of the former. Over this region the olfactory nerves are distributed, and it is, therefore, the seat of the sense of smell. The olfactory mucous membrane is thinner, softer, and less vascular than that in the respiratory region, and it has in the fresh state a yellowish colour. Its epithelium is columnar, but not ciliated; and it is thickly beset with simple tubular glands. Olfactory region.

In the sinuses the mucous lining is thin and pale, and its glands are few and small. Mucous membrane in sinuses.

Dissection. At this stage of the dissection, but little will be seen of the distribution of the olfactory nerves. If the septum be removed, so as to leave entire the membrane covering it on the left side, the nervous filaments will appear on the surface, near the cribriform plate. In the membrane, near the front of the septum, an offset of the nasal nerve is to be found. Dissection of nerves and vessels.

The naso-palatine nerve and artery (fig. 33,³) are to be sought lower down, as they are directed from behind forwards, towards the anterior palatine fossa; the artery is readily seen, especially if it is injected, but the fine nerve is embedded in the membrane, and will be found by scraping with the point of the scalpel.

By cutting through the fore and upper part of the membrane detached from the septum nasi, other branches of the olfactory nerve may be traced on the outer wall of the nasal fossa.

The OLFACTORY NERVES spring from the under surface of the olfactory bulb as it lies on the cribriform plate of the ethmoid bone (fig. 33,¹), and descend to the olfactory region of the nose through the apertures in this part of the roof. They are about twenty in number, and are divided into two sets. Those of the *inner set* are the larger, and run downwards in the grooves on the perpendicular plate of the ethmoid, to be distributed over the upper third of the septum. The *outer set* (fig. 34) ramifies over the upper turbinate bone, the flat surface of the ethmoid in front of this, and the fore part of the middle turbinate bone. As the nerves leave the skull, they receive sheaths from the dura mater and pia mater, which are Olfactory nerves, inner set, outer set.

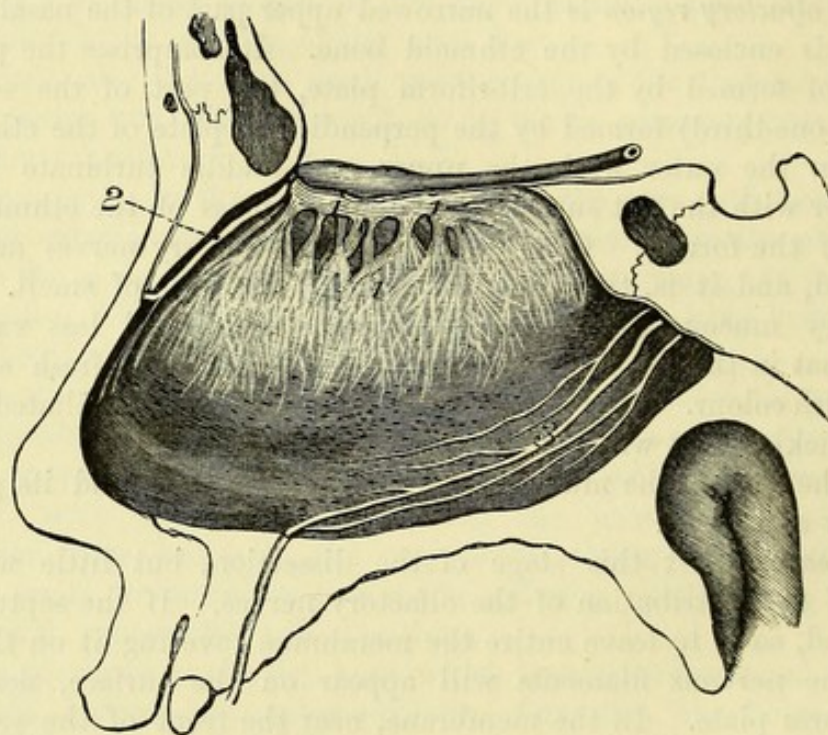
continued as far as their terminal ramifications, and then become lost in the surrounding tissue. The trunks break up into tufts of filaments which communicate freely together, forming a close network beneath the mucous membrane. The olfactory nerves consist wholly of non-medullated fibres.

The other nerves in the nose will be described in the following section.

Blood-vessels of nose,
arteries,

Blood-vessels. For a statement of the different vessels of the nose, see p. 143. The *arteries* form a network in the pituitary mem-

Fig. 33.*



veins.

brane, and a large submucous plexus on the edge of each of the two lower spongy bones, especially on the inferior. The *veins* have a plexiform disposition like the arteries, and this is largest on the lower spongy bone and the septum nasi.

SECTION XIV.

SPHENO-PALATINE AND OTIC GANGLIA, NASAL AND FACIAL NERVES, AND FINAL BRANCHES OF THE INTERNAL MAXILLARY VESSELS.

Meckel's
ganglion.

The preparation of Meckel's ganglion and its branches (fig. 34), and of the terminal branches of the internal maxillary artery, is a

* Nerves of the septum of the nose. 1. Olfactory bulb and inner set of olfactory nerves. 2. Nasal nerve of the ophthalmic trunk. 3. Naso-palatine nerve from Meckel's ganglion (too large in the cut).

difficult task, in consequence of the nerves and vessels being contained in osseous canals which require to be opened. The branches are first to be sought, and these are then to be followed to the ganglion and main trunk.

Dissection. The left half of the head is to be used for the display of the ganglion and its branches; but the student will derive advantage from first attempting the dissection on the remains of the right side. Dissection

To lay bare the branches to the palate, detach the soft parts in the roof of the mouth from the bone, until the nerves and vessels escaping from the posterior palatine canals are arrived at. Cut off, with the bone forceps, the posterior part of the hard palate to a level with the vessels and nerves; and cleaning these, trace offsets behind into the soft palate, and follow the main pieces forwards to the front of the mouth. of palatine and

Take away, without injury to the naso-palatine nerve and vessels (already found), the hinder portion of the loose piece of mucous membrane detached from the septum nasi; and separate the mucous membrane from the outer wall of the nasal fossa, behind the spongy bones, as high as the spheno-palatine foramen. In reflecting forwards the membrane many branches of vessels and nerves will be seen entering it through the foramen; but these may be left for the present, and directions for their dissection will be subsequently given. When the lining membrane of the nose has been removed behind the spongy bones, the palatine nerves and vessels will appear through the thin translucent palate bone, and may be readily reached by breaking carefully through the latter with a chisel. Afterwards, the tube of membrane containing the palatine vessels and nerves being opened, these are to be followed down to the soft palate and the roof of the mouth, and upwards to the ganglion which is close to the body of the sphenoid bone. nasal branches;

To bring the ganglion fully into view, it will be necessary to saw through the overhanging body of the sphenoid bone, to cut away pieces of the bones surrounding the hollow in which it lies, and to remove with care the enveloping fat and the periosteum. The ganglion then appears as a flattened reddish-looking body, from which the Vidian and pharyngeal nerves pass backwards. Besides the branches referred to, the student should seek two large nerves from the top of the ganglion to join the superior maxillary trunk, and smaller offsets to the floor of the orbit. body of ganglion;

To trace backwards the Vidian branch to the carotid plexus and the facial nerve, the student must lay open the canal which contains it and its artery in the root of the pterygoid process; and in doing this he must define the small pharyngeal branches of nerve and artery which are superficial to the Vidian, and lie in the pterygo-palatine canal. At the back of the Vidian canal, a small branch from the nerve to the plexus on the internal carotid artery is to be looked for. Lastly, the prolongation of the Vidian nerve (large superficial petrosal) is to be followed into the skull through the dense tissue in the foramen lacerum, after cutting away the point of Vidian nerve.

the petrous portion of the temporal bone, and dividing the internal carotid artery; and it is to be pursued on the surface of the temporal bone, beneath the ganglion of the fifth nerve, to the hiatus Fallopii: its junction with the facial nerve will be seen with the dissection of that nerve.

Seek
branches to
the nose.

The branches of the ganglion to the nose will be found entering the outer surface of the detached mucous membrane opposite the spheno-palatine foramen, with corresponding arteries. One of these nerves (naso-palatine), dissected before in the membrane of the septum, is to be isolated, and to be followed forwards to where it enters the floor of the nose. The branches of the internal maxillary artery with the nerves are to be cleaned at the same time.

Arteries.

Ganglion of
Meckel.

The SPHENO-PALATINE OR MECKEL'S GANGLION (fig. 34,⁷) lies in the spheno-maxillary fossa, close to the spheno-palatine foramen, and is connected with the branches of the superior maxillary nerve to the palate. The ganglionic mass is somewhat triangular in form, and of a reddish grey colour. It is situate, for the most part, behind the branches (spheno-palatine) of the superior maxillary nerve, so as to surround only some of their fibres; and it is prolonged posteriorly into the Vidian nerve. Meckel's ganglion resembles the other ganglia in connection with the fifth nerve in having sensory, motor, and sympathetic offsets or roots connected with it.

Situation
and connec-
tion with
fifth nerve.

Composi-
tion.

Branches.

The *branches* of the ganglion are distributed chiefly to the nose and palate, but small offsets are given to the pharynx and the orbit. Other offsets or roots connect it with surrounding nerves.

Nasal
branches
are—

Branches to the nose. The nasal branches, from three to five in number, are very small and soft, and pass inwards through the spheno-palatine foramen; they are distributed in the nose and the roof of the mouth.

superior
nasal,

The *superior nasal branches* ramify in the mucous membrane on the two upper spongy bones, and a few filaments reach the back part of the septum nasi.

naso-
palatine.

The *naso-palatine nerve* (nerve of Cotunnus—fig. 33,³) crosses the roof of the nasal fossa to reach the septum, on which it descends to near the front of that partition. In the floor of the nose it enters a special canal by the side of the septum, the left being anterior to the right, and is conveyed to the roof of the mouth, where it lies in the centre of the anterior palatine fossa. Finally, the nerves of opposite sides are distributed in the mucous membrane behind the incisor teeth, and communicate with one another. On the septum nasi filaments are supplied by the naso-palatine nerve to the mucous membrane. To follow the nerve to its termination, the canal in the roof of the mouth must be opened.

Palatine
branches

Branches to the palate. The nerves of the palate, though connected in part with the ganglionic mass, are the continuation of the spheno-palatine branches of the superior maxillary nerve (p. 100). Below the ganglion they are divided into three—large, small, and external.

are three.

Large nerve

The *large or anterior palatine nerve* (fig. 34,⁹) reaches the roof of

the mouth through the largest palatine canal, and courses forwards nearly to the incisor teeth, where it joins the naso-palatine nerve. While in the canal, the nerve furnishes two or more filaments (*inferior nasal*,†) to the membrane on the middle and lower spongy bones; in the roof of the mouth it supplies the mucous membrane and glands, and gives an offset to the soft palate.

The *small* or *posterior palatine nerve* ⁽¹⁰⁾ lies in the smaller canal, and ends inferiorly in the soft palate, the uvula, and the tonsil. It is said to supply the levator palati and azygos uvulæ muscles.

The *external palatine nerve* is smaller than the other two, and descends in the canal of the same name to be distributed to the velum palati and the tonsil.

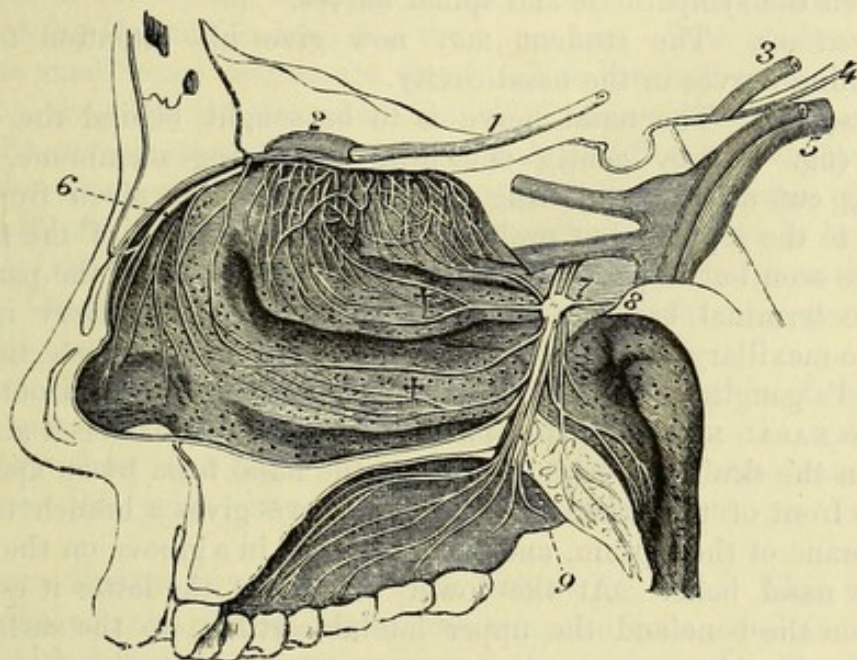
The *pharyngeal branch* is very small, and is directed through the

has branches
to nose;

external
palatine.

Pharyngeal
branch.

Fig. 34.*



pterygo-palatine canal to supply the mucous membrane of the pharynx near the Eustachian tube.

Branches to the orbit. Two or three in number, these ascend through the spheno-maxillary fissure, and end in the periosteum and orbital muscle (p. 50). It will be necessary to cut through the sphenoid bone to follow these nerves to their termination.

Connecting branches. The ganglion is united, as before said, with the sphenopalatine branches of the fifth nerve (fig. 34,⁷), receiving sensory fibres through them; and through the medium of the Vidian, which is described below, it communicates with a motor nerve (facial), and with the sympathetic nerve.

Orbital
branches.

Uniting
branches,
to fifth,

* Nerves of the outer wall of the nose and of the palate. 1. Olfactory tract. 2. Olfactory bulb giving branches to the nose. 3. Third nerve. 4. Fourth nerve. 5. Fifth nerve. 6. Nasal nerve of the ophthalmic trunk. 7. Meckel's ganglion. 8. Vidian nerve. 9. Large palatine nerve. 10. Small palatine nerve. †† Nasal branches.

and to facial
and sympa-
thetic
through the
Vidian.

The *Vidian nerve* ⁽⁸⁾ passes backwards through the Vidian canal, and sends some small filaments through the bone to the membrane at the back of the roof of the nose (*upper posterior nasal branches*). At its exit from the canal, the nerve receives a soft reddish offset (*large deep petrosal nerve*) from the sympathetic on the outer side of the carotid artery. The continuation of the nerve enters the cranium through the foramen lacerum, and is directed backwards in a groove on the surface of the petrous part of the temporal bone, where it takes the name of *large superficial petrosal nerve* (fig. 35,²). Lastly it is continued through the hiatus Fallopii, to join the gangli-form enlargement on the facial nerve (p. 145). While in the temporal bone, the large superficial petrosal receives a twig from the tympanic nerve.

Vidian a
compound
nerve.

The Vidian nerve is supposed to consist of motor and sympathetic fibres in the same sheath, as in the connecting branches between the sympathetic and spinal nerves.

Directions. The student may now give his attention to the remaining nerves in the nasal cavity.

Seek other
nerves and

Dissection. The nasal nerve is to be sought behind the nasal bone (fig. 34) by gently detaching the lining membrane, after having cut off the projecting bone. A branch is given from the nerve to the septum, but probably this, and the trunk of the nerve, will be seen but imperfectly in the present condition of the part.

vessels of
nose.

The terminal branches of the internal maxillary artery in the spheno-maxillary fossa have been laid bare in the dissection of Meckel's ganglion, but they may be now completely traced out.

Nasal nerve
lies beneath
nasal bone ;
gives

The NASAL NERVE (of the ophthalmic) (fig. 34,⁶) has been already seen in the skull and orbit. Entering the nasal fossa by an aperture at the front of the ethmoid bone, the nerve gives a branch to the membrane of the septum, and then descends in a groove on the back of the nasal bone. At the lower margin of the latter it escapes between the bone and the upper lateral cartilage to the surface of the nose (p. 44).

branch to
septum

Branches. The *branch to the septum* (fig. 33) divides into filaments that ramify on the anterior part of that partition, and reach nearly to the lower border.

and to
outer wall.

One or two filaments are likewise furnished by the nerve to the mucous membrane on the outer wall of the nasal fossa ; these extend as low as the inferior spongy bone.

Branches of
internal
maxillary
artery are

TERMINAL BRANCHES OF THE INTERNAL MAXILLARY ARTERY. The branches of the artery in the spheno-maxillary fossa, which have not been examined, are the superior palatine, nasal, pterygo-palatine, and Vidian.

palatine
branch ;

The *superior* or *descending palatine* is the largest branch, and accompanies the large palatine nerve through the canal, and along the roof of the mouth ; it anastomoses behind the incisor teeth with its fellow, and with the naso-palatine branch through the incisor foramen. This artery supplies offsets to the soft palate and tonsil through the other palatine canals, and some twigs are furnished to the lining membrane of the nose. In the roof of the mouth

the mucous membrane, glands and gums receive their vessels from it.

The *nasal* or *spheno-palatine artery* enters the nose through the spheno-palatine foramen, and divides into branches. Some of these are distributed on the spongy bones, and the outer wall of the nasal fossa, and supply offsets to the posterior ethmoidal cells. One long branch, *naso-palatine* or *artery of the septum nasi*, runs on the partition between the nasal fossæ to the incisor foramen, through which it anastomoses with the superior palatine in the roof of the mouth; this branch accompanies the naso-palatine nerve, and covers the septum with numerous ramifications. nasal branches,
one to septum nasi;

The *pterygo-palatine* is a very small branch which, passing backwards through the canal of the same name, is distributed to the lining membrane of the pharynx. pterygo-palatine branch;

The *Vidian* or *pterygoid branch* is contained in the Vidian canal with the nerve of the same name, and ends on the mucous membrane of the Eustachian tube and the upper part of the pharynx. Vidian branch.

Some small *nasal arteries* are furnished to the roof of the nasal fossa by the posterior ethmoidal branch of the ophthalmic (p. 46). Also the *anterior ethmoidal* (internal nasal, p. 46) enters the cavity with the nasal nerve, and ramifies in the lining membrane of the fore part of the nasal chamber as low as the vestibule; a branch passes to the face between the nasal bone and the cartilage with the nerve. Other offsets from the *facial artery* supply the nose near the nostril. Other nasal arteries.

Veins. The veins accompanying the terminal branches of the internal maxillary artery enter the alveolar plexus in the spheno-maxillary fossa (p. 89). Beneath the mucous membrane of the nose the veins have a plexiform arrangement, as before said. Veins to alveolar plexus.

FACIAL NERVE IN THE TEMPORAL BONE (fig. 35). This nerve winds through the petrous part of the temporal bone; and it is followed with difficulty in consequence of the extreme density of the bone, and the absence of marks on the surface to indicate its position. To render this dissection easier, the student should be provided with a temporal bone, in which the course of the facial nerve and the cavity of the tympanum are displayed. Facial nerve.

Dissection. The trunk of the nerve is to be found as it leaves the stylo-mastoid foramen, and from this point it is to be followed upwards through the temporal bone. With this view, the side of the skull should be sawn through vertically between the meatus auditorius externus and the anterior border of the mastoid process, so as to open the lower part of the aqueduct of Fallopius from behind. The nerve will be then seen entering deeply into the substance of the temporal bone; and it can be followed forwards by cutting away with the bone-forceps all the bone projecting above it. In this last step the cavity of the tympanum will be opened, and the chain of bones in it exposed. Dissection of nerve in the bone,

The nerve is to be traced onwards along the inner side of the tympanum, until it becomes enlarged, and bends suddenly inwards and its genu;

to the meatus auditorius internus. The surrounding bone is to be removed from the enlargement, so as to allow of the petrosal nerves being traced from it; and the internal meatus is to be laid open, to see the facial and auditory nerves in that canal.

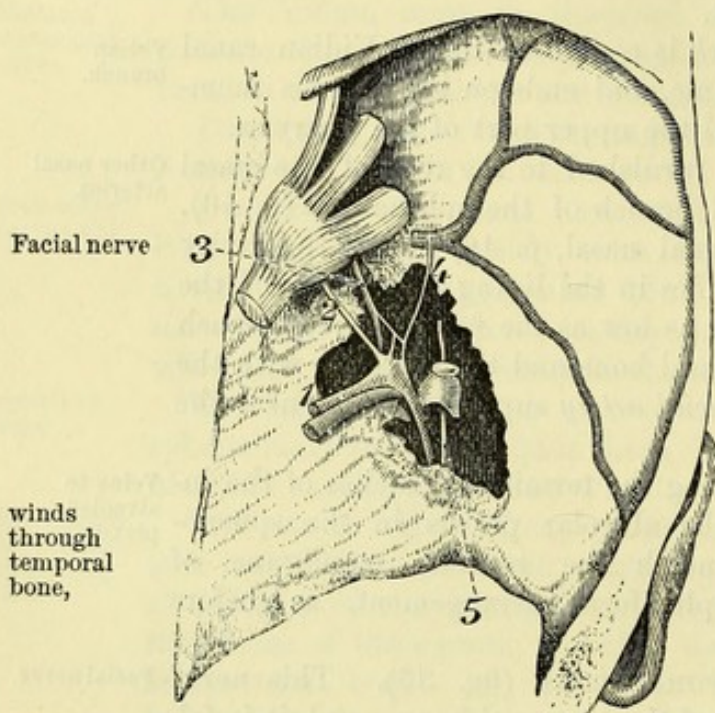
of chorda
tympani;

The course of the chorda tympani nerve (branch of the facial) across the tympanum will be brought into sight by the removal of the central ear bone, the incus. This nerve may be also followed to the facial through the wall of the cavity behind, as well as out of the cavity in front.

and other
branches.

The remaining branches of the facial nerve in the bone are very minute, and are not to be seen except on a fresh piece of the skull

Fig. 35.*



Facial nerve

winds
through
temporal
bone,

is marked
by swelling
which
receives
twigs.

Branches
joining
nerve

to auditory,

is marked by a ganglionic swelling—*geniculate ganglion*, with which several small nerves are united. From this swelling the nerve is continued at first backwards and then downwards through the arched aqueduct, to the aperture of exit from the bone.

The *branches* of the nerve in the bone serve chiefly to connect it with other nerves; but one supplies the tongue, and another the stapedius muscle.

* *Connecting branches* unite the facial with the auditory and glosso-pharyngeal nerves, with Meckel's ganglion, and with the lingual branch of the inferior maxillary nerve.

* *Union with the auditory nerve.* In the bottom of the meatus the facial and auditory nerves are connected by one or two minute filaments.

which has been softened in acid. The student may, therefore, omit the paragraphs marked with an asterisk, until he is able to obtain a part on which a careful examination can be made.

The *facial nerve* (fig. 35,¹) traverses the internal auditory meatus, and entering the aqueduct of Fallopius at the bottom of that hollow, is conducted through the temporal bone to the stylo-mastoid foramen and the face (p. 36). In its serpentine course through the bone, the nerve is first directed outwards to the inner wall of the tympanum; at that spot it bends backwards, and

* Facial nerve in the temporal bone. 1. Facial nerve. 2. Large superficial petrosal. 3. Small superficial petrosal from Jacobson's nerve. 4. External superficial petrosal. 5. Chorda tympani of the facial.

* *Connecting branches of the geniculate ganglion.*—From the convexity of the swelling on the facial nerve three small branches proceed. One is the *large superficial petrosal nerve* ⁽²⁾, passing to the Vidian (p. 142); another is a filament of communication with the small superficial petrosal nerve of the tympanic plexus ⁽³⁾; and the third is the *external superficial petrosal nerve* ⁽⁴⁾, which unites the ganglion with the sympathetic on the middle meningeal artery. to Meckel's ganglion, tympanic of glosso-pharyngeal, and sympathetic;

* The branch of the *stapedius muscle* arises at the back of the tympanum, and is directed forwards to its muscle. nerve to stapedius;

Chorda tympani. This long but slender branch of the facial nerve crosses the tympanum, and ends in the tongue. Arising about a quarter of an inch from the stylo-mastoid foramen, it enters the tympanum below the pyramid. In the cavity (fig. 35,⁵) the nerve is directed forwards across the handle of the malleus and the membrana tympani to an aperture on the inner side of the Glaserian fissure, through which it leaves the tympanum. chorda tympani to lingual.

Outside the skull the chorda tympani joins the lingual nerve, and continues along it to the submaxillary ganglion and the tongue (p. 98).

The AUDITORY NERVE will be learnt with the ear. Entering the internal auditory meatus with the facial nerve, it divides into an upper smaller, and a lower larger part, which are distributed to the membranous labyrinth. Auditory nerve.

OTIC GANGLION. At this stage of the dissection there is little to be seen of the ganglion, but the student should keep in mind that it is one of the things to be examined in a fresh part. Its situation is on the inner aspect of the inferior maxillary nerve, immediately below the foramen ovale, and it adheres closely to the trunk of the nerve. Otic ganglion.

Dissection (fig. 36). Putting the part in the same position as for the examination of Meckel's ganglion, the dissector should define the Eustachian tube and the muscles of the palate, and then take away the levator palati and the cartilaginous portion of the tube, using much care in removing the latter. When some loose areolar tissue has been cleared away, the internal pterygoid muscle (*b*) comes into view, with the trunk of the inferior maxillary nerve above it; and a branch (internal pterygoid,⁵) descending from that nerve to the muscle. If the nerve to the pterygoid be taken as a guide, it will lead to the ganglion. Dissection, to find it,

To complete the dissection, saw vertically through the petrous part of the temporal bone near the inner wall of the tympanum, the bone being supported while it is divided. Taking off some membrane which covers the ganglion, the student may follow backwards a small branch to the tensor tympani muscle; but he should open the small tube that contains the muscle, by entering it below through the carotid canal. Above this small branch there is another minute nerve (small superficial petrosal), which issues from the skull, and joins the back of the ganglion. A small twig is to be sought from the front of the ganglion to the tensor palati to define ganglion and its branches.

muscle ; and other minute filaments to join the sympathetic nerve on the large meningeal artery and the chorda tympani.

Otic ganglion is on inner side of inferior maxillary.

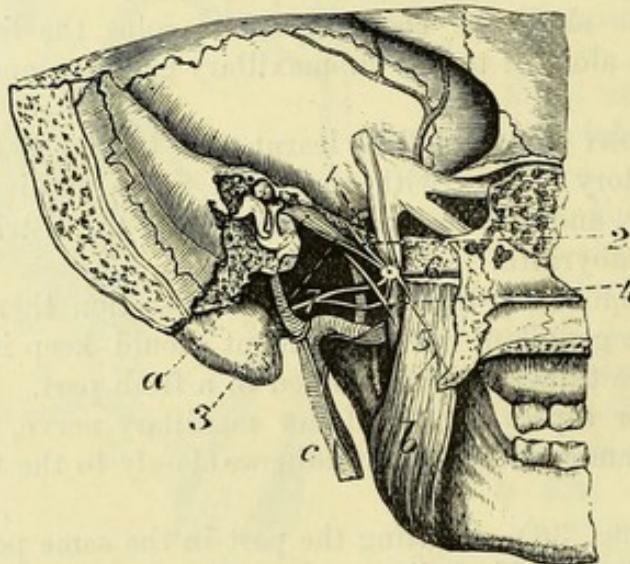
Structure.

Branches join it with fifth,

The OTIC GANGLION (Arnold's ganglion, fig. 36) is a small reddish body, which is situate on the inner surface of the inferior maxillary nerve close to the skull, and surrounds the origin of the nerve to the internal pterygoid muscle. By its inner surface the ganglion is in contact with the Eustachian tube, and at a little distance behind lies the large meningeal artery. In this ganglion, as in the others connected with the fifth nerve, filaments from motor, sensory, and sympathetic nerves are blended. Some twigs are furnished by it to muscles.

Connecting branches—roots. Through its connection with the nerve to the internal pterygoid, the otic ganglion receives fibres from both the small and large roots of the inferior maxillary nerve, so that it

Fig. 36.*



sympa-
thetic,

seventh,
ninth,

auriculo-
temporal,
and chorda
tympani.

Branches to
muscles ;
tensor
tympani

may be said to derive its motor and sensory roots from the fifth. Its sympathetic root comes from the plexus on the middle meningeal artery. The ganglion is farther joined behind by the small superficial petrosal nerve (2), through which fibres are conveyed to it from the facial and glosso-pharyngeal nerves. One or two short branches pass between the ganglion and the beginning of the auriculo-temporal nerve ; and a filament descends to the chorda tympani.

Branches to muscles. Two muscles receive their nerves through the otic ganglion, viz., tensor tympani and tensor palati. The nerve to the tensor tympani (3) is directed backwards to gain the bony

* The otic ganglion from the inner side. a. Tensor tympani muscle. b. Internal pterygoid muscle. c. External carotid artery with the sympathetic on it. 1. Otic ganglion. 2. Small superficial petrosal nerve. 3. Nerve to tensor tympani. 4. Chorda tympani joining lingual. 5. Nerve to internal pterygoid. 6. Nerve to tensor palati. 7. Auriculo-temporal nerve.

canal lodging the muscle. The *branch for the tensor palati* ⁽⁶⁾ arises ^{and} from the front of the ganglion, and enters the outer surface of its ^{tensor} muscle. The fibres of these branches are derived mainly from the internal pterygoid nerve.

The *nerve of the internal pterygoid muscle* ⁽⁵⁾ arises from the inner side of the inferior maxillary nerve near the skull, and penetrates ^{Nerve of} the deep surface of the muscle. This nerve is formed almost ^{internal} entirely by an offset from the motor root of the fifth. ^{pterygoid.}

Directions. The remainder of the pterygo-maxillary region of the left side may be now examined. ^{Directions.}

SECTION XV.

DISSECTION OF THE TONGUE.

Directions. The tongue and larynx are to remain connected with each other while the student learns the general form and structure of the tongue. ^{Directions.}

Dissection. The ends of the extrinsic lingual muscles that have been detached on the right side may be shortened, but enough of each should be left to trace it afterwards into the substance of the tongue. ^{Dissection.}

The TONGUE is an ovoidal, somewhat flattened body, with the larger end turned backwards, which occupies the floor of the mouth, and forms a part of the anterior wall of the pharynx. It is free over the greater part of its surface; but at the back, and at the posterior two-thirds of the under surface, it is attached by muscles and mucous membrane to the parts around. ^{Tongue.} ^{Form and situation.}

The tip of the tongue (apex) touches the incisor teeth. The base is attached to the hyoid bone, and is connected likewise with the epiglottis by three folds of mucous membrane—a central and two lateral. ^{Relations of apex, and base.}

The upper surface or *dorsum* is convex, and in the anterior two-thirds of its extent is marked by a median longitudinal groove or *raphé*, which terminates behind in a depression of variable depth, named the *foramen cæcum*. From the depression a slight lateral groove is directed outwards and forwards on each side for a short distance. The part of the tongue in front of the lateral grooves is distinguished as the *body*, and is received into the hollow of the roof of the mouth: its surface is covered with papillæ. The posterior third or *root* of the organ looks into the pharynx; and its surface is smoother, although rendered somewhat irregular by projecting mucous glands and groups of lymphoid follicles, and by small apertures leading into recesses of the mucous membrane. The under surface, free only in part, gives attachment to the mucous ^{Upper surface.} ^{Body.} ^{Root.} ^{Lower surface.}

membrane and to the different lingual muscles connected with the hyoid bone and the jaw. In front of the muscles the mucous membrane forms a fold in the middle line, termed the *frænum linguae*; and on each side an irregular ridge—*plica fimbriata* (better seen in infants), runs forwards and inwards about midway between the frænum and the margin of the tongue towards the tip.

Borders.

Each border of the tongue is joined opposite the lateral groove above mentioned by the fold of mucous membrane descending from the soft palate, and known as the anterior pillar of the fauces. Behind this fold, the root of the tongue is attached on each side to the wall of the pharynx; but in front, the margin of the body is free. The free border is thick and rounded in its hinder part, where it is marked by vertical ridges and furrows, and becomes gradually thinner towards the tip.

Kinds of papillæ:

PAPILLÆ. On the dorsum of the tongue are the following kinds of papillæ; the conical and filiform, the fungiform, and the circumvallate.

conical and filiform:

The *conical* and *filiform papillæ* are the numerous small projections which cover the anterior two-thirds of the dorsum of the tongue. They taper from the base towards the free extremity, where they are provided with smaller secondary papillæ; and many of them, especially towards the sides of the organ, have their epithelial covering produced into long hair-like processes, whence the name filiform is given to them. Towards their limit behind they are arranged in lines parallel to the lateral grooves, and on the sides they form vertical rows.

fungiform:

The *fungiform papillæ* are less numerous but larger than the preceding set, amongst which they are scattered, especially at the tip and sides of the tongue. They are wider at the free end than at the part fixed to the tongue, and project beyond the conical papillæ. Their surface is covered with small simple papillæ.

circumvallate.

The *circumvallate papillæ* are much larger than the foregoing, and are placed at the junction of the middle and posterior thirds of the tongue. Their number varies from seven to twelve. One, larger than the rest, is situate immediately in front of the foramen cæcum, and the others are disposed in two rows (one on each side) parallel to the lateral groove, so as to form a figure like a widely-spread letter V. Each papilla is attached by a constricted stem, which is surrounded by a groove; its wider end or base projects beyond the surface of the tongue, and is covered with small simple papillæ. Around the groove the mucous membrane forms a slightly prominent fold, which is also beset with secondary papillæ.

Parts found in tongue.

STRUCTURE. The tongue consists of two symmetrical halves separated by a fibrous layer in the median plane. Each half is made up of muscular fibres with interspersed fat; and entering it are the lingual vessels and nerves. The tongue is enveloped by mucous membrane; and a special fibrous layer attaches it to the hyoid bone.

Define septum,

Dissection. To define the septum, and the membrane attaching

the tongue to the hyoid bone, the tongue is to be placed on its dorsum; and, the remains of the right mylo- and genio-hyoid muscles having been removed, the genio-glossi muscles are to be cleaned, and drawn from one another along the middle line. After separating those muscles, and cutting across their intercommunicating fibres, the edge of the septum will appear. By tracing the hinder fibres of the genio-glossus muscle towards the hyoid bone, the hyo-glossal membrane will be arrived at.

hyo-glossal
membrane,

On the outer side of the genio-glossus muscle is the longitudinal bundle of the inferior lingualis, which will be better seen subsequently.

and inferior
lingualis.

Fibrous tissue. Along the middle line of the tongue is placed a thin lamina of this tissue, forming a septum; the root of the tongue is attached by another fibrous structure, the hyo-glossal membrane; and covering the greater part of the organ in a submucous layer of the same tissue.

Fibrous
structures
of tongue.

Septum. This structure forms a vertical partition between the two halves of the tongue (fig. 38, B), and extends from the base to the apex, but does not reach to the dorsum. It is thicker behind than in front, and is connected posteriorly with the hyo-glossal membrane. To each side the transverse muscle is attached. Its disposition may be better seen subsequently on a vertical section.

Septum.

The *hyo-glossal membrane* is a thin but strong fibrous lamina, which attaches the root of the tongue to the upper border of the body of the hyoid bone. On its under or anterior surface some of the hinder fibres of the genio-glossi are inserted, as if this was their aponeurosis to attach them to the hyoid bone.

Hyo-glossal
membrane.

The *submucous fibrous stratum* of the tongue invests the organ, and is continued into the sheaths of the muscles. Over the posterior third of the dorsum its strength is greater than elsewhere; and in front of the epiglottis it forms bands in the folds of the mucous membrane in that situation. Into it are inserted the muscular fibres which end on the surface of the tongue.

Submucous
layer.

MUSCLES. Each half of the tongue is made up of extrinsic and intrinsic muscles. The former or external are distinguished by having only their termination in the tongue; and the latter or internal, by having both origin and insertion within the organ—that is to say, springing from one part and ending at another.

Muscles in
each half.

Two kinds.

The *extrinsic muscles* (fig. 37) are the following: palato-glossus, stylo-glossus, genio-glossus, hyo-glossus, chondro-glossus, and pharyngeoglossus. Only the lingual endings of these, except in the case of the chondro-glossus, are now to be studied.

Extrinsic;
number.

Dissection. After the tongue has been firmly fastened on its left side, the extrinsic muscles may be dissected on the right half. Three of these muscles, viz., palato- (D), stylo- (B), and hyo-glossus (C), come together to the side of the tongue; and, to follow their radiating fibres inwards and forwards, it will be necessary to remove from the dorsum, between them and the tip, a thin layer consisting of the mucous membrane with the submucous fibrous tissue, and the fleshy fibres of the upper lingualis. Beneath the tip a junction

Dissection
of palato-
stylo-, and
hyo-glossus,

between the stylo-glossus muscles of opposite sides is to be traced.

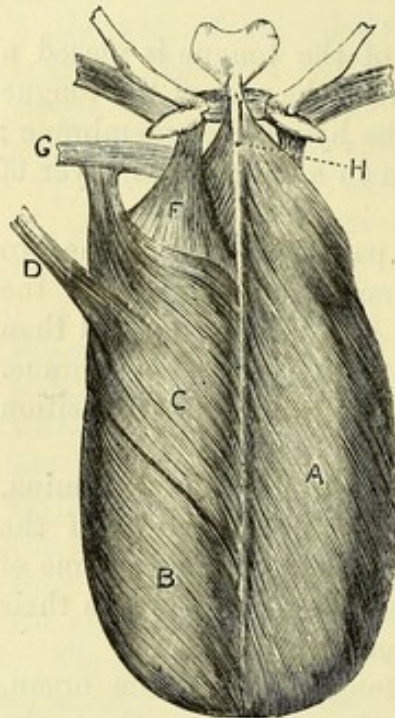
of pharyngeoglossus,

The piece of the constrictor muscle (G) which is attached to the tongue, and the ending of the genio-glossus will come into view on the division of the hyo-glossus.

of chondroglossus.

To lay bare the chondro-glossus (F), which is a small muscular slip attached to the lesser cornu of the hyoid bone, turn upwards the dorsum of the tongue, and feel for the small cornu of the hyoid

Fig. 37.*



Palato-glossus in tongue.

Stylo-glossus prolonged to tip of tongue;

sends many fibres inwards.

Hyo-glossus

united with palato- and stylo-glossus.

Chondro-glossus.

Muscular cortex of tongue.

through the mucous membrane. Then remove the mucous membrane in front of this, and the fibres of the muscle radiating forwards will be visible.

The PALATO-GLOSSUS reaches the side of the tongue at the junction of the posterior and middle thirds. Its fibres are directed inwards, in part on the surface, and in part deeply with the transverse muscle to the septum.

The STYLO-GLOSSUS joins the body of the tongue below the foregoing, and is continued forwards as a gradually tapering bundle beneath the lateral margin to the tip of the organ, where it becomes united with the inferior lingualis, and meets the muscle of the opposite side. From its upper border fibres are directed inwards over the dorsum of the tongue

to the middle line; and other bundles pass inwards from its lower edge between the fasciculi of the hyo-glossus.

The HYO-GLOSSUS enters the under surface of the tongue in its middle third, between the stylo-glossus and the inferior lingualis. Its fibres are collected into bundles which turn round the margin and form, with those of the preceding muscles, a layer on the dorsum of the tongue, the hinder fibres passing almost transversely inwards, the anterior inclining forwards to the tip.

The CHONDRO-GLOSSUS is a small fan-shaped muscle, which arises from the lesser cornu and the adjacent part of the body of the hyoid bone. Its fibres are directed forwards, spreading out beneath the mucous membrane of the posterior third of the tongue, and are inserted into the submucous layer.

Cortex of the tongue. The muscles above described, together with the superficial lingualis, constitute a cortical layer of oblique and longitudinal fibres, which covers the tongue, except below where the genio-glossus and inferior lingualis muscles are placed, and

* Muscles on the dorsum of the tongue. A. Superficial lingualis. B. Stylo-glossus. C. Hyo-glossus. D. Palato-glossus. E. Chondro-glossus. F. Pharyngeoglossus. H. Septum linguae. (After Zaglas.)

resembles "a slipper turned upside down" (Zaglas). This stratum is pierced by the deeper fibres.

The GENIO-GLOSSUS (fig. 38, A) enters the tongue vertically by the side of the septum, and perforates the cortical covering to end in the submucous tissue. In the tongue the fibres spread like the rays of a fan from apex to base, and are collected into transverse laminæ as they pass through the transversalis. The hindmost fibres end on the hyo-glossal membrane and the hyoid bone; and a slip is prolonged from them, beneath the hyo-glossus, to the upper constrictor of the pharynx. A vertical section at a future stage will show the radiation of its fibres.

The PHARYNGEO-GLOSSUS, or the fibres of the upper constrictor attached to the side of the tongue, passes beneath the fibres of the hyo-glossus, and is continued with the transverse muscle to the septum.

The *intrinsic muscles* are four in number in each half of the tongue, viz., transversalis, a superior and an inferior lingualis, and a set of perpendicular fibres.

Dissection. To complete the preparation of the inferior lingualis on the right side, the fibres of the stylo-glossus covering it in front, and those of the hyo-glossus over it behind are to be cut through.

The superior lingualis (fig. 37, A) may be shown on the left side, by taking the thin mucous membrane from the upper surface from tip to base.

The transversalis may be laid bare on the right side, by cutting away on the upper surface the stratum of the extrinsic muscles already seen; and by removing on the lower surface the inferior lingualis and the genio-glossus, after the former muscle has been examined.

The nerves of the tongue are to be dissected on the left half as well as the part will admit; but a fresh specimen will be required to follow them satisfactorily.

The TRANSVERSALIS MUSCLE (fig. 38, c) forms a horizontal layer in the substance of the tongue from base to apex. The fibres are attached internally to the side of the septum, and are directed thence outwards, the posterior being somewhat curved, to their insertion into the submucous tissue at the side of the tongue.

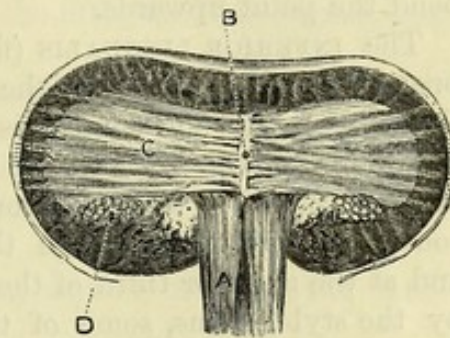
Its fibres are collected into flattened bundles, so as to allow the passage between them of the ascending fibres of the genio-glossus.

Action. By the contraction of the fibres of the two muscles

Genio-glossus in the tongue;

its posterior fibres.

Fig. 38.*



Constrictor in the tongue.

Intrinsic muscles.

First show inferior,

then superior lingualis,

then transversalis.

Trace the nerves.

Transversalis is horizontal.

Attachments.

Fibres in laminæ.

* Transverse section of the tongue. A. Genio-glossus. B. Septum linguae. c. Transversalis. D. Inferior lingualis. (After Zaglas.)

the tongue is made narrower and rounder, and is increased in length.

Superficial
lingualis.

The SUPERIOR LINGUALIS (fig. 37, A) is a very thin layer of oblique and longitudinal fibres close beneath the submucous tissue on the dorsum of the tongue. Its fibres arise from the frænum epiglottidis, and from the fibrous tissue along the middle line; from this attachment they are directed obliquely outwards, the anterior becoming longitudinal, to the margin of the tongue at which they end in the submucous fibrous tissue.

Use.

Action. Both muscles tend to shorten the tongue; and they will bend the point upwards.

Lower
lingualis.

Origin.

Ending.

The INFERIOR LINGUALIS (fig. 38, D) is much stronger than the preceding, and is placed on the under surface of the tongue, between the hyo-glossus and genio-glossus. The muscle *arises* behind from the fascia at the root of the tongue; and the fibres are collected into a roundish bundle: from its attached surface fasciculi are continued upwards through the transverse fibres to the dorsum; and at the anterior third of the tongue, where the muscle is overlaid by the styloglossus, some of the fibres are applied to that muscle and distributed with it.

Use.

Action. This muscle shortens the tongue, and bends the apex downwards.

Perpendicu-
lar muscle.

The intrinsic PERPENDICULAR FIBRES are found near the border of the fore part of the tongue, and can be seen only in transverse sections. They pass from the submucous tissue of the dorsum downwards and somewhat outwards, decussating with the cortical and transverse fibres, to the under surface.

Use.

Action. By their contraction these fibres flatten and render broader the part of the tongue in which they occur.

Medulla of
tongue.

Medullary portion of the tongue. The central part of the tongue, which is thus named, is paler in colour and softer than the cortex. It is composed mainly of the bundles of the transverse muscle crossing the laminae of the genio-glossus internally and the perpendicular fibres externally, together with interspersed fat.

Mucous
membrane;
its epithe-
lium.

The *mucous membrane of the tongue* is a continuation of that lining the mouth, and is provided with a stratified scaly epithelium. It invests the greater part of the tongue, and is reflected off at different points in the form of folds (p. 148). At the epiglottis are three small *glosso-epiglottidean* folds, connecting this body to the root of the tongue; the central one of these is called the *frænum of the epiglottis*. It is furnished with numerous glands, and lymphoid crypts and follicles.

Folds.

Crypts,

The *crypts* are depressions of the mucous membrane, which are surrounded by lymphoid follicles in the submucous tissue, like the arrangement in the tonsil; they occupy the dorsum of the tongue between the circumvallate papillæ and the epiglottis, where they form a stratum close beneath the mucous membrane.

and glands
at the base;

The *lingual glands* are racemose, similar to those of the lips and cheek, and are placed beneath the mucous membrane on the dorsum of the tongue behind the circumvallate papillæ. A few are found

in front of the circumvallate papillæ, where they project into the muscular substance. Some of their ducts open on the surface; others in the hollows around the circumvallate papillæ, or into the foramen cæcum and the depressions of the crypts.

Opposite the circumvallate papillæ, at the margin of the tongue, is a small cluster of mucous glands. Under the tip of the tongue, on each side of the frænum, is another elongated collection of the same kind of glands imbedded in the muscular fibres, from which several ducts issue.

NERVES. There are three nerves on the under surface of each half of the tongue, viz., the lingual of the fifth, the hypoglossal, and the glosso-pharyngeal (fig. 24).

The *lingual nerve* sends upwards filaments through the muscular substance to the mucous membrane of the anterior two-thirds of the tongue, and supplies the conical and fungiform papillæ. Accompanying this nerve are the lingual fibres of the chorda tympani (p. 98).

The *hypoglossal nerve* is spent in long slender offsets to the muscular substance of the tongue.

The *glosso-pharyngeal nerve* divides under the hyo-glossus into two branches. One turns to the dorsum, and ramifies in the mucous membrane behind the foramen cæcum, supplying also the circumvallate papillæ. The other passes to the side of the tongue, and ends in branches for the mucous membrane, extending forwards to about the middle of the border.

VESSELS. The *arteries* are derived from the lingual of each side: the *veins* pass to the internal jugular trunk (p. 96). The *lymphatics* of the tongue for the most part pass backwards to the upper deep cervical glands, and have connected with them two or three small *lingual glands* on the outer surface of the hyo-glossus muscle; but some descend to the submaxillary lymphatic glands.

SECTION XVI.

DISSECTION OF THE LARYNX.

The LARYNX is the upper dilated part of the airtube, in which the voice is produced. It is constructed of several cartilages united together by ligamentous bands; of muscles for the movement of the cartilages; and of vessels and nerves. The whole is lined by mucous membrane.

Dissection. The tongue may be removed from the larynx by cutting through its root, but this is to be done without injuring the epiglottis.

The student will find it advantageous to learn the laryngeal

cartilages before beginning the dissection of the larynx. Their description is given at p. 163.

Situation The larynx is placed in the middle of the neck, in front of the pharynx, and in the resting condition opposite the fourth, fifth and sixth cervical vertebræ. It is however very moveable, its connections permitting especially a considerable degree of elevation, which comes into play in the act of swallowing.

Form ; Its form is pyramidal, the base being turned upwards and attached to the hyoid bone, while the apex joins the trachea. In length it measures, in the male, about an inch and three-quarters ; in width, at the top nearly as much, and at the lower end one inch ; while the greatest depth from before backwards is about an inch and a half. In the female, the average length is an inch and a half, and the depth one inch. Before the age of puberty the larynx is relatively very small.

Relations. On each side the larynx is covered by the depressor muscles of the hyoid bone, the carotid vessels, and the lateral lobes of the thyroid body. The front projects beneath the skin in the middle line of the neck ; and the posterior surface is covered by the mucous membrane of the pharynx.

Muscles, **MUSCLES.** The sterno-thyroid and thyro-hyoid muscles, which, together with the stylo-pharyngeus and inferior constrictor of the pharynx, move the larynx as a whole, are frequently called the *extrinsic* muscles of the larynx. The *intrinsic* muscles are six pairs and one single muscle. Of these, one paired muscle is exposed on the side of the larynx ; two pairs and the single muscle are seen at the back ; and the rest are concealed by the thyroid cartilage.

Directions. *Directions.* On one side of the larynx, say the right, the muscles may be dissected, and on the opposite side the nerves and vessels ; and the superficial muscles are to be first learnt, which do not require the cartilages to be cut.

Dissection *Dissection.* The larynx being extended and fastened with pins, the dissector may clear away from the hyoid bone and the thyroid cartilage the following muscles, viz., omo-hyoid, sterno-hyoid, sterno-thyroid, thyro-hyoid, and inferior constrictor.

of the superficial muscles. Along the side, between the thyroid and cricoid cartilages, the crico-thyroid muscle (fig. 39) will be recognised.

To denude the posterior muscles (fig. 40), it will be necessary to turn over the larynx, and to remove the mucous membrane covering it. On the back of the cricoid cartilage the dissector will find the posterior crico-arytenoid muscle, and above this, on the back of the arytenoid cartilages, the arytenoid muscle will appear, with the crossing fasciculi of the aryteno-epiglottidean muscles on its surface.

Crico-thyroid. The CRICO-THYROID MUSCLE (fig. 39,¹) is fan-shaped, and is separated by a triangular interval from the one on the opposite side. It *arises* from the front and the lateral part of the cricoid cartilage ; and its fibres radiate to be *inserted* into the lower cornu, and the lower border of the thyroid cartilage as far forwards as a quarter of

an inch from the middle line ; as well as for a short distance into the inner surface of that cartilage. The muscle rests on the crico-thyroid membrane, and is concealed by the sterno-thyroid muscle.

Action. It draws the cricoid cartilage upwards and backwards, so as to increase the distance between the thyroid and the arytenoid cartilages, and thus tightens the vocal cords.

Fig. 39.*

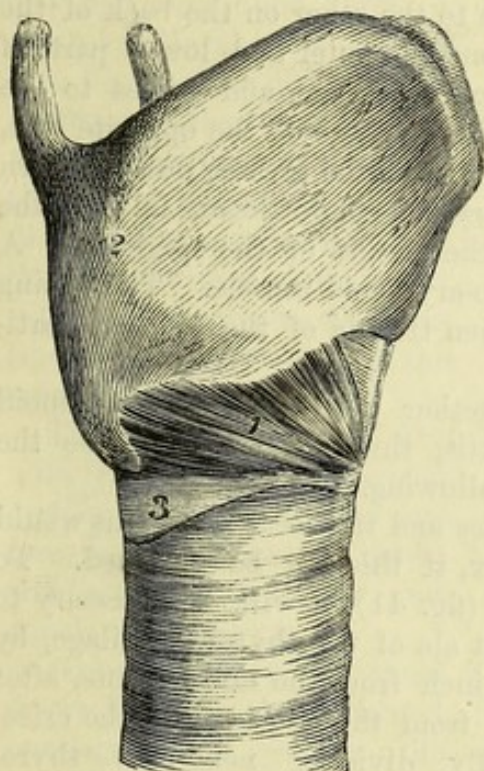
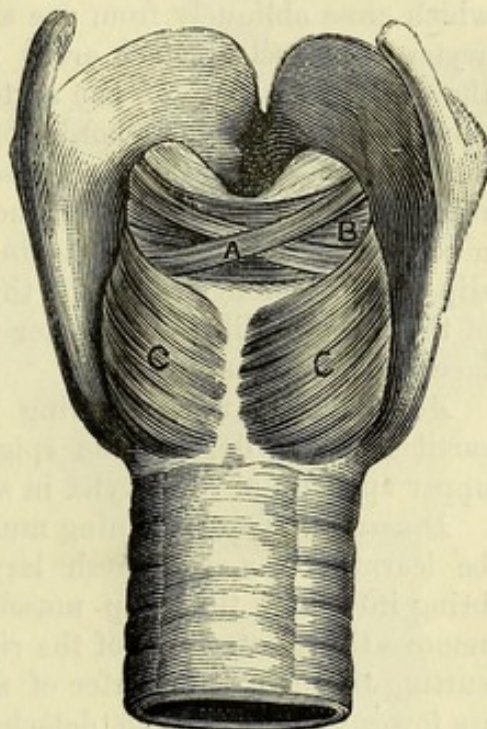


Fig. 40.†



The POSTERIOR CRICO-ARYTENOID MUSCLE (fig. 40, c) arises from the depression by the side of the vertical ridge at the back of the cricoid cartilage. From this origin the fibres are directed outwards and upwards, converging to their *insertion* into the muscular process at the outer side of the base of the arytenoid cartilage. Posterior crico-arytenoid is on back of cricoid cartilage.

Action. It draws the arytenoid cartilage downwards and outwards to a slight extent, separating this from the one of the opposite side ; but its principal action is to rotate the cartilage, turning outwards the vocal process, and thus dilating the glottis. Use.

Kerato-cricoid muscle (Merkel). This is a small fleshy slip which is occasionally seen at the lower border of the preceding muscle. It arises from the cricoid cartilage, and is inserted into the back of the lower cornu of the thyroid cartilage. Kerato-cricoid.

* Side view of the larynx. 1. Crico-thyroid muscle. 2. Thyroid cartilage. 3. Cricoid cartilage.

† Hinder view of the larynx. A. Aryteno-epiglottidean muscle. B. Arytenoid muscle. c. c. Posterior crico-arytenoids.

Arytenoid muscle lies on back of arytenoid cartilages.

The ARYTENOID MUSCLE is single, and extends across the middle line, closing the interval between the arytenoid cartilages behind. Its transverse fibres are attached on each side to the outer part of the posterior surface of the arytenoid cartilage. On its hinder surface lie the aryteno-epiglottidean muscles; and the laryngeal mucous membrane covers it in front in the space between the cartilages.

Use.

Action. It draws together the arytenoid cartilages, rendering narrower the opening of the glottis.

Aryteno-epiglottidean muscles cross like letter X.

The ARYTENO-EPIGLOTTIDEAN MUSCLES are two small bundles which cross obliquely from one side to the other on the back of the arytenoid muscle. Each *arises* from the outer and lower part of the posterior surface of one arytenoid cartilage, and passes to the upper part of the outer border of the cartilage of the opposite side, where a few of the fibres are *inserted*, but the greater number turn round this border and end in the aryteno-epiglottidean fold of the mucous membrane, some reaching the margin of the epiglottis. A slip is also prolonged into the thyro-arytenoid muscle. The ending of the muscle will be seen later when the ala of the thyroid cartilage has been removed.

Use.

Action. These muscles bring together the tips of the arytenoid cartilages, and depress the epiglottis, thus assisting to close the upper aperture of the larynx in swallowing.

Dissection of internal muscles.

Dissection. The remaining muscles and the vocal apparatus would be learnt better on a fresh larynx, if this can be obtained. To bring into view the deep muscles (fig. 41), it will be necessary to remove the greater part of the right ala of the thyroid cartilage, by cutting through it a quarter of an inch from the middle line, after its lower cornu has been detached from the cricoid, and the crico-thyroid muscle taken away. By dividing next the thyro-hyoid membrane attached to the upper margin, the loose piece will come away on separating the subjacent areolar tissue from it.

Remove half of thyroid cartilage.

Position of muscles.

By the removal of some areolar tissue, the dissector will define inferiorly the lateral crico-arytenoid muscle; above it, the thyro-arytenoid muscle; and still higher, the pale fibres of the aryteno-epiglottidean and thyro-epiglottidean muscles in the fold of mucous membrane between the epiglottis and the arytenoid cartilage. On cleaning the fibres of the thyro-arytenoid near the front of the larynx, the top of the sacculus laryngis with its small glands will appear above the fleshy fibres.

Lateral crico-arytenoid muscle.

The LATERAL CRICO-ARYTENOID MUSCLE (fig. 41,³) *arises* from the upper border of the cricoid cartilage at the side, and is directed backwards to be *inserted* into the fore part of the muscular process of the arytenoid cartilage. It is concealed by the crico-thyroid muscle and the thyroid cartilage; and its upper border is contiguous to the succeeding muscle.

Use.

Action. It rotates inwards the arytenoid cartilage, opposing the posterior crico-arytenoid muscle, and approaching the one vocal cord to the other, so as to narrow the glottis.

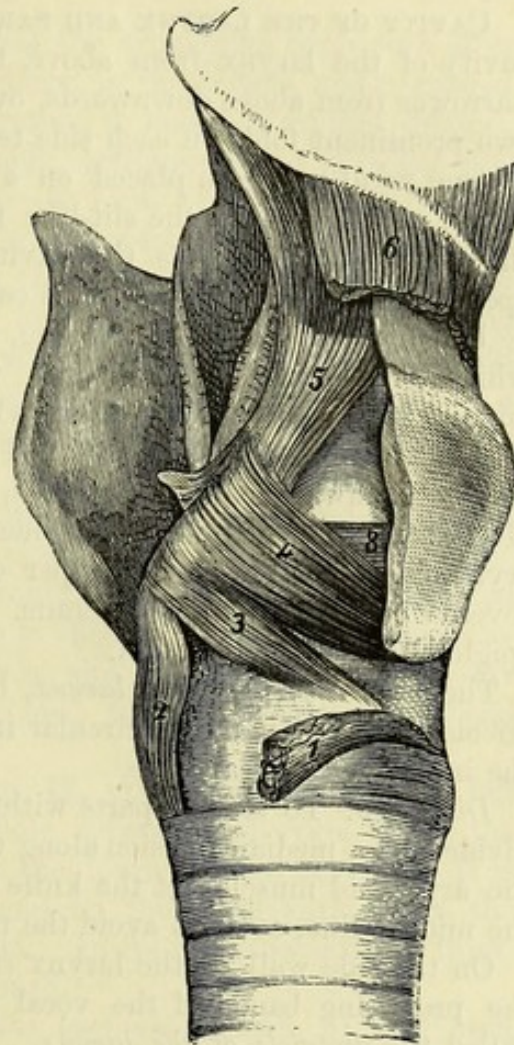
The **THYRO-ARYTENOID MUSCLE** (fig. 41) extends from the thyroid cartilage to the arytenoid cartilage; it is thick below, but thin and expanded above. The muscle *arises* from the thyroid cartilage near the middle line, for about the lower half of its depth, and from the crico-thyroid membrane. The fibres are directed backwards with different inclinations:—The external (⁴) ascend somewhat and are *inserted* into the outer border of the arytenoid cartilage. The internal fibres (⁸) are horizontal, and form a thick bundle which is *inserted* into the margins of the vocal process and the lower part of the outer surface of that cartilage. A few of the deepest fibres of the muscle pass from the outer surface of the vocal process of the arytenoid cartilage to be inserted into the true vocal cord.

The outer surface of the muscle is covered by the thyroid cartilage; and the inner surface rests on the vocal cords, and on the ventricle and pouch of the larynx.

Action. The thyro-arytenoid draws forwards the arytenoid cartilage, and causes the cricoid to move forwards and downwards, thus opposing the crico-thyroid muscle, and shortening the vocal cords. It also moves inwards the fore part of the arytenoid cartilage with the true vocal cord, so as to place the latter in the position necessary for vocalization. The short fibres passing from the arytenoid cartilage to the vocal cord will tighten the fore part, and relax the hinder part of the cord.

The **THYRO-EPIGLOTTIDEAN MUSCLE** is a thin layer which varies much in its development in different bodies. Its fibres *arise* from the thyroid cartilage in conjunction with the outer part of the thyro-arytenoid, and are directed upwards, covering the outer surface of the saccule of the larynx, to be *inserted* into the margin of the

Fig. 41.*

Thyro-ary-
tenoid
muscleconsists of
outerand inner
parts.]Some fibres
from aryte-
noid carti-
lage to vocal
cord.

Relations,

Use.

* Internal muscles of the larynx. 1. Crico-thyroid detached. 2. Posterior crico-arytenoid. 3. Lateral crico-arytenoid. 4. Thyro-arytenoid, superficial part. 5. Depressor of the epiglottis, consisting of fibres of the aryteno-epiglottidean muscle and others given off from the thyro-arytenoid. 6. Thyroid, cut. 8. Deep part of thyro-arytenoid.

epiglottis and the aryteno-epiglottidean fold with the aryteno-epiglottidean muscle. The whole of the muscular fibres passing from the arytenoid and thyroid cartilages to the epiglottis are sometimes described together as the *depressor of the epiglottis*.

Use. *Action.* This muscle draws downwards the epiglottis and aryteno-epiglottidean fold, and assists in closing the upper aperture of the larynx.

Interior of larynx. The cavity is constricted in middle. **CAVITY OF THE LARYNX AND PARTS INSIDE.** On looking into the cavity of the larynx from above, the tube will be seen to become narrower from above downwards, owing to the projection inwards of two prominent folds on each side termed the *vocal cords*. The lower or true vocal cords are placed on a level with the bases of the arytenoid cartilages, and the slit-like interval between them is called the *glottis*. Below this the cavity enlarges again to the *lower aperture of the larynx*, where it is continued into the trachea.

Upper opening, *Upper aperture of the larynx* (fig. 30, N). This is the orifice by which the larynx communicates with the pharynx. It is triangular in shape, with the base, which is formed by the epiglottis, turned forwards and upwards. The sides, which are sloped from before downwards and backwards, are formed by the aryteno-epiglottidean folds of the mucous membrane; and at the apex is the arytenoid muscle, with the upper ends of the arytenoid cartilages, covered by the mucous membrane. This aperture is closed by the epiglottis during deglutition.

Lower opening. The *lower aperture of the larynx*, bounded by the lower edge of the cricoid cartilage, is nearly circular in form, and of the same size as the interior of the cartilage.

Dissection. *Dissection.* To see the parts within the larynx, the tube is to be divided by a median incision along the back; but in cutting through the arytenoid muscle, let the knife be carried a little to the right of the middle line, so as to avoid the nerves entering it.

Parts inside larynx. On the side wall of the larynx (fig. 42) there will now be seen the projecting bands of the vocal cords separated by a depression called the *ventricle of the larynx*. If a probe be passed into this hollow, it will enter a small pouch—*sacculus laryngis*, by an aperture at the upper and fore part, under cover of the superior vocal cord.

Glottis, *The glottis or rima glottidis* is the narrowest part of the laryngeal cavity, and is placed on a level with the bases of the arytenoid cartilages. If the cut surfaces of the back of the larynx be placed together, it will be seen to have the form of an elongated triangle, with the base turned backwards. It is bounded on the sides by the true vocal cords (fig. 42, B) in the anterior two-thirds of its extent, and by the arytenoid cartilages (E) in the posterior third. In front, the right and left vocal cords meet at their attachment to the thyroid cartilage; and behind, the base is formed by the arytenoid muscle. The portion of the slit between the vocal cords, being alone concerned in the production of the voice, is distinguished as the *vocal glottis*, while the part between the arytenoid cartilages is termed the *respiratory glottis*.

The size of the glottis differs in the two sexes; and its form undergoes frequent changes during life, caused by the movements of the arytenoid cartilages and the vocal cords. In the male, the interval measures nearly an inch (eleven lines) from before backwards; in the female, from eight to nine lines. Its breadth at the base is about one-third of the length. The length of the glottis is increased by the stretching, and shortened by the relaxation of the vocal cords.

Size and form vary.
Length, and breadth.

In quiet breathing the glottis has the triangular form seen after death, the space being slightly widened in inspiration, and narrowed in expiration. In forcible inspiration it becomes widely dilated, the vocal processes of the arytenoid cartilages being directed outwards, and the aperture acquiring the form of a lozenge with the posterior angle truncated. The widest part is then opposite the junction of the vocal cords with the arytenoid cartilages, and its transverse measurement is about one half of the length. During vocalization the cords and the vocal processes of the arytenoid cartilages are brought together, and the vocal glottis is reduced to a narrow chink, while the hinder part of the space is closed by the meeting of the anterior borders of the arytenoid cartilages.

Form during life; in easy respiration; in forced inspiration; in production of the voice.

The glottis is rendered longer, and the vocal cords are tightened by the crico-thyroid muscles; the opposite effect is produced by the elasticity of the cords and the contraction of the thyro-arytenoid muscles. Widening of the glottis is effected by the posterior crico-arytenoid muscles; and the cords and arytenoid cartilages are approximated by the thyro-arytenoid, lateral crico-arytenoid, and arytenoid muscles.

Muscles producing changes in glottis.

The *ventricle* of the larynx (fig. 42, A) is best seen on the left side. It is the boat-shaped hollow between the vocal cords, the upper margin being concave, and the lower nearly straight. It is lined by the mucous membrane, and on the outer surface are the fibres of the thyro-arytenoid muscle. In its roof, towards the front, is the aperture of the laryngeal pouch.

Ventricle. Situation.

The *laryngeal pouch* or *sacculus laryngis* (fig. 42, D), has been laid bare partly on the right side by the removal of the ala of the thyroid cartilage (p. 156), but it will be opened in the subsequent dissection for the vocal cords.

Pouch of larynx.

It is a small membranous sac, about half an inch long and rather conical in form, which projects upwards between the false vocal cord and the ala of the thyroid cartilage, reaching as high as the upper border of the latter. Its cavity communicates with the fore part of the ventricle by a somewhat narrow aperture. On the deep surface of the mucous lining are numerous small glands, the ducts of which open on the inside. Its outer side is covered by the thyro-epiglottidean muscle. The size and extent of the pouch vary greatly in different subjects.

Form and position. Surrounding parts.

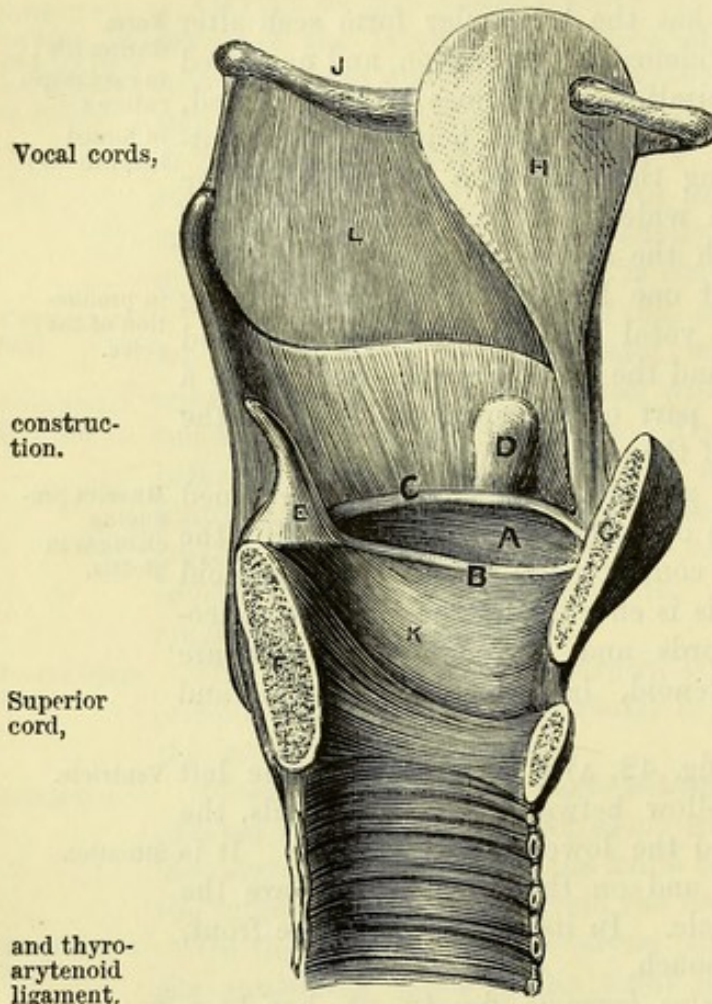
Dissection. The general shape and position of the vocal cords are evident on the left half of the larynx, but to show more fully the nature of the lower cord, put the cut surfaces in contact, and detach on the right side the lateral crico-arytenoid muscle from its

Dissection of vocal cords,

and crico-
thyroid
membrane.

cartilages. Take away in like manner the thyro-arytenoid, raising it from before back. By the removal of the last muscle an elastic membrane, crico-thyroid (fig. 44, ⁶), comes into view; and it will be seen to be continued upwards into, and give rise to the prominence of the inferior or true vocal cord. Lastly, dissect off the mucous membrane

Fig. 42.*



Vocal cords,

construc-
tion.

Superior
cord,

and thyro-
arytenoid
ligament.

Inferior
cord,

from the vocal cords on the right side, and in doing this the wall of the ventricle and saccule, which are formed mainly by this membrane, will disappear.

The *vocal cords* (fig. 42) are two bands on each side, which extend from the angle of the thyroid to the arytenoid cartilage, one forming the upper, the other the lower margin of the ventricle of the larynx. Each consists of a fold of the mucous membrane supported by a ligamentous structure—the superior and inferior thyro-arytenoid ligaments respectively.

The *superior* or *false vocal cord* (c) is arched with its concavity downwards, and is much softer and looser than the lower. Its free border is thick and rounded. The contained *superior thyro-arytenoid ligament* consists mostly of white fibrous tissue, and is

fixed in front to the angle of the thyroid cartilage near the attachment of the epiglottis, behind to the middle portion of the anterior surface of the arytenoid cartilage. It is continuous above with scattered fibrous bundles in the aryteno-epiglottidean fold.

The *inferior* or *true vocal cord* (B) is attached in front to the angle of the thyroid cartilage about half way down below the notch, and behind to the vocal process of the arytenoid cartilage. Between these points, its free margin, by the vibration of which the voice is produced, is straight, sharp and smooth. The cord projects upwards and inwards into the cavity of the larynx, and forms the boundary of the vocal portion of the glottis. It is about seven lines long in

* Vocal apparatus, on a vertical section of the larynx. A. Ventricle of the larynx. B. True vocal cord. c. False vocal cord. D. Saccus laryngis. E. Arytenoid cartilage. F. Cricoid cartilage. G. Thyroid cartilage. H. Epiglottis. K. Crico-thyroid membrane. L. Thyro-hyoid membrane.

the male, and two lines less in the female. The mucous membrane of the true vocal cord is very thin, and intimately united to the *inferior thyro-arytenoid ligament*. The latter structure is the upper edge of the lateral portion of the crico-thyroid membrane, and consists of fine elastic tissue, which shows a slight thickening close to its attachment to the thyroid cartilage. On the outer surface of the ligament is the deep part of the thyro-arytenoid muscle, some of the fibres of which are inserted into the band; and a thin sub-mucous layer of elastic tissue is continued outwards from it to line the ventricle of the larynx.

The *mucous membrane* of the larynx is continued from that lining the pharynx, and is prolonged downwards into the trachea. At the superior aperture of the larynx it forms the aryteno-epiglottidean fold on each side, between the margin of the epiglottis and the tip of the arytenoid cartilage: here it is very loose, and the submucous tissue abundant. In the larynx the membrane lines the wall of the cavity closely, sinks into the ventricle, and sends a prolongation upwards into the laryngeal pouch. On the lower thyro-arytenoid ligaments it is very thin and closely adherent, allowing these to be visible through it.

In the small part of the larynx above the superior vocal cords, the epithelium is of the stratified squamous kind, and free from cilia. But a columnar ciliated epithelium covers the edges of the superior cords and the surface below these, though it becomes flattened without cilia on the lower cords: on the epiglottis the epithelium is ciliated in the lower half.

Numerous racemose *glands* are connected with the mucous membrane of the larynx; and the orifices will be seen on the surface, especially at the posterior aspect of the epiglottis. In the edge of the aryteno-epiglottidean fold there is a little swelling occasioned by a mass of subjacent glands (arytenoid); and along the upper vocal cord lies another set. None exist over the true vocal cords, but close to those bands is the collection of the sacculus laryngis, which moistens the ventricle and the lower vocal cord.

Dissection of nerves and vessels. The termination of the laryngeal nerves may be dissected on the untouched side of the larynx. For this purpose the other half of the thyroid is to be disarticulated from the cricoid cartilage, care being taken of the recurrent nerve, which lies close behind the joint between the two. The trachea and larynx should be fastened down with pins; and after the thyroid has been drawn away from the cricoid cartilage, the laryngeal nerve can be traced over the side of the latter cartilage to the muscles of the larynx and the mucous membrane of the pharynx.

Afterwards the superior laryngeal nerve is to be found as it pierces the thyro-hyoid membrane, and branches of it are to be followed to the mucous membrane of the larynx and pharynx. Two communications are to be looked for between the laryngeal nerves; one is beneath the thyroid cartilage, the other in the mucous membrane of the pharynx.

- of vessels. An artery accompanies each nerve, and its offsets are to be dissected at the same time as the nerve.
- Nerves are from vagus. NERVES. The nerves of the larynx are the superior and inferior laryngeal branches of the pneumo-gastric (p. 110) ; the former is distributed to the mucous membrane, and the latter mostly to the muscles.
- Recurrent nerve. The *inferior laryngeal nerve* (recurrent), when about to enter the larynx, furnishes backwards an offset to the mucous membrane of the pharynx ; this joins filaments of the upper laryngeal. The nerve passes finally beneath the ala of the thyroid cartilage, and ends in branches for all the special muscles of the larynx, except the crico-thyroid. Its small muscular branches are mostly superficial, but that to the arytenoid muscle lies beneath the posterior crico-arytenoid. Beneath the thyroid cartilage the inferior is joined by a long offset of the upper laryngeal nerve.
- supplies intrinsic muscles except one. The *superior laryngeal nerve* pierces the thyro-hyoid membrane, and gives offsets to the mucous membrane of the pharynx ; it furnishes also a long branch beneath the ala of the thyroid cartilage to communicate with the recurrent nerve. The trunk terminates in many branches for the supply of the mucous membrane :—Some of these ascend in the aryteno-epiglottidean fold to the epiglottis, and the root of the tongue. The others, which are the largest, descend on the inner side of the sacculus, and supply the lining membrane of the larynx as low as the true vocal cords. One branch of this set pierces the arytenoid muscle, and ends in the mucous membrane.
- Superior laryngeal nerve. joins recurrent, and ends in mucous membrane.
- Arteries : VESSELS. The arteries of the larynx are furnished from the superior and inferior thyroid branches (pp. 79 and 70).
- superior laryngeal from superior thyroid ; The *laryngeal branch* of the *superior thyroid artery* enters the larynx with the superior laryngeal nerve, and divides into ascending and descending branches ; some of these enter the muscles, but the rest supply the epiglottis, and the mucous membrane from the root of the tongue to the vocal cord. Like the nerves, the two laryngeal arteries communicate both beneath the ala of the thyroid cartilage, and in the mucous membrane of the pharynx.
- inferior laryngeal from inferior thyroid ; The *laryngeal branch* of the *inferior thyroid artery* ascends on the back of the cricoid cartilage, and ends in the mucous membrane of the pharynx and the posterior muscles of the larynx.
- from crico-thyroid artery. Some other twigs from the *crico-thyroid branch* of the *superior thyroid artery* perforate the crico-thyroid membrane, and ramify in the mucous lining of the interior of the larynx at the lower part.
- Veins. *Laryngeal veins.* The vein accompanying the branch of the superior thyroid artery joins the internal jugular or the superior thyroid vein (p. 79) ; and the vein with the artery from the inferior thyroid opens into the plexus of the inferior thyroid veins (p. 119).
- Lymphatics. The *lymphatics* of the larynx pass to the deep cervical glands.

SECTION XVII.

HYOID BONE, CARTILAGES AND LIGAMENTS OF THE LARYNX, AND STRUCTURE OF THE TRACHEA.

Dissection. All the muscles and the mucous membrane are to be taken away so as to denude the hyoid bone, the cartilages of the larynx, and the epiglottis; but the membrane joining the hyoid bone to the thyroid cartilage, and the ligaments uniting one cartilage to another on the left side, should not be destroyed. Dissection.

In the aryteno-epiglottidean fold of mucous membrane, a small cartilaginous body (cuneiform) may be recognised; an oblique whitish projection indicates its position.

The HYOID BONE (fig. 43) is situate between the larynx and the root of the tongue. Resembling the letter U placed horizontally, and with the legs turned backwards, it offers for examination a central part or body, and two lateral pieces or cornua on each side. Hyoid bone.
Form.

The *body* (G) is elongated transversely, in which direction it measures about an inch, and flattened from before back. The anterior surface is convex, and marked in the centre by a tubercle, on each side of which is an impression for muscular attachment. The posterior surface is concave and smooth. To the upper border the hyo-glossal membrane, fixing the tongue, is attached. Body

The cornua are two in number on each side—large and small. The *large cornu* (H) continues the bone backwards, and is joined to the body by an intervening piece of cartilage, or in old persons by continuous bony union. The surfaces of this cornu look rather upwards and downwards; and the size decreases from before backwards. It ends posteriorly in a tubercle. The *small cornu* (J) is directed upwards from the point of union of the great cornu with the body, and is joined by the stylo-hyoid ligament: it is seldom wholly ossified. It is united to the body of the bone by a synovial joint, with a surrounding capsule. Cornua,
large
and small.

CARTILAGES OF THE LARYNX (fig. 43). There are four large cartilages in the larynx, by which the vocal cords are supported, viz., the thyroid, the cricoid, and the two arytenoid. In addition there are some yellow fibro-cartilaginous structures, viz., the epiglottis, a capitulum to each arytenoid cartilage, and a small ovalish piece (cuneiform) in each aryteno-epiglottidean fold of mucous membrane. In larynx
there are
four large
and some
small carti-
lages.

The THYROID CARTILAGE (B) is the largest of all: it forms the front of the larynx, and protects the vocal apparatus as with a shield. The upper part of the cartilage is considerably wider than the lower, and in consequence of this form the larynx is somewhat funnel-shaped. The fore part is prominent in the middle line in front, forming the subcutaneous swelling named *pomum Adami*, and concave behind, where it gives attachment to the epiglottis, and to Thyroid
cartilage

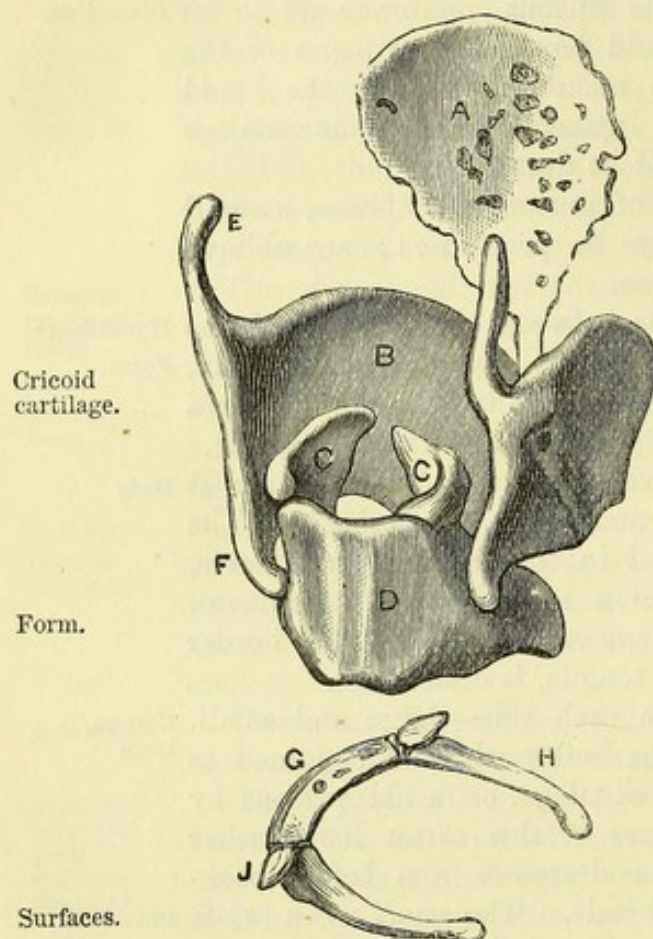
is convex in
front,
concave
behind.

the thyro-arytenoid muscles and ligaments. The upper border is notched in the centre.

Formed of two alæ, each having upper and lower cornua.

The cartilage consists of two squarish halves or *alæ*, which are united in front. Posteriorly each ala has a thick border, which is continued upwards and downwards in a rounded process or *cornu* (E and F). Both cornua are bent slightly inwards : of the two, the

Fig. 43.*



upper (E) is the longer ; but the lower one (F) is the thicker, and articulates with the cricoid cartilage. The inner surface of the ala is smooth ; the outer is marked by an oblique line for the attachment of muscles, which extends from a tubercle near the root of the upper cornu, to a projection at the middle of the lower border.

The CRICOID CARTILAGE (D) is stronger though smaller than the thyroid, and surrounds the lower part of the cavity of the larynx ; it is partly concealed by the thyroid cartilage, below which it is placed. It is very unequal in depth before and behind,—the posterior part being nearly four times as deep as the anterior, something like a signet ring. Its contained space is about as large as the fore finger.

At the back of the cartilage there is a flat and rather square

portion, which is marked on its posterior surface by a median ridge, between two oval depressions occupied by the posterior crico-arytenoid muscles. On each side, immediately in front of the square part, is a slightly raised articular facet, which receives the lower cornu of the thyroid cartilage. The inner surface is smooth, and is covered by mucous membrane.

Borders.

The lower border is horizontal, somewhat undulating, and is united to the trachea by fibrous membrane. The upper border of the broad part of the cartilage is slightly excavated in the middle, and is limited on each side by a convex articular facet for the arytenoid cartilage, which slopes downwards and outwards. In front of that spot, the border descends rapidly as it passes forwards to the middle line.

* Hyoid bone and laryngeal cartilages : G. Body of hyoid bone. H. Large cornu. J. Small cornu.

A. Epiglottis. B. Thyroid cartilage. C.C. Arytenoid cartilages. D. Cricoid cartilage. E. Upper cornu, and F. Lower cornu of thyroid cartilage.

The two ARYTENOID CARTILAGES (c) are placed one on each side at the back of the larynx, on the upper border of the cricoid cartilage. Each is pyramidal in shape, is about half an inch in depth, and offers for examination a base and apex, and three surfaces.

Arytenoid cartilages.

Situation and form.

The base has the form of an elongated triangle, with one of the angles (the postero-internal) rounded off. Its anterior extremity is thin and tapering, and gives attachment to the inferior thyro-arytenoid ligament, whence it is named the *vocal process*. The external angle is thick, and projects backwards and outwards, forming the *muscular process*, into which the crico-arytenoid muscles are inserted. On the under aspect of the muscular process is an oval, concave articular facet, sloped downwards and outwards, for the cricoid cartilage. The apex of the cartilage is directed backwards, and is surmounted by the capitulum of Santorini.

Base.

Apex.

The inner surface is narrow, especially above, and flat; it is covered by the mucous membrane. The anterior or outer surface is the largest and irregular, being convex above and concave below. It is marked near the upper end by a tubercle, and lower down, at the junction of the middle and lower thirds, by an oblique ridge. This surface gives attachment to the superior thyro-arytenoid ligament and the thyro-arytenoid muscle. At its posterior aspect the cartilage is concave and smooth, being covered by the arytenoid muscle.

Surfaces:

internal, anterior or external,

and posterior.

CARTILAGES OF SANTORINI, *cornicula* or *capitula laryngis*. Attached to the apex of each arytenoid cartilage is the small, conical fibro-cartilage of Santorini, which is inclined backwards and inwards. The aryteno-epiglottidean fold is connected with it.

Fibro-cartilages of Santorini.

CUNEIFORM CARTILAGES. Two other small fibro-cartilaginous bodies, one on each side, which are contained in the aryteno-epiglottidean folds, have received this name. Each is somewhat elongated in form, like a grain of rice; it is situated obliquely in front of the capitulum of the arytenoid cartilage, and its place in the fold of the mucous membrane is marked by a slight whitish projection. These cartilages are often absent.

Fibro-cartilages of Wrisberg.

The EPIGLOTTIS (fig. 43, A) is single, and is the largest of the pieces of yellow fibro-cartilage. In form it resembles an obovate leaf, with the stalk below and the blade above. Its position is behind the tongue, and in front of the orifice of the larynx. During respiration it is placed vertically; but during deglutition it takes a horizontal direction so as to close the opening of the larynx.

Epiglottis

Form and position.

The anterior surface is covered in its upper part by mucous membrane, which forms the three glosso-epiglottidean folds (p. 152) between it and the tongue; its lower part is attached to the hyoid bone by fatty tissue containing glands, and by the hyo-epiglottidean ligament. The posterior surface is entirely covered by closely adherent mucous membrane, and is for the most part concave; but at the lower end there is an elevation known as the *tubercle* or *cushion of the epiglottis*. To the sides the aryteno-epiglottidean folds of mucous membrane are united. After the mucous membrane has been removed from the cartilage, its substance will be seen to be excavated by numerous pits, which lodge mucous glands.

Surfaces: anterior,

and posterior.

Sides.

Glands in it.

Ossification
of laryngeal
cartilages.

In the adult the hyaline cartilages of the larynx are commonly to a greater or less extent (in old persons sometimes completely) converted into bone. The ossification begins in the thyroid and cricoid cartilages at about twenty years of age, the deposition of osseous matter in the former taking place first in the neighbourhood of the inferior cornu, and thence extending along the inferior and posterior borders; while in the cricoid two or three bony spots appear near the arytenoid articular surface on each side, and spread through the upper part of the cartilage. The arytenoid cartilages ossify later, from below upwards. The tendency to ossification is more marked in the male than in the female.

Ligaments
of the
larynx.

LIGAMENTS OF THE LARYNX. The larynx is connected by extrinsic ligaments with the hyoid bone above and the trachea below. Other ligaments unite together the cartilages, sometimes with joints.

To hyoid
bone and
trachea.

Union of the larynx with the hyoid bone and the trachea. A loose elastic membrane (thyro-hyoid) extends from the thyroid cartilage to the hyoid bone; and a second membrane connects the cricoid cartilage with the trachea.

Thyro-hyoid
membrane:

The *thyro-hyoid membrane* (fig. 42, L) is attached on the one hand to the upper border of the thyroid cartilage; and on the other, to the upper border of the hyoid bone. Its central part, extending from the body of the hyoid bone to the margins of the notch in the thyroid cartilage, is of some thickness, but its lateral parts are thin and ill-defined. It ends behind in a rounded elastic cord on each side (lateral thyro-hyoid ligament), uniting the extremity of the great cornu of the hyoid bone to the superior cornu of the thyroid cartilage: this band frequently contains a small cartilaginous or osseous nodule (cartilago triticea).

median and
lateral parts.

Lateral
thyro-hyoid
ligament
often
contains
a cartilage.

Relations.

The superior laryngeal nerve and vessels perforate the lateral part of the membrane; and a synovial bursa is placed between its central part and the posterior surface of the body of the hyoid bone.

Crico-
tracheal
membrane.

The membrane joining the lower border of the cricoid cartilage to the first ring of the trachea—*crico-tracheal ligament*, resembles the fibrous layer joining the rings of the trachea to each other.

Between
cricoid and
thyroid
cartilages.

Union of the cricoid and thyroid cartilages. These cartilages are united by a membrane in front, and a synovial joint on each side.

Crico-
thyroid
membrane:

The *crico-thyroid membrane* (fig. 44, ⁶) occupies the space between the thyroid, cricoid, and arytenoid cartilages; and its right half is now visible. It is of a yellow colour and is formed mainly of elastic tissue. By its lower border the membrane is fixed to the upper edge of the cricoid cartilage, reaching back to the articulation with the arytenoid. Its central part is thick and strong, and is attached above to the lower border of the thyroid cartilage. The lateral part is thinner, and is continued upwards beneath the ala of the thyroid cartilage, to end in a thickened border, which is attached behind to the vocal process of the arytenoid cartilage, constituting the inferior thyro-arytenoid ligament in the true vocal cord (p. 161).

median part,
and lateral
parts.

Relations.

The central part of the membrane is partly exposed between the crico-thyroid muscles, and small apertures exist in it for the passage of vessels into the larynx. The lateral part is separated from the

thyroid cartilage by the thyro-arytenoid and lateral crico-arytenoid muscles. The deep surface of the membrane is lined by the mucous membrane.

The *crico-thyroid articulation* is formed between the inferior cornu of the thyroid and the lateral articular facet of the cricoid cartilage. A *capsular ligament*, which is thickest behind, and lined by synovial membrane, surrounds the articulation.

This joint allows of a slight degree of gliding movement backwards and forwards, and of a rotatory movement around a transverse axis, by which the front of the cricoid cartilage is raised or depressed. (See the action of the crico-thyroid and thyro-arytenoid muscles.)

Crico-arytenoid articulation. Between the cricoid and arytenoid cartilages there is a synovial joint surrounded by a loose capsule. To the inner side of the joint there is a well marked *crico-arytenoid ligament*, which passes from the upper border of the cricoid cartilage near the middle line to the adjacent part of the base of the arytenoid, and prevents the latter cartilage being drawn forwards over the cricoid.

The arytenoid cartilage glides upwards and inwards, or downwards and outwards, to a slight extent on the oblique articular facet of the cricoid; but its principal movement is one of rotation, by which the vocal process is carried inwards and somewhat downwards, approximating the vocal cords and narrowing the glottis, or outwards and upwards, enlarging the glottis.

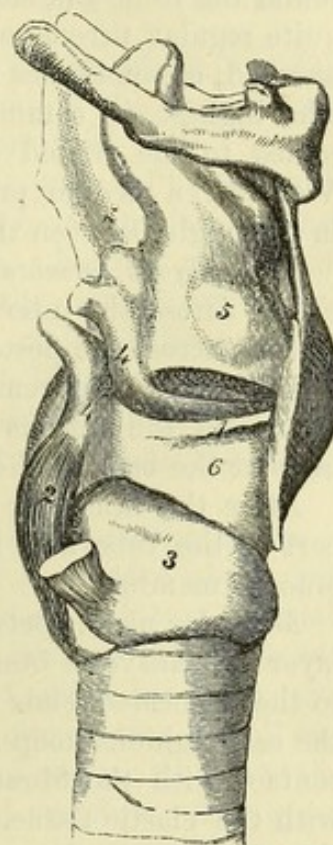
Between the apex of the arytenoid cartilage and the capitulum there is sometimes a synovial joint, but the two cartilages are most frequently united by connective or fibro-cartilaginous tissue.

The *thyro-arytenoid ligaments* have been examined with the vocal cords (p. 160).

Ligaments of the epiglottis. An elastic band, *thyro-epiglottidean ligament*, connects the lower extremity of the epiglottis to the thyroid cartilage, close to the notch in the upper border of the latter (fig. 42); and a membranous layer of fibrous and elastic tissue, *hyo-epiglottidean ligament*, passes between the front of the epiglottis and the hyoid bone.

Fig. 44.*

movements.



Crico-arytenoid joint and ligament.

Movements :
gliding
and
rotation.

* View of the vocal cords and crico-thyroid ligaments. 1. True vocal cord. 2. Posterior crico-arytenoid muscle. 3. Cricoid cartilage. 4. Arytenoid cartilage. 5. Sacculus laryngis. 6. Lateral part of the crico-thyroid membrane.

Constitu- ents of trachea.	STRUCTURE OF THE TRACHEA. The windpipe consists of a series of pieces of cartilage (fig. 40), which are deficient behind, and connected together by fibrous tissue. The interval between the cartilages at the back of the tube is closed by fibrous membrane and muscular fibres; and the interior is lined by mucous membrane with subjacent elastic tissue.
Cartilages. Form. Irregu- larities.	<i>Cartilages.</i> The pieces of cartilage vary in number from sixteen to twenty. Each forms about three-fourths of a ring, extending round the front and sides of the airtube. Their arrangement is not quite regular throughout, for some of them are often bifurcated at one end, or sometimes two adjacent pieces are partly fused together. The highest is commonly broader than the others, and may be joined to the cricoid cartilage. The lowest piece is triradiate, or V-shaped, a median process being sent downwards and backwards in the angle between the two bronchi.
Fibrous layer.	The <i>fibrous membrane</i> ensheaths the cartilages and, being continued across the intervening spaces, binds them together. It also extends across the posterior part of the trachea.
Dissection.	<i>Dissection.</i> On removing for about two inches the fibrous membrane and the mucous glands from the interval between the cartilages at the back of the trachea, the muscular fibres will appear. After the muscular fibres have been examined the membranous part of the tube may be divided, to see the elastic tissue and the mucous membrane.
Muscular layer at back.	<i>Muscular fibres.</i> Between the ends of the cartilages is a continuous layer of transverse bundles of unstriated muscle, which is attached to the truncated ends and the adjacent part of the inner surface of the cartilaginous hoops. By the one surface the fleshy fibres are in contact with the fibrous membrane and glands, and by the other with the elastic tissue. Some longitudinal fibres are superficial to the transverse; they are arranged in scattered bundles, and are attached to the fibrous tissue.
Submucous elastic tissue.	The <i>elastic tissue</i> forms a complete lining to the trachea beneath the mucous membrane; and at the posterior part, where the cartilages are wanting, it is gathered into strong longitudinal bundles. This layer is closely connected with the mucous membrane covering it.
Mucous membrane, epithelium, and glands.	The <i>mucous membrane</i> of the trachea lines the tube, and resembles that of the larynx in being furnished with a columnar ciliated epithelium. Connected with this membrane are numerous branched <i>mucous glands</i> of variable size. The largest are found at the back of the trachea, in the membranous part of the wall, where some are placed outside the fibrous layer, and others between that membrane and the muscular fibres. Smaller glands lie beneath the mucous membrane. Other small glands are found at the front and sides of the trachea, being situate on and in the fibrous tissue connecting the cartilaginous rings.
Vessels and	The <i>arteries</i> of the trachea are derived from the inferior thyroid

and bronchial. The *veins* have a corresponding termination. *Nerves* nerves, are supplied to the tube from the vagus, mainly through the recurrent laryngeal, and from the sympathetic.

SECTION XVIII.

PREVERTEBRAL MUSCLES AND VERTEBRAL VESSELS.

Directions. On the piece of the spinal column which was laid aside after the separation of the pharynx from it the student is to learn the deep muscles on the front of the vertebræ. Muscles in front of spine.

Dissection. The prevertebral muscles will be prepared by removing the fascia and areolar tissue. They are three in number on each side (fig. 45), and are easily distinguished. Nearest the middle line, and the longest, is the longus colli; the muscle external to it, which reaches to the head, is the rectus capitis anticus major; and the small muscle close to the skull, which is external to the last and partly concealed by it, is the rectus capitis anticus minor. The smaller rectus muscle is often injured in cutting through the basilar process of the occipital bone. Dissection.

The LONGUS COLLI MUSCLE (fig. 45, A) is situate on the bodies of the cervical and upper dorsal vertebræ, and is pointed above and below. It consists of three parts—one internal and two external, which differ in the direction of their fibres, but are closely united together. The *internal part* is vertical, and *arises* by fleshy and tendinous processes from the bodies of the upper two dorsal and lower two cervical vertebræ. It is *inserted* by similar slips into the bodies of the second, third and fourth cervical vertebræ. The *upper external part* is inclined obliquely inwards. It *arises* from the anterior tubercles of the transverse processes of the third, fourth, and fifth cervical vertebræ, and is *inserted* into the side of the tubercle on the anterior arch of the atlas. It is generally joined by a slip from the upper end of the vertical part of the muscle. The *lower external part*, also oblique, but in the opposite direction to the last, *arises* in common with the inner part from the upper dorsal vertebræ, and is *inserted* into the transverse processes of the fifth and sixth cervical vertebræ. Longus colli in three parts: internal or straight, superior oblique, and inferior oblique.

In contact with the anterior surface of the longus colli are the pharynx and œsophagus. The inner border is at some distance from the muscle of the opposite side below, but above only the pointed anterior common ligament of the vertebræ separates the two. The outer border is contiguous to the anterior scalenus, to the vertebral vessels, and to the rectus capitis anticus major. The number and attachments of the slips of this muscle are subject to great variation. Parts in contact with it.

Action. Both muscles bend forwards the neck; and the upper oblique part of one may rotate the head to the same side. Use.

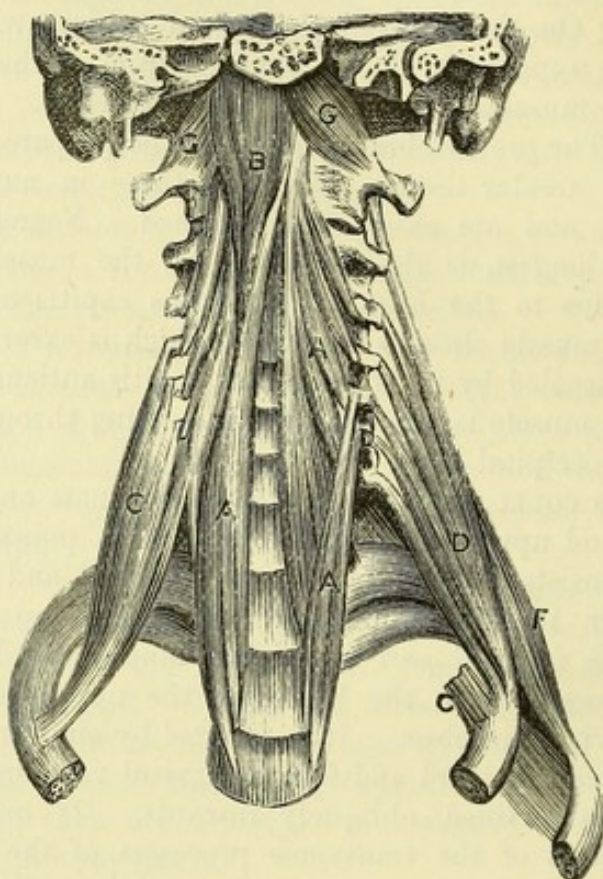
The RECTUS CAPITIS ANTICUS MAJOR (fig. 45, B) is external to Rectus

anticius
major.
Origin.

Insertion.

the preceding muscle, and is largest at the upper end. Its *origin* is by pointed tendinous slips from the anterior tubercles of the transverse processes of the third, fourth, fifth, and sixth cervical vertebræ; and the fibres ascend to be *inserted*, shortly tendinous, into the basilar process of the occipital bone by the side of the pharyngeal tubercle, reaching from the middle line to the petrous portion of the temporal bone.

Fig. 45.*



Relations.

This muscle partly conceals the longus colli and rectus anticus minor. Its anterior surface is in contact with the pharynx, the internal and common carotid arteries, and the sympathetic nerve. The origin from the cervical vertebræ corresponds with that of the scalenus anticus.

Use.

Action. It flexes the head and the cervical portion of the spine.

Rectus
anticius
minor is
beneath
preceding.

The RECTUS CAPITIS ANTICUS MINOR (fig. 45, G) is a small flat muscle, which *arises* from the front of the lateral mass of the atlas at the root of the transverse process, and is *inserted* into the basilar process of the occipital bone behind the last muscle, and half an inch from its fellow.

The anterior primary branch of the suboccipital nerve emerges between the borders of this muscle and the rectus capitis lateralis.

* Deep muscles of the front of the neck and scaleni. A. Longus colli. B. Rectus capitis anticus major. C. Scalenus anticus. D. Scalenus medius. E. Scalenus posterior. F. Scalenus posticus. G. Rectus capitis anticus minor.

Action. It helps in bending forwards the head.

Use.

Dissection. The small intertransverse muscles will come into view when the other muscles have been removed from the front and back of the transverse processes. By tracing towards the spine the anterior primary branches of the cervical nerves, the intertransversales will be readily seen in front of and behind them.

Dissection of intertransversales.

After the muscles and nerves have been examined, the tips of the transverse processes may be cut off to lay bare the vertebral artery.

The INTERTRANSVERSE MUSCLES are slender fleshy slips in the intervals between the transverse processes. In the neck there are six pairs on each side—the first being between the atlas and axis. One set is attached to the anterior, and the other to the posterior tubercles of the transverse processes.

Intertransverse muscles. Number and attachments.

The anterior primary divisions of the corresponding spinal nerves issue between these muscles; and the posterior primary divisions lie to the inner side of the hinder muscles. Between the atlas and the occipital bone the rectus anticus minor and rectus lateralis represent intertransverse muscles.

Relations.

Action. By approximating the transverse processes these muscles bend the spinal column laterally.

Use.

CERVICAL NERVES AT THEIR EXIT FROM THE SPINAL CANAL. The trunks of the cervical nerves issue from the spinal canal through the intervertebral foramina, except the first two, and bifurcate into anterior and posterior primary branches.

Cervical nerves in their foramina give

The *anterior primary branch* passes outwards between the intertransverse muscles, and joins in a plexus with its fellows (p. 71).

anterior

The *posterior primary branch* turns to the back beneath the posterior intertransverse muscle and the other muscles attached to the posterior transverse processes; in its course it lies close to the bone between the articular processes of the vertebra.

and posterior branches.

Peculiarities in the first two. The first two nerves leave the spinal canal above the neural arches of the atlas and axis, and divide at the back of the neck into anterior and posterior branches.

First two nerves differ:

The *anterior primary branch of the first or suboccipital nerve* has been examined (p. 112). The *anterior branch of the second nerve*, after perforating the membrane between the neural arches of the first and second vertebræ, is directed forwards outside the vertebral artery, and between the first pair of *intertransverse* muscles, to join the cervical plexus.

anterior and

The *posterior primary branches* of the first two nerves are described in the dissection of the back.

posterior branches.

The VERTEBRAL ARTERY has been seen at its origin in the lower part of the neck (p. 69); and its termination is described with the vessels of the brain. Entering usually the foramen in the sixth cervical vertebra, the artery ascends through the corresponding foramina in the other vertebræ. Finally, the vessel winds backwards round the upper articular process, and crosses the neural arch of the atlas, piercing the posterior occipito-atlantal ligament and the dura mater, to enter the skull through the foramen magnum. In

Vertebral artery in neck. Course.

Relation to the nerves.	its course upwards the artery lies in front of the anterior trunks of the cervical nerves, except the first, which crosses on the inner side. The vessel is accompanied by a vein, and by a plexus of nerves of the same name.
A vein, and nerves are with it.	
Branches.	In the neck the artery furnishes small twigs to the surrounding muscles, the spinal canal, and the spinal cord.
Vertebral vein.	The <i>vertebral vein</i> begins on the neural arch of the atlas by the union of a considerable offset from the intraspinal venous plexuses with other branches proceeding from a network between the muscles in the suboccipital region. It is also joined by the emissary vein leaving the skull through the posterior condylar foramen when that aperture is present. Accompanying its artery in the neck, the vein descends through the foramina in the transverse processes of the cervical vertebræ, and terminates by emptying itself into the innominate trunk.
Origin.	
Course.	
Ending.	
Branches.	In this course it is joined by branches from the internal and external spinal veins; its other tributaries are noticed at p. 70.
Vertebral plexus of nerves.	The <i>vertebral plexus of nerves</i> is derived from the inferior cervical ganglion of the sympathetic (p. 115). It surrounds the artery, and communicates with the spinal nerves which it crosses.

SECTION XIX.

LIGAMENTS OF THE VERTEBRÆ AND CLAVICLE.

Directions.	<i>Directions.</i> On the remaining part of the spine, the ligaments connecting the cervical vertebræ to each other and to the occipital bone are to be learnt.
Dissection.	<i>Dissection.</i> Disarticulate the last cervical from the first dorsal vertebra. Then remove altogether the muscles, vessels, nerves, and areolar tissue and fat from the cervical vertebræ. By sawing through the occipital bone, so as to leave only an osseous ring behind the foramen magnum, the ligaments between the atlas and the occipital bone can be more easily cleaned.
Common ligaments of vertebræ	The COMMON LIGAMENTS attaching together the cervical vertebræ are similar to those uniting the vertebræ in other parts of the spine, viz., an anterior and a posterior common ligament, bands between the laminae and spines, capsular ligaments lined by synovial membrane for the articular processes, and an intervertebral disc between the bodies of the bones.
are described elsewhere.	<i>Directions.</i> The common ligaments will be best seen on the dorsal or lumbar portion of the spine, where they are more strongly developed; their preparation and description will be found at the end of the thorax, with the description of the ligaments of the spine (p. 374). Should the student examine them in the neck to see their difference in this region, he should leave uncut the neural

arches of the upper two vertebræ, to which special ligaments are attached.

SPECIAL LIGAMENTS unite the first two cervical vertebræ to each other and to the occipital bone: some of these are external to, and others within the spinal canal.

The *ligaments outside the spinal canal* are fibrous membranes, which connect the axis to the atlas, and the latter to the occipital bone in front and behind. Capsular ligaments also surround the articulations formed by these bones on each side, but they will be examined more conveniently after the spinal canal has been opened.

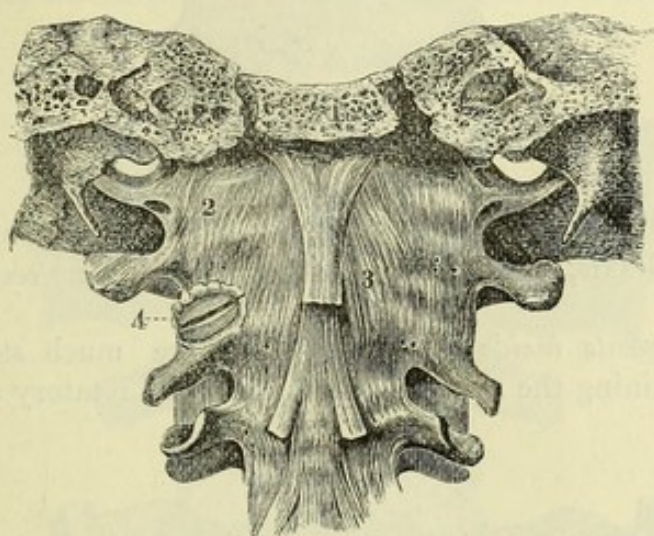
The *anterior atlanto-axial ligament* (fig. 46, ³) consists of a membranous layer attached to the anterior arch of the atlas and the body

Special
ligaments

between
first two
vertebræ
and occipi-
tal bone.

Anterior
ligament
between

Fig. 46.*



of the axis, and a superficial thickened band in the centre, prolonged from the upper end of the anterior common ligament, and connecting the ridge on the front of the axis to the tubercle on the anterior arch of the atlas.

The *anterior occipito-atlantal ligament* (fig. 46) resembles the foregoing, and passes from the basilar process of the occipital bone, immediately in front of the foramen magnum, to the anterior arch of the atlas. Its central part is also thickened, and is fixed to the tubercle on the front of the atlas.

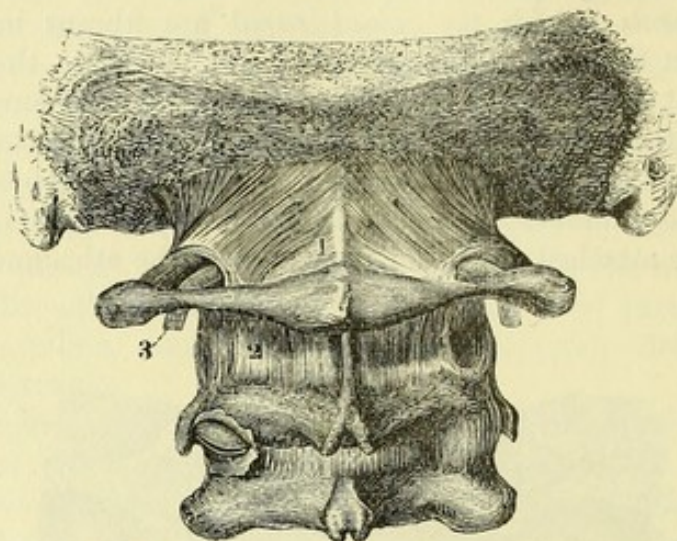
The *posterior occipito-atlantal ligament* (fig. 47, ¹) is a thin broad membrane, the deep surface of which is intimately united to the dura mater. It is attached above to the hinder margin of the foramen magnum of the occipital bone, and below to the posterior arch of the atlas. Behind the upper articular process of the atlas it forms an arch over the groove of the bone in this situation,

* External ligaments in front between the occipital bone, atlas, and axis. (Bourguery.) 1. Sawn basilar process. 2. Capsule of articulation between occipital bone and atlas, internal to which is the anterior occipito-atlantal ligament. 3. Anterior atlanto-axial. 4. Lateral articulation between the atlas and axis opened.

bounding with the latter an aperture through which the vertebral artery and the suboccipital nerve pass.

and between The *posterior atlanto-axial ligament* is also thin, and adherent to

Fig. 47.*



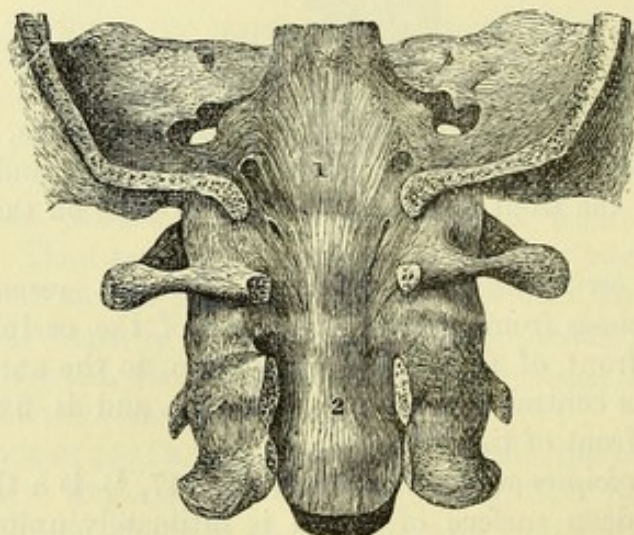
atlas and
axis.

the dura mater. It closes the interval between the neural arches of the atlas and axis, and is pierced on each side by the second cervical nerve.

Internal
ligaments

The *ligaments inside the spinal canal* are much stronger, and assist in retaining the skull in place during the rotatory and nodding

Fig. 48.†



between
same bones.

movements of the head. Between the occipital bone and the second vertebra are four ligaments—a long occipito-axial, with a central

* External ligaments behind between the occipital bone, atlas, and axis. 1. Posterior occipito-atlantal ligament. 2. Posterior atlanto-axial. 3. Vertebral artery entering beneath the occipito-atlantal ligament.

† Internal ligaments between the occipital bone, atlas, and axis, first view. (Bourguery.) 1. Long occipito-axial ligament. 2. Beginning of the posterior common ligament.

and two lateral odontoid; and the odontoid process of the axis is fixed against the body of the atlas by a transverse band.

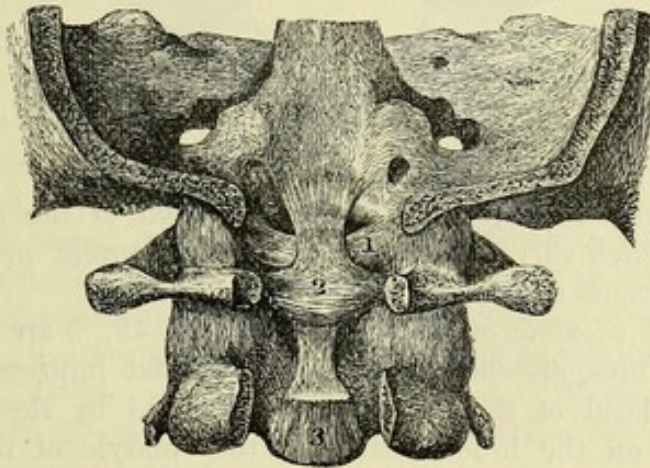
Dissection (fig. 48). Supposing the neural arches of the cervical vertebrae to be removed except in the first two, the arches of these vertebrae are to be sawn through close to the articular processes. Next, the ring of the occipital bone bounding posteriorly the foramen magnum is to be taken away. Lastly, the student should detach the tube of dura mater from the interior of the spinal canal; and, by following upwards the posterior common ligament of the bodies of the vertebrae, its continuation, the long occipito-axial ligament, will be exposed.

The *long* or *posterior occipito-axial ligament* (¹) is a strong flat band which continues upwards the posterior common ligament of the vertebrae. Its upper end is broad, and is attached to the upper surface of the basilar process of the occipital bone, reaching outwards

Dissection
of the
ligaments.

Long
occipito-
axial
ligament.

Fig. 49.*



on each side as far as the insertion of the check ligaments. Descending thence through the foramen magnum, and over the odontoid process, it becomes somewhat narrower, and is inserted mainly into the back of the body of the axis, but many of the superficial fibres are prolonged into the posterior common ligament. Occasionally a bursa is found between it and the transverse ligament.

Dissection (fig. 49). After the removal of the long occipito-axial ligament, by cutting through it transversely above, and reflecting it downwards, the student should define a strong band, the transverse ligament, which crosses the neck of the odontoid process, and sends upwards and downwards a slip to the occipital bone, and the axis. The upper offset from the transverse ligament may be cut through afterwards for the purpose of seeing the odontoid ligaments, which radiate from the process, the central one being a slender band in the middle line, and the lateral, much stronger, passing nearly horizontally outwards.

Dissection
of trans-
verse

and odontoid
ligaments.

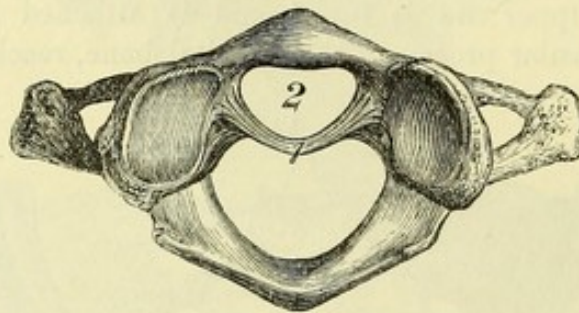
* Internal ligaments between the occipital bone, atlas, and axis, second view. (Bourguery.) 1. Check ligament. 2. Transverse ligament, sending offsets upwards and downwards. 3. Cut end of long occipito-axial ligament.

To fix
odontoid
process
is the
transverse
ligament,

also named
cruciform.

The *transverse ligament of the atlas* (fig. 50, ¹) is a strong arched band behind the odontoid process, which is attached on each side to a tubercle on the inner surface of the lateral mass of the atlas, below the fore part of the upper articular process. The ligament is rounded at each end, but flattened and wider in the middle; and at this spot it has a band of longitudinal fibres connected with its upper and lower margins (fig. 49, ²) so as to produce a cruciform figure: the upper band is inserted into the basilar process, and the lower into the body of the axis. Towards the spinal canal it is concealed by the long occipito-axial ligament.

Fig. 50.*



Socket for
odontoid
process.

This ligament forms, with the anterior arch of the atlas, a ring (fig. 50, ²) which surrounds the neck of the odontoid process of the axis, and prevents separation of the bones.

Check
ligaments.

The *lateral odontoid* or *check ligaments* (fig. 49, ¹) are two strong bundles of fibres, attached by one end to a flat impression on each side of the head of the odontoid process, and by the other to a rough mark on the inner surface of the condyle of the occipital bone. These ligaments are covered by the long occipito-axial band: their upper fibres are short and nearly horizontal; the lower are longer and oblique.

Suspensory
ligament.

The *central odontoid ligament* is a small median cord, which passes from the tip of the odontoid process to the anterior margin of the foramen magnum.

Articular
surfaces of
odontoid
process,
and two
synovial
sacs.

When the transverse and odontoid ligaments have been cut through, the odontoid process will be seen to have two cartilage-covered surfaces, which correspond to as many synovial sacs. One surface is on the front of the process, and articulates with the anterior arch of the atlas; the other is the floor of the groove behind the neck of the process, and is in contact with the transverse ligament. The posterior synovial sac is larger than the anterior.

Occipito-
atlantal
articulations
are
condyloid
joints.

Occipito-atlantal articulations. A synovial joint is formed between the condyle of the occipital bone and the upper articular process of the atlas on each side. Surrounding the articulation is a *capsular ligament* of scattered fibres, which is strongest externally and in

* Atlas with the odontoid process removed from the ring formed by the bone and the transverse ligament. 1. Transverse ligament with its offsets cut. 2. Space occupied by the odontoid process.

front. When the joint is opened, the elliptical articular surface of the condyle will be seen to be convex in all directions, and to look outwards as well as downwards. The articular cavity of the atlas has a corresponding direction, upwards and inwards, and is marked by a slight transverse groove, from which the cartilage is often wanting.

Articular surfaces.

Atlanto-axial articulations. Three synovial joints exist between the atlas and axis. The *central articulation* is between the anterior arch of the atlas and the odontoid process, and has already been exposed. The *lateral articulations* are formed on each side by the inferior articular process of the atlas and the upper articular surface of the axis. These are united by a loose *capsule* (fig. 46,⁴), which is thickened so as to give rise to an accessory ligament at the inner and posterior aspect of the joint. The articular surface of the axis is somewhat convex, and is sloped downwards and outwards; while that of the atlas presents a slight transverse ridge in the middle, so that the opposed surfaces are more extensively in contact when the atlas is turned to one side, than when it is placed symmetrically over the axis.

Between atlas and axis are a pivot-joint and two gliding joints.

Articular surfaces of latter.

Movements of the head. The head can be bent forwards—flexion, or backwards—extension; it can be inclined towards the shoulder—lateral flexion; and it can be turned to either side—rotation.

Movements of head, kinds of.

Flexion and extension take place in the joints between the atlas and occipital bone; and the range of movement is greater in the forward than in the backward direction. Flexion is limited mainly by the long occipito-axial and the check ligaments; extension by the anterior occipito-atlantal ligament, and by the approximation of the occipital bone to the neural arch of the atlas. When the head is moved more freely, flexion and extension of the cervical portion of the spine also come into play.

Nodding movement, seat, extent, and checks.

Lateral flexion is effected mainly by movement between the cervical vertebræ; but a very slight degree may be due to movement having its seat in the occipito-atlantal articulations.

Inclination to side takes place in neck.

Rotation takes place in the atlanto-axial articulations, the atlas and head moving together round the pivot formed by the odontoid process. The movement is stopped by the check ligaments. Less than half of the whole possible rotation of the head is obtained between the atlas and axis, the rest being made up in the neck.

Turning movement between atlas and axis;

and in neck.

STERNO-CLAVICULAR ARTICULATION (fig. 51). The articular surfaces of the two bones are not precisely adapted to each other, and an interarticular fibro-cartilage is placed between them. They are united by a capsular ligament; and the clavicle receives additional support from a ligament passing to the first rib-cartilage, and another band connecting it to the bone of the opposite side.

Sterno-clavicular articulation is a compound joint.

Dissection. For the examination of the ligaments of the sternoclavicular articulation, take the piece of the bones that was set aside for the purpose. If the ligaments have become dry, they may be moistened for a short time. The several ligaments will be seen in the situation indicated by their names, after the removal of some connective tissue.

Dissection.

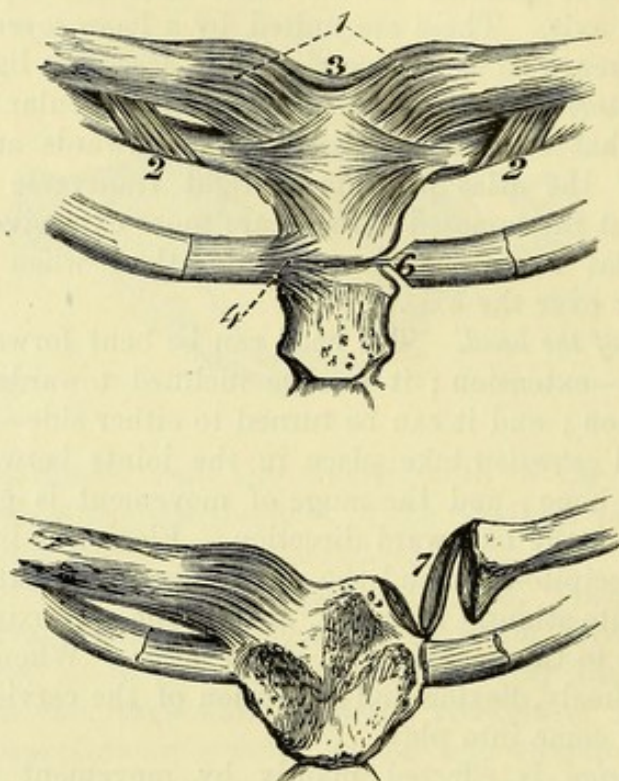
Fibrous
capsule.

The *capsular ligament* (fig. 51,¹) is a stout membrane surrounding the articular portions of the bones and the fibro-cartilage. Its fibres run obliquely from the clavicle downwards and inwards to the sternum. The stronger parts in front and behind are described as the *anterior* and *posterior sterno-clavicular ligaments*.

Inter-
clavicular,

The *interclavicular ligament* (fig. 51,³) extends above the sternum, between the ends of the clavicles. The fibres dip into the hollow between the collar-bones, and are connected with the upper edge of the sternum.

Fig. 51.*



and costo-
clavicular
ligament.

The *costo-clavicular* or *rhomboid ligament* (fig. 51,²) is a short strong band of oblique fibres, passing from the upper surface of the cartilage of the first rib to a rough mark on the under surface of the clavicle near the sternal end. In front of the ligament is the origin of the subclavius muscle. Sometimes the ligament is hollow, and contains a synovial bursa.

Fibro-
cartilage.

The *interarticular fibro-cartilage* (fig. 51,⁷) will come into view by cutting the ligaments before described, and raising the clavicle. It is ovalish in form and flattened, and is thicker at the circumference than in the centre. Its upper margin is firmly united to the inner end of the clavicle; and below, it is similarly fixed to the cartilage of the first rib. At its circumference it unites with the capsule of

Attach-
ments.

* Ligaments of the inner end of the clavicle, and of the cartilage of the second rib. 1. Capsule. 2. Costo-clavicular ligament. 3. Interclavicular ligament. 4. Anterior ligament of the second chondro-sternal articulation. 6. Interarticular ligament of the same joint. 7. Interarticular fibro-cartilage between the sternum and clavicle.

the joint. The fibro-cartilage is of considerable strength, and prevents the clavicle being displaced upwards or inwards.

Two *synovial sacs* are present in the articulation, one on each side of the fibro-cartilage. The external one is prolonged outwards for a short distance below, between the clavicle and the cartilage of the first rib. Two
synovial
sacs.

Movements. The clavicle can be moved upwards and downwards, and forwards and backwards; but the extent of movement in each direction is very limited, in consequence of the shortness of the ligaments surrounding the articulation: the forward and upward movements are freer than the opposite. In the upward and downward movements, the clavicle glides on the interarticular fibro-cartilage; and when the shoulder is depressed, the inner end of the bone is raised, while elevation of the shoulder is accompanied by a sinking of the inner end of the clavicle. In the forward and backward movements, the fibro-cartilage glides in the same direction over the sternal articular surface. Dislocation may take place in any direction, except downwards; but it is of rare occurrence owing to the strength of the ligaments. Motion in
four
directions.

CHAPTER II.

DISSECTION OF THE BRAIN.

SECTION I.

MEMBRANES AND VESSELS.

Position of the brain. DURING the examination of the membranes, vessels, and nerves, the brain is to be placed upside down, resting in the coil of a cloth which supports it evenly.

SUBDIVISIONS OF THE ENCEPHALON. Before the description of the membranes and vessels is given, the chief subdivisions of the encephalon may be shortly noticed.

Outline of cranial mass. The cranial or encephalic mass of the nervous system (fig. 59) consists of cerebrum or great brain, cerebellum or small brain, pons, and medulla oblongata. — Each of these parts has the following situation and subdivisions :—

Medulla oblongata. The medulla oblongata, or the upper end of the spinal cord (fig. 59, *a*), lies in the groove between the halves of the small brain, and is divided into two symmetrical parts by a median fissure. To it several of the cranial nerves are united.

Pons Varolii and its connections. The pons Varolii (fig. 59, *d*) is situate above the medulla oblongata, and is marked along the middle by a groove, which indicates a separation into halves. Above it are two large processes (crura cerebri, *f*) connecting it to the great brain ; and on each side it is united to the small brain by a similar white mass (crus cerebelli).

Cerebellum. The cerebellum (fig. 59, *b*), or the small brain, is separated into two hemispheres by a median groove ; and its surface is marked by concentric laminæ.

Cerebrum, and its great divisions. The cerebrum (fig. 59, *r* and *p*), or the large brain, is divided into hemispheres by a longitudinal fissure in the middle line ; and each half is farther subdivided into two by a transverse cleft—the fissure of Sylvius. The surface of the hemispheres is convoluted. In the centre of the cerebrum, between the hemispheres, and in front of the pons, are several small bodies which will be afterwards enumerated.

Weight of brain. The average weight of the brain in the European male is about 49 oz. ; in the female about 44 oz.

Three membranes. **MEMBRANES OF THE BRAIN.** The coverings of the brain (meninges) are three in number, viz., dura mater, pia mater, and arachnoid membrane. The dura mater is a firm fibrous investment, which

separates and supports different parts of the brain, and serves as an internal periosteum to the bones. The pia mater is the most internal layer, and contains the ramifications of the vessels of the brain. The arachnoid, which is interposed between the other two, is the membrane that is seen when the brain is removed from its cavity.

Besides enveloping the brain, these membranes are prolonged on the cord into the spinal canal. Only the cranial part of the last two will be now noticed. For the description of the cranial portion of the dura mater, see p. 9. Dura mater.

The ARACHNOID is a very thin fibrous membrane, which envelops the brain loosely, and is separated from the dura mater by the interval named the *subdural space*, from the pia mater by the *subarachnoid space*. Its outer surface is free and smooth, and in the natural state is in close apposition to the dura mater. The inner surface is attached to the pia mater by numerous fine cords and bands, which cross the subarachnoid space. The membrane covers the convolutions and laminæ of the large and small brain, bridging over the sulci between them, and at the base of the brain it stretches across from side to side between the cerebral hemispheres, so as to leave a considerable space beneath it. Above, it is prolonged into the median fissure between the cerebral hemispheres as far as the falx cerebri, but does not reach to the bottom of the cleft. Arachnoid membrane.
Relations to sulci.

On the nerves leaving the cavity of the cranium, the arachnoid forms tubular sheaths which enter the apertures in the dura mater, and then terminate in a free edge; but around the vessels passing to or from the brain, the membrane joins the dura mater. Sheaths on nerves and vessels.

The *subarachnoid space* is filled by a watery fluid named *cerebro-spinal*. Its size varies greatly at different parts. Over the convolutions and prominences of the brain the arachnoid approaches the pia mater closely, and the interval is very small; but opposite the sulci and depressions of the surface the space is expanded. The largest cavity is between the cerebellum and medulla oblongata, where the arachnoid is reflected from the one to the other much earlier than the pia mater. By an aperture in the latter membrane at this spot the subarachnoid space communicates with the cavity of the fourth ventricle. Another considerable interval exists between the cerebral hemispheres in front of the pons; and a third extends the whole length of the corpus callosum, in the great longitudinal fissure. Subarachnoid space varies in extent.
Three large cavities.

The PIA MATER closely invests the brain, following all inequalities of the surface, and dipping into the sulci of the cerebrum and cerebellum. It also sends a large process, named *velum interpositum*, into the interior of the cerebrum, and from this vascular processes known as *choroid plexuses* project into some of the ventricles of the brain. Two similar fringes, the *choroid plexuses of the fourth ventricle*, project into that cavity between the cerebellum and medulla oblongata. Pia mater forms velum interpositum and choroid plexuses.

The pia mater consists of a network of vessels, formed by the ramifications of the arteries and veins entering into, or issuing Structure.

from the nervous substance, the intervals between the vessels being closed by connective tissue so as to form a continuous membrane. From its deep aspect minute and very numerous vessels pass into the brain perpendicularly to the surface.

Vessels and nerves of membranes. *Vessels and nerves.* The arachnoid has no vessels, but various anatomists have described minute branches of some of the cranial nerves in the membrane. The sources of the vessels of the pia mater are given below, and its nerves, which are probably destined for the vessels, come from several cranial nerves and the sympathetic.

Dissection of arteries *Dissection.* To follow out the arteries, let the brain remain upside down, and let the arachnoid membrane be removed from them. Having displayed the trunks of the vertebral arteries on the medulla oblongata, and those of the carotid near the median fissure of the large brain, the student should lay bare on one side the branches to the large brain. Define first the two arteries (anterior cerebral) lying in the median fissure and joining by a short branch; next, an artery that passes outwards in the fissure of Sylvius (middle cerebral), and pursue it to the outer surface of the hemisphere. Look then for a much smaller vessel (choroid), which sinks into the brain on the outer side of the crus cerebri. By gently raising the cerebellum on the same side, the last artery of the cerebrum (posterior cerebral) may be traced back to the inner part of the hemisphere.

and of small brain. Two principal arteries pass to the small brain. One on the upper surface (superior cerebellar) may be brought into view with the slender fourth nerve by its side on raising the cerebellum. The other artery (inferior cerebellar) turns backwards from the vertebral to the median groove, and may be easily followed.

Arteries of the brain. **ARTERIES OF THE BRAIN** (fig. 52). The brain is supplied with blood by the vertebral and internal carotid arteries.

Vertebral The VERTEBRAL ARTERY ⁽¹²⁾ is a branch of the subclavian trunk (p. 69), and enters the skull through the foramen magnum; directed upwards and forwards round the medulla oblongata, it blends with its fellow in a common trunk (basilar) at the lower border of the pons. As the vessel winds round the medulla oblongata, it lies between the roots of the suboccipital and hypoglossal nerves; but it is afterwards internal to the latter.

Branches *Branches.* Between its entrance into the spinal canal and its termination, each artery furnishes offsets to the dura mater, to the spinal cord, and to the cerebellum.

to dura mater; *a.* The *posterior meningeal branch* leaves the vertebral trunk opposite the foramen magnum, and ramifies in the dura mater lining the cerebellar fossa of the occipital bone.

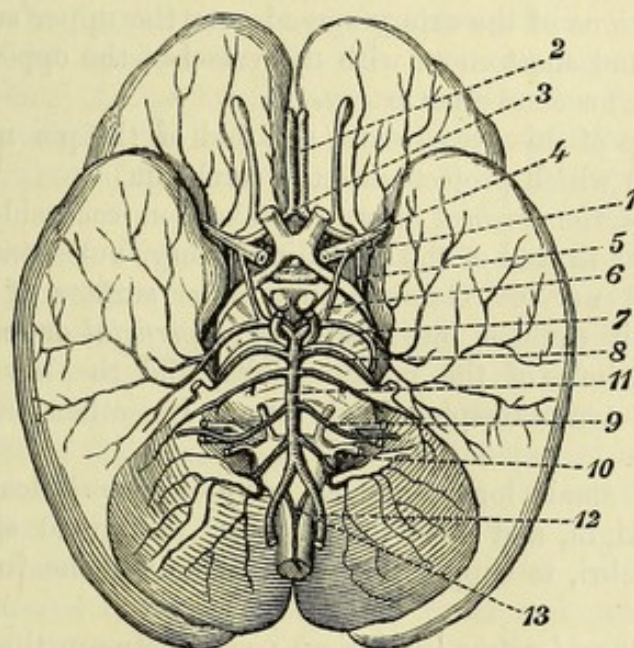
to spinal cord, *b.* The *posterior spinal branch* is of inconsiderable size, and arises opposite the back of the medulla oblongata: it descends along the side of the cord, behind the nerves, and anastomoses with its fellow, and with branches that enter by the intervertebral foramina.

posterior and anterior; *c.* The *anterior spinal branch* ⁽¹³⁾ is small like the preceding, and springs from the trunk opposite the front of the medulla. It joins the corresponding twig of the opposite side, and the resulting vessel is continued along the middle of the cord on the anterior aspect.

d. The *inferior cerebellar artery* (posterior, ¹⁰) arises from the end of the vertebral (sometimes from the basilar), and winds backwards round the medulla oblongata, between the pneumo-gastric and spinal accessory nerves, to the median groove of the cerebellum. Directed onwards in the sulcus between the hemisphere and the inferior vermiform process, the artery reaches the hinder margin of the small brain, and there anastomoses with the superior cerebellar artery.

An offset of this branch ramifies over the under part of the cerebellar hemisphere, and ends externally by anastomosing with the

Fig. 52.*



artery of the upper surface. As the vessel passes by the side of the fourth ventricle, it gives a small *choroid branch* to the plexus of that cavity.

The **BASILAR ARTERY** (¹¹), formed by the union of the two vertebrals, reaches from the lower to the upper border of the pons, where it ends by dividing into two branches (posterior cerebral) for the cerebrum. The vessel lies in the median groove of the pons, resting against the body of the sphenoid bone. On each side of, and almost parallel to it is the sixth nerve.

Branches. Besides the two terminal branches mentioned above, the artery supplies transverse offsets to the pons and the fore part of the cerebellum, and a large branch to the upper surface of the cerebellum.

a. The *transverse arteries of the pons* are four or five small twigs,

* Arteries at the base of the brain. 1. Internal carotid trunk. 2. Anterior cerebral. 3. Anterior communicating. 4. Middle cerebral. 5. Anterior choroid. 6. Posterior communicating. 7. Posterior cerebral. 8. Superior cerebellar. 9. Auditory. 10. Inferior cerebellar. 11. Basilar. 12. Vertebral. 13. Anterior spinal.

- which are named from their direction, and are distributed to the substance of the pons. One of them ⁽⁹⁾ gives an offset (*auditory*) to the internal ear along the auditory nerve.
- auditory ;
- anterior cerebellar ;
- superior cerebellar,
- giving offsets to velum ;
- and posterior cerebral artery,
- branches of which are cortical,
- central,
- choroid,
- and posterior communicating.
- Part of brain supplied by vertebral arteries.
- Internal carotid
- ends in cerebral arteries.
- Branches.
- Posterior communicating.
- b.* Resembling the branches of this set is the *anterior cerebellar artery*: this arises from the basilar trunk, and extends to the fore part of the under surface of the cerebellar hemisphere, on which it is distributed.
- c.* The *superior cerebellar artery* ⁽⁸⁾ is derived from the basilar so near the termination as to be often described as one of the final branches of that vessel. Its destination is to the upper surface of the small brain, to which it is directed backwards, winding round the crus cerebri below the third, but parallel to the fourth nerve. The ramifications of the artery spread over the upper surface of the cerebellum, and anastomose with the vessel of the opposite side, and with the inferior cerebellar artery.
- Some twigs of this vessel enter the fold of the pia mater (*velum interpositum*) which projects into the cerebrum.
- d.* The *posterior cerebral artery* ⁽⁷⁾ takes on each side a backward course, similar to that of the preceding artery, but separated from it by the third nerve. Gaining the under surface of the cerebral hemisphere, it divides into branches (*superficial* or *cortical*) which supply the whole of the occipital lobe, and the lower and inner parts of the temporo-sphenoidal lobe. Its other offsets are the following :—
- Numerous small long branches (*deep* or *central*) leave the trunk close to its origin, and enter the posterior perforated space between the crura cerebri, to supply the optic thalami in the interior of the brain.
- A small *choroid artery* (posterior) passes between the crus and the hemisphere of the cerebrum to the velum interpositum and choroid plexus.
- Near its origin it is farther joined by the posterior communicating artery of the carotid.
- From the foregoing examination of the offsets of the vertebral arteries and the basilar trunk, it appears that about half the encephalon—viz., the medulla oblongata, the pons, the cerebellum, and the posterior third of the cerebrum—receives its blood through these branches of the subclavian arteries.
- The INTERNAL CAROTID ARTERY ⁽¹⁾ terminates in branches for the remaining part of the cerebrum. The vessel emerges from the cavernous sinus (p. 19) internal to the anterior clinoid process, and divides at the inner end of the fissure of Sylvius into cerebral and communicating arteries. At the base of the brain the carotid lies between the second and third nerves, but nearer the former.
- Branches.* In the skull the carotid gives off the ophthalmic offset, before it ends in the following branches.
- a.* The *posterior communicating artery* ⁽⁶⁾ is generally a small vessel, which is directed backwards parallel to, and on the inner side of the third nerve, to join the posterior cerebral artery (of the basilar) near the pons.

b. The *anterior cerebral artery* ⁽²⁾ supplies the inner part of the cerebral hemisphere. It is directed forwards to the median fissure between the halves of the large brain; and as it is about to enter, it is united to its fellow by a short thick branch—the *anterior communicating* ⁽³⁾. Then passing into the fissure, it bends round the fore part of the corpus callosum, and is continued backwards along the upper surface of that body, sending its branches nearly to the posterior extremity of the hemisphere. It is distributed as follows:—

Anterior cerebral artery:

its communicating,

Two or three small offsets (*central branches*) arise near the beginning of the artery, and penetrate the anterior perforated space at the inner end of the fissure of Sylvius to reach the fore part of the corpus striatum in the interior of the hemisphere.

central,

The *cortical branches* supply the fore and upper parts of the internal surface of the hemisphere, extending backwards as far as the parieto-occipital fissure; and some turn round the margin to the adjacent portions of the frontal lobe on both the upper and lower aspects.

and cortical offsets.

c. The *middle cerebral artery* ⁽⁴⁾ is the largest branch of the carotid, and ramifies over the outer surface of the hemisphere. Entering the fissure of Sylvius, it divides into four or five large *cortical branches*, which issue from the outer side of that groove, and supply the whole of the parietal lobe, together with the neighbouring parts of the frontal and temporo-sphenoidal lobes.

Middle cerebral artery:

cortical

A set of small *central branches* arises from the artery at its origin, and passes through the anterior perforated space to the grey matter of the corpus striatum.

and central branches.

d. The *choroid artery* (anterior, ⁵) is small and arises either from the trunk of the carotid, or from the middle cerebral artery: it passes backwards on the outer side of the posterior communicating artery, and makes its way between the hemisphere and the crus cerebri to the choroid plexus of the lateral ventricle.

Choroid artery.

Circle of Willis. The arteries at the under part of the brain are united freely both on their own side and across the middle line in an anastomotic ring—the circle of Willis. On each side this ring is formed by the trunk of the internal carotid giving forwards the anterior cerebral, and backwards the posterior communicating artery. In front it is constructed by the converging anterior cerebrals, and the anterior communicating artery. And behind is the bifurcation of the basilar trunk into the posterior cerebrals. In the area of the circle lie several bodies corresponding with the floor of the third ventricle.

Circle of Willis;

vessels that form it.

The complete inosculation between the cranial vessels in the circle of Willis allows at all times a free circulation of blood through the brain, even though a large vessel on one side of the neck should be obstructed.

Use of the free inosculation.

Beyond the circle of Willis the arteries of the cerebrum communicate together only by fine anastomoses.

Other anastomoses are small.

The VEINS of the brain enter the sinuses of the dura mater, and do not form companion trunks to the arteries.

Veins of the brain.

Two sets to cerebrum; Two sets of veins belong to the *cerebrum*, viz., superficial or external, and deep or internal.

external, which are upper and lower; The *superficial veins* of the upper part of the hemisphere ascend to the superior longitudinal sinus (p. 10); and those of the lateral and under parts enter the sinuses in the base of the skull, especially the cavernous and lateral sinuses. These vessels communicate freely together.

and internal. The *deep veins* of the cerebrum join the veins of Galen (p. 219), and reach the straight sinus (p. 13).

Veins of cerebellum. The *veins of the cerebellum* end differently above and below. On the upper surface they are received by the veins of Galen and the straight sinus; and on the lower surface they terminate in the occipital and lateral sinuses.

Dissection. *Dissection.* The pia mater and the vessels are now to be stripped from the brain, and the origin of the cranial nerves is to be carefully defined. Over the cerebrum and pons, the pia mater can be detached with tolerable ease by using two pairs of forceps; but on the cerebellum and the medulla oblongata the membrane adheres so closely as to require much care in removing it without tearing the brain-substance, or injuring the nerves.

Care to be taken in removing pia mater. In clearing out the groove between the halves of the cerebellum on the under surface, the membrane bounding the opening into the fourth ventricle (p. 235) will be taken away: therefore the position, size, and limits of that opening between the back of the medulla oblongata and the cerebellum should be now noted.

When the surface has been cleaned, the brain is to be replaced in the spirit, but it is to be turned over occasionally, so that all the parts may be hardened.

SECTION II.

ORIGIN OF THE CRANIAL NERVES.

Definition. The cranial nerves take origin from the encephalon, with one exception (spinal accessory), and pass through apertures in the wall of the cranium.

Origin is apparent and real. The origin of a nerve is not determined by the place at which it appears on the surface, for fibres or roots may be traced deeply into the brain-substance. Each nerve has therefore a superficial or apparent, and a deep or real origin.

Real is from grey matter. With respect to the superficial attachment there cannot be any doubt; but there is much difference of opinion concerning the deep origin, in consequence of the difficulty of tracing the roots. When the roots are followed into the encephalon, they enter masses of grey substance, containing nerve-cells, which are looked upon as nuclei of origin.

Classification as nine. The cranial nerves are enumerated as forming nine or twelve

pairs. In the former classification (that of Willis) all the trunks entering one aperture in the skull are regarded as constituting one nerve; and thus the facial and auditory are included in the seventh nerve, while the glosso-pharyngeal, pneumo-gastric and spinal accessory make up the eighth nerve. According to the other arrangement (Sœmmering's) each trunk is considered a separate nerve, although it may be associated with others in the foramen of exit. The classification into twelve pairs is on the whole preferable, and is the one more generally used.

or twelve pairs.

Sœmmering's enumeration followed here.

The several nerves may be designated first, second, third, and so forth: this numerical mode of naming applies to all.

Designation from number,

But a second name has been derived for some of the nerves from the parts to which they are supplied; as instances of this nomenclature the terms pneumo-gastric and hypoglossal may be taken. And a different appellation is given to others, in consequence of the function conferred on the part to which they are distributed, as the terms auditory, oculomotor and olfactory express. In this way two names may be employed in referring to a nerve:—one being numerical, the other local or functional, as is exemplified below.

name of part,

or function.

The FIRST OR OLFATORY NERVES are about twenty fine filaments which spring from the under surface of the olfactory bulb (p. 203). They are very soft, and break off close to their origin when the brain is removed from the skull.

Olfactory nerves.

The SECOND OR OPTIC (fig. 53,²) is the largest of the cranial nerves except the fifth, and appears on the crus cerebri as a flat band, which is directed inwards to join the one of the opposite side in a commissure. The part behind the commissure is distinguished as the *optic tract*, and the name *optic nerve* is confined to the anterior portion, which is round and firm. The destination of the nerve is the eyeball.

Second nerve is optic:

part called tract.

The *optic tract* is the flattened band winding round the peduncle of the cerebrum. In front, it ends in the commissure; and behind, it divides into two pieces which will be subsequently seen to take their origin from the optic thalamus, the corpora geniculata, and the superior corpus quadrigeminum. As the tract passes forwards it is attached to the crus cerebri by its outer or anterior edge; and internal to the crus it is placed between the anterior perforated spot on the outer, and the tuber cinereum on the inner side: it is said to be joined here by additional fibres springing from the latter body.

Optic tract,

origin now concealed,

relations.

The *commissure* (chiasma) of the nerves measures nearly half an inch across, and lies on the olivary eminence of the sphenoid bone, within the circle of Willis. It is placed in front of the tuber cinereum; and passing beneath it (in this position of the brain) is the thin lamina cinerea.

Its commissure:

situation,

In the commissure each tract is resolved into three sets of fibres with the following arrangement:—The outer fibres, few in number, are continued straight to the eyeball of the same side. The middle, the most numerous, decussate with the corresponding fibres of the other tract,—those of the right tract being continued to the left

arrangement of fibres.

nerve, to the opposite eye, and *vice versa*. And the most internal are continued through the tract of the other side back to the brain without entering the eye.

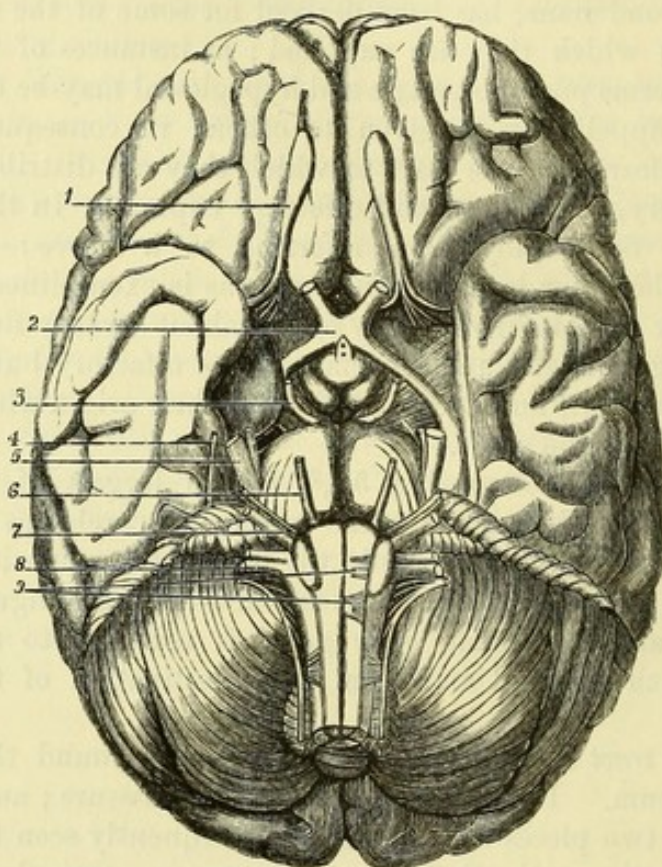
Trunk of
nerve.

The *optic nerve* extends from the commissure to the eyeball, and is about one inch and a half in length. It leaves the skull by the optic foramen, where it receives its sheaths from the dura mater and arachnoid. Its course in the orbit is described on p. 46. In the eyeball it ends in the retina.

Origin of
third nerve :

The THIRD OR OCULOMOTOR NERVE (³) is round and firm, and is

Fig. 53.*



attached by a series of filaments along an oblique line on the inner side of the cerebral peduncle, near the posterior perforated space, and close in front of the pons Varolii.

deep in crus
cerebri.

Deep origin. The fibres of the nerve pierce the peduncle, passing through the substantia nigra, and enter a nucleus of gray substance in the floor of the aqueduct of Sylvius.†

Fourth
nerve from
cerebellum :

The FOURTH OR TROCHLEAR NERVE (⁴) cannot be followed backwards at present to its origin. It is the smallest of the cranial

* Base of the brain, with origin of the cranial nerves. 1. Olfactory lobe. 2. Optic nerve. 3. Oculomotor. 4. Trochlear. 5. Trigeminal, with small and large root. 6. Abducent. 7. Facial and auditory, the former smaller and internal. 8. Glosso-pharyngeal, pneumo-gastric, and spinal accessory nerves, in order from above downwards. 9. Roots of hypoglossal nerve.

† The position of the nuclei of this and the following nerves is shown in fig. 71, on p. 235.

nerves, and is attached to the valve of Vieussens over the fourth ventricle (fig. 65,⁴). The nerve appears between the cerebrum and cerebellum, on the side of the crus cerebri, and is directed forwards to enter an aperture in the free edge of the tentorium cerebelli near the posterior clinoid process.

Deep origin. In the valve of Vieussens the nerve crosses to the opposite side, decussating with its fellow, and then arches round the aqueduct of Sylvius to reach its nucleus in the floor of that canal, immediately below the nucleus of the third nerve.

nucleus in floor of Sylvian aqueduct.

The FIFTH OR TRIGEMINAL (⁵) is the largest of the cranial nerves, and consists of two roots, ganglionic or sensory, and aganglionic or motor, which are separate to beyond the ganglion.

Fifth nerve has two roots,

The nerve is attached to the side of the pons Varolii, nearer the upper than the lower border. The small or aganglionic root is the higher, and is separated from the large root by one or two of the transverse bundles of the pons. Both roots pass outwards through an aperture in the dura mater, above the petrous part of the temporal bone, and join in the peculiar manner stated on page 18.

both issuing from pons.

Deep origin. The large root divides within the pons into two parts. One of these is connected with a mass of grey matter (sensory nucleus of the fifth) near the floor of the fourth ventricle: the other (ascending root of the fifth) arises from the cells of the posterior horn of the grey matter in the lower part of the medulla oblongata (Bechterew), and is directed upwards on the outer surface of the gelatinous substance of Rolando (p.198) to join the upper part.

Deep origin of large root in pons and medulla oblongata;

The small root also has a double origin, one part springing from a special nucleus (motor nucleus of the fifth) in the floor of the fourth ventricle internal to the sensory nucleus, and the other (descending root of the fifth) from a collection of nerve-cells on the side of the aqueduct of Sylvius.

of small in pons and mid-brain.

The SIXTH NERVE (⁶), abducent nerve of the eyeball, springs from the outer part of the pyramidal body close to the pons, and often by a second band from the lower border of the pons.

Sixth nerve from pyramid,

Deep origin. The fibres of the nerve pass backwards, through the lower part of the pons, to a nucleus in the floor of the fourth ventricle, beneath the outer part of the fasciculus teres.

and nucleus in fourth ventricle.

The SEVENTH OR FACIAL NERVE (portio dura of the seventh pair, Willis,⁷) appears at the lower border of the pons, to which it is closely adherent, in the depression between the upper ends of the olivary and restiform bodies. A small accessory bundle (portio intermedia of Wrisberg) leaves the medulla oblongata between the facial and the auditory nerves, and joins the former within the internal auditory meatus.

Seventh nerve from lateral tract of medulla oblongata; joined by intermediate portion.

Deep origin. The fibres of the facial nerve pass backwards to the floor of the fourth ventricle, and there wind round the nucleus of the sixth nerve, to join a group of nerve-cells lying on the outer side of the latter. Whether some of the fibres are connected with the cells of the nucleus of the sixth is uncertain.

Deep origin from a nucleus in dorsal part of pons.

The EIGHTH OR AUDITORY NERVE (portio mollis of the seventh

Eighth nerve from

restiform body. pair, Willis) has a surface attachment outside the foregoing to the restiform body, and to the floor of the fourth ventricle.

Deep origin by two roots from inner and outer auditory nuclei. *Deep origin.* At its attachment to the medulla oblongata the auditory nerve consists of two roots, upper and lower. The fibres of the *upper root* run backwards through the lowest part of the pons to the outer auditory nucleus beneath the lateral angle of the fourth ventricle, and some fibres are said to pass outwards to the cerebellum. The *lower root* is partly connected with the inner auditory nucleus, beneath the auditory tubercle in the floor of the fourth ventricle, by means of fibres passing backwards on the inner side of the restiform body; and another part is continued superficially round the outer side of the restiform body to the floor of the fourth ventricle, where it gives rise to the auditory striæ, but the central origin of these fibres is unknown.

Ninth nerve below facial: The NINTH OR GLOSSO-PHARYNGEAL NERVE (first trunk of the eighth pair, Willis) leaves the medulla oblongata by five or six filaments close below the facial nerve, in the groove between the olivary and restiform bodies.

nucleus in floor of fourth ventricle. *Deep origin.* Directed backwards through the medulla oblongata, the fibres join a nucleus beneath the inferior fovea in the floor of the fourth ventricle.

Tenth nerve below ninth: The TENTH, VAGUS OR PNEUMO-GASTRIC NERVE (second trunk of the eighth pair, Willis,⁸) issues by a number of filaments (twelve to fifteen) from the medulla oblongata in a line with, and below the glosso-pharyngeal.

nucleus beneath fourth ventricle. *Deep origin.* Taking a similar course in the medulla oblongata to the roots of the ninth nerve, the fibres of the vagus reach their nucleus in the calamus scriptorius of the fourth ventricle.

Eleventh nerve in two pieces; The ELEVENTH OR SPINAL ACCESSORY NERVE (third trunk of the eighth pair, Willis) consists of two parts—accessory to the vagus, and spinal.

accessory from medulla oblongata, The *accessory part* is of small size, and is formed by the union of slender filaments continuing the line of the glosso-pharyngeal and vagus nerves along the medulla oblongata, as low as the first cervical nerve. After communicating with the spinal part in the jugular foramen, it throws itself into the vagus nerve outside the skull (p. 111).

spinal from cord. The *spinal part* is firm and round, like the third or the sixth nerve, but only a small piece of it can now be seen. It arises by a number of fine filaments from the lateral column of the spinal cord as low as the sixth cervical nerve. As the nerve ascends along the side of the cord it lies between the ligamentum denticulatum and the posterior roots of the spinal nerves, with the upper of which it may be connected; and it enters the skull by the foramen magnum.

Both from one nucleus. *Deep origin.* The fibres of both accessory and spinal parts have been traced inwards to an elongated column of cells reaching from the lower third of the olivary body to the level of the fifth cervical nerve, and situate in the spinal part of its extent in the outer part of the anterior horn of the grey

matter, in the medulla oblongata behind and to the outer side of the hypoglossal nucleus (Darkschewitsch).

The ninth, tenth, and eleventh nerves converge below the crus cerebelli, and rest here on a small lobe of the cerebellum (flocculus). From that spot they are directed outwards to the jugular foramen (p. 19).

The TWELFTH OR HYPOGLOSSAL NERVE (ninth of Willis,⁹) appears on the front of the medulla oblongata, where it is attached by a series of filaments (ten to fifteen) along the groove between the pyramid and the olivary body, in a line with the anterior roots of the spinal nerves. The filaments of origin unite into two bundles, which pierce the dura mater separately, and unite at the outer part of the anterior condylar foramen.

Twelfth nerve from front of medulla oblongata :

Deep origin. The roots of the nerve can be followed through the medulla oblongata to a nucleus, which is placed in front of the central canal below, and extends upwards into the lower part of the fasciculus teres in the fourth ventricle.

nucleus near central canal and fourth ventricle.

SECTION III.

MEDULLA OBLONGATA AND PONS VAROLII.

The medulla oblongata and the pons are interposed between the spinal cord and the brain proper.

Directions. On a single brain the student may learn nearly all the anatomy of the medulla and pons ; but if he can procure one hardened specimen of the medulla oblongata and pons united, and another of a vertical median section through those bodies, he will comprehend much more readily the following description of them.

Directions.

Position. The brain is to remain in the same position as for the examination of the vessels and nerves.

Position.

The MEDULLA OBLONGATA OR BULB is the expanded upper end of the spinal cord which is contained in the cranium. Its limits are the lower border of the pons in one direction, and the lower margin of the foramen magnum in the other. It is somewhat conical in form, and measures nearly an inch in length, half an inch in breadth below, and about an inch at its widest part above.

Medulla oblongata, extent,

form and size.

Its base joins the pons, the transverse fibres of the latter marking its limit ; and its apex is blended with the spinal cord. The anterior surface (fig. 54) is irregularly convex, and is in contact with the hollowed basilar process of the occipital bone. The opposite surface (fig. 55) is somewhat excavated above, where it forms the floor of the fourth ventricle ; and it rests in the groove between the hemispheres of the cerebellum. On the posterior aspect there are not any cross fibres of the pons, as in front, to mark the extent of the medulla.

Base.

Apex.

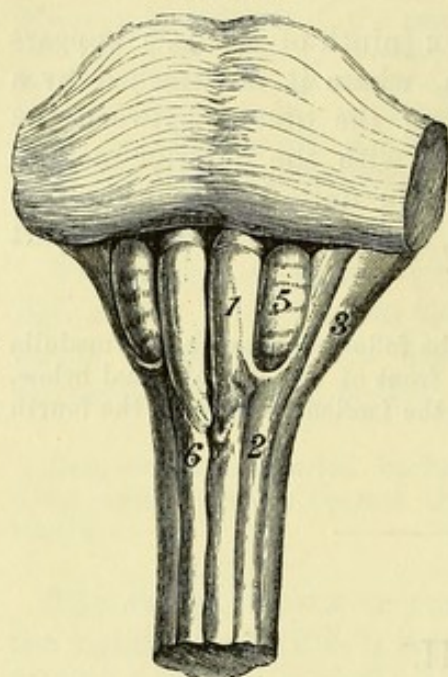
Surfaces.

Median
fissures,
anterior

The medulla oblongata is divided into halves by a median fissure in front and behind, in a line with those of the cord. The *anterior median fissure* is interrupted at the lower end of the medulla by some bundles of fibres which cross obliquely from one side to the other,

Fig. 54.*

and
posterior.



Surface constituents partly continued from cord, partly new.

and constitute the *decussation of the pyramids*; above, it ends at the lower border of the pons in a dilatation (*foramen cæcum*). The *posterior median fissure* is continued upwards from the cord through the lower half of the medulla oblongata, and then terminates by the separation of its lateral boundaries to form the sides of the fourth ventricle.

On each half of the medulla oblongata are elongated eminences, separated by slight grooves, and continuous with the columns of the spinal cord; but they receive different names in this part of their extent, and some fresh bodies are added. Thus, the part continuing the anterior column of the cord, by the side of the anterior median

fissure, is known as the *pyramid* (fig. 54,¹). The prolongation of the lateral column takes the name of *lateral tract* (²), the position of which is occupied in the upper half of the medulla by an oval eminence called the *olivary body*. Continuing the posterior column is the *funiculus cuneatus* (fig. 55, *fc*), which is separated from the lateral tract by a smaller eminence to which the name of *funiculus of Rolando* (*R*) has been given: in the upper part of the medulla these are succeeded by the *restiform body* (fig. 54,³; fig. 55, *rb*) projecting outwards towards the cerebellum. And lastly, between the funiculus cuneatus and the posterior median fissure is the *funiculus gracilis* (fig. 55, *fg*) continued from the posterior median column of the cord.

Pyramid.

The *pyramid* (anterior) is placed between the anterior median fissure on the inner side and the lateral tract with the olivary body on the outer side. It increases in size from below upwards, whence its name; but at the upper end it is somewhat constricted and rounded just before it disappears beneath the superficial transverse fibres of the pons. This body is only in part prolonged from the anterior column of the cord, its inner portion being formed by the decussating fibres seen in the anterior median fissure.

Lateral tract.

The *lateral tract* in the lower half of the medulla oblongata is of the same width as the lateral column of the cord; but above, it is

* Medulla oblongata and pons from before. 1. Pyramid. 2. Lateral tract. 3. Restiform body. 5. Olivary body. 6. Decussation of pyramids.

reduced to a narrow strip along the bottom of the groove between the olivary and restiform bodies.

The *olivary body* is oval in shape and about half an inch long. Olive. Its upper end, which is more prominent than the lower, does not quite reach the pons. Internally it is separated from the anterior pyramid by a narrow groove along which the hypoglossal nerve arises; and externally from the restiform body by a broader one, where the glossopharyngeal and vagus nerves issue.

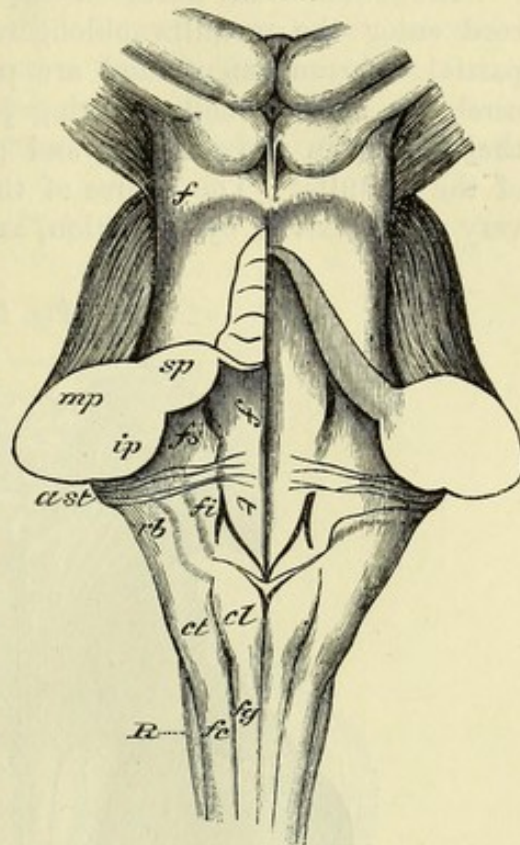
The *funiculus of Rolando* begins in a pointed extremity at the lower end of the medulla oblongata, and enlarging upwards forms, on a level with the lower end of the olivary body, a slight prominence known as the *tubercle of Rolando*. Towards the front this funiculus is separated from the lateral tract by the continuation upwards of the lateral groove of the cord; but posteriorly the line of separation from the cuneate funiculus is often indistinct. The funiculus and tubercle of Rolando are better marked in the child, and the tubercle has then a greyish colour, whence the name *tuberculum cinereum* is also given to it.

The *funiculus cuneatus* is the prolongation of the posterior column of the cord, and forms a swelling—*tuberculum cuneatum* (fig. 55, *ct*), opposite the lower extremity of the fourth ventricle.

The *restiform body* is the largest of the prominences of the medulla oblongata, and appears to be the continuation of the funiculus of Rolando and the funiculus cuneatus. It inclines outwards above, and enters the hemisphere of the cerebellum, of which it constitutes the inferior peduncle. On the back of the medulla, the inner margin of this body forms the lateral boundary of the lower part of the fourth ventricle.

The *funiculus gracilis* (posterior pyramid) lies by the side of the posterior median fissure, and is the smallest of the parts of the medulla oblongata. It ends above in an enlargement termed the *clava* (fig. 55, *cl*), which bounds the lower point of the fourth ventricle.

Fig. 55.*



Funiculus and tubercle of Rolando.

Cuneate funiculus and tubercle.

Restiform body.

Slender funiculus and clava.

* Medulla oblongata and pons from behind. *fg*. Funiculus gracilis. *cl*. Clava. *fc*. Funiculus cuneatus. *ct*. Cuneate tubercle. *R*. Funiculus of Rolando. *rb*. Restiform body. *ast*. Auditory striæ. *ft*. Fasciculus teres.

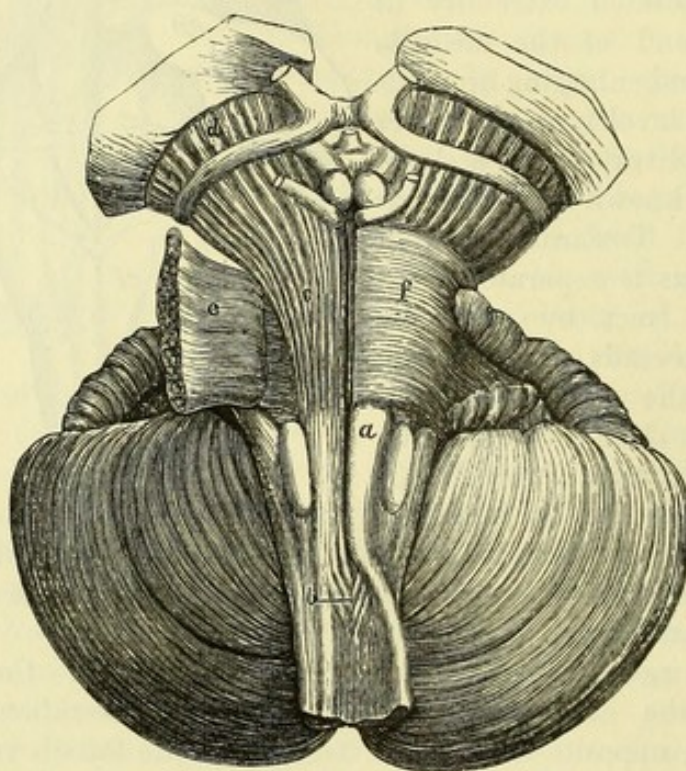
Superficial
arciform
fibres.

On the anterior surface of the medulla oblongata there may be seen, more or less distinctly in different subjects, a set of fibres crossing transversely over the upper half of the pyramid and the olivary body. These are the *superficial arciform fibres*, and they pass externally into the restiform body.

Internal
structure of
medulla
oblongata.

STRUCTURE. The fibres of the several columns of the spinal cord enter the medulla oblongata below, where they undergo a partial re-arrangement, and are partly continued onwards to the cerebrum and cerebellum, being joined by other fibres which take their origin in the medulla, and partly end in the grey substance of the medulla. The course of the fibres can only be shown to a very small extent by dissection, and for the complete study of the

Fig. 56.*



arrangement of the fibres, as well as of the grey matter, it is necessary to examine sections of different parts of the medulla oblongata.

Dissection
to trace
pyramid.

Dissection. To expose the connection of the pyramid with the spinal cord, let the student turn outwards on the left side, as in fig. 56, the small part of the anterior column of the cord that remains below the decussation (for the cord has been cut through near this), and the pyramid of the right side will then be seen to divide below into two parts, one passing directly into the anterior column, and the other crossing the median fissure and disappearing in the opposite half of the cord.

* Superficial dissection of the medulla oblongata and pons. *a.* Pyramid. *b.* Decussation of the pyramids. *c.* Pyramidal fibres in the pons. *d.* The same in the crus cerebri. *e.* Superficial fibres of the pons, cut through and reflected. *f.* Superficial fibres of the pons, in place.

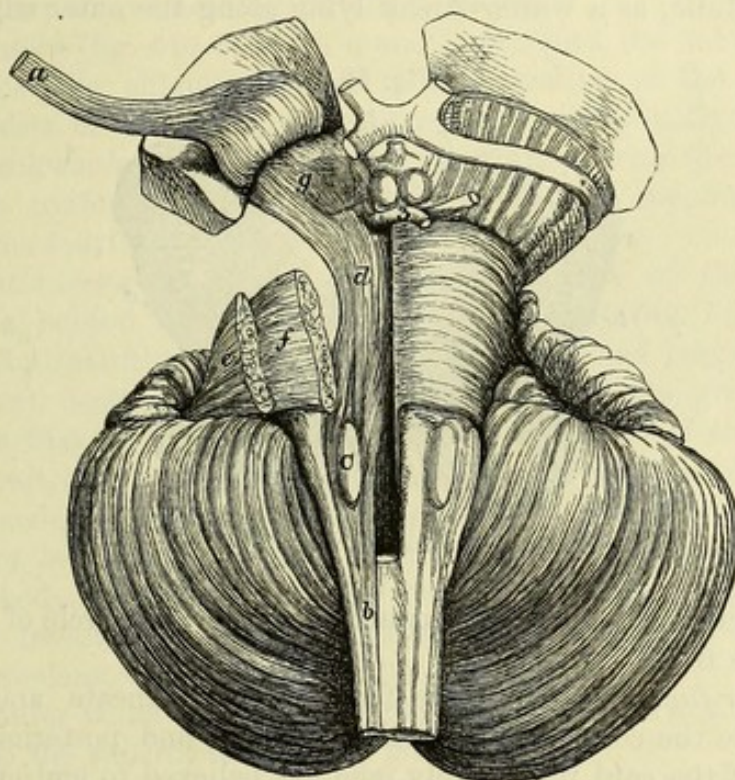
Pyramid and anterior column. The fibres of the pyramid form a well-defined and independent bundle (fig. 58, *a*) through the whole extent of the medulla oblongata, and are continued below partly into the anterior column of the same side, and partly into the lateral column of the opposite half of the cord. The set of fibres keeping to the same side forms the outer portion of the pyramid, but in the anterior column of the cord, where it is known as the *direct pyramidal tract*, it is placed close to the anterior median fissure. The decussating fibres are usually the more numerous, and pass obliquely backwards, across the median fissure and behind the opposite

Fibres of the pyramid,

direct,

and crossed.

Fig. 57.*



anterior column, to enter the lateral column, where they constitute the *crossed pyramidal tract*. Upwards, the fibres of the pyramid are prolonged through the pons to the crura of the cerebral peduncle (fig. 56, *c*, *d*). The fibres of the anterior column of the cord which are not continued into the pyramid incline backwards, and enter the reticular formation of the medulla oblongata.

Rest of anterior column.

The *decussation of the pyramids* (fig. 56, *b*) occupies the anterior fissure of the medulla oblongata at a distance of three-quarters of an inch from the pons. It is about a quarter of an inch in length, and is generally constructed by the crossing of three or four bundles of

Decussation of pyramids.

* Deep dissection of the medulla oblongata, pons, and crus cerebri. *a*. Pyramidal fibres, cut through, and raised as far as the optic thalamus. *b*. Lateral tract. *c*. Olivary body. *d*. Deep longitudinal fibres in the pons, derived from the anterior and lateral columns of the cord. *e*. Superficial, and *f*. Deep transverse fibres of the pons, cut through, and partly removed. *g*. Substantia nigra in the crus cerebri, between the crura and tegmentum.

varies in extent.

fibres from each side, but the proportion of the pyramidal fibres which decussate in the medulla varies much in different individuals.

Dissection.

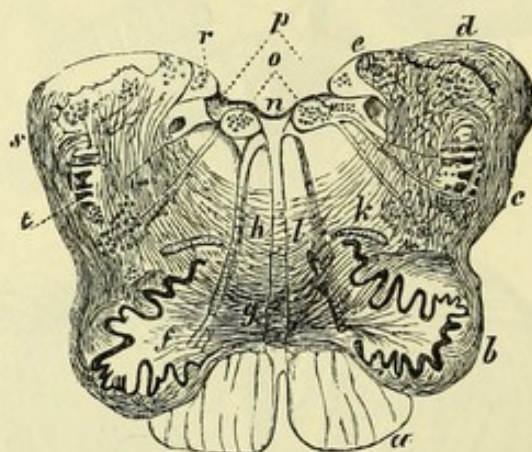
Dissection. For the purpose of seeing the deeper fibres of the medulla oblongata, the pyramid may be cut across on the right side between the decussation and the olivary body (fig. 57) and raised towards the pons.

Fibres of lateral tract.

The *lateral tract* is composed of the remaining fibres of the lateral column of the cord, after the crossed pyramidal tract has been given off. Most of these pass deeply behind the olivary body, and through the reticular formation to the pons; but one small band, the *direct cerebellar tract*, is continued superficially from the lateral column to the cerebellum. This band is often visible on the surface of the medulla, as a whiter streak lying along the outer edge of the

Direct cerebellar tract.

Fig. 58.*



lateral tract, and inclining backwards above the tubercle of Rolando to join the restiform body.

Fibres of funiculus cuneatus, gracilis, and of Rolando.

Posterior funiculi. The white fibres of the cuneate and slender funiculi are the continuation of the posterior, and posterior median columns of the cord respectively, and are believed to end entirely in the grey nuclei of the funiculi. The funiculus of Rolando has only a very thin superficial white layer, which is also derived from the posterior column.

Formation of restiform body.

The *restiform body* is formed mainly by the arciform fibres of the medulla, with the direct cerebellar tract from the lateral column of the cord.

Arciform fibres,

Arciform fibres. In the upper half of the medulla oblongata, covering its anterior surface and traversing its substance, is an extensive system of fibres, curving outwards and backwards from

* Transverse section of the medulla oblongata at the lower part of the fourth ventricle (Clarke). *a.* Pyramid. *b.* Olivary body. *c.* Tubercle of Rolando. *d.* Restiform body. *e.* Lateral boundary of fourth ventricle. *f.* White core of the olivary body, with the roots of the hypoglossal nerve to its inner side. *g.* Olivary peduncle. *h.* Deep arciform fibres entering the raphe (a few more are added from a second drawing). *k.l.* Reticular formation. *n.* Floor of fourth ventricle. *o.* Hypoglossal nucleus. *p.* Glossopharyngeal nucleus. *r.* Inner auditory nucleus. *s.* Superficial arciform fibres. *t.* Remains of the gelatinous substance.

the median plane to the restiform body, to which this name has been given. The *superficial arciform fibres* (fig. 58, *s*) have already been noticed in the description of the exterior of the medulla oblongata (p. 194). The *deep arciform fibres* (*h*) are more numerous, and are seen over the whole area of transverse sections except in the pyramid. Some of them come to the surface on the inner side of, and through the olivary body, and join the superficial set. Others are deep in their whole extent, and pass outwards into the restiform body, and to the nuclei of the cuneate and slender funiculi. Internally, the arciform fibres enter the raphé, through which they are continued to the opposite half of the medulla. There they are thought to become longitudinal, but of their farther course nothing certain is known.

The *raphé* (fig. 58, between *h* and *l*) occupies the median plane of the medulla oblongata above the decussation of the pyramids, and consists of fibres running obliquely, longitudinally, and from before backwards, which are in part continuous with the superficial and deep arciform fibres, and in part spring from the nuclei in the floor of the fourth ventricle.

Formatio reticularis. In the dorsal portion of the medulla oblongata, behind the pyramid and olivary body (fig. 58, *l* and *k*), the longitudinal fibres derived from the anterior and lateral columns of the cord, decussating with the deep arciform fibres, give rise to a structure that is known as the *reticular formation of the medulla*. In the part of the reticular formation behind the olivary body (*k*) interspersed grey matter containing nerve-cells is also present.

Olivary body (fig. 58, *f*). On removing a thin slice from the olivary body, it will be seen to consist of three parts, viz., an external investment of white substance, a thin grey layer—the olivary nucleus, and a central white core.

The outer white layer consists mainly of transverse fibres, which belong to the superficial arciform group.

The *olivary nucleus* or *corpus dentatum* is a thin plaited capsule, or bag, having a zigzag outline in section. Towards the surface and behind it is closed, but on the inner side it is open, forming a narrow neck, which is turned towards the raphé, and gives passage to the olivary peduncle.

The central white matter fills the grey capsule, and is formed by the spreading out of a tract of white fibres called the *olivary peduncle*, which passes inwards through the opening in the nucleus to the raphé. The fibres of the peduncle partly terminate in the cells of the corpus dentatum, and are partly continued through the grey layer to join the arciform fibres.

Grey matter of the medulla oblongata. The larger part of the grey matter in the medulla is a continuation of that of the cord, but there are in addition some smaller independent masses.

Prolongation of grey matter of the spinal cord. At the lower end of the medulla oblongata the central grey matter resembles that in the spinal cord (fig. 129), but as it extends upwards it undergoes the following changes :—

- Changes in anterior horn, The anterior cornu is broken up by the passage through it of the fibres of the crossed pyramidal tract, and the detached extremity of the horn is continued upwards in the lateral tract for some distance as the *lateral nucleus*.
- in posterior horn, The posterior cornu is pushed outwards by the increasing development of the slender and cuneate funiculi, and its extremity (caput), consisting of the substantia gelatinosa of Rolando, becomes greatly enlarged and approaches the surface, giving rise to the funiculus and tubercle of Rolando (fig. 58, c). From the base of the horn, processes of the grey matter extend backwards into the slender and cuneate funiculi, and are known as the nuclei of those bodies. They are largest in the neighbourhood of the lower end of the fourth ventricle, where they cause the swellings which have been described above as the clava and cuneate tubercle (p. 193).
- and in commissure. By the opening out of the posterior median fissure and central canal of the cord to form the fourth ventricle, the anterior portion of the grey commissure and the bases of the anterior horns are exposed, constituting the grey layer in the floor of that cavity.
- Special grey masses. *Special deposits of grey matter.* These are the olivary nucleus, which has just been examined, some groups of nerve-cells at the back of the medulla oblongata forming nuclei of origin for several cranial nerves, which will be noticed in connection with the anatomy of the fourth ventricle, and a few small masses of grey substance on the front of the medulla beneath the superficial arciform fibres (nuclei arciformes).

PONS VAROLII.

- Pons : The PONS VAROLII (annular protuberance, fig. 54) is situate above the medulla oblongata, and between the hemispheres of the cerebellum. In its natural position in the skull it lies below the opening in the tentorium cerebelli, resting against the hinder part of the body of the sphenoid bone. It is nearly of a square shape, though it is rather wider from side to side, in which direction it measures about an inch and a half.
- position,
- form,
- surfaces, The anterior surface is convex and prominent on each side, but marked along the middle line by a groove in which the basilar artery lies. By the opposite surface the pons forms part of the floor of the fourth ventricle.
- borders, The upper border is the longer, and arches over the crura cerebri. The lower border is nearly straight, and projects above the medulla oblongata. On each side the pons is continued into the middle peduncle of the cerebellum, and the fifth nerve issues at the junction of the two.
- and sides.
- It consists of ventral STRUCTURE. The ventral or anterior half of the pons consists of transverse fibres which are in part of their extent divided into two layers by the prolongation upwards of the fibres of the pyramids of the medulla oblongata. The dorsal or posterior half is a continuation of the reticular formation, with the grey layer of the floor of the fourth ventricle, from the medulla.
- and dorsal portions.
- Dissection *Dissection.* The superficial transverse fibres of the pons being

divided along the line of the pyramid of the right side (fig. 56) may be turned outwards so as to denude the longitudinal fibres (c) of that body; and this set of longitudinal fibres, having been cut across already in the medulla oblongata, may be raised as far as the upper border of the pons. Beneath them will appear the second or deep set of transverse fibres of the pons (fig. 57, f).

The deep transverse fibres may next be cut through outside the pyramidal tract (fig. 57), and the reticular formation will then be seen, in which deep longitudinal fibres ascend from the medulla (fig. 57, d).

The *transverse fibres* of the ventral portion of the pons are derived from the crus or middle peduncle of the cerebellum. They are mostly collected into two layers, superficial and deep (fig. 57), which enclose the longitudinal fibres of the pyramid; but some transverse fibres pass between the bundles of the pyramidal tract. The superficial fibres are nearly horizontal in the lower part of the pons, but the upper ones descend to join the cerebellar peduncle, and some are seen on the surface crossing obliquely over the lower fibres.

The *pyramidal fibres* enter the pons below as a single mass, but in their passage upwards through the pons they are broken up by decussating bundles of transverse fibres. Much increased in number, they emerge at the upper border of the pons, and are continued into the superficial portion (crusta) of the crus cerebri.

Scattered amongst the transverse fibres are numerous small masses of grey matter (nuclei pontis); and fibres entering the pons by one cerebellar peduncle are believed to cross to the other side, and there join nerve-cells in these nuclei, from which other fibres take origin, and ascend with the fibres of the pyramid to the crus cerebri.

The *reticular formation* of the pons is formed of longitudinal fibres continued from the medulla oblongata (p. 197), and passing upwards to the deep portion (tegmentum) of the crus cerebri (fig. 57, d), decussating with transverse fibres which are also derived from the peduncle of the cerebellum. It contains much interspersed grey matter; and near the floor of the fourth ventricle there are several nerve-nuclei, which will be referred to when that cavity is described.

In the dorsal portion of the pons, as in the medulla oblongata, there is a median *raphé*, formed mainly by the transverse fibres changing their direction as they cross the middle line.

There is farther in the lower part of the pons, close behind the deep transverse fibres of the ventral portion, and occupying a position immediately above the olivary body, a small collection of grey matter to which the name of *superior olivary nucleus* is given.

SECTION IV.

DISSECTION OF THE CEREBRUM.

Situation
of the
cerebrum.

The CEREBRUM, or great brain, the largest of the subdivisions of the encephalon, fills the upper part of the cranial cavity, and occupies the anterior and middle fossæ of the base of the skull. Its hinder part rests on the tentorium, which separates it from the cerebellum. Its lower limit would be indicated on the surface of the head by a line from the eyebrow to the articulation of the jaw, and from this point to the external occipital protuberance.

Form.

Taking the general form of the cranial cavity, the cerebrum is convex on the upper aspect, and uneven on the lower. It consists of two hemispheres, which are placed side by side, and separated in the greater part of their extent by a median longitudinal fissure. In their lower half the hemispheres are united by some commissures, as well as by several connecting parts at the under surface. The under part of each hemisphere is divided into two by a deep transverse cleft—the *fissure of Sylvius*.

Two hemi-
spheres,

united by
median
parts.

Under
surface of
cerebrum.

UNDER SURFACE OR BASE OF THE CEREBRUM (fig. 59). The under surface of the cerebrum is irregular, in consequence of its fitting into inequalities in the base of the skull; and on this aspect the separation into hemispheres is not so complete as on the upper, for the median fissure exists only at the front and back. The following objects are to be recognised at the centre of the base of the brain:—

Enumera-
tion of
central
parts.

Immediately in front of the pons (*d*) are two large white masses, the *peduncles of the cerebrum* or *crura cerebri* (*f*), one belonging to each hemisphere; and between them is a small area perforated by vessels, which is named the *posterior perforated space* (*g*). Crossing the peduncle is the *optic tract*; and between it and the inner part of the hemisphere is a fissure leading into the lateral ventricle.

In front of the posterior perforated space are seen two rounded white bodies—the *corpora albicantia* (*e*); and then a prominent greyish mass, called *tuber cinereum* (*h*). From the tuber cinereum a conical process, the *infundibulum*, descends to the pituitary body in the sella Turcica of the sphenoid bone.

Anterior to the tuber cinereum are the converging optic tracts with their *commissure* (*i*). In front of the commissure lies a thin greyish layer—the *lamina cinerea* (*m*); and still farther forwards is the great longitudinal fissure between the hemispheres, with the white *corpus callosum* (*n*) in the bottom of it.

At the inner end of the Sylvian fissure is a depression termed the *vallecula Sylvii* (*l*), at the bottom of which is seen another spot perforated by vessels—the *anterior perforated space*.

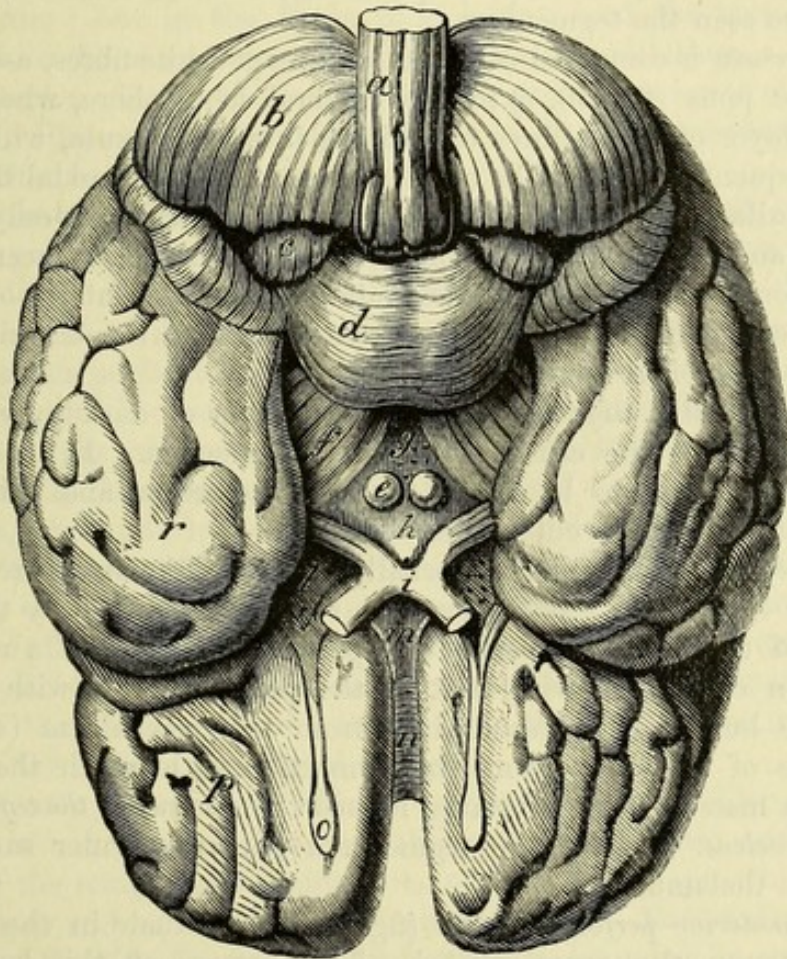
Olfactory
lobe.

Lastly, in front of the anterior perforated space, and resting on

the surface of the frontal lobe of the cerebral hemisphere, is the elongated process of the brain (*o*) named *olfactory lobe*, from which the olfactory nerve-filaments spring. This process is frequently called the olfactory nerve, but its true nature as a lobe of the cerebrum is shown by its position and structure, as well as by its condition in the lower animals, in which it is generally of large size.

PEDUNCLE OF THE CEREBRUM OR CRUS CEREBRI (*f*). This is a *Crus cerebri*, large, white, stalk-like body, which reaches from the upper border of

Fig. 59.*



the pons to the under part of the cerebral hemisphere of the same side, near the inner margin. In the natural position the two peduncles occupy the opening in the tentorium cerebelli. Each is about three-quarters of an inch long, and widens as it approaches the cerebrum. Crossing its anterior surface is the optic tract; and between the crura of opposite sides is the *interpeduncular space*,

* Under surface of the brain. *a*. Medulla oblongata. *b*. Hemisphere of cerebellum. *c*. Flocculus. *d*. Pons. *e*. Corpus albicans. *f*. Crus cerebri. *g*. Posterior perforated space. *h*. Tuber cinereum. *i*. Optic commissure. *l*. Vallecula Sylvii and anterior perforated space. *m*. Lamina cinerea. *n*. Rostrum of corpus callosum : on each side of *m*, is a narrow white band—the peduncle of the corpus callosum. *o*. Olfactory bulb. *p*. Frontal lobe of the cerebral hemisphere. *r*. Temporo-sphenoidal lobe, separated from the foregoing by the fissure of Sylvius.

which contains the posterior perforated space, the corpora albicantia, and the tuber cinereum with the infundibulum.

Composed of three parts. *Structure.* The peduncle consists of a superficial layer of white fibres, the *crusta*, continued from the longitudinal fibres of the pons, a prolongation of the reticular formation termed the *tegmentum*, and an intermediate stratum of grey matter—the *substantia nigra*.

Dissection. *Dissection.* For the purpose of showing the structure of the crus on the right side (fig. 57), the optic tract should be divided, and the fibres continuous with the pyramid of the medulla oblongata should be raised as far as the junction of the crus with the hemisphere. In this proceeding the substantia nigra (*g*) will appear; and beneath it will be seen the tegmentum.

Crusta. The *crusta* is composed of coarse bundles of white fibres, ascending from the pons (fig. 56, *c*) to the cerebral hemisphere, where they enter a layer of white fibres termed the internal capsule, which will be subsequently seen. The continuation of the pyramidal fibres of the medulla (pyramidal tract) occupies the central part only of the crusta; and the lateral parts consist of fibres which have been added in the pons. Those on the inner side pass to the frontal lobe of the hemisphere, while the outer ones are destined for the occipital and temporo-sphenoidal lobes.

Substantia nigra. The *substantia nigra* (fig. 57, *g*) is a layer of dark grey matter which separates the crusta from the tegmentum. In transverse sections it is seen to be convex towards the crusta, and thicker at the inner than at the outer side.

Tegmentum. The *tegmentum* is united internally with the like structure of the opposite side below; but above, the two are separated by the grey matter of the posterior perforated space. It consists of a reticular formation continuous with that of the pons, together with a considerable bundle of fibres derived from the cerebellum (superior peduncle of the cerebellum), in connection with which there is a roundish mass of grey substance named the *nucleus of the tegmentum* or *red nucleus*. Above, the tegmentum joins the under surface of the optic thalamus.

Posterior perforated spot. The *posterior perforated space* (fig. 59, *g*) is situate in the depression between the crura cerebri. The bottom of this hollow is formed by a layer of grey matter, which is perforated by the central branches of the posterior cerebral arteries. This structure forms the hinder part of the floor of the third ventricle.

Corpora albicantia. The *corpora albicantia* (corp. mamillaria; *e*) are two round white bodies, about the size of small peas, which are constructed in greater part by the crura of the fornix. If one, say the right, is cut across, it will be seen to contain grey matter.

Tuber cinereum. The *tuber cinereum* (*h*) is a portion of the thin grey layer forming the floor of the third ventricle, which is continuous behind with the grey matter of the posterior perforated space, and in front, above the optic commissure, with the lamina cinerea. It is convex on the surface, and is prolonged at its fore part into the following body.

and infundibulum. The *infundibulum* is a funnel-shaped tube which reaches from the tuber cinereum to the posterior lobe of the pituitary body. It

consists of a layer of grey matter; and its cavity is a part of the third ventricle. In the fœtus this tube is open between the third ventricle and the pituitary body, but in the adult it is closed below.

The *pituitary body* will be very imperfectly seen when it has been dislodged from its resting place: it should therefore be examined when opportunity offers in the base of the skull by removing the surrounding bone. Its use is unknown. Pituitary body.

It is situate in the hollow of the sella Turcica on the sphenoid bone, and consists of two lobes, anterior and posterior. The anterior is the larger, and is hollowed out behind, where it receives the round posterior lobe. In the adult this body is solid and firm in texture; but in the fœtus it is hollow, and the posterior lobe opens into the third ventricle through the infundibulum. Situation.

Dissection. To see the lamina cinerea and the anterior end of the corpus callosum, the hemispheres are to be gently separated from each other in front. Dissection.

The *lamina cinerea* (*m*) is a thin concave layer of grey substance, which gradually tapers upwards from the tuber cinereum to the termination of the corpus callosum. This stratum closes the anterior part of the third ventricle, and is continuous laterally with the anterior perforated space. In consequence of its great thinness, this structure is often broken through in removing the brain. Grey lamina.

The *corpus callosum* (*n*), bent downwards in front, is continued horizontally backwards in the longitudinal fissure to the lamina cinerea, and ends by two white narrow bands—the *peduncles of the corpus callosum*, which are continued along the edge of the lamina cinerea on each side to the anterior perforated spot. The anterior bend of the corpus callosum is known as the *genu*, and to the prolonged central part the name *rostrum* is given. Laterally this part of the corpus callosum reaches into the frontal lobe, and forms part of the floor of the lateral ventricle. Corpus callosum
ends below in two bands, and extends into hemisphere.

Vallecula Sylvii and anterior perforated space. The vallecula Sylvii is a depression between the optic commissure and the fore part of the temporo-sphenoidal lobe of the hemisphere, which lodges the upper end of the internal carotid artery. Externally it leads into the Sylvian fissure, and in front it is bounded by the diverging roots of the olfactory tract. The floor of the fossa is formed by a layer of grey matter which is perforated by the central branches of the anterior and middle cerebral arteries, thus giving rise to the anterior perforated space. The grey substance is continuous above with the lenticular nucleus of the corpus striatum. Vallecula Sylvii.
Anterior perforated space.

The *Olfactory lobe* consists of an elongated nerve-like part which is named the *olfactory tract*, and a terminal expansion in front—the *olfactory bulb*. It lies in a groove (olfactory sulcus; fig. 61, ol) on the surface of the inner orbital convolution of the frontal lobe of the hemisphere. Olfactory lobe
lies in olfactory sulcus.

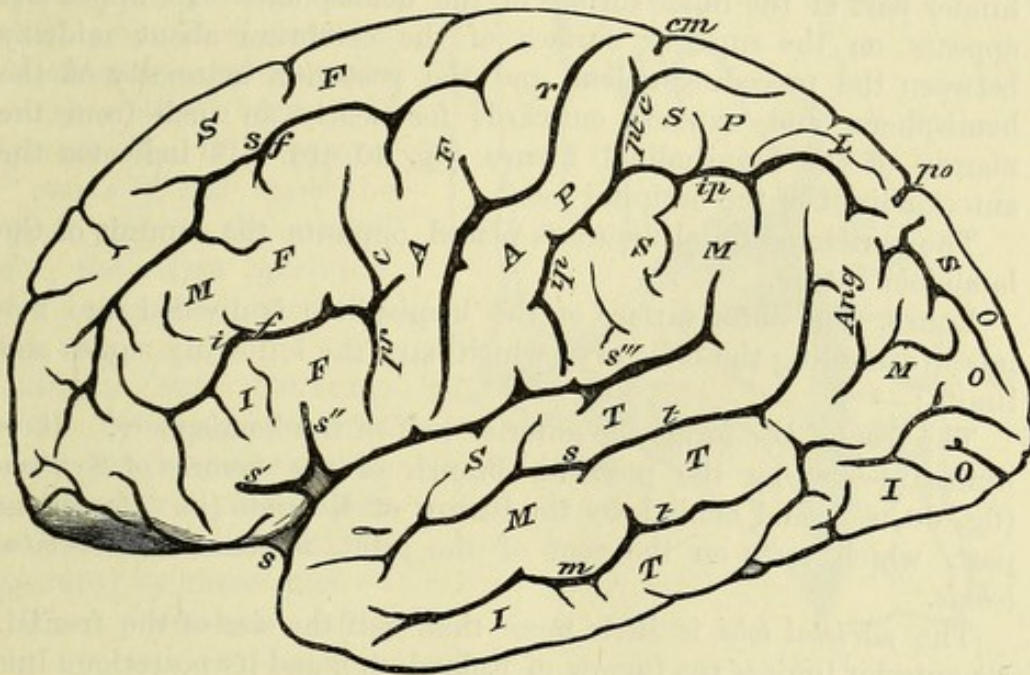
The *olfactory bulb* (fig. 59, o) is an oval mass, of a greyish colour, and nearly half an inch in length, which rests on the cribriform plate of the ethmoid bone. From its under surface the olfactory nerves arise. Olfactory bulb.

Olfactory tract :	The <i>olfactory tract</i> is a prismatic band, about an inch long, the upper edge of which is received into the olfactory sulcus. It is attached by its base, where it is somewhat expanded, to the frontal lobe close in front of the anterior perforated space ; and from this part two diverging white streaks, the <i>roots of the olfactory tract</i> or
roots, outer	<i>olfactory striæ</i> , proceed to neighbouring convolutions. The external root passes along the outer margin of the anterior perforated space, and across the beginning of the Sylvian fissure, to the anterior extremity of the uncinate convolution in the temporo-sphenoidal lobe. The internal root, not always visible, bends inwards, and joins the lower end of the callosal convolution. By raising the
and inner.	olfactory lobe from its sulcus, the dorsal ridge will be seen to become enlarged at its posterior end, forming the <i>olfactory tubercle</i> .
Olfactory tubercle.	
Position of brain to examine upper part.	<i>Position of the part.</i> Now that the base of the cerebrum has been studied, the brain should be turned over for the examination of the upper part. Something should then be placed beneath the fore part, in order that it may be raised to the same level as the back ; and a rolled-up cloth should loosely encircle the whole, to support the hemispheres.
Cerebrum is convex above, and	UPPER SURFACE OF THE CEREBRUM. Viewed from above, the cerebrum is ovoidal in form, and the upper surface is convex in accordance with the shape of the skull.
divided into two by a median fissure.	A <i>median longitudinal fissure</i> divides the cerebrum incompletely into halves. At the front and back the hemispheres are quite separated by it ; but at the middle and under parts they are united by connecting bodies, the largest of which is the white corpus callosum. In the fissure the falx cerebri is lodged.
Hemisphere	Each hemisphere is larger in front than behind, although the greatest breadth of the cerebrum is placed behind the middle. Its outer surface is convex and applied to the skull ; the inner is flat and rests against the falx cerebri. The surface of the hemisphere consists of grey matter (cortex of the cerebrum), and is marked by tortuous eminences separated by grooves. The eminences are named
grey on surface, marked by convolutions and furrows.	<i>convolutions</i> or <i>gyri</i> ; the grooves are <i>furrows</i> or <i>sulci</i> .
Furrows are incomplete	The sulci of the cerebrum are of two kinds. The greater number are superficial depressions which carry inwards the grey cortex and only indent the central white substance ; but a few penetrate more deeply, and these are the result of folds involving the whole thick-
and complete.	ness of both grey and white substance, so as to affect the form of the cavity (lateral ventricle) contained within the hemisphere, or give rise to eminences projecting on its wall. The sulci of the latter group are distinguished as <i>fissures</i> .
Convolutions vary, but	The convolutions and sulci, especially the smaller ones, vary in different brains, and they are not exactly alike even in the two hemispheres of the same cerebrum. Their general arrangement or
plan is uniform.	plan is, however, constant, and there will seldom be much difficulty in recognizing the several parts referred to in the following description.
Division of the hemisphere.	INTERLOBAR SULCI AND LOBES OF THE HEMISPHERE. The outer surface of the hemisphere is divided into regions, or groups of con-

volutions, known as the lobes of the cerebrum, by means of some of the most constant sulci, aided by lines prolonged from these. The interlobar sulci are three in number, viz :—

The *fissure of Sylvius* (fig. 60, *s*) begins at the vallecule Sylvii, ^{Sylvian fissure} whence it extends transversely outwards across the under surface of the hemisphere, separating the frontal and temporo-sphenoidal lobes (fig. 59). As soon as it reaches the outer surface, it gives off one ^{has three branches.} small branch forwards (*anterior*; fig. 60, *s'*), and another upwards (*ascending*; *s''*), with project into the inferior frontal convolution,

Fig. 60.*



and is then continued backwards as the *posterior branch* (*s'''*) through about the middle third of the hemisphere. The posterior branch separates the temporo-sphenoidal from the frontal and parietal lobes; it ascends somewhat as it runs backwards; and at its termination it is bent upwards for a short distance and projects into the parietal lobe.

When the brain is in the skull, the place of division of the fissure of Sylvius is opposite the articulation of the great wing of the sphenoid with the parietal bone. ^{Position in relation to bones of head.}

* Sulci and convolutions of the outer surface of the hemisphere. *Sulci*: *s*. Fissure of Sylvius; *s'*. Its anterior, *s''*. Its ascending, and *s'''*. Its posterior branch. *r*. Furrow of Rolando. *po*. Parieto-occipital fissure. *sf*. Superior, and *if*. Inferior frontal sulcus. *pr. c.* Præcentral sulcus. *ip*. Intraparietal. *pt. c.* Postcentral. *cm*. End of callosal-marginal sulcus. *st*. Superior temporo-sphenoidal or parallel, and *m.t.* Middle temporo-sphenoidal sulcus.

Convolutions: *sf*. Superior, *mf*. Middle, and *if*. Inferior frontal. *af*. Ascending frontal. *ap*. Ascending parietal. *spl*. Superior parietal lobule. *sm*. Supramarginal convolution. *ang*. Angular. *so*. Superior, *mo*. Middle, and *io*. Inferior occipital. *st*. Superior, *mt*. Middle, and *it*. Inferior temporo-sphenoidal.

Sulcus of Rolando	The <i>furrow of Rolando</i> (central sulcus ; fig. 60, <i>r</i>) crosses the outer surface of the hemisphere near the middle. Beginning above close to the margin of the great longitudinal fissure, the furrow runs downwards and somewhat forwards, with a serpentine course, to end about one inch behind the place of division of the Sylvian fissure, and very near to its posterior limb. This sulcus is used to separate the frontal from the parietal lobe.
is behind coronal suture.	The upper end of the furrow of Rolando is placed from an inch-and-a-half to two inches, the lower end about one inch behind the coronal suture.
Parieto-occipital fissure ;	The <i>parieto-occipital fissure</i> (fig. 61, <i>po</i>) is a deep sulcus at the hinder part of the inner surface of the hemisphere. Its upper end appears on the superior surface of the cerebrum about midway between the preceding sulcus and the posterior extremity of the hemisphere, and extends outwards for nearly an inch from the margin of the longitudinal fissure (fig. 60, <i>po</i>). It indicates the anterior limit of the occipital lobe.
situation.	The parieto-occipital fissure is placed opposite the summit of the lambdoid suture.
Lobes of hemisphere.	LOBES. The outer surface of the hemisphere is divided into five lobes (excluding the olfactory) which have the following names and limits :—
Frontal lobe is largest :	The <i>frontal lobe</i> forms the anterior half of the hemisphere. It is limited below by the posterior branch of the fissure of Sylvius (fig. 60, <i>s''</i>), and behind by the furrow of Rolando (<i>r</i>). Its under part, which rests on the roof of the orbit, is named the <i>orbital lobule</i> .
orbital lobule.	
Parietal lobe :	The <i>parietal lobe</i> is little more than half the size of the frontal. Its anterior limit is the furrow of Rolando (<i>r</i>), and its posterior a line drawn transversely over the hemisphere from the parieto-occipital fissure. Below, it is bounded in its fore part by the posterior branch of the fissure of Sylvius (<i>s''</i>), and in its hinder part by a line extending from the spot where this sulcus turns upwards to the posterior extremity of the hemisphere. Its convolutions are continuous with those of the occipital lobe behind, and of the temporo-sphenoidal lobe below.
boundaries are in great part artificial.	
Occipital lobe.	The <i>occipital lobe</i> is small, and triangular in shape. It is separated from the parietal lobe for a short distance above by the parieto-occipital fissure (<i>po</i>) ; but its anterior boundary is for the most part artificial, being constituted by a line continuing the direction of that fissure across the outer surface of the hemisphere. Its convolutions join those of the parietal and temporo-sphenoidal lobes.
Temporo-sphenoidal lobe.	The <i>temporo-sphenoidal lobe</i> projects into the middle fossa of the base of the skull. Its fore part is separated from the frontal and parietal lobes by the fissure of Sylvius, but its hinder part is only limited by the lines above mentioned, across which its convolutions pass into those of the parietal and occipital lobes.
Central lobe, or island of Reil,	The <i>central lobe</i> , insula, or island of Reil (fig. 61, <i>c</i>), is placed at the bottom of the fissure of Sylvius, and is concealed by the overlapping of the temporo-sphenoidal, parietal and frontal lobes. If the

margins of the Sylvian fissure be drawn asunder, it will be seen to have a triangular form, with the apex directed downwards towards the anterior perforated space, and to be bounded by three furrows, the *sulci of Reil* (ar, er, and pr), the hinder of which is continuous with the posterior branch of the fissure of Sylvius. The central lobe is placed opposite the corpus striatum in the interior of the hemisphere.

To the portions of the frontal and parietal lobes which are placed between the ascending and posterior branches of the fissure of Sylvius (fig. 60, between *s''* and *s'''*), and cover the upper part of the central lobe, the name *operculum of the insula* is given (fig. 61).

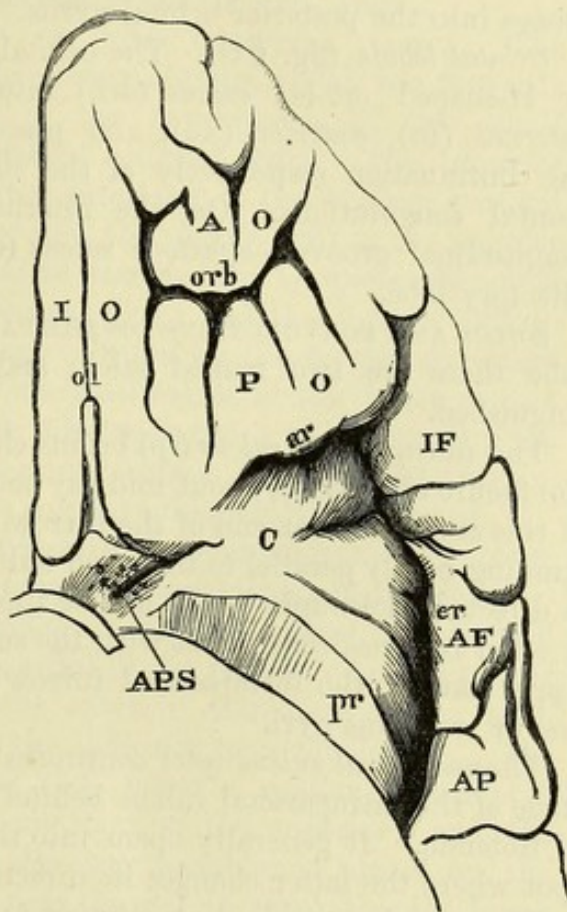
SULCI AND CONVOLUTIONS OF THE FRONTAL LOBE. On the outer surface of the frontal lobe there are four convolutions, separated by three sulci.

The *præcentral sulcus* (fig. 60, *pr c*) is placed in front of, and nearly parallel to, the lower half of the furrow of Rolando. From it the *inferior frontal sulcus* (*if*) runs forwards and downwards, towards the orbital surface of the lobe. Above this, the *superior frontal sulcus* (*sf*), which is often interrupted once or twice by cross gyri, takes a similar course.

The *ascending frontal convolution* (*af*) is simple, and forms the hindmost part of the frontal lobe, extending from the upper margin of the hemisphere to the Sylvian fissure, along the front of the furrow of Rolando. From its fore part the three longitudinal convolutions of this lobe take their origin.

The *superior frontal convolution* (*sf*) is longer and broader than the others, and is commonly much subdivided into secondary gyri. It lies between the margin of the hemisphere and the upper frontal sulcus.

Fig. 61.*



Opereulum
of the
insula.

Frontal
sulci are one
transverse,
and two
longi-
tudinal.

Frontal con-
volutions :
transverse ;

* Orbital lobule and central lobe. orb. Orbital sulcus. ol. Olfactory sulcus. ar. Anterior, er. External, and pr. Posterior sulci of Reil, the last opened by the removal of the temporo-sphenoidal lobe. io. Internal, ao. Anterior, and po. Posterior orbital convolutions. c. Central lobe or island of Reil. IF, AF, and AP. Lower parts of the inferior frontal, ascending frontal, and ascending parietal gyri, constituting the operculum. APS. Anterior perforated space.

middle, The *middle frontal convolution* (MF) runs from the ascending frontal to the lower margin of the lobe, between the upper and lower frontal sulci.

and inferior longi-
tudinal. The *inferior frontal convolution* (IF) is the smallest of all. Springing from the lower end of the ascending frontal convolution, it arches round the ascending and anterior branches of the Sylvian fissure, and passes into the posterior orbital gyrus.

Orbital
sulcus
and gyri. *Orbital lobule* (fig. 61). The orbital lobule is subdivided by a Y or H-shaped *orbital sulcus* (orb) into three convolutions, named *internal* (IO), *anterior* (AO), and *posterior* (PO) *orbital*, which are the continuation respectively of the superior, middle, and inferior frontal convolutions. On the internal orbital convolution is a longitudinal groove—*olfactory sulcus* (ol), for the reception of the olfactory lobe.

Olfactory
sulcus.
Parietal
sulci are **SULCI AND CONVOLUTIONS OF THE PARIETAL LOBE.** In the parietal lobe there are two named sulci; and four convolutions are distinguished.

intraparietal The *intraparietal sulcus* (ip) begins close to the posterior branch of the fissure of Sylvius, about midway between the upturned extremity of this and the lower end of the furrow of Rolando. It first ascends, running nearly parallel to the lower half of the latter sulcus, and then is directed backwards to the hinder limit of the parietal lobe, where it often becomes continuous with the superior occipital sulcus. The upper part of the intraparietal furrow is frequently interrupted by one or two cross gyri.

and post-
central. The *postcentral sulcus* (ptc) continues the direction of the ascending stage of the intraparietal sulcus behind the upper half of the furrow of Rolando. It generally opens into the intraparietal sulcus at the spot where the latter changes its direction.

Convolu-
tions:
ascending
parietal, The *ascending parietal convolution* (AP) is placed opposite the ascending frontal, and like that is simple, and extends from the upper margin of the hemisphere to the posterior branch of the Sylvian fissure. In front of it is the furrow of Rolando, round the ends of which it joins the ascending frontal convolution. Behind, it is limited by the postcentral sulcus above, and the transverse part of the intraparietal sulcus below.

superior
parietal
lobule, *Parietal lobules.* The larger portion of the parietal lobe behind the foregoing convolution is divided into two parietal lobules by the longitudinal part of the intraparietal sulcus. The *superior parietal lobule* (SPL) is connected in front to the upper end of the ascending parietal convolution between the postcentral sulcus and the upper margin of the hemisphere, and behind to the upper occipital convolution by a small winding gyrus which is called the first annectant convolution (below *po*). This lobule is divided into several secondary gyri.

and inferior
parietal
lobule, con-
sisting of
supra-
marginal The *inferior parietal lobule* is again subdivided into two convolutions, but the separation between them is often very indistinct. The *supramarginal convolution* (SM) is the anterior and larger of these: it springs in front from the lower end of the ascending parietal convolution, encircles the extremity of the posterior branch

of the Sylvian fissure, and ends by joining the superior temporo-sphenoidal convolution.

The *angular convolution* (*Ang*) arises from the hinder part of the foregoing, arches over the upper end of the parallel sulcus (*st*), and descends behind that furrow to be continued into the middle temporo-sphenoidal convolution: it is joined behind to the middle occipital convolution by the second annectant gyrus (behind *Ang*). and angular convolutions.

SULCI AND CONVOLUTIONS OF THE OCCIPITAL LOBE. The occipital lobe is divided into three convolutions, which run forwards from the posterior extremity of the hemisphere, by two small furrows—the *superior* and *middle occipital sulci*. The *superior occipital convolution* (*so*) is united anteriorly to the superior parietal lobule by the first annectant gyrus; the *middle* (*mo*) to the angular convolution by the second, and to the middle temporo-sphenoidal convolution by the third annectant gyri; and the *inferior* (*io*) to the lower temporo-sphenoidal convolution by the fourth annectant gyrus. An inconstant *inferior occipital sulcus*, at the lower margin of the hemisphere, separates the third occipital convolution from the external occipito-temporal of the under surface. The occipital convolutions are very variable, and the sulci are frequently ill marked. Occipital sulci and convolutions are superior, middle, and inferior.

SULCI AND CONVOLUTIONS OF THE TEMPORO-SPHENOIDAL LOBE. Three longitudinal sulci limit as many convolutions in this lobe. Temporo-sphenoidal sulci: upper or parallel,

The *superior temporo-sphenoidal* or *parallel sulcus* (*st*) is well marked, and runs below and parallel to the posterior branch of the fissure of Sylvius, from near the anterior extremity of the lobe, backwards and upwards, into the inferior parietal lobule. The *middle temporo-sphenoidal sulcus* (*mt*) takes a similar course at a lower level, but it is not so constant as the superior; and the *inferior* (fig. 62, *it*), which is also very variable, is placed on the under surface of the hemisphere near the margin, separating the lower temporo-sphenoidal from the external occipito-temporal convolution. middle, and inferior.

The *superior temporo-sphenoidal convolution* (inframarginal; *st*) forms the lower boundary of the posterior branch of the Sylvian fissure, and is continuous behind with the supramarginal convolution. The *middle* and *inferior temporo-sphenoidal convolutions* (*mt* and *it*) are commonly united in some part of their extent. The posterior end of the middle one is joined by the angular and third annectant gyri. The inferior forms the lower margin of the lobe, and receives the fourth annectant gyrus. Convolutions are also three.

CONVOLUTIONS OF THE CENTRAL LOBE (fig. 61, *c*). The triangular surface of the insula is divided by shallow sulci, converging from the base towards the apex, into five or six small gyri, which are for the most part concealed by the operculum. Convolutions of island of Reil.

SULCI AND CONVOLUTIONS OF THE INNER SURFACE OF THE HEMISPHERE (fig. 62). The convolutions of the inner aspect of the hemisphere, with which are included those of the lower surface behind the fissure of Sylvius, are generally well defined; but some being so long as to reach beyond the extent of a single lobe of the outer surface, they are not usually described as forming lobes like the foregoing. Sulci and convolutions of inner and tentorial surfaces.

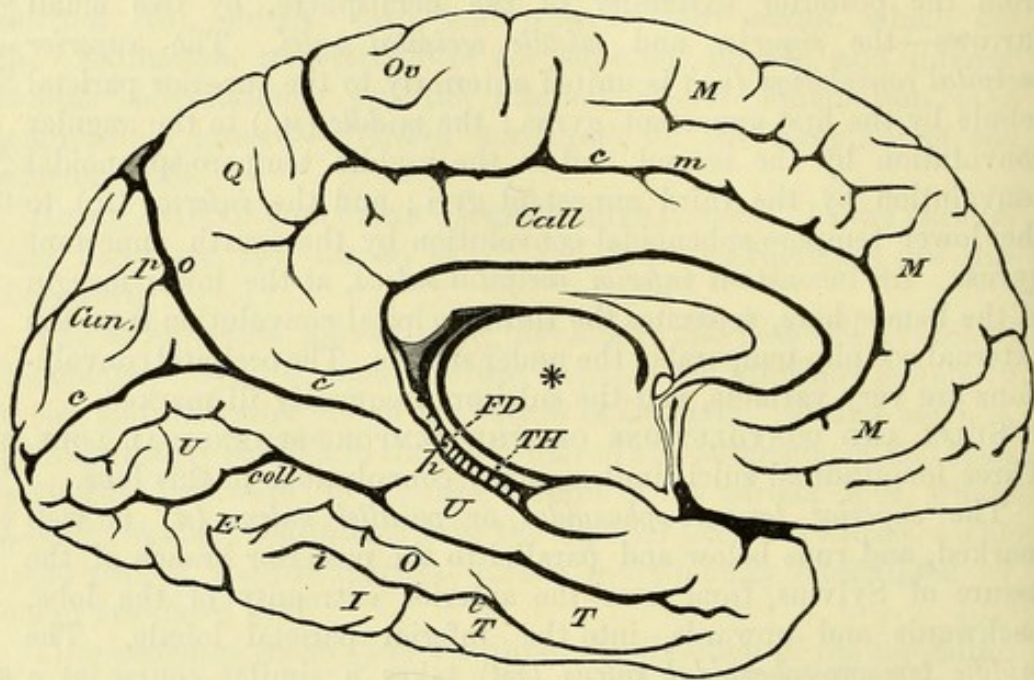
How to see them.

Dissection. The parts to be now described can only be seen satisfactorily on a separate hemisphere; but if the student possesses only the one brain, he may show much of the inner surface by cutting off the left hemisphere as low as the corpus callosum.

Calloso-marginal sulcus.

SULCI. The *calloso-marginal sulcus* (*cm*) begins below the rostrum of the corpus callosum, and arches upwards, following the curve of the fore part of that body. It is then directed backwards as far as

Fig. 62.*



the posterior extremity of the corpus callosum, where it bends upwards and ends by notching the superior margin of the hemisphere (fig. 60, *cm*). Its fore part is frequently interrupted by one or two small gyri uniting the adjacent convolutions.

Parieto-occipital fissure.

The *parieto-occipital* or *perpendicular fissure* (fig. 62, *po*) is a deep cleft which descends from the upper margin of the hemisphere at the back part, with a slight inclination forwards, to join the following sulcus on a level with the hinder end of the corpus callosum.

Calcarine fissure.

The *calcarine fissure* (*c*) is nearly horizontal. It begins close to the posterior extremity of the hemisphere, and is directed forwards, receiving the parieto-occipital fissure about the middle of its length, to end a little below the splenium of the corpus callosum. It gives rise to the eminence called *calcar avis* in the lateral ventricle, whence its name.

* Sulci and convolutions of the inner aspect of the hemisphere. *Sulci*: *cm*. Calloso-marginal. *po*. Parieto-occipital fissure. *c*. Calcarine fissure. *h*. Hippocampal fissure. *coll*. Collateral fissure. *it*. Inferior temporo-sphenoidal sulcus.

Convolutions: *m*. Marginal. *Ov*. Oval lobule. *Call*. Callosal convolution. *Q*. Quadrate lobule. *Cun*. Cuneate lobule. *u*. Uncinate convolution. *ext*. External occipito-temporal. *it*. Inferior temporo-sphenoidal. *FD*. Fascia dentata. *TH*. Tænia hippocampi. * Cut surface of optic thalamus.

The *hippocampal* or *dentate fissure* (*h*) is placed in front of the foregoing, at the inner margin of the lower portion of the hemisphere, and separates the uncinat convolution (*u*) from the *tænia hippocampi* (*th*). It corresponds to the hippocampus major in the descending cornu of the lateral ventricle, and its relations will be better seen when that body is examined.

Hippocampal fissure.

The *collateral fissure* (*coll*) gives rise to the collateral eminence in the lateral ventricle. It extends from near the posterior extremity of the hemisphere to the fore part of the temporo-sphenoidal lobe, and is frequently broken up into two or three parts by cross gyri.

Collateral fissure.

CONVOLUTIONS. The *marginal convolution* (*m*) occupies the space between the calloso-marginal sulcus and the border of the hemisphere. It is much subdivided, and at its posterior extremity a small portion which is marked off by a short vertical furrow is distinguished as the *oval* or *paracentral lobule*. The marginal convolution is continuous over the border of the hemisphere with the internal orbital and superior frontal convolutions, while the oval lobule is formed by the upper end of the ascending frontal convolution.

Marginal convolution.

Oval lobule.

The *callosal convolution* (*gyrus fornicatus*; *Call*) is narrower and simpler than the marginal. Beginning below the rostrum of the corpus callosum, this convolution follows the curve of that body, and turns downwards behind its posterior extremity to end in a thin part which joins the uncinat convolution (*u*). It is bounded in the greater part of its extent by the calloso-marginal sulcus, but behind the spot where this furrow turns upwards it is continuous with the quadrate lobule (*q*). Near its ending, it is limited below by the calcarine fissure.

Convolution of the corpus callosum.

The *quadrate lobule* (*q*) is placed between the end of the calloso-marginal sulcus and the parieto-occipital fissure. Much subdivided by secondary furrows, it reaches the margin of the hemisphere above, where it is continuous with the superior parietal lobule, and joins the callosal convolution below.

Quadrate lobule.

The *cuneate lobule* (occipital lobule; *Cun*) is triangular in shape, the base being formed by the margin of the hemisphere. In front of it is the parieto-occipital, and below the calcarine fissure. Small irregular sulci divide it into secondary gyri.

Cuneate lobule.

The *uncinat* or *internal occipito-temporal convolution* (*u*) extends from the posterior extremity of the hemisphere to the Sylvian fissure, being bounded by the calcarine and hippocampal fissures above, and by the collateral fissure below. It is somewhat narrowed in the middle, where the callosal convolution joins it, and enlarged in front and behind. At its fore part is a small piece (*uncus*) bent backwards over the lower end of the dentate fissure, from which the convolution derives its name.

Uncinat convolution.

The *external occipito-temporal convolution* (*EOT*) lies between the collateral fissure and the inferior temporo-sphenoidal sulcus (*it*). This is frequently not distinct from the lower temporo-sphenoidal convolution.

External occipito-temporal convolution.

At the bottom of the hippocampal fissure, the grey cortex of the

Dentate gyrus.	hemisphere ends in a projecting notched margin, which is named <i>fascia dentata</i> or <i>dentate convolution</i> (FD). This will be better seen subsequently (p. 217).
Form and structure of convolutions :	<i>Structure of the convolutions.</i> Each convolution is continuous with the general mass of the hemisphere on the one side (base), and is free on the other, where it presents a summit and lateral surfaces, which are covered by pia mater. A cross section will show its constitution of a layer of <i>cortical</i> grey substance on the surface, which is continued at the bottom of the sulci from one eminence to another, and a white <i>medullary</i> part in the centre, which appears as a process of the large medullary mass forming the greater part of the substance of the hemisphere. On examining closely the section of a convolution in a fresh specimen, the cortex may generally be seen to consist of three grey, and as many thinner white, layers arranged alternately, the outermost being a thin white stratum, which is most marked over the fore part of the uncinat convolution.
grey cortical,	
and white medullary parts.	
Cortex composed of six layers of white and grey substance alternately.	
Outline of cerebrum.	<i>INTERIOR OF THE CEREBRUM.</i> Each cerebral hemisphere consists of white and grey substance, the white forming the larger portion of the mass (medullary centre of the hemisphere), while the grey matter is chiefly disposed in a superficial layer (cortex) which covers the medullary centre, except over the region on the inner side whence the corpus callosum issues ; but at the lower part of the hemisphere there are other collections of grey matter more or less surrounded by the medullary substance. In each hemisphere is an elongated cavity, named the lateral ventricle, which communicates with another median space—the third ventricle, placed close to the base of the brain.
Medullary centre ; cortical	
and central grey masses ;	
ventricles.	
Cut down to smaller oval centre of the hemisphere.	The student will now proceed to examine the parts in the interior of the hemisphere, carrying the dissection from above downwards. <i>Dissection.</i> Supposing both hemispheres entire, the left is to be cut off to the level of the calloso-marginal sulcus. When this has been done, the surface displays a white central mass of a semi-oval shape (<i>centrum ovale minus</i>), sending processes into the convolutions, and surrounded by an irregular grey margin. In a fresh brain this surface would be studded with drops of blood escaping from the divided vessels.
Reflect callosal convolution.	Next, the callosal convolution is to be divided about the middle, and the two pieces are to be thrown backwards and forwards. On its under surface will be seen a thin band of white fibres, the <i>covered band of Reil</i> or <i>fillet of the corpus callosum</i> , which bends down before and behind the corpus callosum.
Repeat dissection on right side.	A similar dissection is to be carried out on the opposite side ; and the hemisphere being removed to the level of the corpus callosum, the transverse fibres of that body are to be defined as they radiate to the convolutions.
The larger oval centre is deeper.	Now a much larger white surface comes into view (<i>centrum ovale majus</i>), and the white masses in the two hemispheres are seen to be continuous, across the middle line, through the corpus callosum.
Corpus callosum.	The <i>corpus callosum</i> reaches from one half of the cerebrum to the other, and forms the roof of the lateral ventricle in each hemisphere.

Its central part, which is exposed in the longitudinal fissure, is very narrow, and measures about three inches in length. It is nearer to the anterior than to the posterior end of the cerebrum, and is somewhat arched from before backwards. On each side its upper surface is free for a short distance beneath the callosal convolution, from which it is separated by a groove.

Situation,
extent and
form.

In front, the corpus callosum is bent downwards (fig. 62), forming the *genu* and *rostrum* as before described (p. 203); and behind, it ends in a thickened part named the *splenium*.

Anterior
and
posterior
ends.

The fibres of the corpus callosum are for the most part directed transversely, but on the upper surface there is a somewhat irregular, narrow longitudinal band on each side close to the middle line (*striae longitudinales* or nerves of Lancisi). Between the two bands is a median groove or *raphé*. Farther out there may be seen other longitudinal fibres belonging to the covered band, if that has not been completely removed. The longitudinal *striae* are prolonged downwards in front, and form the peduncles of the corpus callosum (p. 203).

Fibres
transverse ;
a few longi-
tudinal.

Dissection. In order to see the thickness of the corpus callosum, and to bring into view the parts in relation with its under surface, a cut is to be made through it on the right side about half an inch from the *raphé*; and this is to be extended forwards and backwards, as far as the limits of the underlying ventricle. While cutting through the corpus callosum, the student may observe that a thin membraniform structure (*ependyma*) lines its under surface.

Dissection.

The corpus callosum is thicker at each end than at the centre, in consequence of a greater number of fibres being collected from the cerebrum; and the posterior part is the thickest of all. Connected with its under surface along the middle is the *septum lucidum* or partition between the ventricles (fig. 63, *b*) at the fore part, and the *fornix* (*c*) behind.

Is thickened
at each end.

Under
surface.

This is the chief commissural body of the halves of the cerebrum, and its fibres pass laterally into the medullary centre of the hemisphere, in which they radiate to the convolutions.

Dissection. The left lateral ventricle is to be now opened in the same way as the right; and to prepare for the examination of the cavity on the right side, as much of the corpus callosum as forms the roof of the space is to be removed. A part of the ventricle extends down in the temporo-sphenoidal lobe towards the base of the brain; and to open it, a cut is to be carried outwards and downwards, through the substance of the hemisphere, along the course of the hollow. (See fig. 63.)

Dissection.

VENTRICLES OF THE BRAIN. Five ventricles are described in the brain; but four of them are subdivisions of one large central cavity, and these are lined throughout by a thin membrane named the *ependyma*, which is covered by epithelium, for the most part ciliated. They are the two lateral ventricles, one in each cerebral hemisphere, the third ventricle close to the base of the brain, and the fourth ventricle between the cerebellum and the back of the pons and medulla oblongata. The fifth ventricle is a small space between

Brain con-
tains five
ventricles.

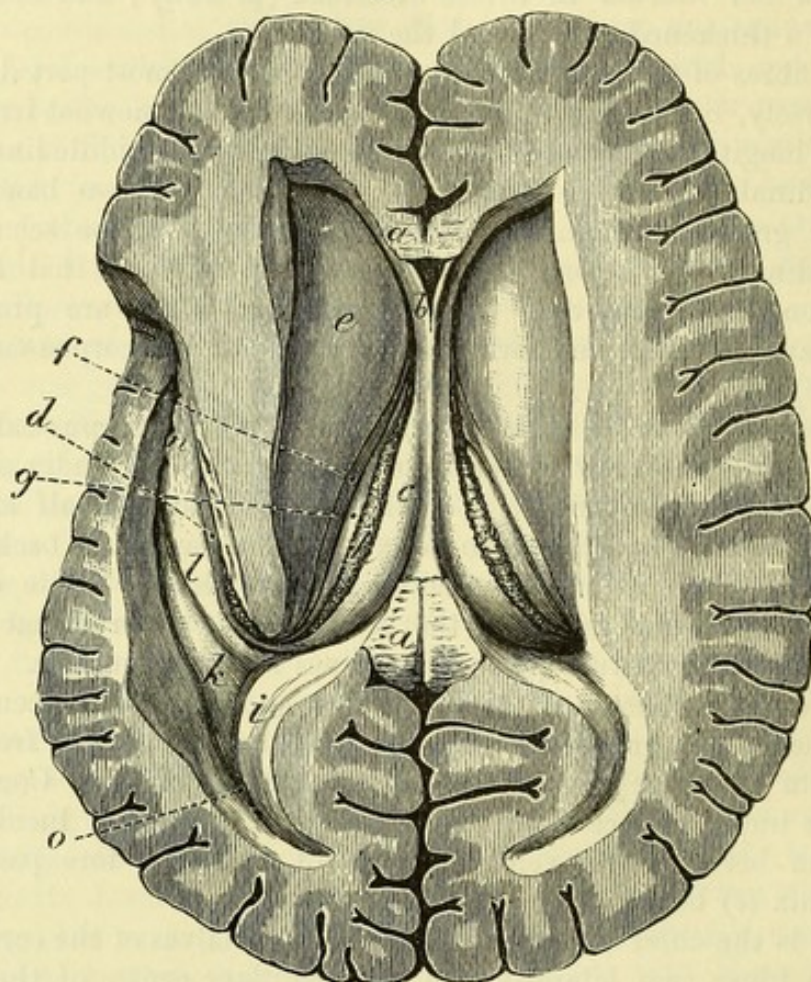
Fifth is

different from others. the layers of the septum lucidum, and has not any lining of ependyma.

Lateral ventricle.

The *lateral ventricle* (fig. 63) is a narrow space which extends nearly the whole length of the hemisphere, and sends a process downwards into the temporo-sphenoidal lobe. The cavities of the two sides approach one another in front, where they are only separated

Fig. 63.*



by the thin septum lucidum; and below the hinder part of that partition, each communicates with the third ventricle by an aperture known as the foramen of Monro. At the back there is a wider interval between them. The roof of the space is formed in its whole extent by the fibres of the corpus callosum passing outwards to the convolutions; in the floor are numerous objects which will be enumerated in connection with the several parts of the ventricle.

Subdivision. The ventricle consists of a central part or *body*, and three processes or *cornua*, anterior, posterior, and middle or inferior.

* View of the lateral ventricles: on the left side the descending cornu is laid open. (From a model in the museum of University College, London.)
a, a. Ends of the corpus callosum. *b.* Septum lucidum, enclosing the small space of the fifth ventricle. *c.* Fornix. *d.* Posterior crus of the fornix or tænia hippocampi. *e.* Caudate nucleus of the corpus striatum. *f.* Tænia semicircularis. *g.* Optic thalamus. *h.* Choroid plexus. *i.* Hippocampus minor. *k.* Eminentia collateralis. *l.* Hippocampus major. *o.* Posterior cornu of the ventricle.

The *body* is beneath the parietal lobe of the hemisphere, and extends from the foramen of Monro to the splenium of the corpus callosum. It is somewhat arched, with the convexity upwards, and in its floor are seen the following parts, proceeding from without inwards :—1, the hinder portion of a pyriform mass of grey matter named the corpus striatum (caudate nucleus ; *e*), 2, a slender white band—the *tænia semicircularis* (*f*), 3, a narrow part of the optic thalamus (*g*), 4, a vascular fringe of the pia mater—the choroid plexus (*h*), and 5, a thin white layer—the lateral part of the fornix (*c*). It is bounded internally for a short distance in front by the hinder part of the septum lucidum (*b*), and behind this by the meeting of the fornix and corpus callosum.

Body :

objects in floor ;

mesial limit.

The *anterior cornu* projects forwards, with an inclination downwards and outwards, into the frontal lobe. In the floor are the large anterior extremity (head) of the caudate nucleus and the rostrum of the corpus callosum ; its anterior boundary is formed by the genu of the latter body ; and internally it is separated from the cavity of the opposite side by the septum lucidum.

Anterior horn :

boundaries.

The *posterior cornu* (*o*) is narrower and generally longer than the anterior, but its breadth and length vary much in different brains. It extends backwards into the occipital lobe, being curved outwards round the parieto-occipital fissure of the internal surface of the hemisphere. Along its inner side is an elongated white eminence—the hippocampus minor (*i*) ; and the floor is formed by the hinder part of the eminentia collateralis (*k*).

Posterior horn :

form ;

inner wall ; and floor.

The *inferior* or *descending cornu* leaves the hinder part of the body of the ventricle opposite the splenium of the corpus callosum, and runs downwards and forwards in the temporo-sphenoidal lobe, describing a curve with the convexity outwards. In the roof are contained the fibres passing from the hinder end of the corpus callosum downwards and outwards into the temporo-sphenoidal lobe, together with the prolongations of the caudate nucleus and *tænia semicircularis*. The floor is formed mainly by a long curved eminence—the hippocampus major (*l*), along the inner margin of which is a thin band prolonged from the fornix—the *tænia hippocampi*, while to its outer side lies the tapering fore part of the eminentia collateralis. The choroid plexus is continued downwards along the inner side to the lower extremity of this cornu.

Middle horn :

direction ;

roof ;

and floor.

The *septum lucidum* (fig. 63, *b*) is placed vertically between the two lateral ventricles, beneath the anterior half of the corpus callosum, to which its upper border is attached. It is triangular in shape, with the base turned downwards and forwards, and fixed to the rostrum of the corpus callosum. The posterior border is oblique, and joins the fornix. Its surfaces look into the lateral ventricles, opposite the head of the caudate nucleus. Although so thin as to be translucent, the septum lucidum consists of two laminae which enclose a space—the fifth ventricle. Each lamina is composed of white substance, with a thin layer of grey matter internally ; and the ependyma of the lateral ventricle covers its outer surface.

Septum lucidum :

position, form, and attachments ;

is a double partition, containing fifth ventricle.

- Dissection.** *Dissection.* The fifth ventricle will be exposed by cutting through the piece of the corpus callosum which remains in the middle line, and detaching the anterior half from the septum lucidum.
- Fifth ventricle.** The *fifth ventricle* (vent. of the septum) is a narrow slit in the fore part of the septum lucidum, where this is deeper. Posteriorly and above, the laminae of the septum are united to a variable extent. Like the septum, it is larger in front than behind. This cavity has not any epithelial lining.
- Dissection.** *Dissection.* The fornix is to be next examined. To lay bare this body the posterior part of the corpus callosum should be detached with care from it, and thrown backwards; and the septum lucidum should also be removed from its upper surface.
- Fornix: position and form.** The *fornix* (fig. 63, *c*) is a thin white layer beneath the corpus callosum, which, projecting on each side into the lateral ventricle, forms part of the floor of that cavity. Its central part or *body* is triangular in shape, with the base turned backwards; and it is continuous with the rest of the brain by processes named *crura* in front and behind.
- Upper surface and borders.** The upper surface of the body has the septum lucidum attached to it along the middle line in front; and behind, its median part is united to the corpus callosum. Each border is free in the corresponding lateral ventricle, where it rests on the optic thalamus, the velum interpositum being between the two; and along it lies the choroid plexus. At its base it joins the corpus callosum in the middle, while on each side it sends off a small riband-like band—the *posterior crus* or *tænia hippocampi* (fig. 64, *c*), along the concave margin of the hippocampus major. At the anterior end it is arched over the foramen of Monro, opposite the front of the optic thalamus, and ends likewise in two processes or *crura*, which will be afterwards followed to the corpora albicantia and the optic thalami (p. 224).
- Posterior and anterior part.**
- Under surface.** If the fornix be cut across near its front, the foramen of Monro will be opened, and the descending anterior pillars will be seen (fig. 64). When the posterior part is raised, it will be found to be supported on a process of the pia mater, named velum interpositum. And near its base, on the under aspect, is a triangular surface, marked by transverse lines, which are produced by the fibres of the corpus callosum appearing in the interval between the two diverging longitudinal bands of the fornix: the part which is so defined has been called the *lyra* (fig. 64, *a*).
- is marked by lines.**
- Fornix formed of two bands.** The fornix may be described as consisting of two bands, right and left, which are united for a certain distance in the central part or body. According to this view, each band, commencing in the optic thalamus and passing through the corpus albicans, arches over the foramen of Monro, and after forming the body of the fornix, is continued as the *tænia hippocampi* to the hook of the uncinatæ convolution.
- Foramen of Monro.** The *foramen of Monro* is a short slit between the fore part of the fornix and the optic thalamus. Through it the lateral ventricle communicates with the third ventricle, and indirectly with the one

of the opposite side. It is lined by a prolongation of the ependyma, which is thus continued from one ventricle to the other.

The student may leave untouched for the present the velum interpositum, and proceed to examine the bodies which have been enumerated in the floor of the posterior and descending cornua.

The *hippocampus minor* or *calcar avis* (fig. 63, *i*) is a spindle-shaped prominence on the inner side of the posterior cornu of the lateral ventricle. If it is cut across, it will be seen to be formed by the calcarine fissure pushing outwards the wall of the cavity (p. 210), and beneath the white layer is the cortical grey substance passing from the uncinatè convolution to the cuneate lobule at the bottom of the fissure. Hippocampus minor, formed by calcarine fissure.

The *hippocampus major* (fig. 63, *l*) is the large convex eminence in the floor of the descending cornu of the lateral ventricle, and like that is curved, with the concavity directed inwards. Its anterior extremity, which is named *pes hippocampi*, is somewhat enlarged, and presents two or three indentations, resembling the foot of a feline animal. Hippocampus major. Pes hippocampi.

Along the inner margin of the hippocampus is the *tænia hippocampi* or *fimbria* (fig. 64, *c*), which is prolonged from the fornix; this ends below by joining the small recurved part of the uncinatè convolution (p. 211). Tænia hippocampi.

Dissection. To examine more fully the hippocampus, the hinder portions of the corpus callosum and fornix should be divided in the middle line, and the posterior part of the right hemisphere should be drawn away from the rest of the brain. When the pia mater has been removed from the inner side of the hippocampus, and this projection has been cut across, its structure will be seen. Dissection.

The hippocampus is covered on the ventricular surface by a thin medullary layer, with which the *tænia* blends. On its opposite surface is the hollow of the hippocampal fissure of the exterior of the brain, which is lined by grey substance. Beneath the *tænia hippocampi* the grey matter projects in the form of a notched ridge, the *fascia dentata*: this is external to the cavity of the ventricle, and has been named the dentate convolution (p. 212). Structure of hippocampus.

The *eminèntia collateralis* (fig. 63, *k*) is the triangular, slightly convex surface occupying the floor of the posterior and descending cornua of the lateral ventricle to the outer side of the hippocampi. It lies over the collateral fissure of the under surface of the hemisphere; and its extent varies greatly in different subjects. Collateral eminence, formed by collateral fissure.

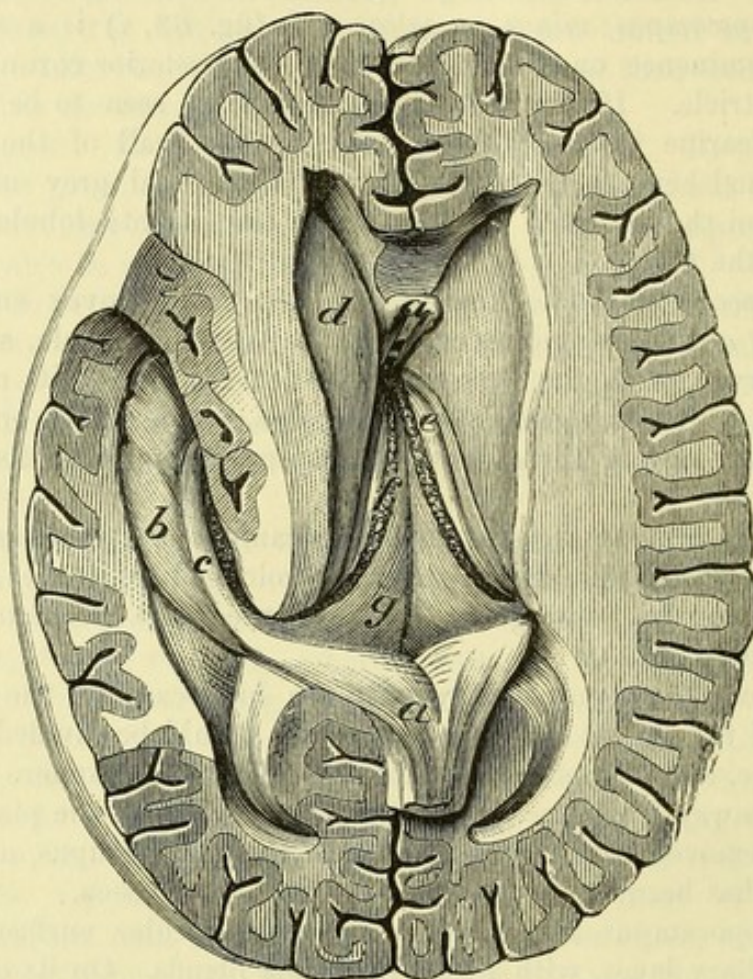
Transverse fissure of the cerebrum. By drawing the separated part of the right hemisphere away from the crus cerebri and the optic thalamus, and replacing it, the dissector will comprehend the position and boundaries, on one side, of the great cleft of the brain. Great transverse fissure

This fissure lies beneath the fornix; and in the dissected brain opens into the lateral ventricle along the edge of the fornix on each side, from the foramen of Monro to the extremity of the descending cornu. The slit opening into the lateral ventricle is bounded by the edge of the fornix with the *tænia hippocampi* on the one side, is beneath fornix, and reaches base of brain.

Pia mater
enters it.

and by the optic thalamus and crus cerebri on the other. A fold of pia mater (*velum interpositum*) projects into the transverse fissure beneath the fornix (fig. 64, *g*), and forms lateral fringes—

Fig. 64. *



the choroid plexuses, which appear in the ventricle along the margin of the slit. In the natural state the fissure is separated from the cavity of the ventricle by the epithelium of the ependyma being continued over the choroid plexus.

Parts in the
middle of
the brain.

The student is now to return to the examination of the parts in the centre of the brain, viz., the fold of pia mater and its vessels, with the third ventricle. Afterwards the corpus striatum and optic thalamus will be studied.

Velum, or
fold of
pia mater

is over third
ventricle,

The *velum interpositum* (fig. 64, *g*) is the fold of pia mater entering the great transverse fissure. Triangular in shape, it has the same extent as the body of the fornix, and reaches in front to the foramen of Monro. The upper surface is in contact with the fornix, to which it supplies vessels. The lower surface, looking to the third ventricle, covers the pineal body and a part of each optic

* Second view of the dissection of the brain, the fornix being cut through in front and raised. (From a model in the Museum of University College, London.) *a*. Fornix. *b*. Hippocampus major. *c*. Tænia hippocampi. *d*. Caudate nucleus. *e*. Optic thalamus. *f*. Choroid plexus. *g*. Velum interpositum.

thalamus : on it, close to the middle line, are the two choroid plexuses of the third ventricle ; and along each side is the choroid plexus of the lateral ventricle. and carries choroid plexuses.

The *choroid plexus of the lateral ventricle* (fig. 64, *f*) is the red, somewhat rounded and fringed margin of the velum interpositum, which projects into the lateral ventricle, extending from the foramen of Monro to the extremity of the descending cornu. Its lower part is larger than the upper. The epithelium lining the ventricle is continued over the choroid plexus, but it loses its cilia in this situation. The right and left choroid plexuses are continuous at the anterior extremity of the velum, where they are similarly excluded from the foramina of Monro by the epithelial lining.* Choroid plexus of the lateral ventricle.

Vessels of the velum. Small *arteries* have been already traced to the velum and the choroid plexus from the cerebral and cerebellar arteries (pp. 184, 185) : they are three on each side, and supply the surrounding cerebral substance. The *veins* of the choroid plexus receive branches from the ventricle, and end in the following. Vessels of the velum.
Arteries ;
veins ;

Veins of Galen. Along the centre of the velum are placed two large veins with this name ; they begin at the foramen of Monro, by the union of branches from the corpus striatum and the choroid plexus. Lying side by side in the membrane, they are usually united into one at the posterior part of the velum ; and through this they join the straight sinus. with veins of Galen.

Dissection. When the velum interpositum has been raised and thrown backwards, the third ventricle will be opened (fig. 65). In reflecting the piece of pia mater the student must be careful not to detach the pineal body (*g*) behind, which is surrounded by the membrane. On the under surface of the velum are seen the choroid plexuses of the third ventricle. Dissection.

The *choroid plexuses of the third ventricle* are two short and narrow fringed bodies below the velum, which resemble the like structures in the lateral ventricle. Choroid plexuses of third ventricle.

The *third ventricle* is the narrow interval between the optic thalami (fig. 65). Its situation is in the median plane of the cerebrum, below the level of the lateral ventricles, with which it communicates ; and it reaches to the base of the brain. Its boundaries and communications are the following :— Third ventricle
is near base of brain.

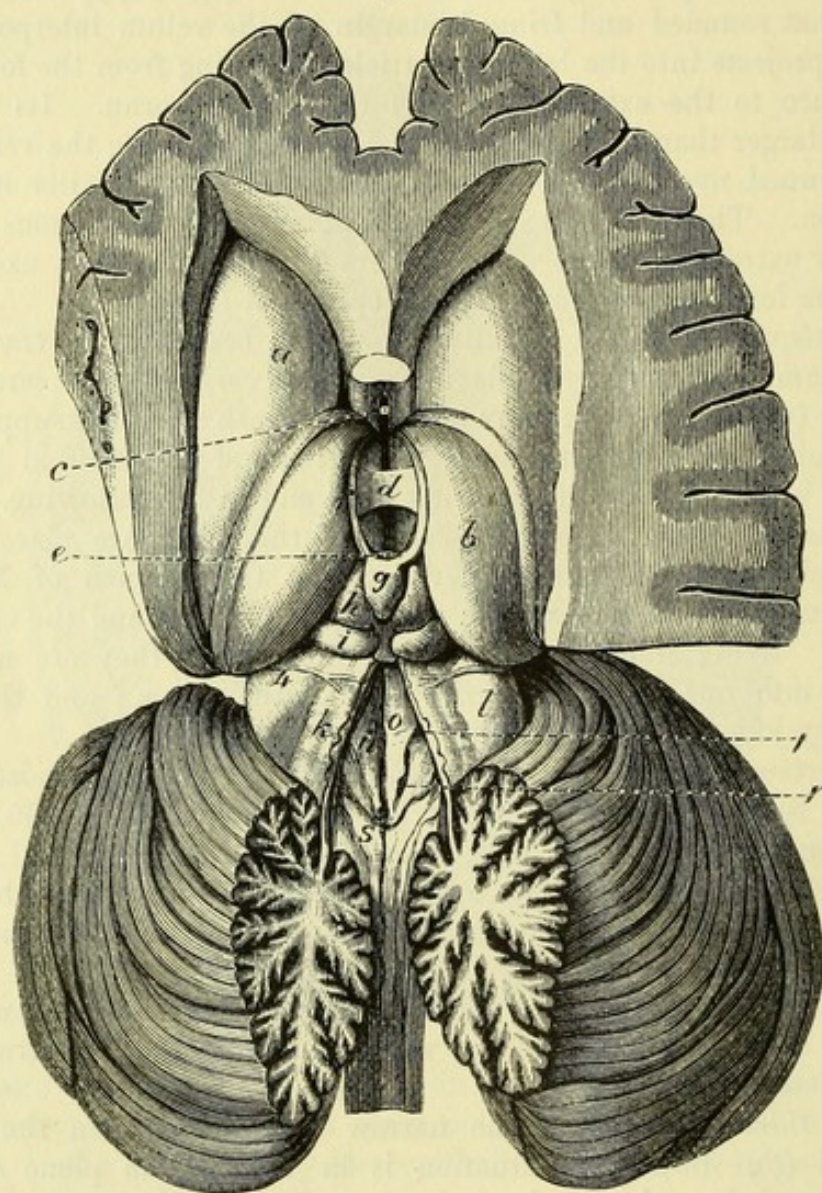
The roof is formed by the velum interpositum with the choroid plexuses, above which is the fornix. The floor is very oblique from behind forwards, so that the depth of the cavity is about three-quarters of an inch in front and half as much behind : its hinder part is formed by the united tegmenta ; and in front of these it corresponds with the parts at the base of the brain, which lie between the crura cerebri (fig. 59), viz., posterior perforated space, corpora albicantia, tuber cinereum with the infundibulum, and the optic commissure. On the sides of the cavity are situate the optic thalami (*b*) and the anterior pillars of the fornix. In front Roof.
Floor.

Parts on the sides,

* Particles of brain-sand, like that in the pineal body, are sometimes present in the choroid plexus.

of the space are the anterior commissure (*c*) and the lamina cinerea. Behind are the posterior commissure (*e*) and the pineal body (*g*).
 in front, and behind.

Fig. 65.*



Crossing the centre of the ventricle, from one optic thalamus to the other, is a band of grey matter—the soft commissure (*d*).

Openings
into other
ventricles.

This space communicates with the other ventricles of the brain in the following way:—In front it joins each lateral ventricle

* View of the third and fourth ventricles; the former being exposed by the removal of the velum interpositum; and the latter by dividing vertically the worm of the cerebellum. (From a model in the Museum of University College.) The third ventricle is the interval in the middle line between the optic thalami, *b*. *a*. Caudate nucleus. *b*. Optic thalamus. *c*. Anterior commissure, seen between the anterior crura of the fornix. *d*. Middle or soft commissure. *e*. Posterior commissure. *f*. Pineal stria. *g*. Pineal body. *h* and *i*. Corpora quadrigemina.

The fourth ventricle, *n*, is at the back of the medulla oblongata. *k*. Valve of Vieussens. *l*. Upper peduncle of the cerebellum. *o*. Fasciculus teres. *p*. Superior fovea. *r*. Inferior fovea. *s*. Clava. 4. Fourth nerve arising from the valve of Vieussens.

through the foramen of Monro; and behind is a passage beneath the posterior commissure into the fourth ventricle, which is named aqueduct of Sylvius. In the floor, in front, there is a depression opposite the infundibulum, where the cavity at an early period of foetal life was prolonged into the pituitary body.

The ependyma lining the ventricle is continued into the neighbouring cavities through the different apertures of communication, and its epithelium is continued over the choroid plexuses in the roof.

Grey matter of the ventricle. A stratum of grey matter forms the lower part of the wall of the ventricle. Portions of this layer appearing at the base of the brain constitute the posterior perforated space, the tuber cinereum and the lamina cinerea. It also extends into the corpus albicans, forming the nucleus of that body. At the fore part of each optic thalamus it covers the crus of the fornix, and ascends to the septum lucidum. In the middle of the space it reaches from side to side, and forms the soft commissure (*d*).

The *corpus striatum* (fig. 63, *e*) is the large grey body which has been seen in the floor of the lateral ventricle. The grey matter composing it is incompletely divided into two masses—*caudate* and *lenticular nuclei*, by a layer of white fibres, named the *internal capsule*; and it has received its name from the striated appearance of this layer.

Dissection. To show the composition of the corpus striatum, the upper part of that body and of the optic thalamus should be sliced off on the right side, until a view resembling that in fig. 66 is obtained. The superficial anatomy of the corpus striatum and optic thalamus may be studied on the left side.

The *caudate* or *intraventricular nucleus* (fig. 65, *a*) is a long pyriform mass of reddish-grey substance which projects into the lateral ventricle. Its larger extremity or *head* (fig. 66, *cn*) is turned forwards, and forms the floor of the anterior cornu of the ventricle. The middle tapering portion is directed backwards and outwards, along the outer side of the optic thalamus, beneath the body of the ventricle, and ends in the *tail* (fig. 66, *cn'*), which bends downwards and is prolonged in the roof of the descending cornu of the cavity, nearly to its anterior extremity. Numerous veins run over the surface of the caudate nucleus, and they may be seen to join a larger vessel (vein of the corpus striatum) which lies along the groove between the caudate nucleus and optic thalamus.

The *lenticular* or *extraventricular nucleus* (fig. 66, *ln*) is entirely surrounded by white matter, and is placed opposite the bottom of the fissure of Sylvius and the insula (*I*) of the exterior of the hemisphere. It appears lens-shaped in horizontal section, but triangular, with the base turned outwards, when cut transversely. Internally, it is separated from the caudate nucleus and optic thalamus by the internal capsule; and externally and below, it is bounded by a thinner white layer named the *external capsule* (*ec*).

The *internal capsule* (fig. 66) is a thick layer of white fibres, which is seen in the horizontal section to form a bend—*genu* (*icg*), opposite

Lining of
cavity.

Grey matter
of the
ventricle.

Corpus
striatum,
structure.

Dissection.

Caudate
nucleus
shows in
lateral
ventricle.

Veins on
surface.

Lenticular
nucleus is
only seen in
sections;

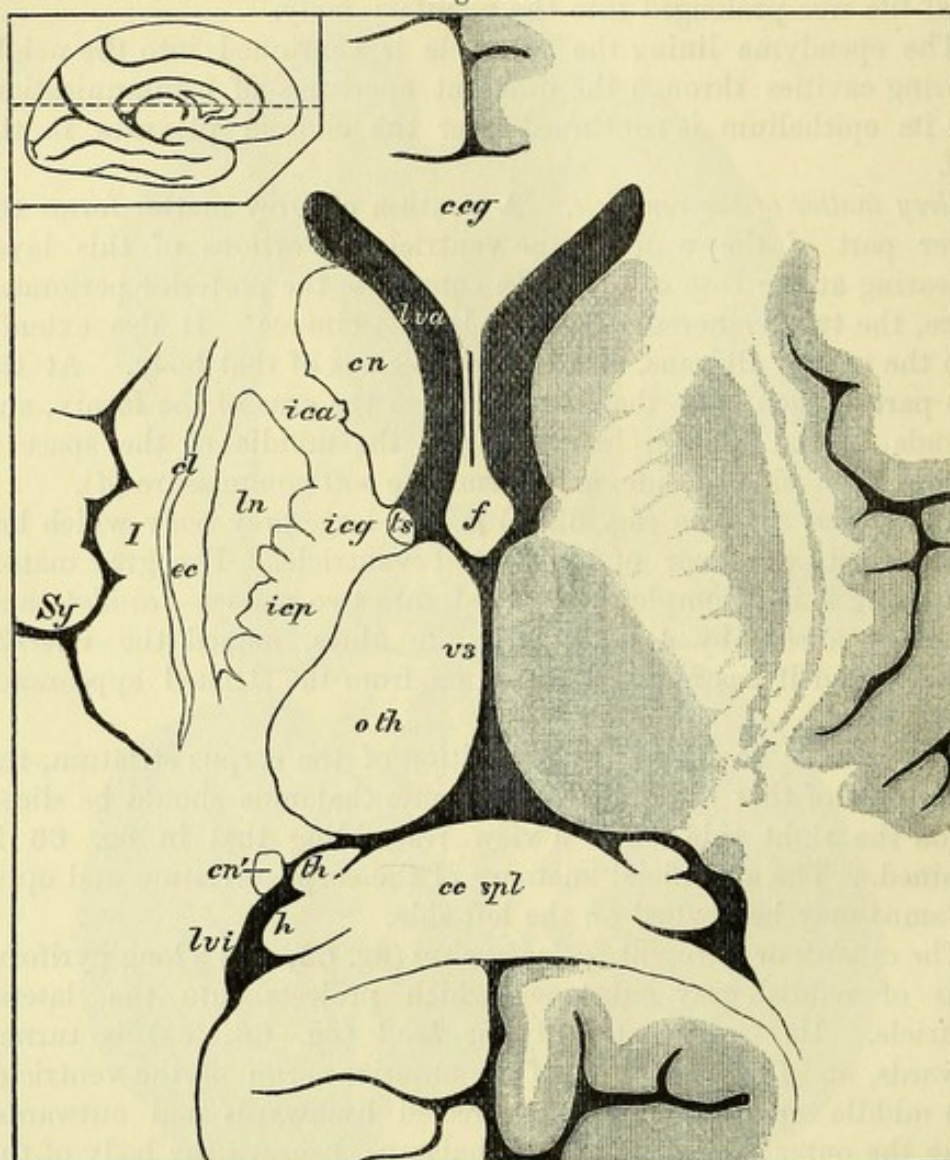
surrounded
by white
capsule.

Internal
capsule,

parts,

the groove between the optic thalamus and the head of the caudate nucleus. The part in front of the genu is named the *anterior limb (ica)*, and the longer part behind is the *posterior limb (icp)* of the

Fig. 66.*



source of
fibres ;

pyramidal
tract.

capsule. The internal capsule is formed in large part by the fibres of the crusta of the crus cerebri coursing upwards to the medullary centre of the hemisphere, but many fibres are added from the nuclei on each side. The pyramidal fibres, which have been traced from the medulla oblongata through the pons (p. 199), and crusta (p. 202), occupy the anterior two-thirds of the posterior limb. The fibres of

* Middle part of a horizontal section through the cerebrum at the level of the dotted line in the small figure of one hemisphere (after Dalton). *ceg.* Genu, and *cc spl.* Splenium of corpus callosum. *f.* Fornix ; the septum lucidum, containing the fifth ventricle between its layers, unites the fornix with the corpus callosum. *lva.* Anterior, and *lvi.* Inferior cornu of the lateral ventricle. *cn.* Caudate nucleus, head, and *cn'*, tail. *ts.* Tænia semicircularis. *oth.* Optic thalamus. *th.* Tænia hippocampi. *h.* Hippocampus major. *ica.* Anterior limb, *ictg.* Genu, and *icp.* Posterior limb of the internal capsule. *ln.* Lenticular nucleus. *cc.* External capsule. *cl.* Claustrum. *I.* Island of Reil. *Sy.* Deep part of fissure of Sylvius.

the capsule are collected into separate bundles, between which the grey matter is continued from the caudate to the lenticular nucleus.

On the outer side of the external capsule, separating that from the medullary substance of the convolutions of the insula, is a third portion of grey matter, a thin layer which appears as a slightly wavy line in sections: this is named the *claustrum* (fig. 66, *cl*). Clastrum.

The *tænia semicircularis* (fig. 63, *f*) is a narrow whitish band of longitudinal fibres, which lies along the groove between the caudate nucleus and the optic thalamus. In front, the band becomes broader and joins the pillar of the fornix; behind, it is continued with the tail of the caudate nucleus into the roof of the descending cornu of the lateral ventricle, at the lower end of which it joins the cortical grey matter. Tænia semi-circularis.

Dissection. The anterior commissure is next to be exposed in its course through the cerebral hemisphere. For this purpose the remaining fore part of the caudate nucleus, the white fibres, and the lenticular nucleus, on the right side, must be successively scraped away with the handle of the scalpel, and the rounded band traced outwards from the spot where it is seen at the front of the third ventricle to the medullary centre of the temporo-sphenoidal lobe. Anterior commissure;
dissection to show it;

The *anterior commissure* is a round bundle of white fibres about as large as a crow-quill, which is free only for about an eighth of an inch in the middle of its extent, where it lies in front of the pillars of the fornix (fig. 65, *c*). Laterally, it passes outwards beneath the corpus striatum, lying between the lenticular nucleus and the grey matter of the anterior perforated space, and curving backwards, spreads out in the white substance of the temporo-sphenoidal lobe above the descending cornu of the lateral ventricle. its form,
position,
course, and
ending.

The *optic thalamus* (fig. 65, *b*) is an oval-shaped body which takes part in bounding the lateral and third ventricles. Its upper surface is marked by a shallow oblique groove, which corresponds to the edge of the fornix. The part of the surface inside the groove is in contact with the velum interpositum; but the narrower outer part is free in the floor of the lateral ventricle, and is covered by the ependyma of that cavity: at its anterior end it forms a slight prominence known as the *tubercle* of the optic thalamus. Externally this surface is bounded by the *tænia semicircularis*, which separates it from the caudate nucleus. The inner surface is for the most part free, forming the lateral wall of the third ventricle, but near the middle it is united to the one of the opposite side by the soft commissure. Along the line of junction of the upper and internal surfaces is a narrow white streak—the *pineal stria* (*f*), which springs behind from the stalk of the pineal body, and ends in front by joining the anterior pillar of the fornix. Optic thalamus;
upper surface,

inner surface,

The under surface is concealed, except at its hindmost part, by the crus cerebri, the tegmentum of which joins the thalamus; and on the outer side it is separated from the lenticular nucleus by the posterior limb of the internal capsule (fig. 66, *icp*). lower and external surfaces,

The anterior end of the optic thalamus bounds the foramen of Monro. The posterior end is much larger, and projects above the anterior and posterior ends;

superior quadrigeminal body (fig. 65, *h*) and crus cerebri, being covered by the pia mater: internally it forms a considerable prominence called the *pulvinar*; and below and outside this is a smaller oval elevation named the *external geniculate body*.

structure. In the section that has been made on the right side (fig. 66), the optic thalamus is seen to be composed of dark grey matter; but it appears white on the upper surface, the grey substance being here covered by a thin medullary layer. A faint white line, which bifurcates in front, divides the grey mass into three portions—a small anterior, and larger internal and external nuclei.

Dissection. *Dissection.* The origin of the fornix in the optic thalamus may now be followed out. As a preparatory step the anterior commissure, the front of the corpus callosum, and the commissure of the optic nerves should be cut along the middle line, so that the fore parts of the hemispheres can be separated from one another. On the left hemisphere the crus of the fornix is to be traced downwards through the grey matter of the third ventricle to the corpus albicans, and thence upwards into the optic thalamus.

Origin of fornix. The *anterior pillar of the fornix* is joined below the foramen of Monro by the fibres of the tænia semicircularis and pineal stria, and then curves downwards and backwards in front of the optic thalamus, through the grey matter of the third ventricle, to the corpus albicans. Here it makes a turn like half of the figure 8, furnishing a white envelope to the grey matter of that body. Finally it ascends to the fore part of the optic thalamus, in the anterior nucleus of which its fibres end.

The bodies lying behind the third ventricle, viz., the corpora quadrigemina, the pineal body, and the posterior commissure may be next examined.

Dissection. *Dissection.* All the pia mater should be carefully removed from the surface of the quadrigeminal bodies, especially on the right side, on which they are to be seen. The posterior part of the hemisphere of the same side may be taken away.

Mid-brain. The constricted portion of the brain between the optic thalami above and the pons and cerebellum below is known as the *isthmus cerebri* or *mesencephalon*, and occupies, when the brain is in the skull, the aperture of the tentorium. The dorsal part of the mesencephalon is formed by a layer which is marked on the surface by four eminences—the *corpora quadrigemina*, and is therefore named the *lamina quadrigemina*. The ventral part of the mid-brain is much larger, constituting the crura cerebri which have already been examined. The lamina quadrigemina is separated from the crura in the middle by a canal—the *aqueduct of Sylvius*; but on each side it is united with the tegmentum.

Lamina quadrigemina. The *corpora quadrigemina* (fig. 65) are four prominent bodies, an upper and a lower pair, which are separated by a crucial groove. The *superior* eminence (nates; *h*) is the larger, and is rather oval in shape. The *inferior* (testis; *i*) is smaller, but more prominent, and rounded; it is also whiter in colour than the upper one. From the outer side of each quadrigeminal body a white band, *brachium*,

Aqueduct of Sylvius.

Quadrigeminal bodies:
superior,
inferior.

Brachia.

is continued outwards and forwards : the upper brachium passes into the optic tract ; while the lower band sinks beneath a small but well defined oval prominence, which is placed between the crus cerebri and the optic thalamus, and is named the *internal geniculate body*. Internal geniculate body.

The quadrigeminal bodies are small masses of grey substance, covered by a white layer. From the grey matter of the upper one fibres of the optic tract take origin.

Behind the quadrigeminal bodies are seen the superior peduncles of the cerebellum (fig. 65, *l* ; 70, *sp*) with the valve of Vieussens (fig. 65, *k*) between them. Issuing from beneath the transverse fibres of pons, and arching over the cerebellar peduncle, is an oblique, slightly raised band named the *fillet* (fig. 70, *f*), which disappears under the lower quadrigeminal body. Below testis the fillet is seen.

The *fillet* is a white fibrous tract, the origin of which is uncertain, but which appears in sections of the upper part of the pons between the reticular formation and the deep transverse fibres. At the upper edge of the pons the outer fibres become superficial, and curving round the superior peduncle of the cerebellum, pass to the quadrigeminal bodies, in which many of the fibres are lost, while others decussate in the lamina quadrigemina, above the aqueduct of Sylvius, with those of the opposite side. The inner fibres of the fillet maintain their deep position, and are continued upwards in the tegmentum to the cerebral hemisphere. Fillet :
outer or superficial part ;
inner or deep part.

The *origin of the optic tract* can now be seen. At the outer side of the crus cerebri the optic tract forms a bend (*genu*), and then divides into two parts. The inner and smaller of these springs from the internal geniculate body ; while the outer is continued from the external geniculate body and optic thalamus, receiving also the brachium of the superior quadrigeminal body. Optic tract arises from nates, geniculate bodies, and thalamus.

The *posterior commissure* (fig. 65, *e*) is the thin foremost part of the lamina quadrigemina, which is folded back so as to present a rounded margin in front towards the third ventricle, above the opening of the aqueduct of Sylvius. On each side it joins the optic thalamus, and to its upper part the stalk of the pineal body is attached. It consists mainly of decussating fibres continuous with those of the fillet ; but some are said to be commissural, uniting the tegmenta of the two sides. Posterior commissure.

The *pineal body* (*conarium* ; fig. 65, *g*) is ovoidal in shape, like the cone of a pine, and about a quarter of an inch in length. It lies with its base turned forwards in the groove between the superior quadrigeminal bodies. It is surrounded by pia mater ; and its base is attached by a hollow white stalk, below to the posterior commissure, and above to the optic thalamus on each side, along which it sends forwards the thin band already described as the pineal stria (*f* ; p. 223). Pineal gland ;

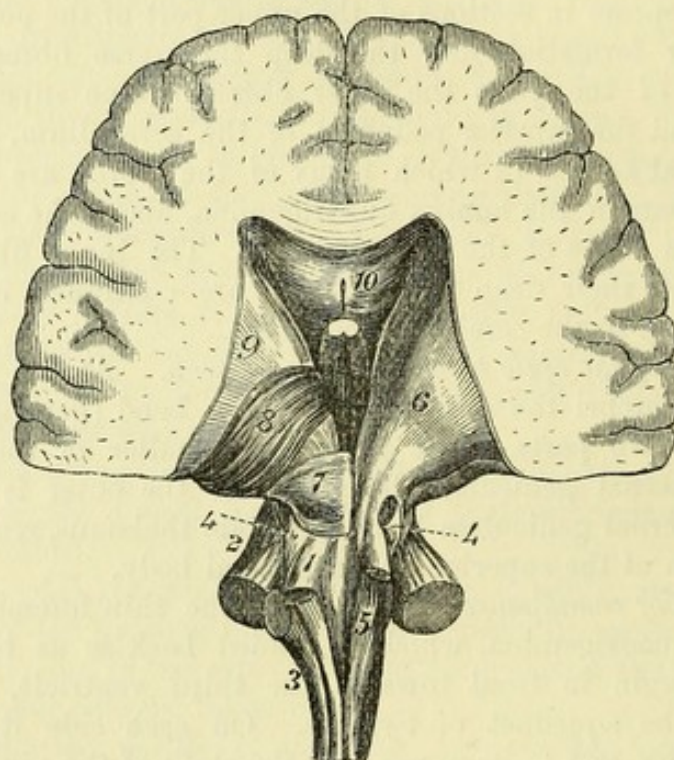
This body is of a red colour and very vascular. It is not composed of nervous substance, but consists of small follicles lined by epithelium, and containing minute granular masses of calcareous matter (brain-sand) : similar concretions are often found on its surface, and adhering to its stalk. structure.

Aqueduct of Sylvius. The *aqueduct of Sylvius* (iter a tertio ad quartum ventriculum) is a narrow passage, about five-eighths of an inch long, uniting the third and fourth ventricles. It is lined by ependyma, external to which is a layer of grey matter continuous with that of the floor of the two cavities.

Three sets of fibres in cerebral hemisphere. **FIBRES OF THE CEREBRUM.** In the cerebral hemispheres three systems of fibres are distinguished, viz., ascending, transverse, and longitudinal. The ascending are derived in large part from the spinal cord and the lower portions of the encephalon; the transverse and longitudinal connect together parts of the cerebrum.

Ascending fibres; *Ascending or peduncular fibres* (fig. 67). The longitudinal fibres entering the mid-brain from the pons are collected into two sets,

Fig. 67.*



which are contained respectively in the crusta and the tegmentum. In this region they are reinforced by the superior peduncles of the cerebellum, and by fibres derived from the corpora quadrigemina, as well as by others springing from the grey nuclei of the crura. The fibres of the crusta enter the internal capsule; and while some (including the pyramidal tract) are continued without interruption through this into the medullary centre of the hemisphere, others pass into the lenticular and caudate nuclei, and fresh fibres are added from those bodies. The longitudinal fibres of the tegmentum for the most part end in the optic thalamus, from the outer side of

* Posterior view of the connections between the cerebrum, medulla oblongata and cerebellum. 1. Superior, 2. Middle, and 3. Inferior peduncle of the cerebellum. 4. Fillet. 5. Funiculus gracilis. 6. Tegmentum passing into the optic thalamus. 7. Lamina quadrigemina. 8. Optic thalamus. 9. Caudate nucleus. 10. Corpus callosum.

which also numerous fibres are given off to the capsule ; but one tract of tegmental fibres, prolonged from the fillet, passes beneath the thalamus into the hinder part of the internal capsule, some of the outer ones inclining to the side and traversing the inner part of the lenticular nucleus as they course upwards.

Dissection. A complete systematic view of the ascending fibres cannot now be obtained on the imperfect brain. At this stage the chief purpose is to show the passage of the radiating fibres from the crus through the large cerebral ganglia. Dissection of them

To trace the ascending fibres through the corpus striatum, the caudate nucleus of this body should be scraped away (fig. 67) ; and the dissection should be made on the left side, on which the striate body and the optic thalamus remain uncut. In this proceeding the internal capsule comes into view, consisting of white fibres with intervening gray matter of the corpus striatum, giving the appearance of the teeth of a comb (pecten of Reil). in the corpus striatum.

On taking away completely the hinder part of the caudate nucleus, others of the same set of fibres will be seen issuing from the outer side of the optic thalamus, and radiating to the posterior and inferior portions of the hemisphere.

Arrangement of the ascending fibres. The fibres of the internal capsule diverge as they pass through the grey matter of the corpus striatum, and at the outer margin of that body they enter the medullary centre of the hemisphere, where they decussate with the transverse fibres of the corpus callosum, and radiate to all parts of the hemisphere. The ascending fibres thus form in the hemisphere a part of a hollow cone, named the *corona radiata*, the apex of which is towards the crus cerebri, and the concavity turned downwards. The base of the cone is at the surface of the hemisphere, where the fibres pass into the grey cortex of the convolutions. From the foregoing description it will be evident that the fibres constituting the corona radiata are of two kinds, viz., those extending without interruption from the cortex to the isthmus cerebri, and those uniting the cortex with the corpus striatum and optic thalamus. Ascending fibres spread out in hemisphere, forming corona radiata.

The *transverse* or *commissural fibres* connect the hemispheres of the cerebrum across the median plane. They give rise to the great commissure or the corpus callosum (p. 212), and to the anterior commissure (p. 223). These bodies have already been examined. Transverse fibres.

Longitudinal or *collateral fibres.* These are connecting fibres which pass from before backwards, uniting together parts of the same hemisphere. The chief bands of this system are the following :—The fornix, the tænia semicircularis, the pineal stria, the longitudinal stria of the corpus callosum, and the covered band of Reil. Other fibres pass in the medullary centre between adjoining, and more distant convolutions, describing arches beneath the sulci : these are known as the *association-fibres*. Longitudinal fibres.

The dissector may now make a transverse section of the remains of the left hemisphere at the fore part of the optic thalamus, when the form and relations of the lenticular nucleus and the claustrum, Make sections of lenticular nucleus,

together with the position of the anterior commissure will be apparent.

geniculate
bodies,

Cuts may also be made into the geniculate bodies to show the grey nuclei within them.

and mesen-
cephalon.

Finally, by dividing transversely the left half of the mid-brain through the superior quadrigeminal body, there will be seen the grey matter of that eminence, the crusta and tegmentum separated by the substantia nigra, the red nucleus of the tegmentum, and the grey matter of the Sylvian aqueduct.

SECTION V.

THE CEREBELLUM.

Prepare
cerebellum.

Dissection. The cerebellum (fig. 59, *b*) is to be separated from the remains of the cerebrum by carrying the knife through the optic thalamus, so that the small brain, the corpora quadrigemina, the crura cerebri, the pons, and the medulla oblongata may remain united together.

Parts to be
separated
from one
another.

Any remaining pia mater is to be carefully removed from the median groove on the under surface; and the different bodies in that hollow are to be separated from one another. Lastly, the handle of the scalpel should be passed along a deep sulcus at the circumference, which is continued from the crus, between the upper and under surfaces.

Form and

The CEREBELLUM or small brain (fig. 68) is oval in shape, and flattened from above down. Its longest diameter, which is directed transversely, measures about four inches. This part of the encephalon is situate in the posterior fossa of the base of the skull, beneath the tentorium cerebelli. Like the cerebrum, it is incompletely divided into two hemispheres; the division being marked by a wide median groove along the under surface, and by a notch at the posterior border into which the falx cerebelli projects. The narrower part uniting the two hemispheres is known as the *worm* (vermis).

No groove
on the upper
surface;

UPPER SURFACE. On the upper aspect the cerebellum is raised in the centre, and sloped towards the sides. There is not any median sulcus on this surface; and the hemispheres are united by a central constricted part—the *superior vermiform process*. Separating the upper from the under surface, at the circumference, is the *horizontal fissure*, which extends from the crus cerebelli in front to the median notch behind.

halves
joined by
upper worm.

Horizontal
fissure.

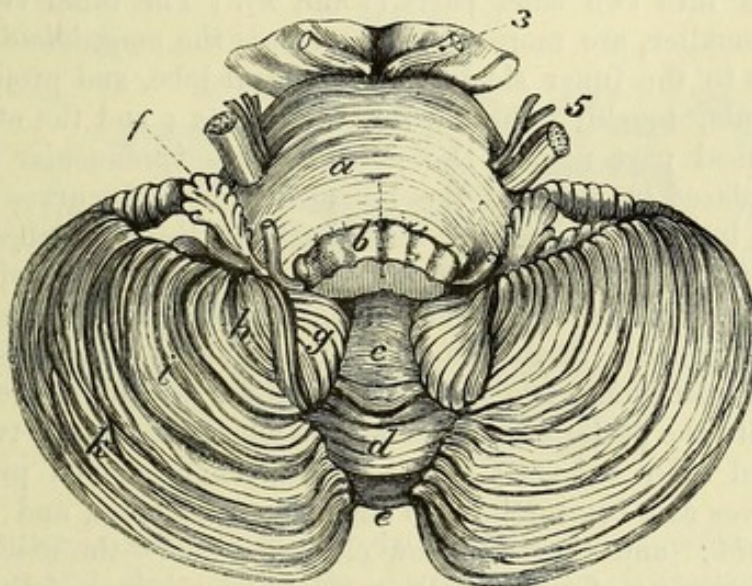
A hollow
below,
which is
called
valley,

The UNDER SURFACE of the cerebellum is convex on each side, where it is received into the lower fossæ of the occipital bone; and the hemispheres are separated by a median hollow—*vallecula* (fig. 68), which is widest in front where it lodges the upper end of the medulla oblongata: the hinder end of the vallecula is continued into the notch at the posterior border, and receives the falx

cerebelli. At the bottom of the groove is an elongated mass named the *inferior vermiform process* (*c* to *e*), which corresponds to the central part uniting the hemispheres above. The two vermiform processes constitute the general commissure of the halves of the cerebellum. and contains lower worm.

LAMINÆ AND SULCI. The superficial part of the cerebellum is composed of grey substance, and is marked by concentric laminæ or folia, which have their free edges towards the surface, and run in a curved direction with the concavity turned forwards. The laminæ are separated by sulci, which are lined by pia mater, and are of variable depth. Only a small number of the laminæ appear on the surface, for many others are placed on the sides of the larger processes, and are concealed within the deeper sulci. The laminæ, Surface foliated.
Between folia are sulci.
Many folia are hidden.

Fig. 68.*



especially the smaller ones, are frequently interrupted by the junction of neighbouring sulci. On the upper aspect many of the laminæ pass continuously from one hemisphere to the other, with only a slight bending forwards in the superior vermiform process; but those of the under surface of the two hemispheres are connected by means of the special commissural bodies composing the inferior vermiform process. The deepest sulci of the hemisphere divide the laminæ into groups which are known as the lobes of the cerebellum. Arrangement in worm.

LOBES OF THE UPPER SURFACE. On the upper surface the hemisphere is divided into two lobes by a deep sulcus which arches outwards and forwards from the hinder end of the superior anterior, Upper lobes are

* Under surface of the cerebellum, the medulla oblongata being cut away in greater part. *a*. Pons Varolii. *b*. Medulla oblongata, cut through. *c* to *e*. Inferior vermiform process, consisting of—*c*. Uvula. *d*. Pyramid. *e*. Tuber valvulæ.

Lobes of the under surface. *f*. Flocculus. *g*. Amygdaloid. *h*, *i*. Biventral. Between *i* and *k*. Slender. *k*. Posterior.

3. Third nerve attached to the crus cerebri. 5. Fifth nerve.

- vermiform process. The *anterior* or *quadrate lobe* is the larger, and its laminae pass without interruption through the vermiform process into the corresponding lobe of the opposite hemisphere. The *posterior lobe* is semilunar in shape, and is connected internally with the one of the opposite side by a single lamina (*folium cacuminis*), which is deeply placed at the bottom of the median notch.
- posterior, and central. Belonging to this surface there is also at the front of the vermiform process a small part, comprising about eight laminae, which overlaps the superior peduncles, and is known as the *central lobe* (fig. 65).
- Lower lobes are posterior, slender, biventral, amygdaloid, and flocculus. The LOBES OF THE UNDER SURFACE of the hemisphere (fig. 68) are five in number. Beginning behind, there is first the *posterior lobe* (*k*), of a semilunar form, like that of the upper surface, from which it is separated by the great horizontal fissure; next comes the *slender lobe* (between *k* and *i*), composed of three or four parallel laminae; and then the larger *biventral lobe*, triangular in shape, and subdivided into two chief parts (*i* and *h*). The other two lobes, although smaller, are more distinct; one is the *amygdaloid lobe* (*g*), which lies to the inner side of the biventral lobe, and projects into the vallecule, touching the medulla oblongata; and the other is a small conical part named the *flocculus* or *subpeduncular lobe* (*f*), which is placed in front of the biventral lobe and curves upwards round the lower border of the crus cerebelli, being attached to the general mass of the small brain only by a narrow white stalk.
- Lower worm includes tuber valvulae, pyramid, uvula, nodule, furrowed band, and inferior medullary velum. PARTS OF THE INFERIOR VERMIFORM PROCESS. On the inferior vermiform process there are seen, from behind forwards—first a small eminence, comprising seven or eight narrow transverse laminae which unite the posterior inferior and slender lobes of the two sides, and named *tuber valvulae*; next a larger, tongue-shaped projection, which serves as a commissure to the biventral lobes, and is called the *pyramid*; and then a narrow elongated part—the *uvula*, at the anterior extremity of which is the rounded prominence of the *nodule*. The uvula is connected to the amygdaloid lobe on each side by a grey strip named the *furrowed band*, and the nodule to the flocculus by a thin white lamina—the *inferior medullary velum*, but to see these parts the following dissection must be made.
- Dissection. The biventral and slender lobes are to be sliced off on the left side, so that the amygdaloid lobe may be everted from the valley (fig. 69). By this proceeding the stalk of the flocculus is exposed, and is seen to be continued into the thin and soft white layer of the inferior medullary velum (*b*), which joins the nodule internally: beneath the velum a bit of paper may be inserted. The furrowed band (*d*) is also exposed on the side of the uvula.
- Inferior medullary velum. The *inferior medullary velum* is a thin white layer which forms a commissure to the flocculi, and is connected to the upper surface of the nodule in the middle. Its exposed part on each side, between the flocculus and the nodule, is semilunar in shape, and the anterior edge is free; but behind, it is continued into the medullary centre of the cerebellum.
- Furrowed band. The *furrowed band* (*d*) is a narrow ridge of grey matter, notched on the surface, which passes from the side of the uvula to the con-

stricted base of the amygdaloid lobe. It lies along the attached posterior margin of the inferior medullary velum.

STRUCTURE OF THE CEREBELLUM. The interior of the cerebellum consists of a large white mass—the *medullary centre*, from which offsets proceed to the laminæ and to other parts of the encephalon. The medullary centre is surrounded, except in front, where the processes to other parts of the brain (peduncles of the cerebellum) issue from it, by a superficial layer of grey substance—the *cortex of the cerebellum*; and other small masses of grey matter are embedded in it.

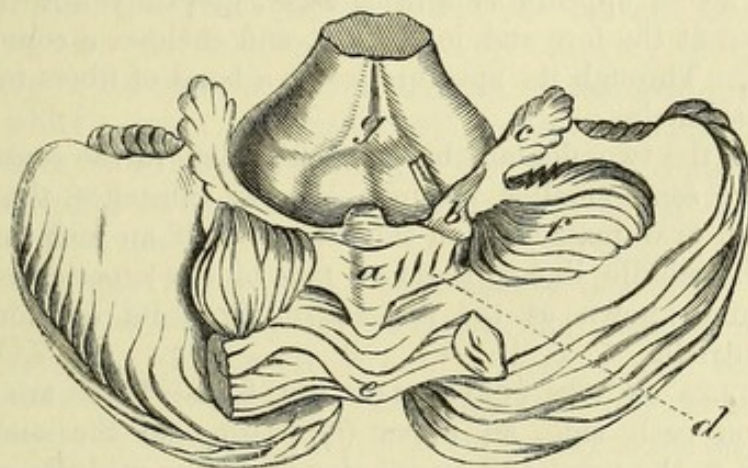
Cerebellum consists of a white medullary centre

and grey cortex.

Structure of the laminæ. The laminæ are seen in the section that has been made of the under part of the left hemisphere to consist of a grey external portion enveloping a white centre (fig. 65). The

Laminæ are grey externally, and white within.

Fig. 69.*



grey matter is subdivided into two layers, the superficial of which is lighter and clear, while the deeper stratum is darker and of a rust-colour. The white part is derived from the medullary centre, which sends off numerous processes to the lobes and the bodies composing the worm, and these, dividing like the branches of a tree, end in small offsets which enter the several laminæ.

Dissection. For the purpose of seeing the medullary centre, with its contained corpus dentatum, remove all the laminæ from the upper surface on the left side. This dissection may be accomplished by placing the scalpel in the horizontal fissure at the circumference, and carrying it inwards as far as the upper vermiform process, so as to detach the anterior and posterior lobes of the upper aspect. If the corpus dentatum does not at first appear, thin slices may be made anteriorly till it is reached.

Dissection.

The *medullary centre* of the cerebellum forms a large oval mass in each hemisphere, but is flattened and narrow in the middle between

White centre

* View from behind of the under surface of the cerebellum, with some of the lobes removed to show the inferior medullary velum. *a.* Uvula. *b.* Inferior medullary velum with a bit of whale-bone under it. *c.* Flocculus. *d.* Furrowed band. *e.* Pyramid. *f.* Amygdaloid lobe, turned aside. *g.* Medulla oblongata raised, showing posterior surface.

the vermiform processes (fig. 65). The lateral part contains the grey corpus dentatum, and is continued in front into a large stalk-like process, which becomes divided into the three peduncles. From its surface, as already stated, offsets are furnished to the different lobes and laminæ. The white centre is composed mainly of the fibres of the peduncles radiating to the cortical grey matter; but there are in addition, as in the cerebrum, *commissural fibres* between the two hemispheres, which are most developed at the fore part of the superior vermiform process, and at the back close to the median notch, as well as a system of *association-fibres* uniting the laminæ beneath the sulci.

consists of
radiating,

commis-
sural,

and
collateral
fibres.

Dentate
body:
situation,

and
structure.

Other grey
masses.

The *corpus dentatum* is situate in the inner part of the white mass of the hemisphere, and resembles the nucleus in the olivary body of the medulla oblongata. It measures about three-quarters of an inch from before back, and consists of a plicated capsule, which when cut across appears as a thin, wavy, greyish-yellow line: the bag is open at the fore and inner part, and encloses a core of white substance. Through its aperture issues a band of fibres to join the superior peduncle.

Between the two dentate bodies, embedded in the central white matter, are some smaller portions of grey substance, the chief of which is an oval mass on each side, nearly half an inch long, lying close to the middle line in the fore part of the superior vermiform process, and known as the *roof-nucleus* from its relation to the fourth ventricle.

PEDUNCLES OF THE CEREBELLUM (fig. 67). These are three in number on each side, an upper ⁽¹⁾ passing to the cerebrum, a middle ⁽²⁾ to the pons, and an inferior ⁽³⁾ to the medulla oblongata.

Superior
peduncle:

origin,

and
destination.

The *superior peduncle* (processus ad cerebrum; fig. 65, *l*) is directed forwards, and disappears beneath the corpora quadrigemina. It is rather flattened in shape, and forms part of the roof of the fourth ventricle. The processes of the two sides are united by the valve of Vieussens (*k*). Its fibres are derived mainly from the interior of the dentate body, but a few are added from the white centre of the hemisphere and the worm. Beneath the corpora quadrigemina the superior peduncle enters the tegmentum of the crus cerebri, and crosses the middle line decussating with the one of the opposite side. The fibres are then connected with the red nucleus (p. 202), and are continued with the longitudinal tegmental fibres to the optic thalamus.

Valve of
Vieussens,

covered by
lingula.

Middle
peduncle.

The *valve of Vieussens*, or *superior medullary velum*, is a thin translucent white layer which enters into the roof of the upper part of the fourth ventricle (fig. 65, *k*). It is narrow in front, but widens behind, where it is continued into the medullary centre of the worm. On each side it joins the superior peduncle. Near the lamina quadrigemina the fourth nerve is attached to the valve; and its upper surface is covered by four or five small transverse grey ridges, constituting the *lingula* (fig. 70).

The *middle peduncle* (processus ad pontem; fig. 70, *mp*), commonly named the *crus cerebelli*, is the largest of the three processes. Its

fibres begin in the lateral part of the hemisphere, and are directed forwards to the pons, of which they form the transverse fibres (p. 199).

The *inferior peduncle* (processus ad medullam; fig. 70, *ip*) passes downwards to the medulla oblongata, where it is known as the restiform body. Its fibres begin chiefly in the laminae of the upper surface of the hemisphere. It will be better seen when the fourth ventricle has been opened. Inferior peduncle to medulla.

Dissection. One other section (fig. 65) must be made to expose the fourth ventricle. The cerebellum still resting on its under surface, let the knife be carried vertically through the centre of the vermiform processes; and then the structure of the worm, as well as the boundaries of the fourth ventricle, may be observed on separating the halves of the cerebellum. Dissection.

Structure of the worm (fig. 65). The upper and lower vermiform processes of the cerebellum are united in one central piece which connects together the hemispheres. The structure of this connecting piece is the same as that of the rest of the cerebellum, viz., a central white portion and investing laminae. Here the branching appearance of a tree (*arbor vitae*) is best seen, in consequence of the laminae being more divided, and the white central stalk being thinner and more ramified. Vermiform process is like other parts.

The **FOURTH VENTRICLE** (*fossa rhomboidalis*) is a space between the cerebellum and the posterior surface of the medulla oblongata and pons (fig. 65). It has the form of a lozenge, with the points placed upwards and downwards. The upper angle reaches as high as the upper border of the pons; and the lower, nearly to the level of the lower end of the olivary body. Its greatest breadth is opposite the lower edge of the pons; and a transverse line in this situation would divide the hollow into two triangular portions—upper and lower. The lower half has been named *calamus scriptorius* from its resemblance to a writing pen. Fourth ventricle : form and extent, breadth : calamus scriptorius.

The *lateral boundaries* are more marked above than below. For about half way down the cavity is limited on each side by the superior peduncle of the cerebellum (*l*), which, projecting over it, forms part of the roof; and along the lower half lies the eminence of the restiform body, with the clava of the funiculus gracilis (fig. 70, *cl*) at the inferior extremity. At the lower border of the middle peduncle of the cerebellum a lateral process of the cavity extends outwards over the surface of the restiform body, being bounded below by a narrow white streak called the *ligula* (fig. 70, on right side). Boundaries on side : lateral recess.

The *roof* of the space is formed above by the valve of Vieussens with the superior peduncles of the cerebellum, and by the inferior medullary velum and nodule of the inferior vermiform process; below by the reflection of the pia mater from that process to the medulla oblongata. Between the valve of Vieussens and the inferior medullary velum the ventricle forms an angular recess, the apex of which is directed towards the medullary centre of the worm. Roof.

Floor : The *floor of the ventricle* (fig. 70) is constituted by the posterior surface of the medulla oblongata and pons, and is greyish in colour. Along the centre is a median groove, which ends below, near the point of the calamus, in a minute hole—the aperture of the canal of the cord. On each side of the groove is a spindle-shaped elevation, the *fasciculus s. eminentia teres* (*ft*). This eminence reaches the whole length of the floor, and is pointed and well defined below, but less distinct above. Its widest part is opposite the centre of the ventricle.

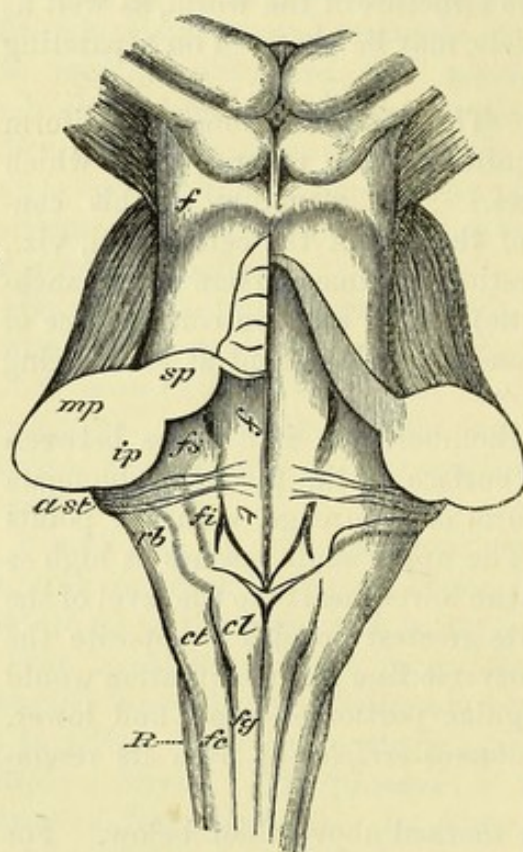
auditory striæ, Crossing the floor on each side, at the lower border of the pons, are some white lines—the *auditory striæ* (*a st*), which vary much in their arrangement: they issue from the median groove, and pass outwards to the auditory nerve (p. 190).

Fig. 70.*

superior and

inferior fovea,

ala cinerea,



The fasciculus teres is limited externally by two small depressions—the *superior* and *inferior foveæ*, separated by the auditory striæ. The *superior* (*fs*) is the broader, and is connected to the lower one by a faint groove. The *inferior fovea* (*fi*) is well marked, and has the form of the letter V inverted. The triangular portion between the two branches is of a darker colour than the surface on each side, and is named the *ala cinerea* (fig. 71, *ac*): it corresponds to the nucleus of the vagus nerve. On the outer side of the fovea the surface is elevated over the principal nucleus of the

auditory tubercle, auditory nerve, forming the *auditory tubercle* (*at*), which is crossed by the auditory striæ.

nucleus of sixth nerve, In the upper half of the floor of the ventricle there may be seen, on the inner side of the superior fovea, a rounded elevation of the fasciculus teres, produced by the nucleus of the sixth nerve, with the deep part of the facial arching round it (p. 189). And lastly, above the superior fovea is a narrow, slightly depressed area of a bluish colour (*locus cæruleus*), caused by a deposit of very dark grey substance (*substantia ferruginea*) beneath the thin surface-layer.

and locus cæruleus.

* Back of medulla oblongata and pons, showing the floor of the fourth ventricle. *f*. Fillet. *sp*. Superior, *mp*. Middle, and *ip*. Inferior peduncle of the cerebellum: attached to the superior peduncle on the left side is the half of the superior medullary velum, covered by the lingula. *ft*. Fasciculus teres. *fs*. Superior fovea. *fi*. Inferior fovea. *a st*. Auditory striæ. *rb*. Restiform body. *cl*. Clava. Crossing the restiform body of the right side, below the auditory striæ, is the lingula.

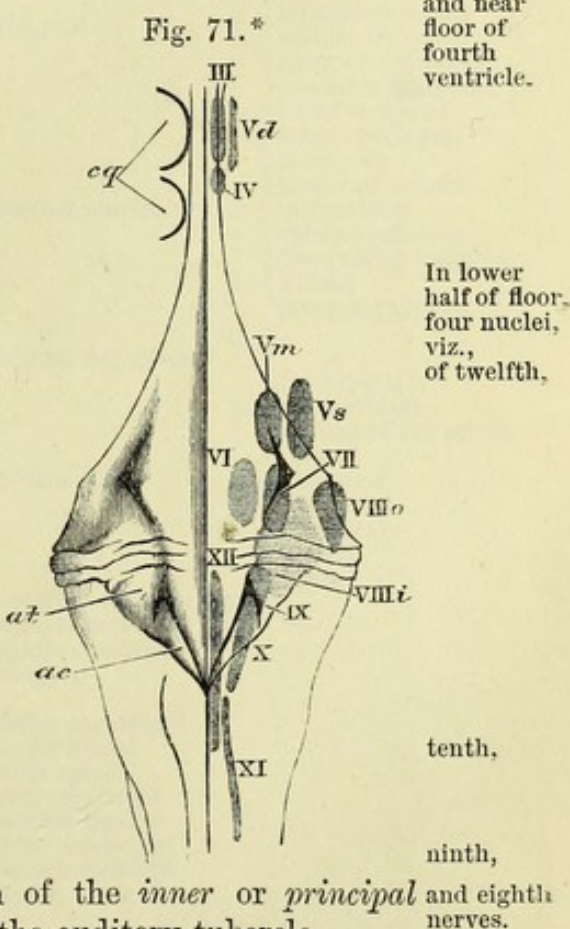
The fourth ventricle communicates above with the third ventricle through the aqueduct of Sylvius, and with the subarachnoid space through an aperture in the pia mater between the cerebellum and medulla oblongata. Below, it opens into the central canal of the cord. It is lined by ependyma, the epithelium of which is continued over the pia mater in the roof, and prolonged upwards and downwards into the canals leading from the ventricle.

Projecting into the lower half of the ventricle is a vascular fold on each side—*choroid plexus*, similar to the body of the same name in the lateral and third ventricles. It is attached to the inner surface of the pia mater which closes the ventricle between the medulla and the cerebellum, and extends from the point of the calamus scriptorius to the extremity of the lateral recess of the cavity. It receives branches from the inferior cerebellar artery.

The floor of the fourth ventricle is covered by a layer of grey matter, which is continuous below with the grey commissure of the cord, and above with the grey substance of the aqueduct.

NUCLEI OF CRANIAL NERVES (fig. 71). In the dorsal portion of the medulla oblongata and pons are situate the collections of nerve-cells from which many of the cranial nerves take their origin. Some of these appear in the floor of the fourth ventricle, while others are placed a little below the surface.

Beneath the calamus scriptorius, and in the portion of the floor of the cavity formed by the medulla oblongata, are the nuclei of the twelfth, tenth, ninth and eighth nerves. The *hypoglossal nucleus* (XII) extends through nearly the whole length of the medulla oblongata; its lower part is hidden, lying in front of the central canal below the level of the fourth ventricle, but its upper half approaches the surface in the lower portion of the fasciculus teres. The *nucleus of the vagus* (X) corresponds to the ala cinerea, and is continued above into the *glossopharyngeal nucleus* (IX) which lies beneath the inferior fovea. The position of the *inner or principal auditory nucleus* (VIIIi) is indicated by the auditory tubercle.



* Diagram showing the position of the nerve-nuclei near the floor of the fourth ventricle. The Roman numbers indicate the nuclei of the corresponding nerves. Vd. Nucleus of the descending root, Vm. Motor nucleus, and Vs. Sensory nucleus of the fifth nerve. VIIIo. Outer, and VIIIi. Inner auditory nucleus. XI. Upper part of the spinal accessory nucleus. On the left side: cq. Position of the corpora quadrigemina. at. Auditory tubercle. ac. Ala cinerea.

Beneath upper half are five nuclei, viz., of sixth, seventh, two of fifth, In the hinder part of the pons, and beneath the upper half of the floor of the ventricle, are nuclei of the fifth (two), sixth, seventh and eighth nerves, but only that of the sixth is indicated by a superficial prominence. The *nucleus of the sixth* (VI) lies beneath the elevation of the fasciculus teres above the auditory striæ. The *facial nucleus* (VII) is placed external to and deeper than the last; and the *motor nucleus of the fifth nerve* (Vm) is above that of the facial. The *sensory nucleus of the fifth* (Vs) lies external to the foregoing, and just beyond the lateral margin of the ventricle.

and outer of eighth. The *outer auditory nucleus* (VIIIo) is situate at the lateral angle of the ventricle, close above the auditory striæ.

In mid-brain three nuclei, viz., of third, fourth, and fifth nerves. Above the fourth ventricle, in the grey matter surrounding the aqueduct of Sylvius, are the *nuclei of the fourth* (IV) and *third* (III) nerves in the floor, and the *nucleus of the descending root of the fifth* (Vd) on the side of the canal.

TABLE OF THE CRANIAL NERVES.

1. First nerve . . . Filaments to the nose.
2. Second nerve . . . To retina of the eyeball.
3. Third nerve . . . To muscles of the orbit.
4. Fourth nerve . . . To superior oblique muscle.

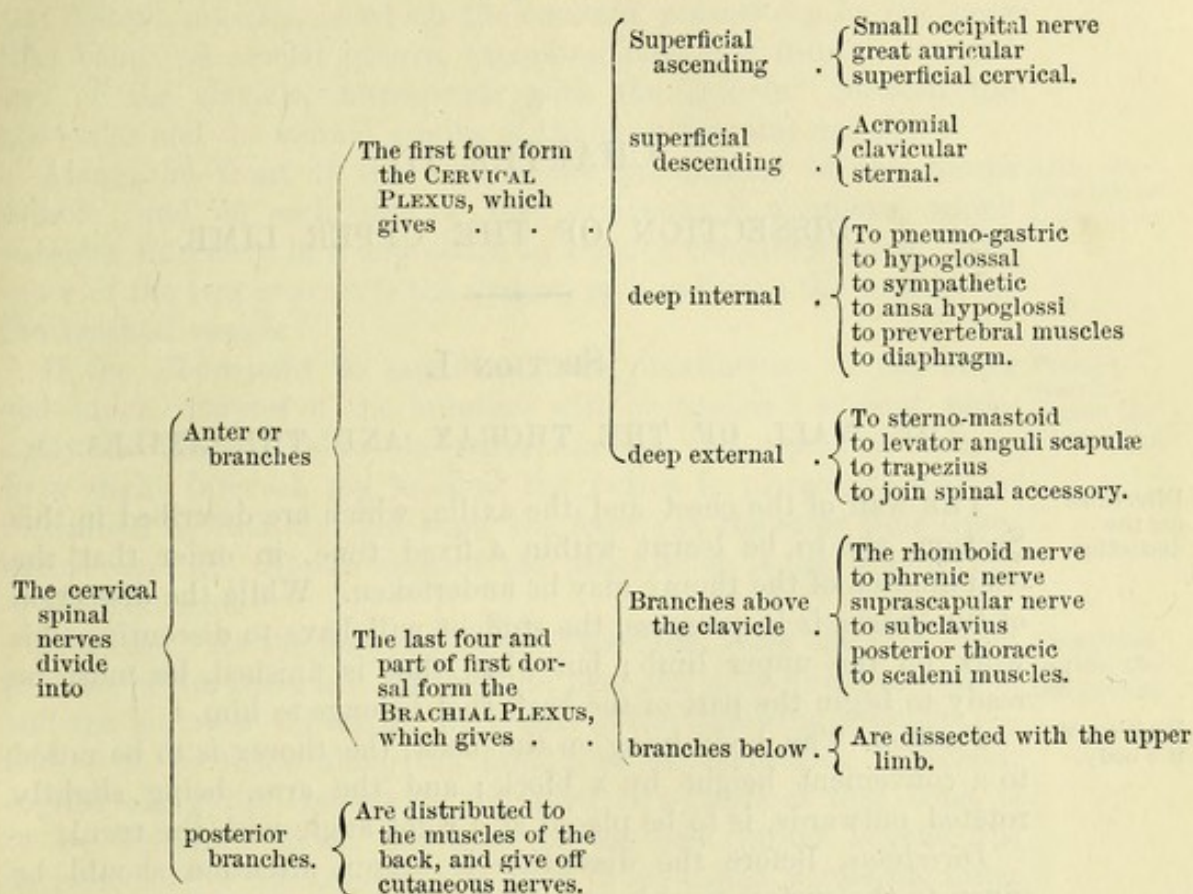
5. Fifth or trifacial nerve . .	Ophthalmic . .	Recurrent	{	lachrymal . . .	{	Lachrymal palpebral.	
		frontal . . .		{		Supraorbital supratrochlear.	
		nasal . . .				{	To lenticular ganglion long ciliary nerves infratrochlear nasal.
	ophthalmic or lenticular ganglion . .	Connecting branches	{	to nasal nerve to third nerve to sympathetic.			
	short ciliary nerves.						
	superior maxil- lary . . .	Orbital branch . .	{	Malar temporal.			
		spheno-palatine					
		posterior dental					
		middle dental					
	Meckel's gang- lion . . .	anterior dental					
		infraorbital.					
		Internal branches .	{	Nasal naso-palatine.			
		ascending . . .		To the orbit.			
		descending . . .	{	Large palatine small palatine external palatine.			
	posterior . . .	Vidian . . .		{	To facial nerve to sympathetic		
inferior maxil- lary . . .	Small part . . .	{	Deep temporal masseteric buccal pterygoid.				
			Auriculo-temporal .	{	Articular to meatus parotid auricular temporal.		
	large part . . .	{	lingual . . .	{	To submaxillary ganglion to hypoglossal to the tongue.		
	nerve to internal pterygoid.	{	inferior dental .	{	Mylo-hyoid dental mental incisor.		
	otic ganglion .	Connecting branches	{	To trunk of inferior maxillary to Jacobson's nerve to auriculo-temporal to sympathetic.			
		branches for muscles		{	To tensor palati. to tensor tympani.		
submaxillary ganglion .	Connecting branches	{	To the lingual, chorda tympani, and sympathetic.				
	branches to glands and mucous mem- brane of mouth.						

TABLE OF THE CRANIAL NERVES—*continued*.

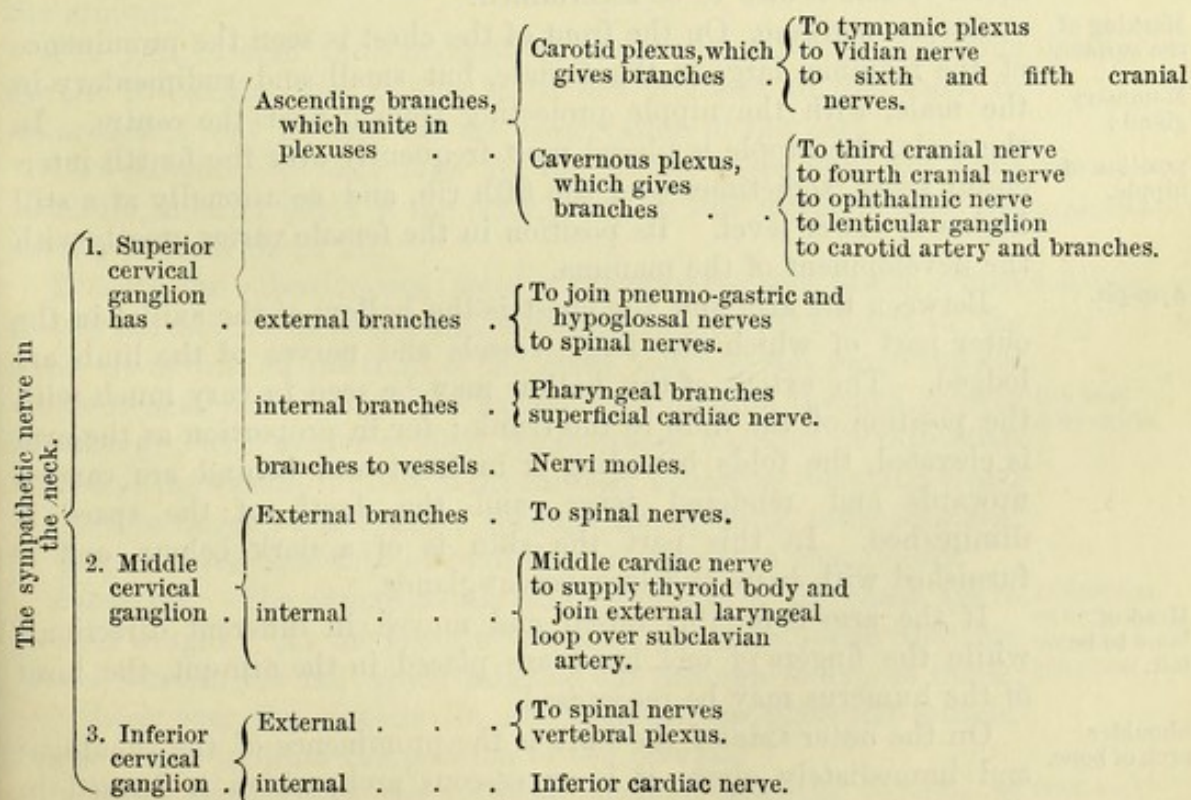
6. Sixth nerve	To external rectus.		
7. Seventh nerve, or facial	<div> <div>Connecting branches</div> <div>branches for distribution</div> </div>	<div> <div>To join auditory to Meckel's ganglion to tympanic, and sympathetic nerves (chorda tympani).</div> <div> <div>Posterior auricular digastric branch stylo-hyoid branch</div> <div>temporo-facial</div> <div>cervico-facial</div> </div> </div>	<div> <div>Temporal malar infraorbital.</div> <div>Buccal supramaxillary inframaxillary.</div> </div>
8. Eighth nerve, or auditory	<div> <div>To the facial</div> <div>upper part</div> <div>lower part</div> </div>	<div> <div>To the common sac to the superior and external semicircular canals.</div> <div>To the cochlea to the saccule to the posterior semicircular canal.</div> </div>	
9. Ninth nerve, or glosso-pharyngeal	<div> <div>Connecting branches</div> <div>branches for distribution</div> </div>	<div> <div>To vagus to sympathetic</div> <div>Jacobson's nerve</div> <div>To the pharynx tonsillitic branches to stylo-pharyngeus lingual.</div> </div>	<div> <div>To sympathetic and otic ganglion, supplies tympanum.</div> </div>
10. Tenth nerve, or pneumo-gastric	<div> <div>Connecting branches</div> <div>branches for distribution</div> </div>	<div> <div>To glosso-pharyngeal to sympathetic auricular nerve to hypoglossal and cervical nerves.</div> <div>Pharyngeal</div> <div>superior laryngeal</div> <div>cardiac nerves.</div> <div>inferior laryngeal</div> </div>	<div> <div>External laryngeal ascending to the mucous membrane to join inferior laryngeal.</div> <div>Cardiac œsophageal, tracheal to inferior constrictor and muscles of larynx to join superior laryngeal.</div> </div>
11. Eleventh nerve, or spinal accessory	<div> <div>Connecting branches</div> <div>branches for distribution</div> </div>	<div> <div>To pneumo-gastric to the cervical plexus.</div> <div>To sterno-mastoid and trapezius.</div> </div>	
12. Twelfth nerve or hypoglossal	<div> <div>Connecting branches</div> <div>branches for distribution</div> </div>	<div> <div>To pneumo-gastric nerve to sympathetic to loop of atlas to lingual of fifth.</div> <div>Descending branch thyro-hyoid nerve to genio-hyoid to lingual muscles</div> </div>	

TABLE OF THE SPINAL AND SYMPATHETIC NERVES OF THE HEAD AND NECK.

Spinal Nerves.



Sympathetic Nerve.



CHAPTER III.

DISSECTION OF THE UPPER LIMB.

SECTION I.

THE WALL OF THE THORAX AND THE AXILLA.

Directions
for the
dissection.

THE wall of the chest and the axilla, which are described in this Section, are to be learnt within a fixed time, in order that the examination of the thorax may be undertaken. While the dissection of the thorax is in progress, the student will have to discontinue his work on the upper limb; but when that is finished, he must be ready to begin the part of the back that belongs to him.

Position of
the body.

Position. The body lying on the back, the thorax is to be raised to a convenient height by a block; and the arm, being slightly rotated outwards, is to be placed at a right angle with the trunk.

Directions. Before the dissection is begun, attention should be given to the surface-marking; and the prominences and depressions formed by the muscles, together with the parts of the bones that are to be recognised, should be noticed. The position of the chief blood-vessels is also to be ascertained.

Marking of
the surface.

Surface-marking. On the front of the chest is seen the prominence of the mamma, large in the female, but small and rudimentary in the male, with the nipple projecting from it near the centre. In the male, the nipple is placed most frequently over the fourth intercostal space, sometimes over the fifth rib, and occasionally at a still higher or lower level. Its position in the female varies greatly with the development of the mamma.

Mammary
gland :

position of
nipple.

Arm-pit.

Between the arm and the chest is the hollow of the axilla, in the outer part of which the large vessels and nerves of the limb are lodged. The extent of this hollow may be seen to vary much with the position of the limb to the trunk; for in proportion as the arm is elevated, the folds bounding it in front and behind are carried upwards and rendered tense, and the depth of the space is diminished. In this part the skin is of a dark colour, and is furnished with hairs and large sweat-glands.

Head of
bone to be
felt.

If the arm is forcibly raised and moved in different directions, while the fingers of one hand are placed in the arm-pit, the head of the humerus may be recognised.

Shoulder
arch of bone.

On the outer side of the limb is the prominence of the shoulder; and immediately above it is an osseous arch, which is formed in

front by the clavicle, behind and externally by the spine and the acromion process of the scapula. Continued downwards from about the middle of the clavicle is a slight depression between the pectoral and deltoid muscles, in which the coracoid process can be felt near that bone. A second groove, extending outwards from the sternal end of the clavicle, corresponds with the interval between the clavicular and the sternal origins of the great pectoral muscle.

Intermuscular depressions.

Along the front of the arm is the prominence of the biceps muscle; and on each side of that eminence is a groove, which subsides inferiorly in a depression in front of the elbow-joint. The inner of the two grooves is the deeper, and indicates the position of the brachial vessels.

Arm: its prominence and grooves.

If the elbow-joint be semiflexed, the prominences of the outer and inner condyles of the humerus will be rendered evident, especially the inner. Below the outer condyle, and separated from it by a slight interval, the head of the radius is placed; it may be recognised by rotating that bone, the fingers at the same time being placed over it. At the back of the articulation is the prominence of the olecranon.

Prominences around the elbow-joint.

Dissection. As the first step in the dissection, raise the skin from the side of the chest and the arm-pit, over the great pectoral muscle and the hollow of the axilla, by means of the following incisions:—One is to be made along the middle of the sternum. A second, carried along the clavicle for the inner two-thirds of that bone, is to be continued down the front of the arm rather beyond the anterior fold of the arm-pit, and then to be turned across the inner surface of the arm as far as the hinder fold of the axilla. From the ensiform process a third cut is to be directed outwards over the side of the chest, as far back as to a level with the posterior fold of the arm-pit.

Dissection to raise the integument.

The flap of skin thus marked out is to be reflected outwards beyond the axilla; but it should be left attached to the body, in order that it may be used for the preservation of the part.

Reflect skin.

The *subcutaneous fatty layer* of the thorax resembles the same structure in other parts of the body; but in this region it does not usually contain much fat.

Fasciæ: superficial;

Beneath the subcutaneous layer is the stronger *deep fascia*, which closely invests the muscles, and is continuous with the fascia of the arm. It is thin on the front of the chest, but becomes much thicker where it is stretched across the axilla. An incision through it, over the arm-pit, will render evident its increased strength in this situation, and the casing it gives to the muscles bounding the axilla; and if the fore finger be introduced through the opening, some idea will be gained of its capability of confining an abscess in that hollow.

and deep,

thickest over axilla.

Dissection. The cutaneous nerves of the side of the chest are to be next sought. At the spots where they are to be found they are placed beneath the fat, which must be cut through to expose them; and those over the clavicle lie also beneath the platysma muscle. Small vessels indicate the position of the nerves.

Dissection of cutaneous nerves of the chest:

Some of them (from the cervical plexus) cross the clavicle at

from cervical plexus

the middle, and the inner end. Others (anterior cutaneous of the thorax) appear at the side of the sternum,—one from each intercostal space. And the rest (lateral cutaneous of the thorax) should be looked for along the side of the chest, about an inch behind the anterior fold of the axilla, there being one from each intercostal space except the first: as the last-mentioned nerves pierce the wall of the thorax, they divide into an anterior and a posterior branch.

The posterior branches of the highest two nerves are larger than the rest. They are to be followed across the arm-pit, and a junction is to be found there with a branch (nerve of Wrisberg) of the brachial plexus.

CUTANEOUS NERVES OF THE CERVICAL PLEXUS. These cross the clavicle and are distributed to the skin over the pectoral muscle. The most internal branch (sternal) lies near the inner end of the bone, and reaches but a short distance below it. Other branches (clavicular), two or more in number and larger, cross the middle of the clavicle, and extend to near the lower border of the pectoralis major; they join one or more of the anterior cutaneous nerves.

The **CUTANEOUS NERVES OF THE THORAX** are derived from the trunks of the intercostal nerves between the ribs. Of these there are two sets:—One set, *lateral cutaneous nerves of the thorax*, arise from those nerves about midway between the spine and the sternum. The other set, *anterior cutaneous nerves of the thorax*, are the terminations of the same trunks at the anterior ends of the intercostal spaces.

The *anterior cutaneous nerves* are slender filaments which pierce the pectoral muscle, and are directed outwards to supply the skin and the mammary gland. The offset of the second nerve joins a cutaneous branch from the cervical plexus. Small branches of the internal mammary vessels accompany these nerves.

The *lateral cutaneous nerves* (fig. 72) issue with companion vessels between the digitations of the serratus magnus muscle, and divide into anterior and posterior branches. There is not usually any lateral cutaneous nerve from the first intercostal trunk.

The *anterior offsets* ⁽⁹⁾ bend over the pectoral muscle, and end in the integuments and the mammary gland: they increase in size downwards, and the lowest give twigs to the digitations of the external oblique muscle. The cutaneous nerve of the second intercostal trunk commonly wants the anterior offset.

The *posterior offsets* ⁽⁸⁾ end in the integuments over the latissimus dorsi muscle and the back of the scapula, and decrease in size from above down.

The branch of the second intercostal nerve ⁽⁷⁾ is larger than the rest, and is named *intercosto-humeral*. Perforating the fascia of the axilla, it is distributed to the skin of the arm (p. 272). As it crosses the axilla it is divided into two or more pieces, and is connected to the nerve of Wrisberg ⁽⁵⁾ by a filament of variable size.

The branch of the third intercostal nerve gives filaments likewise to the arm-pit and the inner side of the arm.

The MAMMA is the gland for the secretion of the milk, and is situate on the lateral part of the front of the chest.* Office of the breast.

Resting on the great pectoral muscle, it is nearly hemispherical in form, but most prominent at the inner and lower aspects. Its dimensions and weight vary greatly. In a breast not enlarged by lactation, the width is commonly about four inches. Longitudinally it extends from the third to the sixth or seventh rib, and transversely from the side of the sternum to the axilla. Its thickness is about one inch and a half. The weight of the mamma ranges from six to eight ounces. Form and position; with its dimensions and weight.

Nearly in the centre of the gland (rather to the inner side) rises the conical or cylindrical projection of the nipple or mamilla. This prominence is about half an inch or rather more in length, is slightly turned outwards, and presents in the centre a shallow depression, where it is rather redder. Around the nipple is a coloured ring—the *areola*, about an inch in width, the tint of which is influenced by the complexion of the body, and becomes darker during pregnancy and lactation. The skin of the nipple and areola is provided with numerous papillæ and glands; and on the surface are some small tubercles marking the position of the latter. Position and form of the nipple: the areola colour is altered. Skin has glands.

In the male the mammary gland resembles that of the female in general form, though it is much less developed; and it possesses a small nipple, which is surrounded by an areola provided with hairs. The glandular or secretory structure is imperfect. Breast of the male.

Structure. The mamma is a compound racemose gland, and consists of small vesicles, which are united to form lobules and lobes. Connected with each lobe is an excretory or lactiferous duct. Structure

A layer of areolar tissue, containing masses of fat, surrounds the gland, and penetrates into the interior, subdividing it into lobes; but between the lobules of the gland, and in the nipple and areola, there is not any fatty substance. Some fibrous septa fix the gland to the skin, and support it; these are the *ligamenta suspensoria* of Astley Cooper. Investing and fibrous tissue.

Vesicles. The little vesicles or alveoli at the ends of the most minute ducts are rounded in shape, and when filled with milk or mercury are just visible to the naked eye. Each is surrounded externally by a close vascular network. Vesicles.

Lobules and lobes. A collection of the vesicles around their ducts forms a lobule, and by the union of the lobules the lobes are produced. Of these there are about twenty altogether, and each is provided with a distinct duct. Lobules and lobes.

The ducts issuing from the several lobes (about twenty) are named from their office *galactophorous*; they converge to the areola, where they swell into oblong dilatations or reservoirs (sinuses) of one-sixth to one-third of an inch in width. Onwards from that spot the ducts become narrower; and, surrounded by areolar tissue and vessels, are continued through the nipple, nearly parallel to one another, to Lactiferous ducts;

* If the student has a male body, he may disregard the description of the mamma; and if the body is a female, he may set aside the breast for a more convenient examination of its structure.

open on end of nipple. open on the summit by apertures smaller than the canals, and varying from the size of a bristle to that of a common pin.

Muscular tissue in nipple. *Nipple.* The substance of the nipple is composed in great part of a network of interlacing bundles of plain muscular tissue, through which the lactiferous ducts pass to the surface. Some of the bundles extend from base to apex of the nipple; and surrounding the base is a set of circular fibres, with which radiating bundles decussate.

Arteries of the gland, and veins. *Blood-vessels.*—The *arteries* are supplied by the axillary, internal mammary, and intercostal, and enter both surfaces of the gland. The *veins* end principally in the axillary and internal mammary trunks; but others enter the intercostal veins.

Nerves. The *nerves* are supplied from the anterior and lateral cutaneous branches of the thorax, viz., from the third, fourth, and fifth intercostal nerves.

Lymphatics. The *lymphatics* of the inner side open into the sternal glands; those of the outer side pass to the axillary glands.

Dissection of pectoral muscle. *Dissection* (fig. 72). With the limb in the same position to the trunk, the student is first to remove the fascia and the fat from the surface of the great pectoral muscle. In cleaning the muscle the scalpel should be carried in the direction of the fibres, viz., from the arm to the thorax; and the dissection may be begun at the lower border on the right side, but at the upper border on the left side.

Remove fat of axilla, follow vessels. The fascia and the fat are to be taken from the axilla, without injury to the numerous vessels, nerves, and glands in the space. The dissection will be best executed by cleaning first the large axillary vessels at the outer part, where these are about to enter the arm; and then following their branches which are directed to the chest, viz., the long thoracic under cover of the anterior boundary, and the subscapular along the posterior boundary. With the latter vessels the middle and lower subscapular nerves are to be found, and turning backwards near the arm the circumflex artery and nerve. Some arterial twigs entering the axillary glands should also be traced out.

Clean back of space. In taking away the fascia and fat from the muscles at the back of the space, the small internal cutaneous branch of the musculospiral nerve (fig. 72, ⁶) should be looked for near the great vessels.

Trace nerves of plexus. The nerves of the brachial plexus are then to be defined. The smallest of these, which possibly may be destroyed, is the nerve of Wrisberg: it lies close to the hinder edge of the axillary vein, and joins with the intercosto-humeral nerve.

and on inner wall. When cleaning the serratus muscle on the ribs the student is to seek on its surface the posterior thoracic nerve; and to trace the posterior offsets of the intercostal nerves crossing the axilla.

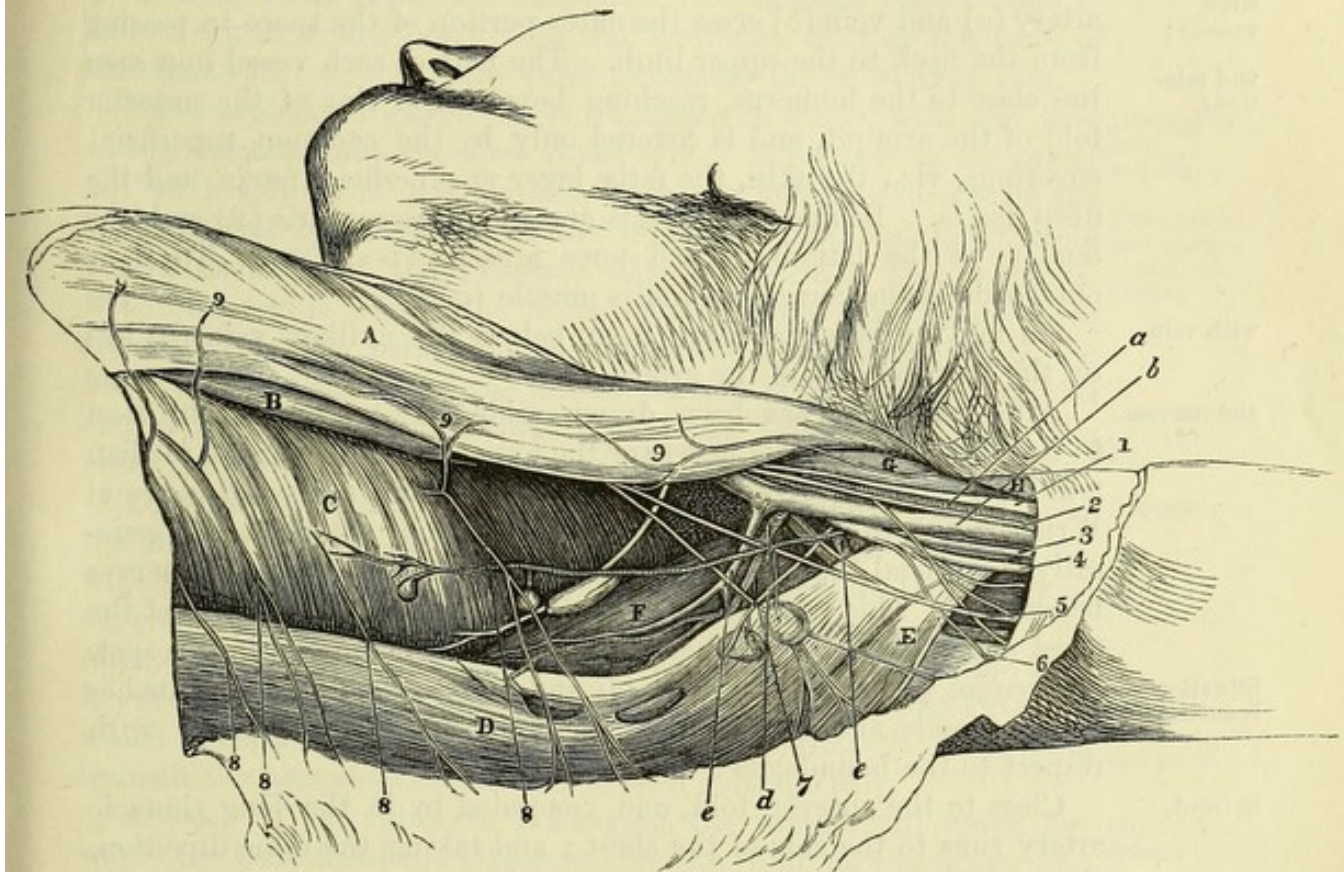
THE AXILLA.

Situation and form of the arm-pit. The axilla is the hollow between the arm and the chest (fig. 72). It is somewhat pyramidal in form, and its apex is directed upwards to the root of the neck. The space is larger near the thorax than at the arm, and its boundaries are as follows:—

Boundaries. *Boundaries.* In front and behind, the space is limited by the

muscles passing from the trunk to the upper limb. In the anterior wall are the two pectoral muscles, but these take unequal shares in its construction, in consequence of the difference in their size:—thus the pectoralis major (A) extends over the whole front of the in front, space, reaching from the clavicle to the edge of the anterior fold; while the pectoralis minor (B) corresponds only to about the middle third of the wall. In the posterior boundary, from above down- and behind; wards, lie the subscapularis (F), the latissimus dorsi muscle (D), and

Fig. 72.*



the teres major (E): the free margin of this boundary, which is formed by the latissimus dorsi and teres major, is thicker and more prominent, especially near the arm, than the anterior.

On the inner side of the axilla lie the first five ribs, with their on the inner, and intervening intercostal muscles, and the part of the serratus magnus (c) taking origin from those bones. On the outer side the space outer sides; has but small dimensions, and is limited by the humerus and the coraco-brachialis and biceps muscles (G and H).

The apex of the hollow is situate between the clavicle, the upper apex,

* View of the dissected axilla (Illustrations of Dissections). *Muscles*: A. Pectoralis major. B. Pectoralis minor. c. Serratus magnus. D. Latissimus dorsi. E. Teres major. F. Subscapularis. g. Coraco-brachialis. H. Biceps. *Vessels*: a. Axillary artery. b. Axillary vein. c. Subscapular vein. d. Subscapular artery. e. Posterior circumflex artery. *Nerves*: 1. Median. 2. Internal cutaneous. 3. Ulnar. 4. Musculo-spiral. 5. Nerve of Wrisberg. 6. Internal cutaneous of musculo-spiral. 7. Intercosto-humeral. 8. Posterior, and 9. Anterior branches of lateral cutaneous of the thorax.

- margin of the scapula, and the first rib ; and the forefinger may be introduced into the space for the purpose of ascertaining the upper boundaries, and the depth. The base or widest part of the pyramid is turned downwards, and is closed by the thick aponeurosis reaching from the anterior to the posterior fold.
- and base.
- Contents of the space. *Contents of the space.* In the axilla are contained the axillary vessels and the brachial plexus, with their branches ; some branches of the intercostal nerves ; together with lymphatic glands, and a large quantity of loose areolar tissue and fat.
- Position of large vessels ; and relations,
- Position of the trunks of vessels and nerves.* The large axillary artery (*a*) and vein (*b*) cross the outer portion of the space in passing from the neck to the upper limb. The part of each vessel now seen lies close to the humerus, reaching beyond the line of the anterior fold of the arm-pit, and is covered only by the common superficial coverings, viz., the skin, the fatty layer or superficial fascia, and the deep fascia. Behind the vessels are the subscapularis (*F*) and the tendons of the latissimus and teres muscles (*D* and *E*). To their outer side is the coraco-brachialis muscle (*G*).
- with vein
- On looking into the space from below, the axillary vein (*b*) lies on the thoracic side of the artery.
- and nerves.
- After the vein has been drawn aside, the artery will be seen to lie amongst the large nerves of the upper limb, having the median trunk (¹) to the outer side, and the ulnar (³) and the small nerve of Wrisberg (⁵) to the inner side ; the internal cutaneous (²) generally superficial to, and the musculo-spiral (⁴) and circumflex nerves beneath it. This part of the artery gives branches to the side of the chest and the shoulder. The vein receives some branches in this spot.
- Situation of branches :
- Position of the branches of vessels and nerves.* The several branches of the vessels and nerves have the undermentioned position with respect to the boundaries :—
- in front,
- Close to the anterior fold, and concealed by it, the long thoracic artery runs to the side of the chest ; and taking the same direction, though nearer the middle of the hollow, are the small external mammary artery and vein.
- behind,
- Extending along the posterior wall, within its free margin and in contact with the edge of the subscapularis muscle, are the subscapular vessels and nerves (*d*) ; and near the humeral end of the subscapularis the posterior circumflex vessels (*e*) and the circumflex nerve bend backwards beneath the large trunks.
- inside.
- On the inner boundary, at the upper part, are a few small branches of the superior thoracic artery, which ramify on the serratus muscle ; but these are commonly so unimportant, that this part of the axillary space may be considered free from vessels with respect to any surgical operation. Lying on the surface of the serratus magnus, is the nerve to that muscle ; and perforating the inner boundary of the space, are the lateral cutaneous nerves of the thorax,—the highest of which is directed across the axilla to the arm, and receives the name intercosto-humeral (*f*).
- Lymphatic glands
- The *lymphatic glands* of the axilla are arranged in three sets : one is placed along the inner side of the great blood-vessels ; another

occupies the hinder part of the space, lying near the subscapular vessels; and the third accompanies the long thoracic artery, beneath the margin of the pectoralis major. Commonly there are in all ten or twelve; but in number and size they vary much. Small twigs from the branches of the axillary vessels are furnished to them.

The glands by the side of the blood-vessels receive the lymphatics of the arm; those along the hinder boundary are joined by the lymphatics of the side of the chest and of the back; and those beneath the pectoral muscle by the lymphatics of the front of the chest, as well as by some from the mamma. The efferent vessels unite to form a trunk, which opens into the lymphatic duct of the neck of the same side; or some may enter separately the subclavian vein.

The PECTORALIS MAJOR (A) is triangular in shape, with the base at the sternum, and the apex at the arm. It *arises* from the inner half of the front of the clavicle, from the anterior surface of the sternum and the cartilages of the upper six ribs, and below from the aponeurosis of the external oblique muscle of the abdomen. From this wide origin the fibres take different directions—those from the clavicle being inclined obliquely downwards, while the lower ones ascend behind the middle portion of the muscle; and all end in a tendon, which is *inserted* into the pectoral ridge on the outer side of the bicipital groove of the humerus.

This muscle bounds the axilla in front, and its lower border forms the anterior fold of the hollow. Covering it are the integuments, with the mamma and the thin deep fascia, as well as the platysma close to the clavicle. The upper border is adjacent to the deltoid muscle, the cephalic vein and a small artery lying between the two. Between the clavicular and sternal origins is a narrow interval, which corresponds to a depression on the surface. The parts beneath the pectoralis major will be seen subsequently.

Action. If the humerus is hanging, the muscle will move forwards the limb until the elbow reaches the front of the trunk, and will rotate it in.

When the limb is raised, the pectoralis depresses and adducts it; and acting with other muscles inserted into the humerus, it may dislocate the head of that bone when the lower end is raised and fixed, as in a fall on the elbow.

Supposing both limbs fixed, as in climbing, the trunk will be raised by both muscles; and the lower fibres can elevate the ribs in laborious breathing.

Dissection (fig. 73). The great pectoral muscle is to be cut across now in the following manner:—

Only the clavicular part is to be first divided, so that the branches of nerve and artery to the muscle may be found. Reflect the cut piece of the muscle, and press the limb against the edge of the table, for the purpose of raising the clavicle and rendering tight the fascia attached to that bone; on carefully removing the fat, and a piece of fascia prolonged from the upper border of the small pectoral muscle, the membranous costo-coracoid sheath will be seen close to the clavicle, covering the axillary vessels and nerves.

of the
axilla;

and vessels
joining
them.

Great pec-
toral
muscle.

Clavicular
and sterno-
costal
origins

Insertion
into hume-
rus.

Relations.

Interval
between the
two parts.

Use: flexes,
rotates in,

and adducts
arm;

raises ribs.

Dissection.

Cut clavicu-
lar part of
the pectoral.

Trace
vessels and
nerves.

At this stage the cephalic vein is to be defined as it crosses inwards to the axillary vein. A branch of nerve (anterior thoracic), and the acromio-thoracic vessels, which perforate the sheath around the axillary trunks, are to be followed to the pectoral muscle.

Divide the
rest of the
muscle to
see its
insertion.

The remaining part of the pectoralis major may be cut about its centre, and the pieces thrown inwards and outwards. Any fat coming into view is to be removed; and the tendon of the pectoralis is to be followed to the humerus.

Tendon of
insertion of
pectoralis.

Insertion of the pectoralis. The tendon of the pectoralis consists of two layers, anterior and posterior, at its attachment to the bone;—the anterior receives the clavicular and upper sternal fibres, and joins the tendon of the deltoid muscle; and the posterior gives attachment to the lower ascending fibres. The tendon is from two inches to two inches and a half wide, and sends upwards one expansion over the bicipital groove to the capsule of the shoulder-joint, and another downwards to the fascia of the arm.

Parts
covered by
the muscle.

Parts covered by the pectoralis. The great pectoral muscle covers the pectoralis minor, and forms alone, above and below that muscle, the anterior boundary of the axilla. Between the pectoralis minor and the clavicle it conceals the subclavius muscle, the sheath containing the axillary vessels, and the branches perforating that sheath. Below the pectoralis minor it lies on the side of the chest, on the axillary vessels and nerves, and on the biceps and coraco-brachialis muscles near the humerus.

Small pec-
toral muscle.

The PECTORALIS MINOR (fig. 73, B) is also triangular in shape, and extends from the thorax to the shoulder. It arises from the third, fourth and fifth ribs, immediately external to their cartilages, by tendinous slips which are blended with the aponeuroses covering the intercostal muscles. The fibres converge to their insertion into the anterior half of the coracoid process of the scapula, at its upper and inner part.

Origin from
ribs.

• Insertion
into cora-
coid process.

Relations.

This muscle assists the pectoralis major in forming the anterior wall of the axilla, and near its insertion it lies over the large vessels and the accompanying nerves. The upper border is separated from the clavicle by a triangular interval. The lower border projects beyond the pectoralis major close to the chest; and along it the long thoracic vessels lie. The tendon of insertion is united with the coraco-brachialis and short head of the biceps.

Use.

Action. It draws the scapula forwards and downwards; and in laborious breathing it becomes an inspiratory muscle, taking its fixed point at the shoulder.

Dissection
of axillary
sheath and
costo-co-
racoid
fascia.

Dissection. Supposing the clavicle raised by pressing backwards the arm, as before directed, the tube of fascia around the vessels will be demonstrated by making a transverse cut below the costo-coracoid membrane (fig. 73), so that the handle of the scalpel can be passed beneath it. Then, by dividing the membrane itself near the clavicle and raising the lower border of the subclavius, this muscle will be seen to be encased by fascia, which is attached to the bone both before and behind it.

Costo-cora-

The *costo-coracoid membrane* or *ligament* (fig. 73) is a firm

band which receives this name from its attachment on the one side to the rib, and on the other to the coracoid process of the scapula. Between these points it is inserted into the clavicle, enclosing the subclavius muscle, and is joined by the piece of fascia that encases the small pectoral muscle. The part of the membrane behind the subclavius is blended with the front of the axillary sheath.

coid membrane
conceals subclavius,
and joins sheath of vessels.

The *sheath* of the axillary vessels and nerves (E) is a funnel-shaped tube, prolonged from the fascia covering the scaleni muscles in the lower part of the neck. It is strongest near the subclavius muscle, where the costo-coracoid band joins it. The anterior part of the sheath is perforated by the cephalic vein (*e*), the acromio-thoracic artery (*a*), and the anterior thoracic nerves (¹ and ²).

Axillary sheath :
strongest in front.

Dissection. After the costo-coracoid membrane has been examined, the remains of it are to be taken away ; and the subclavius muscle, and the axillary vessels and nerves with their branches, are to be carefully cleaned.

Clean the vessels.

The SUBCLAVIUS (fig. 73, D) is a small elongated muscle, placed below the clavicle. It *arises* by a tendon from the first rib and its cartilage at their junction, in front of the costo-clavicular ligament. The fibres pass outwards and somewhat upwards, and are *inserted* into a groove on the under surface of the clavicle, which reaches between the two rough impressions for the costo- and coraco-clavicular ligaments.

Subclavius muscle
is attached to clavicle and first rib.

The muscle crosses the large vessels and nerves of the limb, and is enclosed, as before said, in a sheath of fascia.

Relations.

Action. It depresses the clavicle, and indirectly the scapula.

Use.

The AXILLARY ARTERY (fig. 73) continues the subclavian trunk to the upper limb. The part of the vessel to which this name is applied is contained in the axilla, and extends from the outer border of the first rib to the lower edge of the teres major muscle (H).

Axillary artery :

In the axillary space its position will be marked by a line from the centre of the clavicle to the inner edge of the coraco-brachialis. Its direction will vary with the position of the limb to the trunk ; for when the arm lies by the side of the body the vessel is arched, its convexity being upwards ; but when the limb is raised to the level of the shoulder, it is somewhat curved in the opposite direction. In the upper part of the axilla the vessel is deeply placed, but it becomes superficial as it approaches the arm.

extent,

The depth varies.

Its relations with the surrounding objects are numerous ; and the description of these will be methodised by dividing the artery into three parts—one above, one beneath, and one below the small pectoral muscle.

Relations :—

Above the small pectoral muscle, the artery is contained in the axillary sheath of membrane (E), and is concealed by the clavicular portion of the great pectoral muscle. Behind it are the intercostal muscles of the first space and the first digitation of the serratus magnus.

Above small pectoral :
with muscles

To the thoracic side is placed the axillary vein (*g*). The cephalic vein (*e*) and offsets of the acromio-thoracic vessels cross over it.

vessels,

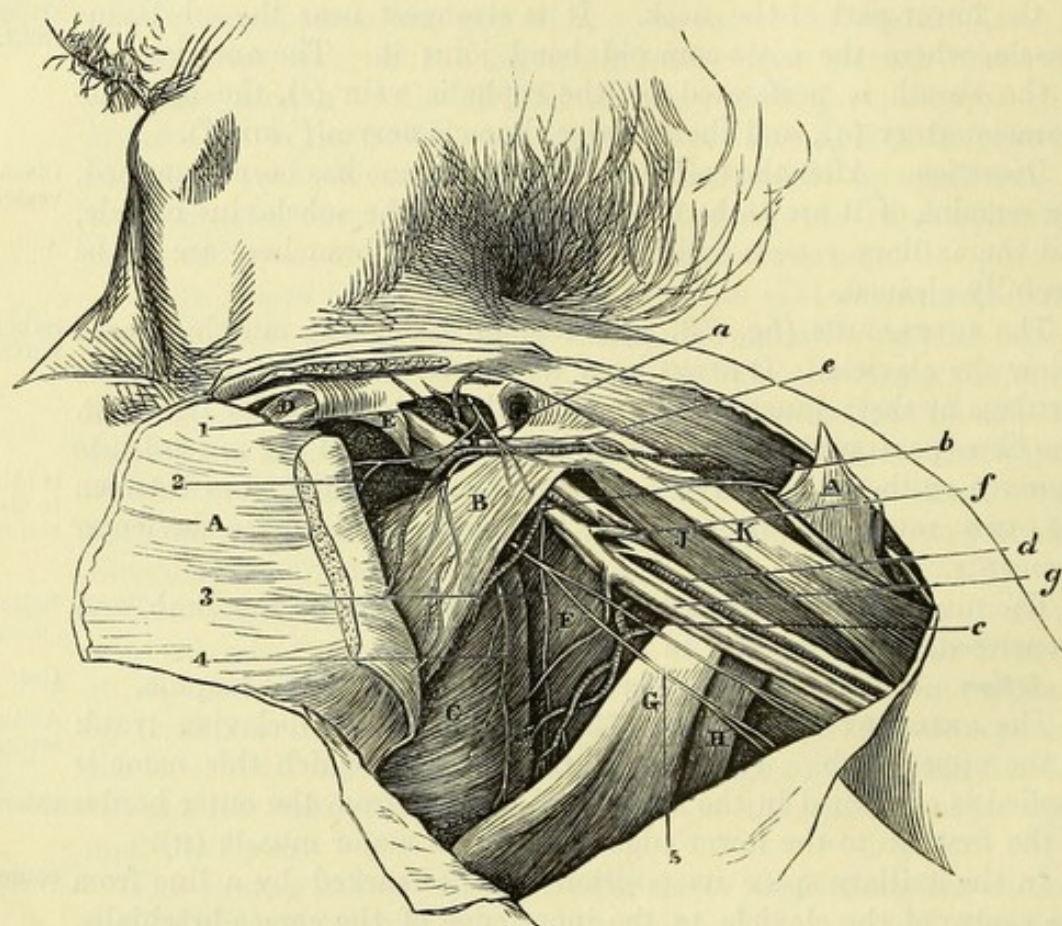
and nerves

On the acromial side lie the cords of the brachial plexus; superficial to it is the external anterior thoracic nerve; and beneath it is the posterior thoracic.

Beneath
pectoral:
with
muscles,

In its second part, the pectoralis minor and major (B and A) are superficial to the artery. But there is not any muscle immediately in contact behind, for the vessel is placed across the top of the

Fig. 73.*



axilla, particularly when the limb is in the position required by the dissection.

vein,

The companion vein (*g*) lies to the inner side, but separated from the arterial trunk by the inner cord of the brachial plexus.

and nerves

In this position the cords of the brachial plexus lie around it, one being outside, another inside, and the third behind the artery.

And beyond
the small
pectoral:

Beyond the pectoralis minor, the artery is at first concealed by the lower border of the great pectoral muscle (A); but thence to

* Second view of the dissection of the chest (Illustrations of Dissections). *Muscles and fasciæ*: A. Pectoralis major, cut. B. Pectoralis minor. C. Serratus magnus. D. Subclavius, encased in the costo-coracoid membrane. E. Axillary sheath. F. Subscapularis. G. Latissimus dorsi. H. Teres major. J. Coraco-brachialis. K. Biceps. *Vessels*: a. Acromio-thoracic branch. b. Long thoracic branch. c. Subscapular branch. d. Axillary artery. e. Cephalic vein. f. Brachial veins joining the axillary vein, g. *Nerves*: 1 and 2. Anterior thoracic branches. 3. Long subscapular branch. 4. Nerve to the serratus. 5. Intercosto-humeral.

its termination it is covered only by the integuments and the fascia. Beneath it are subscapularis muscle (F) and the tendons of the latissimus and teres (G and H). To the outer side is the coraco-brachialis muscle (J).

The axillary vein remains as above on the thoracic side of the artery.

Here the artery lies in the midst of the large trunks of nerves into which the brachial plexus has been resolved:—On the outer side is the median nerve, with the musculo-cutaneous for a short distance; and on the inner side are the ulnar, and the nerve of Wrisberg. Superficial to the vessel is the internal cutaneous; and behind are the musculo-spiral and circumflex nerves, the latter extending only as far as the border of the subscapular muscle.

The branches of the axillary artery are furnished to the wall of the thorax and the shoulder. The thoracic branches are four in number; two (superior and acromio-thoracic) arise from the artery above the pectoralis minor; one (alar thoracic) beneath the muscle; and one (long thoracic) at the lower border. Three branches are supplied to the shoulder, viz., subscapular and two circumflex; they arise close together, at the border of the subscapularis muscle. The last offsets are the external mammary and some muscular twigs.

The *superior thoracic branch* is the highest and smallest offset, and arises opposite the first intercostal space; it ramifies on the side of the chest, anastomosing with the intercostal arteries.

The *acromio-thoracic branch* (fig. 73, a) is a short trunk on the front of the artery, which appears at the upper border of the pectoralis minor, and opposite the interval between the large pectoral and deltoid muscles. Its principal offsets are directed inwards and outwards:—

a. The *inner or thoracic set* supply the pectoral muscles, and give a few offsets to the side of the chest, which anastomose with the intercostal and other thoracic arteries.

b. The *outer or acromial set* enter the deltoid, and some twigs perforate that muscle to anastomose over the acromion with a branch of the suprascapular artery (p. 388).

c. A small *clavicular branch* ascends to the subclavius muscle.

d. The *humeral branch* runs downwards with the cephalic vein between the pectoral and deltoid muscles, to which it is distributed.

The *alar thoracic* is very inconstant as a separate branch, its place being frequently taken by offsets of the subscapular and long thoracic arteries: it is distributed to the glands and fat of the axilla.

The *long thoracic branch* (fig. 73, b) is directed along the border of the pectoralis minor to about the fifth intercostal space; it supplies the pectoral and serratus muscles, and anastomoses, like the other branches, with the intercostal and thoracic arteries. In the female it gives branches to the mammary gland.

An *external mammary artery* is frequently met with, especially in the female; its position is near the middle of the axilla with a companion vein. It supplies the glands, and ends in the wall of the thorax below the preceding.

Subscapular has The *subscapular branch* (fig. 73, c) courses with a nerve of the same name along the subscapularis, as far as the lower angle of the scapula, where it ends in branches for the serratus magnus, and the latissimus dorsi and teres muscles: it gives many offsets to the glands of the space.

a dorsal branch, Near its origin the artery sends backwards a considerable *dorsal branch* round the edge of the subscapular muscle: this gives an *infrascapular offset* to the ventral aspect of the scapula, and then turns to the dorsum of that bone, where it will be afterwards dissected (p. 269).

which gives infra-scapular. The subscapular artery is frequently combined at its origin with other branches of the axillary, or with branches of the brachial artery.

Anterior and posterior circumflex. The *circumflex branches* wind round the humerus below the subscapular muscle. The *anterior* is small, and passes outwards beneath the coraco-brachialis and biceps. The *posterior* is much larger, and disappears with the companion nerve between the subscapularis and teres major muscles. They will be followed in the dissection of the shoulder (p. 264).

Muscular. Small *muscular offsets* enter the coraco-brachialis muscle.

Axillary vein: The AXILLARY VEIN (g) continues upwards the basilic vein of the arm, and has the same extent as the axillary artery. It lies to the thoracic side of its artery, and receives corresponding thoracic and shoulder branches. Opposite the subscapular muscle it is joined externally by a large vein, which is formed by the union of the venæ comites of the brachial artery; and near the clavicle the cephalic vein opens into it.

Dissection of brachial plexus. *Dissection.* To follow out the branches of the brachial plexus, cut through the pectoralis minor near its insertion into the coracoid process, and turn it towards the chest, but without injuring the thoracic nerves. The axillary vessels are next to be divided below the second rib,* and to be drawn down with hooks; and their thoracic branches may be removed at the same time. A dense fascia is to be cleared away from the large nerves of the plexus.

Nerves entering brachial plexus. The BRACHIAL PLEXUS (fig. 74) results from the interlacement of the anterior branches of the lower four cervical nerves and the larger part of the first dorsal; and a slip is added to it above from the lowest nerve in the cervical plexus. It is placed successively in the neck and the axilla, and ends opposite the coracoid process in the nerves of the limb. The part of the plexus above the clavicle is described in the dissection of the head and neck (p. 71). The part below the clavicle has the same relations to surrounding muscles as the axillary artery; and in it the nerve-trunks are disposed as follows:—

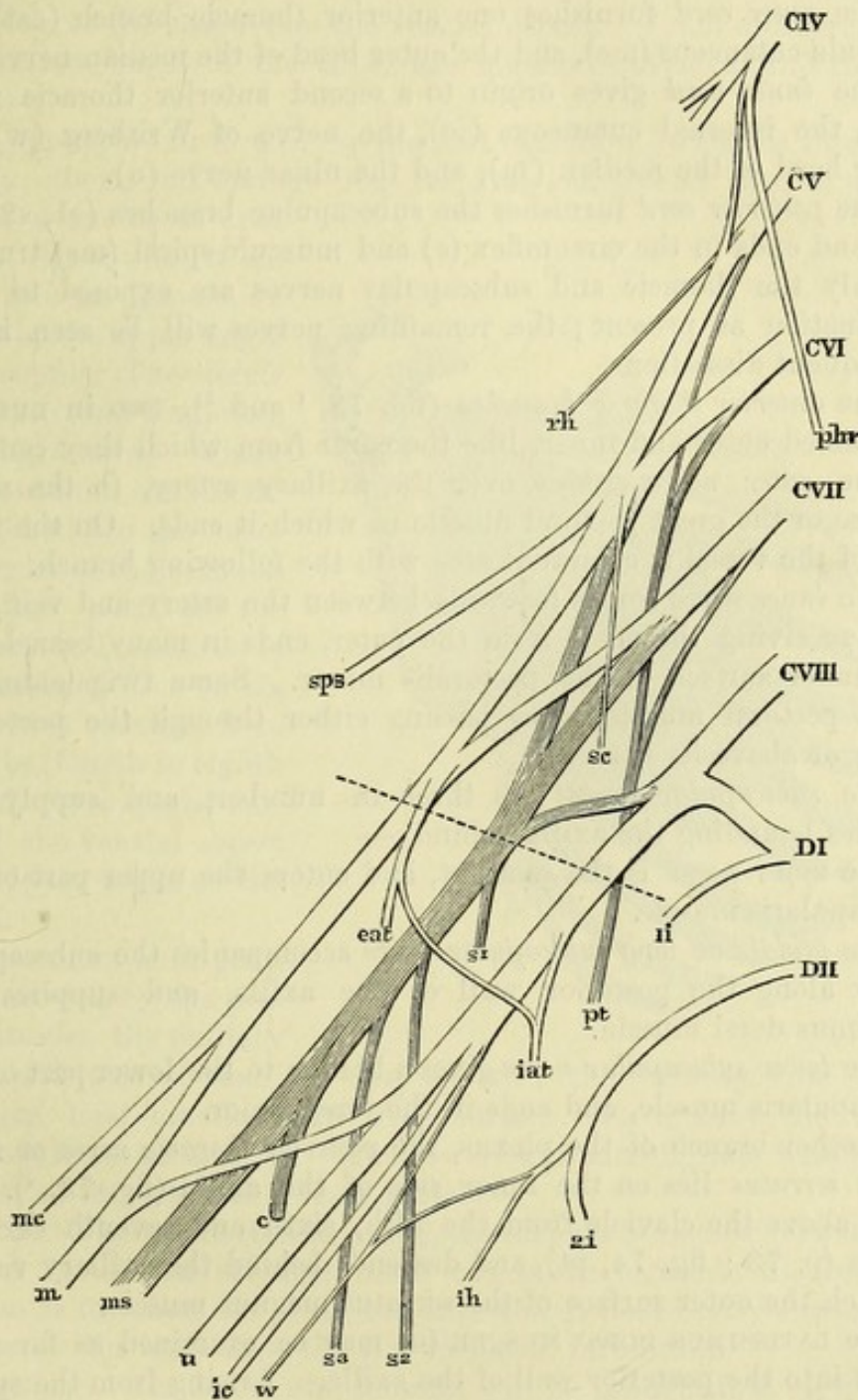
Its situation As the plexus enters the axilla it consists of three cords, inner, outer, and posterior, which lie together in a bundle on the outer side of the artery. Beneath the pectoralis minor the three cords embrace

and relations.

* The student must be careful not to cut the vessels higher than the spot mentioned, otherwise he will injure the dissection of the neck.

the vessel, being placed as their names indicate—the first inside, the second outside and the third behind the artery. Near the lower

Fig. 74.*



* Diagram of the brachial plexus. The dotted line indicates the level at which the cords are crossed by the clavicle. c IV. to c VIII. Fourth to eighth cervical nerves. DI. and DII. First and second dorsal nerves. li and 2i. First and second intercostal nerves. ih. Intercosto-humeral nerve. phr. Phrenic nerve.

Supraclavicular branches of brachial plexus: rh. Branch to rhomboids. sps. Suprascapular. sc. Branch to subclavius. pt. Posterior thoracic.

Infraclavicular branches: From outer cord—eat. External anterior thoracic. mc. Musculo-cutaneous. m. Median. From inner cord—iat. Internal anterior thoracic. w. Nerve of Wrisberg. ic. Internal cutaneous. u. Ulnar. m. Median. From posterior cord—s 1. Upper, s 2. Middle, and s 3. Lower subscapular. c. Circumflex. ms. Musculo-spiral.

edge of the small pectoral muscle, the cords divide to form the large nerves of the limb.

which give
branches :

The *branches* of the plexus below the clavicle arise from the several cords in the following way :—

from the
outer,

The *outer cord* furnishes one anterior thoracic branch (eat), the musculo-cutaneous (mc), and the outer head of the median nerve (m).

inner, and

The *inner cord* gives origin to a second anterior thoracic nerve (iat), the internal cutaneous (ic), the nerve of Wrisberg (w), the inner head of the median (m), and the ulnar nerve (u).

posterior
cord.

The *posterior cord* furnishes the subscapular branches (s1, s2, and s3), and ends in the circumflex (c) and musculo-spiral (ms) trunks.

The follow-
ing are seen
now, viz.—

Only the thoracic and subscapular nerves are exposed to their termination at present; the remaining nerves will be seen in the subsequent dissections.

Two anterior
thoracic :

The *anterior thoracic branches* (fig. 73, ¹ and ²), two in number, are named outer and inner, like the cords from which they come.

outer,

The *outer nerve* crosses over the axillary artery, to the under surface of the great pectoral muscle in which it ends. On the inner side of the vessel it communicates with the following branch.

and inner.

The *inner nerve* comes forwards between the artery and vein, and after receiving the offset from the outer, ends in many branches to the under surface of the pectoralis minor. Some twigs enter the great pectoral muscle, after passing either through the pectoralis minor or above its border.

Three sub-
scapular :

The *subscapular nerves* are three in number, and supply the muscles bounding the axilla behind :—

to subscapularis,

The *upper nerve* is the smallest, and enters the upper part of the subscapularis muscle.

latissimus
dorsi,

The *middle or long subscapular nerve* accompanies the subscapular artery along the posterior wall of the axilla, and supplies the latissimus dorsi muscle.

and teres
major.

The *lower subscapular nerve* gives a branch to the lower part of the subscapularis muscle, and ends in the teres major.

Nerve to
serratus.

Another branch of the plexus, the *posterior thoracic nerve* or *nerve to the serratus* lies on the inner side of the axilla (fig. 73, ⁴). It arises above the clavicle from the fifth, sixth and seventh cervical nerves (p. 73; fig. 74, pt), and descends behind the axillary vessels to reach the outer surface of the serratus magnus muscle.

Latissimus
dorsi :

The LATISSIMUS DORSI MUSCLE (G) may be examined as far as it enters into the posterior wall of the axilla. Arising from the spinal column and the back of the trunk, and crossing the lower angle of the scapula, the muscle ascends to be *inserted* into the bottom of the bicipital groove, by a tendon one inch and a half in width, in front of the teres; at the lower border aponeurotic fibres connect the two, but a bursa intervenes between them near the insertion.

insertion.

Dissection
of the ser-
ratus.

Dissection. To lay bare the serratus magnus, the arm is to be drawn from the trunk, so as to separate the scapula from the thorax. The nerves of the brachial plexus may be cut through opposite the third rib; and the fat and connective tissue should be cleaned from the muscular fibres.

The SERRATUS MAGNUS MUSCLE (fig. 75) extends from the side of the chest to the base of the scapula. It arises from the upper eight or nine ribs by as many slips or digitations, and passes backwards, diminishing in breadth, to be inserted into the whole length of the base of the scapula on the ventral aspect. From a difference in the arrangement of the slips, the muscle is divided into three parts:—

The *upper part* is formed by the first digitation, which is thicker than the others, and springs from the first and second ribs, as well as from a tendinous arch between them: it is inserted into an impression in front of the upper angle of the scapula. The *middle part* is thin, and comprises two digitations, which spread out from the second and third ribs to the vertebral border of the scapula. The *lower part* is the strongest, and consists of the remaining five or six slips, which converge from their ribs (fourth to eighth or ninth) to a special surface on the ventral aspect of the lower angle of the scapula.

The serratus is in great part concealed by the pectoral muscles, the axillary vessels and nerves, and the scapula with the subscapularis and latissimus dorsi muscles. Its deep surface rests against the ribs and the intercostal muscles. The lower slips interdigitate with like processes of the external oblique muscle.

Action. The whole muscle acting, the scapula is carried forwards. But the lower and stronger fibres can move forwards the lower angle, so as to rotate the bone, and turn the glenoid cavity upwards. The lowest slips may raise the ribs in forced inspiration.

Dissection. The intercostal muscles will be brought into view by detaching the processes of the serratus from the ribs for a couple of inches, and by taking away the loose tissue on the surface. At the front of the chest a thin aponeurosis is continued forwards from each external intercostal to the sternum; this is to be left in the third space. Some of the lateral cutaneous nerves should be preserved.

The INTERCOSTAL MUSCLES form two layers in each space, but neither occupies the whole length of the interval. The direction of the fibres is different in the two, those of the external muscle run-

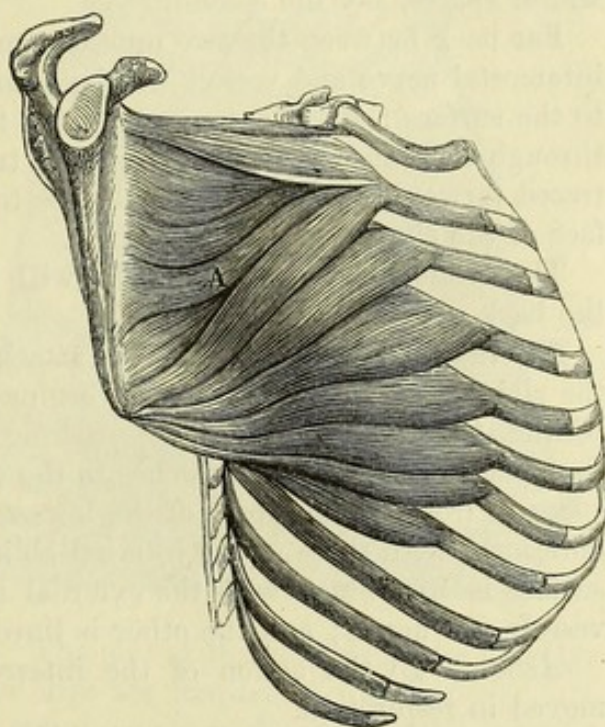


Fig. 75.*

Relations.

* View of the serratus magnus muscle, A.

ning very obliquely downwards and forwards, while those of the internal pass, although less obliquely, downwards and backwards.

Outer layer
is deficient
in front.

The *external muscle* consists of fleshy and tendinous fibres, and is attached to the margins of the ribs bounding the intercostal space. It extends from the tubercle of the upper rib behind to the end of the bone in front, except in the last two spaces, where the muscle is continued forwards between the cartilages. A thin membrane (*anterior intercostal aponeurosis*) takes the place of the muscle between the rib-cartilages.

Dissection
of deeper
muscle,

Dissection. The internal intercostal muscle will be seen by cutting through and removing the external layer and the fascia in one of the widest spaces, say the second.

of nerves
and vessels.

Far back between the two muscles, and close to the rib above, the intercostal nerve and vessels will be found. A branch of the nerve to the surface (lateral cutaneous of the thorax) should be followed through the external muscle; and the trunk of the nerve is to be traced forwards in one or more spaces to the sternum and the surface of the chest.

The hinder part of the muscles will be seen in the dissection of the back and thorax.

Inner layer
deficient
behind.

The *internal intercostal muscle* is attached to the inner surface of the ribs bounding the space. It begins near the angles of the ribs behind, the upper muscles approaching more closely to the spine than the lower ones, and reaches to the extremity of the intercostal space in front. The fibres of the lowest two muscles are continuous anteriorly with those of the internal oblique of the abdomen. One surface is in contact with the external muscle, and the intercostal vessels and nerve; and the other is lined by the pleura.

Use of

Action. By the action of the intercostal muscles the ribs are moved in respiration.

outer
muscles;

The *external intercostals* elevate the ribs and evert the lower edges, so as to enlarge the thorax in the antero-posterior and transverse directions: they come into play during inspiration.

of inner
muscles,

The *internal intercostals* act in a different way at the side and fore part of the chest.

interosseous
part,

Between the osseous parts of the ribs they depress and turn in those bones, diminishing the size of the thorax; and they are brought into use in expiration.

intercarti-
laginous
part.

Between the rib-cartilages they raise the ribs, and are muscles of inspiration, like the outer layer.

Dissection
of internal
mammary
vessels.

Dissection. To bring into view the triangulæris sterni muscle and the internal mammary vessels, the cartilages of the true ribs, except the first and seventh, are to be taken away with the intervening muscles on the right side;* but the two ribs mentioned are to be left untouched for the benefit of the dissectors of the abdomen and of the head and neck. Small arteries to each intercostal space and the surface of the thorax, and the intercostal nerves are to be preserved.

* On the left side the vessels and the muscle may have been destroyed by the injection of the body.

The surface of the triangularis sterni will be apparent when the loose tissue and fat are removed.

The TRIANGULARIS STERNI (fig. 76) is a thin muscle beneath the costal cartilages. It arises internally from the side of the ensiform process, from the back of the sternum as high as the third costal cartilage, and usually from the inner ends of the cartilages of the lower two or three true ribs. Its fibres are directed outwards, the upper ones also ascending considerably, and are inserted by fleshy slips into the true ribs except the first and last, at the junction of the bone and cartilage: some of the fibres frequently end in an aponeurosis in the intercostal spaces.

In front of the muscle are the rib-cartilages and the internal intercostals, with the internal mammary vessels and intercostal nerves. Behind, it lies on the pleura. Its lower part is continuous with the transversalis muscle

of the abdomen (fig. 76, B). The size of this muscle varies greatly, and one or more of the upper slips are frequently wanting.

Action. The triangularis sterni assists in depressing the anterior ends of the ribs, and acts with the interosseous internal intercostals in expiration.

The INTERNAL MAMMARY ARTERY is a branch of the subclavian (p. 70), and enters the thorax beneath the cartilage of the first rib. It is continued through the thorax, lying behind the costal cartilages and about half an inch from the sternum, as far as the sixth intercostal space; here it gives externally a large muscular branch (musculo-phrenic), and then passing beneath the seventh cartilage, enters the sheath of the rectus muscle in the wall of the abdomen. In the chest the artery lies on the pleura and the triangularis sterni, and is crossed by the intercostal nerves. It is accompanied by two veins, and by the chain of sternal lymphatic glands. Its thoracic branches are numerous but small:—

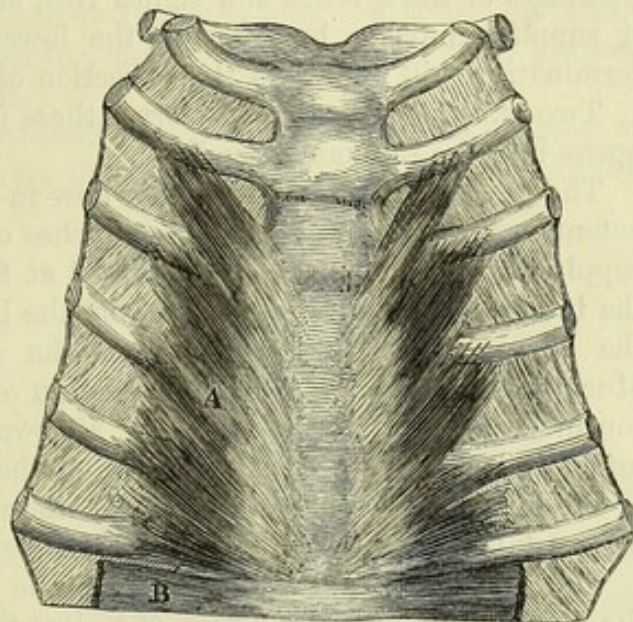
- a. A long, slender branch (comes nervi phrenici) arises as the artery enters the chest, and descends to the diaphragm with the phrenic nerve: this branch is seen in the dissection of the thorax.
- b. Small sternal branches supply the triangularis sterni, and ramify over the back of the sternum. From these, mediastinal

Triangularis sterni:

origin;

insertion;

Fig. 76.*



and relations.

Use.

Internal mammary artery

courses through thorax to abdomen.

Branches:

superior phrenic,

small posterior offsets,

* View from behind of the triangularis sterni muscle, A.

twigs pass backwards to be distributed to the remains of the thymus gland and the pericardium.

intercostal, *c.* Two *anterior intercostal branches* run outwards in each space, lying along the borders of the costal cartilages, and terminate by anastomosing with the aortic intercostal arteries.

perforating, *d.* *Perforating branches*, one or two opposite each space, pierce the internal intercostal and large pectoral muscles, and are distributed on the surface of the thorax with the anterior cutaneous nerves: the lower branches supply the mamma in the female.

musculo-phrenic. *e.* The *musculo-phrenic branch* courses outwards beneath the cartilages of the seventh and eighth ribs, and enters the diaphragm: it supplies anterior branches to the lower intercostal spaces. Its termination will appear in the dissection of the abdomen.

Veins. Two *veins* accompany the artery; these join into one trunk, which opens into the innominate vein.

Intercostal nerves: The INTERCOSTAL NERVES, seen now in the anterior half of their extent, are the anterior primary branches of the dorsal nerves, and supply the wall of the thorax. Placed at first between the layers of the intercostal muscles, each gives off the lateral cutaneous nerve of the thorax about midway between the spine and the sternum. Much diminished in size by the emission of this offset, the trunk is continued onwards, at first in, and afterwards beneath the internal intercostal muscle, as far as the side of the sternum, where it ends as the anterior cutaneous nerve of the thorax. *Branches* supply the intercostal muscles, and the triangularis sterni.

Intercostal arteries bifurcate: The AORTIC INTERCOSTAL ARTERIES lie with the nerves between the strata of intercostal muscles, and close to the upper rib bounding the space. Near the angle of the rib the artery gives off a branch which is continued forwards along the edge of the lower rib; and both anastomose in front with the intercostal offsets of the internal mammary artery.

offsets. A small *cutaneous offset* is distributed with the lateral cutaneous nerve of the thorax; and other branches are furnished to the thoracic wall.

At this stage the thorax and back are dissected. *Directions.* The dissector of the upper limb now waits the appointed time for the examination of the thorax. But as soon as the body is turned he is to take his share in the dissection of the back, and to proceed with the paragraphs marked for him in Chapter V.

After the back is finished, the limb is to be detached from the trunk by sawing the clavicle about the middle, and cutting through the soft parts connected with the scapula.

SECTION II.

SCAPULAR MUSCLES, VESSELS, NERVES, AND LIGAMENTS.

Position. After the limb has been separated from the trunk it is to be placed with the subscapularis uppermost. Position.

Dissection. The different muscles that have been traced to the scapula in the dissection of the front of the chest and of the back are now to be followed to their insertion into the bone. A small part of each, about an inch in length, should be left for the purpose of showing the attachment. Dissection of muscles.

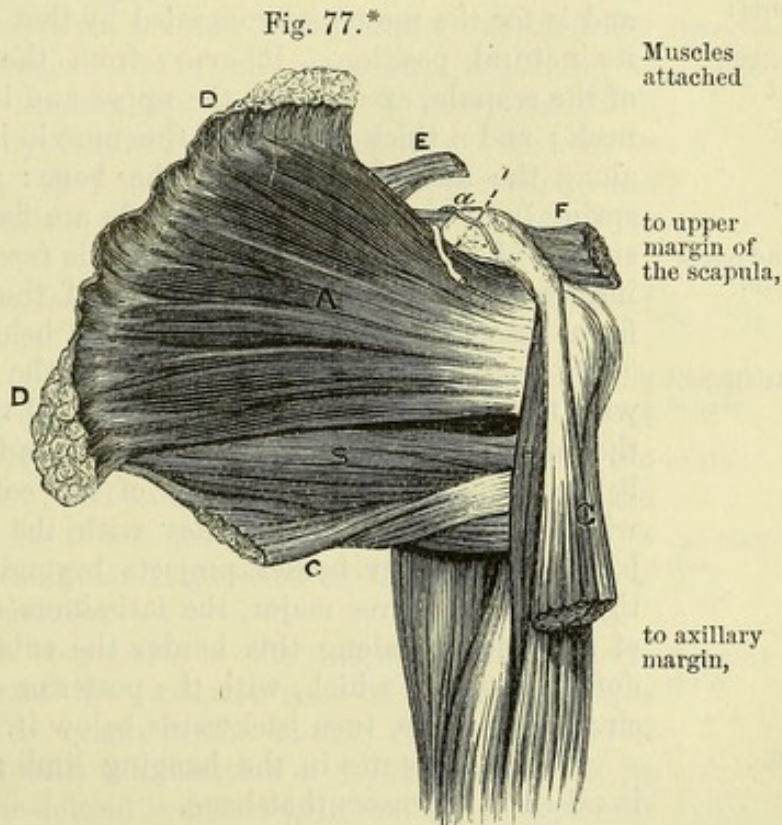
Between the larger rhomboid muscle and the serratus magnus, at the base of the scapula, run the posterior scapular artery and vein, the ramifications of which are to be traced.

To the borders and the angles of the scapula the following muscles are connected :—

From the *upper margin* of the scapula arises one muscle, the omohyoid (fig. 77, E). About half an inch wide at its origin, the muscle is attached to the edge of the bone behind the notch, and sometimes to the ligament which bridges over the notch.

Along the *axillary margin* arise the long head of the triceps (fig. 83, A), and the teres minor (H) and major (G) muscles ; these attachments will be ascertained in the progress of the dissection.

The *vertebral border* of the bone has four muscles inserted into it. Between the superior angle and the spine is the levator anguli scapulæ (fig. 78, H) ; opposite the spine the rhomboideus minor (J) is attached ; and between the spine and the inferior angle the rhomboideus major (K) is inserted : the upper fibres of the last and to base ;



* View of the subscapularis and the surrounding muscles. A. Subscapularis. B. Teres major. C. Latissimus dorsi. D. Serratus magnus. E. Omohyoid. F. Pectoralis minor. G. Biceps. H. Coraco-brachialis.

a. Suprascapular artery. l. Suprascapular nerve, separated from the artery by the suprascapular ligament.

muscle often end in an aponeurotic arch, which is fixed to the bone above and below. In front of these muscles, and inserted into the base of the scapula along its whole length, is the serratus magnus muscle (fig. 77, D), the upper and lower parts of which are much thickened, and occupy special surfaces on the ventral aspect of the corresponding angles of the bone.

to coracoid process.

The insertion of the small pectoral muscle into the anterior half of the *coracoid process* at its upper and inner part is also seen (fig. 77, F).

Dissection, and fascia,

Dissection. By the separation of the serratus from the subscapularis there comes into view a thin fascia, which belongs to the latter muscle, and is fixed to the bone round its margins; after it has been observed, it may be taken away.

of subscapularis.

The subscapularis muscle is to be followed forwards to its insertion into the humerus; and the axillary vessels and nerves, with their offsets to the muscles, should be well cleaned.

Subscapularis:

origin,

The SUBSCAPULARIS MUSCLE (fig. 77, A) lies beneath the scapula, and is for the most part concealed by that bone when the limb is in its natural position. It *arises* from the concave ventral surface of the scapula, except near the upper and lower angles, and over the neck; and a thick portion of the muscle is attached in the groove along the axillary margin of the bone: many of the fleshy fibres spring from tendinous septa which are fixed to the ridges on the surface of the scapula. The muscle is *inserted* by a tendon into the impression on the small tuberosity of the humerus, and by fleshy fibres into the bone for nearly an inch below this mark.

and insertion.

Relations.

By one surface the muscle bounds the axilla, and is in contact with the axillary vessels and nerves, and the serratus magnus. By the other, it rests against the scapula and the shoulder-joint; and between its tendon and the root of the coracoid process is a bursa, which generally communicates with the synovial cavity of that joint. The lower border projects beyond the scapula, and is contiguous to the teres major, the latissimus dorsi, and the long head of the triceps; along this border the subscapular artery runs, the dorsal branch of which, with the posterior circumflex artery and the circumflex nerve, turn backwards below it.

Use.

Action. It rotates in the hanging limb; and when the humerus is raised it depresses that bone.

Dissection of the

Dissection. The subscapularis is to be separated from the scapula, but a thin layer of fibres, in which the vessels lie, is to be left on the bone. As the muscle is raised, its tendinous processes of origin, the connection between its tendon and the capsule of the shoulder-joint, and the bursa are to be observed. A small arterial anastomosis on the ventral surface of the bone is to be dissected out of the fleshy fibres.

small infrascapular artery.

The INFRASCAPULAR ARTERY is an offset of the dorsal branch of the subscapular vessel (p. 254), and ramifies on the ventral surface of the scapula. Passing beneath the subscapular muscle, it forms an anastomosis with small twigs of the suprascapular and posterior scapular arteries.

Position. The examination of the muscles on the opposite surface of the scapula may be next undertaken. For this purpose the limb is to be turned over; and a block, which is deep enough to make the shoulder prominent, is to be placed between the scapula and the arm. Position of limb.

Dissection. The skin is to be removed from the prominence of the shoulder, down to the middle of the outer side of the arm. After its removal some small cutaneous nerves are to be found in the fat: —the upper of these descend over the acromion; and a larger branch comes to the surface about half-way down the posterior border of the deltoid muscle. Dissection of the shoulder.

SUPERFICIAL NERVES. Branches of nerves, *supraacromial*, descend to the surface of the shoulder from the cervical plexus (p. 57). A *cutaneous branch of the circumflex nerve* (fig. 78, ²) turns forwards with a small companion artery from beneath the posterior border of the deltoid, and supplies the integuments covering the lower two-thirds of the muscle. Cutaneous nerves.

Dissection. The fat and fascia are now to be taken from the fleshy deltoid, its fibres being made tense for the purpose. Beginning at the anterior edge of the muscle, the dissector is to carry the knife upwards and downwards, following the direction of the coarse muscular fasciculi. As the posterior edge is approached, the cutaneous nerve and vessels escaping from beneath it are to be dissected out. Dissection of deltoid muscle.

At the same time the fascia may be removed from the back of the scapula, so as to denude the muscles there.

The DELTOID MUSCLE (fig. 78, F) is triangular in form, with the base at the scapula and clavicle, and the apex at the humerus. It arises from the lower border of the spine of the scapula, from the outer edge of the acromion, and from the outer half or third of the front of the clavicle. Its fibres converge to a tendon which is inserted into the rough triangular impression on the outer surface of the humerus, above the middle. Deltoid muscle: origin, and insertion.

The anterior border is contiguous to the pectoralis major muscle and the cephalic vein; and the posterior rests on the infraspinatus and triceps muscles. The origin of the muscle from the bones of the shoulder corresponds with the insertion of the trapezius. At its insertion the tendon of the deltoid is united with that of the pectoralis major; and a fasciculus of the brachialis anticus is attached on each side of it. Adjacent parts.

The middle or *acromial* portion of the deltoid is thicker than the rest, and its fibres form large bundles which run obliquely between tendinous septa prolonged from the origin and insertion of the muscle. The anterior or *clavicular* and posterior or *spinous* portions are somewhat separate from the foregoing, and their fibres converge to the anterior and posterior edges respectively of the lower tendon. It consists of three parts,

Action. The acromial portion of the muscle raises the arm, abducting it from the body; the clavicular part flexes the shoulder-joint, moving the arm forwards and inwards; and the spinous part draws the arm backwards, or extends the shoulder-joint. which have different uses.

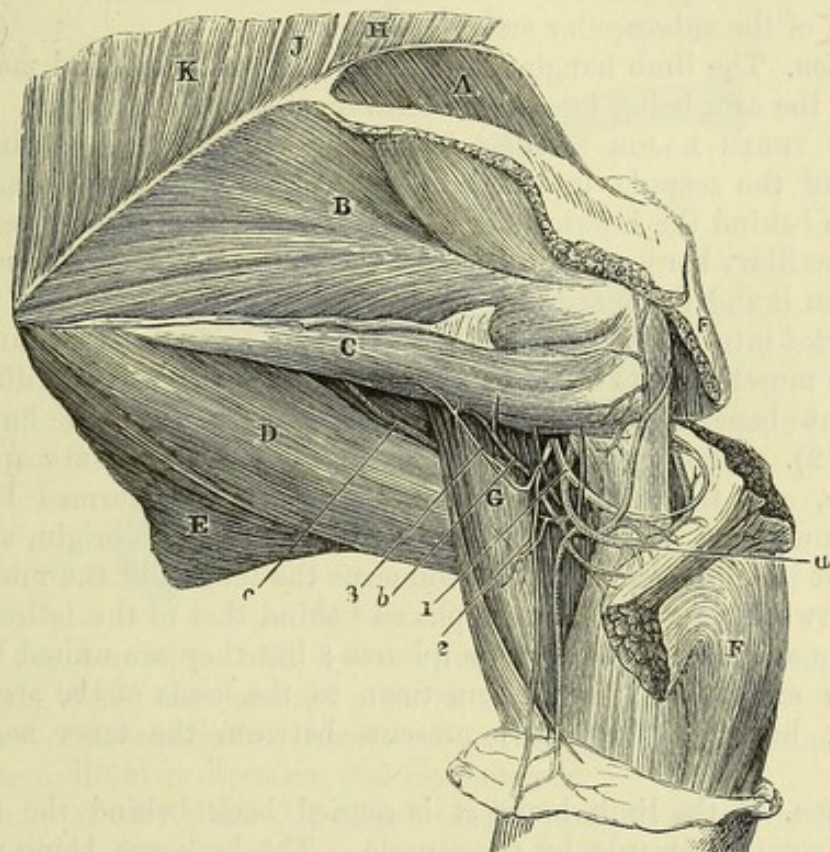
- Dissection to detach deltoid.** *Dissection* (fig. 78). The deltoid is to be divided near its origin, and is to be thrown down as far as the circumflex vessels and nerve beneath will permit. As the muscle is raised a large thick bursa between it and the upper end of the humerus comes into sight. The loose tissue and fat are to be taken away from the circumflex vessels and nerve; and the size of the bursa having been looked to, the remains are to be removed. The insertion of the muscle should be defined.
- Subacromial bursa.**
- Parts covered by the deltoid.** *Parts covered by deltoid.* The deltoid conceals the upper end of the humerus, and those parts of the dorsal scapular muscles which are fixed to the great tuberosity. A large bursa, sometimes divided into sacs, intervenes between the great tuberosity of the humerus and the under surface of the deltoid muscle and the acromion process. Lower down are the circumflex vessels and nerve, and the upper part of the biceps muscle. In front of the humerus is the coracoid process with its muscles.
- Dissection of posterior circumflex vessels,** *Dissection.* By following back the posterior circumflex vessels and nerve through a space between the humerus and the long head of the triceps (g), their connection with the axillary trunks will be arrived at. In clearing the fat from the space a branch of the nerve to the teres minor muscle is to be sought close to the border of the scapula, where it is surrounded by dense fibrous tissue.
- and anterior.** Arching outwards in front of the humerus is the small anterior circumflex artery; this is to be cleaned.
- Two circumflex arteries:** The CIRCUMFLEX ARTERIES arise near the termination of the axillary trunk (p. 254); they are two in number, and are named anterior and posterior from their position to the humerus.
- anterior;** The *anterior branch* is a small artery, which courses beneath the coraco-brachialis and biceps muscles, and ascends in the bicipital groove to the articulation and the head of the humerus: it anastomoses with small offsets of the posterior circumflex.
- posterior,** The *posterior circumflex artery* (fig. 78, a), much larger than the anterior, winds backwards through a space between the humerus and the long head of the triceps, and is distributed chiefly to the deltoid muscle, in which it anastomoses with the acromio-thoracic artery.
- its offsets.** *Branches* are given from it to the shoulder-joint, and to anastomose with the anterior circumflex and superior profunda arteries. It supplies offsets also to the teres minor, the long head of the triceps, and the integuments.
- One circumflex nerve,** *The CIRCUMFLEX NERVE* (fig. 78,¹) leaves the arm-pit with the posterior circumflex artery (p. 256), and bends round the neck of the humerus, beneath the deltoid muscle in which it ends. Many large branches enter the deltoid; and one or two filaments pierce the muscle and become cutaneous.
- which ends in deltoid:**
- branches, articular,** *Branches.* As the nerve passes backwards it gives an *articular* filament to the under part of the shoulder-joint. Behind the humerus it furnishes a *branch to the teres minor* (³), which has a reddish gangliform swelling on it, and the *cutaneous nerve* (²) before noticed, which turns round the edge of the deltoid.
- to teres,**
- cutaneous.**

The INFRASPINATUS MUSCLE (fig. 78, B) occupies the infraspinous fossa of the scapula, and extends to the upper end of the humerus. The muscle *arises* from the lower surface of the spine of the scapula, from the dorsal surface of the bone below that process, except at the neck and the narrow area along the axillary border where the teres muscles are attached, and from a special fascia covering it. Its fibres converge to a tendon, which is inserted into the middle impression on the great tuberosity of the humerus, and joins the

Infraspinatus arises from
fossa of that name ;

insertion :

Fig. 78.*



tendons of the supraspinatus and teres minor. The fleshy fibres arising from the spine overlay the tendon of the muscle.

A part of the muscle is subcutaneous ; but the upper portion is concealed by the deltoid, and the lower angle by the latissimus dorsi. The lower border is in contact with the teres minor, with which it is often united. The muscle lies on the scapula and the scapulo-humeral articulation ; and there is sometimes a small bursa between it and the capsule of the joint.

Action. With the humerus hanging it acts as a rotator outwards ; and when the bone is raised it will move the arm backwards in concert with the hinder part of the deltoid.

* View of the muscles of the dorsum of the scapula, and of the circumflex vessels and nerve. (Illustrations of Dissections.) *Muscles* : A. Supraspinatus. B. Infraspinatus. C. Teres minor. D. Teres major. E. Latissimus dorsi. F. Deltoid. G. Triceps (long head). H. Levator anguli scapulæ. J. Rhomboideus minor. K. Rhomboideus major. *Arteries* : a. Posterior circumflex. b. Branch to teres minor. c. Dorsal scapular. *Nerves* : 1. Circumflex trunk. 2. Its cutaneous offset. 3. Branch to teres minor.

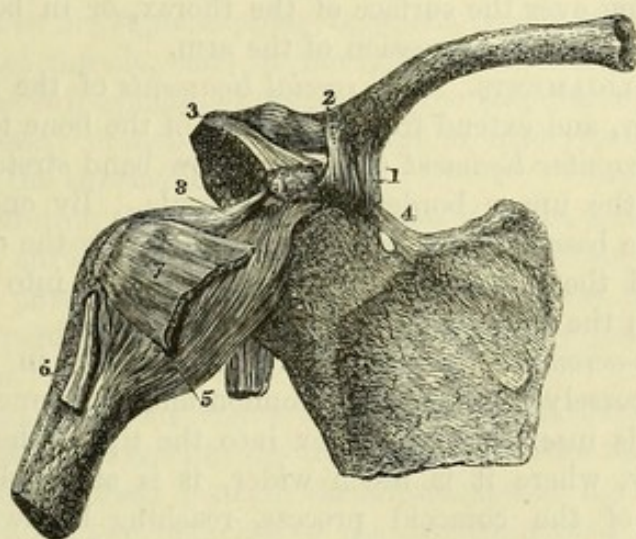
Teres minor : origin ;	The TERES MINOR (fig. 78, c) is a narrow fleshy slip, which is often united inseparably with the preceding muscle. It <i>arises</i> on the dorsum of the scapula from a special impression along the upper two-thirds of the axillary border of the bone, and from an inter-muscular septum on each side ; and it is <i>inserted</i> by a tendon into the lowest of the three marks on the great tuberosity of the humerus, as well as by fleshy fibres into the bone below that spot—about an inch altogether.
parts around it ;	This muscle is partly covered by the deltoid : it rests on the long head of the triceps and the shoulder-joint. Underneath it the dorsal branch of the subscapular artery turns.
and use.	<i>Action.</i> The limb hanging, the muscle rotates it out and moves it back ; the arm being raised, the teres depresses the humerus.
Teres major ; origin ;	The TERES MAJOR MUSCLE (fig. 78, d) passes from the inferior angle of the scapula to the humerus. Its <i>origin</i> is from an oval surface behind the inferior angle of the scapula, from the lower half of the axillary border of the bone, and from the intermuscular septum between it and the teres minor. The fibres end in a tendon which
insertion ;	is <i>inserted</i> into the inner edge of the bicipital groove of the humerus.
relations.	The muscle assists in forming the posterior fold of the axilla, and is situate beneath the axillary vessels and nerves near the humerus (fig. 72). The upper border is contiguous to the subscapularis muscle, and the lower is received into a hollow formed by the latissimus dorsi, which covers the teres behind at its origin, and in front at its insertion. At the humerus the tendon of the muscle is about two inches wide, and is placed behind that of the latissimus : the two are separated above by a bursa ; but they are united below, and an expansion is sent from them to the fascia of the arm. A second bursa is frequently present between the teres and the bone.
Use on swinging	<i>Action.</i> If the limb hangs it is carried back behind the trunk, and is rotated inwards by the muscle. The humerus being raised, the muscle depresses and adducts it.
and fixed limb.	With the limb fixed by the hand the teres will cause the lower angle of the scapula to move forwards.
Spaces between the teres ;	Below the scapula, where the teres muscles separate from one another, is a triangular interval, which is bounded in front by the shaft of the humerus, and above and below by the teres minor and major (fig. 78). This space is divided into two by the long head of the triceps. Through the anterior part, which is of a quadrilateral shape, the posterior circumflex vessels (<i>a</i>) and the circumflex nerve (¹) pass ; and opposite the posterior triangular space, the dorsal branch (<i>c</i>) of the subscapular artery bends backwards.
anterior and posterior.	
Dissection	<i>Dissection</i> (fig. 79). Before sawing through the acromion process to expose the supraspinatus muscle, the ligaments of the scapula and clavicle should be examined.
of ligaments of the clavicle,	A strong ligament (coraco-clavicular) ascends from the coracoid process to the under part of the clavicle : on removing the areolar tissue it will be seen to consist of two parts, anterior and posterior, differing in size, and in the direction of the fibres.

A capsular ligament, connecting the outer end of the clavicle with the acromion, will be shown by taking away the fibres of the trapezius and deltoid muscles.

Another strong band (coraco-acromial) passing transversely between the acromion and the coracoid process, and a small fasciculus (suprascapular ligament), placed over the notch in the superior border, are then to be defined.

LIGAMENTS OF THE CLAVICLE AND SCAPULA (fig. 79). The outer end of the clavicle is connected to the scapula by a distinct joint Union of the clavicle and scapula.

Fig. 79.*



with the acromion, and by a strong ligament (coraco-clavicular) between it and the coracoid process.

The *coraco-clavicular ligament* consists of two portions, each having a different direction and designation. Coraco-clavicular has

The posterior piece (¹), called *conoid* from its shape, is fixed by its apex to the posterior and inner part of the coracoid process; and by its base to the tubercle of the clavicle, at the junction of the outer with the middle third of the bone.

The anterior part (²), *trapezoid ligament*, is larger than the conoid; it is attached below to the inner border of the coracoid process along the hinder half; and above to the line on the under surface of the clavicle, which extends outwards from the tubercle before mentioned. The two pieces of the ligament are in apposition behind, but are separated by an interval in front. and a square piece.

Use. Both pieces of the ligament support the scapula in a state of rest. They serve also to restrain the rotatory movements of that bone; thus, when the acromion is rotated down, the motion is checked by the trapezoid band; and when upwards, by the conoid piece. Use of ligament.

* Ligaments of the clavicle and scapula, and of the shoulder-joint (altered from Bourguery). 1. Conoid ligament. 2. Trapezoid ligament. 3. Coraco-acromial ligament. 4. Suprascapular ligament. 5. Capsule of shoulder-joint. 6. Tendon of long head of biceps, entering the joint. 7. Tendon of subscapularis muscle. 8. Coraco-humeral ligament.

Joint with acromion : capsule,	<i>Acromio-clavicular articulation.</i> The articular surfaces of the clavicle and acromion process of the scapula are connected together by a <i>capsule</i> , which is thick above (superior ligament), but very thin below.
fibro-cartilage, and synovial sac.	An <i>interarticular fibro-cartilage</i> is sometimes present at the upper part of the joint ; and occasionally it forms a complete septum. If the fibro-cartilage is perfect, there are two <i>synovial cavities</i> in the joint ; if it is imperfect, there is only one. The joint should be opened to see the cartilage and the synovial sac.
Use of joint.	<i>Movements.</i> This articulation allows the scapula to change its position in relation to the clavicle when the former bone is moved, either in gliding over the surface of the thorax, or in being rotated with the elevation and depression of the arm.
Ligaments of scapula.	SCAPULAR LIGAMENTS. The <i>special ligaments</i> of the scapula are two in number, and extend from one point of the bone to another.
Posterior, and anterior—	The <i>suprascapular ligament</i> (⁴) is a narrow band stretching across the notch in the upper border of the scapula. By one end it is attached to the base of the coracoid process, and by the other to the border behind the notch. It converts the notch into a foramen, through which the suprascapular nerve passes.
formed of two pieces : use.	The <i>coraco-acromial ligament</i> (³) is triangular in form, and extends transversely between the acromion and the coracoid process. Externally it is inserted by its apex into the tip of the acromion ; and internally, where it is much wider, it is attached to all the outer border of the coracoid process, reaching backwards to the capsule of the shoulder-joint. The ligament consists usually of two thickened bands, anterior and posterior, with a thinner intervening part. It forms part of an arch above the shoulder-joint, which prevents the head of the humerus being displaced upwards.
Dissection.	<i>Dissection.</i> To lay bare the supraspinatus muscle, the acromion process is to be sawn through, and to be turned aside with the outer end of the clavicle ; but in a repetition of the dissection of the upper limb, the bone may be left uncut for the purpose of seeing the use of the coraco-acromial arch. A strong fascia covers the surface of the muscle ; this is to be taken away after it has been observed.
Supraspinatus : origin ; insertion ; relations ; and use.	The SUPRASPINATUS MUSCLE (fig. 78, A) has the same form as the hollow of the bone which it fills. It <i>arises</i> from the surface of the supraspinous fossa of the scapula, except over the neck, from the upper side of the spine of the bone, and from the fascia covering its surface. Its fibres end in a tendon, which crosses over the shoulder-joint, and is <i>inserted</i> into the upper impression on the great tuberosity of the humerus.
Dissection of supra-	The muscle is concealed by the trapezius and the acromion process ; and it rests upon the scapula, the suprascapular vessels and nerve, and the shoulder-joint. Its tendon joins that of the infraspinatus at the attachment to the humerus.
	<i>Action.</i> It comes into use with the acromial portion of the deltoid in raising the limb and supporting the joint.
	<i>Dissection</i> (fig. 83). The vessels and nerves on the dorsum of

the scapula can be traced by detaching from behind forwards the supraspinatus and infraspinatus muscles, so as to leave a thin layer of the fleshy fibres with the ramifying blood-vessels on the surface of the bone. In the supraspinous fossa are the suprascapular vessels and nerve, which are to be followed beneath the acromion to the infraspinous fossa ; and entering the infraspinous fossa, beneath the teres minor muscle, is the dorsal branch of the subscapular artery. The anastomosis between these vessels should be pursued in the fleshy fibres and cleaned.

The SUPRASCAPULAR ARTERY (*a*) is derived from the thyroid axis of the subclavian trunk (p. 70). After a short course in the neck it crosses over the suprascapular ligament, and passing beneath the supraspinatus muscle, ends in the infraspinous fossa, where it gives offsets to the infraspinatus muscle and the scapula, and anastomoses with the dorsal branch of the subscapular artery and the posterior scapular of the subclavian.

Before entering the supraspinous fossa, it gives a small branch to the ventral surface of the scapula ; and beneath the supraspinatus it furnishes offsets to that muscle, the bone, and the shoulder-joint.

The companion vein of the suprascapular artery joins the external jugular vein.

The SUPRASCAPULAR NERVE (¹) is a branch of the brachial plexus (p. 73). When it reaches the upper border of the scapula, it enters the supraspinous fossa beneath the suprascapular ligament. In the fossa it supplies two branches to the supraspinatus ; and it is continued beneath a fibrous band to the infraspinatus muscle, in which it ends.

The nerve gives some *articular* filaments to the shoulder-joint, and other offsets to the scapula.

The POSTERIOR SCAPULAR ARTERY runs along the base of the scapula beneath the rhomboid muscles, furnishing offsets to them and to the surfaces of the bone. It is more fully noticed with the dissection of the back (p. 388).

The DORSAL SCAPULAR ARTERY (*b*) is a branch of the subscapular (p. 254), and after giving off its infrascapular offset, turns round the axillary border of the bone opposite the posterior of the two spaces between the teres muscles. Entering the infraspinous fossa beneath the teres minor, it supplies that muscle and the infraspinatus, and anastomoses with the suprascapular and posterior scapular arteries. It sends a considerable branch downwards between the teres muscles, towards the lower angle of the bone.

SECTION III.

THE FRONT OF THE ARM.

- Position,** *Position.* For the dissection of the superficial vessels and nerves on the front of the arm the limb should lie flat on the table, with the anterior surface uppermost.
- and incisions in the skin.** *Dissection.* The skin is to be raised from the fore and hinder surfaces of the arm and elbow. To reflect it, make one incision along the centre of the limb as far as two inches below the bend of the elbow, and at the termination of this, a second cut half round the forearm. Strip now the skin from the limb as low as the transverse incision, so that the fat which contains the cutaneous vessels and nerves may be denuded. Between the skin and the prominence of the olecranon a bursa may be seen.
- Seek superficial veins.** The cutaneous veins (fig. 80) may be sought first in the fat: they are very numerous below the bend of the elbow, as they issue from beneath the integument. One in the centre of the forearm is the median vein, which bifurcates rather below the elbow. External to this is a small vein (radial); and internal to it are the anterior and posterior ulnar veins, coming from the front and back of the forearm. At the elbow these veins are united into two; one (basilic) is to be followed along the inner side, and the other (cephalic) along the outer side of the arm.
- Trace cutaneous nerves** The cutaneous nerves may be next traced out. Where they perforate the deep fascia they lie beneath the fat; and this layer must be scraped through to find them.
- of outer side,** On the outer side of the arm, about the middle, two external cutaneous branches of the musculo-spiral are to be sought. In the outer bicipital groove, in front of the elbow or rather below it, the cutaneous part of the musculo-cutaneous nerve will be recognised.
- and inner side of the limb.** On the inner part of the limb the nerves to the surface are more numerous. Taking the basilic vein as a guide, the internal cutaneous nerve of the forearm will be found by its side, about the middle of the arm; and a little external to this nerve is a small cutaneous offset from it, which pierces the fascia higher up. Scrape through the fat behind the internal cutaneous, in the lower third of the arm, for the small nerve of Wrisberg; and in the upper third, follow the small nerves which have been already met with in the dissection of the axilla, viz., the intercosto-humeral, and the internal cutaneous of the musculo-spiral.
- Superficial fat.** *Superficial fascia.* The subcutaneous fatty layer forms a continuous investment for the limb, but it is thicker in front of the elbow than in the other parts of the arm. At that spot it encloses the superficial vessels and lymphatics.
- Superficial veins.** **CUTANEOUS VEINS.** The position and relations of the veins in

front of the elbow are to be attentively noted by the dissector, because the operation of venesection is practised in one of them.

The MEDIAN VEIN of the forearm (fig. 80,²) divides into two Median vein branches, internal and external, rather below the bend of the elbow; and at its point of division it is joined by an offset from a deep vein. The internal branch (*median-basilic*) crosses to the inner border of the biceps, and unites with the ulnar veins (³) to form the basilic vein of the inner side of the arm. The external branch (*median-cephalic*) is usually longer than the other, and by its junction with the radial vein (⁷) gives rise to the cephalic vein of the arm.

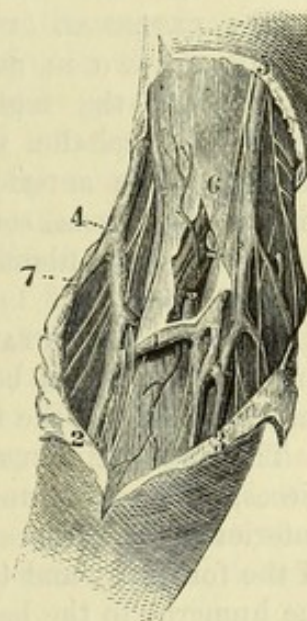
The MEDIAN-CEPHALIC VEIN is directed obliquely, and lies over the hollow between the biceps and the outer mass of muscles of the forearm; beneath it is the trunk of the musculo-cutaneous nerve. This vein is altogether removed from the brachial artery, and is usually smaller than the median-basilic vein. If opened with a lancet it does not generally yield much blood, in consequence of its position in a hollow between muscles rendering compression of it very uncertain and difficult.

The MEDIAN-BASILIC VEIN (¹) is more transverse in direction, and larger than the preceding; and it crosses the brachial artery. It is firmly supported by the underlying fascia,—the aponeurosis of the arm, strengthened by an offset from the biceps tendon, intervening between it and the brachial vessels. Branches of the internal cutaneous nerve lie beneath it, and some twigs of the same nerve are placed over it.

The median-basilic is the vein on which the operation of blood-letting is commonly performed. It is selected in consequence of its usually larger size, and more superficial position, and of the ease with which it may be compressed; but from its close proximity to the brachial vessels, the spot to be opened should not be immediately over the trunk of the artery.

The BASILIC VEIN (⁵), commencing as before said, ascends near the inner border of the biceps muscle to the middle of the arm, where it passes beneath the deep fascia, and is continued into the axillary vein. In this course it lies to the inner side of the brachial artery.

The CEPHALIC VEIN (²) is derived chiefly from the external



and of the median-basilic vein.

Venesection is practised in this branch.

* Cutaneous veins and nerves at the bend of the elbow. (Quain's "Arteries.") 1. Median-basilic vein. 2. Median vein of the forearm bifurcating. 3. Anterior ulnar veins. 4. Cephalic vein, formed by the radial from behind and the median-cephalic in front: the musculo-cutaneous nerve is beneath it. 5. Basilic vein, with the large internal cutaneous nerve by its side. 6. Brachial artery, with its companion veins (one cut). 7. Radial vein.

branch of the median, for the radial vein is oftentimes very small : it is continued to the shoulder along the outer side of the biceps, and sinks between the deltoid and pectoral muscles, near the clavicle, to open into the axillary vein.

Superficial lymphatics.

The *superficial lymphatics* of the arm lie for the most part along the basilic vein, and enter into the glands of the axilla. A few lymphatics accompany the cephalic vein, and end as the others in the axillary glands.

Glands.

One or more superficial lymphatic glands are commonly found a little above the inner condyle of the humerus.

Superficial nerves.

CUTANEOUS NERVES. The superficial nerves of the arm appear on the inner and outer sides, and spread so as to cover the surface of the limb. With one exception (intercosto-humeral) all are derived from the brachial plexus, either as distinct branches, or as offsets of other nerves. On the outer side of the limb are branches of the musculo-spiral and musculo-cutaneous nerves. On the inner side are two internal cutaneous nerves, large and small (from the plexus), a third internal cutaneous from the musculo-spiral, and the intercosto-humeral nerve.

External cutaneous nerves :

two from musculo-spiral ;

The EXTERNAL CUTANEOUS BRANCHES OF THE MUSCULO-SPIRAL NERVE are two in number, and appear at the outer side of the limb about the middle. The *upper* small one turns forwards with the cephalic vein, and reaches the front of the elbow, supplying the anterior part of the arm. The *lower* and larger pierces the fascia somewhat farther down, and after supplying some cutaneous filaments to the back of the arm, is continued to the forearm.

and musculo-cutaneous.

The MUSCULO-CUTANEOUS NERVE pierces the fascia in front of the elbow ; it lies beneath the median-cephalic vein, and divides into branches for the forearm.

Internal cutaneous nerves :

large

The INTERNAL CUTANEOUS NERVE perforates the fascia in two pieces, or as one trunk that divides almost directly into two. Its anterior branch passes beneath the median-basilic vein to the front of the forearm ; and the posterior winds over the inner condyle of the humerus to the back of the forearm.

A slender offset of the nerve pierces the fascia near the axilla, and reaches as far, or nearly as far, as the elbow : it supplies the integuments over the biceps muscle.

and small ;

The NERVE OF WRISBERG (small internal cutaneous) appears behind the preceding, and extends to the interval between the olecranon and the inner condyle of the humerus, where it ends in filaments over the back of the olecranon. The nerve gives offsets to the lower third of the arm on the inner and posterior surfaces, and joins above the elbow the posterior branch of the larger internal cutaneous nerve.

one from musculo-spiral ;

The INTERNAL CUTANEOUS BRANCH OF THE MUSCULO-SPIRAL NERVE, becoming subcutaneous in the upper third, winds to the back of the arm, and reaches nearly as far as the olecranon.

and intercosto-humeral.

The INTERCOSTO-HUMERAL NERVE, a branch of the second intercostal (p. 244), perforates the fascia near the axilla, and ramifies on

the inner side and posterior surface of the arm in the upper half. The size and distribution of this nerve depend upon the development of the small internal cutaneous and the offset of the musculospiral.

The DEEP FASCIA of the arm is a white shining membrane, which surrounds the limb, and sends processes between the muscles. Over the biceps muscle it is thinner than elsewhere. At certain points it receives accessory fibres from the subjacent tendons:—thus, in front of the elbow an offset from the tendon of the biceps joins it; and near the axilla the tendons of the pectoralis major, latissimus dorsi, and teres major send prolongations to it.

At the upper part of the limb the fascia is continuous with that of the axilla, and is prolonged over the deltoid and pectoral muscles to the scapula, clavicle, and chest. Below, it is continued to the forearm, and is connected to the prominences of bone around the elbow-joint, especially to the supracondylar ridges of the humerus, so as to give rise to the intermuscular septa of the arm.

Directions. As the back of the arm will not be dissected now, the skin may be replaced on it until the front has been examined. And to keep in place the vessels and nerves at the upper part of the limb, these should be tied together with string in their natural position to one another, and fastened to the coracoid process.

Position. The limb is still to lie on the back, but the shoulder is to be raised by means of a small block; and the scapula is to be fixed in such a position as to render tense the muscles. The inner surface of the arm is to be placed towards the dissector.

Dissection. The aponeurosis is to be reflected from the front of the arm by an incision along the centre, like that through the skin; and it is to be removed on the outer side as far as the outer supracondylar ridge of the humerus, but on the inner side rather farther back than the corresponding line, so as to lay bare part of the triceps muscle. In raising the fascia the knife must be carried in the direction of the fibres of the biceps muscle; and to prevent the displacement of the brachial artery and its companion nerves, fasten them here and there with stitches.

In front of the elbow is a hollow containing the brachial vessels; and into this the artery should be followed, to show its ending in the radial and ulnar trunks.

MUSCLES ON THE FRONT OF THE ARM. There are only three muscles on the front of the arm. The one along the centre of the limb is the biceps; and that along its inner side, reaching about half way down, is the coraco-brachialis. The brachialis anticus lies beneath the biceps. Some muscles of the forearm are connected to the inner and outer condyles of the humerus, and to the ridge above the outer condyle.

The BICEPS MUSCLE (fig. 81, ^s; 82, B) forms the prominence seen on the front of the arm. It is wider at the middle than at either end; and the upper end consists of two tendinous pieces of different lengths, which are attached to the scapula. The *short head* is the innermost, and *arises* from the tip of the coracoid process

Aponeurosis
of the arm

receives ac-
cessions
from
tendons;

disposition
above,

and below;

forms inter-
muscular
septa.

Directions
to be ob-
served.

Position of
limb.

Dissection
of muscles,

of vessels,

and of hol-
low of
elbow.

Position of
the muscles
of the arm.

Biceps has
a short and
long head.

Origin from
the scapula.

- in common with the coraco-brachialis muscle (fig. 77); and the *long head* is attached to the upper part of the head of the scapula, within the capsule of the shoulder-joint (fig. 93). Muscular fibres spring from each tendinous head, and meet to form a fleshy belly, which is somewhat flattened from before back. Inferiorly the biceps ends in a tendon, which is *inserted* into the tuberosity of the radius, having previously given off a slip to the fascia in front of the elbow.
- Insertion into radius.** The muscle is superficial except at the extremities. At the upper part it is concealed by the pectoralis major and deltoid muscles; and at the lower end the tendon dips into the hollow in front of the elbow. Beneath the biceps are the musculo-cutaneous nerve, the upper part of the humerus, and the brachialis anticus muscle.
- Parts covering it:** Its inner border is the guide to the brachial artery below the middle of the humerus, but above that spot the coraco-brachialis muscle intervenes between them. The connection of the long head of the biceps with the shoulder-joint, and the insertion of the muscle into the radius will be afterwards learnt.
- inner border is guide to the artery.**
- Use on radius, and the trunk,** *Action.* It bends the elbow-joint, and acts powerfully in supinating the radius. When the body is hanging by the hands it will apply the scapula firmly to the humerus, and will assist in raising the trunk.
- on humerus.** With the arm hanging and the radius fixed, the long head will assist the abductors in removing the limb from the side; and after the limb is abducted, the short head will aid in restoring it to the pendent position.
- Coraco-brachialis: origin;** The CORACO-BRACHIALIS (fig. 77, H) is partly concealed by the biceps, and extends to the middle of the arm. Its *origin* is fleshy from the tip of the coracoid process, and from the tendinous short head of the biceps. Its fibres become tendinous below, and are
- insertion;** *inserted* into a narrow mark on the inner side of the humerus, below the level of the deltoid: some of the fibres frequently end on an aponeurotic arch, which extends from the upper end of the humerus to the insertion of the muscle.
- and relations to surrounding parts.** The upper half of this muscle is beneath the pectoralis major (fig. 82); and its inner part projects beyond the short head of the biceps, forming a prominence in the axilla. Its insertion is covered by the brachial vessels and the median nerve. The coraco-brachialis lies over the subscapular muscle, the anterior circumflex vessels, and the tendons of the latissimus dorsi and teres major. Along the inner border are the large artery and nerves of the limb; and the musculo-cutaneous nerve perforates it.
- Use on limb.** *Action.* The coraco-brachialis moves forwards the arm, and adducts it to the thorax.
- Brachial artery extends to elbow.** The BRACHIAL ARTERY (fig. 81,⁴) is a continuation of the axillary trunk, and supplies vessels to the upper limb. It begins at the lower border of the teres major muscle, and terminates rather below the bend of the elbow, or opposite the neck of the radius, in two branches—radial and ulnar, for the forearm.
- Position to bone, and in the limb.** The vessel is internal to the humerus in the upper part of its course, but in front of the bone below the middle of the arm; and

its situation is indicated by the surface-depression along the inner border of the biceps and coraco-brachialis muscles.

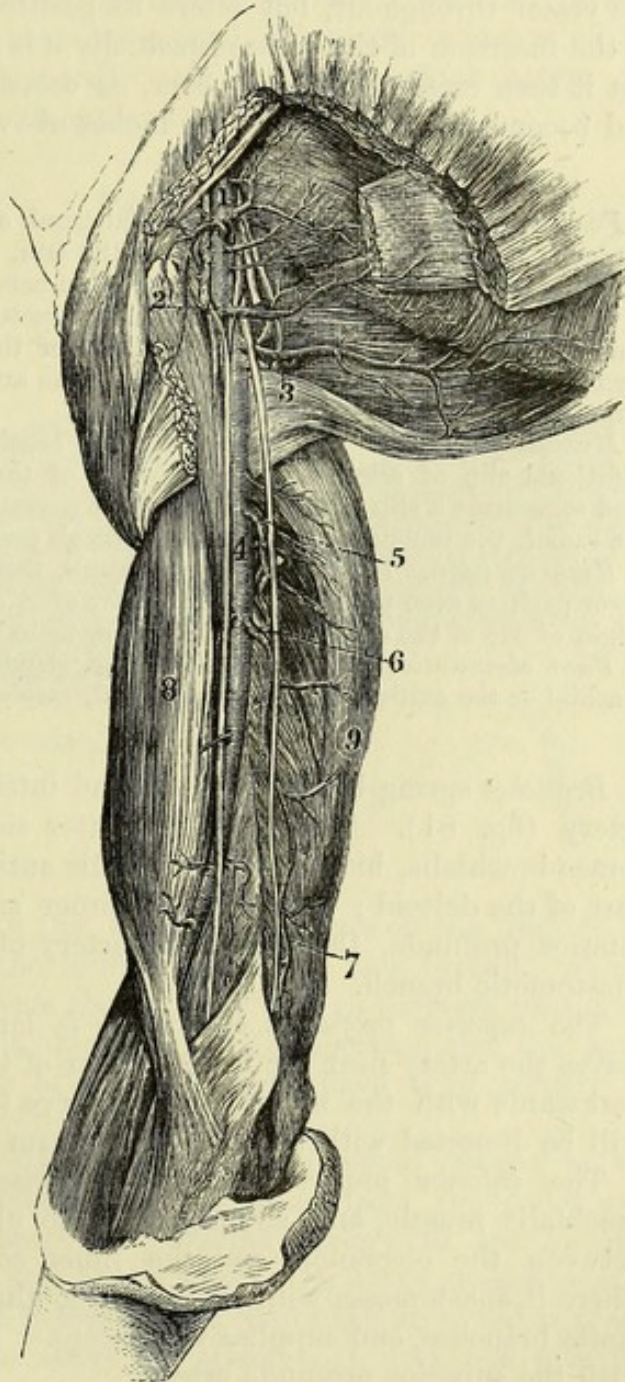
Throughout the arm the brachial artery is superficial, being covered only by the integuments and the deep fascia ; but at the bend of the elbow it becomes deeper, and is crossed by the pro-

longation from the tendon of the biceps. Posteriorly the artery has the following muscular connections (fig. 82) :—While it is inside the humerus it is placed over the long head of the triceps (F) for two inches, but separated partly by the musculo-spiral nerve and profunda vessels ; and over the inner head (G) of the same muscle for about an inch and a half. But when the vessel passes to the front of the bone, it lies on the insertion of the coraco-brachialis (c) and on the brachialis anticus (H). To the outer side are the coraco-brachialis and biceps muscles (c and B), the latter overlapping it.

Veins. Venæ comites lie along the sides of the artery (fig. 82, d), encircling it with cross branches, and the median-basilic vein crosses over it at the elbow.

The basilic vein is near the artery, on the inner side, above ; but it is superficial to the fascia in the lower half of the arm.

Fig. 81.*



and
muscles,

with veins,

* Axillary and brachial arteries. (Quain's "Arteries.") 1. Axillary artery and branches : the small branch above the figure is the superior thoracic, and the larger branch close below, the acromio-thoracic. 2. Long thoracic. 3. Subscapular. 4. Brachial artery. 5. Superior profunda branch. 6. Inferior profunda. 7. Anastomotic. 8. Biceps muscle. 9. Triceps muscle. The median and ulnar nerves are shown in the arm ; the median is close to the brachial artery.

and with
four nerves.

The *nerves* in relation with the artery are the following :—The internal cutaneous (fig. 82, ²) is in contact with the vessel until it perforates the fascia about the middle of the arm. The ulnar nerve (⁴) lies to the inner side as far as the insertion of the coraco-brachialis muscle ; and the musculo-spiral (fig. 72, ⁴) is behind for a distance of two inches. The median nerve (fig. 82, ¹) is close to the vessel throughout, but alters its position in this way :—as low as the insertion of the coraco-brachialis it is placed on the outer side, but it then crosses obliquely over, or occasionally under the artery, and becomes internal about two inches above the elbow-joint.

Deviation
in position ;

Peculiarity in position. The brachial trunk occasionally leaves the inner border of the biceps in the lower half of the arm, and courses along the inter-muscular septum, with or without the median nerve, to near the inner condyle of the humerus. At this spot the vessel is directed to its ordinary position in front of the elbow, beneath the upper fibres of the pronator teres, which has then a wide origin. In this unusual course the artery lies behind a projection (supracondylar process) of the humerus.

in muscular
covering.

Muscular covering. In some bodies the brachial artery is covered by an additional slip of origin of the biceps, or of the brachialis anticus muscle. And sometimes a slip of the brachialis may conceal, in cases of high origin of the radial, the remainder of the arterial trunk continuing to the forearm.

Artery
double.

High division. Instead of a single trunk, there may be two vessels in the lower part, or even the whole length of the arm, owing to an unusually high origin of one of the arteries of the forearm, more frequently the radial.

Aberrant
vessels.

Vasa aberrantia. Occasionally a long slender vessel passes from the brachial or the axillary trunk to the radial, rarely to the ulnar artery.

Its branches
are
muscular,

Branches spring both externally and internally from the brachial artery (fig. 81). Those on the outer side, *muscular*, supply the coraco-brachialis, biceps, and brachialis anticus, as well as the lower part of the deltoid ; those on the inner side are the superior and inferior profunda, the medullary artery of the humerus, and the anastomotie branch.

superior
profunda,

The *superior profunda branch* (⁵) is larger than the others, and leaves the artery near the lower border of the teres major ; it winds backwards with the musculo-spiral nerve to the triceps muscle, and will be dissected with the back of the arm (p. 281).

inferior
profunda,

The *inferior profunda branch* (⁶) arises opposite the coraco-brachialis muscle, and accompanies the ulnar nerve to the interval between the olecranon and the inner condyle of the humerus. There it anastomoses with the posterior ulnar recurrent and anastomotie branches, and supplies the triceps. It often arises in common with the superior profunda artery.

artery to
bone,

The *medullary artery of the humerus* begins near the preceding branch, and enters the aperture about the middle of the humerus, being directed downwards.

and anas-
tomotic.

The *anastomotie branch* (⁷) arises one or two inches above the elbow, and courses inwards through the intermuscular septum to the hollow between the olecranon and the inner condyle of the humerus. Here the artery anastomoses with the inferior profunda and posterior ulnar recurrent branches, and gives twigs to the

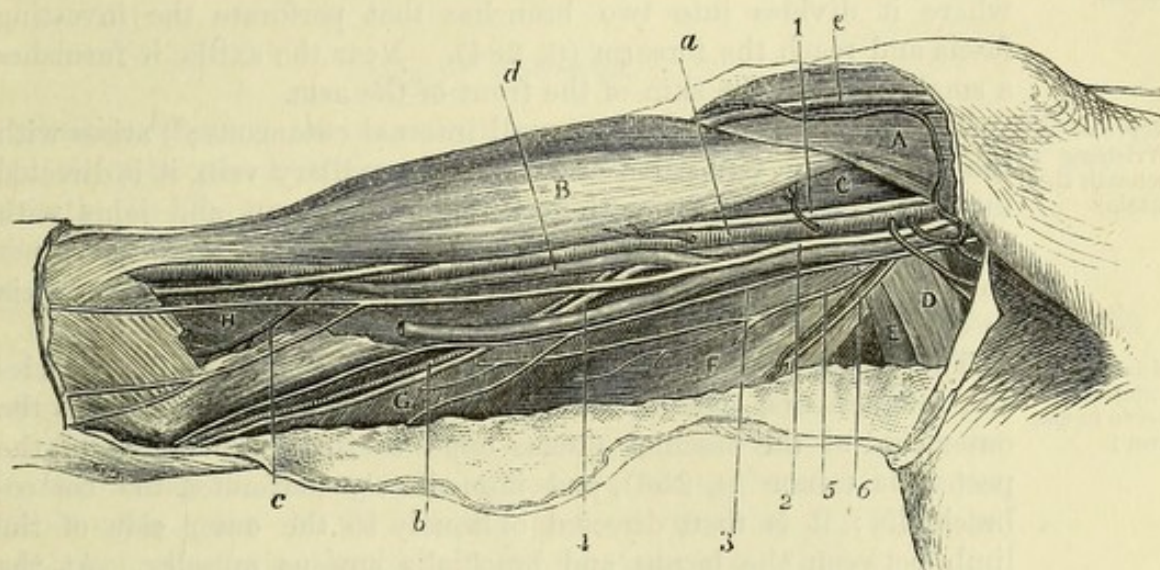
triceps muscle : one of the offsets forms an arch across the back of the humerus with a branch of the superior profunda.

In front of the elbow-joint the anastomotic branch sends an offset to the pronator teres muscle ; this joins the anterior ulnar recurrent branch.

The BRACHIAL VEINS (fig. 82, *d*) accompany the artery, one on each side, and have branches of communication across that vessel ; they receive tributary veins corresponding to the branches of the artery. Superiorly they usually join into one, which enters the axillary vein near the subscapular muscle.

Veins end in the axillary.

Fig. 82.*



NERVES OF THE ARM (fig. 82). The nerves on the front of the arm are derived from the terminal cords of the brachial plexus. Few of them furnish offsets above the elbow, as they are continued, for the most part without branching, to the forearm and the hand. The cutaneous branches of some of them have been already referred to (p. 272).

Nerves on front of arm.

The MEDIAN NERVE (1) arises from the brachial plexus by two heads, one from the outer, and the other from the inner cord (p. 256), and accompanies the brachial artery to the forearm. Beginning on the outer side of the artery, the nerve crosses over, or less frequently under, it below the middle of the arm, and is placed on the inner side a little above the elbow. It does not give any branch in the arm ; but there may be a fasciculus connecting it

Median nerve with the artery,

has not any branch.

* Dissection of the inner side of the arm. (Illustrations of Dissections.)
Muscles : A. Pectoralis major. B. Biceps. c. Coraco-brachialis. D. and E. Latissimus and teres. F. Long head, and G. Inner head of triceps. H. Brachialis anticus. *Vessels* : a. Brachial artery. b. Inferior profunda. c. Anastomotic. d. One of the venæ comites. *Nerves* : 1. Median. 2. Internal cutaneous. 3. Nerve of Wrisberg. 4. Ulnar. 5. Muscular to the triceps, and 6. Internal cutaneous from the musculo-spiral.

with the musculo-cutaneous nerve. Its relations to muscles are the same as those of the artery.

Ulnar nerve The ULNAR NERVE (¹), derived from the inner cord of the brachial plexus, lies at first close to the inner side of the axillary, and then of the brachial artery as far as the insertion of the coraco-brachialis : leaving now the blood-vessel, it is directed backwards through the inner intermuscular septum to the interval between the olecranon and the internal condyle, being surrounded by the muscular fibres of the triceps. There is not any branch from the nerve till it reaches the elbow-joint.

is without
branch as
far as the
elbow.

Internal
cutaneous
nerve be-
neath the
fascia.

The INTERNAL CUTANEOUS (²) is a tegumentary nerve of the forearm. Arising from the inner cord of the plexus, it is at first superficial to the brachial artery as far as the middle of the arm, where it divides into two branches that perforate the investing fascia and reach the forearm (p. 284). Near the axilla it furnishes a small offset to the skin of the front of the arm.

Nerve of
Wrisberg
beneath the
fascia.

The NERVE OF WRISBERG (small internal cutaneous ;³) arises with the preceding. Concealed at first by the axillary vein, it is directed inwards beneath (but sometimes through) that vein, and joins with the intercosto-humeral nerve. Afterwards it lies along the inner part of the arm as far as the middle, where it perforates the fascia to end in the integument (p. 272).

Musculo-
cutaneous
nerve in the
arm :

The MUSCULO-CUTANEOUS NERVE, named from supplying muscles and integuments, ends on the surface of the forearm. It leaves the outer cord of the brachial plexus opposite the lower border of the pectoralis minor (p. 256), and immediately perforates the coraco-brachialis : it is then directed obliquely to the outer side of the limb between the biceps and brachialis anticus muscles. At the front of the elbow it becomes a cutaneous nerve of the forearm.

its muscular
branches.

Branches. The nerve furnishes branches to the muscles of the front of the arm, viz., the coraco-brachialis as it passes through the fibres, and to the biceps and brachialis anticus where it is placed between them.

Dissection.

Dissection. The brachialis anticus muscle will be brought into view by cutting through the tendon of the biceps near the elbow, and turning upwards this muscle. The fascia and areolar tissue should be taken from the fleshy fibres ; and the lateral extent of the muscle should be well defined on each side, so as to show that it reaches the intermuscular septum largely on the inner side, but only for a short distance above on the outer side.

Define
brachialis.

Some care is required in detaching the brachialis externally from the muscles of the forearm, to which it is closely applied. As the muscles are separated the musculo-spiral nerve with a small artery comes into sight.

Brachialis
anticus :
origin ;

The BRACHIALIS ANTICUS (fig. 82, H) covers the elbow-joint and the lower half of the front of the humerus. It *arises* from the anterior surface of the humerus below the insertion of the deltoid muscle ; and from the intermuscular septa on the sides, viz., from all the inner, but from only the upper part of the outer. The fleshy fibres converge to a tendon, which is *inserted* into the impression on the front of the coronoid process of the ulna (p. 295).

insertion.

This muscle is for the most part concealed by the biceps. On it lie the brachial vessels, with the median, musculo-cutaneous, and musculo-spiral nerves. It covers the humerus and the articulation of the elbow. Its origin embraces by two slips the tendon of the deltoid; and its insertion is placed between two fleshy points of the flexor profundus digitorum. The inner border reaches the inter-muscular septum in all its length; but the outer is separated below from the external intermuscular septum by two muscles of the forearm, supinator longus and extensor carpi radialis longior.

Relations of surfaces,

of borders.

Action. The brachialis brings forwards the ulna towards the humerus, and bends the elbow-joint.

Use, forearm free,

If the ulna is fixed, as in climbing with the hands above the head, the muscle bends the joint by raising the humerus.

and fixed.

BACK OF THE ARM.

Position. During the examination of the back of the arm, the limb is to be raised in a semiflexed position by means of a block beneath the elbow. The scapula is to be brought nearly in a line with the humerus, so as to tighten the muscular fibres; and it is to be fastened with hooks in that position.

Position of the part.

Dissection (fig. 83). On the back of the arm there is one muscle, the triceps, beneath which are placed the musculo-spiral nerve and superior profunda vessels. The skin having been already reflected, the muscle will be laid bare readily, for it is covered only by fascia. To take away the fascia, carry an incision along the middle of the limb to the point of the elbow; and in reflecting it, the loose subaponeurotic tissue should be removed at the same time.

How to lay bare the triceps,

Separate the middle from the inner and outer heads of the muscle; and trace the musculo-spiral nerve and vessels beneath it. Define the outer head, which reaches down to the spot at which the musculo-spiral nerve appears on the outer side.

and separate pieces.

The TRICEPS MUSCLE (fig. 83) is divided superiorly into three heads of origin, inner, outer, and middle: two of these are attached to the humerus, and one to the scapula.

Triceps muscle has three heads.

The *middle* or *long head* (A) has a tendinous *origin*, about an inch wide, from the axillary margin of the scapula close to the glenoid cavity, where it is united with the capsule of the shoulder-joint. The *outer head* (B) is narrow and *arises* from the back of the humerus, extending from the root of the large tuberosity to the spiral groove. The *inner head* (C), fleshy and wide, *arises* from the posterior surface of the humerus below the spiral groove, reaching laterally to the intermuscular septa, and gradually tapering upwards as far as the insertion of the teres major. From the different heads the fibres are directed with varying degrees of inclination to a wide common tendon above the elbow. Inferiorly the muscle is *inserted* into the end of the olecranon process of the ulna, and gives an expansion to the aponeurosis of the forearm. Between the tip of the olecranon and the tendon is a small bursa.

Origin of middle head,

of outer head,

and of inner head.

Direction of the fibres.

Insertion.

Relations of
the muscle.

The triceps is superficial, except at the upper part where it is overlapped by the deltoid muscle. It lies on the humerus, and conceals the musculo-spiral nerve, the superior profunda vessels, and the articulation of the elbow. On the sides the muscle is united to the intermuscular septa; and the lower fibres are continuous externally with the anconeus—a muscle of the forearm.

Use.

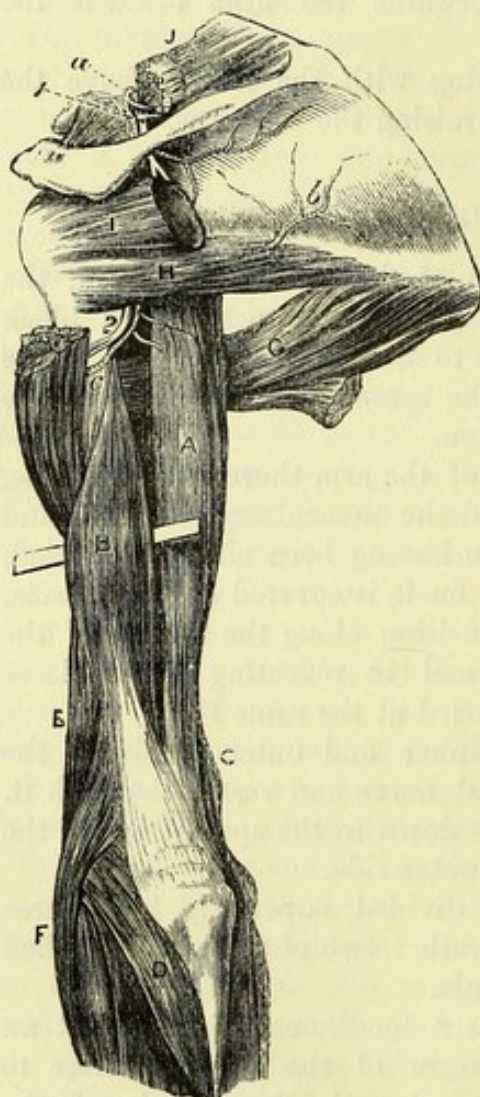
Action. All the pieces of the triceps combining in their action will bring the ulna into a line with the humerus, and extend the elbow-joint. As the long head passes the shoulder, it can depress the raised humerus, and adduct the bone to the thorax.

Fig. 83.*

Two inter-
muscular
septa :

an inner
and

an outer.



Dissection
of vessels
and nerve.

the condyle of the humerus: it is pierced by the musculo-spiral nerve and the accompanying vessels.

Dissection. To follow the superior profunda vessels and the musculo-spiral nerve, the middle head of the triceps should be cut across

* Dissection of the dorsal scapular vessels and nerve, and of the triceps muscle. *Muscles:* A. Long head of triceps. B. Outer head, with a bit of whalebone beneath it to mark the extent of its attachment down the humerus. C. Inner head. D. Anconeus. E. Supinator longus. F. Extensor carpi radialis longior. G. Teres major. H. Teres minor. I. Infraspinatus, cut across. J. Supraspinatus, cut through. *Arteries:* a. Suprascapular. b. Dorsal scapular. c. Posterior circumflex. *Nerves:* 1. Suprascapular. 2. Circumflex.

over them, and the fatty tissue should be removed. The trunks of the artery and nerve are to be afterwards followed below the outer head of the triceps to the front of the humerus.

To trace out the branches of the nerve and artery which descend to the olecranon and the anconeus muscle, the triceps is to be divided along the line of union of the outer with the middle head ; and the veins are to be cut away. Trace branches.

The SUPERIOR PROFUNDA branch of the brachial artery (p. 276) turns to the back of the humerus between the inner and outer heads of the triceps ; in this position it supplies branches to the triceps and deltoid muscles, and is continued onwards in the groove in the bone to the outer part of the arm, where it divides into its terminal offsets :—One of these, which is very small, courses on the musculo-spiral nerve to the front of the elbow, anastomosing with the recurrent radial branch ; while a larger one descends along the intermuscular septum to the elbow, and joins the radial and posterior interosseous recurrent branches. Superior profunda artery
lies behind the humerus ;

Branches. Most of the terminal offsets of the vessel descend to the elbow, supplying the triceps, and communicating with the inferior profunda and anastomotic branches of the brachial artery (p. 276), and with the recurrent branches of the arteries of the forearm except the anterior ulnar. One slender twig accompanies a branch of the musculo-spiral nerve, and ends in the anconeus muscle below the outer condyle of the humerus. supplies triceps, and forms a circle around joint :

Two or more *cutaneous offsets* arise on the outer side of the arm, and accompany the superficial nerves. cutaneous offsets.

The MUSCULO-SPIRAL NERVE (fig. 72,⁴) is the largest trunk of the posterior cord of the brachial plexus (p. 256), and is continued along the back and outer part of the limb to the hand. In the arm the nerve winds with the superior profunda artery beneath the triceps muscle. At the outer aspect of the arm it is continued between the brachialis anticus and supinator longus muscles to the external condyle of the humerus, in front of which it divides into the radial and posterior interosseous nerves (fig. 92,² and ³). The nerve gives muscular branches, and the following cutaneous offsets to the inner and outer sides of the limb. Musculo-spiral nerve winds
to outer side of the arm :
branches.

a. The *internal cutaneous branch* of the arm (fig. 82,⁶) is of small size, and arises in the axillary space in common with the branch to the inner head of the triceps ; it is directed across the posterior boundary of the axilla to the inner side of the arm, where it becomes cutaneous in the upper third, and is distributed as before said (pp. 272 and 284). Internal cutaneous branch.

b. The *external cutaneous branches*, springing at the outer side of the limb, are two in number : they are distributed in the integuments of the arm and forearm (p. 272). Two external cutaneous.

c. The *muscular branches* to the triceps are numerous, and supply all three heads. One slender offset for the inner head arises in common with the internal cutaneous branch, and descends close to the ulnar nerve to enter the muscular fibres at the lower third of the arm. Another long and slender branch behind the humerus, appear- Branches to the triceps
and anconeus,

ing as if it ended in the triceps, can be followed downwards to the anconeus muscle.

brachialis
antecus
and muscles
of forearm.

d. On the outer side of the limb the musculo-spiral nerve supplies the brachialis antecus in part, and two muscles of the forearm, viz., supinator longus and extensor carpi radialis longior.

Directions.

Directions. As the dissection of the arm has been completed as far as the elbow, it will be advisable to keep moist the shoulder-joint until it is examined with the other ligaments.

SECTION IV.

THE FRONT OF THE FOREARM.

Position of
the limb.

Position. The limb is to be placed with the palm of the hand uppermost; and the marking of the surface and the projections of bone are first to be noted

Surface of
the forearm.

Surface-marking. On the anterior aspect of the forearm are two lateral depressions, corresponding with the position of the main vessels. The external is placed over the radial artery, and inclines towards the middle of the limb as it approaches the elbow. The internal groove is evident only below the middle of the forearm, and points out the place of the ulnar artery.

Bony pro-
jections.

The bones (radius and ulna) are sufficiently near the surface to be traced in their whole length: each ends below in a point—the styloid process; and that of the radius is the lower. A transverse line separates the forearm from the hand, and the articulation of the wrist is about three-quarters of an inch above it.

Line of the
wrist-joint.

Surface of
palm of the
hand.

On each side of the palm of the hand is a large projection; the external of these (thenar) is formed by muscles of the thumb, and the internal (hypothenar) by muscles of the little finger. At the upper end of the latter the prominent pisiform bone is easily felt; and towards the outer side of the wrist, below the end of the radius, the tuberosity of the scaphoid bone is to be recognized. Between the muscular eminences is the hollow of the palm, which is pointed towards the wrist. Two transverse lines are seen in the palm, but neither reaches completely across it: they result from the bending of the fingers at the metacarpo-phalangeal articulations, but the lower one is nearly half an inch above the three inner joints when the fingers are extended.

Position of
palmar arch.

The position of the superficial palmar arch of arteries is marked by the middle third of a line across the palm from the root of the thumb, when that digit is placed at a right angle to the hand.

Surface of
the fingers.

Transverse lines on the palmar aspects of the thumb and fingers correspond to the articulations of the phalanges; but while the middle and lower ones are nearly opposite (about a line above) the two interphalangeal articulations, the upper one is fully half an inch below the metacarpo-phalangeal joint.

Dissection

Dissection. With the limb lying flat on the table, an incision is to

be carried through the skin along the middle of the front of the forearm, as far as an inch beyond the wrist; and at its termination a transverse one is to cross it. The skin is to be reflected carefully from the front and back of the forearm, without injury to the numerous superficial vessels and nerves beneath; and it should be taken also from the back of the hand, by prolonging the ends of the transverse cut along each margin to a little beyond the knuckles. The whole of the fore finger should have the integument removed from it, in order that the nerves may be followed to the end.

The superficial vessels and nerves can be now traced in the fat; they have the following position, and most of them have been partly dissected:—Along the inner side, with the ulnar veins, is the continuation of the internal cutaneous nerve; and near the wrist there is occasionally a small offset from the ulnar nerve. On the outer side, with the radial vein, is the superficial part of the musculocutaneous nerve.

Close to the hand, in the centre of the forearm, and inside the tendon of the flexor carpi radialis which can be rendered prominent by extending the wrist, the small palmar branch of the median nerve should be sought beneath the fat. On the ulnar artery, close outside the pisiform bone, a small palmar branch of the ulnar nerve is to be looked for.

At the back of the forearm the large external cutaneous branch of the musculo-spiral nerve is to be traced onwards; and offsets are to be followed to this surface from the nerves in front.

On the posterior part of the hand is a plexus of superficial veins. Winding back below the ulna is the dorsal branch of the ulnar nerve; and lying along the outer border of the hand is the radial nerve: these should be traced to the fingers.

CUTANEOUS VEINS. The superficial veins are named median, radial, and ulnar, from their position in the limb.

DORSAL PLEXUS OF THE HAND. This network receives the superficial veins from both surfaces of the fingers; and from it, on the outer and inner sides, the radial and posterior ulnar veins proceed.

The **RADIAL VEIN** begins in the outer part of the plexus above mentioned, and in some small radicles at the back of the thumb. It is continued along the forearm, at first behind and then on the outer border as far as the elbow, where it gives rise to the cephalic vein by its union with the outer branch of the median vein (fig. 80, 7). In many bodies a considerable branch passes from the lower part of the radial vein to join the median vein on the front of the forearm.

The **ULNAR VEINS** are anterior and posterior, and occupy the ulnar, front and back of the limb:—

The *anterior* begins near the wrist by the junction of small roots from the hand, and runs on the inner part of the forearm to the elbow, where it opens either into the median-basilic or posterior ulnar vein (fig. 80, 3).

The *posterior ulnar vein* arises from the inner part of the dorsal plexus of the hand, and is continued along the back of the forearm

to remove
the skin.

Seek the
superficial
vessels and
nerves in
front,

and on the
back of the
hand.

Subcutaneous veins:

plexus on
the hand;

radial;

and poste-
rior;

nearly to the elbow; here it bends forwards to join the inner branch of the median and form the basilic vein.

median. The MEDIAN VEIN takes origin near the wrist by small branches which are derived from the palmar surface of the hand. It is directed along the centre of the forearm nearly to the elbow, and there divides into median-basilic and median-cephalic, which unite, as before seen (fig. 80,²), with the radial and ulnar veins. At its point of bifurcation the median receives a large communicating branch from the deep veins beneath the fascia.

Superficial nerves of forearm and back of hand are— CUTANEOUS NERVES. Some of the superficial nerves of the forearm are continued from the arm:—those on the inner side from the large internal cutaneous nerve; and those on the outer, from the lower external cutaneous branch of the musculo-spiral, and the musculo-cutaneous. On the fore part of the limb there is occasionally a small offset of the ulnar nerve near the wrist. On the back of the hand is the termination of the radial nerve, together with the dorsal branch of the ulnar nerve.

internal cutaneous; The INTERNAL CUTANEOUS NERVE (p. 272) is divided into two. The *anterior branch* extends on the front of the forearm as far as the wrist, and supplies the integuments on the inner half of the anterior surface. Near the wrist it communicates sometimes with a cutaneous offset from the ulnar nerve. The *posterior branch* continues along the back of the forearm (ulnar side) to the lower part.

external cutaneous; The MUSCULO-CUTANEOUS NERVE (cutaneous part; p. 278) is prolonged on the radial border of the limb to the ball of the thumb, over which it terminates in cutaneous offsets. Near the wrist the nerve is placed over the radial artery, and some twigs pierce the fascia to ramify on the vessel, and supply the carpal articulations. A little above the middle of the forearm the nerve sends backwards a branch to the posterior aspect, which reaches nearly to the wrist, and communicates with the radial and the following cutaneous nerve.

external cutaneous of musculo-spiral; The EXTERNAL CUTANEOUS BRANCH OF THE MUSCULO-SPIRAL NERVE (p. 272) descends along the hinder part of the forearm as far as the wrist. Near its termination it joins the preceding nerve.

radial nerve, The RADIAL NERVE ramifies in the integument of the back of the hand and some of the digits. It becomes cutaneous at the outer border of the forearm in the lower third, and after giving some filaments to the posterior aspect of the limb, divides into two branches:—

ending by external and One (external) is joined by the musculo-cutaneous nerve, and is distributed on the radial border and the ball of the thumb.

internal branches, The other branch (internal) supplies the remaining side of the thumb, both sides of the next two digits, and half the ring finger; so that the radial nerve distributes the same number of digital branches to the dorsum as the median nerve furnishes to the palmar surface. This portion of the radial nerve communicates with the musculo-cutaneous and ulnar nerves; and the offset to the contiguous sides of the ring and middle fingers is joined by a twig from the dorsal branch of the ulnar nerve.

which supply digits;

The DORSAL BRANCH OF THE ULNAR NERVE gives offsets to the rest of the fingers and the back of the hand. Appearing by the styloid process of the ulna, it joins the radial nerve in an arch across the back of the hand, and is distributed to both sides of the little finger, and to the ulnar side of the ring finger: it communicates with the part of the radial nerve furnished to the space between the ring and middle fingers; and sometimes it supplies this space entirely.

and branch
of ulnar
nerve to
back of
hand and
fingers.

The dorsal digital nerves are much smaller than those on the palmar aspect, and cannot be followed on the fingers farther than the base of the second phalanx. On the sides of the finger each communicates with an offset from the palmar nerve.

Extent of
nerves on
fingers.

The APONEUROSIS of the forearm is continuous with the similar investment of the arm. It is of a pearly white colour, and is formed of fibres which cross obliquely. The membrane is thicker behind than in front, and is stronger near the elbow than towards the wrist. At the upper part it receives fibres from the tendon of the biceps in front, and of the triceps behind; and it gives origin to the muscles springing from the condyles of the humerus. Longitudinal white lines indicate the position of deep processes (intermuscular septa), which separate the muscles, and give origin to their fleshy fibres. On the back of the forearm the fascia is attached to the hinder border of the ulna, and to the margins of a triangular surface at the upper end of that bone, which is left subcutaneous.

Deep fascia
of forearm.

At the wrist the fascia joins the anterior annular ligament; and near that band the tendon of the palmaris longus pierces it, and receives a sheath from it. Close to the pisiform bone there is an aperture through which the ulnar vessels and nerve enter the fat of the hand. Behind the wrist it is thickened by transverse fibres, giving rise to the posterior annular ligament; but on the back of the hand and fingers the fascia becomes very thin.

At the
wrist;

posterior
annular
ligament.

Dissection. The skin is to be replaced on the back of the forearm and hand, in order that the denuded parts may not become dry. Beginning the dissection on the anterior surface of the limb, let the student divide the aponeurosis as far as the wrist, and take it away with the cutaneous vessels and nerves, except the small palmar cutaneous offsets of the median and ulnar nerves near the hand. In cleaning the muscles it will be impossible to remove the aponeurosis from them at the upper part of the forearm without cutting the muscular fibres.

Take away
fascia,
nerves, and
veins.

In front of the elbow is the hollow, already partly dissected, between the two masses of muscles arising from the inner and outer sides of the humerus. The space should be carefully cleaned, so as to display the brachial and forearm vessels, the median nerve and branches, the musculo-spiral nerve, and the recurrent radial and ulnar arteries.

Clean out
hollow of
elbow.

In the lower half of the forearm a large artery, radial, is to be laid bare along the outer border; and at the inner side, close to the annular ligament, the trunk of the ulnar artery will be recognised as it becomes superficial. These vessels and their branches should

be carefully cleaned ; and the adjoining muscles may be fixed with stitches to prevent their displacement.

Define
anterior
annular
ligament.

The anterior annular ligament of the wrist, which arches over the tendons passing to the hand, is next to be defined. This strong band is at some depth from the surface ; and while the student removes the fibrous tissue superficial to it, he must take care of the small branches of the median and ulnar nerves to the palm of the hand. The ulnar vessels and nerve pass over the ligament, and will serve as a guide to its depth.

Hollow in
front of the
elbow.

HOLLOW IN FRONT OF THE ELBOW (fig. 84). This hollow is situate between the inner and the outer muscles of the forearm, and is somewhat triangular in shape, with the wider part towards the humerus.

Boundaries.

It is bounded on the outer side by the supinator longus muscle, and on the inner side by the pronator teres. The aponeurosis of the limb is stretched over the space ; and the bones, covered by the brachialis anticus and supinator brevis, form the deep boundary.

Contents of
the space,

Contents. In the hollow are lodged the termination of the brachial artery, with its veins, and the median nerve ; the musculo-spiral nerve ; the tendon of the biceps muscle ; and small recurrent vessels, with much fat and a few glands.

and their
position to
one another.

These several parts have the following relative position :—The tendon of the biceps is directed towards the outer boundary to reach the radius ; and on the outer side, concealed by the supinator longus muscle, is the musculo-spiral nerve. Nearly in the centre of the space are the brachial vessels and the median nerve, the nerve being internal ; but as the artery is inclined to the outer side of the limb, they soon become distant from one another about half an inch. The brachial artery divides here into two trunks—radial and ulnar ; and the recurrent radial and ulnar branches appear in the space—the former on the outer, and the latter on the inner side.

Lymphatic
glands.

Two or three lymphatic glands lie on the sides of the artery, and one below its point of splitting.

MUSCLES ON THE FRONT OF THE FOREARM (fig. 84). The muscles on the front of the forearm are divided into a superficial and a deep group.

Superficial
group
contains
five muscles.

In the superficial group there are five muscles, which are fixed to the inner condyle of the humerus by a common tendon, and lie in the undermentioned order from the outer to the inner side ;—pronator radii teres, flexor carpi radialis, palmaris longus, flexor carpi ulnaris ; and deeper and larger than any of these is the flexor sublimis digitorum.

The deep group will be met with in a subsequent dissection (p. 293).

Pronator
teres :

origin ;

insertion.

The PRONATOR RADII TERES (fig. 84,³) *arises* from the inner condyle of the humerus by the common tendon ; from the ridge above the condyle by fleshy fibres ; from the inner edge of the coronoid process by a second tendinous slip ; and from the fascia, and the septum between it and the next muscle. It is *inserted* by a flat tendon into an impression, an inch in length, on the middle of the outer surface of the radius.

The muscle is superficial except at the insertion, where it is covered by the radial artery, and some of the outer set of muscles, viz., supinator longus, and radial extensors of the wrist. The pronator forms the inner boundary of the triangular space in front of the elbow; and its inner border touches the flexor carpi radialis. By gently separating the muscle from the rest, it will be found to lie on the brachialis anticus, the flexor sublimis digitorum, and the ulnar artery and the median nerve: the second small head of origin intervenes between the artery and nerve.

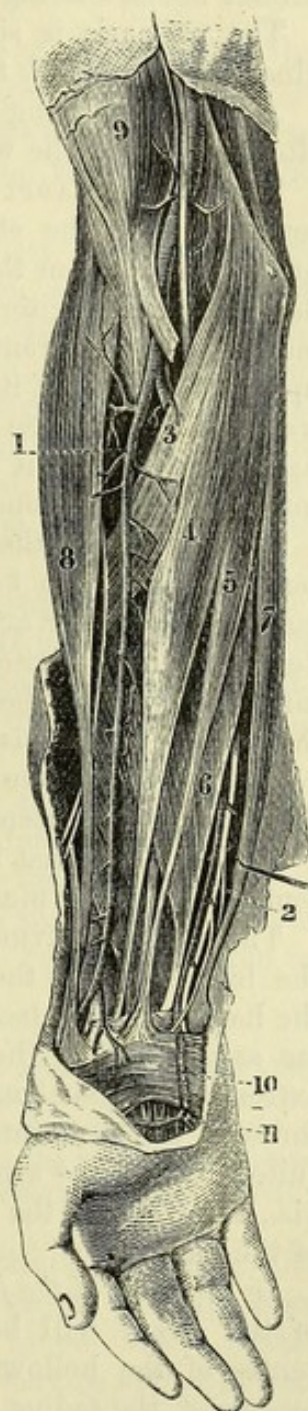
Action. The pronator assists in bringing forwards the radius over the ulna, so as to pronate the hand. When the radius is fixed, the muscle raises that bone towards the humerus, bending the elbow-joint.

The FLEXOR CARPI RADIALIS (fig. 84, *) takes its *origin* from the common tendon, from the aponeurosis of the limb, and from the intermuscular septum on each side. The tendon of the muscle, becoming free from fleshy fibres about the middle of the forearm, passes through a groove in the trapezium, in a special sheath at the outer side of the anterior annular ligament, to be inserted mainly into the base of the metacarpal bone of the index finger, and by a slip into that of the middle finger (p. 306).

The muscle rests chiefly on the flexor sublimis digitorum; but near the wrist it lies over the flexor longus pollicis,—a muscle of the deep group. As low as the middle of the forearm the flexor carpi radialis corresponds externally with the pronator teres, and below that with the radial artery, to which its tendon is taken as the guide. The ulnar border is in contact at first with the palmaris longus muscle, and for about two inches above the wrist, with the median nerve.

Action. The hand being free, the muscle first flexes the wrist-joint, inclining the hand somewhat to the radial side; and it will assist in bringing forwards the lower end of the radius in pronation. Still continuing to contract, it bends the elbow.

Fig. 84.*



Use on
radius
and elbow.

Radial
flexor of
the wrist.

The muscle
is super-
ficial;
is the guide
to radial
artery.

Use on wrist
and radius.

* Superficial view of the forearm. (Quain's "Arteries.") 1. Radial artery with its nerve outside. 2. Ulnar artery and nerve. 3. Pronator teres. 4. Flexor carpi radialis. 5. Palmaris longus. 6. Flexor sublimis digitorum. 7. Flexor carpi ulnaris. 8. Supinator longus. 9. Biceps.

Long palmar muscle	The PALMARIS LONGUS (fig. 84, ⁵) is sometimes absent; or it may present great irregularity in the proportion between the fleshy and tendinous parts. It <i>arises</i> , like the preceding muscle, from the common tendon, the fascia, and the intermuscular septa. Its slender tendon is continued along the centre of the forearm; and piercing the aponeurosis, it passes over the annular ligament to end in the palmar fascia, sending a slip to the abductor muscle of the thumb.
lies over annular ligament and joins fascia of palm.	
	The palmaris is situate between the flexor carpi radialis and ulnaris, and rests on the flexor sublimis digitorum.
Use.	<i>Action.</i> Rendering tense the palmar fascia, the palmaris will afterwards bend the wrist and elbow, like the last muscle.
Flexor carpi ulnaris:	The FLEXOR CARPI ULNARIS (fig. 84, ⁷) <i>arises</i> by a narrow slip in common with the other muscles from the inner condyle of the humerus, and from the intermuscular septum between it and the flexor sublimis digitorum; and by a broad aponeurosis from the inner margin of the olecranon and the posterior border of the ulna for the upper two-thirds of its length. The fibres pass downwards and forwards to a tendon on the anterior aspect of the muscle in the lower half, some joining it as low as the wrist; and the tendon is <i>inserted</i> into the pisiform bone.
origin by two heads;	
insertion into pisiform bone.	
Adjacent parts.	One surface of the muscle is in contact with the fascia; and its tendon, which can be felt readily through the skin, serves as the guide to the ulnar artery. To its radial side are the palmaris and flexor sublimis digitorum muscles. When the attachment to the inner condyle has been divided, the muscle will be seen to conceal the flexor profundus digitorum, the ulnar nerve, and the ulnar vessels: between the attachments to the condyle and the olecranon the ulnar nerve enters the forearm.
Use.	<i>Action.</i> The wrist is bent, and the hand is drawn inwards by the contraction of the muscle.
Course and extent of the radial artery.	The RADIAL ARTERY (fig. 84, ¹) is one of the vessels derived from the bifurcation of the brachial trunk, and extends to the palm of the hand. It is placed first along the outer side of the forearm as far as the end of the radius; next it winds backwards below the extremity of that bone; and finally it enters the palm of the hand through the first interosseous space. In consequence of this circuitous course the artery will be found in three different dissections, viz., the front of the forearm, the back of the wrist, and the palm of the hand.
Situation in the forearm.	<i>In the front of the forearm.</i> In this region of the limb the position of the artery will be marked on the surface by a line from the centre of the hollow of the elbow to the fore part of the styloid process of the radius. This vessel is smaller than the ulnar artery, though it appears in direction to be the continuation of the brachial trunk. It is partly deep and partly superficial; and where it is superficial, it can be felt beating as the pulse near the wrist during life.
Relations to muscles:	In its <i>upper half</i> the vessel is placed beneath the supinator longus (⁸); and it rests successively on the following muscles,—the tendon of the biceps (⁹), the fleshy supinator brevis, the pronator teres (³), and part of the thin origin of the flexor sublimis (⁶).
in upper half,	

In its *lower half* the artery is superficial, being covered only by the integuments and the deep fascia. Here it is placed in a hollow between the tendons of the supinator longus ⁽⁸⁾ and flexor carpi radialis ⁽⁴⁾. It lies from above down on the origin of the flexor sublimis, on two muscles of the deep group, viz., flexor longus pollicis and pronator quadratus, and lastly on the end of the radius.

Veins. Venæ comites lie on the sides, with cross branches over to veins; the artery.

Nerve. The radial nerve is on the outer side of the artery in the upper two-thirds of the forearm, but is separated from the vessels by a slight interval near the elbow. In the lower third the nerve passes backwards and becomes superficial behind the tendon of the supinator longus.

Branches. The radial artery in this part of its course furnishes many unnamed muscular and cutaneous offsets, and three named branches, viz., recurrent radial, superficial volar, and anterior carpal.

a. The *radial recurrent* is the first branch, and supplies the muscles on the outer side of the limb. Its course is almost transverse to the supinator longus, beneath which it terminates in that muscle and the two radial extensors of the wrist. One offset ascends beneath the supinator, and anastomoses with the superior profunda branch of the brachial artery.

b. The *superficial volar branch* (fig. 87, c) is very variable in size, and arises near the lower end of the radius. It is directed towards the palm of the hand, across or through the mass of muscles in the ball of the thumb; and it either ends in those muscles, or joins the superficial palmar arch.

c. The *anterior carpal branch* is very small, and will be seen in the examination of the deep muscles. Arising rather above the end of the radius, it passes transversely inwards at the lower border of the pronator quadratus, and anastomoses with a similar branch from the ulnar artery: from the arch thus formed, offsets are given to the carpus.

Peculiarities of the radial artery. When the radial arises high in the arm, its course is close to the brachial artery, along the edge of the biceps muscle; and in passing the bend of the elbow it is occasionally subcutaneous, i.e., above the deep fascia, and liable to injury in venesection. In the forearm the artery may likewise be subcutaneous, and superficial to the supinator longus muscle.

Dissection. To bring into view the flexor sublimis digitorum, the flexor carpi radialis and palmaris longus must be cut through near the inner condyle of the humerus, and turned to one side. Small branches of the ulnar artery and median nerve may be seen entering the under surfaces of those muscles. For the present, the pronator teres may be left uncut.

The FLEXOR SUBLIMIS DIGITORUM (flex. perforatus; fig. 84, ⁶) is the largest of the superficial muscles, and is named from its position to another flexor in the deep set. It arises in common with the foregoing muscles from the inner condyle of the humerus and the intermuscular septa, also from the internal lateral ligament of the

	elbow-joint and the inner margin of the coronoid process of the ulna; and by a thin layer from the oblique line of the radius, as well as frequently from the anterior border of that bone for a distance of one or two inches below the insertion of the pronator teres. Below the middle of the forearm the muscle ends in four tendons, which are continued beneath the annular ligament and through the hand, to be <i>inserted</i> into the middle phalanges of the fingers, after being perforated by the tendons of the deep flexor.
Insertion.	
Relations.	The flexor sublimis is in great part concealed by the other muscles of the superficial group; and the radial vessels lie on the attachment to the radius. Along the inner border is the flexor carpi ulnaris, with the ulnar vessels and nerve. The tendons of the muscle are arranged in pairs before they pass beneath the annular ligament of the wrist;—the middle and ring finger tendons being anterior, and those of the index and little finger posterior in position. On dividing the condylar and coronoid attachments, the muscle will be seen to cover two deep flexors (flexor profundus digitorum and flexor longus pollicis), the median nerve, and the upper part of the ulnar artery.
Use on fingers,	<i>Action.</i> This flexor bends first the middle and then the proximal joints of the fingers; but when the first phalanges are fixed by the extensor of the fingers, the superficial flexor moves the second phalanges alone.
on elbow and wrist.	After the fingers are bent the muscle will help in flexing the wrist and elbow-joints.
Ulnar artery ends in palm of hand.	THE ULNAR ARTERY (fig. 85, g) is the larger of the two branches coming from the bifurcation of the brachial trunk, and is directed along the inner side of the limb to the palm of the hand, where it forms the superficial palmar arch, and supplies most of the fingers. In the forearm the vessel has an arched direction; and its depth from the surface varies in the first and last parts of its course.
Course in upper half; and relations to muscles:	In the <i>upper half</i> the artery is inclined obliquely inwards from the centre of the elbow to the inner side of the limb. It courses between the superficial and deep muscles, being covered by the pronator teres, flexor carpi radialis, palmaris longus, and flexor sublimis. Beneath it lie the brachialis anticus for a short distance, and the flexor profundus (c).
in lower half; relations to muscles.	In the <i>lower half</i> it has a straight course to the pisiform bone, and is covered by the integuments and fascia, and by the flexor carpi ulnaris. To the outer side are the tendons of the flexor sublimis. Beneath it is the flexor profundus (c).
Venæ comites.	<i>Veins.</i> Two veins accompany the artery, and are united across it at intervals.
Nerves in relation.	<i>Nerves.</i> The median nerve ⁽¹⁾ lies to the inner side of the vessel for about an inch, but then crosses over it to gain the outer side, the coronoid head of the pronator teres being placed between the two. Rather above the middle of the forearm the ulnar nerve ⁽⁴⁾ reaches the artery, and continues thence on the inner side; and a small branch ⁽⁵⁾ , sending twigs around the artery, courses on it to the palm of the hand.

On the *annular ligament* the artery has passed through the fascia, and lies close to the pisiform bone. The ulnar nerve, with its palmar branch, still accompanies the vessel on the inner side.

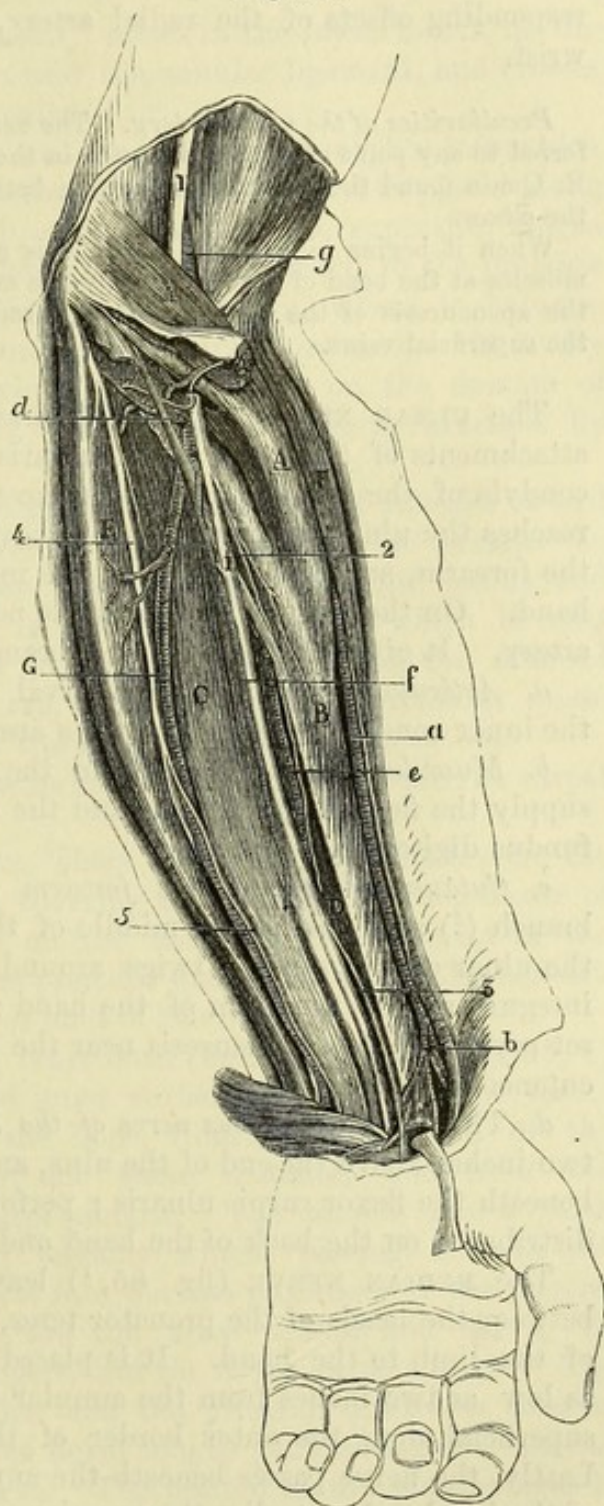
Branches. The greater number of the offsets of the artery are distributed to the muscles. Its named branches are the following :—

a. The *anterior ulnar recurrent branch* frequently arises in common with the next, and ascends on the brachialis anticus muscle, to join the branch of the anastomotic artery beneath the pronator teres. It gives offsets to the contiguous muscles.

b. The *posterior ulnar recurrent branch* (d), of larger size than the anterior, is directed beneath the flexor sublimis muscle to the interval between the inner condyle and the olecranon. There it passes with the ulnar nerve between the attachments of the flexor carpi ulnaris, and joins the ramifications of the inferior profunda and anastomotic arteries on the inner side of the elbow-joint. Some of its offsets enter the muscles, and others supply the articulation and the ulnar nerve.

c. The *interosseous artery* is a short thick trunk, which is directed backwards towards the interosseous membrane, and divides into anterior and posterior branches: the two divisions will be afterwards followed.

Fig. 85.*



Position on the annular ligament.

Its branches are muscular,

anterior and

posterior recurrent

interosseous,

* Dissection of the deep muscles of the forearm, and of the vessels and nerves between the two groups of muscles. (Illustrations of Dissections.)
Muscles: A. Pronator teres. B. Flexor longus pollicis. C. Flexor profundus digitorum. D. Pronator quadratus. E. Flexor carpi ulnaris. *Arteries:*

metacarpal, *d.* The *metacarpal branch* arises from the artery near the lower end of the ulna, and runs along the metacarpal bone of the little finger, of which it is the inner dorsal branch.

and carpal. *e.* The *carpal branches* (anterior and posterior) ramify on the front and back of the carpus, on which they anastomose with corresponding offsets of the radial artery, and form arches across the wrist.

The origin *Peculiarities of the ulnar artery.* The *origin* of the artery may be transferred to any point of the main vessel in the arm or axilla. In one instance R. Quain found the ulnar artery arising between two and three inches below the elbow.

and course may vary. When it begins higher than usual, it is generally superficial to the flexor muscles at the bend of the elbow (only one exception, R. Quain), but beneath the aponeurosis of the forearm; though sometimes it is subcutaneous with the superficial veins.

Ulnar nerve in the forearm. The ULNAR NERVE (fig. 85,⁴) enters the forearm between the attachments of the flexor carpi ulnaris to the olecranon and inner condyle of the humerus. Under cover of that muscle the nerve reaches the ulnar artery somewhat above the middle (in length) of the forearm, and is continued on the inner side of the vessel to the hand. On the annular ligament the nerve is rather deeper than the

artery. It gives off the following branches:—

Its branches are *a. Articular nerves.* In the interval between the olecranon and the inner condyle, slender filaments are furnished to the joint.

to elbow-joint, *b. Muscular branches* arise from the nerve near the elbow, and supply the flexor carpi ulnaris and the inner half of the flexor profundus digitorum.

to two muscles of forearm, *c. Cutaneous nerve of the forearm and hand.* A small palmar branch (⁵) arises about the middle of the forearm, and descends on the ulnar artery, sending twigs around that vessel, to end in the integuments of the palm of the hand: sometimes a cutaneous offset perforates the aponeurosis near the wrist, and joins the internal cutaneous nerve.

cutaneous branch of palm of hand, *d.* The *dorsal cutaneous nerve of the hand* leaves the trunk about two inches above the end of the ulna, and passes obliquely backwards beneath the flexor carpi ulnaris; perforating the aponeurosis, it is distributed on the back of the hand and fingers (p. 285).

cutaneous nerve of back of hand. The MEDIAN NERVE (fig. 85,¹) leaves the hollow of the elbow between the heads of the pronator teres, and runs in the middle line of the limb to the hand. It is placed beneath the flexor sublimis as low as two inches from the annular ligament, where it becomes superficial along the outer border of the tendons of that muscle. Lastly, the nerve passes beneath the annular ligament to the palm of the hand. It supplies the muscles on the front of the forearm, and furnishes a cutaneous offset to the hand.

Median nerve lies between the two groups of muscles.

a. Radial trunk. *b.* Superficial volar branch. *c.* Ulnar trunk. *d.* Its posterior recurrent branch. *e.* Anterior interosseous. *f.* Median artery. *g.* Brachial trunk. *Nerves:* 1. Median. 2. Anterior interosseous. 3. Cutaneous palmar branch. 4. Ulnar trunk. 5. Cutaneous palmar branch of ulnar.

Muscular offsets leave the trunk of the nerve near the elbow, and are distributed to all the superficial muscles except the flexor carpi ulnaris; in addition, the nerve supplies the deep layer through the interosseous branch (p. 294), except the inner half of the flexor profundus digitorum. Supplies the front muscles, except one and a half,

The *cutaneous palmar branch* ⁽³⁾ arises in the lower fourth of the forearm; it pierces the fascia near the annular ligament, and crosses over that band to reach the palm. and a branch to palm of hand.

The RADIAL NERVE is the smaller of the two branches into which the musculo-spiral divides at the elbow. This nerve is placed along the outer border of the limb, under cover of the supinator longus (fig. 84), and on the outer side of the radial artery, to the junction of the middle and lower thirds of the forearm, where it becomes cutaneous at the posterior border of the supinator tendon. It finally divides into two branches, which are distributed on the dorsum of the hand and digits (p. 284). No muscular offset is furnished by the nerve. Radial nerve in forearm :

it ends on back of the hand.

Dissection (fig. 85). To examine the deep layer of muscles it will be necessary to draw well over to the radial side of the forearm the pronator teres, to detach the flexor sublimis from the radius, and to remove its fleshy part. A thin layer of fascia, which is most distinct near the wrist, is to be taken away; and the anterior interosseous vessels and nerve, which lie on the interosseous membrane, and are concealed by the muscles, are to be traced out. Dissection of deep muscles :

Over the ends of the forearm-bones the arch of the anterior carpal arteries may be defined. show carpal arch.

DEEP GROUP OF MUSCLES. There are three deep muscles on the front of the forearm. One, covering the ulna, is the deep flexor of the fingers; a second rests on the radius, the long flexor of the thumb; and the third is the pronator quadratus, which lies beneath the other two, over the lower ends of the bones. Three muscles in the deep set.

The FLEXOR PROFUNDUS DIGITORUM (flex. perforans; fig. 85, c) arises from the anterior and inner surfaces of the ulna for three-fourths of the length of the bone, from the inner half of the interosseous ligament for the same distance, and from the aponeurosis of the flexor carpi ulnaris. The muscle has a thick fleshy belly, and ends in tendons which, passing beneath the annular ligament, are inserted into the last phalanges of the fingers. Deep flexor of fingers :
origin ;

insertion.

Lying over the muscle are the ulnar vessels and nerve, the superficial flexor of the fingers, and the flexor carpi ulnaris. The deep surface rests on the ulna and the pronator quadratus muscle. The outer border touches the flexor longus pollicis and the anterior interosseous vessels and nerve. The portion of the muscle furnishing the tendon to the index finger is separated from the rest by a layer of areolar tissue. Parts around it.

Action. The muscle bends the joints of the fingers and the wrist; but it does not act on the last phalanx till after the second has been moved by the flexor sublimis. Use on fingers and wrist.

The fingers are usually bent in the following order:—firstly, the articulation between the metacarpal and the middle phalanges; How fingers are bent.

- secondly, the last phalangeal joint; and thirdly, the metacarpophalangeal.
- Long flexor of thumb:**
origin; The FLEXOR LONGUS POLLICIS (fig. 85, B) *arises* from the anterior surface of the radius, as low as the pronator quadratus, and from the outer part of the interosseous membrane; it is also joined in most cases by a distinct slip arising in common with the flexor sublimis digitorum either from the internal condyle of the humerus or the coronoid process of the ulna. The fleshy fibres descend to a tendon, which is continued beneath the annular ligament, and is *inserted* into the last phalanx of the thumb.
- insertion.**
- Parts above** The greater part of the muscle is covered by the flexor sublimis digitorum; and the radial vessels rest on it for a short distance
- and beneath it.** below. It lies on the radius and the pronator quadratus. To the inner side is the flexor profundus digitorum.
- Use.** *Action.* This muscle is the special flexor of the last joint of the thumb, but it also aids in bending the other joints of that digit and the wrist.
- Pronator quadratus** The PRONATOR QUADRATUS (fig. 85, D) is a flat muscle, covering the lower fourth of the bones of the forearm. It *arises* from the anterior surface of the ulna, where it is somewhat widened, and is *inserted* into the fore and inner parts of the radius for about two inches.
- is deep in position.** The anterior surface is covered by the tendons of the flexor muscles of the digits, and by the radial vessels; and the posterior surface rests on the radius and ulna with the intervening membrane, and on the interosseous vessels and nerve. Along its lower border is the arch formed by the anterior carpal arteries.
- Use.** *Action.* The end of the radius is moved inwards over the ulna by this muscle, and the hand is pronated.
- Anterior interosseous artery.** The ANTERIOR INTEROSSEOUS ARTERY (fig. 85, e) is continued on the front of the interosseous membrane, between the two flexors or in the fibres of the flexor profundus digitorum, till it reaches an aperture in the membrane beneath the pronator quadratus. At that spot the artery turns from the front to the back of the limb, and descends to the back of the carpus, where it ends by anastomosing with the posterior interosseous and carpal arteries.
- Branches: muscular, median,** *Branches.* Numerous offsets are given to the deep muscles. One long branch, *median* (f), accompanies the median nerve, which it supplies, and either ends in the flexor sublimis, or is continued beneath the annular ligament to the palmar arch.
- medullary to the bones,** Above the middle of the forearm the *medullary arteries* of the radius and ulna arise from the vessel.
- and carpal.** Where it is about to pass through the interosseous membrane it furnishes twigs to the pronator quadratus; and one branch is continued beneath that muscle to anastomose with the anterior carpal arteries.
- Anterior interosseous nerve ends in pronator.** The ANTERIOR INTEROSSEOUS NERVE (fig. 85, ²) is derived from the median, and accompanies the artery of the same name to the pronator quadratus muscle, the under surface of which it enters. Branches are given by it to the deep flexor muscles.

Dissection. The attachment of the biceps and brachialis anticus to the bones of the forearm may be now cleaned and examined. Dissection.

The *insertion of the brachialis anticus* takes place by a broad thick tendon, about an inch in length, which is fixed into the rough impression on the front of the coronoid process of the ulna. Insertion of brachialis anticus.

Insertion of the biceps. The tendon of the biceps is inserted into the rough hinder part of the tuberosity of the radius, a bursa separating it from the fore part of the prominence. Near its attachment the tendon is twisted, so that the anterior surface becomes external. The supinator brevis muscle partly surrounds the insertion. Insertion of biceps.

SECTION V.

THE PALM OF THE HAND.

Dissection (fig. 87). The digits being separated and fixed firmly with tacks, the skin is to be reflected from the palm of the hand by means of two incisions. One is to be carried along the centre from the wrist to the fingers; and the other is to be made from side to side at the termination of the first. In raising the inner flap, the small palmaris brevis muscle will be seen at the inner margin of the hand; and its insertion into the skin may be left till the muscle has been learnt. In the fat the ramifications of the palmar branches of the median and ulnar nerves are to be traced. Dissection.

Clean small palmar muscle,

and trace cutaneous nerves.

The student should remove the fat from the palmaris muscle, and from the strong palmar fascia in the centre of the hand; and he should take care not to destroy a fibrous band (transverse ligament) which lies across the roots of the fingers. When cleaning the fat from the palmar fascia he will recognise, near the fingers, the digital vessels and nerves; and must be especially careful of two,—viz., those of the inner side of the little finger and outer side of the index finger, which appear higher up than the rest, and are more likely to be injured. By the side of the vessels and nerves to the fingers four slender lumbricales muscles are to be exposed. Define the palmar fascia,

digital vessels and nerves;

Lastly, the skin and the fat may be reflected from the thumb and fingers by an incision along each, in order that the sheaths of the tendons with the collateral vessels and nerves may be laid bare. and expose digital sheaths.

Cutaneous palmar nerves. Small twigs are furnished to the integument from both the median and ulnar nerves in the hand; and two branches descend from the forearm. Cutaneous palmar nerves:

One is the offset of the median nerve (p. 293) which crosses the annular ligament: it extends to about the middle of the palm, and is united with the palmar branch of the ulnar: a few filaments are furnished to the ball of the thumb. one from median,

The other palmar branch is derived from the ulnar nerve (p. 292), and has been traced on the ulnar artery to the hand: it is distributed to the upper and inner part of the palm. the other from ulnar.

Palmaris brevis is a cutaneous muscle.

The PALMARIS BREVIS (fig. 87, H) is a small flat muscle, about an inch and a half wide, the fibres of which are collected into separate bundles. It arises from the palmar aponeurosis, and its fibres are directed transversely to their insertion into the skin at the inner border of the hand.

This muscle lies over the ulnar vessels and nerve. After it has been examined it may be thrown inwards with the skin.

Fig. 86.*

Use.

Action. It draws outwards and wrinkles the skin of the inner side of the palm.

Palmar fascia.

The PALMAR FASCIA or aponeurosis consists of a central and two lateral parts; but the lateral, which cover the muscles of the thumb and little finger, are so thin as not to require a special notice.

Its central part

The *central part* is a strong, white layer, which is pointed at the wrist, but expanded towards the fingers, where it nearly covers the palm of the hand. Above, the fascia receives the tendon of the palmaris longus, and is connected to the annular ligament; and below, it ends in four processes, which are continued downwards, one for each finger, to the sheaths of the tendons. At the point of separation of the pieces from one another some transverse fibres are placed, which arch over the lumbricalis muscle and the digital vessels and nerve appearing at this spot. From the pieces of the fascia a few superficial longitudinal fibres are prolonged to the integuments near the cleft of the fingers.

ends in a piece for each finger,

and in the skin.

Dissection.

Deep ending of the pieces of fascia.

Ending of the processes. Each process of the fascia sends backwards an offset on each side of the tendons, which is fixed to the deep ligament connecting together the heads of the metacarpal bones, and to the edge of the metacarpal bone for a short distance.

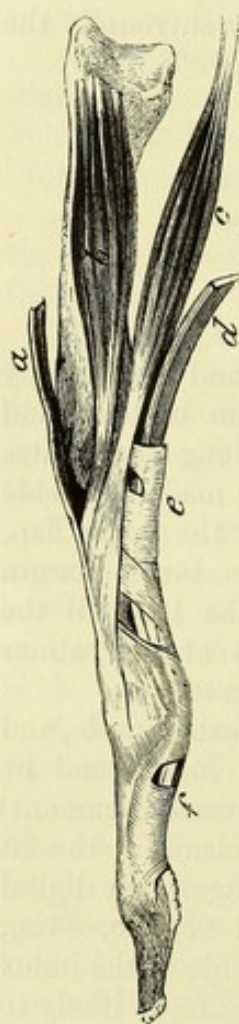
Transverse ligament of the fingers.

The *superficial transverse ligament of the fingers* is a thin fibrous band, which stretches across the roots of the four fingers, and is contained in the fold of skin, forming the rudiment of a web between them. Beneath it the digital nerves and vessels are continued onwards to their terminations.

Sheath of the tendons

Sheath of the flexor tendons (fig. 86). Along each finger the

* The tendons and short muscles of one finger, with the sheath of the flexor tendons. *a.* Extensor tendon, with interosseous (*b*) and lumbrical (*c*) muscles joining it. *d.* Tendon of flexor sublimis passing into its sheath, the thicker parts of which are marked *e* and *f*.



flexor tendons are retained in place against the phalanges by a fibrous sheath. Opposite the middle of the first and second phalanges the sheath is formed by a strong fibrous band (*vaginal ligament*; *e* and *f*) which is almost tendinous in consistence; but opposite the joints it consists of a thin membrane with scattered and oblique fibres. If the sheath be opened it will be seen to be lined by a synovial membrane, which forms long and slender vascular folds (*vincula vasculosa*) between the tendons and the bones. varies in thickness,
has a synovial sac.

Dissection. The palmar fascia, and the thinner parts of the digital sheaths opposite the joints of the fingers may be taken away. On the removal of the fascia the palmar arch of the ulnar artery, and the median and ulnar nerves become apparent. Dissection.

PALMAR PART OF THE ULNAR ARTERY (fig. 87). In the palm of the hand the ulnar artery is directed towards the muscles of the thumb, where it communicates with two offsets of the radial trunk, viz., the superficial volar branch (*c*), and the branch to the radial side of the forefinger (*f*). The curved part of the artery, which lies across the hand, is named the *superficial palmar arch* (*d*). Its convexity is turned towards the fingers, and its position in the palm would be nearly marked by a line across the hand from the cleft of the thumb. Superficial palmar arch:
position in the hand;

The arch is comparatively superficial, being covered for the most part only by the integuments and the palmar fascia; but at the inner border of the hand the palmaris brevis muscle (*H*) lies over it. Beneath it are the flexor tendons and the branches of the ulnar and median nerves. Venæ comites lie on its sides. relations.

Branches. From the convexity of the arch proceed the digital arteries, and from the concavity some small offsets to the palm of the hand. A small deep branch arises as soon as the artery enters the hand. Branches:

a. The *deep* or *communicating branch* (*profunda*; fig. 88, *b*) passes backwards with the deep part of the ulnar nerve, between the abductor and short flexor muscles of the little finger, to inosculate with the deep palmar arch of the radial artery (p. 304). to join the deep arch;

b. The *digital branches* (*g*) are four in number, and supply both sides of the three inner fingers and one side of the index finger. The branch to the inner side of the hand and little finger is undivided; but the others, lying over the three inner interosseous spaces, bifurcate below to supply the contiguous sides of the corresponding digits. In the palm these branches are accompanied by the digital nerves, which they sometimes pierce. four digital branches;

Near the roots of the fingers they receive communicating branches from offsets of the deep arch; but the digital artery of the inner side of the little finger has its communicating branch about the middle of the palm. these join offsets of the deep arch;

From the point of bifurcation the arteries extend along the sides of the fingers; and over the last phalanx the vessels of opposite sides unite in an arch, from the convexity of which offsets proceed to supply the ball of the finger. Branches are furnished to the termination on the fingers;

and arches. finger and the sheath of the tendons ; and twigs are supplied to the phalangeal articulations from small arterial arches on the bones—an arch being close above each joint. On the dorsum of the last phalanx is a plexus from which the nail-pulp is supplied.

Ulnar nerve in the hand PALMAR PART OF THE ULNAR NERVE (fig. 87, ¹). The ulnar nerve divides, on or near the annular ligament, into a superficial and a deep part.

divides into deep and The *deep part* accompanies the deep branch of the artery to the muscles, and will be dissected with that vessel (fig. 88).

superficial parts. The *superficial part* furnishes an offset to the palmaris brevis muscle, and some filaments to the integument of the inner part of the hand, and ends in two digital nerves for the supply of both sides of the little finger and half the next.

Digital nerves are two. *Digital nerves* (²). The more internal nerve is undivided, like the corresponding artery.

The other is directed to the cleft between the ring and little fingers, and bifurcates for the supply of their opposed sides : in the palm of the hand this branch is connected with an offset (³) of the median nerve.

Along the sides of the fingers the digital branches have the same arrangement as those of the median nerve.

Median nerve supplies muscles and digits. PALMAR PART OF THE MEDIAN NERVE (fig. 87, ³). As soon as the median nerve issues from beneath the annular ligament it becomes enlarged and somewhat flattened, and divides into two nearly equal parts for the supply of digital nerves to the thumb and the remaining two fingers and a half ; the outer part also furnishes a small muscular branch to the ball of the thumb. The branches of the nerve are covered by the fascia and the superficial palmar arch ; and beneath them are the tendons of the flexor muscles.

Branch to muscles. a. The *branch to muscles of the thumb* (⁴) supplies the outermost part of the flexor brevis, the abductor, and the opponens pollicis muscles.

Five digital nerves. b. The *digital nerves* (⁵) are five in number. Three of them, which are distributed to the sides of the thumb, and to the radial side of the fore finger, are undivided, and come from the external of the two pieces into which the trunk of the median splits. The other two spring from the inner piece of the nerve, and are bifurcated to supply the opposed sides of the middle and fore, and the middle and ring fingers.

First two, The *first two* nerves belong to the thumb, one on each side, and the outer one communicates with a branch of the radial nerve.

third, The *third* is directed to the radial side of the index finger, and gives a branch to the most external lumbrical muscle.

fourth, The *fourth* furnishes a nerve to the second lumbrical muscle, and divides to supply the contiguous sides of the fore and middle fingers.

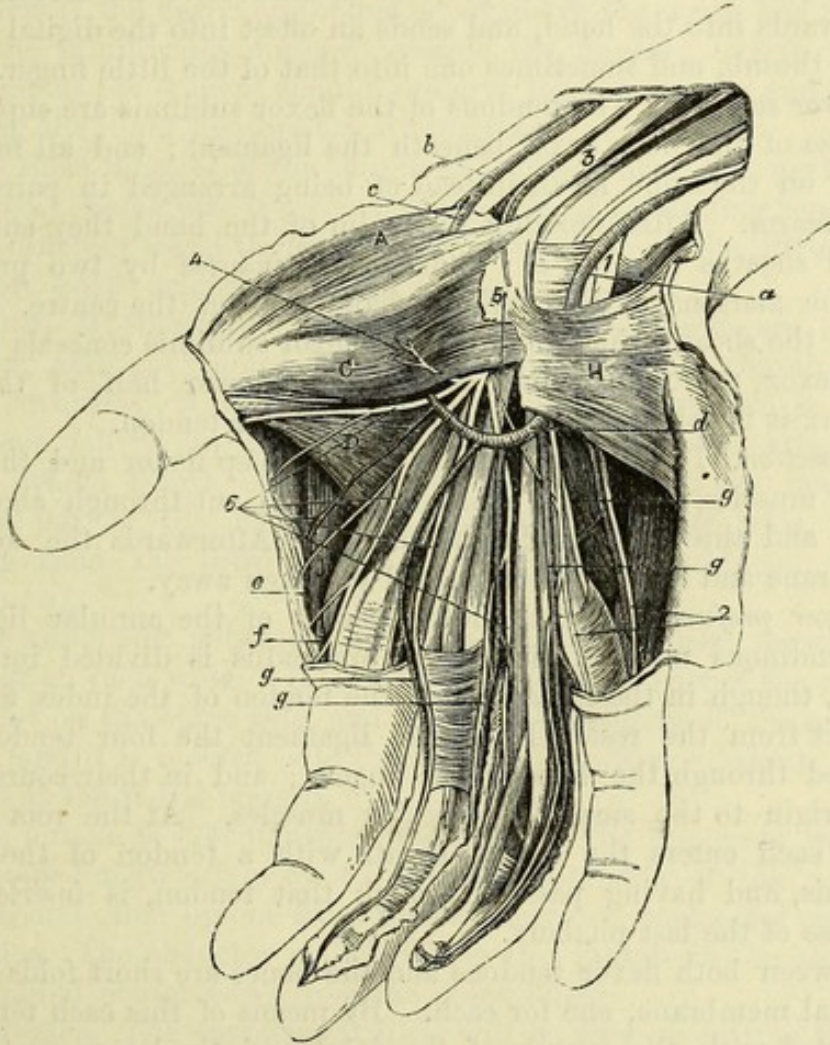
fifth. The *fifth* also divides into two branches, which are distributed to the opposed sides of the middle and ring fingers : it communicates with a branch of the ulnar nerve.

On the sides On the *fingers*. On the sides of the fingers the nerves are super-

ficial to the arteries, and reach to the last phalanx, where they end in filaments for the ball, and the pulp beneath the nail. In their course downwards the nerves supply chiefly tegumentary branches: one of these is directed backwards by the side of the metacarpal phalanx, and after uniting with the digital nerve on the back of the finger (p. 285), is continued to the dorsum of the last phalanx.

of the
fingers :
lateral
offsets.

Fig. 87.*



Dissection. The tendons of the flexor muscles may next be followed to their termination. To expose them, the ulnar artery should be cut through below the origin of the deep branch; and the superficial volar branch of the radial having been divided, the palmar arch is to be thrown towards the fingers. The ulnar and median nerves are also to be cut below the annular ligament, and turned downwards.

Dissection
of the flexor
tendons.

* Superficial dissection of the palm of the hand. (Illustrations of Dissections.) *Muscles:* A. Abductor pollicis. C. Outer head of flexor brevis. D. Adductor pollicis. H. Palmaris brevis. *Arteries:* a. Ulnar. b. Radial. c. Superficial volar branch. d. Superficial palmar arch. e. Branch uniting the arch with f, the radial digital branch of the fore finger. g. Digital branches of the superficial arch. *Nerves:* 1. Ulnar, and 2, its two digital branches. 3. Median, and 5, its digital branches. 4. Branch of the median to thumb-muscles. 5 (On the annular ligament). Communicating branch from the median to the ulnar.

Divide
annular liga-
ment,

A longitudinal incision is to be made through the centre of the annular ligament, without injuring the muscles that arise from it, and the pieces of the ligament are to be thrown to the sides.

and open
sheaths.

Finally, the sheaths of the fingers may be opened in order to show the insertion of the tendons.

Synovial sac
surrounds
tendons.

FLEXOR TENDONS. Beneath the annular ligament the tendons of the deep and superficial flexors are surrounded by a large and loose synovial membrane, which projects upwards into the forearm and downwards into the hand, and sends an offset into the digital sheath of the thumb, and sometimes one into that of the little finger.

Superficial
flexor
tendons

Flexor sublimis. The tendons of the flexor sublimis are superficial to those of the deep flexor beneath the ligament; and all four are nearly on the same level, instead of being arranged in pairs as in the forearm. After crossing the palm of the hand they enter the digital sheaths (fig. 86, *e*); and each is *inserted* by two processes into the margins of the middle phalanx, about the centre. As it enters the sheath, the tendon of the flexor sublimis conceals that of the flexor profundus; but opposite the lower half of the first phalanx it is split for the passage of the latter tendon.

in the hand :
insertion ;

slit for the
deep flexor.

Dissection.

Dissection. To see the tendons of the deep flexor and the lumbrical muscles, the flexor sublimis must be cut through above the wrist, and thrown towards the fingers. Afterwards the synovial membrane and areolar tissue should be taken away.

Tendons of
deep flexor

Flexor profundus. At the lower border of the annular ligament the tendinous mass of the flexor profundus is divided into four pieces, though in the forearm only the tendon of the index finger is distinct from the rest. From the ligament the four tendons are directed through the hand to the fingers; and in their course they give origin to the small lumbricales muscles. At the root of the finger each enters the digital sheath with a tendon of the flexor sublimis, and having passed through that tendon, is *inserted* into the base of the last phalanx.

cross the
hand

to their
insertion.

Short folds
to both
flexor ten-
dons.

Between both flexor tendons and the bones are short folds of the synovial membrane, one for each. By means of this each tendon is connected with the capsule of the joint, and the lower part of the phalanx immediately above the bone into which it is inserted.

Lumbrical
muscles :

origin ;

insertion ;

relations ;

and use.

The LUMBRICALES (fig. 88, 1) are four small muscular slips, which *arise* from the tendons of the deep flexor near the annular ligament; the outer two springing each from a single tendon, while the inner two are connected each with two tendons. They are directed to the radial side of the fingers, to be *inserted* into the expanded extensor tendon on the dorsal aspect of the metacarpal phalanx (fig. 86, *c*).

These muscles are concealed for the most part by the tendons and vessels that have been removed; but they are subcutaneous for a short distance between the processes of the palmar fascia.

Action. The lumbricales assist in bending the metacarpophalangeal joints; and by their insertion into the extensor tendons they straighten the interphalangeal joints.

Tendon of

Tendon of the flexor longus pollicis. Beneath the annular ligament

this tendon is external to the flexor profundus ; and in the hand it inclines outwards between the heads of the flexor brevis pollicis (fig. 88), to be *inserted* into the last phalanx of the thumb. The common synovial membrane surrounds it beneath the annular ligament, and sends a prolongation, as before said, into its digital sheath.

Dissection (fig. 88). The deep palmar arch with the deep branch of the ulnar nerve, and some of the interosseous muscles, will come into view if the flexor profundus is cut above the wrist, and thrown with the lumbricales muscles towards the fingers ; but in raising the tendons the student should preserve the fine nerves and vessels entering the inner two lumbrical muscles.

The short muscles of the thumb and little finger are next to be prepared. Some care is necessary in making a satisfactory separation of the different small thumb-muscles ; but those of the little finger are more easily defined.

SHORT MUSCLES OF THE THUMB (fig. 88). These are four in number, and are named from their action on the thumb. The most superficial is the abductor pollicis (A) ; beneath it is the opponens pollicis (B), which will be recognised by its attachment to the whole length of the metacarpal bone. To the inner side of the last is the bifid short flexor (C) ; and the wide muscle coming from the third metacarpal bone is the adductor of the thumb (D).

The ABDUCTOR POLLICIS (A) is the most superficial muscle, and is about an inch wide. It *arises* from the upper part of the annular ligament on the outer side, and from the tuberosity of the scaphoid bone ; and it is *inserted* into the base of the first phalanx of the thumb at the radial margin.

The muscle is subcutaneous, and rests on the opponens pollicis : it is joined at its origin by a slip from the tendon of the palmaris longus, and often by one from the extensor ossis metacarpi pollicis.

Action. The abductor pollicis moves the thumb in the direction of its radial border away from the index finger.

Dissection. The opponens pollicis will be seen on cutting through the abductor. To separate the muscle from the short flexor on the inner side, the student should begin near the head of the metacarpal bone, where there is usually a slight interval.

The OPPONENS POLLICIS (B) *arises* from the annular ligament beneath the preceding, and from the outer side of the ridge of the trapezium ; and it is *inserted* into the outer surface and radial border of the metacarpal bone for the whole length.

This muscle is for the most part concealed by the preceding, though it projects on the outer side. Along its inner border is the flexor brevis pollicis.

Action. It draws the metacarpal bone inwards over the palm, rotating it at the same time, so as to turn the ball of the thumb towards the fingers, thus producing the movement of opposition.

The FLEXOR BREVIS POLLICIS (C) is the largest of the short muscles of the thumb, and consists of two parts or heads (inner and outer)

long flexor
of thumb,

its insertion.

Dissection
of deep
arch,

and of
muscles of
thumb and
little finger.

Four mus-
cles in the
thenar.

Abductor :
attach-
ments ;

Dissection.

Opponens
fixed to
metacarpal
bone,

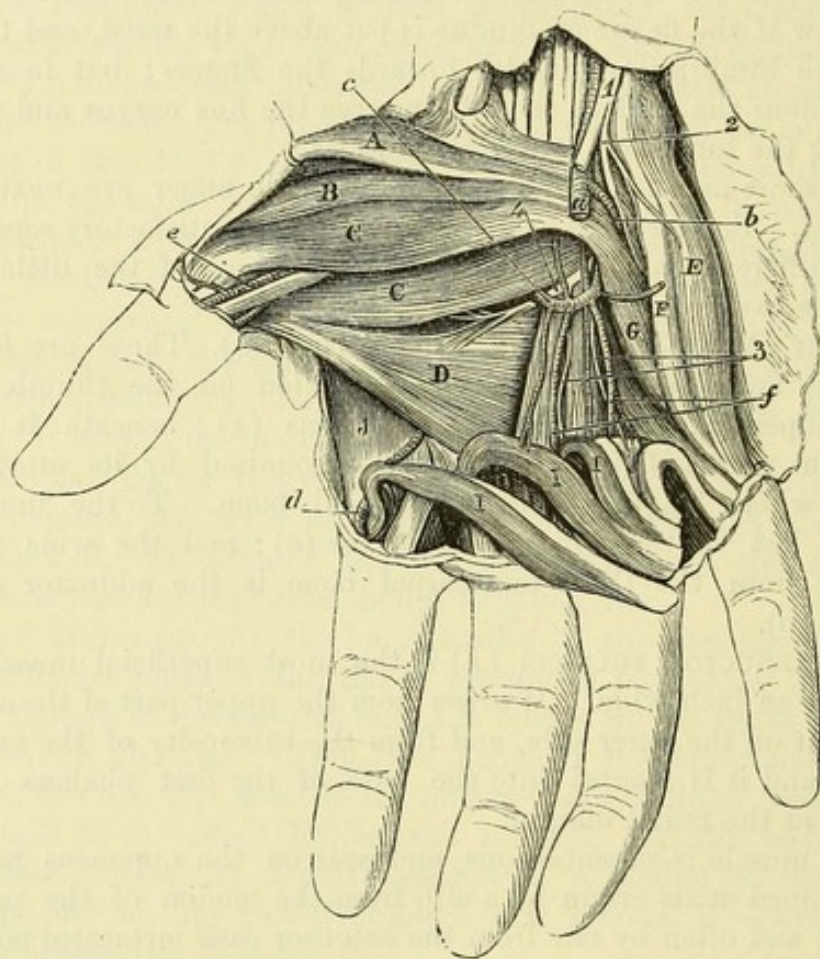
beneath
former ;

Flexor
brevis :

at the insertion, but these are united at the origin. Above, it *arises* from the lower border of the annular ligament and the sheath of the flexor carpi radialis, from the trapezium and os magnum, and from the bases of the second and third metacarpal bones. Below, its two heads are *inserted* into the sides of the base of the first phalanx of

origin ;
insertion by two pieces ;

Fig. 88.*



the thumb, the inner one being united with the adductor pollicis. A sesamoid bone is connected with each head close to its insertion.

The tendon of the long flexor lies on this muscle, occupying the interval between the heads near the insertion ; and the deep palmar arch of the radial artery issues beneath the inner head.

Action. The muscle bends the metacarpo-phalangeal joint, and assists the opponens in drawing the thumb forwards and inwards over the palm.

The ADDUCTOR POLLICIS (D) is triangular in shape, with the apex

* Deep dissection of the palm of the hand. (Illustrations of Dissections.)
Muscles : A. Abductor pollicis. B. Opponens pollicis. c. Flexor brevis pollicis. D. Adductor pollicis. E. Abductor minimi digiti. F. Flexor brevis minimi digiti. G. Opponens minimi digiti. I. Lumbricales. J. First dorsal interosseous. *Vessels* : a. Ulnar artery, cut. b. Its deep branch. c. Deep palmar arch. d. Radial digital artery of the index finger. e. Artery of thumb. f. Interosseous arteries. *Nerves*. 1. Ulnar nerve, cut. 2. Its deep part, continued at 4, to some of the thumb-muscles. 3. Offsets to the inner two lumbricales.

at the thumb, and the base in the centre of the palm. Its *origin* is from the ridge on the lower two-thirds of the palmar aspect of the middle metacarpal bone; and its *insertion* is into the inner side of the first phalanx of the thumb, in common with the short flexor. joins short flexor;

The anterior surface is in contact with the tendons of the flexor profundus and the lumbrical muscles; and the posterior surface lies over the interosseous muscles of the first and second spaces, with the intervening metacarpal bone. The deep palmar arch separates this muscle from the inner head of the short flexor. relations;

Action. It draws the thumb towards the centre of the palm. and use.

SHORT MUSCLES OF THE LITTLE FINGER (fig. 88). In the hypothenar eminence there are the abductor and opponens muscles of the little finger, and sometimes a short flexor. Two or three muscles to little finger.

The ABDUCTOR MINIMI DIGITI (E) is superficial to the opponens muscle. It *arises* from the pisiform bone, and is *inserted* into the ulnar side of the base of the first phalanx of the little finger; an offset from it reaches the extensor tendon on the back of the phalanx. The palmaris brevis partly conceals the muscle. Abductor is beneath skin;

Action. Firstly it draws the little finger away from the others; but continuing to act it bends the metacarpo-phalangeal joint. use.

The FLEXOR BREVIS MINIMI DIGITI (F) is placed at the radial border of the preceding muscle. It takes *origin* from the tip of the process of the unciform bone, and slightly from the annular ligament; and it is *inserted* with the abductor into the first phalanx. Flexor brevis is often absent;

It lies on the opponens; and near its origin it is separated from the abductor by the deep branches of the ulnar artery and nerve. relations;

Action. It flexes and abducts the first phalanx of the little finger. and use.

The OPPONENS MINIMI DIGITI (G) resembles the opponens pollicis in being attached to the metacarpal bone. Its *origin* is from the hook of the unciform bone, and the lower part of the annular ligament: its *insertion* is into the ulnar side of the metacarpal bone of the little finger. Opponens: attachments;

The opponens is partly overlaid by the preceding muscles; and beneath it the deep branches of the ulnar artery and nerve pass. relations;

Action. It raises the inner metacarpal bone, and moves it towards the others, so as to deepen the hollow of the palm. and use.

Dissection. The radial artery comes into the hand between the first two metacarpal bones; and to lay bare the vessel, it will be requisite to detach the origin of the flexor brevis pollicis. The deep palmar arch, and the branch of the ulnar nerve accompanying it, together with their offsets, are to be dissected out. Dissection of deep arch and

A fascia which covers the interosseous muscles is to be removed, after the dissector has observed its connection with the transverse ligament uniting the heads of the metacarpal bones. interosseous muscles and fascia.

RADIAL ARTERY IN THE HAND (fig. 88). The radial artery enters the palm at the first interosseous space, between the heads of the first dorsal interosseous muscle; and after furnishing one branch to the thumb, and another to the index finger, it turns across the hand towards the ulnar side, forming the deep arch. Radial artery in hand forms deep arch,

The *deep palmar arch* (c) extends from the first interosseous space to the base of the metacarpal bone of the little finger, where it joins the deep branch of the ulnar artery (b). Its convexity, which is but slight, is directed downwards; and its situation is nearer the carpal bones than that of the superficial arch. The arch has a deep position in the hand, and lies on the metacarpal bones and the interosseous muscles. It is covered by the long flexor tendons, and in part by the flexor brevis pollicis and opponens minimi digiti muscles. Two veins accompany it. The *branches* of the arch are the following:—

Branches: a. *Recurrent branches* pass from the concavity of the arch to the front of the carpus; these supply the bones and joints, and anastomose with the anterior carpal arteries.

perforating: b. *Three perforating arteries* pierce the inner three dorsal interosseous muscles, and communicate with the interosseous arteries on the back of the hand.

palmar interosseous. c. Usually there are *three palmar interosseous arteries* (f), which lie over the inner three metacarpal spaces, and terminate by joining the digital branches of the superficial palmar arch at the clefts of the fingers. An offset of the inner one, or a separate branch of the arch, joins the digital artery to the inner side of the little finger (p. 297). These branches supply the interosseous muscles, and the two or three inner lumbricales: they vary much in their size and arrangement.

Digital branches: d. *Digital branches of the radial.* The *large artery of the thumb* (e) runs between the first metacarpal bone and the flexor brevis pollicis to the interval between the heads of that muscle, where it divides into the two collateral branches of the thumb: these are distributed like the arteries of the superficial arch (p. 297).

artery of the thumb; e. The *radial digital branch of the index finger* (d) is directed over the first dorsal interosseous muscle (J), and beneath the short flexor and the adductor pollicis, to the radial side of the fore finger. At the lower border of the adductor pollicis (D), this branch is usually connected by an offset with the superficial palmar arch; and at the end of the digit it unites with the branch furnished to the opposite side by the ulnar artery.

artery of the fore-finger. The DEEP PART OF THE ULNAR NERVE (2) accompanies the arch of the radial artery as far as the muscles of the thumb, and terminates in offsets to the adductor pollicis and the deep part of the short flexor.

Deep branch of ulnar nerve: *Branches.* Near its origin the nerve furnishes branches to the muscles of the little finger. In the palm it gives offsets to all the palmar and dorsal interosseous muscles, and to the inner two lumbrical muscles (3), besides the terminal branches before mentioned.

muscular offsets. The TRANSVERSE METACARPAL LIGAMENT is formed by cross fibres uniting the palmar ligaments of the metacarpo-phalangeal articulations of the fingers, and serves to bind together the heads of the inner four metacarpal bones. To its upper border the fascia covering the interosseous muscles is attached. The ligament should now be taken away to see the interosseous muscles.

Transverse ligament of metacarpus.

The INTEROSSEOUS MUSCLES, so named from their position between the metacarpal bones, are seven in number. Two muscles occupy each space, except the first, where there is only one. They arise from the metacarpal bones, and are inserted into the first phalanges of the fingers. They are divided into palmar and dorsal ; but all are seen in the palm of the hand, though the former project more than the others.

Seven inter-
osseous
muscles,

divided into
palmar and
dorsal.

The *palmar muscles* (fig. 89), three in number, are smaller than the dorsal, and have each a single *origin* from the side of the

Palmar go
to index,
ring and
little fingers.

Fig. 89.*

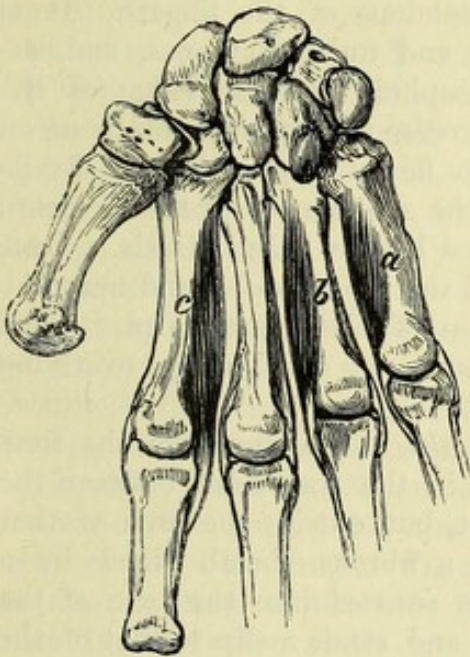
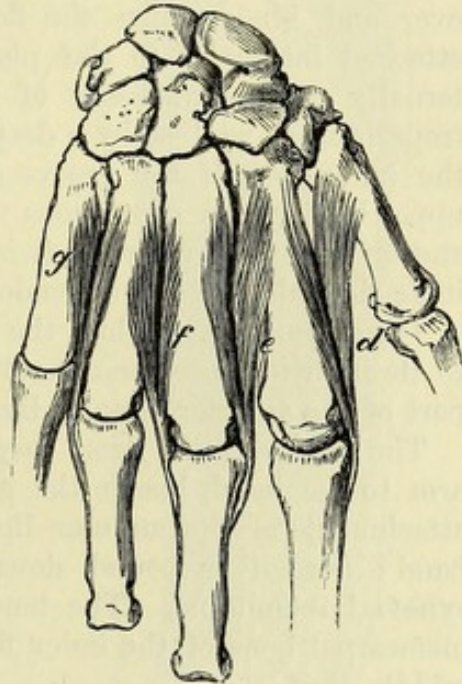


Fig. 90.†



metacarpal bone of the finger to which it belongs. The first is placed on the ulnar side of the index finger, the second and third on the radial side of the ring and little fingers respectively.

The *dorsal muscles* (fig. 90), one in each space, arise by two heads from the lateral surfaces of the metacarpal bones between which they lie. The first (abductor indicis) is inserted on the radial side of the index finger, the second on the radial, and the third on the ulnar side of the middle finger, and the fourth on the ulnar side of the ring finger.

Dorsal: two
to middle
finger, one
each
to index
and ring
fingers.

Both sets of muscles have a similar termination (fig. 86, b):—The fibres end in a tendon, which is inserted into the side of the first or metacarpal phalanx, and sends an expansion to join the extensor tendon on the dorsum of the bone.

Common
insertion of
both sets.

Action. They bend the metacarpo-phalangeal joints by their attachment to the first phalanx, and extend the two interphalangeal joints through their union with the extensor tendon.

Action as
flexors and
extensors,

* The three palmar interosseous muscles. *a*. Muscle of the little finger ; *b*, of the ring finger ; and *c*, of the index finger.

† The four dorsal interosseous muscles. *d*. Muscle of the index finger. *e* and *f*. Muscles of the middle finger. *g*. Muscle of the ring finger.

as abductors
and adduc-
tors.

The interosseous muscles also separate and approximate the straightened fingers, the palmar set adducting the index, ring and little fingers towards the middle digit; while the dorsal abduct their fingers from the median line of the hand, the two fixed to the middle finger moving it to either side of that line.

Dissection.

Dissection. The attachments of the annular ligament to the carpal bones on each side are next to be dissected out by taking away the small muscles of the thumb and little finger. Before reading its description, the ends of the cut ligament may be placed in apposition, and fixed with a stitch.

Annular
ligament
of front
of wrist.

The ANTERIOR ANNULAR LIGAMENT is a broad band, which arches over and binds down the flexor tendons of the fingers. It is attached internally to the pisiform and unciform bones, and externally to the tuberosity of the scaphoid and the ridge of the trapezium, as well as by a deeper process to the trapezoid bone on the inner side of the groove for the flexor carpi radialis. By its upper border it is continuous with the aponeurosis of the forearm; and on its anterior surface it is joined by the palmar fascia. Over it lie the palmaris longus tendon and the ulnar vessels and nerve.

Dissection.

Dissection. Next follow the tendon of the flexor carpi radialis to its insertion into the metacarpal bones, by dividing the overlying part of the anterior annular ligament.

Insertion of
flexor carpi
radialis.

The *tendon of the flexor carpi radialis*, in passing from the forearm to the hand, lies in the groove in the trapezium between the attachments of the annular ligament, but outside the arch of that band; here it is bound down by a fibrous sheath lined by a synovial membrane. The tendon is *inserted* into the base of the metacarpal bone of the index finger, and sends a slip to that of the middle digit.

SECTION VI.

THE BACK OF THE FOREARM.

Position.

Position. During the dissection of the back of the forearm the limb lies on the front, and a small block is to be placed beneath the wrist for the purpose of stretching the tendons.

Take away
the super-
ficial nerves
and the
fascia.

Dissection (fig. 91). The fascia and the cutaneous nerves and vessels are to be reflected from the muscles of the forearm, and from the tendons on the back of the hand; but in removing the fascia in the forearm, the student must be careful not to cut away the posterior interosseous vessels, which are in contact with it on the ulnar side in the lower third. A thickened band of the fascia opposite the carpus (the posterior annular ligament) is to be left.

Strip
fingers.

Let the integument be removed from the fingers, in order that the tendons may be traced to the end of the digits.

Separate
muscles.

The several muscles should be separated from one another up to their origin, especially the two radial extensors of the wrist.

The POSTERIOR ANNULAR LIGAMENT (K) is a part of the deep fascia, thickened by the addition of transverse fibres, and is situated opposite the lower ends of the bones of the forearm. This band is attached on the outer side to the radius, and on the inner to the pyramidal and pisiform bones. Processes from it are fixed to the bones beneath, and confine the extensor tendons. The ligament will subsequently be examined more in detail.

Annular ligament behind the wrist.

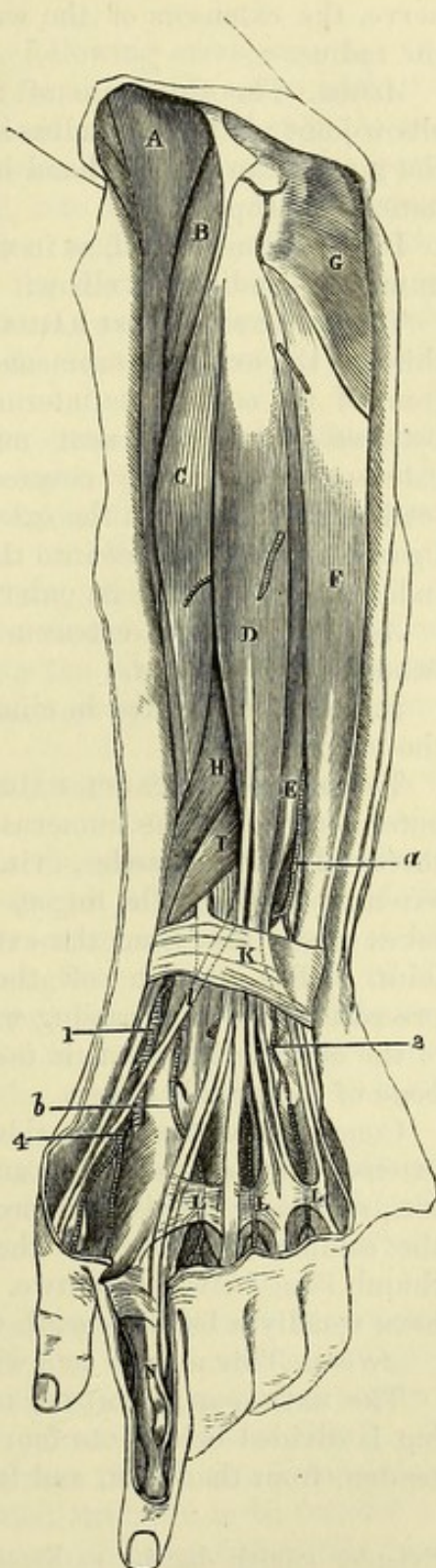
Fig. 91.*

SUPERFICIAL LAYER OF MUSCLES (fig. 91). The muscles of the back of the forearm are arranged in a superficial and a deep layer. The superficial layer contains seven muscles, which arise, in part by a common tendon, from the outer side of the humerus, and are placed in the following order from without inwards;—the long supinator (A), the long and short radial extensors of the wrist (B and C), the common extensor of the fingers (D), the extensor of the little finger (E), and the ulnar extensor of the wrist (F). There is one other small muscle near the elbow—the anconeus (G).

Superficial layer has seven muscles.

The SUPINATOR RADII LONGUS (A) reaches upwards into the arm, and limits on the outer side the hollow in front of the elbow. The muscle arises from the upper two-thirds of the external supracondylar ridge of the humerus, and from the front of the external intermuscular septum of the arm. The fleshy fibres end about the middle of the forearm in a tendon, which is inserted into the lower end of the radius, close above the styloid process.

In the arm the margins of the supinator are directed towards the surface and the bone, but in the forearm the muscle is flattered over the others, with its edges forwards and backwards. Its anterior



Supinator longus :

origin ;

insertion ;

relations ;

* Superficial dissection of the back of the forearm. (Illustrations of Dissections.) *Muscles*: A. Supinator longus. B. Extensor carpi radialis longior. C. Extensor carpi radialis brevior. D. Extensor communis digitorum. E.

border touches the biceps and the pronator teres ; and the posterior is in contact with both radial extensors of the wrist. Near its insertion the supinator is covered by two extensors of the thumb. Beneath the muscle are the brachialis anticus and the musculo-spiral nerve, the extensors of the wrist, the radial vessels and nerve, and the radius.

and use, *Action.* The chief use of the supinator longus is to bend the
radius free, elbow-joint ; but if the radius is either forcibly pronated or supinated, the muscle can put the hand into a state intermediate between pronation and supination.

and fixed. If the radius is fixed, as in climbing, the muscle will bring up the humerus, bending the elbow.

Extensor carpi radialis longior : origin ; The EXTENSOR CARPI RADIALIS LONGIOR (B) *arises* from the lower third of the external supracondylar ridge of the humerus, from the front of the contiguous intermuscular septum, and from the septum between it and the next muscle. It lies on the short radial extensor, being partly covered by the supinator longus ; and its tendon passes beneath the extensors of the thumb, and the annular ligament, to be *inserted* into the base of the metacarpal bone of the index finger. Along its outer border lies the radial nerve.

and use. *Action.* The long extensor first straightens the wrist, and then bends the elbow-joint.

If the hand is fixed in climbing, it will act on the humerus like the long supinator.

Extensor carpi radialis brevior : origin ; The EXTENSOR CARPI RADIALIS BREVIOR (C) is attached to the outer condyle of the humerus by a tendon common to it and the three following muscles, viz., common extensor of the fingers, extensor of the little finger, and ulnar extensor of the wrist ; it takes origin also from the external lateral ligament of the elbow-joint. The tendon of the muscle is closely applied to the preceding, and after passing with it through the same compartment of the annular ligament, is *inserted* into the base of the metacarpal bone of the middle finger.

parts around it ; Concealed on the outer side by the two preceding muscles, this extensor rests on the radius and two of the muscles attached to it, viz., supinator brevis, and pronator teres. Along the ulnar side is the common extensor of the fingers ; and the extensors of the thumb issue between the two. Both radial extensors of the carpus have usually a bursa beneath the tendon, close to the insertion.

and use. *Action.* This muscle acts with its fellow in extending the wrist.

Common extensor of fingers : The EXTENSOR COMMUNIS DIGITORUM (D) is single at its origin, but is divided below into four tendons. It *arises* from the common tendon, from the fascia, and from aponeurotic septa between it and

Extensor minimi digiti. F. Extensor carpi ulnaris. G. Anconeus. H. Extensor ossis metacarpi pollicis. I. Extensor primi internodii. J. Extensor secundi internodii pollicis. K. Posterior annular ligament. L. Bands uniting the tendons of the common extensor on the back of the hand. N. Insertion of the common extensor into the second and third phalanges. Arteries : a. Posterior interosseous 1. Radial. 2. Posterior carpal arch. b. Dorsal interosseous branch. 4. Dorsal branches of thumb and forefinger.

the adjacent muscles. At the lower part of the forearm the muscle ends in four tendons, which pass through a compartment of the annular ligament with the indicator muscle, and are directed along the back of the hand to their insertion into the second and third phalanges of the fingers.

On the fingers the tendons have the following arrangement. On the dorsum of the first phalanx each forms an expansion with the tendons of the lumbricalis and interosseous muscles (fig. 86). At the lower part of that phalanx the expansion divides into three parts (fig. 91, N);—the central one is fixed into the base of the second phalanx, while the lateral pieces unite, and are inserted into the base of the last phalanx. Opposite the first two articulations of each finger the tendon sends down lateral bands to join the capsule of the joint. On the fore and little fingers the expansion is joined by the special tendons of those digits.

This muscle is placed between the extensors of the wrist and little finger, and conceals the deep layer. On the back of the hand the tendons are joined by cross bands (L) which are strongest between the ring finger tendon and its collateral tendons; they prevent the ring finger being raised if the others are closed.

Action. The muscle straightens the fingers and separates them from each other. It acts especially on the first phalanges, the two interphalangeal joints being extended mainly by the interosseous and lumbricales muscles.

The digits being straightened, it will assist the other muscles in extending the wrist and the elbow.

The EXTENSOR MINIMI DIGITI (E) is the most slender muscle on the back of the forearm, and appears to be but a part of the common extensor. Its *origin* is in common with that of the extensor communis, but it passes through a distinct sheath of the annular ligament. Beyond the ligament the tendon splits into two, and the outer part is joined by the fourth tendon of the common extensor: finally, both parts enter the common expansion on the first phalanx of the little finger.

Action. It extends the little finger and moves back the wrist and elbow. As the inner piece of the split tendon is not united with the common extensor, it can straighten the digit during flexion of the other fingers.

The EXTENSOR CARPI ULNARIS MUSCLE (F) arises from the common tendon, the aponeurosis of the forearm, and an intermuscular septum on its outer side; it is also fixed by fascia to the posterior border of the ulna below the anconeus muscle (about the middle third). Its tendon becomes free from fleshy fibres near the annular ligament, and passes through a separate sheath in that structure to be inserted into the tuberosity at the base of the metacarpal bone of the little finger.

Beneath this extensor are some of the muscles of the deep layer, with part of the ulna. On the outer side is the extensor of the little finger, with the posterior interosseous vessels.

Action. The ulnar extensor straightens the wrist, and inclines the hand towards the ulnar side: it can then extend the elbow-joint.

- Anconeus :** The ANCONEUS (G) is a small triangular muscle near the elbow.
- origin ;** It *arises* from the outer condyle of the humerus by a tendon distinct from, and on the ulnar side of the common tendon of the foregoing muscles. From this origin the fibres diverge to their
- insertion ;** *insertion* into the outer side of the olecranon, and into the impression on the upper third of the posterior surface of the ulna.
- touches the triceps ;** The upper fibres are nearly transverse, and are contiguous to the lowest of the triceps muscle. Beneath the anconeus lie the supinator brevis muscle, and the interosseous recurrent vessels.
- use.** *Action.* It assists the triceps in extending the elbow.
- Dissection of deep layer of muscles,** *Dissection* (fig. 92). For the display of the deep muscles at the back of the forearm, and of the posterior interosseous vessels and nerve, three of the superficial muscles, viz., extensor communis digitorum, extensor minimi digiti, and extensor carpi ulnaris, are to be divided above and turned aside ; and the small branches of the nerve and artery entering these muscles may be cut.
- and interosseous vessels and nerve.** The loose tissue and fat are then to be removed from the muscles, and from the ramifications of the artery and nerve ; and a slender part of the nerve, which sinks beneath the extensor of the second phalanx of the thumb about the middle of the forearm, should be traced beyond the wrist.
- Five muscles in the deep layer.** The separation of the muscles should be made carefully, since the outer two of the thumb are not always very distinct from each other.
- DEEP LAYER OF MUSCLES** (fig. 92). In this layer there are five muscles, viz., one supinator of the forearm, and four special extensor muscles of the thumb and index finger. The highest muscle, partly surrounding the upper third of the radius, is the supinator brevis (D). Below this are the three muscles of the thumb in the following order ;—the extensor of the metacarpal bone (E), the extensor of the first (F), and that of the second phalanx (G). On the ulna the indicator muscle (H) is placed.
- Extensor ossis metacarpi pollicis :** The EXTENSOR OSSIS METACARPI POLLICIS (E) is the largest and highest of the extensor muscles of the thumb, and is sometimes united with the supinator brevis. It *arises* from the posterior surface of the radius in its middle third, below the supinator brevis, from a special narrow impression on the ulna, occupying the upper third of the outer division of the posterior surface, and from the intervening interosseous membrane. The tendon is directed outwards over the radial extensors of the wrist, and through the
- origin ;**
- insertion.** annular ligament, to be *inserted* into the base of the metacarpal bone of the thumb, and by a slip into the trapezium : another slip is frequently continued to the abductor pollicis.
- The muscle is at first deep, but afterwards superficial.** The muscle is concealed at first by the common extensor of the fingers ; but it becomes cutaneous in the lower third of the forearm between the last muscle and the radial extensors of the wrist (fig. 91). Opposite the carpus the radial artery winds backwards beneath its tendon. Between the contiguous borders of this muscle and the supinator brevis the posterior interosseous artery (*a*) appears.
- Use.** *Action.* By this muscle the thumb is carried outwards and backwards from the palm of the hand, and the hand is moved to the radial side.

The EXTENSOR PRIMI INTERNODII POLLICIS (F) is the smallest muscle of the deep layer, and its tendon accompanies that of the preceding extensor. Its *origin*, about one inch in width, is from the radius and the interosseous membrane, close below the attachment of the last muscle. The tendon passes through the same space in the annular ligament as the extensor of the metacarpal bone, and is *inserted* into the base of the first phalanx of the thumb. With respect to surrounding parts this muscle has similar relations to the preceding.

Action. It extends first the proximal phalanx, and then the metacarpal bone, like its companion.

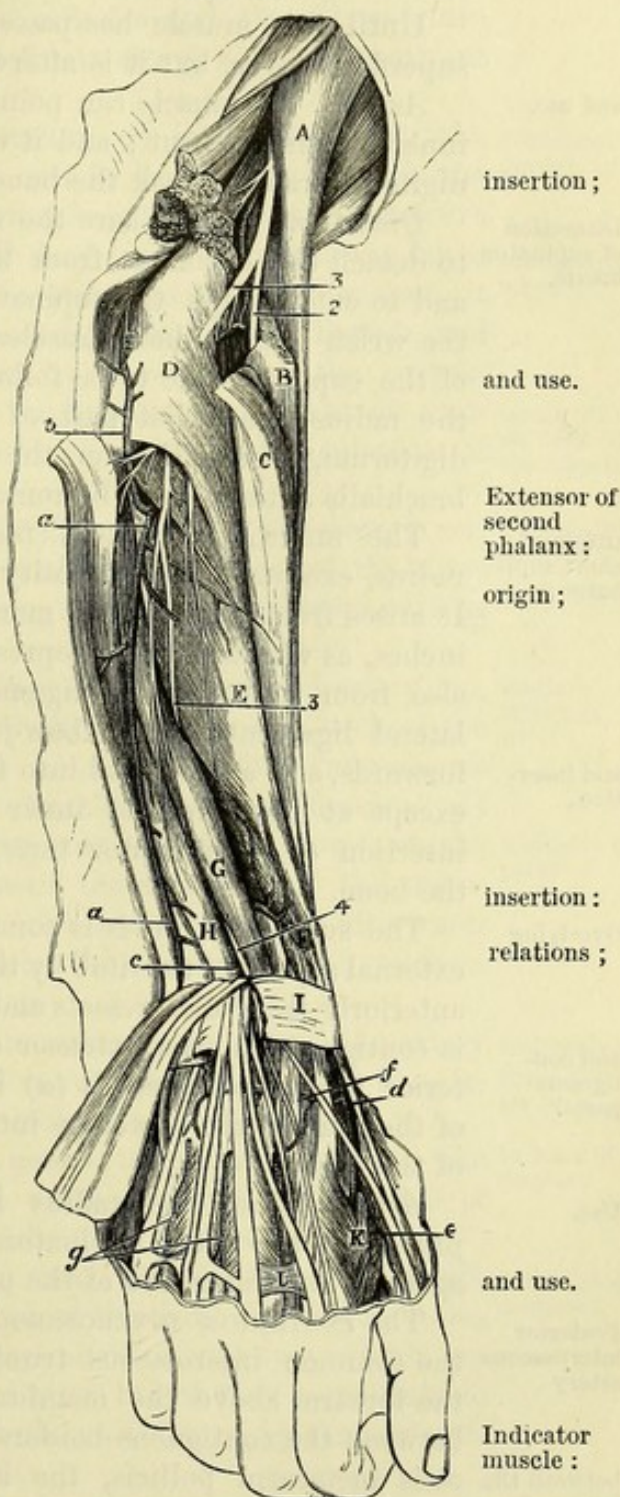
The EXTENSOR SECUNDI INTERNODII POLLICIS (G) arises from the middle third or more of the ulna below the anconeus, along the ulnar side of the extensor of the metacarpal bone; and from the interosseous membrane below, for about an inch. Its tendon, passing through a distinct sheath in the annular ligament, is directed along the dorsum of the thumb to be *inserted* into the base of the last phalanx.

The belly of the muscle is covered by the extensor carpi ulnaris and the extensors of the fingers, but the tendon becomes superficial close to the wrist. Below the annular ligament its tendon crosses the extensors of the wrist and the radial artery.

Action. It first extends both phalanges of the thumb, and then helps in moving backwards the metacarpal bone and the hand.

The EXTENSOR INDICIS (indicator; H) arises on the inner side of the last muscle from the ulna for three or four inches, usually below the middle, and from the lower

Fig. 92.*



* Deep dissection of the back of the forearm. (Illustrations of Dissections.)
Muscles: A. Supinator longus. B and C. Radial extensors of the carpus, cut. D. Supinator brevis. E. Extensor ossis metacarpi pollicis. F. Extensor primi internodii. G. Extensor secundi internodii. H. Extensor indicis. I. Posterior annular ligament. *Arteries:* a. Posterior interosseous. b.

origin ; part of the interosseous membrane. Near the wrist the tendon becomes free from muscular fibres, and passing beneath the annular ligament with the common extensor of the fingers, is applied to, and blends with the external tendon of that muscle in the expansion on the first phalanx of the fore finger.

Until this muscle has passed the ligament it is covered by the superficial layer, but it is afterwards subaponeurotic.

and use. *Action.* The muscle can point the fore finger even when the three inner fingers are bent ; and it will help the common extensor of the digits in drawing back the hand.

Dissection of supinator brevis. *Dissection.* To lay bare the supinator brevis, it will be necessary to detach the anconeus from the external condyle of the humerus, and to cut through the supinator longus and the radial extensors of the wrist. After those muscles have been divided, the fleshy fibres of the supinator are to be followed forwards to their insertion into the radius ; and that part of the origin of the flexor profundus digitorum, which lies on the outer side of the insertion of the brachialis anticus, is to be removed.

Origin of short supinator ; The SUPINATOR BREVIS (D) surrounds the upper part of the radius, except at the tuberosity and the front of the bone below it. It arises from the external margin of the ulna for a distance of two inches, as well as from a depression below the small sigmoid cavity ; also from the orbicular ligament of the radius and the external lateral ligament of the elbow-joint. The fibres pass outwards and forwards, and are *inserted* into the upper third or more of the radius, except at the fore and inner parts, reaching downwards to the insertion of the pronator teres, and forwards to the oblique line of the bone.

Overlying The supinator brevis is concealed altogether at the posterior and external aspects of the limb by the muscles of the superficial layer ; and anteriorly the radial vessels and nerve lie over it. The lower border is contiguous to the extensor ossis metacarpi pollicis, only the posterior interosseous vessels (a) intervening. Through the substance of the muscle the posterior interosseous nerve (3) winds to the back of the limb.

Use. *Action.* When the radius has been moved over the ulna in pronation, the short supinator comes into play to bring that bone again to the outer side of the ulna.

Posterior interosseous artery The POSTERIOR INTEROSSEOUS ARTERY (fig. 92, a) is an offset from the common interosseous trunk (p. 291), and reaches the back of the forearm above the membrane between the bones. Appearing between the contiguous borders of the supinator brevis and extensor ossis metacarpi pollicis, the artery descends at first between the superficial and deep layers of muscles ; and afterwards, with a superficial position in the lower third of the forearm, along the tendon of the extensor carpi ulnaris as far as the wrist, where it

Interosseous recurrent. c. Ending of the anterior interosseous. d. Radial. e. Dorsal branches to the thumb and fore finger. f. Dorsal carpal arch. g. Two dorsal interosseous of the hand. *Nerves:* 2. Radial. 3. Posterior interosseous at its origin, and 4, near its ending on the back of the carpus.

ends by anastomosing with the carpal and anterior interosseous arteries. It furnishes *muscular offsets* to the surrounding muscles, and the following recurrent branch :—

The *recurrent branch* (*b*) springs from the artery near the beginning, and ascends on or through the fibres of the supinator, but beneath the anconeus, to supply both those muscles and the elbow-joint : it anastomoses with the superior profunda artery and the recurrent radial. its recurrent branch

The POSTERIOR INTEROSSEOUS NERVE (³) is derived from the musculo-spiral trunk (p. 281), and winds backwards through the fibres of the supinator brevis. Issuing from the supinator, the nerve is placed between the superficial and deep layers of muscles as far as the middle of the forearm. Much reduced in size at that spot, it sinks beneath the extensor of the second phalanx of the thumb, and runs on the interosseous membrane to the back of the carpus. Finally, the nerve enlarges beneath the tendons of the extensor communis digitorum, and terminates in filaments to the articulations of the carpus. Interosseous nerve :
position to muscles ;
termination on back of the carpus.

Branches. It furnishes offsets to all the muscles of the deep layer, and to those of the superficial layer with the exception of the three following, viz., anconeus, supinator longus, and extensor carpi radialis longior. Its muscular offsets.

RADIAL ARTERY AT THE WRIST (fig. 92). The radial artery (*d*), with its venæ comites, winds below the radius to the back of the carpus, and enters the palm of the hand at the first interosseous space, between the heads of the first dorsal interosseous muscle. At first the vessel lies deeply on the external lateral ligament of the wrist-joint, and beneath the tendons of the extensors of the metacarpal bone (*e*) and first phalanx of the thumb (*f*) ; but afterwards it is more superficial, and is crossed by the tendon of the extensor of the second phalanx of the thumb (*g*). Radial artery at wrist :
relations to parts around,

Offsets of the musculo-cutaneous nerve entwine around the artery (p. 284), and branches of the radial nerve are superficial to it. Its branches are numerous but inconsiderable in size :— and nerves.
Its branches are small :

a. The *dorsal carpal branch* (*f*) passes transversely beneath the extensor tendons, and forms an arch with a corresponding offset of the ulnar artery ; this arch is joined by the interosseous arteries. to back of carpus ;

From the carpal arch branches (*g*) descend to the third and fourth interosseous spaces, and constitute two of the three *dorsal interosseous arteries* : at the cleft of the fingers each divides into two, which are continued along the dorsum of the digits. Below they communicate with the digital arteries ; and above they are joined by the perforating branches of the deep palmar arch. dorsal interosseous ;

b. The *metacarpal or first dorsal interosseous branch* (fig. 91, *b*) gains the space between the second and third metacarpal bones, and receives, like the corresponding arteries of the other spaces, a perforating branch from the deep palmar arch. Finally, it is continued to the cleft of the fingers, where it joins the digital artery of the superficial palmar arch, and gives small dorsal branches to the index and middle fingers. metacarpal ;

- dorsal arteries of thumb *c.* Two small *dorsal arteries of the thumb (c)* arise opposite the metacarpal bone, along which they extend, one on each border, to be distributed on its posterior aspect.
- and fore finger. *d.* The *dorsal branch of the index finger* is distributed on the radial edge of that digit.
- Sheaths of annular ligament The different divisions of the *annular ligament* may be seen more completely by cutting the sheaths of the ligament over the several tendons passing beneath. There are six separate compartments, and each is lubricated by a synovial membrane. The most external one lodges the first two extensors of the thumb. The next is a large hollow for the two radial extensors of the wrist; and a small space for the extensor of the second phalanx of the thumb follows on the ulnar side. Farther to the inner side is the common sheath for the extensor of the fingers, and that of the fore finger; and then comes a slender compartment for the extensor of the little finger. Internal to all is the space for the extensor carpi ulnaris.
- from with-out inwards. The last muscle grooves the ulna; but the others lie in hollows in the radius in the order mentioned above, with the exception of the extensor minimi digiti which is situate between the bones.
- Bones grooved by the tendons. *Dissection.* If the supinator brevis be divided by a vertical incision, and reflected from the radius, its attachment to that bone will be better understood.
- To see insertion of supinator, The posterior interosseous nerve, and the offsets from its gangli-form enlargement, may be traced more completely after the tendons of the extensor of the fingers and indicator muscle have been cut at the wrist.
- interosseous nerve, The posterior surface of the dorsal interosseous muscles of the hand may be cleaned, so that their double origin, and their insertion into the side, and on the dorsum of the phalanges, may be observed. Between the heads of origin of these muscles the posterior perforating arteries appear.
- and inter-osseous muscles.

SECTION VII.

LIGAMENTS OF THE SHOULDER, ELBOW, WRIST, AND HAND.

- Directions. *Directions.* The ligaments of the remaining articulations of the limb, which are still moist, may be examined at once; but if any of them have become dry, they may be softened by immersion in water, or with a wet cloth, while the student learns the others.
- Dissection of external ligaments of shoulder. *Dissection.* For the preparation of the external ligaments of the shoulder-joint the tendons of the surrounding muscles, viz., subscapularis, supraspinatus, infraspinatus, and teres minor, must be detached from the capsule; and as these are united with it, some care will be needed not to open the joint.
- Shoulder-joint, outline of. **THE SHOULDER-JOINT.** This ball and socket joint (fig. 93) is formed between the head of the humerus and the glenoid fossa of the

scapula. Enclosing the articular ends of the bones is a fibrous capsule lined by a synovial membrane. A ligamentous band (glenoid ligament) deepens the shallow scapular cavity for the reception of the large head of the humerus.

The bones are but slightly bound together by ligamentous bands, Looseness. for, on the removal of the muscles, the head of the humerus may be drawn from the scapula for the distance of an inch.

The *capsular ligament* (fig. 79,⁵) encloses the articular portions of the bones. It is much thickened above, and slightly so below; and Capsular ligament: the surrounding tendons are closely adherent to it.

By the one end it is fixed around the articular surface of the scapula, where it is connected with the long head of the triceps. By the other the ligament is fixed (fig. 93) to the neck of the humerus close to the articular surface above, but at a little distance down the bone below; and its attachment is interrupted between the tuberosities (*b*) by the tendon of the biceps muscle, over which it is continued, covering in the bicipital groove (fig. 79). On the inner side there is an aperture in the capsule, below the coracoid process, aperture; through which the synovial membrane of the joint is continuous with the bursa beneath the tendon of the subscapularis.

The following muscles surround the articulation;—above and behind are the supraspinatus, infraspinatus, and teres minor; below are the long head of the triceps and the lower part of the subscapularis; and internally it is covered by the last-named muscle. muscles around;

On the upper part of the capsule is a thick band of fibres—the *coraco-humeral* or *accessory ligament* (fig. 79, ⁸), which springs from the outer side of the coracoid process of the scapula, and widening over the top of the joint, is attached to the margins of the bicipital groove, and to the tuberosities. accessory band.

Dissection. To see the interior of the articulation cut circularly through the capsule near the scapula. When this has been done, the attachment of the capsule to the bones, the glenoid ligament, and the tendon of the biceps will be manifest. Dissection of internal structures.

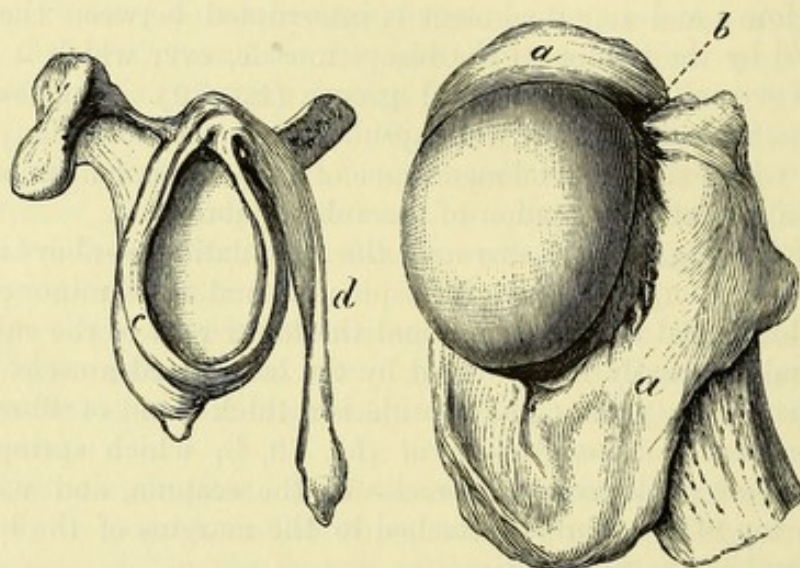
The *tendon of the biceps muscle* arches over the head of the humerus, and serves the purpose of a ligament in supporting the bone. It is attached to the upper part of the head of the scapula (fig. 93, *d*), and is united on each side with the glenoid ligament. At first flat, it afterwards becomes round, and enters the groove between the tuberosities of the humerus, where it is surrounded by the synovial membrane. Tendon of the biceps.

The *glenoid ligament* (fig. 93, *c*) is a fibrous band, which surrounds the fossa of the same name, increasing it for the reception of the head of the humerus. It is about two lines in width, and is connected in part with the sides of the tendon of the biceps; but most of its fibres are fixed separately to the margin of the glenoid fossa. Glenoid ligament.

The *synovial membrane* lines the articular surface of the capsule, and is continued through the aperture on the inner side to join the bursa beneath the subscapular muscle. The membrane is reflected around the tendon of the biceps, and lines the upper part of the bicipital groove of the humerus. Synovial membrane.

- Surface of humerus ;** *Articular surfaces* (fig. 93). The convex articular head of the humerus is three or four times as large as the hollow of the scapula, and forms rather less than the half of a sphere. The head of the bone is supported on a short neck, which is joined to the shaft at an obtuse angle.
- of scapula.** The glenoid fossa of the scapula is ovoidal in form with the larger end down, and is very shallow. Its margin is slightly more prominent below than above.
- Kinds of movement.** *Movements.* In this joint there is the common angular motion in four directions, with the circular or circumductory ; and in addition a movement of rotation.
- Flexion and** In the swinging to and fro movement, the carrying forwards and

Fig. 93.*



- extension** inwards of the humerus constitutes *flexion* ; and the moving it backwards and outwards, *extension*. Flexion is freer than extension ; and as the joint is bent the scapula follows the humerus, undergoing a rotation upwards, so that the whole range of movement of the arm in this direction is much greater than that taking place in the scapulo-humeral articulation. In extension the scapula is similarly rotated downwards, the lower angle approaching the spine.
- are accompanied by rotation of scapula.** During these movements the head of the humerus rests in the bottom of the glenoid fossa, rotating around an axis that is nearly perpendicular to the plane of that cavity ; and there is no tendency to dislocation either from the rapidity or extent of the movement.
- Condition of head of humerus.** Flexion of the humerus upon the scapula is checked by the twisting of the capsule, and by the meeting of the small tuberosity of the former bone with the coraco-acromial arch. Extension is limited mainly by the coraco-humeral ligament.
- Checks to movements.** *Abduction and adduction.* In abduction, the arm is moved out-

* View of the interior of the shoulder-joint. *a.* Attachment of the capsule to the neck of the humerus. *b.* Interval of the bicipital groove. *c.* Glenoid ligament around the glenoid fossa. *d.* Tendon of the long head of the biceps fixed at the top of the fossa.

wards and forwards away from the body ; and in adduction, it is brought downwards to the side. These movements, like the foregoing, are accompanied, and their range is increased by rotation of the scapula.

When the limb is abducted, the head of the humerus glides downwards in the glenoid cavity, and projects beyond it against the lower part of the capsule, which is stretched ; while the great tuberosity sinks beneath the acromial arch, which sets a limit to the movement. In this condition a little more movement down of the head, either by muscles depressing it or by force elevating the farther end of the bone, will throw it out of place, giving rise to dislocation.

In adduction, the head of the humerus rises in the socket, and the coraco-humeral ligament being tightened checks the movement.

In *circumduction*, the humerus passes in succession through the four different states above mentioned, and the limb describes a cone, the apex of which is at the shoulder and the base at the digits.

Rotation. There are two kinds of rotatory movement, viz., in and out ; and in each the humerus revolves around an axis passing from the centre of the head through the shaft to the lower end of the bone.

In rotation in, the great tuberosity moves forwards and inwards, and the head of the bone rolls backwards in the glenoid cavity, and the hinder part of the capsule is rendered tense. In rotation out, the movements of the parts of the humerus are reversed, and the front of the capsule is stretched. The movements are stopped by the tightening of the capsule, assisted by the muscles on the back and front of the joint respectively.

Dissection. To make the necessary dissection of the ligaments of the elbow, the brachialis anticus must be taken away from the front, and the triceps from the back of the joint. The muscles connected with the outer and inner condyles of the humerus, as well as the supinator brevis and the flexor profundus digitorum, are to be removed. With a little cleaning the four ligaments—anterior, posterior, and two lateral—will come into view.

The interosseous membrane between the bones of the forearm will be prepared by the removal of the muscles on both surfaces.

THE ELBOW-JOINT (fig. 94). In this articulation the lower end of the humerus is received into the hollow of the ulna, so as to produce a hinge-like arrangement ; and the upper end of the radius assists to form the outer part of the joint. Where the bones touch, the surfaces are covered with cartilage ; and they are united by the following ligaments :—

The *external lateral ligament* is a roundish fasciculus, which is attached by one end to a depression below the outer condyle of the humerus, and by the other to the orbicular ligament round the head of the radius. A few of the posterior fibres pass backwards to the external margin of the olecranon.

The *internal lateral ligament* is triangular in shape. It is pointed at its upper extremity, and is connected to the inner condyle of the

Abduction.

Adduction.

Circumduction.

Rotation :

Dissection of the elbow-joint.

Bones forming the elbow-joint.

External lateral ligament.

Internal lateral ligament.

humerus. The fibres diverge, and are inserted in this way :—The anterior, which are the strongest, are fixed to the edge of the coronoid process; the posterior are attached to the side of the olecranon; and a few middle fibres join a transverse band over the notch between the olecranon and the coronoid process. The ulnar nerve

is in contact with the ligament; and vessels enter the joint by the aperture beneath the transverse band.

Fig. 94.*

Anterior ligament.

Posterior ligament.

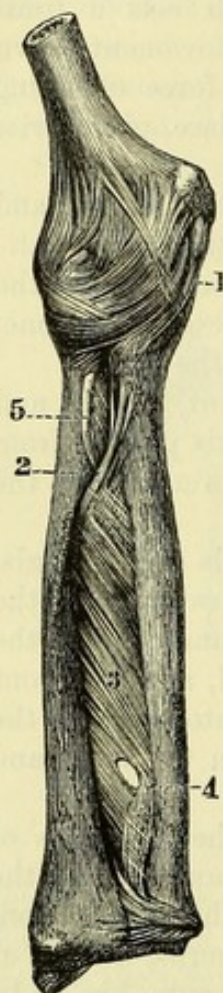
Dissection.

Synovial membrane.

Lower end of the humerus :

two articular surfaces, and three fossæ.

Upper end of the ulna.



The *anterior ligament* is thin, and its fibres are separated by intervals in which masses of fat are lodged. By its upper edge the ligament is attached to the front of the humerus, and by its lower to the front of the coronoid process and the orbicular ligament. The brachialis anticus muscle covers it.

The *posterior ligament* is much thinner and looser than the anterior, and is covered completely by the triceps muscle. Superiorly it is attached to the humerus above the fossa for the olecranon; and inferiorly it is inserted into the olecranon. Some few fibres are transverse between the margins of the fossa before mentioned.

Dissection. Open the joint by an incision across the front near the humerus, and disarticulate the bones, in order that the articular surfaces may be seen.

The *synovial membrane* of the joint passes from one bone to another along the deep surface of the connecting ligaments. It is continued downwards on the inner surface of the orbicular ligament, and serves for the joint of the head of the radius with the small sigmoid cavity of the ulna.

Articular surfaces. The articular surface of the lower end of the humerus is divided into two parts for the bones of the forearm. That for the radius, on the outer side, forms a rounded eminence (capitellum) which is confined to the front of the bone. The surface in contact with the ulna (trochlea) is limited internally and externally by a prominence, and hollowed out in the centre. On the front of the humerus above the articular surface are two depressions which receive the coronoid process and the head of the radius during flexion of the joint; and on the posterior aspect is a large fossa for the reception of the olecranon in extension of the joint.

On the end of the ulna the articular surface of the great sigmoid cavity is narrowed in the centre, but expanded above and below (fig. 95). A median ridge, which is received into the hollow of the trochlea, extends from the upper to the lower end of the fossa; and

* The ligaments of the elbow-joint, and of the radius and ulna (Bourguery.)
1. Capsule of the elbow-joint. 2. Oblique ligament. 3. Interosseous membrane. 4. Aperture for blood-vessels. 5. Tendon of the biceps.

across the bottom of the cavity the cartilage is wanting over a small space between the coronoid and olecranon processes.

The head of the radius presents a circular depression with a raised margin, which plays over the capitellum of the humerus.

Head of the radius.

Movement. This joint is like a hinge in its movements, permitting only flexion and extension.

Kind of motion :

In *flexion*, the bones of the forearm move forwards, each on its own articular surface, so as leave the back of the humerus uncovered. The movement is checked by the meeting of the arm and forearm ; and the posterior and internal lateral ligaments are stretched.

bending ;

In *extension*, the ulna and radius are carried back over the articular surface of the humerus until they come into a line with the arm-bone. This movement is checked by the anterior ligament, and the muscles on the front of the joint.

UNION OF THE RADIUS AND ULNA. The radius is connected with the ulna at both ends by means of synovial joints, with surrounding ligaments ; and the shafts of the bones are united by interosseous ligaments.

UPPER RADIO-ULNAR ARTICULATION. In this joint the head of the radius is received into the small sigmoid cavity of the ulna, and is kept in place by the following ligamentous band :—

The *annular* or *orbicular ligament* (fig. 95, *a*) is about one-third of an inch wide, and is stronger behind than before ; it is placed around the prominence of the head of the radius, and is attached to the anterior and posterior edges of the small sigmoid cavity of the ulna. Its upper border, the thicker, is connected with the ligaments of the elbow-joint ; but the lower is free, and is applied around the neck of the radius. In the socket formed by this ligament and the cavity of the ulna the radius moves freely.

The *synovial membrane* is a prolongation of that lining the elbow-joint ; it projects inferiorly between the neck of the radius and the lower margin of the annular ligament.

synovial membrane.

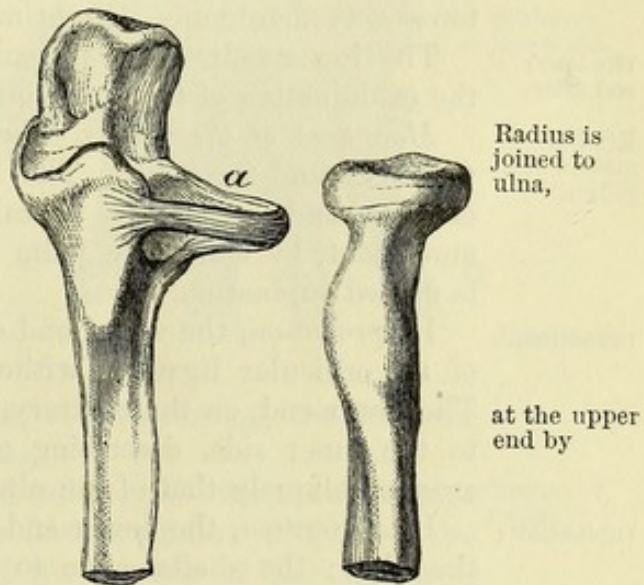
LIGAMENTS OF THE SHAFTS OF THE BONES. The aponeurotic stratum connecting together the bones in nearly their whole length consists of the two following parts :—

Union of the shafts :

The *interosseous membrane* (fig. 94,³) is a thin fibrous layer, which is attached to the contiguous margins of the radius and ulna, and forms an incomplete septum between the muscles on the front

interosseous membrane

Fig. 95.*



* View of the orbicular ligament (*a*) of the radius, which retains the upper end of the bone against the ulna.

is deficient above ;	and back of the forearm. Most of its fibres are directed obliquely downwards and inwards, though a few on the posterior surface have an opposite direction. Superiorly the membrane is wanting for a considerable space, and through the interval the posterior interosseous vessels pass backwards. Some small apertures exist in it for the passage of vessels ; and the largest of these (⁴) is about two inches from the lower end, through which the anterior interosseous artery turns to the back of the wrist. The membrane gives attachment to the deep muscles.
oblique ligament.	The <i>oblique ligament</i> (fig. 94, ²) is a slender band above the interosseous membrane, the fibres of which have a direction opposite to those of the membrane. By one end it is fixed to the lower end of the coronoid process, and by the other to the radius below the tuberosity. The ligament divides into two the space above the interosseous membrane. Oftentimes this band is not to be recognised.
The lower end after.	The lower radio-ulnar articulation cannot be well seen till after the examination of the wrist-joint (p. 322).
Kind of motion of radius :	<i>Movement of the radius.</i> The radius moves forwards and backwards around the ulna. The forward motion, directing the palm of the hand backwards, is called pronation ; and the backward movement, by which the palm of the hand is turned to the front, is named supination.
pronation,	In <i>pronation</i> , the upper end of the bone rotates within the band of the orbicular ligament without shifting its position to the ulna. The lower end, on the contrary, moves over the ulna from the outer to the inner side, describing nearly half a circle ; and the shaft crosses obliquely that of the ulna.
supination ;	In <i>supination</i> , the lower end of the radius turns backwards over the ulna ; the shafts come to be placed side by side, the radius being external ; and the upper end rotates from within out in its circular band.
axis of motion ;	In these movements the radius revolves round a line, internal to the shaft, which is prolonged upwards through the neck and head of the bone, and downwards through the styloid process of the ulna.
use of ligaments ;	The upper end of the bone is kept in place by the orbicular ligament ; the lower end by the triangular fibro-cartilage ; and the shafts are united by the interosseous ligament, which is tightened in supination, and relaxed in pronation.
in fracture motion ceases.	In fracture of either bone the movements cease ; in the one case because the radius cannot be moved unless it is entire ; and in the other because the broken ulna cannot support the revolving radius.
Dissection.	<i>Dissection.</i> To see the ligaments of the wrist-joint, the tendons and the annular ligaments must be removed from both the front and back ; and the fibrous structures and the small vessels should be taken from the surface of the ligaments.
Bones forming wrist-joint united by	THE WRIST-JOINT (fig. 96). The lower end of the radius, and the first row of the carpal bones, except the pisiform, enter into the wrist-joint. Four ligaments connect the bones, viz., anterior and posterior, and two lateral. The ulna is shut out from this articulation by means of a piece of fibro-cartilage.

The *external lateral ligament* is a short band, which passes from the styloid process of the radius to the outer part of the scaphoid bone. external lateral,

The *internal lateral ligament* is longer and thicker than the external. It is attached by one end to the styloid process of the ulna, and by the other to the rough upper part of the pyramidal bone. Some of the anterior fibres are continued to the pisiform bone. internal lateral,

Fig. 96.*

The *anterior ligament* (fig. 96,¹) springs from the radius, and is inserted into the first row of carpal bones, except the pisiform, on the anterior surface.

The *posterior ligament* (fig. 99,¹) is membranous, like the anterior, and its fibres are directed downwards and inwards from the radius to the same three carpal bones of the first row on the posterior aspect.

Dissection. To see the form of the articular surfaces, the joint may be opened by a transverse incision through the posterior ligament, near the bones of the carpus.

Articular surfaces. The end of the radius, and the fibro-cartilage (fig. 97, *c*) uniting it with the ulna form a shallow socket for the reception of the carpal bones; and the surface of the radius is divided by a prominent line into an external triangular, and an internal square impression. The three carpal bones of the first row constitute a convex eminence (fig. 98), which is received into the hollow before mentioned in this way;—the scaphoid bone (*a*) is opposite the external mark of the radius; the semilunar bone (*b*) touches the square impression and the triangular fibro-cartilage; while the pyramidal bone (*c*) is in contact with the capsule, and with the fibro-cartilage when the hand is moved inwards. anterior and
posterior
ligaments.

Dissection.

Surface of
radius;

of first row
of carpal
bones.
Opposed
surfaces.

The *synovial membrane* has the arrangement common to simple joints. This joint communicates occasionally with the lower radio-ulnar articulation by means of an aperture in the fibro-cartilage between the two. Synovial
sac.

Movements. The wrist is a condyloid articulation, and permits of angular motion in four different directions, with circumduction. Kinds of
motion:

Flexion and extension. In flexion the hand is moved forwards, while the carpus rolls on the radius from before back, and projects flexion;

* Front view of the articulations of the wrist, and carpal and metacarpal bones (Bourguery). 1. Anterior ligament of the wrist-joint. 2. Capsule of the joint of the metacarpal bone of the thumb with the trapezium. 3. Pisiform bone, with its ligamentous bands. 4. Transverse bands uniting the bases of the metacarpal bones.

extension ; behind, stretching the posterior ligament. In extension the hand is carried backwards, and the row of carpal bones moves in the opposite direction, viz., from behind forwards, so as to cause the anterior ligament to be tightened. The backward movement is not so free as the forward.

abduction ; *Abduction and adduction.* The hand is carried transversely outwards in the former, and inwards in the latter movement ; and the extent of movement is greater towards the ulnar than the radial side. The lateral ligaments are put on the stretch, the inner in abduction and the outer in adduction ; and the motion is limited on the outer side by the meeting of the styloid process of the radius with the scaphoid bone.

circumduction. *Circumduction.* The hand describes a cone in this movement, the apex being at the wrist and the base at the digits ; and it moves more freely in extension and adduction than in the opposite directions.

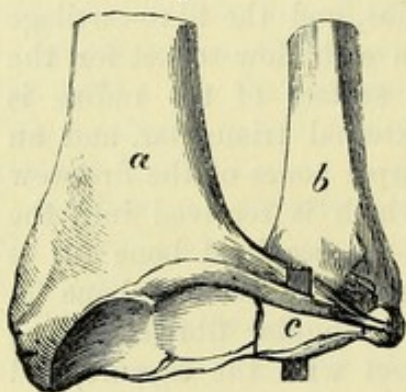
Lower ends of radius and ulna joined by LOWER RADIO-ULNAR ARTICULATION. In this articulation the head of the ulna is received into the sigmoid cavity of the radius ; —an arrangement just the opposite to that between the upper ends of the bones.

capsule, The chief bond of union between the bones is a strong fibro-cartilage ; but a kind of *capsule*, consisting of scattered fibres, surrounds loosely the end of the ulna.

triangular fibro-cartilage ; The *triangular fibro-cartilage* (fig. 97, c) is placed transversely below the end of the ulna, and is thickest at its margins and apex.

By its base the cartilage is fixed to the ridge which separates the carpal from the ulnar articulating surface of the radius ; and by its apex to the styloid process of the ulna, and the depression at the root of that projection. Its margins are united with the contiguous anterior and posterior ligaments of the wrist-joint ; and its surfaces enter into different joints, viz., the wrist, and the lower radio-ulnar. It serves to unite the radius and ulna, and to form part of the socket

Fig. 97.*



attach-
ments,
and rela-
tions.

for the carpal bones. Occasionally it is perforated by an aperture.

Synovial membrane. The *synovial membrane* is very loose, and ascends between the radius and the ulna : it is separated from that of the wrist-joint by the triangular fibro-cartilage.

The motion in this articulation is referred to with the movements of the radius (p. 320).

Bones are joined into two rows. UNION OF THE CARPAL BONES. The several bones of the carpus (except the pisiform) are united into two rows by small dorsal, palmar, and interosseous bands ; and the two rows are connected together by wide separate ligaments.

* Lower ends of the forearm bones with the uniting fibro-cartilage. a. Radius. b. Ulna. c. Triangular fibro-cartilage.

Dissection. The articulations of the carpal bones with each other will be prepared by taking away all the tendons from the hand, and cleaning carefully the connecting ligamentous bands. Two distinct ligaments from the pisiform bone to the unciform and fifth metacarpal are to be defined in the palm.

Dissection
of carpal

At the same time the ligamentous bands uniting the metacarpal with the carpal bones, and with one another should be dissected.

and meta-
carpal
joints.

Bones of the first row (fig. 98). The semilunar bone is united to the scaphoid and pyramidal by *dorsal* (*d*) and *palmar* transverse bands; as well as by small *interosseous ligaments* at the upper part of the contiguous surfaces.

How first
row is
united.

The pisiform bone is articulated to the front of the pyramidal by a distinct *capsule* and *synovial sac*. It has farther two special ligaments; one of these is attached to the process of the unciform, and the other to the base of the fifth metacarpal bone.

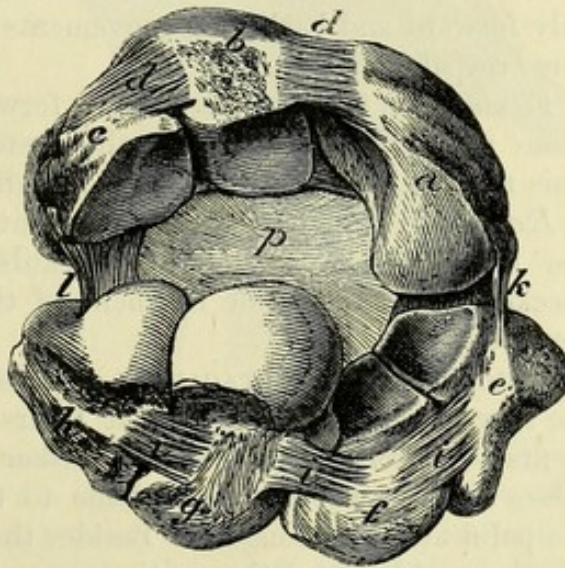
Separate
ligaments of
pisiform
bone.

The *bones of the second row* (fig. 98) are connected together in the same way as those of the first, viz., by a *dorsal* (*i*) and a *palmar* band of fibres from one bone to another. Between the contiguous rough surfaces of the several bones are *interosseous ligaments*, one in each interval.

Second row
is like first.

Movement. Only a small degree of gliding motion is permitted between the different carpal bones, in consequence of the flattened articular surfaces, and the short ligaments uniting one to another; and this is less in the second than in the first row.

Fig. 98.*



A gliding
movement.

One row with another (transverse carpal joint;

Transverse
carpal joint:

fig. 98). The two rows of carpal bones are connected by an anterior and posterior, and two lateral ligaments.

The *anterior ligament* (*p*) consists of strong fibres, which for the most part converge from the three bones of the first row to the os magnum. The *posterior ligament* is thinner and looser; and its strongest fibres are transverse.

Of the *lateral ligaments* the *external* (*k*) is the better marked, and extends between os trapezium and scaphoid bone; the *internal* (*l*) passes from the pyramidal to the unciform bone.

and lateral
ligaments.

* Articulations of the carpal bones, the joint between the two rows being opened behind. *a*. Scaphoid bone. *b*. Semilunar. *c*. Pyramidal. *d*. Dorsal transverse bands between those bones. *e*. Trapezium. *f*. Trapezoid. *g*. Os magnum. *h*. Unciform. *i*. Dorsal transverse bands joining the bones. *k*. External lateral ligament of the intercarpal joint. *l*. Internal lateral ligament. *p*. Anterior ligament.

Dissection. *Dissection.* After the division of the lateral and posterior ligaments, the one row of bones may be separated far enough from the other to allow the articular surfaces to be seen.

Form of joint-surfaces. *Articular surfaces.* The three bones of the first row, viz., scaphoid (*a*), semilunar (*b*), and pyramidal (*c*), together form an arch with its concavity turned downwards, while externally the scaphoid presents a convexity to the second row. The lower articular surface has a corresponding form, the os magnum and unciform making up a condyloid projection which is received into the arch of the first row, and the trapezium and trapezoid forming a slight hollow for the convexity of the scaphoid bone.

One synovial cavity for the carpal bones, *One synovial sac* serves for the articulation of all the carpal bones, except the pisiform with the pyramidal. The cavity extends transversely between the two rows of the carpus, and is continued upwards and downwards between the individual bones. The offsets upwards are two, and they sometimes open into the cavity of the wrist-joint; but the offsets in the opposite direction are three, and may be continued to all, or only to some of the articulations between the four inner metacarpal with their carpal bones.

and some metacarpals. *Movements.* Owing to the irregular shape of the articular surfaces, only forward and backward movements are permitted in the transverse carpal joint.

Flexion. *Flexion.* As the hand is brought forwards the lower row of carpal bones moves backwards, and the posterior ligament is tightened. This motion is brought into play in full bending of the wrist.

Extension. *Extension.* The backward movement is freer than flexion. As the lower carpal row moves towards the palm, its progress is checked by the anterior ligament of the joint, and by the strong flexor tendons.

Metacarpal bones joined at bases, *UNION OF THE METACARPAL BONES.* The metacarpal bones of the four fingers are connected at their bases by the following ligaments:—A *dorsal* (fig. 99) and *palmar* (fig. 96) fasciculus of fibres passes transversely from each bone to the next; and the bands in the palm are the strongest. Besides these, there is a short *interosseous ligament* between the contiguous rough surfaces of the bones.

with synovial joints, Where the metacarpal bones touch they are covered by cartilage; and between the articular surfaces there are prolongations of the synovial cavity serving for their articulation with the carpus.

and at heads. At their distal ends the same four metacarpal bones are connected by the *transverse ligament*, which was seen in the dissection of the hand (p. 304).

Carpal and metacarpal joints. *UNION OF THE METACARPAL AND CARPAL BONES.* The metacarpal bones of the fingers are articulated with the carpal bones after one plan; but the bone of the thumb has a separate joint.

That of the thumb. The *metacarpal bone of the thumb* articulates with the trapezium; and the ends of the bones are encased in a capsular ligament (fig. 96,²), which is lined by a simple *synovial membrane*.

Motion : The thumb-joint possesses angular movement in opposite directions, with opposition and circumduction, thus:—

bending *Flexion and extension.* When the joint is flexed, the metacarpal

bone is brought in front of the palm; and as the movement proceeds, the thumb is gradually turned towards the fingers, passing into the state of *opposition*. In this way the thumb may be made to touch the palmar surface of any or all of the fingers, the phalanges of the latter being somewhat bent at the same time. Extension of the joint is very free, and by it the metacarpal bone is removed from the palm towards the outer border of the forearm.

Abduction and adduction. By these movements the thumb is placed in contact with, or removed from the fore finger.

The *metacarpal bones of the fingers* receive longitudinal bands from the carpal bones on both aspects, thus:—

The *dorsal ligaments* (fig. 99) are two to each, except to the bone of the little finger. The bands of the metacarpal bone of the fore finger come from the trapezium and trapezoid; those of the third metacarpal are attached to the trapezoid and os magnum; the bone of the ring finger receives its bands from the os magnum and unciform; and to the fifth metacarpal bone there is but one ligament from the unciform.

The *palmar ligaments* (fig. 96), usually one to each metacarpal bone, are weaker and less constant than the dorsal. These ligaments may be oblique in direction; and sometimes a band is divided

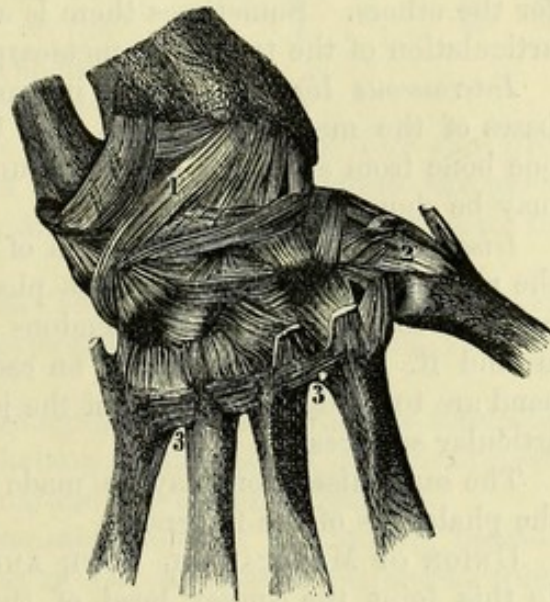
between two, as in the case of a ligament passing from the trapezium to the second and third metacarpals. One or more may be wanting.

On the ulnar side of the metacarpal bone of the middle digit is a longitudinal *lateral band*, which is attached above to the os magnum and unciform, and below to a rough part on the inner side of the base of the above mentioned bone. Sometimes this band isolates the articulation of the last two metacarpals with the unciform bone from the remaining carpo-metacarpal joint; but more frequently it is divided into two parts, and does not form a complete partition.

This band may be seen by opening from behind the articulation between the unciform and the last two metacarpal bones; and by cutting through the transverse ligaments joining the third and fourth metacarpals so as to allow their separation.

Movement. Scarcely any appreciable antero-posterior movement exists in the articulations of the bases of the metacarpal bones of

Fig. 99.*



and palmar bands;

* Posterior ligaments of the wrist, and carpal and metacarpal bones (Bourguery). 1. Posterior radio-carpal. 2. Carpo-metacarpal capsule of the thumb. 3, 3. Transverse bands between the bases of the metacarpal bones.

the fore and middle fingers ; but in the ring and little fingers the motion is greater, with a slight degree of opposition.

Dissection. *Dissection.* The articular surfaces of the bones in the carpo-metacarpal articulation may be seen by cutting through the rest of the ligaments on the posterior aspect of the hand.

Articular surfaces, and contact. *Articular surfaces.* The metacarpal bone of the fore finger presents a hollowed articular surface, which receives the prominence of the trapezoid bone, and articulates laterally with the trapezium and os magnum. The middle finger metacarpal articulates with the os magnum. The metacarpal bone of the ring finger touches the unciform bone and the os magnum. And the little finger bone is opposed to the unciform.

Synovial sacs, two or three. *Synovial sacs.* Usually two synovial sacs are interposed between the carpal and metacarpal bones, viz., a separate one for the bone of the thumb, and offsets of the common carpal synovial sac (p. 324) for the others. Sometimes there is a distinct synovial sac for the articulation of the two inner metacarpals with the unciform bone.

Inter-osseous ligaments, metacarpal, and carpal. *Interosseous ligaments.* The interosseous ligaments between the bases of the metacarpal bones may be demonstrated by detaching one bone from another ; and those uniting the adjacent carpal bones may be shown in the same way.

Dissection of finger-joints. *Dissection.* For the examination of the joint between the head of the metacarpal bone and the first phalanx of the finger, it will be requisite to clear away the tendons and the tendinous expansion around it. A lateral ligament on each side, and an anterior thick band are to be defined. One of the joints may be opened to see the articular surfaces.

The same dissection may be made for the articulations between the phalanges of the fingers.

Metacarpophalangeal articulations : UNION OF METACARPAL BONE AND FIRST PHALANX (fig. 100). In this joint the convex head of the metacarpal bone is received into the glenoid fossa of the phalanx, and the two are united by the following ligaments :—

lateral ligaments ; The *lateral ligament* (a) is the same on both sides of the joint. Each is triangular in form ; it is attached above to the lower part of the tubercle on the side of the head of the metacarpal bone, and below it is inserted into the phalanx and the anterior ligament.

anterior ligament ; The *anterior ligament* (b) is a strong and dense band, which is fixed firmly to the phalanx, but loosely to the metacarpal bone. It is grooved for the flexor tendon ; and to its sides the lateral ligaments are united.

posterior. On the dorsal aspect of the joint, the capsule is completed by a thin layer of connective tissue which supports the synovial membrane, and is closely covered by the extensor tendon. The *synovial sac.* The synovial membrane of the joint is a simple sac.

Joint of thumb. In the articulation of the thumb two sesamoid bones are connected with the anterior ligament, and receive most of the fibres of the lateral ligaments.

Kinds of motion : *Movements.* Motion in four opposite directions, together with circumduction, take place in these condyloid joints.

Flexion and extension. In flexion, the phalanx glides forwards bending ; over the head of the metacarpal bone, and leaves this exposed to form the knuckle when the finger is shut. The lateral ligaments and the extensor tendon are put on the stretch as the joint is bent. In extension, the phalanx moves backwards to slightly beyond the line of the metacarpal bone, so that the two form an obtuse angle. The anterior ligament and the flexor tendons are stretched, and limit the movement.

Abduction and adduction are the lateral movements of the finger from or towards the middle line of the hand. The lateral ligament of the side of the joint which is rendered convex is tightened, and the other is relaxed.

The *circumductory* motion is less impeded in the fore and little fingers than in the others. In the joint of the thumb the movements, especially to the side, are much less extensive than in the fingers.

UNION OF THE PHALANGES. The ligaments of these joints are similar to those in the metacarpo-phalangeal articulation, viz., two lateral and an anterior. Joints of the phalanges have

The *lateral ligaments* are triangular in form. Each is connected by its apex to the proximal phalanx at the side of the head ; and by its base to the distal phalanx and the anterior ligament. lateral and

The *anterior ligament* has the same mode of attachment between the extremities of the bones as in the metacarpo-phalangeal joint, but it is not so strong. anterior ligaments.

There is a simple *synovial membrane* present in the joint. Synovial sac.

The joint of the second with the last phalanx is like the preceding in the number and disposition of its ligaments ; but all the articular bands are much less strongly marked. Last joint.

Articular surfaces. The head of each phalanx is marked by a pulley-like surface. The base presents a hollow on each side of a median ridge, which fits into the central depression of the opposed articular surface. Surfaces of the bones.

Movements. The two interphalangeal joints can be bent and straightened like a hinge. Kinds of motion :

Flexion and extension. In flexion, the distal phalanx moves round the proximal in each joint, and the motion is checked by the lateral ligaments and the extensor tendon : in the joint between the middle and the metacarpal phalanx this movement is most extensive. In extension the farther phalanx comes into a line with the nearer one, and the motion is stopped by the anterior ligament and the flexor tendons. bending ;
extending.

Fig. 100.

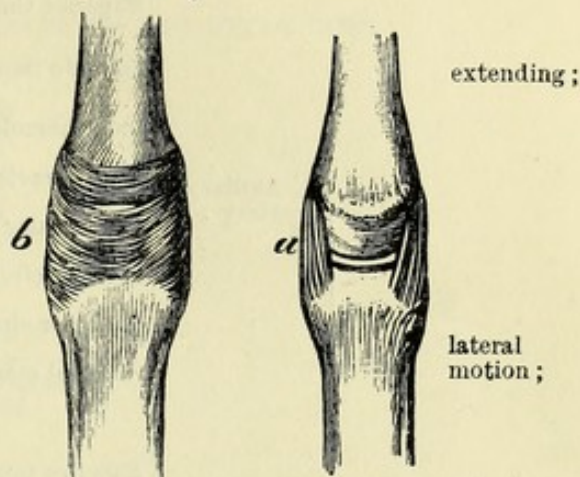


TABLE OF THE CHIEF ARTERIES OF THE UPPER LIMB.

	1. Axillary artery . . .	Superior thoracic		
		acromio-thoracic . . .	{	Acromial thoracic clavicular humeral.
		long thoracic		
		alar thoracic		
	2. brachial artery . . .	subscapular . . .	{	Dorsal scapular . . . { Infrasca- muscular. pular.
		anterior circumflex		
		posterior circumflex		
		external mammary.		
	3. radial artery . . .	Superior profunda . . .	{	Muscular to triceps and anconeus anastomotic.
		medullary		
		inferior profunda . . .	{	Muscular to triceps anastomotic.
		anastomotic muscular.		
	4. ulnar artery . . .	Recurrent muscular		
		superficial volar		
		anterior carpal		
		posterior carpal		
	5. The subelavian is continued in the arm by . . .	dorsal interosseous		
		dorsal of thumb		
		dorsal of index finger		
		volar of thumb		
	6.	radial of index finger		
		deep arch	{	Recurrent perforating palmar inter- osseous.
		Anterior recurrent		
		posterior recurrent		
	7.	interosseous	{	Anterior . . . { Medullary muscular. median muscular.
		muscular	{	posterior . . . { Recurrent muscular.
		metacarpal		
		anterior carpal		
	8.	posterior carpal		
		communicating to deep arch		
		superficial arch	{	Four digital branches cutaneous muscular.

TABLE OF THE SPINAL NERVES OF THE UPPER LIMB.

BRACHIAL PLEXUS gives off below the clavicle.	Anterior thoracic	{ External internal
	subscapular	{ Superior middle or long inferior.
	circumflex	{ Articular cutaneous to teres minor to deltoid.
	nerve of Wrisberg	
	internal cutaneous	{ Small cutaneous anterior of forearm posterior of forearm.
	musculo-cutaneous	{ To coraco-brachialis, biceps and brachialis anticus external cutaneous of forearm articular to carpus.
	median	{ To pronator teres, flexor radialis, palmaris longus, and flexor sublimis anterior interosseous cutaneous palmar to muscles of thumb in part five digital branches.
	ulnar	{ Articular to elbow to flexor carpi ulnaris to flexor profundus in part cutaneous branch of forearm and palm dorsal cutaneous of the hand superficial palmar division. { Communicating deep palmar nerve. two digital branches.
	musculo-spiral	{ Internal cutaneous to triceps and anconeus external cutaneous to supinator longus and extensor carpi radialis longior posterior interosseous { Muscular articular.
	radial	{ Cutaneous of back of thumb, of in- dex and middle fingers and half the ring.

CHAPTER IV.

DISSECTION OF THE THORAX.

SECTION I.

CAVITY OF THE THORAX.

Definition.	THE cavity of the thorax is the space included by the spinal column, the sternum, and ribs, and by certain muscles in the
Contents of cavity.	intervals of the bony framework. In it the organs of respiration, and the heart with its great vessels are lodged ; and through it the gullet, and some vessels and nerves are transmitted.
Dissection to open thorax.	<i>Dissection.</i> Supposing the soft parts covering in front the bony parietes of the thorax to have been examined and taken away, the cavity is to be opened by removing a portion of the anterior boundary. To make a sufficient opening in the thorax, the sternum is to be sawn through opposite the interval between the first two ribs, and again between the cartilages of the fifth and sixth ribs. After detaching the lining membrane (pleura) from the inner surface of the chest-wall, the student is to cut through the true ribs, except the first and seventh,* as far back as he can conveniently reach. The loose sternum and the ribs can be removed by dividing the internal mammary vessels, the triangulæ sterni, and the intercostal muscles in the first and sixth spaces. The bag of the pleura, and the cavity with its contents will be now ready for examination.
Sternum to be kept.	The sternum and the cartilages of the ribs will be required hereafter for the dissection of the ligaments.
Form in general ;	<i>Form.</i> The included cavity is irregularly conical, with the apex above and the base below ; and it appears, from the collapsed state of the lungs, to be only partly filled by the contained viscera, but during life the whole of the now vacant space is occupied by the expanded lungs. On a horizontal section its shape would appear broadly cordiform ; for the cavity is flattened on the sides, is diminished in the middle line by the prominent spinal column, and is projected backwards on each side of the spine.
on a cross section.	
Boundaries.	<i>Boundaries.</i> On the sides are the ribs with the intercostal muscles ; in front is the sternum ; and behind is the spine.

* The student must leave these ribs uncut ; the division of them will not be advantageous to him, and will injure the dissection of the neck and abdomen.

The base is constructed at the circumference by the last dorsal vertebra behind, by the end of the sternum in front, and by the ribs with their cartilages on each side ; while the space included by the bones is closed by the diaphragm.

The base is wider transversely than from before back, and is convex towards the chest ; though at certain spots it projects more than at others. Thus in the centre it is slightly lower than on each side, and is on a level with the base of the ensiform process. On the right side it rises to a level with the upper border of the fifth rib near the sternum ; and on the left, to the corresponding part of the upper border of the sixth rib.* From the lateral projections, the diaphragm slopes suddenly towards its attachment to the ribs, but more behind than before, so as to leave an angular interval between it and the wall of the chest. The level of this attached edge will be marked by an oblique line, over the side of the chest, from the base of the ensiform process to the eleventh dorsal spine ; but it differs slightly on the two sides, being rather lower on the left.

The apex of the space is continued higher than the osseous boundary, and reaches into the root of the neck. Its highest point is not in the middle line, for there the windpipe, blood-vessels, &c., lie ; but is prolonged on each side for one or two inches above the anterior end of the first rib, so that the apex may be said to be bifid. Each point projects between the scaleni muscles, and under the subclavian blood-vessels ; and in the interval between them lie the several objects passing between the neck and the thorax.

Dimensions. The extent of the thoracic cavity does not correspond with the apparent size externally ; for a part of the space included by the ribs below is occupied by the abdominal viscera ; and the cavity reaches upwards, as just stated, into the neck.

In consequence of the arched condition of the diaphragm, the depth of the space varies greatly at different parts. At the centre, where the depth is least, it measures generally from six to seven inches, but at the back about half as much again ; and the other vertical measurements can be estimated by means of the data given of the level of the base on the wall of the thorax.

Alterations in capacity. The size of the thoracic cavity is constantly varying during life with the condition of the ribs and diaphragm in breathing.

The horizontal measurements are increased in inspiration, when the ribs are raised and separated from one another, and are diminished in expiration as the ribs approach and the sternum sinks.

An alteration in depth is due to the condition of the diaphragm in respiration ; for the muscle descends when air is taken into the lungs, thus increasing the cavity ; and it ascends when the air is expelled from those organs, so as to restore the previous size of the space, or to diminish it in violent efforts. But the movement of the

* This is the height in the dead body. The level to which it may reach in great respiratory efforts during life will be stated with the account of the Diaphragm (p. 525).

diaphragm is not equal throughout, and some parts of the cavity will be increased more than others. For instance, the central tendinous piece, which is joined to the heart-case, moves but slightly ; but the lateral, bulging parts descend freely, and increase greatly the capacity of each half of the chest below by their separation from the thoracic parietes.

Thorax
lessened,
how.

The thoracic cavity may be diminished by the diaphragm being pushed upwards by enlargement, either temporary or permanent, of the viscera in the abdomen ; or by the existence of fluid in the latter cavity.

THE PLEURÆ.

Sac of the
pleura :

The pleuræ are two serous membranes, or closed sacs, which are reflected around the lungs in the cavity of the thorax. One occupies the right, and the other the left half of the cavity ; they approach each other along the middle of the chest, forming a thoracic partition or mediastinum.

form ;

Each pleura is conical in shape ; its apex projects into the neck above the first rib (fig. 101) ; and its base is in contact with the diaphragm.

outer sur-
face ;
inner sur-
face ;

The outer surface is rough, and is connected to the lung and the wall of the thorax by areolar tissue ; but the inner surface is smooth and free. Surrounding the lung, and lining the interior of one half of the chest, the serous membrane consists of a parietal part—costal pleura, and of a visceral part—pulmonary pleura.

disposition.

Difference in
sac of right,
and of left
side.

There are some differences in the shape and extent of the two pleural bags. On the right side the bag is wider and shorter than on the left ; and on the latter it is narrowed by the projection of the heart to that side.

The con-
tinuity is
here traced

The continuity of the bag of the pleura may be traced horizontally from a given point, over the lung and the wall, back to the same spot in the following manner :—Supposing the membrane to be followed outwards from the sternum, it lines the wall of the chest as far as the spinal column ; here it is directed forwards to the root of the lung, and is then reflected over the viscus, covering its surface, and extending into the fissures between the lobes. From the front of the root the pleura may be followed over the side of the pericardium to the sternum. Below the root the pleura forms a thin fold, the *ligamentum latum pulmonis*, which intervenes between the inner surface of the lung and the side of the pericardium.

from wall of
chest to
lung :

in upper
part diffe-
rent.

If the serous sac be traced above the root of the lung, it describes two distinct circles, one lining the chest-wall, and the other surrounding the lung.

Along
middle the
sacs form a
septum.

THE MEDIASTINUM. The median thoracic partition, or mediastinum, is formed by the inner portion of the parietal pleura on each side, and the structures interposed between the two membranes. It extends the whole depth of the thorax, and reaches from the spine to the sternum, thus separating the right and left pleural cavities. In the centre the two layers of serous membrane are widely separated by the heart ; but in front and behind they come nearer

together. The partition is artificially divided into four parts, which are distinguished as the superior, anterior, middle, and posterior mediastina.

The *superior mediastinum* is the portion of the septum above the pericardium, and may be defined as bounded below by a plane extending from the lower border of the body of the fourth dorsal vertebra to the junction of the manubrium and body of the sternum. It is limited in front by the manubrium with the origins of the sterno-hyoid and sterno-thyroid muscles, and behind by the upper four dorsal vertebræ and the lower ends of the longi colli muscles. Between the pleuræ in this part there are found, proceeding from before backwards, the following objects,—the remains of the thymus gland, several lymphatic glands, the innominate veins and the upper half of the superior cava, the phrenic and pneumo-gastric nerves, the transverse part of the arch of the aorta with its three large branches, innominate, left carotid and left subclavian, the trachea, œsophagus and thoracic duct, and the left recurrent laryngeal nerve.

Superior
medias-
tinum :

boundaries,

and
contents.

The *anterior mediastinum* is the part in front of the pericardium, and is very narrow in its upper half, since the two pleuræ meet behind the sternum from the level of the second to the fourth costal cartilages. Below the latter spot the left pleura inclines away from the middle line, and is separated from its fellow by an interval in which the pericardium comes into contact with the sternum and the left triangularis sterni muscle. The anterior mediastinum contains only some areolar tissue with a few small lymphatic glands. In some bodies the left pleura is continued behind the sternum nearly as far as the diaphragm.

Anterior
mediasti-
num is the
smallest :

contents.

The *middle mediastinum* is the largest part of the septum, and includes the pericardium with the contained heart and great vessels, viz., the ascending part of the arch of the aorta, the trunk of the pulmonary artery, and the lower half of the superior vena cava ; also the phrenic nerves, the roots of the lungs with the bronchial lymphatic glands, and on the right side the arch of the azygos vein.

Middle me-
diastinum :
contents.

The *posterior mediastinum* is the portion between the pericardium and the spine ; and the interpleural space is here larger than in front of the heart. Its extent and contents will be shewn by dividing the pleura on the right side behind the root of the lung. Enclosed between the serous layers of the posterior mediastinum are the descending thoracic aorta, the azygos veins, the œsophagus with the pneumo-gastric nerves, and the thoracic duct, as well as a set of lymphatic glands.

Posterior
medias-
tinum :

boundaries,

and con-
tents.

Dissection. The pleura and the fat are now to be cleaned from the side of the pericardium.

Clean peri-
cardium and

The root of the lung is to be dissected out by taking away the pleura and the areolar tissue from the front and back, without injuring its component vessels. In this dissection the phrenic artery and nerve will be found in front of the root, together with a few small nerves (anterior pulmonary) ; the last are best seen on the left side. Behind the root of the lung is the vagus nerve, dividing into branches ; and arching above the right one is the large azygos vein.

the root of
the lung.

Trace the
nerves

and azygos
vein.

For the present, the arch of the aorta and the small nerves on it may be left untouched.

Thymus
body in
foetus.

The THYMUS GLAND is an organ which is most developed in the infant, and the use of which is not understood. It is placed mainly in the upper part of the thorax ; and it may be best examined in a full-grown foetus.

Size

At birth it is about two inches in length, and of a greyish colour. It consists of two lobes of a conical form, which touch each other. Its upper end is pointed, and extends on the trachea as high as the thyroid body ; and the lower wider part reaches as far as the fourth rib. In the thorax it rests on the aortic arch and large branches, on the left innominate vein, and on the pericardium.

Remains in
adult.

In the adult all that remains of the thymus is a brownish rather firm material in the interpleural space behind the upper end of the sternum ; and after middle life it has generally disappeared altogether.

RELATIONS OF THE LUNGS.

Number
and use.

The lungs are two in number, and are contained in the cavity of the thorax, one on each side of the spinal column. In these organs the blood is changed in respiration.

Form

Each lung is of a somewhat conical form, and takes its shape from the space in which it is lodged. It is unattached, except at the inner side where the vessels enter forming the root ; and it is covered by the bag of the pleura. It has a base and apex, two borders and two surfaces ; and one or two fissures divide it into lobes.

and parts.

Base
touches
diaphragm :
shape and
level.

The base of the lung is hollowed in the centre and thin at the circumference, fitting the convexity of the diaphragm. Following the shape of that muscle, it is sloped obliquely from before backwards, and reaches in consequence much lower behind than in front. Its position with respect to the wall of the thorax may be indicated by a line drawn from the sixth chondro-sternal articulation to the tenth dorsal spine ; but it will be slightly lower in front on the left, than on the right side (fig. 101). The apex is rounded, and projects from one to two inches above the anterior end of the first rib, where it lies beneath the clavicle, the anterior scalenus muscle, and the subclavian artery.

Apex is in
the neck.

Anterior
edge is thin :
position on
right,
and left
side.

The anterior border is thin, and overlies in part the pericardium. On the right side it lies along the middle of the sternum as low as the sixth costal cartilage (fig. 101). On the left side it reaches the mid-line of the chest as low as the fourth costal cartilage ; but below that spot it presents a V-shaped notch (fig. 101), the apex of which is opposite the outer part of the cartilage of the fifth rib. The posterior border is half as long again as the anterior, and projects inferiorly between the lower ribs and the diaphragm ; it is thick and vertical, and is received into the hollow by the side of the spinal column.

Posterior
edge is
thick

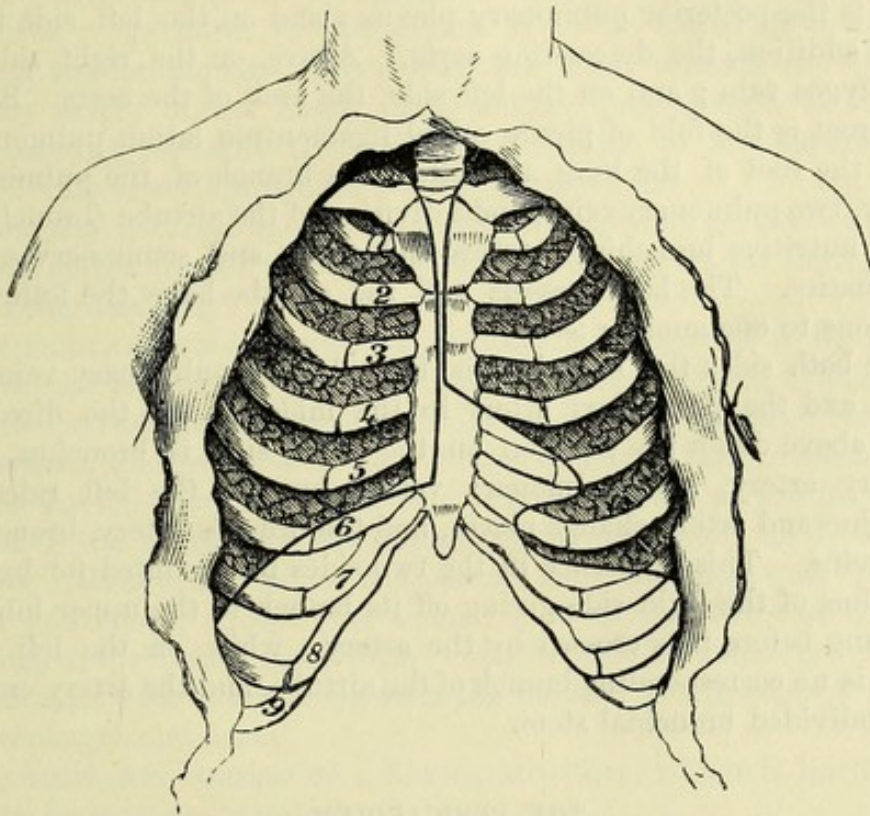
The outer surface of the lung is convex, and is in contact with the wall of the thorax : a large cleft divides it into two parts, and on the right side there is a second smaller fissure. The inner surface is flat when compared with the outer : at the fore part is a large hollow which lodges the heart and great vessels, and is most marked on the left lung ; and behind this is a fissure about three inches long, *hilum pulmonis*, which receives the vessels of the root of the lung.

External surface.

Internal surface

gives attachment to the root.

Fig. 101.*



inches long, *hilum pulmonis*, which receives the vessels of the root of the lung.

Each lung is divided into two lobes by an oblique fissure, which begins at the posterior border near the apex, and ends at the fore part of the base ; and the lower lobe is larger than the upper. In the right lung a second horizontal fissure is directed forwards from the middle of the oblique one to the anterior border, and cuts off a small triangular piece from the upper lobe : this is the third or middle lobe. Occasionally there may be a trace of the third lobe in the left lung.

Divison into lobes.

Left has two, and the right three lobes.

Besides the difference in the number of the lobes, the right lung is larger and heavier, and is wider and more hollowed out at the base, as well as being somewhat shorter than the left. The increased length and the narrowness of the left lung are due to the absence of a large projecting body like the liver below it, and to the direction of the heart to the left side.

Difference in form and size of the lungs.

* Diagram to show the difference in the anterior border of the right and left lung, the edge being indicated by the dark line ; and to mark the different level of the base on the two sides.

Root of the lung :	The <i>root of the lung</i> consists of the vessels entering the fissure on the inner surface ; and as these are bound together by the pleura and some areolar tissue they form a stalk, which attaches the lung to the heart and the windpipe. The root is situate at the inner surface, about midway between the base and apex, and about a third of the breadth from the posterior border of the lung.
situation ;	
relations.	In front of the root on both sides are the phrenic and the anterior pulmonary nerves, the former being some little distance from it ; and anterior to the right root is the descending cava. Behind on both sides is the posterior pulmonary plexus ; and on the left side there is, in addition, the descending aorta. Above, on the right side, is the azygos vein ; and on the left side, the arch of the aorta. Below each root is the fold of pleura called <i>ligamentum latum pulmonis</i> .
Constituents of the root ;	In the root of the lung are collected a branch of the pulmonary artery, two pulmonary veins, and a division of the airtube (bronchus) ; small nutritive bronchial arteries and veins, and some nerves and lymphatics. The large vessels and the airtube have the following positions to one another :—
their relative positions.	On both sides the bronchus is behind, the pulmonary veins in front, and the pulmonary artery in the middle. In the direction from above down the position on the right side is bronchus, pulmonary artery, and pulmonary veins ; but on the left side the bronchus and artery change places, and the order is artery, bronchus, and veins. This difference in the two sides is accounted for by the bronchus of the right side giving off its branch to the upper lobe of the lung before it is crossed by the artery ; while on the left side there is no corresponding branch of the airtube, and the artery crosses the undivided bronchial stem.

THE PERICARDIUM.

Pericardium.	The bag containing the heart is named the pericardium. It is situate in the middle of the thorax, in the interval between the two pleuræ.
Clean vessels of heart.	<i>Dissection.</i> Supposing the surface of the pericardium to be already cleaned, the student should next dissect out the large vessels above the heart, and trace the nerves.
First aorta,	The large artery curving to the left above the pericardium is the aorta, which furnishes three trunks to the head and the upper limbs, viz., from right to left, the innominate, the left common carotid, and left subclavian. On its left side lies the larger pulmonary artery.
then innominate veins	Above the arch of the aorta a large venous trunk, left innominate, crosses over the three arteries mentioned above, and ends by uniting on the right side with the right innominate vein in the upper cava. Several small veins, which may be mistaken for nerves, ascend over the aorta, and enter this trunk. Define the branches of this vein, and especially one crossing the aortic arch towards the left side, which is the left superior intercostal vein (fig. 108, <i>v</i>).
and branches,	
and upper cava.	The large vein by the side of the aorta is the upper cava ; and the azygos vein will be found opening into it behind.

Seek the following nerves of the left side, which cross the arch of the aorta :—The nerve most to the left, and the largest, is the vagus ; the next largest in size, in front of the vagus, is the phrenic. Between the preceding nerves, and close to the artery, are the left superficial cardiac nerve of the sympathetic, and the lower cervical cardiac branch of the left vagus ; of the two, the last is the smaller, and on the right of the other.

Seek nerves crossing arch of aorta.

The cardiac nerves from the left vagus and sympathetic are to be followed to a small plexus (superficial cardiac) in the concavity of the aorta. An offset of the plexus is to be traced downwards between the pulmonary artery and the aorta towards the right coronary artery of the heart ; and another prolongation is to be found coming forwards from the deep cardiac to the superficial plexus : this dissection is difficult, and requires care.

Dissect superficial plexus in arch of aorta.

When the pericardium is afterwards opened the nerves will be followed on the heart. Oftentimes these small nerves are destroyed in injecting the body.

The PERICARDIUM is somewhat conical in form, the wider part being turned towards the diaphragm, and the narrower part extending upwards beyond the heart on the large vessels. It is placed behind the sternum, and projects on each side of that bone, but much more towards the left than the right side. Laterally the pericardium is covered by the pleura, and the phrenic nerve and vessels lie between the two. Its anterior surface is separated from the chest-wall by the pleuræ and lungs, except over a small area on the left side corresponding to the lower part of the anterior mediastinum (p. 333) ; and behind, in the interval between the pleuræ, it is in contact with the oesophagus and aorta.

Pericardium : size and form ; position ; relations.

The heart-case consists of a fibrous structure, which is lined internally by a serous membrane.

Composition.

The *fibrous part* surrounds the heart, and is pierced by the large vessels joining that organ, with the exception of the inferior cava : it gives prolongations around the vessels, and the strongest of these sheaths is on the aorta. Below, it is united to the central tendon of the diaphragm.

Fibrous part gives sheaths to vessels.

This membrane is thickest at the upper part, and is formed of fibres crossing in different directions, many being longitudinal. When the pericardium has been cut open, the serous lining will be seen.

The *serous sac* consists of a parietal and a visceral part, which are continuous with one another along the great vessels. The parietal part lines the fibrous membrane, with which it is inseparably united, and the included portion of the diaphragm ; while the visceral part covers the heart. Where it is reflected around the vessels, it encloses the pulmonary artery and aorta in one sheath ; but the veins are not completely surrounded, their posterior surfaces being devoid of a serous investment. At the back of the left auricle the serous membrane forms a pouch between the pulmonary veins of the two sides.

Serous layer lines fibrous, and covers heart ; disposition over vessels ;

In front of the root of the left lung the serous layer forms a vestigial fold.

small triangular fold, the *vestigial fold of the pericardium* (Marshall), between the pulmonary artery and the upper pulmonary vein: this includes the remains of a left superior cava which existed in the fœtus.

Vessels. The *vessels* of the pericardium are derived from the aorta, the internal mammary, the bronchial, the œsophageal, and the phrenic arteries.

Nerves. *Nerves.* According to Luschka the pericardium receives nerves from the phrenic, sympathetic, and right vagus.

THE HEART AND ITS LARGE VESSELS.

The heart is hollow. The heart is a hollow muscular organ by which the blood is propelled through the body. Into it, as the centre of the vascular system, veins enter; and from it the arteries issue.

Form. *Form.* The heart is conical in form, but somewhat compressed from before backwards. The anterior surface is convex; and the posterior or lower is nearly flat. The left border is thick and round; while the right is thin, sharp, and less firm.

Size and weight. *Size.* The size of the heart varies greatly; and it is usually smaller in the woman than in the man. Its average measurements may be said to be about five inches in length, three inches and a half in width, and two and a half in thickness. Its weight is generally from ten to twelve ounces in the male, and from eight to ten in the female.

Situation in the chest. *Position and direction.* The heart lies behind the lower two-thirds of the sternum, and projects on each side of that bone, but more to the left than the right. Its axis is directed very obliquely, from behind forwards and to the left, as well as somewhat downwards.

Base; The base is towards the spine, being opposite the sixth, seventh and eighth dorsal vertebræ, and looks backwards and upwards.

apex; The apex strikes the wall of the chest during life in the fifth intercostal space of the left side, at the junction of the ribs with their cartilages. The anterior surface looks forwards and somewhat upwards; while the posterior surface is nearly horizontal, resting on

surfaces; The anterior surface looks forwards and somewhat upwards; while the posterior surface is nearly horizontal, resting on the diaphragm. The right margin is turned to the front; and the left is placed farther back.

borders; In consequence of the oblique position of the heart, the right half and the apex are directed towards the thoracic wall, though mostly with lung intervening; while the left half is undermost and deep in the cavity.

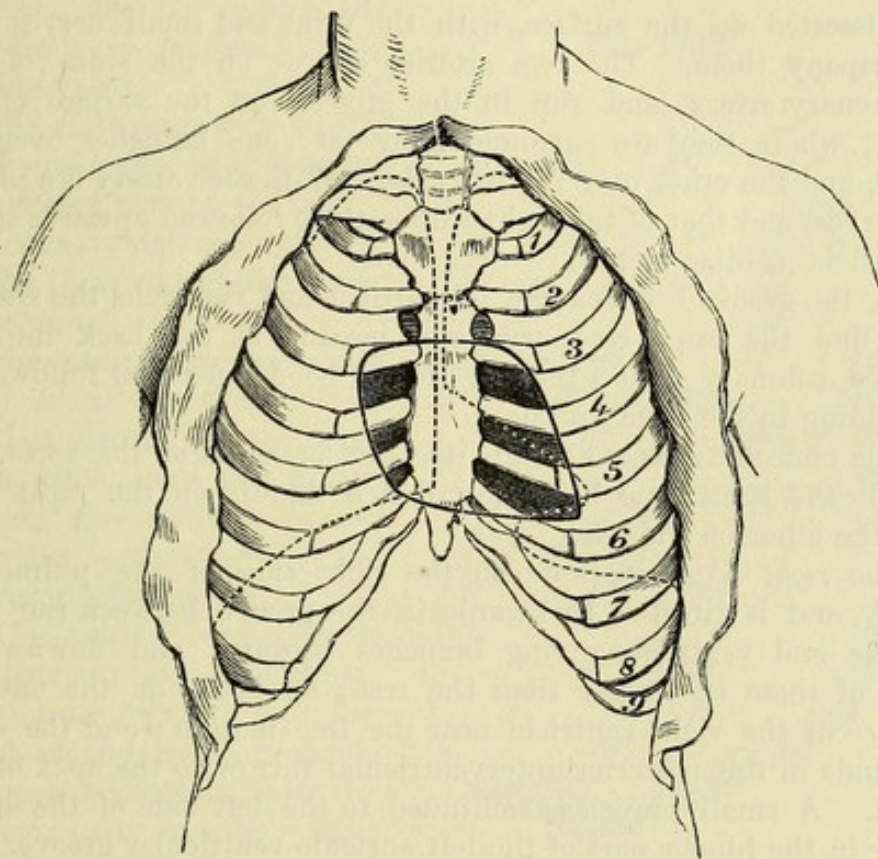
right and left halves. *Limits* (fig. 102). The extent of the heart in relation to the front of the chest may be indicated as follows:—The upper limit is marked by a line across the sternum from the lower edge of the second costal cartilage of the left side to the upper edge of the third cartilage of the right side; and the lower limit by a line, slightly convex downwards, from the seventh chondro-sternal articulation of the right side to the spot where the apex touches, the latter point being usually about one inch and a half below, and three-quarters of an inch to the sternal side of the nipple. On the right side the

Extent of the heart upwards, downwards, to right,

heart projects about one inch and a half from the middle line of the sternum ; and on the left, the apex is distant from three to three and a half inches from the centre of the breast-bone.

The portion of the heart which is uncovered by lung (the area of superficial cardiac dulness) is included between the middle line of the sternum, in its lower third, and a line drawn from the centre of

Fig. 102.*



the breast-bone between the fourth costal cartilages to the apex of the heart (fig. 102).

Component parts. The heart is a double organ ; and in each half there are two chambers, an auricle and a ventricle, which communicate together, and are provided with vessels for the entrance and exit of the blood. The surface is marked by grooves indicating this division. Thus, passing circularly round the heart, nearer the base than the apex, is a groove which cuts off the thin auricular from the fleshy ventricular part ; and on each surface there is a longitudinal sulcus over the partition between the ventricles. The inter-ventricular groove is nearer the left border of the heart in front, and the right border behind.

The *auricles* are two, right and left, and their wall is much thinner than that of the ventricles. They are placed deeply at the base of the heart ; and each is prolonged forwards into a small

* Diagram shewing the position of the heart to the ribs and sternum, the soft parts being removed from the exterior of the thorax. The edge of each lung is shewn by a dotted line. The left auricle extends somewhat higher than the area indicated in the figure, projecting into the second intercostal space.

and append-
ages. tapering part known as the *auricular appendix* or *auricle proper*, so-called from its resemblance to a dog's ear.

Ventricles : The *ventricles* reach unequal distances on the two aspects of the heart ;—thus the right one forms the thin right border and most of the anterior surface ; but the left enters alone into the apex, and constructs the left border, and the greater part of the posterior surface of the heart.

Dissect
coronary
vessels and
nerves, *Dissection.* Before opening the heart, the coronary arteries are to be dissected on the surface, with the veins and small nerves that accompany them. The two arteries appear on the sides of the pulmonary artery, and run in the grooves on the surface of the heart, where they are surrounded by fat : one branches over the right, and the other over the left side. With each artery is a plexus of nerves, and that of the right side is to be followed upwards to the superficial cardiac plexus.

and coro-
nary sinus. In the groove between the left auricle and ventricle the student will find the large coronary vein, passing at the back into the dilated coronary sinus : the last should be defined and followed to its ending in the right auricle.

Two arteries
of the heart,
viz., The CORONARY ARTERIES are the first branches of the aorta, and supply the heart, one being distributed mainly on the right side, and the other on the left.

right coro-
nary, The *right artery* appears on the right side of the pulmonary trunk, and is directed backwards in the groove between the right auricle and ventricle, giving branches upwards and downwards. Two of these are larger than the rest ; one runs on the anterior surface of the right ventricle near the free margin ; and the other descends in the posterior interventricular furrow to the apex of the heart. A small branch is continued to the left side of the heart, lying in the hinder part of the left auriculo-ventricular groove.

and left
coronary : The *left artery* passes outwards behind the pulmonary trunk to the left side of that vessel, where it divides into two branches. Of these, the anterior is the larger, and descends on the front of the heart in the groove between the two ventricles to the apex ; while the posterior runs backwards between the left auricle and ventricle. The branches of the two coronary arteries communicate on the surface of the heart, but their anastomoses are very fine.

Cardiac
veins. The VEINS OF THE HEART (fig. 103) differ in their arrangement from the arteries, and are for the most part collected into one large trunk—the coronary sinus.

Coronary
sinus : The *coronary sinus* (fig. 103,¹) will be seen on raising the heart to be placed in the sulcus between the left auricle and ventricle. About an inch usually in length, it is joined at the one end by the great cardiac vein (⁴) ; and at the other it opens into the right auricle. It is crossed by the muscular fibres of the left auricle. Inferiorly and at its right end it receives some branches from the back of the ventricles ([†]), and at its left extremity another small vein (²), the *oblique vein* (Marshall), which descends to it along the back of the left auricle.

veins join-
ing it ; valves. On slitting up the sinus with the scissors the openings of its

different veins will be seen to be guarded by valves, with the exception of the oblique vein; and at its right end is the Thebesian valve of the right auricle.

The *left coronary or great cardiac vein*, beginning in front near the apex of the heart, first ascends in the interventricular groove, and then turns to the back in the sulcus between the left auricle and ventricle, to open into the coronary sinus (fig. 103,⁴). It receives branches, mainly from the left side of the heart, in its course; and its ending in the sinus is marked by a double valve.

The *right coronary vein* (³) is of small size, and runs in the hinder part of the right auriculo-ventricular groove to the right end of the coronary sinus.

The *posterior cardiac veins* (††) ascend on the back of the left ventricle to the coronary sinus; and one larger vessel, the *middle cardiac vein*, lies in the posterior interventricular furrow.

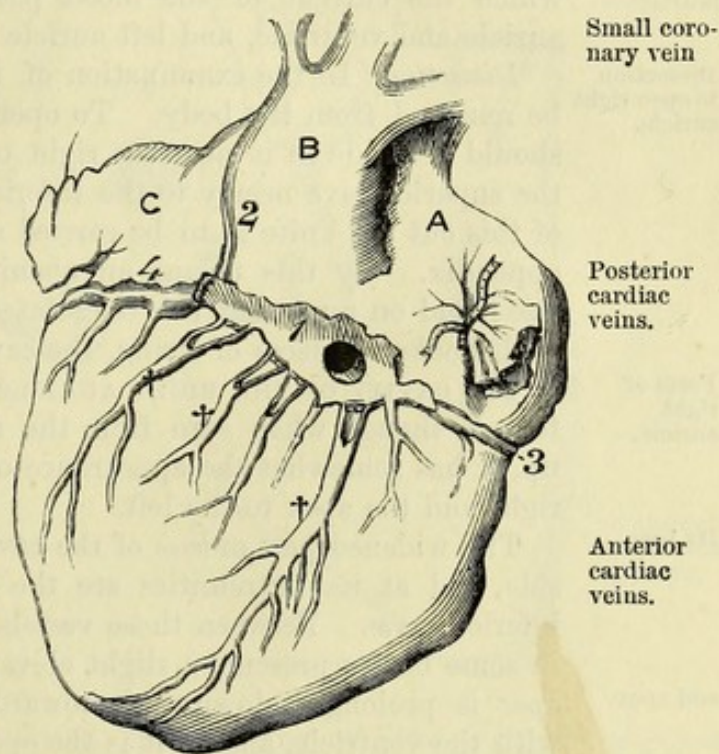
The *anterior cardiac veins* are three or four in number, and run upwards on the front of the right ventricle to open separately into the lower part of the right auricle.

Smallest cardiac veins. Other small veins lie in the substance of the heart, and are noticed in the description of the right auricle.

CARDIAC NERVES. The nerves for the supply of the heart are derived from a large plexus (cardiac) beneath the arch of the aorta, from which offsets proceed to accompany the coronary arteries. The greater part of this plexus is deeply placed, and will be dissected at a later stage, but a superficial prolongation may now be seen.

The *superficial cardiac plexus* is placed below the arch of the aorta, to the right of the ductus arteriosus. The nerves joining it are the left superficial cardiac of the sympathetic, the lower cervical cardiac of the left vagus (p. 357), and a considerable bundle from the deep cardiac plexus. A small ganglion is sometimes seen in the plexus. Inferiorly it sends off nerves along the right coronary artery to the heart. A few filaments run on the left division of the pulmonary artery to the left lung.

Fig. 103.*



Large coronary vein.

Small coronary vein

Posterior cardiac veins.

Anterior cardiac veins.

Smallest veins.

Nerves of heart.

Superficial plexus

ends in right coronary.

* Back of the heart with its veins and the coronary sinus. (Marshall.)
A. Right auricle. B. Left auricle, with the appendix, c. 1. Coronary sinus. 2. Oblique vein. 3. Right coronary vein. 4. Left or great coronary vein. †† Posterior cardiac veins; the larger one on the right is the middle cardiac vein.

Coronary plexuses, right	The <i>right coronary nerves</i> pass from the superficial plexus to the right coronary artery, and receive near the heart a communicating offset from the deep cardiac plexus.
and left ;	The <i>left coronary nerves</i> are derived, as will be subsequently seen, from the deep cardiac plexus, and follow the left coronary artery.
ending in the heart.	At first the nerves surround the arteries, but they soon leave the vessels, and becoming smaller by subdivision, are lost in the muscular substance of the ventricles. On and in the substance of the heart the nerves are marked by small ganglia.
Four cavities of the heart.	The CAVITIES OF THE HEART may be examined in the order in which the current of the blood passes through them, viz., right auricle and ventricle, and left auricle and ventricle.
Dissection to open right auricle.	<i>Dissection.</i> In the examination of its cavities the heart is not to be removed from the body. To open the right auricle, an incision should be made in it near the right or free border, extending from the superior cava nearly to the inferior cava ; and from the centre of this cut the knife is to be carried across the anterior wall to the appendix. By this means an opening will be made of sufficient size ; and on removing the coagulated blood, and raising the flaps with hooks or pieces of string, the cavity may be examined.
Form of right auricle.	The CAVITY OF THE RIGHT AURICLE (fig. 104) is of an irregular form,* though when seen from the right side, with the flaps held up, it has somewhat the appearance of a cone, with the base to the right and the apex to the left.
Its base,	The widened part or <i>base</i> of the cavity is turned towards the right side, and at its extremities are the openings of the superior and inferior cavæ. Between those vessels the wall projects a little, and in some bodies presents a slight elevation (tubercle of Lower). The
and apex.	<i>apex</i> is prolonged downwards towards the junction of the auricle with the ventricle, and in it is the opening into the right ventricular cavity.
Anterior wall presents appendix.	The <i>anterior wall</i> is thin and loose. Near the top is an opening leading into the pouch of the appendix (<i>h</i>), which will admit the tip of the little finger. Near, and in the interior of the appendix are prominent fleshy bands, named <i>musculi pectinati</i> , which run mostly in a transverse direction, and form a network that contrasts with the general smoothness of the auricle.
Posterior wall is marked by fossa ovalis.	The <i>posterior wall</i> corresponds mostly with the septum between the auricles, in consequence of the position of the heart (p. 338). On it, close to the inferior cava, is a large oval depression, the <i>fossa ovalis</i> (<i>d</i>), which is the remains of an opening between the auricles in the fœtus : inferiorly it merges into the lower cava. A thin semitransparent structure forms the bottom of the fossa ; and there is oftentimes a small oblique aperture into the left auricle at its upper part. Around the upper three-fourths of the fossa is an elevated band of muscular fibres, called <i>annulus ovalis</i> or <i>isthmus</i>

* The term cavity of the auricle is sometimes confined to the part in the appendix, and the name atrium or sinus venosus is then given to the rest of the space here named auricle.

Viessensii, which is most prominent above and on the left side, and gradually subsides below. Annulus of Viessens.

Altogether at the lower end of the posterior wall is the aperture of the coronary sinus (*e*). Other small apertures, named *foramina of Thebesius*, are scattered over this surface; some lead only into depressions; but others

are the mouths of veins of the substance of the heart (smallest cardiac veins; p. 341).

The chief apertures in the auricle are those of the two cavæ, coronary sinus, and ventricle. The opening of the superior cava (*a*) is at the top of the auricle, and looks slightly forwards. The inferior cava (*b*) enters the lowest part of the cavity at the back, close to the septum, and is directed inwards to the fossa ovalis (*d*). The auriculo-ventricular opening (*c*) is the largest of all, and is situate at the lower and fore part of the cavity. Between

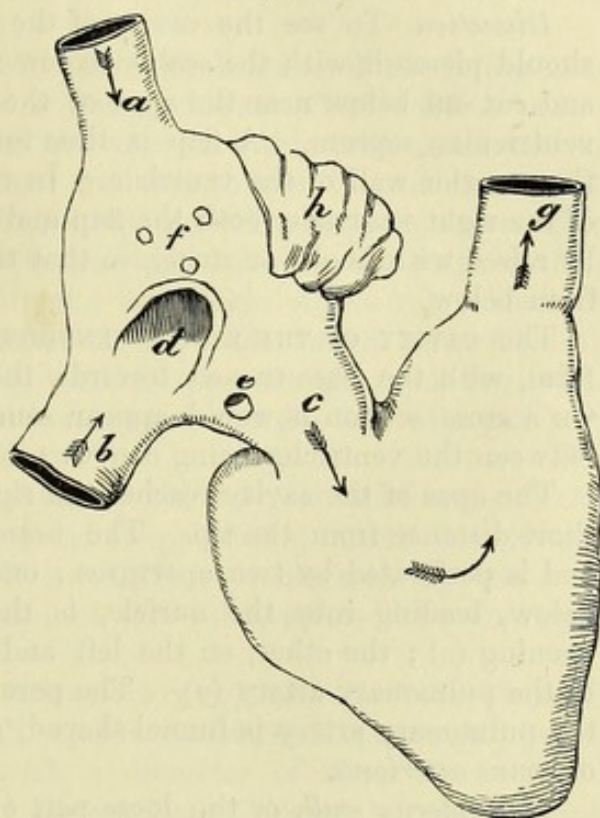
this and the septum is placed the opening of the coronary sinus (*e*).

All the large vessels, except the superior cava, have some kind of valve. In front of the inferior cava is a thin fold of the lining membrane of the cavity, the *Eustachian valve*, which is only a remnant of a much larger structure in the fœtus. This fold is semilunar in form, with its convex margin attached to the anterior wall of the vein, and the other free in the cavity of the auricle. The valve is wider than the vein opening; and its surfaces are directed forwards and backwards: it is often cribriform. The aperture of the coronary sinus is covered by a thin fold of the lining membrane—the *valve of Thebesius*. The auriculo-ventricular opening will be seen, in examining the right ventricle, to be provided with a valve, which prevents the blood flowing back into the auricle.

In the adult there is but one current of blood in the right auricle towards the ventricle. But in the fœtus there are two streams in

* Diagram of the two cavities of the right side of the heart. *a*. Upper cava. *b*. Lower cava. *c*. Right auriculo-ventricular opening. *d*. Fossa ovalis. *e*. Opening of the coronary sinus. *f*. Foramina Thebesii. *g*. Pulmonary artery. *h*. Auricular appendix.

Fig. 104.*



and smallest veins.

Situation of cavæ,

of auriculo-ventricular opening,

of coronary sinus.

Valves of chief apertures.

Inferior cava has Eustachian valve;

one to coronary sinus,

and to auriculo-ventricular opening.

Course of blood in auricle in adult,

and in the
fœtus.

the cavity ; one of pure, and the other of impure blood, which cross one another in early life, but become more commingled as birth approaches. The placental or pure blood, entering by the inferior cava, is directed by the Eustachian valve into the left auricle, through the foramen ovale in the septum ; while the current of systemic or impure blood, coming in by the superior cava, flows downwards in front of the other to the right ventricle.

To open
right
ventricle.

Dissection. To see the cavity of the right ventricle, the student should pierce it with the scalpel below the opening from the auricle, and cut out below near the apex of the heart without injuring the ventricular septum. A flap is thus formed, like the letter V, of the anterior wall of the ventricle. In the examination of the cavity of the right ventricle, both the flap and the apex of the heart should be raised with hooks or string, so that the space may be looked into from below.

Cavity of
right ven-
tricle.

The CAVITY OF THE RIGHT VENTRICLE (fig. 104) is triangular in form, with the base turned towards the auricle of the same side. On a cross section it would appear semilunar in shape, the septum between the ventricles being convex towards the cavity.

Apex.

Base and its
openings.

The *apex* of the cavity reaches the right border of the heart at a short distance from the tip. The *base* of the ventricle is sloped, and is perforated by two apertures ; one of these, to the right and below, leading into the auricle, is the right auriculo-ventricular opening (*c*) ; the other, on the left and much higher, is the mouth of the pulmonary artery (*g*). The part of the cavity leading up to the pulmonary artery is funnel-shaped, and is named *infundibulum* or *conus arteriosus*.

Anterior
and

posterior
wall.

The *anterior wall*, or the loose part of the ventricle, is comparatively thin, and forms most of the anterior surface of the ventricular portion of the heart. The *posterior wall* corresponds with the septum between the ventricles, and is much thicker.

Interior of
the cavity
is uneven :

on it there
are three
sets of fleshy
columns.

Over the greater part of the cavity the surface is marked by projecting muscular bands, the *columnæ carneæ* ; but near the aperture of the pulmonary artery the wall becomes smooth. The fleshy columns are of various sizes, and of three different kinds. Some form merely a prominence in the ventricle, especially on the septum. Others are attached at each end, but free in the middle (*trabeculae carneæ*). And a third set, which are fewer in number and much the largest, project into the cavity, and form rounded bundles, named *musculi papillares* ; these give attachment by their free ends to the little tendinous cords of the valve of the auriculo-ventricular opening.

Opening
from the
auricle :

position,
form and
size ;

The *auriculo-ventricular orifice* (*c*) is situate in the base of the ventricle, and behind the right half of the sternum, on a level with the fourth intercostal space. It is oval in shape, and measures about four inches in circumference, being slightly larger than the corresponding aperture of the left side.

is guarded
by the tri-
cuspid valve,

Fixed around the opening is a large membranous valve, which projects into the cavity of the ventricle. At its attached margin the valve is undivided ; but its lower part is notched, so as to form

three pendent cusps or tongues, whence the name tricuspid is given to it. Into the cusps are inserted small fibrous bands—the chordæ tendineæ, which unite them to the muscular wall of the ventricle.

The three cusps are thus placed ;—one (*right*) is against the anterior wall of the ventricle ; another (*posterior*) touches the septum ; and the third (*left* or *infundibular*), the largest and most moveable, is placed between the auriculo-ventricular opening and the infundibulum.

the cusps of which are right, posterior and left.

The tricuspid valve consists of a duplicature of the lining membrane of the heart, enclosing fibrous tissue. The central part of each tongue is strong, while the edges are thin and notched ; and between the main pieces there are often thinner intermediate points.

Structure of valve ;

The chordæ tendineæ, which keep the valve in place, ascend from the muscoli papillares in the intervals between the cusps, and are connected in each space with the two pieces of the valve bounding it.* They end on the surface of the cusps turned away from the opening, a few reaching the attached upper margin ; but the greater number join the central thickened part, and the thin edge and point of the tongue.

attachment by tendinous cords ;

As the blood enters the cavity the valve is raised so as to close the opening into the auricle ; and its protrusion into the latter cavity during the contraction of the ventricle is arrested by the small tendinous cords. The closure of this valve assists in producing the first sound of the heart.

its use.

The mouth of the pulmonary artery (*g*) will be seen when the incision in the anterior wall of the ventricle is prolonged into it. The opening is circular, with a diameter of about an inch. It occupies the summit of the funnel-shaped portion of the ventricle, and is placed opposite the upper edge of the third costal cartilage of the left side, close to its junction with the sternum.

Pulmonary orifice :

size and position ;

Pulmonary valve. Guarding the orifice of the pulmonary artery is a valve consisting of three semilunar or sigmoid flaps. Each flap is attached to the side of the vessel by its convex border, and is free at the opposite edge, in which there is a slightly thickened nodule—the *corpus Arantii*. In the wall of the artery opposite each flap is a slight hollow—the *sinus of Valsalva*.

its valve of three flaps ;

dilatation of artery.

This valve resembles the tricuspid in structure, being formed of fibrous tissue with a covering of the lining membrane. In each flap the fibres have this arrangement : there is one band along the attached margin ; a second runs along the free edge, and is connected with the projecting nodule ; and a third set of fibres is directed from the nodule across the flap, so as to leave a semilunar interval named *lunula* on each side near the free edge.

Structure of valve ;

The use of the valve is obvious, viz., to give free passage to fluid in one direction, and to prevent its return. While the blood is entering the artery the flaps are separated ; but when the elasticity

and use.

* The papillary muscles are collected into two principal groups, an anterior sending its tendons to the right and left cusps, and a posterior, to the right and posterior cusps. In the interval between the left and posterior segments of the valve the tendinous cords are very small, and spring from the septum.

of the vessel acts on the contained blood they are thrown together in the centre of the vessel, and arrest the flow of the fluid into the ventricle. They are concerned in giving rise to the second sound of the heart.

To open left auricle.

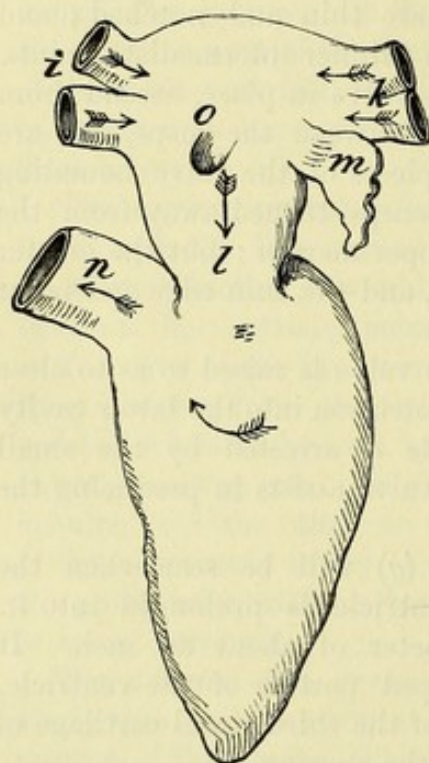
Dissection. To open the cavity of the left auricle, the apex of the heart is to be raised, and a cut is to be made across the posterior surface of the auricle from the right to the left pulmonary veins. Another short incision should be made downwards at right angles to the first. The heart must necessarily be held up during the examination of the cavity.

Fig. 105.*

Form of cavity of left auricle.

Appendix and muscoli pectinati.

On septum remnant of foramen ovale.



The CAVITY OF THE LEFT AURICLE (fig. 105) is smaller than that of the right side, and is rather oblong in shape, with its longest diameter directed transversely. It is joined at each end by the two pulmonary veins of that side; and at the lower and fore part it opens into the left ventricle.

In the front wall, at the left extremity, is the opening of the appendix (*m*), which is longer and narrower than the corresponding part on the right side. Musculi pectinati are also present, but on this side they are usually confined to the appendix.

To the right of the opening into the appendix, on the part of the wall formed by the septum, is a superficial fossa (fig. 105, *o*), the remains of the

oval aperture through that partition; this is bounded below by a projecting margin, concave upwards, which is the edge of the valve that closed the opening in the foetus. This impression in the left auricle is above the fossa ovalis in the right cavity, because the aperture between the two in the foetus was an oblique canal through the septum.

Openings :
four pulmo-
nary veins,
and to
ventricle.

The *apertures* in this auricle are those of the four pulmonary veins, and the opening into the left ventricle. The mouths of each pair of pulmonary veins are close together; those from the right lung (*i*) open into the extreme right of the auricle against the septum, and those from the left lung (*k*) enter the opposite side of the cavity, near the appendix.

Valves.

The pulmonary veins have no valves. The aperture into the ventricle (*l*) will be subsequently seen to have a large and complicated valve to guard it, as on the right side.

* Diagram of the two cavities of the left side of the heart. *i*. Right pulmonary veins. *k*. Left pulmonary veins. *l*. Left auriculo-ventricular opening. *m*. Auricular appendix. *n*. Aorta. *o*. Remains of the foramen ovale.

In the adult the blood enters this cavity from the lungs by the pulmonary veins, and flows into the left ventricle by the large opening between the two. In the fœtus only a very small quantity of blood passes through the lungs; and the left auricle receives its pure blood at once from the right auricle through the aperture in the septum (foramen ovale).

Current of
blood in
adult;
in fœtus.

Dissection. The left ventricle may be opened by an incision along both the anterior and the posterior surfaces, near the septum; these are to be joined at the apex, but are not to be extended upwards so as to reach the auricle. On raising the triangular flap the interior of the cavity will be visible.

How to
open left
ventricle.

The CAVITY OF THE LEFT VENTRICLE (fig. 105) is longer and more conical in shape than that of the opposite ventricle; and is oval, or almost circular, on a transverse section.

Form of left
ventricle.

The *apex* of the cavity reaches the apex of the heart. The *base* is turned towards the auricle; and in it are the openings into the aorta (*n*) and the left auricle (*l*).

Apex.

Base with
openings.

The *wall* of this ventricle is thicker than that of the right, and the anterior boundary is formed for the most part by the septum.

Wall.

Its *surface* is irregular, like that of the right ventricle, in consequence of the projection of the columnæ carneæ; but near the great artery (aorta) the surface is smoother. There are three sets of fleshy columns in this as in the right ventricle; and the muscoli papillares, which give attachment to the tendinous cords of the valve, are strongly marked: these are arranged in two large bundles, which spring from the right and left sides of the cavity.

Inner sur-
face has
fleshy
columns,

and some
very large.

The *left auriculo-ventricular opening* is placed beneath the orifice of the aorta, but close to it, only a thin fibrous band intervening between the two. It is rather smaller than the corresponding aperture of the right side, being about three inches and a half in circumference, and is longest in the transverse direction. The centre of the opening corresponds to the junction of the fourth costal cartilage of the left side with the sternum. It is furnished with a membranous valve (mitral) which projects into the ventricle.

Left auri-
culo-ventri-
cular aper-
ture:

form and
size;

position.

The *mitral valve* is stronger and of greater length than the tricuspid, and has also firmer and more tendinous cords: it takes its name from a fancied resemblance to a mitre. Attached to a fibrous ring round the aperture, it is divided below by a notch on each side into two pieces. Its segments lie one before the other, with their edges directed to the sides, and their surfaces towards the front and back of the cavity. The anterior tongue of the valve intervenes between the auricular and aortic openings, and is larger and looser than the posterior.

Mitral
valve:

segments;

The mitral resembles the tricuspid valve in its structure and office. Its segments consist of thicker and thinner parts; and in the notches at the sides there are also thinner pieces between the two primary segments. The chordæ tendineæ ascend to be attached to the valve in the notches between the tongues; and they end on the segments in the same way as in the tricuspid valve. Each of the large papillary muscles acts on both portions of the valve.

structure;

attachment
of cords;

use.	While the blood is entering the cavity, the cusps of the valve are separated ; and when the ventricle contracts, they meet to close the passage into the left auricle. In combination with the tricuspid it assists in producing the first sound of the heart.
Aortic opening:	The <i>opening of the aorta</i> , anterior to that of the auricle, is close to the septum. This aperture is round, and rather smaller than that of the pulmonary artery, measuring slightly less than an inch in diameter. It is situate behind the left half of the sternum, on a level with the lower border of the third costal cartilage.
size and position ; valve.	In its interior is a <i>valve</i> of three semilunar or sigmoid flaps, which are thicker and stronger than the corresponding parts in the pulmonary artery, but have a like structure and attachment. The projection in the centre of each valve, the <i>corpus Arantii</i> , is better marked. Opposite each valve the coat of the aorta is bulged as in the pulmonary artery, though in a greater degree, and forms a hollow on the inner side, named <i>sinus of Valsalva</i> . The apertures of the coronary arteries are placed in two of these sinuses.
Sinuses of Valsalva.	
Use.	Like the valves in the pulmonary artery, these meet in the middle to prevent the blood passing back into the ventricle, and combine with them in causing the second sound of the heart.
Position of apertures	<i>Position of the ventricular apertures.</i> Two openings have been seen in each ventricle,—one of the auricle of its own side of the heart, and one of an artery.
of arteries,	The apertures of the arteries (aorta and pulmonary) are nearest the septum ; and as the two vessels were originally formed from one tube, they are close together ; but of the two, the pulmonary artery is anterior and more to the left, as well as somewhat higher.
and of auricles.	The aperture of communication with each auricle is nearer the circumference of the heart, and is posterior to the artery issuing from the fore part of the ventricle. The left auriculo-ventricular opening is nearest of all to the back of the heart.
Structure of the heart.	STRUCTURE. The heart is composed chiefly of muscular fibres, together with certain fibrous rings and a fibro-cartilage.
Directions.	The structure may be studied in the heart of the sheep or ox, in which the muscular substance has been hardened, and the connective tissue destroyed by boiling, so as to allow of the fibres being separated. The description of the structure of the heart may be omitted by the student till a suitable preparation of the fibres can be made.
Fibrous bands	The <i>fibrous structure</i> forms rings around the auriculo-ventricular and arterial orifices, and is prolonged into the valves connected with those openings.
form rings around auriculo-ventricular	The <i>auriculo-ventricular rings</i> give attachment to the framework of fibrous tissue in the tricuspid and mitral valves ; and the band surrounding the left auriculo-ventricular opening is blended in front with the aortic ring.
and arterial openings.	The <i>arterial rings</i> surround the aortic and pulmonary orifices ; and the margin of each towards the artery forms three notches with intervening projections. The notches are occupied by thinner parts of the arterial wall bounding the sinuses of Valsalva ; and to the concave edges the sigmoid flaps of the valve are attached.

Behind the aortic opening, between it and the auriculo-ventricular apertures, is a piece of *fibro-cartilage*, with which the fibrous rings are united. Fibro-cartilage.

The *muscular fibres* of the heart, although involuntary, are striped; but they differ in their character from those of the voluntary muscles. The fibres of the auricles are distinct from those of the ventricles. Muscular substance of heart.

In the *wall of the auricles* the fibres are mostly transverse (fig. 106, *a, b*), and are best marked near the ventricles, though they form there but a thin layer; and some of the fibres dip into the septum between the auricular cavities. Besides this set, there are annular fibres surrounding the appendages of the auricles and the endings of the different veins; and lastly, a few looped fibres (*c, d*) pass obliquely over the auricle from front to back.

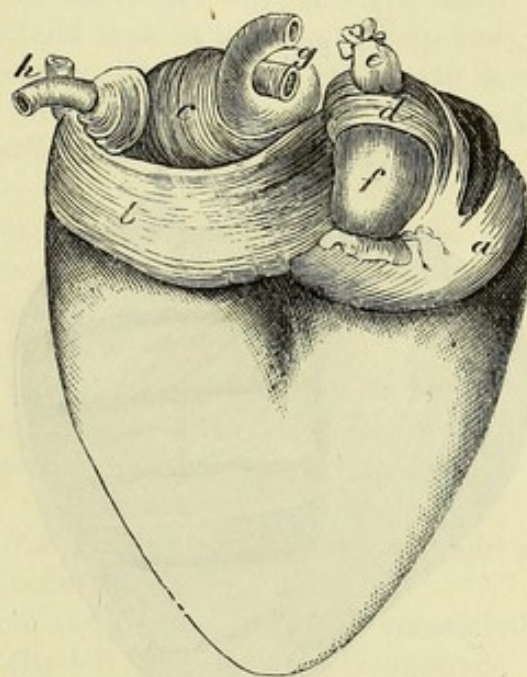
Dissection. The auricles having been learnt, separate them from the ventricles by dividing the fibrous auriculo-ventricular rings. Next clean the fleshy fibres of the ventricles by removing all the fat from the base of the heart around the two arteries (aorta and pulmonary), and from the anterior and posterior surfaces.

Before cutting into the heart, let the student note that the anterior surface is to be recognised by the fibres turning in at the septum, with the exception of a small band at the base and another at the apex; while on the posterior aspect the fibres are continued from the left to the right ventricle across the septum.

To shew the direction of the muscular bundles in the left ventricle, divide the superficial fibres in front longitudinally near the septum, and transversely about half an inch below the left auriculo-ventricular opening; and reflect a thin layer of the fibres carefully towards the left side. In the same way a second layer is to be reflected; then a third, and so on, each layer that is raised being about as thick as the thin end of the scalpel. It will not be difficult to demonstrate thus six or seven layers in the wall; and as each is raised, the fleshy fibres will be seen to change their direction (fig. 107). Dissection of left ventricle,

On the right side a similar dissection may be made, and a like number of layers may be displayed, but greater care will be necessary and of right.

Fig. 106.*



are transverse,
annular,
and looped.

Detach
auricles

* Muscular fibres of the auricles. *a.* Transverse fibres of the right, and *b.* of the left auricle. *c.* Looped fibres of the left, and *d.* of the right auricle. *e.* Superior cava. *f.* Inferior cava. *g.* Right, and *h.* left pulmonary veins. Annular fibres surround the veins.

owing to the thinness of the wall. Make a vertical cut along the anterior aspect from the root of the pulmonary artery to the apex of the ventricle ; and reflect the several layers inwards and outwards. As the superficial ones are raised, their fibres may be followed into the septum in front, and across the middle line into the wall of the left ventricle at the back.

Thickness
of left ven-
tricle,

of right,
and of
septum :

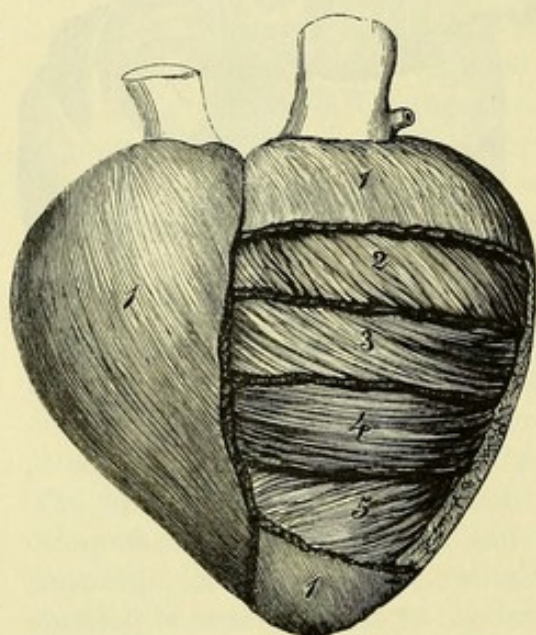
Thickness of ventricular walls. The wall of the left ventricle is in general nearly three times as thick as that of the right. Its thickest part is about one-fourth of its length from the base ; and at the apex it is very thin. The free wall of the right ventricle is of more uniform thickness than the left. The septum is about as thick as the wall of the left ventricle, except at the upper end, in a small area

close below the aortic orifice, where there is a very thin part from which muscular fibres are absent (*pars membranacea septi*).

Fig. 107.*

membranous
part of sep-
tum.

Fibres can
be separated
into layers
by dissec-
tion.



Arrangement of fibres. It has been shewn by the foregoing dissection that the direction of the muscular fasciculi composing the ventricular wall varies at different depths from the surface, and that at a given spot a number of layers may be separated, which are characterized by the difference in direction of their fibres. Such a division into distinct layers is however in great measure artificial, for the change in direc-

tion is gradual, and many fibres pass across from one layer to another, and have to be cut to effect the separation.

Direction of
fibres :

external,

middle,

and internal.

Over both ventricles the most superficial fibres are directed very obliquely from base to apex, and from right to left on the anterior surface, from left to right on the posterior surface. Proceeding inwards, the obliquity gradually diminishes ; and in the centre of the wall the fibres are transverse. Within the last, as the cavity of the ventricle is approached, the fibres become oblique again, but in the opposite direction to the external ones ; and the innermost fibres of all are nearly longitudinal.

Course of
fibres is
obscure.

The attempt to trace the whole course of the bundles is, except in the case of the superficial fibres, attended with great difficulty, owing to the interlacement, branching, and joining of the fasciculi.

* A diagram of the arrangement of the fibres in layers in the left ventricle. The dissection is carried through about two-thirds of the thickness of the wall. 1, 2, 3. Outer layers, the fibres of which gradually become less oblique. 4. Middle layer of transverse fibres. 5. Inner set of oblique fibres. The deepest fibres, corresponding to 1 and 2 of the exterior, are not shewn.

The principal groups of fibres that have been distinguished may be arranged as follows ; but it must be understood that they are to a great extent intermixed, and that bundles frequently pass from one set into another. Chief sets :

a. The external oblique fibres (fig. 107,¹) begin at the base of the ventricles, where most of them spring from the auriculo-ventricular and arterial fibrous rings, and descend with the spiral course above described to the apex of the heart. On the posterior surface they pass without interruption from the left to the right ventricle ; but in front the fibres crossing the right ventricle in part dip in at the interventricular groove to the septum, while those continued to the left ventricle are joined by others which issue from the septum along the furrow. At the apex of the heart they form a sharp twist, known as the *vortex* or *whorl*, and sink in to become deep and ascend towards the base as the innermost layer of the left ventricle. Some of them are continued to the base and join the auriculo-ventricular and aortic rings ; but others enter the papillary muscles, which are thus formed. external oblique
and internal longitudinal
are one ;

b. The transverse or annular fibres (fig. 107,⁴) are partly special to the left ventricle, and partly common to the two ventricles. Some of them appear to form simple rings round the cavities, but a great many pass from this into the oblique system of fibres. annular ;

c. The looped fibres of the left ventricle spring from the fibrous rings at the base, and passing downwards in the ventricular wall, enter the lower part of the septum, in which they ascend to the central fibro-cartilage. looped of left,

d. Similar looped fibres pass from the outer wall of the right ventricle through the septum to the fibro-cartilage. and of right ventricle ;

e. The figure of 8 fibres pass from the front of the right ventricle through the septum to the back of the left, and from the front of the left to the back of the right, the two sets decussating in the septum. figure of 8 fibres.

Endocardium. Lining the interior of the cavities of the heart is a thin membrane, which is named endocardium. It is continuous on the one hand with the lining of the veins, and on the other with that of the arteries. Where the membrane passes from an auricle to a ventricle, or from a ventricle to an artery, it forms duplicatures in which fibrous tissue is enclosed, thus giving rise to the valves ; and in the ventricles it covers the tendinous cords, and the projecting muscular bundles. The thickness of the membrane is greater in the auricles than in the ventricles, and in the left than in the right half of the heart. Lining membrane of the heart.

GREAT VESSELS. The arteries which take origin from the heart are the aorta and the pulmonary trunk. The large veins entering the heart, besides the coronary sinus, are the superior and inferior cavæ, and the pulmonary. Vessels joining the heart.

The **PULMONARY ARTERY** is a short thick trunk, which conveys the dark blood from the right side of the heart to the lungs. From its commencement in the right ventricle the vessel is directed upwards and backwards on the left of the aorta ; and at a distance of an inch and a half or two inches, it divides into two branches for The pulmonary artery
divides into two for the lungs.

- Relations.** the lungs. The trunk of the pulmonary artery is contained in the pericardium; and beneath its lower end is the beginning of the aorta. On each side are the coronary artery and the auricular appendix.
- Right branch.** The *right branch* is longer and somewhat larger than the left. In its course to the lung it passes outwards above the right auricle of the heart, and beneath the aorta and superior vena cava. Behind it is the right bronchus. At the lung the artery divides into three primary branches, one for each lobe.
- Left branch.** The *left branch* is directed in front of the descending aorta and the left bronchus to the fissure of the lung, where it ends in two branches for the two pulmonic lobes.
- Space at the bifurcation.** As the right and left branches of the pulmonary artery pass outwards, they cross the two bronchi diverging from the end of the trachea, and enclose with them a lozenge-shaped space which contains some bronchial glands.
- Ligament of arterial duct.** *Ductus arteriosus.* Near the bifurcation of the pulmonary artery a fibrous cord, about the size of a crow-quill, passes from the left branch of the vessel to the arch of the aorta. This is the remnant of the ductus arteriosus of the fœtus, and is named the *ligament of the arterial duct*.
- Arterial duct in fœtus :
course of the blood.** In the fœtus the right and left branches of the pulmonary artery are small, and the trunk is continued by the ductus arteriosus, which opens into the aorta beyond the origin of the last great branch (subclavian) of the arch. The impure blood then passes from the pulmonary artery mainly through the arterial duct into the aorta, below the attachment of the vessels of the head and neck, in order that it may be transmitted to the placenta to be purified. But after birth, when the function of the lungs is established, the current of blood is directed along the branches of the pulmonary artery instead of through the arterial duct; and this tube becoming gradually smaller, is occluded by the eighth or tenth day, and forms finally the ligament of the arterial duct.
- The aorta extends
through chest and abdomen.** The AORTA is the great systemic vessel which conveys the arterial blood from the heart to the different parts of the body. It first arches backwards to reach the spinal column, along which it is then continued downwards through the chest and abdomen. In the thorax the vessel is divided into two parts—the arch of the aorta, and the descending thoracic aorta.
- Its first part is arched.
Extent** ARCH OF THE AORTA (fig. 108). The aorta has its origin in the left ventricle of the heart, and curving backwards to the left of the windpipe and the gullet, forms an arch which ceases on the left side of the spinal column, at the lower border of the fifth dorsal vertebra.
- and divisions of the arch.** The arch has its convexity upwards, and its concavity to the root of the left lung; and from it the large vessels for the supply of the upper part of the body take their origin. For purposes of description it is divided into three parts—ascending, transverse, and descending.
- First part :** The *first* or *ascending part* is about two inches in length, or slightly more, and is directed upwards behind, and close to the sternum : it

reaches as high as the upper border of the cartilage of the second rib on the right side, and is contained nearly altogether in the pericardium. The pulmonary artery is at first superficial to it, but afterwards lies on its left side. Behind it are the left auricle of the heart and the right branch of the pulmonary artery. On the right side is the descending cava. Near the heart the vessel bulges opposite the flaps of the valve (sinuses of Valsalva; fig. 108). There is sometimes another dilatation along the right side, which is named the *great sinus of the aorta*.

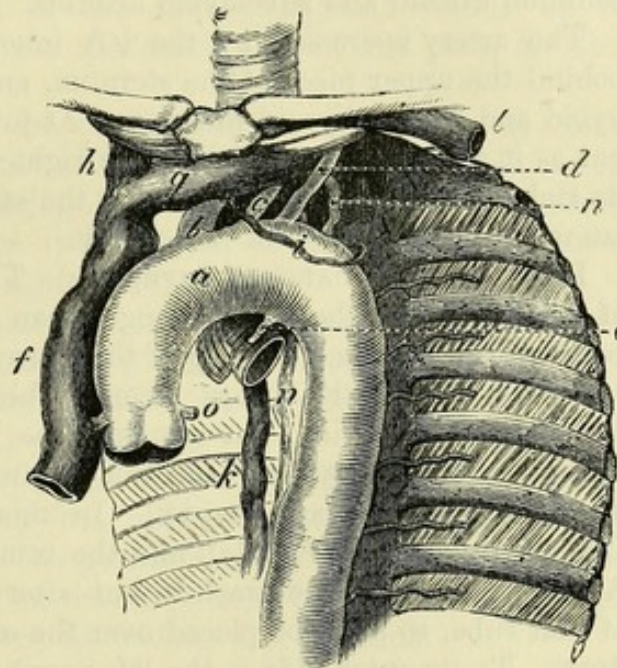
The *second or transverse part* recedes from the sternum, and reaches from the second right costal cartilage to the lower border of the body of the fourth dorsal vertebra on the left side. It rests upon the trachea, the œsophagus and the thoracic duct. Lying in front of this part of the artery are the vagus, phrenic, and superficial cardiac nerves of the left side,—the first nerve sending backwards its recurrent branch beneath the vessel. Along the upper border is the left innominate vein (*g*), to which the left upper intercostal vein (*i*) is directed over the left side of the arch; and to the lower border, near its termination, the remnant of the arterial duct (*e*) is attached. From it arise the three great vessels of the head and upper limbs.

The *third or descending part* of the arch is very short, extending from the lower edge of the fourth to that of the fifth dorsal vertebra. It lies against the fifth vertebra, and the fibro-cartilage between this and the fourth, and is covered by the pleura of the left side of the chest.

In the concavity of the arch of the aorta are contained the root of the left lung, the branching of the pulmonary artery with its arterial duct, and the left recurrent nerve.

The *branches* of the arch of the aorta are five in number: two come from the ascending, and three from the transverse part. The first two are the coronary arteries of the heart (*o*), which have already been noticed (p. 340). The other three are much larger,

Fig. 108.*



Second part is transverse;

relations;

gives origin to large vessels.

Third part is without branches.

Objects contained in the arch.

Five branches of the arch.

* Arch of the aorta and its great branches. *a*. Aortic arch. *b*. Innominate artery. *c*. Left common carotid. *d*. Left subclavian. *e*. Ligament of arterial duct. *f*. Vena cava superior. *g*. Left innominate vein. *h*. Right innominate vein. *i*. Left upper intercostal vein. *k*. Large azygos vein. *l*. Left subclavian vein. *n*. Thoracic duct. *o*. Coronary artery.

and supply the neck, the head, and the upper limbs. First on the right is the large trunk of the innominate artery (*b*); close to it is the left carotid (*c*); and last of all comes the left subclavian (*d*).

Innominate artery ends in carotid and subclavian:

The INNOMINATE ARTERY (brachio-cephalic; *b*), the first and largest of the three branches, measures from one inch and a half to two inches in length. Ascending to the right beneath the sternum, it divides opposite the sterno-clavicular articulation into the right common carotid and subclavian arteries.

relations.

The artery is crossed by the left innominate vein (*g*), and lies behind the upper piece of the sternum, and the origins of the sterno-hyoid and sterno-thyroid muscles. At first it rests on the trachea, but as it ascends it is placed on the right side of the airtube. To its right is the innominate vein of the same side (*h*). Usually no lateral branch arises from this artery.

Left common carotid:

LEFT COMMON CAROTID ARTERY (*c*). The common carotid artery of the left side of the neck is longer than the right by the distance between the arch and the top of the sternum.

relations in the thorax.

In the thorax the artery ascends obliquely to the left sterno-clavicular articulation, but not so close as the innominate to the first piece of the sternum and the origin of the depressor muscles of the hyoid bone and larynx. In this course it passes beneath the left innominate vein (*g*), and the remains of the thymus gland. At first it lies on the trachea, but afterwards inclines to the left of that tube, so as to be placed over the œsophagus and the thoracic duct. To its outer side is the left vagus, with one or more cardiac branches of the sympathetic nerve.

Left subclavian artery:

The LEFT SUBCLAVIAN ARTERY (*d*) ascends to the neck through the upper aperture of the thorax, and then curves outwards between the scaleni, where it has the same relations as the vessel of the right side (p. 68).

course and relations in the chest.

The trunk is directed almost vertically from the arch of the aorta to the level of the first rib. In the thorax it is deeply placed, near the spine. To its inner side is at first the trachea, and afterwards the œsophagus with the thoracic duct. On its outer side it is invested by the left pleura; and the left innominate vein crosses in front of the vessel as it enters the neck. Somewhat anterior to the level of the artery, though running in the same direction, are some of the cardiac nerves.

The relations of the first part of the left subclavian artery in the neck are given on p. 116.

The great veins are:—

VEINS (fig. 108). In addition to the cardiac veins (p. 340), there are the superior and inferior cavæ, and the pulmonary veins;—the former are the great systemic vessels which return impure blood to the right auricle of the heart; and the latter convey pure blood from the lungs into the left auricle.

Vena cava superior:

The SUPERIOR or DESCENDING CAVA (*f*) results from the union of the right and left innominate veins, and brings to the heart the blood of the head and neck, upper limbs, and thorax.

formed by innominate veins;

Its origin is placed behind the junction of the first costal cartilage of the right side with the sternum. From that spot the large vein

descends to the pericardium, perforates the fibrous layer of that bag course ; about one inch and a half above the heart, and ends in the right auricle. On its outer surface the vein is covered by the pleura, and the phrenic nerve is in contact with it. To the inner side are the relations innominate artery and the ascending part of the arch of the aorta. Behind the vein is the root of the right lung.

When the cava is about to perforate the pericardium it is joined branches by the large azygos vein of the thorax (*k*) ; and higher up it receives small veins from the pericardium, and the parts in the mediastinal space.

The INNOMINATE VEINS are two in number, right and left ; and each is formed near the inner end of the clavicle by the junction of the subclavian and internal jugular veins. Below, they are united in the superior cava. The trunks differ in length and direction, and in their relations to surrounding parts. Brachio-
cephalic
veins :

The *right vein* (*h*) is about one inch long, and descends almost right, vertically, on the right side of the innominate artery, to its junction with the opposite vein. On the outer surface the pleura covers it, and along it the phrenic nerve is placed.

The *left vein* (*g*) is nearly three inches in length, and is directed and left ; obliquely to the right, along the upper border of the arch of the aorta. It crosses behind the sternum, and the remains of the thymus gland ; and it lies on the three large branches of the aortic arch, as well as on the nerves descending over the arch.

The *branches* of the veins are nearly alike on the two sides. Each receives the vertebral, the internal mammary, and the inferior thyroid of its own side ; and the left vein is joined in addition by the superior intercostal, and some small thymic and pericardial veins. their
branches.

Sometimes the innominate veins are not united in the vena cava, but descend separately to the heart, where each has a distinct opening in the right auricle. When such a condition exists, the right vein takes the course of the upper cava in front of the root of the right lung ; but the left vein descends in front of the root of the left lung, and turning to the back of the heart, receives the cardiac veins, before it opens into the right auricle. A cross branch generally connects the two above the arch of the aorta. Sometimes
they open
separately
into the
heart.

This occasional condition in the adult is a regular one in a very early period of the growth of the foetus ; and the two vessels are also persistent in some mammalia.

Change of the two veins into one. The changes taking place in the veins during foetal growth, to produce the usual arrangement in the adult, concern the trunk on the left side. The following is an outline of them. First a cross branch is formed between the two trunks, and this enlarging gives rise to the left innominate vein. Then the left trunk below the cross branch disappears at its middle, and undergoes transformation at each end :—At the upper end it becomes converted into a part of the superior intercostal vein. At the lower end it remains pervious for a short distance as the coronary sinus ; and the small oblique vein opening into the end of that sinus in the adult (p. 340) is a remnant of the trunk as it lay beneath the heart. How two
are changed
into one,

and coro-
nary sinus
formed.

In the adult there is a trace of the occluded vessel in the form of a small fibrous band in the vestigial fold of the pericardium (p. 337).

Vena cava
inferior.

The INFERIOR or ASCENDING CAVA enters the right auricle as soon as it has pierced the diaphragm. No branches join the vein in the thorax. The anatomy of this vein will be given with the vessels of the abdomen (p. 530).

Four pul-
monary
veins.

The PULMONARY VEINS are two on each side. They issue from the hilum of the lung, and end in the left auricle: their position to the other vessels of the root has been noticed at p. 336.

Right veins
the longer.

The right veins are longer than the left, and lie beneath the right auricle of the heart. The superior receives its roots from the upper and middle lobes of the lung; and the inferior vein is formed by branches from the lower lobe.

Left veins.

The left veins cross in front of the descending aorta; and one springs from each lobe of the lung.

NERVES OF THE THORAX.

Nerves of
the thorax.

The pneumo-gastric and the sympathetic nerves supply the viscera of the thorax; and the phrenic nerve courses through the cavity to the diaphragm.

To trace
vagus.

Dissection. The phrenic nerves have already been fully displayed in the thorax; but the pneumo-gastric nerves are now to be prepared.

The vagus is to be followed, on each side, behind the root of the lung, and its large plexus in that position is to be dissected out: some fine branches from the gangliated cord of the sympathetic, coming forwards over the spinal column to the plexus, must also be looked for. To the front of the root the vagus supplies a few filaments. Beyond the root, the nerve is to be pursued along the œsophagus by raising the lung and removing the pleura.

Phrenic
nerve from
the cervical
plexus,

passes to
diaphragm.

The PHRENIC NERVE is a branch of the cervical plexus (p. 74). In its course through the thorax it lies along the side of the pericardium, and at a little distance in front of the root of the lung, with a small companion artery. When near the diaphragm it divides into branches, which perforate the muscle, and are distributed on the under surface. The nerves of opposite sides differ in length, and in their relations above the root of the lung.

Right nerve
above root
of lung.

The *right nerve* is deeper at first, and is also shorter and straighter than the left. In entering the chest it crosses behind the subclavian vein, but in front of the internal mammary artery; and it lies afterwards along the right side of the innominate vein and superior cava till it reaches the pericardium.

Left nerve
above root.

The *left nerve* crosses the subclavian artery, but has the same position as the right to the mammary vessels when entering the cavity. In the thorax it is directed in front of the arch of the aorta to the root of the lung, and makes a curve lower down around the projecting heart. Before reaching the aorta the nerve is placed external to the left common carotid artery; and it crosses the left vagus from without inwards, so as to be internal to that nerve on the arch.

Branches. Some small filaments are said to be furnished from the nerve to the pleura and pericardium. Some offsets.

INTERNAL MAMMARY ARTERY. A small part of this artery, which lies beneath the first rib, and winds round the phrenic nerve and the innominate vein to reach the side of the sternum, is now to be seen. It gives the following offset :— Internal mammary artery

The *superior phrenic branch* (comes *nervi phrenici*) is a very slender artery, which accompanies the phrenic nerve to the diaphragm, and is distributed to that muscle, anastomosing therein with the phrenic artery from the aorta (p. 528), and with the musculo-phrenic branch of the internal mammary (p. 259). gives phrenic branch.

The PNEUMO-GASTRIC OR VAGUS NERVE passes through the thorax to the abdomen. In the lower part of the thorax the right and left nerves have a similar position, for they pass behind the root of the lung, each on its own side, and along the œsophagus to the stomach. But above the root of the lung, the two nerves have different relations. Each supplies branches to the viscera, viz., to the heart, the windpipe and lungs, and the gullet. Vagus nerve.

The *right vagus* enters the thorax between the subclavian artery and the innominate vein, and is directed obliquely backwards, by the side of the trachea, to the posterior aspect of the root of the lung, where it gives rise to the posterior pulmonary plexus. From the plexus two large offsets are continued to the back of the gullet, and unite below into one trunk, which reaches the posterior surface of the stomach. Right vagus above root of lung, and on back of œsophagus.

The *left nerve* appears in the thorax on the outer side of the left common carotid artery, and courses over the arch of the aorta, and beneath the root of the lung, forming there a larger plexus than on the right side. From the pulmonary plexus one or two branches pass to the front of the œsophagus, and join with offsets of the right nerve in a plexus ; but the pieces are collected finally into one trunk, which is continued on the front of the gullet to the anterior part of the stomach. Left nerve above root of lung, and on front of œsophagus.

The *branches* of the pneumo-gastric nerve seen in the thorax are the following :— Branches are :—

a. The *recurrent or inferior laryngeal nerve*, arising on the right side on a level with the subclavian artery, and on the left at the lower border of the arch of the aorta, bends backwards to the trachea, along which it ascends to the larynx. On each side this branch is freely connected with the cervical cardiac branches of the sympathetic nerve, especially on the left side beneath the arch of the aorta. Recurrent laryngeal.

b. *Cardiac branches* (thoracic). Besides the cardiac branches furnished by the vagus in the neck, other offsets pass in front of the trachea to the cardiac plexus. On the right side they come from the trunk of the vagus and the recurrent branch, but they are supplied by the recurrent nerve alone on the left side. Cardiac branches

The termination of the *lower cervical cardiac branch* of each vagus nerve (p. 111) may be now seen. The branch of the right nerve lies by the side of the innominate artery, and joins a cardiac lower cervical cardiac branch.

offset of the sympathetic of the same side ; and the branch of the left vagus crosses over the arch of the aorta, to end in the superficial cardiac plexus (p. 341).

Pulmonary
branches :

c. Pulmonary branches. There are two sets of nerves for the lung, one on the anterior and the other on the posterior aspect of the root.

small
anterior ;

The *anterior branches*, two or three in number, are small, and communicate with filaments of the sympathetic on the pulmonary artery : these nerves are best seen on the left side.

large pos-
terior form
a plexus.

The *posterior branches* are larger and much more numerous. Forming a plexiform arrangement (*posterior pulmonary plexus*) behind the root of the lung by the flattening and splitting of the trunk of the nerve, they are joined by filaments from the third and fourth ganglia of the knotted cord of the sympathetic, and are conveyed into the lung on the divisions of the airtube.

Œsophageal
branches
form a
plexus.

d. Œsophageal branches are furnished to the gullet, but in greatest abundance in the lower half. Below the root of the lung the branches of the pneumo-gastric nerves surround the œsophagus with a network (*plexus gulæ*).

Sympathetic
in thorax
consists of

SYMPATHETIC NERVE. In the thorax the sympathetic nerve consists of a knotted cord along each side of the spinal column, which communicates with the spinal nerves ; and of a large prevertebral or cardiac plexus, which distributes branches to the heart and the lungs.

a gangliated
cord,

The gangliated cord will be seen in a future stage of the dissection, after the heart and the lungs have been removed (p. 368).

and a cen-
tral cardiac
plexus.

The CARDIAC PLEXUS lies over the lower end of the trachea, and above the bifurcation of the pulmonary artery. A part of this network, the superficial cardiac plexus, has been already described (p. 341). The remaining part, or the deep cardiac plexus, is placed beneath the arch of the aorta.

Dissection of
the plexus :

Directions. The cardiac plexus has been injured by the previous examination of the heart, so that it should be dissected in a body in which the heart and the large vessels are entire.

to expose
the right
part,

Dissection. The arch of the aorta is to be cut across near the heart, and is to be drawn over to the left side : next, the upper cava is to be divided above the entrance of the azygos vein, and its lower part is to be thrown down. By the removal of some fibrous and fatty tissues and lymphatic glands, the right part of the plexus will be seen in front of the trachea, above the right branch of the pulmonary artery. The offsets to the heart should be followed downwards on the trunk of the pulmonary artery ; and those to the lung should be traced along the right branch of that vessel.

and the left.

To lay bare the part of the plexus into which the nerves of the left side enter, the arch of the aorta is to be cut through a second time, between the subclavian artery and the attachment of the ligament of the ductus arteriosus ; and the transverse part of the arch is to be turned upwards with the great vessels attached. The lymphatic glands and the areolar and fatty tissue being cleared away from the plexus as on the opposite side, the offsets to the left coronary plexus of the heart will be visible.

The *deep cardiac plexus* is situate between the trachea and the arch of the aorta, and consists of right and left halves, which are joined by cross branches. In it are united the cardiac nerves of the sympathetic and vagus, with the exception of two branches of the left side ; and from it nerves are furnished to the heart and lungs. Deep cardiac plexus.

The *right part of the plexus* is placed above the right branch of the pulmonary artery, and receives the nerves of the right side, viz., the cardiac nerves of the sympathetic in the neck, the cardiac branches of the trunk of the vagus in both the neck and chest, and the cardiac offsets of the recurrent branch. Right part, how formed ;

The branches of this half of the plexus are distributed mostly to the right side of the heart, and pass downwards before and behind the right branch of the pulmonary artery ; those in front run on the trunk of the pulmonary artery to end in the right coronary plexus (p. 342) ; and the nerves behind supply the right auricle of the heart. Offsets are sent laterally on the branch of the artery to the root of the lung. branches to right coronary plexus ;
a few go to root of lung.

The *left half of the plexus* lies close to the ligament of the arterial duct, and rather on the left of the trachea. In it are collected the cardiac nerves of the sympathetic ganglia of the left side of the neck, except the highest, and numerous and large branches of the left recurrent nerve of the vagus. Left part : nerves entering it ;

Nerves descend from it to the heart around the left branch and the trunk of the pulmonary artery, and after supplying branches to the left auricle, terminate in the left coronary plexus (p. 342). A considerable offset is directed forwards by the side of the ligament to the superficial cardiac plexus ; and some nerves reach the left anterior pulmonary plexus by coursing along the branch of the pulmonary artery. offsets end in left coronary plexus, and in root of lung.

Termination of the *cardiac branches of the sympathetic nerve* of the neck (p. 114). Other cardiac nerves.

On the *right side* there may be only two cardiac nerves entering the thorax, for the highest nerve is often blended with one of the others. These nerves pass beneath the subclavian artery to the right half of the deep plexus ; and they communicate with the branches of the recurrent laryngeal nerve of the vagus. The right enter deep plexus.

On the *left side* the highest cardiac nerve lies over the arch of the aorta, and ends in the superficial cardiac plexus ; it may give a branch beneath the arch to the deep plexus. Only one other nerve, the middle cardiac, is usually seen entering the left side of the deep plexus, as the lower one generally blends with it. One left enters superficial ; others the deep plexus.

THE TRACHEA AND THE LUNG.

Dissection. To see fully the pieces of the airtube in the root of the lung, it will be necessary to divide the branches of the pulmonary artery and the pulmonary veins. And when the transverse part of the arch of the aorta, which has been already cut through, is turned to one side, the dissector will be able to clear away the bronchial glands, the nerves, and the connective tissue from the To see the trachea and its divisions.

part of the trachea in the thorax, and from the branches into which it bifurcates.

Trachea The **TRACHEA**, or windpipe, reaches from the larynx to the lungs, and lies on the front of the spinal column. The tube begins opposite the sixth cervical vertebra; and it ends commonly at the lower border of the fourth dorsal vertebra by dividing into two pieces (bronchi), one for each lung.

In the neck. Its relations in the neck are described on p. 119, and its structure on p. 168. The part in the thorax remains to be studied.

Its relations in the thorax. In the thorax the trachea is situated with the great vessels in the superior mediastinum; and its lower end is usually inclined somewhat to the right side. Here it is covered by the arch of the aorta, by the innominate and left carotid arteries, and by the cardiac plexus of nerves. Behind the airtube is the œsophagus, which projects to the left above the arch of the aorta. On the right side are the pleura, the vagus, and the innominate artery for a short distance, after this has passed over the trachea; and on the left side lie the left subclavian artery, and the recurrent branch of the vagus.

Bronchi lie in the roots of the lungs; The **BRONCHI**, or the branches of the airtube, are contained in the roots of the lungs, and are surrounded by vessels, glands and nerves. **are like the trachea in form.** Near the lung each is divided into as many primary pieces as there are lobes. In their structure and form the bronchi resemble the windpipe, for they are round and cartilaginous in front, but flat, and muscular and membranous behind. Their position behind the other pulmonary vessels has been described at p. 336.

The right differs from the The *right bronchus* is about an inch in length, and is larger than the left; it also forms a more direct continuation of the trachea, from which circumstance a foreign body in the airtube is more likely to enter this bronchus. It passes obliquely outwards, on a level with the fifth dorsal vertebra, behind the upper cava and the right pulmonary artery; and the azygos vein arches above it.

left in size and relations. The *left bronchus* is about two inches long, and reaches to the level of the sixth dorsal vertebra. It is directed obliquely downwards through the arch of the aorta, and crosses behind the corresponding pulmonary artery. It lies in front of the œsophagus and descending thoracic aorta.

Remove the lungs. *Dissection.* The lungs are now to be removed from the body by cutting through the bronchi and the small vessels of the root.

Take away heart and pericardium. The remains of the heart and pericardium are to be taken away afterwards. For their removal the inferior cava is to be divided, and the pericardium is to be detached from the surface of the diaphragm: in removing the pericardium, the dissector should be careful not to injure the things contained in the interpleural space in front of the spine.

Surface of lung is smooth; **is marked by lobules and small cells.** **PHYSICAL CHARACTERS OF THE LUNG.** The surface of the lung is smooth and shining, and is invested by the pleura. Through the serous covering the mass of the lung may be seen to be divided into small irregularly shaped pieces or lobules. On looking closely at it, especially at a thin margin, minute cells will be perceived in it.

Colour The tint of the lung varies with age. In infancy the colour is a

pale red ; but in the adult the texture becomes greyish, and presents here and there dark grey spots or lines of pigment, the shade of which deepens with increasing age, and becomes even black in old people. After death, the colour of the posterior border may be bluish-black from the accumulation of blood.

varies with age.
Accidental colour.

To the touch the lung is soft and yielding, and on a section the pulmonary substance appears like a sponge ; but the lung which is deprived of air by pressure has a tough leathery feel. Slight pressure with the thumb and finger drives the air from the containing spaces through the pulmonary structure, and produces the noise known as crepitation. If the lung contains serum or mucus, a frothy red fluid will run out when it is cut.

Consistence.

Crepitation.

The texture of the lung is very elastic, this elasticity causing the organ to contract when the thorax is opened, and to expel air that may be blown into it.

and elasticity.

The specific gravity of the lung varies with the conditions of dilatation and collapse, or of infiltration with fluid. When the pulmonary substance is free from fluid, and filled with air, it floats in water ; but when it is quite deprived of air it is slightly heavier than water, and therefore sinks. The weight of the lung is influenced greatly by the quantity of foreign material contained in its texture ; ordinarily it ranges from sixteen to twenty-four ounces, the right lung being about two ounces heavier than the left. In the male the lungs are larger, and together about twelve ounces heavier than in the female.

Specific gravity,

and weight of the lung.

OBVIOUS STRUCTURE OF THE LUNG. The substance of the lung is composed of small polyhedral masses or lobules, which are hollow, and again subdivided into minute vesicles called the air-cells. The lobules are visible as little polygonal areas upon the surface of the lung ; and by inflating a portion of the organ, the cellular structure may be seen. The several lobules are united together by connective tissue without fat ; and each is attached to a terminal branch of the airtube, and receives offsets of the pulmonary vessels.

Lung consists of lobules, and these of air-cells.

The lung is invested by the pulmonic pleura, except at the hilum, where the vessels enter. The serous membrane is thin and transparent, and is closely attached to the lung-substance by means of a fine layer of subserous areolar tissue, which is continuous with the interlobular tissue. Both the pleura and the subserous tissue are very elastic, so that in the collapsed state the surface of the lung is still smooth.

Serous covering

and sub-serous layer.

Arrangement of the airtube and pulmonary artery entering the lung. It has already been seen that in the root of the lung the pulmonary artery lies at first in front of the bronchus ; but before entering the organ the artery crosses over, and gains the posterior surface of the airtube. On the left side the artery passes backwards above the undivided bronchus ; but on the right side the bronchus gives off the branch to the upper lobe of the lung before it is crossed by the arterial trunk, which therefore runs between the upper and middle divisions of the airtube. From this arrangement it would appear that the lower half of the left bronchus and the two lobes of the

Relation of artery to bronchus,

on left side,
and on right.

left lung are represented on the right side by the continuation of the bronchus below the artery and the middle and lower lobes of the lung ; and that the upper lobe of the right lung with its division of the airtube have no representatives on the left side (Aeby).

Airtubes in lung :

mode of branching ;

structure ;

and ending.

Bronchial branches in the lung. If the primary divisions of the bronchi be followed into the lung, they will be found to give off secondary branches ; and these, together with the smaller offsets of the air-passages, divide for the most part dichotomously. The branches of the airtube within the lung are known as the *bronchia* or *bronchial tubes*, and differ from the bronchi in being circular in section. Their structure resembles that of the bronchi ; but the pieces of cartilage are irregular in shape and occur on all sides of the tube, and the muscular tissue completely surrounds the canal. The ultimate bronchial tubes are about half a line in diameter ; and each leads to a group of somewhat funnel-shaped dilatations (infundibula), which are beset with air-cells and form the lobules of the lung.

Vessels are two sets :—

VESSELS OF THE LUNG. Two sets of vessels are furnished to the lung, viz., the pulmonary, which bring blood to the lung to be aerated, and then return it to the heart, and the smaller bronchial, which convey the blood destined for the nutrition of the lung.

Pulmonary artery

The *pulmonary artery* divides like the bronchus, and within the lung its branches run usually on the posterior surface of the bronchial tubes, which they accompany to the lobules. The arterial branches do not anastomose together ; and they end in the capillary network of the air-cells.

and veins.

The *pulmonary veins* are not so regular in their arrangement as the arteries. They arise from the network of the air-cells ; and the branches from adjoining lobules communicate freely together. The larger branches for the most part lie in front of the airtubes which they accompany. The pulmonary veins have no valves.

Bronchial arteries

The *bronchial arteries* are derived from the aorta, and enter the lung on the airtube, which they also follow in its ramifications. They distribute branches to the bronchial lymphatic glands, to the walls of the larger blood-vessels and bronchial tubes, and to the interlobular connective tissue. Other small offsets ramify on the surface of the lung beneath the pleura. On the smallest bronchial tubes minute branches anastomose with offsets of the pulmonary arteries.

and veins.

The *bronchial veins* begin by twigs corresponding with the superficial and deep branches of the artery, and leave the root of the lung to end in the azygos veins. Many of these veins, however, open into the pulmonary veins, both within the lung and in the root (Zuckermandl).

Lymphatics.

The *lymphatics* of the lung are superficial and deep : the latter accompany both the bronchia and the branches of the pulmonary vessels. All pass to the bronchial glands at the root of the lung.

Pulmonary nerves.

The *nerves* of the lung are derived through the pulmonary plexuses from the vagus and sympathetic, and follow the branches of the airtube. They have minute ganglia connected with their filaments.

PARTS ON THE SPINE AND THE SYMPATHETIC CORD.

In front of the spinal column are the objects in the interpleural space of the posterior mediastinum, viz., the aorta, azygos veins, thoracic duct, and œsophagus; and beneath the pleura on each side of the spine is the sympathetic nerve.

Dissection. The thoracic duct should be found first near the diaphragm by removing the pleura; there it is about as large as a crow-quill, and rests against the right side of the aorta: this slender vessel may be injected with tallow. Dissection of thoracic duct,

The areolar tissue and the pleura are to be cleared away from the different things before mentioned; and the azygos veins, one on the right and two on the left of the aorta, should be dissected. Next follow the thoracic duct upwards beneath the arch of the aorta, and along the œsophagus beneath the pleura, till it leaves the upper aperture of the thorax. of other objects,

After raising the pleura from the inner surface of the chest, the gangliated cord of the sympathetic nerve will be seen lying over the heads of the ribs. Branches are to be followed outwards from the ganglia to the intercostal nerves; and others inwards over the bodies of the vertebræ,—the lowest and largest of these forming the three trunks of the splanchnic nerves. and of sympathetic.

The DESCENDING THORACIC AORTA is the part of the great systemic vessel between the termination of the arch and the diaphragm. Its extent is from the lower border of the fifth dorsal vertebra (the left side) to the front of the last dorsal vertebra. Descending thoracic aorta: extent;

Contained in the posterior mediastinum, the vessel is rather curved, lying at its upper end on the left, but below on the front of the spinal column. Beneath it are the vertebræ and the smaller azygos veins. In front of the vessel are the root of the left lung and the pericardium. On its left side it is covered throughout by the pleura; and on its right side are the œsophagus, the thoracic duct, and the large azygos vein, though near the diaphragm the gullet is placed over the aorta. course; and relations.

The *branches* of the vessel are distributed to the surrounding parts, and are named from their destination bronchial, pericardial, œsophageal, mediastinal, and intercostal. Branches.

a. The *bronchial arteries* supply the structure of the lungs, and adhere to the posterior part of the bronchial tubes, on which they ramify (p. 362); they give some twigs to the bronchial glands and the œsophagus. Arteries of the lung: distribution;

For the left lung there are two arteries (superior and inferior), which arise from the front of the aorta at a short distance from each other. two left;

The artery of the right lung arises in common with one of the left bronchial arteries (superior), or from the first intercostal artery of the right side. one right.

Bronchial veins. A vein issues from the root of each lung, and Vein of the lung.

ends on the right side in the large azygos vein, and on the left in the superior azygos vein of its own side.

Pericardial branches. *b.* The *pericardial branches* are some irregular twigs, which are furnished to the posterior part of the cardiac bag.

Œsophageal branches. *c.* The *œsophageal branches* are four or five in number, and ramify in the gullet, forming anastomoses with one another; above, they communicate with branches of the inferior thyroid artery; and below, with twigs of the coronary artery of the stomach.

Mediastinal branches. *d.* Small *mediastinal branches* (posterior) supply the areolar tissue and the glands in the interpleural space.

Intercostal arteries: *e.* The *intercostal arteries* are nine on each side, and pass to the same number of lower intercostal spaces: to the upper two spaces branches are supplied from the intercostal artery of the subclavian trunk.

course to intercostal spaces; These vessels arise from the posterior part of the aorta, and run outwards on the bodies of the vertebræ, beneath the cord of the sympathetic nerve, to the intercostal spaces, where each divides into an anterior and a posterior branch. In this course the upper arteries have a somewhat oblique direction; and as the aorta lies on the left of the spine, the right vessels are the longer; the right run also beneath the œsophagus, the thoracic duct, and the large azygos vein. Many twigs are supplied to the bodies of the vertebræ.

right longer. In the intercostal space, the *anterior branch*, the larger of the two, continues onwards between the muscular strata to the front of the chest, where it ends by anastomosing with an intercostal branch of the internal mammary artery (p. 260). At first the artery lies in the middle of the space, beneath the pleura, and resting on the external intercostal muscle; but near the angle of the rib it ascends to the upper boundary. Accompanying the artery are the intercostal vein and nerve,—the vein being commonly above, and the nerve below it; but in the upper spaces the nerve is, at first, higher than the artery.

The anterior branch occupies intercostal space *Branches* are furnished to the intercostal muscles, and to the ribs. Near the angle of the rib a larger branch is given off, which runs forwards along the lower border of the space, and joins in front a branch of the internal mammary; and about the centre (from front to back) of the intercostal space a superficial twig arises, to accompany the lateral cutaneous nerve (p. 260).

with vein and nerve. The highest artery of the aortic set of intercostals anastomoses with the superior intercostal branch of the subclavian artery; and the last two are continued in front into the abdominal wall, where they lie between the internal oblique and transversalis muscles, and anastomose with the epigastric and lumbar arteries (p. 453).

Offsets. The *posterior branch* turns backwards between the vertebra and the ascending costo-transverse ligament, and is distributed in the back (p. 397). As it passes the intervertebral foramen it furnishes a small spinal branch to the vertebræ and the spinal cord. (See VESSELS OF THE SPINAL CANAL.)

Anastomoses. The *intercostal vein* resembles closely the artery in its course and

Posterior branch turns to the back.

Intercostal vein.

branching. Near the head of the rib it receives a contributing dorsal branch, and then joins an azygos vein.

The SUPERIOR INTERCOSTAL ARTERY of the subclavian trunk (p. 71) descends over the neck of the first rib, external to the cord of the sympathetic, and supplies a branch to the first intercostal space : continuing to the second space, which it supplies in like manner, it ends by anastomosing with the upper aortic branch.

Superior
intercostal
supplies one
or two
spaces.

Its intercostal offsets divide into anterior and posterior branches, which are distributed like the arteries from the aorta.

The AZYGOS VEINS are two in number on the left side and one on the right, and receive branches corresponding to the offsets furnished by the descending thoracic aorta.

Three
azygos
veins.

The *right* or *large azygos* (fig. 109,³) begins in the lumbar veins on the right side of the spine ; and its origin is described with the vessels of the abdomen (p. 538). It enters the thorax through the aortic opening of the diaphragm, and ascends on the right side of the aorta and thoracic duct, over the intercostal arteries and the bodies of the vertebræ. Opposite the fifth rib the vein arches forwards above the root of the right lung, and enters the superior cava as this vessel pierces the pericardium. Its valves are few and very incomplete, so that the intraspinal and intercostal veins may be injected through it.

Large
azygos is on
right side,

and joins
superior
cava :

Branches. In this vein are collected the intercostals of the right side with the exception of the first ; most of the intercostals of the left side of the thorax, through the left azygos veins ; and some small œsophageal, mediastinal, and vertebral veins, with the right bronchial vein.

branches
joining it.

By means of the right azygos vein the inferior communicates with the superior cava, so that blood may reach the heart from the lower half of the body if the inferior cava should be obstructed.

The *left lower azygos vein* (fig. 109,⁴) begins in the abdomen in the lumbar veins on the left side of the vertebral column. Entering the thorax along with the aorta, or through the crus of the diaphragm, the vein ascends on the left of the aorta as high as the ninth or eighth dorsal vertebra, where it crosses beneath that vessel and the thoracic duct to end in the right azygos. It receives the three or four lower intercostal veins of the left side, and some œsophageal and mediastinal branches.

Left lower
vein

begins in
abdomen,

ends in
larger
azygos :
branches.

The *left upper azygos vein* (fig. 109,⁵) is formed by offsets from the spaces between the superior intercostal and the preceding. Receiving three or four branches, the trunk either joins the lower azygos of its own side, or crosses the spine to open into the right vein.

Left upper
vein.

The *superior intercostal vein* is a short trunk which is formed by the union of the veins from the second, third, and fourth spaces. On the right side it descends to join the beginning of the arch of the large azygos vein ; but on the left side (fig. 108, *i*) it is directed forwards across the arch of the aorta, and then turns upwards to enter the left innominate vein.

Superior
intercostal
vein :

ending of
right,

and of left.

The *highest intercostal vein* ascends from the first intercostal space,

Vein from
first space.

in company with the superior intercostal artery, and joins the lower end of the vertebral vein.

Œsophagus The ŒSOPHAGUS or gullet is a hollow muscular tube, which extends from the pharynx to the stomach : the cervical portion has been described at p. 119, and the thoracic part is now to be examined.

in the thorax, Appearing in the thorax to the left of the middle line, the gullet is directed beneath the arch of the aorta, and reaches the middle of the spine about the fifth dorsal vertebra. From that spot it is continued through the interpleural space on the right of the aorta till near the diaphragm, where it takes a position over the aorta, to gain the œsophageal opening of that muscle.

passes through diaphragm. As far as the aortic arch the œsophagus lies beneath the trachea, though it projects to the left of the airtube ; beyond the arch it is crossed by the left bronchus, and is thence in contact with the pericardium as far as the diaphragm. At the upper part of the thorax the gullet rests on the longi colli muscles and the vertebræ ; but below the arch of the aorta it is separated from the spine by the large azygos vein, the thoracic duct, and the right intercostal arteries, as well as by the aorta near the diaphragm. Laterally it touches the left pleura above the arch, and both pleuræ below, but the right much more extensively than the left. Below the bronchus the pneumo-gastric nerves surround the œsophagus with their branches ; and above the same spot the thoracic duct is in contact with it on the left.

Parts covering it, *Structure.* If a piece of the gullet be removed and distended with tow, it will be easy to show a muscular, an areolar, and a mucous coat, from without inwards.

beneath it, *A muscular coat of* The *muscular coat* is thick and strong, and consists of two layers of fibres, of which the external is longitudinal, and the internal circular in direction, like the muscular tunic of the other parts of the alimentary tube. In the upper third of the œsophagus the muscular coat is red, and composed of striped fibres ; but below this it becomes gradually paler, and the striped fibres give way to involuntary muscular tissue.

Three coats are in it. The *external layer* is formed of parallel longitudinal fibres, which form a continuous covering, and end below on the stomach. The fibres begin opposite the cricoid cartilage (p. 131) ; and at intervals varying from half an inch to an inch and a half, they are interrupted by small tendons ($\frac{1}{20}$ to $\frac{1}{10}$ of an inch long) like the fibres of the rectus abdominis muscle.

external longitudinal The *internal layer* of circular fibres is continuous above with the fibres of the pharynx ; they are more oblique at the middle than at either end of the œsophagus.

and internal circular fibres. The *areolar or submucous layer* is situate between the muscular and mucous coats, and attaches the one to the other loosely.

Fibrous layer. The *mucous coat* will be seen on cutting open the tube : it is reddish in colour above but pale below, and is very loosely connected with the muscular coat, so that it is thrown into longitudinal folds when the œsophagus is contracted. The surface is studded with minute papillæ, which are however concealed by the thick, laminated, scaly epithelium.

Mucous coat.

Papillæ and epithelium.

Some *compound glands* (œsophageal) are scattered along the tube, and are most numerous at the lower end of the gullet. Some glands.

LYMPHATICS OF THE THORAX. In the thorax are lymphatic vessels of the wall and the viscera, which enter collections of glands, and end in one or other of the lymphatic ducts. Besides these, the large thoracic duct traverses the thorax in its course from the abdomen to the neck. Lymphatics in the thorax.

LYMPHATIC GLANDS. Along the course of the internal mammary artery lies a chain of *sternal glands*, which receive lymphatics from the upper part of the abdominal wall, the front of the chest, the mamma, and the fore part of the diaphragm. Sternal glands.

On each side of the spine, near the heads of the ribs, as well as between the intercostal muscles, is placed a group of *intercostal glands* for the reception of the lymphatics of the posterior wall of the thorax. Intercostal.

Three or four *anterior mediastinal glands* lie in the fore part of the interpleural space, and receive lymphatics from the upper surface of the liver and the diaphragm. Anterior mediastinal.

Numerous *bronchial glands* are situate at the division of the trachea, and along the bronchi; through them the lymphatics of the lung pass. Bronchial.

Along the side of the aorta and œsophagus is a chain of *posterior mediastinal glands*, which are joined by the lymphatics of the œsophagus, and hinder parts of the pericardium and diaphragm. Posterior mediastinal.

Along the front and lower border of the arch of the aorta are the *superior mediastinal* or *cardiac glands*, which receive the lymphatics of the heart, the pericardium, and the thymus. Superior mediastinal.

The THORACIC DUCT (fig. 109,¹) is the main channel by which the lymph of the lower half of the body, and of the left side of the upper half of the body, as well as the chyle, is conveyed into the blood. The duct begins in the abdomen in an enlargement (receptaculum chyli; p. 534), and ends in the veins of the left side of the neck. It is from fifteen to eighteen inches in length, and is contained in the thorax, except at its origin and termination. It has the following course and relations:— Thoracic duct begins in the abdomen and ends in neck.

Entering the cavity through the same opening as the aorta, the duct ascends on the right side of that vessel as high as the arch. Opposite the fourth dorsal vertebra it passes beneath the aortic arch, and is then applied to the left side of the œsophagus, on which it is conducted to the neck under the left subclavian artery. At the lower part of the neck the duct arches outwards, as before described (p. 116), to open into the left subclavian vein at its junction with the internal jugular. Relations in the thorax.

In this course the tube is oftentimes divided in two, which unite again; or its divisions may even form a plexus. Near its termination it is frequently branched. It is provided with valves at intervals, like a vein; and these are in greatest number at the upper part. It may be divided; is furnished with valves;

Branches. In the thorax the duct receives the lymphatics of the left half of the cavity, viz., from the sternal and intercostal glands; receives most lymphatics.

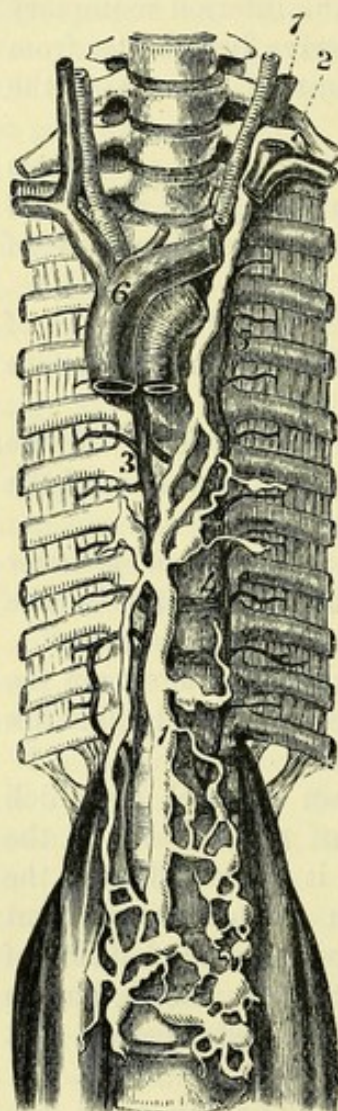also the lymphatics of the left lung, the left side of the heart, and the trachea and œsophagus.

Right duct
is in the
neck :

The RIGHT LYMPHATIC DUCT (fig. 28) receives large branches from the viscera of the thorax. It is a short trunk, about half an inch in length, and opens into the angle of union of the subclavian and jugular veins of the same side (p. 71) : its opening is guarded by valves.

receives
lymphatics
of one-
fourth of
body.

Fig. 109.*



Thoracic
cord of
sympathetic

has twelve
ganglia.

Branches :

to join
spinal
nerves :

to supply
viscera.

Offsets of
upper six
ganglia are
small ;

Branches. Into this trunk the lymphatics of the right upper limb and right side of the head and neck pour their contents. In addition, the lymphatics of the right side of the chest, right lung and right half of the heart, and some from the right lobe of the liver, after passing through their respective glands, unite into a few large trunks, which ascend beneath the innominate vein to reach the duct in the neck.

CORD OF THE SYMPATHETIC NERVE. The thoracic part of the gangliated cord of the sympathetic nerve is covered by the pleura, and is placed over the heads of the ribs and the intercostal vessels. The ganglia on it are usually twelve, one being opposite each dorsal nerve, but this number is frequently reduced by the fusion of two adjoining swellings. The first ganglion is the largest ; and the last two are rather anterior to the line of the others, being situate on the side of the bodies of the corresponding vertebræ.

Each ganglion furnishes external branches to communicate with the spinal nerves, and internal for the supply of the viscera.

External or connecting branches (fig. 110). Two offsets pass outwards from each ganglion to join a spinal nerve (intercostal). In the branches of communication both

spinal and sympathetic nerve-fibres are combined ; but one (*h*) consists almost entirely of spinal, and the other (*i*) mainly of sympathetic fibres.

The *internal* or *visceral branches* differ in size and distribution, according as they are derived from the upper or lower ganglia.

The offsets of the *upper six ganglia* are very small, and are distributed to the aorta, and to the vertebræ with the ligaments. From the third and fourth ganglia offsets are sent to the posterior pulmonary plexus.

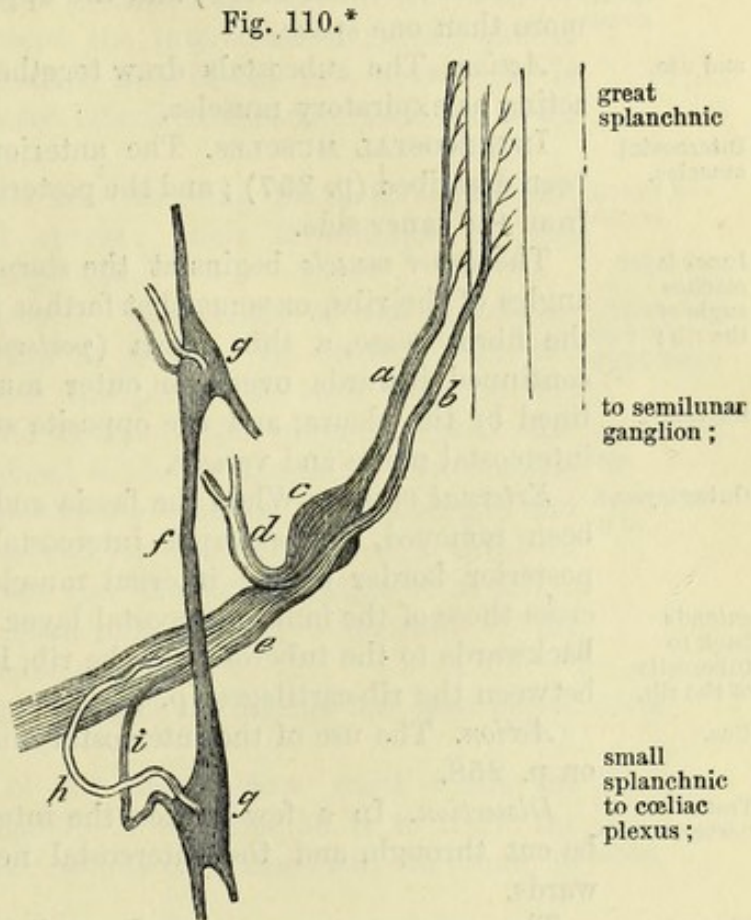
* The thoracic duct, and the azygos veins. 1. Thoracic duct. 2. Ending of the duct in the left subclavian vein. 3. Large azygos vein. 4. Left lower azygos vein. 5. Left upper azygos vein. 6. Vena cava superior. 7. Left internal jugular vein, cut through.

The branches of the *lower six ganglia* are larger and much whiter than the others, and are united to form visceral or splanchnic nerves of the abdomen: these are three in number (large, small, and smallest) and pierce the diaphragm to end in the solar and renal plexuses.

The *great splanchnic nerve* is a large white cord, which receives roots apparently from only four or five ganglia (sixth to the tenth), but its fibres may be traced upwards on the knotted cord as high as the third ganglion. Descending on the bodies of the vertebræ, it pierces the fibres of the crus of the diaphragm, and ends in the semilunar ganglion of the abdomen. At the lower part of the thorax the nerve may present a ganglion.

The *small splanchnic nerve* begins in the tenth and eleventh ganglia, or in the intervening cord. It is transmitted inferiorly through the crus of the diaphragm, and enters the part of the solar plexus by the side of the celiac artery.

The *smallest splanchnic nerve* springs from the last ganglion, and accompanies the other nerves through the diaphragm; in the abdomen it ends in the renal plexus. This nerve may be absent, and its place is then taken by an offset of the preceding.



PARIETES OF THE THORAX.

Between the ribs are lodged the two layers of intercostal muscles, with the intervening nerves and arteries; and inside the ribs is a thin fleshy layer at the back,—the subcostals. The base of the thorax is formed by the diaphragm.

The SUBCOSTAL MUSCLES are small slips of fleshy fibres, which are situate on the inner surface of the ribs, where the internal intercostals cease. Apparently part of the inner intercostals, they arise

* Scheme to illustrate the connection between the spinal and sympathetic nerves. (Todd and Bowman.) a. Posterior root of a spinal nerve, with a ganglion, c. b. Anterior root. d. Posterior primary branch. e. Anterior primary branch of the spinal nerve. f. Knotted cord of the sympathetic. g. Ganglia on the cord. h. White offset from the spinal to the sympathetic nerve. i. Grey offset from the sympathetic to the spinal nerve.

attach- ments ;	from the inner surface of one rib, and are attached to the like surface of the rib next succeeding.
irregulari- ties ;	They are uncertain in number, but there may be ten : they are smaller above than below, and the upper and lower may pass over more than one space.
and use.	<i>Action.</i> The subcostals draw together, and depress the ribs, thus acting as expiratory muscles.
Intercostal muscles.	INTERCOSTAL MUSCLES. The anterior part of these muscles has been described (p. 257) ; and the posterior part may be now examined from the inner side.
Inner layer reaches angle of the rib ;	The <i>inner muscle</i> begins at the sternum, and reaches back to the angles of the ribs, or somewhat farther in the upper spaces. Where the fibres cease, a thin fascia (<i>posterior intercostal aponeurosis</i>) is continued inwards over the outer muscle. The inner surface is
relations.	lined by the pleura, and the opposite surface is in contact with the intercostal nerve and vessels.
Outer layer	<i>External muscle.</i> When the fascia and the subcostal muscles have been removed, the external intercostal will be seen between the posterior border of the internal muscle and the spine. Its fibres
extends back to tuberosity of the rib.	cross those of the inner intercostal layer. While this muscle extends backwards to the tuberosity of the rib, it is generally absent in front between the rib-cartilages (p. 258).
Use.	<i>Action.</i> The use of the intercostal muscles in respiration is given on p. 258.
Trace nerves.	<i>Dissection.</i> In a few spaces the internal intercostal muscle may be cut through, and the intercostal nerve and artery traced outwards.
Eleven intercostal nerves.	The INTERCOSTAL NERVES, eleven in number, are anterior primary branches of dorsal nerves ; and they pass from the intervertebral foramina into the intercostal spaces without forming a plexus. Near the head of the rib each nerve is joined to the sym- p
Upper and lower ones differ.	pathetic by two communicating filaments (p. 368). The upper six are confined to the wall of the thorax ; but the lower five are prolonged into the abdominal wall, where the ribs cease in front.
Last dorsal nerve.	The anterior branch of the twelfth dorsal nerve lies below the last rib, and is seen in the dissection of the abdomen.
Course of upper six,	<i>Upper six nerves.</i> At first the nerves lie between the pleura and the external intercostal muscle with an artery and vein ; but they soon enter between the intercostal muscles, and extend forwards to the side of the sternum (p. 260). In their course
and branches.	they supply <i>branches</i> to the muscles of the thoracic wall, viz., the subcostals, intercostals, and triangularis sterni, as well as to the levatores costarum and serrati muscles of the back, and cutaneous offsets to the surface, which are described in the dissection of the upper limb (p. 244).
Exceptions in first two.	There are some deviations in the first and second nerves from the arrangement above specified.
First nerve ends mostly in brachial plexus.	The <i>first nerve</i> (fig. 74) ascends in front of the neck of the first rib, and enters the brachial plexus. Before it leaves the chest it supplies to the first intercostal space a branch, which furnishes

muscular offsets, and becomes cutaneous by the side of the sternum. There is not any lateral cutaneous offset from this branch, except when the second nerve is not as large as usual.

The *second nerve* may extend a considerable way on the wall of the chest before entering between the intercostal muscles; and it frequently sends upwards a branch to join the first nerve. It is remarkable in having a very large lateral cutaneous branch (p. 244). In front it ends like the others. Second nerve.

The *lower five nerves* resemble the foregoing in their course and branches in the intercostal spaces: their termination in the abdominal wall is described on p. 449. Lower five nerves.

Upper surface of the diaphragm. The centre of the muscle is tendinous, and the circumference is fleshy. In contact with the upper surface are the lung with the pleura on each side, and the heart and pericardium in the middle: the phrenic vessels and nerves pierce this surface, external to the pericardium. In the diaphragm are the following apertures;—one for the œsophagus and the pneumo-gastric nerves, a second for the vena cava, a third for the aorta with the thoracic duct and the large azygos vein, and a cleft on each side for the splanchnic nerves. Beneath it the sympathetic passes into the abdomen. Upper surface of diaphragm.
Parts touching.
Apertures in it.

The arch of the diaphragm towards the thorax has been before referred to (p. 331). Curve.

Directions. The dissector of the thorax now waits while the examination of the back is made. Afterwards he is to learn the ligaments of the ribs and spine: a notice of these will be found in the following SECTION. The dissection of the back is now made.

SECTION II.

LIGAMENTS OF THE TRUNK.

The ligaments of the vertebræ, ribs, and sternum are included in this SECTION.

ARTICULATIONS OF THE RIBS. Each rib is united to the spinal column at the one end, and to the costal cartilage at the other. Between it and the spine there are two synovial joints, and two sets of ligaments, viz., one between the head of the rib and the bodies of the vertebræ, and a second passing from the neck and tuberosity to the transverse processes of the vertebræ. Articulations of the ribs,

The costal cartilages are connected to the sternum and to one another by synovial joints and ligaments. and costal cartilages.

Dissection. For the purpose of examining the ligaments between the ribs and the vertebræ, take a piece of the spinal column with three or four ribs attached. After removing the intercostal and other muscles, and the loose tissue from the surface of the bones, the student will be able to define, as below, the ligaments passing To see the costo-vertebral ligaments,

from the head and neck of the rib to the bodies and transverse processes of the vertebræ.

and chondro-
sternal.

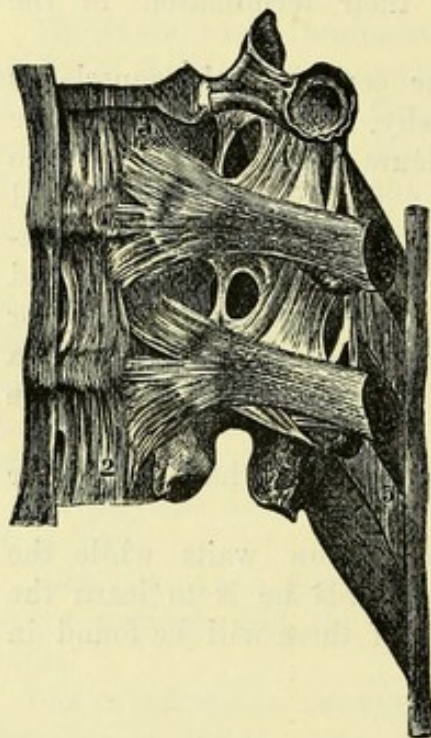
The ligaments attaching the costal cartilages to the sternum are to be dissected on the part of the thorax which was removed in opening the cavity.

Ligaments
of head of
rib are

LIGAMENTS OF THE HEAD OF THE RIB. Where the head of the rib is received into a hollow in the bodies of two contiguous vertebræ, there are two ligaments to the articulation—*anterior costo-central* and *interarticular*, with two synovial sacs.

Fig. 111.*

anterior or
stellate



and interar-
ticular,

The *anterior costo-central* or *stellate ligament* (fig. 111,³) is composed of radiating fibres, which pass from the head of the rib to the two vertebral bodies forming the articular cavity, and to the disc between them. Where the rib is in contact only with one vertebra, *i.e.*, in the first, eleventh and twelfth, a few fibres ascend to the vertebra immediately above.

The *interarticular ligament* will be seen when the stellate is divided. It is a very short thin band, which is attached on one side to the ridge separating the two articular surfaces on the head of the rib, and on the other to the intervertebral disc. In the joints of the first, eleventh, and twelfth ribs, where the head is not

in contact with the intervertebral substance, this ligament is absent.

with syno-
vial sacs.

Synovial sacs. There are usually two synovial cavities in the costo-central articulation, one on each side of the interarticular ligament; but in the three joints before mentioned (1st, 11th, 12th) there is but one.

Costo-
transverse
ligaments:

LIGAMENTS OF THE NECK AND TUBEROSITY. Three ligaments pass from the neck and tuberosity of the rib to the transverse processes of the two vertebræ with which the head is connected; and the tuberosity forms a synovial joint with the transverse process of the lower vertebra.

superior or
ascending,

The *superior costo-transverse ligament* (fig. 111,⁴) is larger and longer than the others. It ascends from the upper edge of the neck of the rib to the transverse process of the vertebra above: it is wanting to the first rib. Between this ligament and the vertebra the posterior branches of the intercostal vessels and nerves pass; and externally it is continued into the posterior intercostal aponeurosis.

posterior,

The *posterior costo-transverse ligament* (fig. 118,³) is a short band

* Ligaments of the ribs and vertebræ (Bourguery). 1. Anterior ligament of the bodies of the vertebræ. 2. Short lateral fibres uniting the bodies. 3. Stellate ligament. 4. Superior costo-transverse ligament. 5. Interspinous ligament.

of fibres between the rough part of the tuberosity of the rib and the tip of the transverse process with which the latter articulates.

The *middle* or *interosseous costo-transverse ligament* is placed and middle; between the neck of the rib and the transverse process which the tuberosity touches. It will be best seen by sawing horizontally through the rib and the transverse process. Its fibres are collected into separate bundles, with fatty tissue between them.

The *synovial cavity* of the costo-transverse articulation will be synovial opened by dividing the posterior ligament. sac.

There is no joint between the last two ribs and their transverse processes; and the posterior and middle costo-transverse ligaments are united in one band. Differences in eleventh and twelfth ribs.

Movements of the ribs. The ribs undergo a movement of rotation around an axis which passes through the costo-central articulation in a direction corresponding very nearly to that of the neck of the bone. By this rotation the fore part of the rib is carried upwards and outwards in inspiration, and downwards and inwards in expiration. The degree of outward movement is necessarily proportionate to the obliquity of the axis, and is therefore greater in the case of the lower ribs than the upper, since the backward inclination of the transverse processes of the dorsal vertebræ, and of the necks of the ribs, increases from above downwards. The lower ribs, while being elevated, also move somewhat backwards, their tuberosities gliding over the sloped facets of the transverse processes; and in the eleventh and twelfth ribs the upward and downward movements are but slight, while the forward and backward movements are relatively free, owing to the absence of the costo-transverse articulation. The ribs rotate around an axis which is more or less oblique. The lower ones also move backwards and forwards.

COSTAL CARTILAGE WITH THE RIB. The end of the rib is hollowed to receive the costal cartilage, and the two are directly united. The periosteum of the rib is continued into the perichondrium of the cartilage. Rib and cartilage.

CHONDRO-STERNAL ARTICULATIONS. The cartilages of the true ribs, except the first, are articulated to the sternum by synovial joints. The extremity of each cartilage is received into a depression on the side of the sternum, and is fixed by a surrounding capsule (fig. 51,⁴). In front and behind the capsule is thickened by radiating fibres, which are described as *anterior* and *posterior ligaments*. Costal cartilages with the sternum.

In the joint of the second cartilage there is an *interarticular ligament* (fig. 51,⁶), like that to the head of the rib, which joins the cartilage between the pieces of the sternum; and the synovial sac is double. Similar bands are sometimes present in one or two of the succeeding joints. Second cartilage has a double joint.

A special band of fibres passes from the cartilage of the seventh rib to the ensiform process, and is named *costo-xiphoid ligament*. Costo-xiphoid ligament.

The cartilage of the first rib adheres directly to the sternum, without forming any joint. First cartilage.

INTERCHONDRAL ARTICULATIONS. The cartilages of the ribs from the sixth to the ninth articulate together by means of broad processes on their adjacent edges, which are connected by synovial joints. Cartilages with one another.

Each joint is surrounded by a short capsule, and is supported in front by strong fibres of the anterior intercostal aponeurosis (p. 258). The ends of the eighth, ninth and tenth cartilages are united each to the cartilage above by bands of fibrous tissue.

Motion of cartilages.

Movements. There is only a limited degree of movement in the chondro-sternal and interchondral articulations, the cartilages being elevated with the ribs in inspiration, and sinking in expiration.

Manubrium and body of sternum.

ARTICULATION OF THE STERNUM. The manubrium and body of the sternum are united by a piece of cartilage, with anterior and posterior longitudinal fibres. In some cases there is a cavity resulting from the absorption of the central portion of the cartilage. There is no appreciable movement between the pieces of the sternum, but the articulation aids in giving elasticity to the front of the chest.

Two sets of ligaments unite the vertebræ.

ARTICULATIONS OF THE VERTEBRÆ. The vertebræ are united together by two sets of ligaments,—one for the bodies, and the other for the arch and processes.

Along the spinal column the ligaments have a general resemblance, and one description will suffice except for those between the first two vertebræ and the head, and those of the pelvis.

How to see the several ligaments.

Dissection. After the articulations of the ribs have been examined, the same piece of the spinal column will serve for the preparation of the ligaments of the bodies of the vertebræ. The anterior ligament of the bodies will be defined with very little trouble, by removing the areolar tissue.

It is supposed that the spinal canal has been opened to examine the spinal cord, and that the posterior ligament of the bodies of the vertebræ is laid bare; but if the canal should not be open, the

neural arches of the vertebræ are to be removed by sawing through the pedicles.

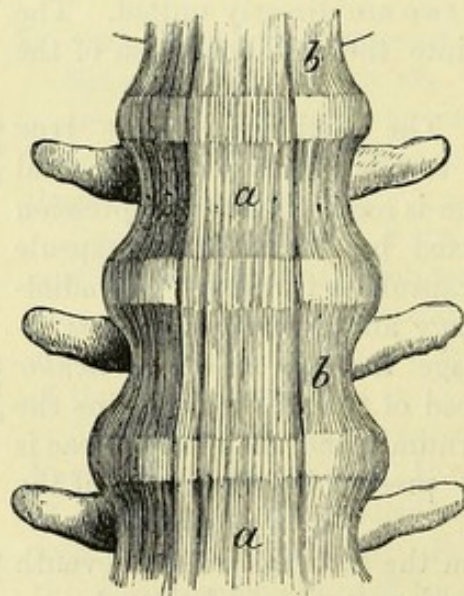
The remaining ligaments between the neural arches, spines, and articular processes of the bones may be dissected on the piece taken away in opening the spinal canal.

LIGAMENTS OF THE BODIES. The bodies of the vertebræ are united by an anterior and a posterior common ligament, with an intervening piece of fibro-cartilage.

The *anterior common ligament* (fig. 112, *a*) reaches from the axis to the sacrum. It is narrow above and wide below; and it also increases in thickness from above

downwards. Its fibres are longitudinal; and by detaching parts of the ligament, the superficial ones will be seen to extend over

Fig. 112.*



The bodies are united by:—

Anterior common ligament: form and thickness;

extent of fibres;

* *a*. Anterior common ligament of the bodies of the vertebræ. *b*. Lateral short fibres.

three or four vertebræ, while the deepest pass from one bone to the next. More of the fibres are attached to the intervertebral discs than to the bones; and few or none are fixed to the centre of the bodies. The ligament bridges over the transverse hollows on the vertebral bodies, and renders the front of the column smooth and even.

On each side, over the part uncovered by the anterior common ligament, the bodies of the vertebræ are united by a thin layer of short fibres (fig. 112, *b*). and mode of attachment.
Short lateral fibres.

The *posterior common ligament* (fig. 113) is contained in the spinal canal, lying on the back of the vertebral bodies, and also extends from the axis to the sacrum. It is much thinner than the anterior, and, unlike that, is broad above and narrow below. It is wider opposite the intervertebral discs than on the bodies, so that Posterior common ligament:
form;

Fig. 113A.*

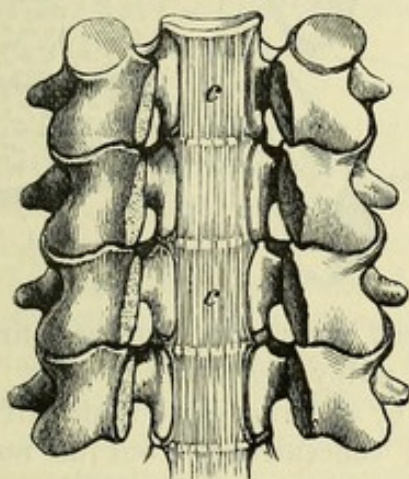
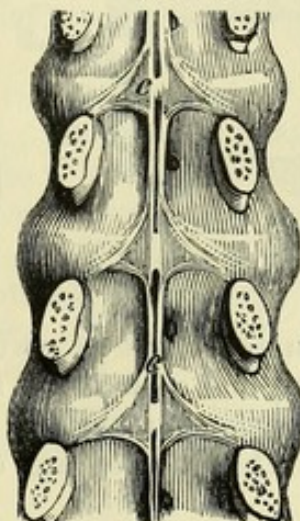


Fig. 113B.*



the margins are dentate. In the neck (A) it covers nearly the whole breadth of the bodies; but in the dorsal and lumbar regions (B) it is a narrow band, which sends off a pointed process on each side to be attached to the intervertebral disc and the upper margin of the pedicle. The hinder surface of the ligament is in contact with the dura mater; and between the band and the centre of the bodies are intervals where large veins issue from the bones. The fibres are arranged as in the anterior ligament; and they are more closely united with the intervertebral substance than with the bone. relations;

Dissection. To see the intervertebral discs, the anterior and posterior common ligaments must be taken away; and to show their structure, one disc should be cut through horizontally, while another is to be divided vertically by sawing through the bodies of two vertebræ. To see the inter-vertebral substance.

The *intervertebral substances* or *discs* (fig. 114) are placed between the bodies of the vertebræ, with the exception of the atlas and axis. Each disc is a flattened or slightly biconvex plate (fig. 115), which is firmly united to the adjacent surfaces of two bodies; and its form Inter-vertebral discs:
form and

* Two views of the posterior common ligament, *c*, to show the difference in shape, A, in the neck, and B, in the loins.

connec-
tions

and size are determined by the bones between which it lies. It is connected in front and behind with the anterior and posterior common ligaments; and on the sides, in the dorsal region, with the stellate and interarticular ligaments of the ribs.

structure;

In the sections that have been made the intervertebral substance

Fig. 114.*

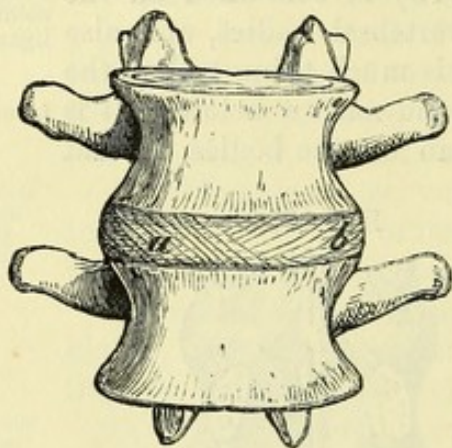
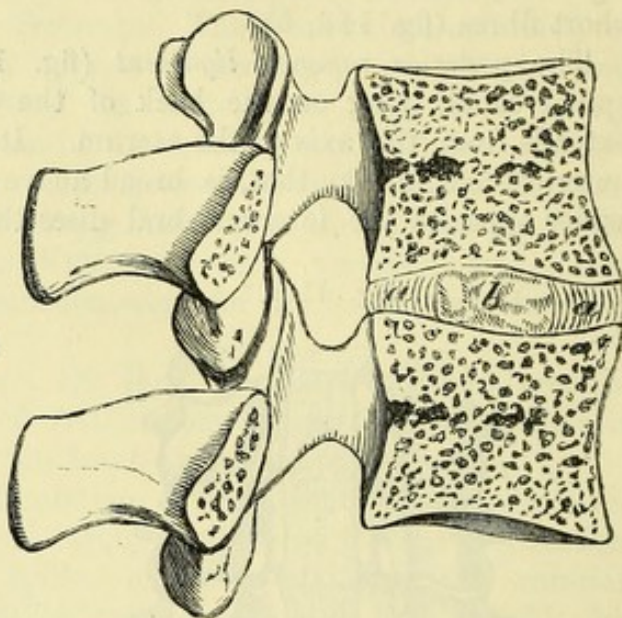


Fig. 115.†



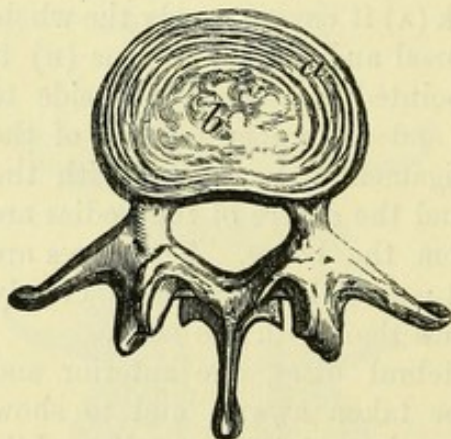
outer part
of fibrous
laminae;

is seen to consist of two different parts,—an external, firm and laminar, and an internal, soft and pulpy (fig. 115).

The outer laminar part (fig. 116, *a*) forms more than half of the disc. The laminae are disposed concentrically, but do not form

complete rings; and they are attached by their edges to the bodies of the vertebrae (fig. 115, *a*). They are composed for the most part of white fibro-cartilage; but the superficial ones consist of fibrous tissue. The fibres are parallel in each lamina, and run obliquely between two vertebrae; but the direction is reversed in alternate layers (fig. 114). This arrangement of the fibres is best seen on the thicker discs between the lumbar vertebrae; and it may

Fig. 116.‡



inner part
of pulpy
substance,

be demonstrated by dissecting layer after layer.

The central pulpy portion of the disc (fig. 116, *b*) is very soft,

* Intervertebral substance in the lumbar region with its laminae displayed. *a*. Superficial, and *b*, deeper layer, the fibres in the two taking different directions.

† Vertical section of the intervertebral substance. *a*. Peripheral laminar part. *b*. Central pulpy part.

‡ Horizontal section of an intervertebral disc. *a*. Laminar external part. *b*. Pulpy central substance.

and being tightly confined by the surrounding laminae, it projects when two vertebræ and the interposed mass are sawn through. Placed nearer the back than the front of the disc, it is more marked in the loins and neck than in the dorsal region. It has a yellowish colour, and is deficient in the stratiform arrangement so conspicuous at the circumference.

situation,
where
largest.

The surfaces of the vertebræ in contact with the disc have a cartilaginous covering, which may be seen by cutting the intervertebral substance from the bone. Over the centre of the osseous surface it forms a continuous layer, but it is wanting towards the circumference.

Cartilage
covering
bones.

The discs are thicker between the lumbar and cervical, than between the upper and middle dorsal vertebræ; and in the loins and neck, where the spinal column is convex forwards, they are deepest at the anterior edge, being wedge-shaped. The thickest piece of all, and the most wedge-shaped, is between the fifth lumbar vertebra and the sacrum.

Thickness
and form of
discs.

Use. The intervertebral discs form the chief bond of union between the several bones of the column; and by reason mainly of their strength displacement of the vertebræ is a rare occurrence.

They bind
bones firmly
together,

In the movements of the spine the vertebræ revolve around the central pulpy portion of the discs; and the extent of the movement between two segments of the column is limited by the circumferential laminar portion of the discs.

but permit
movement;

Through their wedge-shaped form the discs are chiefly instrumental in giving rise to the convexity of the spine in the loins and neck; and by their elasticity they moderate the effect of jars or shocks transmitted through the column.

render
column
convex,

The total thickness of the discs amounts to about a fourth of the length of the moveable part of the spinal column; but as they yield under pressure, the height of the body will be shorter from half an inch to an inch in the course of the day, according to the fatigue undergone.

and add to
its length.

LIGAMENTS OF THE NEURAL ARCH AND PROCESSES. The articular processes of the vertebræ are connected by synovial joints with surrounding capsules; the neural arches are united by yellow ligaments; the spinous processes have one band along their tips and others in the intervals between them; and some of the transverse processes are joined by fibrous bands.

Several
ligaments of
the arch and
processes.

Joints of articular processes. Between the articulating processes there is a moveable joint, in which the bones are covered with cartilage, and are surrounded by a *capsular ligament*, enclosing a *synovial membrane*. The capsules are loosest in the cervical, and strongest in the lumbar region.

Articular
have capsule
and synovial
sac.

Movement. In these gliding joints the articular processes of the vertebræ move to a limited extent over one another, the direction of the motion being determined by the form and inclination of their surfaces. The kinds of movement permitted in any portion of the column are thus dependent upon the characters of the joints between the articular processes. The movements are freest in the cervical

Motion in
the joints.

region, and least extensive between the upper dorsal vertebræ. By their overlapping, the articular processes also help in giving security to the spine; and in dislocation of the vertebræ they are generally broken off.

Yellow
ligaments of
the laminæ:

Ligaments of the arches. The *ligamenta subflava* are small rhomboidal sheets of yellow elastic tissue, which close the intervals between the neural arches at the back of the spinal canal from the

Fig. 117.*

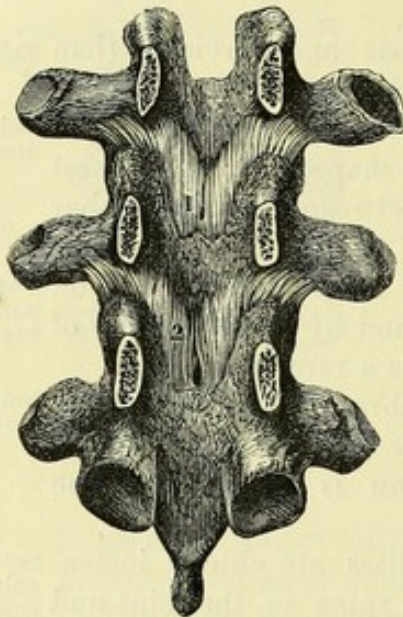
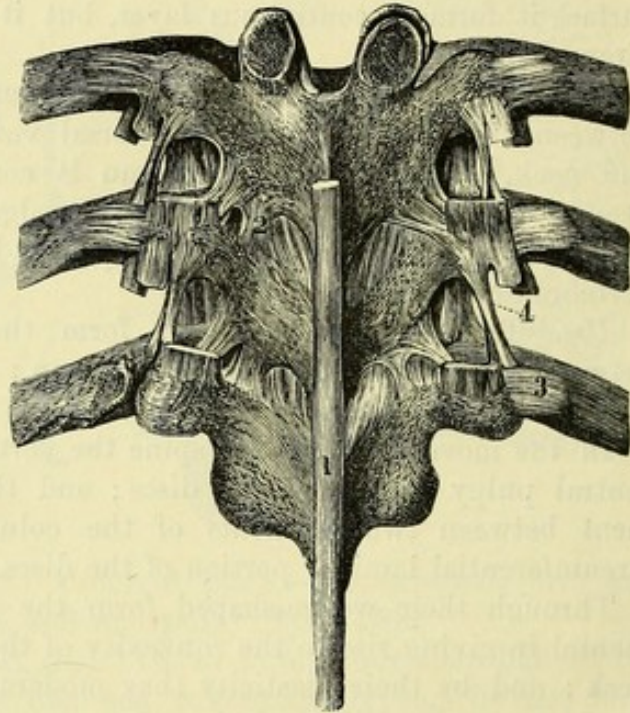


Fig. 118.†



extent;
attach-
ments;

thickness.

Ligaments
of spines:

supraspi-
nous;

and inter-
spinous.

axis to the sacrum. In each interval there are two ligaments, a right and a left, which meet in the middle line, and extend from the root of the spine to the articular processes. They are attached above to the anterior or deep surface of the laminæ of one vertebra, and below to the upper border and posterior surface of the laminæ of the next. They are thin in the neck, and strongest in the loins.

Ligaments of the spines. Along the tips of the spinous processes of the dorsal and lumbar vertebræ is a longitudinal band of fibres (fig. 118, 1)—the *supraspinous ligament*. It is thickest in the lumbar region; and it consists of superficial fibres which pass over three or more spines, and deep fibres which unite adjoining bones. Many of the back muscles arise from it on each side.

In the same regions there are also membranous *interspinous ligaments* (fig. 111, 5) reaching from the root to the tip of the spinous processes. They are thicker and broader in the lumbar than in the dorsal part of the column.

* An inner view of the neural arches of the vertebræ, with their interposed ligaments. (Bourguery.) 1 and 2. Ligamenta subflava.

† Ligaments of the processes of the vertebræ, and of the ribs. (Bourguery.) 1. Supraspinous ligament. 2. Ligamentum subflavum. 3. Posterior costotransverse ligament: on the opposite side the band has been removed and the joint opened. 4. Intertransverse ligament.

In the neck the place of the supraspinous and interspinous ligaments is taken by the ligamentum nuchæ (p. 384).

Ligaments of the transverse processes. In the loins the *inter-transverse ligaments* are thin membranous bands in the intervals between the processes. In the dorsal region there are rounded fibrous bundles (fig. 118,⁴) passing between the extremities of the transverse processes of the middle vertebræ, and representing inter-transverse muscles of the lower spaces. In the neck they are generally absent altogether.

Inter-transverse ligaments.

LIGAMENTS OF SPECIAL VERTEBRÆ. The description of the ligaments of the first two cervical, and of the sacral and coccygeal vertebræ, will be found with the dissection of the neck (p. 172) and of the pelvis (p. 589).

Ligaments of special vertebræ.

MOVEMENTS OF SPINAL COLUMN. The spinal column can be bent forwards, backwards, and to each side; and it can be rotated.

Kinds of motion.

In *flexion* the vertebræ between the axis and sacrum are inclined forwards. The greatest movement takes place between the lower lumbar vertebræ and the sacrum; there is an intermediate degree in the neck; and the least is in the upper half of the dorsal region, where the ribs are united to the sternum.

Flexion : degree ;

The bodies of the bones are brought nearer together in front, while they are separated behind. The inferior pair of articular processes of the second vertebra glide upwards on the upper of the third; the inferior processes of the third bone move in like manner on the upper of the fourth; and so on throughout the moveable column.

movement of bones ;

The ligament in front of the bodies is relaxed, but the posterior, and those uniting the neural arches and processes are tightened. The fore part of each intervertebral disc is compressed, and the back is stretched.

state of ligaments.

In *extension* the column is arched backwards. The motion is most in the neck, and least in the dorsal vertebræ, which are fixed by the true ribs and the sternum, and are impeded in their movement by the overlapping spinous processes.

Extension : where most, and least ;

The posterior parts of the vertebræ are approximated, while the anterior are separated; and the inferior articular processes of each glide downwards on the upper ones of the next succeeding bone.

movement of bones ;

The condition of the ligaments is the opposite to that in flexion. Thus, the intervertebral discs are compressed behind, and stretched in front; the spinous and yellow ligaments are relaxed; the anterior common ligament of the bodies is tightened, and the hinder band is slackened.

state of ligaments.

Lateral inclination. The spine can be curved to the right or the left side. Like the last movement, this bend is least in the more fixed upper dorsal vertebræ, and is greatest in the neck.

Bending to side : extent ;

On the concave side of the curve, say the right, the bodies are brought nearer together; and they are carried away from each other on the opposite aspect. The right inferior articular surface glides down, and the left up, in the joints with the vertebra beneath.

movement of bones ;

On the right side the ligaments will be relaxed and the inter-

state of ligaments.

vertebral substance compressed; and on the left those structures will be tightened so as to check the movement.

Rotation : *Rotation* is the twisting of the bodies of the vertebræ around a vertical axis through their centres, the fore part being turned to the right or left, while the lower articular processes glide in the opposite direction over the upper of the next bone below. The movement will obviously be checked by the tightening of one set of oblique fibres in the intervertebral disc.

where present. A pure rotation of this kind, however, takes place only to a small extent in the upper dorsal region; but in the neck a greater degree of turning movement is permitted in combination with lateral flexion, owing to the conformation of the articular surfaces. In the loins the articular surfaces are so disposed that rotation is impossible.

CHAPTER V.

DISSECTION OF THE BACK.

Directions. The dissection of the back may be undertaken by one student; or conjointly by the dissectors of the head and upper limbs, the former preparing the neck, and the latter making ready the dorsal and lumbar regions. Directions.

If the back should be allotted to more than one student, the dissector of the upper limb may attend chiefly to the paragraphs marked with an asterisk; and the dissector of the neck may study specially the paragraphs which are not so marked. But as many of the dissections in the earlier stages require the co-operation of the students employed on the same side of the body, a general attention should be given to the whole by each.

The dissector of the abdomen is to examine the arrangement of the fascia lumborum, after the first layer of the dorsal muscles has been learnt.

Position. The body lies with the face downwards; and the trunk is to be raised by blocks beneath the chest and the pelvis, so that the limbs may hang over the end and sides of the dissecting table. To make tense the neck, the head is to be depressed and fastened with hooks. Position of body.

In this region there are five successive layers of muscles, amongst which vessels and nerves are interspersed. Strata in back.

Dissection. The first step is to raise the skin in two flaps by means of the following incisions:—One cut is to be made along the middle of the body from the occipital protuberance to the back of the sacrum. Another is to be carried from the last dorsal spine to the acromion process of the scapula. The flap of skin above the last cut is to be turned outwards by the dissectors of the head and upper limb. To raise the skin.

By another transverse incision opposite the iliac crest, the remaining piece of integument may be detached, and reflected by the dissector of the upper limb in the same direction as the upper flap.

Beneath the upper flap of skin the trapezius muscle is placed, and under the lower one the latissimus dorsi.

The cutaneous nerves may be now sought in the superficial fatty layer: they are accompanied by small arteries which will guide the student to their position. The nerves vary much in size in the Seek cutaneous nerves:

different parts of the back, and their number is also irregular: as a general rule, there is one opposite each vertebra except in the neck.

in the neck; To find them in the cervical region, look near the middle line, from the 3rd to the 6th vertebra, and trace an offset from the third nerve upwards to the head: the branch of the second nerve (great occipital) has been laid bare at the back of the head (p. 5).

in thorax and loins; Over the upper part of the thorax, they will be found near the spines of the vertebræ, where they lie at first beneath the fat; but at the lower part, and in the loins, they issue in a line with the angles of the ribs.

sacral. The cutaneous branches of the sacral nerves are included in the dissection of the lower limb.

Cutaneous nerves how derived. CUTANEOUS NERVES. The tegumentary nerves are derived from the posterior primary branches of the spinal nerves, which divide amongst the deep muscles into two pieces, inner and outer. Arteries accompany the greater number of the nerves, bifurcate like them, and furnish cutaneous offsets.

In the neck: CERVICAL NERVES. In the neck the nerves are derived from the inner of the two branches into which the posterior trunks divide: source. they perforate the trapezius, and supply the neck and the back of the head. They are four in number, and come from the second, third, fourth, and fifth nerves.

Second The branch of the second nerve is named great occipital, and accompanies the occipital artery to the back of the head (p. 8).

and third nerve. The branch of the third cervical nerve supplies a transverse offset to the neck, and then ascends to the lower part of the head, where it is distributed near the middle line, communicating with the great occipital nerve (p. 8).

In the dorsal region: * DORSAL NERVES. These are furnished by both the inner and outer branches—the upper six or seven from the inner, and the lower five or six from the outer. On the surface they are directed outwards in the integument over the trapezius and latissimus dorsi muscles.

upper nerves; The upper nerves perforate the trapezius near the spines of the vertebræ; and the branch of the second, which is larger than the rest, extends outwards over the scapula. The lower nerves pierce the latissimus dorsi mostly in a line with the angles of the ribs; the lower nerves. the number of the superficial offsets from these nerves often varies.

In the loins. * LUMBAR NERVES. In the loins the nerves are derived from the outer branches of the first three trunks; they perforate the latissimus dorsi muscle at the outer border of the erector spinæ, and crossing the iliac crest of the hip-bone, are distributed in the integuments of the buttock.

Two muscles in first layer. * FIRST LAYER OF MUSCLES (fig. 119). Two muscles, the trapezius and the latissimus dorsi, are included in this layer.

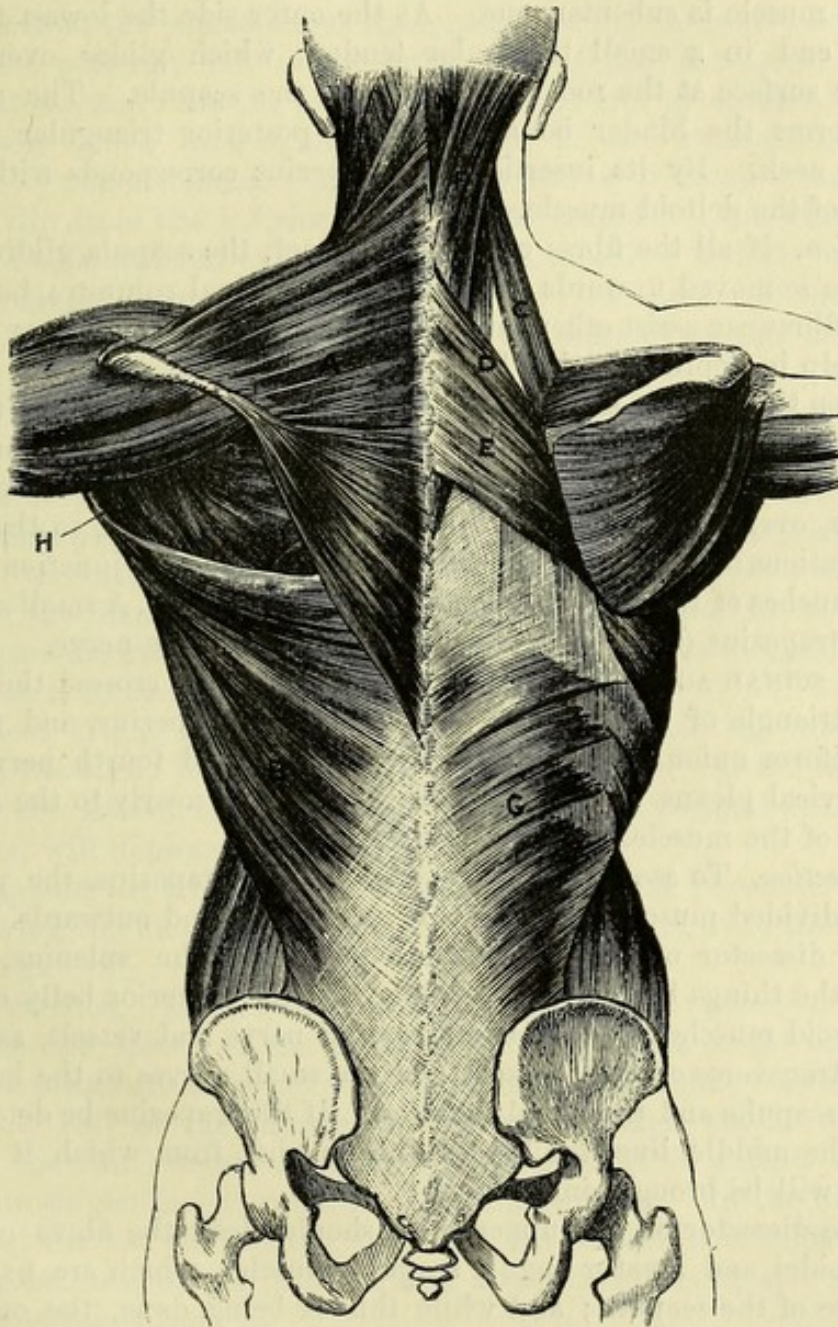
Dissection. Dissection. The superficial fatty layer and the unimportant deep fascia are to be removed together from the trapezius and latissimus dorsi in the direction of the fibres of each, viz., from the shoulder to the spinal column; and the upper limb is to be carried back-

wards or forwards according as it may be necessary to put on the stretch different portions of the muscles.

Some of the cutaneous nerves and vessels may be left in order that they may be afterwards traced through the muscles to their origin.

* The TRAPEZIUS MUSCLE (fig. 119, A) is triangular in shape, with Trapezius :

Fig. 119.*



the base towards the spine, but the two have a trapezoid form. The muscle has an extensive *origin*, by short tendinous fibres, from the origin; spines of all the dorsal and the seventh cervical vetabræ, and their supraspinous ligament, from the ligamentum nuchæ, and from the

* Muscles of the back. On the left side the first layer is shown, and on the right side the second layer, with part of the third. A. Trapezius. B. Latissimus dorsi. C. Levator anguli scapulæ. D. Rhomboides minor. E. Rhomboides major. F. Splenius. G. Serratus posticus inferior.

insertion.	inner third of the superior curved line of the occipital bone. From this origin the fibres are directed outwards, converging to the shoulder, and are <i>inserted</i> into the outer third of the clavicle, at its posterior aspect, into the inner border of the acromion, and into the upper border of the spine of the scapula as far as an inch from the root of that process, as well as into a rough prominence on the lower margin of the spine near the inner end.
Relations.	The muscle is subcutaneous. At the outer side the lowest fleshy fibres end in a small triangular tendon, which glides over the smooth surface at the root of the spine of the scapula. The upper edge forms the hinder boundary of the posterior triangular space of the neck. By its insertion the trapezius corresponds with the origin of the deltoid muscle.
Use : scapula free to glide ;	<i>Action.</i> If all the fibres of the muscle act, the scapula gliding on the ribs is moved upwards and towards the spinal column ; but the upper fibres can assist other muscles in elevating, and the lower fibres will help in depressing that bone.
in rotation of bone.	When the scapula is prevented from gliding on the ribs, the trapezius imparts a rotatory movement to it, and raises the acromion.
Trace spinal accessory.	<i>Dissection.</i> The fibres of the trapezius are to be divided near the scapula, over the situation of the spinal accessory nerve, so that the ramifications of that nerve beneath the muscle, and its junction with the branches of the cervical plexus may be observed. A small artery to the trapezius (superficial cervical) accompanies the nerve.
Spinal accessory nerve in trapezius.	The SPINAL ACCESSORY NERVE (p. 111), having crossed the posterior triangle of the neck, passes beneath the trapezius, and forms a plexiform union with branches of the third and fourth nerves of the cervical plexus. The nerve can be followed nearly to the lower border of the muscle.
Dissection to reflect trapezius ; to prepare parts in the neck.	<i>Dissection.</i> To see the parts covered by the trapezius, the pieces of the divided muscle are to be thrown inwards and outwards. The dissector of the neck should now clean the splenius, and define the things beneath the clavicle, viz., the posterior belly of the omo-hyoid muscle with the suprascapular nerve and vessels, as well as the transverse cervical vessels, and the small nerves to the levator anguli scapulæ and rhomboid muscles. If the trapezius be detached along the middle line, the ligamentum nuchæ, from which it takes origin, will be brought into view.
Clean the scapular muscles.	* The dissector of the upper limb should clean the fibres of the rhomboidei and levator anguli scapulæ muscles, which are fixed to the base of the scapula ; and while this is being done, the scapula is to be drawn away from the trunk to make tense the fleshy fibres.
Parts covered by trapezius.	* <i>Parts covered by the trapezius.</i> The trapezius conceals in the neck the splenius, a small part of the complexus, and the levator anguli scapulæ ; in the dorsal region it covers the rhomboidei, the erector spinæ, and the latissimus dorsi. Near the insertion it lies over the supraspinatus muscle.
Ligamen- tum nuchæ	The LIGAMENTUM NUCHÆ is a narrow fibrous band, which extends from the spinous process of the seventh cervical vertebra to the external occipital protuberance. From its deep surface a thin layer

of fibres, which forms a median partition between the muscles of the two sides of the neck, is sent forwards to be attached to the external occipital crest and the other cervical spines.

* The LATISSIMUS DORSI (fig. 119, B) is the widest muscle of the back, and is thin and aponeurotic at its attachment to the spine and pelvis. It arises along the middle line from the spinous processes of the six lower dorsal, all the lumbar, and the upper sacral vertebræ, as well as from the supraspinous ligament. On the outer side it arises from the posterior half of the outer edge of the iliac crest by its aponeurosis, and from the lowest three or four ribs by as many fleshy processes, which interdigitate with slips of the external oblique muscle of the abdomen. And in many bodies it receives another fleshy slip from the inferior angle of the scapula. The fibres are directed outwards and upwards, converging rapidly; and the muscle, much reduced in breadth, turns round the lower border of the teres major, to be inserted by tendon into the bottom of the bicipital groove of the humerus (p. 256).

Latissimus
dorsi :
origin from
spine,
pelvis,
and ribs ;

insertion
into hume-
rus ;
relations ;

The muscle is superficial, except at the upper and inner part, where it is covered to a small extent by the trapezius. Farther out there is a space between the two, in which the rhomboid and infraspinatus muscles appear. The lower or outer border overlaps the edge of the external oblique muscle in the interval between the last rib and the iliac crest. The aponeurosis of the latissimus is in its lower part incorporated in the posterior layer of the fascia lumborum, of which it forms the chief constituent.

Action. If the arm is hanging loose, the muscle can move it behind the back, rotating it in at the same time. If the limb is raised, the latissimus, combining with the large pectoral and teres muscles, will depress the humerus.

use,
when the
limb is free,

Supposing the arm fixed, the latissimus assists the pectoralis major in drawing the moveable trunk towards the humerus, as in the act of climbing.

and fixed.

* *Dissection.* The latissimus is to be divided about midway between the spines of the vertebræ and the angle of the scapula, and the pieces are to be reflected inwards and outwards. In raising the inner half of the muscle, care must be taken not to destroy either the thin lower serratus, with which it is united, or the aponeurosis continued upwards from the serratus. In the interval between the last rib and the iliac crest the latissimus is adherent to the aponeurosis of the transversalis abdominis muscle, and should not be detached from it.

Dissection
to reflect
latissimus.

* *Parts covered by the latissimus.* The latissimus dorsi lies on the erector spinæ, the serratus posticus inferior, the lower ribs with their intercostal muscles, and the lower angle of the scapula, with parts of the rhomboideus major, infraspinatus, and teres major muscles. Nearer the humerus it turns round the teres major, and is placed in front of that muscle at its insertion. In passing from the chest to the arm, the latissimus forms part of the posterior boundary of the axilla.

Parts be-
neath latis-
simus.

Dissection of fascia lumborum. After the latissimus dorsi has been

Dissection

of fascia reflected, the dissector of the abdomen can look to the disposition of the fascia lumborum between the last rib and the hip-bone.

In the spot referred to are portions of the external and internal oblique muscles, left in the dissection of the wall of the abdomen. After the removal of those muscles, the aponeurosis of the transversalis muscle (fascia lumborum) appears, and perforating it are two nerves : one, the last dorsal, with an artery near the last rib ; and the other, the ilio-hypogastric, with its vessels close to the iliac crest.

to show
three layers
in it,—
posterior,

Three layers of the fascia lumborum are to be demonstrated, passing from the aponeurosis of the transversalis to the spinal column. The superficial layer is already exposed, being formed mainly by the aponeurosis of the latissimus dorsi. To see the middle layer, which passes beneath the erector spinæ to the transverse processes, the first layer is to be divided, with the attached portion of the latissimus dorsi, by a horizontal incision carried outwards from the third lumbar spine. On raising the outer border of the erector spinæ muscle, which comes into view, the strong process of the fascia will be apparent.

middle.

and anterior.

After cutting in the same way through this prolongation, another muscle, the quadratus lumborum, will be seen ; and on raising its outer border, the thin deepest layer of the fascia will be evident on the abdominal aspect of that muscle.

Lumbar
fascia,

derived from
transversalis
tendon,

THE FASCIA LUMBORUM OR LUMBAR APONEUROSIS occupies the interval between the last rib and the iliac crest, and extends inwards to the spine. It is formed mainly by the posterior tendon of the transversalis muscle of the abdominal wall (fig. 140, c), but its superficial part receives important accessions from two of the muscles of the back. If the tendon of the transversalis be followed inwards, it will be found to divide at the outer edge of the quadratus lumborum into two layers, which encase that muscle ; and the posterior of these again splits, or gives off a superficial process, at the outer margin of the erector spinæ. There are thus in the lumbar aponeurosis three layers of membrane, forming with the vertebræ two sheaths, the one of which encloses the quadratus lumborum, and the other the multifidus and erector spinæ muscles.

consists of
three layers :

anterior,

The *anterior layer* is thin, and passes on the abdominal surface of the quadratus lumborum to be fixed to the front of the transverse processes of the lumbar vertebræ near their tips.

and middle
to transverse
processes ;

The *middle layer* is the direct continuation of the transversalis tendon, and lies between the quadratus lumborum and the erector spinæ muscles ; it is fixed to the extremities of the transverse processes.

posterior to
spinous
processes.

The *posterior* or *superficial layer* is the thickest, and is attached internally to the spines of the lumbar vertebræ. In this layer are united the aponeuroses of the latissimus dorsi and serratus posticus inferior muscles, with only a small offset of the tendon of the transversalis.

* SECOND LAYER OF MUSCLES (fig. 119). This stratum contains

the elevator of the angle of the scapula, and the large and small rhomboid muscles: besides these, the posterior belly of the omohyoid muscle, and some vessels and nerves directed outwards towards the scapula, are now to be examined. The parts referred to have been prepared in the dissection following the reflection of the trapezius (p. 384).

* The *LEVATOR ANGULI SCAPULÆ* (fig. 119, c) arises by tendinous slips from the posterior tubercles of the transverse processes of the upper four cervical vertebræ. The fibres form an elongated muscle, which is *inserted* into the base of the scapula between the spine and the superior angle.

Second muscular layer.

Elevator of angle of scapula: attachments:

At its origin the levator lies beneath the sterno-mastoid, and at its insertion beneath the trapezius, where it meets the serratus magnus muscle; the rest of the muscle appears in the posterior triangular space of the neck. Beneath it are some of the other cervical muscles, viz., splenius colli and cervicalis ascendens.

relations;

Action. The muscle raises the angle and hinder part of the scapula, and depresses the acromion; but in combination with the upper fibres of the trapezius, which prevent the rotation down of the acromion, it shrugs the shoulder.

and use, on scapula,

When the shoulder is fixed, the neck can be bent to the side by the levator.

on the neck.

* *RHOMBOIDEI MUSCLES.* The muscular layer of the rhomboides is attached to the base of the scapula, and consists of two pieces, large and small, which are usually separated by a slight interval.

Rhomboid muscles are two.

* The *rhomboides minor* (fig. 119, d) is a thin narrow band, which *arises* from the spines of the seventh cervical and first dorsal vertebræ, and the ligamentum nuchæ, and is *inserted* into the base of the scapula, opposite the smooth surface at the root of the spine.

Small muscle.

* The *rhomboides major* (fig. 119, e) is much larger than the preceding muscle. It *arises* from the spines of four or five dorsal vertebræ below the rhomboides minor, and from the supraspinous ligament; and its fibres are directed outwards and downwards to be *inserted* into the base of the scapula between the spine and the lower angle. Sometimes the upper fibres are not fixed to the scapula directly, but end on a tendinous arch near the bone.

Large muscle: origin; insertion.

The rhomboides are for the most part covered by the trapezius and latissimus; but a portion of the larger muscle is subcutaneous near the scapula.

Relations.

Action. From the direction of their fibres both rhomboides will draw the base of the scapula upwards and backwards, so as to depress the acromion. In combination with the trapezius they carry the scapula directly back; and acting with the serratus magnus they serve to fix the scapula.

Use, by themselves, with others.

The *OMO-HYOID MUSCLE* consists of two fleshy bellies, anterior and posterior, which are united by an intervening tendon. Only the posterior half is now seen.

Posterior belly of omohyoid:

The muscle *arises* from the upper border of the scapula behind the notch, and from the ligament converting the notch into a fora-

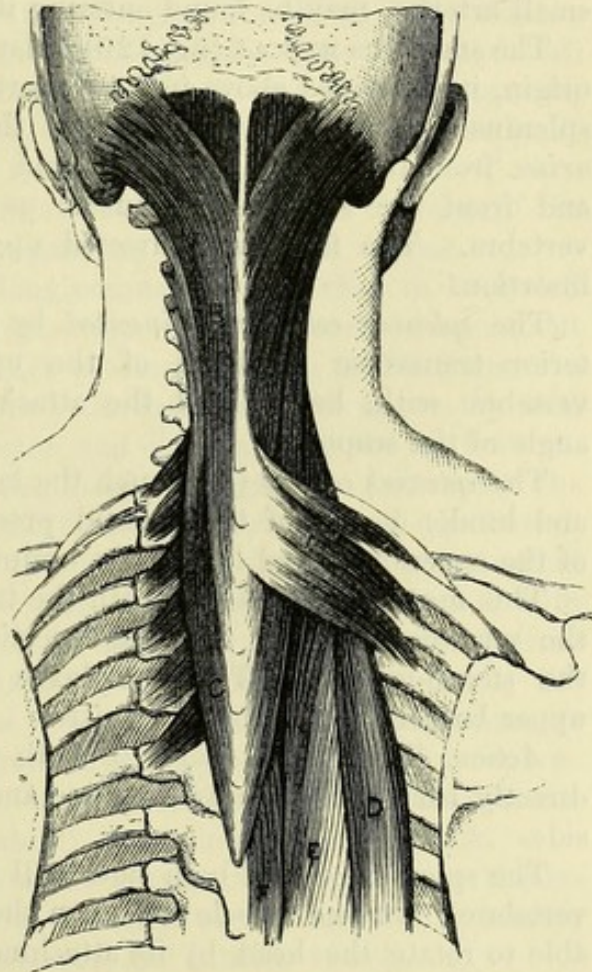
origin,

and termination ;	men. The fibres form a thin, riband-like muscle, which is directed forwards across the lower part of the neck, and ends anteriorly in a tendon beneath the sterno-mastoid (p. 64). This belly is partly placed beneath the trapezius, and is partly superficial in the posterior triangular space of the neck, where it lies above the clavicle and the subclavian artery, and crosses the brachial plexus and the suprascapular nerve.
relations :	
use.	<i>Action.</i> For the use of the muscle, see page 64.
Supra-scapular artery : course to shoulder ;	The SUPRASCAPULAR ARTERY, a branch of the subclavian (p. 70), is directed outwards through the lower part of the neck to the upper border of the scapula. It runs behind the clavicle, and crosses the suprascapular ligament in front of the omo-hyoid muscle, to enter the supraspinous fossa. Its termination on the dorsum of the scapula is seen in the dissection of the shoulder (p. 269). Before entering the fossa it gives off a <i>supra-acromial branch</i> , which perforates the trapezius muscle, and ramifies over the acromion.
offset.	
Supra-scapular nerve.	The SUPRASCAPULAR NERVE is an offset of the brachial plexus (p. 73), and inclines downwards beneath the omo-hyoid muscle to the notch in the upper border of the scapula, through which it passes into the supraspinous fossa (p. 269).
Transverse cervical artery	The TRANSVERSE CERVICAL ARTERY, also a branch of the subclavian (p. 70), has the same direction as the suprascapular, towards the upper angle of the scapula, but is higher than the clavicle. Crossing the upper part of the space in which the subclavian artery lies, it passes beneath the trapezius, and divides into two branches—superficial cervical and posterior scapular.
divides into	
superficial cervical and	<i>a.</i> The <i>superficial cervical branch</i> is distributed chiefly to the under surface of the trapezius, though it furnishes offsets to the levator anguli scapulæ and the cervical glands.
posterior scapular.	<i>b.</i> The <i>posterior scapular branch</i> crosses under the levator anguli scapulæ, and descends along the base of the scapula beneath the rhomboid muscles. If these muscles are divided, the artery will be seen to furnish branches to them, and to give small anastomotic twigs to both surfaces of the scapula. This branch arises very frequently from the third part of the subclavian trunk.
Accompanying veins.	The <i>suprascapular</i> and <i>transverse cervical veins</i> have the same course and branches as the arteries above described ; they open into the external jugular, near its junction with the subclavian vein.
Nerve of rhomboid muscles.	NERVE TO THE RHOMBOID MUSCLES. This slender offset of the brachial plexus (p. 73) courses beneath the elevator of the angle of the scapula, and is distributed to the rhomboidei on the under surface. Before its termination it supplies one or two twigs to the elevator of the scapula.
Third layer of muscles.	* THIRD LAYER OF MUSCLES. In this stratum are included the serratus posticus superior and inferior, and the splenius muscles.
Dissection.	* <i>Dissection.</i> By reflecting the rhomboid muscles towards the spinous processes, and removing loose areolar tissue, the thin upper serratus muscle beneath them will be laid bare.
	The inferior serratus has been previously exposed by the reflection of the latissimus.

* The **SERRATI MUSCLES** are very thin, and receive their name from their toothed attachment to the ribs. They are two in number, superior and inferior, and have aponeurotic origins from the spines of the vertebræ. Serrati are two in number.

* The *serratus posticus superior* (fig. 120, A) arises from the ligamentum nuchæ, and from the spinous processes of the last cervical, and upper two or three dorsal vertebræ, with the supraspinous ligament. The fleshy fibres are inclined down and out, and are inserted by slips into four ribs, from the second to the fifth, external to their angles. The upper the smaller :
attach-
ments ;

Fig. 120.*



relations.

Inferior
serratus :

origin ;

insertion ;

relations.

The muscle rests on the splenius, and is covered by the rhomboidei except at its upper border.

* The *serratus posticus inferior* (fig. 119, G) is wider than the preceding muscle. Its aponeurosis of origin is inseparably united with that of the latissimus dorsi, and with the fascia lumborum, and is connected to the spinous processes of the last two dorsal and upper two or three lumbar vertebræ. The fleshy fibres ascend somewhat to be inserted into the last four ribs outside their angles, each successive piece extending farther forwards than the one below.

This muscle lies on the mass of the erector spinæ ; and with the upper border of its tendon the vertebral aponeurosis is united.

Action. Both serrati are inspiratory muscles. The upper one raises the ribs into which it is inserted ; while the lower one draws backwards the lower ribs, and prevents their being carried upwards by the contraction of the diaphragm. Use of
serrati.

The **VERTEBRAL APONEUROSIS** is a thin fascia which covers the fourth layer of muscles in the thoracic region. Internally it is attached to the spinous processes of the vertebræ. Externally it is fixed to the angles of the ribs ; and in the intervals between the bones it joins the layer of connective tissue covering the intercostal Vertebral
aponeu-
rosis :
attach-
ments ;

* Part of the third and fourth layers of the muscles of the back. A. Serratus posticus superior. B. Splenius capitis. C. Splenius colli. D. Continuation of the ilio-costalis. E. Longissimus dorsi. F. Spinalis dorsi.

- continuation below, and above. muscles. It is continuous below with the tendon of the serratus posticus inferior, and through this with the superficial layer of the fascia lumborum; but above, it passes beneath the upper serratus, and blends with the deep intermuscular fascia of the neck. The strongest fibres of the membrane are directed transversely.
- Dissection. * *Dissection.* The upper serratus is to be cut through, and the vertebral aponeurosis taken away; and the part of the splenius muscle under the serratus should be cleaned. In turning outwards the fleshy part of the serratus, slender twigs of the intercostal nerves, which perforate the external intercostal muscle accompanied by small arteries, may be found entering its slips.
- Splenius has two parts: The SPLENIUS MUSCLE (fig. 120) is flat and elongated. Single at its origin, it is divided above into two parts, one passing to the head—splenius capitis, and the other to the neck—splenius colli. It arises from the upper six dorsal and the seventh cervical spines, and from the ligamentum nuchæ as high as the third cervical vertebra. The fibres are directed upwards and outwards to their insertion.
- one to the neck; The *splenius colli* (c) is inserted by tendinous slips into the posterior transverse processes of the upper two or three cervical vertebræ with, but behind the attachment of the elevator of the angle of the scapula.
- the other to the head; The *splenius capitis* (B), much the larger, is inserted into the apex and hinder border of the mastoid process, and into the outer third of the superior curved line of the occipital bone.
- relations. This muscle is situate beneath the trapezius, the rhomboidei, and the serratus superior; and the insertion into the skull is beneath the sterno-mastoid. The complexus muscle appears above the upper border of the splenius capitis.
- Use of splenius capitis, *Action.* The cranial parts of both muscles will carry the head directly back; and one will incline and rotate the head to the same side.
- splenius colli. The splenius colli of both sides will bend back the upper cervical vertebræ; but one muscle will turn the face to the same side, being able to rotate the head by its attachment to the transverse process of the atlas.
- Fourth layer of muscles. * **FOURTH LAYER OF MUSCLES.** In this layer are included the erector spinæ, with its divisions and accessory muscles to the neck, and the complexus. Most of the vessels and nerves of the back are to be learnt with this layer of muscles.
- Dissection of complexus. *Dissection* (fig. 121). To lay bare the complexus muscle in the neck, the splenius must be detached from the spinous processes, and thrown outwards.
- Define offsets from the erector spinæ. And while the erector spinæ is being displayed in the dorsal and lumbar regions by the dissector of the upper limb, two prolongations from it to the cervical vertebræ and the head are to be defined by the dissector of the neck:—One, a thin narrow muscle, the cervicalis ascendens, is continued beyond the ribs from the outer piece of the erector (ilio-costalis), and is to be separated from the muscles around. The other is a larger offset of the inner piece of the erector (longia-

simus dorsi); single at first where it is united with the fibres of the longissimus, it is divided afterwards, like the splenius, into a cranial part (trachelo-mastoid) and a cervical part (transversalis colli).

* The serratus inferior is to be detached from the spines and thrown outwards, when fine nerves will be found entering it like those to the upper muscle. The superficial layer of the fascia lumborum is also to be removed, and the areolar tissue is to be cleaned from the surface of the large mass of the erector spinæ which now comes into view. Opposite the last rib is an inter-muscular interval, which divides the erector spinæ into an outer piece (ilio-costalis), and an inner (longissimus dorsi). By sinking the knife into this interval the sacro-lumbalis may be turned outwards, so as to uncover the fleshy slips of its accessory muscle, which are fixed to the angles of the ribs: a muscular slip (cervicalis ascendens) is prolonged from this to the neck.

Show the
erector
spinæ and
its divisions.

Ilio-
costalis :

its offset to
the neck.

* In preparing the ilio-costalis muscle, the external branches of the dorsal nerves with their accompanying arteries will appear.

Vessels and
nerves.

* The attachments of the longissimus dorsi are then to be traced out. Externally it has thin muscular slips of insertion into about the lower nine ribs, and thicker processes passing to the transverse processes of the lumbar vertebræ; the latter may be shown by raising the outer border of the erector, and clearing away the fat between it and the middle layer of the fascia lumborum. Internally the longissimus is inserted into the transverse processes of the dorsal, and the accessory processes of the lumbar vertebræ by rounded tendons; and to see these it will be necessary to detach a thin tendinous and muscular portion of the erector (spinalis dorsi) from the inner side of the longissimus, and to divide longitudinally the part of the thick aponeurosis springing from the lumbar spines, so as to separate the erector from the subjacent multifidus spinæ. From the longissimus, as from the ilio-costalis, a fleshy piece (transversalis colli and trachelo-mastoid) is continued into the neck.

Longissi-
mus dorsi :

outer

and inner
insertions ;

spinalis
dorsi ;

offsets to the
neck.

* Between the longissimus and the multifidus spinæ are the internal branches of the posterior divisions of the dorsal and lumbar nerves, with offsets of the intercostal and lumbar vessels.

Vessels and
nerves.

* **ERECTOR SPINÆ.** This is the muscular mass on the side of the spine, extending from the lower part of the sacrum to the head. It is single and pointed below, attains its greatest size in the loins, and on the thorax becomes divided into secondary portions to which special names are given. Its prolongations to the neck and head are very slender. On its posterior surface, in the lumbar and sacral regions, is a strong flat tendon of origin, from which most of the fleshy fibres spring. The muscle arises internally from the lower two or three dorsal, and all the lumbar and sacral spines; externally from the posterior fifth of the iliac crest at the inner aspect; and inferiorly from the lower part of the back of the sacrum. Below the last rib it divides into the ilio-costalis and longissimus dorsi; and in the thoracic region the spinalis dorsi is given off from the inner side of the latter part.

Erector
spinæ is
single
below ;

divided
above ;

superficial
tendon ;

origin.

* The ILIO-COSTALIS or SACRO-LUMBALIS is derived from the outer

Ilio-
costalis :

and superficial part of the common mass of the erector in the loins.
 insertion. Its fibres end in six or seven tendons, which are *inserted* into the angles of as many of the lower ribs. It is continued to the upper ribs and the neck by the two following muscles :—

* The ACCESSORIUS (musculus accessorius ad ilio-costalem; fig. 120, D) *arises* by a series of tendinous and fleshy slips from the angles of the lower six ribs internal to the insertion of the ilio-costalis; and it ends in tendons which are *inserted* into the remaining ribs in a line with the ilio-costalis, and into the transverse process of the seventh cervical vetebra.

Cervicalis ascendens : The CERVICALIS ASCENDENS is a muscular slip prolonging the accessorius into the neck : it *arises* from four ribs, viz., the sixth, fifth, fourth, and third, and is *inserted* into the posterior tubercles of the sixth, fifth, and fourth cervical vetebræ.

Longissimus dorsi : * The LONGISSIMUS DORSI is the largest of the pieces resulting from the division of the erector spinæ, and has two sets of insertions into the vertebræ and ribs. Internally it gives off a series of fleshy and tendinous bundles to the accessory processes of the lumbar vertebræ, and the transverse processes of all the dorsal vertebræ : externally it is attached by thick fleshy slips to the transverse processes of the lumbar vertebræ, and the middle layer of the fascia lumborum ; and by thin flattened processes to the ribs, except the first two or three, between the tuberosity and angle.

is continued to neck by Its muscular prolongation to the neck is united with the upper fleshy fibres, and splits into the two following pieces :—

transversalis colli, The TRANSVERSALIS COLLI (fig. 121, B) *arises* from the transverse processes of the upper dorsal vertebræ (from four to six), and is *inserted* into the posterior tubercles of the transverse processes of the cervical vertebræ except the first and last.

and to head by trachelo-mastoid. The TRACHELO-MASTOID MUSCLE (transversalis capitis; fig. 121, C) *arises* in common with the preceding, and receives additional slips from the articular processes of the lower three or four cervical vertebræ. It is *inserted* beneath the splenius capitis into the posterior margin of the mastoid process, where it is about three-quarters of an inch wide.

Spinalis dorsi : * The SPINALIS DORSI is very narrow, and springs from the tendinous slips of the erector which arise from the lower dorsal and upper two or three lumbar spines. Its fibres are *inserted* into a variable number (from four to nine) of the upper dorsal spines.

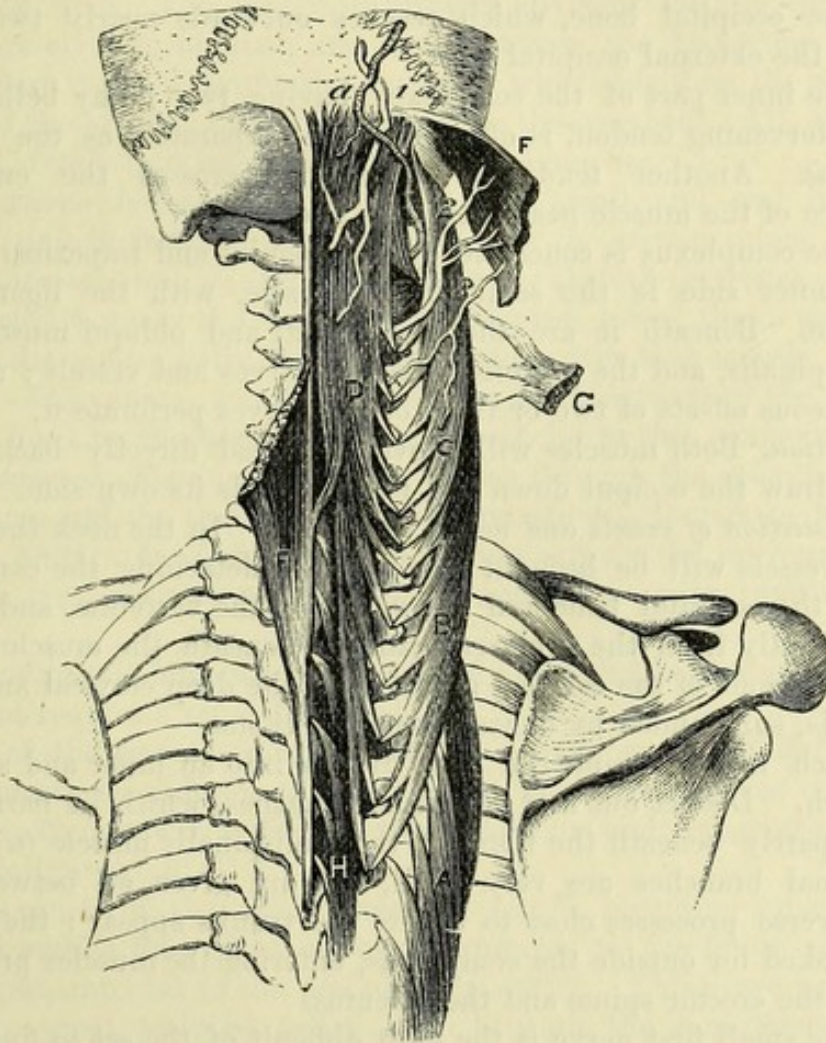
Relations of erector in lumbar and dorsal regions ; * *Relations of the erector spinæ.* The erector spinæ is concealed by the muscles of the layers already examined. It lies over the semi-spinalis and multifidus spinæ muscles, portions of the ribs and external intercostal muscles, and the levatores costarum. In the loins it is contained in an aponeurotic sheath of the fascia lumborum (p. 386) ; and in the thoracic region a similar sheath is formed for the muscle by the vertebral aponeurosis with the ribs and dorsal vertebræ. The tendon of origin is united over the sacrum with the posterior layer of the fascia lumborum ; and from its outer border in this part some fibres of the gluteus maximus arise.

and in neck. The prolongations of the muscle in the neck lie between the

splenius and levator anguli scapulæ on the outer side, and the complexus on the inner side, the trachelo-mastoid being next to the complexus. The cervicalis ascendens is attached to the transverse processes in a line with the splenius colli, and immediately behind the middle and posterior scalene muscles.

* *Action of erector spinæ.* These powerful muscles draw backwards or extend the spine, and come into play in bringing the column Use of both erectors,

Fig. 121.*



into, and in maintaining the erect position. The parts inserted into the dorsal vertebræ will be to some extent inspiratory muscles, since the dilatation of the thorax is aided by extension of the vertebral column; but the slips inserted into the ribs will draw downwards these bones, and may thus act in forced expiration. The muscle of one side acting alone will incline the spine laterally. The cervical prolongations have a similar action upon the neck and head.

of one muscle, and of portions in neck.

* Dissection of the muscles beneath the splenius. A. Longissimus dorsi. B. Transversalis colli. C. Trachelo-mastoid. D. Complexus. F. Splenius capitis, cut. G. Splenius colli, cut. H. Semispinalis dorsii. a. Occipital artery. 1. Great occipital nerve. 2. External branch of the second nerve. 3. Outer branch of the third nerve.

Complexus : The COMPLEXUS (fig. 121, D) is internal to the prolongations from the longissimus dorsi, and converges towards its fellow of the opposite side at the occipital bone. Narrow at its lower end, the
origin ; muscle *arises* by tendinous slips from the transverse processes of the upper six dorsal and seventh cervical vertebræ, and from the articular processes of the succeeding cervical vertebræ as high as the third : it is also joined in most cases by one or two slips from the
insertion ; lowest cervical or upper dorsal spines. The fleshy fibres pass upwards to be *inserted* into an impression between the curved lines of the occipital bone, which reaches outwards nearly two inches from the external occipital crest.

tendinous inter-sections ; The inner part of the complexus, having two fleshy bellies with an intervening tendon, is often described separately as the *biventer cervicis*. Another tendinous intersection crosses the cutaneous surface of the muscle near the upper end.

relations ; The complexus is concealed by the splenius and trapezius. Along the inner side is the semispinalis muscle, with the ligamentum nuchæ. Beneath it are the small recti and obliqui muscles, the semispinalis, and the posterior cervical nerves and vessels ; and the cutaneous offsets of two or three of the nerves perforate it.

use. *Action.* Both muscles will move the head directly back. One will draw the occiput down and back towards its own side.

Dissection of the nerves of the neck ; *Dissection of vessels and nerves* (fig. 122). In the neck the nerves and vessels will be brought into view by detaching the complexus from the occipital bone and the spines of the vertebræ, and raising it carefully from the subjacent parts. Beneath the muscle are the ramifications of the cervical nerves, and the deep cervical and other vessels, surrounded by dense connective tissue.

inner and Each nerve, except the first, divides into an inner and an outer branch. Dissect out first the inner branches, which lie partly over and partly beneath the fibres of the semispinalis muscle (G). The
outer branches ; external branches are very small, and are given off between the transverse processes close to where the trunks appear : they are to be looked for outside the complexus, entering the muscles prolonged from the erector spinæ and the splenius.

first nerve ; The small first nerve is the most difficult of the set to find : it is a short trunk, contained in the interval between the recti and obliqui muscles near the head, and will be best found by looking for the small twigs furnished by it to the muscles around.

and the vessels : The deep cervical artery is met with on the semispinalis muscle ; a part of the vertebral artery will be found in contact with the first nerve ; and the occipital artery will be visible crossing the occipital bone.

nerves and vessels in the dorsal region * Opposite the thorax the dorsal nerves and vessels will be readily displayed on the inner side of the longissimus dorsi muscle, on the removal of a little fatty tissue from between the transverse processes. External and internal branches are to be traced from each nerve and vessel into the muscles : some of the former have been seen in the interval between the ilio-costalis and the longissimus dorsi.

* The two branches of the lumbar nerves and vessels are in the same line as the dorsal ; but the inner set are difficult to find. in the lumbar region.

* The sacral nerves are placed beneath the multifidus spinæ, and will be dissected after the examination of that muscle (p. 401).

* POSTERIOR PRIMARY BRANCHES OF THE SPINAL NERVES. The spinal nerves, with a few exceptions in the cervical and sacral groups, divide in the intervertebral foramina into their anterior and posterior primary branches. The posterior supply the integuments and the muscles of the back, and are now to be learnt. Posterior branches of spinal nerves.

IN THE NECK. The posterior primary divisions of the cervical nerves are eight in number, and issue between the transverse processes ; but those of the first and second, which begin on the neural arches of the atlas and axis, appear above those arches. All, except the first, divide into internal and external branches. In the neck they divide into two except first.

The *external branches* (fig. 121) are very small, and end in the splenius, and in the muscles prolonged from the erector spinæ. External branches are small.

The *internal branches* (fig. 122) are larger than the external ; they are directed towards the spinous processes, the lower three passing beneath the semispinalis, and the upper four over that muscle. By the side of the spines cutaneous branches are furnished to the neck and the head by the nerves that are superficial to the semispinalis : these *cutaneous offsets* ascend to the surface through the splenius, the complexus, and the trapezius muscles, and are distributed as before seen (p. 382). In their course the nerves supply the surrounding muscles, viz., complexus, semispinalis, multifidus spinæ, and interspinales. Internal branches : some give cutaneous offsets.

The cutaneous branches of the second and third nerves reach the head, and require a separate notice.

That of the *second nerve* (fig. 122,²), named *great occipital*, appears beneath the inferior oblique muscle, to which it gives offsets, and is directed upwards through the complexus and trapezius to end on the occiput (p. 8). Second ascends to head.

The branch of the *third nerve* (fig. 122,³), becoming superficial near the middle line, gives an offset upwards to the lower part of the occiput, internal to the preceding (p. 382). This nerve usually joins the great occipital twice, viz., beneath the complexus and superficial to the trapezius. Third supplies neck and head.

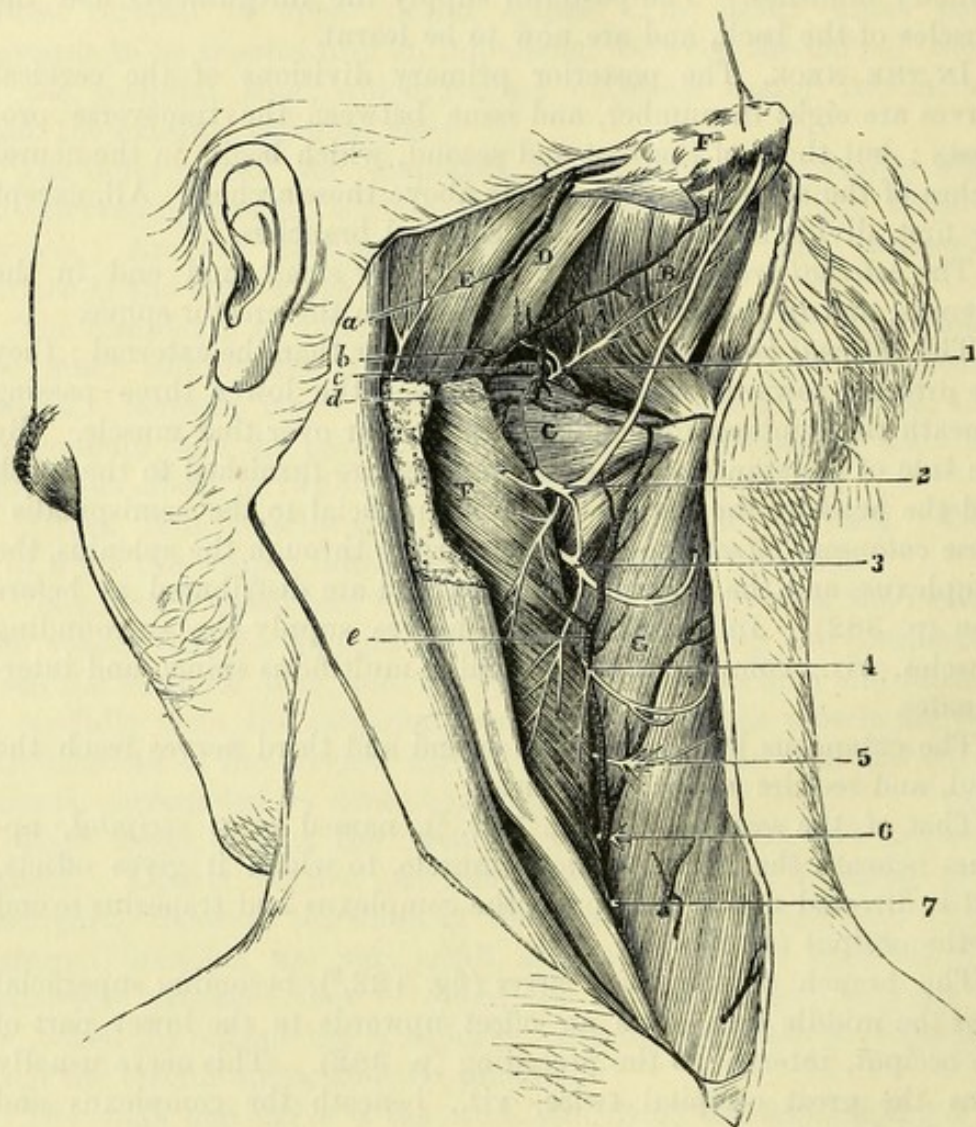
The *posterior primary division of the suboccipital or first spinal nerve* (fig. 122,¹) is very short, and appears in the interval between the recti and obliqui muscles. In passing from the spinal canal it is placed between the arch of the atlas and the vertebral artery. From its extremity branches radiate to the surrounding muscles, viz., one to the upper part of the complexus, another to the rectus posticus major and minor, and two short branches to the obliquus superior and inferior : the offset to the last muscle joins the inner branch of the second cervical nerve. Occasionally the first nerve gives a cutaneous branch to the occiput. First nerve ends in muscles.

* IN THE DORSAL REGION. The posterior primary divisions of the dorsal nerves, twelve in number, appear between the transverse processes, and bifurcate into internal and external branches. Dorsal nerves.

Outer
branches to
erector
spinæ :

* The *external branches* increase in size from above downwards, and pass beneath the longissimus dorsi to the interval between that muscle and the ilio-costalis, distributing offsets to the several divisions of the erector spinæ. The branches of the *upper six or seven* nerves end in these muscles ; but the *lower five or six*, after

Fig. 122.*



lower ones
become
cutaneous.

reaching the interval between the longissimus and ilio-costalis, are continued to the surface through the serratus and latissimus muscles, nearly in a line with the angles of the ribs.

Inner
branches to
transverso-
spinales :

* The *internal branches* are larger above than below, and supply the transverso-spinales muscles. The *upper six or seven* are directed inwards between the semispinalis and multifidus spinæ, and become

* Deep dissection of the back of the neck. (Illustrations of Dissections.)
Muscles : A. Rectus posticus major. B. Rectus posticus minor. c. Obliquus inferior. D. Obliquus superior. E. Sterno-mastoid. F. Complexus, cut across. G. Semispinalis colli. *Arteries* : a. Occipital, and b. Its cervical branch. c. Vertebral artery, and d. Its cervical branch. e. Deep cervical. *Nerves* : 1. Posterior branch of the suboccipital. 2 to 7. Inner branches of the posterior primary divisions of the respective cervical nerves.

cutaneous by the side of the spinous processes, after perforating the splenius, serratus superior, rhomboideus, and trapezius muscles. The *lower five or six* are much smaller, and end in the multifidus spinæ. upper ones reach surface.

* IN THE LOINS. The posterior primary branches of the lumbar nerves, five in number, appear between the erector and multifidus spinæ. In their mode of dividing and general arrangement they resemble the lower dorsal nerves, cutaneous offsets being furnished by the external set of branches. Lumbar nerves are divided into two.

* The *external branches* pass to the erector spinæ, and supply it and the intertransverse muscles. The first three pierce the erector spinæ, and become cutaneous after perforating the posterior layer of the fascia lumborum. The branch of the last nerve is connected with the corresponding part of the first sacral nerve by an offset near the bones. External branches : first three become cutaneous.

* The *internal branches* are furnished to the multifidus spinæ muscle. They are difficult to find, being contained in grooves on the upper articular processes. Internal branches.

* VESSELS IN THE BACK. The vessels now dissected are the occipital and the deep cervical arteries, a small part of the vertebral, and the posterior branches of the intercostal and lumbar arteries of the aorta. Veins accompany the arteries. Vessels.

The OCCIPITAL ARTERY (fig. 122, *a*) courses along the occipital bone. Appearing from beneath the digastric muscle, the vessel is directed backwards under the sterno-mastoid, the splenius, and usually the trachelo-mastoid, but over the obliquus superior and complexus muscles. Behind the insertion of the sterno-mastoid it becomes superficial, and ascends to the occiput, where it is distributed (p. 6). It supplies the surrounding muscles, and gives the following branch to the neck :— Part of the occipital artery. which gives a

The *cervical branch* (*b*) distributes twigs to the splenius and trapezius, and passing beneath the complexus, anastomoses with the vertebral and deep cervical arteries. cervical branch.

The VERTEBRAL ARTERY (fig. 122, *c*) lies on the neural arch of the atlas, behind the articulating process, and appears in the interval between the straight and oblique muscles. Beneath it is the suboccipital nerve. Small branches are given to the surrounding muscles, and to anastomose with the contiguous arteries. Part of the vertebral artery.

The DEEP CERVICAL ARTERY (fig. 122, *e*) is a branch of the superior intercostal of the subclavian (p. 71). Passing back between the transverse process of the last cervical vertebra and the neck of the first rib, it ascends between the complexus and semispinalis muscles, as high as the upper border of the latter, and anastomoses with the cervical branch of the occipital artery. The contiguous muscles receive branches from it, and anastomoses are formed between its offsets and those of the vertebral. Deep cervical artery.

* The POSTERIOR BRANCHES OF THE INTERCOSTAL ARTERIES (p. 364) pass back between the vertebræ and the ascending costo-transverse ligament, and divide like the nerves into inner and outer pieces. Dorsal arteries are split into

* The *internal branches* end in the fleshy mass of the multifidus inner and

spinæ and semispinalis, and furnish small cutaneous offsets with the nerves.

outer branches, * The *external branches* cross beneath the longissimus dorsi, and supply it and the ilio-costalis. Like the nerves, the lowest branches of this set are the largest and extend to the surface.

and give a spinal branch. As the dorsal branch of the intercostal artery passes by the intervertebral foramen, it furnishes a small *intraspinal artery* to the spinal canal (p. 414).

Lumbar arteries * The POSTERIOR BRANCHES OF THE LUMBAR ARTERIES divide, like the foregoing, into internal and external pieces, as soon as they reach the interval between the erector and multifidus spinæ. Each gives also a *spinal branch* to the spinal canal.

are also divided into inner and * The *internal branches* are small, and end in the multifidus spinæ.

outer branches. * The *external branches* supply the erector spinæ ; and offsets are continued to the integuments with the superficial nerves.

Occipital veins. VEINS. The *occipital veins* communicate usually with the lateral sinus of the skull through the mastoid foramen, and pass beneath the complexus to enter the deep cervical vein.

Deep cervical vein, and plexus of back of neck. The *deep cervical vein* is of large size, and besides receiving the occipital veins, communicates with the other deep veins of this region, forming the posterior plexus of the neck. It passes forwards with its artery between the transverse processes, and joins the vertebral vein.

Beginning of vertebral vein. The *vertebral vein* begins above the neural arch of the atlas by the union of an offset leaving the spinal canal with the artery and branches from the above-mentioned plexus.

Dorsal and lumbar, * The *dorsal and lumbar veins* agree in their branching and distribution with the arteries they accompany, and end in the corresponding trunks of the thoracic and abdominal wall.

and deep veins. In contact with the spinous processes and laminæ of the vertebræ is a deeper set of veins (*dorsal spinal*), which anastomose freely together, and communicate through the ligamenta subflava with the veins in the interior of the spinal canal.

Muscles of the fifth layer. * FIFTH LAYER OF MUSCLES. In this layer are included the small recti and obliqui of the head, the transverso-spinales, the inter-spinales, and the intertransversales.

Dissection of the last layer of muscles. *Dissection.* Most of the remaining muscles of the back have been uncovered by the previous dissections. Between the first two vertebræ and the occipital bone are the straight and oblique muscles.

* Between the erector spinæ and the spines of the vertebræ are the transverso-spinales, and internal to these the small interspinales. The intertransverse muscles of the lumbar region will be exposed by removing the erector spinæ.

Rectus posticus major : The RECTUS CAPITIS POSTICUS MAJOR (fig. 122, A) arises from the side of the spinous process of the axis, and is inserted into the outer part of the inferior curved line of the occipital bone for about an inch, as well as into the surface below it.

attach-
ments ;
relations ; The muscle is covered by the complexus, and at its insertion by

the obliquus superior. It lies over the posterior arch of the atlas and the ligaments attached to that part of the bone.

Action. By the action of both muscles the head will be drawn backwards. One rectus acting alone will rotate, as well as extend the head, turning the face to the same side.

The RECTUS CAPITIS POSTICUS MINOR (fig. 122, B) is a small fan-shaped muscle, lying to the inner side of the preceding. *Arising* close to the middle line from a slight roughness on the posterior arch of the atlas, it is *inserted* into the inner third of the inferior curved line of the occipital bone, and an impression below this.

This muscle is deeper than the rectus major: it lies over the posterior occipito-atlantal ligament. The two small recti correspond to the interspinal muscles between the other vertebræ.

Action. The rectus posticus minor extends the head.

The OBLIQUUS CAPITIS INFERIOR (fig. 122, C) is the strongest of the suboccipital muscles. It *arises* from the spinous process of the axis below the rectus posticus major, and is *inserted* into the lower and back part of the transverse process of the atlas.

The inferior oblique is concealed by the complexus and trachelo-mastoid muscles, and is crossed by the great occipital nerve.

Action. This muscle turns the face to the same side, by rotating the atlas on the axis.

The OBLIQUUS CAPITIS SUPERIOR (fig. 122, D) *arises* from the transverse process of the atlas above the insertion of the preceding muscle, and is directed upwards and inwards to be *inserted* into the outer part of the space between the curved lines of the occipital bone.

The origin of the muscle is beneath the trachelo-mastoid, and its insertion beneath the complexus. In the interval between these it is covered by the splenius. It lies over the vertebral artery and the insertion of the rectus posticus major.

Action. With its fellow the upper oblique will assist in carrying backwards the head. By the action of one muscle the head will be inclined backwards, and to the same side.

Suboccipital triangle (fig. 122). This name is given to the small space which is bounded below by the obliquus inferior muscle, and above by the rectus posticus major on the inner side, and the obliquus superior on the outer side. It is covered by the complexus; and its floor is formed by the neural arch of the atlas, with the posterior occipito-atlantal ligament. In it are seen a small part of the vertebral artery, and the posterior branch of the suboccipital nerve.

* TRANSVERSO-SPINALES. Occupying the vertebral groove by the side of the spinous processes is a long muscular mass, which extends from the lower part of the sacrum to the axis. This is composed of slips which are directed obliquely from transverse or articular processes to spinous processes, and are therefore designated collectively transverso-spinales. The slips differ in length, and form three layers, which are described as separate muscles, viz., a superficial stratum of long slips, confined to the cervical and dorsal regions—

the semispinalis ; a middle portion, with slips of intermediate length—the multifidus spinæ ; and a deep set of very short fasciculi, present only in the thoracic region—the rotatores dorsi.

Semispinalis
is divided
into

* The SEMISPINALIS consists of slips which pass over four or five vertebræ, and is subdivided into the following two parts, but the separation between them is not always distinct.

semispinalis
dorsi

* The *semispinalis dorsi* is thinner than the upper part : it *arises* from the transverse processes of the dorsal vertebræ from the sixth to the tenth, and is *inserted* into the spines of last two cervical and upper four dorsal vertebræ.

and semispi-
nalis colli.

The *semispinalis colli* (fig. 122, G) *arises* from the transverse processes of the upper six dorsal vertebræ, and is *inserted* into the spines of the cervical vertebræ above the last, the atlas not receiving any slip.

Dissection
of multifi-
dus spinæ.

Dissection. The upper part of the multifidus spinæ is to be prepared by the dissector of the head and neck. It will be exposed by cutting through the insertion of the semispinalis, and turning aside that muscle.

* Over the sacrum the thick aponeurosis of the erector spinæ must be removed. In the dorsal region the multifidus spinæ will appear on detaching and reflecting the semispinalis from the spines. The slips by which the muscle is attached to the processes of the vertebræ should be defined and separated.

Origin of
multifidus
spinæ

from pelvis,

from lumbar,
dorsal, and

cervical
vertebræ.

Insertion
into spines.

Dissection.

Rotatores
dorsi :

attach-
ments.

Relations of
transverso-
spinales ;

and use.

* The MULTIFIDUS SPINÆ reaches from the sacrum to the axis : it is larger below than above, and is smallest in the upper dorsal region. It takes *origin* at the pelvis from the back of the sacrum between the spines and the external row of processes as low as the fourth aperture, from the posterior sacro-iliac ligament, from the inner side of the posterior superior spine of the ilium, and from the overlying tendon of the erector spinæ ; in the loins it arises by large fasciculi from the mamillary processes of the vertebræ ; in the dorsal region by thinner slips from the transverse processes ; and in the neck from the articular processes of the lower four cervical vertebræ. From these attachments the fibres are directed obliquely upwards and inwards, passing over from one to three vertebræ, to be *inserted* into the spinous processes from the axis to the last lumbar vertebra.

* *Dissection.* To see the rotatores dorsi the slips of the multifidus should be detached from the dorsal spines and turned downwards.

* The ROTATORES DORSI are eleven short muscular slips in the dorsal region beneath the multifidus spinæ, from which they are separated by fine areolar tissue. Each *arises* from the upper and back part of a transverse process, and is *inserted* into the lower border of the neural arch of the vertebra next above. The first springs from the transverse process of the second vertebra.

* The transverso-spinales are entirely concealed by the erector spinæ and complexus muscles ; and beneath them are the laminæ of the vertebræ, with the dorsal spinal plexus of veins. Internally they rest against the spinous processes and the interspinal muscles.

* *Action.* The transverso-spinales of the two sides acting together

will extend the spine; and the muscles of one side can rotate the column in the cervical and dorsal regions, turning the face in the opposite direction.

* *Dissection.* The multifidus spinæ is now to be separated from the cervical and lumbar spines to show the interspinal muscles.

* The INTERSPINALES are arranged in pairs in the intervals between the spinous processes. They are most developed in the neck and loins. Interspinal muscles:

In the *cervical region* the muscles are small rounded bundles attached to the bifurcated extremities of the spines from the axis downwards.

* In the *dorsal region* interspinal muscles are only present in one or two of the highest and lowest spaces. in dorsal region;

* In the *lumbar region* they are thin flat muscles, reaching the whole length of the spines, one on each side of the interspinous ligament. in loins;

Action. These muscles help to extend the spine.

their use.

* The INTERTRANSVERSALES lie between the transverse process of the vertebræ; but only those in the loins and the back are now dissected. Inter-transverse muscles:

In the *neck* they are double, and resemble the interspinal muscles of the cervical vertebræ (p. 171). in neck;

* In the *dorsal region* they are single rounded bundles of small size, and are found only between the four or five lower vertebræ. They are represented in the middle spaces by thin fibrous bands, which constitute the so-called intertransverse ligaments (p. 379). in dorsal region;

* In the *lumbar region* there are two muscles in each space. The outer set are thin flat muscles between the transverse processes. The inner muscles are rounded bundles in a line with those of the dorsal region; they are attached to the accessory processes above, and the mamillary processes below; and the highest is between the last dorsal and first lumbar vertebræ. in loins;

Action. The intertransverse muscles assist in bending the spine laterally. their use.

* *Dissection* (fig. 123). To see the posterior divisions of the sacral nerves, it will be necessary to remove the part of the multifidus spinæ covering the sacrum. The upper three nerves are split into two each; their external branches will be found readily on the great sacro-sciatic ligament, from which they may be traced inwards; the inner branches are very slender and difficult to find. Dissection of sacral nerves.

The lower two nerves are very small, and do not divide like the others. They are to be sought on the back of the sacrum, below the attachment of the multifidus spinæ. The fourth comes through a sacral aperture, and the fifth between the sacrum and coccyx. The coccygeal nerve is still lower, by the side of the coccyx.

* SACRAL NERVES (fig. 123). The posterior primary branches of the sacral nerves are five in number. Four issue from the spinal canal by the apertures in the back of the sacrum, and the fifth between the sacrum and the coccyx. The first three have the Five sacral nerves.

common branching into inner and outer pieces, like the other spinal nerves ; but the last two are undivided.

First three have

The *first three nerves* are covered by the multifidus spinæ, and divide regularly.

inner and

The *inner pieces* (1) are distributed to the multifidus ; and the last of this set is very fine.

outer branches ;

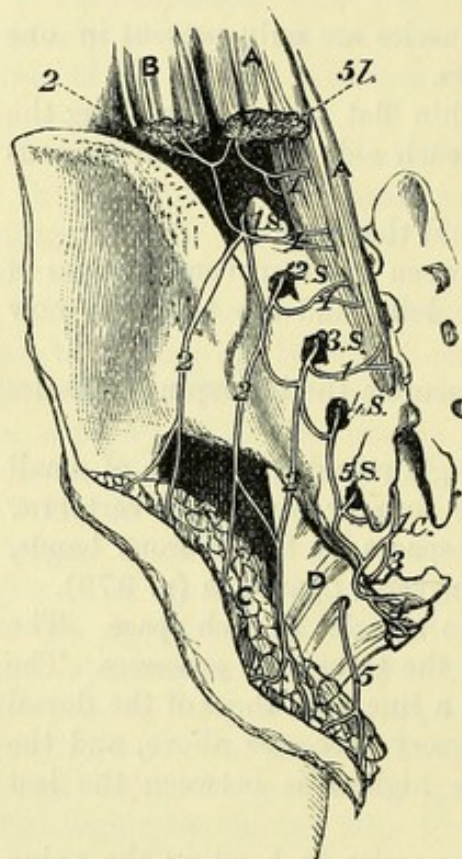
The *outer pieces* (2) are larger, and have communicating offsets from one to another on the back of the sacrum ; the branch of the

first nerve is also connected with the corresponding part of the last lumbar ; and the branch of the third joins in a similar way the sacral nerve next below. After this looping they pass outwards to the surface of the great sacro-sciatic ligament, where they join a second time, and become cutaneous. (DISSECTION OF THE BUTTOCK.)

Fig. 123.*

latter give cutaneous offsets.

Last two are undivided.



Coccygeal nerve.

* *Last two nerves* (4 s and 5 s).

These nerves, which are below the multifidus, are much smaller than the preceding, and want the regular branching of the others : they are connected with each other and the coccygeal nerve by loops on the back of the sacrum. A few filaments are distributed to the back of the sacrum and the coccyx.

Coccygeal nerve (1 c). Its posterior primary branch issues through the lower aperture of the spinal canal, and appears

by the side of the coccyx. It is joined by a loop from the last sacral nerve, and ends on the posterior surface of the coccyx.

Small sacral arteries.

* **SACRAL ARTERIES.** Small branches of the lateral sacral arteries leave the spinal canal with the sacral nerves ; they supply the multifidus spinæ, and anastomose on the back of the sacrum with offsets from the gluteal and sciatic arteries.

Dissection of costal muscles.

* *Dissection.* The posterior part of the wall of the thorax may be examined before the body is again turned. By removing, opposite

* Dissection of the sacral nerves (Lond. Med. Gazette, 1843). *Muscles* : A. Multifidus spinæ, and B. Erector spinæ : both cut. C. Gluteus maximus detached from its origin, and thrown down. D. Great sacro-sciatic ligament. *Nerves* : 5 l. Last lumbar. 1 s to 5 s. The five sacral nerves issuing from the sacrum. 1 c. The coccygeal nerve escaping by the opening of the sacral canal. 1. Internal offsets of the last lumbar and first three sacral (these are represented too large). 2. External offsets of the same nerves. 3. Anterior, and 4. Posterior primary branch of the coccygeal nerve. 5. The perforating cutaneous nerve derived from the sacral plexus.

the ribs, the ilio-costalis and longissimus dorsi, the small levatores costarum will be uncovered. The hinder part of the external intercostal muscles will be denuded at the same time.

* The LEVATORES COSTARUM are twelve small fan-shaped muscles, Levatores costarum: which are connected with the hinder parts of the ribs. Each, except the first, *arises* from the tip of the transverse process of a dorsal vertebra, and is *inserted*, the fibres spreading out, into the upper border of the rib beneath, from the tuberosity to the angle. The muscles increase in size from above down, and their fibres have the same direction as the external intercostal layer. attach-ments.

The first is fixed above to the transverse process of the last cervical vertebra, and below to the outer border of the first rib. Some of the fibres of the lower muscles are continued beyond one rib to that next succeeding: these longer slips have been named *levatores longiores costarum*. The first. Longer elevator muscles.

Action. These muscles have but little influence in elevating the ribs; and their principal use appears to be in extending and bending laterally the spine. Use.

* The EXTERNAL INTERCOSTAL MUSCLE is continued backwards along the ribs as far as the tuberosity, where it joins the elevator muscle. Beneath the muscle are the intercostal nerve and artery. Outer intercostal muscle.

Dissection. To trace the anterior and posterior primary branches of the dorsal nerves to their common trunk, the elevator of the rib and the external intercostal muscle are to be cut through in one or more spaces. The intercostal artery with its posterior branch is laid bare by this proceeding. Dissection.

* The DORSAL NERVES split in the intervertebral foramina into anterior and posterior primary branches. Dorsal nerve has

* The *posterior branches* are directed backwards, internal to the ascending costo-transverse ligament; and their distribution has been seen in the foregoing dissection. posterior

The *anterior*, named *intercostal*, are continued between the ribs to the front of the chest: their anatomy is learnt in the dissection of the thorax (p. 370) and upper limb (p. 260). and anterior branches.

* The INTERCOSTAL ARTERY has an almost exact correspondence with the dorsal nerve in its branching and distribution (p. 364). Intercostal artery.

CHAPTER VI.

THE SPINAL CORD AND ITS MEMBRANES.

Cord is contained in spinal canal, invested by membranes.

THE spinal cord (*medulla spinalis*) gives origin to the spinal nerves, and is lodged in the canal bounded by the bodies and neural arches of the vertebræ. It is invested by prolongations of the membranes of the brain, which form sheaths around and support it.

Dissection to show the cord

Dissection. After all the muscles have been taken from the arches and spines of the vertebræ, the spinal canal is to be opened by sawing through the laminae on each side, close to the articular processes; and the cuts of the saw should extend to the lower end of the sacrum, but not higher in the neck than the fourth cervical vertebra. As it is difficult to use the saw in the hollow of the lumbar region, a chisel and a mallet will be found useful to complete the division of the neural arches.

and the membranes.

The tube of the *dura mater* is covered by some veins and fat, and by a loose areolar tissue containing fluid sometimes, especially at the lower part. The fat may be scraped away with the handle of the scalpel; and the lateral prolongations of the membrane through the intervertebral foramina are to be defined.

Spinal meninges are three in number.

MEMBRANES OF THE CORD (fig. 125). Three membranes, like those on the brain, surround the cord, viz., an external tube of *dura mater*, an internal covering of *pia mater*, and an intermediate sheath of *arachnoid*.

Dura mater surrounds cord loosely; lower ending; size of sheath;

The **DURA MATER** (*a*) is the strongest tube, and is continuous with the membrane lining the interior of the skull. It forms a loose sheath (*theca*) along the spinal canal as far as the last lumbar vertebra; and then tapering gradually it ends opposite the third piece of the sacrum in a slender impervious cord which is continued to the back of the coccyx (fig. 124, *b*). The capacity of the sheath greatly exceeds the dimensions of the cord; and it is larger in the neck and loins than in the dorsal region.

connections;

On the outer aspect the spinal *dura mater* is smooth, in comparison with that in the skull, for it does not act as a periosteum to the bones. Between it and the wall of the canal are some vessels and fat; and it is connected to the posterior common ligament of the vertebræ by a few fibrous bands.

offsets on nerves;

On each side the *dura mater* sends offsets along the spinal nerves in the intervertebral foramina; and these offsets become gradually longer below (fig. 124), where they form tubes which enclose the sacral nerves,

and lie for some distance within the spinal canal. In the centre, between the lowest offsets on the nerves, is the slender fibrous cord (b), which blends with the periosteum covering the back of the coccyx.

Dissection. To remove the spinal cord with the sheath of the dura mater from the body, the lateral processes in the intervertebral cord,

Dissection
to remove
cord,

Fig. 124.*

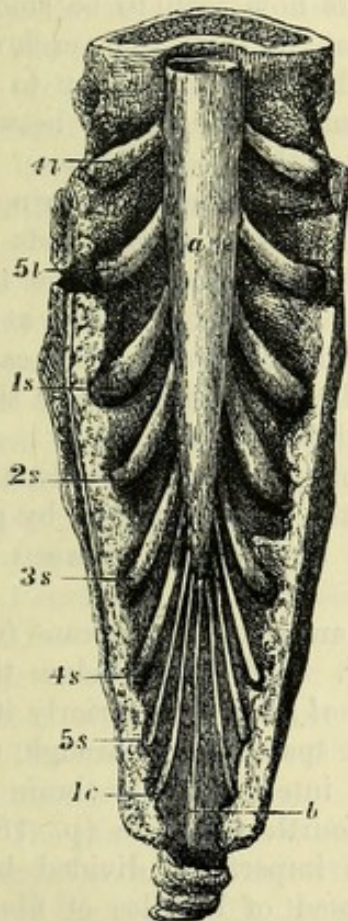
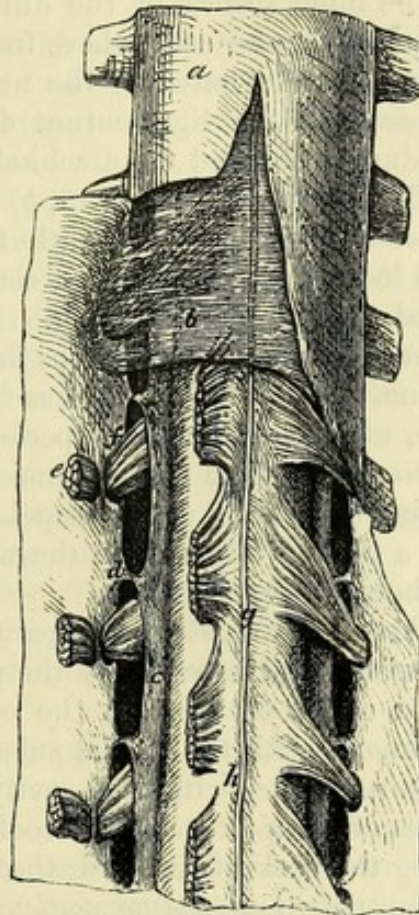


Fig. 125.†



foramina, with the contained nerves, are to be cut ; and one or two of them in the dorsal region should be followed outwards beyond the apertures by cutting away the surrounding bone. The central prolongation may be now detached from the coccyx ; and the cord and its membranes are to be divided opposite the fourth cervical

* Lower end of the dura mater with its central and lateral processes. (Museum of University College, London.) *a*. Sheath of the dura mater. *b*. Central fibrous band fixing it to the coccyx. The lateral offsets encasing the last two lumbar, the five sacral, and the coccygeal nerves are also shown. Each nerve is marked by the numeral, and the first letter of its name.

† Membranes of the spinal cord. *a*. Dura mater cut open and reflected. *b*. Small part of the translucent arachnoid. *h*. Pia mater, closely investing the spinal cord. *c*. Ligamentum denticulatum on the side of the cord, shown by cutting through the anterior roots of the nerves. *d*. Processes joining it to the dura mater. *e*. Anterior roots of the nerves, cut ; and *f*, posterior roots, each entering a separate hole in the dura mater. *g*. Linea splendens.

vertebra, and to be removed by cutting the bands that attach the dura mater to the posterior common ligament.

and see next
covering.

When the cord is taken out, place the anterior surface uppermost, with the lateral offsets widely separated. To show the arachnoid covering, the dura mater is to be slit along the middle as far as the small terminal fibrous cord before referred to; but the membrane is to be raised while it is being cut through, so that the loose arachnoid on the cord may not be injured. Lastly fasten back the dura mater with pins.

Deep surface
of dura
mater.

The inner surface of the dura mater is now seen to be smooth and shining, and everywhere free except at the spots along each side where it is perforated by the nerves, and gives attachment to the processes of the ligamentum denticulatum. The cavity between the dura mater and the arachnoid is named the *subdural space*.

Subdural
space.

Arachnoid
membrane
is loose,
and leaves
a space
beneath.

The ARACHNOID (fig. 125, *b*) is the thin translucent covering of the cord immediately beneath the dura mater. It surrounds the cord loosely, so as to leave a considerable interval between the two, called the *subarachnoid space*. The loose sheath is largest at its lower part, where it envelops the mass of nerves forming the cauda equina. Around the roots of each nerve the arachnoid forms a short tube, which is lost as they perforate the dura mater.

To show
subarach-
noid space.

Dissection. The subarachnoid space may be made evident by placing the handle of the scapel beneath the membrane, or by putting a piece of the cord in the water and blowing air between the arachnoid and pia mater.

Subarach-
noid space

contains a
fluid, and

opens into
ventricles of
brain;

an imperfect
septum
behind.

The *subarachnoid space* separates the arachnoid membrane from the spinal cord invested by the pia mater. It is larger below than above, and is occupied by the *cerebro-spinal fluid*. Superiorly it is continuous with the cranial subarachnoid space; and through this it communicates with the cavity in the interior of the brain by means of an aperture in the roof of the fourth ventricle (p. 181). Along the back of the cord the space is imperfectly divided by a median partition (*septum posticum*) composed of bundles of fibrous tissue, which is most developed in the neck. Similar fine trabeculae pass between the posterior nerve-roots and the arachnoid. The subarachnoid space also contains the serrations of the ligamentum denticulatum, and the roots of the spinal nerves, with some vessels.

Dissection
of third
covering.

Dissection. In order to see the next covering of the cord, with the ligamentum denticulatum, the arachnoid membrane is to be taken away; and two or three of the anterior roots of the upper dorsal nerves may be cut through and reflected, as in fig. 125.

Pia mater

supports
the cord,
gives offsets.

The PIA MATER (fig. 125, *h*) is much less vascular on the spinal cord than on the brain. Thicker and more fibrous in its nature, the membrane closely surrounds the cord with a sheath, and sends a thin fold into the anterior median fissure: it furnishes coverings to the roots of the spinal nerves.

Fibrous
bands.

The outer surface of the pia mater is rough. Along the front is a median fibrous band (*linea splendens*, Haller; fig. 125, *g*); and on each side another fibrous band, the ligamentum denticulatum, is

attached to it. In the cervical region the membrane has usually a rather dark colour, due to the presence of pigment-cells in it.

Where the spinal cord ceases, viz., about the lower edge of the body of the first lumbar vertebra, the sheath of the pia mater contracts, and gives rise to a slender thread-like prolongation, the *filum terminale* or *central ligament of the cord* (fig. 127, *d*). This contains a little nervous substance in its upper part; and below, it blends with the central impervious process of the dura mater. A vein and artery accompany the *filum terminale*, and distinguish it from the surrounding nerves.

It ends below in a small fibrous cord, the *filum terminale*.

The *ligamentum denticulatum* (fig. 125, *c*) is a white, fibrous band on each side of the spinal cord, and has received its name from its serrated appearance. It serves to support the cord, which is fixed by it to the sheath of the dura mater.

The dentate ligament

Situate between the anterior and posterior roots of the nerves, the band reaches upwards to the beginning of the medulla oblongata, and ends below on the pointed extremity of the cord. Internally it is united to the pia mater. Externally it ends in a series of triangular or tooth-like projections (*d*), which are fixed at intervals into the dura mater, each being about midway between the apertures of the roots of the spinal nerves. There are twenty or twenty-one denticulations, of which the first is attached to the dura mater opposite the margin of the occipital foramen, and the last, opposite the twelfth dorsal or the first lumbar vertebra.

is fixed on one side to cord,

and on other to dura mater: number and attachment of points.

Vessels and nerves of the membranes. The spinal *dura mater* has but few vessels in comparison with that in the skull, its office being different. Filaments of the sympathetic and spinal nerves are furnished to the membrane.

Vessels and nerves of dura mater;

The *arachnoid* has no vessels; and proof of its containing nerves in man is yet wanting.

of arachnoid;

The *pia mater* has a network of vessels in its substance, though this is less marked here than on the brain; and from them offsets enter the cord. In the membrane are many nerves derived from the sympathetic and the posterior roots of the spinal nerves.

of pia mater.

Dissection. The arachnoid membrane is to be taken away on one side; and the nerve-roots are to be traced outwards to their transmission through apertures in the dura mater.

Dissection of roots of nerves,

One of the offsets of the dura mater, which has been cut of some length, is to be laid open to expose the contained ganglion. The student should define the ganglion, showing its bifid condition at the inner end (fig. 126 *B*), and should trace a bundle of threads of the posterior root into each point. The anterior root, consisting also of two bundles of threads, is to be followed over the ganglion to its union with the posterior root beyond the ganglion.

and the ganglion.

SPINAL NERVES. There are thirty-one pairs of spinal nerves; and each nerve is constructed by the blending of two roots (anterior and posterior) in the intervertebral foramen (fig. 126).

Trunks of spinal nerves.

They are divided into groups corresponding with the regional subdivisions of the spinal column, viz., cervical, dorsal, lumbar, sacral, and coccygeal. In each group the nerves are the same in

Number and groups.

number as the vertebrae, except in the cervical region of the spine where they are eight, and in the coccygeal region where there is only one. The cervical nerves from the first to the seventh pass out above the

several vertebrae; and the eighth is below the last cervical vertebra; the succeeding nerves are placed each below its corresponding vertebra.

Each nerve divides into two primary branches, anterior and posterior; the former of these is distributed to the front of the body and the limbs; and the latter is confined to the hinder part of the trunk.

ROOTS OF THE NERVES (fig. 126). Two roots (anterior and posterior) attach the nerve to the spinal cord; and these unite together to form a common trunk in the intervertebral foramen. The posterior root is marked by a ganglion, but the anterior root is aganglionic.

The *posterior* or *ganglionic roots* (fig. 126, *b*) are larger than the anterior, and are formed by thicker and more numerous fibrils.

They are attached to the side of the cord between the posterior and lateral columns in a straight line, which they keep even to the last nerve.

In their course to the trunk of the nerve the fibrils converge to an aperture in the dura mater, opposite the intervertebral foramen; as they approach that aperture they are collected into two bundles (fig. 126 B, *b*) which, lying side by side, receive a sheath from the dura mater, and enter the two points of the intervertebral ganglion.

The *intervertebral ganglion* (fig. 126, *c*) is reddish in colour, and oval in shape; and its size is proportioned to that of the root. By means of the previous dissection, the ganglion may be seen to be bifid at the inner end (fig. 126 B), where it is joined by the bundles of filaments of the root (*b*); or the root might be said to possess two

Relation
of nerves
to vertebrae.

Fig. 126.*

Primary
divisions.

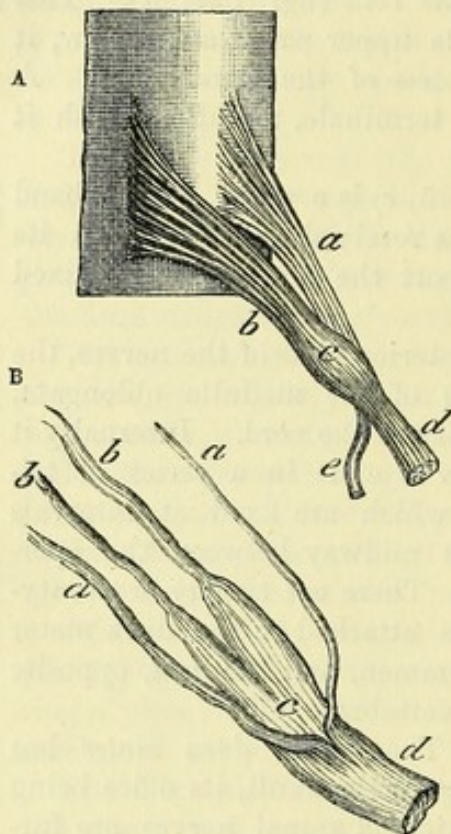
Roots,
anterior and
posterior.

Posterior
larger than
anterior,

forms two
bundles

that enter
the ganglion.

Ganglia
form,
and size;
each is
bifid.



* A. Plan of the origin of a spinal nerve from the spinal cord. *a*. Anterior root. *b*. Posterior root. *c*. Ganglion on the posterior root. *d*. Anterior primary branch. *e*. Posterior primary branch of the nerve-trunk.

B. A drawing to shew the arrangement of the nerve-roots, and the form of the ganglion in a lumbar nerve. *b, b*. Posterior root gathered into two bundles of threads. *c*. The ganglion, bifid at the inner end. *a, a*. Filaments of the anterior root, also gathered into two bundles.

small ganglia, one for each bundle of filaments, which are blended at their outer ends.

Sometimes the first or suboccipital nerve is without a ganglion.

The *anterior* or *aganglionic roots* (fig. 126 A, a) arise from the side of the spinal cord by filaments which are attached irregularly—not in a straight line, and approach near the middle fissure at the lower end of the cord.

Anterior root is without ganglion,

Taking the same direction as the posterior root to the intervertebral foramen, the fibrils enter a distinct opening in, and have a separate sheath of, the dura mater. In their farther course to the trunk of the nerve they are gathered into two bundles (fig. 126 B, a), and pass over the ganglion without joining it. Finally, the anterior root blends with the posterior beyond the ganglion, to form the trunk.

pierces dura mater and joins posterior root beyond ganglion.

Characters of the roots. Besides variations in the relative size of the two roots, the following characters are to be noted:—

Characters of roots.

Union of the fibrils. The fibrils of contiguous anterior roots may be intermingled, and the fibrils of the neighbouring posterior roots may be connected in a like manner; but the anterior is never mixed with the posterior root.

Some sets of fibrils join.

Size of the roots to each other. The posterior root is larger than the anterior, except in the suboccipital nerve; and the number of the filaments is also greater. Farther, the posterior is proportionally larger in the cervical than in any other group; in the dorsal nerves there is but a very slight difference in favour of the hinder root.

Posterior root larger, proportionally largest in neck.

Size of both roots along the cord. Both roots are larger where the nerves for the limbs arise than at any other part of the cord; and they are largest in the nerves to the lower limbs. They are smallest at the lower extremity of the cord.

Roots are largest for nerves of limbs.

Direction and length of the roots. As the apertures of transmission from the spinal canal are not generally opposite the place of origin of the nerves, the roots are for the most part directed obliquely. This obliquity increases from above down; for in the upper cervical nerves the roots are horizontal; but in the lumbar and sacral nerves they have a vertical direction around the filum terminale (fig. 127); and the bundle of long nerve-roots descending from the end of the spinal cord is named, from its resemblance to a horse's tail, the *cauda equina*.

Oblique in their course,

most so inferiorly,

where they form cauda equina.

The length of the roots increases in proportion to their obliquity. Thus, the distance between the origin and the place of exit of the roots of the lowest cervical nerve equals the depth of one vertebra; in the lowest dorsal nerve it amounts to the depth of two vertebræ; and in the lumbar and sacral nerves each succeeding root becomes nearly a vertebra longer, for the cord does not reach beyond the first lumbar vertebra.

Length increases from above down.

Place of union of the roots. Commonly the roots unite as before stated in the intervertebral foramina; and the trunk of the nerve bifurcates at the same spot into anterior and posterior primary branches (fig. 126, d and e). But deviations from this arrangement

Union of the roots in intervertebral foramen,

are found at the upper and lower ends of the spinal column in the following nerves.

except in
first two
cervical,
The roots of the first two cervical nerves join on the neural arches of the corresponding vertebræ; and the anterior and posterior primary branches diverge from the trunks in that situation.

the sacral,
In the sacral nerves the union of the roots takes place within the spinal canal; and the primary branches of the nerves issue by the apertures on the front and back of the sacrum.

and coc-
cygeal
nerves.
The roots of the coccygeal nerve are also united in the spinal canal; and the anterior and posterior branches of its trunk escape by the lower aperture of that canal.

Situation of
ganglia.
Situation of the ganglia. The ganglia are placed commonly in the intervertebral foramina, but where the position of these apertures is irregular, as at the upper and lower extremities of the spinal column, they have the following situation:—In the first two nerves they lie on the neural arches of the atlas and axis. In the sacral nerves they are contained in the spinal canal; and in the coccygeal nerve the ganglion is usually within the sac of the dura mater.

Arteries of
cord.
VESSELS OF THE SPINAL CORD. The arteries on the surface of the cord are anterior and posterior spinal.

Anterior
spinal,
a single
artery;
The *anterior spinal artery* occupies the middle line of the cord beneath the fibrous band before alluded to in that position. It begins by the union of two small branches of the vertebral artery (p. 182); and it is continued to the lower end of the cord by a series of anastomotic branches, which are derived from the vertebral and ascending cervical arteries in the neck, and from the intercostal termination; arteries in the dorsal region. Inferiorly it supplies the roots of the nerves forming the cauda equina, and ends on the central fibrous offsets, prolongation of the cord. The branches of this artery ramify in the pia mater, some entering the median fissure.

Posterior
arteries are
two;
The *posterior spinal arteries*, one on each side, are continued from the upper to the lower part of the cord, behind the roots of the nerves. These vessels are furnished from the same source as the anterior (p. 182), and their continuity is maintained by a series of anastomotic offsets, which enter the canal along the spinal nerves. Dividing into small branches, the vessels of opposite sides form a free anastomosis around the posterior roots, and some twigs enter the posterior septa of the cord.

lie on sides
of cord.
The *veins of the spinal cord* are very tortuous and form a plexus on the surface. At intervals larger trunks arise, which accompany the spinal nerves to the intervertebral foramina, and end in the veins outside the spinal canal. Near the top of the cord the veins are united into two or more small branches, which, communicating with the intraspinal veins, join in the skull the inferior cerebellar veins, or the inferior petrosal sinuses.

Veins :
termina-
tion;
at top of
cord.
The *veins of the spinal cord* are very tortuous and form a plexus on the surface. At intervals larger trunks arise, which accompany the spinal nerves to the intervertebral foramina, and end in the veins outside the spinal canal. Near the top of the cord the veins are united into two or more small branches, which, communicating with the intraspinal veins, join in the skull the inferior cerebellar veins, or the inferior petrosal sinuses.

Situation of
the cord.
The SPINAL CORD (*medulla spinalis*) is the elongated rounded part of the cerebro-spinal centre, which is enclosed within the spinal canal. Invested by the membranes before examined, the cord occupies about two-thirds of the length of its canal, and is much smaller than the bony case surrounding it.

The extent of the spinal cord is from the lower margin of the foramen magnum of the occipital bone to the lower border of the first lumbar vertebra, but its termination inferiorly may be a little higher or lower than that spot. In the embryo before the third month the medulla reaches the whole length of the spinal canal; but it gradually recedes as the surrounding bones enlarge faster than it, until it takes the position it has in the adult. Its length is usually from sixteen to eighteen inches.

Above, the cord joins the medulla oblongata; and below, it ends in a small tapering part (*conus medullaris*), from which the filum terminale (fig. 127, *d*) is continued downwards. The lower end of the *conus medullaris* is sometimes marked by one or two irregular swellings.

The size of the spinal cord is much increased where the nerves of the limbs are attached. There are, therefore, two enlargements on it, viz., cervical and lumbar; the one in the neck reaches from the first cervical to the first dorsal vertebra; the other is smaller, and is on a level with the eleventh and twelfth dorsal vertebrae. In the upper enlargement the greatest thickness is from side to side; but in the lower swelling the measurement from before back nearly equals the transverse.

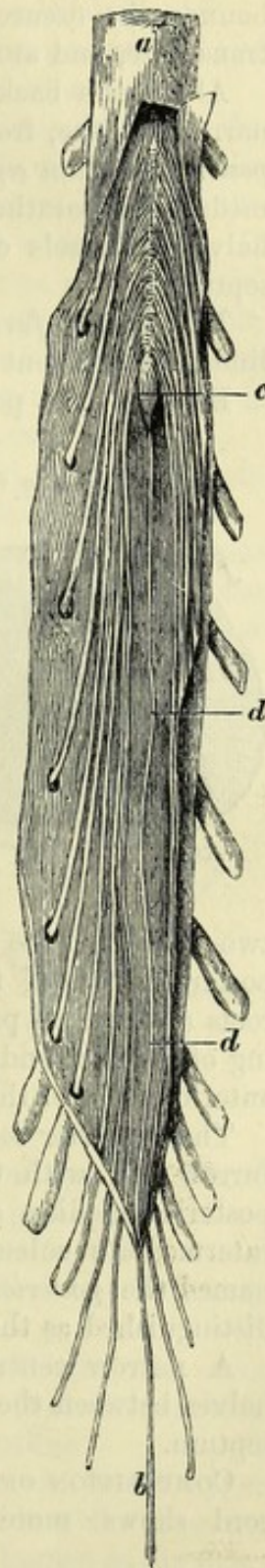
While the pia mater remains on the cord, the anterior surface is distinguished from the posterior by the central fibrous band and the anterior spinal artery; as well as by the irregular line of the anterior nerve-roots, which approach the middle towards the lower end.

Dissection. For the examination of the structure the student will require a piece of a fresh cord which has been hardened in spirit; for the cord which is obtained from the spinal canal at this period is not fitted for the purpose of dissection. Supposing the pia mater removed from the surface, with the roots of the nerves left on one side, the student will be able to observe the following divisions of the cord.

SULCI OF THE CORD (fig. 128). The *anterior median fissure* occupies the middle line of the front of the cord in

* Membranes of the spinal cord laid open, to show the lower end of the cord with the filum terminale. *a*. Dura mater, and *b*, the fibrous band fixing it to the coccyx. *c*. Pointed lower end of the cord (*conus medullaris*). *d*. Filum terminale of the cord.

Fig. 127.*

Extent
varies
below,and in the
embryo.

Length.

Inferior
termination
in the adult.Two
swellings
on it.Anterior
surface, how
known.Dissection
to see con-
stituents of
cord.Furrows of
the cord are
anterior
median,

its whole length, and penetrates about one-third of the thickness of the medulla. It is lined by a fold of the pia mater, and is deepest towards the lower end of the cord. White medullary substance bounds the fissure; and at the bottom of it the white fibres are transverse, and are separated by apertures for blood-vessels.

posterior
median,

Along the back of the cord, also in the middle line, there is a narrow groove, from which a process of the pia mater called the *posterior median septum* extends forwards nearly to the centre of the medulla, separating the nervous substance of the right and left halves. Vessels of the posterior surface of the cord enter in the septum.

lateral,

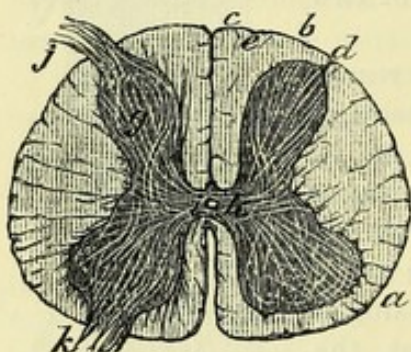
The *lateral furrow* (fig. 128, *d*) is a shallow groove along the line of attachment of the fasciculi of the posterior roots.

and pos-
terior inter-
mediate.

Between the posterior median and the lateral grooves another slight furrow, the *posterior intermediate*, may be seen in the upper part of the cord (fig. 128, *e*).

Fig. 128.*

The cord is
divided into



antero-
lateral
column,

DIVISIONS OF THE CORD. Each half of the cord between the median sulci is divided into two by the lateral furrow (fig. 128, *d*); the part in front of that groove and the posterior roots of the nerves is called the *antero-lateral column* (*a*); and the part behind, the *posterior column* (*b*).

The *antero-lateral column* (fig. 128, *a*) includes rather more than two-thirds of the half of the cord, extending backwards to the posterior roots of the nerves, and gives attachment to the anterior roots (*k*). This part of the cord is sometimes described as consisting of anterior and lateral columns, the two being separated by the anterior roots of the nerves.

posterior
column,

with median
and external
parts,

The *posterior column* (fig. 128, *b*) is situate between the lateral furrow (*d*), with the posterior roots of the nerves (*j*), and the posterior median septum. In the cervical region, the posterior intermediate sulcus (*e*) marks off a small inner portion, which is named the *posterior median column* (*c*); and the remainder is then distinguished as the *postero-external column* (*b*).

and com-
missure.

A narrow central piece, the *commissure of the cord*, unites the halves between the anterior median fissure and the posterior median septum.

Cord con-
sists of grey
and white
matter.

COMPOSITION OF THE CORD (fig. 128). A horizontal section of the cord shows more distinctly its division into halves, with the

* A section of the spinal cord, to show its composition and divisions. In the middle line below is the anterior median fissure, and above are the posterior median groove and septum. *d*. The lateral sulcus. *e*. The posterior intermediate sulcus. *Columns*: *a*. Antero-lateral. *b*. Posterior external. *c*. Posterior median. *Composition*: *g*. Grey crescent, surrounded by white fibres. *h*. Grey transverse commissure, and *i*. Canal of the cord in it. *j*. Posterior, and *k*. Anterior root of a nerve entering the grey crescent.

commissural or connecting piece between them. The same cut demonstrates the existence of a mass of grey matter in the interior, which is arranged in the form of two crescents (one in each half), united by a cross piece, and surrounded by white substance.

The *commissure* consists of two parts, viz., a transverse band of grey matter (fig. 128, *h*), with a white stratum in front.

The grey transverse band (*posterior* or *grey commissure*) connects the opposite crescents, and is placed rather nearer the front than the back of the cord. In its centre is the shrunk canal of the spinal cord (fig. 128, *i*), which is best seen in the fœtus. It reaches the whole length of the medulla, and a cross section of the cord shows it as a round spot. Above, the canal opens on the floor of the fourth ventricle; and below, it is continued into the filum terminale. It is lined by a columnar ciliated epithelium, and is obstructed by a granular material near the upper end.

The *anterior* or *white commissure* is best marked opposite the enlargements on the cord, and is least developed in the dorsal region.

The half of the medulla. In the half of the cord, as in the commissure, grey and white portions exist; the former is elongated from before back, being crescentic in shape as before said, and is quite surrounded by the latter.

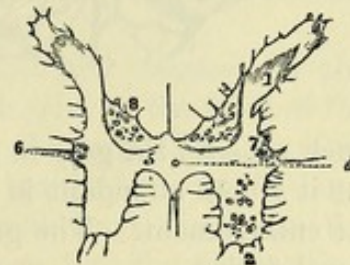
The *grey crescent* (fig. 128, *g*) has its extremities or cornua directed towards the roots of the nerves, and the convexity to the middle line. The crescentic masses in the opposite halves of the cord are united by the grey commissure.

The *posterior cornu* is long and slender (fig. 129), and reaches nearly to the surface along the lateral fissure. It is rather narrow at its base (*cervix*; ⁷), and enlarged towards its extremity (*caput*; ¹), where it is surmounted by a semi-transparent layer which has been named the *substantia gelatinosa* (³). There is also on the inner side of the cervix of the posterior cornu a special portion of grey matter containing nerve-cells, the *posterior vesicular column* of Clarke (⁸), which is most developed in the lower dorsal region.

The *anterior cornu* (fig. 129, ²) is shorter and thicker than the posterior, and projects towards the anterior roots without reaching the surface. Its end has an irregular or zigzag outline.

A third smaller projection of the grey matter is seen in the upper part of the dorsal region of the cord, on the outer side of the crescent, between the anterior and posterior horns: this is known as the *intermediate process* (Gowers) or the *lateral cornu* (fig. 129, ⁶).

Fig. 129.*



Posterior cornu :

its parts.

Anterior cornu.

Intermediate process.

* Outline of the grey substance in the spinal cord, near the middle of the dorsal region (Lockhart Clarke). 1. Caput cornu posterioris. 2. Anterior cornu. 3. Substantia gelatinosa. 4. Central canal of the cord. 5. Posterior commissure. 6. Intermediate process. 7. Cervix cornu posterioris. 8. Posterior vesicular column.

White
substance.

The *white substance of the cord* is composed chiefly of medullated nerve-fibres disposed in longitudinal bundles, which are enclosed by irregular septa of connective tissue prolonged from the pia mater on the surface. Three larger processes of the pia mater extend into the back of the cord; these are the *posterior median septum* already referred to, and the *posterior intermediate septum* on each side, which passes forwards in the cervical region from the furrow of the same name, and separates the posterior median and postero-external columns.

Grey and
white sub-
stance vary.

Modifications in the grey and white substance. The white substance

Fig. 130.*

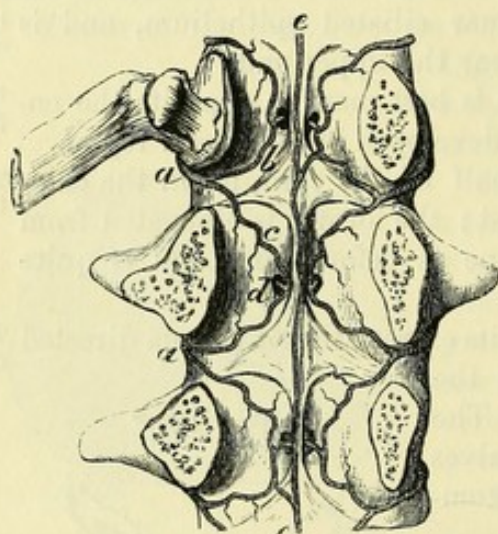
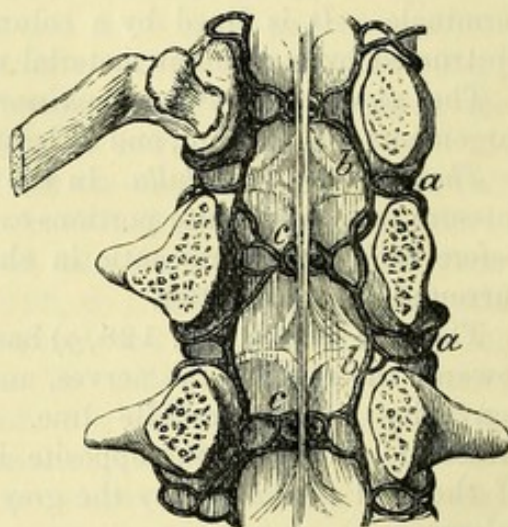


Fig. 131.†



much exceeds the grey in quantity in the cervical and dorsal regions; but it is less abundant in proportion to the grey matter in the lumbar enlargement. The grey substance is least in amount in the dorsal region.

Crescents
alter their
shape.

The cornua of the grey crescents decrease in length from above down, especially the posterior, and towards the end of the cord they blend in one indented or cruciform mass.

Vessels of
the intra
spinal
canal.

INTRASPINAL VESSELS. Arteries supply the cord and its membranes, and the bodies of the vertebræ. The veins form a remarkable plexus within the canal, but this will not be seen unless they have been specially injected.

Source of
the intra
spinal
arteries.

The *intraspinous arteries* (fig. 130, *a*) are derived from the vessels along the sides and front of the spinal column, viz., from the vertebral and ascending cervical in the neck, from the intercostal in

* Intraspinous arteries in the loins (Museum of University College, London). *a*. Branch of a lumbar artery. *b*. Ascending, and *c*, descending offset. *d*. Offset to the body of the vertebra on each side. *e*. Central artery formed by offsets from the lateral loops.

† Intraspinous veins in the loins. *a*. Branch to join a lumbar vein. *b*. Anterior longitudinal vein, one on each side. *c*. Veins from the bodies of the vertebræ.

the back, and from the lumbar and lateral sacral below. They are distributed after the following plan :—

As each artery enters the spinal canal by the intervertebral foramen, it divides into two branches, upper and lower. From the point of division the branches are directed, one (*b*) upwards and the other (*c*) downwards, behind the bodies of the two contiguous vertebræ, and join in anastomotic loops with an offset of the intraspinal artery above and below. From the loops offsets (*d*) are furnished to the periosteum and the bodies of the vertebræ. Anastomotic twigs connect the arches across the vertebræ.

The intraspinal vessels produce also a central longitudinal artery (*e*), like that on the front of the spinal cord, which lies on the bodies of the vertebræ, and is reinforced at intervals by offsets from the loops.

The *intraspinal veins* (fig. 131) consist of two anterior longitudinal vessels, which extend the whole length of the spinal canal ; of veins inside the bodies of the vertebræ ; and of a plexus of veins beneath the neural arches.

The *anterior longitudinal veins* (*b*) are close to the bodies of the vertebræ, one on each side of the posterior common ligament ; and they are irregular in outline, owing to certain constrictions near the intervertebral foramina. They receive opposite the body of each vertebra the veins (*c*) from that bone ; and through the intervertebral foramina they have branches of communication (*a*) with the veins outside the spine in the neck, the dorsal region, the loins, and the pelvis.

Veins of the bodies of the vertebræ. Within the channels in the bodies of the vertebræ are large veins, which join on the front of the bone with veins in that situation. Towards the back of the vertebra they are united in an arch, from which two trunks issue by the large apertures on the posterior surface. Escaped from the bone, the trunks diverge to the right and left, and open into the longitudinal veins.

The *posterior spinal veins* form a plexus between the dura mater and the arches of the vertebræ. A large vein may be said to lie on each side of the middle line, which joins freely with its fellow, and with the anterior longitudinal vein by lateral branches. Offsets from these vessels are directed through the intervertebral foramina, to end in the veins (*a*) at the roots of the transverse processes.

CHAPTER VII.

DISSECTION OF THE PERINEUM.

SECTION I.

PERINEUM OF THE MALE.

Before the
dissection
pass catheter.

Directions. The perineum may be allotted with greatest advantage to the dissector of the abdomen; and its examination should be made first, as the distinctness of many of the parts is destroyed soon after death. Before the body is placed in the position suited for the dissection, the student may practise passing the catheter along the urethra.

Place the
body in
position,

and fasten
upwards
the legs.

Position of the body. While the body lies on the back it is to be drawn to the end of the dissecting table, till the buttocks project slightly over the edge; and a block is to be placed beneath the pelvis, to raise the perineum to a convenient height. The legs are to be raised and kept out of the way by the following means:—After the knees have been bent, and the thighs raised upon the trunk, the limbs are to be fastened with a cord in their bent position. For this purpose make one or two turns with the cord round one bent knee (say the right); carry the cord beneath the table, and, encircling the opposite limb in the same manner, fasten it finally round the right knee. When the position has been arranged, let the student raise the scrotum, and place a small piece of cotton-wool or tow within the anus, but without distending the rectum.

The surface
limits.

Superficial limits and marking. The perineal space in the male is limited, on the surface of the body, by the scrotum in front, and by the thighs and buttocks on the sides and behind.

The anus,

The skin of this region is of a dark colour, and is covered with hairs. In the middle line is the aperture of the anus, which is behind a line extending from the anterior part of the one ischial tuberosity to the other. In front of the anus the surface is slightly convex over the urethra, and presents a longitudinal prominent line or *raphé*, which divides the space into halves. Between the anus and the tuberosity of the hip-bone the surface is somewhat depressed over the hollow of the subjacent ischio-rectal fossa, especially in emaciated bodies.

the raphé,
hollow on
side of anus,

and folds
and veins
around that
opening.

The margin of the anal aperture possesses numerous converging folds, but these are more or less obliterated by the position of the body and the distension of the anus; and projecting oftentimes

through and around the opening are some dilated veins (hæmorrhoids).

Deep boundaries. The deep boundaries of the perineal space will be ascertained, in the progress of the dissection, to correspond with the inferior aperture or the outlet of the pelvis. The limits may be seen on a dry or prepared pelvis, on which the ligaments remain entire; and the student should trace on the body the several boundaries with his finger. In front is the symphysis pubis; and at the back is the tip of the coccyx, with the great gluteal muscles. On each side in front is the portion of the hip-bone which bounds the subpubic arch, viz., from the pubic symphysis to the ischial tuberosity; and farther back is the great sacro-sciatic ligament extending from the tuberosity to the coccyx. This region sinks into the outlet of the pelvis as far as the recto-vesical fascia, which forms its floor.

Bounding parts same as those of outlet of pelvis.

Form and size. The interval included within the boundaries above said is rather heart-shaped, owing to the projection of the coccyx behind; and it measures over the surface about four inches from before backwards, and three and a half inches between the ischial tuberosities.

Form of the space, and measurements.

Depth. The depth of the perineum from the surface to the floor may be said to be generally about three inches between the anus and the ischial tuberosity, but this measurement varies greatly in different bodies; and it amounts to about an inch at the fore part, between the pubic bones.

Depth of the space.

Division. A line from the front of the tuberosity of one side to the corresponding point on the other will divide the perineal space into two parts. The anterior half (urethral) contains the root of the penis and the urethra, with their muscles, and vessels and nerves. The posterior half (rectal) is occupied by the lower end of the large intestine, with its muscles, &c.

A line between the tuberosities divides it into two.

POSTERIOR HALF OF THE SPACE.

This portion of the perineal space contains the lower end of the rectum, surrounded by its elevator muscles and the muscles acting on the anus. The gut does not occupy, however, the whole of the interval between the pelvic bones; for on each side is a space, the ischio-rectal fossa, in which is contained much loose fat, with the vessels and nerves for the supply of the end of the gut.

Contents of anal half, and their general position.

Dissection (fig. 132). The skin is to be raised from this part of the perineum by the following cuts:—One is to be made across the perineum at the front of the anus, and is to extend rather beyond the ischial tuberosity on each side. A second is to be carried a little behind the tip of the coccyx in the same direction, and for the same distance. The two transverse cuts are to be connected by carrying the knife along the mid-line, and around the anus. The flaps of the skin thus marked out are to be raised and thrown outwards from the middle line: in detaching the skin from the margin

Dissection

of external
sphincter
muscle.

of the anus, the superficial sphincter muscles may be injured without care, for they are close to the skin, without the intervention of fat. The dissector should trace the external sphincter to the coccyx, and forwards for a short distance beneath the skin, and define a fleshy slip on each side in front and behind to the subcutaneous fatty layer.

Difference
in cleaning
the ischio-
rectal fossae.

The next step is to bring into view the ischio-rectal hollow between the side of the rectum and the tuberosity of the hip-bone. On the left side the fat is to be cleaned out of it without reference to the vessels and nerves, but on the opposite side a special dissection is to be made of them. To take out the fat from the left fossa, begin at the outer margin of the sphincter ani, and proceed forwards and backwards. In front the dissection should not extend farther than the anus, while behind it should lay bare the margin of the gluteus maximus. On the inner side of the hollow the levator ani (sometimes very pale) is to be exposed by the removal of a thin layer of areolar tissue (anal fascia.) On the outer boundary the pudic vessels and the accompanying nerves should be denuded: they lie in a canal formed by fascia, and at some distance from the surface.

Dissection
of left ischio-
rectal fossa.

On right
side, seek
vessels and
nerves.

On the right side it is not necessary to clean the muscular fibres when following the vessels and nerves. If the student begins at the outer border of the sphincter, he will find the inferior hæmorrhoidal vessels and nerve, which he may trace outwards to the pudic trunks; some of the branches, which join the superficial perineal and inferior pudendal nerves, are to be followed forwards. In the posterior angle of the space seek a small offset of the fourth sacral nerve; and external to it, branches of the perforating cutaneous nerve from the sacral plexus, with small vessels, turning round the border of the gluteus. Near the front of the fossa is the superficial perineal artery with a nerve; and the last, after communicating with the hæmorrhoidal nerve, leaves the fossa. A second perineal nerve, with a deeper position, may be found at the front of the hollow.

Situation of
fossa;

form;

dimensions;

boundaries.

The ISCHIO-RECTAL FOSSA (fig. 132) is the interval between the rectum and the ischial part of the hip-bone. It is a somewhat pyramidal hollow, which is larger behind than before, and diminishes in width as it sinks on the inner side of the hip-bone. Its width is about one inch at the surface; and its depth about two inches at the outer side. It is filled by a soft granular fat.

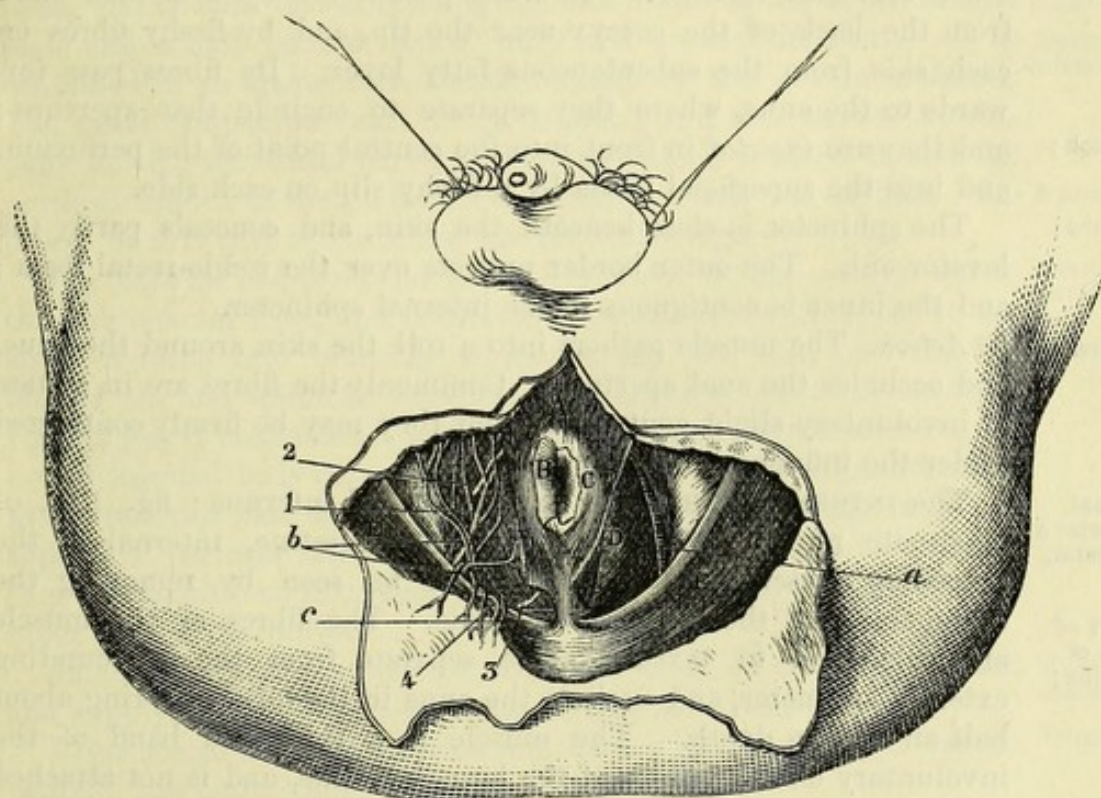
The inner or longest side of the space is very oblique, and is formed by the levator ani muscle (D), together with the coccygeus at the back; but the outer side is vertical, and is formed by the obturator internus muscle and the fascia covering it. In front it is limited by the triangular ligament (to be afterwards seen); and behind are the great sacro-sciatic ligament, and the largest gluteal muscle. Towards the surface it is covered by the teguments, and is overlaid in part by the gluteus (E) and the sphincter externus (A).

Pudic ves-
sels on the
outer wall,

Vessels and nerves in the space. Along the outer wall lie the pudic vessels (a) and the perineal and dorsal divisions of the pudic nerve,

which are contained in a sheath of fascia; opposite the ischial tuberosity they are situate about an inch and a half from the edge of the bone, but towards the front of the space they approach to within half an inch of the margin of the ischial ramus. Crossing the centre of the hollow are the inferior hæmorrhoidal vessels and nerve (*b*),—branches of the pudic. At the anterior part, for a short distance, are two superficial perineal nerves (²) (of the pudic); and at the posterior part is a small branch of the fourth sacral nerve (³), and nerves in the space.

Fig. 132.*



with cutaneous offsets of the sacral plexus (⁴) and inferior hæmorrhoidal vessels (*c*), bending round the gluteus.

Into this space the surgeon sinks his knife in the first incision in the lateral operation of lithotomy; and as he carries it from before backwards, he will divide the superficial hæmorrhoidal vessels and nerve. First cut in lithotomy enters this space.

MUSCLES. Connected with the lower end of the rectum are four muscles, viz., a fine cutaneous muscle, and two sphincters (external and internal), with the levator ani. Muscles of rectum.

CORRUGATOR CUTIS ANI† (fig. 132, B). This thin subcutaneous Corrugator cutis ani:

* A view of the dissection of the rectal half of the perineum (Illustrations of Dissections). *Muscles*: A. External sphincter. B. Corrugator cutis, only part left. c. Internal sphincter. d. Levator ani. e. Gluteus maximus. *Arteries*: a. Trunk of the pudic artery. b. Inferior hæmorrhoidal, and c, its gluteal branches. *Nerves*: 1. Inferior hæmorrhoidal. 2. Superficial perineal. 3. Perineal branch of the fourth sacral. 4. Perforating cutaneous.

† Illustrations of Dissections, p. 243. London, 1865.

- attach-ments ;** layer of involuntary muscle surrounds the anus with radiating fibres. Externally it blends with the subdermic tissue outside the internal sphincter ; and internally it enters the anus and ends in the sub-mucous tissue within the sphincter.
- use.** *Action.* This muscle draws upwards and inverts the mucous membrane of the lower end of the gut, after it has been protruded and everted in the passage of the fæces.
- External sphincter :** The EXTERNAL SPHINCTER (sphincter ani externus ; fig. 132, A) is a flat, orbicular muscle, which surrounds the lower end of the rectum. The fibres form ellipses around a central aperture, as in
- origin ;** other orbicular muscles. It *arises* posteriorly by a fibrous band from the back of the coccyx near the tip, and by fleshy fibres on each side from the subcutaneous fatty layer. Its fibres pass for-
- insertion ;** wards to the anus, where they separate to encircle that aperture ; and they are *inserted* in front into the central point of the perineum, and into the superficial fascia by a fleshy slip on each side.
- relations ;** The sphincter is close beneath the skin, and conceals partly the levator ani. The outer border projects over the ischio-rectal fossa ; and the inner is contiguous to the internal sphincter.
- and use.** *Action.* The muscle gathers into a roll the skin around the anus, and occludes the anal aperture. Commonly the fibres are in a state of involuntary slight contraction, but they may be firmly contracted under the influence of the will.
- Internal sphincter a pale band,** The INTERNAL SPHINCTER (sphincter ani internus ; fig. 132, c) is situate round the extremity of the intestine, internal to the
- is part of fibres of intestine ;** preceding muscle, and its edge will be seen by removing the corrugator and the mucous membrane. The fibres of the muscle are pale, fine in texture, quite separate from the surrounding external sphincter, and encircle the anus in the form of a ring about half an inch in depth. The muscle is a thickened band of the involuntary circular fibres of the large intestine, and is not attached to the bone.
- use.** *Action.* This sphincter assists the external in closing the anus ; and its contraction is altogether involuntary.
- Insertion of levator ani** The LEVATOR ANI (fig. 132, D) can be seen only in part ; and the external sphincter may be detached from the coccyx, in order that its insertion may be more apparent. The muscle descends from its
- into coccyx and tendon in front of it ;** origin at the inner aspect of the hip-bone, and is *inserted* along the middle line from the coccyx to the central point of the perineum. The hindmost fibres are attached to the side of the coccyx ; and between that bone and the rectum the muscles of opposite sides
- into rectum, and the centre of the perineum :** are united in a median tendinous line. The middle fibres are blended with the side of the rectum. And the anterior are joined with the opposite muscle, in front of the rectum, in the central point of the perineum.
- relations ;** This muscle bounds the ischio-rectal fossa on the inner side, and unites with its fellow to form a fleshy layer (pelvic diaphragm), convex downwards, through which the rectum is transmitted. Deeper than the muscle is the recto-vesical fascia. Along the hinder border is placed the coccygeus.

Action. It compresses the lower part of the rectum during the act of defæcation. use on rectum.

This muscle will be more fully seen in the dissection of the pelvis.

ARTERIES (fig. 132). The pudic artery, with its inferior hæmorrhoidal branch, and other small offsets of it, are now visible. Arteries of the space.

The **PUDIC ARTERY** (*a*) is derived from the internal iliac in the pelvis (p. 559), and in its course to the genital organs distributes offsets to the perineum; one portion will be laid bare in the posterior, and the other in the anterior half of the perineum. Pudic artery : course ;

As now seen, the vessel enters the hinder part of the ischio-rectal fossa, and courses forwards along the outer wall at the depth of one inch and a half behind, but of only half an inch in front. It is contained in an aponeurotic sheath formed by the obturator fascia. The usual companion veins lie by its side; and two nerves accompany it, viz., the dorsal nerve of the penis which is above it, and the perineal branch of the pudic nerve which is nearer the surface. Its offsets in this part of its course are the following :— posterior part in fossa ; depth and relations. Branches :—

The *inferior hæmorrhoidal branch* (*b*) arises as the artery enters the ischio-rectal fossa, and is directed inwards across the space to the anus, dividing into branches which supply the skin and fat, the levator ani and sphincter muscles, and the lower end of the rectum. On the gut it anastomoses with the other hæmorrhoidal arteries. In a well injected body cutaneous branches may be seen to run forwards to the anterior part of the perineum, and to communicate with the superficial perineal artery. Other offsets turn upwards round the edge of the gluteus maximus to the integument of the lower and inner part of the buttock. Inferior hæmorrhoidal.

Small *muscular branches* cross the front of the ischio-rectal fossa, and supply the anterior part of the levator ani muscle. Muscular offsets.

Veins accompany the arteries, and have a like course and ramification : the pudic veins end in the internal iliac. Veins.

NERVES (fig. 132). The nerves seen at this stage of the dissection are the three divisions of the pudic trunk, a branch of the fourth sacral nerve, and the perforating cutaneous offset of the sacral plexus. Nerves of the space.

The **PUDIC NERVE** is derived from the sacral plexus, and lies over the small sacro-sciatic ligament with the artery in the buttock (p. 641). In the small sacro-sciatic foramen the nerve breaks up into the three following branches, which enter the perineum :— Pudic nerve divides into three parts :

The *inferior hæmorrhoidal branch* (¹) crosses the ischio-rectal fossa, and reaches the margin of the anus, where it terminates in offsets to the integument and the sphincter muscle. Other cutaneous offsets of the nerve run forwards over the fossa, and communicate with one of the superficial perineal nerves, and with the inferior pudendal (of the small sciatic) on the margin of the thigh. inferior hæmorrhoidal ;

The *perineal branch* is the largest of the three divisions, and runs forwards in a sheath of the obturator fascia, lying below the pudic vessels. At the fore part of the ischio-rectal fossa it divides into cutaneous, muscular, and genital offsets. Its two cutaneous branches perineal ;

(superficial perineal) may be seen on the right side, where they lie for a short distance in the fat of the hollow.

and dorsal
nerve of the
penis.

The *dorsal nerve of the penis* accompanies the pudic artery along the outer side of the ischio-rectal fossa to the fore part of the perineum. It is also enclosed in the obturator fascia, but is deeper than the blood-vessels.

Offset of
fourth sacral
nerve.

The PERINEAL BRANCH OF THE FOURTH SACRAL NERVE ⁽³⁾ reaches the ischio-rectal fossa between the levator ani and coccygeus, or by piercing one of these muscles, near the coccyx, and ends by supplying the external sphincter.

Perforating
cutaneous
nerve.

The PERFORATING CUTANEOUS NERVE is an offset from the lowest part of the sacral plexus, and is named from its piercing the great sacro-sciatic ligament in its course to the perineum (fig. 123, ⁵). Turning upwards round the lower edge of the gluteus maximus, its branches are distributed to the skin of the inner and lower part of the gluteal region (fig. 132, ⁴).

ANTERIOR HALF OF THE PERINEAL SPACE.

Urethral
half :
contents
and general
position of
parts.

In the anterior part of the perineal space are lodged the crura of the penis, and the tube of the urethra as it courses from the interior of the pelvis to the surface of the body. Placed midway between the bones, the urethra is supported by the triangular ligament of the perineum, and by its union with the penis.

Muscles are collected around the urethra and the crura of the penis : most of these are superficial to, but one is within the triangular ligament.

The vessels and nerve lie along the outer side, as in the posterior half, and send inwards offsets.

Incisions to
raise the
skin.

Dissection (fig. 133). To raise the skin from the anterior half of the perineum, a transverse cut is to be made at the back of the scrotum, and is to be continued for a short distance (two inches) on each thigh. A second incision along the middle line will allow the flaps of skin to be reflected outwards. After the removal of the skin, the superficial fascia which covers the front of the perineal space is to be blown up by means of a pipe introduced beneath it posteriorly. Each side is to be inflated to demonstrate a partition along the middle line, and a septum between the perineal space and the thigh, which prevents the air passing to the limb.

Blow up
superficial
fascia, and
reflect it.

Define parti-
tion between
thigh and
perineal
space.

The student is next to cut through the superficial fascia on the left side from the scrotum to the ischio-rectal fossa ; and after reflecting it, and removing loose fatty tissue, its line of attachment to the bone externally, and to the triangular ligament posteriorly, will be brought into view. The septum along the middle line should be also defined. To show more completely the attachment of this layer to the hip-bone between the perineal space and the thigh, it will be necessary to take away from the left limb the fat on the fascia lata, external to the margin of the bone.

On right
side seek
inferior

In the fat of the thigh on the right side the student should seek the inferior pudendal nerve, which pierces the fascia lata one inch

in front of the ischial tuberosity, and about the same distance from the margin of the bone; and he should trace its junction in the fat with the inferior hæmorrhoidal nerve. Afterwards the nerve is to be followed forwards to where it enters beneath the superficial fascia nearer the middle line.

The *superficial fascia* of the anterior half of the perineum is composed of two layers, which differ in their characters and relations.

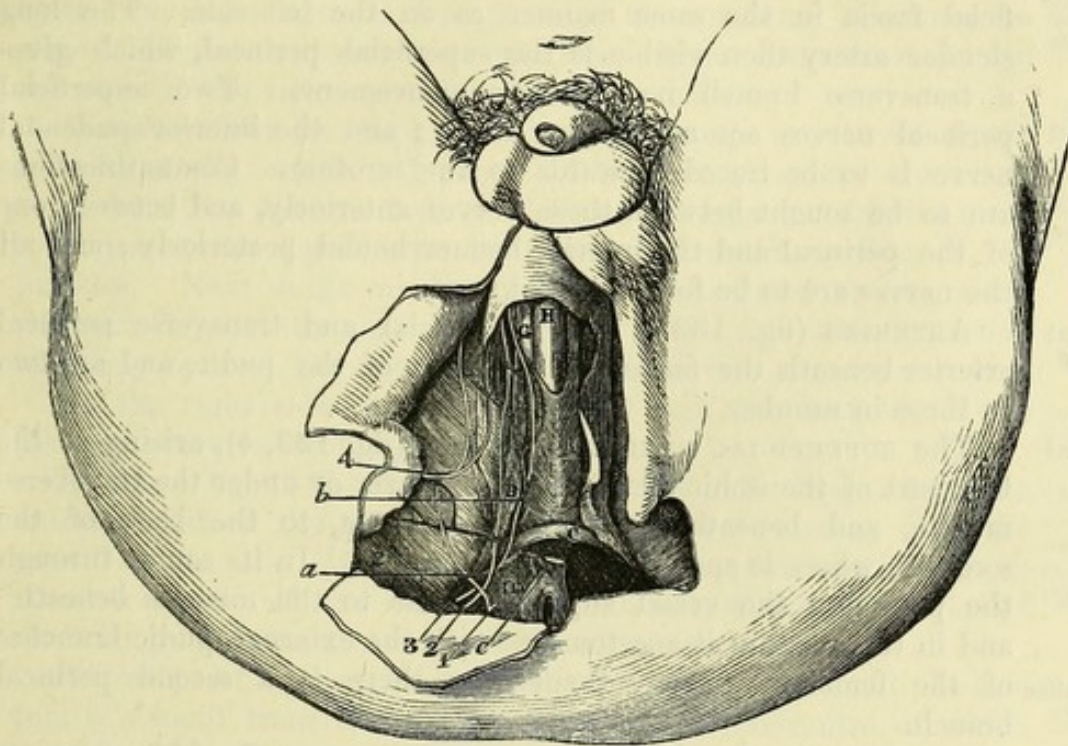
One is the subcutaneous fatty part, continuous with that of the adjoining regions: its thickness, and the quantity of fat in it vary

pudendal
nerve.

Superficial
fascia:

subcutane-
ous part;

Fig. 133.*



with the condition of the body. Passing in front into the scrotum, it there loses its fat, and contains involuntary muscular fibres, forming the layer known as the *dartos*.

The other (fascia of Colles) is a more membranous stratum of limited extent, and is connected with the firm subjacent structures.

Externally it is fixed to the conjoined rami of the ischium and pubis, outside the line of the crus penis and its muscle, extending as far back as the ischial tuberosity. Posteriorly this layer bends upwards to join the triangular ligament of the urethra; but in front it is unattached, and is continued to the scrotum and penis. By means of similar connections of the membrane on both sides, a space is enclosed over the anterior half of the perineum. From its

and mem-
branous
layer.

The latter
forms a
pouch, open
in front;

* Superficial dissection of the anterior half of the perineum (Illustrations of Dissections). *Muscles, &c.*: A. Ejaculator urinæ. B. Erector penis. C. Transversus perinei. D. Levator ani. E. Gluteus maximus. G. Crus penis. H. Urethra. *Arteries*: a. Transverse perineal. b. Superficial perineal. *Nerves*: 1. Inferior hæmorrhoidal. 2 and 3. Superficial perineal. 4. Inferior dudendal.

this divided by a septum. deep surface a septum extends upwards in the middle line, and divides posteriorly the subjacent space into two; but anteriorly this partition is less perfect, or may disappear.

Course of air and effused urine. Air blown beneath the fascia passes forwards to the scrotum; and this direction is given to it by the deep connections of the membrane with parts around. Should urine be effused beneath the superficial fascia, the fluid will necessarily be directed forwards, like the air, through the scrotum to the penis and the front of the abdomen.

Dissection of nerves and vessels on right side. *Dissection.* The superficial vessels and nerves are to be dissected on the right side of the perineum, by cutting through the superficial fascia in the same manner as on the left side. The long slender artery then visible is the superficial perineal, which gives a transverse branch near its commencement. Two superficial perineal nerves accompany the artery; and the inferior pudendal nerve is to be traced forwards to the scrotum. Communications are to be sought between these nerves anteriorly, and between one of the perineal and the inferior hæmorrhoidal posteriorly; and all the nerves are to be followed backwards.

Superficial vessels of pudic. ARTERIES (fig. 133). The superficial and transverse perineal arteries beneath the fascia are branches of the pudic, and are two or three in number.

Superficial perineal ends in scrotum, and supplies muscles. The SUPERFICIAL PERINEAL ARTERY (fig. 133, *b*), arising at the fore part of the ischio-rectal fossa, runs over or under the transverse muscle, and beneath the superficial fascia, to the back of the scrotum, where it ends in flexuous branches. In its course through the perineum the vessel supplies offsets to the muscles beneath; and in the scrotum it anastomoses with the external pudic branches of the femoral artery. Sometimes there is a second perineal branch.

Transverse artery. The TRANSVERSE ARTERY OF THE PERINEUM (fig. 133, *a*) arises from the preceding, and is directed transversely to the middle of the perineal space, where it is distributed to the integuments and the muscles between the urethra and the rectum. It anastomoses with the one of the opposite side.

Veins with the arteries. Branches of *veins* accompany the arteries, and open into the trunk of the pudic vein; those with the superficial perineal artery are plexiform at the scrotum.

Cutaneous nerves of scrotum. NERVES (fig. 133). Three nerves run forwards to the scrotum on each side, viz., the inferior pudendal of the small sciatic, and two superficial perineal branches of the pudic nerve.

Two superficial perineal; external. The SUPERFICIAL PERINEAL NERVES, two in number, are named external and internal: both arise in the ischio-rectal fossa from the perineal division of the pudic nerve (p. 421).

The *external branch* (²) is continued forwards, beneath the superficial fascia, with the artery of the same name to the back of the scrotum. While in the fossa the nerve gives inwards an offset to the integuments in front of the anus; and this communicates with the inferior hæmorrhoidal nerve.

The *internal branch* ⁽³⁾ passes under the transverse muscle, and and internal; accompanies the other to the scrotum.

The superficial perineal branches communicate with one another, and the external is joined by the inferior pudendal nerve. At the scrotum they are distributed by long slender filaments, which reach distributed to scrotum and penis. as far as the under surface of the penis.

Other *muscular branches* of the perineal nerve will be afterwards examined (p. 426). Muscular branches.

The INFERIOR PUDENDAL NERVE ⁽⁴⁾ is a branch of the small sciatic. It pierces the fascia lata about one inch in front of the ischial tuberosity, and enters beneath the superficial fascia of the perineum, to end in the outer and fore parts of the scrotum. Communications take place between this nerve, the inferior hæmorrhoidal, and the outer of the two superficial perineal branches. ends in scrotum.

Dissection. For the display of the muscles, the superficial fascia, as well as the vessels and nerves of the left side, must be taken away from the anterior half of the perineal space. Afterwards a thin aponeurotic layer is to be removed from the surface of the muscles. Next to the middle line lies the ejaculator urinæ; along the outer edge of the space is the erector penis; and behind, passing obliquely between the other two, is the transverse muscle. Dissection of muscles of the urethra and penis,

On the right side the student should seek the branches of the perineal nerve to the muscles. and of their nerves.

MUSCLES (fig. 133). Superficial to the triangular ligament, in the anterior half of the perineal space, are three muscles, viz., the erector penis, the ejaculator urinæ, and the transversus perinei. Another muscle of the urethra is contained between the layers of the triangular ligament, and will be subsequently seen. Three muscles over triangular ligament.

Central point of the perineum. Between the urethra and the rectum is a small transverse tendinous septum, to the centre of which this name has been applied. It is placed about one inch in front of the anus, and in it the muscles acting on the rectum and urethra are united. Its development varies greatly in different bodies. Central point, where muscles join.

The ERECTOR PENIS (ischio-cavernosus; fig. 133, B) is the most external of the three muscles, and is narrower at each end than in the middle. It covers the crus penis; and its fibres arise from the ischial tuberosity farther back than the attachment of the penis, and from the bone on each side of the crus. In front, the muscle is inserted into the inner and outer surfaces of the crus penis. It rests on the root of the penis and the bone. Erector penis: origin; insertion;

Action. The muscle compresses the crus penis against the subjacent bone, and retards the escape of the blood from the corpus cavernosum by the veins: in that way it will contribute to the erection of the organ. use.

The EJACULATOR URINÆ (bulbo-cavernosus; fig. 133, A) lies on the urethra. The muscles of opposite sides unite by a median tendon along the middle line and in the central point of the perineum (*origin*). The fibres are directed outwards, curving around the convexity of the urethra, and give rise to a thin muscle, which has the following *insertion*:—The hindmost fibres end on the Ejaculator urinæ: origin at middle lin

lower surface of the triangular ligament. The anterior fibres, which are the longest and best marked, are inserted into the penis on its outer aspect, in front of the erector; and, according to Kobelt, they send a tendinous expansion over the dorsal vessels of the penis. The intervening fibres turn round the urethra, surrounding it for two inches, and join their fellows in a common tendon.

The ejaculator muscle covers the bulb and the corpus spongiosum for nearly three inches below and in front of the triangular ligament. If the muscle be cut through on the left side, and turned off the urethra, the junction with its fellow above that tube will be apparent.

Action. The two halves, acting as one muscle, can diminish the urethra, and eject forcibly its contents. During the flow of fluid in micturition the fibres are relaxed, but they come into use at the end of the process, when the passage has to be cleared. The action is involuntary in the emission of the semen.

The TRANSVERSUS PERINEI (fig. 133, c) is a small thin muscle, which lies across the perineum opposite the base of the triangular ligament. *Arising* from the inner side of the ischial tuberosity at the fore part, it is *inserted* into the central point of the perineum with the muscle of the opposite side, and with the sphincter ani and the ejaculator urinæ. Behind this muscle the superficial fascia curves round to join the triangular ligament.

Action. From the direction of the fibres the muscle will draw backwards the central point of the perineum, and help to fix it preparatory to the contraction of the ejaculator.

Sometimes there is a second small fleshy slip in front of the transversalis, which has been named *transversalis alter*; this throws itself into the ejaculator muscle.

The three muscles above described, when separated from each other by the dissection, limit a triangular space, of which the ejaculator urinæ forms the inner boundary, the erector penis the outer side, and the transversus perinei the base. In the area of this interval is the triangular ligament of the urethra, with the superficial perineal vessels and nerves. The knife entering the posterior part of this space during the deeper incisions in the lateral operation of lithotomy will divide the transverse muscle and artery, and probably the superficial perineal vessels and nerves.

The PERINEAL DIVISION OF THE PUDIC NERVE (p. 421) breaks up in the fore part of the ischio-rectal fossa into superficial and deep branches. Its two superficial offsets have been followed to the scrotum (p. 424). The deep branches are *muscular* to the fore parts of the external sphincter and levator ani, to the transversus perinei, erector penis, and ejaculator urinæ, and the *nerve to the bulb*, a long slender branch, which pierces the last muscle and, dividing into filaments, enters the hinder portion of the corpus spongiosum.

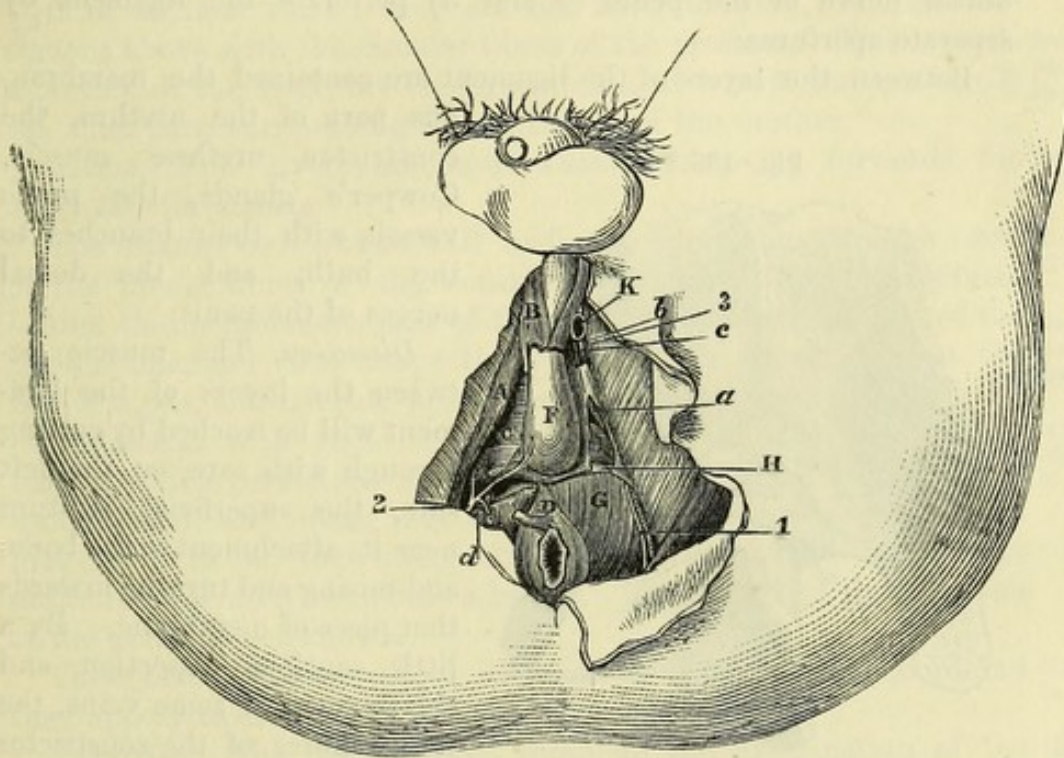
Dissection (fig. 134). For the display of the triangular ligament, the muscles and the crus penis, which are superficial to it, are to be detached on the left side in the following way;—the ejaculator urinæ

is to be removed completely from the corpus spongiosum and the surface of the ligament, and the erector muscle from the crus of the penis. Next, the crus penis is to be detached from the bone; but this must be done with care so as not to cut the triangular ligament nor to injure, near the pubic ramus, the terminal branches of the pudic artery and the nerve to the penis.

The TRIANGULAR LIGAMENT OF THE URETHRA (deep perineal aponeurosis; fig. 134, c) occupies the anterior part of the sub-

Triangular ligament of urethra:

Fig. 134.*



pubic arch, and is about one inch and a half in depth in the middle line.

On each side it is fixed to the pubic and ischial rami beneath the crus penis. Its base is turned towards the rectum, and in the middle line is united with the central point of the perineum; while laterally it is free and sloped towards the bone, so that the ligament is deeper at the sides than in the centre. Superficial to it are the bulb of the corpus spongiosum and the crura of the penis, with the muscles of the anterior half of the perineal space; and the superficial fascia joins it along the hinder border. From its deep surface some fibres of the levator ani arise; and the thin anal fascia is continued backwards from the ligament over that muscle in the ischio-rectal fossa.

* Deep dissection of the perineum (Illustrations of Dissections). *Muscles, &c.*: A. Erector penis. B. Ejaculator urinæ, cut. c. Triangular ligament, inferior layer. D. External sphincter. F. Bulb of corpus spongiosum. G. Levator ani. H. Superior layer of triangular ligament. I. Constrictor urethræ. K. Crus penis, cut. *Arteries*: a. Pudic, in the triangular ligament. b. Dorsal of penis. c. Cavernous. d. Deep muscular branch. *Nerves*: 1 and 3. Dorsal of penis. 2. Perineal branch, giving offset to bulb.

consists of
two strata ;

The ligament is composed of two layers of membrane (superior and inferior) which are united along the base. The superior layer is derived from the recto-vesical fascia. The inferior is a separate membrane, formed chiefly of transverse fibres ; but it is so thin as to allow the vessels and the muscular fibres to be seen through it.

apertures in
it for
urethra,

Perforating the inferior layer of the ligament, about one inch from the symphysis pubis, is the canal of the urethra ; but the margin of the opening giving passage to that tube is blended with the tissue of the corpus spongiosum. Nearer the symphysis, and close to the bone on each side, the terminal part of the pudic artery and the dorsal nerve of the penis (*b* and 3) perforate the ligament by separate apertures.

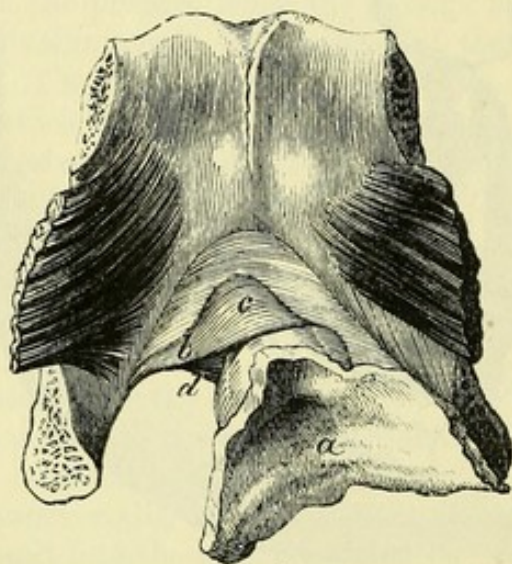
for arteries
and nerves of
penis ;

parts
between
layers.

Between the layers of the ligament are contained the membranous part of the urethra, the

constrictor urethræ muscle, Cowper's glands, the pudic vessels with their branches to the bulb, and the dorsal nerves of the penis.

Fig. 135.*



Dissection

Dissection. The muscle between the layers of the ligament will be reached by cutting through with care, on the left side, the superficial stratum near its attachment to the bone, and raising and turning inwards that piece of membrane. By a little cautious dissection, and the removal of some veins, the fleshy fibres of the constrictor urethræ will be exposed.

Constrictor
urethræ :

The CONSTRICTOR URETHRÆ (fig. 134, *i* ; 135, *b*) extends transversely across the subpubic arch, enclosing the membranous part of the urethra in the same way as the sphincter ani externus surrounds the end of the rectum. The muscle is attached by tendinous bundles on each side to the rami of the pubis and ischium, and other fibres spring from the two layers of the triangular ligament. Between these attachments the fleshy fibres are directed transversely and obliquely across the middle line, one set passing in front of, and another behind the urethra, where they are interrupted in some cases by a small median tendon. At the anterior border of the muscle there is a short fibrous band stretching across between the inferior rami of the pubic bones, and bounding with the subpubic ligament at the lower margin of the symphysis an oval opening, through which the dorsal vein of the penis enters

attach-
ments ;

disposition
of fibres.

Transverse
ligament.

* The symphysis pubis seen from above, with part of the urinary bladder and the prostate, and with the tube of the urethra surrounded by the constrictor muscle (Santorini). *a*. Bladder cut open : the swelling of the prostate surrounds it in front. *b*. Constrictor urethræ :—*c*. Part of the muscle before, and *d*, part behind the urethra.

the pelvis. The hindmost fibres of the constrictor are connected with the central point of the perineum, and are sometimes described separately as the *transversus perinei profundus*. Deep transverse muscle.

Action. This muscle acts as a sphincter in narrowing the membranous part of the urethra, and ejecting the contents of the tube. It may also aid in producing erection of the penis by compressing the veins of the corpora cavernosa, which are surrounded by its fibres. Use of constrictor.

Involuntary circular fibres within the constrictor muscle surround the urethra from the bulb to the prostate, and form a layer about $\frac{1}{30}$ th of an inch thick; they are not fixed to bone, and are continuous above with the circular fibres of the prostate. This layer is a portion of the large involuntary muscle, of which the prostate is the chief part, surrounding the beginning of the urethra.* Circular fibres of urethra, from the prostate to the bulb:

Action. This involuntary layer assists in moving forwards the urine and the semen. use.

The GLANDS OF COWPER will be found by cutting through some of the hinder fibres of the constrictor muscle. They are situated behind the membranous part of the urethra, one on each side of the middle line, and close above the bulb. Each gland is about the size of a pea, and is made up of small lobules. Cowper's glands: situation, size, and structure;

Connected with each is a minute duct, an inch or more in length, which perforates obliquely the wall of the urethra (corpus spongiosum), and opens into the canal about three-quarters of an inch in front of the triangular ligament. Its aperture in the ordinary state does not admit a bristle. The nature of the secretion of the gland is not known. length and termination of the duct;

These bodies are sometimes so small as to escape detection, and they appear to decrease in size with advancing age. they vary in size.

Dissection. The student may complete the examination of the perineum by tracing out on the left side the pudic vessels with their remaining branches, and the dorsal nerve of the penis. From the point of its division beneath the crus into two branches (dorsal of the penis, and cavernous), the artery is to be followed backwards along the bone: the nerve will be found by the side of, but deeper than the artery. Dissection of vessels and nerve.

The PUDIC ARTERY has already been dissected in the posterior half of the perineum (p. 421). At the front of the ischio-rectal fossa it penetrates the base of the triangular ligament, and then runs forwards close to the edge of the hip-bone (fig. 134, a), in a canal formed by the tendinous origin of the constrictor urethræ. About half an inch behind the symphysis pubis it pierces the inferior layer of the ligament, and immediately divides into the arteries of the cavernous structure and dorsum of the penis. It is accompanied by venæ comites and the dorsal nerve of the penis. Pudic artery: course and ending. Branches:—

a. *Deep muscular branches (d).* As the artery is about to enter between the layers of the triangular ligament it furnishes one Muscular.

* See a paper on the Arrangement of the Muscular Fibres of the Urethra, in vol. xxxix, 1856, of the Trans. of the Roy. Med. Chir. Society.

or more branches to the levator ani and sphincter, and fine twigs through the ligament to the constrictor and the urethra.

Artery of
bulb in the
triangular
ligament:

b. The *artery of the bulb* is a branch of considerable size, and arises near the base of the triangular ligament. Passing almost transversely inwards between the fibres of the constrictor muscle, about half an inch from the base of the triangular ligament, the artery reaches the upper surface of the bulb, and enters the spongy structure. Near the urethra it furnishes a small branch to Cowper's gland.

its situation
varies.

The distance of this branch from the base of the ligament will be influenced by its origin nearer the front or back of the perineal space. If the vessel arises earlier than usual, it may be altogether behind the ligament, and may cross the front of the ischio-rectal fossa, so as to be liable to be cut in the operation of lithotomy.

Artery of
body of
penis.

c. The *artery of the corpus cavernosum* (*c*) is one of the terminal branches of the pudic. At first this vessel lies between the crus penis and the bone, but it soon enters the crus, and ramifies in the cavernous structure of the penis (p. 577).

Artery of
dorsum of
penis.

d. The *dorsal artery of the penis* (*h*) is in direction the continuation of the pudic; it runs upwards between the crus and the bone, and reaches the dorsum of the penis by passing through the suspensory ligament. Its distribution with the accompanying nerve is noticed at page 440.

Accessory
pudic
artery:

Accessory pudic artery. In some cases the pudic artery is not large enough to supply the branches above described to the penis and the urethra. One or more offsets will then be contributed by an accessory vessel, which leaves the pelvis in front by piercing the triangular ligament. The source of this accessory artery is the internal iliac (p. 559).

source.

Pudic
veins.

The *pudic veins*, two in number, have frequent communications together, so as to form a plexus round the artery; they receive similar branches, except that the dorsal vein of the penis does not join them.

Dorsal nerve
of the penis.

The **DORSAL NERVE OF THE PENIS** has been seen in the ischio-rectal fossa (p. 422). In the anterior half of the perineum it takes a similar course to the pudic artery, but at a deeper level and in a distinct sheath, within the triangular ligament, and then pierces the superficial layer of that structure close to the inferior ramus of the pubis, to be continued with the dorsal artery to the penis. Its termination is described at p. 440. The nerve supplies filaments to the constrictor urethræ muscle.

Parts cut in
lithotomy,

in cutting
down to
urethra,

Parts cut in the lateral operation of lithotomy. This operation for stone in the bladder may be divided into three stages, viz., cutting down to the urethra, opening the canal, and slitting the tube and the neck of the bladder. In the external incision the knife is entered near the middle line of the perineum, one inch in front of the anus, and is drawn backwards on the left side as far as midway between the ischial tuberosity and the anus. The skin and fat, the transverse perineal muscle and artery, the inferior hæmorrhoidal vessels and nerve lying across the ischio-rectal fossa,

and possibly the superficial perineal vessels and nerves, will be cut in this first stage of the operation.

In the subsequent attempt to reach the staff, when the knife is introduced into the front of the wound, the hinder part of the triangular ligament and constrictor urethræ, and the fore part of the levator ani will be divided; and when the knife is placed within the groove of the staff, the membranous part of the urethra will be cut, with the muscular fibre about it. in reaching the staff,

Lastly, as the knife is pushed along the staff into the bladder, it incises in its progress the membranous portion of the urethra, part of the prostate with large veins around it, and the neck of the bladder. When the last two parts are being cut, the handle of the knife is to be raised, and the blade depressed; and the incision is to be made downwards and outwards, in the direction of a line from the urethra through the left lateral lobe of the prostate, above the level of the ejaculatory duct. and in running knife along staff.

Parts to be avoided. In the first incision in the ischio-rectal fossa, the rectum may be cut if the knife is turned inwards across the intestine, instead of being kept parallel with it; and if the gut is not held out of the way with the fore finger of the left hand. The pudic vessels on the outer wall of the ischio-rectal fossa may be wounded near the anterior part of the hollow, where they approach the margin of the triangular ligament; but, posteriorly, they are securely lodged inside the projection of the ischial tuberosity. Parts to be avoided are rectum, pudic vessels,

While making the deeper incisions to reach the staff, the artery of the bulb lies immediately in front of the knife, and will be wounded if the incisions are made too far forwards; but the vessel must almost necessarily be cut, when it arises farther back than usual, and crosses the front of the ischio-rectal fossa in its course to the bulb of the urethra. artery of bulb,

In the last stage of the operation the neck of the bladder should not be incised to a greater extent than is necessary for the extraction of the stone, lest the recto-vesical fascia separating the perineum from the pelvis should be divided, and the abdominal cavity opened. Too large an incision through the prostate may wound also an unusual accessory pudic artery on the side of that body. recto-vesical fascia and accessory pudic artery.

Directions. When the dissection of the perineum is completed, the flaps of skin are to be fastened together, after a preservative has been applied, and the limbs are to be put down for the examination of the abdomen. Directions.

SECTION II.

PERINEUM OF THE FEMALE.

The perineum in the female differs from that in the male more in the external form than the internal anatomy. On the surface it has special parts distinguishing it, viz., the aperture of the vagina Perineum of female has special parts.

and the surrounding vulva, which occupy the position of the scrotum in the male.

Apertures
of anus and
vulva.

Surface-marking.—*External organs of generation.* In the middle line there are the aperture of the anus and the cleft of the vulva, which are separated from one another by an interval of about an inch. The anus is situate a little farther back than in the male.

External
labia

The cleft or *rima* of the vulva is bounded at the sides by the *labia majora*, two prominent folds, thick and rounded in front, but becoming thinner as they pass backwards, which correspond to the scrotum of the male. The labia are formed externally by skin, which is provided with scattered hairs, and internally by mucous membrane. They are united in front and behind in the *anterior* and *posterior commissures*.

and com-
missures.

Clitoris.
Internal
labia.

Within the rima, at the fore part, is the *clitoris*, from which two folds of mucous membrane, the *labia minora* or *nymphæ*, extend backwards, one on each side of the aperture of the vagina. At its anterior end each nymphæ divides into two smaller folds, the outer of which unites with the one of the opposite side so as to form a kind of hood over the front of the clitoris—the *præputium clitoridis*, while the inner one, much shorter and thinner, is attached to the back of the clitoris in contact with its fellow, the two constituting the *frænulum clitoridis*.

Prepuce and
frænum of
clitoris.

Vestibule.

Enclosed by the labia minora, and between the clitoris and the orifice of the vagina, is a median recess about an inch and a half deep, which is called the *vestibule*. At the hinder part of the vestibule is the orifice of the urethra (*meatus urinarius*), surrounded by a slight eminence, about one inch behind the clitoris, and near the aperture of the vagina.

Opening of
urethra.

Aperture of
vagina.

The *orifice of the vagina* varies much in size; and in the child and virgin it is often partly closed behind by a thin semilunar fold of the mucous membrane—the *hymen*. After the destruction of the hymen small, irregularly shaped projections, the *carunculae myrtiformes*, are found in its place.

Hymen and
caruncles.

Fourchette
and fossa
navicularis.

At the back of the rima, within the posterior commissure of the labia, is a narrow transverse fold of the integument called the *fourchette* or *frænulum pudendi*; and to the interval between the frænulum and the commissure the name *fossa navicularis* is given.

Boundaries
alike in
both sexes.

Deep boundaries. The deep boundaries of the perineum are alike in both sexes; but in the female the outlet of the pelvis is larger than in the male.

Dissection.

Dissection. The steps of the dissection are much the same in both sexes, and the same description will serve, generally, for the male and female perineum.

Take first
ischio-rectal
fossa.

First, the dissection of the ischio-rectal fossa is to be made. Afterwards the muscles, vessels and nerves of the posterior half of the perineal space are to be examined. (See description of the male perineum, pp. 417 to 422).

Then ex-
amine ante-
rior half of
perineum.

Next, the skin is to be taken from the anterior half of the perineal space, as in the male; and the transverse incision in front is to be made at the anterior part of the vulva. The attachments of the

superficial fascia are then to be looked to, and the cutaneous vessels and nerves are to be traced beneath it (p. 422).

Superficial fascia. The description of this fascia in the male will serve for the like part in the female, with these modifications :—that in the female it is interrupted in the middle line, and is of less extent, in consequence of the aperture of the vulva ; and that it is continued forwards through the labia majora to the inguinal region. In the labia the superficial fascia contains involuntary muscular fibres, like the dartos tunic of the scrotum, as well as fat.

Superficial fascia.

Dartoid tissue.

The SUPERFICIAL PERINEAL VESSELS and NERVES, and the INFERIOR PUDENDAL NERVE have the same arrangement as in the male (p. 424) ; but they are distributed to the labia instead of to the scrotum.

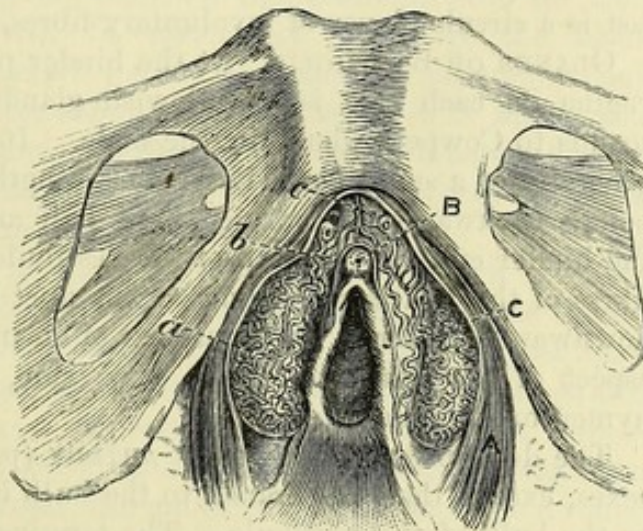
Superficial vessels and nerves.

Dissection. The labia and the superficial fascia are to be removed, to follow the sphincter muscle around the opening of the vagina.

Dissection of the muscles.

Two other muscles are exposed at the same time, viz., the erector clitoridis lying along the ramus of the ischium, and the transversus perinei passing across the perineum to the central point.

Fig. 136.*



Sphincter vaginae :

origin ;

The SPHINCTER VAGINÆ (bulbo-cavernosus ; fig. 136, A) is an orbicular muscle around the orifice of the vagina, and corresponds to the ejaculator urinæ in the male. Posteriorly it is attached

to the central point of the perineum, where it blends with the sphincter ani and transversus muscles ; and its fibres are directed forwards on each side of the vagina, to be inserted into the body of the clitoris. The muscle covers the bulb of the vestibule and the gland of Bartholin by the side of the entrance to the vagina.

insertion

Action. Like the other orbicular muscles, the sphincter diminishes that part of the vagina which it encircles ; and it assists in fixing the central point of the perineum.

The ERECTOR CLITORIDIS (ischio-cavernosus) resembles the erector of the penis in the male, though it is much smaller (p. 425).

Erector clitoridis.

The TRANSVERSUS PERINEI is similar to the muscle of the same name in the male. The one description will suffice for the muscle in both sexes (p. 426).

Superficial transverse muscle.

* Venous plexuses of the genital organs, and opening of the vagina (Kobelt). A. Sphincter vagina muscle. B. Clitoris. c. Nympha. a. Bulb of the vestibule. b. Venous plexus continuous with veins of the clitoris. c. Dorsal vein of the clitoris.

- To expose triangular ligament. *Dissection.* To see the triangular ligament of the urethra, the erector and the crus clitoridis are to be detached from the bone on the left side, and the corresponding half of the sphincter vaginae is to be removed.
- Triangular ligament. The TRIANGULAR LIGAMENT transmits the urethra, but is not quite so strongly marked as in the male (p. 427); it is interrupted to a large extent in the middle line by the aperture of the vagina.
- To see deep muscle. *Dissection.* By cutting through the superficial layer of the ligament in the same way as in the male (p. 428), the deep muscle, with the pudic vessels and their branches, and the dorsal nerve of the clitoris, will be arrived at.
- Deep transverse muscle. The TRANSVERSUS PERINEI PROFUNDUS is the representative of the constrictor urethrae of the male. It *arises* on each side from the pubic and ischial rami; and the fibres are directed inwards to be *inserted* mainly into the side of the vagina. The hindmost ones join the central point of the perineum; and anteriorly some are continued across from side to side in front of the urethra. Beneath the last is a circular layer of involuntary fibres, as in the other sex.
- Glands of Bartholin: GLANDS OF BARTHOLIN. At the hinder part of the entrance to the vagina on each side is a yellowish glandular body, which corresponds to Cowper's gland in the male. It has the shape and size generally of a small bean, its greatest length, which is directed from before backwards, measuring about half an inch. It lies close to the hinder end of the bulb of the vestibule, and is covered by the fibres of the sphincter vaginae. The duct is directed forwards and downwards for about three-quarters of an inch, to open on the inner aspect of the nympha of the same side, immediately below the hymen or its remains.
- shape and size; duct. The description of the PUDIC ARTERY (p. 429) will serve for both sexes, except that the branch to the bulb is small, and is furnished to the bulb of the vestibule. The terminal branches are the artery of the corpus cavernosum and the dorsal artery of the clitoris, and are also much smaller than the corresponding vessels in the male.
- Pudic vessels. The PUDIC NERVE has the same arrangement as in the male. From its perineal division proceed the two superficial nerves, branches to the superficial muscles, and an offset to the bulb. The dorsal nerve of the clitoris is of small size.
- Pudic nerve.

CHAPTER VIII.

DISSECTION OF THE ABDOMEN.

SECTION I.

WALL OF THE ABDOMEN.

THE dissection is to be carried as far as the end of SECTION III (p. 493), before the body is turned for the examination of the back.

Directions
for the
dissection.

Position. The body will be sufficiently raised by the blocks beneath the thorax and head for the dissection of the upper limbs and neck, but the dissector should see that the chest is higher than the pelvis. If the abdomen is flaccid, it may be inflated through an aperture in the umbilicus, but if it is firm, proceed with the dissection without blowing it up.

Position of
the body.

Surface-marking. On its anterior aspect the abdomen is pretty uniformly convex, especially in fat bodies; but at the side there is a slight hollow below the ribs, and a groove marks the position of the iliac crest. Along the middle line is a groove over the linea alba, which begins above in a depression over the ensiform process (*epigastric* or *infrasternal fossa*), and becoming gradually shallower below, ends a little beyond the umbilicus. The latter is a round, depressed cicatrix, situate nearer to the pubic bones than to the lower end of the body of the sternum, and opposite, as a rule, the disc between the third and fourth lumbar vertebrae. On each side of the median groove is the elevation of the rectus muscle, which is intersected in adult well-formed bodies by two or three transverse furrows.

Appear-
ances on the
surface of
the abdo-
men.

Pit of the
stomach.
Navel.

Over the lower ends of the recti and the adjacent parts of the pubic bones the surface is somewhat elevated, owing to a slight accumulation of fat; and the name *pubes* has been given to this part from its thick covering of hair. This projection is especially marked in front of the bones in the female, where it is distinguished as the *mons Veneris*. Beneath the eminence of the pubes the student will be able to recognize with his finger the symphysis pubis, and to trace outwards from it the osseous pubic crest, which leads to the prominent pubic spine. From this to the anterior superior iliac spine the curved *inguinal furrow* extends, separating the abdomen from the thigh. If the finger be carried along the furrow it will detect the firm band of Poupart's ligament, and sometimes one or two inguinal glands.

Eminence of
pubes.

Mons
Veneris.

Inguinal
furrow.

Poupart's
ligament.

Abdominal
rings,
outer,

and inner.

Raise the
skin from
the front.

Position of
cutaneous
nerves :

on the side ;

and in front.

Seek vessels

and nerves
in right
groin.

Separate
fascia in
left groin
into super-
ficial

and deep
layer.

Immediately above and to the outer side of the pubic spine the opening of the external abdominal ring may be felt ; and the prominence of the spermatic cord descending through it to the testicle may be detected. The internal abdominal ring is farther to the outer side, though it cannot be recognized on the surface with the finger ; but its position may be ascertained by taking a point midway between the symphysis pubis and the anterior superior iliac spine, and a finger's breadth above Poupart's ligament.

Dissection. The requisite incisions for raising the skin from the sides and front of the belly are the following :—One cut is to extend outwards over the side of the chest from the ensiform process to about midway between the sternum and the spine. A second incision is to begin at the symphysis pubis, and to be carried outwards along Poupart's ligament and the iliac crest till it ends opposite the first cut. Lastly, the hinder extremities of the two incisions are to be connected along the side of the chest and belly. The piece of skin thus marked out is to be raised towards the middle line, but is not to be taken away ; and the cutaneous vessels and nerves are to be sought in the fat at the side and front of the abdomen.

Along the side of the abdomen look for the lateral cutaneous nerves, five or six in number, which issue in a line with the corresponding nerves of the thorax. At first they lie beneath the fat, and divide into two : one offset is to be traced forwards, and the other backwards, with small cutaneous arteries. On the iliac crest, near the front, is a large branch from the last dorsal nerve ; and usually farther back on the crest, and deeper, is a smaller branch of the ilio-hypogastric nerve. Near the middle line the small anterior cutaneous nerves will be recognized with small arteries ; these are uncertain in number and size, and are to be followed outwards in the fat.

In the inguinal region the cutaneous vessels and nerves are to be dissected on the right side, and the superficial fascia on the left. For this purpose, all the fascia superficial to the vessels is to be removed from the right groin. The vessels which will then appear are the superficial pudic internally, the superficial epigastric in the centre, and an offset of the superficial circumflex iliac artery externally. Some inguinal glands lie along the line of Poupart's ligament. Two cutaneous nerves are to be sought :—one, the ilio-inguinal, comes through the external abdominal ring, and descends to the thigh and scrotum ; the other, ilio-hypogastric, appears in the superficial fascia above, and rather outside the abdominal ring.

In the examination of the superficial fascia on the left side two strata are to be made out, one over and one beneath the vessels. The layer that is superficial to the vessels is to be reflected by means of a transverse cut directed inwards from the front of the iliac crest, and by a vertical one near the middle line to the pubic bone. The subjacent vessels mark the depth of this layer ; and when these are reached, a triangular flap of the fascia is to be thrown towards the thigh. To define the thinner deep stratum, cut it across in the same manner as the other layer, and detach it carefully with the

vessels from the tendon of the external oblique muscle. This stratum, like the preceding, is to be traced around the cord to the scrotum ; and as the student follows it downwards, he will find it connected with Poupart's ligament, and blended with the fascia lata close below that structure.

The *superficial fascia* is a single layer over the greater part of the abdomen ; but in the groin it is divided into a subcutaneous and a deeper stratum by the vessels and the glands.

Superficial fascia is divided into two layers.

The *subcutaneous layer* contains the fat, and varies therefore in appearance and thickness in different bodies ; for it is sometimes divisible into strata, while at others it is very thin, and somewhat membranous near the thigh. It is continuous with the fatty covering of the thigh and abdomen ; and when traced to the limb, it is separated from Poupart's ligament beneath by the superficial vessels and glands. Internally it is continued to the penis and scrotum, where it changes its adipose tissue for involuntary muscular fibre ; and after investing the testicle, it is prolonged to the perineum.

The subcutaneous layer contains fat,

except in the penis and scrotum.

The *deeper layer* (fascia of Scarpa) is thinner and more membranous than the other, and is closely united to the tendon of the external oblique by fibrous bands along the linea alba. Like the subcutaneous part, this layer is continued upwards on the abdomen, and inwards to the penis and the scrotum, through which it is prolonged to the perineum, where it has attachments to the subjacent parts, as before specified (p. 423). Towards the limb, it ends a little below Poupart's ligament by joining the fascia lata across the front of the thigh.

Deeper layer is thin and membranous ; special characters and disposition ;

and ends on fascia lata.

Urine effused in the perineum from rupture of the urethra will be directed through the scrotum and along the spermatic cord to the abdomen (p. 424). From the arrangement of the deeper layer of the fascia across the thigh, it is evident that the fluid cannot pass down the limb, though its progress over the front of the abdomen is uninterrupted.

Attachments determine course of effused urine.

In the female the superficial fascia of the groin is separable into two layers, and the disposition of each is nearly the same as in the male ; but the part that is continued to the scrotum in the one sex, enters the labium in the other. In the female the round ligament of the uterus is lost in it.

Fascia in the female.

CUTANEOUS NERVES. The skin of the abdomen is supplied mainly by the lower intercostal nerves : thus, the cutaneous branches along the side of the belly are offsets from five or six of those nerves ; and the cutaneous branches along the front are the terminal parts of the same trunks. Two other cutaneous offsets from the lumbar plexus, viz., ilio-hypogastric and ilio-inguinal, appear at the lower part of the abdomen.

Cutaneous nerves

are derived from two sources.

The **LATERAL CUTANEOUS NERVES** of the abdomen emerge between the digitations of the external oblique muscle, in a line with the same set of nerves on the thorax ; and the lowest are the most posterior. As soon as they reach the surface they divide, with the exception of the last, into an anterior and a posterior branch :—

Lateral cutaneous of intercostal, which divide into

- posterior and
anterior branches.
The *posterior branches* are small, and are directed back to the integuments over the latissimus dorsi muscle.
- The *anterior branches* are continued forwards nearly to the edge of the rectus muscle, and increasing in size from above down, supply the integuments on the side of the belly : they furnish offsets to the digitations of the external oblique muscle.
- Last dorsal nerve.
The *lateral cutaneous branch of the last dorsal nerve* is larger than, and does not divide like the others. After piercing the fibres of the external oblique muscle, it is directed over the iliac crest to the surface of the gluteal region (p. 631).
- Anterior cutaneous nerves of intercostal.
The ANTERIOR CUTANEOUS NERVES of the abdomen pierce the sheath of the rectus : in the integuments they bend outwards towards the lateral cutaneous nerves. The number and the situation of these small nerves are very uncertain.
- Ilio-hypogastric of lumbar plexus :
The ILIO-HYPOGASTRIC NERVE is distributed by two pieces : one passes over the crest of the ilium (iliac branch) ; the other ramifies on the lower part of the abdomen (hypogastric branch) :—
- iliac branch,
(a) The *iliac branch* lies close to the crest of the hip-bone near the last dorsal nerve, and enters the fat of the gluteal region (p. 632).
- hypogastric branch.
(b) The *hypogastric branch* pierces the aponeurosis of the external oblique muscle above the abdominal ring, and is distributed to the skin of the lower part of the abdomen.
- Ilio-inguinal nerve of the plexus.
The ILIO-INGUINAL NERVE becomes cutaneous through the external abdominal ring, and descends to the teguments of the scrotum, and upper and inner part of the thigh.
- Vessels with nerves ;
CUTANEOUS VESSELS. Cutaneous vessels run with both sets of nerves on the abdomen ;—with the lateral cutaneous nerves are branches from the intercostal arteries ; and with the anterior cutaneous are offsets from the internal mammary and epigastric vessels. In the groin are three small superficial branches of the femoral artery, viz., pudic, epigastric, and circumflex iliac.
- both lateral
The LATERAL CUTANEOUS ARTERIES have the same distribution as the nerves they accompany. The anterior or chief offsets are directed towards the front of the abdomen, and end about the outer edge of the rectus muscle.
- and anterior cutaneous.
The ANTERIOR CUTANEOUS ARTERIES are irregular in number and in position, like the nerves. After piercing the sheath of the rectus, they run outwards with the nerves towards the other set of branches.
- From femoral artery three branches ;
BRANCHES OF THE FEMORAL ARTERY. Three cutaneous offsets ascend from the thigh between the layers of the superficial fascia, and ramify in the integuments of the genital organs and lower part of the abdomen. The beginning of these vessels appears in the dissection of the thigh.
- external pudic,
The *external pudic branch* (superficial) crosses the spermatic cord, to which it gives offsets, and ends in the integuments of the under part of the penis.
- superficial epigastric
The *superficial epigastric branch* ascends over Poupart's ligament,

near the centre, and is distributed in the fat nearly as high as the umbilicus.

The *circumflex iliac branch* lies below the level of Poupart's ligament, and sends only a few offsets upwards to the abdomen. circumflex iliac.

The companion *veins* to these arteries join the internal saphenous vein of the thigh. Veins.

The LYMPHATIC GLANDS OF THE GROIN are three or four in number, and lie along the line of Poupart's ligament. They are placed between the strata of the superficial fascia; and receive lymphatics from the abdominal wall, from the gluteal region and perineum, from the upper and outer portion of the thigh, and from the superficial parts of the genital organs. Their efferent ducts pass downwards to the saphenous opening in the thigh to enter the abdomen. Inguinal glands :
ducts enter abdomen.

Dissection. After the examination of the superficial fascia with its vessels and nerves, the student may prepare the cutaneous coverings of the penis and scrotum. The skin should be divided along the dorsum of the penis, and thrown to each side; and the skin of the scrotum is to be reflected on the left side by means of a vertical incision. Dissection of coverings of penis and testicle.

CUTANEOUS COVERINGS OF THE PENIS AND SCROTUM. The penis is attached to the front of the pelvis by a suspensory ligament, and is provided with a tegumentary covering continuous with that of the abdomen, but devoid of fat. Tegumentary covering of penis is thin, and without fat,

Around the end of the penis it forms the loose sheath of the prepuce in the following way:—When the skin has reached the extremity, it is reflected backwards as far as the base of the glans, constituting thus a sheath with two layers—the *prepuce*; it is afterwards continued over the glans, and joins the mucous membrane of the urethra at the orifice on the surface. At the under part of the glans and behind the aperture of the urethra, the integument forms a small triangular fold, *frænum præputii*. forms prepuce
and frænum.

Where the skin covers the glans, it is inseparably united with that part, is very thin and sensitive, being provided with papillæ, and assumes in some cases the characters of a mucous membrane. Behind the glans are some sebaceous follicles—*glandulæ odoriferæ*. Sebaceous glands.

In the scrotum the two layers of the superficial fascia of the groin become united in a thin membrane of a reddish colour. The prolongation around the testicle on one side is separate from that on the other side; and the two pouches, coming in contact in the middle line, form the *septum scroti*. Teguments in scrotum.

The subcutaneous layer in the scrotum, penis, and front of the perineum contains involuntary muscular fibres, to which the corrugation of the skin is owing. This contractile structure is named the *dartoid tissue*. Muscular nature of fascia.

Dissection. By removing all the fatty tissue from the root of the penis and the front of the symphysis pubis, the suspensory ligament will be defined. And the dorsal arteries and nerves, with the dorsal vein of the penis, which will be partly laid bare, are to be followed forwards to the glans. Dissection of vessels and nerves.

The *suspensory ligament of the penis* is a band of fibrous tissue, Suspensory

ligament
of penis ;
attach-
ments ;
contains
vessels and
nerves.
Source of
vessels and
nerves.

of a triangular form, which is attached by its apex to the front of the symphysis pubis. Widening below, it is fixed to the upper surface of the body of the penis, and is prolonged for some distance on the organ. Perforating the ligament at its junction with the penis are the dorsal vessels and nerves.

DORSAL VESSELS AND NERVES. The arteries and nerves on the dorsum of the penis are branches of the pudic trunks of both sides (p. 430). The vein accompanying the arteries enters the pelvis below the symphysis pubis.

Dorsal
artery of
penis.

The **DORSAL ARTERY**, one on each side, pierces the suspensory ligament, and extends forwards to the glans, where it ends in many branches for that structure : in its course the vessel supplies the integuments and the body of the penis. It may be derived from the accessory pudic (p. 430).

Dorsal vein
ends in
prostatic
plexus.

The **DORSAL VEIN** is a single trunk, and commences by numerous branches from the glans penis and the prepuce. It runs backwards, between the two arteries, through the suspensory ligament, and then through a special opening below the subpubic ligament (p. 428), to join the prostatic plexus of veins. The vein receives branches from the erectile structure and the integuments of the penis.

Dorsal nerve
of pudic.

Each **DORSAL NERVE** takes the same course as the artery, and ends like it in numerous branches to the glans penis. It furnishes twigs to the corpus cavernosum penis, and other offsets to the integuments of the dorsum, sides, and prepuce of the penis.

Vessels on
clitoris.

In the female these vessels and nerves are much smaller than in the male, and occupy the upper surface of the clitoris—the organ that represents the penis.

To expose
external
oblique
muscle.

Dissection of the muscles. The surface of the external muscle of the abdominal wall (fig. 137) is now to be freed from fascia on both sides of the body.

Precautions.

It is not advisable to begin cleaning this muscle in front, because there it has a thin aponeurosis, which may be taken away too readily with the fat. Beginning the dissection at the posterior part, the student is to carry the knife obliquely upwards and downwards in the direction of the fibres. The thin aponeurosis before referred to is in front of a line extended upwards from the anterior end of the iliac crest ; and as the dissector approaches that spot, he must be careful not to injure the tendon, more particularly above, where it lies on the margin of the ribs, and is very indistinct.

To define
abdominal
ring.

On the right side the external abdominal ring (c) may be defined, to show the spermatic cord passing through it ; but on the left side a thin fascia (intercolumnar), which is connected with the margin of that opening, is to be preserved. Lastly, the free border of the external oblique should be made evident between the last rib and the iliac crest.

On the side
are three
flat muscles,

MUSCLES OF THE ABDOMINAL WALL. On the side of the abdomen are three large flat muscles, which are named from their position to one another, and from the direction of their fibres. The most superficial muscle is the external oblique ; the underlying one, the internal oblique ; and the deepest, the transversalis.

Nearer the middle line are placed other muscles which have a vertical direction. In front lie the rectus and pyramidalis, and behind is the quadratus lumborum: these are encased by sheaths derived from the aponeuroses of the lateral muscles.

the aponeuroses of which encase three vertical.

The EXTERNAL OBLIQUE MUSCLE (fig. 137, A) is fleshy on the side, and aponeurotic on the fore part of the abdomen. It arises by fleshy processes from the eight lower ribs, the five highest pieces alternating with similar parts of the serratus magnus, and the lowest three with slips of the latissimus dorsi muscle. From the attachment to the ribs the fibres are directed over the side of the abdomen to end in the following manner:—the lower ones descend almost vertically to be inserted into the anterior half or more of the iliac crest, at the outer margin; and the upper and middle fibres are continued forwards obliquely to the tendon or aponeurosis on the front of the belly.

External oblique muscle: origin from ribs;

The aponeurosis occupies the front of the abdomen, internal to a line drawn from the prominence of the ninth rib-cartilage to a point about an inch and a half in front of the anterior superior iliac spine; and it is broader below than above. Along the middle line this expansion ends in the *linea alba*—the common place of union of the aponeuroses of opposite sides. Above, it is thin, and is continued over the thorax to the pectoralis major muscle. Below, its fibres are stronger and more distinct than above, and are directed obliquely downwards and inwards to the pelvis;—some of them are fixed to the front of the pubis; and the rest are collected into a firm band, *Poupart's ligament* (B), between the pubic spine and the iliac crest.

insertion into pelvis and linea alba.

Aponeurosis covers front of the belly:

disposition above and below.

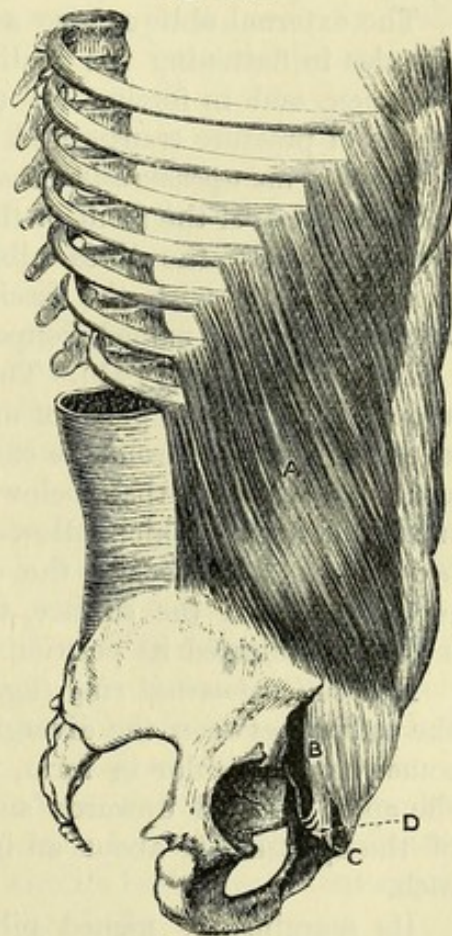


Fig. 137.*

Relations. The muscle is subcutaneous. Its posterior border is unattached between the last rib and the iliac crest, but is overlapped commonly by the edge of the latissimus dorsi, except for a short distance below. At the outer part of the aponeurosis is a curved white line, the *linea semilunaris*, marking the outer edge of the rectus muscle (fig. 141); and crossing between this and the linea alba are three or four somewhat irregular lines—the *lineæ transversæ*.

Lines on the aponeurosis:

* A. External oblique muscle. B. Poupart's ligament. c. External abdominal ring. D. Gimbernat's ligament.

apertures in it :	Numerous small apertures in the tendon transmit cutaneous vessels and nerves ; and near the pubis is the large opening of the external abdominal ring (c), which gives passage to the spermatic cord in the male, and to the round ligament in the female.
abdominal ring.	
Use of both muscles, acting from pelvis, and thorax :	<i>Action.</i> Both muscles taking their fixed point at the pelvis will bend the trunk forwards ; but supposing the spine fixed, they will draw down the ribs. If they act from the thorax they will elevate the pelvis.
one muscle acting ;	Should one muscle contract it will incline the trunk to the same side, or raise the pelvis, according as the upper or the lower attachment may be moveable ; or if the trunk is prevented from being bent, it will turn the thorax to the opposite side.
influence on abdominal cavity.	The external oblique also acts powerfully with the other broad muscles in flattening the wall and diminishing the cavity of the abdomen, and in forcing up the diaphragm during expiration by means of pressure transmitted through the abdominal viscera.
	<i>Parts of the aponeurosis.</i> Besides the general arrangement of the aponeurosis over the front of the abdomen, the student is to examine more minutely the linea alba in the middle line, the external abdominal ring with the fascia prolonged from its margin, and the thickened border named Poupart's ligament.
In the linea alba the aponeuroses are united :	<i>Linea alba</i> (fig. 141). This white band on the front of the abdomen marks the place of meeting of the aponeuroses of opposite sides. It extends from the ensiform process to the pubic symphysis, and is wider above than below. It is perforated here and there by small apertures, which allow pellets of fat to protrude in some bodies. A little below the centre is the umbilicus, which now projects beyond the surface, though before the skin was removed, a hollow indicated its position.
below middle is umbilicus.	
External abdominal ring :	<i>External abdominal ring</i> (fig. 137, c). This opening is situate near the pubis, between the diverging fibres of the aponeurosis. It is somewhat triangular in form, with the base at the pubic crest, and the apex directed upwards and outwards. The long measurement of the aperture is about an inch, and the transverse about half an inch.
form and situation ;	
size ;	
inner side or pillar ;	Its margins are named pillars, and differ in form and strength. The inner one, thin and straight, is attached below to the front of the symphysis pubis, where it decussates with the corresponding piece of the opposite side. The outer margin is stronger, and is
outer pillar ;	curved, so as to form a kind of groove for the support of the spermatic cord : this margin is continuous with Poupart's ligament, and is attached below to the pubic spine. A thin membrane (intercolumnar fascia), derived from some fibres on the surface of the aponeurosis, covers the opening.
fascia prolonged from margin ;	
objects passing through.	The ring gives passage in the male to the spermatic cord, and in the female to the round ligament ; and in each sex the transmitted part lies on the outer pillar as it passes through, and obtains a covering from the intercolumnar fascia. Through this aperture an inguinal hernia protrudes from the wall of the abdomen.
Intercolumnar fibres :	The <i>intercolumnar fibres</i> run transversely on the surface of the

aponeurosis, and bind together its parallel fibres, so as to construct a firm membrane. Inferiorly, where they are strongest, some well-marked bundles are connected with the outer third of Poupart's ligament, and the anterior end of the iliac crest. At the external abdominal ring the fibres stretch from side to side, and close the upper end of that opening ; and as they are prolonged on the cord from the margin of the ring, they give rise to a membrane named the *intercolumnar* or *spermatic fascia*. On the left side, where the fascia is entire, this thin covering will be manifest on the surface of the cord, or on the round ligament in the female.

attachment inferiorly ;

they produce inter-columnar fascia.

Dissection. To see the attachments and connections of Poupart's ligament, it will be necessary to reflect, on both sides of the body, the lower part of the aponeurosis towards the thigh, as in fig. 142. For this purpose an incision is to be carried inwards, through the aponeurosis, from the front of the iliac crest to a spot about three inches from the linea alba ; and the tendon is to be detached from the subjacent parts with the handle of the scalpel. When the aponeurosis cannot be separated farther from the tendons beneath, near the linea alba, it is to be cut in the direction of a line descending to the symphysis pubis.

To see insertion of Poupart's ligament,

throw down piece of external oblique,

After the triangular piece of the aponeurosis has been thrown towards the thigh, the spermatic cord is to be dislodged from the surface of Poupart's ligament, to see the insertion of this band into the pubis, and to lay bare the fibres (triangular fascia) which ascend therefrom to the linea alba.

and show triangular fascia.

Poupart's ligament (fig. 138, D) is the lower border of the aponeurosis of the external oblique, which is thickened and folded backwards, so as to form a slight groove with the concavity upwards. In the hollow of the ligament the lowest fibres of the internal oblique and transversalis muscles, and the cremaster take their origin. Externally it appears round and cord-like, and is attached to the anterior superior iliac spine. Internally it widens as it approaches the pubis (fig. 137, D), and is inserted into the pubic spine and the pectineal line of the hip-bone for about three-quarters of an inch, forming a triangular piece with its base directed outwards, which is named *Gimbernat's ligament* (fig. 140).

Poupart's ligament :

outer and inner attachments ;

forms Gimbernat's ligament ;

By its lower border Poupart's ligament joins the fascia lata of the thigh ; and so long as this membrane remains uncut, the band is curved with its convexity downwards, especially when the limb is extended on the trunk. The outer half of the ligament is oblique, and is firmly united with the subjacent iliac fascia : its inner half is placed over the vessels passing from the abdomen to the thigh.

its direction,

and parts in contact with it.

Triangular fascia. From the insertion of Gimbernat's ligament into the pectineal line, some fibres are directed upwards and inwards to the linea alba, where they blend with the other tendons. As the fibres ascend, they diverge and form a thin sheet, to which the above name has been given.

Triangular fascia.

Dissection. The upper part of the external oblique is now to be taken away, on both sides of the body, to see the parts beneath. It may be detached by carrying the scalpel through the digitations on

Dissection to expose internal oblique.

the ribs back to the free border, and then through the insertion into the iliac crest. The muscle is to be thrown forwards as far as practicable, after the nerves crossing the iliac crest are dissected out; but in raising it care must be taken not to detach the rectus muscle from the ribs above, nor to cut through the tendon of the internal oblique at the upper part. By the removal of the fatty tissue the underlying internal oblique muscle, with some nerves issuing through it below, will be prepared.

Clean the cremaster.

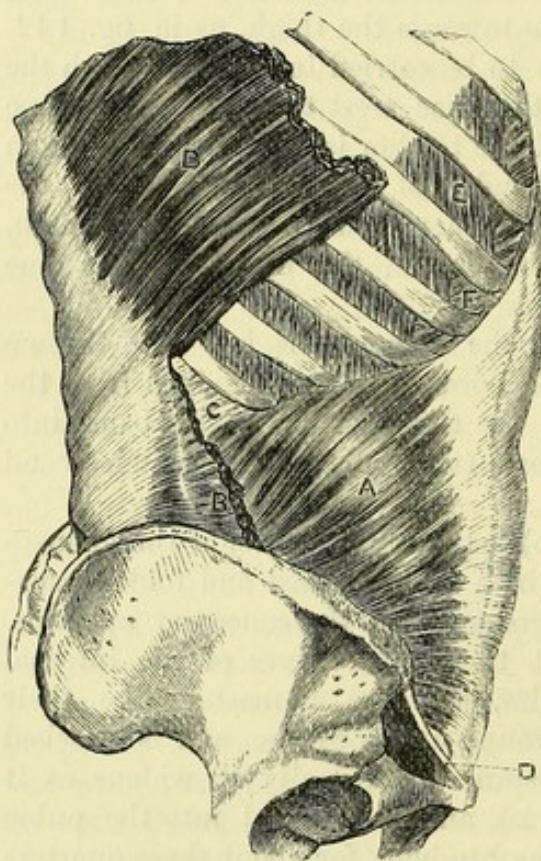
At the lower border of the internal oblique the cremaster muscle

on the cord is to be defined (fig. 139): it is about as wide as the little finger, and consists of fleshy loops which descend through the external abdominal ring. Its inner attachment is tendinous, and is easily taken away.

Parts covered by the external oblique (fig. 138). Beneath the external muscle are the internal oblique, with the ribs and the intercostal muscles. At the lower part of the abdomen the muscle conceals the spermatic cord, and the branches of the lumbar plexus in the abdominal wall.

The INTERNAL OBLIQUE MUSCLE (fig. 138, A) is fleshy at the side and aponeurotic in front, like the preceding; but its fibres (except the lowest) ascend across those of the external oblique. The muscle *arises* from the outer

Fig. 138.*



Parts covered by external oblique.

Internal oblique muscle:

origin from pelvis;

insertion into the ribs and linea alba.

Aponeurosis divides to enclose rectus,

half of Poupart's ligament, from the anterior two-thirds of the crest of the ilium, and from the tendon of the transversalis muscle (fascia lumborum; c) in the interval between that bone and the last rib. The fibres diverge on the abdomen to their destination:—The upper ones ascend, and have a fleshy *insertion* into the cartilages of the last three ribs, where they join the internal intercostal muscles of the lowest two spaces. The remaining fibres pass forwards, with varying degrees of obliquity, to the aponeurosis.

The *aponeurosis* of the muscle extends from the thorax to the pelvis, and is broader above than below. For the most part it is

* A. Internal oblique muscle. B. Latissimus dorsi, cut. C. Part of the hinder tendon of the transversalis muscle. D. Poupart's ligament. E. External, F. Internal intercostals.

split to encase the rectus; but in the lower half of the space between the umbilicus and pubis it is undivided, and lies altogether in front of that muscle. Along the middle line the two layers are united together, as well as with those of the opposite side, in the linea alba. Superiorly it is arranged in the following manner:— for a short distance before it divides, the aponeurosis is fixed to the ninth costal cartilage; and the posterior layer continues this attachment along the eighth and seventh cartilages to the ensiform process; while the anterior layer is prolonged over the chest, being blended with the aponeurosis of the external oblique. Inferiorly its fibres become more distinct and separate from each other, and are inserted into the front of the pubis, and into the pectineal line for half an inch behind the attachment of Gimbernat's ligament.

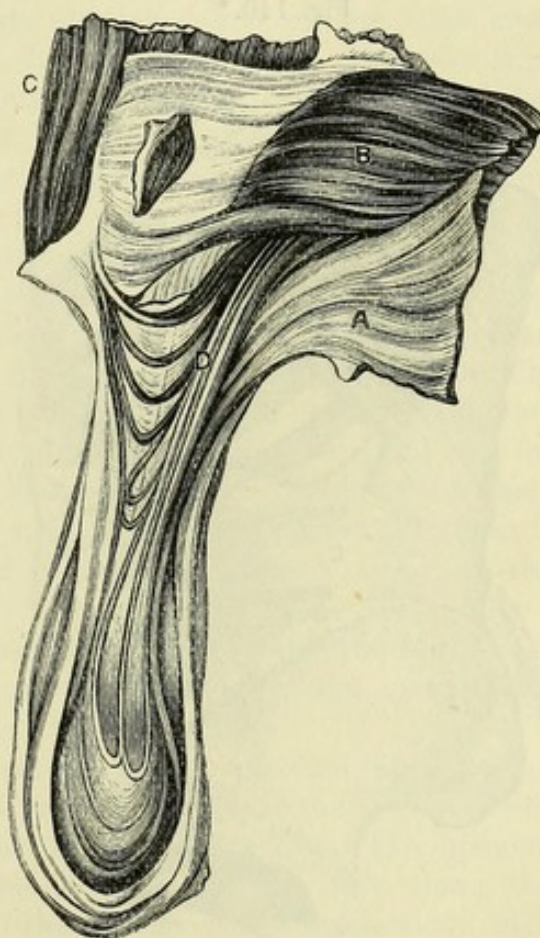
Relations. The internal is covered by the external oblique muscle. It is attached on all sides, except between Poupart's ligament and the pubis, where it arches over the cord, and has the cremaster muscle contiguous to it. The parts covered by the internal oblique will be seen when the muscle is reflected.

Action. Both muscles will depress the ribs, and will assist in forcing back the viscera of the belly, which have been protruded by the descent of the diaphragm.

One muscle may incline the body laterally; and contracting with the opposite external oblique (the fibres of the two having the same direction) it will rotate the trunk to the same side.

The CREMASTER MUSCLE (fig. 139, D) is a muscular slip which lies along the lower border of the internal oblique, and is named from suspending the testicle. The muscle has attachments, at the inner and outer sides, similar to those of the lowest fibres of the internal oblique. Externally it is fleshy, and arises from Poupart's ligament below, and in part beneath the internal oblique, with which some of the fibres are connected. Internally it is narrow, and is

Fig. 139.*



and pelvis.

Parts in contact with internal oblique.

Use of both muscles,

of one.

Cremaster muscle:

attachments; external fleshy,

* View of the lower part of the internal oblique, with the cremaster muscle and the testicle. A. External oblique, reflected. B. Internal oblique. C. Rectus abdominis. D. Cremaster, with its loops over the spermatic cord and the testicle.

internal tendinous ; *inserted* by tendon into the front of the pubis, joining the tendon of the internal oblique.

forms loops over the cord, Between the two points of attachment the fibres descend on the front and sides of the cord, forming loops with the convexity downwards, which reach to and over the testis. The bundles of fibres are united by areolar tissue so as to give rise to a covering on the front of the cord, which is named the *cremasteric fascia*. Occasionally the fibres may be behind as well as on the sides and front of the cord.

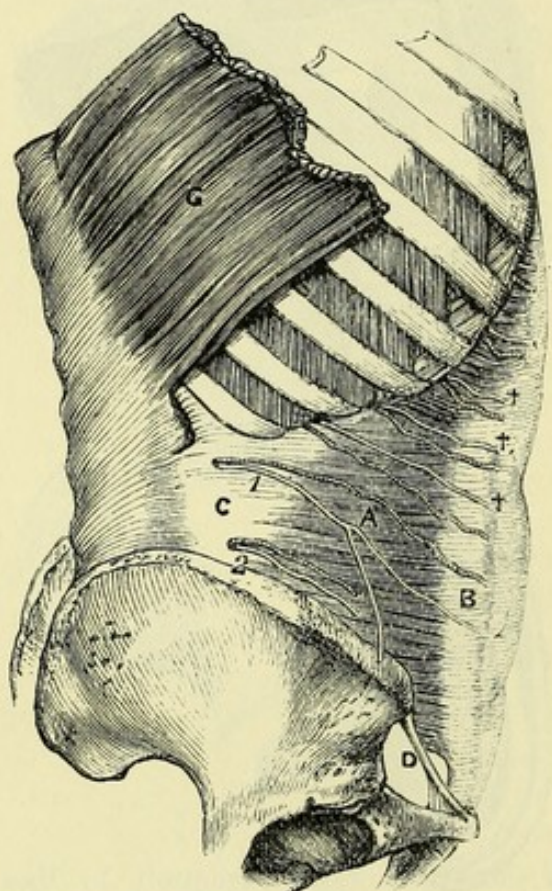
use. *Action*. It elevates the testicle towards the abdomen, and in some cases is under the influence of the will ; but it may be excited to contract involuntarily by cold, fear, &c.

Fig. 140.*

In left groin replace the parts.

On right side reflect cremaster

and internal oblique.



Dissection. On the left side of the body the student is not to make any farther dissection of the abdominal wall ; and the layers that have been reflected in the groin should be replaced, until the examination of that region is resumed in connection with hernia.

On the right side the dissection is to be carried deeper by the removal of the internal oblique and the cremaster. The last muscle may be reflected from the cord by means of a longitudinal incision.

To raise the internal oblique, it will be necessary to cut it through firstly near the ribs, secondly along the crest of the ilium and

Poupart's ligament, and lastly at the hinder part, so as to connect the first two incisions. Its depth will be indicated by a fatty layer between it and the transversalis, and by a branch of artery between the two muscles near the anterior superior iliac spine (fig. 142, *b*). In raising the muscle towards the edge of the rectus, let the student separate with great care the lower fibres from those of the transversalis, with which they are often conjoined ; and dissect out, between the two, the intercostal nerves and arteries, and the two branches of the lumbar plexus (ilio-hypogastric and ilio-inguinal) near the

* A. Transversalis muscle, with B, its anterior, and C, its posterior tendon (fascia lumborum). D. Poupart's ligament. 1. Last dorsal nerve with its accompanying artery. 2. Ilio-hypogastric nerve with its artery. ++ Intercostal nerves and arteries.

fore part of the ilium. The offsets entering the muscle must be cut.

Parts covered by the internal oblique (fig. 140). The internal oblique conceals the transversalis muscle, and the vessels and nerves between the two. Near Poupart's ligament it lies on the spermatic cord and the transversalis fascia. The rectus muscle is covered below by the aponeurosis.

Parts covered by internal oblique.

The TRANSVERSALIS MUSCLE (fig. 140, A) forms the third stratum in the wall of the abdomen, and differs from the two oblique muscles in having a posterior as well as an anterior aponeurosis. Like the internal oblique it is attached on all sides, except where the spermatic cord lies. At the pelvis it *arises* from the outer third of Poupart's ligament, and the anterior two-thirds of the iliac crest along the inner border; at the chest it takes origin by fleshy slips from the inner surface of the lower six costal cartilages; and between the chest and the pelvis it is connected with the lumbar vertebræ by means of the posterior aponeurosis or the fascia lumborum. All the fibres are directed to the aponeurosis in front.

Transversalis muscle:

origin from chest, loins and pelvis

fibres end in aponeurosis.

Its *anterior aponeurosis* is widest in the centre, and narrowest at the upper end. Internally it is continued to the linea alba, passing beneath the rectus as low as midway between the umbilicus and the pubis, but in front of the muscle below that spot. Its attachment below to the pelvis is nearly the same as the internal oblique; for it is fixed to the front of the pubis, and to the pectineal line for about an inch, but beneath the oblique muscle. Some of the fibres end on the transversalis fascia, and are connected beneath Poupart's ligament with a thickened band of that fascia which is called the deep crural arch.

The aponeurosis passes behind rectus, except in lower part.

Fibres to transversalis fascia.

Action. The transversalis muscle draws downwards the lower ribs, and diminishes the abdominal cavity, compressing the viscera and forcing upwards the diaphragm.

Use.

Conjoined tendon. The aponeuroses of the internal oblique and transversalis muscles are united more or less near their attachment to the pubis, and give rise to the conjoined tendon. The aponeurosis of the oblique muscle extends about half an inch along the pectineal line; while that of the transversalis reaches an inch along the bony ridge, and forms the greater part of the conjoined tendon.

At pelvis unites in conjoined tendon.

The *posterior aponeurosis* of the transversalis, or the fascia lumborum (c), is described in the dissection of the back, p. 386.

Posterior aponeurosis.

Relations. Superficial to the transversalis are the two muscles before examined; and beneath it is the thin transversalis fascia. Its fleshy attachments to the ribs alternate with like processes of the diaphragm; and the highest slip joins the lower edge of the triangularis sterni muscle. The lower border of the transversalis is fleshy in the outer, but tendinous in the inner half, and is arched above the internal abdominal ring.

Relations of transversalis muscle.

Dissection. To remove the aponeurotic layer from the rectus muscle of the right side, make a longitudinal incision through the tendinous sheath, and turn it to each side. As the fascia is reflected,

Expose rectus and pyramidalis.

its union with three or more tendinous bands across the rectus will have to be cut through; and near the pubis a small muscle, the pyramidalis, will be exposed. The dissector should leave the nerves entering the outer border of the rectus.

Leave the
left side.

On the left side of the body the rectus should not be laid bare below the umbilicus, in order that the special dissection of the parts concerned in inguinal hernia may be made on this side.

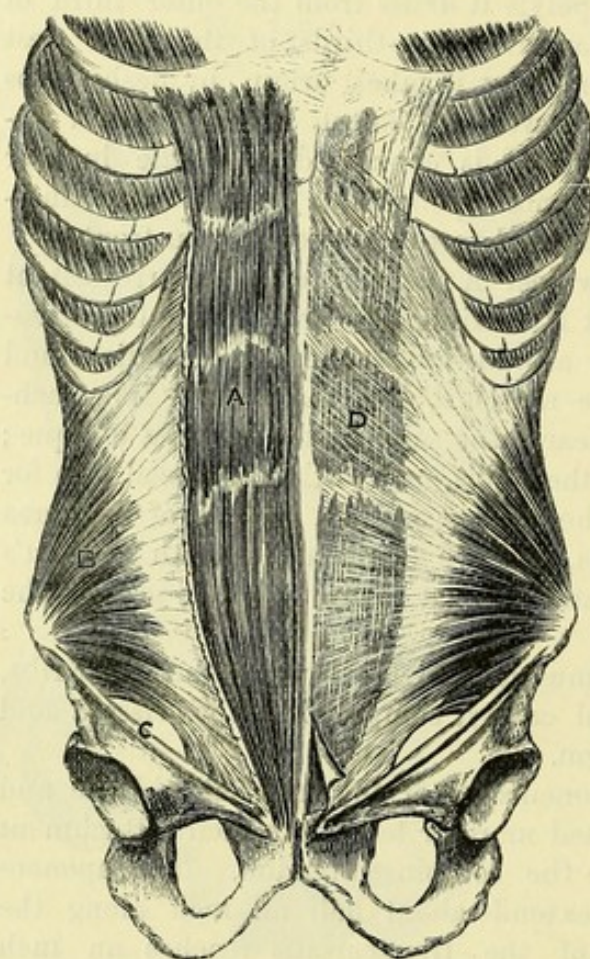
Rectus
muscle:

The RECTUS MUSCLE (fig. 141, A) extends along the front of the abdomen from the pelvis to the chest. It is narrowest below, where

origin from
pubis;

Fig. 141.*

insertion
into rib-
cartilages;



has cross
tendons;

it arises from the pelvis by two tendinous processes:—one, the internal and smaller, is attached to the front of the symphysis pubis in common with that of the opposite side; and the external process springs from the pubic crest. Becoming wider towards the thorax, the rectus is inserted by three large fleshy and tendinous slips into the cartilages of the last three true ribs, the outermost slip usually extending to the bone of the fifth rib. Some of the inner fibres are often attached to the ensiform process.

The muscle is contained in an aponeurotic sheath, except above and below; and its fibres are interrupted at intervals by irregular tendinous lines—the *inscriptiones tendineae*.

use on
trunk,
on abdomen.

Action. It will draw down the thorax and the ribs, or raise the pelvis, according as its fixed point may be above or below. Besides imparting movement to the trunk, it will diminish the cavity of the abdomen, and compress the viscera.

Its sheath:

how formed;

Sheath of the rectus (D). This sheath is derived from the splitting of the aponeurosis of the internal oblique at the outer edge of the rectus. One piece passes before, and the other behind the muscle; and the two unite at the inner border so as to complete the sheath. Inseparably blended with the stratum in front of the rectus is the

* Rectus muscle of the abdomen, dissected on the right side, and in its sheath on the left. Close to the pelvis the pyramidalis is exposed. A. Rectus. B. Internal oblique. C. Poupart's ligament. D. Anterior layer of the sheath of the rectus.

aponeurosis of the external oblique ; and joined in a similar manner with that behind, is the aponeurosis of the transversalis. The anterior layer of the sheath adheres closely to the tendinous intersections of the muscle.

The sheath is deficient behind, both at the upper and lower end of the muscle. Above, the muscle rests on the ribs, without the intervention of the sheath, which is fixed to the margin of the thorax. Below, at, or somewhat above, a point midway between the umbilicus and pubis, the aponeurosis of the internal oblique ceases to split, and then passes altogether in front of the rectus, with the other aponeuroses. When the rectus is raised, the termination of the hinder layer of the sheath is seen to be marked by a more or less distinct white line, concave towards the pubis, which is termed the *semilunar fold of Douglas* : below this the rectus is in contact with the transversalis fascia.

deficient
above and
below.

Fold of
Douglas.

The *lineæ transversæ* (fig. 141) on the front of the sheath are caused by the tendinous intersections of the rectus. The most constant are three in number, and have the following position ; one is opposite the umbilicus, another at the lower end of the ensiform process, and the third midway between the two. If there is a fourth it will be placed below the umbilicus. These markings seldom extend the whole depth or breadth of the muscular fibres, more particularly above and below.

Lineæ
transversæ
are three or
more ;
situation.

Linea semilunaris (fig. 141). This line corresponds with the outer edge of the rectus, and reaches from the cartilage of the ninth rib to the pubic spine of the hip-bone : it marks the line of division of the aponeurosis of the internal oblique muscle.

Linea semi-
lunaris
is at edge of
rectus.

The PYRAMIDALIS MUSCLE (fig. 141) is triangular in form, and is placed in front of the lower end of the rectus. It *arises* by its base from the front of the pubis, and is *inserted* into the linea alba below the mid-point between the umbilicus and the pelvis. This small muscle is often absent.

Pyramidalis
muscle :
attach-
ments ;

Action. The muscle renders tense the linea alba ; and when large it may assist slightly the rectus in compressing the viscera.

use.

NERVES OF THE ABDOMINAL WALL (fig. 140). Between the internal oblique and transversalis muscles are situate the intercostal nerves ; and near the pelvis are two branches of the lumbar plexus, viz., the ilio-hypogastric and ilio-inguinal nerves. Some arteries accompany the nerves, but they will be referred to with the vessels of the abdominal wall (p. 453).

Nerves in
wall of
abdomen.

The LOWER FIVE INTERCOSTAL NERVES († †) enter the wall of the abdomen from the intercostal spaces. Placed between the two deepest lateral muscles, the nerves are directed forwards to the edge of the rectus, and through this muscle to the surface of the abdomen near the middle line (p. 438). About midway between the spine and the linea alba, the nerves furnish cutaneous branches to the side of the abdomen (lateral cutaneous ; p. 437) ; and while between the abdominal muscles they supply muscular branches, and offsets of communication with one another. A greater part of the lower than of the upper nerves is visible, owing to the shortness of the inferior spaces.

Intercostal
nerves
are between
oblique and
transver-
salis ;

offsets.

Last dorsal
nerve.

The LAST DORSAL NERVE ⁽¹⁾ is placed below the twelfth rib, and therefore not in an intercostal space, but it has a similar course and distribution to the foregoing. As it extends forwards to the rectus it communicates sometimes with the ilio-hypogastric nerve. Its lateral cutaneous branch perforates the two oblique muscles (p. 438).

Ilio-hypo-
gastric
nerve :

The ILIO-HYPOGASTRIC NERVE ⁽²⁾ perforates the back of the transversalis muscle near the iliac crest, and divides into iliac and hypogastric branches.

iliac part :

The *iliac branch* pierces both oblique muscles close to the crest of the ilium, to reach the gluteal region (p. 632).

and hypo-
gastric part.

The *hypogastric branch* is directed forwards above the hip-bone, giving twigs to the transverse and internal oblique muscles, and communicating with the ilio-inguinal nerve. It perforates the fleshy part of the internal oblique near the front of the iliac crest, and the aponeurosis of the external oblique near the linea alba, finally becoming cutaneous in the hypogastric region (p. 438).

Ilio-inguinal
nerve.

The ILIO-INGUINAL NERVE perforates the transversalis muscle near the front of the iliac crest. It afterwards pierces the internal oblique, and reaches the surface through the external abdominal ring (p. 438) : it furnishes offsets to the internal oblique, the transversalis, and the pyramidalis.

Dissection
of transver-
salis fascia.

Dissection. To see the transversalis fascia on the right side, it will be necessary to raise the lower part of the transversalis muscle by two incisions :—one of these is to be carried through the fibres attached to Poupart's ligament ; the other, across the muscle from the front of the iliac crest to the margin of the rectus. With a little care the muscle may be separated easily from the thin fascia beneath.

Transver-
salis fascia

The *transversalis fascia* (fig. 142, G) is a thin fibrous layer between the transversalis muscle and the peritoneum. In the inguinal region, where it is unsupported by muscles, the fascia is considerably stronger than elsewhere, and is joined by some tendinous fibres of the transversalis muscle ; but farther from the pelvis it gradually decreases in strength, until at the thorax it becomes very thin.

is best
marked in
the groin ;

pierced by
internal
abdominal
ring.

In the part of the fascia now laid bare is the internal abdominal ring, which gives passage to the spermatic cord, or the round ligament of the uterus, according to the sex ; it resembles the hole into the finger of a glove in being visible from within, but not externally, owing to the fascia being prolonged from its margin on the cord. On the inner side of the ring the fascia is thinner than on the outer, and is fixed to the body of the pubis, and to the ilio-pectineal line behind the conjoined tendon, with which it is united.

Ending of
fascia below.

Along the outer half of Poupart's ligament the fascia ends by joining the posterior margin of that band, and it will be afterwards seen to unite with the iliac fascia for the same extent (p. 463) ; but beneath the inner half of the ligament it is continued downwards to the thigh, in front of the blood-vessels, to form the anterior part of the crural sheath around them.

Situation of

Internal abdominal ring (fig. 142). This opening is situate mid-

way between the symphysis pubis and the anterior superior iliac spine, and half an inch above Poupart's ligament. From its margin a thin tubular prolongation of the fascia (infundibuliform fascia) is continued around the cord as before said.

internal abdominal ring.

Dissection. The tubular prolongation on the cord may be traced by cutting the transversalis fascia horizontally above the opening of the ring, and then longitudinally over the cord. With the handle of the scalpel the thin membrane may be reflected to each side, so as to lay bare the subperitoneal fat.

Dissection to follow process on cord.

The *subperitoneal fat* forms a layer between the transversalis fascia and the peritoneum. Its thickness varies much in different bodies, but is greater at the lower than at the upper part of the abdomen. This structure will be more specially noticed in the examination of the wall of the abdomen from the inside.

Subperitoneal tissue in groin.

Dissection. After the subperitoneal fat has been seen, let it be reflected to look for the remains of a piece of peritoneum along the cord, in the form of a fibrous thread.

Trace remains of peritoneum.

The *peritoneum*, or the serous sac of the abdominal cavity, projects forwards slightly opposite the internal abdominal ring. Connected with it at that spot is a fibrous thread (the remains of a prolongation to the testis in the fœtus) which extends a variable distance along the front of the cord. It is generally impervious, and can be followed only a very short way; but it may sometimes be traced as a fine band to the tunica vaginalis of the testis.

Peritoneum of the groin is prolonged on the cord:

piece may be impervious,

In some bodies the process may be partly open, being sacculated at intervals; or it may form occasionally a single large bag in front of the cord. Lastly, as a rare state, the tube of peritoneum receiving the testis in the fœtus may be unclosed, so that a coil of intestine could descend in it from the abdomen.

or sacculated,
or open.

In the female the fœtal tube of peritoneum sometimes remains pervious for a short distance in front of the round ligament; the unobliterated pouch is named the *canal of Nuck*.

In female may be partly open.

The SPERMATIC CORD (fig. 142, F) extends from the internal abdominal ring to the testis, and consists mainly of the vessels and the efferent duct of the gland, united together by coverings from the structures by or through which they pass.

Spermatic cord

In the wall of the abdomen the cord lies obliquely, since its aperture of entrance amongst, is not opposite its aperture of exit from, the muscles; but escaped from the abdomen, it descends almost vertically to its destination. In the oblique part of its course it is contained in the passage named the inguinal canal; it is placed at first beneath the internal oblique, and rests against the transversalis fascia; but beyond the lower border of the oblique muscle, it lies on the upper surface of Poupart's ligament, with the aponeurosis of the external oblique between it and the surface of the body, and the conjoined tendon behind it.

is oblique in the abdominal wall,

and vertical beyond;

relations;

Its several coverings are derived from the strata in the wall of the abdomen. Thus, from within out come—the subperitoneal fat, the infundibuliform process of the transversalis fascia, the cremaster muscle continuous with the internal oblique, the intercolumnar or

coverings.

spermatic fascia from the external oblique muscle, and lastly the superficial fascia and the skin.

In female
round liga-
ment is in
place of
cord.

The *round ligament*, or the suspensory cord of the uterus, occupies the inguinal canal in the female, and ends in the integuments of the groin. Its coverings are similar to those of the spermatic cord, except that it wants the cremaster.

Dissection.

Dissection. The constituents of the cord will be displayed by cutting through longitudinally, and turning aside the different surrounding layers, and removing the areolar tissue. The dissector should trace branches of the genito-crural nerve and epigastric artery into the cremasteric covering.

Constitu-
ents of the
cord.

Vessels and nerves of the cord. In the cord are collected together the spermatic artery and veins, which convey the blood to and from the testicle, the nerves and lymphatics of the testicle, and the vas deferens or the efferent duct.

Vessel in
female.

In the female a branch from the ovarian artery enters the round ligament.

Vas defe-
rens :

The *vas deferens* reaches from the testicle to the urethra, and is placed behind the other constituents of the cord ; it will be recognised by its resemblance in feel to a piece of whipcord, when it is taken between the finger and the thumb. As it enters the abdomen through the opening in the transversalis fascia (internal ring), it lies on the inner side of the vessels of the testicle ; and as it begins its descent to the pelvis, it winds behind the epigastric artery.

situation
and course.

Artery and
nerve of the
coverings of
the cord ;

Cremasteric artery and nerve. The cremasteric covering of the cord has a separate artery and nerve. The *artery* is derived from the epigastric, and is distributed to the coverings of the cord. The *genital branch of the genito-crural nerve* enters the cord by the internal abdominal ring, and ends in the cremaster muscle.

and cuta-
neous.

Cutaneous vessels and nerves are supplied to the integuments covering the cord from the superficial pudic artery and the ilio-inguinal nerve.

Dissection
of deep arch

Dissection. By cutting through the spermatic cord near the pubis, and raising it towards the internal abdominal ring, a fibrous band below Poupart's ligament, the deep crural arch, will appear : it passes inwards to the pubis, and is to be defined with some care.

and of the
vessels in
the wall of
abdomen.

The remaining vessels of the abdominal wall, viz., the epigastric and circumflex iliac, and the ending of the internal mammary artery, are to be next dissected. The epigastric and mammary arteries will be found on raising the outer edge of the rectus, one above and the other below, ramifying in the muscle.

Deep crural
arch :

The epigastric, with its earliest branches, may be traced by removing the transversalis fascia from it near Poupart's ligament. The circumflex iliac artery lies behind the outer half of Poupart's ligament, and should be pursued along the iliac crest to its ending.

attach-
ments.

Deep crural arch. Below the level of Poupart's ligament is a thin band of transverse fibres over the femoral vessels, which has received the name deep crural arch from its position and resemblance to the superficial crural arch (Poupart's ligament). This fasciculus of fibres, beginning about the centre of the ligament, is prolonged

inwards to the pubis, where it is widened, and is inserted into the pectineal line at the deep aspect of the conjoined tendon of the broad muscles of the abdomen.* It is closely connected with the front of the crural sheath.

VESSELS IN THE WALL OF THE ABDOMEN. On the side of the abdomen are some of the intercostal and lumbar arteries with the nerves. In the sheath of the rectus lie the epigastric and internal mammary vessels. And running along the crest of the ilium is the circumflex iliac branch. Vessels in abdominal wall.

The **INTERCOSTAL ARTERIES** of the lowest two spaces issue between the corresponding ribs (p. 364), and enter the abdominal wall between the transversalis and internal oblique muscles: they extend forwards with the nerves, supplying the contiguous muscles, and forming anastomoses with the internal mammary, epigastric and lumbar arteries. Intercostal arteries.

LUMBAR ARTERIES. The anterior branches of the lumbar arteries supply the muscles in the hinder part of the abdominal wall, and anastomose with the foregoing arteries above, with the circumflex iliac and ilio-lumbar arteries below. The highest artery accompanies the last dorsal nerve below the twelfth rib, and is distributed with the nerve. From the lowest lumbar artery a branch passes to the integuments with the iliac part of the ilio-hypogastric nerve. Lumbar arteries.

INTERNAL MAMMARY ARTERY. The abdominal branch of this vessel (superior epigastric artery; p. 259) enters the wall of the abdomen beneath the cartilage of the seventh rib. Descending in the sheath of the rectus, the vessel soon enters the substance of the muscle, and anastomoses in it with the epigastric artery. Branches are given to the neighbouring muscles and the overlying integument. Internal mammary artery.

The **EPIGASTRIC ARTERY** (fig. 142, *a*) arises from the external iliac about a quarter of an inch above Poupart's ligament; it ascends in the sheath of the rectus, and above the umbilicus divides into branches which enter that muscle, and anastomose with the internal mammary. Inferior or deep epigastric artery:

As the artery courses to the rectus it passes beneath the spermatic cord (or round ligament of the uterus), and on the inner side of the internal abdominal ring; and it is directed obliquely inwards across the lower part of the abdomen, so as to form the outer boundary of a triangular space along the edge of the rectus. It lies at first beneath the transversalis fascia; but it soon perforates that membrane, and enters the sheath of the rectus over the semilunar border at the posterior aspect. relations in wall of abdomen.

The *branches* of the artery are numerous, but inconsiderable in size:— Branches:

a. The *pubic branch* is a small artery, which runs transversely pubic joins obturator;

* Sometimes this structure is a firm distinct band, which is joined by some of the lower fibres of the aponeurosis of the external oblique. At other times, and this is the most common arrangement, it is only a thickening of the transversalis fascia, with fibres added from the tendon of the transversalis muscle.

behind Poupart's ligament to the back of the pubis, where it anastomoses with the similar branch of the opposite side, and with an offset from the obturator artery (fig. 143, *f*); the size of the last anastomosis varies much, but its situation is internal to the crural ring.

cremasteric ;

b. A *cremasteric branch* is furnished to the muscular covering of the cord.

muscular ;

c. *Muscular branches* are given from the outer side of the artery to the abdominal wall, and anastomose with the intercostal and lumbar arteries ; others enter the rectus.

utaneous.

d. *Cutaneous offsets* pierce the muscle, and ramify in the integuments with the anterior cutaneous nerves.

Epigastric veins.

Two *epigastric veins* lie with the artery ; they join finally into one, which opens into the external iliac vein.

Circumflex iliac artery :

The CIRCUMFLEX ILIAC ARTERY arises from the outer side of the external iliac, opposite, or a little below the epigastric. It runs at first over the iliacus, close behind Poupart's ligament, in a fibrous sheath at the junction of the iliac and transversalis fasciæ, and then along the inner margin of the iliac crest to about the middle, where it ends by anastomosing with the iliac branch of the ilio-lumbar artery.

offsets, muscular,

Branches. Near the front of the iliac crest a branch (fig. 142, *b*) ascends between the internal oblique and transversalis muscles, supplying them, and anastomosing with the epigastric and lumbar arteries.

and anastomotic.

As the vessel extends backwards it gives lateral offsets, which supply the neighbouring muscles, and communicate on the one side with the ilio-lumbar, and on the other with the gluteal artery.

Circumflex iliac vein.

The *circumflex iliac vein* is formed by the junction of two collateral branches, and crosses the external iliac artery nearly an inch above Poupart's ligament, to open into the external iliac vein.

SECTION II.

HERNIA OF THE ABDOMEN.

Inguinal hernia.

The lower part of the abdominal wall, which has been reserved on the left side of the body, should now be dissected for inguinal hernia.

The dissection in the left groin.

Dissection. The integuments and the aponeurosis of the external oblique having already been reflected, the necessary dissection of the inguinal region will be completed by raising the internal oblique muscle as in fig. 142.

Reflect internal oblique.

To raise the oblique muscle, let one incision be made across the fleshy fibres from the iliac crest towards the linea alba ; and after the depth of the muscle has been ascertained by the layer of areolar and fatty tissue beneath it, let the lowest fibres be carefully cut through at their attachment to Poupart's ligament. By lifting up

the muscle cautiously, the student will be able to separate it from the subjacent transversalis so that it may be turned inwards on the abdomen. The separation of the two muscles just mentioned is often difficult in consequence of their lowest fibres being blended together, but a branch of the circumflex iliac artery serves as a guide to the intermuscular interval.

The cremaster muscle is next to be divided along the cord, and to be reflected to the sides. Let the dissector then clean the surface of the transversalis muscle, without displacing its lower arched border, and define with care the conjoined tendon of it and the internal oblique to show the exact extent outwards. The transversalis fascia and the spermatic cord should also be nicely cleaned.

Crossing the interval below the border of the transversalis muscle are the epigastric vessels, which lie close to the inner side of the internal abdominal ring, but beneath the transversalis fascia. A small piece of the fascia may be cut out to show the vessels.

INGUINAL HERNIA. A protrusion of intestine or other organ through the lower portion of the abdominal wall near Poupart's ligament (answering to the inguinal region) is named an inguinal hernia. The escape of the intestine in this region is favoured by the deficiencies in the muscular strata, by the passage of the spermatic cord through the abdominal parietes, and by the existence of fossæ on the inner surface of the wall.

The gut in leaving the abdomen either passes through the internal abdominal ring with the cord, or is projected through the part of the abdominal wall between the epigastric artery and the edge of the rectus muscle. These two kinds of hernia are distinguished by the names external and internal, from their position to the epigastric artery; or they are called oblique and direct, from the direction they take through the abdominal wall. Thus, the hernia protruding through the internal abdominal ring with the cord is called external from being outside the artery, and oblique from its slanting course; while the hernia between the edge of the rectus and the epigastric artery is named internal from being inside the artery, and direct from its straight course.

EXTERNAL or OBLIQUE INGUINAL HERNIA leaves the cavity of the abdomen with the spermatic cord, and traversing the inguinal canal, makes its exit from that passage by the external abdominal ring.

ANATOMY OF EXTERNAL HERNIA. To understand the anatomy of this form of hernia, it will be necessary to study the passage which it occupies in its course through the abdominal wall (inguinal canal), the apertures by which it enters and leaves the wall (abdominal rings), and the coverings it receives in its progress.

The *inguinal canal* (fig. 142) is the interval between the flat muscles of the abdominal wall, which contains the spermatic cord in the male, and the round ligament of the uterus in the female. It extends from the internal to the external abdominal ring, and measures about one inch and a half in length. From its beginning at the internal ring, it is directed obliquely downwards and inwards,

Cut the cremaster.

Clean subjacent parts.

Show the epigastric vessels.

Situation of inguinal hernia.

Predisposition naturally.

Course it follows.

Two kinds:

external or oblique;

internal or direct.

External or oblique.

Anatomy of parts concerned.

Inguinal canal:

extent,

length and direction;

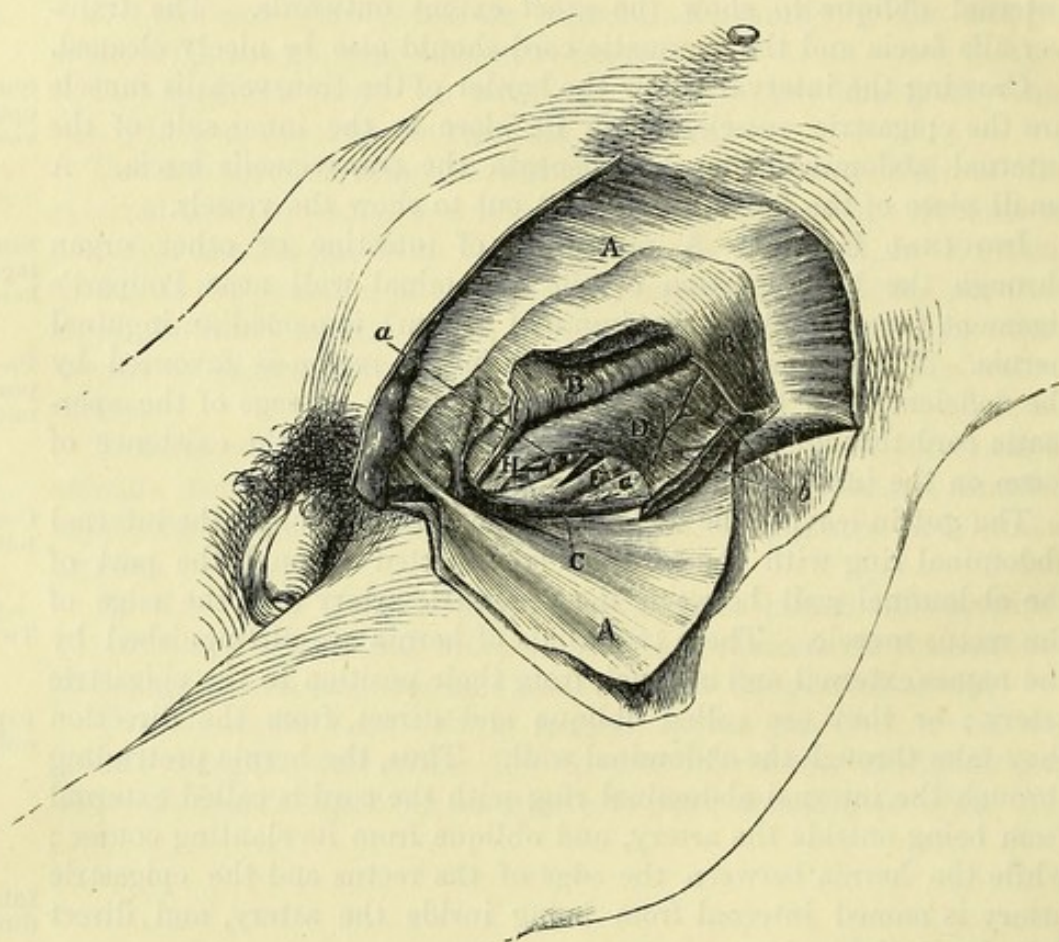
being placed above, and nearly parallel to, the inner half of Poupart's ligament.

boundaries
in front,

and behind ;

Towards the surface of the body the canal is bounded by the integuments and the aponeurosis of the external oblique muscle (A) for its whole extent, and by the internal oblique (B) in addition for the outer third. Towards the cavity of the abdomen its wall is similarly formed by the peritoneum, subperitoneal tissue and transversalis fascia (G) throughout its whole length, and by the

Fig. 142.*



conjoined tendon (H) of the internal oblique and transversalis muscles in its inner two-thirds.

floor,

and roof.

Along the lower part, or the floor, the canal is limited by the meeting of the transversalis fascia with Poupart's ligament, and by the fibres of the ligament inserted into the pectineal line (Gimbernat's ligament); while along the upper part its extent is determined only by the apposition of the muscles, and by the arched borders of the internal oblique and transversalis.

Canal in the
female.

In the female, the canal has the same boundaries, but is usually

* Dissection for inguinal hernia (Illustrations of Dissections). *Muscles, &c.* : A. External oblique tendon, thrown down. B. Internal oblique, the lower part raised. C. Cremaster muscle in its natural position. D. Transversalis muscle with a free border. F. Spermatic cord, surrounded by the infundibuliform fascia. G. Transversalis fascia. H. Conjoined tendon. *Arteries* : a. Epigastric. b. Offset of the circumflex iliac.

somewhat longer and narrower. In that sex it lodges the round ligament.

The *internal abdominal ring* (fig. 142) is an aperture in the transversalis fascia, which is situate midway between the symphysis pubis and the anterior superior iliac spine, and half an inch above Poupart's ligament. It is oval in form; and its longest diameter, which is directed vertically, measures about half an inch: the fascia at its outer and lower parts is stronger than at the opposite sides.

Internal abdominal ring:

situation, form and margin;

Arching above and on the inner side of the aperture is the lower border of the transversalis muscle (D), which is fleshy in the outer but tendinous in the inner half. Below it is Poupart's ligament, which separates the aperture from the external iliac artery. On the inner side lie the epigastric vessels (a).

relations;

This opening in the transversalis fascia is the inlet to the inguinal canal, and through it the cord, or the round ligament, passes into the wall of the abdomen. An external hernia enters the canal at the same spot. All the protruding parts receive as a covering the prolongation (infundibuliform fascia) from the margin of the opening.

parts transmitted through it.

The *external abdominal ring* (fig. 137, c) is the outlet of the inguinal canal, and through it the spermatic cord reaches the surface of the body. This aperture is placed in the aponeurosis of the external oblique muscle, near the crest of the pubis; and from the margin a prolongation (spermatic fascia) is sent on the parts passing through it (p. 443).

External abdominal ring: situation.

Course and coverings of an external hernia. A piece of intestine leaving the abdomen with the cord, and passing through the inguinal canal to the surface of the body, will obtain a covering from every stratum of the wall of the abdomen in the groin, except from the transversalis muscle.

The intestine, following the course of the cord,

It receives its investments in this order:—As the intestine is thrust forwards, it carries before it first the peritoneum and the subperitoneal fat, and enters the tube of the infundibuliform fascia (F) around the cord. Still increasing in size, it is forced downwards to the lower border of the internal oblique muscle, where it will have the cremasteric fascia (c) applied to it. The intestine is next directed along the front of the cord to the external abdominal ring, and in passing through that opening receives the investment of the intercolumnar or spermatic fascia. Lastly, as the hernia descends towards the scrotum, it has the additional coverings of the superficial fascia and the skin.

has coverings of the peritoneum and fat, transversalis fascia,

cremaster, spermatic fascia, superficial fascia and skin;

In a hernia which has passed the external abdominal ring, the coverings from without inwards are therefore the following:—the skin and superficial fascia, the spermatic and cremasteric fasciæ, the infundibuliform fascia, the subperitoneal tissue, and the peritoneum or hernial sac. Two of the coverings, viz., the peritoneal and subperitoneal, originate as the gut protrudes; but the rest are ready formed round the cord, and the intestine slips inside them. The different layers become much thickened in a hernia that has existed for some time.

seven in number;

how produced.

- How to distinguish it.** *Diagnosis.* If the hernia is small, and is confined to the wall of the belly, it gives rise to an elongated swelling along the inguinal canal. If it has proceeded farther, and entered the scrotum, it forms a flask-shaped tumour with the large end below, and the narrow neck occupying the inguinal passage.
- The taxis.** While efforts are being made to put back a piece of protruded intestine during life, the direction of the canal, and the situation of the internal abdominal ring, should be borne in mind.
- Stricture : where situate ;** *Seat of stricture.* The protruded intestine may be constricted at the internal abdominal ring, in the inguinal canal by the fleshy internal oblique muscle, or at the external abdominal ring.
- two kinds.** The stricture is placed usually at the internal abdominal ring, and may be produced either by a constricting fibrous band outside the narrowed neck of the tumour, or by a thickening and contraction of the peritoneum itself at the inner surface of the neck.
- To set free external,** *Division of stricture.* To set free the intestine, an incision is made down to the internal abdominal ring ; and, all fibrous bands outside the peritoneum being divided, the intestine is to be returned if possible into the abdomen by gentle pressure.
- and internal stricture.** Supposing the intestine cannot be replaced in the abdomen after the previous steps have been taken, the surgeon proceeds to lay open the peritoneum, and to divide the internal stricture, from within out, on a director placed beneath it. With the view of avoiding the surrounding vessels, the cut is directed upwards on the front and mid-part of the hernia.
- Two varieties.** *Varieties of external hernia.* There are two varieties (congenital and infantile) of oblique inguinal hernia, which are distinguished by the condition of the peritoneal covering.
- Congenital hernia :** *Congenital hernia.* This kind is found for the most part in the infant and the child, though it may occur in the adult male. In the tube of peritoneum (processus vaginalis), which receives the testicle in the fœtus, remaining unclosed, the intestine descends into a sac already formed for its reception.
- how constituted ;**
- coverings** As it follows the course of the inguinal canal, it will possess the coverings before enumerated for the external hernia ; and it passes
- and course ;** at the first to the bottom of the scrotum, instead of being arrested at the top of the testis.
- diagnosis ;** With care it may be distinguished, while it is of moderate size, by its position in front of the testicle.
- stricture.** For the seat, cause, and division of the stricture, refer to what is before stated for external hernia.
- Infantile hernia :** *Infantile or encysted hernia* is much rarer than congenital, and cannot be distinguished from the common external hernia during life. It was first recognised in the young child, and received its name of infantile from that circumstance ; but it may be met with at any period of life.
- how constituted ;** This form of hernia occurs when the fœtal processus vaginalis of the peritoneum is closed only in the neighbourhood of the internal abdominal ring, instead of being obliterated from that point down to the testicle, so that a large serous sac will be situate in front of

the spermatic cord, and may occupy the inguinal canal. With this state of the peritoneum, should an external hernia with its coverings descend along the cord in the usual way, it will pass behind the unobliterated sac, like a viscus in a serous membrane. In this way there will be two sacs: an anterior (the tunica vaginalis) containing serum, and a posterior enclosing the intestine.

An infantile hernia is first recognised during an operation by the knife opening the tunica vaginalis. The operator then proceeds to lay bare the neck of the hinder or hernial sac, and to treat the stricture of it as before described (p. 458). how known and treated.

INTERNAL OR DIRECT INGUINAL HERNIA escapes on the inner side of the epigastric artery, and has a straight course through the abdominal parietes. Its situation and coverings, and the seat of stricture, will be understood after the examination of the part of the abdominal wall through which it passes. Internal hernia.

ANATOMY OF INTERNAL HERNIA. In the abdominal wall near the pubis is a triangular space to which the name of *Hesselbach's triangle* has been given. This is bounded by the epigastric artery on one side, the outer edge of the rectus muscle on the other, and the inner part of Poupart's ligament below; it measures about two inches from above down, and one inch and a half across at the base. Triangle of Hesselbach: boundaries; size;

The constituents of the abdominal wall in this area are—the integuments, the muscular strata, and the layers lining the interior of the abdomen, viz., transversalis fascia, subperitoneal tissue, and peritoneum. The muscles have the following arrangement:—The aponeurosis of the external oblique is pierced by the external abdominal ring, towards the lower and inner angle of the space. The internal oblique and transversalis, which come next, are united together in the conjoined tendon; and as this descends to its insertion into the pectineal line, it covers the inner two-thirds (about an inch) of the space; and leaves uncovered about half an inch between its outer edge and the epigastric vessels, where the transversalis fascia appears. constituents of wall; and disposition of muscles

Any intestine protruding in this spot must make a new path for itself, and elongate the different structures, since there is not any passage by which it can descend, like an external hernia. Farther, the coverings of the hernia, and its extent and direction in the abdominal wall, must vary according as the gut projects through the portion of the space covered by the conjoined tendon, or through the part external to that tendon. Hernia in this space of two kinds.

Course and coverings of the hernia. The commoner kind of internal hernia (inferior) passes through the part of the triangular space which is covered by the conjoined tendon. Coverings of the more common kind are

The intestine in protruding carries before it the peritoneum, the subperitoneal fatty membrane, and the transversalis fascia; next it elongates the conjoined tendon, or as in a sudden rupture, separates the fibres, and escapes between them. Then the intestine advances into the lower part of the inguinal canal, opposite the external abdominal ring, and passes through that opening on the inner side of the cord, receiving at the same time the covering of the spermatic peritoneum and subjacent tissue, transversalis fascia, conjoined tendon, spermatic fascia, superficial

fascia, and skin. fascia. Lastly it is invested by the superficial fascia and the skin.

In number the coverings of an internal hernia are the same as those of an external; and in kind the only differences are that the covering of transversalis fascia is not furnished by the infundibuliform process, and the conjoined tendon is substituted for the cremasteric fascia.

The taxis. The position of the openings in the abdominal wall, and the straightness of its course, should be kept in mind during attempts to reduce this kind of hernia.

How known from external: *Diagnosis.* This rupture will be distinguished from external hernia by its straight course through the abdominal wall, and by the neck being placed close to the pubis.

impossible if it is large. When an inguinal hernia has attained a large size, it is impossible to tell by an external examination whether it began originally in the triangular space, or at the internal abdominal ring; for as an external hernia increases, its weight drags inwards the internal ring into a line with the external, and in this way the swelling acquires the appearance of a direct rupture.

Stricture: *Seat of stricture.* The stricture in this form of hernia occurs most frequently outside the neck of the tumour, at the opening that has been formed in the conjoined tendon, though it may be inside from thickening of the peritoneum; and it may occasionally be found at the external abdominal ring.

situation; to free from stricture; *Division of the stricture.* The neck of the tumour is to be laid bare, and all fibrous bands around it are to be divided without injury to the peritoneum; but if, after this has been done, the intestine cannot be put back into the abdomen, the sac is to be opened, and the internal constricting band is to be divided directly upwards on a director.

in large hernia. In dividing the stricture on a large rupture appearing to be direct, the cut should be made directly upwards in the middle of the front of the tumour, so as to avoid the epigastric vessels, the position of which cannot be ascertained.

Rarer kind of internal hernia is oblique in direction with the cord. *Variety of internal hernia.* Another kind of internal hernia (superior) occurs through that part of the area of the triangular space which is external to the conjoined tendon. The intestine protrudes through the wall of the abdomen close to the epigastric artery, and descends along nearly the whole of the inguinal canal to reach the external abdominal ring; so that the term "direct" would not apply strictly to this form of internal hernia.

Coverings are same as in external hernia. *Coverings.* As the gut traverses nearly the whole of the inguinal canal, it has the same coverings as an external hernia, viz., the skin and the superficial fascia, the spermatic and cremasteric fasciæ, the transversalis fascia (but not the infundibuliform fascia), and the subperitoneal fat with the peritoneum.

Diagnosis not possible in life. *Diagnosis.* This form of internal hernia would be considered external during life from its course and its form; and yet it must be remembered that the epigastric vessels are placed on the outer part of its neck, while in the hernia which it simulates they lie on

the inner side. Its nature can be ascertained with certainty only after death.

Seat of stricture. The constriction of the intestine will take place from similar causes, and at the same spots as in the external hernia. Stricture at same spots as external.

Division of the stricture. From an inability to decide always in the living body whether a small hernia is internal or external, the rule observed in dividing the stricture of the neck of the sac is, to cut down upon the mid-part of the tumour; and if it is necessary to open the peritoneum, to cut directly upwards, as in the other kinds of inguinal hernia. Division of stricture.

UMBILICAL HERNIA, or exomphalos, is a protrusion of the intestine through or by the side of the umbilicus. It is very variable in size, and its course is straight through the abdominal wall. Umbilical hernia : course ;

Coverings. The coverings of the intestine are—the skin and superficial fascia, a prolongation from the tendinous margin of the aperture in the linea alba, together with coverings of the transversalis fascia, the subperitoneal fat, and the peritoneum. Over the end of the tumour the superficial fascia blends with the other contiguous structures, and its fat disappears. coverings become united over the tumour,

If the hernia is suddenly produced, it may want the investment otherwise derived from the edge of the umbilicus. changes in ;

Seat of stricture. The stricture on the intestine is generally at the margin of the tendinous opening in the abdominal wall; and it may be either outside, or in the neck of the sac, as in the other kinds of hernia. It should be remembered that the narrowed neck is at the upper end and not in the centre of the swelling. stricture, where found.

Division of the stricture. The constriction may be removed by cutting externally the parts around the neck. Or if the sac is to be opened, the knife may be carried upwards in cutting the stricture; but there is not any vessel liable to injury in the operation.

OTHER FORMS OF HERNIA. At each of the other apertures in the parietes of the abdomen, a piece of intestine may be protruded, so as to form a hernia. For instance there may be *femoral hernia* below Poupart's ligament, with the femoral vessels; *obturator hernia* through the thyroid foramen, with the artery of the same name; and *ischiatric hernia* through the ischiatic notch. Other abdominal herniæ are femoral, obturator, ischiatic.

The femoral hernia, as the most important, will be noticed presently; but the student may refer to some special treatise for information respecting the other abdominal herniæ.

Dissection. The abdomen is now to be opened to see the cords and depressions on the posterior surface of the wall. A transverse cut may be made through the umbilicus across the front of the abdomen; and on holding up the lower half of the wall, three prominent fibrous cords, the urachus and the obliterated hypogastric arteries, will be seen ascending to the umbilicus from the pelvis. Dissection to open abdomen.

Cords of the abdominal wall. In the middle line is the urachus, which reaches from the summit of the bladder to the umbilicus; on each side is the obliterated hypogastric artery, extending from the side of the pelvis to the umbilicus; and a little external to the last, One median cord one on each side,

and an
artery.

near Poupart's ligament, is a less marked prominence of the peritoneum caused by the epigastric artery.

Three
inguinal
fossæ :

Fossæ. With this disposition of the cords, three hollows (*inguinal fossæ*) are seen near Poupart's ligament, one internal to the obliterated hypogastric artery, another outside the epigastric artery, and the third between the two prominences. The *external fossa* corresponds by its lower and inner part to the internal abdominal ring, opposite which there is often a slight depression of the peritoneum, and is the place where an external inguinal hernia begins to protrude.

external,

internal,

The *internal fossa* is between the obliterated hypogastric artery and the urachus ; its outer part is opposite the external abdominal ring, and is the seat of the commoner (inferior) variety of internal hernia.

and middle.

The *middle fossa* is the smallest, and is placed behind the inguinal canal ; in it the superior variety of internal hernia leaves the abdominal cavity.

In some bodies the obliterated hypogastric artery is close to, or behind, the epigastric artery ; and in that case the middle fossa will be wanting.

Situation of
femoral
hernia.

FEMORAL HERNIA. In this hernia the intestine leaves the abdomen below Poupart's ligament, and descends in the membranous sheath around the femoral vessels. Only so much of the structures will be described here as can be now seen ; the rest are noticed fully in the dissection of the thigh (p. 606).

Dissection
of the parts
concerned.

Dissection. The dissection for femoral hernia is to be made on the left side of the body.

Divide wall,

The lower portion of the abdominal wall is to be divided from the umbilicus to the pubis, the cut being made on the left side of the urachus, and care being taken not to injure the bladder, which may project above the pubic bones. The peritoneum is to be detached from the inner surface of the flap, and from the iliac fossa.

detach
peritoneum
and fat,

The layer of subperitoneal fatty tissue is to be separated in the same way, and in doing this the spermatic vessels and vas deferens will come into view as they meet at the internal abdominal ring to form the spermatic cord. Beneath these the external iliac vessels are to be cleaned, with some lymphatic glands lying along them, and the genito-crural nerve on the artery. (In the female the round ligament of the uterus is seen entering the internal abdominal ring round the epigastric artery ; and the ovarian vessels cross the external iliac trunks higher up.) Any loose tissue remaining is to be taken away to show the beginning of the crural sheath around the femoral vessels, and the interval (crural ring) on their inner side (fig. 143).

and clean
iliac vessels.

Afterwards the transversalis and iliac fasciæ are to be traced to Poupart's ligament, to see the part that each takes in the formation of the crural sheath.

Anatomy
of the
structures.

ANATOMY OF FEMORAL HERNIA. The membranes concerned in femoral hernia are the peritoneum, the subperitoneal fatty layer, the transversalis and iliac fasciæ lining the interior of the abdominal cavity, with the sheath on the femoral vessels to which they give origin at Poupart's ligament.

The *peritoneum* lines the inner surface of the abdominal wall, whence it is prolonged without interruption into the iliac fossa and the pelvis; and its thinness and weakness are apparent now it is detached. Peritoneal layer.

The *subperitoneal fat* extends as a continuous layer beneath the peritoneum, but is thickest and most fibrous at the lower part of the abdomen, where the iliac vessels pass under Poupart's ligament. At that spot it extends over the upper opening of the membranous sheath around the vessels, and covers the space of the crural ring internal to the vein. Subperitoneal fat,

The part of this layer which stretches over the crural ring is named the *septum crurale* (Cloquet); and a lymphatic gland is generally attached to its under surface. forms septum crurale.

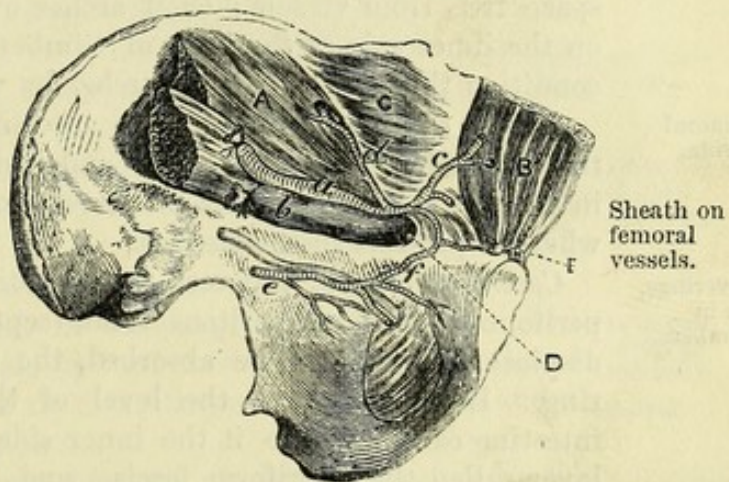
The *transversalis fascia* has been before noticed (p. 450). At Poupart's ligament it joins the iliac fascia outside the situation of the external iliac artery; but internal to that spot it is continued downwards to the thigh in front of the femoral vessels, and forms the anterior part of the crural sheath. Transversalis fascia.

The *iliac fascia* covers the ilio-psoas muscle, and lies beneath the iliac vessels. At Poupart's ligament it joins the transversalis fascia external to the iliac vessels; but behind the vessels it is prolonged into the posterior part of the crural sheath. Iliac fascia.

The *crural sheath* is a loose membranous tube, which encloses the femoral vessels as they enter the thigh, and is obtained from the fasciæ lining the abdomen. Its anterior half is continuous with the transversalis fascia, and its posterior is derived from the iliac fascia and the pubic fascia of the thigh. The sheath is not entirely filled by the vessels, for a space (crural canal) exists on the inner side of the vein, through which the intestine descends in femoral hernia. The aperture leading into the crural canal is called the crural ring.

The *crural ring* (fig. 143, d) is referred to also in the dissection of the thigh, but its boundaries are better seen in the abdomen. It is an interval at the base of the sheath, to the inner side of the femoral vein, which is about half an inch wide, and is filled by a

Fig. 143.*



* View of the parts concerned in femoral hernia. (R. Quain.) *Muscles, &c.*: A. Iliacus covered by the iliac fascia. B. Rectus. C. Transversalis, covered by the transversalis fascia. D. Crural ring. E. Gimbernat's ligament. *Vessels*: a. External iliac artery. b. Iliac vein. c. Epigastric artery. d. Circumflex iliac. e. Obturator, with its nerve. f. Anastomosis between the pubic branches of the obturator and epigastric arteries.

size and
boundaries.

lymphatic gland. Bounding it internally are Gimbernat's ligament (E) and the conjoined tendon; and limiting it externally is the femoral vein (b). In front is Poupart's ligament, with the deep crural arch; and behind is the pubis, covered by the pectineus muscle and the pubic portion of the fascia lata. Crossing the front of the space, but at some little distance from it, is the spermatic cord in the male, and the round ligament in the female. The opening is larger in the female than in the male.

Constricting
boundaries,
how re-
laxed.

Two of the boundaries, anterior and inner, are firm and sharp-edged, though their condition varies with the position of the limb; for if the thigh is raised and approximated to its fellow, those bounding parts will be relaxed.

Usual ves-
sels around
ring.

Position of vessels around the ring (fig. 143). On the outer side is the femoral vein (b); and above this are the epigastric vessels (c). In front is a small branch (pubic) from the epigastric artery to the back of the pubis; and the vessels of the spermatic cord may be said to be placed along the anterior aspect of the ring.

Unusual
state of
vessels.

But in some bodies the obturator artery takes origin from the epigastric, and lies along the ring as it passes to the pelvis. It may have two positions with respect to the crural ring:—either it is placed close to the iliac vein, so as to leave the inner side of that space free from vessels; or it arches over the aperture, descending on the inner side at the base of Gimbernat's ligament; in this last condition the ring will be encircled by vessels except behind.

Femoral
hernia.

Course of femoral hernia. The intestine leaves the abdomen by the opening of the crural ring; and it descends internal to the vein in the crural sheath, as far as the saphenous opening in the thigh, where it projects to the surface.

Coverings,
six in
number.

Coverings. In its progress the intestine will push before it the peritoneum and subperitoneal fat (septum crurale); and it will displace, or cause to be absorbed, the gland which fills the crural ring. Having reached the level of the saphenous opening, the intestine carries before it the inner side of the crural sheath, and a layer called the cribriform fascia; and, lastly, it is invested by the superficial fascia and skin of the thigh. The dissection of the thigh may be referred to for fuller details (pp. 606 to 610).

Stricture
either at
neck, or at
saphenous
opening.

Seat of stricture. The stricture of a femoral hernia is placed opposite the base of Gimbernat's ligament, or lower down at the margin of the saphenous opening in the thigh. And the constriction may be caused either by a fibrous band outside the upper narrow end of the tumour, or by the thickening of the peritoneum inside the neck, as in inguinal hernia.

Incision to
divide ex-
ternal

Division of the stricture. To free the intestine from the constricting fibrous band arching over it, an incision is to be made down to the neck of the sac at the inner and upper part.

and internal
stricture.

And to relieve the deep stricture within the neck of the sac, the peritoneal bag is to be opened and a director introduced, and the knife is to be carried horizontally inwards, or upwards and inwards, through the thickened sac and a few fibres of the edge of Gimbernat's ligament.

Danger to vessels. When the incision is made upwards and inwards to loosen the constricting band in the neck of the tumour, there will not be any vessel injured unless the cut should be made so long as to reach the spermatic cord in the male, or the small pubic branch of the epigastric artery. Risk of wounding vessels in regular

And when the incision is made directly inwards with the same view, there is not usually any vessel in the way of the knife. But in some few instances (once in about eighty operations, Lawrence) the obturator artery takes its unusual course in front; and on the inner side of the neck of the hernia, and will be before the knife in the division of the stricture. As this condition of the vessel cannot be recognised beforehand, the surgeon will best avoid the danger of wounding the artery by a cautious and sparing use of the knife. and irregular condition of them.

SECTION III.

CAVITY OF THE ABDOMEN.

The abdominal cavity is the space included between the spinal column behind, and the muscles stretching from the thorax to the pelvis in front. It is lined by a serous membrane (peritoneum), and contains the digestive, urinary, and generative organs, with vessels and nerves. Definition, and contents.

Dissection. To prepare the cavity for examination, the remainder of the abdominal wall above the umbilicus is to be cut, along the left side of the linea alba, as far as the ensiform process. The resulting flaps may be thrown to the sides. Dissection to open abdomen.

Size and form. This cavity is the largest in the body. It is ovoidal in form, with the ends upwards and downwards, so that it measures more in the vertical than the transverse direction; and it is much wider above than below. Is largest cavity in the body; is oval.

Boundaries. Above it is limited by the diaphragm; below by the recto-vesical fascia and the levatores ani muscles, and by the other structures closing the outlet of the pelvis: both these boundaries are concave towards the cavity, and are in part fleshy, so that the space will be diminished by their contraction and flattening. Boundaries above and below,

In front and on the sides the parietes are partly osseous and partly muscular;—thus, towards the upper and lower limits is the bony framework of the skeleton, viz., the ribs in one direction and the pelvis in the other; but between these the wall is formed by the broad muscles which have been examined. in front and on sides,

Behind is placed the spinal column with the muscles contiguous to it, viz., the psoas and the quadratus lumborum. and behind.

Alterations in size. The dimensions of the cavity are influenced by the varying conditions of the boundaries. Its depth is diminished by the contraction and descent of the diaphragm, and the contraction and ascent of the levatores ani; and the cavity is restored to its former dimensions by the relaxation of those muscles. Depth is altered by action of diaphragm and levator ani.

Width by muscles in wall of abdomen.	The width is lessened by the contraction of the abdominal muscles ; but it is increased, during their relaxation, by the action of the diaphragm forcing outwards the viscera. The greatest
How excreta expelled.	diminution of the space is effected by the simultaneous contraction of all the muscular boundaries, as in the expulsion of the excreta.
Division of space.	<i>Division of the space.</i> A division has been made of the space into the abdomen proper and the cavity of the pelvis.
Abdomen proper.	The <i>abdominal portion</i> reaches from the diaphragm to the brim of the pelvis, and lodges nearly the whole of the alimentary tube and its appendages, together with the kidneys.
Pelvic portion.	The <i>pelvic portion</i> is situate below the brim of the pelvis, and contains chiefly the generative and urinary organs.
Abdomen proper here described.	The following description concerns the part of the cavity between the diaphragm and the brim of the pelvis. Towards the end of
Pelvis after.	the dissection of the abdomen, the pelvic portion will receive a separate notice (p. 539).
Abdominal cavity is	<i>Regions.</i> The upper part of the abdominal cavity is divided into regions by lines drawn through certain points of the parietes.
marked out into regions.	If two horizontal lines are carried round the body, so that one shall be opposite the lowest point of the thoracic wall on each side, and the other on a level with the highest point of the iliac crest, the abdomen will be divided into three zones,—upper, middle and lower.
Three lateral on each side,	Each of these zones is farther subdivided into three by a vertical line on each side, falling on the centre of Poupart's ligament. The
and three central.	regions marked off, on each side, from the three zones by the vertical line are named respectively, from above downwards, hypochondriac, lumbar, and iliac ; while the central parts are designated, from above down, epigastric, umbilical, and hypogastric.
Other subdivisions.	In addition, the middle and lower part of the hypogastric space is named pubic region, while the contiguous portions of the hypogastric and iliac constitute the inguinal region.
Things in cavity.	<i>Contents and their position.</i> The alimentary tube, the liver, pancreas, spleen, and kidneys occupy the abdomen proper.
Viscera seen without displacement.	<i>Superficial view.</i> On first opening the abdomen the following viscera appear (fig. 144):—Above and to the right is the liver, which is in great part concealed by the ribs. Lower down, and more to the left, a piece of the stomach is visible ; but this viscus lies mostly beneath the ribs and the liver. Descending from the stomach is a loose fold of peritoneum (the large omentum), which reaches to the pelvis, and conceals the small intestine : in some bodies the omentum is raised into the left hypochondriac region, and leaves the intestine uncovered. The cæcum (<i>cœ</i>) is usually to be seen in the right iliac region ; and sometimes a part of the sigmoid flexure of the colon comes to the surface in the corresponding situation on the left side.
General division of	Close above the pubic symphysis is the apex of the bladder (<i>bl</i>), with the urachus (<i>ur</i>) continued upwards from it ; and if the organ is distended, a larger part of it is exposed.
	The alimentary tube presents differences in form, and is divided

into stomach, small intestine, and large intestine ; and the two last are farther subdivided as will afterwards appear. The several viscera have the following general position :—The small intestine is much coiled, and occupies the greater part of the cavity ; while the great intestine arches round it. Both are held in position by portions of the serous lining. Above the arch of the great intestine are situate the stomach, the liver, the spleen, and the pancreas ; and below it is the convoluted small gut. Behind the intestine, on each side, is the kidney with its excretory tube.

alimentary
tube ;
position of
several
parts ;
and of
kidney.

Before the natural position of the viscera is disturbed, their situation in the different regions of the abdomen, and their relations to surrounding parts should be examined.

Relations
of viscera
to be seen.

RELATIONS OF THE VISCERA.

The STOMACH (fig. 144) intervenes between the gullet and the small intestine, and is partly retained in position by folds of the serous membrane. It is somewhat pyriform in shape, with the larger end on the left side ; and it is placed in the left hypochondriac and the epigastric regions.

Position
and relations
of the
stomach.

At its large end the stomach is joined by the œsophagus, which fixes it to the diaphragm. The opening of the œsophagus into the stomach is named the *cardia*, and lies behind the seventh costal cartilage of the left side about an inch from its junction with the sternum, being on a level with the tenth dorsal vertebra. To the left of the cardia, the *fundus* of the stomach bulges upwards in the left vault of the diaphragm. The concave border of the stomach to the right of the œsophagus is the *small curvature*, and is attached to the liver by a fold of peritoneum—the small omentum.

Cardia and
fundus ;
small
curvature ;

The right extremity leads into the small intestine (duodenum) by the *pyloric orifice*, the situation of which is indicated externally by a slight constriction of the tube, and a thickened band in the wall that may be felt with the finger. The pyloric end of the stomach is placed beneath the liver, and about two inches below the xiphi-sternal articulation, at the level usually of the disc between the twelfth dorsal and first lumbar vertebræ.

pyloric end ;

The anterior surface of the stomach is in contact above and to the right with the liver, on the left with the diaphragm, and between these with the abdominal wall. The posterior surface lies over the spleen, to which it is connected by a fold of peritoneum (gastro-splenic omentum), the left kidney and suprarenal capsule, the pancreas, and the transverse meso-colon.

anterior
and pos-
terior
surfaces ;

The convex border or *great curvature* is directed to the left and downwards, and has the great omentum attached to it ; along it lies the transverse colon. This is the most moveable part of the organ.

great curva-
ture is least
fixed part.

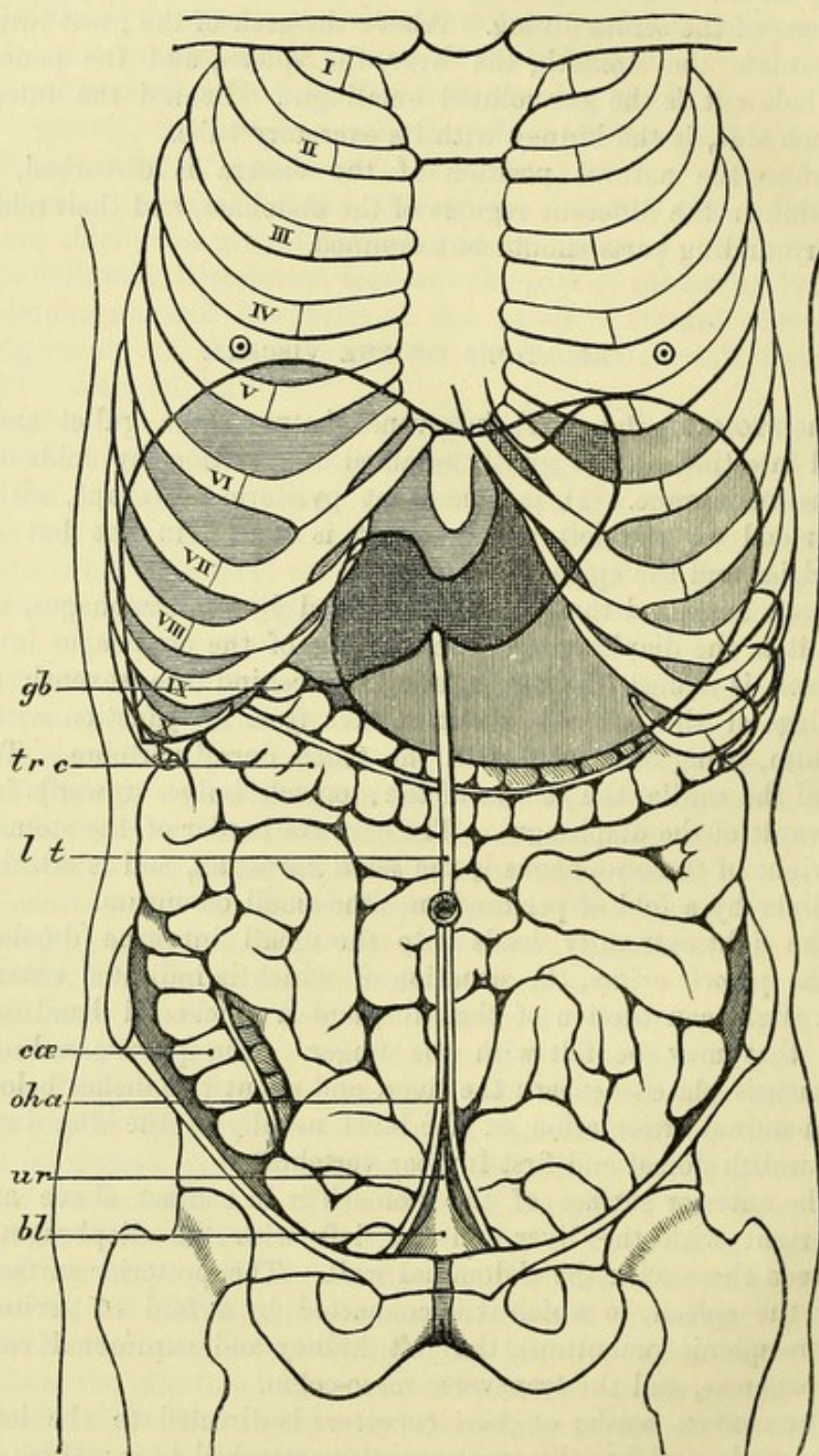
The form and position of the stomach vary with its degree of distension. When the organ is empty, it is flattened from before backwards, and drawn up towards the left hypochondriac region, the pyloric end reaching very little to the right of the middle line.

Changes in
form and
position ;
empty

and full
stomach.

But when full, the stomach becomes rounded, and its anterior surface is directed somewhat upwards; the fundus pushes upwards the

Fig. 144.



* Diagram showing the position of some of the abdominal viscera. The liver is shaded with horizontal, and the stomach with vertical lines. *gb.* Gall-bladder. *tr c.* Transverse colon. *lt.* Ligamentum teres of the liver. *cæ.* Cæcum. *o h a.* Obliterated hypogastric artery. *ur.* Urachus. *bl.* Urinary bladder.

diaphragm, pressing on the heart and left lung ; the great curvature moves to the left and downwards, as well as somewhat forwards ; and the pyloric extremity is carried to the right.

The SMALL INTESTINE reaches from the stomach to the right iliac region, where it ends in the large intestine. It is arbitrarily divided into three parts,—duodenum, jejunum, and ileum. Small intestine : extent and divisions.

The *duodenum* comprises the first nine or ten inches (twelve fingers' breadths) of the small intestine. By raising the liver it may be traced from the pyloric end of the stomach, at first backwards, and then downwards, until it disappears beneath the transverse colon. If the great omentum, with the attached transverse colon, be turned up over the margin of the thorax, and the mass of small intestine be drawn to the right, the end of the duodenum will be seen on the left of the spine. It here ascends for a short distance, and at the level of the second lumbar vertebra passes into the jejunum, forming a sharp bend forwards and downwards, which is named the *duodeno-jejunal flexure*. The relations of the duodenum cannot, however, be satisfactorily seen at present, and they will be examined at a later stage (p. 485). Duodenum : beginning, and ending : to be fully seen later.

The *jejunum* and *ileum* include the remainder of the small intestine, two-fifths belonging to the jejunum and three-fifths to the ileum, but there is no natural division between them. This part of the intestinal tube forms many convolutions in the umbilical, hypogastric, lumbar, and iliac regions of the abdomen ; and it descends commonly, but more extensively in the female, into the cavity of the pelvis. In front of the convolutions is the great omentum ; and behind, they are fixed to the spine by a large fold of peritoneum named the mesentery, which contains the vessels and nerves. The termination of the ileum ascends slightly from the pelvis to the right iliac fossa, crossing the external iliac vessels and the psoas muscle, to open into the large intestine at a spot a little to the outer side of the sacro-iliac articulation. Jejunum and ileum : situation ; relations ; end of ileum.

The LARGE INTESTINE OR COLON is more fixed than the jejunum and ileum, from which it is to be distinguished by its sacculated appearance, and by its being furnished with small processes of peritoneum containing fat—the *appendices epiploicæ*. It begins in the right iliac region in a rounded part or head (*cæcum*), and ascends to the liver through the right iliac and lumbar regions. Then crossing the abdomen below the stomach, it reaches the left hypochondriac region ; and it lies in this transverse part of its course between the epigastric and umbilical regions, or altogether in the latter. Finally, it descends, on the left side, through the regions corresponding with those it occupied on the right, and forms a remarkable bend (sigmoid flexure) in the left iliac fossa ; then becoming straighter (rectum) it passes through the pelvis to end on the surface of the body. Large intestine : how distinguished ; course and extent.

It is divided into six parts, viz., *cæcum*, ascending colon, transverse colon, descending colon, sigmoid flexure, and rectum. Divisions.

The *cæcum* (*caput cæcum coli* ; fig. 144, *cæ*) is placed in the right iliac fossa, above the outer half of Poupart's ligament. When Cæcum : position ;

- relations ; empty it may be entirely covered by the convolutions of the small intestine ; but more frequently it is found more or less distended, and resting against the anterior abdominal wall. The cæcum is as a rule entirely surrounded by peritoneum, which sometimes forms a small fold (meso-cæcum) behind it ; but occasionally it is closely bound down by the peritoneum being reflected off on each side, so as to leave the hinder surface uncovered, and connected to the iliac fascia by areolar tissue.
- peritoneum around it.
- Junction of ileum. This part of the large intestine is joined at its inner and posterior aspect by the termination of the ileum, which marks the division between the cæcum and ascending colon ; and near the blind extremity the cæcum has attached to it a slender worm-like process—the *vermiform appendix*. This process is usually directed upwards and inwards, under cover of the cæcum, to which it is connected by a fold of peritoneum.
- Vermiform process.
- Ascending colon : The *ascending colon* reaches from the cæcum to the under surface of the liver, where the intestine makes a bend known as the *hepatic flexure*. It lies against the iliacus and quadratus lumborum, and in its upper part along the outer border of the kidney. In front and to its inner side are the convolutions of the small intestine. The peritoneum fixes the ascending colon to the wall of the abdomen, and surrounds commonly about two-thirds of the circumference ; but it may encircle the tube, and form a fold behind (ascending meso-colon).
- parts around.
- Transverse colon : The *transverse colon* (fig. 144, *tr c*) begins at the hepatic flexure, and passes across to the left and upwards, along the great curvature of the stomach, as far as the spleen. Here another bend is formed at the junction with the descending colon, sharper than that on the right side, and named the *splenic flexure*.
- extent and course ;
- splenic flexure ;
- arch of colon ; In this course the transverse colon is deeper at each end than in the middle, and thus forms the *arch of the colon*, which has its convexity directed forwards. Above the arch are placed the liver and gall-bladder, the stomach, and the spleen ; and below, the convolutions of the small intestine. In passing from right to left, the transverse colon first lies over the right kidney and the second part of the duodenum, and is fixed to these organs by its peritoneum, which is arranged like that of the ascending colon. But beyond the duodenum, it is only loosely attached to the back of the abdomen by a long fold of peritoneum, the transverse meso-colon (fig. 145, *mc*) ; while the great omentum (*g om*), which passes between it and the stomach, covers it in front.
- relations of arch ;
- disposition of peritoneum.
- Descending colon : The *descending colon* extends from the spleen to the iliac crest, and is longer than the ascending part. At first it is placed deeply in the left hypochondriac region, resting against the diaphragm, and partly concealed by the stomach. Lower down, it has the small intestine in front and the quadratus lumborum behind. Along the inner side, it is closely applied to the outer part of the left kidney.
- situation ;
- and peritoneum. This part of the colon is smaller than either the right or the transverse portion, and is commonly less surrounded by the

peritoneum; its upper end is attached to the diaphragm by a special fold (pleuro-colic) of that membrane.

The *sigmoid flexure* of the colon, beginning at the iliac crest, first descends in the left iliac fossa, over the ilio-psoas muscle and the external iliac vessels, being fixed in this position by the peritoneum, until it reaches the brim of the pelvis. Here the intestine forms a large loop, which is provided with a long process of peritoneum—the sigmoid meso-colon, and is therefore freely moveable. The loop commonly hangs down in the cavity of the pelvis; but it often projects forwards in the iliac fossa, and reaches the anterior wall of the abdomen. Opposite the brim of the pelvis, in the neighbourhood of the left sacro-iliac articulation, it ends in the rectum.

Sigmoid flexure: course;

forms a loop, which varies in position;

ending.

The *rectum*, or the termination of the large intestine, is contained in the pelvis, and will be examined in the dissection of that cavity.

Rectum.

The LIVER (fig. 144) is situate in the right hypochondriac and the epigastric regions, and often reaches slightly into the left hypochondriac. It is covered in front by the ribs with their cartilages, except over a small area in the subcostal angle. Folds of peritoneum, called ligaments, attach it to the abdominal parietes.

Position of liver;

The upper surface fits against the diaphragm, and is convex on each side, but slightly hollowed in the centre below the heart: the right portion is more prominent than the left, and reaches to the level of the fourth intercostal space. This surface is divided into two parts, corresponding to the right and left lobes of the organ, by the falciform ligament.

surfaces, upper

The lower surface looks also somewhat backwards; it is in contact with the stomach, the first and second parts of the duodenum, the small omentum, the right kidney, and the beginning of the transverse colon. To this surface the small omentum, containing the hepatic vessels, is attached.

and lower;

The anterior border is thin and directed downwards. On the right side it is concealed by the ribs; but in the epigastric region it is exposed, running obliquely from the ninth right to the eighth left costal cartilage: it crosses the middle line of the body about a hand's-breadth below the xiphi-sternal articulation. The fundus of the gall-bladder (fig. 144, *gb*) projects beyond this edge, close to the ninth costal cartilage of the right side.

anterior border;

Posteriorly, the liver has the following relations, but they cannot all be seen at present:—The left lobe lies in front of the œsophagus, and is attached to the diaphragm by a triangular fold of peritoneum—the left lateral ligament. The two layers of peritoneum fixing the right lobe are for the most part widely separated, and constitute the coronary ligament; but at the right end they come together, and give rise to a small triangular fold which is distinguished as the right lateral ligament. The portion of the surface between the layers of the coronary ligament is adherent directly to the diaphragm by means of areolar tissue: in this space also the left suprarenal capsule touches the liver; and the inferior vena cava is embedded in a deep groove in its substance (fig. 158).

posterior relations of left lobe, and of right lobe.

Position is changed by diaphragm, and by posture of body.	The liver changes its situation with the ascent and descent of the diaphragm in respiration; for in inspiration it descends, and in expiration it regains its former level. In the upright and sitting postures also, it descends lower than in the horizontal condition of the body; so that when the trunk is erect, the anterior border may be felt below the edge of the ribs, but when the body is reclined, it is withdrawn within the margin of the thorax.
Spleen : position ;	The SPLEEN is deeply placed behind the stomach, at the back of the hypochondrium and the adjoining part of the epigastric region. It lies very obliquely, the upper end being near the spine, while the lower end reaches about half-way round the side of the body.
relations of surfaces, phrenic, gastric, and renal ;	Its outer or posterior surface is convex and free; it touches the diaphragm opposite the ninth, tenth and eleventh ribs. The anterior surface is concave and applied to the stomach, to which it is attached by the gastro-splenic omentum (fig. 146, <i>g s om</i>); the tail of the pancreas also touches the lower end of this surface. A third narrow surface, the internal, lies against the outer border of the left kidney in its upper half; and a fold of peritoneum, called the lienorenal ligament (fig. 146, <i>lr</i>), which contains the splenic vessels, passes between the two. The upper end of the spleen is close to the suprarenal capsule; the lower end rests on the splenic flexure of the colon and the pleuro-colic ligament.
of ends.	
Expose kidney on left side.	<i>Dissection.</i> The kidney should be examined on the left side of the body, so that the duodenum may not be displaced. In order to see it, the peritoneum and descending colon must be separated from the abdominal wall; and its casing of fat should be torn through with the fingers.
Kidney : situation ;	The KIDNEY is situate at the back of the abdomen, opposite the last dorsal and upper two or three lumbar vertebræ, and occupies parts of the epigastric, hypochondriac, umbilical and lumbar regions. Its position is somewhat oblique, the upper end being nearer to the spine than the lower; and the surface which is called anterior looks much outwards.
relations common to both,	The viscus lies behind the peritoneum, and is surrounded with fat. It rests upon the diaphragm, the psoas and quadratus lumborum muscles. Its upper end supports the suprarenal body; and at the inner border the vessels enter, and the duct (ureter) leaves the organ.
and special	<i>Differences on the two sides.</i> The right kidney is placed rather lower than the left; it reaches as high as the last intercostal space, while its fellow rises to the upper border of the eleventh rib. The right kidney has in front of it the liver and transverse colon, with the second part of the duodenum along its inner border; and the hepatic flexure of the colon lies against its outer border below. The left kidney has the stomach and pancreas in front, and the spleen and descending colon along its outer side.
of right,	
of left.	
Pancreas later.	The relations of the pancreas may be omitted for the present; they will be found on p. 486.

THE PERITONEUM.

This is the largest serous membrane in the body. In the male it is a closed sac, like other serous membranes; but in the female there is an aperture of communication with the Fallopian tube, and the mucous lining of the latter becomes continuous with the serous membrane. It lines the wall of the abdomen (parietal peritoneum), and is reflected over the several viscera (visceral peritoneum), some of which it invests completely, except where the vessels enter. The inner surface is free and smooth; but the outer is rough, when it is detached from the parts to which it is naturally adherent. The membrane, as it passes from viscus to viscus, or from the abdominal wall to viscera, forms processes or folds, to which different names are given, and which for the most part consist of two layers enclosing vessels.

Peritoneum :
general arrangement ;

surfaces ;

folds.

The continuity of the sac may be traced both horizontally and vertically.

Horizontal circle round the lower part of the abdomen. From the umbilicus the peritoneum may be followed along the abdominal wall on the left side to the hinder part of the lumbar region, where it partly surrounds the descending colon, and thence over the kidney to the front of the spine. Here it is reflected forwards along the superior mesenteric vessels, passes round the small intestine, and returns to the spine along the same vessels, thus forming the mesentery. From the spine it is continued in the same way on the right side, over the kidney, round the colon, and along the wall of the abdomen to the umbilicus again.

Circle of the membrane opposite umbilicus.

Vertical circles (fig. 145). Starting at the under surface of the liver, the small omentum (*s om*) is found descending to the small curvature of the stomach, where the two layers of which it consists separate to enclose that organ, one passing in front and the other behind. At the great curvature they meet again, and give rise to the great omentum or epiploon (*g om*). After descending to the lower part of the abdomen, they bend backwards and ascend to the transverse colon, which they enclose in the same way as the stomach; and they are then continued to the posterior abdominal wall, forming the transverse meso-colon (*m c*). Opposite the lower border of the pancreas these two layers, which have been followed from the liver to the spine, part company,—the one passing upwards, and the other downwards.*

Circles from above down :
omental layers ;

transverse meso-colon ;

The ascending layer is continued in front of the pancreas and

its ascending layer ;

* In the foetus at an early period the reflected portion of the great omentum is continued up to the spine; and while the anterior layer ascends over the pancreas as explained in the text, the posterior or descending layer surrounds the transverse colon before passing into the mesentery, thus forming a transverse meso-colon distinct from the great omentum. The front of the transverse meso-colon then becomes adherent to the opposed part of the great omentum, so that the two are united in a single process, and the colon appears to be enclosed between the omental layers. Occasionally traces of the foetal condition are met with in the adult.

diaphragm, and is then reflected on to the posterior surface of the liver, where it covers the part called the Spigelian lobe, and passes into the hinder layer of the small omentum.

mesentery; The descending layer immediately passes off along the superior

mesenteric vessels to the small intestine (jejunum and ileum), forming the mesentery (*m*) as before explained in tracing the horizontal circle.

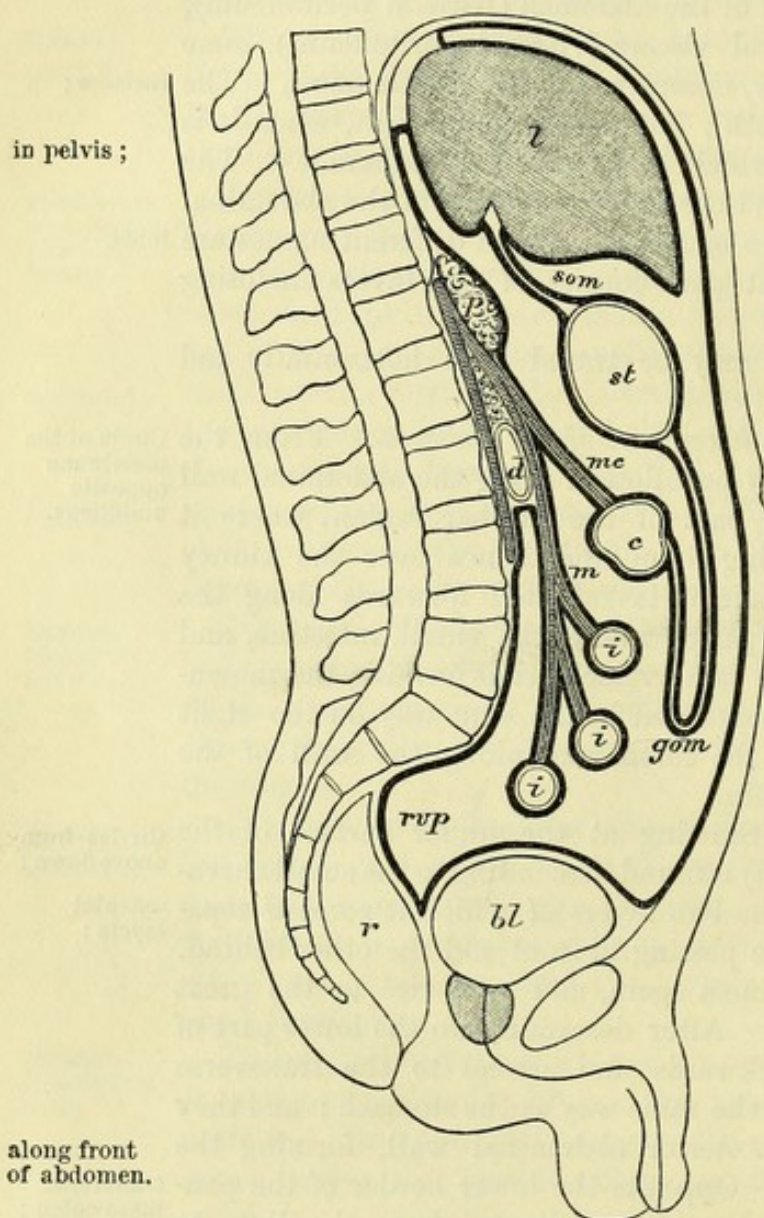
From the root of the mesentery, this layer descends over the lower end of the aorta and the promontory of the sacrum to the pelvis, where it partly invests the viscera of that cavity. Thus, it surrounds the upper part of the rectum, and attaches that to the front of the sacrum by the meso-rectum; from the rectum it is reflected forwards to the bladder in the male, or the uterus in the female, forming a pouch between the two; and after covering the upper part of the bladder, it passes off at the front and sides to the abdominal wall, forming the fossæ before noticed in the inguinal region (p. 462).

Lastly, the membrane is continued upwards, lining the anterior wall of the abdomen, and the

under surface of the diaphragm nearly to the spine; there it is reflected over the upper surface of the liver, and then turning round to the under surface it joins the anterior layer of the small omentum.

In the foregoing account it will be seen that two vertical circles have been traced, which surround distinct cavities in the figure. The portion of the membrane which forms the circle behind the

Fig. 145.*



in pelvis ;

along front
of abdomen.

Small and
large bags :

* Diagram showing the arrangement of the peritoneum in a median section of the abdomen. *l.* Liver. *st.* Stomach. *c.* Transverse colon. *p.* Pancreas. *d.* Duodenum, third part. *i, i, i.* Coils of small intestine. *r.* Rectum. *bl.* Bladder. *som.* Small omentum. *gom.* Great omentum. *mc.* Transverse meso-colon. *m.* Mesentery. *rvp.* Recto-vesical pouch.

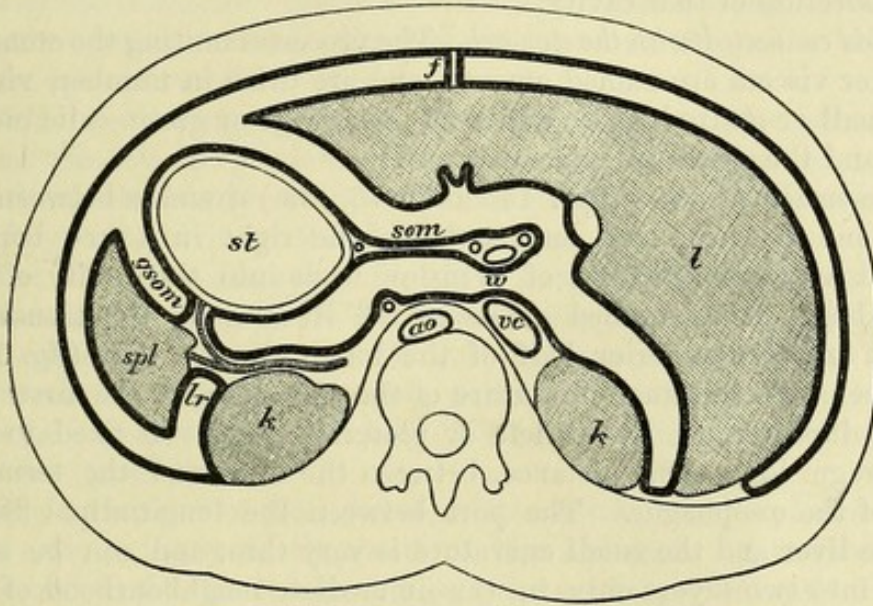
liver and stomach is known as the small bag of the peritoneum ; while the part in front of those organs, which is much more extensive, and reaches into the pelvis, constitutes the large bag. The two bags are however continuous, and their cavities communicate through the aperture termed the foramen of Winslow, as will be apparent by tracing the horizontal circle at a higher level than before, viz., immediately above the pyloric end of the stomach.

Horizontal circle at the level of the foramen of Winslow (fig. 146). Beginning in front at the falciform ligament of the liver (*f*), the

their continuity.

Circle at foramen of Winslow :

Fig. 146.*



peritoneum may be followed on the left side along the abdominal wall and the diaphragm to the outer part of the left kidney, where it is reflected along the back of the splenic vessels to the spleen, forming one layer of the lieno-renal ligament (*lr*). Having furnished the investment of the spleen, the membrane passes as the outer layer of the gastro-splenic omentum (*gs om*) to the stomach, and over the front of the latter into the anterior layer of the small omentum (*s om*). From the front, it turns round the hepatic vessels to the back of the small omentum ; and at the spot where it passes behind the vessels it bounds the foramen of Winslow (*w*), and the small bag begins. It then forms in succession the posterior covering of the stomach, and the inner layer of the gastro-splenic omentum and lieno-renal ligament, and turning to the right, is continued

covering of spleen ;

small omentum ;

foramen of Winslow and small bag.

* Diagram of a horizontal section of the abdomen through the twelfth dorsal vertebra, to show the arrangement of the peritoneum at the foramen of Winslow and round the spleen. *l*. Liver. *st*. Stomach. *spl*. Spleen. *k, k*. Kidneys. *ao*. Aorta ; farther forwards the coronary artery is seen, cut twice. *vc*. Inferior vena cava. *w*. Foramen of Winslow. *s om*. Small omentum, at the right end of which are, from left to right, the hepatic artery, portal vein, and bile-duct. *gs om*. Gastro-splenic omentum. *lr*. Lienorenal ligament. *f*. Falciform ligament. In front of the left kidney is the splenic artery, sending its branches to the stomach between the layers of the gastro-splenic omentum.

over the left kidney and the diaphragm to the inferior vena cava, where it forms the posterior boundary of the foramen of Winslow. Here becoming large bag again, it can be followed over the right kidney to the liver, and round the latter to the falciform ligament. On the right side of the falciform ligament the peritoneum simply passes over the liver and diaphragm.

Chief folds
of the
peritoneum.

SPECIAL PARTS OF THE PERITONEUM. After tracing the continuity of the serous sac over the wall and the viscera, the dissector is to study the chief processes or folds of the membrane in connection with the alimentary tube and its appendages. The pieces of peritoneum in connection with the viscera of the pelvis will be seen in the dissection of that cavity.

Gastric
folds :
omenta.

Folds connected with the stomach. The processes uniting the stomach to other viscera are named omenta, and are three in number, viz.—the small or gastro-hepatic omentum, the large or gastro-colic omentum, and the gastro-splenic omentum.

Gastro-
hepatic
omentum :

attach-
ments ;

The *small omentum* (figs. 145 and 146, *s om*) stretches between the liver and stomach, and ends towards the right in a free border, behind which the foramen of Winslow leads into the cavity of the small bag. It is attached above to the liver along the transverse fissure and the posterior half of the longitudinal fissure (fig. 158, *so*) ; below to the small curvature of the stomach and the first part of the duodenum. At its left or posterior end it is fixed to the diaphragm for a short distance, between the liver and the termination of the œsophagus. The part between the longitudinal fissure of the liver and the small curvature is very thin, and can be separated into two layers only in the immediate neighbourhood of the viscera ; but that extending from the transverse fissure to the duodenum is much thicker, and encloses the hepatic artery, portal vein, common bile-duct, and nerves and lymphatics of the liver.

contents.

Gastro-colic
omentum :

formation ;

cavity ;

The *great omentum* (fig. 145, *g om*) is the largest fold of the peritoneum, and results from the meeting of two layers which leave the great curvature of the stomach, and the first part of the duodenum. The sheet thus formed descends in front of the intestine, extending farther on the left side than the right, and at the lower part of the abdomen is doubled backwards to join the transverse colon. The fold therefore encloses the lower part of a space (cavity of the small bag), which originally extended to its lower border ; but in the adult the anterior and posterior portions of the omentum are usually closely adherent, and the cavity seldom exists below the transverse colon.

fusion of
layers.

Between the layers of the great omentum, especially near the stomach, are some branches of vessels, minute nerves, and a variable quantity of fat ; but over the greater part of their extent the layers are inseparably united, and the resulting membrane is very thin, and in places cribriform.

Cavity of
small bag :

boundaries

Cavity of the small bag or sac of the omentum. By dividing the fore part of the great omentum near the stomach, this cavity will be opened, and the hand may be introduced to ascertain its extent. In front it is bounded by the anterior part of the great omentum, the stomach, the small omentum, and the Spigelian lobe of the liver.

Behind it are the posterior part of the great omentum, the transverse colon and meso-colon, the pancreas, the left kidney and suprarenal capsule, and the diaphragm. To the right it extends as far as the inner border of the duodenum (second part), and to the left as far as the spleen. Between the duodenum and the liver it opens into the general cavity or large bag by the foramen of Winslow.

The *foramen of Winslow* is bounded in front by the right portion of the small omentum, containing the hepatic vessels; below are the same vessels and the first part of the duodenum; above is the caudate lobe of the liver; and behind, the inferior vena cava.

The *gastro-splenic omentum* (fig. 146, *gs om*) reaches from the back of the stomach to the front of the spleen, and is continued below into the great omentum. Between its layers are the gastric branches of the splenic vessels.

Folds of the large intestine. The disposition of the peritoneum round the several portions of the colon has been explained in giving their relations (p. 469). The following processes pass between the large intestine and the abdominal wall:—

The *transverse meso-colon* (fig. 145, *m c*) extends from the lower border of the pancreas to the transverse colon, to the left of the spot where the latter crosses the duodenum, and contains the middle colic vessels. In the adult it is formed by a continuation of the omental layers, but in the foetus it was a distinct process of peritoneum (p. 473).

The upper end of the left colon has a distinct fold—*pleuro-colic* or *costo-colic*, fixing it to the wall of the abdomen. Attached by a wide end to the diaphragm opposite the tenth and eleventh ribs, it passes transversely inwards to the colon, and forms the lower boundary of a hollow in which the spleen rests.

The *sigmoid meso-colon* is a long process of the serous membrane, which attaches the loop of the sigmoid flexure to the brim of the pelvis: it contains the sigmoid vessels.

The *meso-rectum* contains the superior hæmorrhoidal vessels, and attaches the upper part of the rectum to the front of the sacrum.

In some bodies the ascending and descending colon are surrounded by peritoneum, which meets behind the gut and forms a fold—the *ascending* or *descending meso-colon*, between it and the abdominal wall. The cæcum may also be provided with a similar fold (*meso-cæcum*) attaching it to the right iliac fossa (p. 469).

Small processes of the peritoneum are attached along the tube of the great intestine, chiefly to the transverse colon; they are the *appendices epiploicæ*, and contain fat.

Folds to the small intestine. The small intestine is not enveloped by the peritoneum after the same manner throughout. For while the jejunum and ileum are attached to the abdominal wall by one process (mesentery), the duodenum has special relations with the serous membrane.

Serous covering of the duodenum. The first part of the duodenum has peritoneal relations like those of the stomach, but its posterior or left surface is only covered for a short distance by the serous

Boundaries
of foramen
of Winslow.

Gastro-
splenic
omentum.

Peritoneal
folds to
large
intestine:

transverse
meso-colon;

pleuro-colic
fold;

sigmoid
meso-colon;

and meso-
rectum;

sometimes
an ascend-
ing or
descending
meso-colon,
or meso-
cæcum.

Appendices
epiploicæ.

Peritoneal
covering of
small intes-
tine.

Peritoneum
on duode-
num.

membrane. The second part is covered in front, except at the spot where it is crossed by the transverse colon. And the last part, which crosses the aorta, is separated from the peritoneum in the middle by the superior mesenteric vessels (fig. 145), but is covered in front by the serous membrane on each side of them. In many cases the peritoneum extends inwards behind the end of the duodenum, forming a recess or pouch to which the name of *duodeno-jejunal fossa* has been given.

Mesentery : *Fold of the jejunum and ileum.* The *mesentery* supports the rest of the small intestine, and is stronger than any other piece of the serous membrane. Its hinder end is narrow, and is attached along the front of the spine and great vessels from the left side of the second lumbar vertebra to the right sacro-iliac articulation. The other end of the fold is wide, and is connected with the intestine.

form ;

attach-ments.

Peritoneal ligaments of the liver : *Ligaments of the liver.* On the upper surface of the liver is the suspensory ligament ; and along the back there is a wide process which is divided into coronary, and right and left lateral ligaments.

falciform ligament ; The *suspensory* or *falciform ligament* extends from before backwards between the upper convex surface of the liver and the parietes of the abdomen. Its lower border is concave, and fixed to the liver ; while the upper border is convex, and is connected to the abdominal wall on the right of the linea alba, and to the under surface of the diaphragm. In its free anterior border or base is the remains of the umbilical vein, which is named the *round ligament of the liver*.

coronary ligament ; The *coronary ligament* is placed at the back of the right lobe of the liver, and is composed of two layers which are separated by an interval (p. 471). The superior layer passes from the liver to the diaphragm ; but the inferior layer (fig. 158, *icl*) is reflected over the front of the kidney and inferior vena cava. This layer becomes continuous round the Spigelian lobe with the posterior layer of the small omentum.

right lateral ligament ; The *right lateral ligament* (fig. 158, *rl l*) is a small fold at the right end of the coronary ligament, formed by the meeting of the two layers for a short distance.

left lateral ligament. The *left lateral ligament*, larger than the foregoing, is a triangular fold of peritoneum, with a free edge turned to the left. It is attached by its anterior border to the liver above the margin of the left lobe ; and by its posterior border to the diaphragm in front of the œsophageal opening. At its right end the upper layer is continued into the left side of the falciform ligament, and the lower layer into the front of the small omentum.

MESENTERIC VESSELS AND SYMPATHETIC NERVES.

Examine first vessels to intestine. *Directions.* The mesenteric vessels and nerves, which supply the greater part of the alimentary tube, may be first dissected. After these have been examined, and the relations of the aorta and vena cava have been learnt, most of the intestine can be taken out to give room for the display of the viscera and vessels in the upper part of the abdomen.

MESENTERIC VESSELS. The superior and inferior mesenteric arteries are two large branches of the aorta, which supply the intestine, except a part of the duodenum and the lower end of the rectum. Each is accompanied by a vein, and by a plexus of the sympathetic nerve. Mesenteric vessels.

Dissection (fig. 147). For the dissection of the superior mesenteric vessels and nerves, the transverse colon and the great omentum are to be placed on the margin of the ribs, and one layer (anterior or right) of the mesentery is to be removed. While tracing the branches of the artery to the small intestine, corresponding veins and slender offsets of the sympathetic nerve on the arteries will be met with. Mesenteric glands and lacteal vessels also come into view at the same time. Dissection of superior mesenteric vessels,

The branches from the right side of the vessel to the large intestine are to be next followed under the peritoneum; and after all the branches have been cleaned, the trunk of the artery should be traced back beneath the pancreas. The surrounding plexus of nerves should be also defined. and nerves.

The **SUPERIOR MESENTERIC ARTERY** (fig. 147, *a*) supplies wholly the small intestine beyond the duodenum, and half the large intestine, viz., as far as the end of the transverse colon. Superior mesenteric artery

Arising from the aorta near the diaphragm, the vessel is directed downwards between the layers of the mesentery, forming an arch with the convexity to the left side, and terminates in offsets to the end of the small intestine. At first the artery lies beneath the pancreas and the splenic vein; and as it descends to the mesentery it is placed in front of the duodenum and the left renal vein. It is surrounded by a plexus of nerves, and accompanied by the vein of the same name. courses in the mesentery; relations,

Branches. The artery furnishes a small offset to the pancreas and duodenum, intestinal branches to the jejunum and ileum, and colic branches to the large intestine. and branches.

a. The *inferior pancreatico-duodenal artery* (*b*) is small, and usually arises in common with the first intestinal branch. It is directed to the right between the pancreas and duodenum, to both of which it supplies branches, and anastomoses with the superior pancreatico-duodenal artery from the hepatic. Pancreatico-duodenal.

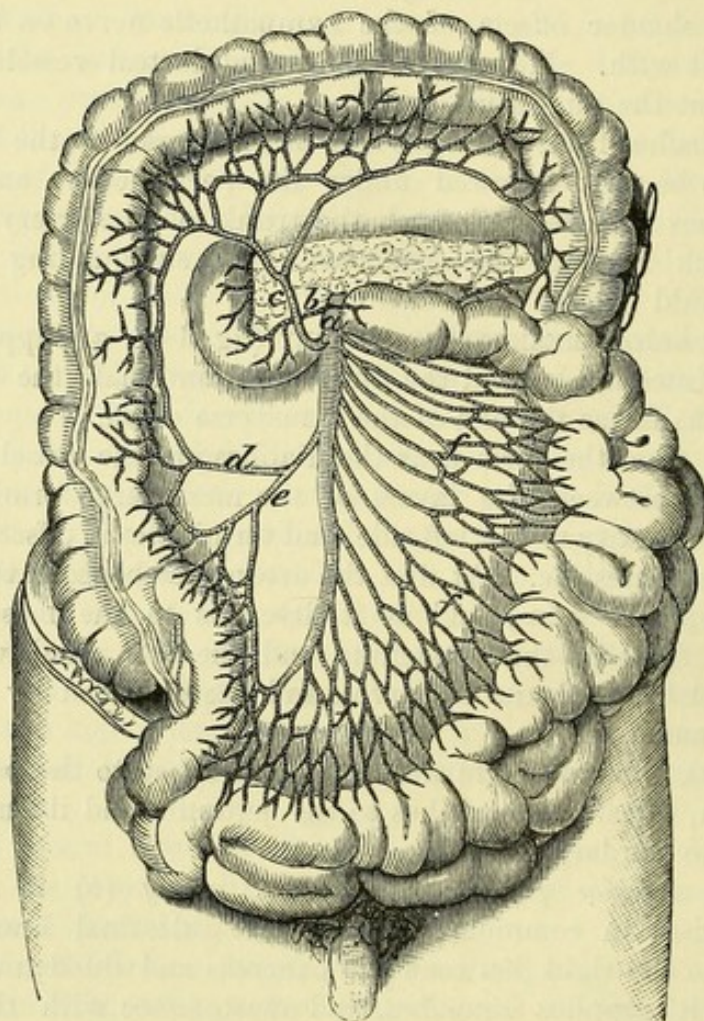
b. The *intestinal branches* for the jejunum and ileum (*f*) are twelve or more in number, and pass from the left side of the artery between the layers of the mesentery. About two inches from their origin the branches bifurcate, and the resulting pieces unite with similar offsets from the collateral arteries, so as to form a series of arches. From the convexity of the arches other branches take origin, which divide and unite as before. This process is repeated four or five times between the origin and the distribution, but at each branching the size of the vessels diminishes. From the last set of arches twigs are sent to the intestine on both aspects of the tube, and anastomose round it. Branches to small intestine: number and arrangement in arches; distribution on the gut.

The *branches to the large intestine* are three in number, ileo-colic, right colic, and middle colic arteries. Arteries of large gut.

Ileo-colic
branch runs
to cæcum.

c. The *ileo-colic artery* (e) arises from the right side of the trunk, and divides opposite the cæcum into ascending and descending branches. The ascending branch supplies the cæcum with the vermiform appendix and the beginning of the ascending colon, and anastomoses with the right colic artery; while the descending branch joins in a loop with the termination of the mesenteric trunk, and distributes offsets to the lower end of the ileum.

Fig. 147.*



Right colic
branch sup-
plies ascend-
ing colon.

d. The *right colic artery* (d) is frequently conjoined at its origin with the preceding. Near the ascending colon it divides into ascending and descending branches, which anastomose with the ileo-colic artery on the one side, and with the middle colic on the other.

Middle colic
branch
passes to
transverse
colon;

e. The *middle colic branch* (c) springs from the upper part of the artery, and entering between the layers of the transverse mesocolon, divides into two branches: the right one anastomoses with the artery to the ascending colon, and the left with the left colic branch of the inferior mesenteric artery (fig. 148, c). The intestinal

* Superior mesenteric artery and its branches (Tiedemann). a. Superior mesenteric. b. Inferior pancreatico-duodenal. c. Middle colic. d. Right colic. e. Ileo-colic. f. Intestinal branches to the jejunum and ileum.

twigs are united in arches before entering the gut, like those to the small intestine. branches form arches.

The *superior mesenteric vein* (fig. 150, *b*) is formed by the union of branches from the intestine corresponding to the offsets of the artery. The trunk passes beneath the pancreas on the right side of the artery, and there joins the splenic vein to form the *vena portæ*. At the lower border of the pancreas it receives the right gastro-epiploic branch from the stomach (fig. 150, *c*). Superior mesenteric vein.

The MESENTERIC LYMPHATIC GLANDS are numerous between the layers of the mesentery. An upper group lies by the side of the artery, and contains the largest glands; and a lower group, near the intestine, is lodged in the intervacular spaces. The chyloferous vessels of the small intestine, and the absorbents of the part of the large intestine supplied by the superior mesenteric artery, pass through the mesenteric glands in their course to the thoracic duct. Mesenteric glands: lymphatics entering them.

Along the side of the ascending and the transverse colon are a few other small lymphatic glands, *meso-colic*, which receive some absorbents of the large intestine. Meso-colic glands.

Dissection (fig. 148). By drawing the small intestine over to the right side, the dissector will observe the inferior mesenteric artery on the front of the aorta, a little above the bifurcation. The peritoneum should be removed from its surface, and the branches should be traced outwards to the remaining half of the large intestine: a part of the artery enters the pelvis, but this will be dissected afterwards. On the artery and its branches the inferior mesenteric plexus of nerves ramifies. Dissection of inferior mesenteric artery,

The inferior mesenteric vein is to be followed upwards beneath the pancreas to its junction with the superior mesenteric or the splenic vein. and vein:

On the aorta the dissector will meet with a plexus of nerves, which is to be left uninjured. aortic plexus.

The INFERIOR MESENTERIC ARTERY (fig. 148, *b*) supplies branches to the large intestine beyond the transverse colon, and communicating with the superior mesenteric, continues the chain of anastomoses along the intestinal tube. Inferior mesenteric artery:

This vessel is of smaller size than the superior mesenteric, and arises from the aorta from one to two inches above the bifurcation. It descends, lying at first on, and then close to the left side of the aorta, and after giving off branches to the descending colon and the sigmoid flexure, terminates as the superior hæmorrhoidal artery to the rectum. origin, and branches.

a. The *left colic artery* (*c*) passes out in front of the left kidney, and divides into an ascending and a descending branch for the supply of the descending colon: by the ascending offset it anastomoses with the middle colic branch of the superior mesenteric. Left colic branch to descending colon

b. The *sigmoid artery* (*d*) is distributed to the sigmoid flexure, and divides into offsets which anastomose above with the preceding colic, and below with the hæmorrhoidal branch. Here, as in the rest of the intestinal tube, arches are formed by the arteries before they reach the intestine. Sigmoid branch to sigmoid flexure.

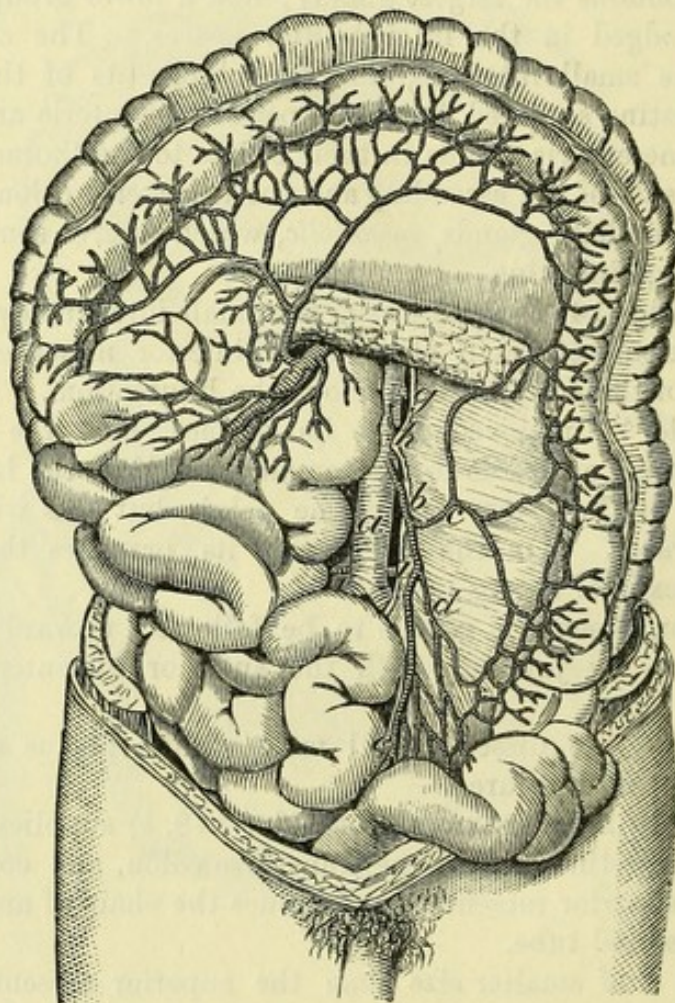
Branch to
rectum.

c. The *superior hæmorrhoidal artery* (*e*) crosses over the left common iliac vessels, and enters between the layers of the meso-rectum, to be distributed to the lower end of the large intestine : it will be described in the dissection of the pelvis.

Inferior
mesenteric
vein :
origin,
course, and

The *inferior mesenteric vein* (fig. 150, *d*) begins in the part of the large intestine to which its companion artery is distributed, and ascends over the psoas muscle higher than the origin of the artery. Passing beneath the pancreas, the vein inclines to the right, and

Fig. 148.*



terminations. opens into the superior mesenteric trunk at its junction with the splenic, or sometimes into the splenic vein.

No valves
in veins.

Both mesenteric veins are without valves, and may be injected from the trunk to the branches, like an artery.

Lymphatic
glands.

Lymphatic glands are ranged along the descending colon and the sigmoid flexure. The absorbents of the intestine, after passing through these glands, enter the left lumbar lymphatic glands.

Plexuses of
the sympa-

SYMPATHETIC NERVE. The following plexuses of the sympathetic

* The lower mesenteric artery, and the aorta, seen by turning aside the upper mesenteric artery and the small intestine (Tiedemann). *a.* Aorta. *b.* Inferior mesenteric artery. *c.* Left colic, *d.* Sigmoid, and *e.* Superior hæmorrhoidal branches. *f.* Superior mesenteric. *g.* Renal. *h.* Spermatic of the left side.

on the vessels, viz., superior mesenteric, aortic, spermatic, and inferior mesenteric, are derived from the solar plexus beneath the stomach. The remaining portion of the sympathetic nerve in the abdomen will be subsequently referred to (p. 491).

Dissection. On the two mesenteric arteries the dissector will have already made out the plexuses of nerves distributed to the intestinal tube beyond the duodenum.

He has now to trace on the aorta the connecting nerves between the mesenteric plexuses, by taking the peritoneum from the aorta below the pancreas. From the upper part of the aortic plexus an offset is to be followed along the spermatic artery; this may be done on the left side, where the vessel is partly laid bare.

By detaching the peritoneum below the bifurcation of the aorta, and following downwards over the iliac arteries the nerves from the aortic plexus and the lumbar ganglia, the dissector will arrive at the hypogastric plexus, above the promontory of the sacrum.

The *superior mesenteric plexus* is a large bundle of nerves, and is distributed to the same extent of the intestinal tube as the mesenteric artery. The nerves surround closely the trunk and larger branches of the artery; but near the intestine some of them leave the vessels, and divide and communicate before entering the gut. The offsets of the main plexus are named after the arteries which they accompany, viz., intestinal nerves to the small intestine, and ileo-colic, right colic, and middle colic plexuses to the large intestine.

The *aortic plexus* is an open network of nerves covering the aorta below the superior mesenteric artery; it is stronger on the sides than the front of the aorta, in consequence of its receiving accessory branches from the lumbar ganglia, especially the left. Above, the plexus derives an offset, on each side of the aorta, from the solar and renal plexuses. It ends below, on each side, in branches which cross the common iliac artery, and enter the hypogastric plexus. From it offsets are furnished to the spermatic and inferior mesenteric arteries.

The *spermatic plexus*, formed by roots from both the aortic and the renal plexus, runs on the spermatic artery to the testicle; in the cord it joins other filaments on the vas deferens.

In the female, the nerves on the ovarian (spermatic) artery are furnished to the ovary and the uterus.

The *inferior mesenteric plexus* supplies the part of the intestinal tube to which its artery is distributed. This plexus is furnished from the left side of the aortic plexus; and the nerves composing it are whiter and larger than in either of the preceding plexuses of the sympathetic. Near the sigmoid flexure the branching of the nerves and the union of contiguous twigs are well marked. Its offsets (plexuses) are left colic, sigmoid, and superior hæmorrhoidal: they ramify on those arteries, and have a like distribution.

The *hypogastric plexus*, or the large prevertebral centre for the supply of sympathetic nerves to the viscera of the pelvis, is situated in front of the last lumbar vertebra. It is formed by the union of the prolongations of the aortic plexus; and the nerves composing it

thetic to the viscera.

Dissection of

aortic plexus, and

hypogastric plexus.

Superior mesenteric plexus

is on artery of same name: secondary plexuses.

Aortic plexus is between mesenteric arteries:

offsets.

Spermatic plexus:

in female.

Inferior mesenteric plexus:

nerves join like the vessels; secondary plexuses.

Hypogastric plexus:

situation; formatio.

are of large size, and interlace in a dense flattened mass, without any interspersed ganglia. Below, the plexus divides into two portions, right and left, which are continued downwards on the inner side of internal iliac vessels to the pelvic plexuses.

RELATIONS OF AORTA AND VENA CAVA.

Before the viscera are removed from the body, the relations of the abdominal aorta and vena cava may be learnt.

Dissection
of aorta,

Dissection. To see the aorta above the origin of the superior mesenteric artery, it will be necessary to detach the great omentum from the stomach, without injuring the gastro-epiploic arteries along the great curvature; and after raising the stomach, to remove the peritoneum from the surface of the pancreas. A short arterial trunk (coeliac axis) above the pancreas is not to be quite cleaned now, otherwise the nerves about it would be destroyed.

and vena
cava.

The vena cava on the right side of the aorta may be followed up as far as the liver, where it disappears. The relations of its upper end can be better observed after the dissection of the vessels of the liver.

Aorta lies
on front of
spine:

The AORTA enters the abdomen between the pillars of the diaphragm, and divides into the common iliac arteries opposite the fourth lumbar vertebra. At its beginning the vessel lies somewhat to the left of the middle line; and it commonly inclines slightly inwards as it descends.

parts
around.

In the abdomen the aorta is covered at first by the pancreas, then by the third part of the duodenum, and for a short distance below by the peritoneum. Beneath the pancreas it is crossed by the splenic vein above the superior mesenteric artery, and by the left renal vein below that vessel; and the solar and aortic plexuses of the sympathetic lie along its anterior surface throughout. It rests on the lumbar vertebræ, with the pillars of the diaphragm embracing it at the beginning. To its right side is the vena cava. For its relation to other deep parts, see p. 527.

Vena cava
inferior:

The INFERIOR VENA CAVA begins opposite the fifth lumbar vertebra by the union of the common iliac veins, and reaches thence to the heart.

extent;

relations;

is by the
side of the
aorta,

except
above.

The venous trunk is placed on the front of the vertebral column, to the right of the aorta. It lies close to the aorta, and is concealed by the same viscera as high as the crus of the diaphragm; but above that spot it is inclined away from the artery, and ascending in front of the diaphragm, is embedded in the back of the liver for about an inch and a half. Lastly, it leaves the abdomen by an aperture in the tendinous centre of the diaphragm, on the right of, and higher than, the aortic opening.

Arteries
crossing it;

Its relations with vessels are not the same as those of the aorta. Beneath it are the right lumbar, renal, capsular, and diaphragmatic arteries; and crossing over it below the kidney is the spermatic. Superficial to it beneath the pancreas is the beginning of the portal vein.

and vein.

RELATIONS OF THE DUODENUM AND PANCREAS.

Dissection. To see satisfactorily the duodenum and the pancreas, the intestinal tube beyond the duodenum is to be removed in the following way:—A double ligature is to be placed on the upper part of the jejunum, another on the lower end of the sigmoid flexure of the colon, and the gut is to be cut through between the pieces of string where it is tied. The detached piece of the intestinal tube is to be taken away by cutting through the vessels, and the peritoneum connecting it to the wall of the abdomen. After it has been separated, it is to be set aside for future study while the body is turned. Remove intestine

The student should moderately inflate the stomach and duodenum from the cut extremity of the latter, and remove the loose peritoneum and the fat: while cleaning them, he should lay bare the larger vessels and nerves. to see the duodenum,

On turning upwards the stomach, the pancreas may be traced from the spleen on the one side to the duodenum on the other (fig. 149). By pulling forwards the duodenum, the common bile-duct may be found behind, between the intestine and the head of the pancreas; and some of the pancreas may afterwards be removed, to show its duct entering the duodenum. and pancreas, with duct.

DUODENUM (fig. 149, D). The first part of the small intestine, or the duodenum, begins at the pyloric end of the stomach, and crossing the spinal column, ends at the duodeno-jejunal flexure (p. 469), on the left side of the second lumbar vertebra. It makes a curve round the head of the pancreas, and is placed in the epigastric and umbilical regions of the abdomen. From its winding course round the pancreas it is divided into three portions, as follows:— Duodenum: extent; course and situation; division.

The *first* or *superior portion* is nearly horizontal, and is free and moveable like the stomach. It measures about two inches in length, and is directed backwards from the pylorus to near the upper end of the right kidney. Above and in front are the liver and gall-bladder; below is the head of the pancreas; and behind it are the common bile-duct, the portal vein, and the gastro-duodenal artery. First part is shortest, and is moveable.

The *second* or *middle portion*, about three inches in length, descends to the level of the third lumbar vertebra, and is fixed almost immoveably by the peritoneum and the pancreas. In front of it are the liver and transverse colon; behind it the inner border of the kidney and the renal vessels; and on its inner side the head of the pancreas, with the common bile-duct. The ducts of the liver and pancreas open into this part of the duodenum. Second part is vertical, and fixed.

The *third* or *inferior portion* is the longest of all: it first crosses from right to left opposite the third lumbar vertebra, and then ascends for a short distance on the surface of the left psoas muscle to its termination in the jejunum. It lies in front of the vena cava and aorta, and its anterior surface is crossed by the superior mesenteric vessels. Above it is the pancreas. Third part is longest, and also fixed.

The peritoneal relations of the duodenum have been noticed at p. 477.

Pancreas :
situation
and form ;

PANCREAS (fig. 149, E). The pancreas is situate behind the stomach, extending from the duodenum to the spleen, and occupying parts of the epigastric and left hypochondriac regions. In form it is elongated, with its right portion much expanded from above down, constituting the head ; this part lies in front of the first and second lumbar vertebræ, the great vessels intervening.

relations,
of surfaces,

The gland is covered in front by peritoneum derived from the ascending layer of the transverse meso-colon. Its anterior surface is for the most part concave, corresponding to the stomach ; but in front of the spine it forms a projection (*omental tuberosity*, His) opposite the small curvature and lesser omentum. Posteriorly it is in contact with the vena cava, aorta, pillars of the diaphragm, left kidney and renal vessels, splenic vein and beginning of the vena portæ.

of borders,

Projecting above the pancreas, where it crosses the aorta, is the cœliac axis, from which the splenic artery runs to the left along the upper border ; while on the right side the hepatic artery and the first part of the duodenum lie above it. At the lower border is the third part of the duodenum ; and the superior mesenteric vessels emerge between the two.

and of ends.

The head of the pancreas is received into the concavity of the duodenum ; and the common bile-duct lies between the two for a short distance behind. The greater breadth of the head is due to a portion of the gland being bent downwards ; and this projecting part is directed to the left along the duodenum, beneath the superior mesenteric vessels. The left end or tail touches the spleen, and rests on the splenic flexure of the colon.

CÆLIAC AXIS AND PORTAL VEIN.

Arteries of
viscera.

A short branch of the aorta—the cœliac axis—furnishes arteries to the stomach and duodenum, the liver, pancreas, and spleen : it subdivides into three primary branches—coronary, hepatic, and splenic.

Veins.

The veins corresponding to the arteries (except the hepatic) are collected into one trunk—the vena portæ.

How to dis-
sect cœliac
axis,
and branch-
es,
coronary,

Dissection. The vessels have been in part laid bare by the previous dissection, and in tracing them out fully the student should spare the nerve-plexuses around them. Supposing the liver well raised, he may first follow to the left side the small coronary artery, and show its branches to the œsophagus and the stomach.

hepatic,

Next, the hepatic artery, with the portal vein and the bile-duct, may be traced to the liver and the gall-bladder ; and a considerable branch of the artery should be pursued beneath the pylorus to the stomach, duodenum, and pancreas. Lastly, the splenic artery, which lies along the upper border of the pancreas, is to be cleaned ; and its branches to the pancreas, stomach, and spleen should be

and splenic.

defined ; this is a difficult task without the aid of someone to hold aside the stomach and spleen.

The veins will have been dissected for the most part with the arteries ; but the origin of the portal trunk is to be made out beneath the pancreas, and in front of the vena cava.

The CÆLIAC AXIS (fig. 149, *c*) is the first visceral branch of the abdominal aorta, and arises close to the upper margin of the opening in the diaphragm. It is a short thick trunk, about half an inch long, which projects above the upper border of the pancreas, and is surrounded by the solar plexus of the sympathetic. Its branches—coronary, hepatic, and splenic—radiate from the trunk (whence the name axis) to their distribution to the surrounding viscera.

Cœliac axis supplies the three following :—

The CORONARY ARTERY (*d*) is the smallest of the three, and runs upwards between the peritoneum and diaphragm to the cardiac orifice of the stomach. Having furnished some œsophageal branches, it then bends downwards, and passes between the layers of the small omentum, along the small curvature of the stomach, to anastomose with the pyloric branch (*o*) of the hepatic artery. Its offsets are thus distributed :—

Coronary, which gives

a. Œsophageal branches ascend on the gullet through the opening in the diaphragm, and anastomose with branches of the descending thoracic aorta.

offsets to the œsophagus

b. Gastric branches are given to both sides of the stomach, and those on the left end communicate with twigs (*vasa brevia*) of the splenic artery.

and the stomach.

The SPLENIC ARTERY (*e*) is the largest branch of the cœliac axis in the adult. It is a tortuous vessel, and runs almost horizontally to the spleen along the upper border of the pancreas. Near the spleen it divides into terminal branches, about seven in number (from four to ten), which enter that viscus by the surface towards the stomach. It is accompanied by the splenic vein, which is below it ; and it distributes branches to the pancreas and the stomach.

Splenic artery

supplies the spleen,

a. Pancreatic branches. Numerous small branches are supplied to the pancreas ; and one of these (*arteria pancreatica magna*) arises near the left end, and runs to the right in the gland with the duct.

the pancreas by large and small twigs,

b. Gastric branches arise from the artery or its divisions near the spleen, and pass to the stomach between the layers of the gastro-splenic omentum. Most of these (*vasa brevia*) are small, and ramify over the left end of the organ ; but one larger branch, the *left gastro-epiploic artery* (*f*), turns to the right between the layers of the great omentum, along the great curvature of the stomach, and inosculates with the right gastro-epiploic branch of the hepatic artery. This artery distributes twigs to both surfaces of the stomach, and between the pieces of peritoneum forming the great omentum.

and the stomach by *vasa brevia*,

and left gastro-epiploic.

The HEPATIC ARTERY (*g*) is intermediate in size between the other two, and is encircled by the largest plexus of nerves. In its course to the liver, the vessel is directed at first to the right and forwards to the pyloric end of the stomach, where it supplies its

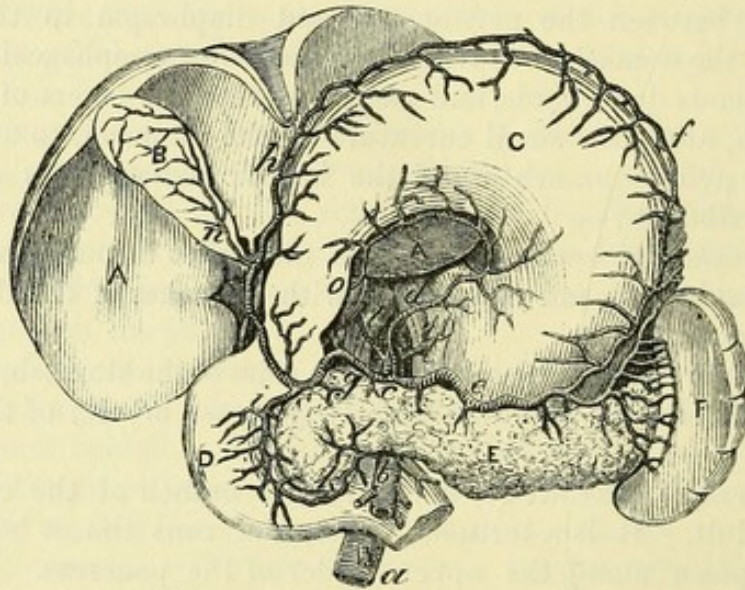
Hepatic artery courses to the liver,

in which it ends, gastric branches. It then ascends between the layers of the small omentum, on the left side of the bile-duct and portal vein, and divides near the transverse fissure of the liver into two—the right and left hepatic. Branches are distributed not only to the liver, but also to the stomach, the duodenum, and the pancreas, as below :—

offsets to a. The *gastro-duodenal artery* is a short vessel which descends beneath the duodenum near the pylorus, and divides into the two following branches :—

stomach, The *right gastro-epiploic artery (h)* is the continuation of the gastro-duodenal trunk, and runs from right to left along the great

Fig. 149. *



curvature of the stomach. It gives offsets upwards to the surface of the stomach, and downwards to the great omentum, and ends by inosculating with the left gastro-epiploic artery.

duodenum
and
pancreas.

The *superior pancreatico-duodenal artery (i)* is of small size, and descends between the duodenum and pancreas to join the inferior pancreatico-duodenal branch of the superior mesenteric. Offsets are given to both the viscera; and on their posterior aspect is another small artery of the pancreatico-duodenal, with a similar position and distribution.

b. The *pyloric branch (o)* descends to the small curvature of the stomach, and, running from right to left, anastomoses with the coronary artery; it distributes small twigs on both surfaces of the stomach.

Branches to
the liver,

The *hepatic branches* sink into the liver at the transverse fissure, and ramify in its substance :—

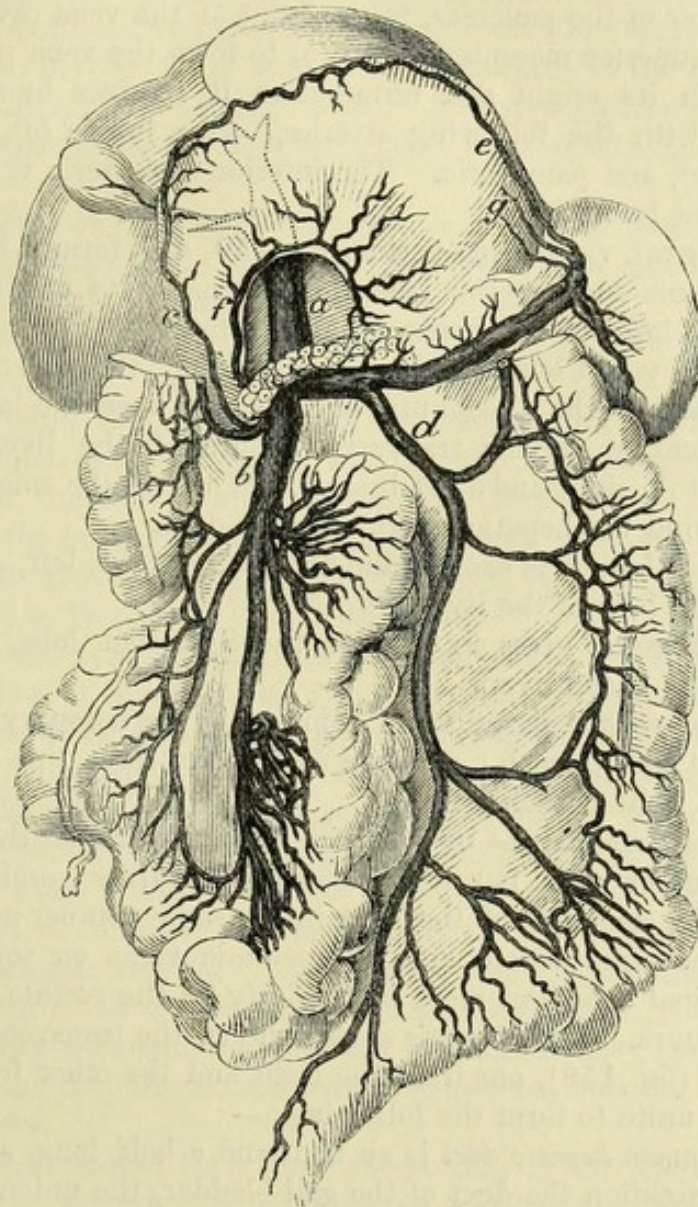
* View of the celiac axis, and of the viscera to which its branches are supplied (Tiedemann). A. Liver. B. Gall-bladder. c. Stomach. D. Duodenum. E. Pancreas. F. Spleen. Arteries : a. Aorta. b. Upper mesenteric. c. Celiac axis. d. Coronary. e. Splenic. f. Left gastro-epiploic. g. Hepatic. h. Right gastro-epiploic. i. Superior, and k. Inferior pancreatico-duodenal. l. Phrenic. n. Cystic. o. Pyloric.

c. The *right branch* is divided when about to enter the organ, and supplies the following small artery to the gall-bladder. one for the right lobe and gall-bladder,

The *cystic artery* (*n*) bifurcates on reaching the neck of the gall-bladder, and its two twigs ramify on the upper and lower surfaces.

d. The *left branch* is smaller than the other, and enters the liver and one for the left lobe.

Fig. 150.*



at the left end of the transverse fissure : a branch to the Spigelian lobe of the liver arises from this piece of the artery.

PORTAL VEIN. The veins of the stomach and intestine, and of the spleen and pancreas, pour their blood into the vena portæ. Portal system of veins. The two mesenteric veins and their branches have been referred to (pp. 481, 482) ; and the three following, with the trunk of the portal vein, remain to be noticed.

* Portal vein and tributaries (Henle). *a.* Trunk of the portal vein. *b.* Upper mesenteric. *c.* Right gastro-epiploic. *d.* Inferior mesenteric. *e.* Left gastro-epiploic. *f.* Pyloric (in this case of large size). *g.* Vasa brevia.

- Coronary vein.** The *coronary vein* accompanies the artery of the same name along the small curvature of the stomach, and bending downwards at the cardia, passes to the lower end of the portal vein.
- Pyloric vein.** The *pyloric vein* (fig. 150, *f*) lies with the pyloric branch of the hepatic artery along the lower part of the small curvature of the stomach, and opens into the portal vein opposite the duodenum.
- Splenic vein :** The *splenic vein* (fig. 150) is of large size, and is formed by the union of branches from the spleen. It runs below the artery, and under cover of the pancreas, to the front of the vena cava, where it joins the superior mesenteric vein (*b*) to form the vena portæ.
- tributaries.** Between its origin and termination it receives branches corresponding with the following arteries,—*vasa brevia* (*g*), left gastro-epiploic (*e*), and pancreatic. The inferior mesenteric vein (*d*) sometimes opens into it.
- Portal vein : origin ;** The PORTAL VEIN (*vena portæ* ; fig. 150, *a*) is formed by the union of the splenic and superior mesenteric veins. Its origin is placed behind the head of the pancreas, and in front of the inferior vena cava. The vessel is about three inches long, and ascends beneath the first part of the duodenum, and then between the layers of the small omentum, to the transverse fissure of the liver, where it divides into a right and a left branch. While in the small omentum it lies behind the hepatic artery and bile-duct.
- course and relations ;**
- branches ;** The *right branch* is shorter and larger than the left, and ramifies in the right lobe of the liver.
- The *left branch* gives an offset to the Spigelian lobe, and enters the left half of the liver.
- and tributaries.** In its course the portal trunk is joined by the coronary and pyloric veins from the stomach ; and the cystic vein from the gall-bladder enters the right branch.
- Peculiarities of portal vein.** This vein commences by roots in some viscera of the abdomen, like any other vein, but it is deficient in valves ; and it ramifies through the structure of the liver in the same manner as an artery. Its radicles communicate with the systemic veins on some parts of the intestinal tube, but more particularly on the rectum.
- Right and left hepatic ducts.** BILE-DUCTS. Two *hepatic ducts* issue at the transverse fissure of the liver (fig. 158), one from the right and the other from the left lobe, and unite to form the following :—
- Common hepatic duct.** The *common hepatic duct* is an inch and a half long, and receives at its termination the duct of the gall-bladder, the union of the two giving origin to the common bile-duct.
- Common bile-duct : length and course ; termination ;** The *common bile-duct* (*ductus communis choledochus*) is about three inches long. It descends almost vertically beneath the upper portion of the duodenum ; then passing between the pancreas and the vertical piece of the duodenum, it opens into this portion of the intestine at the inner side, and about the middle. While in the small omentum the duct lies to the right of the hepatic artery, and somewhat before the portal vein.
- joined by pancreatic.** As it pierces the wall of the intestine it is joined commonly by the pancreatic duct, but the two may enter the duodenum separately.

SYMPATHETIC AND VAGUS NERVES.

SYMPATHETIC NERVE. In the abdomen, as in the thorax, the sympathetic nerve consists of a gangliated cord on each side of the vertebral column, and of prevertebral centres or plexuses, which furnish branches to the viscera.

General disposition of nerves.

The chief prevertebral plexuses in the abdomen are the epigastric or solar and the hypogastric. The epigastric plexus is placed behind the stomach, and supplies nerves to all the viscera above the cavity of the pelvis: it is continued downwards to the hypogastric plexus by the aortic plexus (p. 483). The hypogastric plexus distributes nerves to the pelvic viscera, and has already been noticed (p. 483).

Two large centres, epigastric and hypogastric.

The knotted or gangliated cord will be met with in a subsequent stage of the dissection; and only the great solar plexus with its offsets is to be now examined.

Dissection. To denude the epigastric plexus, the following dissection is to be made:—After the air has been let out of the stomach and duodenum, the portal vein, the common bile-duct, and the gastro-duodenal artery are to be cut through near the pylorus; and the stomach, duodenum, and pancreas are to be drawn over to the left side. On raising the liver, the vena cava appears; this is to be cut across above the junction of the renal veins with it, and the lower end is to be drawn down with hooks.

How to lay bare solar plexus,

Beneath the vein the dissector will find the large reddish semilunar ganglion of the right side; and mixed up with the nerves of the plexus are numerous lymphatic glands (coeliac glands), with a dense tissue, which require to be removed with care. From its inner part he can trace the numerous nerves and ganglia around the coeliac and superior mesenteric arteries, and the secondary plexuses on the branches of those arteries. From the outer part of the ganglion offsets are to be followed to the kidney, the suprarenal body, and the diaphragmatic arteries. At its upper end the junction with the large splanchnic nerve may be seen; and deeper than the last, one or two smaller splanchnic nerves may be found as they issue through a fissure of the diaphragm, and throw themselves into the coeliac and renal plexuses.

and the semilunar ganglia.

The student should then trace the ending of the pneumo-gastric nerves on the stomach. The left nerve will be found at the small curvature in front, near the oesophagus; and the right nerve will be seen at a corresponding spot on the opposite aspect. Branches from the right nerve are to be followed to the plexus of the sympathetic by the side of the coeliac axis; and from the left, to the hepatic plexus.

Follow the ending of the vagus nerves.

The **EPIGASTRIC OR SOLAR PLEXUS** is a large network of nerves and ganglia, which lies in front of the aorta and pillars of the diaphragm, and behind the pancreas and inferior cava: it fills the space between the suprarenal capsules of opposite sides, and surrounds the coeliac axis and the superior mesenteric artery. The plexus is connected on each side with the large and small splanchnic

Solar plexus: appearance and extent;

gives offsets on blood-vessels.	nerves ; and it is joined also by a great part of the right pneumo-gastric nerve. Large branches are furnished to the different viscera along the vessels.
Semilunar ganglia :	The <i>semilunar ganglia</i> , one in each half of the plexus, are the largest in the body, and are placed close to the suprarenal capsules, resting on the diaphragm : the ganglion of the right side is beneath the vena cava. At the upper end each is joined by the great splanchnic nerve. The mass is irregular in shape, and often divided into smaller ganglia ; from its outer side nerves are directed to the kidney and the suprarenal capsule.
situation ;	
form.	
Several offsets of the plexus.	<i>Offsets of the plexus.</i> The nerves supplied to the viscera form plexuses round the vessels ; thus, there are celiac, mesenteric, renal, spermatic, diaphragmatic plexuses, &c.
Plexus to the diaphragm	The <i>diaphragmatic</i> or <i>phrenic plexus</i> comes from the upper end of the semilunar ganglion, but it soon leaves the artery to enter the substance of the diaphragm : a communication takes place between the phrenic nerve of the cervical plexus and these branches of the sympathetic. On the right side is a small ganglion where the plexus is joined by the spinal nerve ; and from it filaments are supplied to the vena cava and the suprarenal body : this ganglion is absent on the left side (Swan).
has a ganglion on right side.	
Suprarenal nerves.	The <i>suprarenal nerves</i> are very large and numerous, in comparison with the size of the viscus supplied, and are directed outwards to the suprarenal body. One of the splanchnic nerves communicates with this plexus.
Renal plexus.	The <i>renal plexus</i> is derived from the semilunar ganglion and outer side of the solar plexus, and is joined by the smallest splanchnic nerve. The nerves surround the renal artery, having small ganglia on them, and enter the kidney with the vessels. An offset is given from the renal to the spermatic plexus (p. 483).
Celiac plexus	The <i>celiac plexus</i> is a direct continuation of the plexus around its artery : it is joined by the small splanchnic nerve on each side, and by a branch from the right pneumo-gastric nerve. The plexus divides like the artery into three offsets—coronary, splenic, and hepatic.
divides like the artery,	
into coronary,	a. The <i>coronary plexus</i> accompanies the vessel of the same name to the stomach : it communicates with the left vagus nerve.
splenic,	b. The <i>splenic plexus</i> furnishes nerves to the pancreas, and to the stomach along the left gastro-epiploic artery ; and it is joined by an offset from the right pneumo-gastric nerve.
and hepatic ;	c. The <i>hepatic plexus</i> is continued on the vena portæ, the hepatic artery, and the bile-duct into the liver, and ramifies on those vessels : in the small omentum the plexus is joined by offsets from the left vagus. The following secondary plexuses are furnished around the branches of the hepatic artery, and have the same name and distribution as the vessels :
the last has secondary plexuses, viz.,	
pyloric,	A <i>pyloric plexus</i> courses along the small curvature of the stomach.
gastro-epiploic, and duodenal,	Two other plexuses— <i>right gastro-epiploic</i> and <i>pancreatico-duodenal</i> , correspond in distribution with the branches of each artery.
cystic.	A <i>cystic plexus</i> passes to the gall-bladder with the artery.

The remaining offsets of the plexus, viz., superior and inferior mesenteric, aortic, and spermatic, have been already noticed (p. 483); but the derivation of the superior mesenteric and aortic plexuses from the epigastric centre can be now seen.

Ending of the splanchnic nerves. The large nerve perforates the crus of the diaphragm, and generally ends altogether in the semi-lunar ganglion. Ending of large splanchnic nerve,

The small nerve comes through the same opening in the diaphragm as the preceding, and joins the cœliac plexus. small,

The smallest nerve, which is often absent, throws itself into the renal plexus. and smallest.

ENDING OF THE VAGUS NERVE. The pneumo-gastric nerves end on the stomach :—

The left nerve divides into branches, which extend along the small curvature, and over the front of the stomach; these send offsets to the hepatic plexus. Ending of left vagus

The right nerve is distributed to the posterior surface of the stomach near the upper border; it communicates with its fellow, and gives branches to the cœliac and splenic plexuses. and right.

Dissection. Most of the viscera are now to be removed from the abdomen, in order that the body may be turned for the dissection of the back. Prepare for turning the body by

The stomach and the spleen, with the duodenum and the pancreas, are to be taken away together by cutting through the œsophagus near the diaphragm, as well as the vessels and nerves they receive. The liver is to be removed from the abdomen by dividing its ligaments, and cutting the vena cava below the diaphragm. removing the viscera.

At the same time the left testicle, and the right kidney with the suprarenal body, should be removed for examination while the body is turned; the former can be taken out by cutting through the spermatic cord, and the latter by dividing its vessels about the middle.

Directions. Supposing the body to be now turned for the dissection of the back, and to lie with the face downwards for the usual time, the dissector may look first to the fascia lumborum, which is described in CHAPTER V, p. 386. Directions for the dissector.

The rest of the time should be occupied in learning the viscera included in the following SECTION.

SECTION IV,

ANATOMY OF THE VISCERA OF THE ABDOMEN.

THE STOMACH.

The stomach is the dilated part of the alimentary tube between the œsophagus and the small intestine, into which the masticated food is received to be changed into chyme. Definition.

Dissection. To see the form, the stomach must be blown up mode- Separate and blow

up the stomach. rately, and the surface cleaned ; but, previously, let the student detach the spleen, and cut through the duodenum close to the pylorus.

Form, size, and divisions. FORM AND DIVISIONS. The stomach is rather pyriform in shape, and in its natural condition strongly curved (fig. 144). Its size varies much in different bodies, and is sometimes much diminished by a constriction to the right of the centre : when it is moderately distended, it is about twelve inches long and four wide. There are two ends, two orifices, two surfaces, and two borders or curvatures to be examined.

Left end, and right. The left end is called the *fundus* or *great cul-de-sac*, and projects upwards to the left of the end of the œsophagus. The right or *pyloric end* is much smaller, and tapers to the duodenum.

Cardiac and pyloric openings. The *cardiac opening*, which communicates with the œsophagus, is placed two or three inches from the most prominent part of the fundus, and is funnel-shaped towards the cavity of the organ. The *pyloric orifice* opens into the duodenum, and is guarded internally by a muscular band (pylorus) : at this spot the stomach is slightly constricted externally, where a firm circular thickening may be felt.

Surfaces. The anterior and posterior surfaces are somewhat flattened when the viscus is empty, but rounded when it is distended : the parts in contact with them have been referred to (p. 467).

Small curvature, and large. The upper border or *small curvature* is concave, except for a short distance at the pyloric end. The lower border or *large curvature* is much longer, convex, and when the organ is distended forms at the pyloric end a slight projection to the right, which has been named the *small cul-de-sac*. An arterial arch and a fold of peritoneum (omentum) are connected with each border.

Four strata in stomach. STRUCTURE. In the wall of the stomach are four coats, viz., serous, muscular, fibrous, and mucous ; and belonging to these there are vessels, nerves, and lymphatics.

The serous coat is thin and adherent. *Serous coat.* The peritoneum gives a covering to the stomach, and is adherent to the surface except at each margin, where an interval exists corresponding with the attachment of the small and large omentum : in those spaces are contained the vessels, nerves, and lymphatics. During distension of the stomach the spaces above mentioned are much diminished.

The muscular coat is made up of The *muscular coat* will be laid bare by the removal of the serous covering. Its fibres are unstriated or involuntary, and arranged in three sets, viz., longitudinal, circular, and oblique, in the order mentioned from without inwards.

longitudinal. The *longitudinal fibres* (fig. 151, *a*) are derived from the œsophagus ; they spread over the surface, and are continued to the pylorus and the small intestine. The fibres are most marked along the borders, particularly at the smaller one ; and at the pylorus they are stronger than in the centre of the stomach.

circular. The *circular fibres* (fig. 151, *b*) form the middle stratum, and will be best seen by removing the longitudinal fibres near the pylorus. They reach from the left to the right end of the stomach ; but at

the pylorus they are most numerous and strongest, and form a ring or sphincter (*c*) round the opening.

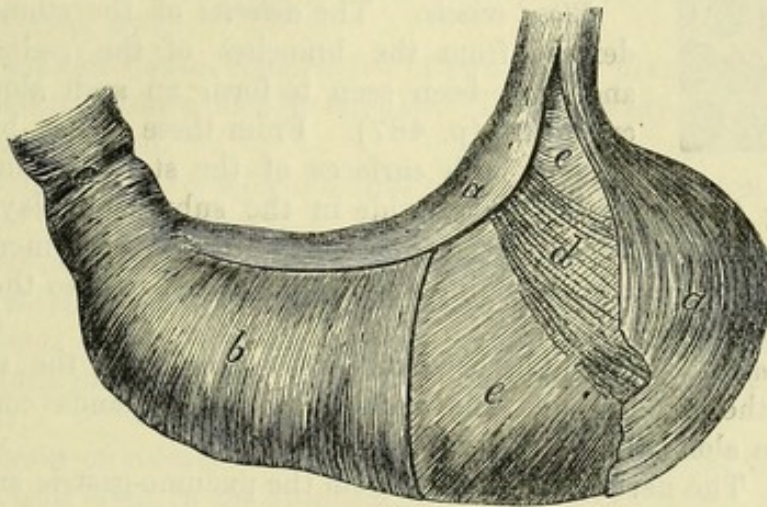
The *oblique fibres* (fig. 151, *e*) are continuous with the circular or deep layer of the œsophagus. On the left and right of the cardiac orifice they are so arranged as to form a kind of sphincter (*d* and *e*) (Henle); those on the left (*e*), the strongest, arch over the great end of the stomach, and spread out on the anterior and posterior surfaces, gradually disappearing on them.

Fibrous or submucous coat. By removing the muscular layer over a small space, the fibrous coat will appear as a white shining stratum

and oblique fibres.

The fibrous coat is thin but firm.

Fig. 151.*



of areolar tissue. This coat gives strength to the stomach, and serves as a bed in which the larger vessels and nerves ramify before their distribution to the mucous layer. If a small opening is made in this membrane, the mucous coat will project through it, supposing the stomach to be distended with air.

The *mucous coat* will come into view on cutting open the stomach, but the appearances now described can be recognised only in a recent specimen.

This coat is a softish layer, of a pale rose colour soon after death, in the healthy condition. In the empty state of the stomach the membrane is less vascular than during digestion; and in infancy the natural redness is greater than in childhood or old age. When the stomach is contracted the membrane is thrown into numerous wavy ridges or *rugæ*, which become longitudinal along the great curvature, towards the pylorus.

The thickness of the mucous membrane is greatest near the pylorus; and at that spot it forms a fold, opposite the muscular ring, which assists in closing the opening. If this membrane and

Mucous coat:

feel and colour;

folds;

thickness;

disposition at pylorus.

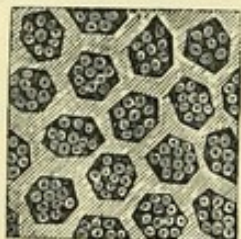* Diagram representing the arrangement of the muscular fibres of the stomach. The external and middle layers are partly removed. *a*. External or longitudinal fibres. *b*. Middle or circular. *c*. Sphincter of the pylorus. *d*. Oblique fibres on the right of the cardiac opening. *e*. Oblique fibres, more numerous, on the left of the cardiac orifice, and covering the great end of the stomach.

the submucous layer are removed from the pyloric part of the stomach, the ring of muscular fibres (sphincter of the pylorus) will be more perfectly seen.

On the surface are pits or alveoli; their size, shape, and appearance.

With the aid of a lens, the surface of the mucous membrane, when well washed, may be seen to be covered by shallow depressions or alveoli (fig. 152), which measure from $\frac{1}{200}$ th to $\frac{1}{100}$ th of an inch across. Generally hexagonal or polygonal in outline, the hollows become larger and more elongated towards the small end of the stomach; and near the pylorus the margins of the alveoli project, and become irregular. In the bottom of each depression are the apertures of minute tubular glands.

Fig. 152.*



Arteries;

Blood-vessels. The *arteries* of the stomach are derived from the branches of the celiac axis, and have been seen to form an arch along each curvature (p. 487). From these arches branches pass to both surfaces of the stomach, and after

veins;

supplying the muscular coat, divide in the submucous layer into minute vessels which enter the substance of the mucous membrane. The *veins* have a corresponding arrangement, and pass to the portal system (p. 490).

lymphatics;

Lymphatics. The lymphatic vessels proceeding from the stomach run with the blood-vessels, and have a few small glands connected with them along the two curvatures.

and nerves.

Nerves. The nerves are derived from the pneumo-gastric and sympathetic (p. 492), and can be followed to the fibrous coat: small ganglia have been observed on them.

SMALL INTESTINE.

Characters

The three portions into which the small intestine is divided, have the following characters:—

of duodenum,

The *duodenum* is about ten inches long, and is more fixed than the rest of the intestinal tube. It is wider than either the jejunum or the ileum, and its muscular coat is also thicker. Into it the bile and pancreatic ducts pour their contents.

of jejunum and ileum.

The *jejunum* and the *ileum* together measure about twenty feet in length, and are connected with the mesentery. There is not any perceptible difference between the termination of the one and the beginning of the other, but two-fifths of the length are assigned to the jejunum, and three-fifths to the ileum. Between the ends, however, a marked difference may be perceived; for the upper part of the jejunum is thicker and more vascular than the lower end of the ileum, and its width is also greater.

Structure.

STRUCTURE. In the small intestine the wall is formed by the same number of layers as in the stomach, viz., serous, muscular, fibrous, and mucous.

* Alveolar depressions of the mucous membrane of the stomach, magnified 32 diameters, with the minute tubes opening into them. (Sprott Boyd.)

Dissection. The different layers are to be examined on pieces, about three inches long, taken from the duodenum, the upper part of the jejunum, and the lower end of the ileum. After the pieces have been cut off, they are to be distended with air; and the serous covering is to be torn off for a short distance, to show the muscular coat, but in doing this, the external longitudinal fibres will be taken away without great care.

The *serous coat* is closely connected with the subjacent muscular layer. To the jejunum and ileum it furnishes a covering, except at the attached side where the vessels enter: at this spot the peritoneum is reflected off to form the mesentery, and a space exists resembling that at the borders of the stomach. The peritoneum only partly surrounds the duodenum; this peculiarity has been described at p. 477.

The *muscular coat* is constructed of two sets of fibres, a superficial or longitudinal, and a deep or circular. The fibres are pale in colour, and are not striated.

The *longitudinal fibres* form a thin covering, which is most marked at the free border of the gut.

The *circular fibres* are much more distinct than the others, and give the chief strength to the muscular coat.

Dissection. On the removal of some of the muscular stratum from the jejunum or the ileum, the submucous fibrous layer will come into view.

The *fibrous* or *submucous coat* has the same position and use as the corresponding layer in the stomach.

Dissection. In the upper part of the duodenum the student is to seek some small compound glands—those of Brunner, which are embedded in the submucous tissue. They lie beneath the mucous membrane, and will be seen shining through the fibrous layer, when the muscular coat has been taken away.

The pieces of intestine may be opened and washed to show the mucous coat, but the gut should be cut along the line of attachment of the mesentery, so as to avoid Peyer's glands on the opposite side.

Mucous coat. The lining membrane is thicker and more vascular at the beginning than at the ending of the small intestine. It is marked by numerous prominent folds (*valvulae conniventes*); and the surface of the membrane is covered with small processes (*villi*) like the pile of velvet. Occupying the substance of the mucous coat are numerous glands.

The *valvulae conniventes* (valves of Kerkring) are permanent ridges of the mucous membrane, which are arranged circularly in the intestine and project into the cavity of the tube. Crescentic in form, they extend round the intestine for half or two-thirds of its circumference, and some end in bifurcated extremities. Larger and smaller folds are met with, sometimes alternating; and the larger are about two inches long, and one-third of an inch in depth towards the centre. Each is formed of a doubling of the mucous membrane, which encloses a prolongation of the submucous coat, with vessels, between the layers.

Dissection
for it.

Serous coat
nearly
complete,
except in
the duo-
denum.

Muscular
coat is
formed by a

longitudina

and a cir-
cular layer.

Dissect
fibrous coat.

Fibrous coat
like that in
stomach.

Seek glands
of Brunner:

show mu-
cous coat.

Mucous
coat:
thickness,
folds,
villous
surface,
and glands.

Folds:
arrange-
ment,
length,

size and
depth;

how formed;

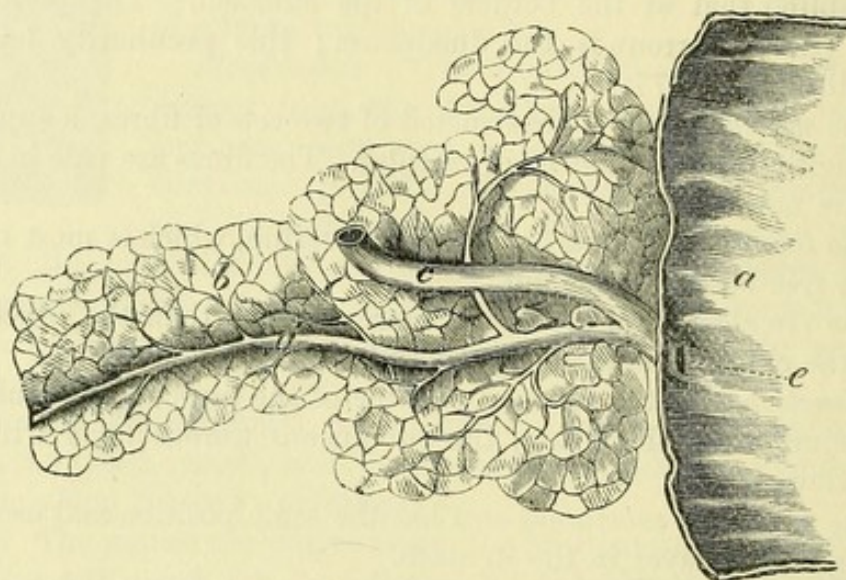
extent on
the intes-
tine.

They begin in the duodenum, about one or two inches beyond the pylorus, and are continued in regular succession to the middle of the jejunum; but beyond that point they become smaller and more distant from one another, and finally disappear about the middle of the ileum, having previously become irregular and rudimentary. The folds are largest and most uniform beyond, and not far from the opening of the bile-duct.

Opening of
bile-duct;

The *aperture of the common bile and pancreatic ducts* (fig. 153, *e*) is a narrow orifice, from three to four inches below the pylorus, and

Fig. 153.*



where
situate.

situate in a small prominence of the mucous membrane, at the inner and posterior part of the duodenum (p. 485). A probe passed into the bile-duct will show its oblique course (half an inch or more) under the mucous coat. Occasionally the pancreatic duct opens by a distinct orifice.

To see satisfactorily the following objects, some pieces of fresh intestine will be necessary.

The villi
cover the
surface;

their shape,
size,

and number.

Several
kinds of
glands.

Villi. When a piece of the lower part of the duodenum, from which the mucus is washed away, is examined in water, the mucous membrane will be seen to be thickly studded with small projections, like those on velvet. These bodies exist along the whole of the small intestine, and are irregular in form (fig. 155), some being triangular, others conical or cylindrical with a large end. Their length is from $\frac{1}{40}$ th to $\frac{1}{20}$ th of an inch; and they are best marked where the valvulae conniventes are largest. In the duodenum their number is estimated at 50 to 90 in a square line, but in the lower end of the ileum at only 40 to 70 on the same surface (Krause).

Glands. In the glandular apparatus of the small intestine are

* A small piece of the duodenum opened, with a part of the pancreas, showing the termination of the bile and pancreatic ducts (Henle). *a.* Duodenum. *b.* Pancreas. *c.* Common bile-duct. *d.* Pancreatic duct. *e.* Common opening of the ducts in the intestine.

included the crypts of Lieberkühn, solitary glands, and Peyer's and Brunner's glands.

The *crypts of Lieberkühn* are minute simple tubes, which exist throughout the small intestine. They open on the surface of the mucous membrane by small orifices between the villi, and around the larger glands; but they are not to be recognised with the naked eye.

The so-called *solitary glands* (fig. 155, B) are roundish white eminences, about the size of mustard-seed if distended, which are scattered along the small intestine, but in greatest number in the ileum. Placed on all parts of the intestine, and even on or between the *valvulae conniventes*, they are covered by the villi of the mucous membrane, and are surrounded at their circumference by apertures of the crypts of Lieberkühn. These small bodies are nodules of lymphoid tissue.

The *agminated glands* or *glands of Peyer* (fig. 154) exist chiefly in the ileum, in the form of oval patches, which measure from half an inch to two inches or more in length, and about half an inch in width. They are situate on the part of the intestine opposite to the attachment of the mesentery, and their direction is longitudinal in the gut: usually they are from twenty to thirty in number. In the lower part of the ileum they are largest and most numerous; but they decrease in number and size upwards from that spot, till at the lower end of the jejunum they become irregular in form, and may consist only of small roundish masses. The patches are most distinct in young persons, and generally disappear in old age.

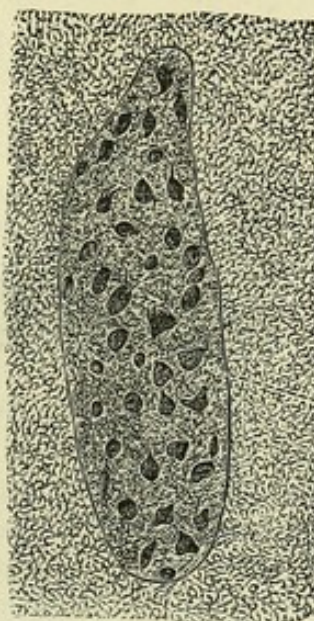
The mucous membrane over them is hollowed into pits (fig. 154, b), and is generally destitute of villi (fig. 155, A); but between the pits it has the same characters as in other parts.

These patches are simply collections of lymphoid nodules of the same nature as the "solitary glands."

The *Glands of Brunner* are small compound bodies, similar to the buccal and labial glands of the mouth, which exist in the duodenum. For a distance of one or two inches near the pylorus they are most numerous, and there they are visible without a lens, being nearly as large as hemp-seed.

Dissection. To demonstrate the areolar tissue between the coats of the intestine, a piece of the bowel turned inside out is to be inflated forcibly; and to ensure the success of the attempt, a few

Fig. 154.*



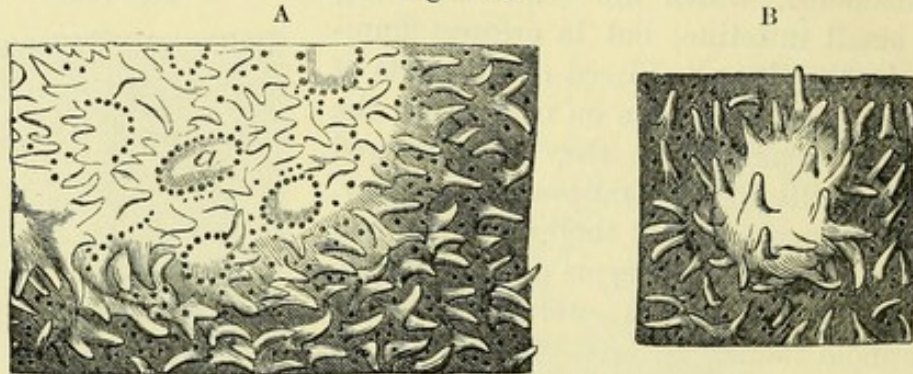
* Patch of Peyer's glands, four times enlarged (Kölliker). a. Surface of the mucous membrane covered with villi. b. Pits over the follicles where the villi are absent.

cuts may be previously made through the peritoneal coat. The air enters the wall of the intestine where the peritoneal covering is injured, and spreads through the whole gut; but opposite the solitary glands, and the patches of Peyer, the mucous coat is more closely connected with the contiguous structures, and the subjacent portion will not be distended with the air. The piece of the intestine may be examined when it is dry.

Arteries of
the intes-
tine;

Vessels of the intestine. The *arteries* are derived from the intestinal

Fig. 155.*



branches of the superior mesenteric trunk (p. 479), and enter the wall of the intestine at the attached border. They run at first beneath the serous coat, round the side of the bowel, and give off numerous ramifications, which anastomose freely together, and perforate the muscular coat, supplying branches to its substance. Finally, they break up into very minute twigs in the submucous layer, before entering the mucous coat. The *veins* have their usual resemblance to the companion arteries.

veins;

The *absorbents* (lacteals) leave the intestine with the vessels and pass to the mesenteric glands (p. 481).

Nerves of the small intestine come from the upper mesenteric plexus, and entering the coats by the side of the arteries, form plexuses with interspersed ganglia.

and nerves.

Structure of the common bile-duct. The bile-duct consists of an external, strong fibrous layer, and of an internal, mucous coat. On the surface of the inner membrane are the openings of numerous branched mucous glands, which are embedded in the fibrous coat; some of them are aggregated together, and are visible with a lens.

Two coats
in the bile-
duct;

glands.

LARGE INTESTINE.

The large intestine is the part of the alimentary canal between the termination of the ileum and the anus. Its division, and its attachment by peritoneum to the abdominal wall, have been described (p. 469).

Extent of
the gut:

* A. A piece of mucous membrane enlarged, with its villi and tubules. Part of a patch of Peyer's gland is also represented with the follicles (*a*), each having a ring of tubes at the circumference. B. A "solitary gland" of the small intestine, also enlarged, covered by villi (Boehm).

In length this portion of the alimentary canal measures about length; five or six feet,—one-fifth of the length of the intestinal tube. The diameter of the colon is largest at the commencement of the cæcum, size, and gradually decreases as far as the upper part of the rectum: in the lower part of the rectum there is a dilatation above the anus.

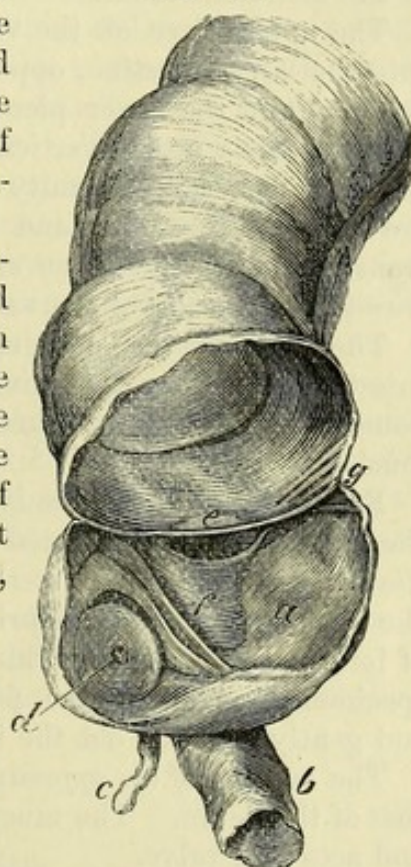
When compared with the small intestine, the colon is distinguished by the following characters:—It is generally of greater capacity, being in some places as large again, and is more fixed in its position; it is also free from convolution, except in the left iliac fossa, where it forms the sigmoid flexure. Instead of being a smooth cylindrical tube, the colon is sacculated, and is marked by three longitudinal muscular bands, which alternate with as many rows of dilatations; but in the rectum the surface is smooth, and the longitudinal bands disappear. Attached to the surface, especially along the transverse colon, are small processes of peritoneum containing fat—the appendices epiploicæ.

Dissection. For the purpose of examining the large intestine, the student should cut off and blow up the cæcum, with part of the ileum entering it; and he should prepare in a similar way a piece of the transverse colon, and a piece of the sigmoid flexure (about four inches of each). The areolar tissue and the fat are to be removed with care from each, after it has been inflated.

The CÆCUM, or the head of the colon (fig. 156, *a*), is the rounded end of the large intestine which projects, in the form of a pouch, below the junction of the ileum with it. It measures about two inches and a half in length, and rather more in width, though gradually narrowing below: it is the widest part of the colon. At its inner side it is joined by the small intestine (*b*); and still lower there is a small worm-like projection (*c*)—the vermiform appendix.

Appendix vermiformis (fig. 156, *c*). This little convoluted tube is attached to the lower and hinder part of the cæcum, of which it was a continuation at one period in the embryo. From three to six inches in length, the appendix is rather larger than a goose-quill, and is connected to the inner side of the cæcum by a fold of peri-

Fig. 156.*



Compared with small gut, larger,

more fixed,

not coiled, sacculated with bands,

but not in the rectum.

Appendages.

Inflate pieces of the large intestine.

definition of cæcum;

length and width;

receives ileum and appendix.

Vermiform appendix: attachment;

dimensions.

* Interior of a cæcum, dried and laid open. *a*. Cæcum. *b*. Small intestine. *c*. Vermiform appendix, and *d*, its aperture. *e*. Ileo-colic piece of the valve at the junction of the small intestine. *f*. Ileo-cæcal piece of the valve. *g*. Retinaculum of the valve on each side.

it is hollow. toneum. Its hollow has an aperture of communication with the intestine (*d*). In structure it resembles the rest of the colon.

Dry the cæcum, and open it to see the valve. *Dissection.* To examine the interior of the cæcum, and the valve between it and the small intestine, the specimen should be dried, and the following cuts should be made in it:—One oval piece is to be taken from the upper aspect of the ileum near its termination; and another from the side of the cæcum, opposite the entrance of the small intestine.

Situation of the valve; two pieces in it. *Ileo-cæcal valve* (fig. 156). This valve is situate at the entrance of the ileum into the large bowel. It is composed of two pieces, which project into the interior of the colon, and bound a narrow, nearly transverse aperture of communication between the two parts of the intestinal canal.

One ileo-colic; the other ileo-cæcal; these are joined at the ends, and form fræna. The upper piece of the valve, *ileo-colic* (*e*), projects horizontally into the large intestine, opposite the junction of the ileum with the colon. And the lower piece, *ileo-cæcal* (*f*), which is the larger of the two, has a nearly vertical direction between the ileum and the cæcum. At each extremity of the opening the pieces of the valve are blended together; and the resulting prominence (*g*) extends transversely on the front and back of the intestine, forming the *fræna* or *retinacula* of the valve.

Opening in the valve. The size of the opening is altered by the distension of the intestine; for when the retinacula of the valve are stretched the folds bounding the aperture are approximated, and may be made to touch.

The valve a prolongation of the wall of the gut. Each piece of the valve is formed by circular muscular fibres of the intestinal tube, covered by mucous membrane and submucous tissue; as if the ileum were thrust obliquely through the wall of the cæcum, after being deprived of its peritoneal coat and the layer of longitudinal fibres. This construction is easily seen on a fresh specimen by dividing the peritoneum and the longitudinal fibres, and gently drawing out the ileum from the cæcum.

Appendix opens into cæcum. The *opening of the appendix* into the cæcum (*d*) is placed below that of the ileum. The mucous membrane partly closes the aperture and acts as a valve.

Ridges in the cæcum; how formed. *Folds* or *ridges* are directed transversely in the interior of the gut, and correspond with depressions on the outer surface: these folds result from the doubling of the wall of the intestine, and the largest enclose vessels.

Four strata in the wall of the gut. **STRUCTURE OF THE COLON.** The coats of the large are similar to those of the small intestine, viz., serous, muscular, fibrous, and mucous.

Serous coat differs along the intestine. *Serous coat.* The peritoneum does not clothe the large intestine, throughout, in the same degree. It usually surrounds the cæcum, but covers only the front and sides of the ascending and descending colon (p. 477). The transverse colon is encased like the stomach, and has intervals along the borders, where the transverse meso-colon and the great omentum are attached.

Two layers of fleshy fibres; The *muscular coat* is formed of longitudinal and circular fibres, as in the small intestine.

The *longitudinal fibres* may be traced as a thin layer over the surface, but most are collected into three longitudinal bands, about a quarter of an inch in width. On the vermiform appendix the fibres form a uniform layer; but they are continued thence into the bands on the cæcum and colon: on the rectum they are diffused over the surface. When the bands are divided the intestine elongates,—the sacculi and the ridges in the interior of the gut disappearing at the same time.

longitudinal
in three
bands,
which are
united on
appendix
and rec-
tum;

The *circular fibres* are spread over the whole surface, but are most marked in the folds projecting into the intestine. In the rectum (to be afterwards seen) they form the band of the internal sphincter muscle.

and circular.

The *fibrous* or *submucous coat* resembles that of the small intestine. It will be exposed by removing the peritoneal and muscular coverings.

Submucous
coat as in
small gut.

The *mucous coat*, which may be examined on opening the intestine, is smooth, and of a pale yellow colour; and it is not thrown into special folds, except in the rectum. The surface is free from villi; and by this circumstance the mucous membrane of the large can be distinguished from that of the small intestine. This difference in the two portions of the alimentary tube is well marked on the ileo-cæcal valve; for the surface looking to the ileum is studded with villi, while the surface continuous with the mucous lining of the large intestine is free from those eminences.

Mucous coat
is without
folds

and villi.

Glands. The mucous membrane is thickly beset with very small tubular glands or *crypts of Lieberkühn*, like those of the small intestine; and lymphoid nodules (solitary glands) are scattered over the whole of the large intestine, but are most abundant in the cæcum and vermiform appendix.

Tubular
glands,
and lym-
phoid no-
dules.

Vessels and nerves. The distribution of the vessels and nerves in the wall of the large intestine is the same as in the small.

Vessels,
nerves,
and lym-
phatics.

The *absorbent vessels*, after leaving the gut, join the lymphatic glands along the side of the colon.

THE PANCREAS.

The pancreas (fig. 149, E) is a narrow flattened gland, from six to eight inches in length, and larger at the right than the left end. It is divided into head, tail, and body.

Form and
length;
divisions.

The *head*, or the right extremity, occupies the concavity of the duodenum; and the left extremity, or the *tail*, is rounded, and touches the spleen.

The head
and tail;

The *body* of the gland measures about one inch and a half in breadth, and from half an inch to an inch in thickness. The relations of the pancreas to surrounding parts are described at p. 486.

and the
body.

Dissection. Let the pancreas be placed on the anterior surface, and let the excretory duct be traced from the head to the tail by cutting away the substance of the gland. The duct will be recognised by its whiteness.

Trace out
the duct.

STRUCTURE. The pancreas resembles the parotid gland in struc-

It is a
compound

gland, without a distinct capsule.	ture, consisting of separate lobules, each of which is provided with a special duct. It is destitute of a distinct capsule; but it is surrounded by areolar tissue, which projects into the interior, and connects together its smaller pieces. The lobules are soft and loose, and of a greyish white colour, and are united into larger masses by areolar tissue, vessels, and ducts.
The duct of the gland:	The <i>duct</i> of the pancreas (canal of Wirsung; fig. 153, <i>d</i>) extends the whole length of the gland, and is somewhat nearer the lower than the upper border. It begins in the tail of the pancreas, where it presents a bifurcated extremity; and as it continues onwards to the head, it receives many branches. It finally ends by opening into the duodenum, usually in union with the common bile-duct (p. 498). Of the tributary branches, the largest is derived from the lower part of the head of the pancreas.
extent;	
branches;	
size and structure.	The duct measures from $\frac{1}{15}$ th to $\frac{1}{10}$ th of an inch in diameter near the duodenum. It is formed of a fibrous coat with a very smooth mucous lining.
Vessels and nerves.	<i>Vessels, lymphatics, and nerves.</i> The arteries and veins have been described (p. 487); and the lymphatics pass to the cœliac glands. The nerves are furnished by the solar plexus.

THE SPLEEN.

Consistence and colour.	The spleen is a vascular spongy organ of a bluish or purple colour, sometimes approaching to grey. Its texture is friable, and easily broken under pressure.
Form and position.	The viscus is somewhat elliptical in shape, and is placed obliquely behind the great end of the stomach. Its size varies much. In the adult it measures commonly about five inches in length, three or four inches in breadth, and one inch to one inch and a half in thickness. Its weight lies between four and ten ounces, and is rather less in the female than the male.
Size and weight.	
Surfaces are phrenic, gastric, and renal.	At the posterior or outer aspect it is convex towards the ribs. On the opposite side a longitudinal ridge separates an anterior or gastric surface from a narrow internal or renal surface, both of which are concave (p. 472). Just in front of the ridge is a groove, or more commonly a series of small depressions, where the branches of the vessels enter: this part is called the <i>hilum</i> of the spleen.
Borders and extremities.	The anterior border is thinner than the posterior, and is often notched. Of the two extremities, the lower is more pointed than the upper.
Sometimes accessory spleens.	Small masses or <i>accessory spleens</i> (splenculi), varying in size from a bean to a moderate-sized plum, are found occasionally, near the hilum of the spleen, in the gastro-splenic omentum, or in the great omentum.
Two coats and special material.	STRUCTURE. Enveloping the spleen are two coverings, a serous and a fibrous. It is formed by a network of fibrous or trabecular tissue, which contains in its meshes the splenic pulp. Throughout the mass the blood-vessels and the nerves ramify. It has no duct.

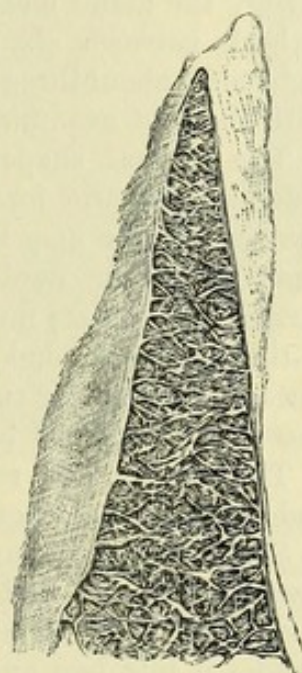
The *serous* or *peritoneal coat* encases the spleen, covering the surface except at the hilum and the ridge behind. It is closely connected to the subjacent fibrous coat. Serous coat nearly complete.

The *fibrous coat* (*tunica propria*) gives strength to the spleen, and forms a complete case for it. At the hilum this investment passes into the interior with the vessels, to which it furnishes sheaths; and if an attempt is made to detach this coat, numerous fibrous processes will be seen to be connected with its deep surface. Its colour is whitish; and it is made up of areolar and elastic Fibrous coat sends inwards processes, structure tissues.

Dissection. The spongy or trabecular structure will best appear by washing and squeezing a piece of fresh bullock's spleen under water, so as to remove the inner grumous-looking material. Interior of spleen,

The *trabecular tissue* (fig. 157) forms a network through the whole interior of the spleen, similar to that of a sponge, which is joined to the external casing, and forms sheaths around the vessels. Its processes or threads are white, flattened or cylindrical, and consist of fibrous and elastic tissues, with a few muscular fibres. The interstices communicate freely together, and contain the pulp of the spleen. disposition of fibrous tissue to form an areolar structure.

Fig. 157.*



Pulp of spleen.

Malpighian bodies.

Splenic artery:

ending;

no anastomoses.

Vein begins by open spaces; branches anastomose.

The *splenic pulp* is a soft red-brown mass, which is lodged in the areolæ of the trabecular structure, and consists in great part of blood. In a fresh section small whitish spots (about $\frac{1}{60}$ th of an inch in diameter) may be seen scattered amongst the dark pulp: these are the *Malpighian corpuscles* of the spleen—lymphoid nodules attached to the small branches of the artery.

Blood-vessels. The larger branches of the *splenic artery* are surrounded by sheaths of fibrous tissue in the trabeculæ; but the smallest branches leave the sheathing, and break up into tufts of capillaries, which are said to open into the fine meshes of the spleen substance. There are few or no anastomoses between the arterial branches in the organ.

The *splenic vein* is supposed to begin in the meshes of the splenic pulp by open channels. The small branches resulting from the union of these radicles anastomose freely together, and unite into trunks larger than the accompanying arteries, which issue by the hilum of the spleen.

Lymphatics and nerves. The *lymphatics* are superficial and deep, and leaving the organ at the hilum, traverse small glands lying along the splenic vessels on their way to the cœliac glands. The *nerves* come from the solar plexus, and surround the artery and its branches. Lymphatics. Nerves.

* A drawing of the trabecular structure of the spleen of the ox, at some distance from the hilum.

THE LIVER.

Office of the liver.	The liver secretes the bile, and is the largest gland in the body. Its duct opens into the duodenum with that of the pancreas.
Clean vessels on under surface ;	<i>Dissection</i> (fig. 159). Preparatory to examining the liver, the vessels at the under surface should be dissected out. This proceeding will be facilitated by distending the vena cava and vena portæ with tow or cotton-wool, and the gall-bladder with air through its duct. The several vessels and the ducts are then to be defined, and the gall-bladder is to be cleaned.
follow left piece of vena portæ.	On following outwards the left branch of the portal vein to the longitudinal or antero-posterior fissure, it will be found united anteriorly with the round ligament (<i>c</i>) or the remains of the umbilical vein, and posteriorly with the thin fibrous remnant of the ductus venosus (<i>d</i>).
Colour and consistence ; weight ; measurements.	The LIVER is of a red-brown colour and firm consistence, and weighs commonly in the adult from three to four pounds. Transversely the gland measures from ten to twelve inches ; from front to back between six and seven inches ; and in thickness, at the right end, about three inches, but this last measurement varies much with the spot examined.
Form altered when removed ;	The natural shape of the liver when within the body is very different from the form it assumes when removed and placed on a flat surface, as may be seen by comparing fig. 158, which represents the organ hardened <i>in situ</i> , with fig. 159. It has three
divisions.	surfaces—superior, inferior, and posterior,—one well-defined border—the anterior,—and two extremities. The inferior and posterior surfaces are farther subdivided into lobes by fissures which contain vessels, and marked by fossæ and impressions.
	The position and relations of the liver are described at p. 471, and the peritoneal ligaments at p. 478.
Upper surface smooth ;	<i>Surfaces.</i> On the upper aspect the liver is smooth, and marked towards the left side by a shallow impression for the heart. The suspensory ligament extends from front to back of this surface, and divides it into two unequal parts, of which the right is the larger.
lower surface uneven ;	The under surface (fig. 158) is rendered irregular by fissures and fossæ ; in contact with it is the gall-bladder ; and a longitudinal sulcus separates the right from the left lobe.
hinder surface also irregular.	The posterior surface, which is also divided into two by a continuation of the longitudinal sulcus, is broad over the right lobe, but narrow on the left. In the centre is a hollow for the spine, to the right of which the inferior vena cava is partly embedded in the liver. On the right of the cava, the surface is rough between the layers of the coronary ligament (fig. 158, *), where it was adherent to the diaphragm ; and close to the vein is a small hollow (<i>suprarenal impression</i> ; fig. 158, <i>sr i</i>) into which the right suprarenal body is received.
Anterior border thin and notched.	<i>Border.</i> The anterior border is thin, and is marked by two notches : one is opposite the longitudinal sulcus on the under

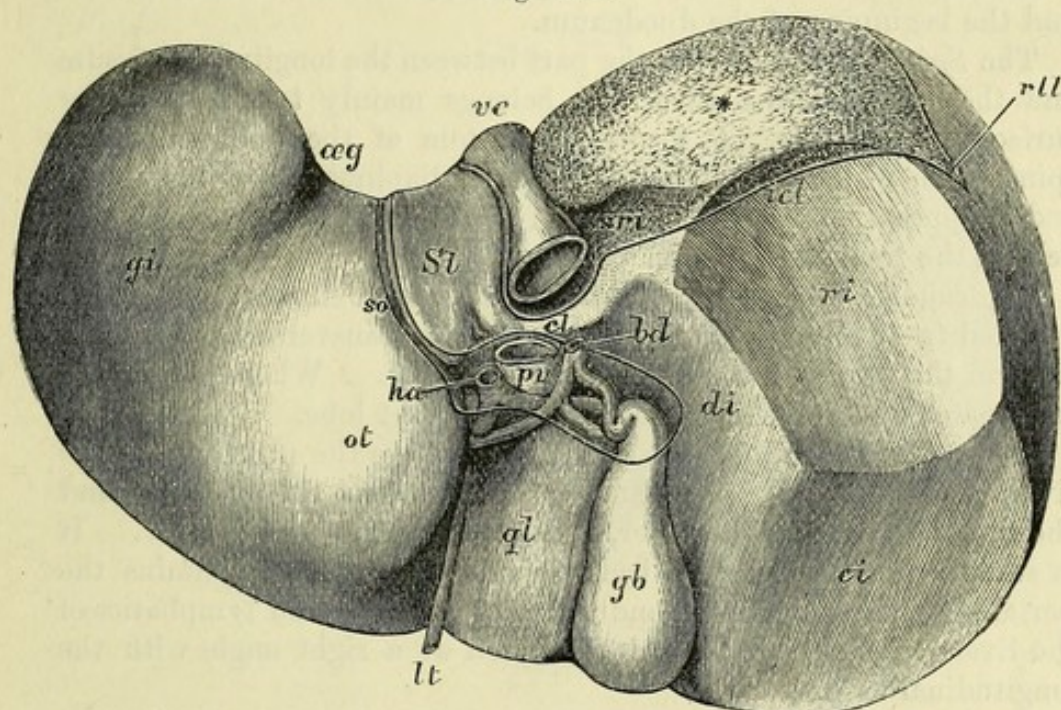
surface before alluded to, and the other is over the large end of the gall-bladder.

Extremities. The right extremity is thick and rounded ; and the left is thin and flattened.

LOBES. On the under and posterior surfaces the liver is divided primarily into two lobes, a right and a left, by the antero-posterior or longitudinal fissure ; and occupying part of the right lobe are three others, viz., the quadrate, Spigelian, and caudate lobes.

The *left lobe* is smaller and thinner than the right ; on its posterior aspect is a groove (*œsophageal groove* ; fig. 158, *æ g*) which lodges the œsophagus and stomach.

Fig. 158.*



the lower end of the œsophagus, and widens out below into a hollow for the stomach (*gastric impression* ; *g i*) occupying the greater part of the under surface of the lobe ; but next to the longitudinal fissure is a considerable elevation (*omental tuberosity*, *His* ; *o t*), which lies against the small omentum and the lesser curvature of the stomach.

The *right lobe* forms the greater part of the liver, and is separated from the left by the longitudinal fissure below and behind, and by the suspensory ligament above. The under surface has a *fossa* for the gall-bladder.

* The liver, viewed from below and slightly from behind (after His). *Subdivisions and markings* : On the left lobe—*æ g*. Œsophageal groove. *g i*. Gastric impression. *o t*. Omental tuberosity. On the right lobe—*S l*. Spigelian lobe. *c l*. Caudate lobe. *q l*. Quadrate lobe. *s r i*. Suprarenal impression. *d i*. Duodenal impression. *r i*. Renal impression. *c i*. Colic impression.

Vessels, &c. : *v c*. Inferior vena cava. *p v*. Portal vein. *h a*. Hepatic artery. *b d*. Common bile-duct : the last three occupy the portal fissure. *l t*. Ligamentum teres, lying in the fore part of the longitudinal fissure. *g b*. Gall-bladder.

Cut edges of peritoneum : *s o*. The two layers of the small omentum. *i c l*. The inferior layer of the coronary ligament. *r l l*. Right lateral ligament.

* Surface uncovered by peritoneum.

- impressions for duodenum, kidney, colon, and supra-renal body, and three small lobes, viz., quadrate, Spigelian, and caudate. Three fissures, viz., portal or transverse, longitudinal, and one for vena cava. Vessels in the transverse fissure. Hepatic duct.
- the gall-bladder*, and is marked to the right of this by three impressions ;—the one next to the gall-bladder is the *duodenal impression* (fig. 158, *d i*), and corresponds to the second part of the duodenum ; more externally is the *renal impression* (*r i*) for the right kidney ; and farther forwards is the *colic impression* (*c i*), where the liver rests on the transverse colon. On the posterior surface is the *suprarenal impression* (*sr i*) already referred to. The three following so-called lobes also are portions of the surface of the right lobe :—
- The *quadrate lobe* (*q l*) is situate between the gall-bladder and the longitudinal fissure. It reaches anteriorly to the margin of the liver, and posteriorly to the fissure (transverse) by which the vessels enter the viscus. It is impressed by the pyloric end of the stomach and the beginning of the duodenum.
- The *Spigelian lobe* (*S l*) is the part between the longitudinal fissure and the inferior vena cava, and belongs mainly to the posterior surface of the liver. It forms the bottom of the hollow for the spine, from which it is separated by the diaphragm and the aorta ; and it appears on the under aspect of the organ as a slight projection behind the transverse fissure.
- The *caudate lobe* (*c l*) is a narrow, elongated eminence, which is directed from the Spigelian lobe behind the transverse fissure, so as to form the posterior boundary of that sulcus. Where the fissure terminates this projection subsides in the right lobe.
- FISSURES.** Extending nearly half way across the right part of the liver, between the Spigelian and caudate lobes on the one hand, and the quadrate lobe on the other, is the *transverse* or *portal fissure*. It is situate much nearer the back than the front, and contains the portal vein, hepatic artery, and the nerves, ducts, and lymphatics of the liver. At the left end it is united at a right angle with the longitudinal fissure.
- The *longitudinal fissure* (fig. 159, *F*) extends from the front to the back of the liver, between the right and left lobes. In it, anterior to the transverse fissure, lies the remnant of the umbilical vein (*c*), which is called the round ligament, and is oftentimes arched over by a piece of the hepatic substance (*pons hepatis*) ; and behind that fissure is a small fibrous cord (*d*), the remains of the vessel named *ductus venosus* in the fœtus.
- The *groove for the vena cava* is placed on the right side of the Spigelian lobe, and is frequently bridged over by the liver. If the cava (*a*) be opened, two or three large and some smaller hepatic veins will be observed entering it.
- VESSELS OF THE TRANSVERSE FISSURE.** The vessels in the transverse fissure, viz., portal vein, hepatic artery and duct, have the following position ;—the duct is anterior, the portal vein posterior, and the artery between the other two.
- The *hepatic duct* (fig. 159, *e*) is formed by two branches,—one from the right, and one from the left lobe, which soon blend in a common tube. After a distance of one inch and a half it is joined by the duct of the gall-bladder (*f*) ; and the union of the two gives rise to the common bile-duct (*g*).

and adheres closely to the fibrous coat. At certain spots intervals exist between the two, viz., in the fissures occupied by vessels, along the line of attachment of the ligaments, and at the surface touching the gall-bladder.

The *fibrous covering* is very thin, but it is rather stronger where the peritoneum is not in contact with it. It invests the liver, and is continuous at the transverse fissure with the fibrous sheath (capsule of Glisson) surrounding the vessels in the interior. When the membrane is torn from the surface, it will be found connected with fine shreds entering into the liver.

Size and form of the lobules. The lobules (fig. 160, *l*) constitute the proper secreting substance, and can be seen either on the exterior of the liver, on a cut surface, or by means of a rent in the mass. As thus observed, these bodies are about the size of a pin's head, and measure from $\frac{1}{20}$ th to $\frac{1}{10}$ th of an inch in diameter. Closely massed together, they possess a dark central point; and there are indications of lines of separation between them, though they are to some extent united together. By means of transverse and vertical sections of the lobules, their form will appear flattened on the exterior, but many-sided in the interior of the liver. They are clustered around the smallest divisions of the hepatic vein, to which each is connected by a small twig issuing from the centre, something like the union of the stalk with the body of a small fruit.

VESSELS OF THE LIVER. Two sets of blood-vessels ramify in the liver:—One enters the transverse fissure, and the branches are directed transversely in spaces (portal canals) where they are enveloped by areolar tissue. The other set (hepatic veins) run from the anterior to the posterior border of the liver without a sheath. The ramifications of these different vessels are to be followed in the liver.

The *capsule of Glisson* is a layer of areolar tissue, which envelops the vessels and the ducts in the transverse fissure, and is continued on their branches in the portal canals. In this sheath the vessels ramify, and become minutely divided before their termination in the lobules. If a transverse section is made of a portal canal, the vessels will retract somewhat into the loose surrounding tissue.

The *portal vein* ramifies in the liver like an artery; and the blood circulates through it in the same manner, viz., from trunk to branches. After entering the transverse fissure the vein divides into large branches; these lie in the portal canals or spaces, with offsets of the hepatic artery, the hepatic duct, and the nerves and lymphatics (fig. 160, *p*). The division is repeated again and again, until the last branches of the vein (*interlobular*) penetrate between the lobules, where they communicate together, and supply the hepatic substance.

In the portal canals the offsets of the vena portæ are joined by small *vaginal* and *capsular veins*, which convey blood from branches of the hepatic artery.

The *hepatic artery* (fig. 160, *c*), while surrounded by the capsule,

furnishes *vaginal branches*, which ramify in the sheath, giving it a red appearance in a well-injected liver, and supply twigs to the coats of the portal vein and biliary ducts, and to the areolar tissue: from the vaginal branches a few offsets (*capsular*) are given to the coat of the liver. Finally, the artery ends in fine *interlobular branches*, from which offsets enter the lobules.

The *hepatic veins* (*venæ cavæ hepaticæ*) begin by small *intralobular veins* from the centre of the lobules; these are received into the *sublobular branches*, which anastomose together, and unite into larger vessels. Finally, uniting with neighbouring branches to produce larger trunks, the hepatic veins are directed from before backwards to the vena cava inferior, into which they open by large orifices. The hepatic veins may be said to be without a sheath, except in the larger trunks; so that when they are cut across the ends remain patent, in consequence of their close connection with the liver structure.

Hepatic duct. The biliary ducts follow the portal vein in their mode of branching, and run with the other vessels in the portal canals (fig. 160, *d*). They issue from the liver at the transverse fissure in a right and left trunk, which by their union form the common hepatic duct (fig. 159, *e*).†

Structure. The moderately-sized hepatic ducts consist of a fibrous coat, lined by a mucous layer; and penetrating the wall is a longitudinal row of openings, on each side, leading into sacs, and into branched tubes which sometimes communicate.

Lymphatics of the liver are superficial and deep. The superficial of the upper surface in part join the lymphatics of the thorax by piercing the diaphragm, and enter the anterior mediastinal glands; those of the under surface mainly join the deep lymphatics issuing at the portal fissure.

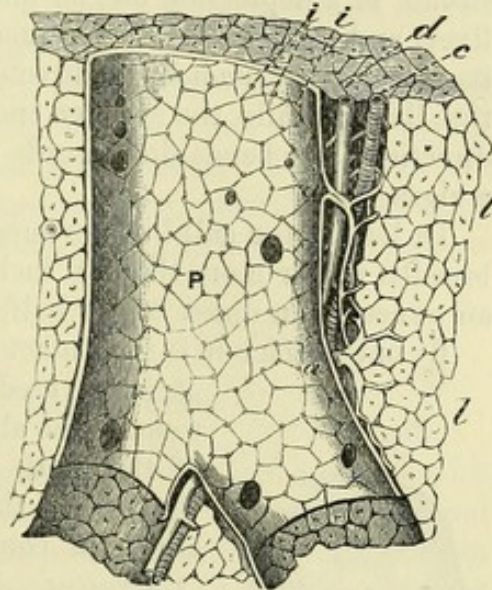
The deep lymphatics accompany both sets of vessels in the liver; and deep. those with the portal vein descend through some small glands in the

nourishes the vessels and capsule:

ending in lobules.

Hepatic veins without a sheath, begin in the lobules,

Fig. 160.*



and end in the vena cava.

Biliary ducts form

right, left, and common hepatic ducts.

Structure of medium-sized ducts.

Lymphatics: superficial,

* Vessels in a portal canal, and the lobules of the liver (Kiernan). *l*. Lobules of the liver. *p*. Branch of the portal vein, with *a, a*, small branches which supply interlobular offsets. *c*. Hepatic artery. *d*. Hepatic duct. *i, i*. Openings of interlobular branches of the portal vein.

† Aberrant ducts exist between the pieces of the peritoneum in the left lateral ligament of the liver, and in the pons bridging over the round ligament and vena cava; they anastomose together, and are accompanied by branches of the vessels of the liver, viz., portal vein, hepatic artery, and hepatic vein.

lesser omentum and end in the coeliac glands ; while those accompanying the hepatic veins pass through the diaphragm, and enter the glands of the posterior mediastinum.

Nerves.

Nerves come from the sympathetic and the pneumo-gastric, and ramify with the hepatic artery.

THE GALL-BLADDER.

Use and situation ;

form ;

size ;

relations.

Structure of wall.

Serous coat.

Fibrous and muscular stratum.

Mucous layer is alveolar on surface ;

projections of the wall.

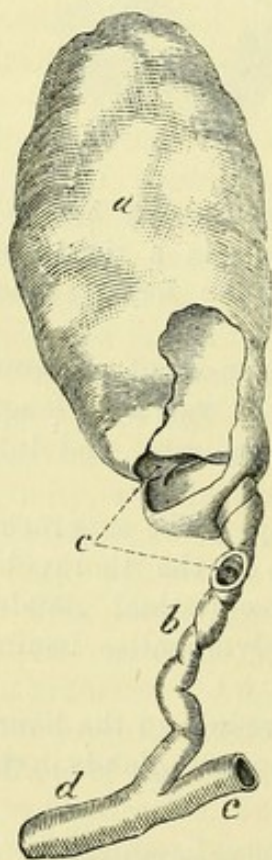
Duct of gall-bladder ;

The gall-bladder (fig. 158, *gb*) is the receptacle of the bile. It is situate in a depression on the under surface of the right lobe of the liver, and to the right of the quadrate lobe. It is pear-shaped, and its larger end (*fundus*) is directed forwards beyond the margin of the liver ; while the smaller end (*neck*) is turned in the opposite direction, and bends downwards to terminate in the cystic duct by a zigzag part.

In length the gall-bladder measures three or four inches, and in breadth rather more than an inch at the widest part. It holds from an ounce to an ounce and a half.

By one surface it is in contact with the liver, and on the opposite it is covered by peritoneum. The larger end touches the abdominal wall opposite the cartilage of the ninth rib (fig. 144, *gb*), where it is contiguous to the transverse colon ; and the small end is in contact with the duodenum.

Fig. 161.*



Structure. The gall-bladder possesses a peritoneal, a fibrous and muscular, and a mucous coat.

The *serous coat* is stretched over the under or free surface of the gall-bladder, and surrounds the large end.

The *fibrous coat* is strong, and forms the framework of the sac ; intermixed with it are some involuntary *muscular fibres*, the chief being longitudinal, but others circular.

The *mucous coat* is marked internally by numerous ridges and intervening depressions, which give an alveolar or honeycomb appearance to the surface. On laying open the gall-bladder this condition will be seen, with the aid of a lens, to be most developed about the centre of the sac, and to diminish towards each extremity. In the bottom of the larger pits are depressions leading to recesses.

Where the gall-bladder ends in the cystic duct (fig. 161) its coats project into the interior, and give rise to ridges resembling those in the sacculated large intestine.

The *cystic duct* (*b*) joins the hepatic duct at an acute angle, to

* Gall-badder and its duct. *a.* Gall-bladder. *b.* Cystic duct. *c.* Ridges in the interior. *d.* Common bile-duct. *e.* Common hepatic duct.

form the common bile-duct. It is about an inch and a half long, and is distended and somewhat sacculated near the gall-bladder.

Structure. The coats of the duct are formed like those of the sac from which it leads, but the muscular fibres are very few. The mucous lining is provided with glands, as in the hepatic and common bile-ducts. structure same as sac; and is provided with glands.

On opening the duct the mucous membrane may be observed to form about twelve semilunar projections (fig. 161, c), which are arranged obliquely around the tube, and increase in size towards the gall-bladder. This structure is best seen on a gall-bladder which has been inflated and dried, as in this state the parts of the duct between the ridges are most stretched. Mucous coat like a screw.

Blood-vessels and nerves. The vessels of the gall-bladder are named *cystic*. The artery is a branch of the hepatic; and the cystic vein opens into the right branch of the vena portæ. The nerves are derived from the hepatic plexus, and entwine around the vessels. The *lymphatics* follow the cystic duct, and join the lymphatics on the under surface of the liver. Artery and vein; nerves and lymphatics.

THE KIDNEY AND THE URETER.

The KIDNEY has a characteristic form, resembling an oval with one side (the inner) somewhat hollowed out, and being compressed from before backwards. For the purpose of distinguishing between the right and left kidneys, let the excavated margin be turned inwards, with the ureter or the excretory tube behind the other vessels; and let that end of the viscus be directed downwards, towards which the ureter is naturally inclined. Kidney: form; to distinguish right from left.

With the special form above mentioned, the kidney is of a deep red colour, and has an even surface. Its average length is about four inches; its breadth two and a half inches; and its thickness rather more than one inch; but the left is commonly longer and more slender than the right kidney. Its usual weight is about four ounces and a half in the male, and rather less in the female. The left kidney is slightly heavier than the right. Colour; size; and weight.

The upper extremity of the kidney is broader than the lower, and is surmounted by the suprarenal body. The lower end is more pointed. The position with respect to the spinal column has been before detailed (p. 472). Extremities;

On the anterior surface the viscus is rounded, but on the opposite surface it is more flattened. surfaces;

The outer border is convex; but the inner is excavated, and is marked by a longitudinal fissure—the *hilum*. In the fissure the vessels are thus placed with respect to one another:—The divisions of the renal vein are in front, the ureter is behind, and the branches of the artery lie between the two. On the vessels the nerves and lymphatics ramify; and areolar tissue and fat surround the whole. The fissure leads into a hollow named the *sinus*, in which the vessels and the duct are contained before they pierce the renal substance. borders. Contents of the fissure: their position. Sinus.

Open the
kidney, and
clean the
vessels.

Renal
substance
divided into
cortical and
pyramidal.
Pyramids :

number ;

apex

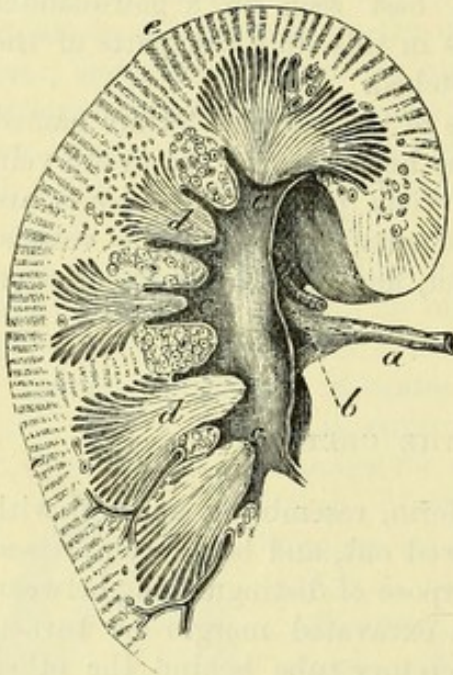
ends in
papilla ;

base.

Dissection. To see the interior it will be necessary to cut through the kidney from the inner to the outer border, and to remove the loose tissue from the vessels, and from the divisions of the excretory duct. The sinus containing the blood-vessels now comes completely into view.

The *interior of the kidney* (fig. 162) is seen on a section to consist of an external granular or cortical portion, and of internal, darker coloured, pyramidal masses, which converge towards the centre.

Fig. 162.*



The *pyramidal masses* (pyramids of Malpighi; *d*) are from eight to eighteen in number, but generally more than twelve. The apex of each mass, which is free from cortical covering, is directed to the sinus, and ends in a smooth, rounded part, named *mamilla* or *papilla* (*c*). In it are the openings of the urine tubes, which are about twenty in number, some being situate in a central depression, and others on the surface; and it is surrounded by one of the divisions (calyx) of the excretory tube. Occasionally two of the masses are united in one papillary termination. The base is embedded in the cortical substance, and from it slender processes are continued into the cortical covering. The cut surface

of the pyramid has a striated appearance, owing to the arrangement of the uriniferous tubules composing it, and the blood-vessels. If the mass is compressed in a fresh kidney, urine will exude from the tubes through the apertures in the apex.

Extent of
cortical
substance :

colour ;

consistence.

The *cortical part* (fig. 162, *e*) forms about three-fourths of the kidney; it covers the pyramidal masses with a layer about two lines in thickness, and sends prolongations between them nearly to their apices. Its colour is of a light red, unless the kidney is blanched; and its consistence is so slight that the mass gives way beneath the finger. In the injected kidney red points (Malpighian bodies) are scattered through the cortex, giving it a granular appearance.

Fibrous
coat

sends in
offsets.

The kidney has a *fibrous tunic* or *capsule*, which is connected to the glandular substance by fine processes and vessels, and is readily detached from it by slight force. At the inner margin of the kidney it sinks into the sinus, where it sends processes on the entering vessels, and becomes continuous with the outer coat of the excretory duct.

* Section through a piece of the kidney, showing the medullary and cortical portions, and the beginning of the ureter (Henle). *a*. Ureter. *b*. Pelvis of the ureter. *c*. Calyx of the excretory tube. *d*. Pyramids. *e*. Cortical portion of the kidney.

Blood-vessels. The artery and vein distributed to the kidney are very large in proportion to the size of the organ they supply. Blood-vessels.

Renal artery. Before reaching the kidney the renal artery divides into four or five pieces; and these in the sinus break up into smaller branches, which enter the organ between the papillæ. They run in the processes of cortical substance that separate the pyramids, being surrounded by sheaths from the fibrous capsule, and undergoing farther subdivision, until they reach the bases of the pyramids. Here the branches form arches, from which the minute offsets to the secreting structures are given off. Some twigs are supplied to the capsule of the kidney; and these anastomose with the subperitoneal branches of the lumbar arteries. Branching of the renal artery.

Renal vein. The larger branches of the vein spring from arches like those of the artery, and take a similar course through the cortical septa to the sinus. In the neighbourhood of the hilum all are commonly united into one trunk, which joins the inferior cava. Vein agree with artery.

Nerves. The ramifications of the sympathetic nerve may be traced to the smaller branches of the artery. Nerves.

The *absorbents* are superficial and deep. Both unite at the hilum of the kidney, and join the lumbar glands. Lymphatics

The URETER is the tube by which the fluid secreted in the kidney is conveyed to the bladder. Between its origin and termination the canal measures from fourteen to sixteen inches in length. Its size corresponds commonly with that of a large quill. Near the kidney it is dilated into a funnel-shaped part, named *pelvis*; and near the bladder it is again somewhat enlarged, though the lower aperture by which it terminates is the narrowest part of the tube. Its relative anatomy must be studied afterwards, when the body is in a suitable position. Ureter : office ; length ; size varies.

In its course from the one viscus to the other, the ureter is close beneath the peritoneum, and is directed obliquely downwards and inwards along the posterior wall of the abdomen to the pelvis. At first the ureter is placed over the *psaos*, inclining on the right side towards the inferior vena cava; and about the middle of the muscle it is crossed by the spermatic vessels. Lower down it lies over the common or the external iliac artery, being beneath the sigmoid flexure on the left side, and the end of the ileum on the right side. Lastly, it inclines forwards below the level of the obliterated hypogastric artery to reach the base of the bladder (p. 549). Course and relations.

Sometimes the ureter is divided into two for a certain distance. Sometimes double.

Part in the kidney (fig. 162, b). Near the kidney the ureter is dilated into a funnel-shaped part called the *pelvis*. It begins in the kidney by a set of cup-shaped tubes, named *calices* or *infundibula*, which vary in number from seven to thirteen. Each cup-shaped process embraces the rounded end of a pyramidal mass, and receives the urine from the apertures in that projection: sometimes a calyx surrounds two or more masses. The several calices are united together to form two or three larger tubes; and these are finally blended in the pelvis. Ureter dilated near the kidney ; has calices, which embrace papillæ.

- Three coats to ureter : *Structure.* The chief part of the wall of the ureter is composed of a *muscular coat*, in which there is an outer layer of circular, and an inner layer of longitudinal fibres (Henle). This has an external fibrous, muscular, and mucous. investment of *fibrous tissue*, and is lined by *mucous membrane*.
- The calices also three coats. The *calices* resemble the rest of the duct in having a fibrous, a muscular, and a mucous coat. Around the base of the papilla the outer coat of the calyx is continuous with the enveloping tunic of the kidney; and at the apex the mucous lining is prolonged into the uriniferous tubes through the small openings.
- Vessels. *Vessels.* The *arteries* are numerous but small, and are furnished by the renal, spermatic, internal iliac, and inferior vesical. The *veins* correspond with the arteries.
- Lymphatics. The *lymphatics* are received into those of the kidney.

THE SUPRARENAL BODY.

- Suprarenal capsule : use unknown ; no duct. *This small body, the use of which is unknown, has received its name from its position to the kidney. Its vessels and nerves are numerous, but it is not provided with any excretory duct.*
- Situation ; colour ; and form. One on each side, it is situate on the upper end of the kidney, with an inclination to the inner side ; and without care it may be removed with the surrounding fat, which it resembles. Its colour is a brownish yellow. It is rather triangular in shape, and flattened from before back, but with the upper angle rounded off, and the base or lower part hollowed, where it touches the kidney. On the anterior surface is a transverse fissure, termed the *hilum*, where the vein issues.
- Hilum. In the adult it measures about one inch and a half in depth, and rather less in width ; and its weight is between one and two drachms, but the left is commonly larger than the right.
- Size and weight. Areolar tissue attaches the suprarenal body to the kidney ; and the vessels and nerves retain it in place. The relations to surrounding parts are the same as those of the upper end of the kidney. Thus, it rests on the diaphragm on both sides ; while in front of the right is the liver, and in front of the left the pancreas and the stomach. On the inner side of the right capsule are the vena cava and the solar plexus ; and internal to the left are the aorta, with the cœliac axis, and the solar plexus.
- Relations. *Obvious structure.* A vertical section of a fresh suprarenal body shows it to be formed of an external or cortical layer, and an internal or medullary substance. The whole is surrounded by a thin fibrous capsule, which sends processes into the interior, and along the blood-vessels.
- Consists of two parts, with a fibrous capsule. The *cortical part* is of a deep yellow colour, and firm. It forms about two-thirds of the thickness of the whole body, and in the section appears striated perpendicularly to the free surface of the organ. The *medullary part* is dark brown or nearly black, and very soft and pulpy. If the specimen is not fresh, it may look as if the cortical part enclosed a cavity.
- Cortical and medullary parts.

Blood-vessels. Numerous *arteries* are furnished to the suprarenal body from the aorta and from the diaphragmatic and renal arteries. Their small branches penetrate the organ at many spots of its circumference. The *veins* are for the most part collected into one large trunk, which issues by the hilum, and opens on the right side into the vena cava, on the left into the renal vein. Other smaller veins pass out through the cortex to the renal vein and the vena cava.

Nerves. The nerves are very numerous and large, and come from the solar plexus.

Lymphatics are superficial and deep; and both join those of the kidney.

THE TESTICLE.

The testicles (testes) are the glandular organs for the secretion of the semen. Each is suspended in the scrotum by the spermatic cord and its coverings (p. 451), but the left is usually lower than the right; and each is provided with an excretory duct named vas deferens. A serous sac partly surrounds each organ.

Dissection. For the purpose of examining the serous covering of the testicle (tunica vaginalis), make a small aperture into it at the upper part, and inflate it. The sac and the spermatic cord are then to be cleaned; and the vessels of the latter are to be followed to their entrance into the testicle.

The *tunica vaginalis* (fig. 163, *d*) is a serous bag, which is continuous in the fœtus with the peritoneal lining of the abdomen, but becomes subsequently a distinct sac through the obliteration of the part connecting the two (p. 451).

It invests the testicle after the manner of other serous membranes; for the testicle is placed behind it, so as to be partly enveloped by it. The sac, however, is larger than is necessary for covering the testicle, and projects some distance above it. Like other serous membranes, it has an external rough, and an internal smooth surface; and like them it has a visceral and a parietal part. To examine its disposition, the sac should be opened.

The *visceral layer* (tunica vaginalis testis) covers the testicle, except posteriorly where the vessels lie. On the outer side it extends farther back than on the inner, and invests the greater part of the epididymis, forming a pouch (digital fossa) between that body and the testicle.

The *parietal part* of the sac (tunica vaginalis scroti) is more extensive than the piece covering the testicle, and lines the contiguous layer of the scrotum.

Form and position of the testis (fig. 163). The testicle is oval shape, with a smooth surface, and is somewhat compressed from side to side. The anterior margin is convex and free; the posterior, which is flattened, is pierced by the spermatic vessels and nerves. Stretching like an arch along the outer side is the epididymis (*b*). Attached to the upper end of the testis is a small body (*c*) two or

Body of
Morgagni.

three lines in length (*corpus Morgagni*), which is the remains of the upper end of the foetal duct of Müller ; and occasionally other smaller projections of the tunica vaginalis are connected with the top of the epididymis.

Suspended
obliquely.

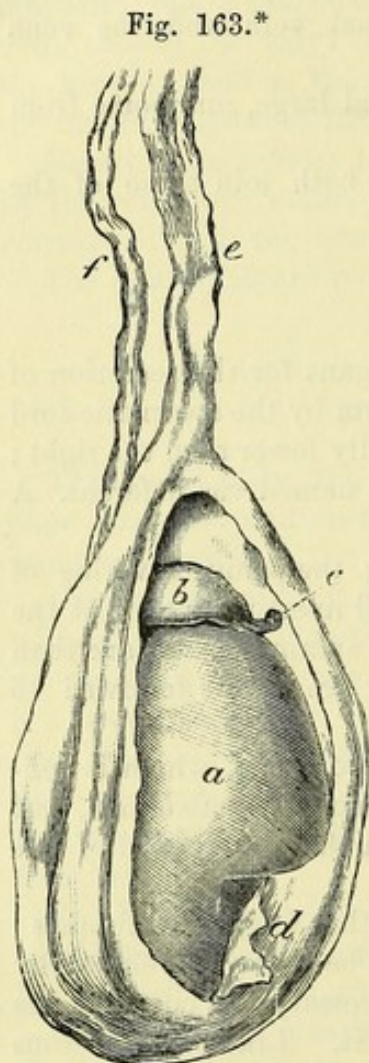
The testis is suspended obliquely, so that the upper part is directed forwards and somewhat outwards, and the lower end backwards and rather inwards.

Dimensions,

and weight.

A dense
tunic en-
closes small
secreting
tubes.

How to see
the struc-
ture of the
testis.



Size and weight. The length of the testis is an inch and a half or two inches ; from before backwards it measures rather more than an inch, and from side to side rather less than an inch. Its weight is nearly an ounce, and the left is frequently larger than the other.

STRUCTURE. The substance of the testicle is composed of minute secerning tubes, around which the blood-vessels are disposed in plexuses. Surrounding and supporting the delicate seminiferous tubes is a dense covering—the tunica albuginea. Its excretory or efferent duct is named vas deferens.

Dissection. With the view of examining the investing fibrous coat, let the testis be placed on its outer side, viz., that on which the epididymis lies, and let it be fixed firmly in that position with pins. The fibrous coat is to be cut through along the anterior part, and thrown backwards as far as the entrance of the blood-vessels. While raising this membrane a number of fine bands will be seen traversing the substance of the testicle, and a short septal piece (*mediastinum*) may be perceived at the back of the viscus, where the vessels enter ; but it will be expedient to remove part of the mass of tubes in the interior, to bring more fully into view the *mediastinum*, and to trace back some of the finer septa to it.

Fibrous
coat :

characters ;
use ;

sends
inwards
processes,

The *tunica albuginea*, or the fibrous coat of the testicle, is of a bluish-white colour, and resembles in appearance the sclerotic coat of the eyeball. This membrane protects the secreting part of the testicle, and maintains the shape of the organ by its dense and unyielding structure : it also sends inwards processes to support and separate the seminal tubes. These several offsets of the membrane appear in the dissection ; and one of them at the back of the testicle, which is larger than the rest, is the *mediastinum*.

* The testis, with the tunica vaginalis laid open. *a.* Testicle. *b.* Head of the epididymis. *c.* Corpus Morgagni. *d.* Parietal part of the tunica vaginalis. *e.* Vessels of the spermatic cord. *f.* Vas deferens.

The *mediastinum testis* (corpus Highmorianum; fig. 164, r) projects into the gland for a third of an inch with the blood-vessels. It is situate at the back of the testis, extending from the upper nearly to the lower end, and is rather larger and deeper above than below. It is formed of two pieces, which are united in front at an acute angle. To its front and sides the finer septal processes are connected; and in its interior are contained the blood-vessels behind, and a network of seminal ducts (rete testis) in front.

Of the *finer processes* of the tunica albuginea (fig. 164, b) which enter the testis, there are two kinds. One set, round and cord-like, but of different lengths, is attached posteriorly to the mediastinum, and serves to maintain the shape of the testis. The other set forms delicate membranous septa, which divide the mass of seminal tubes into lobes, and join the mediastinum, like the rest.

Within the tunica albuginea is a thin vascular layer, the *tunica vasculosa*, which lines the fibrous coat, and covers the different septa in the interior of the gland. It is formed of the ramifications of the blood-vessels, united by areolar tissue, like the pia mater of the brain: in it the arteries are subdivided before they are distributed on the secerning tubes, and the small veins are collected into larger trunks.

Form and length of the seminal tubes (tubuli seminiferi). The secerning or seminal tubes are very convoluted, and are but slightly held together by fine areolar tissue and surrounding blood-vessels, so that they may be readily drawn out of the testis for some distance: their length is said by Lauth to be two feet and a quarter.

Ending, size and structure. Within the lobes of the testis some tubes end in distinct closed extremities; but the rest communicate, forming loops or arches. The diameter of the tubules varies from $\frac{1}{100}$ th to $\frac{1}{150}$ th of an inch. The wall of the tubule is formed of a thin translucent membrane, but it has considerable strength.

Names from the arrangement of the tubes. To different parts of the seminal tubes, the following names have been applied. Where the tubules are collected into masses, they form the lobes of the testis. As they enter the fibrous mediastinum they become straight, and are named tubuli recti. Communicating in the mediastinum, they produce the rete testis. And, lastly, as they leave the upper end of the gland they are convoluted, and are called coni vasculosi, or vasa efferentia.

The *lobes of the testis* (fig. 164, a) are formed by bundles of the seminiferous tubes, and are situate in the intervals between the processes of the tunica albuginea. From 100 to 200 in number (Krause), they are conical in form, with the base of each at the circumference, and the apex at the mediastinum testis; and those in the centre of the testicle are the largest.

Each is made up of two or more tortuous seminal tubules; and the minute tubes in one lobe are united with those in the neighbouring lobes. Towards the apex of each lobe the tubules become less bent, and are united together; and the tubuli of the several lobes are farther joined at the same spot into the tubuli recti.

Tubes next
become
straight
(tubuli
recti),

afterwards
join toge-
ther (rete
testis),

and leave
the gland
as vasa
efferentia.

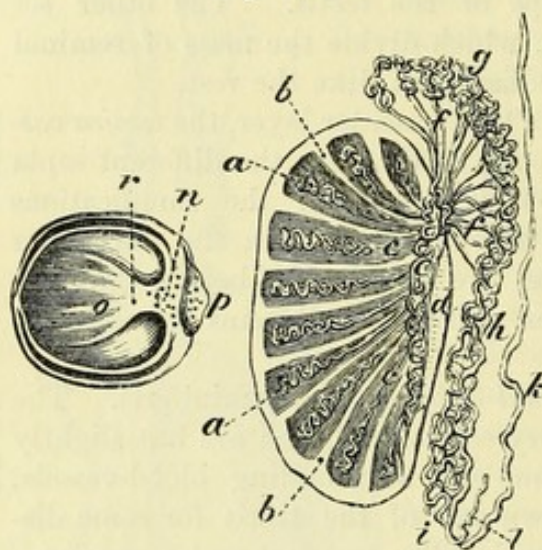
Tubuli recti (fig. 164, c). The seminal tubes uniting together become narrower and straighter in direction, and are named tubuli recti or vasa recta: they pierce the fibrous mediastinum and enter the rete testis.

Rete testis (fig. 164, e). In the mediastinum the seminal tubes have no proper walls (beyond epithelium), and are situate in the anterior part, in front of the blood-vessels; they communicate freely so as to form a network.

Vasa efferentia (fig. 164, f). From twelve to twenty tubes leave

the top of the rete, and issue from the upper end of the testicle as the vasa efferentia: these are larger than the tubes with which they are continuous, and end in the canal of the epididymis (part of the common excretory duct). Though straight at first, they soon become convoluted, and have been named *coni vasculosi*. In the natural state they are about half an inch in length, but when unravelled they measure six inches; and they join the excretory duct at intervals of about three inches.

Fig. 164.*



Excretory
duct in
two parts.

The EXCRETORY DUCT receives the vasa efferentia from the upper part of the gland, and extends thence to the urethra. Its first part, which is in contact with the testis, is very flexuous, and forms the epididymis; but the remainder is comparatively straight, and is named vas deferens.

Epididymis
consisting

of head,

tail,

and body;

how fixed;

formed of a
coiled tube;

The EPIDIDYMIS (fig. 164, h) extends in the form of an arch along the outer side of the testis, from the upper to the lower end, and receives its name from its situation. Opposite the upper part of the testicle it presents an enlarged portion or head, the *globus major* (g); and at the lower end of that organ it becomes more pointed or tail-like—*globus minor* (i), before ending in the vas deferens. The intervening narrow part of the epididymis is called the *body* (h). It is attached to the testis, most closely at the ends, by fibrous tissue and by the reflection of the tunica vaginalis, the *globus major* also by the vasa efferentia.

The epididymis is formed of a single tube, bent in a zigzag way, the coils of which are united into a solid mass by fibrous tissue.

* Vertical and horizontal sections of the testis, to show the arrangement of the septa and seminal tubes. a. Lobes of the testis. b. Septa between the lobes. c. Tubuli recti. d. Mediastinum testis. e. Rete testis. f. Vasa efferentia. g. Globus major, h. Body, and i. Globus minor of the epididymis. k. Vas deferens. l. Vas aberrans. n. Rete testis, in section. o. Finer septa. p. Epididymis, cut across. r. Mediastinum, cut across.

After the removal of the serous membrane and some fibrous tissue this part of the tube may be uncoiled ; it will then measure twenty feet or more in length. The diameter of its canal is about $\frac{1}{70}$ th of an inch, though there is a slight diminution in size towards the globus minor ; but it increases again as it approaches the vas deferens.

length and size.

The VAS DEFERENS (fig. 164, *k*) begins opposite the lower end of the testis, at the termination of the globus minor of the epididymis. At first the excretory duct is slightly wavy, but afterwards it becomes for the most part a firm, round, and direct tube ; near its termination it is enlarged again and sacculated, but this condition will be referred to with the viscera of the pelvis.

Vas deferens :

In its course to the urethra it ascends over the hinder part of the testicle, on the inner side of the epididymis, and then along the blood-vessels of the spermatic cord, with which it enters the internal abdominal ring ; here it bends downwards round the epigastric artery (p. 452), and is then continued over the bladder (p. 550), and through the prostate to open into the urethra. The length of this part of the excretory duct is about two feet, and the width of its canal about $\frac{1}{50}$ th of an inch.

course to urethra :

length and size.

Opening into the vas deferens, at the angle of union with the epididymis, there is frequently a small, narrow, cæcal appendage, the *vas aberrans* of Haller (fig. 164, *l*). It is convoluted, and projects upwards for one or two inches amongst the vessels of the cord. Like the epididymis, it is longer when it is uncoiled. Its capacity is greatest at the free end.

Vas aberrans frequently present : situation,

and size.

Structure. The excretory duct of the testis has a thick muscular coat, which is covered externally by fibrous tissue, and lined internally by mucous membrane. To the feel the duct is firm and wiry, like whip-cord. On a section its wall is dense and of a rather yellow colour : it is thinnest at the head of the epididymis.

Three coats form the duct : a fibrous,

The *muscular coat* is composed of longitudinal and circular fibres arranged in strata. Both externally and internally is a longitudinal layer, the latter being very thin ; and between them is the layer of circular fibres.

a muscular,

The *mucous membrane* is marked by longitudinal folds in the straight part of the canal, and by irregular ridges in the sacculated portion.

and a mucous.

Organ of Giralaldès. In the spermatic cord of the fœtus and child, sometimes in the adult, a small whitish, granular-looking body may be recognised, which is named after its discoverer the *organ of Giralaldès*, or the *paradidymis* (Waldeyer). It consists of several small masses of convoluted tubules, which appear to be remnants of the lower part of the Wolffian body.

Organ of Giralaldès :

remains of Wolffian body.

Blood-vessels and nerves of the testicle. The branches of the *spermatic artery* supply offsets to the epididymis, and enter the posterior part of the mediastinum. The vessels are finely divided in the vascular structure lining the interior of the tunica albuginea, before being distributed to the lobes of the testis.

Spermatic artery.

The *spermatic vein* results from the union of branches issuing

Spermatic vein.

from the back of the testicle and the epididymis. As it ascends along the cord its branches form the spermatic plexus. It joins the vena cava on the right side, and the renal vein on the left (p. 531).

Lymphatics The *lymphatics* of the testicle ascend on the blood-vessels, and join the lumbar glands.

and nerves. The *nerves* are derived from the sympathetic, and accompany the artery to the testis.

Vessels of the duct. *Vessels of the vas deferens.* A special *artery* is furnished to the excretory duct from the upper or lower vesical, and reaches as far as the testis, where it anastomoses with the spermatic artery. *Veins* from the *epididymis* enter the spermatic vein. The *nerves* are derived from the hypogastric plexus.

SECTION V.

DIAPHRAGM WITH AORTA AND VENA CAVA.

Dissect vessels and muscles. *Directions.* After the body is replaced in its former position on the back, the student should prepare first the diaphragm, next the large vessels and their branches, and then the deep muscles of the abdomen.

To see the diaphragm. *Dissection.* For the dissection of the diaphragm it will be necessary to remove the peritoneum, defining especially the central tendinous part, and the strong processes or pillars which are fixed to the lumbar vertebræ. While cleaning the muscle the student should be careful of the vessels and nerves on the surface, and of others in and near the pillars.

Define arches. On the right side two aponeurotic bands or arches near the spine, which give attachment to the muscular fibres, should be dissected; one curves over the internal muscle (psoas); the other extends over the external muscle (quadratus), and will be made more evident by separating it from the fascia covering the quadratus.

Diaphragm: situation and form; The DIAPHRAGM or midriff (fig. 165, A) forms the vaulted moveable partition between the thorax and the abdomen. It is fleshy externally, where it is attached to the surrounding ribs and the spinal column, and tendinous in the centre.

origin at the circumference; The *origin* of the muscle is at the circumference, and is similar on each side of the middle line. Thus, it arises by fleshy slips from the inner surface of the ensiform process and the six lower rib-cartilages; from two aponeurotic arches between the last rib and the spinal column,—one being placed over the quadratus lumborum, and the other over the psoas muscle; and, lastly, from the lumbar vertebræ by a thick muscular piece or pillar. From this extensive origin the fibres are directed inwards, with different degrees of obliquity and length, to the central tendon; but some have a peculiar disposition in the pillars which will be afterwards noted (p. 524).

insertion of fibres into a central tendon.

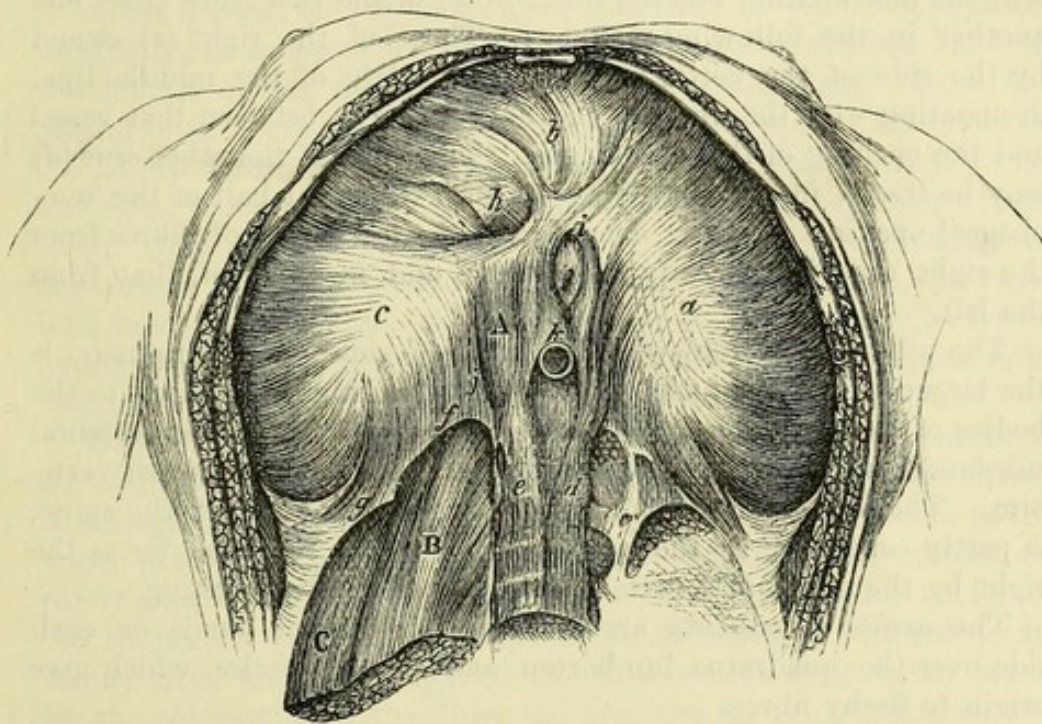
The abdominal surface is concave, and is covered for the most part by the peritoneum. In contact with it on the right side are the liver and the kidney; and on the opposite side, the stomach, the spleen, and the left kidney: in contact also with the pillars are the pancreas and the solar plexus with the semilunar ganglia. The thoracic surface is covered by the pleura of each side and the pericardium (p. 371). At the circumference of the midriff the fleshy processes of origin alternate with like parts of the transversalis muscle; but a slight interval separates the slips from the ensiform process and seventh cartilage, and a second space exists sometimes between the fibres from the last rib and the arch over the quadratus

Parts in contact with the under surface,

and with the upper. Attachment of border.

Intervals in the muscle.

Fig. 165.*



lumborum muscle. In it are certain apertures for the transmission of things from the thorax to the abdomen. Apertures.

The muscle is convex towards the chest, and concave to the abdomen. Its vault reaches higher on the right than the left side, and is constantly varying during life in respiration. In the condition of rest, as met with after death (state of expiration), the central portion is about opposite the xiphi-sternal articulation; on the right side it rises to the level of the fifth, and on the left side to the sixth chondro-sternal articulation. Vault: extent upwards after death.

Special parts of the diaphragm. The following named parts are now to be noticed more fully, viz., the central tendon, the pillars, the arches, and the apertures. Special parts to be examined.

* Under surface of the diaphragm. A. Diaphragm. B. Psoas magnus. c. Quadratus lumborum. a. Left piece of the tendon of the diaphragm; b, middle, and c, right piece. d. Left, and e, right crus. f. Inner, and g, outer arched ligament. h. Opening for vena cava, i, for oesophagus, k, for aorta i for splanchnic nerves.

Central tendon,	The <i>central tendon</i> (cordiform tendon) occupies the middle of the diaphragm (fig. 165), and is surrounded by muscular fibres: the large vena cava pierces it. It is of a pearly white colour, and its tendinous fibres cross in different directions. In form it is compared to a trefoil leaf; of its three lobes or segments the right (<i>c</i>) is the largest, and the left (<i>a</i>) the smallest.
like a trefoil leaf.	
Two pillars,	The <i>pillars</i> (crura) are two large muscular and tendinous processes (<i>d</i> and <i>e</i>), one on each side of the abdominal aorta. They are narrow and tendinous below, where they are attached to the upper lumbar vertebræ, but large and fleshy above; and between them is a tendinous arch over the aorta.
with arch over aorta:	
arrangement of fibres in each	In each pillar the fleshy fibres pass upwards and forwards, diverging from each other; the greater number join the central tendon without intermixing, but the inner fibres of the two crura cross one another in the following manner:—Those of the right (<i>e</i>) ascend by the side of the aorta, and pass to the left of the middle line, decussating with the fibres of the opposite crus between that vessel and the opening of the œsophagus. The fibres of the other crus (<i>d</i>) may be traced in the same way, to form the right half of the œsophageal opening. In the decussation the fasciculus of fibres from the right crus is generally larger than, and in front of, that from the left.
as they ascend to tendon:	
differences in the pillars.	The pillars differ somewhat on opposite sides. The right (<i>e</i>) is the larger of the two, and is fixed by tendinous processes to the bodies of the first three lumbar vertebræ, and their intervertebral substances, reaching to the disc between the third and fourth vertebræ. The left pillar (<i>d</i>) is situate more on the side of the spine, is partly concealed by the aorta, and does not reach so far as the right by the depth of a vertebra: it is occasionally wanting.
Two arched ligaments,	The <i>arches</i> (ligamenta arcuata) are two fibrous bands on each side over the quadratus lumborum and psoas muscles, which give origin to fleshy fibres.
internal	The arch over the psoas (lig. arcuat. internum; <i>f</i>) is the stronger, and is connected by the one end to the tendinous part of the pillar of the diaphragm, and by the other to the transverse process of the first or second lumbar vertebra.
and external.	The arch over the quadratus lumborum (lig. arcuat. externum; <i>g</i>) is only a thickened piece of the fascia covering that muscle, and extends from the same transverse process to the last rib.
Apertures are:—	<i>Apertures.</i> There are three large openings for the aorta, the vena cava, and the œsophagus; with some smaller fissures for nerves and vessels.
For the aorta; its contents.	The opening for the aorta (<i>k</i>) is rather behind than in the diaphragm, for it is situate between the pillars of the muscle and the spinal column: it transmits the aorta, the thoracic duct, and the large azygos vein.
For gullet and nerves.	The opening for the œsophagus and the pneumo-gastric nerves (<i>i</i>) is above and slightly to the left of the aortic aperture; it is placed in the muscular part of the diaphragm, and is bounded by the fibres of the pillars as above explained.

The opening for the vena cava (foramen quadratum ; *h*) is situated between the middle and right divisions of the central tendon ; and its margins are attached to the vein by tendinous fibres.

For the vena cava.

There is a *fissure* (*j*) in each pillar for the three splanchnic nerves ; and through that in the left crus the small azygos vein also passes.

Fissures in the pillars.

Action of the diaphragm. By the contraction of the muscular fibres the tendon is moved downwards, and the arch of the diaphragm is lessened in inspiration ; and during their relaxation, the centre of the muscle is elevated, and the height of the vault increased in expiration, owing to the elasticity of the lungs, and the pressure of the viscera below, which are forced upwards by the action of the abdominal muscles (p. 442).

Use in respiration

In the descent of the diaphragm, the parts of the tendon move unequally, in consequence of differences in their relations, and in the length of the fleshy fibres connected with them. Thus, the central lobe, above which the heart is placed, moves least ; while the lateral lobes, which are below the lungs, descend more freely, the right, however, less than the left, owing to the presence of the liver. It is estimated that the central lobe of the tendon moves downwards in full inspiration about two-fifths of an inch, the right lobe twice as much, and the left lobe one inch (Hasse). In forced expiration the muscle reaches as high as the fourth rib on the right side, and the fifth on the left, close to the sternum.

Central part moves least ;

left part most. Average descent in full inspiration. Height in forced expiration.

With the movement of the diaphragm the size of the cavities of the abdomen and thorax will be altered. By its descent the thorax is enlarged, and the abdomen diminished ; and the viscera in the upper part of the latter cavity, viz., liver, stomach, and spleen, are partly moved from beneath the ribs. By its ascent the cavity of the thorax is lessened, and that of the abdomen is restored to its former size ; and the displaced viscera return to their usual place. By the contraction of the fibres the aperture for the œsophagus will be rendered smaller, and that tube may be compressed ; but the other openings for the vena cava and aorta are not materially changed.

Effect on thorax and abdomen, on viscera,

and on apertures.

The action of the diaphragm is commonly involuntary, but it is perfectly under the control of the will.

Action involuntary.

Dissection. After the diaphragm has been learnt, the ribs that support it on each side may be cut through, and the loose pieces of bone with the fore part of the diaphragm may be taken away, to facilitate the dissection of the deeper vessels and muscles. But the posterior third of the diaphragm, with its pillars and arches, should be left ; and the vessels ramifying on it should be followed back to their origin.

Take away greater part of the diaphragm.

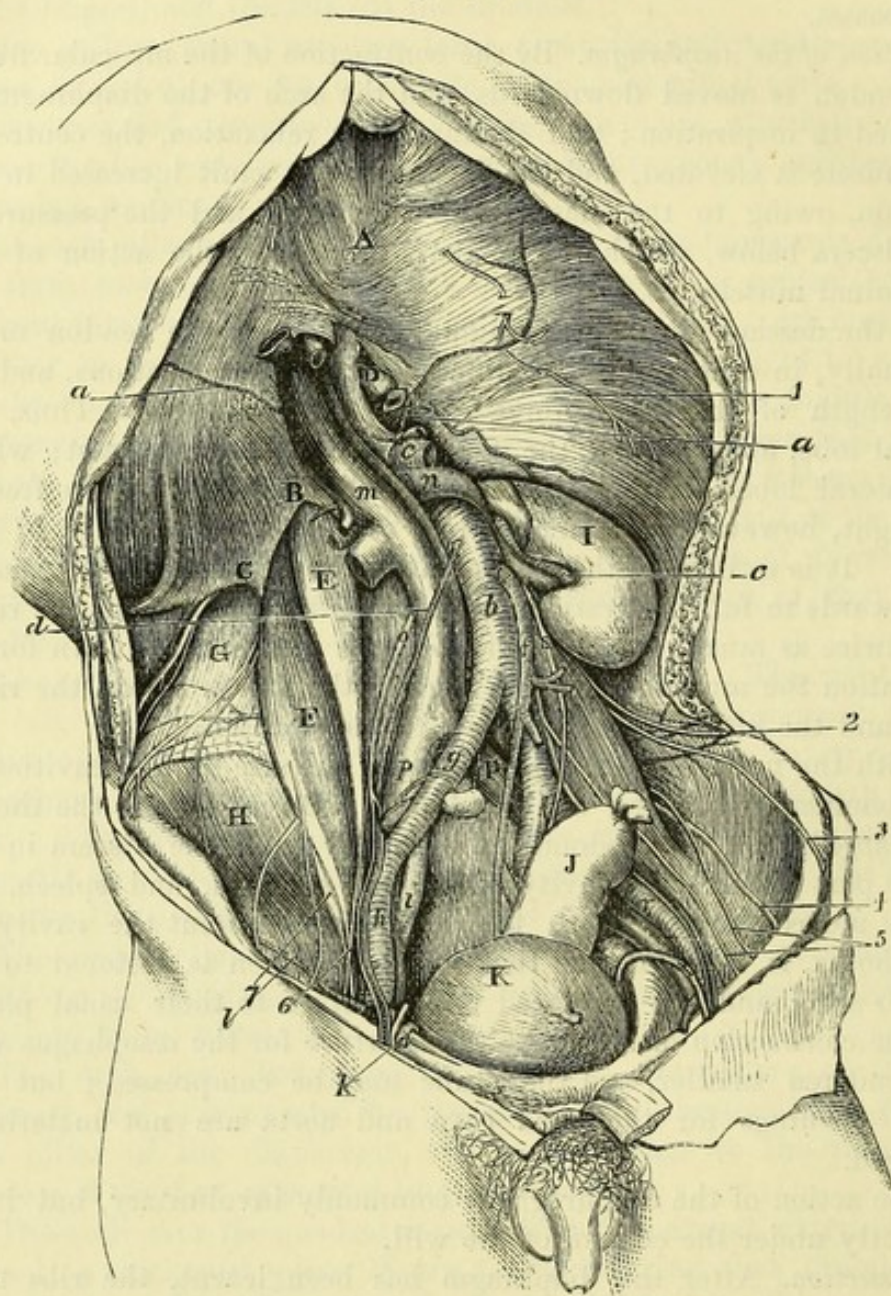
The large vessels of the abdomen, viz., the aorta and the vena cava, are to be cleaned by removing the fat, the remains of the sympathetic plexuses, and the lymphatic glands ; and their branches are to be followed to the diaphragm, to the kidney and suprarenal body, and to the testicle. In like manner the large iliac branches of the aorta and cava are to be laid bare as far as Poupart's ligament.

Clean aorta cava, and branches ;

also iliac vessels.

The ureter and the spermatic vessels are to be cleaned as they cross the iliac artery ; and on the same vessel, near the thigh, branches of a small nerve (genito-crural) are to be sought.

Fig. 166.*



* Deep view of the muscles, vessels, and nerves of the abdominal cavity (Illustrations of Dissections). *Muscles and viscera* : A. Diaphragm, with B, internal, and C, external arching ligament. D. End of the œsophagus, cut. E. Small psoas. F. Large psoas. G. Quadratus lumborum. H. Iliacus. I. Kidney. J. Rectum. K. Bladder. *Vessels* : a. Diaphragmatic artery. b. Aorta. c. Renal. d. Spermatic. e. Upper mesenteric, cut. f. Lower mesenteric. g. Common iliac, and h, external iliac artery. k. Epigastric artery, cut ; by its side is the vas deferens, bending into the pelvis. l. Circumflex iliac. m. Vena cava. n. Renal vein. o. Right spermatic vein. p. Common iliac vein, and r, external iliac (this letter is put on the left artery instead of the vein just below it). s. Ureter. *Nerves* : 1. Phrenic. 2. Ilio-hypogastric. 3. Ilio-inguinal. 4. External cutaneous of the thigh. 5 and 6. Genito-crural. 7. Anterior crural.

The muscles are to be laid bare on the right side, but on the left side the fascia covering them is to be shown; and the fat is to be cleared away from the kidney.

Dissect muscles;

The psoas muscle, the most internal, lies on the side of the spine, with the small psoas (if present) superficial to it. On its surface, and in the fat external to it, the following branches of the lumbar plexus will be found:—The genito-crural nerve lies on the front. Four other nerves issue at the outer border,—the ilio-hypogastric and ilio-inguinal near the top, the external cutaneous about the centre, and the large anterior crural at the lower part. Along the inner border of the psoas the gangliated cord of the sympathetic is to be sought, with a chain of lumbar lymphatic glands; and lower down the obturator nerve may be recognised entering the cavity of the pelvis. External to the psoas is the quadratus lumborum, and crossing the latter near the last rib is the last dorsal nerve, with an artery. In the hollow of the hip-bone is the iliacus muscle, which unites below with the large psoas.

psoas and nerves of lumbar plexus,

quadratus lumborum, and iliacus.

The ABDOMINAL AORTA (fig. 166, *b*) extends from the lower part of the last dorsal vertebra to about the middle of the body of the fourth lumbar vertebra, where it divides into the common iliac arteries. Its commencement is between the pillars of the diaphragm, and its termination is placed opposite a spot below and slightly to the left of the umbilicus, and nearly on a level with the highest point of the iliac crest.

Extent of abdominal aorta.

The chief relations of the vessel to surrounding parts have been before referred to (p. 484), but some deep vessels in connection with it now come into view. As the aorta rests on the spine it lies on the left lumbar veins, which end in the inferior cava. And between it and the right crus of the diaphragm are the large azygos vein and the thoracic duct. Along the sides of the vessel are the lumbar lymphatic glands, from which large vessels run beneath it to end in the beginning of the thoracic duct.

Relations

with deep vessels.

The *branches* of the aorta are numerous, and arise in the following order:—First, are the diaphragmatic arteries, two in number, which leave the front of the vessel immediately it appears in the abdomen. Close to the tendinous ring of the diaphragm, the single trunk of the cœliac axis arises from the front; and about a quarter of an inch lower down, also on the front, the trunk of the superior mesenteric artery begins. Half an inch lower, the renal arteries, right and left, take origin from the sides of the aorta. On the lateral part of the vessel, close above each renal, is the small capsular branch; and below the renal is the slender spermatic artery. From the front of the arterial trunk, one or two inches above the bifurcation, springs the inferior mesenteric artery. And from the back of the vessel arise five lumbar arteries on each side, and the middle sacral close above the bifurcation.

Place of origin of the branches;

The branches may be classified into two sets,—one to the viscera of the abdomen (visceral), and another to the abdominal wall (parietal).

their classification

The *visceral branches* are cœliac axis, superior and inferior mesen-

Some visceral branches.

teric, renal, capsular, and spermatic. Of these, the first three have already been examined.

Renal artery

The *renal arteries* (fig. 166, *c*) leave the aorta nearly at a right angle, and are directed outwards, one on each side. Near the kidney each divides into four or five branches, which enter the hilum of the organ between the vein and the ureter. Each artery lies beneath its companion vein, being surrounded by a plexus of nerves, and supplies small twigs to the suprarenal body (*inferior capsular*), to the ureter, and to the fatty layer about the kidney.

is beneath its vein ; gives off-sets ;

difference between left and right.

The arteries of opposite sides have some differences. The left is the shorter, owing to the position of the aorta : the right crosses the spine, and passes beneath the vena cava.

Capsular artery.

The *middle capsular* or *suprarenal artery* is a small branch which runs almost transversely outwards to the suprarenal body : this offset anastomoses with the other branches to the suprarenal body from the renal and diaphragmatic arteries. It is of large size in the fœtus.

Spermatic artery is remarkable ;

The *spermatic artery* of the testicle (fig. 166, *d*) is remarkable for its small size in proportion to its length ; for leaving the cavity of the abdomen ; and for having the part in the abdomen straight, but that in the cord tortuous.

course to the testicle ;

From its origin below the renal, the vessel passes downwards along the posterior wall of the abdomen to the internal abdominal ring, where it enters the spermatic cord (p. 452). In its course beneath the peritoneum the vessel runs along the front of the psoas, crossing over the ureter ; and on the right side it passes over the vena cava. It is accompanied by the spermatic vein, and the spermatic plexus of nerves. In the fœtus before the testicle leaves the abdomen the spermatic artery is very short, but the vessel elongates as the testis is removed from its original position.

condition in the fœtus :

in the female.

In the female the corresponding artery (*ovarian*) descends into the pelvis to end in the ovary and the uterus.

Branches to wall of abdomen.

The *parietal branches* of the aorta are the diaphragmatic, lumbar, and middle sacral.

Inferior phrenic :

The *diaphragmatic arteries* (inferior phrenic ; fig. 166, *a*) are frequently united together at their origin, or with the cœliac axis. They course upwards along the posterior part of the under surface of the diaphragm, the left artery passing behind the œsophageal opening, and the right behind the vena cava. Each ends in two branches :—One (internal) passes onwards towards the front of the diaphragm, and anastomoses with its fellow, and with the superior phrenic and musculo-phrenic branches of the internal mammary. The other (external) is larger, and is directed outwards to the side of the muscle, where it communicates with the intercostal arteries.

course of left and right ;

distribu- tion ;

small offsets.

Branches. Small offsets to the suprarenal body from the external division of this artery are named *superior capsular*. Some twigs are given by the left artery to the œsophagus, and by the right to the vena cava.

Other arteries to diaphragm.

On the under surface of the diaphragm are two branches of the

internal mammary artery (p. 259); one, *superior phrenic*, accompanies the phrenic nerve, and ramifies over the middle of the muscle; the other, *musculo-phrenic*, appears opposite the ninth cartilage, and supplies the upper costal slips of the diaphragm.

The other parietal branches, viz., lumbar and middle sacral, are not learnt in this stage: the former will be seen after the lumbar plexus (p. 537), and the latter in the pelvis (p. 561).

The COMMON ILIAC ARTERY (fig. 166, *g*) is directed downwards and outwards from the bifurcation of the aorta, and divides into two large trunks opposite the fibro-cartilage between the last lumbar vertebra and the sacrum;—one of these (external iliac) supplies the lower limb, and the other (internal iliac) enters the pelvis. Placed obliquely on the vertebral column, the vessel measures about two inches in length. It is covered by the peritoneum, and is crossed by branches of the sympathetic nerve, and sometimes by the ureter. It is accompanied by a vein of the same name. Usually it does not furnish any named branch, but it may give origin to the ilio-lumbar, or a renal artery. On opposite sides the vessels have some differences.

Common iliac artery:

extent and termination; relations;

usually no branches.

The *right artery* has the vena cava to its outer side above, and near its termination touches the psoas muscle. The companion vein (*p*) is at first beneath, but becomes external to the artery at the upper part; and beneath the right artery also is the left common iliac vein. The *left artery* is crossed by the superior hæmorrhoidal vessels; and its companion vein is situate to its inner side. It lies close to the psoas muscle throughout.

Differences between right

and left vessel.

The *length* of the common iliac artery ranges from less than half an inch to four inches and a half; but in the majority of instances it varies between one inch and a half and three inches (R. Quain).

Variations in length.

The EXTERNAL ILIAC ARTERY (fig. 166, *h*) is the first part of the vessel leading to the lower limb, and is contained in the cavity of the abdomen. Its extent is from the bifurcation of the common iliac to the lower border of Poupart's ligament, where it becomes femoral. And its direction would be indicated, on the surface of the abdomen, by a line from the left of the umbilicus to the middle of the space between the symphysis pubis and the front of the iliac crest.

External iliac leads to lower limb: extent and direction;

The vessel lies above the brim of the pelvis in its course to Poupart's ligament, and is covered closely by the peritoneum and the subperitoneal fat. The right artery is crossed by the lower end of the ileum, and the left by the sigmoid flexure. To its outer side is the psoas, except at its termination under Poupart's ligament, where it lies over the muscle. A chain of lymphatic glands is placed along the front and the inner side of the artery.

relations with parts around,

Near its origin the artery is crossed sometimes by the ureter; and near Poupart's ligament the vas deferens bends down along its inner side; while the spermatic vessels, and the genital branch of the genito-crural nerve lie on it for a short distance.

with other vessels, with nerve,

and veins.	The external iliac vein (<i>r</i>) is behind the artery above, but gradually comes forwards and gains its inner side over the pubis. The circumflex iliac vein crosses it nearly an inch above Poupart's ligament.
Two named branches :	<i>Branches.</i> Two branches, epigastric and circumflex iliac, arise about a quarter of an inch from the end of the artery, and are distributed to the wall of the abdomen (p. 453).
unnamed offsets.	Some small unnamed twigs are given to the psoas muscle and the lymphatic glands.
Origin of branches varies.	<i>Peculiarities in usual branches.</i> The epigastric and circumflex iliac branches may wander over the lower inch and a half or two inches of the artery.
Occasional branches from it.	<i>In unusual branches.</i> Though the trunk of the vessel is commonly free from any unusual branch, it may be occupied between the middle and the end by the obturator artery, or by the internal circumflex artery of the thigh.
Veins of the abdomen, except vena portæ.	ILIAC VEINS AND VENA CAVA (fig. 166). The larger veins of the abdomen correspond so closely with the arteries, both in number, extent, and relations, as to render unnecessary much detail in their description. As the veins increase in size from the circumference towards the centre of the body, those most distant from the heart will be first referred to.
Anatomy of external iliac vein :	The EXTERNAL ILIAC VEIN (<i>r</i>) is a continuation of the femoral vein beneath Poupart's ligament. It has an extent like the artery of the same name, and ends by uniting with the vein from the pelvis (internal iliac), to form the common iliac vein. On the pubis it is internal to its companion artery, and lies between the psoas and pectineus muscles ; but as it ascends it gradually passes behind the artery.
position to artery :	
tributaries.	The veins opening into it are the epigastric and circumflex iliac (p. 454), and a <i>pubic branch</i> from the obturator vein.
Common iliac veins form cava :	The COMMON ILIAC VEIN (<i>p</i>) ascends by the side of its accompanying artery, the right almost vertically, and the left obliquely, to the front of the body of the fifth lumbar vertebra (the right half), where it blends with its fellow in one trunk—the vena cava.
difference in length and relations :	The <i>right vein</i> is the shorter, and lies at first behind, but afterwards outside the artery of the same name. The <i>left</i> is internal to and below the artery of its own side, and crosses beneath the right common iliac artery.
tributaries.	Each vein receives the ilio-lumbar branch ; and the common iliac of the left side is joined by the middle sacral vein.
Vena cava inferior :	The INFERIOR OR ASCENDING VENA CAVA (<i>m</i>) collects and conveys to the heart the blood of the lower half of the body. Taking origin opposite the fifth lumbar vertebra, lower than the bifurcation of the aorta, this large vein ascends on the right side of the arterial trunk, and reaches the heart by perforating the diaphragm. Its relations to surrounding parts have been already noticed (p. 484), but the description may be again referred to, as the position of the branches of the aorta to it can be better seen now.
extent :	
relations :	
receives branches from abdomen,	<i>Branches.</i> The cava receives parietal branches (lumbar and diaphragmatic) from the wall of the abdomen and the diaphragm ; and

visceral branches from the testicle, the kidney, the suprarenal body, and the liver.

The veins belonging to the stomach, the intestinal canal, the spleen, and the pancreas, are united to form the vena portæ (p. 489); and the blood contained in those vessels reaches the cava by the hepatic veins, after it has circulated through the liver. except those of digestive apparatus.

The *spermatic vein* (*o*) enters the abdomen by the internal abdominal ring, after forming the spermatic plexus in the cord (p. 521). At first there are two branches in the abdomen, which lie on the sides of the spermatic artery; but these soon join into one trunk. On the left side it opens into the renal vein at a right angle, and there is generally a small valve over the aperture; on the right side it enters the inferior cava below the renal vein. As the vein ascends to its destination, it receives one or more branches from the wall of the abdomen, and the fat about the kidney. Spermatic vein ends differently on left and right sides; branches:

In the female this vein (*ovarian*) has the same ending as in the male, and it forms a plexus in the broad ligament of the uterus. Valves are absent from the vein and its branches, but commonly there is one at its union with the renal. vein in the female.

The *renal or emulgent vein* (*n*) is of large size, and joins the vena cava at a right angle. It commences by many branches in the kidney; and the trunk resulting from their union is superficial to the renal artery. Renal vein: position to artery;

The right vein is the shorter, and usually joins the cava a little lower than the other. The left vein crosses the aorta close to the origin of the superior mesenteric artery; it receives the left spermatic and suprarenal veins. difference on two sides.

The *suprarenal vein* is of considerable size when it is compared with the body from which it comes. The right opens into the cava, and the left into the renal vein. Suprarenal ends differently on each side.

The *hepatic veins* enter the vena cava where it is in contact with the liver. These veins are described in the dissection of the liver (p. 511). Hepatic veins, before noticed.

The *lumbar veins* correspond in number and course with the arteries of the same name: they will be dissected later (p. 538). Lumbar veins.

The *diaphragmatic veins* (inferior), two with each artery, spring from the under surface of the diaphragm. They join the cava either as one trunk or two. Phrenic veins.

DEEP MUSCLES OF THE ABDOMEN.

The deep muscles in the interior of the abdomen are the psoas, iliacus, and quadratus lumborum.

The *PSOAS MAGNUS* (fig. 166, F) reaches from the lumbar vertebræ to the femur, and is situate partly in the abdomen and partly in the thigh. Psoas magnus: situation;

The muscle *arises* from the front of the transverse processes of the lumbar vertebræ, from the bodies and intervertebral discs of the last dorsal and all the lumbar vertebræ by five fleshy pieces,— origin from lumbar vertebræ

each piece being connected with the intervertebral substance and the borders of two contiguous vertebræ, and from tendinous bands over the blood-vessels opposite the middle of the vertebræ. The fibres give rise to a roundish belly, which gradually diminishes towards Poupart's ligament, and ends below in a tendon on the outer aspect, which receives also most of the fibres of the iliacus, and passes beneath Poupart's ligament to be *inserted* into the small trochanter of the femur.

insertion
into femur;

relations
in front,

behind,

of outer
border,
of inner
border;

lumbar
nerves in its
substance;
use to bend
hip-joint
with iliacus,

or to bend
trunk on
the limb.

Psoas
parvus:
origin;

insertion;

use.

Iliacus has
the form of
the iliac
fossa;
origin;

insertion;

parts cover-
ing it on
two sides;
beneath it;

The abdominal part of the muscle has the following relations:—

In front are the internal arch of the diaphragm, the kidney with its vessels and duct, the spermatic vessels and the genito-crural nerve, and near Poupart's ligament, the ending of the external iliac artery: beneath these, the muscle is covered by the inner part of the iliac fascia. Behind, the muscle is in contact with the transverse processes, with the quadratus lumborum, and with the hip-bone.

The outer border touches the quadratus and iliacus; and branches of the lumbar plexus issue from beneath it. The inner border is partly connected to the vertebræ, and is partly free along the margin of the pelvis;—along the attached part of this border lies the sympathetic nerve, with the cava on the right, and the aorta on the left side; along the free or pelvic part are the external iliac vessels. The nerves of the lumbar plexus lie between the slips of origin from the transverse processes.

Action. If the femur is free to move it is raised towards the belly; and in flexing the hip-joint the psoas is always combined with the iliacus.

When the lower limbs are fixed the two muscles will draw forwards the lumbar part of the spine, and bend the hip-joints, as in stooping to the ground. One muscle under the same circumstances can incline the spine laterally.

The PSOAS PARVUS (fig. 166, E) is a small, inconstant muscle with a long tendon, which is placed on the front of the large psoas. Its fibres *arise* from the bodies of the last dorsal and first lumbar vertebræ, with the intervening fibro-cartilage. Its tendon becomes broader below, and is *inserted* into the ilio-pectineal eminence and the brim of the pelvis, joining the iliac fascia.

Action. This muscle aids in flexing the lumbar portion of the spine, either drawing forwards the upper part of the trunk, or raising the front of the pelvis, according to which end is fixed.

The ILIACUS MUSCLE (fig. 166, H) occupies the iliac fossa on the inner aspect of the hip-bone, and is blended inferiorly with the psoas. It is triangular in form, and has a fleshy *origin* from the iliac fossa, and slightly from the ala of the sacrum and the anterior sacro-iliac ligament. The fibres pass obliquely inwards to the tendon of the psoas, uniting with it even to its insertion into the femur; and a few have a separate attachment to the femur below the small trochanter.

Above Poupart's ligament the muscle is covered by the iliac fascia; and over the right iliacus is placed the cæcum, over the left, the sigmoid flexure. Beneath it are the hip-bone and the capsule of the

hip-joint. The inner margin is overlapped by the psoas ; and the anterior crural nerve lies between the two. The relations of the united psoas and iliacus below Poupart's ligament are given with the dissection of the thigh (p. 629).

Action. The iliacus raises the femur with the psoas when the limb is moveable, and bends forwards the pelvis when the limb is fixed. use to bend hip-joint.

The psoas and iliacus may be regarded as two heads of one muscle—the ILIO-PSOAS.

The QUADRATUS LUMBORUM (fig. 166, G) is a short, flattened muscle between the pelvis and the last rib. About two inches wide below, it arises from the ilio-lumbar ligament, and from the iliac crest behind, and an inch outside that band ; it generally receives in addition two or three slips from the transverse processes of the upper lumbar vertebræ. The fibres ascend to be inserted by distinct fleshy and tendinous slips into the apices of the transverse processes of the upper four lumbar vertebræ, and into the lower border of the last rib for a variable distance. Quadratus lumborum : origin ; insertion ;

This muscle is encased in a sheath derived from the fascia lumborum. Crossing the surface are branches of the lumbar plexus, together with the last dorsal nerve and its vessels. Behind the quadratus is the erector spinæ muscle. is contained in a sheath ;

Action. Both muscles keep straight the spine (one muscle antagonising the other) ; and by fixing the last rib they aid in the more complete contraction of the diaphragm. use of both muscles,

One muscle will incline laterally the lumbar region of the spine to the same side, and depress the last rib. of one.

Fascia of the quadratus. Covering the surface of the quadratus is a thin membrane, which is derived from the hinder aponeurosis of the transversalis abdominis (fascia lumborum ; p. 386) ; it passes in front of the quadratus to be fixed to the tips and borders of the lumbar transverse processes, to the ilio-lumbar ligament below, and to the last rib above. A thickened band of this fascia forms the external arched ligament, to which the diaphragm is connected (p. 524). Fascia of the quadratus.

Fascia of the iliacus and psoas. A fascia covers the double flexor of the hip-joint, and is fixed to the bone on each side of the muscle. The membrane is strongest opposite the pelvis, where it is attached to the iliac crest on the outer side, and to the brim of the cavity on the inner side : it receives a strong accession from the tendon of the psoas parvus when that muscle is present. Over the upper part of the psoas it becomes thin, and is fixed on the one side to the lumbar vertebræ ; while on the other it is blended with the fascia over the quadratus ; and above, it joins the internal arched ligament of the diaphragm. Its disposition at Poupart's ligament, and the part that it takes in the formation of the crural sheath, have been before explained (p. 463). Iliac fascia covers ilio-psoas : attachments below, and above.

Dissection. The student is now to clean the lymphatic glands lying along the vertebræ, and to trace upwards some lymphatic vessels to the thoracic duct. Trace the lymphatics,

and the
recepta-
culum, and

splanchnic
nerves.

Lumbar
lymphatic
glands :

ducts end in
one trunk.

Celiac
glands :

ducts join
those from
intestine.

Beginning
of the tho-
racic duct.

To show the origin of the duct, the diaphragm is to be divided over the aorta, and its pillars are to be thrown to the sides : a piece may be cut out of the aorta opposite the first lumbar vertebra. The beginning of the duct (*receptaculum chyli*), and the lower end of the large azygos vein may be well seen : and the two are to be followed upwards into the thorax.

On the left side the student may trace the splanchnic nerves and the small azygos vein through the pillar of the diaphragm, and may show the knotted cord of the sympathetic nerve entering the abdomen beneath the arch over the psoas muscle.

Lymphatic glands. A chain of glands is placed along the side of the external iliac artery, and along the front and sides of the lumbar vertebræ ; they are connected by short tubes, which increase in size and diminish in number, and opposite the first lumbar vertebra form one principal trunk which enters the thoracic duct. Into the glands the lymphatics of the lower limbs, and those of some of the viscera and of the wall of the abdomen are received.

Another cluster of large glands surrounds the celiac axis, and covers the upper end of the abdominal aorta. They are distinguished as the *celiac glands*, and receive the lymphatics of the stomach, spleen, pancreas and great part of the liver. Their ducts unite with those of the mesenteric glands, and give rise to one or more large trunks, which pass to the common thoracic duct.

Receptaculum chyli. The thoracic duct begins in the abdomen by the union of three or four large lymphatic trunks. Its commencement is marked by a dilatation, which is placed on the right side of the aorta, opposite the first or second lumbar vertebra. The duct enters the thorax by passing through the diaphragm with the aorta.

SECTION VI.

SPINAL AND SYMPATHETIC NERVES.

The spinal nerves of the loins enter into a plexus, and supply the limb and the contiguous portions of the trunk.

Dissection
of the lum-
bar plexus
on left side,

Dissection (fig. 167). The lumbar nerves and their plexus are to be learnt on the left side, although the woodcut shows them on the right side ; and to bring them into view, the dissector should cut through the external iliac vessels, and afterwards scrape away the psoas. For the most part the fleshy fibres may be removed freely ; but a small branch (accessory of the obturator) should be first looked for at the inner border of the muscle. On, or in the substance of, the quadratus lumborum a communication may be sometimes found between the last dorsal and the first lumbar nerve.

with sym-
pathetic.

The cord of the sympathetic nerve lies along the edge of the psoas, and offsets of it join the spinal nerves ; these are to be followed back along the lumbar arteries.

On the right side the psoas is to be left untouched, in order that the place of emergence from it of the different offsets of the plexus may be noticed.

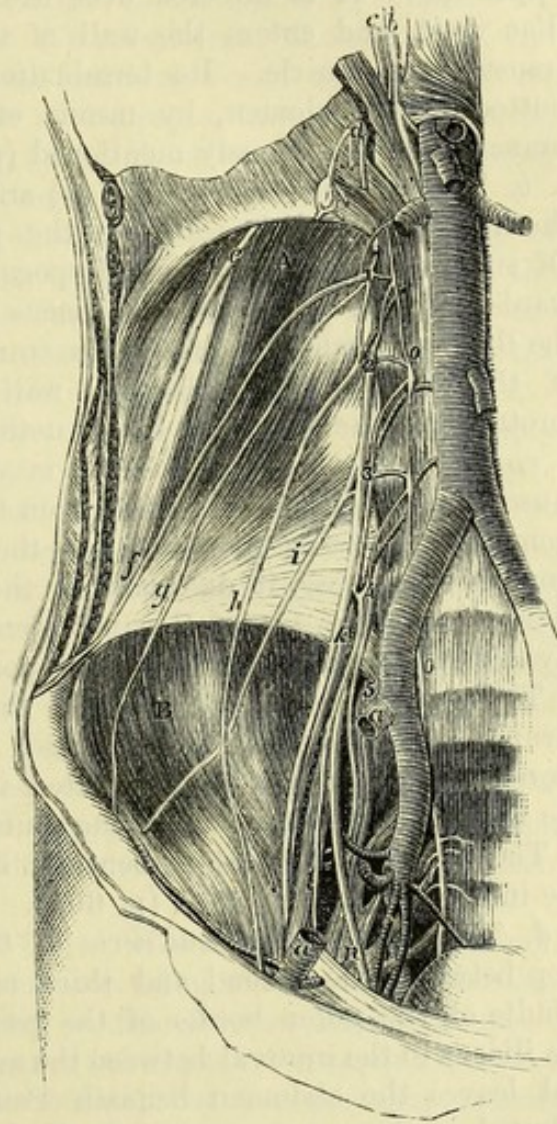
LUMBAR SPINAL NERVES. The anterior primary branches of the lumbar nerves enter the lumbar plexus, with the exception of the last. Five in number, they increase in size from above down, and are joined by filaments of the sympathetic near the intervertebral foramina. Before entering the plexus, they supply branches to the psoas and quadratus lumborum muscles.

The fifth nerve (fig. 173) receives a communicating branch from the fourth, and is to be followed into the pelvis to its junction with the sacral plexus. After the two are united, the name *lumbo-sacral cord* is applied to the common trunk.

The **LUMBAR PLEXUS** (fig. 167) is formed by the intercommunication of the first four lumbar nerves. Contained in the substance of the psoas, near the posterior surface, it consists of communicating loops between the several nerves, and increases in size from above downwards, like the individual nerves. Superiorly it is sometimes united by a small branch with the last dorsal nerve; and inferiorly it joins the sacral plexus through the large lumbo-sacral cord.

The *branches* of the plexus are six in number, and supply the lower part of the abdominal wall and the muscular covering of the

Fig. 167.*



and supply muscles :

fifth to the sacral plexus.

Plexus how formed ;

situation ;

connections with nerves.

Six branches, viz. :—

* Dissection of the lumbar plexus and its branches. (Illustrations of Dissections.) *a.* External iliac artery, cut across. *b.* Thoracic duct. *c.* Azygos vein. *Nerves:* The figures 1 to 5 mark the trunks of the five lumbar nerves. *d.* Splanchnic nerves. *e.* Last dorsal. *f.* Ilio-hypogastric. *g.* Ilio-inguinal. *h.* Genito-crural. *i.* External cutaneous. *k.* Anterior crural. *l.* Accessory to obturator. *n.* Obturator. *o.* Gangliated cord of the sympathetic.

spermatic cord, the fore and inner parts of the thigh, and the inner side of the leg.

Two cutaneous branches.

The first two branches (ilio-hypogastric and ilio-inguinal) end as cutaneous nerves of the buttock, the lower part of the abdomen, and the scrotum.

Ilio-hypogastric :

course in abdomen.

a. The *ilio-hypogastric branch* (fig. 167, *f*) is derived from the first nerve, and appears at the outer border of the psoas muscle, near the upper end. It is directed over the quadratus lumborum to the iliac crest, and enters the wall of the abdomen by piercing the transversalis muscle. Its termination in the integuments of the buttock and abdomen, by means of an iliac and a hypogastric branch, has been already mentioned (p. 450).

Ilio-inguinal arises with preceding,

and accompanies it.

b. The *ilio-inguinal branch* (*g*) arises with the preceding from the first nerve, and issues from the psoas nearly at the same spot. Of smaller size than the ilio-hypogastric, this branch courses outwards over the quadratus and iliacus muscles towards the front of the iliac crest, where it pierces the transversalis. The farther course of the nerve in the abdominal wall, and its distribution to the scrotum and the groin, are before noticed (p. 450).

Genito-crural

pierces psoas,

and divides into

genital and

c. The *genito-crural nerve* (*h*) is distributed to the cremaster muscle and the limb. It arises from the second lumbar nerve, and from the connecting loop between the first two; issuing from the front of the psoas, it descends on the surface of the muscle, and divides into the two following pieces. Sometimes the nerve is divided in the psoas, and the pieces perforate the muscle separately.

The *genital branch* descends on the external iliac artery, and furnishes offsets around it: it passes from the abdomen with the spermatic vessels, and is distributed in the cremaster muscle. In the female the nerve is lost in the round ligament.

crural branch.

The *crural branch* issues beneath Poupart's ligament to supply the integument of the thigh (p. 603).

Course of external cutaneous

to the thigh.

d. The *external cutaneous nerve* of the thigh (*i*) arises from the loop between the second and third nerves, and appears about the middle of the outer border of the psoas. The nerve then crosses the iliacus to the interval between the anterior iliac spinous processes, and leaves the abdomen beneath Poupart's ligament, to be distributed on the outer aspect of the limb (p. 603).

Origin of anterior crural ;

position in the abdomen ; its branches

to iliacus,

to femoral artery.

Obturator

e. The *anterior crural nerve* (*k*) is the largest offset of the plexus, and supplies branches mainly to the extensor muscles of the knee-joint, and to the integuments of the front of the thigh and inner side of the leg. Taking origin from the second, third and fourth nerves, this large trunk appears towards the lower part of the psoas, where it lies between that muscle and the iliacus. It passes from the abdomen beneath Poupart's ligament ; but before the final branching in the thigh (p. 622), the nerve sends off the following twigs :—

Some small *branches to the iliacus* are furnished from the outer side of the nerve.

A *branch to the femoral artery*, the place of origin of which varies much, is distributed around the upper part of that vessel.

f. The *obturator nerve* (*n*) is distributed chiefly to the adductor

muscles of the thigh (p. 625). Arising in front of the anterior crural from the second, third, and fourth nerves in the plexus (sometimes not from the second), it makes its appearance at the inner border of the psoas near the sacro-iliac articulation. Escaped from beneath the muscle, the nerve crosses the side of the pelvis below the external iliac, but above the obturator vessels, and enters the thigh through the aperture at the top of the thyroid foramen. Occasionally the obturator gives origin to the following branch :—

The *accessory obturator nerve* (*l*) arises from the trunk of the obturator, or from the third and fourth nerves of the plexus. Its course is along the inner border of the psoas, beneath the investing fascia, and over the hip-bone to the thigh, where it ends by joining the obturator nerve, and supplying the hip-joint (p. 625).

GANGLIATED CORD OF THE SYMPATHETIC. The lumbar part of the gangliated cord of the sympathetic is placed on the front of the spinal column (fig. 167, *o*) : it lies along the inner border of the psoas muscle, and is somewhat concealed on the right side by the vena cava, on the left by the aorta. The cord possesses four or five oval ganglia opposite the bodies of the vertebræ, which supply connecting and visceral branches.

Connecting branches. From each ganglion two small branches are directed backwards along the centre of the body of the vertebra, with the lumbar artery ; these unite with one or two spinal nerves near the intervertebral foramen. The connecting branches are long in the lumbar region, in consequence of the gangliated cord being carried forwards by the psoas muscle from the intervertebral foramina.

Branches of distribution. Most of the internal branches throw themselves into the aortic and hypogastric plexuses, and so reach the viscera indirectly. Some filaments enter the vertebræ and their connecting ligaments.

LAST DORSAL NERVE (fig. 167, *e*). The anterior primary branch of the last dorsal resembles the intercostal nerves in its distribution, but differs from them in not being contained in an intercostal space. Lying below the last rib, the nerve is directed outwards across the upper part of the quadratus lumborum, but beneath the external arched ligament and the fascia of the quadratus. At the outer border of that muscle it perforates the middle layer of the fascia lumborum, and enters the wall of the abdomen, where it ends in an abdominal and a lateral cutaneous branch (p. 450). The first lumbar artery accompanies it.

Near the spine it furnishes a small branch to the quadratus muscle ; and it may communicate by means of this with the first lumbar nerve.

The **LUMBAR ARTERIES** of the aorta (p. 527) are furnished to the back, the spinal canal, and the wall of the abdomen : they resemble the aortic intercostals in their course and distribution. Commonly five in number on each side, they arise from the back of the aorta, and the vessels of opposite sides are sometimes joined in a common trunk. They then pass backwards over the hollowed surface of the

in the
abdomen ;

ends in the
thigh ;

occasionally
an accessory
branch.

Sympathetic
cord in the
abdomen
joins that
in thorax ;

has four or
five ganglia ;

branches to
the spinal
nerves,

and to the
viscera.

Last dorsal
nerve :

course to
wall of the
abdomen ;

branch to
muscle.

Lumbar
arteries
five in num-
ber on each
side :

course ;

bodies of the last dorsal and upper four lumbar vertebræ, and beneath the pillar of the diaphragm and the psoas, to reach the interval between the transverse processes, where each ends in an abdominal and a dorsal branch. The arteries of the right side lie beneath the vena cava.

The *posterior* or *dorsal branches* continue to the back between the transverse processes, and supply offsets to the spinal canal (pp. 398, 414).

The *anterior* or *abdominal branches* are directed outwards, and enter the posterior part of the abdominal wall, where they are distributed (p. 453). The first lies with the last dorsal nerve across the front of the quadratus lumborum, but the others usually pass behind that muscle. Offsets are furnished to the psoas and quadratus muscles, and to the subperitoneal fat; the last anastomose with branches of the renal, capsular, spermatic, right and left colic, and some other visceral arteries.

The LUMBAR VEINS are the same in number, and have the same course as the arteries. Commencing by the union of a dorsal and an abdominal branch at the root of the transverse process, each trunk is directed forwards to the vena cava. They open into the back of the cava, either singly, or conjointly with those of the opposite side. On the left side the veins are longer than on the right, and pass beneath the aorta.

Around the transverse processes, and beneath the psoas muscle, the lumbar veins communicate freely with one another, with the ilio-lumbar, and with the common iliac, so as to form a plexus of veins. Issuing above from the plexus is a branch, the *ascending lumbar vein*, which joins the azygos vein of the corresponding side of the body.

Beginning of the azygos veins. The azygos vein begins on each side about the first lumbar vertebra by the above-mentioned ascending lumbar vein; and it is often joined by a branch of communication with the inferior cava or the renal vein. The *right vein* enters the thorax usually with the thoracic duct and the aorta, to the right of which it lies. The *left vein* passes through the pillars of the diaphragm, or sometimes through the aortic opening.

The anatomy of these veins is given at p. 365.

CAVITY OF THE PELVIS.

THE cavity of the pelvis is the part of the general abdominal space situate below the brim of the true pelvis (p. 466). Definition and situation.

Boundaries. The space is surrounded by the firm ring of the pelvic bones : it is bounded behind by the sacrum and coccyx, with the pyriformes muscles and the sacro-sciatic ligaments ; and laterally and in front, by the hip-bones covered by the internal obturator muscles. Boundaries ; behind and before ;

Inferiorly, or towards the perineum, the cavity is limited by the fascia reflected from the wall to the viscera, and by the levatores ani and coccygei muscles : it is only in this direction, where the bounding structures are to some extent moveable, that the size of the space can be appreciably altered. below.

Contents. In the pelvis are contained the urinary bladder with the beginning of the urethra, the lower end of the large intestine or the rectum, and some of the generative organs, according to the sex. The viscera are supplied with vessels, nerves, and lymphatics ; and the serous membrane is reflected over them. Contents.

SECTION I.

PELVIC FASCIA AND MUSCLES OF THE OUTLET.

Lining the wall of the pelvis is a thin fascia (pelvic), which covers the obturator internus and pyriformis muscles, and sends a process inwards to support the viscera. Outline of the fascia of the pelvis.

Dissection. To bring into view the pelvic fascia, the external iliac vessels, and the psoas (if this has not been removed in the dissection of the lumbar plexus), are to be taken away on the left side of the body. The obturator vessels and nerve are to be cut through on the same side ; and the peritoneum being detached from the wall of the pelvis, the fascia will be seen on scraping away with the handle of the scalpel a quantity of fat. By this proceeding the membrane is dissected in its upper half, or as low as the situation of the portion (recto-vesical) which is directed inwards to the viscera. Steps to define the pelvic fascia : in the pelvis,

To display the lower half, the student must raise the outlet of the

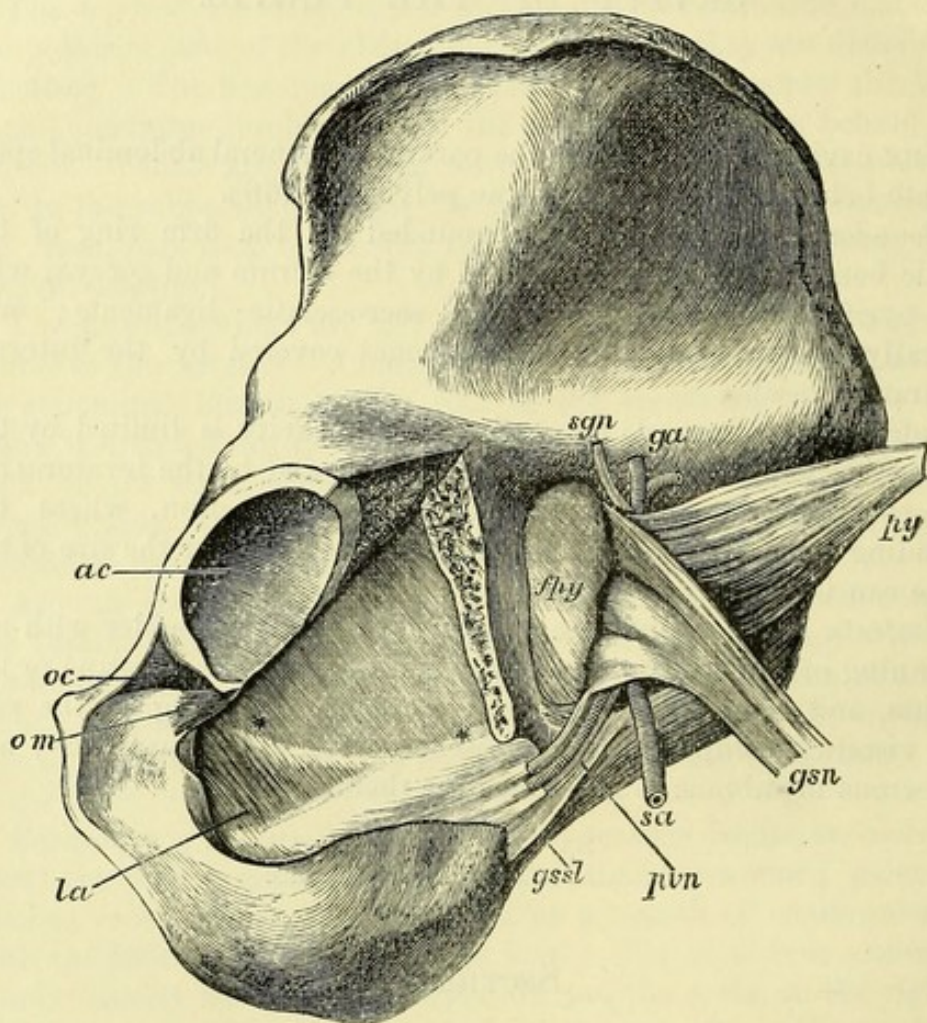
and the
perineum ;

pelvis ; and, should the perineum be undissected, the fat must be taken from the ischio-rectal fossa. The lower part of the pelvic fascia will now appear on the outer side of that fossa, as it covers the obturator muscle.

from outer
side ;

To see the outer surface of the fascia (fig. 168), the obturator externus muscle and the obturator membrane should be removed,

Fig. 168.*



with the exception of a small portion of the latter at the upper end of the thyroid foramen, where it bounds the aperture through which the vessels and nerve issue. A portion of the bone is then to be cut out behind the foramen, and extending into the small sciatic

* Dissection of the pelvic fascia (from a drawing by C. F. Beadles). *ac*. Acetabulum. *oc*. Aperture of canal for obturator vessels and nerve, bounded below by *om*, the upper end of the obturator membrane, the greater part of which has been taken away. Below these, the fascia of the obturator internus is exposed by the removal of a portion of the bone and the muscle. **. Line along which the recto-vesical fascia is given off from the inner side of the obturator fascia. *la*. Tendinous fibres of origin of the levator ani, showing through the obturator fascia. *fpv*. Fascia of the pyriformis. *sgn*. Superior gluteal nerve. *ga*. Gluteal artery. *py*. Pyriformis muscle. *gsn*. Great sciatic nerve. *sa*. Sciatic artery. *pvn*. Pudic vessels and nerve, entering the sheath in the obturator fascia. *gssl*. Great sacro-sciatic ligament.

notch, as in the figure ; and the obturator internus muscle is to be carefully separated from the fascia and taken away.

Lastly, by turning back the pyriformis muscle and the great sciatic nerve, a thin piece of the fascia covering those structures will be exposed in the great sacro-sciatic foramen (*fpv*). and over pyriformis.

The PELVIC FASCIA is a thin membrane which covers the deep surface of the muscles bounding the cavity, and may be described in three parts. Two of these line the wall of the pelvis,—one covering the obturator internus muscle is named the obturator fascia, and the other extending over the pyriformis muscle is the fascia of the pyriformis ; while the third enters into the formation of the floor of the cavity, and supports the rectum and bladder, whence it is known as the recto-vesical fascia. Pelvic fascia divided into three parts, viz. :—

The *obturator fascia* (fig. 168) invests closely the pelvic portion of the obturator internus muscle, and is fixed to the bone around the attachment of the fleshy fibres. Thus, it is attached above to the ilio-pectineal line of the hip-bone between the sacro-iliac articulation and the upper end of the thyroid foramen ; at the latter spot it joins the obturator membrane over the edge of the muscle, so as to form the floor of the canal transmitting the obturator vessels and nerve ; and in front it is fixed to the body of the pubis, following the border of the muscle. Below, it is inserted into the inner side of the inferior ramus of the pubis, and the ramus and tuberosity of the ischium in conjunction with the falciform process of the great sacro-sciatic ligament. Behind, the membrane is fixed to the hip-bone along the anterior margin of the great sciatic notch ; and between the ischial spine and tuberosity it is united with the great sacro-sciatic ligament, where the obturator internus issues from the pelvis. Obturator fascia :
attach-
ments ;

From the inner surface of this membrane the recto-vesical fascia is given off, along a curved line extending from the ischial spine to the upper and inner part of the thyroid foramen (fig. 168, * *). Above this line the obturator fascia bounds the cavity of the pelvis, and is in contact with the peritoneum ; while below, it looks into the ischio-rectal fossa, except over a small space in front, where it is closely united with the pubic origin of the levator ani (*la*). relations.

The *fascia of the pyriformis* (*fpv*) is very thin, and is continued backwards from the hinder part of the obturator fascia to the sacrum, passing over the front of the sacral plexus and the pyriformis muscle, but beneath the internal iliac vessels, by the gluteal, sciatic and pudic branches of which it is perforated. Fascia of pyriformis.

The *recto-vesical fascia* may now be seen in part by looking into the pelvis ; and the student may notice a whitish line extending from the lower part of the pubis, close to the symphysis, to the ischial spine. This line corresponds in its hinder part to the origin of the recto-vesical fascia from the obturator fascia ; but in front, the levator ani extends upwards between the two. The disposition of this part of the fascia will be better seen after the hip-bone has been taken away. Recto-vesical fascia later.

To remove
hip-bone :
detach
fascia,
saw bone,

and divide
soft parts.

Then blow
up bladder
and distend
other parts.

Outlet of
pelvis is
closed by

pyriformis,
by coccy-
geus and
sacro-sciatic
ligament,

with vessels
and nerves,

by levator
ani,

and by
triangular
ligament.

Coccygeus :
origin :

insertion :

relations of
surfaces

and borders ;

use.

Dissection. To obtain a side-view of the pelvis (fig. 169), it will be necessary to remove the left hip-bone. The obturator fascia and great sacro-sciatic ligament are first to be detached, and then the bone is to be sawn through, in front about three-quarters of an inch outside the symphysis pubis, and behind at the articulation with the sacrum. After the bone has been pulled somewhat away from the rest of the pelvis, the ischial spine, with the recto-vesical fascia attached to it, may be cut off with a bone-forceps ; and the loose piece may then be removed by cutting through the fibres of the iliacus and pyriformis muscles, and any other structure that may retain it.

A block is afterwards to be placed beneath the pelvis. The bladder is to be moderately distended with air through the ureter, and the urethra is to be tied. Some tow is to be introduced into the rectum, also into the vagina if it is a female pelvis ; and a small piece is to be placed in the pouch of peritoneum between the bladder and the rectum. After the viscera are thus made prominent without distension, the ischial spine and the recto-vesical fascia should be raised with hooks while the levator ani (D) and coccygeus (C) muscles below it are cleaned.

Parts closing the pelvis below. In addition to the recto-vesical fascia, the following parts close the pelvic cavity on each side, between the sacrum and the pubic symphysis.

Behind, the student will meet with the pyriformis passing through the great sacro-sciatic foramen, with the gluteal vessels and nerve (fig. 168, *ga* and *sgn*) above it. Next comes the coccygeus muscle (fig. 169, *c*) on the small sacro-sciatic ligament, between the ischial spine and the coccyx ; one border of the muscle is contiguous to the pyriformis, the other to the levator ani ; and between its upper border and the pyriformis lie the great sciatic and pudic nerves (^{1, 2, 3}), with some other branches of the sacral plexus, and the sciatic and pudic vessels. The greater part of the pelvic outlet is closed by the levator ani, (D) which extends forwards from the coccygeus to the symphysis pubis. It meets its fellow behind, but the muscles of opposite sides are separated in front by the urethra, with the vagina in the female ; and the interval between them is closed by the triangular ligament of the perineum (H).

The COCCYGEUS MUSCLE (fig. 169, *c*) is flat and triangular, and has much tendinous substance mixed with its fibres. It *arises* from the upper part of the ischial spine, and some fibres are attached to the adjoining part of the obturator fascia. Widening as it passes inwards, the muscle is *inserted* into the side, and the contiguous anterior surface of the coccyx, and into the side of the lowest piece of the sacrum.

The inner surface looks to the pelvis, and is in contact with the rectum : the opposite surface is in great part covered by the small sacro-sciatic ligament, to which it is closely united. The upper border is contiguous to the pyriformis muscle, vessels and nerves intervening ; and the lower meets the levator ani.

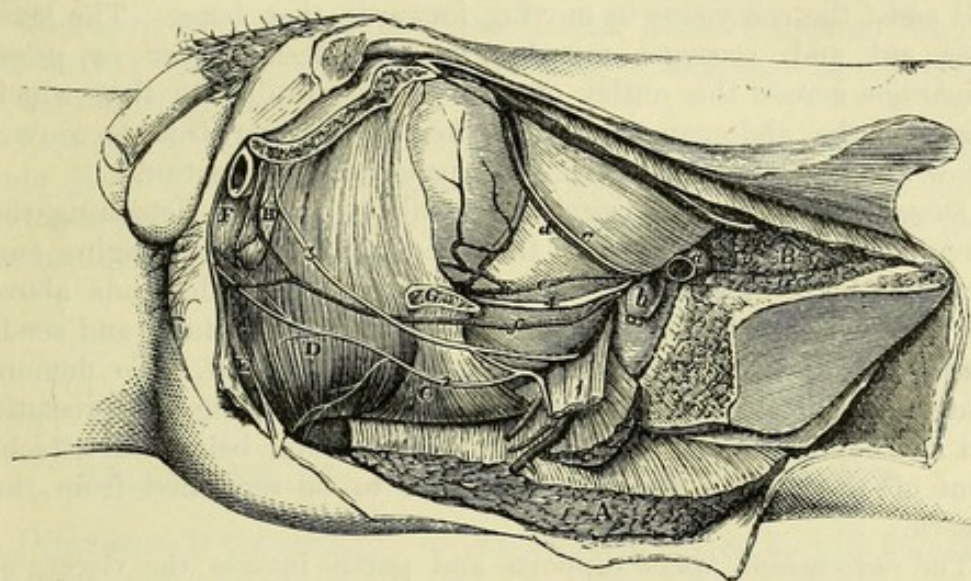
Action. This muscle helps the levator ani in supporting and

raising the floor of the pelvis : it may also draw the coccyx slightly forwards.

The LEVATOR ANI (fig. 169, D) is a thin flat muscle, which is attached above to the side of the pelvis, and descends into the outlet of the cavity, where it joins its fellow and supports the viscera.

It arises anteriorly by tendinous fasciculi from the back of the pubis along an oblique line in front of the obturator internus ; and

Fig. 169.*



below this some fleshy fibres often spring from the upper surface of the triangular ligament. Posteriorly it is attached to the lower and inner part of the ischial spine ; and between the osseous attachments the muscle takes origin in the angle between the obturator and recto-vesical portions of the pelvic fascia (along the curved line * * in fig. 168). From this wide origin the fibres converge, the anterior being directed backwards, and the posterior downwards and inwards, to be inserted in the following manner :—The most anterior fibres, few in number, join with the muscle of the opposite side in the central point of the perineum ; the succeeding fibres, which arise from the pubis, are the longest, and pass backwards over the prostate to the side of the rectum, where they mix with the fibres of the sphincter muscles ; and the posterior fibres meet the opposite muscle in a narrow aponeurosis behind the gut, and are attached in part to the side of the coccyx (p. 420).

The anterior fibres of the levator are in contact with the triangular perineal ligament ; and there is an interval between the two

* Side view of the muscles in the outlet of the pelvis (Illustrations of Dissections). Muscles : A. Gluteus maximus, cut. B. Ilio-psoas, cut. C. Coccygeus. D. Levator ani. E. External sphincter. F. Ejaculator urinæ. G. Ischial spine, cut off. H. Triangular ligament. Arteries : a. External iliac artery, cut, with b, its accompanying vein. c. Obliterated hypogastric. d. Upper, and e, lower vesical. f. Internal pudic. Nerves : 1. Great sciatic. 2. Inferior hæmorrhoidal and perineal of pudic. 3. Dorsal nerve of penis.

muscles which allows the urethra, with the vagina in the female, to pass from the pelvis. The posterior border is adjacent to the coccygeus muscle. The upper surface is in contact with the recto-vesical fascia; and the under surface looks to the ischio-rectal fossa, and is covered by the thin anal fascia.

Action. The levatores ani acting together support and raise the floor of the pelvis, and compress the pelvic viscera. They are used in expelling the contents of the abdomen, and in forcible expiratory efforts, acting then in conjunction with the muscles of the abdominal wall. The hindmost fibres, which are fixed to the coccyx, will assist the coccygeus in moving forwards that bone. The levatores ani and coccygei muscles form a fleshy layer or *pelvic diaphragm* across the outlet of the pelvis, similar to that which separates the abdomen from the chest: this partition is convex below and concave above, and gives passage to the rectum.

Dissection. The recto-vesical fascia will be seen by detaching the fibres of the levator ani and the coccygeus at their origin, and throwing both downwards. The thin membrane descends above the levator ani to the side of the bladder and the rectum, and sends downwards sheaths round the prostate and the gut. To demonstrate those sheaths, one incision is to be made along the prostate, and another along the lower end of the rectum, below the attachment of the fascia; and the tubes are to be separated from the viscera.

The *recto-vesical fascia* supports and partly invests the viscera of the pelvis. Covering the pelvic surface of the levator ani, it is fixed above, like that muscle, to the pubis in front, and to the obturator fascia at the side; while behind, it is continued over the coccygeus muscle into the fascia of the pyriformis. Below, it meets the fascia of the opposite side in the centre of the pelvis, and forms a partition across the cavity, like that of the levator ani, which is perforated by the bladder and the rectum. The partition is strengthened on each side by a thicker band (the so-called *white line of the pelvic fascia*) stretching from the pubis to the ischial spine (p. 541). It is concave above and convex below, and divides the cavity of the pelvis from the perineal space. This septum is attached to the viscera which pierce it, forming ligaments for them; and from the under surface tubes are prolonged on the rectum and the prostate.

The sheath on the rectum encloses the lower three inches of the intestine, and gradually becomes very thin towards the anus; between it and the intestine are interposed the branches of the upper hæmorrhoidal vessels with a layer of fat.

On the prostate the sheath is thinner than on the rectum, and very closely adherent; it is continued downwards to the apex of that body, where it passes into the upper layer of the triangular ligament of the urethra: between it and the substance of the prostate are a plexus of veins and some small arteries.

In the female the fascia has much the same arrangement as in the male; but the vagina perforates the membrane, and receives a tube from it, like the prostate.

and
surfaces;

use,
on pelvic
floor,
on cavity of
abdomen,
on coccyx.

Pelvic dia-
phragm.

Dissection
for recto-
vesical
fascia.

Recto-vesi-
cal fascia:

attach-
ments;

forms the
floor of
the pelvis;

supports
viscera;

prolonga-
tions are,
sheath on
the rectum,

and on
prostate

Fascia in
the female.

The *true ligaments of the bladder* are two on each side, anterior and lateral, and are portions of the recto-vesical fascia. Ligaments of the fascia :

The *anterior* reaches from the back of the pubis to the fore part of the prostate and the neck of the bladder ; it is a narrow white band, and encloses muscular fibres of the bladder. anterior ligaments,

The *lateral ligament* is the side piece of the fascia, which is fixed to the upper border of the prostate gland, and to the side of the bladder close above the vesicula seminalis ; from it an offset is continued inwards behind the vesicula seminalis, so as to join a like piece from the other side, and form a sheath for those bodies. and lateral of the bladder ;

There are other ligaments of the bladder (false ligaments), which are derived from the peritoneum investing it, and will be described in the following SECTION.

Ligament of the rectum. On each side of the rectum is a strong wide piece of the recto-vesical fascia, which is attached externally to the ischial spine of the hip-bone, and supports that viscus like the bladder. ligament of rectum.

SECTION II.

RELATIONS OF THE VISCERA IN THE MALE.

Directions. If the student dissects a female pelvis, he will find the description of it at page 552.

Contents and position (fig. 170). The viscera of the male pelvis are—the rectum, the bladder with the prostate and first part of the urethra, the lower ends of the ureters, part of the vasa deferentia, and the vesiculæ seminales. These have the following relative situation :— Contents of the pelvis,

The rectum (*k*) lies at the back of the pelvis, and takes a curved course in the hollow of the sacrum and coccyx. The bladder (*a*) is placed in the concavity of the rectum, its neck being surrounded by the prostate gland (*b*) ; and the urethra, after perforating the last, curves forwards to the penis. The ureter (*h*) descends by the side of the rectum to the hinder part of the bladder ; and the vas deferens (*f*) and vesicula seminalis (*g*) are between the bladder and rectum on each side. Some of these organs are partly invested by peritoneum. and outline of their position.

Dissection. All the recto-vesical fascia, except the anterior true ligament of the bladder, may be taken from the prostate and rectum. The obliterated hypogastric cord from the internal iliac artery should be followed forwards along the bladder from the back of the pelvis ; and the branches of the same artery to the bladder should be cleaned. When the fat has been cleared from the rectum, without injuring its arteries, the pouch of the peritoneum, in which tow has been placed, will be brought into view, with the ureter (*h*) passing to the bladder across its side. Take away fascia, and clean vesicels.

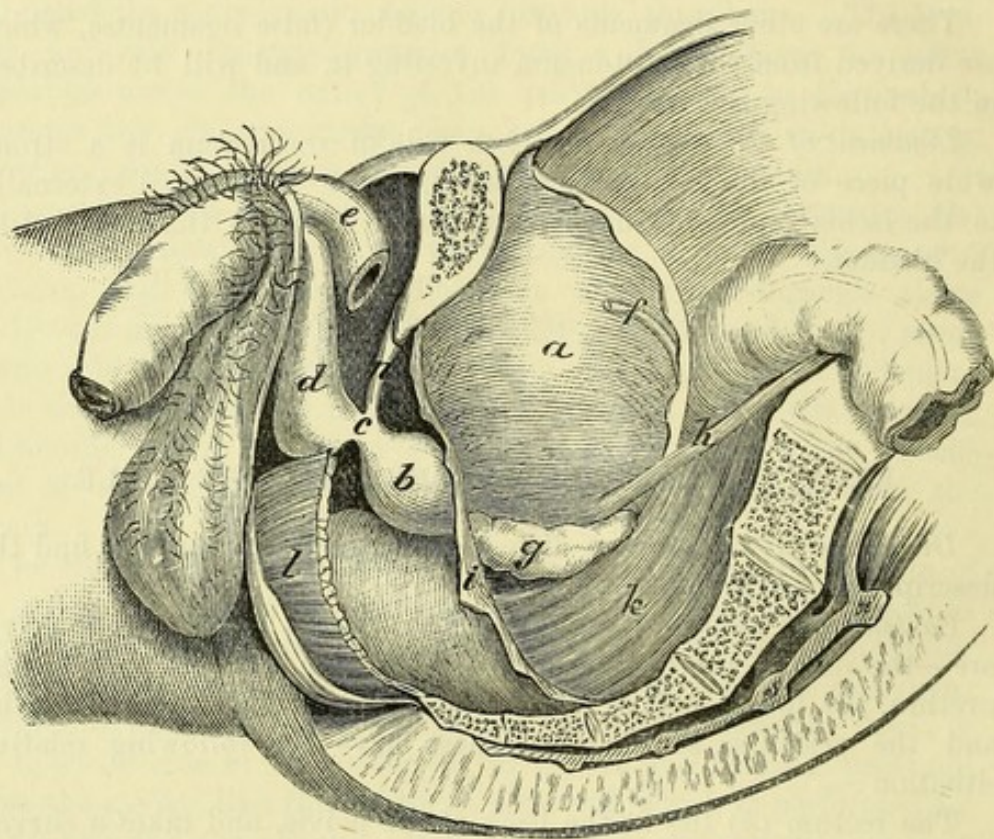
The bladder below the peritoneum is to be cleaned ; and the vas deferens (*f*) is to be followed down to the seminal sac. The several viscera are to be cleaned.

with care the remains of the sheath of the vesicula seminalis, defining at the same time the vas deferens internal to the latter.

The peritoneum covers partly the rectum ;

The PERITONEUM does not envelop the viscera in the pelvis so completely as in the upper part of the abdomen. After surrounding the upper portion of the rectum, and forming a fold (*mesorectum*) behind it, the membrane covers the upper surface of the bladder, and projects for some way between the two viscera, thus giving rise to the recto-vesical pouch (fig. 145, *rvp*): on each

Fig. 170.*



and partly the bladder, leaving front and lower part free.

Pouch between the rectum and bladder :

extent and distance from anus vary.

side of the pouch the serous membrane is raised into a ridge or slight fold by the obliterated hypogastric artery. From the summit and sides of the bladder it is reflected to the wall of the pelvis and abdomen. All the front and lower part of the bladder are therefore uncovered by peritoneum ; and when the bladder is distended it rises above the pubic bones, so as to allow of its being opened in front without injury to the serous membrane.

The *recto-vesical pouch* is wide above, where it corresponds with the interval between the iliac arteries, and is narrow below between the rectum and bladder. It descends slightly into the interval between the vesiculæ seminales, and ends usually at a line joining the spots where the ureters enter the wall of the bladder. The extent downwards of the pouch varies greatly with the condition of

* Side view of the dissected male pelvis. *a.* Urinary bladder. *b.* Prostate. *c.* Membranous part of the urethra. *d.* Spongy part of the urethra. *e.* Crus penis, divided. *f.* Vas deferens. *g.* Vesicula seminalis. *h.* Ureter. *i.* Recto-vesical fascia. *k.* Rectum. *l.* Levator ani, cut.

the bladder and the rectum, the place of reflection being lower when those organs are empty, and rising when they are distended. With the bladder and rectum moderately filled, the end of the pouch is commonly about one inch and a half from the tip of the coccyx, and three inches (or the length of the fore finger) from the anus.

False ligaments of the bladder. These are parts of the continuous sheet of peritoneum reflected from the bladder to the pelvic and abdominal wall. Five ligaments are described, viz., two posterior, two lateral, and one superior. False ligaments of bladder :

The *posterior false ligament* (one on each side) reaches from the upper and hinder part of the bladder to the front of the sacrum, and forms the side-wall of the recto-vesical pouch. Beneath it are the internal iliac vessels, the obliterated hypogastric artery, the ureter, and the pelvic plexus of the sympathetic. posterior ;

The *lateral false ligament* (also one on each side) is the widest, and is reflected from the side of the bladder to the iliac fossa and the wall of the pelvis. It is separated from the posterior and superior ligaments by the obliterated hypogastric artery. lateral ;

The *superior false ligament* is the portion of peritoneum between the two obliterated hypogastric arteries, reflected from the upper surface of the bladder over the urachus to the anterior abdominal wall. superior

The RECTUM, or last part of the great intestine (fig. 170, *k*), extends from the brim of the pelvis, near the sacro-iliac articulation of the left side, to the anus, and is about eight inches long. The bowel has a sinuous course, for it first follows the curve of the sacrum and coccyx, and then inclines backwards to the anus ; and it is supported mainly by the peritoneum, the recto-vesical fascia, and the perineal muscles. For convenience of description it is divided into three parts :— Rectum :
extent and
length ;
course and
supports ;
divisions.

The *upper portion*, longer than the others, extends to the centre of the third piece of the sacrum. It is almost entirely surrounded by peritoneum, which forms a distinct fold, or *meso-rectum*, between its upper end and the front of the sacrum, so that some degree of movement from side to side is permitted. Behind it are the sacrum, with the pyriformis muscle and sacral plexus of the left side ; and the left ureter and internal iliac vessels are adjacent to it, but separated by the peritoneum.* First part
most
covered by
peritoneum,
and move-
able ;
relations.

The *middle portion* lies behind the bladder, and reaches to the tip of the coccyx ; it is about three inches in length, and is covered by peritoneum in front for about the upper half of its extent. Immediately below this it pierces the recto-vesical fascia, and receives its sheath from that membrane. Resting on it is the triangular part of the bladder, with the vesiculæ seminales and vasa deferentia ; and beneath it are the sacrum and coccyx. On each side is the coccygeus muscle. Second part
is fixed ;
relations.

The *lower portion* is about an inch and a half long, and is curved Third part is
largest ;

* In some bodies the first part of the rectum is much curved to the right side ; and occasionally this piece of the intestine lies altogether on the right of the sacrum, the lower end of the left colon crossing the spine at the brim of the pelvis.

from the tip of the coccyx to the anus: at first it is dilated, but at the anus it is contracted. This end of the intestine is without peritoneal covering, and is supported by the triangular ligament of the urethra, and by the levatores ani and external sphincter muscles.

relations
with parts
around;

sometimes
much
dilated.

Bladder is
in pelvis
when empty,

and projects
above when
full.

Axis.

Position in
pelvis varies
with age.

Apex has
three cords
from it.

Base:
parts in
contact
with it.

Surfaces:
inferior,

superior

In front of the extremity of the rectum are the prostate, the membranous part of the urethra, and the bulb of the corpus spongiosum urethræ; but as the gut recedes from the urethra there is an angular interval left between the two. The levatores ani muscles descend on its sides, and unite beneath it, supporting it in a sling; and the sphincter muscles surround the aperture. Sometimes the end of the intestine within the anus is very much enlarged, especially in women and old men; and in that condition in the male it rises up on each side of the prostate.

The URINARY BLADDER (*vesica urinaria*; fig. 170, *a*) is the receptacle for the urine, and is situate in the fore part of the pelvis.

When the bladder is contracted it is flattened, and of a triangular form, and lies against the anterior wall of the pelvis; but when distended it becomes rather egg-shaped, with the larger part towards the rectum, and the apex to the abdominal wall. In distension during life it is slightly curved forwards over the pubic bones, and projects above them; and if its axis were prolonged, it would touch the abdominal wall anteriorly a variable distance (according to the distension) above the pubic symphysis, and the lower end of the sacrum posteriorly.

The position and form of the bladder are not the same in early life as in the adult. For in the child this viscus rises much above the brim of the pelvis into the hypogastric region of the abdomen, and the part near the neck is elongated. But in the adult the bladder is for the most part contained within the space enclosed by the pelvic bones, and the base projects backwards.

The organ is maintained in position by the recto-vesical fascia and the peritoneum, which form its ligaments (pp. 545 and 547). The relations of the moderately full bladder are as follows:—

The *summit* or *apex* is rounded, and from it three ligamentous cords are prolonged to the umbilicus; the central one of these is the urachus; and the two lateral are the obliterated hypogastric arteries. All the surface behind the obliterated vessels is covered by peritoneum.

The *base* or *fundus* is large, and rests against the middle piece of the rectum. Connected with the fundus are the vesiculæ seminales and the vasa deferentia; and between these is a *triangular space*, from which the peritoneum is mostly absent. The ureter opens into the upper part of the base on each side.

Surfaces of the body. The *inferior* or *pubic surface* of the body is in contact with the pubic bones and anterior true ligaments, as well as with the abdominal wall if the bladder is very full, and is altogether free from peritoneum. The *superior* or *abdominal surface* is entirely covered by the serous membrane, and has the small intestine and

sigmoid flexure resting on it: the vas deferens courses over the hinder part of this surface beneath the peritoneum.

Extending along the upper part of each lateral region is the and lateral obliterated hypogastric artery, which marks the extent of the peritoneal covering at the side. The surface below this is connected with the pelvic fascia by very loose areolar tissue.

The *neck* (cervix) is the part of the bladder near the urethra, and Neck. is surrounded by the prostate gland. This is the lowest part of the organ.

When the bladder is empty, the upper wall falls upon the lower; Condition of empty bladder. the apex lies at the upper end of the pubic symphysis; and the base is of very small extent and looks downwards. In a vertical section the cavity then appears as a slit, which is continued backwards for a short distance beyond the beginning of the urethra.

The URETER (fig. 170, *h*) crosses the common or the external iliac Ureter in pelvis, artery, and inclines forwards below the level of the obliterated hypogastric artery, being covered by the peritoneum constituting the posterior false ligament of the bladder. It enters the bladder at the upper and outer part of the base, at the distance of one inch and a enters bladder. half or two inches from the prostate gland.

The PROSTATE GLAND (fig. 170, *b*) surrounds the neck of the Prostate: bladder. Its shape is conical with the base turned upwards, and position; its size about equals that of a large chestnut. In the present form; position of the pelvis, a line from the apex through the middle of axis; the gland would be directed obliquely backwards and slightly downwards towards the sacrum; but in the erect state of the body the axis is nearly vertical.

The *anterior surface* is about three-quarters of an inch from the relations of anterior surface, symphysis pubis, to which it is attached by the anterior true ligaments of the bladder. On this surface the dorsal vein of the penis divides to enter the prostatic plexus. The *posterior surface* has the posterior surface, greatest extent, and is close to the rectum; this is the part that is and side; felt by the finger introduced into the bowel through the anus. On each side the prostate is covered by the levator ani.

The *apex* rests on the upper surface of the triangular ligament; apex and base; and the *base* surrounds the neck of the bladder and the common seminal ducts.

The prostate is enveloped by a sheath obtained from the rectovesical fascia (p. 544), and the prostatic plexus of veins surrounds it. Through the gland the urethra takes its course to the perineum; it is contained in a sheath; and the common seminal ducts pierce it obliquely to open into the urethra (fig. 177, *f*). The size of the prostate varies much; and in size may increase. old men it may acquire a considerable magnitude.

The VESICULÆ SEMINALES (fig. 170, *g*) are two small sacculated Seminal vesicles: bodies, each about two inches long, between the base of the bladder and the rectum. Each is pyramidal in form, and has the larger end turned upwards towards the ureter, while the smaller touches the their relations, prostate. Along the inner side is the vas deferens. At the prostate gland the vesiculæ approach one another, only the vasa deferentia intervening; but higher up they diverge, and enclose

with the pouch of the peritoneum the *triangular space* at the base of the bladder. The vesiculæ are contained in a membranous sheath, which is derived from the recto-vesical fascia, and is lined by involuntary muscular fibres.

Vas deferens : The VAS DEFERENS or the excretory duct of the testis (fig. 170, *f*) in its course to the urethra enters the abdomen by the internal abdominal ring, and crossing the obliterated hypogastric artery, is directed downwards along the hinder part of the bladder to the base of the prostate, where it forms the common seminal or ejaculatory duct by joining with the duct from the vesicula seminalis. The position of this tube to the external iliac artery has been noticed ; on the bladder it passes internal to the ureter and the vesicula of the same side. By the side of the vesicula the duct is much enlarged, and is sacculated.

Urethra : The URETHRA is the excretory passage for the urine and semen (fig. 170), and reaches from the bladder to the end of the penis. **length ;** In length it measures about eight inches, and it presents one or **curves ;** two curves according to the state of the penis. At first the canal is directed downwards and forwards through the triangular ligament of the perineum to the root of the penis, forming a large curve with the concavity to the pubis. Thence to its termination the urethra is contained in the penis ; and while this body remains pendent the canal forms a second bend with the concavity downwards ; but if **division.** the penis is raised the tube makes but one curve. The canal is divided into three parts,—prostatic, membranous, and spongy.

Prostatic. The *prostatic part* (*b*) is contained in the prostate gland, and receives its name from that circumstance. Its length is about one inch and a quarter, and in the erect posture of the body it descends nearly vertically to the triangular ligament.

Membranous : The *membranous part* (*c*), about three-quarters of an inch long, intervenes between the apex of the prostate and the lower surface of the triangular ligament. It slants forwards in the erect posture to the lower part of the triangular ligament ; and as the bulb of the next portion of the urethral tube is directed backwards below it, the under surface measures only half an inch.

relations. This division of the urethra is the weakest ; but it is supported by the triangular ligament (*n*). Surrounding it are the muscular fibres of the constrictor urethræ ; and close behind it are Cowper's glands and the rectum.

Spongy. The *spongy part* (*d*) is so named from its being surrounded by a cellulo-vascular structure. It is applied to and assists to form the body of the penis, and terminates anteriorly in the orifice named *meatus urinarius* at the end of the glans. It is the longest part of the urethra, and measures about six inches. At its commencement this division of the excretory canal is covered by the ejaculatoriæ muscle (fig. 133).

Fixed curve of urethra : The *curve of the urethra* is the fixed bend at the hinder part of the canal which lies behind the pubis. It extends from the bladder to an inch and a half in front of the aperture in the triangular ligament, and comprises the prostatic and membranous portions, **extent ;**

with a fourth of the spongy part. Its convexity, which is turned downwards and backwards, is greatest immediately below the triangular ligament in the erect posture of the body ; and from this point it ascends to the bladder, but is directed nearly horizontally forwards to the penis.

It is surrounded by voluntary and involuntary muscular fibres : thus, above the ligament, by the involuntary muscular tissue of the prostate ; within the ligament by the voluntary constrictor urethræ, with a thin involuntary layer inside that muscle ; and below the ligament by the voluntary ejaculator urinæ.

Its size is smallest where the tube pierces the perineal ligament (*n*), and lies between the layers ; and it is largest in the middle of the prostate.

Dissection. The tegumentary covering of the penis may be completely removed, to see the components of that body ; and after its removal the spongy part of the urethra will be better seen. The skin should be replaced after the penis has been learnt.

The PENIS is attached to the fore part of the pelvis, and hangs in front of the scrotum. It is constructed of two firm fibrous bodies (fig. 170, *e*) named *corpora cavernosa*, which are filled with an areolar structure containing blood. Below these is a soft spongy substance (*corpus spongiosum*) which surrounds the urethra, and forms the head or the glans penis. The tegumentary investment, which covers the whole, is noticed at p. 439.

The *body* of the penis is rather prismatic in shape. The upper surface is slightly grooved along the middle line ; and the lower rounded border is formed by the corpus spongiosum, which is received into a larger groove between the corpora cavernosa. Besides the attachment of the corpora cavernosa to the bone, the body of the penis is connected with the front of the symphysis pubis by the suspensory ligament (p. 439).

The *corpus spongiosum urethræ* encloses the urethral canal beyond the triangular ligament, and forms the head of the penis. It is a vascular and erectile texture, like the corpora cavernosa, but is much less strong. Commencing posteriorly by a dilated part—the bulb, it extends forwards around the urethra to the extremity of the penis, where it swells into the conical glans penis.

The *bulb* (fig. 170, *d*) is directed backwards below the membranous part of the urethra, and is firmly united to the under surface of the triangular ligament. The ejaculator urinæ muscles cover it. This enlargement presents usually a slight central depression, with a bulging on each side, forming two lateral lobes.

The *glans penis* (fig. 178, *l*) is somewhat conical in form, and covers the truncated ends of the corpora cavernosa. Its base is directed backwards, and is marked by a slightly prominent border—the *corona glandis* ; it is sloped obliquely along the under aspect, from the apex to the base. In the apex is the vertical slit (*meatus urinarius*), in which the urethral canal terminates ; and below that aperture is an excavation, which contains the fold of skin named *frænum præputii*.

where
greatest.

Voluntary
and invol-
untary
muscles
surround it.

Size.

Dissection.

Consti-
tuents and
situation of
the penis :

form and
attachment.

Corpus
spongiosum

surrounds
urethra, and
swells into

the bulb,

which is
bilobate,

and the
conical
glans penis

SECTION III.

RELATIONS OF THE VISCERA IN THE FEMALE.

Contents of
the female
pelvis,

In the pelvis of the female are contained the rectum and the bladder, with the ureters and urethra, as in the male ; but there are in addition the uterus with its accessories, and the vagina.

and their
situation.

Position. The rectum is posterior to the rest as in the male pelvis, and forms a like curve. In the concavity of the bent intestine lie the uterus with its appendages, and the tube of the vagina. And in front of all are the bladder and the urethra. Thus, there are three tubes connected with the viscera in this sex, viz., the urethra, the vagina, and the rectum ; and all are directed downwards to the surface.

Use descrip-
tion of male
pelvis for
muscles
and
fasciæ.

Directions. The description in SECTION I (p. 539) is to be used for instructions respecting the removal of the hip-bone, and the distension of the viscera ; also for the muscles of the pelvic outlet and the anatomy of the fasciæ. After the student has learnt the muscles and the fascia (p. 541), which are nearly alike in both sexes, he may make the following special dissection of the viscera of the female pelvis.

Then clean
the viscera
of the female
pelvis.

Dissection. On taking away the recto-vesical fascia and much fat, the viscera will come into view. To maintain the position of the uterus, raise it up with a piece of string passed through the upper end. The reflections of the peritoneum on the viscera are to be preserved ; and a piece of cotton-wool is to be placed between the rectum and the uterus.

The obliterated cord of the hypogastric artery is to be followed on the bladder ; and the ureter is to be traced forwards by the side of the uterus to the bladder. Afterwards the urethra, the vagina, and the rectum are to be cleaned and separated a little from one another at the lower part of the pelvis ; but the arteries on the rectum are to be preserved.

Reflections
of the peri-
toneum.

The PERITONEUM gives a partial covering to the viscera, as in the male pelvis. Investing the upper part of the rectum, and forming behind it the meso-rectum, the membrane is continued to the back of the vagina and uterus. It covers the posterior, and most of the anterior surface of the uterus, and can be traced to the bladder without again touching the vagina : on each side of the uterus it forms a wide fold (broad ligament), which attaches that viscus to the wall of the pelvis. As the peritoneum is followed forwards it may be observed to cover the upper surface of the bladder, and the lateral surface above the position of the obliterated hypogastric artery.

In the pelvis the serous membrane forms the following ligaments for the uterus and bladder.

Broad liga-
ment of the
uterus,

The *broad ligament of the uterus* (fig. 171) passes from the side of the uterus to the wall of the abdomen, and supports that organ. By its position across the pelvis, it divides the cavity into an

anterior and a posterior space : in the former the bladder is placed ; in the latter the upper part of the rectum, the small intestine, and the sigmoid flexure when it reaches the pelvis.

Each ligament shows traces of a subdivision into three pieces, which is subdivided into three parts. corresponding with the bodies contained between its two layers. Thus, there is a posterior piece belonging to the ovary and its ligament (L) ; an anterior, near the upper edge, which contains the round ligament (N) ; and a middle piece, the highest of all, enclosing the Fallopian tube (M).

Anterior and posterior ligaments of the uterus. As the peritoneum is reflected from the rectum to the uterus, and from the uterus to the bladder, it forms two anterior and two posterior folds or ligaments. The anterior or *vesico-uterine* pair is smaller than the posterior or *recto-uterine*. Anterior and posterior ligaments of uterus.

The *recto-uterine pouch*, also called *recto-vaginal*, corresponds with the recto-vesical in the male. On each side it is bounded by the obliterated hypogastric artery ; and below, it reaches beyond the uterus, so as to touch the back of the vagina. Recto-uterine pouch.

The *vesico-uterine pouch* is between the uterus and bladder, and is much smaller than the foregoing. Vesico-uterine pouch.

The *false ligaments of the bladder* are five in number, the same as in the male, viz., two posterior, two lateral, and a superior : they are all parts of one large piece of peritoneum that reaches from the bladder to the side and front of the pelvis. The posterior ligaments, containing the vessels of the bladder, are identical with the vesico-uterine folds, and are much smaller than in the male. Five ligaments of the bladder.

The RECTUM (fig. 171, K) is not so curved in the female as in the male, and is generally larger. Descending along the middle of the sacrum and coccyx to the anus, the intestine is divided into three parts :— Relations of the rectum viz.

The *upper portion* ends over the third piece of the sacrum, and is enveloped by the peritoneum : its relations are similar to those of the rectum in the male (p. 547). of first,

The *middle portion* reaches to the tip of the coccyx, and has the vagina in front, and in contact with it. The peritoneum extends on the front for a short distance. second,

The *lower piece* curves to the anus away from the vagina so as to leave between the two a space which corresponds, on the surface of the body, with the perineum between the anus and the vulva. The levatores ani are on the sides, and unite below it, and the sphincter muscles surround the extremity. and third part

The UTERUS (fig. 171, O) is rather pyriform in shape, and flattened from before backwards. Unless enlarged, it lies below the brim of the pelvis, between the bladder and the rectum ; and it is supported by the ligaments. Its wider end is free and placed upwards ; and the lower end communicates with the vagina. Uterus : form and situation ;

The axis of the uterus may be said to correspond generally with that of the inlet of the pelvis ; but the position of the organ is subject to considerable variation, and is especially influenced by the state of the bladder. The fundus is commonly directed forwards, position and direction vary ;

and the anterior surface rests against the bladder; but sometimes the organ is more upright, or even inclined backwards, and then the small intestine descends into the vesico-uterine pouch.

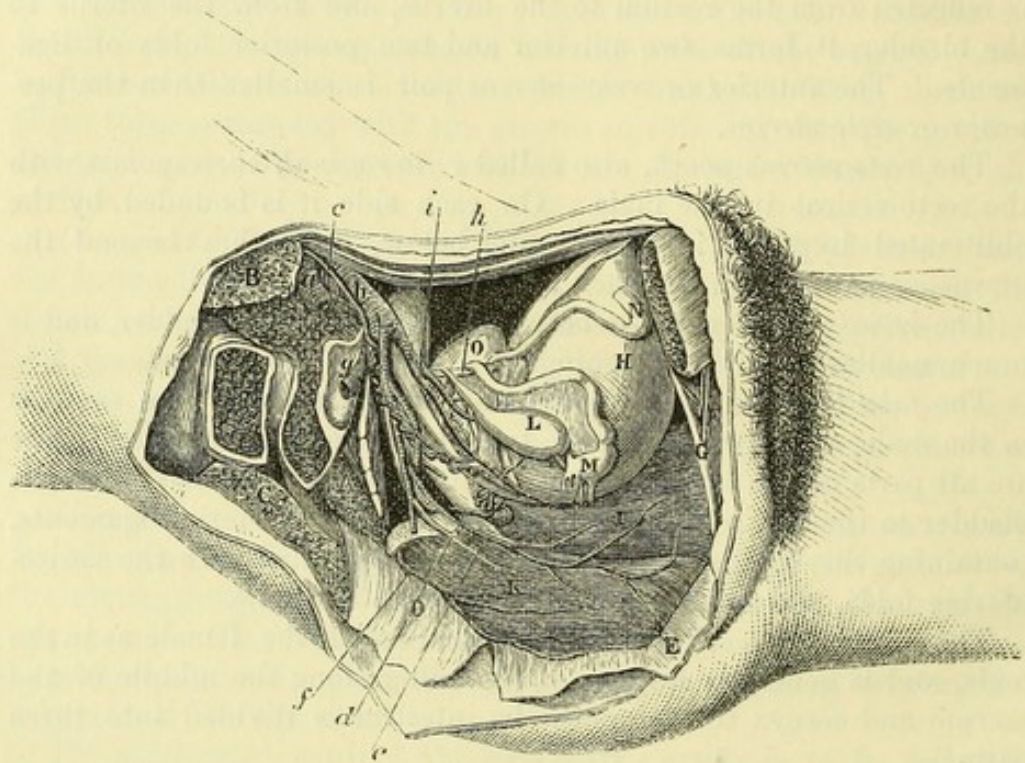
relations of
surfaces,

The *anterior surface*, somewhat flattened, is covered by peritoneum, except in the lower fourth where it is in contact with the bladder. The *posterior surface*, rounded, is invested altogether by the serous membrane.

extremities,

The *upper end* or *fundus* is the largest part of the organ, and is in

Fig. 171.*



contact with the small intestine. The *lower end* or *neck* (cervix) is received into the vagina.

and side.

To each *side* are attached the broad ligament with the Fallopian tube, the round ligament, and the ovary.

Round
ligament.

The *round* or *suspensory ligament* (N) is a fibrous cord about five inches long, which is directed forwards and outwards to the internal abdominal ring, and then through the inguinal canal to end in the groin. This cord lies over the obliterated hypogastric, and the external iliac artery; and it is surrounded by the peritoneum, which accompanies it a short way into the canal.

Fallopian
tube.

The *FALLOPIAN TUBE* (M), about four inches long, is contained in

* Side view of the female pelvis. (Illustrations of Dissections.) *Muscles and Viscera*: A. Pyriformis muscle, cut. B. Large psoas, cut. c. Gluteus maximus, cut. d. Coccygeus, and E. Levator ani, thrown down. f. Sphincter vaginae. g. Urethra. h. Urinary bladder. i. Vagina. k. Rectum. l. Ovary and its ligament. m. Fallopian tube. n. Round ligament. o. Uterus. *Arteries*: a. External iliac. b. Internal iliac. c. Ovarian. d. Uterine. e. Vaginal. f. Upper hæmorrhoidal. g. Gluteal, cut. h. Obliterated hypogastric. i. Vesical.

the upper or free border of the broad ligament. One end is connected to the uterus close to the fundus, while the other is folded round the ovary. At the uterine end the tube is of small size, but at the opposite extremity it is dilated like a trumpet, and fringed, forming the *corpus fimbriatum*: one of the fimbriæ is attached to the upper part of the ovary.

The OVARY (L) is oval in form, but rather flattened, and very variable in size. It forms a projection at the back of the broad ligament, and is invested by the peritoneum except along one (the attached) border. In the natural condition it lies nearly vertically against the side wall of the pelvis, and is embraced by the outer part of the Fallopian tube: the direction of its free border varies. Its lower end, which is directed somewhat forwards, is attached to the uterus by a special fibrous band, about one inch and a half in length, the *ligament of the ovary*. Ovary,
and its
ligament.

The VAGINA (fig. 171, I) is the tube by which the uterus communicates with the exterior of the body. It is compressed from before back; and its length is about three inches. As it follows the bend of the rectum, it is slightly curved; and its axis corresponds below with that of the outlet, but higher up with that of the cavity of the pelvis. Vagina:
extent and
form;
length;
axis;

In front of the vagina are the base of the bladder, and the urethra; and behind it is the rectum, but the peritoneum intervenes between the two for a short distance at the upper end. It is transmitted through an opening in the recto-vesical fascia, which sends a sheath along the lower half of the tube; and the levator ani lies along the side external to this. The upper end receives the neck of the uterus by an aperture in the anterior wall; and the lower end, the narrowest part of the canal, is encircled by the sphincter vaginae muscle. A large plexus of veins surrounds the vagina within its sheath. In children, and in the virgin, the external aperture is partly closed by the hymen (p. 432). relations.

The BLADDER (fig. 171, H) is placed at the fore part of the pelvis, in front of the vagina, and in contact with the back of the pubic bones. Its position and relations so closely resemble those of the bladder in the male body, as to render unnecessary a separate description of them (p. 548). The chief differences in the bladder of the two sexes are the following:— Bladder
resembles
that of the
male;

In the female the bladder is more globular than in the male, and the transverse often exceeds the vertical measurement. The base is of less extent, and is in contact with the vagina and the neck of the uterus. The vasa deferentia, vesiculæ seminales, and prostate are absent. differences
in the two
sexes.

The URETER has a longer course in the female than in the male pelvis before it reaches the bladder. After crossing the internal iliac vessels, it passes by the neck of the uterus to its destination. Course of
ureter.

The URETHRA (fig. 171, G) is about one inch and a half long, and by its position corresponds to the prostatic and membranous portions of the male passage, although it represents only the upper half of the prostatic urethra. It is situate in front of the vagina, Urethra:
length;
position and
course;

and describes a slight curve, with the concavity forwards, below the symphysis pubis. Its external opening (*meatus urinarius*) is placed within the vulva (p. 432).

relations. In its course to the surface it is embedded in the tissue of the vaginal wall, and perforates the triangular ligament of the perineum, where it is surrounded by fibres of the deep transverse muscle, and a layer of circular involuntary fibres (p. 434). A plexus of veins surrounds the urethra as well as the vagina.

SECTION IV.

VESSELS AND NERVES OF THE PELVIS.

Vessels and nerves of the pelvis. In the pelvis are contained the internal iliac vessels and their branches to the viscera, the sacral plexus of nerves, and the sympathetic nerve. This section is to be used by the dissectors of both the male and female pelvis.

Directions. The internal iliac vessels are to be dissected on the right side. The air should be previously let out of the bladder; and this viscus and the rectum, with the uterus and the vagina in the female, should be drawn aside from their situation in the centre of the pelvis.

To dissect the vessels of the pelvis, *Dissection.* The loose tissue and fat are to be removed from the trunks of the vessels, as well as from the branches of the artery that leave the pelvis, or supply the viscera; and the cord of the obliterated hypogastric artery is to be traced on the bladder to the umbilicus.

nerves, With the vessels are offsets of the hypogastric plexus of nerves, though these will probably not be seen; but in dissecting the vessels to the bladder and rectum, branches of the sacral spinal nerves will come into view. The veins may be removed in a general dissection.

When the vessels are prepared the bladder may be again distended, and the viscera replaced.

Internal iliac artery: The INTERNAL ILIAC ARTERY (fig. 172, *g*) is one of the trunks resulting from the division of the common iliac artery, and furnishes branches to the viscera and wall of the pelvis, to the organs of generation, and to the limb.

size and length; In the adult the vessel is a short trunk of large capacity, which measures from an inch to an inch and a half in length. Directed downwards towards the great sacro-sciatic foramen, the artery terminates generally in two large pieces, from which the several offsets are furnished. From the extremity a partly obliterated vessel (hypogastric) extends forwards on the bladder.

relations; The artery is covered by the peritoneum, and the ureter crosses its upper end obliquely on the inner side. It lies on the sacrum and lumbo-sacral cord. It is accompanied by the internal iliac vein, which is posterior to it, and somewhat to its inner side.

position of vein;

The *branches* of the artery are numerous, and arise usually in the following manner:— From the posterior piece of the trunk three arise, viz., the ilio-lumbar, lateral sacral, and gluteal. And from the anterior portion come the upper vesical, lower vesical (vaginal in female), middle hæmorrhoidal, obturator, sciatic, and pudic; and in the female also the uterine artery.

Artery in the fœtus. In the fœtus the *hypogastric artery* takes the place of the internal iliac, and leaves the abdomen by the umbilicus. At that time it is larger than the external iliac artery; and, entering but slightly into the cavity of the pelvis, it is directed forwards to the bladder, and along the side of that viscus to the apex.

Beyond the bladder the artery ascends along the posterior aspect of the abdominal wall with the urachus, converging to its fellow. Finally, at the umbilicus, the vessels of opposite sides come in contact with the umbilical vein, and, passing from the abdomen through the aperture at that spot, enter into the placental cord, where they receive the name *umbilical*.

In the fœtus, branches similar to those in the adult are furnished by the artery, though their relative size at the two periods is very different.

Change to adult state. When uterine life has ceased, the hypogastric artery shrinks in consequence of the arrest of the current of blood through it, and finally becomes obliterated, more or less completely, to within an inch or so of its commencement. The part of the trunk which is unobliterated becomes the internal iliac; and commonly a portion of the vessel remains pervious as far as the bladder, forming the superior vesical artery.

Peculiarities. The *length* of the internal iliac artery varies from half an inch to three inches, its extreme measurements; but in two-thirds of a large number of bodies it ranged from an inch to an inch and a half (R. Quain).

Size. In the rare cases where the femoral trunk is derived from the internal iliac, and is placed at the back of the thigh, this vessel is larger than the external iliac.

A. The three branches arising from the posterior piece of the internal iliac may be first examined.

The *ilio-lumbar artery* (fig. 172, *h*) passes outwards beneath the psoas muscle and the obturator nerve, but in front of the lumbosacral cord, and divides into an ascending and a transverse branch:—

The *ascending* or *lumbar branch*, which is beneath the psoas, supplies that muscle and the quadratus lumborum, and anastomoses with the last lumbar artery: it sends a small *spinal branch* through the foramen between the sacrum and the last lumbar vertebra.

The *transverse* or *iliac branch* divides into offsets that ramify in the iliacus muscle, some running over and some beneath it. At the iliac crest these branches anastomose with the lumbar and circumflex iliac arteries; some deep twigs communicate with the obturator artery, and enter the hip-bone.

The *ilio-lumbar vein* opens into the common iliac trunk.

Lateral
sacral
arteries

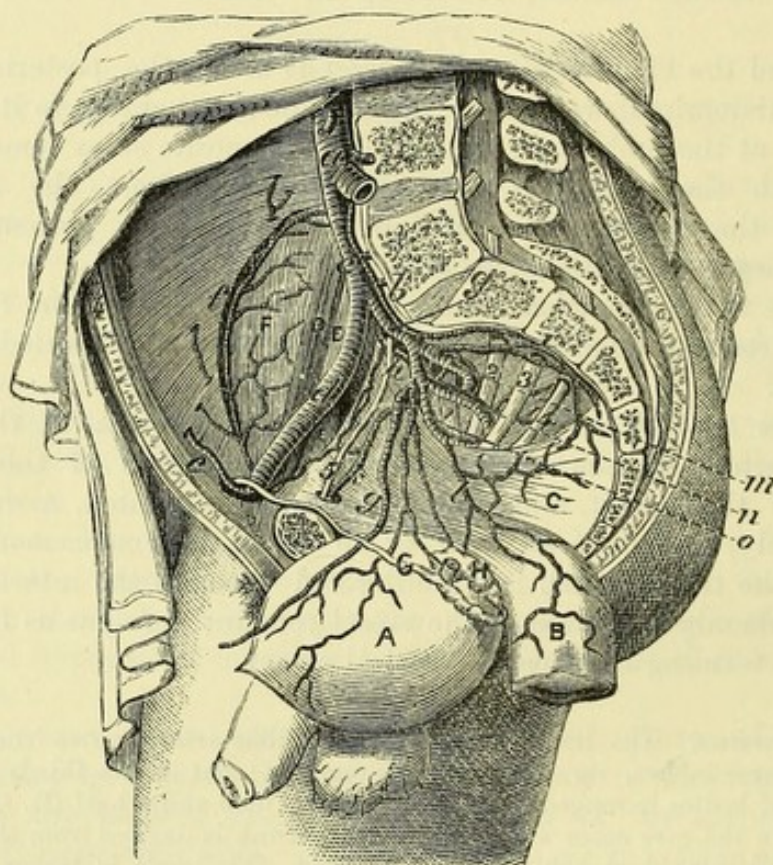
supply
spinal
branches.

Gluteal
artery :

The *lateral sacral arteries* (fig. 172, *i*) are commonly two in number, superior and inferior: they correspond in situation with the lumbar arteries, and form a chain of anastomoses by the side of the apertures in the sacrum. These arteries supply the pyriformis and coccygeus muscles, and anastomose with each other, as well as with the middle sacral. A *spinal branch* enters each aperture in the sacrum.

The *gluteal artery* (fig. 172, *m*) is the continuation of the posterior

Fig. 172. *



small
offsets.

division of the internal iliac, and is destined for the gluteal muscles on the outer surface of the hip-bone. It is a short, thick trunk, which leaves the pelvis through the great sacro-sciatic foramen, above the pyriformis muscle, with its accompanying vein and the superior gluteal nerve. In the pelvis the artery gives small *branches* to the contiguous muscles, viz., iliacus, pyriformis, and obturator, and a twig to the hip-bone.

* Dissection of the internal iliac artery (Tiedemann). A. Bladder. B. Lower end of the rectum. C. Levator ani. D. Psoas magnus. E. Psoas parvus. F. Iliacus. G. Vas deferens. H. Vesicula seminalis. *Arteries*: a. Aorta splitting into the common iliacs. b. Middle sacral. c. Common iliac. d. External iliac. e. Epigastric. f. Circumflex iliac. g. Internal iliac, continued by an impervious cord along the bladder. h. Ilio-lumbar. i. Lateral sacral. k. Obturator. l. Middle hæmorrhoidal. m. Gluteal. n. Sciatic. o. Pudic. *Nerves*: 1. Lumbo-sacral cord. 2, 3, 4. Upper three sacral nerves. 5. Obturator.

B. The branches of the anterior portion of the internal iliac artery are the following :—

The *superior vesical artery* is the imperfectly obliterated portion of the foetal hypogastric artery. It divides into three or four branches, which ramify over the apex and body of the bladder: the lowest of these is sometimes called the *middle vesical branch*.

The *inferior vesical artery* often arises in common with the branch to the rectum. It is distributed to the base of the bladder, the vesiculæ seminales, and the prostate. A small offset from this artery, or from the upper vesical, is furnished to the vas deferens.

The *vaginal artery* (fig. 171, *e*) of the female takes the place of the inferior vesical of the male. It descends on the vagina, and ramifies in its wall as low as the outer orifice. This branch is often given off by the uterine artery.

The *middle hæmorrhoidal artery* commonly arises from the inferior vesical (or vaginal), or from the pudic trunk. It is spent on the anterior and lower part of the rectum, and anastomoses with the other hæmorrhoidal arteries.

The *obturator artery* (fig. 172, *k*) is directed forwards below the brim of the pelvis to the aperture at the top of the thyroid foramen: passing through that opening it ends in two branches, which ramify on the membrane closing the thyroid foramen, beneath the obturator externus muscle. In the pelvis the artery has its companion nerve above, and vein below it; and it gives origin to the following small branches :—

The *iliac branch* enters the iliac fossa to supply the bone and the iliacus muscle; it anastomoses with the ilio-lumbar artery.

The *pubic branch* (fig. 143, *f*) ascends on the posterior aspect of the pubis, and communicates with the corresponding branch of the opposite side, and with an offset from the epigastric artery.

Sometimes the obturator takes origin from the epigastric, or the external iliac artery.

The *sciatic artery* (fig. 172, *n*) is the next largest branch to the gluteal, and is continued over the pyriformis muscle and the sacral plexus to the lower part of the great sacro-sciatic foramen, where it issues between the pyriformis and the coccygeus muscles. External to the pelvis it divides into branches beneath the gluteus maximus, and is distributed to the buttock: in the pelvis it supplies the pyriformis and coccygeus muscles.

The *internal pudic artery* (fig. 172, *o*) supplies the perineum and the genital organs, and has nearly the same relations in the pelvis as the sciatic. It accompanies the sciatic artery, though external to it, and leaves the pelvis between the pyriformis and coccygeus. At the back of the pelvis it winds over the ischial spine of the hip-bone, and enters the perineal space (p. 421). The artery gives some unimportant offsets in the pelvis, and frequently the middle hæmorrhoidal branch arises from it.

Accessory pudic (R. Quain). The pudic artery is sometimes smaller than usual, and fails to supply some of its ordinary perineal branches, especially the terminal ones to the penis. In those cases the

Branches
of anterior
part.

Upper
vesical.

Lower
vesical

or vaginal.

Middle
hæmor-
rhoidal.

Obturator
artery
courses
across
pelvis:

offsets in
pelvis;

iliac branch.

pubic
branch.

Sciatic
artery

in the pelvis,

and outside
it.

Pudic
artery in
the pelvis:

some small
offsets.

An acces-
sory pudic
branch.

deficient branches are derived from an accessory artery, which takes origin from the internal iliac (mostly from the trunk of the pudic), and courses forwards on the side of the bladder and the prostate gland, to perforate the triangular ligament. It furnishes branches to the penis to supply the place of those that are wanting.

Uterine
artery :

The *uterine artery* (fig. 171, *d*) passes inwards between the layers of the broad ligament to the neck of the uterus, where the vessel changes its direction, and ascends to the fundus. Numerous branches enter the substance of the uterus, and ramifying in it, are remarkable for their tortuous condition.

offsets to
vagina ;
joins
ovarian.

At the neck of the uterus some small twigs are supplied to the vagina and the bladder ; and opposite the ovary a branch bends outwards to anastomose with the ovarian artery of the aorta.

Internal
iliac vein :
position to
its artery ;

The INTERNAL ILIAC VEIN receives the blood from the wall of the pelvis, and the pelvic viscera, by branches corresponding for the most part with those of the artery. The vein is a short thick trunk, which is situate at the posterior and inner aspect of the artery ; and it ends by uniting with the external iliac to form the common iliac vein.

its branches
that are
peculiar are

Branches. Most of the branches entering the trunk of the internal iliac vein have the same anatomy as the arteries ; but the following branches,—the pudic and dorsal of the penis, the vesical and hæmorrhoidal, the uterine and vaginal, have some peculiarities.

pudic,

The *pudic veins* receive roots corresponding with the branches of the pudic artery in the perineum (p. 430), but not those corresponding with the offsets of the artery on the dorsum of the penis.

dorsal vein
of penis,

The *dorsal vein of the penis* (p. 440) receives veins from the corpora cavernosa and corpus spongiosum of the penis, and entering the pelvis below the symphysis pubis, divides into two, a right and a left branch, which join a large plexus round the prostate (*prostatic plexus*).

hæmor-
rhoidal,

The *middle hæmorrhoidal vein* communicates with a large plexus (hæmorrhoidal) around the lower end of the rectum beneath the mucous membrane (p. 579).

vesical,

The *vesical veins* begin in a plexus about the fundus of the bladder, and anastomose with the prostatic and hæmorrhoidal veins.

uterine, and

The *uterine veins* are numerous, and form a plexus in and by the side of the uterus : this plexus inosculates above with the ovarian plexus, and below with one on the vagina.

vaginal
veins.

The *vaginal veins* surround their tube with a large vascular plexus (p. 582).

Other
arteries in
the pelvis.

The arteries in the pelvis, which are not derived from the internal iliac, are the ovarian, superior hæmorrhoidal, and middle sacral.

Ovarian
artery :

The OVARIAN ARTERY (p. 528), after passing the brim of the pelvis, becomes tortuous, and enters the broad ligament to be distributed to the ovary : it supplies an offset to the Fallopian tube, and another to the round ligament ; and a large branch anastomoses internally with the uterine artery.

offsets.

The SUPERIOR HÆMORRHOIDAL ARTERY, the continuation behind the rectum of the inferior mesenteric (p. 482), divides into two branches near the middle of the sacrum. From the point of division the branches are continued along the rectum, one on each side, and each ends in about three branches, which pierce the muscular layer of the gut three inches from the anus; they terminate opposite the internal sphincter in anastomotic loops beneath the mucous membrane, and anastomose with the middle and inferior hæmorrhoidal arteries. Superior hæmorrhoidal ends in loops.

The MIDDLE SACRAL ARTERY of the aorta (p. 527; fig. 172, *b*) descends along the middle of the last lumbar vertebra, the sacrum, and the coccyx. The artery gives small branches laterally, opposite each piece of the sacrum, to anastomose with the lateral sacral arteries, and to supply the nerves, and the bones with the periosteum. Sometimes a small branch is furnished by it to the lower end of the rectum, to take the place of the middle hæmorrhoidal artery. Middle sacral, which has lateral offsets.

The *middle sacral veins* end in the left common iliac.

Dissection (fig. 173). To dissect the nerves of the pelvis, on the right side, it will be necessary to detach the triangular ligament with the urethra from the bone; and to cut through, on the right side, the fore part of the recto-vesical fascia and levator ani, together with the visceral arteries, in order that the viscera may be drawn from the side of the pelvis. If the bladder is distended, let the air escape from it. Dissection of the nerves of the pelvis,

By means of the foregoing dissection the sacral nerves may be found as they issue from the sacral foramina. The dissector should follow the first four into the sacral plexus, and some branches from the third and fourth to the viscera. The last sacral and the coccygeal nerve are of small size, and will be detected coming through the coccygeus muscle, close to the coccyx: these are to be dissected with care; and the student will succeed best by tracing the connecting filaments which pass from one to another, beginning above with the offset from the fourth nerve. first four sacral, last and coccygeal,

Opposite the lower part of the rectum, bladder, and vagina is a large plexus of the sympathetic (pelvic plexus), which sends branches to the viscera along the arteries. This plexus is generally destroyed in the previous dissection; but if any of it remains, the student may trace the offsets distributed from it, and its communicating branches with the spinal nerves. sympathetic.

SACRAL SPINAL NERVES (figs. 173 and 174). The anterior primary branches of the sacral nerves are five in number, and decrease rapidly in size from above downwards. Issuing by the apertures in the front of the sacrum (the fifth nerve excepted), they receive short filaments of communication from the gangliated cord of the sympathetic. The first three nerves and part of the fourth enter the sacral plexus, but the fifth ends on the back of the coccyx. Sacral nerves are five: most enter plexus.

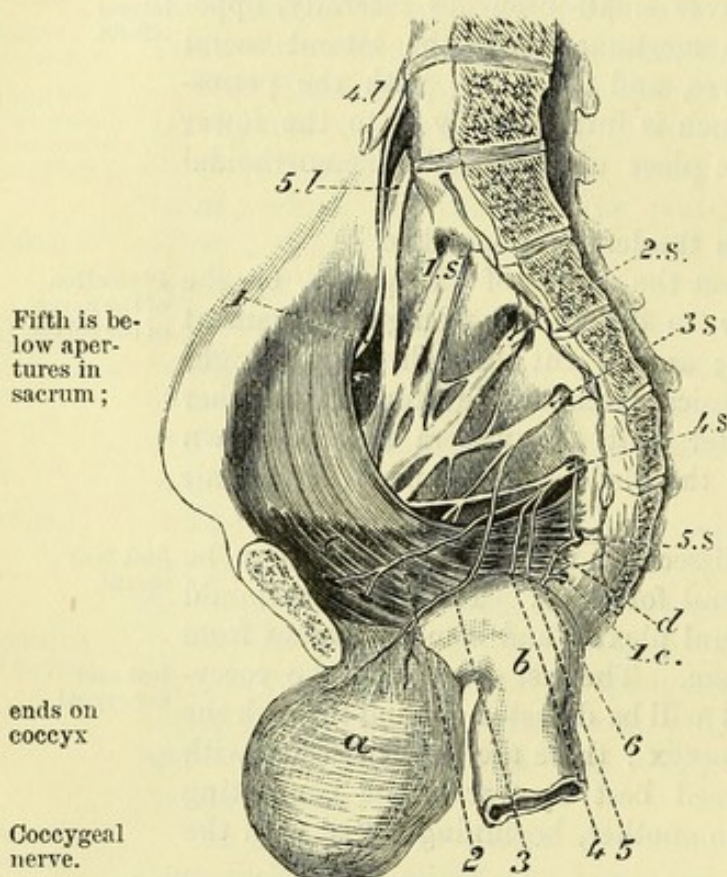
The coccygeal nerve, and the peculiarities of the fourth and fifth sacral, will be noticed before the plexus is described.

Fourth, The *fourth nerve* (fig. 173, 4 S) sends one branch upwards to the sacral plexus, another downwards to join the fifth nerve, and distributes the following offsets to the viscera and the muscles of the floor of the pelvis :—

visceral, The *visceral branches* (³) supply the bladder and the vagina, and communicate with the sympathetic nerve to form the pelvic plexus. Other offsets are added to them from the third sacral nerve (fig. 174, v).

and muscular offsets. The *muscular branches* are three in number. One rather long branch (fig. 173, ²) enters the levator ani on the visceral aspect; another (⁴) supplies the coccygeus; and the third (perineal or hæmorrhoidal branch; ⁵) reaches the perineum by piercing the levator ani or coccygeus muscle, and supplies the external sphincter (p. 422).

Fig. 173.*



Fifth is below apertures in sacrum;

ends on coccyx

Coccygeal nerve.

The *fifth nerve* (5 S) comes forwards between the sacrum and coccyx, and receives the communicating branch from the fourth nerve; it is then directed downwards in front of the coccygeus, where it is joined by the coccygeal nerve, and perforates that muscle, the sacro-sciatic ligament, and the gluteus maximus, to end on the posterior surface of the coccyx.

The *coccygeal nerve* (1 c), after issuing by the lower aperture of the spinal canal,

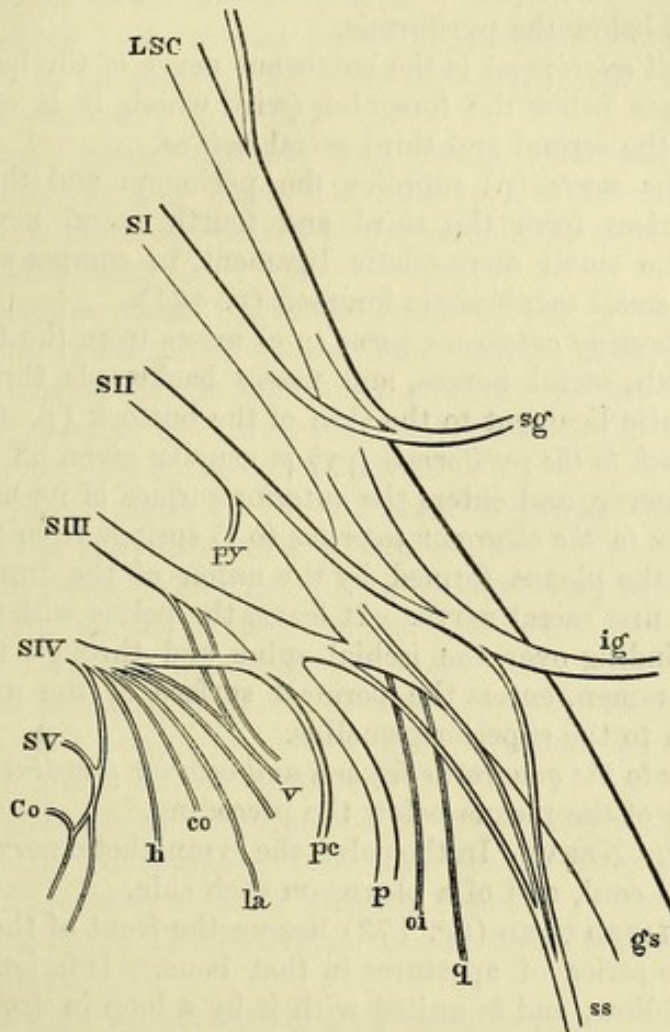
appears through the coccygeus muscle, and joins the fifth sacral nerve as above stated.

Sacral plexus : This plexus is formed by the lumbo-sacral cord, the first three sacral nerves, and part of the fourth sacral. It is situate on the pyriformis muscle, beneath the sciatic and pudic branches of the internal iliac artery; and the nerves entering it converge towards the large sacro-sciatic foramen. Here they are united for the most part in a broad flat band, which, becoming

* Dissection of the sacral nerves and plexus (altered from Henle). a. Urinary bladder. b. Rectum. c. Levator ani. d. Coccygeus. Nerves: 4 l and 5 l. Fourth and fifth lumbar nerves, giving rise to the lumbo-sacral cord. 1 S to 5 S. Five sacral nerves. 1 c. Coccygeal nerve. 1. Upper gluteal nerve. 2. Branch to levator ani. 3. Branch to the bladder. 4. Branch to coccygeus. 5. Branch to the perineum. 6. Common branch of 4 S, 5 S, and 1 c, for the back of the coccyx.

gradually narrower as it leaves the pelvis below the pyriformis, ending; forms the great sciatic nerve. A part of the third nerve, however, and the branch of the fourth entering the plexus unite to form a lower smaller trunk—the pudic nerve; and other branches are given off by the several nerves before their union.

Fig. 174.*



Branches. Most of the offsets of the plexus are distributed outside the pelvis, and are met with in the dissection of the buttock (p. 639); of these only the origin is to be seen now. The named branches are the great and small sciatic, the superior and inferior gluteal, the pudic, and the perforating cutaneous. Other small offsets are furnished to some of the muscles of the buttock.

a. The *great sciatic nerve* (fig. 174, gs) is the principal nerve of the Great sciatic.

* Diagram of the sacral plexus, from behind. LSC. Lumbo-sacral cord, formed by the fifth lumbar nerve and a small branch from the fourth. SI to SV. First to fifth sacral nerves. Co. Coccygeal nerve. gs. Great sciatic nerve. ss. Small sciatic. p. Pudic. sg. Superior gluteal. ig. Inferior gluteal. py. Branch to pyriformis. oi. Nerve to obturator internus. q. Nerve to quadratus. v. Visceral branches of third and fourth sacral nerves. la. Branch to levator ani. co. Branch to coccygeus. h. Hæmorrhoidal or perineal branch of fourth sacral.

the lower limb, and is formed by the union of four large roots from the lumbo-sacral cord and the first three sacral nerves.

Superior
gluteal.

b. The *superior gluteal nerve* (sg) arises by two roots from the lumbo-sacral cord and the first sacral nerve, and leaves the pelvis with the gluteal artery above the pyriformis for the supply of the muscles on the outer surface of the ilium.

Inferior
gluteal.

c. The *inferior gluteal* (ig) is the nerve of the gluteus maximus. It springs from the lumbo-sacral cord and first two sacral nerves, and passes out below the pyriformis.

Small
sciatic.

d. The *small sciatic* (ss) is the cutaneous nerve of the back of the thigh, and arises below the foregoing (with which it is often connected) from the second and third sacral nerves.

Pudic.

e. The *pudic nerve* (p) supplies the perineum and the genital organs. It arises from the third and fourth sacral nerves, and courses over the small sacro-sciatic ligament, in company with its artery, to the small sacro-sciatic foramen (p. 421).

Perforating
cutaneous.

f. The *perforating cutaneous nerve* (p c) arises from the fourth, or third and fourth, sacral nerves, and passes backwards through the great sacro-sciatic ligament to the skin of the buttock (p. 422).

Branch to
pyriformis.

g. The *branch to the pyriformis* (py) is usually given off from the second sacral nerve, and enters the anterior surface of its muscle.

Branch to
obturator
internus.

h. The *nerve to the obturator internus* (o i) springs from the front of the part of the plexus formed by the union of the lumbo-sacral cord with the first sacral nerve. It leaves the pelvis with the pudic artery, and winding over the ischial spine and through the small sacro-sciatic foramen, enters the perineal surface of the muscle: it gives a branch to the superior gemellus.

Branch to
quadratus.

i. The *nerve to the quadratus femoris and inferior gemellus* (q) arises from the front of the plexus below the preceding.

Sympathetic
in the pelvis.

SYMPATHETIC NERVE. In the pelvis the sympathetic nerve consists of a gangliated cord, and of a plexus on each side.

The gan-
gliated cord

The GANGLIATED CORD (fig. 173) lies on the front of the sacrum, internal to the series of apertures in that bone. Inferiorly it converges to its fellow, and is united with it by a loop in front of the coccyx, on which there is often a median ganglion (*gang. impar*). Each cord is marked by ganglia at intervals, the number varying from three to five: from them branches of communication pass outwards to the spinal nerves, and some filaments are directed inwards in front of the sacrum.

to the spinal
nerves,

The *connecting branches* are usually two to each ganglion, grey and white, and are very short.

to the pelvic
plexus and
the viscera.

The *internal branches* are small, and communicate around the middle sacral artery with the branches of the opposite side. From the first, or first two ganglia, some filaments are furnished to the pelvic plexus; and from the terminal loop offsets descend over the coccyx.

Pelvic
plexuses:

The PELVIC PLEXUSES (lateral inferior hypogastric) are two in number, right and left, and are continuous with the lateral prolongations of the hypogastric plexus (p. 483). Each is situate by the side of the bladder and rectum in the male, and by the side of

the uterus and vagina in the female, and is united with offsets of situation ;
the third and fourth sacral nerves. Numerous ganglia are found in how formed ;
the plexus, especially at the points of union of the spinal and
sympathetic nerves.

Offsets. From each plexus offsets are furnished along the branches offsets to
of the internal iliac artery to the viscera of the pelvis, and the genital the viscera
organs : these form secondary plexuses, and have the same name as of the male,
the vessels on which they are placed. viz.,

The *inferior hæmorrhoidal plexus* is an offset from the back of to the
the plexus to the rectum, and joins the sympathetic on the superior rectum ;
hæmorrhoidal artery (p. 483).

The *vesical plexus* contains large offsets, with many white-fibred to the
or spinal nerves, and passes forwards to the side and neck of the bladder ;
bladder. It gives one plexus to the vesicula seminalis, and another
to the vas deferens.

The *prostatic plexus* leaves the front of the pelvic plexus, and to the pro-
supplies the substance of the prostate. At the front of the prostate state and
an offset (cavernous) is continued onwards to the dorsum of the penis ;
penis, to supply the cavernous structure. On the penis the
cavernous nerves join the pudic nerve.

In the female there are the following additional plexuses for the offsets in
supply of the viscera peculiar to that sex :— the female,

Ovarian plexus. The chief nerves to the ovary are derived from to the
the renal and aortic plexuses (p. 483), and accompany the artery of ovary ;
that body ; but the uterine nerves supply some filaments to it.

Vaginal nerves. The nerves of the vagina are large, and are not to the
plexiform, but consist in greater part of spinal nerve-fibres ; they vagina ;
end in the lower part of the tube.

The *uterine nerves* are furnished to the uterus with only a small and to the
admixture of the spinal nerves : they ascend along the side of the uterus.
uterus, and consist of long slender filaments without ganglia or
communications. The Fallopian tube receives its branches from the
uterine nerves.

Some few nerves surrounding the arteries of the uterus are plexi-
form and ganglionic.

The LYMPHATIC GLANDS OF THE PELVIS form one chain in front Chain of pel-
of the sacrum, and another along the internal iliac vessels : their vic glands ;
efferent ducts join the lumbar glands. Into these glands the deep
lymphatics of the penis, those of the genital organs in the female, lymphatics
and the lymphatics of the viscera and wall of the pelvis are col- entering
lected. them.

SECTION V.

ANATOMY OF THE VISCERA OF THE MALE PELVIS.

Directions. The bladder and the bodies at its base, viz., the vesiculæ
seminales, and the prostate gland, are to be taken first for examina-
tion.

Take out the viscera ; *Dissection.* To study the form and structure of the viscera, it will be necessary to remove them from the pelvis. For this purpose the student should carry the scalpel round the pelvic outlet, close to the osseous boundary, so as to detach the crus of the penis from the bone, and the end of the rectum from the parts around. When the viscera are removed, the rectum is to be separated from the other organs ; but the bladder, the penis, and the urethra are to remain united.

separate rectum ;

clean the bladder, After the bladder has been distended with air, the areolar tissue is to be removed from the muscular fibres. The prostate gland and the vesiculæ seminales are then to be cleaned ; and the duct of the latter, with the vas deferens, is to be followed to the gland.

and penis. If any of the integument has been left on the penis it is to be taken away.

THE PROSTATE GLAND AND SEMINAL VESICLES.

Prostate gland : PROSTATE GLAND (fig. 175). This is a firm muscular body containing glands, which surrounds the neck of the bladder and the beginning of the urethra. Its relations have been enumerated at p. 549.

situation ;

form ; The prostate is conical in form, like a chestnut, with the base or larger end directed upwards. Its dimensions are the following :—

dimensions ; Transversely at the base it measures about an inch and a half ; from apex to base an inch and a quarter ; and from before back about three-quarters of an inch or an inch : so that an incision directed obliquely outwards and backwards will be the longest that can be practised in the half of this body. Its weight is about an ounce, but in this respect it varies greatly.

and weight.

Surfaces ; The anterior surface of the prostate is narrow and rounded. The posterior surface, larger and flatter, is marked by a median hollow which indicates the division into lateral lobes.

base ; The base is thick, and at its posterior part has a median notch, which receives the common seminal ducts. The apex is pierced by the urethra.

and apex.

Three lobes, Two lateral, Three lobes are described in the prostate, viz., a middle and two lateral, though there is no fissure in the firm mass. The *lateral lobes* (fig. 175, *b*, *c*) are similar on the two sides, and are separated only by the hollow on the under surface ; they form the chief part of the prostate, and are prolonged back, on each side, beyond the notch in the base. The *middle lobe* (*d*) will be brought into view by detaching the vesiculæ seminales and the vasa deferentia from the bladder : it is the piece of the gland between the neck of the bladder and the seminal ducts, which extends across between the lateral lobes. Oftentimes the middle lobe is enlarged in old people, and projects upwards into the bladder, so as to interfere with the flow of the urine from that viscus, or the passage of a catheter into it.

and a central.

Gland contains three tubes. The urethra and the two common seminal ducts are contained in the substance of the prostate (fig. 177). The former is transmitted through the gland from base to apex ; and the latter perforate it obliquely to terminate in the urethral canal.

Structure. On a section the gland appears reddish grey in colour, is very firm to the feel, and is scarcely lacerable. It is made up of a mass of muscular and fibrous tissues, with interspersed glandular structure; and the whole is enveloped by a fibrous sheath derived from the recto-vesical fascia (p. 544). Structure.

Muscular tissue. The firm mass of this body consists mainly of involuntary muscular fibres, intermixed with elastic and fibrous tissues. One set of muscular fibres is arranged circularly round the urethral canal,—these are continuous above with the annular fibres of the bladder, and below with a thin layer of circular fibres surrounding the membranous portion of the urethra; others run transversely behind the urethra, and radiate in each lateral lobe through the glandular substance; and over the greater part of the surface is an external stratum, forming a kind of capsule, which adheres to the fibrous sheath. Along the front and towards the apex, the superficial part of the organ is composed of striated muscular fibres, also disposed transversely, which are continued into the constrictor urethræ muscle between the layers of the triangular ligament. Muscular fibres are plain—
circular,
radiating,
and
superficial;
and striped.

Glandular substance. This is composed of a number of small branched glands, which are embedded in the muscular stroma. There are three chief collections,—a small one in the central lobe, and a larger one in each lateral lobe. The ducts of the glands vary in number from twelve to twenty, and open into the prostatic part of the urethra (p. 573). Glands in three masses :
ducts open into the urethra.

Blood-vessels. The *arteries* are small, and are furnished by the inferior vesical and middle hæmorrhoidal. The *veins* form a plexus round the gland, which receives in front the dorsal vein of the penis, and is continued behind into the plexus at the base of the bladder. In old men these vessels may give rise to considerable hæmorrhage in the operation of lithotomy. Arteries.
Veins form a plexus.

The *nerves* are supplied from the pelvic plexus. The *lymphatics* of this body and of the vesiculæ seminales are received into the glands by the side of the internal iliac artery. Nerves.
Lymphatics.

VESICULÆ SEMINALES (fig. 175, *e*). These vesicles are two membranous sacs, which serve as receptacles for, and probably secrete a special fluid to mix with, the semen. They are placed at the base of the bladder above the prostate, and diverge from one another so as to limit laterally a triangular space in that situation: their form and relations have been already described (p. 549). Though sacculated and bulged above, the vesicula becomes straight and narrowed below (duct); and at the base of the prostate it blends with the vas deferens to form the common seminal or ejaculatory duct (*g*). Seminal vesicles:
definition;
situation;
form;

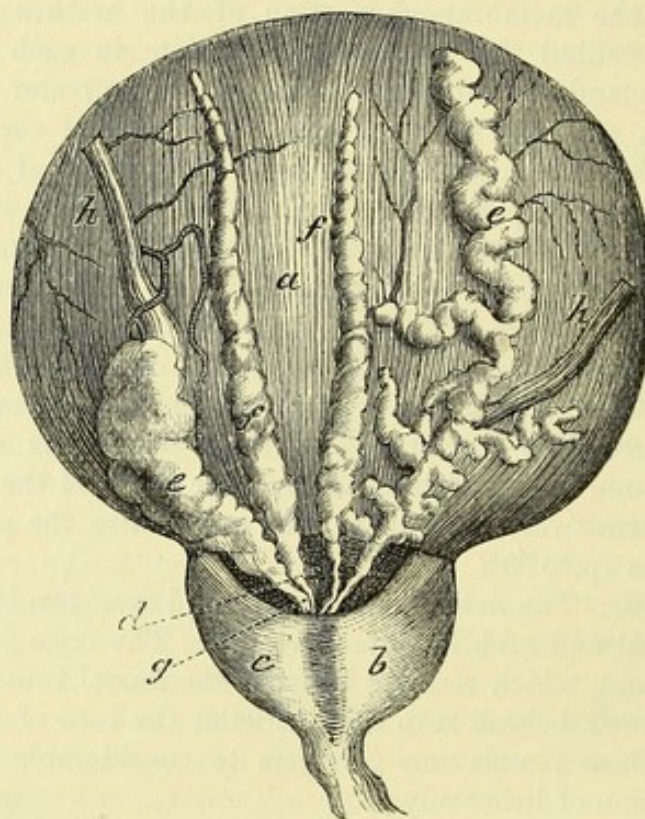
The vesicula seminalis consists, like the epididymis, of a tube bent into a zigzag form, so as to produce lateral sacs or pouches, the bends of which are bound together by fibrous tissue; this cellular structure will be shown by means of a cut into it. When the bends of the vesicle are undone, its formative tube, which is about the size of a quill, measures from four to six inches in length, consist of a folded tube;
length and size.

and ends above in a closed extremity : connected with the tube at intervals, are lateral cæcal appendages (fig. 175).

Vesicle has usual coats ; *Structure.* The wall of the seminal vesicle has the same number of layers as the vas deferens (p. 521) ; but the muscular coat is thinner.

a covering of muscular fibres ; Within the casing of the recto-vesical fascia, the vesiculæ and vasa deferentia are covered by a layer of transverse and longitudinal plain muscular fibres. The transverse are the more superficial

Fig. 175.*



(the base of the bladder being upwards), are strongest near the prostate, and act most on the vasa deferentia. The longitudinal fibres, placed chiefly on the sides of the vesiculæ, are continued forwards with the common seminal ducts to the urethra. (Roy. Med. Chir. Trans. 1856.)

and a mucous coat. The *mucous membrane* is thrown into ridges by the bending of the tube, and presents an alveolar or honeycomb appearance ; it is provided with tubular glands, as in the vas deferens.

End of vas deferens. *End of vas deferens* (fig. 175). Opposite the vesicula the vas deferens is enlarged, and is rather sacculated like the contiguous vesicle ; but before it joins the tube of that body to form the

* View of the posterior surface of the bladder, with the vesiculæ seminales and vasa deferentia (slightly altered from Haller). *a.* Bladder. *b* and *c.* Right and left lateral lobes of the prostate. *d.* Middle lobe. *e.* Vesicula seminalis, the right one unravelled. *f.* Vas deferens. *g.* Common seminal duct, formed by the union of the vas deferens with the duct of the vesicula. *h.* Ureter.

common seminal duct, it diminishes in size, and becomes straight. In the mucous lining are numerous tubular glands (Henle).

Common seminal ducts (fig. 177, f). These tubes (right and left) are formed by the junction of the narrowed part or duct of the vesicula seminalis with the vas deferens of the same side. They begin opposite the base of the prostate, and are directed downwards and forwards through an aperture in the transverse prostatic fibres, and along the sides of the hollow (vesicula prostatica), to open into the urethral tube. Their length is rather less than an inch, and their course is convergent to their termination close to each other in the floor of the urethra (p. 573).

Seminal ducts, how formed:

extent;

course;

length;

termination;

Structure. The wall of the common duct is thinner than that of the vesicula seminalis; but it possesses similar coats. It is surrounded by longitudinal involuntary muscular fibres, which blend in the urethra with the submucous stratum.

structure.

THE BLADDER.

After the bladder has been removed from the pelvis, its form and the extent of its different regions can be more conveniently studied.

Bladder out of the body:

While the bladder is in the body, it is ovoidal in shape, and rather flattened from above down; but out of the body it is rounder than when in its natural position, and it loses that arched form by which it adapts itself in distension to the curve of the pelvis.

form;

If this viscus is moderately dilated, it measures about five inches in length, and three inches across (Huschke). Its capacity is greatly influenced by the age and habits of the individual. Ordinarily the bladder holds about a pint without inconvenience during life, though it can contain much more when distended.

dimensions.

STRUCTURE. A muscular and a mucous coat, with an intervening fibrous layer, exist in the wall of the bladder: at certain parts the peritoneum may be also enumerated as a constituent of the wall. The vessels and nerves are large.

Coats of the bladder.

The imperfect covering of *peritoneum* has been described (p. 546).

Peritoneal.

The *muscular coat* is formed of thin layers of unstriated muscular fibres, viz., an external or longitudinal, a middle or circular, and an internal or submucous.

Muscular has three strata.

The *longitudinal fibres* (fig. 176, ¹) form a continuous covering, with the usual plexiform disposition of the muscular bundles, and extend from apex to base. Above, some are connected with the urachus, and the subperitoneal fibrous tissue. Below, the posterior and lateral fibres enter the prostate; while the anterior are attached to the fascia covering the prostate, but a fasciculus on each side is united to the back of the pubis through the anterior true ligament of the bladder. On the front and back of the bladder the muscular layer is stronger, and its fibres more vertical than on the sides. Sometimes this outer layer of fibres is called *detrusor urinæ* from its action in the expulsion of the urine.

External or longitudinal:

attachments;

forms detrusor urinæ.

Middle continuous with prostate.

The *circular fibres* (fig. 176, ²) are thin and scattered on the body of the bladder; but around the cervix they are collected into a thick bundle, the *sphincter vesicæ*, and are continuous below with the fibres of the prostate. When these fibres are hypertrophied, they project into the interior of the organ, forming the fasciculated bladder; and in some bodies the mucous coat may be forced outwards here and there between them, in the form of sacs, producing the sacculated bladder.

Submucous layer:

The *submucous stratum* (fig. 176, ³) forms a continuous layer over the lower half of the bladder,

extent;

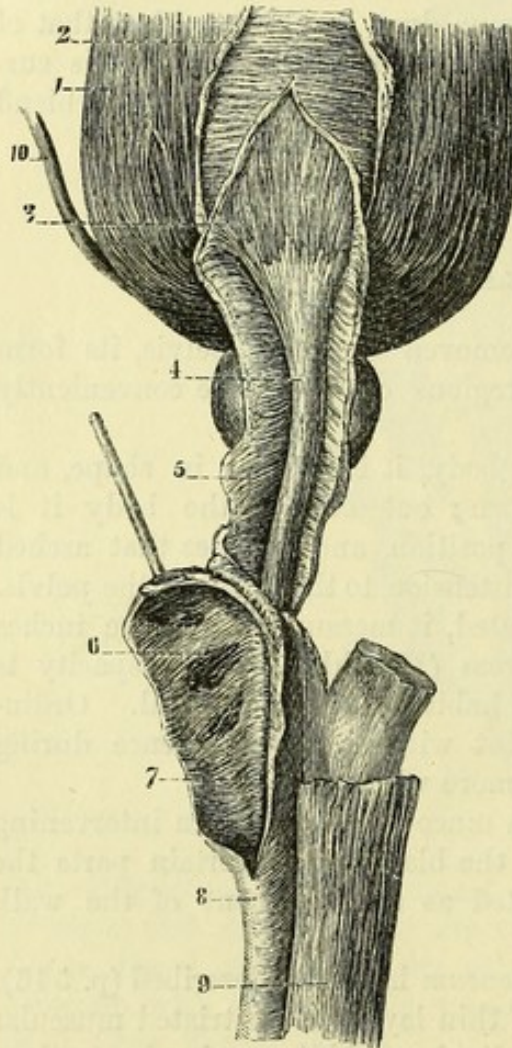
Fig. 176.*

fibres;

addition to it.

Strata are joined.

Fibrous coat.



but its fibres are scattered above. In the lower third of the viscus the fibres are longitudinal, and are continued around the urethra; but they become oblique above that point. At the back of the bladder the layer is increased in strength by the longitudinal fibres of the ureters blending with it.

The muscular strata communicate freely, so that one cannot be separated from another without division of the connecting bundles of fibres. In both sexes the disposition of the fibres is similar (Roy. Med. Chir. Trans., 1856).

Fibrous or submucous coat. A fibrous layer is placed between the muscular and mucous strata, and is enumerated as one of the coats of the bladder; it is composed, as in other hollow viscera, of areolar and elastic tissues, in which the vessels and nerves ramify.

Open the bladder.

now to be opened by an incision along the pubic surface; and the cut is to be continued down the front of the prostate gland.

Mucous coat

The *mucous membrane* of the bladder is of a pale rose colour, in the healthy state soon after death. It is continuous above with the lining of the ureters, and below with that of the urethra. It is very

* Muscular fibres of the bladder, prostate, and urethra. 1. External or longitudinal fibres of the bladder. 2. Circular fibres of the middle coat. 3. Submucous layer. 4. Muscular layer around the urethra. 5. Circular fibres of the prostate and urethra continuous with the circular of the bladder. 6, 7. Septum of the corpus spongiosum. 8. Corpus spongiosum. 9. Corpus cavernosum. 10. Ureter.

slightly united to the muscular layer; and it is thrown into numerous folds in the flaccid state of the viscus, except over a small triangular space behind the urethral opening.

has folds except at one part.

Objects inside the bladder. Within the bladder are the following special parts, viz., the orifices of the ureters and urethra, with the triangular surface (fig. 178).

Interior of the bladder.

Orifices. At the lower part of the bladder is the orifice of the urethra, surrounded by the prostate gland. The mucous membrane presents here some longitudinal folds; and the aperture is partly closed by a small elongated prominence below, *uvula vesicæ*, occasioned by a thickening of the submucous muscular and fibrous layers. This eminence is placed over the middle lobe of the prostate; and from its anterior end a slight ridge is continued on the floor of the urethra.

Opening of urethra,

with the uvula.

About an inch and a half from the orifice of the urethra, and rather more than that distance apart, are the two narrow openings of the ureters (fig. 178). These tubes perforate the wall of the bladder obliquely, lying in it for the distance of three-quarters of an inch, so that the reflux of fluid through them towards the kidney is prevented as the bladder is distended. Each terminates by a slit-like opening in a prominence of the subjacent muscular fibres.

Openings of the ureters.

Triangular surface. Immediately behind the orifice of the urethra is a smooth triangular surface, which is named *trigone* (trigonum vesicæ; fig. 178). Its apex reaches the prostate, and its base the ureters. Its boundaries may be marked out by a line on each side from the urethra to the ureter, and by a transverse one, behind, between the openings of the ureters. This surface corresponds with the triangular space externally at the base of the bladder, between the vesiculæ seminales and vasa deferentia. Over it the mucous coat is more closely united to the muscular, so as to prevent the accidental folds occurring in the other parts of the empty bladder.

Trigone of the bladder:

how bounded;

part corresponding externally.

Dissection. The arrangement of the fleshy fibres of the ureters will come into view on the removal of the mucous membrane from the lower third of the bladder.

To expose muscles of ureters.

Ending of the fibres of the ureter. As soon as the ureter pierces the outer and middle coats of the bladder, its longitudinal fibres are thus disposed;—the more internal and strongest are directed transversely, and join the corresponding fibres of the other urine tube; while the remainder are continued down over the triangular surface, and blend with the submucous layer.

Muscular fibres of ureters.

Blood-vessels and nerves. The source of the vesical arteries, and the termination of the veins, have been detailed (p. 559). The vessels are disposed in greatest number about the base and neck of the bladder. Most of the nerves distributed to the bladder, though supplied from the pelvic plexus of the sympathetic (p. 565), are derived directly from the spinal nerves. The lymphatics enter the glands by the side of the internal iliac artery.

Arteries; veins;

nerves of the bladder.

Lymphatics.

THE URETHRA AND PENIS.

Urethra :
extent and
length ;

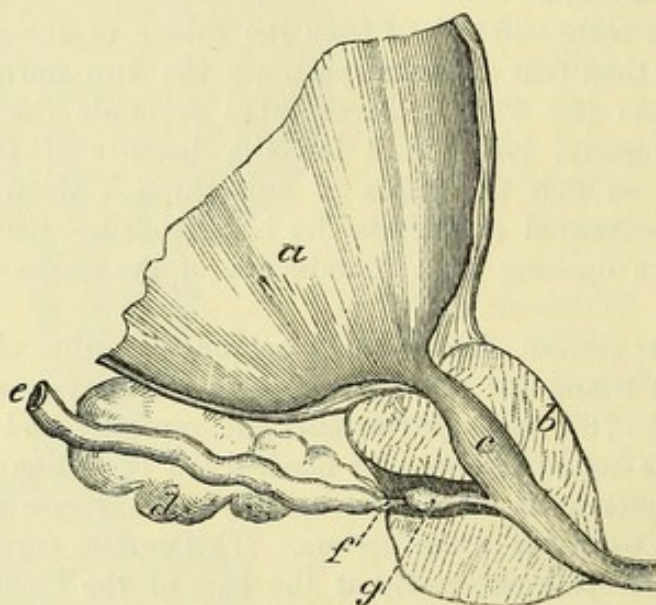
division
into parts.

How to open
the urethra.

URETHRA (fig. 178). The tube of the urethra extends from the neck of the bladder to the end of the penis, and has an average length of about eight inches ; but it is shorter by one inch during life (Thompson). It is supported by the prostate, the triangular ligament, and the spongy structure of the penis. The tube is divided, as before said (p. 550), into a prostatic, a membranous, and a spongy part.

Dissection. To open the urethra, let the incision through the prostate

Fig. 177.*



be continued onwards to the extremity of the penis along the line of union of the urethral canal with the corpus cavernosum.

Prostatic
part :

dimensions
and
shape ;
diameter.

On the floor
is a crest :

The *prostatic part* (fig. 177) is nearer the anterior than the posterior surface of the muscular mass surrounding it. It is one inch and a quarter in length, and is the widest portion of the urethral canal. Its form is spindle-shaped, for it is larger in the middle than at either end. Its transverse measurement at the neck of the bladder is nearly a third of an inch ; at its centre a line or two more ; and at the lower end rather less than at the beginning.

Separating this part of the passage from the bladder is the eminence of the uvula vesicæ. Beginning half an inch below this is a central longitudinal eminence of the mucous lining (fig. 178 *d*), about three-quarters of an inch in length, and larger above than below, which is prolonged towards the membranous part of the canal, and is named *crest of the urethra* (verumontanum, caput

* Section through the bladder, prostate, and urethra, to show the vesicula prostatica and the common seminal duct. *a.* Bladder. *b.* Prostate. *c.* Prostatic part of the urethra. *d.* Vesicula seminalis. *e.* Vas deferens. Common ejaculatory duct. *g.* Vesicula prostatica.

gallinaginis) : it is formed of erectile substance, with a framework of elastic and muscular tissues. In the crest of the mucous membrane, near its posterior extremity, is a small hollow (*e*) named *vesicula prostatica*, *sinus pocularis*, or *utricle*. in the crest is a pouch.

The *vesicula prostatica* (fig. 177, *g*) is directed backwards in the prostate, for a quarter of an inch, passing beneath the middle and between the lateral lobes. Its orifice in the urethra is about a line wide, and its closed extremity is about as large again. Along the wall, on each side, is placed the *common seminal duct* (*f*), which terminates on or within the margin of the mouth of the sac ; and if bristles are introduced into the common seminal duct behind the prostate, they will render the apertures evident. Small glands open on the surface of the mucous membrane lining the utricle. The *vesicula* is the remains of the united lower ends of the ducts of Müller in the foetus, and represents the uterus in the female. Vesicula projects into the prostate, and by its side are the ejaculatory ducts.

On each side of the central crest is an excavation, which is named the *prostatic sinus* (fig. 178, *f*). Into this hollow the greater number of the ducts of the prostatic glands open ; but the apertures of some are seen at the back of the central eminence. Prostatic sinuses also in floor.

The MEMBRANOUS PART OF THE URETHRA (fig. 178, *g*) is three-quarters of an inch in length, and intervenes between the apex of the prostate gland and the bulb (*k*) of the corpus spongiosum urethræ. In its interior are slight longitudinal folds. This is the narrowest piece of the whole tube, with the exception of the outer orifice, and measures rather less than a quarter of an inch across. It is the weakest of the three portions of the canal, and is supported by a thin stratum of erectile tissue, by a thin layer of unstriated circular fibres (p. 429), and outside all by the constrictor urethræ muscle. Membranous part : dimensions ; parts around.

The SPONGY PART (fig. 178, *i*) reaches to the end of the penis. It is about six inches in length, and its strength depends upon a surrounding material named corpus spongiosum urethræ. Spongy part :

The average size of the canal is about a quarter of an inch in diameter, though at the vertical slit (meatus urinarius), by which it terminates on the glans penis, the tube is smaller than elsewhere. On a cross section it appears star-shaped, but in the glans, as a vertical slit. Two dilations exist in the spongy portion ;—one is along the floor close to the triangular ligament, being contained in the bulb or bulbous part of the urethra, and is named *sinus of the bulb* ; the other is an elongated hollow, situate in the glans penis, and has been called *fossa navicularis* (*n*). dimensions two dilations,—one in bulb, one in glans ;

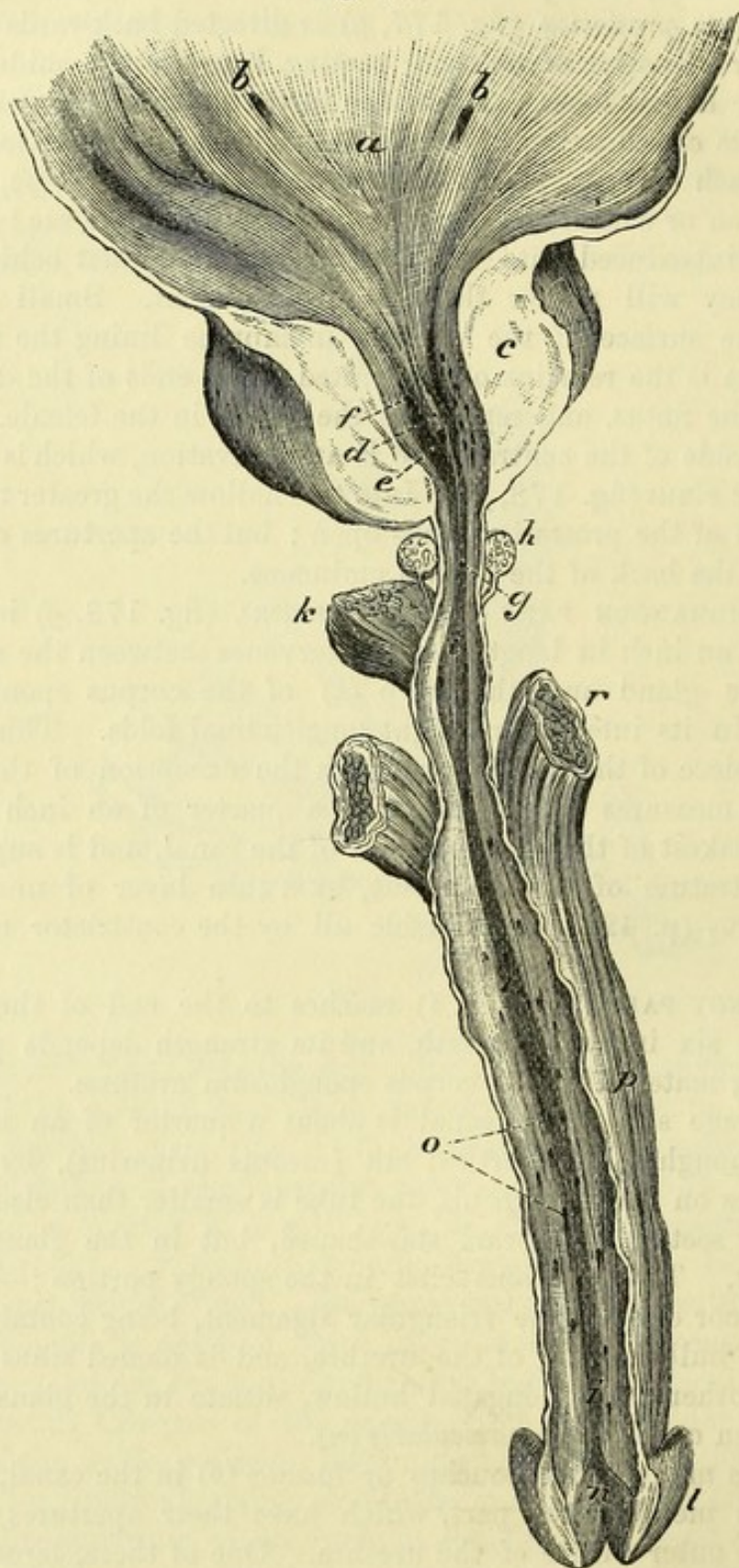
There are many small pouches or *lacunæ* (*o*) in the canal, as far back as the membranous part, which have their apertures turned towards the outer orifice of the urethra. One of these, larger than the rest, *lacuna magna*, is found generally immediately within the meatus, in the roof of the fossa navicularis. lacunæ one larger than the rest.

The *ducts of Cowper's glands* (fig. 178, *h*) are two in number, and terminate, one on each side, on the floor of the urethra near the bulb ; but their openings are generally too small to be recognised. Ducts of glands of Cowper.

Mucous lining of the urethra. The mucous membrane of the urethra Mucous membrane :

is continued into the bladder, as well as into the ducts opening into the canal, and joins in front the tegumentary covering of the glans

Fig. 178.*



colour; penis. It is of a reddish colour in the spongy and membranous portions, but in the prostate it becomes whiter. In the spongy and

* View of the lower part of the bladder and of the urethra laid open. *a.* Trigone of the bladder. *b.* Openings of the ureters. *c.* Prostate, cut. *d.* Crest of urethra. *e.* Sinus pocularis. *f.* Prostatic sinus, with openings of

membranous parts it is thrown into longitudinal folds during the folds; contracted state of the penis.

Its surface is studded throughout with the apertures of minute glands, glands, which are lodged in the submucous tissue, and the ducts of which are inclined obliquely forwards.

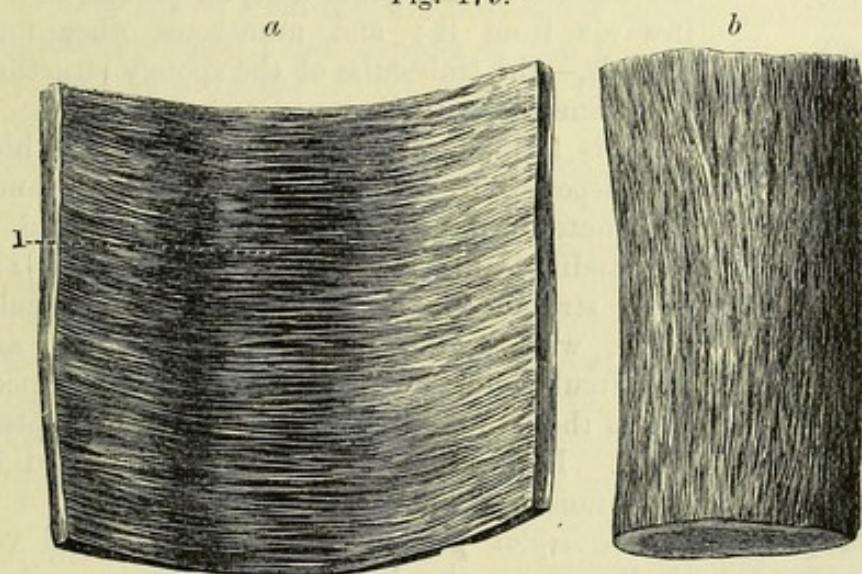
Submucous tissue. Beneath the mucous lining of the urethra is a stratum of longitudinal unstriated muscular fibres, mixed with elastic and fibrous tissues. It is continuous behind with the submucous fibres of the bladder, and is joined in the prostate by the muscular fibres accompanying the common seminal ducts. The stratum differs at spots:—It is most developed in the prostate; in the membranous portion the muscular structure is less abundant;

Submucous tissue:

nature;

arrangement in urethra.

Fig. 179.*



and in the spongy part fibrous tissue forms most of the submucous layer.

Around the membranous and prostatic divisions of the urethra there is, in addition, immediately beneath the mucous membrane, a thin layer of vascular or erectile tissue, which is continued backwards from the corpus spongiosum to the neck of the bladder.

Erectile tissue throughout.

STRUCTURE OF THE PENIS. The form and the relations of the penis having been described on p. 551, the bodies of which it is composed remain to be noticed. If a section is made along one side of the penis, it will show this organ to be composed of two masses of spongy and vascular tissue (corpora cavernosa) encased in a fibrous covering, with an imperfect septum between them, and having the corpus spongiosum attached along their under surface.

Penis formed of two vascular erectile bodies.

CORPORA CAVERNOSA (fig. 178, *r*). These bodies form the bulk of

Corpora cavernosa

the glands of the prostate. *g*. Membranous part of the urethra. *h*. Cowper's glands, a duct from each opening into the urethra. *i*. Spongy part of the urethra. *k*. Bulb of the corpus spongiosum. *l*. Glans penis. *n*. Fossa navicularis. *o*. Openings of lacunæ and glands. *r*. Corpus cavernosum of the penis.

* View of the fibres of the case of the corpus cavernosum. *b*. External or longitudinal layer. *a*. Inner or circular fibres. 1. Pectiniform septum.

attached
behind
separately,
blend
together
in front :

bulb.

Structure :

a case

that sends in
processes ;

fibres form
strata ;

a septal
piece,

which is
imperfect ;

how
formed ;

and nume-
rous bands
and cords to
form a net-
work.

Vessels.

the penis, and are two dense cylindrical tubes of fibrous tissue, containing erectile structure. Each is fixed behind by a pointed process, *crus penis*, to the conjoined rami of the ischium and pubis for about an inch, and blends with its fellow in the body of the penis, about an inch and a half from its posterior extremity. There is a slight swelling on the crus, called the bulb of the corpus cavernosum (Kobelt).

Each corpus cavernosum is composed of a fibrous case containing a cavernous or trabecular structure, with blood-spaces between the trabeculae of the spongy mass. An incomplete median septum exists along the body of the penis.

The *fibrous case* is a white, strong, elastic covering (fig. 179), from half a line to a line in thickness. Along the middle of the penis a septal process is sent inwards from it ; and numerous other finer threads,—the trabeculae of the spongy structure, are connected with its inner surface.

It is formed of white shining fibres which are disposed in two layers, outer and inner. The outer stratum (fig. 179, *b*) is formed of longitudinal fibres with close meshes. The inner stratum (fig. 179, *a*) consists of circular fibres, with a like plexiform disposition ; and the circular fibres of each cavernous body meeting in the middle line give rise to the septum penis. Both strata are inseparably united by communicating bundles.

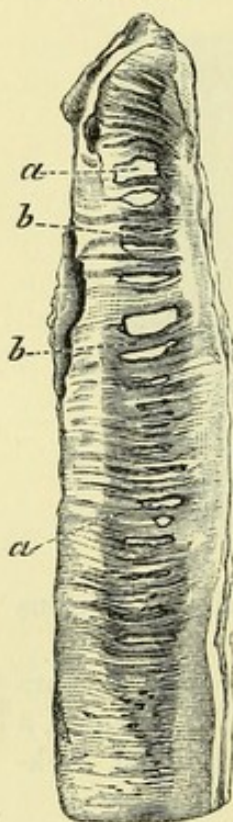
The *septal process* (fig. 180) is placed vertically along the body of the penis, and is thicker and more perfect behind than in front. Near the junction of the crura this partition divides the enclosed cavity into two ; but as it reaches forwards it becomes less strong, and is pierced by elongated apertures, which give it the appearance of a comb, from which the name *septum pectiniforme* is derived. Through the

intervals in the septum the vessels in the corpora cavernosa communicate. It is formed by the circular fibres of the fibrous case.

The *cavernous* or *trabecular structure* is a network of fine threads, which fills the interior of the corpora cavernosa. Its processes are thinner towards the centre than at the circumference ; and the areolar spaces are larger in the middle and at the fore part of the contained cavity, than at the circumference or in the crura of the penis. The spongy structure may be demonstrated by sections of the penis, after it has been distended with air and dried.

Blood-vessels. The blood-vessels of the penis are of large size, and

Fig. 180.*



* Pectiniform septum of the penis. *a*. Apertures in the partition. *b*. Separate fibrous processes like the teeth of a comb, which are formed by the circular fibres.

serve to nourish as well as to minister to the function of the organ. Having entered the cavernous mass, they ramify in the trabecular structure.

The *arteries* of the corpora cavernosa are offsets of the pudic; the chief branch (*artery of the corpus cavernosum*; p. 430) enters at the crus, and runs forwards through the middle of the cavernous structure, distributing offsets; and the rest, coming from the dorsal artery (p. 440), pierce the fibrous case along the dorsum of the penis. Source of the arteries;

In the interior they divide into branches, which ramify in the trabeculæ, becoming finer, until they terminate in very minute branches, which open into the intertrabecular venous spaces. By the distension of these spaces the erection of the corpora cavernosa is produced. termination in venous spaces.

The *veins* spring from the intertrabecular spaces, and some issue along the upper and under aspects of the penis to join the dorsal vein; but the principal trunks escape at the crus penis and pass to the pudic veins. Veins in two sets.

CORPUS SPONGIOSUM URETHRÆ. This constituent part of the penis surrounds the urethra, but not equally on all sides; for at the bulb only a thin stratum is above the canal, while at the glans penis (fig. 178, l) the chief mass is placed above the urethral tube. Spongy material of the penis:

Structure. The tissue of the corpus spongiosum is similar to that of the corpus cavernosum; thus it consists of a fibrous tunic enclosing a trabecular structure with blood-spaces. its structure like cavernous.

The *fibrous covering* is less dense and strong than in the corpora cavernosa, and consists only of circular fibres. A *septal piece* (fig. 176, 6) projects inwards from it in the middle line, opposite the tube of the urethra; this is best marked for a short distance in front of the bulb, and assists in dividing that part into two lobes. The *trabecular bands* are much finer, and more uniform in size than in the corpora cavernosa. The fibrous case: imperfect septum; trabeculæ.

Blood-vessels. The arrangement of the blood-vessels in the erectile structure of the corpus spongiosum is similar in the bulb to that in the corpora cavernosa; but in the rest of the spongy substance the arteries are said to end in capillaries in the usual way. Blood-vessels:

The *arteries* are derived from the pudic on each side: a large one behind, the *artery of the bulb* (p. 430), enters the upper surface of the bulb; and several in front, offsets of the dorsal artery (p. 440), penetrate the glans. Kobelt describes another branch to the fore part of the bulb. source of arteries;

Most of the *veins*, including those of the glans, end in the large dorsal vein of the penis, some communicating with veins of the cavernous body: others issue from the bulb, and terminate in the pudic vein. termination of the veins.

Nerves and lymphatics. The *nerves* of the penis are large, and are supplied by both the spinal and sympathetic nerves. The *superficial lymphatics* of the integuments, and those beneath the mucous membrane of the urethra, join the inguinal glands; the *deep* accompany the veins beneath the subpubic arch, to end in the lymphatic glands. Nerves. Lymphatics.

THE RECTUM.

- To prepare the gut. *Dissection.* The rectum is to be washed out, and then distended with tow ; and the peritoneum and the loose fat are to be removed from it.
- Rectum is smooth ; The lower end of the large intestine, which is contained in the pelvis, is not sacculated like the colon, but is smooth on the surface, the longitudinal bands of the colon being absent from it.
- length ; It is about eight inches in length ; and its average diameter is dimensions. that of the sigmoid flexure of the colon. Its size is uniform as far as the lower extremity, where it is dilated, particularly in old people ; but the aperture of termination or anus is the smallest part of the gut.
- Same coats as in the rest of the intestine :— *Structure.* The rectum contains in its wall a peritoneal, a muscular, a submucous, and a mucous stratum ; and the muscular and mucous coats have certain characters which distinguish this part of the intestinal tube.
- Peritoneum. The *peritoneum* forms but an incomplete covering, and its arrangement is referred to in the description of the relations of the pelvic viscera (p. 547).
- Muscular coat The *muscular coat* is thick, and consists of two layers of pale or unstriated fibres, viz., a superficial or longitudinal, and a deep or circular. The *longitudinal*, continuous with those in the bands on the colon, are here diffused to form a stratum round the gut. The *circular* describe arches around the intestine, and become thicker and stronger towards the anus, where they are collected in the band of the internal sphincter muscle (p. 420).
- has longitudinal and circular fibres. The *mucous coat* is more moveable than in the colon, and resembles in this respect the lining of the œsophagus ; it is also thicker and more vascular than in the rest of the large intestine.
- Mucous coat is thick and vascular ; When the bowel is contracted the mucous lining is thrown into folds in it, numerous accidental folds ; but some near the anus are longitudinal, enclosing submucous muscular fibres, and form the *columns* of Morgagni. There are also three permanent folds (Houston) which are half an inch or less in depth, and contain circular fibres of the gut. The most constant of these is about three inches from the anus, on the front of the rectum, opposite the base of the bladder ; another is placed on the right side of the intestine, towards the top ; and the third is on the left side, midway between the other two. These folds will be seen by laying open the gut along the side, provided it is tolerably fresh.
- some are permanent ;
- structure. The mucous membrane has the same general structure as in the colon, but towards the anus the secretory apparatus gradually disappears.
- Arteries : *Blood-vessels.* The *arteries* are supplied from three different sources, viz., superior hæmorrhoidal of the inferior mesenteric, middle hæmorrhoidal of the internal iliac, and inferior hæmorrhoidal of the internal pudic. All three sets anastomose on the lower end of the gut ; but only the upper hæmorrhoidal, which is the largest, re-

quires farther notice. The final branches of this artery (p. 561), about six in number, pierce the muscular layer three inches from the anus, and descend between the mucous and muscular coats as far as the internal sphincter, where they unite in loops just within the anus. arrangement of superior hæmorrhoidal.

The *veins* have no valves, and communicate freely in a large plexus (hæmorrhoidal) between the muscular and mucous coats, round the lower end of the gut. Above, they join the inferior mesenteric vein, and through it reach the vena portæ; and below they pour some blood into the internal iliac vein by the middle and inferior hæmorrhoidal branches. Veins are without valves.

Nerves and lymphatics. The *nerves* of the intestine are obtained from the sympathetic; but those of the external sphincter come from the spinal nerves. The *lymphatics* terminate in the chain of glands on the sacrum. Nerves. Lymphatics.

SECTION VI.

ANATOMY OF THE FEMALE PELVIC VISCERA.

In the pelvis are contained the viscera alike in both sexes, viz., the bladder, urethra, and rectum, and those special to the female, or the organs of generation. Viscera in the pelvis.

Dissection. The contents of the pelvis are to be removed, together with the genital organs. For this purpose the student should keep the scalpel close to the osseous boundary of the pelvic outlet, to avoid injuring the end of the rectum; and he should also detach the crus of the clitoris from the bone. To remove the viscera,

After the parts are taken from the body, the rectum is to be separated from the uterus and the vagina, but the rest of the viscera may remain united until after the genital organs are examined. The bladder and rectum may be moderately distended; and the fat and areolar tissue are to be removed from the viscera. and prepare them.

GENITAL ORGANS.

The genital organs, or external organs of generation, consist of the following parts:—the mons Veneris and external labia, the clitoris and internal labia, and the vestibule with the meatus urinarius. Within the internal labia is the aperture of the vagina, with the hymen. The name *vulva* or *pudendum* is applied to these parts as a whole. Only the clitoris remains to be examined now, the others having been seen in the dissection of the perineum (p. 432); but there is also an erectile body on each side of the entrance to the vagina, called the bulb of the vestibule, to be noticed. External organs of generation.

Dissection. To see the clitoris, the integuments forming the

dissection
to see it;

is like the
penis;

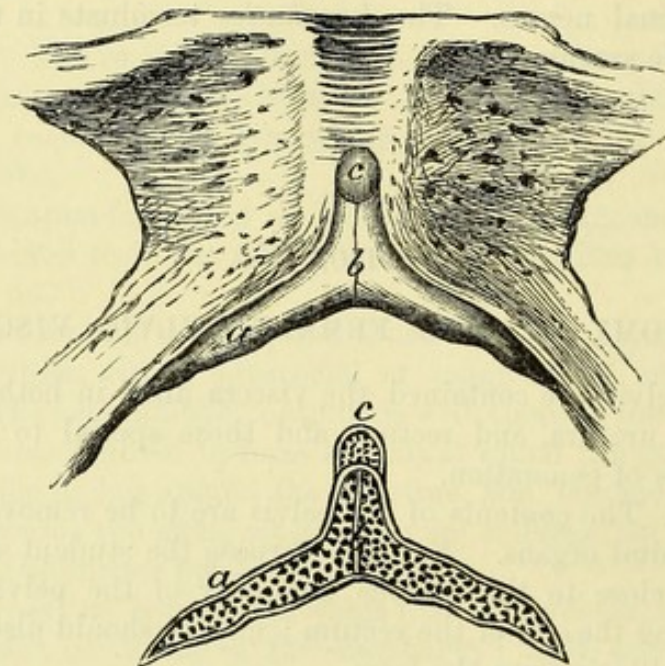
has a glans
and pre-
puce;
composi-
tion,

anterior commissure must be removed; and, after the body of the organ has been laid bare, the crura, one on each side, are to be followed outwards.

The CLITORIS (fig. 181, *b*) is a small erectile body, and is the representative of the penis. It has the same composition as the penis, except that the urethra is not continued along it. Its anterior extremity is terminated by a rounded part or glans (*c*), and is covered by a fold of the mucous membrane corresponding to the prepuce of the male (p. 432).

In its structure this organ resembles the penis in the following particulars:—It consists of corpora cavernosa, which are attached

Fig. 181.*



corpora
cavernosa,

corpus
spongio-
sum,
and erectile
tissue.

Bulbs of
vestibule:

by crura (one on each side; *a*) to the ischio-pubic rami, and are blended in the body. A small suspensory ligament descends to it from the superficial fascia of the mons Veneris; and along the middle is an imperfect pectiniform septum. Farther, it possesses a portion of corpus spongiosum, but this structure is limited to the glans clitoridis (*c*).

Structure. The outer fibrous casing and the septum are alike in both penis and clitoris; and in the interior of the clitoris is an erectile tissue, like that in the male organ (p. 576).

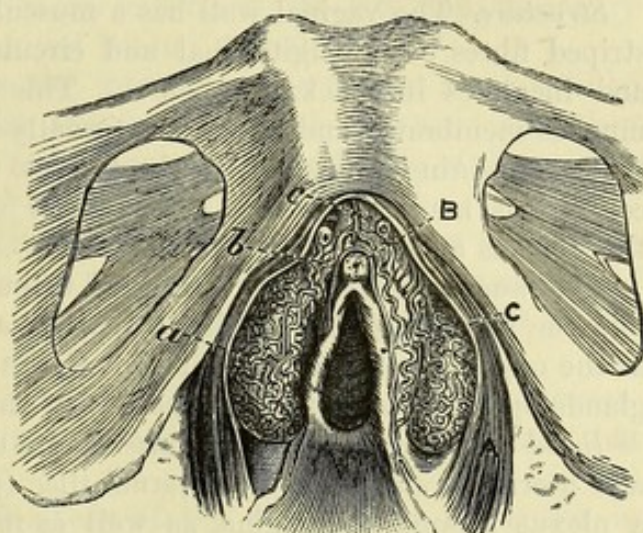
The *blood-vessels* of the corpus cavernosum are like those of the penis; and the glans receives the ending of the dorsal artery (p. 440).

The BULB OF THE VESTIBULE (semi-bulb, Taylor; fig. 182, *a*) is an elongated and flattened mass of cavernous or erectile tissue, which is enclosed in a thin fibrous coat. It lies by the side of the vestibule

* Representation of the clitoris. *a*. Crus, and *b*. Body of the corpus cavernosum. *c*. Glans clitoridis. The lower figure shows the structure on a vertical section; the same letters refer to like parts.

and the entrance to the vagina, above (deeper than) the nympha, situation ; resting against the lower surface of the triangular ligament, and relations ; being covered by the sphincter vaginae muscle (A). Each is about an inch and a half long, and is larger at its hinder end, where it measures size ; about half an inch in depth. By their narrow anterior ends the two bulbs are united in front of the urethra ; and they are joined by a venous plexus to the small glans of the clitoris. These bodies answer to the divided bulb of the corpus spongiosum urethrae in the male.

Fig. 182.*



connected
to clitoris ;

represent
bulb of male

GENERATIVE ORGANS.

The generative organs, or internal organs of generation, are the uterus and vagina, and the ovaries with the Fallopian tubes.

Dissection. The viscera are now to be separated, so that the bladder and the urethra may be together, and the vagina and the uterus remain united. The bladder is to be set aside for subsequent use. The surface of the vagina and the lower part of the uterus should be cleaned ; but the peritoneal investment of the latter is to be left untouched for the present.

Separate
vagina and
uterus ;

clean
vagina.

THE VAGINA

The tube of the vagina (fig. 171, 1) is connected with the uterus at one end, and with the vulva at the other. It has a slightly curved course between the two points mentioned ; and the anterior and posterior walls are not equal in length, for the former measures about two inches, and the latter three.

Vagina :
extent
and curved
course ;

In the body the vagina is flattened from before back, so that the form opposite surfaces are in contact ; and the upper part of the posterior wall is applied to the lower end of the uterus. Its size varies at different spots ;—thus the external orifice, which is surrounded by the constrictor vaginae muscle, is the narrowest part ; the middle portion is the largest ; and the upper end is intermediate in dimensions between the other two.

and size.

After the vagina has been laid open by an incision along the side, Interior

* Erectile bodies of the female genital organs, and opening of the vagina (Kobelt). A. Sphincter vaginae muscle. B. Clitoris. c. Nympha. a. Bulb of the vestibule. b. Venous plexus continuous with veins of the clitoris. c. Dorsal vein of the clitoris.

- the position of the uterus in the anterior wall, instead of at the extremity of the passage, may be remarked; and the tube may be seen to extend farther on the posterior than the anterior lip of the os uteri. On the inner surface, towards the lower part, is a longitudinal ridge both in front and behind, named *columns of the vagina*. Before the tissue of the vagina has been distended, other transverse ridges or rugæ pass between the columns. The wall of the vagina is thicker in front round the urethra than at any other part of the canal.
- has columns and rugæ. *Structure.* The vaginal wall has a muscular coat, composed of unstriated fibres both longitudinal and circular, which is thin above, and increases in thickness below. This is lined internally by mucous membrane, and covered externally by a layer of connective tissue containing a dense network of veins. The prominence of the columns is mainly due to a collection of cavernous tissue between the mucous and muscular layers.
- Thickness. The *mucous membrane* is continued through the lower aperture to join the integument on the labia majora, and through the os uteri, at the opposite end, to the interior of the uterus. Many mucous glands open on the surface, especially at the upper part.
- Three coats: mucous, muscular, and fibrous; also erectile tissue.
- Mucous membrane.
- Arteries. *Blood-vessels and nerves.* The *arteries* are derived from the vaginal and uterine branches of the internal iliac (p. 559). The *veins* form a plexus around the vagina, as well as in the genital organs, and open into the internal iliac vein. For a description of the *nerves*, see page 565.
- Veins are plexiform.
- Nerves.
- Lymphatics. The *lymphatics* accompany the blood-vessels to the glands by the side of the internal iliac artery.

THE UTERUS.

- Uterus: The uterus or womb is formed chiefly of unstriated muscular fibres. Its office is to receive the ovum, and to contain the developing foetus.
- form; This viscus in the virgin state is somewhat pear-shaped, the body being flattened (fig. 183), and the narrow end below.
- dimensions; Before impregnation the uterus measures about three inches in length, two in breadth at the upper part, and an inch in greatest thickness. Its weight varies from an ounce to an ounce and a half. But after gestation its size and volume always exceed the measurements here given.
- upper end; The upper end is convex, and is covered by peritoneum: the name *fundus* is given to the part of the organ above the attachment of the Fallopian tubes (*e*).
- the lower end is small, and has an opening; The lower end is small and rounded, and in it is a transverse aperture of communication between the uterus and the vagina, named *os uteri* (*os tincae*): its margins or *lips* (*labia*) are smooth, and anterior and posterior in situation, but the hinder one is the longer and thinner. Towards the lower part the uterus is constricted; and the smaller portion is called the *neck* of the uterus
- neck;

(*cervix uteri*; *b*) : it is nearly an inch in length, and gradually tapers towards the extremity, where it projects into the vagina, being enclosed by this tube to a greater extent behind than in front.

The *body* (*a*) of the uterus is more convex posteriorly than anteriorly, and decreases in size down to the neck. It is covered on both aspects by the peritoneum, except at the lower part in front (about half an inch), where it is connected to the bladder. To each side the parts contained in the broad fold of the peritoneum are attached (fig. 171), viz., the Fallopian tube at the top (*m*), the round ligament (*n*) rather below and before the last, and the ovary (*l*) and its ligament below and behind the others.

Dissection. To examine the interior of the uterus, a cut is to be made along the front from the fundus to the os uteri; and then some of the thick wall is to be removed on each side of the middle line to show the contained cavity.

The *thickness* of the uterine wall is greatest opposite the middle of the body. It is greater at the centre than at the extremities of the fundus (fig. 183), the wall becoming thinner towards the attachment of the Fallopian tubes.

Interior of the uterus (fig. 183). Within the uterus is a small space, which is divided artificially into two—that of the body, and that of the neck.

The space occupying the body of the viscus (*c*) is triangular in form, and compressed from before back. Its base is at the fundus, where it is convex towards the cavity, and the angles are prolonged into the Fallopian tubes. The apex is directed downwards, and joins the cavity in the neck by a narrowed circular part, *isthmus*, which may be narrower than the opening of the uterus into the vagina.

The space within the neck (*d*) terminates below at the os uteri, and is continuous above with the cavity within the body. It is larger at the middle than at either end, being spindle-shaped, and is somewhat flattened like the cavity of the body. Along both the anterior and the posterior wall is a longitudinal ridge; and other ridges (*rugæ*) are directed obliquely from these on each side: this appearance has been named *arbor vitæ uterinus*. In the intervals between the *rugæ* are mucous follicles, which sometimes become distended with fluid, and give rise to rounded clear sacs.

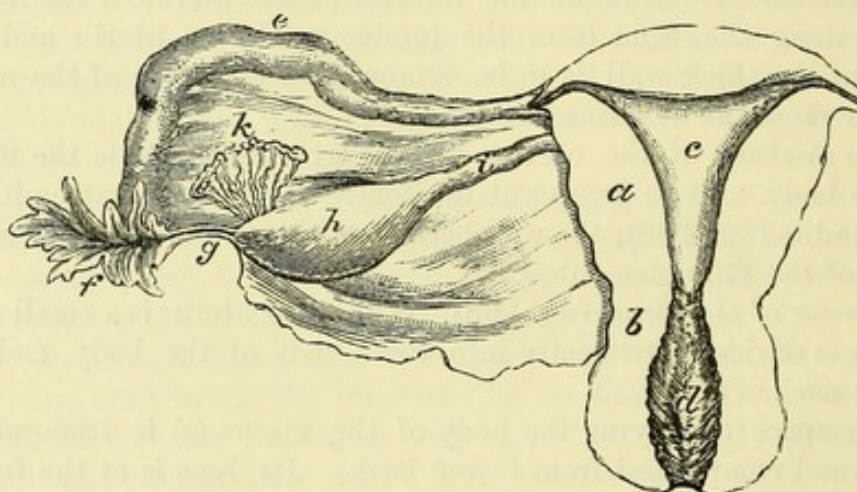
STRUCTURE. The dense wall of the uterus is composed of layers of unstriated muscular fibre, intermixed with areolar and elastic tissues and large blood-vessels. On the exterior is the peritoneum; and lining the interior is a thin mucous membrane.

The *muscular fibres* can be demonstrated at the full period of gestation to form three strata in the wall of the uterus, viz., external, internal, and middle:—

The external layer contains fibres which are mostly transverse; but at the fundus and sides they are oblique, and are more marked than along the middle of the organ. At the sides the fibres converge towards the broad ligament; some are inserted into the sub-peritoneal fibrous tissue; and others are continued into the Fallopian tube, the round ligament, and the ligament of the ovary.

- internal, The internal fibres describe circles round the openings of the Fallopian tubes, and spread from these apertures till they meet at the middle line. At the neck of the uterus they are arranged in a transverse direction.
- and middle. The middle or intervening set of fibres are more indistinct than the others, and have a less determinate direction.
- Mucous membrane. The *mucous lining* of the uterus is continued into the vagina at one end, and into the Fallopian tubes at the other. In the body it is thin and soft, of a reddish-white colour, smooth, and closely

Fig. 183.*



adherent. In the cervix it is stronger, and presents the folds before referred to.

- Vessels are large. The *blood-vessels* of the uterus are large and tortuous, and occupy canals in the uterine substance, in which they communicate freely together. The *arteries* are furnished from the uterine and ovarian branches (p. 560).
- Arteries.
- Veins. The *veins* correspond with the arteries; they are of large size, and form plexuses in the uterus (p. 560).
- Nerves. The *nerves* are derived from the sympathetic (p. 565), and are very small in proportion to the size of the uterus.
- Lymphatics: two sets. *Lymphatics*. One set accompanies the uterine vessels to the glands on the iliac artery. Another set issues from the fundus, enters the broad ligament, and accompanies the ovarian artery to the glands on the aorta: the last are joined by lymphatics of the ovary and Fallopian tube.
- Round ligament ends in groin; attachment to uterus; *Round ligament of the uterus* (fig. 171, N). This firm cord supports the uterus, and is contained partly in the broad ligament, and partly in the inguinal canal. It is about five inches in length, and is attached to the upper end of the uterus close below and in front of the Fallopian tube. A process of the peritoneum

* Interior of the uterus, with a posterior view of the broad ligament and the uterine appendages. *a*. Body, and *b*. Neck of the uterus. *c*. Cavity of the body, and *d*, of the neck. *e*. Fallopian tube, and *f*. Its trumpet-shaped end. *g*. The fimbria attached to the ovary. *h*. Ovary. *i*. Ligament of the ovary. *k*. Parovarium.

accompanies it in the inguinal canal, and remains pervious sometimes for a short distance.

The ligament is composed of unstriated muscular fibres, derived from the uterus, together with vessels and areolar tissue.

OVARIES AND FALLOPIAN TUBES.

OVARY (fig. 183, *h*). The ovaries are two bodies, corresponding with the testes of the male. They are contained in the broad ligaments of the uterus, one in each.

Each ovary is of an oval form, and somewhat compressed in one direction. It is of a whitish colour, with either a smooth or a scarred surface. Its volume is variable; but in the virgin state it is about one inch and a half in length, half as much in width, and a third of an inch in thickness. Its weight varies from one to two drachms.

The ovary is placed at the back of the broad ligament, and is attached to that membrane by one margin, where the vessels enter the organ at the *hilum*. The other margin and both surfaces are free. One end (the upper in the natural position) is rounded, and is connected with one of the fimbriæ (*g*) at the mouth of the Fallopian tube. The opposite extremity is narrowed, and is fixed to the side of the uterus by a fibrous cord,—the ligament of the ovary (*i*), below the level of the Fallopian tube and round ligament.

Structure. The ovary consists of a stroma enclosing small sacs named Graafian vesicles, which contain the ova, and the whole is surrounded by a fibrous tunic. The peritoneum invests it except at the attached margin.

The *fibrous coat* is continuous with the contained stroma. Sometimes a yellow spot (*corpus luteum*), or some cicatrices, may be seen in this covering.

Stroma (fig. 184). The substance of the ovary is spongy, vascular, and fibrous. At the centre the fibres radiate from the hilum towards the circumference. But at the exterior is a granular material (cortical layer) which contains very many small follicles, about $\frac{1}{100}$ th of an inch in size—the nascent Graafian vesicles.

The *Graafian vesicles* or *ovisacs* (fig. 184) are round and transparent sacs, containing fluid, and scattered through the stroma of the ovary below the cortical layer. During the child-bearing period some are larger than the rest (*a*); and of this larger set ten to thirty,

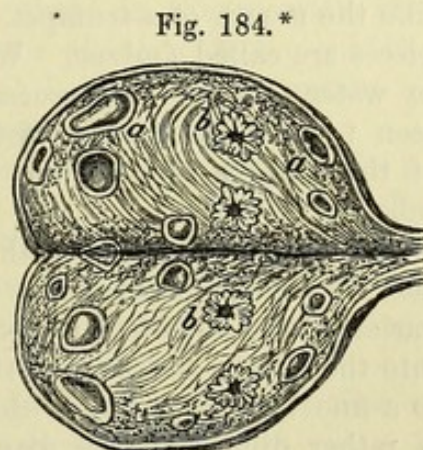


Fig. 184.*

* Ovary during the child-bearing period laid open. *a*. Graafian vesicles in different stages of growth. *b*. Plicated body remaining after the escape of the ovum (Farre).

or more, may be counted at the same time, which vary in size from a pin's head to a small pea. The largest are situate at the circumference of the organ, and sometimes they may be seen projecting through the fibrous coat.

Shedding of
an ovum :

When the Graafian vesicle is matured it bursts on the surface of the ovary, and the contained ovum escapes into the Fallopian tube.

corpus
luteum.

After the shedding of the ovum the ruptured vesicle gives origin to a yellow substance, *corpus luteum*, which finally changes into a cicatrix (b).

Artery ;

Blood-vessels and nerves. The ovarian artery pierces the ovary at the attached border, and its branches run in zigzag lines through the stroma, to which and the Graafian vesicles they are distributed. The

veins ;

veins begin in the texture of the ovary, and after escaping from its substance, form a plexus (*pampiniform*) within the fold of the broad

nerves.

ligament. The *nerves* are derived from the sympathetic on the ovarian and uterine vessels.

Appendage
to ovary :

Parovarium or organ of Rosenmüller (epoophoron of Waldeyer ; fig. 183, k).

situation ;

On holding up the broad ligament of the uterus to the light, a collection of small tortuous tubules will be seen between the ovary and the Fallopian tube.

form ;

These are the remains of the upper part of the Wolffian body of the fœtus, and correspond to the vasa efferentia of the testicle in the male. The mass is about one inch broad, with its base to the Fallopian tube, and apex to the attached border of the ovary. The small tubes are from twelve to twenty in

structure.

number ; at the wider end they are joined more or less perfectly by a tube crossing the rest (the remnant of the Wolffian duct), which is prolonged sometimes a short way into the broad ligament.

Fallopian
tube :

FALLOPIAN TUBES (fig. 183, e). Two in number, one on each side, they convey the ova from the ovaries to the uterus.

length ;

Each is about four inches in length : cord-like at the inner end, where it is attached to the upper part of the uterus, it increases in

and form ;
it is dilated
externally,

size towards the outer end, and terminates in a wide extremity (f), like the mouth of a trumpet. This dilated end is fringed, and the pieces are called *fimbriæ*. When the fimbriated end is floated out

and fimbri-
ated ;

in water, one of the processes (the ovarian fimbria ; g) may be seen to be fixed to the distal end of the ovary. In the centre of the fimbriæ is a groove leading to the orifice of the Fallopian tube.

size of the
canal is least
at the ends.

On opening the tube with care, the size of the contained space and its small aperture into the uterus can be observed. Its canal varies in size at different spots ;—the narrowest part is at the orifice into the uterus (*ostium uterinum*), where it scarcely gives passage to a fine bristle ; towards the outer end it increases a little, but it is rather diminished in diameter at the outer aperture (*ostium abdominale*).

A muscular
structure :

Structure. This tube has the same structure as the uterus with which it is connected, viz., a muscular layer covered externally by peritoneum, and lined by mucous membrane.

fibres pro-
longed from
uterus.

The *muscular coat* is formed of an external or longitudinal, and an internal or circular layer ; both these are continuous with similar strata in the wall of the uterus.

The *mucous membrane* forms some longitudinal folds, particularly at the outer end. At the inner extremity of the canal it is continued into the mucous lining of the uterus, but at the outer end it joins the peritoneum. Mucous coat is continuous with peritoneum.

The *blood-vessels* and *nerves* are furnished from those supplied to the ovary and uterus. Vessels.

THE BLADDER, URETHRA, AND RECTUM.

BLADDER. The peculiarities in the form of the female bladder have been detailed in the description of the relations of the viscera of the female pelvis (p. 555). For a notice of its structure, the anatomy of the male bladder is to be referred to (p. 569). Anatomy of bladder.

Dissection. To prepare the bladder, distend it with air, and remove the peritoneal covering and the loose tissue from the muscular fibres. Preparation of it;

After the external anatomy of the bladder and urethra has been learnt, they are to be slit open along the fore part. open t.

URETHRA. The length and the relations of the excretory tube are given at p. 555. Urethra : length;

The average diameter of the urethra is rather more than a quarter of an inch, and the canal is enlarged and funnel-shaped towards the neck of the bladder : near the external aperture is a hollow in the floor. In consequence of not being surrounded by resistant structures, the female urethra is much more dilatable than the corresponding passage in the male. size ; it can be much dilated.

Structure. Like the urethra of the male, it consists of a mucous coat, which is enveloped by a plexus of blood-vessels, and by muscular fibre. Tube like that in the male.

The *muscular layer* extends the whole length of the urethra. Its fibres are circular, corresponding with those in the prostatic enlargement of the other sex, and continuous above with the middle layer of the bladder. In the perineal ligament this stratum is covered by the fibres of the deep transverse muscle (p. 434). Muscular coat of circular fibres.

The *mucous coat* is pale except near the outer orifice. It is marked by longitudinal folds ; and one of these, in the floor of the canal, resembles the median crest in the male urethra (p. 572). Around the outer orifice are some *mucous follicles* ; and towards the inner end are tubular *mucous glands*, the apertures of which are arranged in lines between the folds of the membrane. Mucous coat : a fold in the floor ; follicles and glands.

A *submucous stratum* of longitudinal elastic and muscular tissues lies close beneath the mucous membrane, as in the male. Submucous tissue.

Dissection. The rectum may be prepared for examination by distending it with tow, and by removing the peritoneal covering and the areolar tissue from its surface. Preparation of rectum.

RECTUM. The structure of the rectum is similar in the two sexes ; and the student may use the description in the SECTION on the viscera of the male pelvis (p. 578). Rectum like that of the male.

SECTION VII.

INTERNAL MUSCLES AND LIGAMENTS OF THE PELVIS.

- Two muscles. Two muscles, the pyriformis and obturator internus, have their origin within the cavity of the pelvis.
- Define the muscles. *Dissection.* Take away any fascia or areolar tissue which may remain on the muscles ; and define their exit from the pelvis,—the pyriformis passing through the great, and the obturator through the small sacro-sciatic foramen. On the right side the dissector may look to the attachment of the levator ani muscle to the pubic part of the hip-bone.
- and the levator ani.
- Pyriformis : The PYRIFORMIS MUSCLE is directed outwards through the great sacro-sciatic foramen to the great trochanter of the femur. The muscle has received its name from its form.
- origin in the pelvis ; In the pelvis the pyriformis *arises* by three slips from the second, third, and fourth pieces of the sacrum, between the anterior apertures, and from the surface of the bone external to those holes ; as it passes from the pelvis, it takes origin also from the surface of the hip-bone forming the upper boundary of the large sciatic notch, and from the great sacro-sciatic ligament. From this origin the fibres converge to the tendon of *insertion* into the trochanter (p. 638).
- insertion ;
- relations with parts around ; The anterior surface is in contact with the sacral plexus, with the sciatic and pudic branches of the internal iliac vessels, and with the rectum on the left side. The opposite surface rests on the sacrum, and is covered by the great gluteal muscle outside the pelvis. The upper border is near the hip-bone, the gluteal vessels and the superior gluteal nerve being between ; and the lower border is contiguous to the coccygeus muscle, the sciatic and pudic vessels and nerves intervening.
- use as an external rotator of hip-joint. *Action.* The pyriformis belongs to the group of external rotators of the hip-joint ; and its use will be given with the description of the rest of the muscle in the dissection of the buttock (p. 638).
- Obturator internus The OBTURATOR INTERNUS MUSCLE has its origin in the pelvis, and insertion at the great trochanter of the femur, like the preceding ; but the part outside forms an acute angle with that inside the pelvis.
- is bent over pelvis ;
- origin in the pelvis ; The muscle *arises* by a broad fleshy attachment from the obturator membrane, except a small part below ; from the pelvic fascia covering its surface ; slightly from the bone anterior to the thyroid hole, but from all the smooth inclined surface of the pelvis behind and above that aperture, except opposite the small sacro-sciatic foramen, where a thin layer of fat separates the fleshy fibres from the bone. The fibres are directed backwards and downwards, and end in four or five tendinous pieces, which turn over the edge of the hip-bone corresponding with the small sciatic notch. Outside the
- arching of its tendons over the hip-bone ;

pelvis the tendons blend into one, which is *inserted* into the great insertion; trochanter (p. 642).

The muscle is in contact by one surface with the wall of the relations of part in pelvic cavity; obturator part of the pelvic fascia, and towards its lower border with the pudic vessels and nerve.

Action. The muscle also rotates out the hip-joint (p. 642).

use.

COCCYGEUS MUSCLE. The position and the relations of this muscle Coccygeus muscle. may now be studied from within: it is described at p. 542.

LIGAMENTS OF THE PELVIS.

The following are the articulations between the bones of the pelvis:—The several pieces of the sacrum and coccyx are united with one another. The sacrum is joined at its base to the last lumbar vertebra, at its apex to the coccyx, and laterally to the two hip-bones. And the hip-bones are connected together in front, as well as to the spinal column behind.

Outline of the articulations.

UNION OF PIECES OF SACRUM AND COCCYX. So long as the pieces of the sacrum and coccyx remain moveable they are articulated as in the other vertebræ by an anterior and posterior common ligament, with an intervertebral disc for the bodies; and by other ligaments for the neural arch and processes (p. 374).

Ligaments of pieces, separate,

After the sacral vertebræ have coalesced, only rudiments of the ligaments of the bodies are to be recognised; and when the pieces of the coccyx unite by bone, their ligaments disappear.

and joined.

SACRO-VERTEBRAL ARTICULATION. The base of the sacrum is articulated with the last lumbar vertebra by ligaments similar to those uniting one vertebra to another (p. 374); and by one special ligament—the sacro-vertebral.

Sacrum with last lumbar vertebra.

Dissection. For the best manner of bringing these different ligaments into view, the dissector may consult the directions given for the dissection of the ligaments of the vertebræ (p. 374).

Dissection.

The *common ligaments* for the bodies of the two bones are an anterior and a posterior, with an intervening fibro-cartilaginous substance. Between the neural arches lie the ligamenta subflava; and between the spines the supra- and interspinous bands are situate. The articular processes are united by capsular ligaments with synovial membranes.

By ligaments as in the vertebræ,

The *sacro-vertebral ligament* is a variable bundle of fibres, which reaches from the under surface of the tip of the transverse process of the last lumbar vertebra to the lateral mass at the base of the sacrum. Widening as it descends, the ligament joins the fibres in front of the sacro-iliac articulation.

and by a special band, sacro-vertebral.

SACRO-COCCYGEAL ARTICULATION. The sacrum and coccyx are united at the centre by a fibro-cartilage, and by an anterior and posterior ligament. There are also lateral and interarticular ligaments on each side.

Union of sacrum and coccyx.

Dissection. Little dissection is needed for these ligaments. When Dissection.

the areolar tissue has been removed altogether from the bones, the ligaments will be apparent.

An anterior and

The *anterior ligament* (sacro-coccygeal) consists of a few fibres that pass between the bones in front of the fibro-cartilage.

a posterior ligament,

The *posterior ligament* is wide at its attachment to the margin of the lower opening of the sacral canal, but narrows as it descends to be inserted into the coccyx.

with a fibro-cartilage.

The *fibro-cartilage* resembles that between the bodies of the other vertebræ, and is attached to the surfaces of the bones.

A band between articular,

Interarticular ligaments. The cornua of the sacrum and coccyx do not usually form joints, but are united by a ligamentous band on each side.

and transverse processes.

The *lateral ligament* passes on each side between the projections representing the transverse processes of the last sacral and first coccygeal vertebræ.

Motion.

Movement. While the coccyx remains unossified to the sacrum, a slight antero-posterior movement will take place between them.

Union of sacrum and hip-bone.

SACRO-ILIAC ARTICULATION. The irregular surfaces by which the sacrum and the hip-bone articulate are covered with cartilage, and are maintained in contact by anterior and posterior sacro-iliac ligaments. Inferiorly the bones are farther connected, without being in contact, by the strong sacro-sciatic ligaments.

To dissect the ligaments.

Dissection. To see the posterior ligaments, the mass of muscle at the back of the sacrum is to be removed on the side on which the hip-bone remains. The thin anterior bands will be visible on the removal of some areolar tissue. The small sacro-sciatic ligament will be brought into view by removing the fleshy fibres of the coccygeus; and the large ligament is dissected with the lower limb.

Anterior ligament.

The *anterior sacro-iliac ligament* consists of a few thin scattered fibres between the bones, near their articular surfaces.

Posterior ligament:

The *posterior sacro-iliac ligament* is very strong, and consists of bundles of fibres which pass obliquely from the rough part of the inner side of the ilium above the auricular surface to the depressions on the back of the first and second pieces of the sacrum. A distinct band, longer and more superficial than the rest, runs from the posterior superior iliac spine to the third and fourth pieces of the sacrum: this is named the *long posterior ligament*.

a special long band.

A layer of cartilage on each bone

Articular cartilage. This may be seen after the sacro-sciatic and ilio-lumbar ligaments have been examined, by opening the articulation and separating the bones. It covers the auricular surfaces of both sacrum and ilium, but is much thicker on the sacrum. Its surface is generally uneven; and the intermediate cleft is sometimes partly interrupted by transverse fibres uniting the two layers.

Use of joint is

Mechanism. There is scarcely any appreciable movement in this articulation, owing to the tightness with which the two bones are bound together by ligaments, and the irregular form of the articular surfaces, which are consequently unable to glide over one another. In the erect posture the sacrum is suspended between the two hip-bones by the thick posterior sacro-iliac ligaments, and the upper arch of the pelvis is thereby rendered less rigid than would be the

to render pelvis elastic.

case if it were formed of continuous bone. The sacro-iliac articulation thus serves to give elasticity to the pelvis, and to diminish the effect of shocks passing to the spine.

TWO SACRO-SCIATIC LIGAMENTS pass from the side of the sacrum and coccyx to the hinder border of the hip-bone, across the space between those bones at the back of the pelvis : they are named great and small.

The *great* or *posterior ligament* (fig. 185, *a*) is attached above to large, the posterior inferior iliac spine, and to the side of the sacrum and coccyx ; and below to the inner margin of the ischial tuberosity, sending forwards a prolongation (*falciform process*) along the ramus of the ischium. It is wide at the sacrum, and gets narrower towards the lower end ; but it is somewhat expanded again at the tuberosity. The relations of this band are seen in the dissection of the buttock (p. 644).

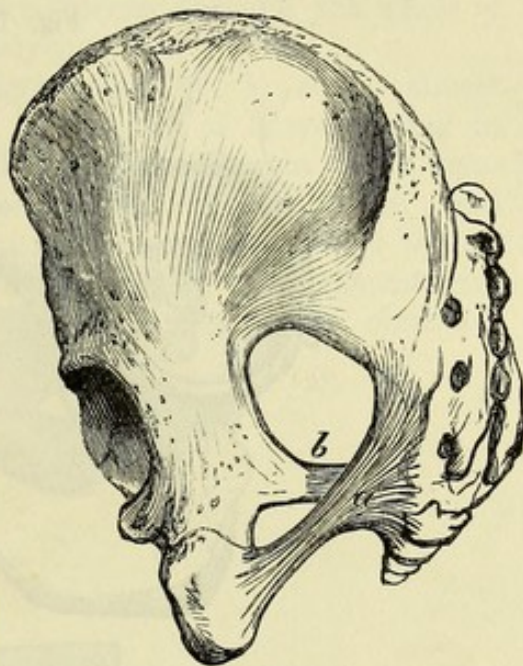
The *small* or *anterior ligament* (fig. 185, *b*) is attached internally by a wide piece to the border of the sacrum and coccyx, where it is united with the origin of the preceding band. The fibres are directed outwards, and are inserted as a narrow band into the ischial spine of the hip-bone. Its deep surface is blended with the coccygeus ; and it may be looked upon as being a fibrous portion of that muscle. Above it is the large sacro-sciatic foramen ; and below it is the small foramen of the same name, which is bounded by the two ligaments.

By their position these ligaments convert into two foramina (sacro-sciatic) the large sacro-sciatic excavation in the dried bones : the openings, and the things they give passage to, are described with the buttock (p. 644).

Use. The sacro-sciatic ligaments, by holding down the lower part of the sacrum, serve to prevent that bone from rotating at the sacro-iliac articulation, under the influence of the weight pressing on its upper end in the erect position.

The ILIO-LUMBAR LIGAMENT is a strong triangular band, which springs by its narrow end from the extremity of the transverse process of the fifth lumbar vertebra. Directed outwards and somewhat backwards, it spreads out to be inserted into the iliac crest for about an inch, opposite the back part of the iliac fossa. To the upper border of the ligament the anterior layer of the fascia lum-

Fig. 185.*



* Sacro-sciatic ligaments : *a*. Large, and *b*. Small.

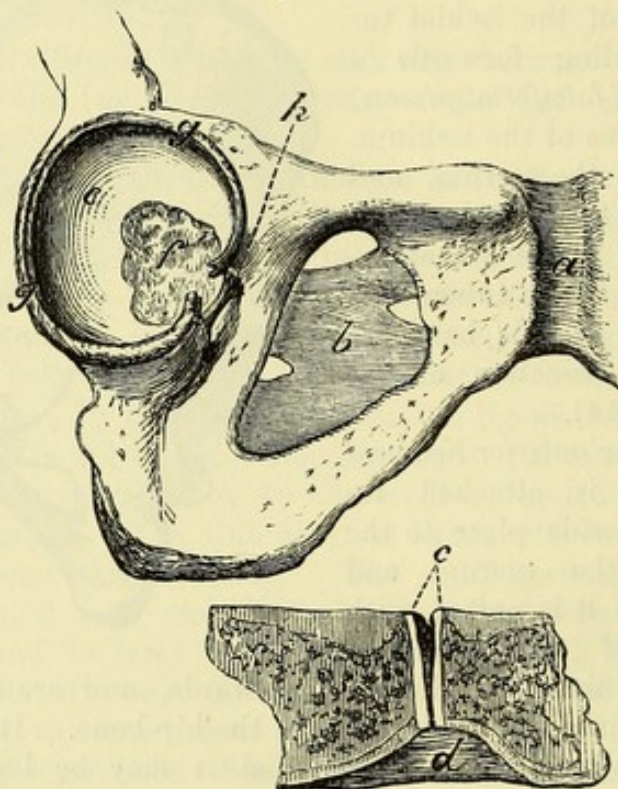
borum is attached ; and its posterior surface is covered by the quadratus lumborum.

Use. This ligament supports the upright moveable portion of the spinal column, and resists the tendency of the last lumbar vertebra to slip forwards over the inclined base of the sacrum.

Symphysis pubis. PUBIC ARTICULATION (symphysis pubis ; fig. 186, *a*). The two pubic bones are united by an interpubic disc, by ligamentous fibres in front and above, and by a strong subpubic ligament.

Anterior ligament. The *anterior pubic ligament* is composed of interlacing fibres

Fig. 186.*



which are mixed with fibres of the tendon of the external oblique muscle.

Few fibres behind, There is not any definite posterior band ; but the periosteum is thickened by a few scattered fibres.

and above. The *superior ligamentous fibres* fill the interval between the bones above the disc.

Subpubic ligament. The *subpubic ligament* (ligamentum arcuatum ; fig. 186, *d*) is a strong triangular band occupying the angular interval between the pubic rami at the lower part of the symphysis. Its apex is continuous with the fibrous portion of the interpubic disc ; its base is free and concave, and forms the summit of the subpubic arch.

* Ligaments of the symphysis pubis, thyroid hole, and acetabulum. *a*. Anterior ligament of the symphysis. *b*. Obturator membrane. *c*. Interpubic disc, with a slit in the middle. *d*. Subpubic ligament. *e*. Surface of the acetabulum covered with cartilage. *f*. Fatty substance in the acetabulum. *g*. Cotyloid ligament, which is cut where it forms part of the transverse band over the notch. *h*. Deep part of the ligament over the cotyloid notch.

Dissection. The disc will be best seen by making a transverse section of the bones, which will show the disposition of the anterior ligament of the articulation, and the thickness of the plate, with its toothed mode of attachment to the bone ; and when another opportunity offers, a vertical section may be made.

How to
show disc.

The *interpubic disc* consists of a layer of cartilage on each side, which is firmly adherent to the ridged surface of the bone, and a fibrous portion in the centre. The fibrous part is thickest in front ; and at the upper and back portion of the symphysis there is generally a fissure, produced by the absorption of the fibrous substance. In some bodies the fissure extends through the whole of the disc, so as to divide it completely into two.

Interpubic
disc :

cleft in it.

The thin **OBTURATOR MEMBRANE** (fig. 186, *b*) closes almost entirely the thyroid foramen, and is composed of fibres crossing in different directions. It is attached to the bony margin of the foramen, except above where the obturator vessels pass through ; and at the lower and inner part of the aperture it is connected to the pelvic aspect of the hip-bone. The surfaces of the ligament give attachment to the obturator muscles. Branches of the obturator vessels perforate it.

Obturator
membrane
closes an
aperture
in front.

TABLE OF THE ARTERIES OF THE ABDOMEN.

The ABDOMINAL AORTA gives off	1. Phrenic . . .	Superior capsular.		
	2. celiac axis*.	<ul style="list-style-type: none"> Coronary . . . { hepatic . . . { splenic . . . { 	<ul style="list-style-type: none"> Œsophageal gastric. Gastro-duodenal . . . { pyloric left hepatic branch right hepatic branch . . . Cystic. pancreatic vasa brevia left gastro-epiploic splenic. 	<ul style="list-style-type: none"> Right gastro-epiploic superior pancreatico-duodenal.
	3. superior mesenteric*.	<ul style="list-style-type: none"> Inferior pancreatico-duodenal intestinal ileo-colic right colic middle colic. 		
	4. middle capsular			
	5. renal . . .	Inferior capsular.		
	6. spermatic			
	7. inferior mesenteric*.	<ul style="list-style-type: none"> Left colic sigmoid superior hæmorrhoidal. 		
	8. lumbar			
	9. middle sacral*			
	10. common iliac .	<ul style="list-style-type: none"> External iliac . . . { internal iliac . . . { 	<ul style="list-style-type: none"> Epigastric . . . { circumflex iliac. Parietal branches . . . { visceral branches . . . { 	<ul style="list-style-type: none"> Pubic cremasteric muscular cutaneous. Ilio-lumbar lateral sacral gluteal . . . { sciatic . . . { pudic . . . { obturator . . . { Middle hæmorrhoidal vesical vaginal uterine.

* The branches marked with an asterisk are single.

TABLE OF THE VEINS OF THE ABDOMEN.

The INFERIOR VENA CAVA receives	1. Common iliac .	Internal iliac .	Visceral branches .	Hæmorrhoidal plexus vesico-prostatic plexus . . uterine vaginal.	{ Vesical dorsal of the penis.
VENA PORTÆ .	2. lumbar 3. right spermatic 4. renal . . . { Right left . . . { Capsular spermatic. 5. right capsular 6. diaphragmatic 7. hepatic veins, which bring blood from the vena portæ.	external iliac . { Epigastric circumflex iliac. ilio-lumbar middle sacral into the left.	parietal branches .	Obturator pudic . . . sciatic . . . gluteal lateral sacral.	{ Veins of corpus cavernosum of the bulb transverse perineal superficial perineal inferior hæmorrhoidal. coccygeal comes nervi ischiadici muscular.
VENA PORTÆ .	superior mesenteric .	Splenic . . .	Splenic branches vasa brevia pancreatic left gastro-epiploic. Inferior mesenteric .	{ Left colic sigmoid superior hæmorrhoidal. intestinal ileo-colic right colic middle colic right gastro-epiploic pancreatico-duodenal. coronary pyloric cystic.	

TABLE OF THE SPINAL NERVES IN THE ABDOMEN.

LUMBAR SPINAL NERVES divide into .	Posterior branches .	Internal . . .	Muscular.
		external . . .	{ Muscular cutaneous.
	Anterior branches: of these the four first end in the LUMBAR PLEXUS, which supplies . . .	Ilio-hypogastric.	{ Iliac branch. hypogastric branch.
		ilio-inguinal . .	{ To integuments of the groin.
		genito-crural . .	{ Genital branch crural branch.
		external cuta- neous . . .	{ To integuments of the thigh.
		anterior crural . .	{ Branches inside the pelvis
			{ To the iliacus muscle to the femoral artery.
		obturator . . .	{ Branches outside the pelvis
			{ are noticed in the thigh.
		Accessory . . .	{ Other offsets are de- scribed in the thigh.
SACRAL SPINAL NERVES divide into	Posterior branches { Muscular unite together and give off { and cutaneous filaments.		
	Terminal branches	Great sciatic . .	described in the lower limb.
		pudic	Inferior hæmorrhoidal
			perineal
			{ Superficial, internal and external muscular to the bulb.
			dorsal of penis.
	The anterior branches of the four superior unite with the lumbo-sacral in the SACRAL PLEXUS,* and furnish . . .	Superior gluteal inferior gluteal small sciatic	{ noticed in the lower limb.
		perforating cutaneous to pyriformis	
		to obturator internus and superior gemellus to quadratus femoris and inferior gemellus	{ noticed in the buttock.
		visceral to levator ani to coccygeus to external sphincter.	

* The other sacral nerves are described at p. 562.

TABLE OF THE SYMPATHETIC NERVE IN THE ABDOMEN.

SOLAR PLEXUS * furnishes the following plexuses	Diaphragmatic	
	coeliac	<div> <div>Coronary plexus</div> <div> <div>hepatic</div> <div>splenic</div> </div> </div> <div> <div>Pyloric</div> <div>right gastro-epiploic</div> <div>pancreatico-duodenal</div> <div>cystic.</div> </div> <div> <div>Left gastro-epiploic</div> <div>pancreatic.</div> </div>
	superior mesenteric	Offsets to small and large intestine.
	suprarenal	
	renal	Spermatic plexus, filaments to the.
	aortic	Hypogastric.
	spermatic	
	inferior mesenteric	<div>Offsets to the large intestine</div> <div>superior hæmorrhoidal.</div>

* This receives

Great splanchnic nerves

small splanchnic nerves

offsets of right pneumo-gastric.

HYPOGASTRIC PLEXUS † ends in the pelvic plexus on each side, which gives the following plexuses	inferior hæmorrhoidal	
	vesical	<div>Prostatic</div> <div>cavernous</div> <div>deferential</div> <div>to vesiculæ seminales.</div>
	uterine	
	vaginal.	

GANGLIATED CORD of the sympathetic in the abdomen supplies	External branches	To the lumbar and sacral spinal nerves.
	internal	<div>To aortic plexus</div> <div>to hypogastric plexus</div> <div>to join round middle sacral artery</div> <div>between the cords on the coccyx, in the</div> <div><i>ganglion impar.</i></div>

† This is joined above by

The aortic plexus

filaments from the lumbar ganglia.

PNEUMO-GASTRIC NERVE IN THE ABDOMEN.

Pneumo-gastric	Right	<div>Coronary branches to the back of the stomach</div> <div>filaments to join the coeliac and splenic plexuses</div>
	left	<div>Coronary branches to the front of the stomach</div> <div>branches to the hepatic plexus.</div>

CHAPTER IX.

DISSECTION OF THE LOWER LIMB.

SECTION I.

THE FRONT OF THE THIGH.

- Directions.** ALL the parts described in SECTION I (to p. 631) are to be examined before the time for turning the body arrives.
- Position of the body.** *Position.* During the dissection of the front of the thigh the body lies on the back, with the buttocks resting on the edge of the table, and with a block of suitable size beneath the loins. The lower limb should be supported in a half-bent position by a stool beneath the foot, and should be rotated outwards to make evident a hollow at the top of the thigh.
- Objects on the surface.** *Surface-marking.* Before any of the integument is removed from the limb, the student is to observe the chief eminences and hollows on the surface of the thigh.
- Limits of the thigh above.** The limit between the thigh and abdomen is marked, in front, by the firm band of Poupart's ligament reaching from the anterior superior spine of the ilium to the pubis. On the outer side, the separation is indicated by the convexity of the iliac crest of the hip-bone, which subsides behind in the sacrum and coccyx. Internally is the projection of the pubis, from which the bony margin of the subpubic arch may be traced backwards, forming the inner boundary of the limb, to the ischial tuberosity.
- Hollow of Scarpa's space.** On the anterior aspect of the thigh, and close to Poupart's ligament, is a slight hollow, corresponding with the triangular space of Scarpa, in which the larger vessels of the limb are contained; and extending thence obliquely towards the inner side of the limb, is a slight depression marking the situation of the femoral artery beneath.
- Groove over femoral artery.** The position of the arterial trunk may be ascertained by a line from the centre of the interval between the symphysis pubis and the anterior superior iliac spine to the inner condyle of the femur.
- Position of great trochanter.** At the outer side of the hip, from three to four inches below and behind the anterior part of the iliac crest, the well-marked projection of the great trochanter of the femur will be recognised. In a thin body the head of the femur may be felt by rotating the limb inwards and outwards, while the thumb of one hand is placed in the hollow below Poupart's ligament, or the fingers behind the great trochanter.
- Head of the femur.**

At the knee the outline of the several bones entering into the formation of the joint may be traced with ease. In front of the joint, when it is half-bent, the rounded prominent patella may be perceived; this bone is firmly fixed while the limb is kept in the bent position, but is moved with great freedom when the joint is extended, so as to relax the muscles inserted into it. On each side of the patella is the projection of the condyle of the femur, but that on the inner side is the larger. If the fingers are passed along the sides of the patella while the joint is half bent, they will be conducted to the tuberosities of the head of the tibia, and to a slight hollow between it and the femur.

Bony
eminences
of knee:
patella;

condyles
of the
femur;

tuberosities
of the tibia.

Behind the joint is a slight depression over the situation of the ham or popliteal space; and on its sides are firm boundaries, which are formed by the tendons (hamstrings) of the flexor muscles of the knee.

The ham
behind.

Dissection. With the limb placed as before directed, the student begins the dissection with the examination of the subcutaneous fatty tissue with its nerves and vessels.

Dissection.

At first the integument is to be reflected only from the hollow on the front of the thigh close below Poupart's ligament. To raise the skin over it, an incision about four inches in length, and only skin deep, is to be made from the pubis along the inner border of the thigh. At the lower end of the first incision, another cut is to be directed outwards across the front of the limb to the outer aspect; and at the upper end the knife is to be carried along the line of Poupart's ligament as far as the crest of the ilium. The piece of skin included by these incisions is to be raised and turned outwards, without taking with it the subcutaneous fat.

Take up
skin at the
top of the
thigh.

The subcutaneous fatty tissue, or the *superficial fascia*, forms a general investment for the limb, and is constructed of a network of areolar tissue, with fat or adipose substance amongst the meshes. As a part of the common covering of the body, it is continuous with that of the neighbouring regions; consequently it may be followed inwards to the scrotum or the labium according to the sex, and upwards on the abdomen. Its thickness varies in different bodies, according to the quantity of fat in it; and when well developed it may be divided into separate layers. Its relations will be made more evident by the following dissection.

Superficial
fascia:

how
formed;

thickness
varies.

Dissection. To reflect the superficial fascia, incisions similar to those made in the skin are to be employed; and the separation from the subjacent structures is to be begun below, where the large saphenous vein, and a condensed or membranous appearance on the under surface, will mark the depth of the stratum. The layer of fat may be thrown outwards readily by a few touches of the knife, when the superficial vessels and inguinal lymphatic glands will come into view.

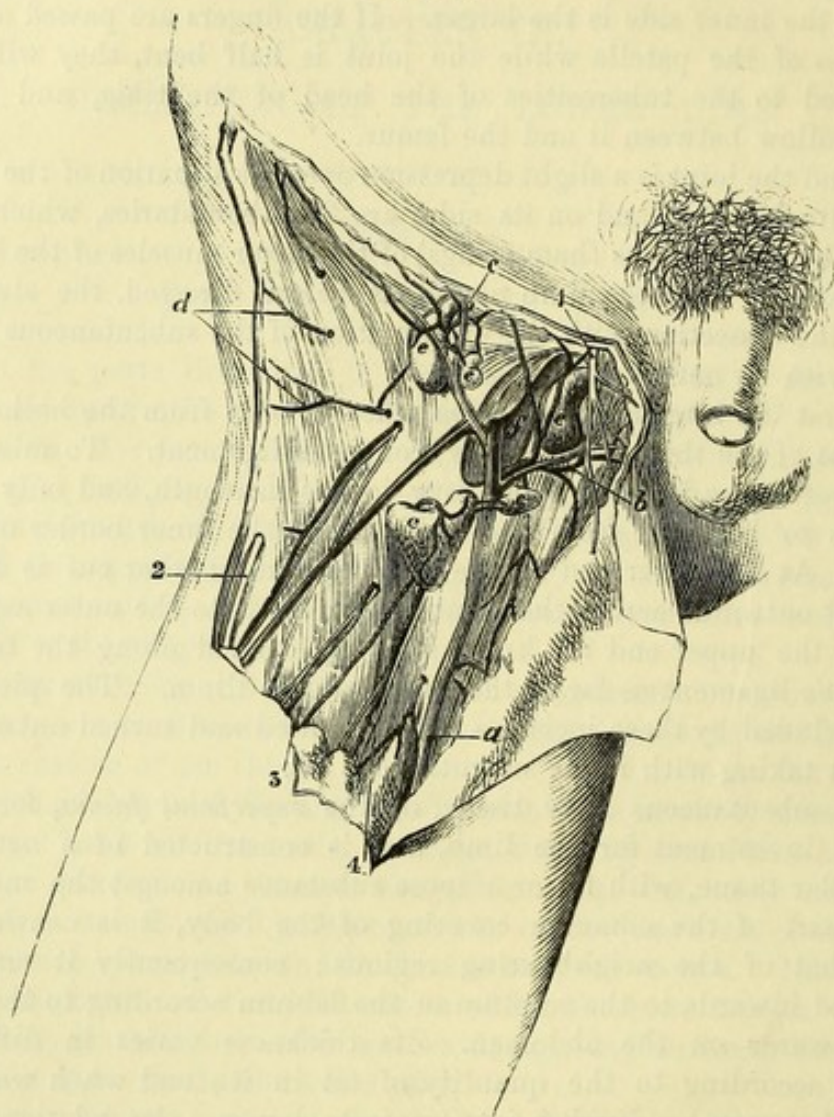
To raise the
superficial
fascia.

The *subcutaneous layer* decreases in thickness, and becomes more fibrous near Poupart's ligament; and at its under aspect it has a smooth and membranous surface. It conceals the superficial vessels and the inguinal glands, and is separated by these from Poupart's ligament.

Relations of
superficial
fascia.

Dissection *Dissection* (fig. 187). The inguinal glands and the superficial vessels are to be next cleaned by the removal of any surrounding fat; but the student is to be careful not to destroy a deeper, very thin layer of areolar tissue which is beneath them, and is visible on the inner side of the centre of the limb. Three sets of vessels are

Fig. 187.*



to see the
superficial
vessels.

to be dissected out:—One set (artery and vein) is directed inwards to the pubes, and is named external pudic; another, superficial epigastric, ascends over Poupart's ligament; and the third, the superficial circumflex iliac, appears at the outer part of the limb. The large vein towards the inner side of the thigh, to which the branches converge, is the internal saphenous.

ymphatics,

Some of the small lymphatic vessels may be traced from one inguinal gland to another.

* Dissection of the superficial parts of the thigh (Illustrations of Dissections). *Vessels*: *a*. Internal saphenous vein. *b*. Superficial pudic. *c*. Superficial epigastric. *d*. Superficial circumflex iliac. *e*. Inguinal glands. *f*. Saphenous opening. *Nerves*: 1. Ilio-inguinal. 2. External cutaneous. 3. Genito-crural. 4. Middle cutaneous. Small unnamed vessels accompany the different nerves to the integuments.

A small nerve, the ilio-inguinal, is to be sought on the inner side of the saphenous vein, close to the pubis; and a branch of the genito-crural nerve may be found a little outside the vein.

SUPERFICIAL VESSELS. The small cutaneous arteries at the top of the thigh are the first branches of the femoral trunk, they pierce the deep fascia (fascia lata), and are distributed to the integuments and the glands of the groin and neighbourhood.

The **EXTERNAL PUDIC ARTERY** (superior; fig. 187, *b*) crosses the spermatic cord in its course inwards, and ends in the integuments of the penis and scrotum, where it anastomoses with offsets of the internal pudic artery.

Another external pudic branch (inferior; p. 612) pierces the fascia lata at the inner border of the thigh, and ramifies also in the scrotum. In the female both branches supply the labium pudendi.

The **SUPERFICIAL EPIGASTRIC ARTERY** (*c*) passes over Poupart's ligament to the abdomen (p. 438), and communicates with branches of the deep epigastric artery.

The **SUPERFICIAL CIRCUMFLEX ILIAC ARTERY** (*d*) is the smallest of the three branches: appearing as two or more pieces at the upper part of the thigh near the iliac crest, it is distributed in the integuments: it supplies an offset with the external cutaneous nerve.

A vein accompanies each artery, having the same name as its companion vessel, and ends in the upper part of the saphenous vein, with the exception of that with the inferior pudic artery: these veins will be noticed subsequently (p. 602).

The **SUPERFICIAL INGUINAL GLANDS** (*e*) are arranged in two lines. One set lies across the thigh, near Poupart's ligament; and the other is situate along the side of the saphenous vein. In the lower or femoral group the glands are larger than in the upper, and the lymphatic vessels from the surface of the lower limb enter them. The upper or abdominal group is joined by the lymphatics of the penis, by those of the surface of the abdomen, and by those of the buttock. The glands vary much in number and size; and not unfrequently some of the longitudinal set by the side of the vein are blended together.

Cribriform fascia. Beneath, and to the inner side of, the internal saphenous vein there is a thin layer of areolar tissue on the surface of the fascia lata, which is sometimes described as a special deeper layer of the superficial fascia. This stratum is continued across the aperture in the deep fascia (saphenous opening; fig. 187, *f*) through which the vein disappears; and being there perforated by many large lymphatic vessels, as well as by the saphenous vein, the name cribriform fascia has been given to this part. The cribriform fascia is closely united to the outer margin of the saphenous opening; and it is also adherent to the subjacent crural sheath of the vessels in the aperture. In a hernial protrusion through the saphenous opening, the cribriform fascia is stretched and pushed forwards by the tumour, and forms one of the coverings.

Dissection. Now the student has observed the disposition of the superficial fascia near Poupart's ligament, he may proceed to ex-

The arteries from the femoral.

One external pudic artery;

another beneath the fascia.

Superficial epigastric.

Superficial circumflex iliac.

Veins join the saphenous.

Inguinal glands: two sets,

which receive different lymphatics.

Cribriform fascia is

an areolar membrane over saphenous opening:

relation to femoral hernia.

Dissection of the front of the thigh.

amine the remainder of the subcutaneous covering of the thigh, together with the vessels and nerves in it.

Take away
the skin,

To raise the skin from the front of the thigh, a cut is to be carried along the centre of the limb, over the knee-joint, to rather below the tubercle of the tibia. At the extremity of this a transverse incision is to be made across the front of the leg, but this is to reach farthest on the inner side. The skin may be reflected in flaps inwards and outwards; and as it is raised from the front of the knee, a superficial bursa between it and the patella will be opened.

and follow
saphenous
vein.

The saphenous vein is to be first traced out in the fat as far as the skin is reflected, but in removing the tissue from it the student should be careful of branches of the internal cutaneous nerve.

Seek cutane-
ous nerves
of front of
thigh,

The cutaneous nerves of the front of the thigh (fig. 188) are to be sought in the fat, with small cutaneous arteries, in the following positions:—On the outer margin, below the upper third, is placed the external cutaneous nerve. In the middle of the limb, below the upper third, lie the two branches of the middle cutaneous nerve. At the inner margin are the ramifications of the internal cutaneous nerve,—one small offset appearing near the upper part of the thigh, one or more about half-way down, and one of the terminal branches (anterior) about the lower third.

and on side
of the knee.

On the inner side of the knee three other cutaneous nerves are to be looked for:—One, a branch of the great saphenous, is directed outwards over the patella. Another, the trunk of the great saphenous nerve, lies by the side of the vein of the same name, close to the lower edge of the surface now dissected. And the third is a terminal branch (posterior) of the internal cutaneous nerve, which is close behind the preceding, and communicates with it.

Superficial
veins.

VESSELS. All the cutaneous veins on the anterior and inner aspects of the thigh are collected into one; and this trunk is named saphenous from its manifest appearance on the surface.

Internal
saphenous
vein in
thigh

The INTERNAL SAPHENOUS VEIN (fig. 187, *a*) is the cutaneous trunk of the inner side of the lower limb, and extends from the foot to the top of the thigh. In the part of its course now dissected, the vessel lies inferiorly somewhat behind the knee-joint; but as it ascends to its termination, it is directed along the inner side and the front of the thigh. Near Poupart's ligament it pierces the fascia lata by a special opening named saphenous, and enters the deep vein (femoral) of the limb.

pierces
fascia lata
to join the
femoral.

Veins join-
ing it

Superficial branches join it both externally and internally; and near Poupart's ligament the three veins corresponding with the arteries in that situation, viz., external pudic (*b*), superficial epigastric (*c*), and circumflex iliac (*d*), terminate in it. Towards the upper part of the limb the veins of the inner side and back of the thigh are frequently united into one branch, which enters the saphenous trunk near the aperture in the fascia lata; and sometimes those on the outer side of the thigh are collected together in a similar way. When this arrangement exists three large veins will be present on the front of the thigh, near the saphenous opening.

may form
three trunks
at the top
of the thigh.

On the side of the knee the vein receives a communicating branch from the deep veins.

Some unnamed *cutaneous arteries* are distributed to the integuments along with the nerves; and the superficial branch of the anastomotic artery (p. 618) accompanies the saphenous nerve and its branches near the knee.

NERVES. The cutaneous nerves of the thigh are derived from branches of the lumbar plexus, and in greater number on the inner than the outer side.

ILIO-INGUINAL. This nerve (p. 536) is small, and reaches the surface by passing through the external abdominal ring (fig. 187,¹); it supplies the scrotum, and ends on the adjacent part of the thigh, internal to the saphenous vein.

GENITO-CRURAL. The *crural branch* of this nerve (p. 536) pierces the fascia lata near Poupart's ligament (fig. 188,⁶), rather external to the line of the femoral artery. After or before the nerve has become superficial it communicates with the middle cutaneous nerve; and it extends on the anterior aspect of the thigh as far as midway between the knee and the pelvis.

Occasionally this branch is of large size, and takes the place of the external cutaneous nerve on the outer side of the limb.

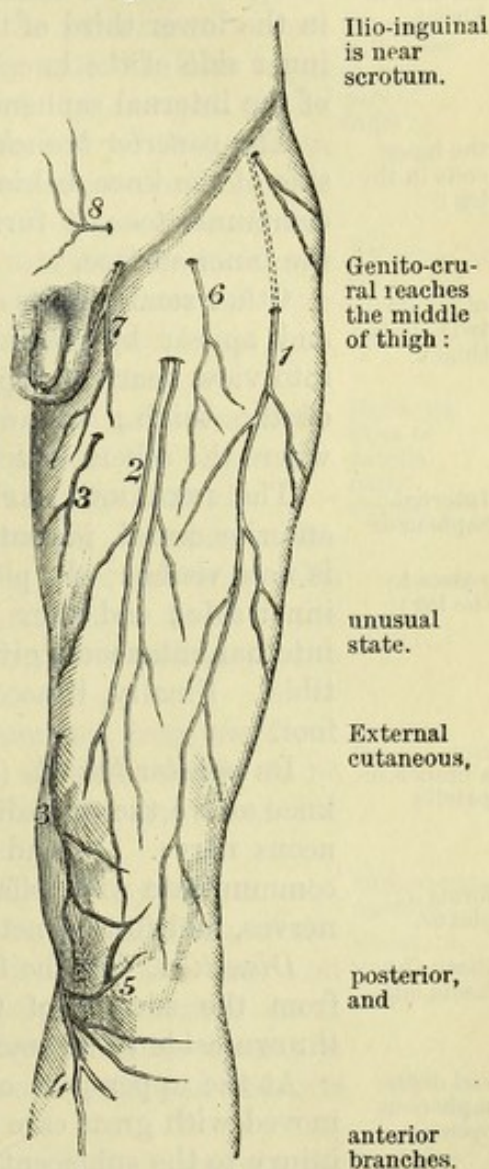
The **EXTERNAL CUTANEOUS NERVE** (p. 536) ramifies on the outer aspect of the limb (fig. 188,¹). At first it is contained in a prominent ridge of the fascia lata on the outer margin of the thigh, where it divides into an anterior and a posterior branch.

The posterior branch subdivides into two or three others, which arch backwards to supply the integuments of the outer side of the thigh as low as the middle.

The anterior branch appears on the fascia lata about four inches from Poupart's ligament and is continued to the knee below the other; it distributes branches laterally, but those towards the posterior surface are more numerous, and larger.

MIDDLE CUTANEOUS (fig. 188,²). The nerve of the centre of the thigh is a cutaneous offset of the anterior crural (p. 622), and divides into two branches. It is transmitted through the fascia lata about three inches from Poupart's ligament, and its branches reaches the knee.

Fig. 188.*



Cutaneous arteries.

Cutaneous nerves.

Ilio-inguinal is near scrotum.

Genito-crural reaches the middle of thigh:

unusual state.

External cutaneous,

posterior, and

anterior branches.

* Cutaneous nerves on the front of the thigh. 1. External cutaneous. 2. Middle cutaneous. 3. Internal cutaneous. 4. Internal saphenous. 5. Patellar branch of saphenous. 6. Genito-crural. 7. Ilio-inguinal. 8. Ilio-hypogastric on the belly.

are continued to the knee. In the fat this nerve is united with the genito-crural and internal cutaneous nerves.

Internal cutaneous :

INTERNAL CUTANEOUS. Derived from the anterior crural trunk, this nerve is furnished to the inner side of the thigh and leg. It is divided into two branches (anterior and posterior) which perforate the fascia at separate places.

the anterior branch

The *anterior branch* becomes cutaneous in the lower third of the thigh, in the line of the inner intermuscular septum (fig. 188, ³), along which it is continued to the knee. This branch is distributed in the lower third of the thigh, as well as over the patella and the inner side of the knee-joint, and is united with the patellar branch of the internal saphenous nerve.

extends to knee ;

the inner ends in the leg ;

The *posterior branch* (fig. 203, ⁸) perforates the fascia on the inner side of the knee, behind the internal saphenous nerve, with which it communicates ; it furnishes offsets to the upper half of the leg, on the inner surface.

other small twigs to the thigh.

Other small offsets of the nerve supply the inner side of the thigh, and appear by the side of the saphenous vein. One or two come into view near the top of the vein, and reach as far as the middle of the thigh ; and one, larger than the rest, becomes cutaneous where the others cease, and extends as far as the knee.

Internal saphenous

passes to the leg :

The INTERNAL SAPHENOUS NERVE (fig. 188, ⁴), a branch of the anterior crural, is continued to the foot, but only a small part of it is now visible. It pierces the fascia close below the knee on the inner side ; and after communicating with the inner branch of the internal cutaneous, gives forwards some offsets over the head of the tibia. Finally, it accompanies the saphenous vein to the leg and foot.

a branch on patella

Its *patellar branch* (fig. 188, ⁵) appears on the inner side of the knee above the preceding, and is soon joined by the internal cutaneous nerve. It ends in many branches over the patella ; these communicate with offsets from the middle and internal cutaneous nerves, and form a network (*patellar plexus*) over the joint.

forms a plexus.

Clean the fascia lata,

Dissection. Let the fat and the inguinal glands be now removed from the surface of the fascia lata, the cutaneous nerves being thrown aside to be traced afterwards to their trunks.

and define saphenous opening.

At the upper part of the thigh the cribriform fascia is to be removed with great care so as to show the saphenous opening, without injury to the subjacent crural sheath ; and on the outer side of the aperture a semilunar border is to be defined by dividing the fibrous bands that unite it to the front of the sheath.

Fascia lata surrounds limb.

The FASCIA LATA is the deep aponeurosis of the thigh. It is of a bluish-white colour, and surrounds the limb with a firm sheath ; but in fat bodies it is sometimes so slight as to be taken away with the subcutaneous fat.

Ilio-tibial band.

It is strongest on the outer aspect of the limb, where it receives the insertion of the tensor vaginae femoris, and most of the gluteus maximus muscle. This thickened part (*ilio-tibial band*) is attached above to the hip-bone, and below to the outer tuberosity of the tibia, and helps to keep the knee-joint straight in standing.

Numerous apertures exist in the fascia for the transmission of the cutaneous nerves and vessels ; and the largest hole is near Poupart's ligament, to permit the passage of the internal saphenous vein.

Apertures
in fascia.

Processes prolonged from the deep surface form septa between, and fibrous sheaths around, the several muscles. Two of the processes are larger than the rest, and are named outer and inner inter-muscular septa of the thigh : they are fixed to the femur, so as to limit on the sides the extensor of the knee. The position of these partitions is marked by white lines on the surface.

Processes
between the
muscles.

At the top of the thigh the fascia is fixed to the prominent borders of the pelvis. Thus, it is connected externally with the iliac crest, and internally with the body of the pubis and the margin of the pubic arch. Behind, it is joined to the lower end of the sacrum and coccyx ; and in front, to Poupart's ligament between the pubis and the iliac crest. Behind the knee-joint the fascia passes uninterruptedly to the leg ; but in front of the articulation it blends with an expansion from the extensor muscle, and is continued over the joint and the patella, though separated from that bone by a bursa, to be inserted into the heads of the tibia and fibula.

Connected
with bone
at upper
part of
thigh :

difference at
lower part.

On each side of the patella is a band of almost transverse fibres (retinaculum), which is attached to and supports the knee-cap. The outer, thick and strong, is continuous externally with the ilio-tibial band, and joins the insertion of the vastus externus at its attachment to the patella : it guides the patella outwards when the joint is bent. The inner band, of slight strength, is fixed to the patella lower than the other, and unites with the insertion of the inner vastus.

Bands on
sides of
patella,
outer
strong,

inner
weak.

Directions. The flaps of skin which were removed from the front of the thigh, to follow the cutaneous vessels and nerves, are to be now stitched together to keep moist the subjacent parts ; and the saphenous opening is to be learnt.

Replace
flaps of skin.

The *saphenous opening* in the fascia lata (fig. 187, *f*) is an oval aperture, which is situate rather internal to the middle line of the thigh. It measures about half an inch in width, and one inch and a half in length. Its upper extremity (superior cornu) is at Poupart's ligament ; and its lower extremity (inferior cornu) is distant from that structure about one inch and a half, and presents (when dissected) a well-defined margin.

Saphenous
opening :
situation,
and
size ;

Internally, the saphenous opening has not any distinct margin, for the membrane here (called the *pubic portion of the fascia lata*) is continued outwards over the subjacent muscle (pectineus), and behind the femoral vessels, to form the back of the crural sheath.

no defined
border on
inner side ;

Externally, the fascia lata (*iliac part*) forms a semilunar border, when detached, the concavity of which is turned downwards and inwards. This edge is named from its shape *falciform margin* of the saphenous opening (falciform process of Burns) ; it is superficial to the femoral vessels, and is connected by fibrous bands to the crural sheath, and to the cribriform fascia. Traced upwards, the outer edge blends with the base of Gimbernats's ligament (part of Poupart's

on outer
side the
falciform
margin,

which joins
Gimbernats's
ligament,

and forms
femoral
ligament;
tenseness of
the margin
varies.

ligament) : the upper end of this border, where it is internal to the subjacent femoral vein, has been named the *femoral ligament*.

The rigidity of the margin of the opening is much influenced by the position of the limb; for with the finger beneath the upper part of the falciform border, while the thigh is moved in different directions, this band will be perceived to be most unyielding when the limb is extended and rotated out, and most relaxed when the thigh is bent and turned in the opposite direction.

Parts
transmitted
through the
opening.

Through the lower cornu of the opening the saphenous vein is transmitted; and through the upper part, close to the falciform edge, a femoral hernia projects. Lymphatics and one or two superficial arteries also pass through it.

PARTS CONCERNED IN FEMORAL HERNIA.

Anatomy of
femoral
hernia.

To understand the anatomy of a hernial protrusion in the thigh, the dissector has to study the undermentioned parts, viz., the crural arch and Gimbernat's ligament, the crural sheath with its crural canal and ring, together with a partition (*septum crurale*) between the thigh and the abdomen.

Dissection
for femoral
sheath.

Dissection (fig. 189). To examine Poupart's ligament and the membranous sheath round the femoral vessels, the piece of the fascia lata outside the saphenous opening is to be reflected inwards by the following incisions:—One cut is to be begun near the upper end of the falciform border, and to be carried outwards for one inch and a half, parallel and close to Poupart's ligament. Another is to be directed obliquely downwards and inwards from the termination of the first, to a little below the inferior cornu of the opening. When the fascia marked out by those incisions has been raised and turned inwards, and the fat removed, the tube on the vessels (crural sheath) will be brought into view as it descends beneath Poupart's ligament.

Define
sheath.

With the handle of the scalpel the crural sheath is to be separated carefully from Poupart's ligament in front, and from Gimbernat's ligament on the inner side.

Crural
arch:
attach-
ments;
form;

Poupart's ligament or the *crural arch* (fig. 189, c) is the firm band of the aponeurosis of the external oblique muscle of the abdomen, which stretches from the front of the iliac crest to the pubis (p. 443). When viewed on the surface the arch is curved downwards towards the limb, so long as the fascia lata remains on the thigh. The outer half is oblique. But the inner half is almost horizontal, and widens as it approaches the pubis, where it is inserted into the pubic spine and pectineal line of the hip-bone, forming Gimbernat's ligament.

parts closing
hollow
beneath.

The space between the crural arch and the hip-bone is larger in the female than in the male, and is closed by parts passing from the abdomen to the thigh. The outer half of the interval is filled by the psoas and iliacus muscles, between which is the anterior crural nerve, while the external cutaneous nerve lies on the iliacus near the

anterior superior iliac spine : in this part Poupart's ligament is closely bound down to the muscle by its attachment to the iliac fascia. The inner half is occupied by the femoral vessels and their sheath, with the upper end of the pectineus muscle ; the crural branch of the genito-crural nerve issues on the outer side of the artery.

Gimbernat's ligament, or the piece of the tendon of the external oblique muscle which is inserted into the pectineal line, is about three-fourths of an inch in length, and is triangular in shape. Its apex is at the pubic spine ; while its base is in contact with the crural sheath, and is joined by the femoral ligament of the fascia lata. By one margin (anterior) it is continuous with the crural arch, and by the opposite it is fixed to the pectineal line. In the erect position of the body the ligament is almost horizontal. Gimbernat's ligament :
form and relations.

The *crural sheath* (fig. 189, B) is a loose tube of membrane around the femoral vessels. It has the form of a funnel, sloped unequally on the sides. The wide part of the tube is upwards ; and the narrow part ceases about two inches below Poupart's ligament, by blending with the common areolar sheath of the blood-vessels. Its outer border is nearly straight, and is perforated by the genito-crural nerve (¹). Its inner border is oblique, and is pierced by lymphatics, superficial vessels, and the saphenous vein (*f*) ; this part of the sheath appears in the saphenous opening, and is connected to the falciform margin and the cribriform fascia. In front of the crural sheath is the iliac part of the fascia lata. Crural sheath :
shape and relations ;

The sheath is continuous with the fasciæ of the abdomen and thigh in this way ;—the anterior part is a prolongation of the transversalis fascia beneath Poupart's ligament ; and the posterior part is formed externally by the iliac fascia covering the psoas muscle, and internally by the pubic part of the fascia lata covering the pectineus. how formed.

Crossing the front of the sheath, beneath the arch of Poupart's ligament, is a fibrous band, the *deep crural arch*. It is noticed in the description of the transversalis fascia (p. 452). Deep crural arch.

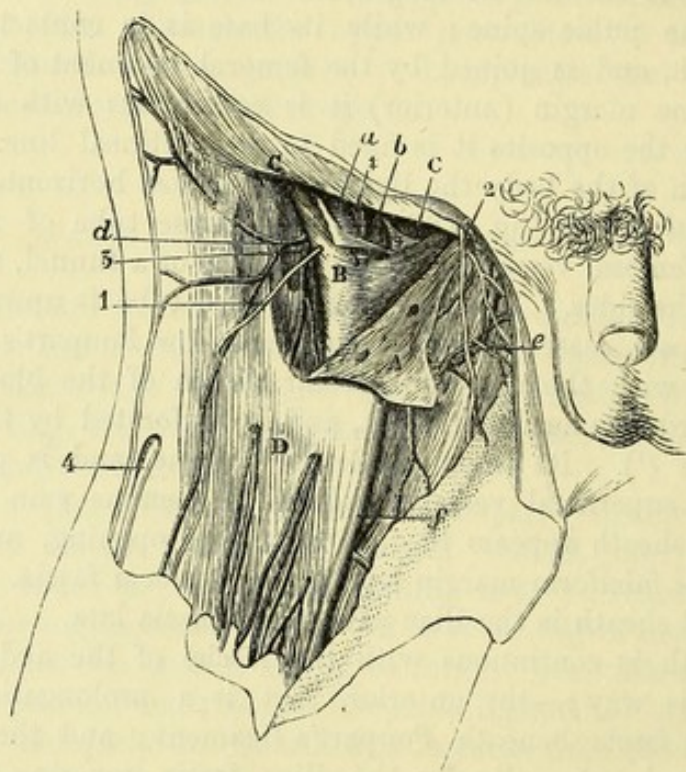
Dissection (fig. 189). The student is to open the sheath by an incision across the front, and to raise the anterior part with hooks. Inside the tube are contained the femoral vessels, each surrounded by its covering of areolar tissue, together with an inguinal gland ; and if a piece of the areolar casing be cut out over both the artery and the vein, there will be an appearance of two thin partitions, the one being situate on the inner side of the vein, separating this vessel from the gland, and the other (†) between the vein and the artery. Open the crural sheath.
Vessels have areolar sheath.

Interior of the crural sheath (fig. 189). The sheath is said to be divided into three compartments by two partitions ; and the position of the so-called septa has been before referred to,—one being internal to the femoral vein, and the other between the two large vessels. In the outer compartment is contained the femoral artery (*a*), lying close to the side of the sheath ; in the middle one is placed the femoral vein (*b*) ; and in the inner space (crural canal) only a lymphatic gland (*c*) is situate. Contents of crural sheath.
Space divided into three :

the inner is
the crural
canal;

The *crural canal* (fig. 189) is the innermost space in the interior of the crural sheath :—Its length is about a third of an inch, and it reaches from the base of Gimbernath's ligament to the upper cornu of the saphenous opening. It decreases rapidly in size from above down, and is closed below. The aperture by which the space communicates with the cavity of the abdomen is named the crural ring.

Fig. 189.*



parts
around it.

In front of the canal are Poupart's ligament and the upper end of the falciform margin of the saphenous opening; while behind it is the pectineus muscle. On the outer side of the canal, but in the sheath, is the femoral vein. Through this channel the intestine passes from the abdomen in femoral hernia.

Crural ring:

The *crural ring* is the upper opening of the crural canal. It is on a level with the base of Gimbernath's ligament (fig. 143, D), and is larger in the female than in the male. Oval in shape, its greatest measurement is from side to side, in which direction it equals about half an inch; and it is filled by a lymphatic gland.

situation
and form;

boundaries.

The structures around the ring, outside the crural sheath, are similar to those bounding the canal, viz., in front, the superficial and the deep crural arch, and behind, the pubis covered by the

* Dissection of the crural sheath (Illustrations of Dissections). A. Iliac part of the fascia lata, reflected. B. Crural sheath, opened. C. Poupart's ligament. D. Fascia lata of the thigh in place. ‡. Two septa dividing the space of the crural sheath into three compartments. Vessels: a. Femoral artery, and b. Femoral vein, enclosed in the crural sheath with c. A lymphatic gland. d. Superficial circumflex iliac. e. Superficial pudic. f. Saphenous vein. Nerves: 1. Genito-crural. 2. Ilio-inguinal. 4. External cutaneous.

pectineus muscle. Internally is Gimbernat's ligament with the conjoined tendon; and externally (but within the sheath) is the femoral vein. The position of vessels on the several sides of the ring is stated at page 464.

Septum crurale. That part of the subperitoneal fatty layer which is placed over the crural ring has been named crural septum from its position between the thigh and abdomen (Cloquet). The situation of the septum is now visible, but its characters are ascertained in the dissection of the abdomen (p. 463).

Crural septum :
position ;
how formed.

FEMORAL HERNIA. In this kind of hernia there is a protrusion of intestine into the thigh beneath Poupart's ligament. And the gut descends in the crural sheath, being placed on the inner side of the vein.

Femoral hernia.
Definition.

Course. At first the intestine takes a vertical direction in its progress from the abdomen, and passes through the crural ring, and along the crural canal as far as the saphenous opening. At this spot it changes its course, and is directed forwards to the surface of the thigh, where it becomes elongated transversely; and should the gut protrude still farther, the tumour ascends on the abdomen, in consequence of the resistance being less in this direction than on the front of the thigh.

Course ;
first vertical,
next forwards,
and then upwards.

The winding course of the hernia may suggest to the dissector the direction in which attempts should be made to replace the intestine in the abdominal cavity. With the view of making the bowel retrace its course, it will be necessary, if the protrusion is small, to direct it backwards and upwards; but if the hernia is large, it must be pressed down first to the saphenous opening, and afterwards backwards and upwards towards the crural canal and ring.

How it is
to be pushed
back.

During the manipulation to return the intestine to its cavity, the thigh is to be raised and rotated inwards, in order that the margin of the saphenous opening and the other structures may be relaxed.

Coverings. As the intestine protrudes it is clothed by the following layers, which are elongated and pushed before it from within outwards. First is a covering of the peritoneum lining the abdomen, which forms the hernial sac. Next one from the septum crurale across the crural ring. Afterwards comes a stratum from the crural sheath, unless the hernia bursts through an aperture in the side. Over this is spread a layer of the cribriform fascia. And, lastly, there is an investment of the superficial fat or fascia, together with the skin.

Coverings
from peri-
toneum,
crural sep-
tum, crural
sheath,

cribriform
fascia, fat
and skin.

The coverings may vary, or may be conjoined in different degrees according to the condition of the hernia. In some instances the prolongation from the crural sheath is wanting. Farther, in an old hernia the covering derived from the septum crurale is united usually with that from the crural sheath, so as to form one layer, the *fascia propria* (Cooper). In general, in an operation for the relief of the strangulated bowel, the surgeon, after dividing the subcutaneous fat, can recognise but little of the coverings enumerated by anatomists until he meets with that of the subperitoneal fat or septum crurale.

The cover-
ings may
altered.

Tumour, how known.	<i>Diagnosis.</i> This hernial tumour is generally smaller than inguinal, and does not extend into the scrotum in the male, or the labium in the female ; and if its neck can be traced below Poupart's ligament, it can be distinguished certainly from an inguinal hernia.
Place of stricture.	<i>Seat of stricture and division of it.</i> The strangulation of a femoral hernia may be situate either outside or inside the neck of the sac.
How to cut the external	The external stricture may be found opposite the margin of the saphenous opening, or deeper in, opposite Poupart's ligament. It may be removed by cutting down on the neck of the tumour at the inner side, and dividing the constricting band arching over the neck of the hernia in this situation, without opening the sac.
and the internal stricture.	The stricture inside the neck of the sac is occasioned by the thickening of the peritoneum. For its relief the neck of the sac is to be laid bare, as if there was an external stricture ; and if the intestine cannot be passed into the abdomen after division of all resisting bands on the exterior of the neck, the sac of the peritoneum is to be opened ; and a director having been introduced through the constriction, a cut is to be made horizontally inwards for the extent of one or two lines. The several vessels that may be wounded in attempting to relieve the deep stricture are enumerated at page 465.

SCARPA'S TRIANGULAR SPACE.

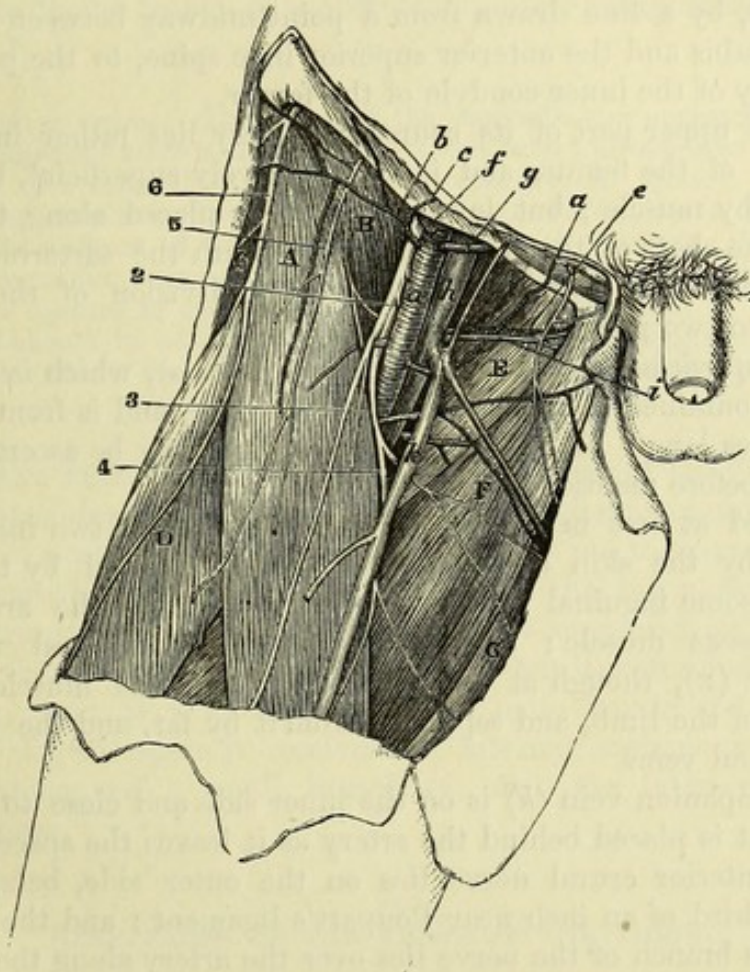
Triangular space.	This hollow is situate on the front of the thigh, and lies beneath the superficial depression observed near Poupart's ligament.
Clean out Scarpa's space.	<i>Dissection</i> (fig. 190). The space will appear on removing the fascia lata near Poupart's ligament. The muscular boundaries on the sides may be first dissected, and the muscle on the outer side (sartorius) should be fixed in place with stitches. Afterwards the remains of the crural sheath are to be taken away ; and the femoral vessels are to be followed downwards as far as the sartorius muscle.
Follow vessels,	On the outer side of the vessels clean the divisions of the anterior crural nerve, together with the branches of an artery (profunda), which are buried in the fat. In removing the fat from beneath the femoral artery, the student is to look for one or two small nerves to the pectineus muscle.
seek nerves,	
take away fat.	
Contents,	SCARPA'S TRIANGLE (fig. 190) is an intermuscular space containing the trunks of the blood-vessels of the thigh, and the anterior crural nerve, with lymphatics and fat. It extends commonly over the upper third of the thigh ; but the length varies with the breadth of the sartorius, and the height at which this muscle crosses inwards.
extent,	
base and sides,	The base of the space is at Poupart's ligament ; externally it is bounded by the inner border of the sartorius ; and internally by the inner border of the adductor longus.
roof and floor.	Towards the surface it is covered by the fascia lata, and by the integuments with inguinal glands and superficial vessels. The floor slopes backwards on each side towards the middle ; it is constructed externally, where it is of small extent, by the conjoined psoas and

iliacus (B); and internally by the pectineus and adductor longus muscles (E and F); and between and beneath these, near the large vessels, is a small piece of the adductor brevis.

The femoral artery runs through the deepest part of the hollow, lying slightly outside the centre of the space, and supplies small cutaneous offsets, as well as a large deep branch, the profunda: a small offset (external pudic) is directed from it to the scrotum across the inner boundary. On the inner side of the artery and close to it

Position of
femoral
artery;

Fig. 190.*



is placed the femoral vein, which is here joined by the saphenous of vein; and profunda branches. About a third of an inch external to the vessel is situate the large anterior crural nerve, which lies deeply at

of anterior
crural nerve.

* Dissection of Scarpa's triangular space (Illustrations of Dissections).
Muscles: A. Sartorius. B. Iliacus. c. Tensor fasciæ latæ. D. Rectus femoris. E. Pectineus. F. Adductor longus. g. Gracilis. *Vessels:* a. Femoral artery. b. Superficial circumflex iliac. c. Superficial epigastric. e. External pudic (inferior). f. Deep circumflex iliac. g. Deep epigastric. h. Femoral vein. i. Inferior external pudic vein. k. Internal saphenous vein. *Nerves:* The large anterior crural is close outside the artery. 2. Offset to the pectineus. 3. Middle cutaneous. 4. Internal cutaneous. 5. Genito-crural. 6. External cutaneous.

first between the iliacus and psoas, but afterwards becomes more superficial and divides into branches.

Lymphatics. Deep lymphatics accompany the femoral vessels, and are continued into the iliac glands in the abdomen; they are joined by the superficial lymphatics.

Femoral artery: extent; course; **FEMORAL ARTERY** (fig. 192). This vessel is a continuation of the external iliac, and reaches from the lower border of Poupart's ligament to the opening in the adductor magnus muscle; at that spot it passes into the ham, and takes the name popliteal. Occupying three-fourths of the length of the thigh, the course of the vessel will be indicated, during rotation outwards of the limb with the knee-joint half bent, by a line drawn from a point midway between the symphysis pubis and the anterior superior iliac spine, to the prominent tuberosity of the inner condyle of the femur.

position to femur and parts around; In the upper part of its course the artery lies rather internal to the head of the femur, and is comparatively superficial, being uncovered by muscle; but lower down it is placed along the inner side of the shaft of that bone, and is beneath the sartorius muscle. This difference in its relations allows of a division of the arterial trunk into two portions, superficial and deep.

division into two. **Superficial portion:** The *superficial part of the artery* (fig. 190, *a*), which is now laid bare, is contained in Scarpa's triangular space, and is from three to four inches long. Its position in that hollow may be ascertained by the line before mentioned.

relations to parts around; Encased at first in the crural sheath for about two inches, it is covered by the skin and the superficial fascia, and by the fascia lata and some inguinal glands. At its beginning the artery rests on the psoas muscle; and it is subsequently placed over the pectineus (*E*), though at some distance from the muscle in this position of the limb, and separated from it by fat, and the profunda and femoral veins.

position of vein and nerves. Its companion vein (*h*) is on the inner side and close to it at the pubis, but is placed behind the artery as it leaves the space.

The anterior crural nerve lies on the outer side, being distant about a third of an inch near Poupart's ligament; and the internal cutaneous branch of the nerve lies over the artery along the edge of the sartorius. Crossing beneath the vessels is the nerve of the pectineus (*2*).

Unusual position. *Unusual position.* A few examples of transference of the main artery of the limb from the front to the back of the thigh have been recorded. In these cases the vessel passed from the pelvis through the great sacro-sciatic foramen, and accompanied the great sciatic nerve to the popliteal space.

Branches:— The *branches* of the artery in Scarpa's space are the superficial epigastric and circumflex iliac, two external pudic, and the deep femoral branch. The cutaneous offsets have been seen (p. 601), with the exception of the following, which lies at first beneath the fascia lata.

An external pudic. The *inferior external pudic artery* (fig. 190, *e*) arises separately from, or in common with, the other pudic branch. It courses in-

wards over the pectineus muscle, and perforates the fascia lata at the inner border of the thigh to end in the scrotum or labium pudendi, according to the sex : in the fat it anastomoses with branches of the superficial perineal artery.

The *deep femoral branch* or the *profunda* (fig. 192, ²) is the largest offset of the femoral artery, and arises from the outer side of that trunk from one to two inches below Poupart's ligament. Its distribution is to the muscles of the thigh, and will be afterwards followed. In the present dissection it may be seen to lie over the iliacus muscle, where it gives the external circumflex artery to the outer part of the thigh ; and then to turn, with a large vein, beneath the trunks of the femoral vessels to the inner side of the limb.*

Profunda :

origin,

and position
in Scarpa's
triangle ;

Variation in origin. The origin of the profunda may approach nearer to Poupart's ligament until it arrives opposite that band ; or may even go beyond, and reach the external iliac artery (one example, R. Quain). And the branch may recede farther from the ligament, till it leaves the parent trunk at the distance of four inches from the commencement ; but in this case the circumflex branches usually arise separately from the femoral. In applying a ligature to the femoral artery in the upper part of the thigh, the thread should be placed four inches below Poupart's ligament, in order that the spot chosen may be free from the disturbing influence of so large an offset.

origin of
profunda
varies.

FEMORAL VEIN (fig. 190, *h*). The principal vein of the limb, while in the triangular space, has almost the same relative anatomy as the artery : its position to that vessel, however, is not the same throughout. Beneath Poupart's ligament it is on the inner side of the arterial trunk, and on the same level, and is supported on the pubis between the psoas and pectineus muscles ; but it soon winds beneath the artery, and is placed between the main trunk and its deep branch. In this space it receives the internal saphenous and deep femoral veins, and a small branch (*i*) with the inferior external pudic artery.

Femoral
vein :
first inside
the artery ;

afterwards
behind it.

DEEP PARTS OF THE FRONT OF THE THIGH.

The muscles on the front of the thigh are to be learnt next : they are the sartorius and the extensor of the knee ; and at the top of the thigh is the small tensor of the fascia lata. Four muscles are combined in the extensor, viz., rectus, crureus, vastus externus, and vastus internus.

Muscles on
the front of
the thigh.

The external circumflex branch of the profunda artery lies amongst the muscles and supplies them with branches ; and a large nerve, the anterior crural, furnishes offsets to them.

Vessels.
Nerve.

Dissection. To proceed with the deep dissection, the limb is to be retained in the same position as before, and the flaps of skin on the

Take the
fascia from

* Sometimes the term common femoral is applied to the trunk above the origin of the profunda, and the names superficial and deep femoral to the nearly equal pieces into which it divides.

the front of the thigh. front of the thigh are to be thrown aside. The fascia lata is to be cut along the middle line of the thigh and knee, and to be reflected to each side nearly to the same extent as the skin. Over the knee-joint the student is to note its attachment to the edges of the patella, and its union with a prolongation from the tendon of the extensor muscle of the knee.

Follow out sartorius, and fix it, In raising the inner piece of the fascia, the narrow muscle appearing (sartorius) should be followed to its insertion into the tibia; and to prevent its displacement, it should be fixed with stitches along both edges. Care should be taken of the small nerves in contact with the sartorius, viz., a plexus beneath it at the middle of the thigh from the saphenous, internal cutaneous, and obturator; two branches of the internal cutaneous below its middle,—one crossing the surface, and the other lying along the inner edge of the muscle; and the trunk of the great saphenous escaping from beneath it near the knee, with the patellar branch of the same perforating it rather higher.

Dissect the adductors, Internal to the sartorius some strong muscles (adductors) are inclined downwards from the pelvis to the femur. The student is to lay bare the fore part of these muscles; and beneath the most superficial (adductor longus), near where it touches the sartorius, he is to seek a branch of the obturator nerve to the plexus before mentioned in the middle of the thigh. On the outer side of the sartorius is the large extensor of the knee. For its dissection the knee is to be bent, to make tense the fibres; and an expansion below from the common tendon to the fascia lata and the knee-joint is not to be removed now,—its arrangement will be noticed after.

Dissect tensor of fascia. The little muscle at the upper and outer part of the thigh,—tensor of the fascia lata, is to be cleaned; and a strip of the fascia, corresponding with the width of the muscle, should be left along the outer aspect of the limb. After this slip has been detached, the rest of the fascia on the outer side of the thigh is to be divided by one or two transverse cuts, and is to be followed backwards to its insertion into the femur.

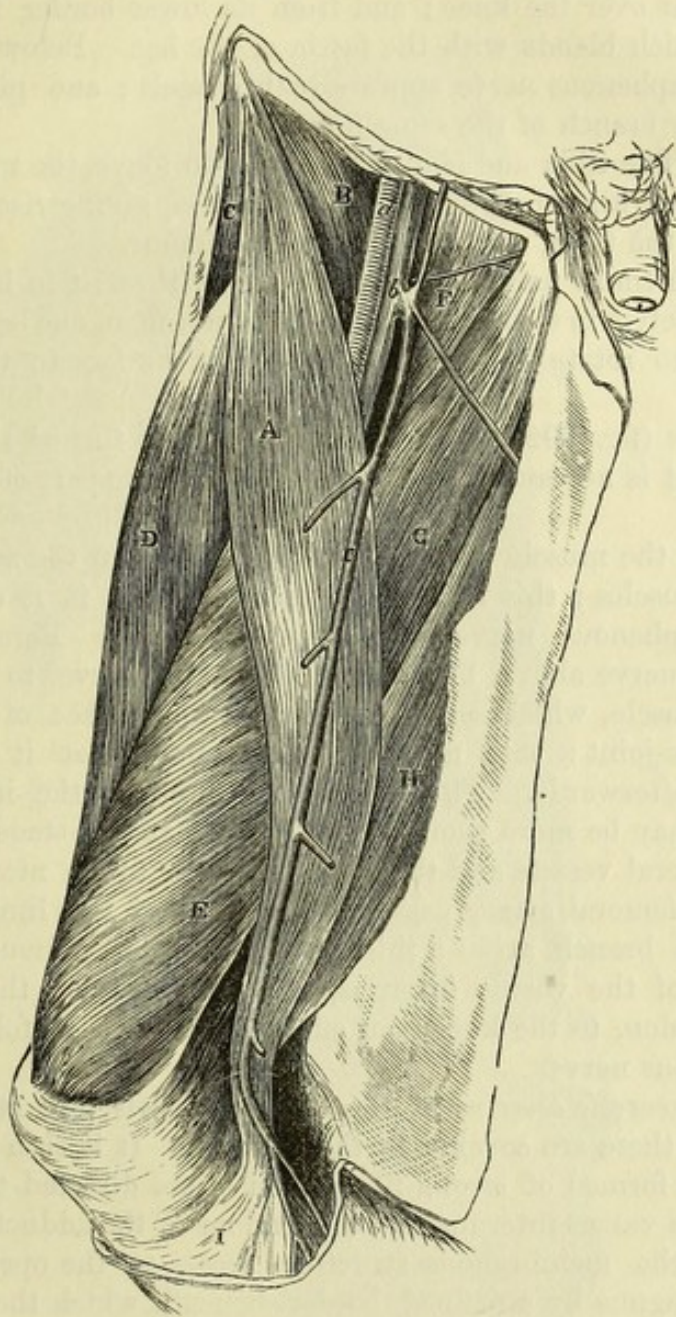
Sartorius: The SARTORIUS (fig. 191, A) is the longest muscle in the body, and extends from the pelvis to the leg. It arches over the front of the thigh, passing from the outer to the inner side of the limb, and lies in a hollow between the extensor on the one side, and the adductors on the other.

origin; Its *origin* is tendinous from the upper anterior iliac spinous process of the hip-bone, and from about half the interval between this and the inferior process. The fibres constitute a ribband-like muscle, which ends in a thin tendon below the knee, and is *inserted* into the inner surface of the tibia,—mainly into a slight depression by the side of the tubercle for an inch and a half, but also, by its upper edge, as far back as the internal lateral ligament of the knee-joint.

Relations of the first or oblique portion; The muscle is superficial throughout, and is perforated by some cutaneous nerves and vessels. Its upper part is oblique, and forms the outer boundary of Scarpa's triangle; it rests on the

following muscles : iliacus (B), rectus (D), and adductor longus (G), as well as on the anterior crural nerve and the femoral vessels. The middle portion is vertical, and lies in a hollow between the ^{of the} middle,

Fig. 191.*



vastus internus (E) and the adductor muscles, as low as the opening for the femoral artery ; but beyond that aperture, where it bounds the popliteal space, it is placed between the vastus with the great adductor in front, and the gracilis (H) with the inner hamstrings behind. The femoral vessels and their accompanying nerves are

* Surface view of the front of the thigh, the integuments and fascia lata being removed (Illustrations of Dissections). *Muscles* : A. Sartorius. B. Iliacus. c. Tensor fasciæ latæ. D. Rectus femoris. E. Vastus internus. F. Pectineus. g. Adductor longus. H. Gracilis. i. Tendon of sartorius. *Vessels* : a. Femoral artery. b. Femoral vein. c. Internal saphenous vein.

and of the
lower part.

concealed by this portion of the muscle. The lower tendinous part (1) rests on the internal lateral ligament of the knee-joint, being superficial to the tendons of the gracilis and semitendinosus, and separated from them by a prolongation of their synovial bursa: from its upper border there is an aponeurotic expansion to join that from the extensor over the knee; and from its lower border is given off another which blends with the fascia of the leg. Below the tendon the great saphenous nerve appears with vessels; and piercing it is the patellar branch of the same nerve.

Use; the
limb free,

Action. The tibia and femur being free to move, the muscle bends the knee and hip-joints over which it passes, giving rise to rotation inwards of the tibia, and outwards of the femur.

and fixed;

With the limbs fixed, the two muscles will assist in bringing forwards the pelvis in stooping; and when standing on one leg the muscle will help to rotate the body, so as to turn the face to the opposite side.

Divide the
sartorius,

Dissection (fig. 192). The sartorius is to be turned aside, or cut through if it is necessary, to follow the remaining part of the femoral artery.

show apo-
neurosis,
and dissect
the nerves

Beneath the muscle is an aponeurosis between the adductor and extensor muscles; this is thin above, and when it is divided the internal saphenous nerve will come into view. Parallel to the saphenous nerve above, but outside it, is the nerve to the vastus internus muscle, which sends an offset on the surface of the vastus to the knee-joint: this may be traced now, lest it should be destroyed afterwards. The plexus of nerves on the inner side of the thigh may be more completely dissected at this stage.

and vessels.

The femoral vessels and their branches are to be nicely cleaned. Where the femoral artery passes to the back of the limb its small anastomotic branch arises: this branch is to be pursued through the fibres of the vastus internus, and in front of the adductor magnus tendon, to the knee; an offset of it is to be followed with the saphenous nerve.

Aponeurosis
over the
femoral
artery

The *aponeurotic covering* of the femoral vessels (fig. 192, 7) exists only where these are covered by the sartorius. It is thin above; but below, it is formed of strong fibres, which are directed transversely between the vastus internus and the tendons of the adductor muscles. Inferiorly, the membranous structure ceases at the opening in the adductor magnus by a defined border, beneath which the saphenous nerve and its vessels escape.

ends below
by a free
border.

Deep part
of femoral
artery:

The DEEP PART OF THE FEMORAL ARTERY (fig. 192, 1) lies in a hollow between the muscles (Hunter's canal) until it reaches the opening in the adductor magnus. It is covered by the sartorius muscle and the subjacent aponeurosis, in addition to the integuments and fascia. Beneath it are the pectineus, the adductor brevis in part, the adductor longus, and a small piece of the adductor magnus. On the outer side is the vastus internus.

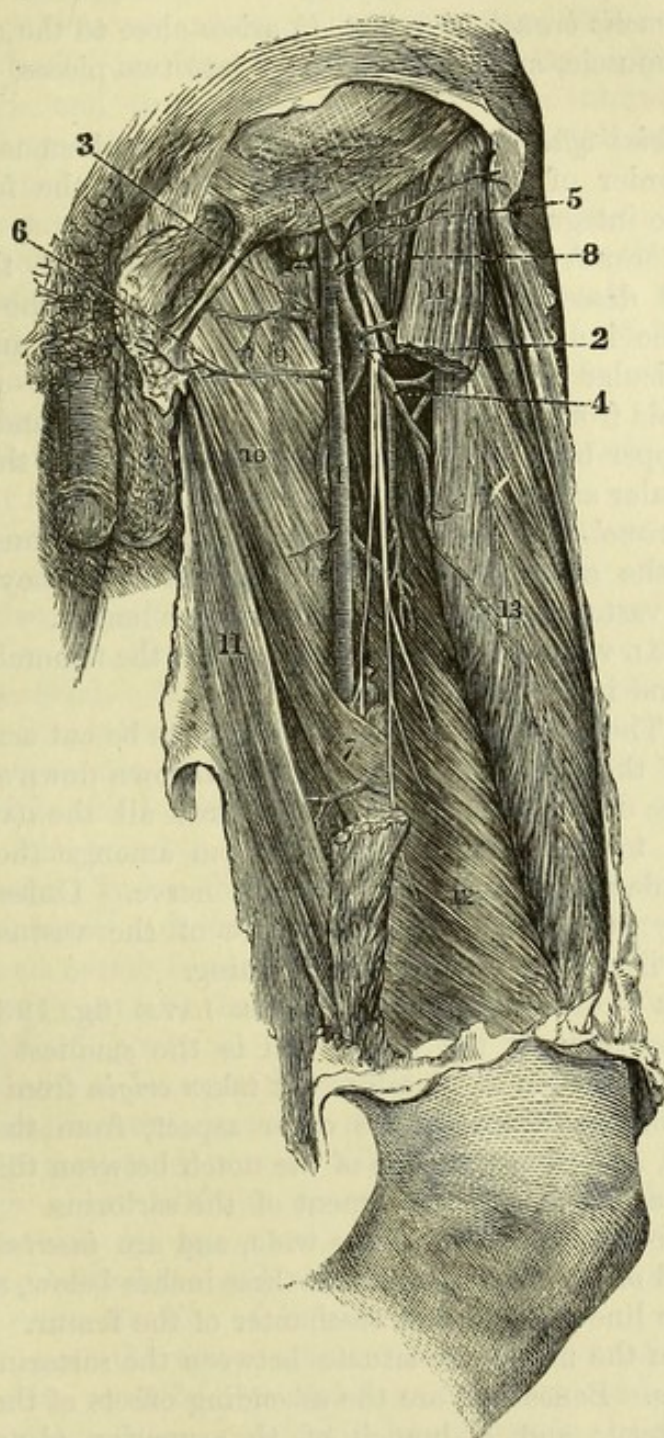
relations:

position of
veins and

The femoral vein lies close to the artery, on its posterior and outer aspect; and in the integuments oftentimes an offset of the saphenous passes across the line of the arterial trunk.

Lying along the front of the artery is the internal saphenous nerve, which is beneath the aponeurosis before noticed, but is not contained within the areolar sheath of the vessels.

Fig. 192.*



* Deep part of the femoral artery and its branches, with muscles of the thigh (Quain's Arteries). 1. Femoral artery. 2. Profunda artery. 3. Internal circumflex. 4. External circumflex. 5. Superficial circumflex iliac. 6. External pudic. 7. Lower part of the aponeurosis over the femoral artery. 8. Anterior crural nerve. 9. Pectineus muscle. 10. Adductor longus. 11. Gracilis. 12. Vastus internus. 13. Rectus femoris. 14. Sartorius, in part removed.

The femoral artery may be divided. *Splitting of the artery.* Occasionally the femoral artery is split into two below the origin of the profunda; but in all the cases that have been met with, the branches have united again above the opening in the adductor muscle.

Branches :— *Branches.* One named branch—anastomotic, and muscular offsets, spring from this part of the artery.

Anastomotic : The *anastomotic branch* (fig. 193, *k*) arises close to the opening in the adductor muscle, and divides at once into two pieces, superficial and deep :—

superficial, and The *superficial offset* (*n*) continues with the saphenous nerve to the lower border of the sartorius, and piercing the fascia lata, ramifies in the integuments.

deep part. The *deep branch* (*l*) is concealed in the fibres of the vastus internus, and descends in front of the tendon of the adductor magnus to the inner side of the knee-joint, where it anastomoses with the articular branches of the popliteal artery. A branch passes outwards from it in the substance of the vastus, and forms an arch at the upper border of the patella with an offset of the superior external articular artery.

Muscular branches. *Muscular branches.* Branches for the supply of the muscles come mostly from the outer side of the femoral artery; they enter the sartorius, the vastus internus, and the adductor longus.

Femoral vein. The FEMORAL VEIN corresponds closely with the femoral artery in its relations and in its branches.

To expose muscles on front of the femur. *Dissection.* The femoral artery and vein are to be cut across below the origin of the profunda, and are to be thrown downwards preparatory to the deeper dissection. Afterwards all the fat, and all the veins, are to be carefully removed from amongst the branches of the profunda artery and anterior crural nerve. Unless this dissection is fully carried out, the upper part of the vastus internus and crureus will not be prepared for learning.

Tensor vaginæ femoris arises from pelvis, The TENSOR VAGINÆ FEMORIS s. FASCIÆ LATÆ (fig. 193, *L*) occupies the upper third of the thigh, and is the smallest and most external of the outer set of muscles. It takes *origin* from the front of the crest of the ilium at the outer aspect, from the anterior superior spine, and from the edge of the notch between this and the inferior spine as far as the attachment of the sartorius. Its fibres form a fleshy belly about two inches wide, and are *inserted* into the ilio-tibial band of the fascia lata about three inches below, and rather in front of the line of, the great trochanter of the femur.

ends in fascia lata. Parts around. At its origin the muscle is situate between the sartorius and the gluteus medius. Beneath it are the ascending offsets of the external circumflex artery; and a branch of the superior gluteal nerve enters its under surface. A strong sheath of fascia surrounds the muscle.

Use on limb; *Action.* Supposing the limb moveable the muscle abducts the thigh, and may help in rotating inwards the femur.

on pelvis; When the limb is fixed it will support the pelvis, and assist in balancing the latter on the femur in walking.

on knee. The chief function of the tensor vaginæ femoris is, however, to

act with the gluteus maximus in tightening the ilio-tibial band so as to support the extended knee (p. 634).

Dissection. After the tensor has been learnt, the slip of fascia extending from it to the knee may be cut through; and when it is detached from the muscles around, the rectus may be followed upwards to its origin from the pelvis. Cut through the band of fascia.

The QUADRICEPS EXTENSOR CRURIS (fig. 191) consists of four parts or heads, one long or superficial (rectus), which springs from the pelvis, and three short or deep (vastus internus, crureus, and vastus externus) which arise from the femur: all are united below in a common tendon. Great extensor of knee.

The RECTUS FEMORIS (fig. 192, ¹³) gives rise to a fleshy prominence on the front of the thigh. It arises from the pelvis by two tendinous heads: one, the anterior, is attached to the anterior inferior iliac spine; and the other, posterior, is fixed to a rough mark on the outer surface of the ilium close above the acetabulum: near their origin they join to form a single tendon. The fleshy fibres terminate below in another tendon, which joins the aponeuroses of the other muscles in the common tendon. Rectus has double origin at pelvis; insertion into common tendon.

The rectus is larger in the middle than at the ends; and its fibres are directed from the centre to the sides, giving rise to the condition called penniform. Its upper end is covered by the tensor vaginæ femoris, iliacus, and sartorius; but in the rest of its extent it is superficial. It conceals branches of the external circumflex artery and anterior crural nerve, and rests on the crureus and vasti. The upper tendon of the rectus reaches farthest on the anterior surface; while the lower tendon is most extensive on the posterior aspect of the muscle. The muscle is penniform, and superficial, except above.

Dissection. To see the remaining muscles, cut across the rectus near the lower end, and raise it without injuring the branches of vessels and nerves beneath. The muscular mass covering the shaft of the femur is to be thoroughly cleaned, and its three parts defined in the following way:— Cut the rectus, and display three deep heads of extensor;

The division between the vastus externus on the outer side and the crureus in front is readily made along the situation of some descending vessels and nerves. Then, on turning to the outer side of the thigh, about half-way down, the tendinous edge of the vastus externus will be perceived, with oblique fibres of the crureus appearing behind it: sink the handle of the scalpel between these until it meets the line of division in front. define vastus externus;

To separate the vastus internus from the crureus, the lower end of the rectus must be detached from the others and turned down as far as possible, when a cleft will be evident in the subjacent tendon above the inner part of the patella. From this interval the division may be easily carried upwards between the tendons of the two muscles, but at the upper end some fleshy fibres generally need cutting to complete the separation. If the vastus internus is turned inwards off the crureus, a large part of the inner surface of the femur will be seen to be free from muscular attachment. separate crureus and vastus internus, beginning below, and exposing bare surface of bone.

The VASTUS EXTERNUS has a narrow attachment to the femur Vastus externus

is thin at
the origin ;

in comparison with its size. It takes *origin* from the upper half of the femur, by a piece from half an inch to an inch thick, which is attached to the root of the neck of the femur, and the fore and outer parts of the root of the great trochanter ; then along the outer side of the gluteal ridge, and the upper half of the linea aspera ; and lastly to the contiguous external intermuscular septum. Inferiorly the fibres of the muscle end in flat tendon, which blends with those of the other portions in the common tendon.

ends in
common
tendon.

Parts in
contact with
the surfaces.

The vastus externus is the largest part of the quadriceps, and produces the prominence on the outer side of the thigh. Its cutaneous surface is aponeurotic above, and is partly covered by the rectus, tensor vaginae femoris, and gluteus maximus muscles. The deep surface rests on the crureus, and receives branches of the external circumflex artery and anterior crural nerve.

Vastus
internus
arises from
femur and
adductor
tendons ;

The VASTUS INTERNUS (fig. 191, E) also has a narrow origin from the inner surface of the femur along the linea aspera and the prolongation upwards of its inner lip, reaching as high as the small trochanter ; and in the lower half of the thigh from the tendons of the adductor longus and adductor magnus. The fibres join an aponeurosis which blends in the common tendon, and is attached to the patella lower than the vastus externus.

forms
prominence
above knee.

The muscular mass is in part covered by the sartorius and rectus, but it projects between those muscles below. Some of the lower fibres are almost transverse, and will be able to draw the patella inwards.

Crureus has
widest
origin ;

The CRUREUS arises from the upper three-fourths of the anterior and outer surfaces of the femur, except where they are occupied by the vastus externus, and from the lower half of the external intermuscular septum. Its fibres end, like the other parts, in an aponeurosis which enters into the common tendon.

common
ending ;

is deepest
part of all.

The rectus and vasti cover the crureus except for a small extent at its lower and hinder part. It lies upon the bone and the sub-crureus muscle.

Common
tendon
above knee.

The *common tendon* resulting from the union of the foregoing is attached to the fore part of the upper border of the patella. It is oblong in shape, and about three inches long. A few fibres are prolonged over the front of the bone into the ligamentum patellæ, which forms the continuation of the tendon.

Lay bare
part below
knee.

Dissection. To see the continuation of the tendon, and its insertion into the tibia, the student should divide along the middle line of the patella and knee-joint a thin aponeurotic layer, which is derived from the lower fibres of the muscle, and covers the joint. On reflecting inwards and outwards the fibrous layer, the tendon will be exposed.

Infrapatellar
tendon
inserted into
tubercle of
tibia ;

The lower part of the common tendon, or *ligamentum patellæ*, is about two inches long, and is narrower and thicker than the part above the knee. It extends from the lower margin of the patella to the tubercle of the tibia ; and a bursa separates it from the bone above its insertion.

expansion
over it.

From the lower part of the vasti muscles a superficial aponeurotic

expansion is derived : this prolongation, which is strongest on the inner side, is united with the fascia lata and the other tendinous offsets to form a capsule in front of the joint, and is fixed below to the heads of the tibia and fibula.

Subcrureus muscle. Beneath the crureus, near the knee-joint, is a thin layer of pale fibres, which is but a part of the large muscle, separated from the rest by areolar tissue. Attached to the femur in the lower fourth, and often by an outer and inner slip, it ends in aponeurotic fibres on the synovial sac of the knee-joint.

Small sub-crureus muscle ends on the synovial sac.

Action. All parts of the quadriceps extend the knee-joint when the tibia is moveable ; and the rectus can flex the hip-joint over which it passes. The fleshy bellies are strong enough to break the patella transversely over the end of the femur, or to rupture sometimes the common tendon.

Use with tibia moveable ;

With the tibia as the fixed point the vasti will bring forwards the femur, and straighten the knee, as in rising from the stooping posture and jumping ; and the rectus will prop the pelvis on the femur, or assist in moving it forwards in stooping.

with tibia fixed :

The subcrureus contracts in extension of the knee, and elevates the synovial membrane above the patella.

how sub-crureus acts.

INTERMUSCULAR SEPTA. The processes of the fascia lata, which limit laterally the extensor muscle of the knee, are thus named, and are fixed to the linea aspera and the lines leading to the condyles of the femur.

Intermuscular septa are two :

The *external septum* is the stronger, and reaches from the insertion of the gluteus maximus to the outer condyle of the femur. It is situate between the vastus externus and crureus on the one side, and the short head of the biceps on the other, to all of which it gives origin : it is perforated near the outer condyle by the upper external articular vessels and nerve.

the outer is the stronger ;

The *inner partition* is very thin along the side of the vastus internus ; and its place is supplied by the strong tendon of the adductor magnus between the inner condyle and the linea aspera.

the inner is indistinct.

The EXTERNAL CIRCUMFLEX ARTERY (fig. 192, ⁴) is the chief vessel for the supply of the muscles of the front of the thigh. It arises usually from the outer side of the profunda (deep femoral) artery, but often from the femoral trunk. It is directed outwards through the divisions of the anterior crural nerve, and beneath the sartorius and rectus muscles, and supplies offsets to those muscles. Its terminal branches are ascending, transverse, and descending :—

External circumflex artery

divides into

The *ascending branch* is directed beneath the tensor vaginae femoris to the outer side of the hip, where it anastomoses with the gluteal artery, and supplies the contiguous muscles.

ascending,

The *transverse branch*, the smallest, divides into two or three which enter the vastus externus, and anastomose with the perforating arteries.

transverse,

The *descending branch* is the largest, and ends in pieces which are distributed to the crureus and vastus externus muscles. One considerable branch descends to the knee, and anastomoses with the

and descending branches.

upper external articular artery; a small offset courses over the muscle with a nerve to the joint.

Anterior
crural nerve

The ANTERIOR CRURAL NERVE (fig. 192, ⁸) of the lumbar plexus (p. 536) supplies the muscles, and most of the integuments of the front of the thigh, and the integuments of the inner side of the leg. Soon after the trunk of the nerve leaves the abdomen it is flattened, and is divided into superficial and deep pieces.

is divided.

From its
superficial
part arise—
middle
cutaneous;

A. The *superficial part* gives off the middle and internal cutaneous nerves, and branches to the sartorius and pectineus muscles.

The *middle cutaneous nerve* perforates the fascia lata, sometimes also the sartorius, about three inches below Poupart's ligament, and extends to the knee (p. 603).

internal
cutaneous,

The *internal cutaneous nerve* sends two or more small twigs through the fascia lata to the integument of the upper two-thirds of the thigh, and then divides in front of the femoral artery, or on the inner side, into anterior and posterior branches. Sometimes these branches arise separately from the anterior crural trunk.

which has

anterior and

The *anterior branch* is directed to the inner side of the knee. As far as the middle of the thigh it lies over the sartorius, but it then pierces the fascia lata, and ramifies in the integuments (p. 604).

posterior
branches;

The *posterior branch* remains beneath the fascia lata as far as the knee (p. 604). While underneath the fascia the nerve lies along the inner border of the sartorius, and joins in a plexus, about the middle of the thigh, with offsets of the obturator, and nearer the knee, with a branch of the internal saphenous nerve.

nerve to
pectineus;

The *nerve to the pectineus* (fig. 190, ²) is slender, and is directed inwards beneath the femoral vessels to the anterior surface of the muscle: sometimes there are two branches.

branches to
sartorius.

Two or three *branches to the sartorius* arise in common with the middle cutaneous nerve.

The deep
part gives
off branches

B. The *deep part* of the anterior crural nerve furnishes branches to the several heads of the quadriceps extensor muscle, and one cutaneous nerve—the internal saphenous.

to rectus,

The *branch to the rectus* enters the deep surface of the muscle; from this branch a twig is sent to the hip-joint.

to vastus
externus,

The *nerve to the vastus externus* divides into two or more pieces as it enters the muscle. From one of these an *articular filament* is often continued downwards to the knee-joint.

to crureus,

Two or three *branches to the crureus* pass into the anterior surface of the muscle; and from the most internal a long twig descends to the subcrureus and the knee-joint.

and to
vastus
internus;

The *nerve to the vastus internus* (fig. 193, ⁸) is nearly as large as the internal saphenous, in common with which it often arises. To the upper end of the vastus it furnishes one or more branches, and is then continued as far as the middle of the thigh, where it ends in offsets to the muscle and the knee-joint.

Its *articular branch* (fig. 193, ⁹) is prolonged on or in the vastus, and on the tendon of the adductor magnus, to the inner side of the knee-joint, where it is distributed over the synovial membrane of

the articulation. This small nerve accompanies the deep branch of the anastomotic artery (p. 618).

The *internal* or *long saphenous nerve* (fig. 192) is the largest branch of the anterior crural. In the thigh the nerve takes the course of the deep blood-vessels, and is continued along the artery, beneath the aponeurosis covering the same, as far as the opening in the adductor magnus muscle. At that spot the nerve passes from beneath the aponeurosis, and is prolonged under the sartorius muscle to the upper part of the leg, where it becomes cutaneous (fig. 188, 4). It supplies two offsets while it is beneath the fascia in the thigh.

A *communicating branch* arises about the middle of the thigh, and crosses inwards beneath the sartorius to join in the plexus of the internal cutaneous and obturator nerves, or with the internal cutaneous nearer the knee : this branch is often absent.

The *patellar branch* springs from the nerve near the knee-joint, and perforating the sartorius muscle and the fascia lata, ends in the integument over the knee (p. 604).

A *branch of nerve to the tensor vaginæ femoris* is derived from the superior gluteal (p. 637) ; it enters the deep surface of the muscle, and may be followed nearly to the lower end.

Directions. After the examination of the muscles of the front of the thigh, with their vessels and nerves, the student is to learn the adductor muscles, and the vessels and nerves which belong to them.

PARTS ON THE INNER SIDE OF THE THIGH.

The muscles in this position are the three adductors,—longus, brevis, and magnus, with the gracilis and pectineus. These have the following position with respect to one another :—Internal to all, and the longest, is the gracilis. Superficial to the others are the pectineus and the adductor longus ; and beneath the last two are the short adductor and the adductor magnus.

In connection with the muscles, and supplying them, are the profunda artery (of the femoral) with the accompanying vein, and the obturator nerve.

Dissection. For the preparation of the muscles, the investing fascia and tissue are to be taken away ; and the two superficial adductors are to be separated from one another.

Let the student be careful of the branches of the obturator nerve in connection with the muscles, viz., those entering the fleshy fibres, and one issuing beneath the adductor longus, to join the plexus at the inner side of the thigh.

Lastly, should any fat and veins be left with the profunda and its branches, they must be removed.

The GRACILIS reaches from the pelvis to the tibia (fig. 193, c), and is fleshy and riband-like above, but tendinous below. The muscle arises by a thin aponeurosis, two or three inches in depth, from the pubic border of the hip-bone close to the margin, viz., opposite the lower half of the symphysis, and the upper part of the

is inserted into tibia. pubic arch. Inferiorly it is *inserted* by a flat tendon, about one-third of an inch wide, into the inner surface of the tibia, beneath and close to the sartorius.

Position to other muscles. The muscle is superficial throughout. For two-thirds of the thigh it is flattened against the adductors brevis and magnus, so as to have its borders directed forwards and backwards; and in the lower third, it intervenes between the sartorius and semimembranosus muscles, and helps to form the inner boundary of the popliteal space. At its insertion the tendon is nearer the knee than that of the semitendinosus, though at the same depth from the surface, and both lie over the internal lateral ligament; from the tendon an expansion is continued to the fascia of the leg, like the sartorius. A bursa separates the tendon from the ligament, and projects above it to the sartorius.

Use on knee-joint and femur; *Action.* It bends the knee-joint if the tibia is not fixed, rotating in that bone, and then brings the moveable femur towards the middle line with the other adductors.

on pelvis. Supposing the foot resting on the ground, the gracilis will aid in propping the pelvis on the limb.

Pectineus: The PECTINEUS (fig. 191, F) is the highest of the muscles directed from the pelvis to the inner side of the femur. It has a fleshy *origin* from the pubic portion of the ilio-pectineal line, and slightly from the surface in front of that line; and it is *inserted* by a thin tendon, about two inches in width, into the femur behind the small trochanter, and into the upper part of the line which extends from that process to the linea aspera.

relations of surfaces; One surface of the muscle is in contact with the fascia lata; and the femoral vessels lie over its lower part: the opposite surface touches the obturator externus and adductor brevis muscles, and the superficial portion of the obturator nerve. The pectineus lies between the psoas and the adductor longus; and the internal circumflex vessels pass between its outer border and the psoas.

Use on femur free and fixed. *Action.* It adducts the limb and bends the hip-joint. When the femur is fixed it can support the pelvis in standing; or it can draw forwards the pelvis in stooping.

Adductor longus extends from pelvis to femur; The ADDUCTOR LONGUS lies below the pectineus (fig. 191, G), and is triangular in form, with the apex at the pelvis and the base at the femur. It *arises* by a narrow tendon from the front of the pubis in the angle between the crest and the symphysis; and it is *inserted* into the inner edge of the linea aspera.

relations to muscles and vessels. This muscle is situate between the gracilis and the pectineus, and forms part of Scarpa's triangular space. Its anterior surface is covered near the femur by the femoral vessels and the sartorius: the posterior rests on the other two adductors, on the superficial part of the obturator nerve, and on the deep femoral artery. The tendon of insertion is closely united to the adductor magnus and vastus internus.

Use on femur, *Action.* With the femur moveable, it will flex the hip-joint, and with the aid of the other adductors will carry inwards the limb, so

as to cross the thigh-bones. In walking it helps the other adductors to project the limb.

With the femur fixed, the muscle props and tilts forwards the on pelvis. pelvis.

Dissection. The adductor brevis muscle, with the obturator nerve and the profunda vessels, will be arrived at by reflecting the two last muscles. On cutting through the pectineus near the pubis, and throwing it down, the dissector may find occasionally the small accessory nerve of the obturator which turns beneath the outer border; if this is present, its branches to the hip-joint and the obturator nerve are to be traced out. The adductor longus is then to be divided near its origin, and raised with care, so as not to destroy the branches of the obturator nerve beneath: its tendon is to be detached from that of the adductor magnus beneath it, to see the branches of the profunda artery.

Now the adductor brevis will be laid bare. A part of the obturator nerve crosses over this muscle to the femoral artery, and sends an offset to the plexus at the inner side of the thigh: a deeper part of the same nerve lies beneath this adductor. The muscle should be separated from the subjacent adductor magnus, where the lower branch of the nerve with an artery issues. In this last step of the dissection, the student should follow on and in the fibres of the adductor magnus a slender articular branch of the obturator nerve; this will afterwards be traced to the knee (p. 649).

The *accessory obturator nerve* (Schmidt) is derived from the trunk of the obturator, near the lumbar plexus (p. 537), and passes from the abdomen over the brim of the pelvis. In the thigh it turns beneath the pectineus, and joins the superficial branch of the obturator nerve; it supplies an offset to the hip-joint with the articular artery, and occasionally one to the under surface of the pectineus.

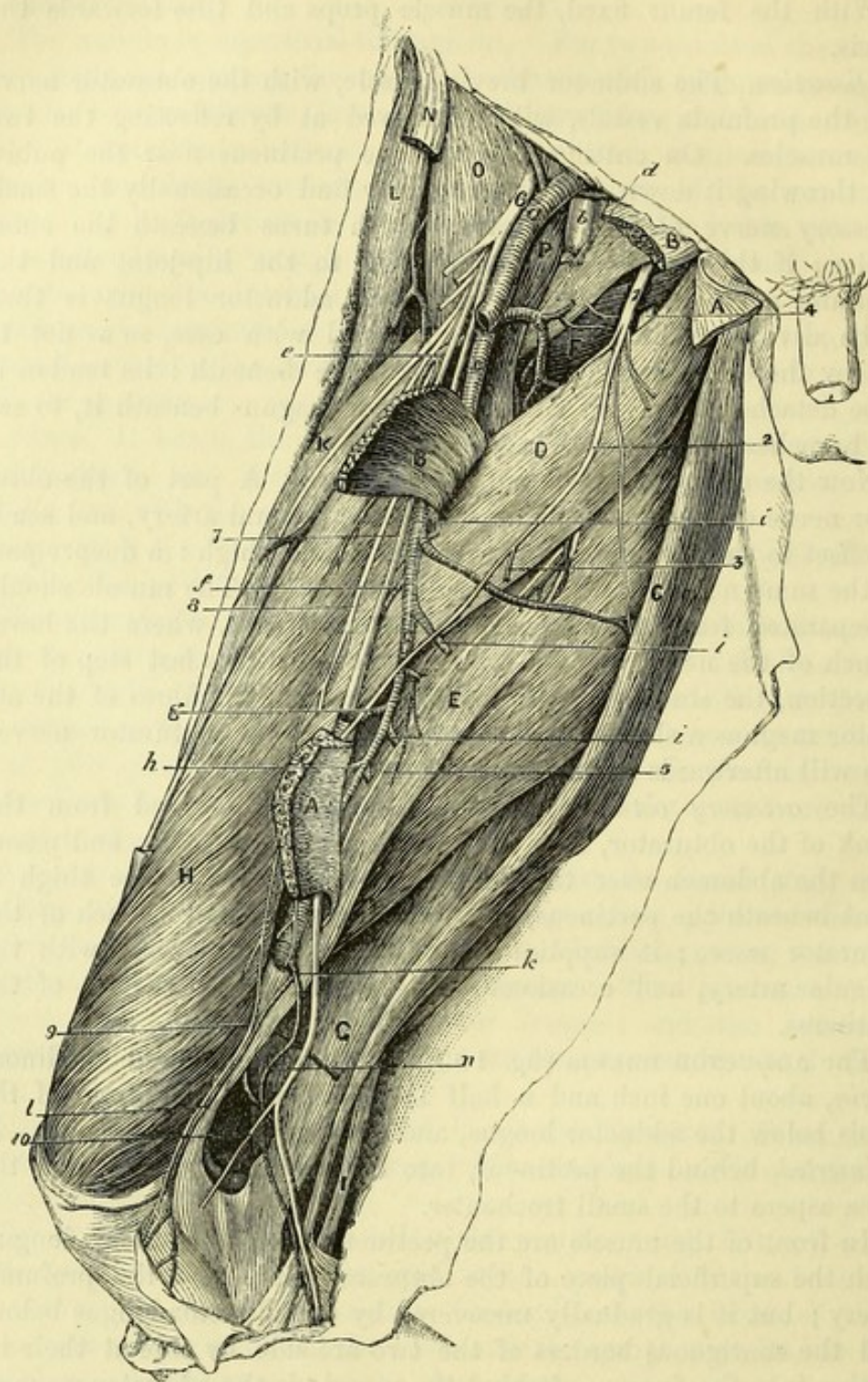
The ADDUCTOR BREVIS (fig. 193, D) has a fleshy and tendinous origin, about one inch and a half in depth, from the front of the pubis below the adductor longus, and close outside the gracilis. It is inserted, behind the pectineus, into all the line leading from the linea aspera to the small trochanter.

In front of the muscle are the pectineus and the adductor longus, with the superficial piece of the obturator nerve, and the profunda artery; but it is gradually uncovered by the adductor longus below, and the contiguous borders of the two are side by side at their insertion into the femur. Behind the muscle is the adductor magnus, with the deep piece of the obturator nerve and a branch of the internal circumflex artery. In contact with the upper border lies the obturator externus (F), and the internal circumflex artery passes between the two.

Action. This muscle adducts the limb with slight flexion of the hip-joint, like the pectineus. And if it acts from the femur, it will balance and move forwards the pelvis.

The OBTURATOR NERVE (fig. 193, I) is a branch of the lumbar plexus (p. 536), and supplies the adductor muscles of the thigh, as

Fig. 193.*



* Deep dissection of the adductor muscles, with their vessels and nerves. (Illustrations of Dissections). *Muscles:* A. Adductor longus, cut. B. Pectineus, cut. C. Gracilis. D. Adductor brevis. E. Adductor magnus. F. Obturator externus. G. Semimembranosus. H. Vastus internus. K. Rectus femoris. L. Tensor fasciæ latæ. N. Piece of the sartorius. O. Iliacus. P. Psoas. *Vessels:* a. Femoral artery, and b. Femoral vein. c. Trunk of the profunda. d. Internal, and e. External circumflex. f. First, g. Second, and h. Third perforating. i. Muscular of the profunda. k. Anastomotic of the femoral, with l. Its deep, and n. Its superficial branch. *Nerves:* 1. Obturator, joined by the accessory obturator nerve, with 2. The superficial,

well as the hip and knee-joints. The nerve issues from the pelvis through the aperture in the upper part of the thyroid foramen ; and it divides in that opening into two pieces, which are named superficial and deep, from their position with respect to the adductor brevis muscle.

is divided into two.

A. The *superficial part* ⁽¹⁾ of the nerve is directed over the adductor brevis, but beneath the pectineus and the adductor longus, to the femoral artery, on which it is distributed : at the lower border of the last muscle it furnishes an offset or two, which join in a plexus with the internal cutaneous and saphenous nerves (p. 622), and often help to supply the integuments.*

The superficial part ends on femoral artery, and joins plexus in the thigh ;

In the aperture of exit, this piece of the nerve sends outwards an *articular twig* to the hip-joint.

branches are to hip-joint,

Muscular branches are furnished to the adductor longus, the adductor brevis, and the gracilis.

muscular to adductors.

B. The *deep part* ⁽⁴⁾ of the obturator nerve pierces the fibres of the external obturator muscle, and, continuing beneath the adductor brevis, is consumed chiefly in the adductor magnus. The following offsets are supplied by it :—

Deep part of the nerve

Muscular branches enter the obturator externus as the nerve pierces it ; others are furnished to the large, and sometimes to the short adductor.

ends in adductor magnus,

A slender *articular branch* (fig. 183,⁵) enters the fibres of the adductor magnus, and passes through this near the linea aspera to reach the popliteal artery, by which it is conducted to the back of the knee-joint : its termination is seen in the dissection of the popliteal space (p. 649).

and gives branch to knee-joint.

Dissection. To prepare the profunda artery and its branches, as far as they are to be seen on the front of the thigh, it will be requisite to follow back the internal circumflex artery above the upper border of the adductor brevis, and to trace the perforating branches to the apertures in the adductors near the femur.

Dissect profunda.

The PROFUNDA (fig. 193, c) is the chief muscular artery of the thigh, and arises from the femoral about an inch and a half below Poupart's ligament (p. 613). At its origin the vessel is placed on the outer side of the parent trunk ; but it is soon directed inwards beneath the femoral vessels to the inner side of the femur, and ends at the lower third of the thigh in a small branch that pierces the adductor magnus.

Profunda artery :

origin, course, and ending ;

Where the vessel lies in the triangular space of the thigh it rests on the iliacus muscle. But on the inner side of the femur it is parallel to the femoral artery, though deeper in position ; and it is

parts around.

* In some bodies the superficial part of the nerve is of large size and has a distribution similar to that of the inner branch of the internal cutaneous nerve, the place of which it takes : in such instances it joins freely in the plexus.

and 4. The deep part. 3. Cutaneous branch of the obturator. 5. Articular branch to the knee from the deep part. 6. Anterior crural nerve. 7. Internal saphenous, and 10. Its patellar branch. 8. Nerve to the vastus internus, and 9. Its articular branch to the knee.

	placed first over the pectineus and adductor brevis, and thence to its termination between the adductors longus and magnus.
Branches to muscles of the thigh join freely.	Its branches are numerous to the surrounding muscles on the front and back of the thigh, and maintain free anastomoses with other vessels of the thigh (p. 653); through these communications the blood finds its way to the lower part of the limb when the chief artery is obliterated either above or below the origin of the profunda.
The named branches are :—	The named <i>branches</i> are these :—
External circumflex.	a. The <i>external circumflex artery</i> (fig. 193, <i>e</i>) has been described in the dissection of the parts on the front of the thigh (p. 621).
Internal circumflex	b. The <i>internal circumflex artery</i> (fig. 193, <i>d</i>) arises from the inner and posterior part of the profunda, and turns backwards between the psoas and pectineus, but above the adductor brevis. Opposite the small trochanter it ends in two branches, which will be seen in the dissection of the buttock (p. 643). It supplies the undermentioned offsets to the inner side of the thigh :—
ends on back of thigh,	
supplies hip-joint and	An <i>articular artery</i> enters the hip-joint through the notch in the acetabulum.
muscles.	At the border of the adductor brevis two <i>muscular branches</i> arise;—one ascends to the obturator and the superficial adductor muscles; the other, which is larger, descends with the deep piece of the obturator nerve beneath the adductor brevis, and ends in this and the largest adductor.
Three perforating branches :	c. The <i>perforating arteries</i> , three in number, pierce the tendons of some of the adductor muscles close to the linea aspera of the femur : they supply muscles on the back of the thigh, and wind round the bone to end in the vastus externus and crureus (p. 653).
first	The <i>first</i> (<i>f</i>) begins opposite the lower border of the pectineus, and perforates the short and large adductors.
second ;	The <i>second</i> (<i>g</i>) arises below the middle of the adductor brevis, and passes through the same muscles as the preceding.
third ;	The <i>third</i> (<i>h</i>) springs from the deep femoral trunk below the adductor brevis, and is transmitted through the adductor magnus. From the second or third perforating vessel a <i>medullary artery</i> is supplied to the femur.
and the ending is a fourth.	The terminal branch of the profunda (fourth perforating) pierces the adductor magnus near the aperture for the femoral artery.
Anastomotic branches.	d. <i>Muscular or anastomotic branches</i> (<i>i</i>) to the back of the thigh (three or four in number) pass through the adductor magnus at some distance from the linea aspera, and end in a chain of anastomoses in the hamstrings (p. 653).
Profunda vein.	THE PROFUNDA VEIN results from the union of the different branches corresponding with the offsets of its companion artery. It accompanies closely the artery of the same name, to which it is superficial, and ends above in the femoral vein.
Cut through adductor brevis.	<i>Dissection.</i> To bring into view the remaining muscles, viz., adductor magnus, obturator externus, and the insertion of the psoas and iliacus, the adductor brevis is to be cut through near the pelvis, and to be thrown down. Then the investing layer of fascia and areolar tissue is to be removed from each muscle.

After the adductor magnus has been learnt, detach a few of the upper fibres to examine the obturator externus.

The ADDUCTOR MAGNUS (fig. 193, E) is triangular in form, with its base directed upwards, one side being attached to the femur, and the other free at the inner side of the thigh. Adductor magnus :

The muscle arises from the conjoined rami of the pubis and ischium along their inner margin, and from the lower impression on the ischial tuberosity. The anterior fibres diverge from their origin, being horizontal above but more oblique below, and are *inserted* (from above down) into the back of the femur close inside the gluteal ridge, into the linea aspera, and into the internal supracondylar line for about an inch. The posterior fibres, from the ischial tuberosity, are vertical in direction, and end at the lower third of the thigh in a tendon, which is inserted into the inner condyle of the femur, surrounding the adductor tubercle, and is connected by a fibrous expansion to the lower part of the internal supracondylar line. origin is narrow ;
fibres diverge to their insertion,
some being horizontal
others vertical,

The muscle consists of two parts, which differ in their characters. The anterior, thin and fleshy, forms a septum between the other adductors and the muscles on the back of the thigh ; but the posterior piece, partly fleshy and partly tendinous, constitutes the inner thick margin of the muscle. On the anterior surface are the other two adductors and the pectineus, with the obturator nerve and the profunda vessels. The posterior surface touches the hamstring muscles and the great sciatic nerve. In contact with the upper border are the obturator externus and the quadratus femoris, with the transverse branch of the internal circumflex vessels ; and along the inner border lie the gracilis and the sartorius. At its attachment to the femur the muscle is closely united with the other adductors, particularly the adductor longus, and in its lower part with the vastus internus. Near the bone it is pierced by apertures for the passage of the femoral and perforating arteries. and form two parts.

Relations of surfaces,
and borders.

Action. This muscle is a powerful adductor ; and the part arising from the tuberosity is also an extensor of the hip. In standing, the latter part of the muscle, acting from the femur, has an important influence in steadying the hip-joint ; and in walking, the great and other adductors co-operate with the gluteal muscles externally to support the pelvis on the fixed limb. Use on femur ;
in standing ;
in walking.

The *opening* in the adductor for the transmission of the femoral vessels into the popliteal space is tendinous at the anterior, but fleshy at the posterior aspect. It is situate at the junction of the upper three-fourths with the lowest fourth of the thigh, and is larger than is necessary for the passage of the vessels. On the outside it is bounded by the vastus internus ; and on the inside by the tendon of the adductor magnus, with some fibres added from the tendon of the long adductor. Opening for the vessels :

boundaries.

The PSOAS and ILIACUS (fig. 193) arise separately in the abdomen (p. 531), but are united in the thigh, the conjoined portion of the muscles lying beneath Poupart's ligament. The psoas (P) is *inserted* by tendon into the small trochanter of the femur ; and the Psoas and iliacus in the thigh :
insertion into femur ;

fleshy iliacus (o) mainly joins the tendon of the psoas, but a few of its fibres are fixed into a special triangular surface of bone in front of and below the trochanter.

parts
around ;

Beneath the ligament the muscles occupy the interval between the ilio-pectineal eminence and the anterior superior iliac spinous process ; and below the pelvis the mass covers the capsule of the hip-joint, a large bursa intervening. On the front of the psoas is the femoral artery, and between the two muscles lies the anterior crural nerve. The pectineus and the internal circumflex vessels are contiguous to the inner border ; and the sartorius and vastus internus touch the outer edge.

use.

Action. These muscles act as flexors of the hip-joint ; and the use of the psoas on the spinal column is given with the description in the abdomen (p. 532).

Obturator
externus :

origin ;

The OBTURATOR EXTERNUS (fig. 193, F) is triangular in form, with the base at the pelvis and the apex at the femur. The fibres of the muscle take *origin* from the outer surface of the obturator membrane for the inner half, and from the bony circumference of the thyroid foramen for a corresponding extent,—the bony attachment being an inch wide opposite the body of the pubis, and reaching inwards to the adductor brevis and magnus. The fibres are directed backwards and outwards to be *inserted* by a tendon into the pit at the root of the great trochanter.

insertion.

The adduc-
tors cover it ;

and it
touches hip-
joint.

This muscle is concealed by the pectineus, and adductor brevis and magnus. It covers the obturator membrane and vessels, and is pierced by the deep part of the obturator nerve. As it winds back it is in contact with the lower surface of the hip-joint. The insertion of the muscle will be seen in the dissection of the buttock (p. 644).

Use.

Action. The muscle is an external rotator of the thigh ; but its action will be given in full with the other muscles of the same group in the buttock (p. 644).

Detach
obturator.

Dissection. By detaching the obturator muscle from the pelvis, the branches of the artery of the same name will be seen beneath its fibres. The deep part of the nerve may be followed back to the foramen at the same time. A better view will be obtained if this dissection is deferred till after the limb is removed.

Obturator
artery

divides into
two ;

inner,

The OBTURATOR ARTERY is a branch of the internal iliac (p. 559), and enters the thigh through the top of the thyroid foramen. In the aperture the artery divides into two pieces, which form a circle on the obturator membrane beneath the muscle :—

The *internal piece* runs along the inner half of the membrane, and furnishes offsets to the obturator externus and the upper ends of the adductor muscles.

and outer
branch.

The *external piece* descends close to the outer edge of the foramen, and after giving a branch inwards to join the lower end of the preceding, is continued to the ischial tuberosity and the muscles arising therefrom. Offsets pass to both obturator muscles ; and an *articular* twig is given to the hip-joint.

Branches of nerve to the obturator externus come from the deep portion of the obturator, and enter the posterior surface of the muscle. Branches of the nerve.

SECTION II.

THE BUTTOCK, OR THE GLUTEAL REGION.

Directions. Both this SECTION and the following one (to p. 658) are to be completed by the student in the time appointed for the body to lie in the prone position. Directions.

Position. During the dissection of the back of the thigh the body is placed with the face down; and the pelvis is to be raised by blocks, until the lower limbs hang vertically over the end of the dissecting table. When the body is turned, the points of bone marking posteriorly the limit between the thigh and the abdomen can be better ascertained. Position of the body.

Dissection. The integument is to be raised from the buttock by means of the following incisions:—One is to be made along the iliac crest, and is to be continued in the middle line of the sacrum to the tip of the coccyx. Another is to be begun where the first terminates, and is to be carried outwards and downwards across the thigh till it is about six inches below the great trochanter. The flap of skin thus marked out is to be thrown down. Take up the skin:

Many of the cutaneous nerves of this region will be found in the fat along the line of the iliac crest (fig. 194). Thus, in front, but rather below the crest, are branches of the external cutaneous, if these have not been cut in the dissection of the thigh. Crossing the crest towards the fore part is a large offset of the last dorsal nerve; and usually farther back, but close to the bone, a smaller branch from the ilio-hypogastric nerve. At the outer border of the erector spinæ are two or three branches of the lumbar nerves. seek cutaneous nerves on the crest,

By the side of the sacrum and coccyx two or three offsets of the sacral nerves are to be looked for beneath the fat. and by side of sacrum:

The remaining cutaneous nerves are derived from the small sciatic, and must be sought beneath the fat along the line of the lower incision, where they come from underneath the gluteus maximus. Some turn upwards over that muscle, and others are directed down the thigh. other nerves of small sciatic below:

Cutaneous arteries accompany all the nerves, and will serve as guides to their situation. cutaneous arteries.

CUTANEOUS NERVES (fig. 194). The nerves distributed in the integuments of the buttock are small but numerous, and are derived from the last dorsal nerve, from branches of the lumbar and sacral plexuses, and from the posterior primary divisions of the lumbar and sacral nerves. Sources of the cutaneous nerves:

The LAST DORSAL NERVE (^s) supplies the buttock by means of its lateral cutaneous branch (p. 450). This offset perforates the muscles from last dorsal;

of the abdomen, and crosses the front of the iliac crest to be distributed over the fore part of the gluteal region, as low as the great trochanter.

from lumbar plexus,

NERVES OF THE LUMBAR PLEXUS. Parts of two nerves of the lumbar plexus (p. 536), viz., ilio-hypogastric and external cutaneous, are spent in the integuments of this region.

through ilio-hypogastric, and

The *iliac branch of the ilio-hypogastric* (⁷) crosses the iliac crest in front of the branches from the lumbar nerves, lying in a groove in the bone, and extends generally only a short distance below the crest.

external cutaneous ;

Offsets of the *external cutaneous nerve* of the thigh bend backwards to the integuments above the great trochanter, and cross the ramifications of the last dorsal nerve.

from posterior branches of lumbar

POSTERIOR PRIMARY BRANCHES. The offsets of the posterior primary pieces of the *lumbar nerves* (⁶) are two or three in number, and cross the crest of the ilium at the outer edge of the erector spinæ; they ramify in the integuments of the middle of the buttock, and some branches may be traced nearly to the great trochanter.

and sacral nerves ;

The branches of the *sacral nerves* (⁵) perforate the gluteus maximus near the sacrum and coccyx, and are then directed outwards for a short distance in the integuments over the muscle. These offsets are usually two in number: the largest is opposite the lower end of the sacrum, and the other by the side of the coccyx.

from sacral plexus, through small sciatic,

SMALL SCIATIC (¹). This nerve of the sacral plexus (p. 564) sends superficial branches to the buttock. Its cutaneous offsets appear along the lower border of the gluteus maximus, accompanied by superficial branches of the sciatic artery; two or three ascend round the edge of the muscle, and are lost in the integuments of the lower part of the buttock; the remaining branches (²) descend to the thigh, and will be afterwards noticed on it (p. 641).

and perforating cutaneous branch.

The PERFORATING CUTANEOUS NERVE of the sacral plexus (⁴) turns round the edge of the gluteus maximus near the coccyx, and supplies the skin of the adjacent part of the buttock: this nerve has been exposed in the dissection of the perineum.

Clean gluteus maximus :

Dissection. The thin and unimportant deep fascia of this region may be disregarded, in order that the great gluteal muscle, which is the most difficult in the body to clean, may be well displayed. To lay bare the muscle, let the student turn aside the cutaneous nerves, and adduct and rotate inwards the limb to make tense the muscular fibres. Having cut through the fat and fascia from the origin to the insertion, let him carry the scalpel along one bundle of fibres at a time in the direction of a line from the sacrum to the femur, until all the coarse fasciculi are cleaned. If the student has a right limb, it will be more convenient to begin the dissection at the upper border; but if a left limb, at the lower margin of the muscle.

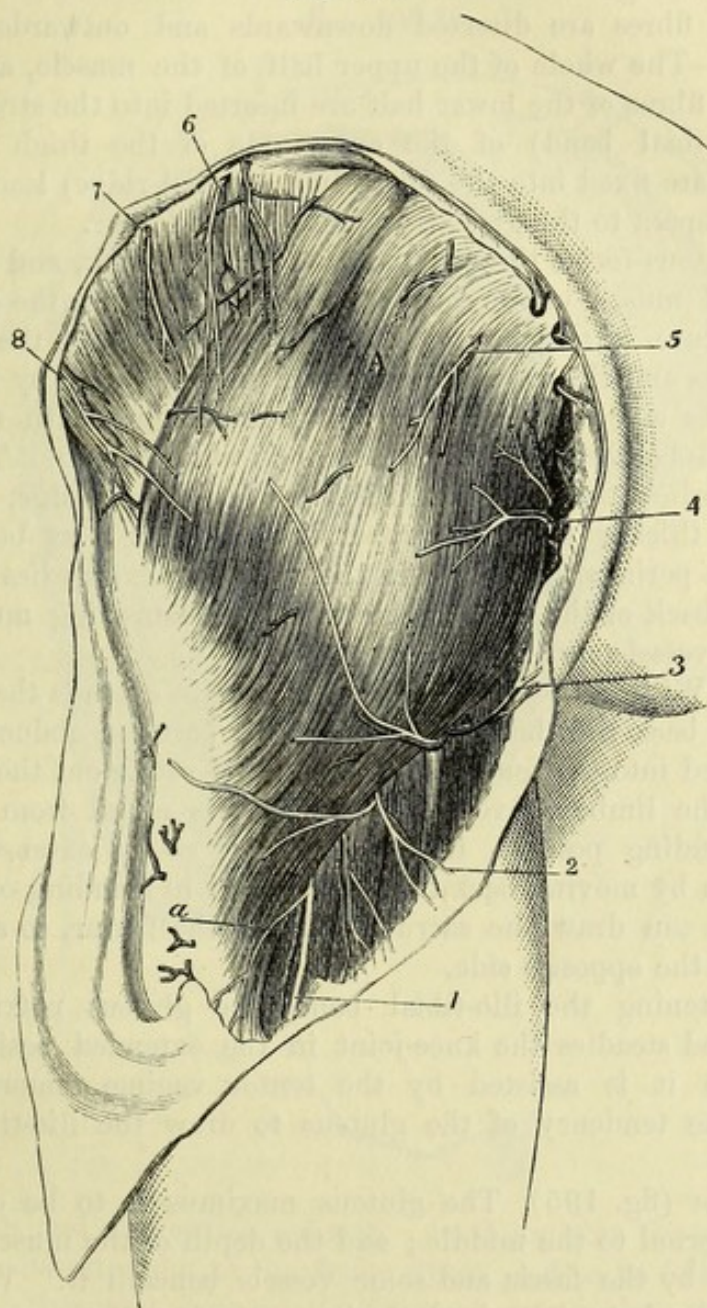
mode of proceeding.

Fascia of the buttock is thin and unimportant.

The *fascia of the buttock* is a prolongation of that enveloping the thigh, and is fixed to the crest of the ilium, and to the sacrum and coccyx. It is much thicker in front of, than on the gluteus

maximus, and gives attachment superiorly to the gluteus medius, which it covers. At the edge of the gluteus maximus, the fascia splits to encase the muscle.

Fig. 194.*



The GLUTEUS MAXIMUS (fig. 194, A) is the most superficial muscle of the buttock, and reaches from the pelvis to the upper part of the femur. Its *origin* from the pelvis is fleshy, and is connected with bone and with aponeurosis:—Thus, the muscle is attached, Gluteus maximus:
origin internally from pelvis;

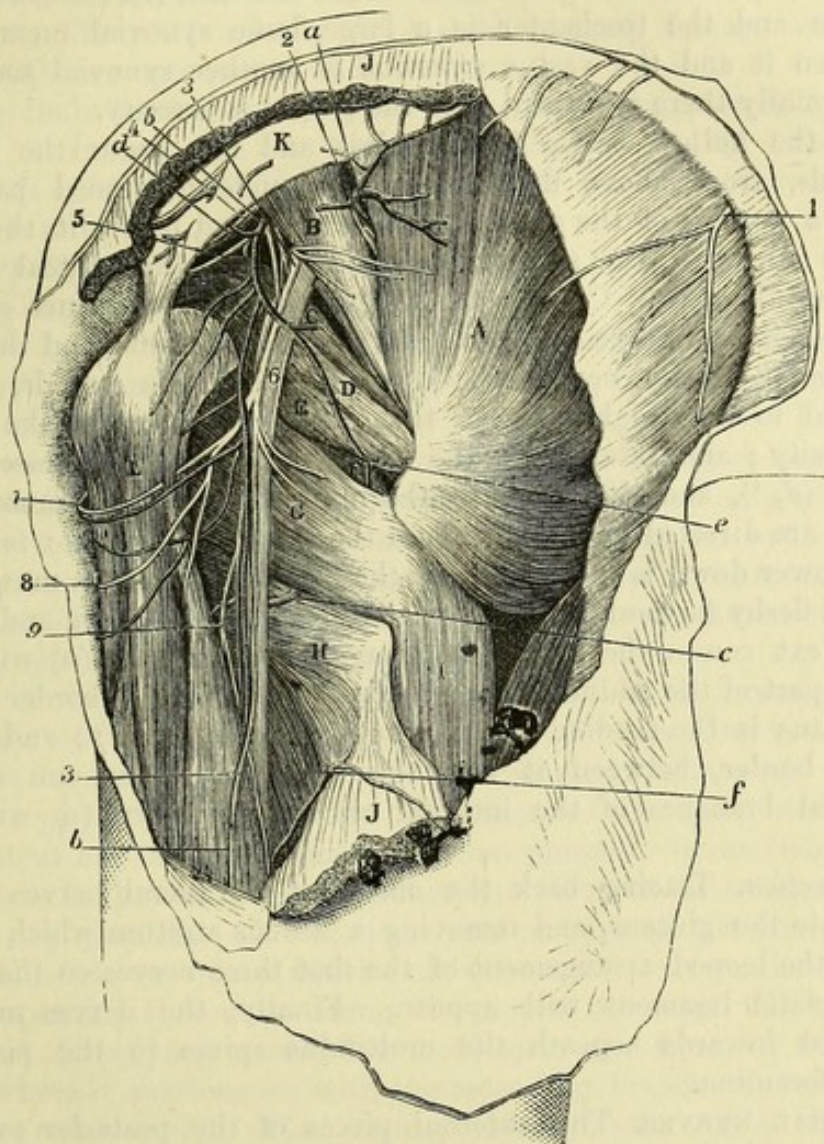
* Superficial view of the buttock of the left side (Illustrations of Dissections).
A. Gluteus maximus muscle, with the gluteus medius projecting above it.
a. Continuation of sciatic artery along the back of the thigh. *Nerves*: 1. Small sciatic trunk. 2. Its cutaneous thigh branches. 3. Inferior pudenda. 4. Branches of perforating cutaneous. 5. Cutaneous of the sacral. 6. Posterior branches of the lumbar nerves. 7. Ilio-hypogastric. 8. Last dorsal.

insertion externally into fascia and femur.	<p>from above down, to the posterior fourth of the iliac crest, and to a special impression on the hip-bone below it; next, to the aponeurosis of the erector spinæ muscle; then to the back of the fourth and fifth pieces of the sacrum, and the back of the coccyx; and lastly, to the great sacro-sciatic ligament. From this extensive origin the fibres are directed downwards and outwards to their <i>insertion</i>:—The whole of the upper half of the muscle, and a few superficial fibres of the lower half are inserted into the strong fascia lata (ilio-tibial band) of the outer side of the thigh; and the remainder are fixed into the rough line (gluteal ridge) leading from the linea aspera to the great trochanter of the femur.</p>
Relations of the surfaces	<p>The gluteus forms the prominence of the buttock, and resembles the deltoid muscle of the arm in its situation and in the coarseness of its texture. Its cutaneous surface is covered by the common integuments and the investing fascia of the limb, and by the superficial nerves and vessels. The things in contact with the under surface will be seen when the muscle is cut through. The upper border overlies the gluteus medius. The lower edge, which is longer and thicker than the upper, in its inner part bounds posteriorly the perineal space, and in the rest of its extent lies obliquely across the back of the thigh; beneath it the hamstring muscles and the sciatic vessels and nerves issue.</p>
Use on femur, on pelvis,	<p><i>Action.</i> With the femur hanging the muscle extends the hip-joint by putting back that bone; and the upper part can abduct, but the part inserted into the femur will adduct and rotate out the limb.</p> <p>When the limb is fixed, and the body is raised from a sitting into a standing posture, the gluteus acts as an extensor of the articulation by moving back the pelvis; and in standing on one leg, the muscle can draw the sacrum towards the femur, so as to turn the face to the opposite side.</p>
and on knee.	<p>By tightening the ilio-tibial band, the gluteus maximus also supports and steadies the knee-joint in the extended position. In this action it is assisted by the tensor vaginæ femoris, which corrects the tendency of the gluteus to draw the ilio-tibial band backwards.</p>
Divide the gluteus maximus,	<p><i>Dissection</i> (fig. 195). The gluteus maximus is to be cut across a little external to the middle; and the depth of the muscle will be ascertained by the fascia and some vessels beneath it. When this intermuscular layer is arrived at, the outer piece of the gluteus may be at once thrown towards its insertion; but the inner piece is to be carefully raised, and the branches of the inferior gluteal nerve, and of the gluteal and sciatic arteries entering its deep surface, are to be cleaned.</p>
clean parts beneath,	<p>The loose fat is then to be taken away from the hollow between the pelvis and the trochanter, without injuring the vessels and nerves; and the several muscles are to be cleaned, the fibres of each being made tense at the time of its dissection by rotating the femur. The vessels, nerves, and muscles, which are to be defined, may be ascertained by referring to the enumeration below of the parts beneath the gluteus. In removing the areolar tissue from the</p>

ischial tuberosity and the great trochanter, a bursa on each prominence of bone may be observed.

Lastly, the fibres of the muscle are to be detached at their origin ; remove and the inner piece may be removed entirely by cutting through origin,

Fig. 195.*



the vessels and nerves that enter it. In doing this the sacral nerves are to be dissected out of the fleshy fibres, and to be followed to the surface of the great sacro-sciatic ligament, where they will be afterwards seen. and dissect out sacral nerves.

* Second view of the dissection of the buttock (Illustrations of Dissections).
Muscles : A. Gluteus medius. B. Pyriformis. c. Upper gemellus. D. Obturator internus. E. Gemellus inferior. F. Obturator externus. G. Quadratus femoris. H. Adductor magnus. I. Vastus externus. J. Gluteus maximus, cut. K. Great sacro-sciatic ligament. L. Hamstring muscles.
Arteries : a. Gluteal, superficial part. b. Sciatic. c. Internal circumflex, transverse branch. d. Pudic. e. Anastomotic branch of sciatic. f. First perforating. *Nerves* : 1. Last dorsal. 2. Upper gluteal. 3. Small sciatic ; above this are branches of the inferior gluteal nerve, cut. 4. Pudic. 5. Nerve to the obturator internus. 6. Great sciatic. 7. Inferior pudendal. 8. Cutaneous of the thigh of small sciatic. 9. Muscular branch of great sciatic.

Parts
covered by
gluteus at
its origin

and inser-
tion ;

and by the
intervening
piece of the
muscle.

Parts beneath the gluteus (fig. 195). At its origin the gluteus maximus rests on the pelvis, and conceals part of the ilium, sacrum and coccyx, also the ischial tuberosity with the origin of the hamstring muscles (L) and the great sacro-sciatic ligament (κ). At its insertion it covers the upper end of the femur, with the great trochanter, and the origin of the vastus externus (I). Between the muscle and the trochanter is a large, loose synovial membrane ; between it and the vastus externus is another synovial sac ; and occasionally there is a third over the ischial tuberosity.

In the hollow between the pelvis and the femur the muscle conceals, from above downwards, the undermentioned parts :— First, a portion of the gluteus medius (A) ; and below it the pyramidalis (B), with the superficial branch (a) of the gluteal vessels between the two. Coming from beneath the pyramidalis are the inferior gluteal nerve supplying the gluteus maximus, and the large and small sciatic nerves (³, ⁶), with the sciatic vessels, which descend to the thigh between the great trochanter and the ischial tuberosity ; and internal to the sciatic are the pudic vessels and nerve (d, ⁴), and the nerve to the obturator internus muscle (⁵), which are directed inwards through the small sacro-sciatic foramen. Still lower down is the tendon of the obturator internus muscle (D) with a fleshy fasciculus—the gemellus (C and E)—above and below it. Next comes the thin quadratus femoris muscle (G) with the upper part of the adductor magnus (H) ; at the upper border of the quadratus is the tendon of the obturator externus (F) ; and at the lower border, between it and the adductor, issues one of the terminal branches of the internal circumflex artery (c) with its veins.

Trace sacral
nerves.

Dissection. Tracing back the offsets of the sacral nerves which perforate the gluteus, and removing a fibrous stratum which covers them, the looped arrangement of the first three nerves on the great sacro-sciatic ligament will appear. Finally, the nerves may be followed inwards beneath the multifidus spinæ to the posterior sacral foramina.

The sacral
nerves are
united
beneath
gluteus :

cutaneous
offsets.

SACRAL NERVES. The external pieces of the posterior primary branches of the first three sacral nerves, after passing outwards beneath the multifidus spinæ (p. 402), are joined by loops on the surface of the great sacro-sciatic ligament (fig. 123).

Two or three cutaneous offsets are derived from this intercommunication, and pierce the fibres of the gluteus maximus to be distributed on the surface (p. 632).

Gluteus
medius

arises from
hip-bone,

and inserted
into tro-
chanter.

Relations

The **GLUTEUS MEDIUS** (fig. 195, A) is triangular in form, with its base at the iliac crest, and apex at the femur. It *arises* from the outer surface of the ilium between the crest and the superior curved line above, and the middle curved line below ; and many superficial fibres come from the strong fascia covering the front of the muscle. The fibres converge to a tendon, which is *inserted* into an impression across the outer surface of the great trochanter, extending from the tip behind to the root in front.

The superficial surface is concealed in part by the gluteus maxi-

mus; and the deep is in contact with the gluteus minimus, and the gluteal vessels and nerve. The anterior border lies over the gluteus minimus, and is in contact with the tensor of the fascia lata. The posterior is contiguous to the pyriformis, only the superficial part of the gluteal vessels intervening. A small bursa is interposed between the tendon of insertion and the trochanter.

Action. The whole muscle abducts the hanging femur; and the anterior fibres rotate in the limb.

Use with limb hanging;

Both limbs resting on the ground, the muscles assist in fixing the pelvis. In standing on one leg this gluteus will aid in balancing the pelvis on the top of the femur, and will draw the body over to the same side.

both limbs fixed;

in standing on one leg,

In walking the fore part of the muscle acts in rotating the pelvis over the fixed limb.

and walking.

Dissection. When the gluteus medius is detached from the pelvis, and partly separated from the gluteus minimus beneath, the gluteal vessels and the superior gluteal nerve will come into view. The two chief branches of the artery,—one being near the iliac crest, and the other lower down,—are to be traced beneath the fleshy fibres as the reflection of the gluteus is proceeded with; and the main piece of the nerve is to be followed forwards to the tensor vaginæ femoris muscle. The branches of the artery and nerve to the gluteus medius will be cut in removing that muscle.

Detach gluteus medius to see gluteal vessels

and nerve.

The GLUTEAL ARTERY is the largest branch of the internal iliac (p. 558), and issues from the pelvis above the pyriformis muscle, where it at once divides into superficial and deep parts:—

Gluteal artery is

divided into two: superficial

The *superficial part* (fig. 195, *a*) penetrates the under surface of the gluteus maximus and ramifies in that muscle. Some twigs pass inwards over the sacrum; and others are given to the integuments.

The *deep part* (fig. 197, *a*) is the continuation of the artery, and subdivides into two pieces which run between the two smaller glutei. One (superior; *b*) courses along the upper border of the gluteus minimus (supplying mostly the medius) to the front of the iliac crest, where it anastomoses with the ascending branch of the external circumflex artery. The other portion (inferior; *c*) is directed forwards over the middle of the smallest gluteal muscle, with the nerve, towards the anterior lower iliac spine, where it enters the tensor of the fascia lata, and communicates with the external circumflex branch (p. 621): many offsets are furnished to the gluteus minimus, and some pierce that muscle to supply the hip-joint.

and deep parts;

the latter has an upper and a lower branch.

Vein. The companion vein with the artery enters the pelvis, and ends in the internal iliac vein.

Gluteal vein.

The SUPERIOR GLUTEAL NERVE (fig. 197, *1*) is the highest branch of the sacral plexus, and arises from the lumbo-sacral cord and the first sacral nerve (p. 564). It accompanies the gluteal artery, and divides into two for the supply of the gluteus medius and minimus; its lower branch terminates anteriorly in the tensor vaginæ femoris (*B*).

Superior gluteal nerve

is muscular.

The GLUTEUS MINIMUS (fig. 197, *c*) is triangular in shape, and arises from the dorsum of the ilium between the middle and inferior

Gluteus minimus:

attach- ments ;	curved lines, extending backwards as far as the middle of the anterior margin of the great sciatic notch. Its tendon is <i>inserted</i> into an impression along the fore part of the great trochanter, where it is united inferiorly with the gluteus medius : some fibres are attached to the capsule of the hip-joint.
relations ;	One surface is in contact with the gluteus medius, and the gluteal vessels and nerve ; the other with the hip-bone, the hip-joint, and the outer head of the rectus femoris muscle. The anterior border lies by the side of the gluteus medius ; and the posterior is covered by the pyriformis muscle. A bursa is placed between the tendon and the bone.
use like medius.	<i>Action.</i> This muscle agrees in its action with the gluteus medius ; but as it reaches farther backwards, the hinder fibres may also have some influence in rotating out the hanging femur.
Divide smallest gluteus ;	<i>Dissection.</i> Cut through the smallest gluteal muscle near the ilium, and define the tendinous portion of the rectus femoris underneath it, close above the hip-joint. While detaching the gluteus from the parts underneath, the student cannot fail to notice the connection between its tendon and the capsule of the joint.
trace deep vessels.	The deep vessels to the articulation may be observed and followed as the muscle is removed.
Posterior head of the rectus.	The <i>posterior</i> or <i>reflected head of the rectus femoris</i> is a tendon as wide as the little finger, and about two inches long, which is fixed into the impression above the margin of the acetabulum. In front it joins the straight head, which is attached to the anterior inferior iliac spine ; and its lower border is connected with the capsule of the hip-joint.
Origin of pyriformis ;	The PYRIFORMIS (fig. 195, B) <i>arises</i> in the pelvis from the front of the sacrum (p. 588), and leaves that cavity through the great sacro-sciatic foramen. Outside the pelvis it ends in a rounded
insertion ;	tendon, which is <i>inserted</i> into the upper edge of the great trochanter, between the two smaller glutei.
relations in foramen ;	The muscle occupies the greater part of the sacro-sciatic foramen, and divides the vessels and nerves passing through that aperture into two groups :—Above it are the gluteal vessels and the superior gluteal nerve ; and below it the sciatic and pudic vessels and nerves,
in buttock.	and some other branches of the sacral plexus. Its upper border is contiguous to the gluteus medius ; and its lower, to the superior gemellus. Like the other rotator muscles in this situation, it is covered by the gluteus maximus, and by the gluteus medius at the insertion ; it rests on the gluteus minimus, which separates it from the hip-joint. Its tendon is united by fibrous tissue to that of the obturator and gemelli.
Use with femur hang- ing, and raised ;	<i>Action.</i> The pyriformis rotates out the femur when that bone is in a line with the trunk ; but if the hip-joint is bent it abducts the limb.
both limbs on ground,	Both limbs being fixed, the muscles balance the pelvis, and help to make the trunk erect after stooping to the ground. In standing
only one.	on one leg, besides assisting to support the trunk, the pyriformis turns the face to the opposite side.

Dissection. The pyriformis may be cut across and raised towards the sacrum, to allow the dissector to follow upwards the sciatic and pudic vessels, and to trace the accompanying nerves to their origin from the sacral plexus.

Dissect out the chief vessels and nerves,

A small nerve to the obturator internus (fig. 197, ⁵) and gemellus superior (⁷) is to be sought in the fat at the lower border of the plexus. A branch to the quadratus and inferior gemellus (⁶) may be found by raising the trunk of the great sciatic nerve; but this will be followed to its termination after the muscles it supplies have been seen.

and muscular branches.

SCIATIC AND PUDIC VESSELS. The arteries on the back of the pelvis, below the pyriformis muscle, are branches of the internal iliac (p. 559).

The vessels come from the iliac.

The SCIATIC ARTERY (fig. 195, *b*) supplies the buttock below the gluteal. After escaping from the pelvis below the pyriformis, it descends with the small sciatic nerve over the gemelli and obturator internus muscles, as far as the lower border of the gluteus maximus; here the artery gives off many branches with the superficial offsets of its companion nerve; and much reduced in size, it is continued with that nerve along the back of the thigh. In this course it furnishes the following branches:—

Sciatic artery:

course and ending;

branches;—

a. The *coccygeal branch*, arising close to the pelvis, perforates the great sacro-sciatic ligament and the gluteus maximus, and ramifies in this muscle, and on the back of the sacrum and coccyx.

coccygeal;

b. The *branch to the great sciatic nerve* (comes nervi ischiadici) is very slender, and entering the nerve near the pelvis, ramifies in it along the thigh.

branch to sciatic nerve;

c. *Muscular branches* enter the gluteus maximus, the upper gemellus, and obturator internus; and by means of a branch to the quadratus, which passes with the nerve of the same name beneath the gemelli and obturator internus, it gives offsets to the hip-joint and the inferior gemellus.

muscular;

d. *Anastomotic branch* (fig. 195, *e*). Varying in size, this artery is directed outwards to the root of the great trochanter, where it anastomoses with the internal circumflex and first perforating arteries.

anastomotic.

The PUDIC ARTERY (fig. 195, *d*) belongs to the perineum and the genital organs: it is smaller than the sciatic, internal to which it lies. Only the small part of the vessel which winds over the ischial spine is seen on the back of the pelvis, for it enters the perineal space through the small sacro-sciatic foramen, and is there distributed (p. 421).

Pudic artery

crosses the ischial spine;

It supplies a small branch over the back of the sacrum, which anastomoses with the gluteal and sciatic arteries; and a twig from it accompanies the nerve to the obturator internus muscle.

offsets.

The *veins* with the sciatic and pudic arteries receive contributing twigs corresponding with the branches of those arteries at the back of the pelvis, and open into the internal iliac vein.

Veins.

NERVES. The nerves appearing at the back of the pelvis, below the pyriformis, are derived from the sacral plexus (p. 562); the

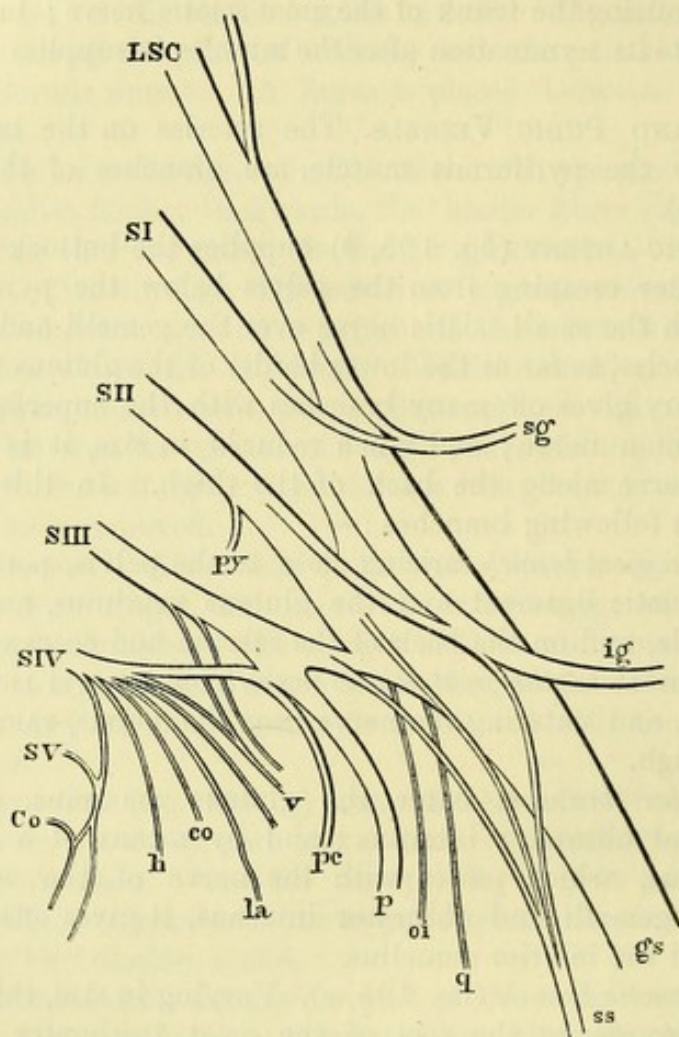
Nerves come from sacral plexus.

largest are furnished to parts beyond the gluteal region, but some are distributed to the muscles at the back of the pelvis.

Inferior
gluteal to
gluteus
maximus.

The INFERIOR GLUTEAL NERVE is larger than the superior, and arises from the upper part of the sacral plexus (fig. 196, ig). The short trunk is directed backwards below the pyriformis, and divides

Fig. 196.*



into numerous branches which radiate upwards and downwards, and enter the gluteus maximus midway between its origin and insertion.

Small sciatic
is a cutane-
ous nerve ;

The SMALL SCIATIC (fig. 195,³) is a cutaneous nerve of the back of the thigh. It springs from the second and third sacral nerves (fig. 196, ss), and takes the course of the sciatic artery as far as the lower border of the great gluteus, where it gives many cutaneous branches. Much diminished in size at that spot, the nerve is continued along the back of the thigh beneath the fascia, and ends

* Diagram of the sacral plexus from behind. LSC. Lumbo-sacral cord formed by the fifth lumbar nerve and a small branch from the fourth. SI to SV. First to fifth sacral nerves. gs. Great sciatic nerve. ss. Small sciatic. sg. Superior gluteal. ig. Inferior gluteal. p. Pudic. pc. Perforating cutaneous. py. Branch to pyriformis. oi. Nerve to obturator internus. q. Nerve to quadratus femoris. The remaining reference : are explained on p. 563.

below the knee in the integuments of the back of the leg (p. 662). The branches distributed to, or near the buttock, are the following:—

The *ascending* or *gluteal cutaneous branches* (fig. 194) turn upwards round the border of the gluteus maximus, and are distributed to the skin over the lower third of the muscle.

The *descending cutaneous branches* (fig. 194,²) supply the integuments of the upper third of the thigh at the inner and posterior aspects. One of these branches (fig. 195,⁷), which is larger than the others, is distributed to the genital organs, and is named *inferior pudendal* (p. 425); as it courses to the perineum, it turns below the ischial tuberosity, and perforates the fascia lata at the inner side of the thigh to end in the scrotum.

The GREAT SCIATIC (fig. 195,⁶) is the largest nerve in the body. It is the source of all the muscular, and most of the cutaneous branches to the limb beyond the knee, as well as of the muscular branches at the back of the thigh.

At its origin it appears to be a prolongation of the sacral plexus (fig. 196, *g s*). It is directed through the buttock to the back of the thigh, and rests on the external rotator muscles below the piriformis. Commonly it does not supply any branch to the buttock, but it may give origin to one or two filaments to the hip-joint. Frequently the nerve is divided into two large trunks at its origin, and one of them (the external popliteal) pierces the fibres of the piriformis muscle.

The PUDIC NERVE (fig. 195,⁴) winds over the small sacro-sciatic ligament by the side of its companion artery, and is distributed with this vessel to the perineum and the genital organs (p. 421). No branch is supplied to the buttock.

Small MUSCULAR BRANCHES of the sacral plexus are furnished to the external rotators except the obturator externus.

The *branch to the piriformis* is seen in the dissection of the sacral plexus in the pelvis (p. 564).

The *nerve to the obturator internus* (fig. 197,⁵) arises from the upper part of the plexus, and is directed to its muscle through the small sacro-sciatic foramen with the pudic vessels: it gives off a small twig to the superior gemellus (⁷).

The *nerve to the quadratus femoris* (fig. 197,⁶) is a slender branch, which passes with a companion artery beneath the gemelli and the obturator to the anterior surface of its muscle. This branch will be seen more fully in a subsequent dissection, when offsets from it to the inferior gemellus and the hip-joint may be traced.

Dissection. To see the remaining external rotator muscles, hook aside the great sciatic nerve, and take away the branches of the sciatic artery if it is necessary. In cleaning these muscles the limb should be rotated inwards. The gemelli are to be separated from the tendon of the obturator internus.

The SUPERIOR GEMELLUS (fig. 195, *c*) is the higher of the two muscular slips along the sides of the tendon of the obturator muscle. Internally it arises from the outer and lower part of

the ischial spine, and externally it is *inserted* with the obturator into the great trochanter. Sometimes the muscle is absent.

Inferior gemellus : The INFERIOR GEMELLUS (fig. 195, E) is larger than its fellow. Its *origin* is connected with the upper part of the ischial tuberosity, along the lower edge of the groove for the obturator internus muscle; and its *insertion* is in common with the obturator tendon. This muscle is placed between the obturator internus and quadratus, but near the femur the tendon of the obturator externus comes into contact with its lower border.

use to help obturator. *Action.* These small fleshy slips are but accessory pieces of origin to the internal obturator, with which they combine in use.

Obturator internus The OBTURATOR INTERNUS (fig. 195, D) arises from the hip-bone inside the pelvis (p. 588), and passes to the exterior through the small sacro-sciatic foramen. The tendon of the muscle is directed outwards over the hip-joint, and is *inserted* with the gemelli, in front of the pyriformis, into the inner side of the great trochanter, at the upper and fore part.

relations ; Outside the pelvis the obturator is mostly tendinous, and is embraced by the gemelli muscles in the following way ; near the pelvis the gemelli meet beneath, but near the trochanter they cover the tendon. Crossing the muscle are the large and small sciatic nerves and the sciatic vessels ; and covering the whole is the gluteus maximus. On cutting through the tendon and raising the inner end, it will be found divided into four or five pieces as it turns over the margin of the pelvis (fig. 197, H) ; at this spot the bone is covered with cartilage, which forms ridges corresponding to the intervals between the tendinous slips, and the surfaces are lubricated by a synovial sac. There is sometimes another bursa between the tendon and the back of the hip-joint.

tendon is divided on the edge of the pelvis ; *Action.* The action of this muscle is in all respects the same as that of the pyriformis (p. 638).

use like pyriformis. The QUADRATUS FEMORIS (fig. 195, G) is situate between the inferior gemellus and the adductor magnus. Internally it *arises* from the outer border of the ischial tuberosity for two inches, by the side of the semimembranosus and adductor magnus ; externally it is *inserted* into a tubercle on the posterior intertrochanteric ridge of the femur (tubercle of the quadratus), and along a line on the upper end of that bone for about two inches, above the attachment of the great adductor.

Quadratus femoris : By one surface it is in contact with the sciatic vessels and nerves, and the gluteus maximus. By the other it rests on the obturator externus, the internal circumflex vessels, and its small nerve and vessels. Between its lower border and the adductor magnus the transverse branch of the internal circumflex artery issues. Between it and the small trochanter is a bursa, which is also common to the upper part of the adductor magnus.

origin ; *Action.* The quadratus differs from the foregoing muscles of the same group in being able to rotate out the femur when the hip-joint is bent, as well as in the extended position ; and it will assist slightly in adducting the limb.

insertion ;

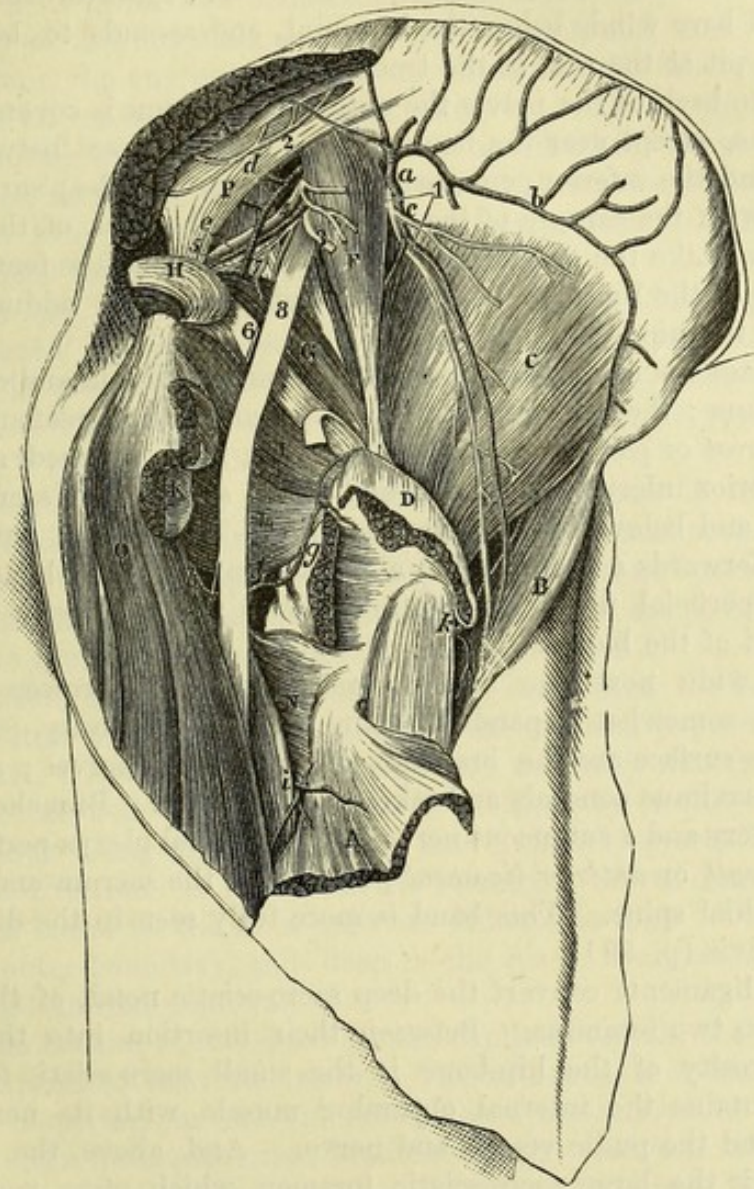
parts over and beneath it,

and at lower border ;

use.

Dissection (fig. 197). The quadratus and the gemelli muscles may be now cut across, in order that their small nerve and artery, the ending of the internal circumflex artery, and the obturator externus may be dissected out. Divide quadratus and gemelli.

Fig. 197.*



The INTERNAL CIRCUMFLEX branch (fig. 197, *f*) of the profunda artery (p. 628) divides finally into two pieces. One (*ascending*; *g*) runs beneath the quadratus (in this position of the body) to the pit Interna circumflex artery

* Third view of the dissection of the buttock (Illustrations of Dissections).
Muscles: A. Gluteus maximus, cut. B. Tensor fasciæ latæ. C. Gluteus minimus. D. Gluteus medius, cut. F. Pyriformis. G. Gemellus superior. H. Obturator internus, cut. I. Gemellus inferior. K. Quadratus femoris, cut. L. Obturator externus. N. Adductor magnus. O. Hamstrings. P. Great sacro-sciatic ligament. *Arteries*: a. Gluteal. b. Its upper, and c, its lower piece. d. Sciatic. e. Pudic. f. Internal circumflex. g. Its ascending, and h, its transverse offset. i. First perforating. k. External circumflex. *Nerves*: 1. Superior gluteal. 2. Sacral. 3. Small sciatic, cut. 4. Pudic. 5. Nerve to obturator internus. 6. Nerve to quadratus and inferior gemellus. 7. Branch to upper gemellus. 8. Great sciatic.

- ends in two branches. of the trochanter, where it anastomoses with the gluteal and sciatic arteries, and supplies the bone. The other (*transverse; h*) passes between the quadratus and adductor magnus to the hamstring muscles, and communicates with the perforating arteries.
- Obturator externus is inserted into pit of trochanter; The OBTURATOR EXTERNUS (fig. 197, L) has been dissected at its origin in the front of the thigh (p. 630). The part of the muscle now laid bare winds below the hip-joint, and ascends to be inserted into the pit at the root of the trochanter.
- relations; On the back of the pelvis the obturator externus is covered by the quadratus, except near the femur where it is exposed between that muscle and the inferior gemellus (fig. 195, F). Its deep surface is in contact with the capsule of the hip-joint and the neck of the femur.
- use. *Action.* Like the quadratus femoris, it rotates out the femur in all positions of the limb: it is also to a slight extent an adductor and flexor of the hip-joint.
- Sacro-sciatic ligaments: The SACRO-SCIATIC LIGAMENTS pass from the sacrum and coccyx to the ischium: they are two in number, and are named great and small.
- large, The *great* or *posterior ligament* (fig. 197, P) is attached above to the posterior inferior iliac spine, and to the side of the sacrum and coccyx; and below, to the inner margin of the ischial tuberosity, sending forwards a prolongation along the ramus of the bone: some of the superficial fibres are continued over the tuberosity into the long head of the biceps.
- and small; It is wide next the sacrum, and becomes narrower below; but it is somewhat expanded again at the tuberosity. On the cutaneous surface are the branches of the sacral nerves; and the gluteus maximus conceals and takes origin from it. Branches of the sciatic artery and a cutaneous nerve from the sacral plexus perforate it.
- form two foramina; The *small* or *anterior ligament* passes from the sacrum and coccyx to the ischial spine. This band is more fully seen in the dissection of the pelvis (p. 591).
- small, with contents; These ligaments convert the deep sacro-sciatic notch of the dried pelvis into two foramina. Between their insertion into the spine and tuberosity of the hip-bone is the small sacro-sciatic foramen, which contains the internal obturator muscle with its nerve and vessels, and the pudic vessels and nerve. And above the smaller
- large, and parts passing through it. ligament is the large sacro-sciatic foramen, which gives passage to the pyriformis muscle, with the gluteal vessels and the superior gluteal nerve above it, and the sciatic and pudic vessels and nerves, the inferior gluteal nerve, and the nerves to the obturator internus and quadratus femoris below it.

SECTION III.

THE BACK OF THE THIGH.

- Directions. *Directions.* The ham or popliteal space may be taken after the buttock, in order that it may be seen in a less disturbed state than if it was dissected after the examination of the muscles at the back

of the thigh. When this space has been learnt, the student will return to the dissection of the thigh.

Position. The limb should be raised into the horizontal position. Position.

Dissection (fig. 198). To remove the skin from the popliteal region, let a longitudinal incision be made behind the knee for the distance of six inches above, and four inches below the joint. At each extremity of this cut make a transverse incision, and raise the skin in two flaps, the one being turned outwards and the other inwards. Take the skin from over the ham.

In the fat are some small cutaneous nerves, viz., one or two twigs in the middle line of the limb from the small sciatic nerve beneath the fascia; and some offsets of the internal cutaneous nerve towards the inner side. After the subcutaneous fat is removed, the special fascia of the limb will be brought into view. Seek the cutaneous nerves.

Fascia lata. Where this fascia covers the popliteal space it is strengthened by transverse fibres, particularly on the outer side; and it is connected laterally with the tendons bounding that interval. The short saphenous vein perforates it opposite the knee, or a little lower down. Fascia of the limb over the ham.

Dissection (fig. 198). The fascia over the ham is now to be removed without injuring the small sciatic nerve and accompanying artery, and the short saphenous vein, which are close beneath it. A large quantity of fat may be next taken out of the space, but without injury to the several small vessels and nerves in it. Remove fascia, and take the fat from the ham.

In cleaning the space the student will come upon the large internal popliteal nerve in the middle, and the external popliteal on the outer side. Both nerves give branches; and the numerous offsets of the inner will be recognized more certainly by tracing them from above down along the trunk of the nerve, than by proceeding in the opposite direction: in fat bodies the two small nerves from the inner popliteal trunk to the knee-joint are difficult to find. Under cover of the outer boundary, and deep in the space, is an articular nerve from the external popliteal. Seek the nerves in the space.

In the bottom of the space are the popliteal vessels, the vein being more superficial than the artery. The student is to seek an articular branch (superior) on each side, close above the condyle of the femur, and to clean numerous other branches of the vessels to the muscles around, especially to those of the calf. On the upper part of the artery, the branch of nerve from the obturator to the knee-joint is to be found; and on the sides of the artery are three or four lymphatic glands in the fat. Clean the vessels; find obturator nerve, and glands.

After the ham has been cleaned, the sartorius and the gracilis are to be replaced in their natural position on the inner side.

The POPLITEAL SPACE, or ham (fig. 198), is the hollow behind the knee: it allows of the free flexion of the joint, and contains the large vessels of the limb. When dissected, this interval has the form of a lozenge, and extends upwards along one-third of the femur, and downwards along one-sixth of the tibia; but in the natural condition the muscles on the sides are approximated by the fascia of the limb, and the space is limited almost to the region of the joint. The ham: situation and extent;

boundaries, This hollow is situate between the muscles on the back of the limb; and the lateral boundaries are therefore formed by the muscles of the thigh (hamstrings), and leg. Thus, on the outer side, is the biceps muscle (6) as far as the joint, and the plantaris and the external head of the gastrocnemius (8) beyond that spot. On the inner side, as low as the articulation, are the semimembranosus (4) and semitendinosus (5) muscles with the gracilis and sartorius between them and the femur; and beyond the joint is the inner head of the gastrocnemius (7). The upper point of the ham is formed by the apposition of the inner and outer hamstrings; and at the lower point the heads of the gastrocnemius touch each other.

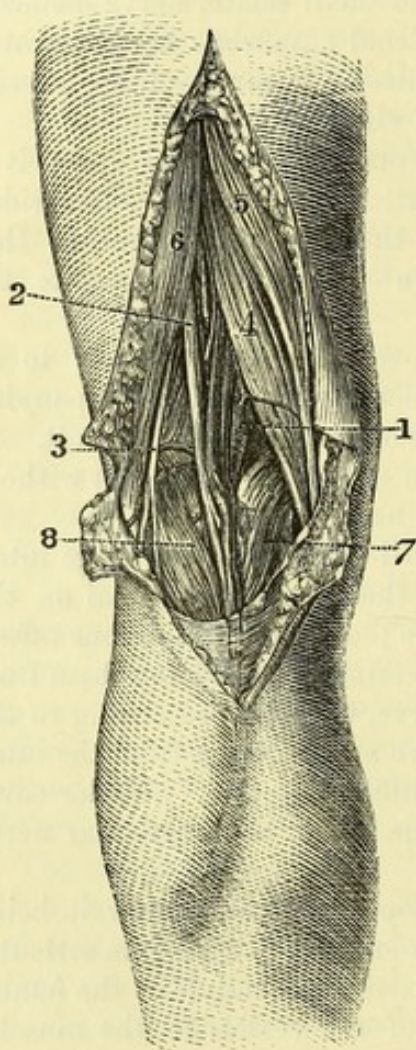
Fig. 198*.

limit above
and below;

superficial
and deep
boundaries;

greatest
width and
depth;

contents.



Stretched over the cavity are the fascia lata and the integuments. In the deep boundary, or the floor, are the following things,—the surface on the back of the femur included between the lines to the condyles (popliteal surface), the posterior ligament of the knee-joint, and part of the popliteus muscle with the upper end of the tibia.

The popliteal space is widest and deepest immediately above the femoral condyles. Above and below it communicates, beneath the muscles, with the back of the thigh and leg.

In the hollow are contained the popliteal vessels with their branches, and the ending of the external saphenous vein; the popliteal trunks of the great sciatic nerve, and some of their branches; together with lymphatic glands, and a large quantity of fat. The small sciatic nerve

and its vessels are placed superficially in the ham; and a branch of the obturator nerve lies on the artery in the bottom of the space.

Popliteal
artery:

extent;

only a small
part in
space.

The POPLITEAL ARTERY (fig. 198, 1) is the continuation of the femoral, and reaches from the opening in the adductor magnus to the lower border of the popliteus muscle, where it terminates by bifurcating into the anterior and posterior tibial arteries. A portion of the artery lies in the popliteal space, and is not covered by muscle;

* View of the popliteal space (Quain's Arteries). 1. Popliteal vessels. 2. Internal popliteal nerve. 3. External popliteal nerve. 4. Semimembranosus muscle. 5. Semitendinosus muscle. 6. Biceps muscle. 7, 8. Inner and outer heads of the gastrocnemius muscle. The superficial vein on the gastrocnemius is the short saphenous, which enters the popliteal.

but both above and below, it is concealed by the muscles bounding the hollow. The description of the artery may be conveniently divided into two parts,—one reaching to the lower limit of the ham, and the other being beneath the gastrocnemius.

As far as the ham the vessel is inclined obliquely from the inner side of the limb to the interval between the condyles of the femur, and is then directed along the middle of the space over the knee-joint. The artery is overlain by the belly of the semimembranosus muscle to within an inch of the internal condyle; but thence onwards it is situate between the heads of the gastrocnemius, and is covered only by the fascia lata and the integuments. Beneath it is the femur, with the posterior ligament of the knee-joint.

The part in the ham:

course and relations;

In contact with the vessel, and somewhat on the outer side at first, lies the popliteal vein, so that on looking into the space, the arterial trunk is almost covered; but in the interval between the heads of the gastrocnemius, the vein and its branches conceal altogether the artery. In the lower part of the ham the short saphenous vein (fig. 199, *i*), and the muscular branches of the artery, are also superficial to the popliteal trunk.

position of the vein,

More superficial than the large vessels, and slightly external to them in position, is placed the internal popliteal nerve, which, with its branches, lies over the artery, like the vein, between the heads of the gastrocnemius. In the bottom of the hollow the small obturator nerve runs on the artery to the joint.

and of the nerves.

Dissection. To see the deep part of the artery, the inner head of the gastrocnemius should be cut through and raised. On removing the areolar tissue the vessels and nerves will appear. The lower articular branches of the vessels and nerve are now brought into view;—the inner artery is below the head of the tibia, and the outer, higher up, between the tibia and fibula, each with a vein; and the first has a companion nerve.

Cut inner head of the gastrocnemius.

Beyond the ham. While the artery is beneath the gastrocnemius (fig. 204) it sinks deeply into the limb; here it is crossed by a small muscle—the plantaris (*c*), and the ending is concealed by the soleus (*b*). It rests on the popliteus muscle.

Artery beyond ham:

Both the companion vein and the internal popliteal nerve change their position to the artery, and gradually cross over to it, so as to lie on its inner side at the lower border of the popliteus.

position of vein and nerve.

Sometimes the artery is divided as high as the back of the knee-joint; and then the anterior tibial artery may lie beneath the popliteus muscle.

Branches (fig. 199) are furnished by the artery to the surrounding muscles, to the integuments, and to the articulation;—those that belong to the joint are five in number, and are called articular, viz., two superior, inner and outer; two inferior, also inner and outer; and a central or azygos branch.

Branches of artery.

a. The *muscular branches* are upper and lower. The upper set, three or four in number, arise above the knee, and end in the semimembranosus and biceps muscles, communicating with the perforating and muscular branches of the profunda. The lower set (sural)

Muscular branches,

are furnished to the muscles of the calf, viz., gastrocnemius, soleus, and plantaris.

and cutaneous.

b. The *cutaneous* or *superficial sural branches* descend to the skin of the calf of the leg : they are usually three in number, one in the middle line, and one over each head of the gastrocnemius.

Articular branches are five :—

c. The *superior articular arteries* arise from the popliteal trunk, one from the inner and one from the outer side, above the condyles of the femur ; they are directed almost transversely beneath the hamstring muscles, and turn round the bone to the front of the joint.

Two superior :

external ;

The *external branch* (*k*) perforates the intermuscular septum, and divides in the substance of the crureus. Some of the branches end in that muscle, and anastomose with the external circumflex (of the profunda) ; others descend to the joint and anastomose with the lower external articular artery ; and one offset forms an arch across the front with the anastomotic artery.

internal.

The *internal artery* (*l*), oftentimes very small, winds beneath the tendon of the adductor magnus, and terminates in the vastus internus ; it supplies this and the knee-joint, and communicates with the deep part of the anastomotic artery.

Two inferior :

d. The *inferior articular arteries* (fig. 204) lie beneath the gastrocnemius, but are not on the same level on opposite sides of the limb ; for the inner one descends below the internal tuberosity of the tibia, while the outer one is placed above the head of the fibula. Each lies beneath the lateral ligament of its own side.

external ;

The *external branch* (*c*) supplies the outer side of the knee-joint, anastomosing with the other vessels on the articulation, and with the recurrent branch of the anterior tibial artery ; it sends an offset beneath the ligament of the patella to join a twig from one of the internal branches.

internal.

The *internal artery* (*b*) ramifies over the front of the internal tuberosity of the tibia, and anastomoses with the upper internal and lower external articular branches, and with the superficial branch of the anastomotic artery.

And one central artery.

e. The *azygos branch* enters the joint through the posterior ligament, and is distributed to the ligamentous structures, the fat, and the synovial membrane of the interior.

Popliteal vein :

The POPLITEAL VEIN (fig. 199, *h*) originates in the union of the anterior and posterior tibial venæ comites, and has the same extent and relations as the artery it accompanies. At the lower border of the popliteus muscle the vein is internal to the arterial trunk ; between the heads of the gastrocnemius it is superficial to that vessel ; and thence to the opening in the adductor magnus it lies to the outer side of, and close to, the artery. It is joined by branches corresponding with those of the artery, as well as by the short saphenous vein.

position to the artery ;

branches.

Popliteal nerves are two, inner and outer.

The POPLITEAL NERVES (fig. 198) are the two large trunks derived from the division of the great sciatic in the thigh (p. 652), and are named internal and external. Each furnishes cutaneous and articular offsets, but only the inner one supplies branches to muscles.

The INTERNAL POPLITEAL NERVE (²) is larger than the external, and occupies the middle of the ham: its relations are similar to those of the artery, that is to say, it is partly superficial, and partly covered by the gastrocnemius. The nerve is continued to the back of the leg; but it retains the name popliteal only to the lower border of the popliteus muscle. Its position to the vessels has been already noticed. The branches arising from it are the following:—

Internal
popliteal
nerve:

a. Two small *articular twigs* (fig. 199, ⁹) are furnished to the knee-joint with the vessels. One accompanies the lower internal articular artery to the front of the articulation, and is the larger; the other takes the same course as the azygos artery, and enters the back of the joint with it.

branches
are

two
articular:

b. *Muscular branches* arise from the nerve between the heads of the gastrocnemius. One is furnished to each head of the gastrocnemius, and the outer of these usually supplies the plantaris. Another descends beneath the gastrocnemius, and enters the posterior surface of the soleus. And a fourth penetrates the popliteus at the anterior aspect, after turning round the lower border.

four
muscular;

c. The *tibial communicating branch* (fig. 203, ³) is a cutaneous offset to the leg and foot. It lies beneath the fascia, and between the heads of the gastrocnemius, as far as the middle of the leg, where it becomes superficial, and unites with the peroneal communicating branch of the external popliteal, to form the short saphenous nerve (p. 660).

and one
cutaneous,
the tibial
communi-
cating.

The EXTERNAL POPLITEAL NERVE (peroneal; fig. 198, ³) lies along the outer boundary of the ham, and is at first concealed by the edge of the biceps muscle; becoming superficial, it is continued over the outer head of the gastrocnemius, following the hinder border of the biceps tendon, until it is below the head of the fibula. There it enters the fibres of the peroneus longus, and divides beneath that muscle into two—musculo-cutaneous and anterior tibial. Its branches are articular and cutaneous:—

External
popliteal
nerve:

course
and ending:

a. The *articular nerve*, arising high in the space, runs with the upper external articular artery to the outer side of the knee, and sends a twig along the lower articular artery: both enter the joint.

articular;

b. The *peroneal communicating branch* (fig. 203, ⁴) soon pierces the fascia, and descends over the outer head of the gastrocnemius to join the tibial communicating from the internal popliteal in the short saphenous nerve.

peroneal
communi-
cating;

c. One or two *external cutaneous branches* arise either in common with the preceding or separately, and supply the skin of the outer side of the leg, reaching nearly to the external malleolus.

and external
cutaneous
of leg.

The ARTICULAR BRANCH OF THE OBTURATOR NERVE (fig. 199, ⁷) perforates the adductor magnus (p. 627), and is conducted by the popliteal artery to the back of the knee. After supplying filaments to the vessels, the nerve enters the articulation through the posterior ligament.

Articular
nerve of the
obturator.

The POPLITEAL LYMPHATIC GLANDS are situate round the large arterial trunk. Two or three are ranged on the sides; while one

Lymphatic
glands
around the
artery.

is superficial to, and another beneath the vessel : they are joined by the deep lymphatic vessels, and by the superficial set with the external saphenous vein.

THE BACK OF THE THIGH.

Dissect the back of the thigh.

Seek out cutaneous nerves,

clean muscles and nerves.

Three muscles on back of thigh :

situation.

Biceps arises by a long

and a short head ;

is inserted into the fibula and tibia ;

relations ;

use on knee and hip-joints,

on pelvis,

and femur.

Semitendinosus is attached to pelvis and tibia ;

Dissection (fig. 199). After the popliteal space, the student may proceed with the dissection of the back of the thigh. The limb being replaced in the hanging position, the piece of skin between the buttock and the ham should be divided and reflected to the sides. In the fat on the outer side of the limb fine offsets of the external cutaneous nerve of the thigh may be found ; and along the middle some filaments from the small sciatic nerve pierce the fascia.

Remove the deep fascia of the limb, taking care of the small sciatic nerve and its artery. Lastly, clean the hamstring muscles ; trace the perforating and anastomotic arteries from the front of the thigh ; and clean the branches of the great sciatic nerve to the muscles.

MUSCLES. The muscles behind the femur are flexors of the knee-joint. They reach from the pelvis to the bones of the leg, and are named hamstrings from their cord-like appearance on the sides of the ham. They are three in number, viz., biceps, semitendinosus, and semimembranosus. The first of these lies on the outer, and the others on the inner side of the popliteal space.

The BICEPS (fig. 199, D) has two heads of origin, long and short, which are attached to the pelvis and the femur. The long head *arises* from the upper and inner impression on the ischial tuberosity, in common with the semitendinosus muscle. The short head is fixed to the femur below the gluteus maximus, viz., to all the linea aspera, and to the upper three-fourths of the line leading to the outer condyle, as well as to the external intermuscular septum. The fibres end below in a tendon, which is *inserted* into the head of the fibula by two slips which embrace the external lateral ligament ; and a slight piece is prolonged to the head of the tibia.

The muscle is superficial, except at the origin, where it is covered by the gluteus maximus ; it rests on the upper end of the semimembranosus, on the great sciatic nerve, and on the adductor magnus muscle. On the inner side are the semitendinosus and semimembranosus as far as the ham. Its tendon gives an offset to the deep fascia of the limb.

Action. It can bend the knee if the leg-bones are not fixed, and afterwards rotate out the tibia ; and the long head will extend the bent hip-joint when the knee is straight.

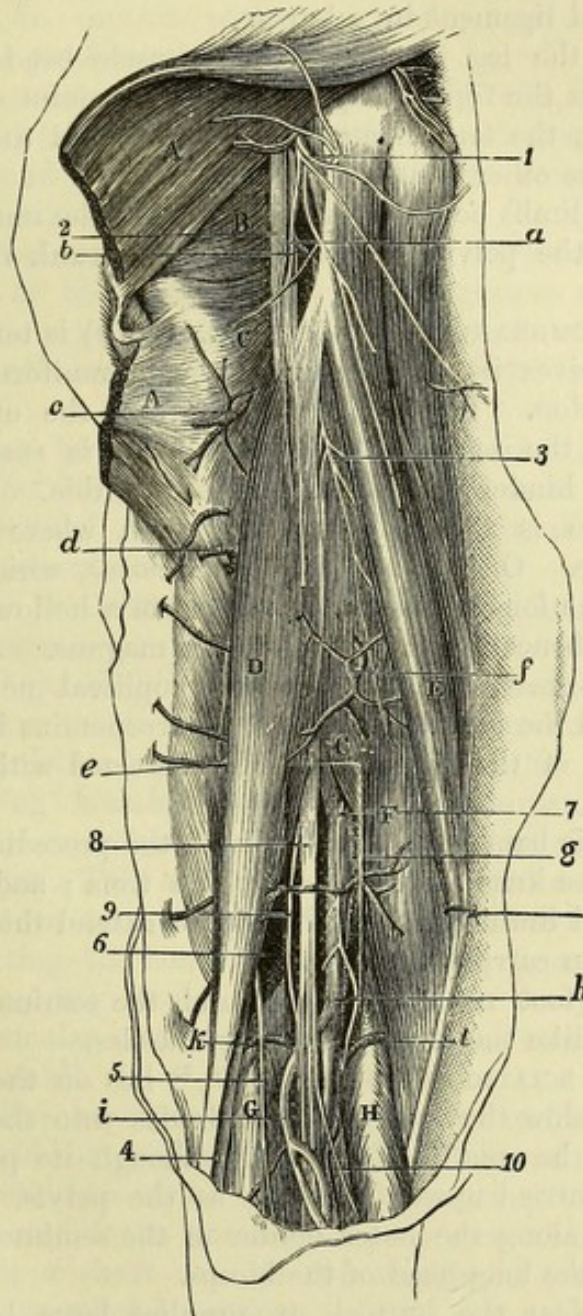
The leg being supported on the ground, the long head will assist in balancing and erecting the pelvis ; and the short head will draw down the femur so as to bend the knee in stooping.

The SEMITENDINOSUS (fig. 199, E) is a slender muscle and receives its name from its appearance. It *arises* from the tuberosity of the ischium with the long head of the biceps, and by fleshy fibres from the tendon of that muscle. Inferiorly it is *inserted* into the

inner surface of the tibia, close below the gracilis, and for a similar extent.

This muscle, like the biceps, is partly covered by the gluteus parts in contact maximus. About its middle an oblique tendinous intersection may with it;

Fig. 199.*



* Dissection of the back of the thigh (Illustrations of Dissections). *Muscles:* A. Gluteus maximus, cut below, and partly raised. B. Quadratus femoris. C. Adductor magnus. D. Biceps. E. Semitendinosus. F. Semimembranosus. G. Outer, and H, inner head of the gastrocnemius. *Vessels:* a. Sciatic artery. b. Ending of internal circumflex to hamstrings. c. First, d, second, and e, third perforating arteries. f. Muscular branch of profunda. g. Popliteal artery. h. Popliteal vein. i. Short saphenous vein. k. Upper external, and l. upper internal articular artery. *Nerves:* 1. Small sciatic, cut. 2. Large sciatic. 3. Branch to hamstrings from large sciatic. 4. External popliteal. 5. Communicating peroneal. 7. Articular branch of obturator to knee. 8. Internal popliteal. 9. Articular branch to knee of the internal popliteal. 10. Tibial communicating.

be observed. It rests on the semimembranosus, and on the internal lateral ligament of the knee-joint. The outer border is in contact with the biceps as far as the lower third of the thigh. As the tendon turns forwards to its insertion, an expansion is continued from it to the fascia of the leg; and it is attached, with the gracilis, on a level with the tubercle of the tibia, the two being separated from the internal lateral ligament by a bursa.

use on
knee
and hip-
joints,

Action. If the leg is movable, the muscle bends the knee and rotates inwards the tibia. Supposing the knee-joint straight but the hip-joint bent, the femur can be depressed, and the hip extended by this and the other hamstrings.

on the
pelvis.

Should the limbs be fixed on the ground, the muscle will assist in balancing the pelvis, or in erecting the trunk from a stooping posture.

Semimem-
branosus
reaches from
pelvis to
tibia;

The SEMIMEMBRANOSUS MUSCLE (fig. 199, F) is tendinous at both ends, and receives its name from the membraniform appearance of the upper tendon. The muscle *arises* from the upper and outer impression on the ischial tuberosity; and it is *inserted* below into the inner and hinder part of the head of the tibia.

parts
around it;

The muscle is thick and fleshy below, where it bounds the popliteal space. On it lies the semitendinosus, which is lodged, together with the long head of the biceps, in a hollow in the upper tendon; and beneath it is the adductor magnus. Along the outer border lie the great sciatic and internal popliteal nerves. Between its tendon and the inner head of the gastrocnemius is a large bursa. The insertion of the muscle will be dissected with the knee-joint (p. 693).

use on knee

Action. This hamstring is united with the preceding in its action, for it bends the knee and rotates in the tibia; and with the knee straight it will limit flexion of the hip, or extend this joint after the femur has been carried forwards.

and hip-
joints,

on pelvis.

When the foot rests on the ground, the semimembranosus acts on the pelvis like the other hamstring muscles.

Great sciatic
nerve in
the thigh

The GREAT SCIATIC NERVE (fig. 199, ²) lies on the adductor magnus muscle below the buttock, and divides into the two popliteal nerves about the middle of the thigh, though its point of bifurcation may be carried upwards as far as the pelvis. In this extent the nerve lies along the outer border of the semimembranosus, and is crossed by the long head of the biceps.

supplies
muscles.

Branches. Near the buttock it supplies large branches to the flexor muscles, and a small one to the adductor magnus.

Small
sciatic in
the thigh:

SMALL SCIATIC NERVE (fig. 199, ¹). Between the gluteus maximus and the ham this small nerve is close beneath the fascia; but it becomes cutaneous below the knee, and accompanies the external saphenous vein for a short distance.

cutaneous
offsets.

Small *cutaneous* filaments pierce the fascia; and the largest of these arises near the popliteal space.

Detach the
hamstrings.

Dissection. To see the posterior surface of the adductor magnus, and the branches of the perforating and anastomotic arteries, the hamstring muscles must be detached from the hip-bone and thrown

down ; and the branches of arteries and nerves they receive are to be dissected out with care. All the parts are to be cleaned.

ADDUCTOR MAGNUS MUSCLE (fig. 199, c). At its posterior aspect the large adductor is altogether fleshy, even at the opening for the femoral artery ; and the fibres from the pubic arch appear to form a part almost distinct from those connected with the tuberosity of the ischium. In contact with this surface are the hamstring muscles and the great sciatic nerve.

Posterior
surface of
adductor
magnus.

ENDING OF THE PERFORATING ARTERIES (fig. 199, c, d, e). These branches of the profunda appear through the adductor magnus close to the femur, and are directed out through the short head of the biceps and the outer intermuscular septum to the vastus externus and crureus muscles ; but as the first branch is placed higher than the attachment of the biceps, it pierces the gluteus maximus in its course. In the extensor muscles they anastomose together, and with the transverse and descending branches of the external circumflex artery.

Perforating
arteries :
course

and ending ;

Muscular branches are furnished by the perforating arteries to the heads of the biceps ; and a cutaneous offset is given by each to the integuments of the outer side of the thigh, along the line of the outer intermuscular septum.

offsets to
biceps and
the skin.

ANASTOMOTIC BRANCHES OF THE PROFUNDA (fig. 199, f) pierce the adductor magnus internal to the preceding, and at some distance from the femur (p. 628). Three or four in number, the highest appears about five inches from the pelvis, and the rest in a line at intervals of about two inches from one another : they are distributed to the hamstring muscles, especially the semimembranosus, and communicate below with offsets of the popliteal trunk.

Anastomotic
branches :
number and
course.

THE HIP-JOINT. This articulation is a ball and socket joint, the head of the femur being received into the acetabulum of the hip-bone. Connecting the bones are the following ligaments ;—one to deepen the receiving cavity, which is named cotyloid ; another between the articular surfaces of the bones—the interarticular ; and a capsule around all.

Hip-joint,
how formed ;
its liga-
ments.

Dissection. The muscles are to be taken away from the back of the hip-joint, and the areolar tissue is to be removed from the upper and lower attachments of the capsular ligament.

Lay bare
the capsule
behind,

Next, the front of the joint should be cleaned with the body turned over for a short time, if this change in position does not interfere with the other dissections.

and in front,

In the capsule itself the student has to define a wide thick part in front, and a transverse band near the neck of the femur behind.

define its
fibres.

The *capsular ligament* (fig. 200) is a thick fibrous case, which encloses the head and the greater part of the neck of the femur. Its upper margin is attached to the circumference of the acetabulum close to the edge, as well as to a transverse ligamentous band over the notch at the lower part of the cavity. Its lower margin is inserted in front into the anterior intertrochanteric line (fig. 200) ; behind, by a very thin piece, into the neck of the femur about a finger's breadth from the small trochanter and the posterior inter-

Capsule :

attach-
ments above
and below ;

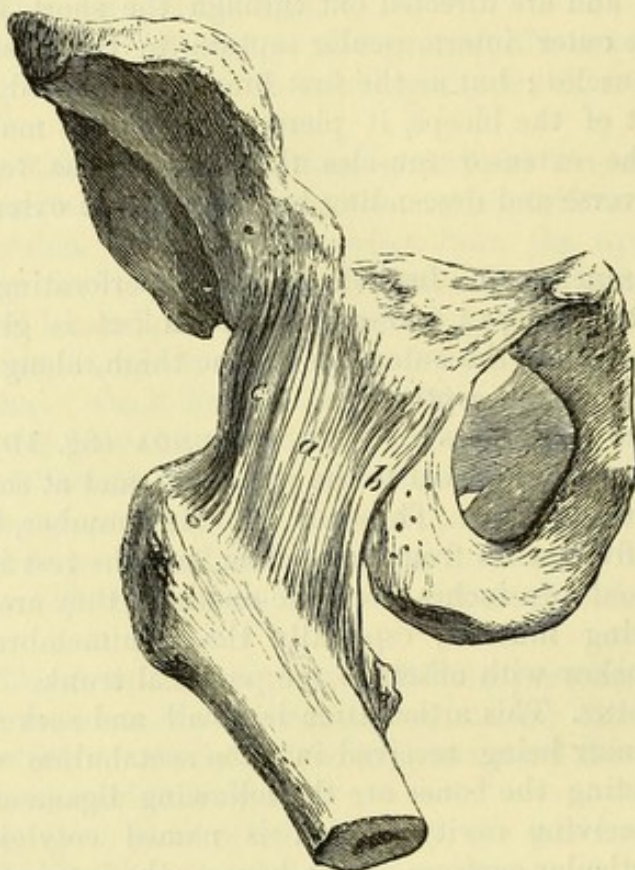
thickness
varies.

Ilio-femoral
ligament :
attach-
ments ;

trochanteric line (fig. 201) ; and above, into the neck near the great trochanter. The capsule differs much in strength, and in the arrangement of the fibres at the fore and hinder parts.

On the front it is strengthened by a broad and thick layer of longitudinal fibres—the *ilio-femoral ligament* (fig. 200, *a, c*). This is fixed above, where it is about an inch broad, to the lower part of the anterior inferior iliac spine and to a rough mark continued backwards therefrom on the outer surface of the ilium immediately

Fig. 200.*



division :

and use.

Pubo-
femoral
band.

Thin part of
capsule.

above the acetabulum. Becoming wider below, it is inserted into the whole length of the anterior intertrochanteric line ; and its fibres generally form two stronger bands, which are attached at the upper and lower ends respectively of the intertrochanteric line, with a thinner part in the middle : from this arrangement the name of the Y ligament has also been given to it. From its position, the ilio-femoral ligament will arrest extension of the joint ; and when the femur is fixed in standing it will support the pelvis.

At the inner and fore part of the joint is a much smaller band (fig. 200, *b*), which extends from the prominent portion of the pubis internal to the acetabulum to the lower end of the anterior intertrochanteric line, and is named the *pubo-femoral ligament*.

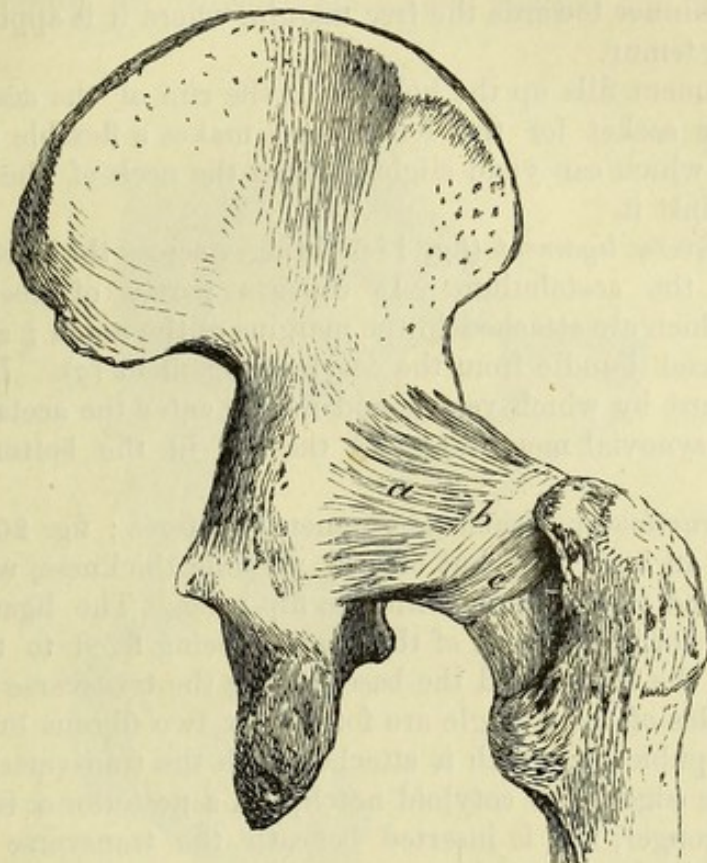
Between the ilio-femoral and pubo-femoral ligaments, near the hip-bone, the capsule is very thin, and sometimes presents an open-

* Fore part of the capsule of the hip-joint. *a, c*. Ilio-femoral ligament. *b*. Pubo-femoral band.

ing, through which the bursa under the ilio-psoas communicates with the joint-cavity.

At the back of the capsule is a band of transverse fibres (fig. 201, *b*), about half an inch wide, which arches like a collar Circular band at back of capsule :

Fig. 201.*



over the neck of the femur. By its lower edge it is united to the bone by a thin layer (*c*) of fibrous tissue and synovial membrane ; at the upper edge it is joined by the longitudinal capsular fibres (*a*). It gives insertion to the longitudinal fibres of the capsule, and prevents that restriction of the swinging movement which would result from their insertion into the hinder part of the neck. use.

Posteriorly the joint is covered by the obturator internus and gemelli muscles ; and anteriorly by the rectus femoris and ilio-psoas. Above is the gluteus minimus, the tendon of which is united to the capsule ; and below is the obturator externus. Muscles around.

Dissection (fig. 202). The capsular ligament is now to be divided over the prominence of the head of the femur, and this bone being disarticulated but not detached, the cotyloid and interarticular ligaments inside it will appear. Cut open the capsule.

The interarticular or round ligament is attached to the acetabulum by two pieces ; and to bring these into view, the synovial membrane and areolar tissue must be removed. The transverse ligament over the notch is also to be defined. Define round ligament.

* Hinder part of the capsule of the hip-joint. *a*. Longitudinal fibres. *b*. Transverse band. *c*. Thin piece attached to the neck of the femur about half way down.

Cotyloid
ligament

attached
round
acetabulum ;

use.

Transverse
ligament

forms a hole
with bone.

Round
ligament

shape and

attach-
ments ;

how to see
its action ;

loose in
extension ;

tight in
flexion with
adduction
and rotation
out.

Synovial
membrane.

Detach the
limb.

The *cotyloid ligament* (fig. 186, *g*) is a narrow band of fibro-cartilage, which is fixed to the margin of the acetabulum, and is prolonged across the notch below, so as to form part of the transverse ligament. Its fibres are not continued around the acetabulum, but are fixed to the margin of the cavity, and cross one another in the band. It is thickest at its attachment to the bone, and becomes gradually thinner towards the free margin, where it is applied to the head of the femur.

This ligament fills up the hollows in the rim of the acetabulum, deepens the socket for the femur, and makes a flexible margin to the cavity, which can yield slightly when the neck of the femur is pressed against it.

The *transverse ligament* (fig. 186) bridges across the notch in the margin of the acetabulum. It consists partly of deep special fibres (*h*) which are attached to the margins of the notch ; and partly of a superficial bundle from the cotyloid ligament (*g*). Beneath it is an aperture by which vessels and nerves enter the acetabulum to supply the synovial membrane and the fat in the bottom of that hollow.

The *interarticular ligament* (ligamentum teres ; fig. 202, *b*) is a band about an inch long, but of very variable thickness, which connects the head of the femur with the hip-bone. The ligament has a triangular form, the apex of the triangle being fixed to the pit on the head of the femur, and the base joining the transverse ligament. The free sides of the triangle are formed by two fibrous bundles, an anterior or pubic (*c*), which is attached with the transverse ligament to the pubic edge of the cotyloid notch, and a posterior or ischial (*d*), which is stronger, and is inserted beneath the transverse ligament into the ischial border of the notch.

To see the condition of the interarticular ligament in the different movements of the joint, it should be examined in a specimen in which the capsule is entire, and the floor of the acetabulum has been cut out with a chisel from inside the pelvis.

During extension of the joint the ligament is relaxed ; and it cannot be tightened so long as the fully extended position is maintained.

In flexion of the joint the ligament is rendered somewhat tighter ; but it is only fully stretched when, with the joint bent, the femur is adducted or rotated out : the pubic fasciculus of the band is especially tightened by the adduction, and the ischial slip by the outward rotation.

A *synovial membrane* lines the capsular ligament, and is continued along the neck of the femur to the margin of the articular surface. In the bottom of the cotyloid cavity it is reflected over the fat in that situation ; and it surrounds the ligamentum teres.

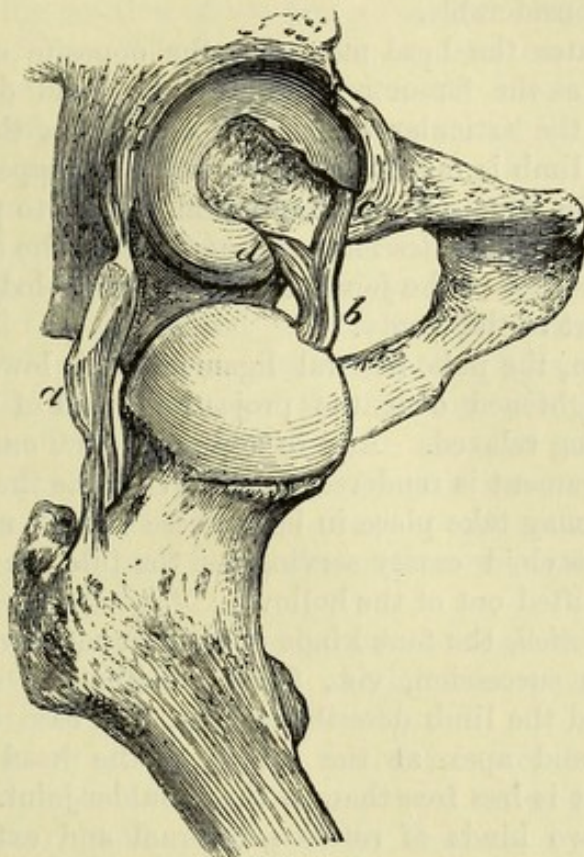
Dissection. To see the surface of the acetabulum, the lower limb is to be separated from the trunk by dividing the interarticular ligament, and by cutting through any parts that connect it to the pelvis : at this stage the pelvic attachments of the interarticular ligament can be better displayed.

Surfaces of bone. The articular surfaces of the bones are not completely covered with cartilage. Articular surface of

In the head of the femur is a pit into which the round ligament is inserted. femur.

The acetabulum is coated with cartilage at its circumference, except opposite the cotyloid notch, and touches the head of the Acetabulum, cartilaginous externally.

Fig. 202.*



femur by this part: this articular surface is deep above, but gradually decreases towards the edges of the notch.

In the hollow of the cartilage, and close to the notch, is a mass of fat (fig. 186, *f*) covering about one-third of the area of the cotyloid cavity, which constitutes the gland of Havers: it communicates with the fat of the thigh beneath the transverse ligament. Fat in the bottom.

Movements. In this ball and socket joint, there are the same kinds of movement as in the shoulder, viz., flexion and extension, abduction and adduction, circumduction, and rotation. Kinds of

Flexion and extension. In the swinging movement flexion is freer than extension, the thigh being capable of such elevation as to touch the belly. Swinging movement

While swinging, the head of the femur revolves in the bottom of the acetabulum, rotating around a horizontal axis; and the rapidity and extent of the movements do not endanger the security of the joint, the head of the bone not having any tendency to escape. motion of head of femur;

* Hip-joint opened, to show the interarticular ligament. *a.* Part of the capsule. *b.* Interarticular ligament: *c.* its pubic, and *d.* its ischial attachment.

checks to movement.

In extension the strong ilio-femoral ligament (the inner band especially) is tightened, and stops the movement. Flexion is not naturally arrested by the ligaments of the joint, but by the meeting of the soft parts of the thigh and abdomen.

Lateral movement :

In *abduction* and *adduction* the femur is removed from, or brought towards, the middle line of the body. Of the two, abduction is the more extensive, because the limb may soon meet its fellow when it is moved inwards, though, if it is carried in front of the other, adduction is considerable.

motion of the head ;

In both states the head moves in the opposite direction to the shaft. Thus, as the femur is abducted, the head descends, and a great part of the articular surface projects below the acetabulum ; and when the limb is raised to its utmost, the upper edge of the neck meets the edge of the acetabulum, so as to prevent farther motion. As the limb descends and approaches the other, the head rises into the socket of the joint, and is securely lodged, finally, in the deepest part of the cavity.

state of the ligaments.

In abduction, the pubo-femoral ligament and lower part of the capsule are tightened over the projecting head of the femur, the upper part being relaxed. And in adduction, the outer band of the ilio-femoral ligament is rendered tense and arrests the movement.

Dislocation in lateral movements.

Dislocation may take place in both these lateral movements, the edge of the cotyloid cavity serving as the fulcrum on which the femur can be lifted out of the hollow.

Circumduction.

In *circumduction*, the four kinds of angular motion above noticed take place in succession, viz., flexion, abduction, extension, and adduction ; and the limb describes a cone, the base of which is at its extremity, and apex at the centre of the head of the femur. This movement is less free than in the shoulder-joint.

Rotation :

There are two kinds of *rotation*, internal and external ; in the former, the great toe is turned in ; and in the latter it is moved outwards.

inwards,

In rotation inwards, the head of the femur rolls backwards horizontally across the acetabulum, the great trochanter being put forwards ; and the shaft of the bone revolves around a line internal to it, which passes from the centre of the head to the inner condyle. During this movement the posterior half of the capsule is put on the stretch, and the anterior is relaxed.

and outwards.

In rotation out, the head of the bone rolls forwards across the cotyloid cavity, and the great trochanter is brought backwards. The outer band of the ilio-femoral ligament is tightened and checks the movement.

Examine attachment of muscles.

Dissection. After the limb is removed, the attachments of all the muscles in the thigh are to be examined more minutely before the dissection of the leg is undertaken. The muscles should not be removed from the femur, but about two inches of each should be left for after study.

SECTION IV.

THE BACK OF THE LEG.

Directions. Before the dissection of the leg is begun, the student should make himself acquainted, as in the thigh, with the prominences of bone and muscle on the surface, and with the markings which indicate the position of the larger vessels. Surface-marking.

Prominences of bone. The bones of the leg can be traced beneath the skin from the knee to the ankle-joint. At the inner and fore part is the tibia, which is subcutaneous in all its extent, and is limited in front and behind by a sharp edge. Above, it presents in front a prominent tubercle into which the ligament of the patella is inserted; and on each side of this the tuberosities of the bone are superficial. The internal tuberosity is a uniform rounded prominence; but the external forms a marked projection at the outer and fore part of the knee. Below, the tibia ends on the inner side of the ankle in the internal malleolar projection. On the outer side of the leg the lower half of the fibula may be felt with ease, but the upper half with more difficulty in consequence of the prominence of the muscles of the calf. The head of this bone may be recognized below the knee; and the lower end forms the eminence (malleolus) on the outer side of the ankle-joint. In the leg the tibia is superficial, and the fibula in part.

At the sides of the ankle are the prominent malleoli, the external being nearer to the heel; and when the joint is extended, the head of the astragalus can be felt below the tibia. Ankle-joint.

Muscles and vessels of the leg. On the back of the leg is the swell of the calf: this is formed by the superficial muscles, and from it descends the firm band of the tendo Achillis, by which those muscles are connected with the heel. Between the tendon and the edge of the tibia, but nearer the former, is placed the superficial part of the posterior tibial artery. In front, between the tibia and fibula are the flexor muscles of the ankle and the extensors of the toes, amongst which the anterior tibial artery lies deeply; the position of the vessel will be indicated by a line from a point midway between the head of the fibula and the projection of the external tuberosity of the tibia to the centre of the ankle-joint. Behind are calf of the leg, tendo Achillis, and tibial vessels. Line of anterior tibial vessels.

Prominences of the foot. At the inner border of the foot, about an inch and a half in front of the internal malleolus, is the tuberosity of the navicular bone pointing out the spot at which an amputation (Chopart's) is practised; while one inch and a half farther forwards is a slight depression marking the articulation between the internal cuneiform and the metatarsal bone of the great toe. About the centre of the outer border of the foot is the tuberosity of the fifth metatarsal bone. A line over the dorsum of the foot, from the centre of the ankle-joint to the interval between the inner two toes, will lie over the position of the main artery. Inner border of the foot. Outer border. Dorsal artery.

Position. For the dissection of the back of the leg, the limb is to be placed on its front, with the foot over the side of the dissecting- Position of the part.

table ; and the muscles of the calf are to be put on the stretch by fastening the foot.

Take away
the skin,

Dissection. For the removal of the skin, one cut may be made along the middle of the leg to the sole of the foot, where a transverse incision is to be carried over the heel. The two resulting flaps of skin may be raised,—the outer one as far as the fibula, and the other as far as the inner margin of the tibia.

seek cu-
taneous
nerves in
the fat.

In the fat the cutaneous nerves and vessels are to be followed. On the inner side, close to the tibia, is the internal saphenous vein with the nerve of the same name, together with twigs of the internal cutaneous near the knee. In the centre of the leg lies the external saphenous vein, with the small sciatic nerve as its companion above, and the external saphenous nerve below the middle of the leg. On the outer side cutaneous offsets of the external popliteal nerve will be met with.

Superficial
fascia.

The *superficial fascia*, or the fatty layer of the back of the leg, is least thick over the tibia. Along the line of the superficial vessels it may be separated into two layers.

Two super-
ficial veins.

SUPERFICIAL VEINS. Two veins appear in the dissection of the back of the leg, which are named saphenous—inner and outer.

Internal
saphenous.

The **INTERNAL SAPHENOUS VEIN** (fig. 204, *d*) begins in an arch on the dorsum of the foot (p. 682). Ascending along the leg in front of the inner ankle, and then behind the inner edge of the tibia, it reaches the thigh (p. 602). In the leg the vein is joined by superficial branches, and by deep roots from the tibial veins.

External
saphenous.

The **EXTERNAL SAPHENOUS VEIN** (fig. 203, *c*) begins at the outer end of the arch on the dorsum of the foot, and appears below the outer ankle. The vein then courses along the back of the leg to the ham, where it ends in the popliteal vein. It receives large branches about the heel, and others on the back of the leg, communicating with the internal saphenous.

Cutaneous
arteries.

Cutaneous arteries accompany the superficial veins and nerves of the leg.

Cutaneous
nerves.

CUTANEOUS NERVES (fig. 203). The nerves in the fat of the back of the leg are prolongations of branches already met with, viz., the internal and external saphenous, external popliteal, small sciatic, and internal cutaneous of the thigh.

Internal
saphenous :

The **INTERNAL SAPHENOUS NERVE** (fig. 203, *f*) accompanies the vein of the same name beyond the knee (p. 623), and terminates at the middle of the inner border of the foot. In the leg the nerve gives off lateral cutaneous offsets, the largest of which turn over the tibia to the anterior aspect.

External
saphenous :
origin ;

The **EXTERNAL OR SHORT SAPHENOUS NERVE** (fig. 203, *e*) is formed by the union of the tibial and peroneal communicating branches (p. 649), usually about the middle of the leg. It runs with the external saphenous vein below the outer ankle, and ends by supplying the outer side of the foot and little toe. It furnishes twigs to the skin of the lower part of the back of the leg, and large branches over the heel.

ending ;

branches.

Branches of

CUTANEOUS NERVES OF THE EXTERNAL POPLITEAL. In

addition to the peroneal communicating (fig. 203, *), the external popliteal nerve gives off one or two cutaneous offsets (p. 649) to the outer side and fore part of the leg.

Fig. 203.*

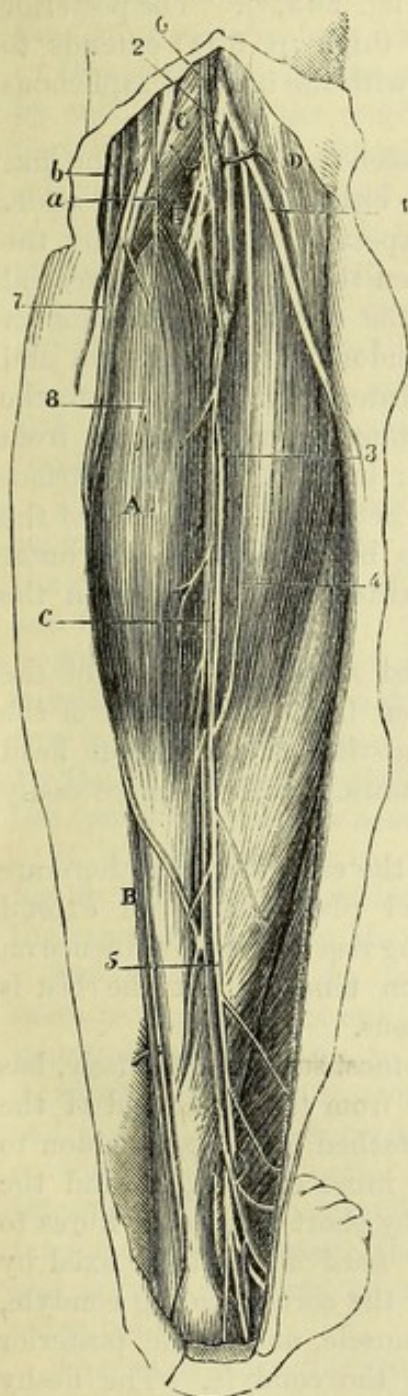
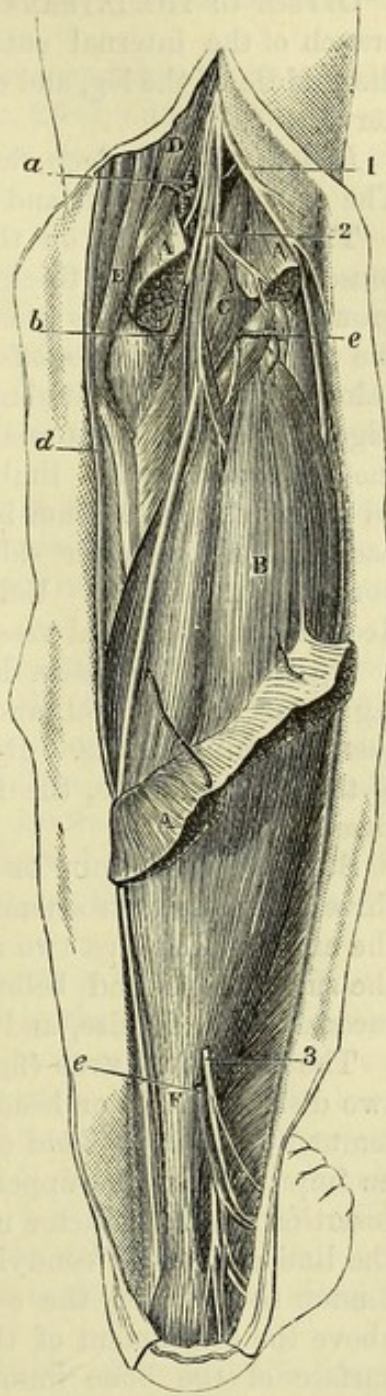


Fig. 204.†



* First view of the back of the leg (Illustrations of Dissections). *Muscles* : A. Gastrocnemius. B. Soleus. C. Semimembranosus. D. Biceps. *Vessels* : a. Popliteal artery. b. Internal saphenous vein. c. External saphenous vein. *Nerves* : 1. External popliteal. 2. Internal popliteal. 3. Tibial communicating. 4. Peroneal communicating. 5. Short saphenous. 6. Small sciatic. 7. Internal saphenous. 8. Internal cutaneous.

† Second view of the back of the leg (Illustrations of Dissections). *Muscles* : A. Gastrocnemius, cut. B. Soleus. C. Plantaris. D. Semimembranosus. E. Semitendinosus. F. Tendo Achillis. *Vessels* : a. Popliteal artery. b. Internal lower articular. c. External lower articular. d. Internal saphenous vein. e. External saphenous vein. *Nerves* : 1. External popliteal. 2. Internal popliteal. 3. Short saphenous, cut.

- Termination of small sciatic.** The SMALL SCIATIC NERVE (fig. 203, ⁶) perforates the fascia at the lower end of the popliteal space, and reaches to about the middle of the leg with the external saphenous vein: it ramifies in the integuments, and joins the external saphenous nerve.
- Termination of internal cutaneous.** OFFSET OF THE INTERNAL CUTANEOUS (fig. 203, ⁵). The posterior branch of the internal cutaneous of the thigh (p. 604) extends to the middle of the leg, and communicates with the internal saphenous nerve.
- Take away the fat.** *Dissection.* The deep fascia will be seen by removing the fat. The superficial vessels and nerves may be either cut or turned aside.
- Deep fascia : continuity and attachments.** The DEEP FASCIA on the posterior aspect of the leg covers the muscles, and sends a thick process between the deep and superficial groups. Above, it is continuous with the investing membrane of the thigh, and receives offsets from the tendons about the knee; and below, it joins the annular ligaments. Internally, it is fixed to the edge of the tibia: externally, it is continued uninterruptedly from the one aspect of the limb to the other; but from its deep surface an intermuscular septum is sent inwards between the muscles of the back and of the outer side of the leg to be attached to the outer border of the fibula. Veins are transmitted through it from the deep to the superficial vessels.
- Take away the fascia.** *Dissection.* The fascia is to be divided along the centre of the leg as far as the heel, and is to be taken from the surface of the gastrocnemius muscle. By fixing with a stitch the inner cut head of the gastrocnemius, the fibres of the muscle will be more easily cleaned.
- Muscles in superficial group.** SUPERFICIAL GROUP OF MUSCLES. In the calf of the leg there are three muscles, gastrocnemius, soleus, and plantaris, which extend the ankle. The first two are large, giving rise to the prominence on the surface, and end below by a common tendon; but the last is inconsiderable in size, and chiefly tendinous.
- Gastrocnemius** The GASTROCNEMIUS (fig. 203, A), the most superficial muscle, has two distinct pieces or heads, which *arise* from the lower end of the femur. The *inner head* of origin is attached by a large tendon to an impression at the upper aspect of the inner condyle, behind the insertion of the adductor magnus; and by short tendinous fibres to the line above the condyle. The *outer head* is similarly fixed by tendon to a pit on the outer surface of the corresponding condyle, above the attachment of the popliteus muscle, and to the posterior surface of the bone immediately above the condyle. The fleshy fibres of the two heads are united along the middle line by a narrow thin aponeurosis, and terminate below with the soleus in the common tendon of insertion.
- arises by two heads from the femur,**
- ends below in tendo Achillis;**
- relations;** One surface is covered by the fascia. The other is in contact with the soleus and plantaris, and with the popliteal vessels and the internal popliteal nerve. The heads, by which the muscle arises, assist to form the lateral boundaries of the popliteal space, and are crossed by the tendons of the hamstrings. The inner head is larger, and descends lower than the outer. In the outer head a piece of fibro-cartilage or a sesamoid bone may exist.

Action. When the foot is unsupported, the gastrocnemius extends the ankle; and when the toes rest on the ground, it raises the os calcis and the weight of the body, as in standing on the toes, and in progression.

use with the
foot free,
and fixed;

Taking its fixed point at the os calcis, the muscle draws down the femur so as to bend the knee-joint.

acting from
below.

Dissection. To see the soleus, the gastrocnemius is to be reflected by cutting across the remaining head (fig. 204), and the vessels and nerves it receives. After the muscle has been thrown down, the soleus and plantaris must be cleaned.

Detach
gastrocne-
mius.

The SOLEUS (fig. 204, B) is a large flat muscle, which is attached to both bones of the leg. It *arises* from the head, and the upper third of the posterior surface of the shaft of the fibula; from the oblique line across the tibia, and from the inner edge of this bone as low as the middle; and between the bones from an aponeurotic arch over the large blood-vessels. Its fibres are directed downwards to the common tendon.

Soleus is
attached to
the bones
of the leg,
and joins
the tendon
below;

The superficial surface of the soleus is in contact with the gastrocnemius; and where the two touch they are aponeurotic. Beneath the soleus lie the bones of the leg, the deep muscles, and the vessels and nerves.

parts over
and under
it;

Action. In its action on the foot the soleus, like the gastrocnemius, extends the ankle and points the toes when the foot is free to move; and raises the heel if the toes rest on the ground. By the sudden and powerful contraction of the fibres of both muscles the common tendon is sometimes broken across.

use,
the foot
free,
and fixed;

If it acts from the os calcis, it will draw back the bones of the leg into a vertical position over the foot, as the body is raised to the erect posture after stooping.

acting from
below.

TENDO ACHILLIS (fig. 204, F). The *common tendon* of the gastrocnemius and soleus is one of the strongest in the body. About three inches wide above, it commences at the middle of the leg, though it receives fleshy fibres on the under surface nearly to the lower end: below, it is narrowed, and is *inserted* into the middle impression on the posterior aspect of the tuberosity of the os calcis. A bursa intervenes between it and the upper part of the tuberosity. The tendon is close beneath the fascia; and the external saphenous vein and nerve are superficial to it at first, but afterwards lie along its outer border.

Tendo
Achillis:
extent,
and inser-
tion.

The PLANTARIS (fig. 204, c) is remarkable in having the longest tendon in the body, which takes the appearance of a riband when it is stretched laterally. About three-quarters of an inch wide, the muscle *arises* from the line above the outer condyle of the femur, and from the posterior ligament of the knee-joint; and the tendon is *inserted* into the os calcis with, or by the side of, the tendo Achillis, or into the fascia of the leg.

Plantaris:
origin;
insertion;

The belly of the muscle, about three inches in length, is concealed by the gastrocnemius, but the tendon appears on the inner side of the tendo Achillis about the middle of the leg. This little muscle crosses the popliteal vessels, and lies on the soleus.

position of
the muscle;

use like
gastrocne-
mius.

Action. It assists slightly the gastrocnemius in extending the ankle if the foot is not fixed ; and in bending the knee-joint if the foot is immoveable.

Detach
soleus,

Dissection (fig. 205). The soleus is to be detached from the bones of the leg, and the muscles and nerves entering it are to be divided ; but in raising it, the student should take care not to injure the thin deep fascia and the vessels and nerves beneath. The superficial muscles may be next removed by cutting through their tendons near the os calcis ; and the bursa between the tendo Achillis and the os calcis should be opened.

and clean
the deep
fascia.

The piece of fascia between the muscles of the superficial and deep groups is then to be cleaned ; and the integuments between the inner ankle and the heel are to be taken away to lay bare the annular ligament, but a cutaneous nerve to the sole of the foot, which pierces the ligament, is to be preserved.

Deep part of
the fascia of
the leg.

Deep part of the fascia. This intermuscular piece of the fascia of the leg is fixed to the tibia and fibula, and binds down the flexor muscles of the deep group. In the upper part of the leg it is thin and indistinct ; but lower in the limb it is much stronger, and is marked by some transverse fibres near the malleoli, which give it the appearance and office of an annular ligament in that situation. Inferiorly it joins the internal annular ligament between the heel and the inner ankle.

Clean the
deep
muscles :

Dissection. The deep layer of muscles, the posterior tibial nerve, and the trunk and offsets of the posterior tibial vessels will be laid bare by the removal of the fascia and the areolar tissue. A muscle between the bones (tibialis posticus) is partly concealed by an aponeurosis which gives origin to the two lateral muscles (flexor digitorum and flexor hallucis) ; and it will not fully appear until after the membrane covering it has been divided longitudinally, and reflected to the sides.

dissect
peroneal
artery.

To prepare the peroneal artery, evert and partly divide the flexor hallucis, by which it is concealed ; then define branches from its lower part to the front of the leg, the outer side of the foot, and to join the posterior tibial artery.

Four mus-
cles in the
deep group ;

DEEP GROUP OF MUSCLES (fig. 205). The deep muscles at the back of the leg are four in number, viz., popliteus, flexor longus hallucis, flexor longus digitorum, and tibialis posticus. The first of these is close to the knee-joint ; it crosses the bones, and is covered by a special aponeurosis. The flexors lie on the bones, the one of the great toe resting on the fibula, and that of the other toes on the tibia. And the tibialis covers the interosseous membrane. With the exception of the popliteus, all enter the sole of the foot ; and they have a fleshy part parallel to the bones of the leg, and a tendinous part beneath the tarsus.

position and
destination.

Popliteus
arises
within
knee-joint ;

The **POPLITEUS** (fig. 205, A) arises by tendon, within the capsule of the knee-joint, from the front of an oblong depression on the outer surface of the external condyle of the femur ; and external to the capsule of the joint, some fleshy fibres arise from the posterior ligament. The muscular fibres spread out, and are inserted into the

inserted

tibia above the oblique line on the posterior surface, as well as into into tibia; the aponeurosis covering them.

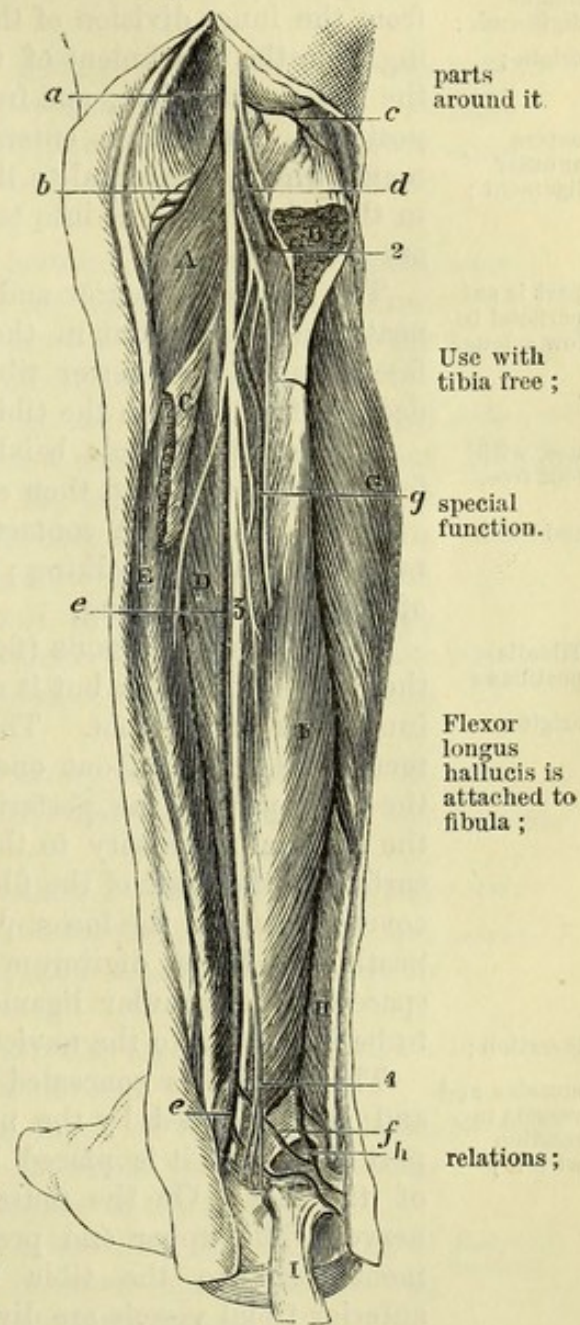
The muscle rests on the tibia, and is covered by a fascia derived in great part from the tendon of the semimembranosus muscle: on it lie the popliteal vessels and nerve, and the gastrocnemius and plantaris. Along the upper border are the lower articular vessels and nerve of the inner side of the knee; and the lower border corresponds with the attachment of the soleus on the tibia. The tendon of origin will be seen in the dissection of the ligaments of the knee-joint.

Action. The leg being free, the muscle bends the knee-joint, and then rotates inwards the tibia. The popliteus is used especially in beginning the act of flexing the knee, as it produces the rotation inwards of the tibia (or outwards of the femur) without which that movement cannot take place.

The FLEXOR LONGUS HALLUCIS (flex. long. pollicis pedis; fig. 205, F) arises below the soleus from the lower two-thirds of the posterior surface of the fibula; from the intermuscular septum between it and the peronei muscles; and from the aponeurosis over the tibialis. Inferiorly the tendon of the muscle enters a groove in the astragalus, and crosses the sole of the foot to its insertion into the great toe.

Above, the muscle is covered by the soleus; but below, it is superficial, and is in contact with the fascia. It lies on the fibula and lower end of the tibia, and conceals the peroneal vessels. Along the inner side are the posterior tibial nerve and vessels; and contiguous to the outer margin, but separated by fascia, are the peronei muscles.

Fig. 205.*



* Deep dissection of the back of the leg (Illustrations of Dissections). *Muscles:* A. Popliteus. B. Outer, and c, inner part of soleus, cut. D. Tibialis posticus. E. Flexor digitorum. F. Flexor hallucis. G. Peroneus longus. H. Peroneus brevis. I. Tendo Achillis. *Arteries:* a. Popliteal. b. Inferior internal, and c, inferior external articular. d. Anterior tibial. e. Posterior tibial, and f, a communicating branch to peroneal. g. Peroneal. h. Continuation of peroneal to outer side of the foot. *Nerves:* 1. Internal popliteal. 2. Muscular branch of posterior tibial. 3. Posterior tibial. 4. Cutaneous plantar.

use, the
foot being
free,
and fixed.

Action. The foot being unsupported, the flexor bends the last phalanx of the great toe, and then extends the ankle.

The foot resting on the ground, the muscle raises the heel ; and it moves back the fibula as the body rises from stooping.

Flexor
longus
digitorum :
origin ;

The FLEXOR LONGUS DIGITORUM (flex. perforans ; fig. 205, E) *arises* from the inner division of the posterior surface of the tibia, extending from the attachment of the soleus to about three inches from the lower extremity ; and from the aponeurosis covering the tibialis posticus. Its tendon enters a compartment in the annular ligament, which is external to the sheath of the tibialis ; and it divides in the sole of the feet into tendons for the last phalanges of the four outer toes.

part is su-
perficial be-
low soleus ;

The muscle is narrow and pointed above, where it is placed beneath the soleus ; but in the lower half it is in contact with the fascia, and the posterior tibial vessels and nerve lie on it. The deep surface rests on the tibia and the tibialis posticus.

use, with
foot free,

Action. The muscle bends the farthest phalangeal joints of the four smaller toes, and then extends the ankle.

and fixed.

If the toes are in contact with the ground, the flexor helps to raise the heel in walking ; and to move back the tibia in the act of rising from stooping.

Tibialis
posticus :
origin ;

The TIBIALIS POSTICUS (fig. 205, D) occupies the interval between the bones of the leg, but it crosses over the tibia below to reach the inner side of the foot. The muscle *arises* from the interosseous membrane, except about one inch below, from an impression along the outer part of the posterior surface of the tibia extending from the external tuberosity to the middle of the bone, from the inner surface of the shaft of the fibula, and slightly from the aponeurosis covering it. In the lower part of the leg the muscle is directed beneath the flexor digitorum ; and its tendon, entering the inner space in the annular ligament, reaches the inner side of the foot to be inserted into the navicular and other bones (p. 681).

insertion ;

muscles and
vessels in
relation
with it ;

The tibialis is concealed by the aponeurosis before mentioned, and is overlapped by the neighbouring muscles ; but in the lower part of the leg it is placed between the tibia and the long flexor of the toes. On the muscle are the posterior tibial vessels and nerve. The upper end presents two pointed processes of attachment—that to the tibia being the higher—between which the anterior tibial vessels are directed forwards.

use, with
foot free,

Action. Its action on the moveable foot is to depress the fore part and outer side, and carry the toes inwards, producing the movement in the tarsal joints known as inversion (p. 704), and to extend the ankle-joint. The toes resting on the ground, it will aid the muscles of the calf in raising the heel in the progression of the body.

and fixed ;

in standing,

In standing, the muscle can raise the inner border of the foot with the tibialis anticus, so as to throw the weight of the body on the outer edge.

in rising up.

As the body rises from stooping, the tibialis draws back the bones of the leg, with the soleus.

The *aponeurosis covering the tibialis* is attached externally to the inner border of the fibula ; but internally it joins the flexor longus digitorum without being attached to bone : it may be regarded as constituting a fibular origin of that muscle. Fibres of the flexor longus hallucis arise from one surface of the membrane, and of the tibialis posticus from the other.

The POSTERIOR TIBIAL ARTERY (fig. 205, *e*) is one of the vessels resulting from the bifurcation of the popliteal trunk (p. 646). It extends from the lower border of the popliteus muscle to the lower edge of the internal annular ligament, where it ends in two plantar branches for the sole of the foot.

At its origin the artery lies midway between the tibia and fibula, but as it approaches the lower part of the leg it gradually inclines inwards ; and at its termination it is placed below the tibia, in the centre of the hollow between the heel and the inner ankle.

For the upper two-thirds of the leg the vessel is concealed by two muscles of the calf, viz., gastrocnemius and soleus ; but in the lower third, as it lies between the tendo Achillis and the inner edge of the tibia, it is covered only by the integuments and the deep fascia. At its termination it is placed beneath the annular ligament. For its upper half the trunk lies over the tibialis posticus, but afterwards on the flexor digitorum, and on the lower end of the tibia and the ankle-joint. On the outer side is the flexor hallucis.

Between the heel and the ankle, the artery is placed between the tendons of the common flexor of the digits and special flexor of the great toe.

Venæ comites closely surround the vessel. The posterior tibial nerve is at first internal to the artery ; but at the distance of about an inch it crosses to the outer side, and retains that position throughout.

This artery supplies *branches* to the muscles and the tibia, and a large peroneal trunk to the outer side of the leg.

a. Muscular branches enter the deep layer of muscles, and the soleus ; and an offset from the branch to the soleus pierces the attachment of that muscle to the tibia, and ascends to the knee-joint.

b. The medullary artery of the tibia arises near the beginning of the trunk : penetrating the tibialis, it enters the canal on the posterior surface of the bone, and ramifies in the interior.

c. Cutaneous offsets appear through the fascia in the lower half of the leg.

d. One or two small internal malleolar branches ramify over the inner malleolus.

e. A communicating branch arises opposite the lower end of the tibia, and passes outwards beneath the flexor longus hallucis, to unite in an arch with a corresponding offset of the peroneal artery. Sometimes there is a second loop between these vessels superficial to the flexor hallucis (fig. 205, *f*).

Peculiarities. If the *posterior tibial artery* is smaller than usual, or

Aponeurosis
over the
muscle.

Posterior
tibial
artery :
extent ;

course ;

parts cover-
ing it above
and below ;

parts be-
neath it ;

under
annular
ligament ;

veins ;
nerve ;

branches :—

Muscular.

Medullary
to tibia.

Cutaneous.

Internal
malleolar.

Communi-
cating.

Size of

tibial may vary. absent, its deficiencies in the foot will be supplied by a large communicating branch from the peroneal artery, which is directed inwards at the lower end of the tibia, and either joins the small tibial vessel, or runs alone to the sole of the foot.

Peroneal artery. The PERONEAL ARTERY (fig. 205, *g*) is often as large as the posterior tibial, and arises from that vessel about one inch from the beginning. It takes the fibula as its guide, and lying close to that bone in a fibrous canal between the origins of the flexor longus hallucis and tibialis posticus, reaches the lower part of the interosseous membrane. At this spot it sends forwards a branch to the front of the leg (anterior peroneal); and it is directed onwards over the articulation between the tibia and fibula to the outer side of the heel (*h*), where it terminates in branches, which anastomose with offsets of the tarsal and external plantar arteries.

veins and nerve; Two companion veins surround the artery; and the nerve to the flexor hallucis lies on it generally.

branches:— *Branches.* Besides the anterior peroneal, it furnishes muscular, medullary and communicating offsets.

Muscular. *a. Muscular branches* are distributed to the soleus, tibialis posticus, and flexor hallucis; and some turn round the fibula to the long and short peroneal muscles, lying in grooves in the bone.

Medullary to fibula. *b. The medullary artery* is smaller than that to the tibia, and is transmitted through the tibialis posticus to the aperture about the middle of the fibula.

Anterior peroneal to front of foot. *c. The anterior peroneal branch* passes forwards through an opening below the interosseous membrane, and is continued to the dorsum and outer part of the foot; on the front of the leg and foot it anastomoses with the external malleolar and tarsal branches of the anterior tibial artery.

Communicating. *d. A communicating offset* near the ankle joins in an arch with a similar branch of the posterior tibial.

Peculiarities. The anterior branch of the peroneal may take the place of the anterior tibial artery on the dorsum of the foot.

Substitutions. A compensating principle may be observed amongst the arteries of the foot, as in those of the hand, by which the deficiency in one is supplied by an enlarged offset of another.

Posterior tibial veins. The POSTERIOR TIBIAL VEINS begin at the inner side of the foot by the union of the plantar: they ascend, one on each side of the artery, and unite with the anterior tibial at the lower border of the popliteus to form the large popliteal vein. They receive the peroneal veins, and branches corresponding with the offsets of the artery: branches connect them with the saphenous veins.

Posterior tibial nerve: extent; The POSTERIOR TIBIAL NERVE (fig. 205, *f*), a continuation of the internal popliteal (p. 649), reaches like the artery from the lower border of the popliteus muscle to the interval between the os calcis and the inner malleolus. While beneath the annular ligament, or somewhat higher than it, the nerve divides into the internal and external plantar branches of the foot.

and relations; Its relations to surrounding muscles are the same as those of the

artery; but its position to the vessel changes, for it lies on the inner side above the origin of the peroneal offset, but thence to the termination, on the outer side. Its branches are muscular and cutaneous.

Muscular branches are furnished to the two long flexors, the tibialis posticus, and the soleus. There is an offset for each of the muscles; and they may arise either separately along the trunk, or together from the upper end of the nerve. The branch to the tibialis is the largest; and that to the flexor hallucis lies on the peroneal artery.

A cutaneous nerve of the sole of the foot (calcaneo-plantar; fig. 205,⁴) begins above the ankle, and piercing the internal annular ligament as two or more pieces, ends in the integuments of the inner and under parts of the heel: this nerve will be followed to its termination in the dissection of the foot (fig. 206).

The INTERNAL ANNULAR LIGAMENT stretches between the heel and the inner ankle, and serves to confine the tendons of the deep layer of muscles of the foot and toes. Attached by a narrow part to the internal malleolus, the fibres diverge, and are inserted into the os calcis. One border (upper) is continuous with the fascia of the leg; and the opposite gives attachment to the abductor hallucis muscle of the foot.

Beneath it are sheaths for the tendons. The innermost encloses the tibialis posticus, lodged in a groove on the back of the malleolus. Immediately outside this is another space for the flexor digitorum. And about three-quarters of an inch nearer the os calcis is the flexor hallucis, resting in a groove in the astragalus. Each sheath is lined by a synovial membrane.

Between the tendons of the two flexors of the digits are placed the tibial vessels and nerve.

SECTION V.

SOLE OF THE FOOT.

Position. The foot is to be placed over a block of moderate thickness with the sole towards the dissector; and the part is to be made tense by fixing the heel with hooks, and by separating and fastening apart the toes.

Dissection. The skin is to be raised in two flaps, inner and outer, by means of one incision along the centre of the sole from the heel to the front; and by another across the foot at the root of the toes. Afterwards the skin is to be removed from each toe, and the digital vessels and nerves on the sides are to be dissected out at the same time.

In the fat near the heel the student should follow the cutaneous nerve of the sole (fig. 206); and he may trace out, at a little dis-

tance from each border of the foot, some small branches of the plantar nerves and arteries.

Subcutaneous fat.

The *subcutaneous fat* is very abundant, and forms a thick cushion over the parts that press most on the ground in standing, viz., over the os calcis, and the metatarso-phalangeal articulations.

Lay bare the plantar fascia,

Dissection. The fat should now be removed, and the plantar fascia laid bare. Beginning the dissection near the heel, follow forwards the fascia towards the toes, to each of which a process is to be traced. In the intervals between the processes the digital nerves and arteries will be detected amongst much fatty and fibrous tissues; but the vessels and nerves to the inner side of the great toe and outer side of the little toe pierce the fascia farther back than the rest.

define the ligament of the toes.

The student is next to define a transverse fibrous band across the toes, over the digital vessels and nerves; and when this has been displayed, he may remove the superficial fascia from the toes to see the sheaths of the tendons.

Plantar fascia:

PLANTAR FASCIA. The special fascia of the sole of the foot is of a pearly white colour and great strength, and sends septa between the muscles. Its thickness varies in different parts of the foot; and from this circumstance, and the existence of longitudinal depressions over the two chief intermuscular septa, the fascia is divided into a central and two lateral pieces.

division into parts.

Central part

The *central part*, which is much the thickest, is pointed at its attachment to the os calcis, but widens and becomes thinner as it extends forwards. A slight depression, corresponding with an intermuscular septum, marks its limit on each side; and opposite the heads of the metatarsal bones it divides into five processes, which send fibres to the integuments near the web of the foot, and are continued onwards to the toes, one to each. Where the pieces separate from each other, the digital vessels and nerves, and the lumbricales muscles become superficial, and are arched over by transverse fibres.

divides into five pieces:

termination of the pieces.

If one of the digital processes be divided longitudinally, and its parts reflected to the sides, it will be seen to join the sheath of the flexor tendons, and to be fixed laterally into the margins of the metatarsal bone, and into the transverse metatarsal ligament.

Inner piece of the fascia.

The *lateral pieces* of the fascia are thinner than the central one. On the inner margin of the foot the fascia has but little strength, and is continued to the dorsum; but on the outer side it presents a strong band between the os calcis and the projection of the fifth metatarsal bone.

Outer piece.

Expose the septa.

Dissection. To examine the septa, a longitudinal incision may be made along the middle of the foot through the central piece of the fascia, and a transverse one near the calcaneum. On detaching the fascia from the subjacent flexor brevis digitorum, by carrying the scalpel from before backwards, the septal processes will appear on the sides of that muscle.

Two intermuscular septa.

The *intermuscular septa* pass deeply on the sides of the flexor brevis digitorum, and a piece of fascia reaches across the foot from

one septum to the other, beneath that flexor, so as to isolate it. The *inner* septum separates the short flexor from the abductor hallucis ; and the *outer*, from the abductor minimi digiti.

The *superficial transverse ligament* crosses the roots of the toes, and is contained in the skin forming the rudimentary web of the foot. It is attached at the ends to the sheath of the flexor tendons of the great and little toes, and is connected with the sheaths of the others as it lies over them. Beneath it the digital nerves and vessels issue. Transverse ligament of the toes.

The *sheaths of the flexor tendons* (fig. 207, G) are similar to those of the fingers, though not so distinct, and serve to confine the tendons against the grooved bones. The sheath is weak opposite the articulations between the phalanges, but is strong opposite the centre of both the metatarsal and the next phalanx. Each is lubricated by a synovial membrane, and contains the tendons of the long and short flexor muscles. Sheaths of flexor tendons.

Dissection (fig. 206). In the sole of the foot the muscles are numerous, and have been arranged in four layers. To prepare the first layer all the fascia must be taken away ; but this dissection must be made with some care, lest the digital nerves and vessels, which become superficial to the central muscle towards the toes, should be injured. Dissect first layer of muscles.

The tendons of the short flexor muscle are to be followed to the toes, and one or more of the sheaths in which they are contained should be opened.

FIRST LAYER OF MUSCLES. In this layer are three muscles, viz., the flexor brevis digitorum, the abductor hallucis, and abductor minimi digiti. The short flexor of the toes lies in the centre of the foot ; and each of the others is in a line with the toe on which it acts. Muscles in the first layer.

The ABDUCTOR HALLUCIS (abd. pollicis pedis ; fig. 206, A), the most internal muscle of the superficial layer, takes *origin* from the inner side of the larger tubercle on the under surface of the os calcis, from the plantar fascia, from the lower border of the internal annular ligament, and from the internal intermuscular septum. In front, the muscle ends in a tendon, which is joined by fibres of the short flexor, and is *inserted* into the inner side of the base of the metatarsal phalanx of the great toe. Abductor hallucis : origin ; insertion ;

The cutaneous surface of the muscle is in contact with the plantar fascia ; and the other touches the tendons of the tibial muscles, the plantar vessels and nerves, and the tendons of the long flexors of the toes, with the accessorius muscle. relations ;

Action. This abductor acts chiefly as a flexor of the metatarsophalangeal joint of the great toe, but it will slightly abduct that toe from the others. use, as flexor and abductor.

The FLEXOR BREVIS DIGITORUM (flexor perforatus ; fig. 206, B) arises posteriorly by a pointed process from the fore part of the larger tubercle of the os calcis, and from the plantar fascia and the septa. About the centre of the foot the muscle divides into four slips, which become tendinous and are directed forwards over the tendons of the long flexor to enter the sheaths of the four smaller Flexor brevis digitorum

- divides into tendons for four toes ; toes, where they are *inserted* into the middle phalanges. In the sheath of the toe the tendon of this muscle lies at first (in this position of the foot) on the long flexor ; opposite the centre of the metatarsal phalanx it is slit for the passage of the other, and it is attached by two processes to the sides of the middle phalanx.
- insertion ; relations ; The short flexor of the toes is contained in a sheath of the plantar fascia, and occupies the middle of the foot. It conceals the tendon of the long flexor of the toes, the accessory muscle, and the external plantar vessels and nerve.
- and use. *Action.* It bends the first and second phalangeal joints of the four smaller toes, like the flexor sublimis in the upper limb, and approximates the toes at same time.
- Abductor of the little toe : The ABDUCTOR MINIMI DIGITI (fig. 206, c) has a wide *origin* behind from the small outer tubercle of the os calcis, from the adjacent part of the inner tubercle, and from the plantar fascia and the external intermuscular septum. It ends anteriorly in a tendon which is *inserted* into the outer side of the base of the metatarsal phalanx of the little toe.
- origin and insertion ; relations ; The muscle lies along the outer border of the foot, and conceals the flexor accessorius, and the tendon of the peroneus longus. On its inner side are the external plantar vessels and nerves. Sometimes a part of the muscle is fixed into the projection of the fifth metatarsal bone.
- use as abductor and flexor. *Action.* Though it can abduct the little toe from the others, as the name signifies, its chief use is to bend the metatarso-phalangeal joint.
- Dissect the next muscular layer, *Dissection.* To bring into view the second layer of muscles and the plantar vessels and nerves, the muscles already examined must be reflected (fig. 207). Cut through the flexor perforatus at the os calcis, and as it is raised, notice a branch of nerve and artery to it. Dividing the abductor minimi digiti near its origin, and turning it to the outer side of the foot, seek its nerve and vessel close to the calcaneum. The abductor hallucis can be drawn aside if it is necessary, but it may remain uncut till afterwards.
- and plantar vessels and nerves. Next, the internal plantar vessels and nerve are to be followed forwards to their termination, and backwards to their origin ; and the external plantar vessels and nerve, the tendons of the long flexors of the toes, the accessory muscle, and the small lumbricales, should be freed from fat.
- Two plantar arteries : The PLANTAR ARTERIES (fig. 207) are the terminal branches of the posterior tibial trunk, and supply digital offsets to the toes. They are two in number, and are named external and internal from their relative position in the sole of the foot. Of the two, the external is the larger, and forms the plantar arch.
- inner and outer. They are two in number, and are named external and internal from their relative position in the sole of the foot. Of the two, the external is the larger, and forms the plantar arch.
- Internal small ; The INTERNAL ARTERY (a) is inconsiderable in size, and accompanies the internal plantar nerve, under cover of the abductor hallucis, as far as the middle of the foot, where it ends in four superficial digital branches. (Illustrations of Dissections, p. 437.)
- course and ending. The INTERNAL ARTERY (a) is inconsiderable in size, and accompanies the internal plantar nerve, under cover of the abductor hallucis, as far as the middle of the foot, where it ends in four superficial digital branches. (Illustrations of Dissections, p. 437.)
- Branches to muscles ; *Branches.* The artery furnishes muscular branches, like the nerve, to the abductor hallucis, flexor perforatus, and the flexor brevis

hallucis. Its superficial digital branches accompany the digital and superficial digital; nerves of the internal plantar (fig. 206), and are thus disposed of :—

Fig. 206.*

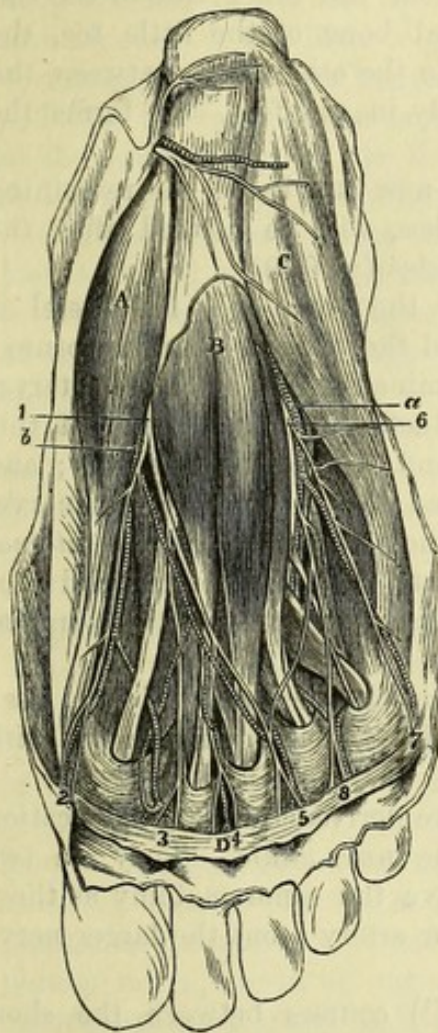
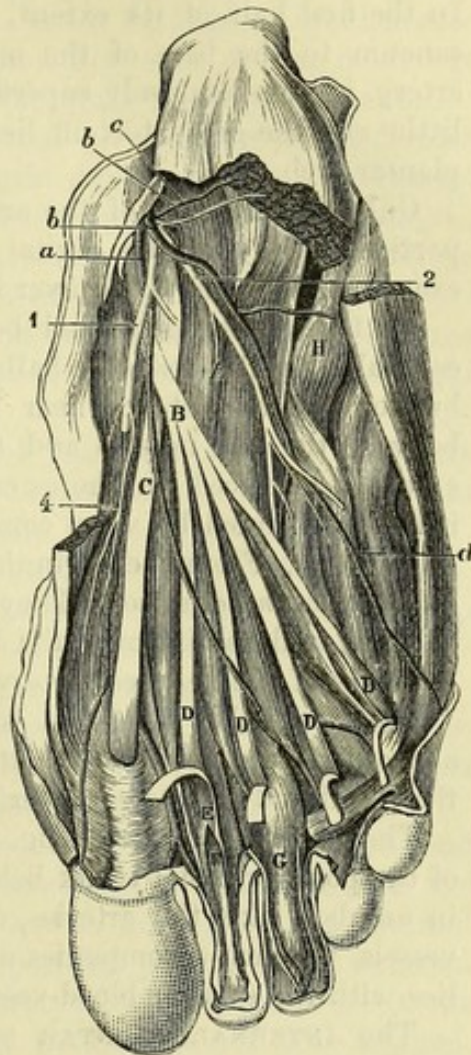


Fig. 207.†



The *first* is distributed to the inner side of the foot and great first, toe; the *second* lies over the first interosseous space; the *third* second, corresponds with the second space; and the *fourth* is placed over third, the third space. At the root of the toes the last three join the fourth, deeper digital arteries in those spaces.

* First view of the sole of the foot (Illustrations of Dissections). *Muscles* : A. Abductor hallucis. B. Flexor brevis digitorum. c. Abductor minimi digiti. D. Transverse ligament of the toes. *Arteries* : a. External plantar. b. Internal plantar. *Nerves* : 1. Internal plantar, with its four branches, 2, 3, 4 and 5, for three toes and a half. 6. External plantar nerve, with two digital branches, 7 and 8, for one toe and a half.

† Second view of the sole of the foot (Illustrations of Dissections). *Muscles* : A. Accessorius. B. Tendon of flexor longus digitorum. c. Tendon of flexor longus hallucis. D, marks the four lumbricales muscles, but the letters are put on the tendons of the flexor perforans. E. Tendon of flexor perforatus. F. Tendon of flexor perforans. G. Sheath of flexor tendons. H. Tendon of peroneus longus. *Arteries* : a. Internal plantar. b. External plantar. c. Branch to abductor minimi digiti. d. Branch to outer side of little toe. *Nerves* : 1. Internal, and 2. External plantar. 4. Branch to flexor brevis hallucis.

External artery has a curved course ;

partly superficial, partly deep.

Superficial part :

relations ;

branches to heel,

to muscles, and outer side of foot.

Plantar nerves also two.

Internal nerve to three toes and a half ;

muscular branches ;

digital nerves are divided, except first,

and give muscular branches,

cutaneous and articular offsets.

The EXTERNAL ARTERY (*b*) takes an arched course in the foot, with the concavity of the arch turned inwards. The vessel is first directed outwards across the sole, and then obliquely inwards towards the root of the great toe, so that it crosses the foot twice. In the first half of its extent, viz., from the inner side of the calcaneum to the base of the metatarsal bone of the little toe, the artery is comparatively superficial ; in the other half, between the little and the great toe, it lies deeply in the foot, and forms the plantar arch.

Only the first part of the artery is now laid bare ; the remaining portion, supplying the digital branches, will be noticed after the examination of the third layer of muscles (p. 679).

As far as the metatarsal bone of the little toe, the vessel is concealed by the abductor hallucis and the flexor brevis digitorum ; but for a short distance near its termination it lies in the interval between the last muscle and the abductor minimi digiti. In this extent it is placed on the os calcis, and the flexor accessorius ; and it is accompanied by venæ comites, and the external plantar nerve.

Branches. From the beginning of the artery two or three *internal calcaneal branches* arise. They perforate the origin of the abductor hallucis, and ramify over the heel, anastomosing with the terminal branches of the peroneal artery.

Offsets are also furnished to the muscles between which it lies ; and others turn round the outer border of foot to anastomose with the tarsal and metatarsal arteries.

The PLANTAR NERVES (fig. 207) are derived from the bifurcation of the posterior tibial trunk behind the inner ankle. They are two in number, like the arteries, and have the same anatomy as those vessels, for each accompanies a plantar artery ; but the larger nerve lies with the smaller blood-vessel.

The INTERNAL PLANTAR NERVE (¹) courses between the short flexor of the toes and the abductor hallucis, and giving but few muscular offsets, divides into four digital branches (fig. 206, ², ³, ⁴, ⁵) for the supply of both sides of the inner three toes, and half the fourth ; it resembles thus the median nerve of the hand in the distribution of its branches.

Muscular offsets are given by the trunk to the short flexor of the toes (*perforatus*) and the abductor hallucis ; and a few superficial twigs perforate the fascia.

The four *digital nerves* have a numerical designation, and the first is nearest the inner border of the foot. The branch (²) to the inner side of the great toe is undivided, but the others are bifurcated at the cleft between the toes.

Muscular branches are furnished by two of these nerves before they reach the toes ; thus, the first (most internal) supplies the flexor brevis hallucis ; and the second gives a branch to the innermost lumbrical muscle.

Digital nerves on the toes. Each of the outer three nerves, being divided at the spot mentioned, supplies the contiguous sides of two toes, while the first belongs altogether to the inner side of the great

toe ; all give offsets to the integuments, and the cutis beneath the nail, and articular filaments are distributed to the joints as in the fingers.

The EXTERNAL PLANTAR NERVE (fig. 207, ²) is spent chiefly in the deep muscles of the sole of the foot, but it furnishes digital nerves to both sides of the little toe, and the outer side of the next. It corresponds in its distribution with the ulnar nerve in the hand.

External
plantar to
one toe and
a half ;

It has the same course as the external plantar artery, and divides at the outer margin of the flexor brevis digitorum into a superficial and a deep portion ;—the former gives origin to two digital nerves ; but the latter accompanies the arch of the plantar artery into the foot, and will be dissected afterwards (p. 680).

has super-
ficial and
deep parts ;

While the external plantar nerve is concealed by the short flexor of the toes, it gives *muscular branches* to the abductor minimi digiti and the flexor accessorius.

branches to
muscles ;

The *digital branches* of the external plantar nerve (fig. 206) are two. One (⁷) is undivided ; it is distributed to the outer side of the little toe, and gives offsets to the flexor brevis minimi digiti, and oftentimes to the interosseous muscles of the fourth space. The other (⁸) bifurcates at the cleft between the outer two toes, and supplies their collateral surfaces : this nerve communicates in the foot with the last digital branch of the internal plantar nerve.

two digital
branches,
one single,

one divided,

On the sides of the toes the digital nerves have the same distribution as those from the other plantar trunk, and end like them in a tuft of fine branches at the extremity of the digit.

distribution
like others.

Dissection (fig. 207). To complete the preparation of the second layer of muscles, the abductor hallucis should be detached from the os calcis, and the muscle should be turned inwards. The internal plantar nerve and artery, and the superficial portion of the external plantar nerve, are to be cut across and thrown forwards ; but the external plantar artery and the nerve with it are not to be injured. All the fat, and the loose tissue and fascia, are then to be taken away near the toes.

Lay bare
second
layer of
muscles.

SECOND LAYER OF MUSCLES (fig. 207). In this layer are the tendons of the two flexor muscles at the back of the leg, viz., flexor longus digitorum and flexor longus hallucis, which cross one another. Connected with the former, soon after it enters the foot, is an accessory muscle ; and at its division into pieces four fleshy slips (*lumbricales*) are added to it.

Muscles of
second
layer.

The tendon of the FLEXOR LONGUS DIGITORUM (fig. 207, B), while entering the foot beneath the annular ligament, lies on the internal lateral ligament of the ankle-joint. In the foot it is directed obliquely towards the centre, where it is joined by the accessory muscle and a slip from the tendon of the flexor longus hallucis, and divides into tendons for the four outer toes.

Tendon of
long flexor
of toes

divides into
four ;

Each tendon enters the sheath of the toe with and beneath a tendon from the flexor brevis (E). About the centre of the metatarsal phalanx the tendon of the long flexor (F) is transmitted through the other, and passes onwards to be *inserted* into the base of the ungual phalanx. Uniting the flexor tendons with the two

these pierce
the other
tendons ;

short folds
to tendons

nearest phalanges of the toes are short synovial folds, one to each, as in the hand ; and the one fixing the flexor perforans is anterior (p. 300).

use. *Action.* It flexes the last phalangeal joint, and combines with the short flexor in bending the first and second joints. If it acted by itself it would tend to bring the toes somewhat inwards, in consequence of its oblique position in the foot.

Four lumbricales : attachment to long flexor, and extensor tendons ; The LUMBRICALES (fig. 207, D) are four small muscles between the tendons of the flexor longus digitorum. Each *arises* from two tendons with the exception of the most internal, and this is connected with the inner side of the tendon to the second toe. Becoming tendinous, they pass upwards on the tibial side of the four outer toes, and are *inserted* into the expansion of the extensor tendons on the dorsum of the first phalanx ; but they often end partially in an attachment to the side of the phalanx. The muscles decrease in size from the inner to the outer side of the foot.

Action. These small muscles assist in flexing the metatarsophalangeal joints ; and through their union with the long extensor tendon they may aid that muscle in straightening the two interphalangeal joints.

Flexor accessorius The ACCESSORIUS MUSCLE (fig. 207, A) has two heads of *origin* :— One is mostly tendinous, and is attached to the outer surface of the os calcis, and to the long plantar ligament ; the other is large and fleshy, and springs from the inner concave surface of the calcaneum. The fibres end in aponeurotic bands, which join the tendon of the flexor longus digitorum about the centre of the foot, and contribute slips to the pieces of that tendon going to the second, third and fourth digits (Turner).

relations ; The muscle is bifurcated behind, and the heads of origin are separated by the long plantar ligament. On it lie the external plantar vessels and nerve ; and the muscles of the first layer conceal it.

use. *Action.* By means of its offsets to the tendons of certain digits the muscle helps to bend those toes ; and from its position on the outer side of, and behind the long flexor to which it is united, it will oppose the inward pull of that muscle, and enable it to bend the toes directly backwards.

Insertion of tendon of flexor hallucis The tendon of the FLEXOR LONGUS HALLUCIS (fig. 207, C) is deeper in the sole of the foot than the flexor longus digitorum : taking a straight course to the root of the great toe, it enters the digital sheath, to be *inserted* into the base of the unguis phalanx. It is united to the long flexor tendon by a strong tendinous process, which, joined by bands of the accessorius, is continued into the pieces of that tendon belonging to the second and third toes (Turner).

relations ; Beneath the internal annular ligament this tendon lies in a groove on the back of the astragalus : in the foot it first occupies a similar groove on the under surface of the sustentaculum tali, and then lies over the flexor brevis hallucis.

use on first *Action.* For the action of this muscle on the great toe, see page 666. Through the slip that it gives to the tendons of the common

flexor going to the second and third toes, it will bend those digits and other toes. with the great toe.

Dissection (fig. 208). For the dissection of the third layer of muscles, the accessorius and the tendons of the long flexors are to be cut through near the calcaneum, and turned towards the toes. While raising the tendons, the external plantar nerve and artery are not to be interfered with; and small nerves and vessels to the outer three lumbricales are to be looked for. Afterwards the areolar tissue is to be taken from the muscles now brought into view.

THIRD LAYER OF MUSCLES (fig. 208). Only the short muscles of the great and little toes enter into this layer. On the metatarsal bone of the great toe the flexor brevis hallucis lies, and external to this is the adductor hallucis; on the metatarsal bone of the little toe is placed the flexor brevis minimi digiti. Crossing the heads of the metatarsal bones is the transversus pedis muscle.

The fleshy mass between the adductor hallucis and the short flexor of the little toe consists of the interosseous muscles of the next layer.

The FLEXOR BREVIS HALLUCIS (flex. brev. pollicis pedis; fig. 208, A) arises behind by two tendinous slips, one of which is fixed to the inner side of the cuboid bone, while the other is prolonged from the tendon of the tibialis posticus. Near the front of the first metatarsal bone the fleshy belly divides into two heads, which are inserted into the sides of the base of the metatarsal phalanx.

Resting on the muscle at one part, and in the interval between the heads at another, is the tendon of the flexor longus hallucis. The inner head joins the abductor, and the outer is united with the adductor hallucis. A sesamoid bone is developed in the tendon connected with each head.

Action. By its attachment to the first phalanx it flexes the metatarso-phalangeal joint of the big toe.

The ADDUCTOR HALLUCIS (add. pollicis pedis; fig. 208, B), which is larger than the preceding muscle and external to it, arises from the sheath of the tendon of the peroneus longus, and from the bases of the third and fourth metatarsal bones. Anteriorly the muscle is united with the outer head of the short flexor, and is inserted into the base of the metatarsal phalanx of the great toe.

To the inner side is the flexor brevis; and beneath the outer border the external plantar vessels and nerves are directed inwards.

Action. Its first action will be to adduct the great toe to the others, and it will help afterwards in bending the metatarso-phalangeal joint of the toe.

The TRANSVERSUS PEDIS (fig. 208, D) is placed transversely over the heads of the metatarsal bones. Its origin is by fleshy bundles from the capsule of the metatarso-phalangeal articulations of the three outer toes (frequently not from the little toe), and from the transverse metatarsal ligament. Its insertion into the great toe is united with that of the adductor hallucis.

The cutaneous surface is covered by the tendons and the nerves of

Dissect
third layer
of muscles.

Muscles of
third layer.

Flexor
brevis,
hallucis :
origin ;

insertion ;

relations ;

Adductor
hallucis :
origin ;

insertion ;

relations ;

use.

Transversus
pedis :
origin ;

insertion ;

relations ;

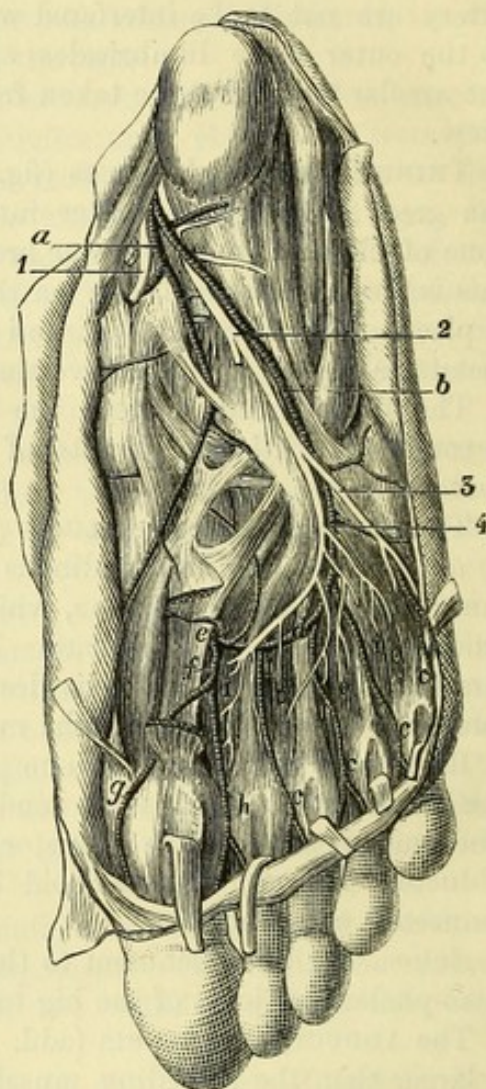
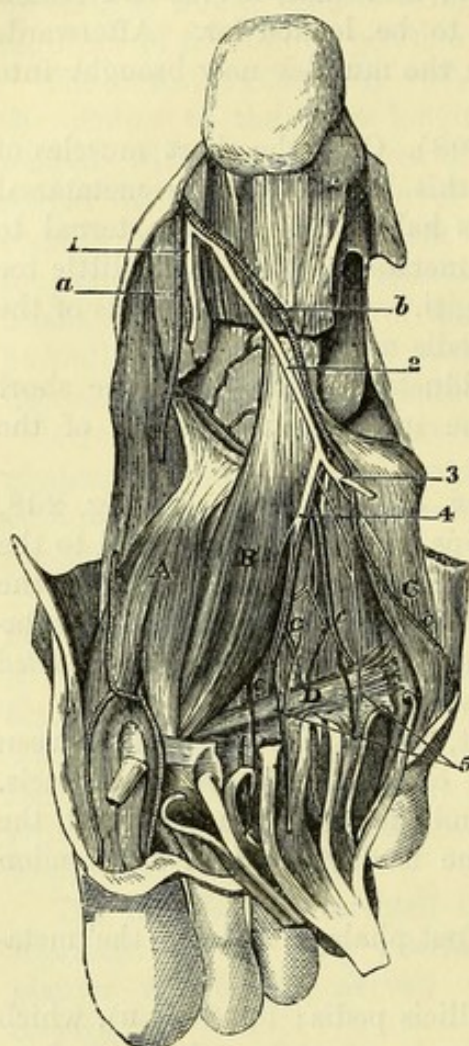
the toes ; and the opposite surface is in contact with the interosseous muscles and the digital vessels.

use on the
toes.

Action. It will adduct the great toe to the others, and then approximate the remaining toes.

Fig. 208.*

Fig. 209.†



Flexor
minimi
digiti :
origin :

The FLEXOR BREVIS MINIMI DIGITI (fig. 208, c) is a narrow muscle lying on the metatarsal bone of the little toe, and resembles one of the interossei. *Arising* behind from the metatarsal bone and

* Third view of the sole of the foot (Illustrations of Dissections). *Muscles* : A. Flexor brevis hallucis. B. Adductor hallucis. c. Flexor brevis minimi digiti. D. Transversus pedis. *Arteries* : a. Internal plantar, cut. b. External plantar, and c, its four digital branches. *Nerves* : 1. Internal plantar. 2. External plantar ; 3, its superficial part, cut ; 4, the deep part, with the plantar arch. 5. Offsets to the outer lumbrical muscles.

† Fourth view of the sole of the foot (Illustrations of Dissections). *Muscles* : o. Three plantar interossei. i. Four dorsal interossei. *Arteries* : a. Internal plantar, cut. b. External plantar ; c, its four digital branches. d. Plantar arch. e. Dorsal of foot entering the sole. f. Artery of great toe. g. Branch to inner side of great toe. h. Branch for the supply of great toe and the next. *Nerves* : 1. Internal plantar, cut. 2. External plantar ; 3, its superficial, and 4, its deep part, both cut ; the latter supplying offsets to the interosseous muscles.

the sheath of the peroneus longus, it blends in front with the inferior ligament of the metatarso-phalangeal articulation, and is *inserted* insertion; into the base of the first phalanx of the toe; some of the fibres are often inserted into the fore part of the metatarsal bone.

Action. Firstly, it bends the metatarso-phalangeal joint, and next use. it draws down and adducts the fifth metatarsal bone.

Dissection (fig. 209). In order that the deep vessels and nerves Dissect the deep vessel and nerves. may be seen, the flexor brevis and adductor hallucis are to be cut through behind, and thrown towards the toes; but the nerve supplying the latter is to be preserved. Beneath the adductor lie the plantar arch and the external plantar nerve with their branches; and through the first interosseous space the dorsal artery of the foot enters the sole. All these vessels and nerves, with their branches, require careful cleaning.

The muscles projecting between the metatarsal bones are the interossei; the fascia covering them should be removed.

The PLANTAR ARCH (fig. 209, *d*) is the portion of the external Arch of the plantar artery: extent; plantar artery which reaches from the base of the metatarsal bone of the little toe to the back of the first interosseous space: internally the arch is completed by a communicating branch from the dorsal artery of the foot (*e*; p. 680). It is placed across the tarsal ends of the metatarsal bones, in contact with the interossei, but relations with muscles, under the flexor tendons and the adductor hallucis.

Venæ comites lie on the sides of the artery, and the deep part of veins and nerve; the external plantar nerve accompanies it.

From the front or convexity of the arch the digital branches are branches:— supplied, and from the opposite side small nutritive branches arise.

Three small arteries, the *posterior perforating*, leave the deep Posterior perforating. aspect of the vessel: they pass to the dorsum of the foot through the three outer metatarsal spaces, and join the dorsal interosseous branches of the anterior tibial artery (p. 689).

The *digital branches* (*c*) are four in number, and supply both Digital branches to three toes and a half; sides of the three outer toes and half the next. One to the outer side of the little toe is single; the others lie over the interossei in the outer three metatarsal spaces, but beneath the transversus pedis (fig. 208), and bifurcate in front to supply the contiguous sides of two toes. They give fine offsets to the interossei, to some muscular and lumbricales, and the transversus pedis; and at the point of division they send small communicating branches—*anterior perforating*, to anterior perforating offsets; join the interosseous arteries on the dorsum of the foot (p. 689).

The *first digital* runs on the outer side of the little toe, supplying first the flexor brevis minimi digiti, and distributes small arteries to the integuments of the outer border of the foot.

The *second* belongs to the sides of the fifth and fourth toes, and second, furnishes a branch to the outer lumbrical muscle.

The *third* is distributed to the contiguous sides of the fourth and third, third, third toes, and emits a branch to the third lumbricalis.

The *fourth*, or most internal, corresponds with the second inter- fourth digital osseous space, and ends like the others on the third and second digits; it may assist in supplying the third lumbricalis.

junction
with inner
plantar;
distribution
on the toes.

The last two are joined by superficial digital branches of the internal plantar at the root of the toes.

On the sides of the toes the disposition of the arteries is like that of the digital in the hand. They extend to the end, where they unite in an arch, and give offsets to the sides and ball of the toe; and the artery on the second digit anastomoses at the end of the toe with a branch from the anterior tibial artery. Near the front of both the metatarsal and the next phalanx, they form anastomotic loops beneath the flexor tendons, from which the phalangeal articulations are supplied.

Ending of
the dorsal
artery of
the foot;

The DORSAL ARTERY OF THE FOOT (fig. 209, *e*) enters the sole at the posterior part of the first (inner) metatarsal space, and ends by inosculating with the plantar arch. By a large digital artery it furnishes branches to both sides of the great toe and half the next, in the same manner as the radial artery in the hand is distributed to one digit and a half.

its digital
branches,

The *digital branch* (*f*) extends to the front of the first interosseous space, and divides into collateral branches (*h*) for the contiguous sides of the great toe and the next. Near the head of the metatarsal bone it sends inwards, beneath the flexor muscles, a digital branch (*g*) for the inner side of the great toe.

on the
digits.

The arteries have the same arrangement along the toes as the other digital branches; and that to the second digit anastomoses at the end with a branch of the plantar arch.

External
plantar
nerve ends
in the deep
muscles:

The DEEP PART OF THE EXTERNAL PLANTAR NERVE (fig. 209, *4*) accompanies the arch of the artery, and ends internally in the adductor hallucis. It furnishes branches to all the interossei, to the transversus pedis, and to the outer three lumbrical muscles (Brooks). This nerve corresponds with the deep portion of the ulnar nerve in the hand.

like ulnar
nerve.

Dissection.

Dissection. It will be needful to remove the transverse muscle, to see a ligament across the heads of the metatarsal bones.

Transverse
metatarsal
ligament.

The TRANSVERSE METATARSAL LIGAMENT is a strong fibrous band, like that in the hand (p. 304), which connects together all the metatarsal bones at their anterior extremity. A thin fascia covering the interosseous muscles is attached to its hinder edge. It is concealed by the transversus pedis, and by the tendons, vessels, and nerves of the toes.

Dissect the
last layer
of muscles.

Dissection. To complete the dissection of the last layer of muscles, the flexor brevis minimi digiti may be detached and thrown forwards. Dividing then the metatarsal ligament between the bones, the knife is to be carried directly backwards for a short distance in the centre of each interosseous space, except the first, in order that the two interosseous muscles may be separated from each other. All the interossei are visible in the sole of the foot.

The fascia covering the muscles should be taken away if any remains, and the branches of the external plantar nerve to them should be dissected out.

Fourth
layer of
muscles.

FOURTH LAYER OF MUSCLES (fig. 209). In the fourth and last layer of the foot are contained the interosseous muscles, and the tendons of the tibialis posticus and peroneus longus.

The INTEROSSEOUS MUSCLES (fig. 209) are situate in the intervals between the metatarsal bones : they consist of two sets, plantar and dorsal, like the interossei in the hand. Seven in number, there are three plantar and four dorsal ; and two are found in each space, except the innermost.

The *plantar muscles* (o) belong to the outer three toes, and are slender fleshy slips. Each *arises* from the under and inner surface of the metatarsal bone ; and is *inserted* partly into the tibial side of the base of the metatarsal phalanx of the same toe, and partly by an expansion to the extensor tendons on the dorsum of the phalanx. These muscles are smaller than the dorsal, and are placed more in the sole of the foot.

The *dorsal muscles* (r), one in each space, *arise* by two heads from the lateral surfaces of the bones between which they lie ; and are *inserted* like the others into the side, and on the dorsum of the metatarsal phalanx of certain toes :—Thus, the inner two muscles belong to the second toe, one to each side ; the next belongs to the outer side of the third toe ; and the remaining one to the outer side of the fourth toe.

The interossei are crossed by the external plantar vessels and nerve, and their digital branches, and lie beneath the transversus pedis and the metatarsal ligament. The posterior perforating arteries pierce the hinder extremities of the dorsal set.

Action. Like the interossei of the hand (p. 305) they will contribute to the bending of the metatarso-phalangeal joints, and straighten the two interphalangeal joints.

They can act also as abductors and adductors of the toes. Thus, the plantar set will bring the three outer toes towards the second toe ; and the dorsal muscles will abduct from the middle line of the second toe,—the two attached to that digit moving it to the right and left of the said line.

Dissection. Following the tendon of the tibialis posticus muscle from its position behind the inner malleolus to its insertion into the navicular bone, trace the numerous processes that it sends forwards and outwards. Open also the fibrous sheath of the tendon of the peroneus longus, which crosses from the outer to the inner side of the foot.

The tendon of the TIBIALIS POSTICUS is continued forwards over the internal lateral ligament of the ankle-joint, and over the astragalo-navicular articulation, to be *inserted* into the tuberosity of the navicular bone. From its insertion processes are continued to many of the other bones of the foot :—One is directed backwards to the sustentaculum tali of the os calcis. Two offsets are directed forwards ;—one to the internal cuneiform bone ; the other, much the largest, is attached to the middle and outer cuneiform, to the cuboid bone, and to the bases of the second, third, and fourth metatarsal bones. In other words, pieces are fixed into all the tarsal bones except one (astragalus), and into all the metatarsal bones except two (first and fifth).

Where the tendon is placed beneath the articulation of the astra-

Interossei.

Three plantar for three outer toes.

Four dorsal between the bones.

Relations.

Use as flexors, and extensors ; as adductors, and abductors.

Trace out the deep tendons.

Insertion of tendon of tibialis posticus

into tarsus

and metatarsus.

galus, it contains a fibro-cartilage, or occasionally a sesamoid bone.

Insertion of
tendon of
peroneus
longus :

The tendon of the PERONEUS LONGUS MUSCLE winds round the cuboid bone, and is continued inwards in the groove on the under surface, to be *inserted* into the internal cuneiform bone, and the base of the metatarsal bone of the great toe ; and sometimes by a slip into the base of the second metatarsal bone.

relations.

In the sole of the foot (fig. 209), it is contained in a sheath which is completed, towards the outer part, by the fibres of the long plantar ligament prolonged to the tarsal ends of the third and fourth metatarsal bones ; but it is formed internally only by areolar tissue. A synovial membrane lubricates the sheath.

Where the tendon turns round the cuboid bone it is thickened, and contains fibro-cartilage or a sesamoid bone.

SECTION VI.

THE FRONT OF THE LEG.

Position of
the limb.

Position. The limb is to be raised to a convenient height by blocks beneath the knee, and the foot is to be extended in order that the muscles on the front of the leg may be put on the stretch.

Raise the
skin.

Dissection. To enable the dissector to raise the skin from the leg and foot, one incision should be made along the middle line from the knee to the toes, and this should be intersected by cross cuts at the ankle and the root of the toes.

Seek the
cutaneous
nerves in
the leg ;

After the flaps of skin are reflected, the cutaneous vessels and nerves are to be looked for. At the upper and inner part of the leg are some filaments from the great saphenous nerve ; and at the outer side others, still smaller, from the external popliteal nerve. Perforating the fascia in the lower third, on the anterior aspect, the musculo-cutaneous nerve may be found, the branches of which should be pursued to the toes.

on the foot
both vessels
and nerves ;

On the dorsum of the foot is a venous arch, which ends laterally in the saphenous veins. On the outer side lies the external saphenous nerve ; and about the middle of the instep the internal saphenous nerve ceases. In the interval between the great toe and the next the cutaneous part of the anterior tibial nerve appears.

clean the
fascia.

The digital nerves should be traced to the ends of the toes by removing the integuments ; and after the several vessels and nerves are dissected, the fat is to be taken away, in order that the fascia may be seen.

Cutaneous
veins :

The VENOUS ARCH on the dorsum of the foot has its convexity turned forwards, and receives digital branches from the toes ; at its concavity it is joined by small veins from the instep. Internally and externally it passes into the saphenous veins.

internal
saphenous ;

The INTERNAL SAPHENOUS VEIN begins at the inner side of the great toe, and in the arch. It ascends in front of the inner ankle

to the inside of the leg (p. 660). Branches enter it from the inner border and sole of the foot.

The EXTERNAL SAPHENOUS VEIN begins on the outside of the little toe and foot, as well as in the venous arch; and it is continued below the outer ankle to the back of the leg (p. 660).

CUTANEOUS NERVES (fig. 210). The superficial nerves on the front of the leg and foot are derived mainly from branches of the popliteal trunks, viz., from the musculo-cutaneous and anterior tibial nerves of the external popliteal, and from the external saphenous nerve of the two popliteal. Some inconsiderable offsets ramify on the front of the leg from the internal saphenous and external popliteal.

The MUSCULO-CUTANEOUS NERVE (2) ends on the dorsum of the foot and toes. Perforating the fascia in the lower third of the leg with a cutaneous artery, it divides into two principal branches (inner and outer), which give dorsal digital nerves to the sides of all the toes, except the outer part of the little toe and the contiguous sides of the great toe and the next. The branches may be traced in the integument as far as the end of the last phalanx:—

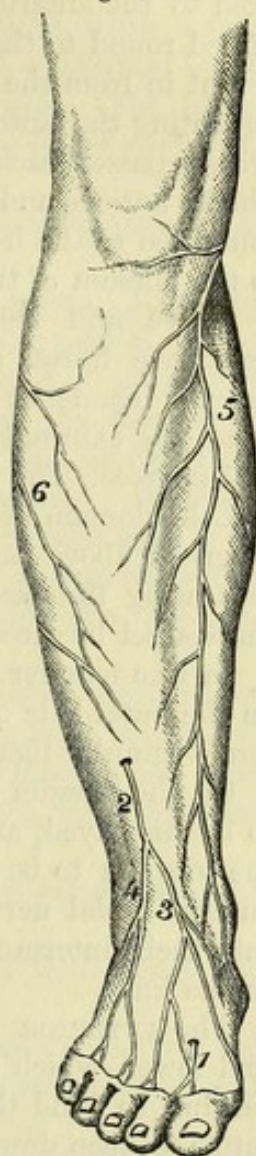
The *inner branch* (3) sends one offset to the inner side of the foot and great toe, and another to the adjacent sides of the second and third toes: it communicates with the internal saphenous and the anterior tibial nerves.

The *outer branch* (4) also divides into two nerves; these lie over the third and fourth interosseous spaces, and bifurcate at the web of the foot for the contiguous sides of the three toes corresponding with those spaces: it joins the external saphenous nerve on the outer border of the foot.

The ANTERIOR TIBIAL NERVE (1) becomes cutaneous in the first interosseous space, and is distributed to the opposed sides of the great toe and the next. The musculo-cutaneous nerve joins it, and sometimes assists in supplying the same toes.

The EXTERNAL SAPHENOUS NERVE (fig. 203,⁵) comes from the back of the leg below the outer ankle, and is continued along the foot to the outside of the little toe; all the outer margin of the foot receives nerves from it, and the offsets towards the sole are larger than those to the dorsum. Occasionally it supplies both sides of the little toe and part of the next.

Fig. 210.*



Source of the cutaneous nerves.

Musculo-cutaneous supplies most of the toes;

divides into

inner and

outer branch.

Anterior tibial, where found.

External saphenous.

* Cutaneous nerves of the front of the leg and foot. 1. Anterior tibial. 2. Musculo-cutaneous, with 3, its inner, and 4, its outer piece. 5. Internal saphenous. 6. Offsets of external popliteal.

- Internal saphenous.** INTERNAL SAPHENOUS NERVE (fig. 210,⁵). This nerve is continued along the vein of the same name to the middle of the instep, where it ceases mostly in the integuments, but some branches pass through the deep fascia to end in the tarsus.
- Deep fascia of the leg:** The DEEP FASCIA of the front of the leg is thickest near the knee-joint, where it gives origin to muscles. On the inner side it is fixed to the anterior border of the tibia; but externally it is continued round to the back of the leg. A strong intermuscular septum is sent in from the deep surface to the anterior border of the fibula, separating the anterior and external muscles; and another weaker process passes backwards in the upper third of the leg between the tibialis anticus and extensor longus digitorum. Above, the fascia is connected to the heads of the leg-bones; but below, it is continued to the dorsum of the foot.
- transverse fibres at the ankle.** Above and below the ankle-joint it is strengthened by some transverse fibres, and gives rise to the two parts of the anterior annular ligament; and below the end of the fibula it forms another band, the external annular ligament.
- Take away the fascia,** *Dissection.* The fascia is to be removed from the front of the leg and the dorsum of the foot, but the thickened band of the annular ligament above and below the end of the tibia is to be left. In separating the fascia from the subjacent muscles, let the edge of the scalpel be directed upwards.
- leave ligamentous bands,** In like manner the fascia may be taken from the peronei muscles on the outer side of the fibula, but without destroying the band (external annular ligament) below that bone.
- clean nerves and vessels.** On the dorsum of the foot, the dorsal vessels with their nerve are to be displayed, and the tendons of the short and long extensors of the toes are to be traced to the ends of the digits. In the leg, the anterior tibial nerve and vessels are to be followed from the dorsum into their intermuscular space, and are then to be cleaned as high as the knee.
- Anterior annular ligament:** The ANTERIOR ANNULAR LIGAMENT consists of two pieces, upper and lower, which confine the muscles in their position,—the former serving to bind the fleshy bellies to the bones of the leg, and the latter to keep down the tendons on the dorsum of the foot.
- its upper** The *upper part*, above the level of the ankle-joint, is attached laterally to the bones of the leg; it possesses one sheath with synovial membrane for the tibialis anticus.
- and lower piece;** The *lower part* is situate in front of the tarsal bones. It is inserted externally by a narrow piece into the upper surface of the os calcis, in front of the interosseous ligament; and internally, where it is thin and widened, into the plantar fascia and the inner malleolus. In this piece of the ligament there are three sheaths;—an inner one for the tibialis anticus; an outer for the extensor longus digitorum and peroneus tertius; and an intermediate one for the extensor hallucis. Separate synovial membranes line the sheaths.
- sheaths differ in each.**
- External annular ligament.** The EXTERNAL ANNULAR LIGAMENT is placed below the fibula, and is attached on the one side to the outer malleolus, and on the other to the os calcis. Its lower edge is connected by fibrous tissue

to the sheaths of the peronei muscles on the outer side of the os calcis. It contains the two lateral peronei muscles in one compartment; and this is lined by a synovial membrane, which sends two offsets below into the separate sheaths of the tendons.

The MUSCLES ON THE FRONT OF THE LEG (fig. 211) are four in number. The large muscle next the tibia is the tibialis anticus; that next the fibula, the extensor longus digitorum; while a small muscle, apparently the lower end of the last with a separate tendon to the fifth metatarsal bone, is the peroneus tertius. The muscle between the tibialis and extensor digitorum, in the lower part of the leg, is the extensor proprius hallucis.

On the dorsum of the foot only one other muscle appears, the extensor brevis digitorum.

The TIBIALIS ANTICUS (fig. 211,¹) reaches the tarsus: it is thick and fleshy in the upper, but tendinous in the lower part of the leg. It arises from the outer tuberosity, and the upper half of the external surface of the tibia; from the contiguous part of the interosseous membrane; and from the fascia of the leg, and the intermuscular septum between it and the extensor longus digitorum. Its tendon begins below the middle of the leg, and passes beneath both pieces of the annular ligament, where it is surrounded by a synovial sheath, to be inserted into the internal cuneiform bone, and the metatarsal bone of the great toe.

The muscle is subaponeurotic. It lies at first outside the tibia, resting on the interosseous membrane; but it is then placed successively over the end of the tibia, the ankle-joint, and the inner tarsal bones. On its outer side are the extensor muscles of the toes, and the anterior tibial vessels and nerve.

Action. Supposing the foot not fixed, the tibialis bends the ankle, and raises the inner border of the foot.

If the foot is fixed, it can lift the inner border with the tibialis posticus, and support the foot on the outer edge.

If the tibia is slanting backwards, as when the advanced limb reaches the ground in walking, it can bring forwards and make steady that bone.

The EXTENSOR PROPRIUS HALLUCIS (ext. prop. pollicis pedis; fig. 211) is deeply placed at its origin between the former muscle and the extensor longus digitorum, but its tendon becomes superficial on the dorsum of the foot. The muscle arises from the middle two-fourths of the narrow anterior surface of the fibula, and from the interosseous membrane for the same distance. At the ankle it ends in a tendon, which comes to the surface through a sheath in the lower piece of the annular ligament, and continues over the tarsus to be inserted into the base of the last phalanx of the great toe.

The anterior tibial vessels lie on the inner side of the muscle at its origin, but afterwards on the outer side of its tendon, so that they are crossed by it in the lower third of the leg.

Action. It straightens the great toe by extending the phalangeal joints, and afterwards bends the ankle.

Muscles on
the front of
the leg

Tibialis
anticus:
origin;

insertion;

parts in
contact;

use on the
foot, free,

and fixed;

on the tibia
in walking.

Extensor
longus
hallucis;

origin from
fibula;

insertion to
great toe;

it crosses
the vessels;

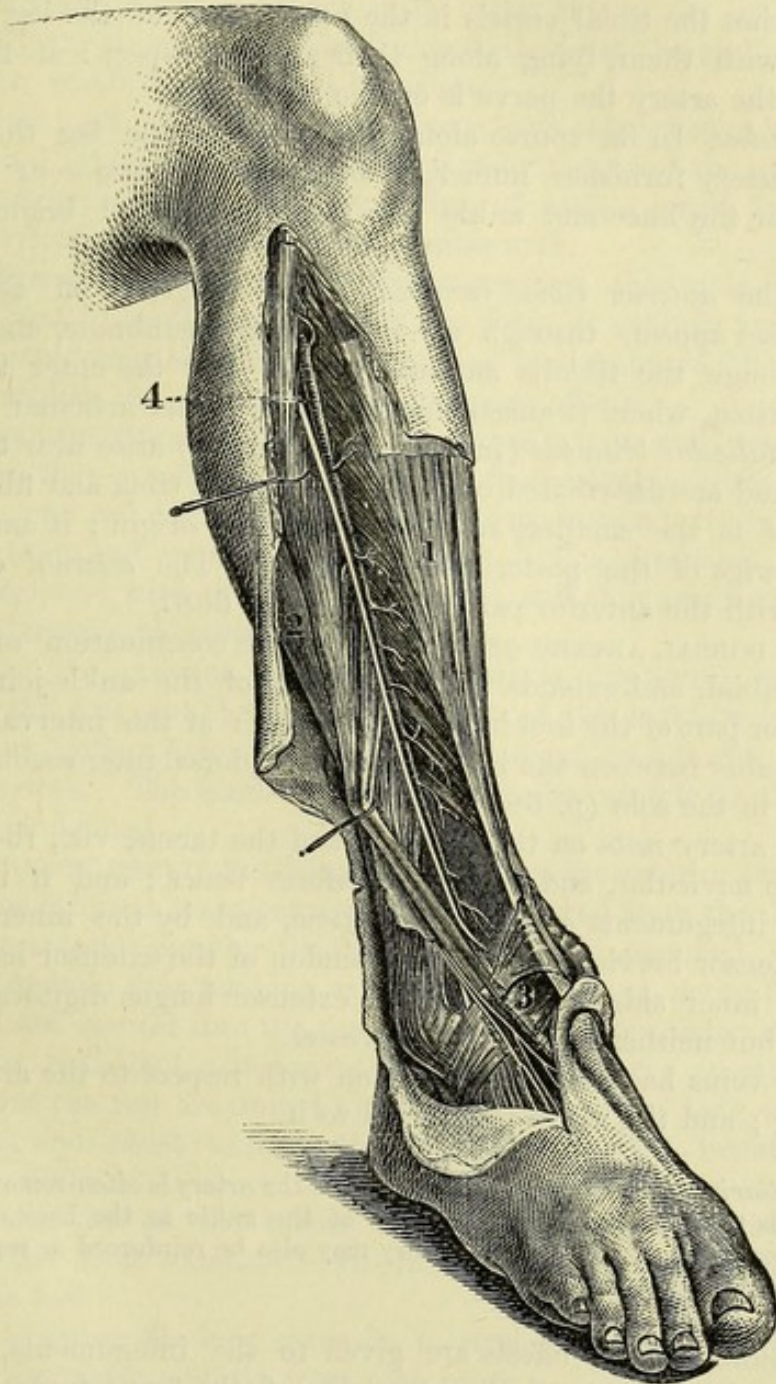
use on great
toe;

- on tibia. When the foot is fixed on the ground and the tibia slants backwards, the muscle can draw forwards that bone.
- Extensor longus digitorum The EXTENSOR LONGUS DIGITORUM (fig. 211,²) is fleshy in the leg, and tendinous on the foot, like the other muscles. Its *origin* is from the head, and upper three-fourths of the anterior surface of the fibula ; from the external tuberosity of the tibia, and about an inch (above) of the interosseous membrane ; and from the fascia of the leg, and the intermuscular septum on each side. The tendon enters its sheath in the annular ligament with the peroneus tertius, and divides into four pieces. Below the ligament these slips are continued to the four outer toes, and are *inserted* into the middle and unguinal phalanges :—
- arises from tibia and fibula ;
- inserted into four outer toes :
- arrangement of the tendons on the toes ;
- On the metatarsal phalanx the tendons of the long and short extensor join with prolongations from the interossei and lumbricales to form an aponeurosis ; but there is no tendon from the short extensor to the expansion on the little toe. At the distal end of this phalanx the aponeurosis is divided into three parts—a central and two lateral ; the central piece is inserted into the base of the middle phalanx, while the lateral unite at the front of the middle, and are fixed into the unguinal phalanx.
- relations of the muscle ;
- In the leg the muscle is placed between the peronei on the one side, and the tibialis anticus and extensor proprius hallucis on the other. It lies on the fibula, the lower end of the tibia, and the ankle-joint. In the foot the tendons rest on the extensor brevis digitorum ; and the vessels and nerve are internal to them.
- use on toes and ankle ;
- Action.* The muscle extends the four outer toes, acting mainly on the metatarso-phalangeal joints ; it can also bend the ankle-joint.
- on tibia.
- If the tibia is inclined back, as when the foot reaches the ground in walking, it will be moved forwards by this and the other muscles on the front of the leg.
- Peroneus tertius :
- The PERONEUS TERTIUS is situate below the extensor longus digitorum, from which it is seldom separate. It *arises* from the lower fourth of the anterior surface of the fibula, from the lower end of the interosseous membrane, and from the intermuscular septum between it and the peroneus brevis muscle ; and it is *inserted* into the base of the metatarsal bone of the little toe on the upper surface.
- origin ;
- insertion ;
- This muscle has the same relations in the leg as the lower part of the long extensor, and is contained in the same space in the annular ligament.
- use with tibialis, with peronei.
- Action.* The muscle assists the tibialis anticus in bending the ankle ; but it differs from that muscle in raising the outer border of the foot, and thus helps the other peronei in producing the movement of eversion.
- Anterior tibial artery :
- The ANTERIOR TIBIAL ARTERY (fig. 211, ⁴) extends from the bifurcation of the popliteal trunk to the front of the ankle-joint. At this spot it becomes the dorsal artery of the foot.
- course and extent ;
- The course of the artery is forwards through the aperture in the upper part of the interosseous membrane, along the front of that membrane, and over the tibia to the foot. A line drawn along the front of the leg from a point midway between the projection of the
- direction ;

outer tuberosity of the tibia and the head of the fibula to the centre of the ankle will mark the position of the vessel.

For a short distance (about two inches) the artery lies between the tibialis anticus and the extensor longus digitorum ; afterwards relations to parts around ;

Fig. 211.*



it is placed between the tibial muscle and the extensor proprius hallucis as far as the lower third, where the last muscle becomes superficial and crosses to the inner side. The vessel rests on the interosseous membrane in two-thirds of its extent, being overlapped

* Dissection of the front of the leg (Quain's Arteries). 1. Tibialis anticus muscle. 2. Extensor hallucis and extensor longus digitorum drawn aside. 3. Part of the anterior annular ligament. 4. Anterior tibial artery : the nerve outside it is the anterior tibial.

by the fleshy bellies of the contiguous muscles, so that it is at some depth from the surface ; but it is placed in front of the tibia and the ankle-joint in the lower third, and is comparatively superficial between the tendons of the muscles.

position of veins and nerve ; Venæ comites entwine around the artery, covering it very closely with cross branches in the upper part. The anterior tibial nerve approaches the tibial vessels in the upper third of the leg, and continues with them, lying along their anterior aspect : at the lower end of the artery the nerve is on the outer side.

branches :— *Branches.* In its course along the front of the leg the anterior tibial artery furnishes numerous *muscular* and *cutaneous branches* ; and near the knee and ankle the following named branches take origin :—

Recurrent. *a.* The *anterior tibial recurrent artery* is given off as soon as the vessel appears through the interosseous membrane, and ascending through the tibialis anticus, ramifies over the outer tuberosity of the tibia, where it anastomoses with the other articular arteries.

Malleolar ; *b.* *Malleolar branches* (internal and external) arise near the ankle-joint, and are distributed over the ends of the tibia and fibula. The *internal* is the smaller, and less constant in origin ; it anastomoses with twigs of the posterior tibial artery. The *external* communicates with the anterior peroneal artery (p. 668).

Dorsal artery : extent and course ; The DORSAL ARTERY OF THE FOOT is the continuation of the anterior tibial, and extends from the front of the ankle-joint to the posterior part of the first interosseous space : at this interval it passes downwards between the heads of the first dorsal interosseous muscle, to end in the sole (p. 680).

relations ; The artery rests on the inner part of the tarsus, viz., the astragalus, the navicular, and middle cuneiform bones ; and it is covered by the integuments and the deep fascia, and by the inner piece of the extensor brevis muscle. The tendon of the extensor hallucis lies on the inner side, and that of the extensor longus digitorum on the outer, but neither is close to the vessel.

position of veins and nerve. The veins have the same position with respect to the artery as in the leg ; and the nerve is external to it.

Varieties in dorsal artery. *Peculiarities.* On the dorsum of the foot the artery is often removed farther outwards than the line from the centre of the ankle to the back of the first interosseous space. The dorsal artery may also be reinforced or replaced by a large anterior peroneal branch.

Branches :— *Branches.* Small offsets are given to the integuments, and the bones and ligaments of the inner side of the foot ; from the outer side of the vessel proceed two larger branches named tarsal and metatarsal ; and an interosseous branch is furnished to the first metatarsal space.

Tarsal. *a.* The *tarsal branch* arises opposite the head of the astragalus, and runs beneath the extensor brevis digitorum to the outer border of the foot, where it divides into twigs that inosculate with the metatarsal, external plantar, and anterior peroneal arteries : it supplies offsets to the extensor muscle beneath which it lies.

b. The *metatarsal branch* takes an arched course to the outer side of the foot, near the base of the metatarsal bones and beneath the short extensor muscle, and anastomoses with the external plantar and tarsal arteries. Metatarsal,

From the arch of the metatarsal branch three *dorsal interosseous arteries* are furnished to the three outer metatarsal spaces ; and the external of these sends a branch to the outer side of the little toe. They supply the interosseous muscles, and divide at the cleft of the toes into two small dorsal digital branches. which gives interosseous,

At the fore part of the metatarsal space each interosseous branch joins a digital artery in the sole of the foot by means of the *anterior perforating twig* ; and from the beginning of each a small branch, *posterior perforating*, descends to the plantar arch. and perforating.

c. The *first dorsal interosseous artery* arises from the main trunk as this is about to leave the dorsum of the foot ; it extends forwards in the space between the first two toes, and is distributed by dorsal digital pieces like the other dorsal interosseous offsets. First interosseous.

The ANTERIOR TIBIAL VEINS have the same extent and relations as the vessel they accompany. They take their usual position along the artery, one on each side, and form loops around it by cross branches ; they end in the popliteal vein. The branches they receive correspond with those of the artery ; and they communicate with the internal saphenous vein. Anterior tibial veins.

Dissection. To examine the extensor brevis digitorum on the dorsum of the foot, cut through the tendons of the extensor longus and peroneus tertius below the annular ligament, and throw them towards the toes. The hinder attachment of the muscle to the os calcis is to be defined. Divide extensor longus.

The EXTENSOR BREVIS DIGITORUM arises from the anterior extremity of the os calcis at its upper and outer part, and from the lower band of the anterior annular ligament. Over the metatarsal bones the muscle ends in four tendons, which spring from as many fleshy bellies, and are inserted into the four inner toes. The tendon of the great toe has a distinct attachment to the base of the metatarsal phalanx ; but the rest are united to the outer side of the long extensor tendons, and assist to form the expansion on the metatarsal phalanx (p. 686). Extensor brevis digitorum sends tendons to four inner toes ;

The muscle lies on the tarsus, and is partly concealed by the tendons of the long extensor. Its inner belly crosses the dorsal artery of the foot. relations ;

Action. Assisting the long extensor, it straightens the four inner toes, separating them slightly from each other. use.

Dissection. The branches of artery and nerve which are beneath the extensor brevis will be laid bare by cutting across that muscle near its front, and turning it upwards. Cut through extensor brevis,

By dividing the lower band of the annular ligament over the tendon of the extensor hallucis, and throwing outwards the external half of it, the different sheaths of the ligament, the attachment to the os calcis, and the origin of the extensor brevis digitorum from it may be observed. and annular ligament :

follow up
the nerves.

The anterior tibial and musculo-cutaneous nerves are now to be followed upwards to their origin from the external popliteal; and a small branch to the knee-joint from the same source is to be traced through the tibialis anticus.

Nerves of
the front of
the leg.

NERVES OF THE FRONT OF THE LEG. Between the fibula and the peroneus longus muscle the external popliteal nerve divides into the musculo-cutaneous and anterior tibial; and from the beginning of the anterior tibial nerve, or the end of the popliteal trunk, a small branch called the recurrent articular is given off.

Recurrent.

The RECURRENT ARTICULAR BRANCH takes the course of the artery of the same name through the tibialis anticus muscle, in which most of its fibres end. A small twig may be followed to the knee-joint.

Musculo-
cutaneous

The MUSCULO-CUTANEOUS NERVE is continued between the extensor longus digitorum and the peronei muscles to the lower third of the leg, where it pierces the fascia, and is distributed to the dorsum of the foot and the toes (p. 683). Before the nerve becomes cutaneous it furnishes branches to the two larger peronei muscles.

supplies
peronei.

Anterior
tibial is with
the artery:

The ANTERIOR TIBIAL NERVE (fig. 211) is directed beneath the extensor longus digitorum, and reaches the tibial artery in the lower part of the upper third of the leg. From this spot it takes the course of the vessel along the leg and foot to the first interosseous space (p. 683). In the leg it lies for the most part in front of the anterior tibial vessels, but on the foot it is generally external to the dorsal artery.

branches to
muscles.

Branches. In the leg the nerve supplies the anterior tibial muscle, the extensors of the toes, and the peroneus tertius. On the dorsum of the foot it furnishes a considerable branch to the short extensor: this becomes enlarged, and gives offsets to the articulations of the foot.

External
muscles of
the leg.

MUSCLES ON THE OUTER SIDE OF THE LEG (fig. 205). Two muscles occupy this situation, and are named peroneal from their attachment to the fibula: they are distinguished as long and short. Intermuscular processes of fascia, which are attached to the fibula, isolate these muscles from others.

Peroneus
longus:

origin from
the fibula;

The PERONEUS LONGUS (fig. 205, G), the more superficial of the two muscles, passes into the sole of the foot round the outer border. It *arises* from the outer tuberosity of the tibia by a small slip; from the head, and the outer surface of the shaft of the fibula for two-thirds of the length, gradually tapering downwards; and from the fascia and the intermuscular septa. Inferiorly, it ends in a tendon which is continued through the external annular ligament with the peroneus brevis, lying in the groove at the back of the external malleolus; and it passes finally in a separate sheath below the peroneus brevis along the side of the os calcis, and through the groove in the outer border of the cuboid bone, to the sole of the foot. Its position in the foot, and its *insertion* are described before (p. 682).

insertion
into bones
of the foot;

relations in
the leg

In the leg the muscle is immediately beneath the fascia, and lies on the peroneus brevis. Beneath the annular ligament it is placed over the middle piece of the external lateral ligament of the ankle

with the peroneus brevis, and is surrounded by a single synovial membrane common to both. The extensor longus digitorum and the soleus are fixed to the fibula in front of, and behind it respectively.

Action. With the foot free, the muscle extends the ankle; then it can depress the inner, and raise the outer border of the foot in the movement of eversion. use on foot, free,

When the foot rests on the ground, it assists to lift the os calcis and the weight of the body, as in standing on the toes, or in walking. And in rising from a stooping posture it draws back the fibula. and fixed; on the leg.

The PERONEUS BREVIS (fig. 205, H) reaches the outer side of the foot, and is smaller and deeper than the preceding muscle. It arises from the outer surface of the shaft of the fibula for about the lower two-thirds, extending upwards by a pointed piece in front of the peroneus longus; and from the intermuscular septum on each side. Its tendon passes with that of the peroneus longus beneath the external annular ligament, and is placed next the fibula as it turns below this bone. Escaped from the ligament, the tendon enters a distinct fibrous sheath, which conducts it along the tarsus to its *insertion* into the tuberosity at the base of the metatarsal bone of the little toe. Peroneus brevis is attached to fibula, and fifth metatarsal bone;

In the leg the muscle projects in front of the peroneus longus. On the outer side of the os calcis it is contained in a sheath above the tendon of the former muscle; and each sheath is lined by a prolongation from the common synovial membrane behind the outer ankle. relations;

Action. If the foot is unsupported, this peroneus extends the ankle, and moves the foot upwards and outwards in eversion. use on foot, free,

Like the long muscle, it is able if the foot is supported to raise the heel, and to bring back the fibula as the body rises from stooping. and fixed; on the leg.

SECTION VII.

LIGAMENTS OF THE KNEE, ANKLE, AND FOOT.

Directions. In examining the remaining articulations of the limb, the student may take first the knee-joint, unless this has become dry; in that case the ligaments of the leg, ankle-joint, and foot may be dissected while the knee is being moistened. Examine first the knee-joint.

Dissection. For the preparation of each ligament of the knee-joint, it is sufficient to detach the muscles and tendons from around it, and to remove the areolar tissue or fibrous structure which may obscure or conceal the ligamentous band. A kind of aponeurotic capsule is to be defined on the front of the joint; and some tendons, namely, those of the biceps, popliteus, adductor magnus, and semimembranosus, are to be followed to their insertion, a part of each being left. Dissection to see knee, capsule, and tendons.

Bones in the
knee-joint.

ARTICULATION OF THE KNEE. The knee is the largest joint in the body, and is formed by the contiguous ends of the tibia and femur, with the patella. The articular surfaces of the bones are covered with cartilage, and are maintained in apposition by strong and numerous ligaments.

Capsul :

how formed,

arrange-
ment.;

The *capsule* (fig. 212) is an aponeurotic covering on the front of the joint, which closes the wide intervals between the anterior and the lateral ligaments; and it is derived from the fascia lata united with fibrous offsets of the extensor and flexor muscles. It covers the anterior and the external lateral ligaments, being inserted below into the heads of the tibia and fibula; and it blends on the inner side

Fig. 212.*

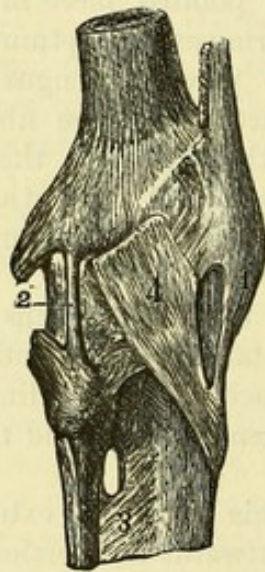
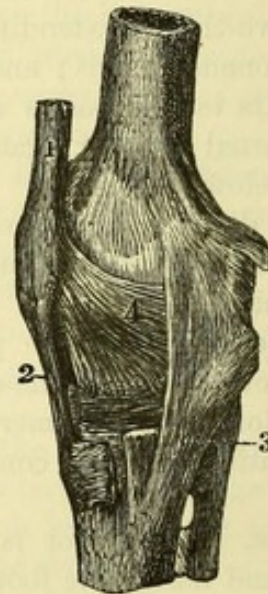


Fig. 213.†



with the internal lateral ligament. It is separated from the synovial membrane by the anterior ligament and by fat.

The external
ligaments.

To define
the liga-
ments
how to
proceed.

Dissection. Four external ligaments, anterior and posterior, internal and external lateral, are situate at opposite parts of the articulation. The posterior and the internal lateral ligaments will appear on the removal of the areolar tissue from their surfaces; but the anterior and the external lateral are covered by the aponeurosis on the front of the joint, and will not be laid bare till this has been cut through. If there is a second external lateral band present, it is not concealed by the aponeurosis.

External
lateral liga-
ment is
small :

The *external lateral ligament* (fig. 212, ²) is round and cord-like. It is attached to the tuberosity of the outer condyle of the femur, below the tendon of the gastrocnemius, and descends vertically between two pieces of the tendon of the biceps to a depression on the

* External aspect of the knee-joint (Bourcery). 1. Anterior ligament. 2. External lateral ligament. 3. Interosseous membrane. 4. Part of the capsule.

† Internal aspect of the knee-joint (Bourcery). 1. Tendon of the extensor muscle, ending below in the ligament of the patella, 2. 3. Internal lateral ligament. 4. Inner part of the capsule.

upper and outer part of the head of the fibula. Beneath the ligament are the tendon of the popliteus, and the external lower articular vessels and nerve.

A second fasciculus is sometimes present behind the other, but it is not attached to the femur; it is connected above with the gastrocnemius, and below with the styloid process of the head of the fibula. occasional band.

The *tendon of the biceps* is inserted by two pieces into the head of the fibula; and from both of these, fibres are prolonged to the head of the tibia. The external lateral ligament passes between the pieces into which the tendon is split. Tendon of the biceps is divided.

The *tendon of the popliteus* may be followed by dividing the posterior ligament. It arises from the fore part of the oblong depression on the outer surface of the external condyle of the femur. In its course to the outside of the joint, it crosses the external semilunar fibro-cartilage and the upper tibio-peroneal articulation. When the joint is bent, the tendon lies in the hollow on the condyle; but it slips out of that groove when the limb is extended. Tendon of the popliteus,

The *tendon of the adductor magnus* is inserted into the adductor tubercle on the internal condyle of the femur, above the attachment of the internal lateral ligament. and of adductor magnus.

The *internal lateral ligament* (fig. 213, ³) is attached above to the condyle of the femur, where it blends with the capsule; but becoming thicker below, and separate from the rest of the capsule, it is fixed for about an inch into the inner surface of the tibia, below the level of the ligamentum patellæ: some of the deeper fibres join the internal semilunar fibro-cartilage. Internal lateral ligament: attachments;

The tendons of the sartorius, gracilis, and semitendinosus muscles lie over the ligament; and the tendon of the semimembranosus, and the internal lower articular vessels and nerve are beneath it. To the posterior edge some fibres from the tendon of the semimembranosus are added. is joined by semimembranosus.

The *tendon of the semimembranosus muscle* is inserted beneath the internal lateral ligament into the lower part of the groove at the back of the inner tuberosity of the tibia: between it and the upper edge of the groove is a synovial bursa. The tendon sends a few fibres to the internal lateral ligament, a prolongation to join the fascia on the popliteus muscle, and another to the posterior ligament of the knee-joint. Insertion of the semimembranosus.

The *posterior ligament* is wide and membranous, and is formed in great part by a strong slip from the tendon of the semimembranosus, which is directed across the joint to the outer side. It is fixed below to the head of the tibia behind the articular surface; and above, it is attached to the femur at the upper border of the intercondylar notch in the centre, but on each side it joins the tendinous head of the gastrocnemius. Numerous apertures exist in it for the passage of the vessels and nerves to the interior of the articulation; and the tendon of the popliteus pierces its outer part. Posterior ligament.

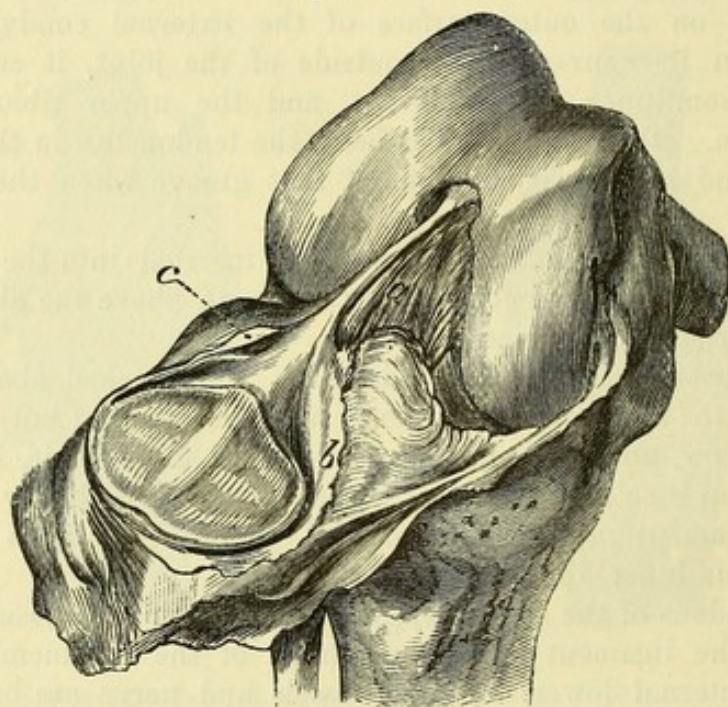
Anterior
ligament
is tendon
of the
extensor.

Open the
knee-joint
in front

The *anterior ligament* or *ligamentum patellæ* (fig. 213, ²) is part of the tendon of insertion of the extensor muscle of the knee (p. 620). About two inches long, it is attached above to the apex and lower border of the patella; and below to the tubercle of the tibia. An expansion of the triceps extensor covers it; and a bursa intervenes between it and the front of the tibia above the tubercle.

Dissection (fig. 214). To see the reflections of the synovial membrane, raise the knee on blocks, and open the joint by an incision on each side, above the patella. When the anterior portion of the capsule with the patella is thrown down, a fold (mucous ligament)

Fig. 214.*



will be seen extending from the intercondylar fossa of the femur to a mass of fat below the patella. On each side of the knee-pan is another fold (alar ligament) over some fat.

The limb may be laid flat on the table, and some of the posterior ligament removed, to show the pouches of the synovial membrane which project behind over the condyles of the femur; but the limb is to be replaced in the former position before the parts are learnt.

Synovial
membrane

The *synovial membrane* (fig. 214) lines the interior of the joint, and is continued to the margins of the articular surfaces of the bones. It invests the interarticular fibro-cartilages after the manner of serous membranes, and sends a pouch between the tendon of the popliteus and the external fibro-cartilage and the head of the tibia; it is also reflected over the strong crucial ligaments at the back of the joint.

* The capsule of the knee-joint cut across, and the patella thrown down, to show the named folds of the synovial sac. *a.* Mucous ligament. *b.* Internal, and *c.* External alar ligament.

There are three named folds of the synovial membrane. One in the centre of the joint is the *mucous ligament* (*a*), which contains small vessels and some fat, and extends from the interval between the condyles to the fat below the patella. Below and on each side of the patella is another fold—*alar ligament* (*b* and *c*), which is continuous with the former below the patella, and is placed over a mass of fat: the inner (*b*) is prolonged farther than the outer by a semi-lunar piece of the synovial membrane.

At the back and front of the articulation pouches are prolonged beneath the tendons of muscles. Behind there are two, one on each side, between the condyle of the femur and the tendinous head of the gastrocnemius. On the front, the sac projects under the extensor muscle one inch above the articular surface; and if it communicates with the bursa in that situation, it will reach two inches above the joint-surface of the femur. When the joint is bent there is a greater length of the serous sac above the patella.

Fat around the joint. Two large masses are placed above and below the patella, and a smaller quantity of fat surrounds the crucial ligaments.

The infrapatellar mass, the largest of all, fills the interval between the patella with its ligament and the head of the tibia, and gives origin to the ridges of the synovial membrane. From it a piece is continued round the patella; but it is larger at the inner margin than at the outer, and overhangs the inner perpendicular facet of that bone. This infrapatellar pad adapts itself to the varying shape and extent of the angular interspace between the bones and the ligamentum patellæ in the movements of the joint.

The suprapatellar pad is interposed between the common extensor tendon and the femur round the top of the synovial sac, and is larger on the outer than the inner side.

Dissection (fig. 215). The ligamentous structures within the capsule will be brought into view, while the limb is still in the same position, by throwing down the patella and its ligament, and clearing away the fat behind it. In this step the student must be careful of a small transverse band which connects anteriorly the interarticular fibro-cartilages.

The remains of the capsule and other ligaments, and the synovial membrane, are next to be cleared away from the front and back of the crucial ligaments, and from the fibro-cartilages. While cleaning the posterior crucial ligament, the limb is to be placed flat on the table with the patella down; and the student is to be careful of a band in front of it from the external fibro-cartilage, or of two bands, one before and the other behind it.

Ligaments within the capsule. The ligamentous structures within the capsule consist of the central crucial ligaments, and of two plates of fibro-cartilage on the head of the tibia.

The *crucial ligaments* (fig. 215) are two strong fibrous cords between the ends of the tibia and femur, which maintain the bones in contact. They cross one another like the legs of the letter X, and have received their name from that circumstance.

thrown into
folds named
ligaments,—
mucous,

and alar.

Pouches:

two behind,

and one
before.

Articular
fat:

below the
patella;

use;

above the
patella.

Dissect
internal
ligaments.

Ligaments
within the
capsule.

Two crucial
ligaments.

One is much anterior to the other at the attachment of the tibia.

Anterior is oblique ;
its attach-
ments.

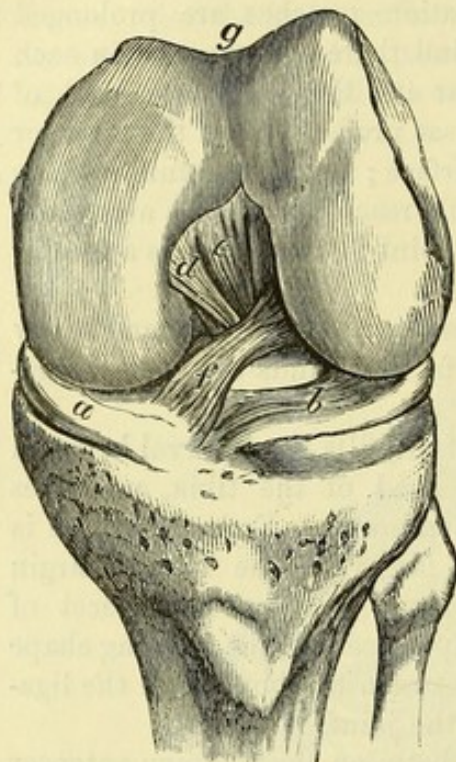
The *anterior ligament* (*f*) is very oblique in its direction, and is longer than the posterior. Inferiorly it is attached in front of the spine of the tibia, close to the inner articular surface, reaching back to the inner point of the spine ; superiorly it is inserted into an

impression on the hinder part of the inner surface of the external condyle of the femur.

Fig. 215.*

Posterior is vertical ;

its attach-
ments.



Their use.

Both unite
the bones.

Rotation in
checked by
anterior.

Special use
of anterior,

and poste-
rior crucial.

The *posterior ligament* (*e*), the thicker of the two, is almost vertical between the bones at the back of the joint. By the lower end it is fixed to the hindmost impression of the hollow behind the spine of the tibia, near the margin of the bone ; and above, it is inserted into a mark occupying the lower part of the outer surface of the internal condyle, and extending forwards to the centre of the intercondylar fossa.

The *use* of these ligaments in the movements of the joint may now be studied after the external ligaments have been cut through.

As long as both ligaments are whole the bones cannot be separated from each other.

Rotation in of the tibia is stopped by the anterior crucial. Rotation out is not checked by either ligament ; for the bands uncross in the execution of the movement, and will permit the tibia to be turned hind part foremost.

Supposing the tibia to move as in straightening the limb, the anterior prevents that bone being carried too far forwards by the extensor muscle, or by external force ; and the ligament is brought into action at the end of extension, because the tibia is being put in front of the femur. Its use is shown by cutting it across, and leaving the posterior entire, as then the tibial articulating surfaces can be placed in front of the femoral in the half-bent state of the joint.

The posterior crucial arrests the too great movement backwards of the tibia by the flexors or by force ; and it is stretched in extreme flexion, in which the tibia is being drawn back from the femur. This use will be exemplified by cutting across the posterior (in

* Interarticular ligaments of the knee-joint. *a*. Internal, and *b*, external semilunar fibro-cartilage ; the latter rather displaced by the bending of the joint. *e*. Posterior crucial ligament, with *d*, the ascending ligamentous band of the external fibro-cartilage. *f*. Anterior crucial ligament. *g*. Patellar surface of the femur.

another joint or in another dissection) and leaving entire the anterior; when this has been done, the articular surfaces of the tibia can be carried nearly altogether behind the condyles of the femur.

The two *interarticular* or *semilunar fibro-cartilages* (fig. 216) partly cover on each side the articular surface of the tibia.

They are thick at the convex margin, where they are united by fibres to the capsule, and are thin, sharp, and free at the concave edge; they are hollowed on the upper surface, so as to assist in giving depth to the fossæ for the reception of the condyles of the femur, but are flattened below. Inserted into the tibia at their extremities, they are coarsely fibrous at their attachment to the bone, like the crucial ligaments; and they become cartilaginous only where they lie between the articular surfaces. The synovial membrane is reflected over them.

The *internal fibro-cartilage* (a) is ovoid in form, and is less sharply curved than the external. In front it is attached by a pointed end close to the anterior margin of the head of the tibia, in front of the anterior crucial ligament. At the back, where it is much wider, it is fixed to the inner lip of the hollow behind the spine of the tibia, between the attachment of the other cartilage and the posterior crucial ligament.

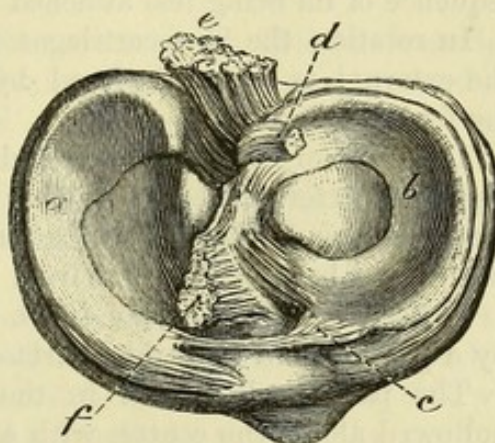
The *external fibro-cartilage* (b) is nearly circular in form, and is connected to the bone within the points of attachment of its fellow. Its anterior part is fixed in front of the spine of the tibia, close to the outer articular surface, and opposite the anterior crucial ligament which it touches; and its posterior extremity is inserted behind and between the two osseous points of the spine. This fibro-cartilage is less closely united to the capsule than the internal, for the fore part is in the centre of the joint, and the tendon of the popliteus muscle separates it behind from that membrane.

The outer fibro-cartilage is provided with two accessory bands, one in front, the other behind.

The *anterior* or *transverse ligament* (c) is a narrow band of fibres between the semilunar cartilages at the front of the joint. Sometimes it is very small or even absent.

The *posterior* or *ascending band* (d), thicker and stronger than the other, springs from the back of the outer fibro-cartilage, and is inserted into the femur, as a single band (fig. 216, d), when it is

Fig. 216.*



Internal is ovoid.

External nearly circular in form:

its transverse and

posterior band.

* View of the head of the tibia with the fibro-cartilages attached: the crucial ligaments have been cut through. a. Inner, and b, outer semilunar fibro-cartilage. c. Transverse, and d, ascending or posterior band (cut) of the external cartilage. e. Posterior, and f, anterior crucial ligament.

generally in front of the posterior crucial, or as two bands—one being before, and the other behind that ligament.

Use of fibro-cartilages,

Use. The fibro-cartilages deepen the sockets of the tibia for the reception of the condyles of the femur, and fill the interval between the articular surfaces of the bones at the circumference of the joint; they distribute the pressure of one bone on the other over a larger surface, and cause the force of shocks to be diminished in transmission.

in flexion and extension,

In flexion and extension they move forwards and backwards with the tibia. During flexion they recede somewhat from the fore part of the joint, and surround the narrow parts of the condyles of the femur; but in extension they are flattened out on the surface of the tibia. Of the two cartilages, the external moves the most in consequence of its being less attached to the capsule.

and in rotation:

In rotation the fibro-cartilages follow the tibial movements, but the external is most displaced by the projecting outer condyle of the femur.

use of accessory bands.

The accessory bands in front and behind serve to retain in place the less fixed external fibro-cartilage; thus the anterior ligament keeps forwards the front of that cartilage in flexion, and the posterior secures the back of the same from displacement in rotation.

Surfaces of bone.

Articular surfaces of the bones. The end of the femur is marked by a patellar and two tibial surfaces.

On femur, patellar

The patellar is placed in the middle above the others; it is hollowed along the centre, with a slanting surface on each side, the outer being much the larger of the two.

and tibial: characters of tibial;

The surfaces for contact with the tibia, two in number, occupy the ends of the condyles, and are separated from the patellar impression by an oblique groove on each side. At the lower part of each is a somewhat flattened surface, which is in contact with the tibia in standing; while behind there is a more convex portion, which touches the tibia in flexion.

peculiarities of inner.

The inner condyle of the femur is curved at its anterior third, the concavity being directed out: this has been named the "oblique curvature." At the outer margin of the curve is a semilunar facet, which touches the perpendicular surface of the patella in extreme flexion.

Articular surfaces of tibia.

On the head of the tibia are two slight articular hollows, the inner being the deeper and larger, which rise towards the middle of the bone, on the points of the tibial spine.

Subdivision of joint-surface of patella.

The joint-surface of the patella is marked by the following impressions. Close to the inner edge is a narrow perpendicular facet, and along the lower border is a similar transverse mark. Occupying the rest of the bone is a squarish surface, which is subdivided by a vertical and a transverse line into two pairs of marks—upper and lower. (Goodsir.)

Kinds of movement.

Movements of the joint. The chief movements of the knee are two in number, bending and straightening, like the elbow; but there is, in addition, rotation of the tibia when the joint is bent.

Flexion and extension. Each of these movements may be divided into stages for the purpose of indicating changes in its direction.

In *flexion*, the tibia with its fibro-cartilages moves backwards round the end of the femur; and the motion is limited by the extensor muscle, and by the meeting of the calf of the leg with the thigh.

Flexion :
movement
of tibia ;

For the anterior third of the movement the tibia is directed backwards and inwards along the oblique curve of the inner condyle, giving rise to an inward rotation of that bone; but for the posterior two-thirds, the tibia passes straight back and up over both condyles.

change in
direction ;

All the external ligaments are relaxed, except the anterior; and the same is the case with the anterior crucial: the posterior crucial ligament is put forcibly on the stretch towards the end of flexion.

state of
ligaments.

In *extension*, the tibia is carried forwards until it passes slightly beyond the line of the femur, when the uniting ligaments prevent its farther progress.

Extension
movement
of tibia ;

In the hinder two-thirds of the movement the tibia has a straight course over the condyles of the femur; but in the anterior third the leg-bone is directed forwards and outwards over the oblique curve of the inner condyle, and is rotated out.

course
changes ;

The posterior and lateral ligaments, together with the whole of the anterior crucial ligament, are rendered tense and set a limit to the movement.

state of
the liga-
ments.

Rotation. A half-bent state of the knee is necessary for this movement, for the purpose of relaxing the anterior crucial and the lateral ligaments; and the foot must be free. Then, the tibia with its fibro-cartilages rotates around a longitudinal axis, the great toe being turned in and out.

Two kinds
of rotation.

During *rotation in*, the inner articular surface of the tibia moves but little beneath the inner condyle of the femur; but the outer articular surface, with its fibro-cartilage, glides forwards under the external condyle.

Rotation in ;
movement
of tibia ;

Both lateral ligaments are loose; but the anterior crucial is gradually tightened, and finally stops the motion.

state of
ligaments.

In *rotation out* the opposite movement of the tibia takes place,—the outer articular surface being directed backwards.

Rotation
out ;

The internal lateral ligament is gradually tightened, and controls the movement: the crucials have not any influence on it (p. 696).

state of
ligaments.

Movement of the patella. When the knee passes from flexion to extension, the patella travels upwards and slightly inwards over the lower end of the femur, touching in succession different parts of the femoral articular surfaces.

Movement
of patella :

In complete flexion, the knee-pan lies on the outer side of the joint below the femur, where it is scarcely perceptible, and is fixed in its situation. It touches the semilunar surface on the inner condyle by its perpendicular facet; and the under part of the outer condyle by the upper and outer mark on its square surface.

in flexion,
where it
touches ;

When the joint is passing from flexion to extension, the upper pair of impressions on the square surface of the patella, and the lower pair rest successively on the trochlear surface of the femur.

while
straighten-
ing ;

In complete extension, the patella is situate at the upper part of the knee-joint, where it is very prominent, with its apex and the ligament of the patella directed down and out to the tibia. For the

in exten-
sion,

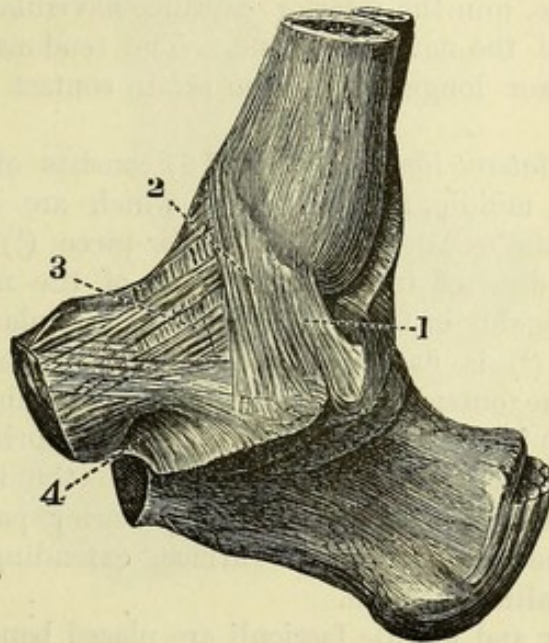
position to femur.	most part the knee-pan articular surface is raised above the trochlea of the femur, which it touches only at the upper edge by its lower transverse facet.
Articulation of tibia and fibula.	PERONEO-TIBIAL ARTICULATIONS. The tibia and fibula are united by ligamentous bands at the extremities where they touch, and by an interosseous membrane between the shafts of the bones.
Dissection of the ligaments.	<i>Dissection.</i> The muscles are to be taken away from the front and back of the interosseous membrane; and the loose tissue is to be removed from a small band in front of, and behind, the upper and lower ends of the tibia and fibula.
Upper articulation,	The UPPER ARTICULATION has very slight movement, and the structures between the ends of the bones are two small bands, anterior and posterior.
by anterior and posterior band.	The <i>anterior ligament</i> extends over the joint from the outer tuberosity of the tibia to the head of the fibula. The <i>posterior ligament</i> , thinner than the anterior, is attached to the bones behind the joint: it is covered by the tendon of the popliteus muscle and a prolongation of the synovial membrane of the knee-joint.
Synovial sac.	The articular surfaces are covered with cartilage; and the <i>synovial cavity</i> of the articulation is only separated by the thin posterior ligament from that of the knee-joint.
Lower articulation has	The LOWER ARTICULATION possesses anterior, posterior, and inferior bands, together with an interosseous ligament (inferior) between the ends of the bones.
anterior, posterior,	The <i>anterior ligament</i> reaches obliquely from the lower end of the tibia to the fibula; and the <i>posterior</i> has attachments behind the articulation similar to those of the band in front.
inferior,	The <i>inferior ligament</i> closes the notch at the back between the contiguous ends of the tibia and fibula, and consists of transverse yellowish fibres distinct from the posterior ligament. It is fixed on one side to the end of the fibula above the pit; and on the other it is inserted into the contiguous part of the tibia, and into the posterior edge of the articular surface, so as to assist in deepening the hollow into which the astragalus is received. This band cannot be seen until the astragalus has been disarticulated after the examination of the ankle-joint.
and interosseous ligaments.	The <i>inferior interosseous ligament</i> consists of strong bundles of fibres passing obliquely downwards and outwards between the adjacent rough surfaces at the lower ends of the two bones. This also may be seen after the dissection of the ankle-joint, by sawing longitudinally the ends of the leg-bones.
Interosseous membrane between the shafts:	The INTEROSSEOUS MEMBRANE fills the interval between the bones of the leg, and serves as an aponeurotic partition between the muscles on the front and back of the limb. Its fibres are directed for the most part downwards from the tibia to the fibula; but a few cross in the opposite direction.
attachments;	Internally it is fixed to the outer edge of the tibia; and externally, to the prominent interosseous ridge on the inner side of the fibula.
apertures.	In its upper part, close to the neck of the fibula, is an oval opening about an inch in length, which transmits the anterior tibial vessels;

and at the lower end, between the membrane and the inferior articulation, is another small opening for the anterior peroneal vessels.

Movement. Very little movement is allowed in the tibio-peroneal articulations, as the chief use of the fibula is to give strength and elasticity to the ankle-joint, and attachment to muscles of the leg. Motion slight,

In the upper joint there is a slight gliding chiefly from within out. In the lower articulation the ligaments permit some yielding of the fibula to the pressure of the astragalus, as when the weight of the body is thrown on the inner side of the foot; but if the force is violent, that bone will be fractured about the junction of the third and lowest fourths sooner than the ligaments give way. in upper, and lower articulation.

Fig. 217.*



ARTICULATION OF THE ANKLE (fig. 217). The ankle is a hinge or ginglymoid joint, in which the upper part of the astragalus is received into an arch formed by the lower ends of the tibia and fibula; and the four ligaments belonging to this kind of articulation connect together the bones. Bones in the ankle-joint.

Dissection. To make the dissection required for the ligaments of the ankle-joint, the muscles, and the fibrous tissue and vessels must be removed from the front and back of the articulation. Dissection of the ankle-joint.

For the purpose of defining the lateral ligaments, the limb must be placed first on one side and then on the other. The internal ligament is wide and strong, and lies beneath the tendon of the tibialis posticus. The external is divided into three separate pieces; and to show these, the peronei muscles, and the remains of the annular ligament below the outer malleolus, should be taken away.

* Internal lateral ligament of the ankle (altered from Bourguery). 1. Posterior, 2. Middle, and 3. Anterior fibres of the inner ligament. 4. Inferior calcaneo-navicular ligament.

Anterior
ligament is
thin and
imperfect.

The *anterior ligament* is a thin fibrous membrane, which is attached to the tibia close to the articular surface; and to the upper part of the astragalus near the articulation with the navicular bone. In the ligament are some rounded intervals and apertures for vessels. On the sides it joins the lateral ligaments.

Posterior
ligament.

The *posterior ligament* is thinner than the anterior, and is attached to the tibia and astragalus, close to the articular surfaces of the bones. Towards the outer side it consists of transverse fibres, which are fixed into the hollow on the inner side of the external malleolus.

Internal or
deltoid :
attach-
ments.

The *internal lateral or deltoid ligament* (fig. 217) is attached by its upper, smaller end to the inner malleolus, and by its base to the tarsal bones, by fibres which radiate to their insertion in this manner :—The posterior (¹) are directed to the hinder part of the inner surface of the astragalus; the middle (²) pass vertically to the sustentaculum tali of the os calcis; and the anterior (³), which are thin and oblique, join the inferior calcaneo-navicular ligament and the inner side of the navicular bone. The tendons of the tibialis posticus and flexor longus digitorum are in contact with this ligament.

External
has three
pieces ;
anterior,

The *external lateral ligament* (fig. 218) consists of three separate pieces, anterior, middle, and posterior, which are attached to the astragalus and the os calcis. The *anterior* piece (¹) is a short flat band, which is directed from the fore part of the malleolus to the side of the astragalus in front of the lateral articular surface. The *middle* portion (²) is flattened, and descends from the tip of the malleolus to the outer surface of the os calcis, about the middle. The *posterior* (³) is the strongest, and is almost horizontal in direction; it is connected externally to the pit on the inner surface of the malleolus, and is inserted into the posterior part of the astragalus behind the upper articular surface, extending to the groove for the flexor hallucis tendon.

middle,

and pos-
terior ;

relations.

The posterior and middle fasciculi are placed beneath the peronei muscles. The middle piece is but slightly in contact above with the synovial membrane of the ankle-joint; and both it and the posterior piece touch the synovial membrane between the astragalus and the os calcis.

Open the
ankle joint.

Dissection. Dividing the ligaments of the ankle-joint, separate the astragalus from the bones of the leg, to see the osseous surfaces entering into the joint.

Synovial
sac.

The *synovial membrane* of the joint lines the capsule, and is simple in its arrangement; but the cavity is continued upwards for a short distance between the tibia and fibula.

Surfaces of
the bones
in the joint.

Articular surfaces. On the tibia there are two articular surfaces, one of which corresponds with the end of the shaft, and the other with the malleolus. On the fibula the surface of the malleolus which is turned to the astragalus is covered with cartilage.

The astragalus has a central articular surface, wider before than behind and trochlea-shaped, which touches the end of the tibia; and on its sides are articular impressions for contact with the malleoli, but the outer one is the larger.

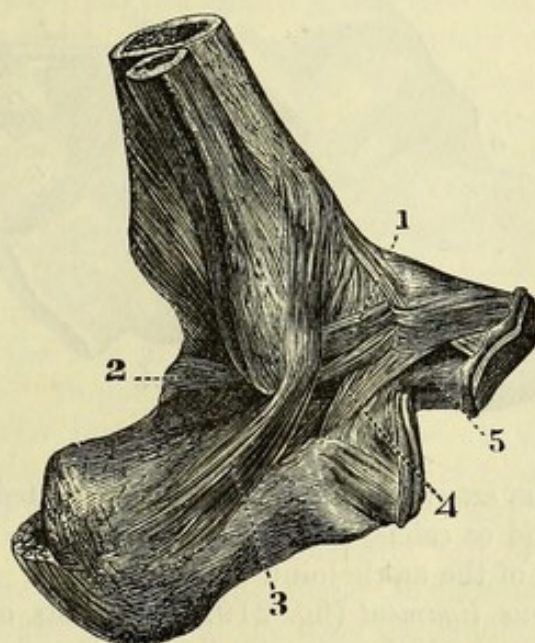
Movements. Only the movements of flexion and extension are permitted in the ankle; in the former state the toes are raised towards the fore part of the leg; and in the latter, they are pointed towards the ground. Kinds of motion.

In *flexion* the astragalus moves backwards so as to project behind; and the motion is arrested by the wide part of the astragalus being wedged in between the malleoli. Flexion :
moving bone;

The posterior ligament is stretched over the projecting astragalus, and the posterior and middle pieces of the external lateral, and the posterior part of the internal lateral ligament, are made tense. state of ligaments.

In *extension* the astragalus moves forwards over the end of the tibia, and projects anteriorly. Extension :

Fig. 218. *



tibia, and projects anteriorly. A limit to the movement is imposed by the meeting of the astragalus with the tibia behind. moving bone;

The lateral ligaments are partly made tight as in flexion, for instance, the anterior piece of the external, and the fore and middle portions of the internal. state of ligaments ;

When the joint is half extended, so that the small hinder part of the astragalus is brought into the arch of the leg-bones, a slight movement of the foot inwards and outwards may sometimes be obtained; but if the foot is forcibly extended, the portions of the lateral ligaments attached to the astragalus prevent this lateral movement by their tightness. slight lateral motion.

Dissection. The joints of the foot will be demonstrated by removing from both the dorsum and the sole all the soft parts which have been examined. Between the different tarsal bones bands of Dissection for the joints of the foot.

* External lateral ligament of the ankle (altered from Bourguery). 1. Anterior part, 2. Posterior part, and 3. Middle part of the outer ligament. 4. Interosseous of astragalus and os calcis. 5. External calcaneo-navicular ligament.

ligament extend, which will be defined by removing the areolar tissue from the intervals between them (fig. 219).

It will be more advantageous for the student to clean all the ligaments before he proceeds to learn any, than to prepare only the bands of one articulation at a time.

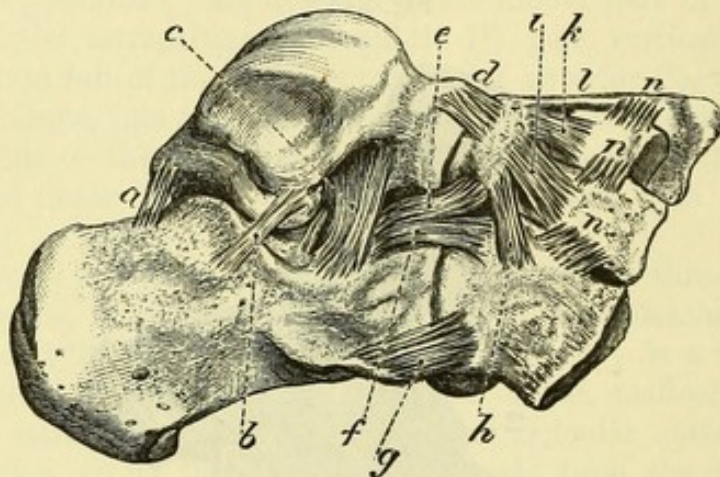
Astragalus
with os
calcis by

posterior,

ARTICULATION OF THE ASTRAGALUS AND OS CALCIS. These bones form two joints, and are kept together by a strong interosseous ligament; there are also thin bands at the outer side and behind.

The *posterior ligament* (fig. 219, *a*) consists of a few fibres between the bones, where they are grooved by the tendon of the flexor

Fig. 219.*



external,

hallucis; and the *external ligament* (*b*) is connected to the sides of the astragalus and os calcis, near the middle piece of the external lateral ligament of the ankle-joint.

and interos-
seous liga-
ments.

The *interosseous ligament* (fig. 219, *c*) consists of strong vertical and oblique fibres, which are attached above and below to the depressions on the contiguous surfaces of the two bones. This band extends across the bones, and its depth is greatest at the outer side.

Articular
surfaces;
synovial
cavities.

In a subsequent stage of the dissection (p. 707) the articular surfaces of the bones will be seen, viz., one behind the interosseous ligament, and one in front of it, with two *synovial cavities*.

Movement
between as-
tragalus and
os calcis:
axis of
motion.

Movements. It is between the astragalus and os calcis that the important movements of the foot known as inversion and eversion chiefly take place. The motion is one of rotation about an oblique axis, which is directed from the upper and inner part of the head of the astragalus, backwards, downwards, and outwards to the lower and outer part of the posterior extremity of the os calcis. Supposing the astragalus fixed between the malleoli, and the rest of the

* View of the dorsal ligaments of the tarsus. *a*. Posterior, *b*, external, and *c*, interosseous ligaments between astragalus and os calcis. *d*. Astragalo-navicular. *e*. External calcaneo-navicular. *f*. Internal, and *g*, upper calcaneo-cuboid ligaments. *h*. Dorsal naviculo-cuboid band. *i*, *k*, *l*. Dorsal external, middle, and internal naviculo-cuneiform longitudinal bands. *n*. Dorsal transverse bands between the cuneiform and cuboid bones.

foot free to move, then in *inversion* the outer part of the os calcis moves forwards and downwards, and the sustentaculum tali in the opposite direction, while the anterior end of the bone is carried somewhat inwards. As a result of this, aided by corresponding movements of the anterior tarsal bones, the fore part of the foot is depressed, and the arch increased; the toes are moved inwards; and the outer border of the foot sinks, turning the sole in.

In *eversion* the above movements are reversed.

In the ordinary mode of standing the foot is everted to the utmost, or nearly so, by the weight of the body; if then inversion is practised, the inner side of the foot is raised from the ground, and the part is supported on its outer edge.

ASTRAGALUS WITH THE NAVICULAR BONE. The head of the astragalus is received into the hollow of the navicular bone, and is united to it by a dorsal ligament; but the place of plantar and external lateral ligaments is supplied by strong bands between the os calcis and the navicular bone, which will be noticed below.

The *astragalo-navicular ligament* (fig. 219, *d*) is attached to the astragalus close to the articulation, and to the dorsal surface of the navicular bone: its attachments will be better seen when it is cut through.

Dissection. The external ligament of the articulation may be seen on the dorsum of the foot in the hollow between the os calcis and the navicular bone. Supposing the tendon of the tibialis posticus removed, the inferior ligament will be defined in the sole of the foot by cutting some fibro-cartilaginous substance from it.

The *inferior calcaneo-navicular ligament* (fig. 221, *c*) is attached behind to the fore part of the sustentaculum tali of the os calcis, and in front, to the hollow on the under surface of the navicular bone. In the upright posture of the body the tendon of the tibialis posticus is beneath it in the sole of the foot; and on it the head of the astragalus rests.

The *external calcaneo-navicular ligament* (fig. 219, *e*) is placed outside the head of the astragalus, and serves as a lateral ligament to the astragalo-navicular articulation: it is about three-quarters of an inch deep. Behind, it is fixed to the upper part of the os calcis, between the articular surfaces for the cuboid bone and astragalus; and in front it is inserted into the outer side of the navicular bone.

The *synovial cavity* of this articulation is continued backwards into the joint between the front of the os calcis and the astragalus.

Articular surfaces. The head of the astragalus has two articular faces; a smaller, below, for the os calcis; and a larger one, elongated transversely and broader externally than internally, for the navicular bone. The surface of the navicular bone is hollowed, and is widest externally.

Movement. The navicular moves down and in over the head of the astragalus in inversion, or up and out in eversion.

As the bone is forced downwards, the upper and external ligaments of the joint are made tight; and when the navicular is moved in the opposite way, the strong inferior ligament is put on the stretch.

Inversion.

Eversion.

Condition of
foot in
standing;
effect of
inversion.Astragalus
with
navicular
bone:dorsal
ligament.To lay bare
the other
ligaments.Inferior
andexternal
ligament.Synovial
sac.Surfaces of
bone.

Movement:

state of
ligamen

Os calcis
with cuboid
bone, by
dorsal,

THE OS CALCIS WITH THE CUBOID BONE. The ligaments in this articulation are plantar, dorsal, and internal.

The *dorsal* or *superior calcaneo-cuboid ligament* (fig. 219, *g*) is a rather thin fasciculus of fibres, which is attached near to the contiguous ends of the os calcis and the cuboid bone; it is sometimes divided into two pieces, or it may be situate at the outer border of the foot.

internal,

At the inner side of the cuboid bone is a stronger *internal band* (fig. 219, *f*) from the os calcis; this is fixed behind to the upper

Fig. 220.*

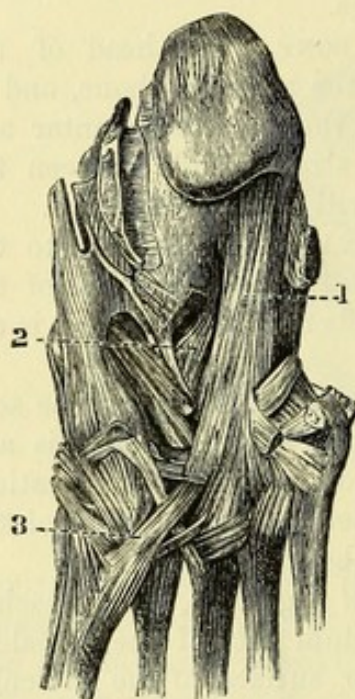
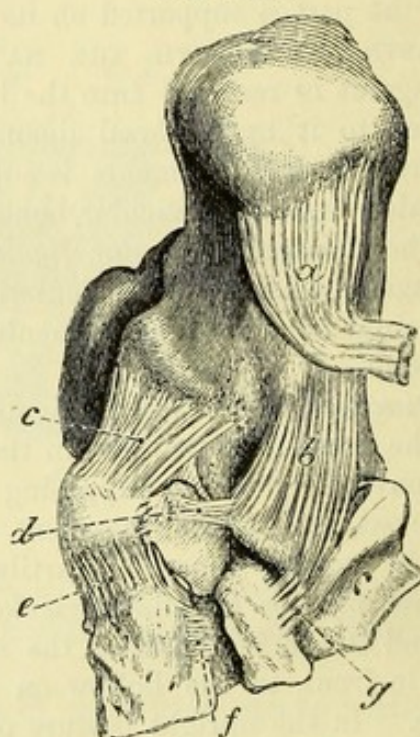


Fig. 221.†



part of the os calcis, external to the band to the navicular bone, and in front to the contiguous inner side of the cuboid.

and inferior
ligaments.

The *inferior calcaneo-cuboid ligament* is much the strongest, and is divided into a superficial and a deep part:—

The last is
strongest,
and divided
into two
parts:
superficial
and

The superficial portion, *long plantar ligament* (fig. 220, *1*), is attached to the under surface of the os calcis from near the posterior to the anterior tubercle; its fibres pass forwards to be connected with the ridge on the under surface of the cuboid bone; but the most internal are continued over the tendon of the peroneus longus muscle, assisting to form its sheath, and are inserted into the bases of the third and fourth metatarsal bones.

* Plantar ligaments of the foot (Bourguery). 1. Long plantar ligament. 2. Inner part of the short plantar ligament. 3. Tendon of the peroneus longus muscle.

† View of the inferior ligaments of the tarsal bones. *a*. Long plantar, cut. *b*. Short or deep inferior calcaneo-cuboid ligament. *c*. Inferior calcaneo-navicular. *d*. Plantar transverse naviculo-cuboid ligament. *e*. Dorsal inner naviculo-cuneiform extending into the sole of the foot. *f*. Plantar transverse ligament between the inner and middle cuneiform bones. *g*. Plantar transverse band between the cuboid and outer cuneiform.

The deep piece, *short plantar ligament* (fig. 221, *b*), seen on deep band. division of the superficial (*a*), extends from the tubercle and the hollow on the fore part of the under surface of the os calcis, to the cuboid bone internal or posterior to the ridge.

The *synovial cavity* of the articulation is simple.

Synovial
sac.

Articular surfaces. Both bones are flattened towards the outer part of the articulation; but at the inner side the os calcis is hollowed transversely, and the cuboid bone is convex to fit into it.

Surfaces of
bones.

Movement. In this joint the cuboid bone may move in two directions, viz., obliquely down and in with inversion of the foot, and up and out with eversion.

Movement:

In the downward movement the internal lateral and the upper ligament are made tight; and in the upward, the calcaneo-cuboid ligaments of the sole are stretched.

state of
ligaments.

TRANSVERSE TARSAL ARTICULATION. This name is given to the line of articulation crossing the foot between the astragalus and os calcis behind and the navicular and cuboid bones in front: it will be noticed, however, that it is not a continuous joint, but is composed of two separate articulations, viz., the astragalo-navicular and the calcaneo-cuboid.

Transverse
tarsal arti-
culation

includes
two joints:

These joints participate, as has been already seen, in the movements of inversion and eversion, the anterior bones moving over the hinder ones, downwards and inwards in inversion, and upwards and outwards in eversion. It is at this line that the foot is divided in the operation known as Chopart's amputation.

movements:

amputation
practised
here.

Dissection. Saw through the astragalus in front of the attachment of the interosseous ligament between it and the os calcis, and remove the head of the bone for the purpose of observing the lower and outer calcaneo-navicular ligaments.

Dissection.

Then the interosseous ligament uniting the astragalus and the os calcis is to be cut through, to demonstrate its attachments, the articular surfaces of the bones, and the synovial sacs (p. 704).

Articular surfaces of the two hinder tarsal bones. There are two articular surfaces, anterior and posterior, to both the astragalus and the os calcis. The hinder one of the os calcis is convex from before back, and the anterior is concave; but sometimes the latter is subdivided into two. The surface of the astragalus will have a form exactly the reverse of that of the os calcis, viz., the hinder one concave and the anterior convex; the anterior is seated on the head of the astragalus.

Surfaces of
os calcis

and astra-
galus.

Dissection. The calcaneo-cuboid joint may be opened to see the articular surfaces; and the student is to keep in mind that all the other articulations of the foot are to be opened for the like purpose, even should directions not be given.

ARTICULATIONS OF THE NAVICULAR BONE. The navicular bone articulates in front with the three cuneiform bones, and laterally with the cuboid.

Union of the
navicular
bone

In the *articulation with the cuneiform bones* (fig. 219) there are three longitudinal *dorsal ligaments* (*i, k, l*), one to each bone; but

to the cunei-
form;

the innermost is the strongest and widest, and extends round the inside of the articulation into the sole of the foot (fig. 221, *e*).

The place of *plantar bands* is supplied by processes of the tendon of the *tibialis posticus*.

synovial
sac :

The naviculo-cuneiform articulations form one continuous joint, and from their synovial cavity offsets are sent forwards between the cuneiform bones.

to the cu-
boid bone :

In the *articulation with the cuboid* there is a *dorsal oblique band* of fibres (fig. 219, *h*) between the contiguous parts of the bones ; a *plantar transverse band* (fig. 221, *d*), which is concealed by the tendon of the *tibialis posticus* ; and a strong *interosseous ligament*.

synovial
sac.

When the bones touch, the surfaces are tipped with cartilage, and a process of the naviculo-cuneiform synovial cavity extends between them.

Union of the
cuneiform
bones

ARTICULATIONS OF THE CUNEIFORM BONES. These bones are united to one another by cross bands ; and the external one articulates with the cuboid after a similar manner.

one with
another,

The three *cuneiform bones* are connected together by short transverse *dorsal bands* (fig. 219, *n*) between the upper surfaces. Similar *plantar ligaments* are wanting, except one between the two innermost (fig. 221, *f*). There are also *interosseous ligaments* between the contiguous surfaces of the bones. Laterally there are *articular surfaces* between the bones, with offsets of the common synovial cavity.

and with
the cuboid
bone :

Where the external cuneiform touches the cuboid bone, the surfaces are covered with cartilage. A *dorsal ligament* (fig. 219, *n*) passes transversely between the two ; and a *plantar ligament* (fig. 221, *g*) takes a similar direction. Between the bones there is also an *interosseous ligament*.

synovial
sac.

This joint is furnished either with a distinct synovial sac, or with a prolongation of the common synovial cavity.

Common
synovial
sac.

The *synovial cavity* of the articulations of the cuneiform bones is common to many of the bones of the tarsus. Placed between the navicular and the three cuneiforms, it sends one prolongation forwards between the inner and middle cuneiform to the joints with the second and third metatarsal bones ; another between the middle and outer cuneiform bones ; a third outwards to the articulation of the navicular with the cuboid bone (when present) ; and sometimes a fourth to the joint between the external cuneiform and the cuboid.

Surfaces of
bones.

Articular surfaces. On the navicular are three articular facets, the inner being rounded, and the other two flattened. The three cuneiforms unite in a shallow elliptical hollow, which is most excavated internally.

Motion in
inversion
and ever-
sion ;

Movement. The cuneiform bones glide up and out on the navicular in inversion of the foot, and down and in in eversion ; and the inner one moves more than the others in consequence of the shape of the articular surfaces, and the attachment to it of the *tibialis anticus*.

state of the
ligaments,

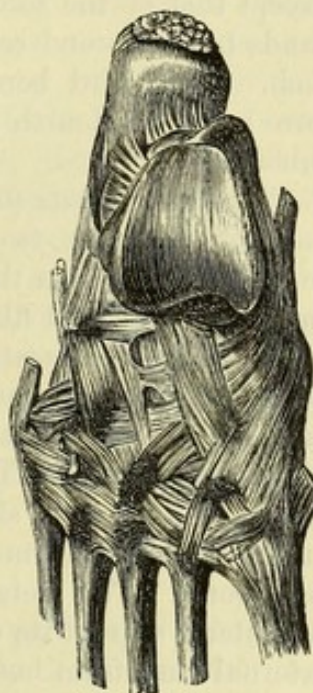
When the bones pass down the dorsal ligaments are made tight ; and as they rise the interosseous and transverse plantar bands will keep them united.

In standing and in progression these bones are separated somewhat from each other with diminution of the arch of the foot, and stretching of the transverse ligaments which connect them. and joints in standing.

ARTICULATION OF THE METATARSAL BONES. The bases of the four outer metatarsal bones are connected together by dorsal, plantar, and interosseous ligaments; and where their lateral parts touch, they are covered with cartilage, and have offsets of a synovial sac. Union of the metatarsus by

The *dorsal ligaments* (fig. 222) are small transverse bands from the base of one metatarsal bone to the next. The *plantar ligaments* (fig. 220) are similar to the dorsal. The *interosseous ligaments* are short transverse fibres between the contiguous rough lateral surfaces: they may be afterwards seen by forcibly separating the bones. dorsal, plantar, and interosseous ligaments.

Fig. 222.*



Lateral union. The four outer bones touch one another laterally; the second metatarsal lies against the internal and external cuneiforms; and the fourth is in contact internally with the outer cuneiform. The articulating surfaces are covered with cartilage; and their synovial cavities are offsets of those serving for the articulation of the same four metatarsal with the tarsal bones.

The metatarsal bone of the great toe, like that of the thumb, is not united to the others at its base by any intervening bands.

The distal ends of the five metatarsal bones are united by the *transverse metatarsal ligament*; this has been described on page 680.

TARSAL WITH METATARSAL BONES. These articulations resemble the like parts in the hand, as there is a separate joint for the great toe, and a common one for the four outer metatarsals. Tarsus and metatarsus.

Articulation of the great toe. The articular ends of the bones are encased by a *capsule*, and are provided with an *upper* and a *lower longitudinal band* to give strength to the joint: the lower band is placed between prolongations from the tendons of the *tibialis anticus* and *peroneus longus*. Joint of great toe separate from rest:

A simple *synovial sac* serves for the articulation. synovial sac.

The *articular surfaces* are oval from above down, curved inwards, and constricted in the middle; that of the metatarsal bone is excavated, and the other is convex. Form of bones.

Movement. There is an oblique movement of the metatarsal bone down and in and up and out, like that of the internal cuneiform with the navicular bone; and this will contribute a little to inversion and eversion of the foot. Motion up and down,

* Dorsal ligaments uniting the tarsus to the metatarsus, and the metatarsal bones to each other behind (Bourguery).

- and lateral motion. The joint possesses likewise slight abductory and adductory movement.
- Joints of four outer toes : *Articulation of the four outer toes.* The three outer tarsal bones of the distal row correspond with four metatarsals,—the middle cuneiform being opposite the second metatarsal bone, the external cuneiform touching the third, and the cuboid carrying the outer two bones. The surfaces in contact are tipped with cartilage, and have longitudinal dorsal, plantar, and lateral ligaments, with some oblique in the sole.
- dorsal ligaments ; The *dorsal ligaments* (fig. 222) are thin bands of fibres, which are more or less longitudinal as they extend from the tarsal to the metatarsal bones. Each metatarsal bone receives one ligament, except that of the second toe, to which there are three,—the three bands to the second coming from all the cuneiform bones, one from each. The third bone obtains a ligament from the external cuneiform ; and the fourth and fifth have a fasciculus to each from the cuboid.
- plantar ligaments ; *Plantar ligaments* (fig. 220). There is one *longitudinal band* from each of the outer two cuneiform to the corresponding metatarsal bone ; but between the cuboid and its metatarsal bones there are only some scattered fibres.
- lateral ligaments ; The *lateral ligaments* are longitudinal ; they lie deeply between the bones, and are connected with the second and third metatarsals : they will be better seen by cutting the transverse bands joining the bases of the bones. To the bone of the second toe there are two bands, one on each side ;—the inner is strong and is attached to the internal cuneiform ; and the outer is fixed to the external cuneiform bone. The metatarsal bone of the third toe is provided with one lateral slip on its outer side, which is inserted behind into the external cuneiform bone.
- oblique plantar. *Oblique plantar ligaments.* A fasciculus of fibres extends across from the front of the internal cuneiform to the second and third metatarsals ; and from the external cuneiform there is another slip to the metatarsal bone of the little toe.
- Line of the articulation across the foot. *Line of the articulation.* The line of the articulation between the tarsus and metatarsus is zigzag, in consequence of the unequal lengths of the cuneiform bones. To open the articulation, the knife should be carried obliquely forwards from the tuberosity of the fifth to the outer side of the second metatarsal bone ; then about two lines farther back for the union of the second metatarsal with the middle cuneiform ; and finally, half an inch in front of the last articulation, for the joint of the internal cuneiform with the first metatarsal bone.
- Two synovial sacs. Two *synovial cavities* are present in these tarso-metatarsal articulations.
- There is one between the cuboid and the two outer metatarsals, which serves also for the adjacent lateral articular surfaces of the latter bones : this is not always separate from the following.
- The second is placed in the joint between the external and middle cuneiforms with their metatarsal bones (third and second), and is

an offset of the common synovial cavity belonging to the articulation of the navicular with the cuneiform bones (p. 708) : prolongations from it extend between the lateral articular faces of the second, third, and fourth (inner side) metatarsals.

Articular surfaces. The osseous surfaces are not flat ; for the metatarsal bones are undulating, and the tarsal are uneven to fit into the others. Form of the bones.

Movement. From the wedge-shaped form of the metatarsal bones, only a slight movement from above down is obtainable ; and this is greatest in the little toe and the next. Motion from above down,

In the little toe there is an abductory and adductory motion ; and a small degree of the same exists in the fourth toe. with abduction and adduction.

Dissection. All the superficial ligaments having been taken away, the interosseous ligaments of the tarsus and metatarsus may be seen by separating forcibly the cuneiform bones from one another and from the cuboid, the latter bone from the navicular, and the bases of the metatarsals from one another. The dissector will find that, in using force, the bones will sometimes tear sooner than the ligaments. Separate the bones to see interosseous ligaments.

METATARSUS WITH PHALANGES. These are condyloid joints, in which the head of the metatarsal bone is received into the cavity of the phalanx. Union of metatarsus and phalanges, by

Each articulation has an *inferior* and two *lateral ligaments*, as in the hand ; and the joint is farther strengthened above by an expansion derived from the tendons of the extensors of the toes. A distinct *synovial sac* exists in each joint. two lateral ligaments, and inferior : synovial sac.

In the articulation of the great toe there are two sesamoid bones, which are connected with the inferior ligament.

All these structures are better seen in the hand, where they are more distinct ; and their anatomy is more fully described with the dissection of that part. (See page 326.)

Surfaces of bone. The metatarsal bone has a rounded head, which is longest from above down, and reaches farthest on the plantar surface. On the end of the phalanx is a cup-shaped cavity. Form of bones.

Movement. In this condyloid joint, as in the hand, there is angular motion in four different directions, with circumduction. Kind of motion.

Flexion and extension. When the joint is bent, the phalanx passes under the head of the metatarsal bone ; and when it is extended, the phalanx moves back beyond a straight line with the metatarsal bone. Bending and extending,

A limit to flexion is set by the meeting of the bones, by the stretching of the upper part of the lateral ligaments, and by the extensor tendon ; and to extension, by the tightness of the inferior, and the lower part of each lateral ligament, and by the flexor tendons. state of ligaments :

Lateral movement. The phalanx passes from side to side across the end of the metatarsal bone. Its motion is checked by the lateral ligament of the side from which it moved, and by the contact with the other digits. lateral motion :

Circumduction, or the revolving of the phalanx over the rounded circular

motion limited. head of the metatarsal bone, is least impeded in the great toe joint ; but these movements in the foot are not so free as in the hand.

ARTICULATIONS OF THE PHALANGES. There are two interphalangeal joints to each toe, except the first.

Union of the phalanges. Ligaments similar to those in the metatarso-phalangeal joints, viz., two *lateral* and an *inferior*, are to be recognized in these articulations. The joint between the last two phalanges is least distinct ; and oftentimes the small bones are immoveably united by osseous substance. These ligaments receive a more particular notice with the dissection of the hand (p. 327).

synovial sac. A simple *synovial membrane* exists in each phalangeal articulation.

Form of bones. *Articular surfaces.* In both phalangeal joints, the nearer phalanx presents a trochlear surface ; and the distal one is marked by two lateral hollows or cups with a median ridge.

Kind of motion, *Movement.* Only flexion and extension are permitted in the two phalangeal joints of the toes, as in the hand.

movement of bone, In *flexion* the farther phalanx glides under the nearer ; and in *extension* the two are brought into a straight line.

state of ligaments. The bending is checked by the lateral ligaments and the extensor tendon ; and the straightening is limited by the inferior ligament and the flexor tendons.

TABLE OF THE ARTERIES OF THE LOWER LIMB.

The FEMORAL ARTERY gives off	External pudic .	{ Superior inferior.	
	superficial epi- gastric		
	superficial cir- cumflex iliac		
		External circumflex .	{ Ascending transverse descending.
		internal circumflex .	{ Muscular articular ascending . transverse .
	profunda .		} final branches.
		first perforating	
		second perforating	
		third perforating .	medullary to femur.
		fourth perforating.	
	muscular		
	anastomotic .	{ Superficial branch. deep branch.	
		Upper muscular upper internal articular upper external articular lower internal articular lower external articular azygos articular sural.	
		Anterior tibial .	{ Recurrent cutaneous muscular internal malleolar external malleolar tarsal metatarsal . . . { Three interos- seous. first interosseous communicating to deep arch digital . . . { to great toe and half the next.
	Popliteal .		
		Peroneal .	{ Muscular medullary to fibula anterior peroneal external calcaneal.
		medullary to tibia muscular communicating to peroneal internal malleolar	
		Posterior tibial.	
		internal plantar .	{ Muscular superficial digital.
		external plantar .	{ Internal calcaneal muscular anastomotic. plantar arch. { Posterior per- forating digital, for three toes and a half.

N.B. The branches of the internal iliac artery which end in the limb will be found in the Table of the Arteries of the Abdomen.

TABLE OF THE VEINS OF THE LOWER LIMB.

The FEMORAL VEIN, continued from the popliteal, receives	Popliteal . . .	Posterior tibial . . .	External plantar . . .	{ Muscular plantar arch . . .	{ Posterior per- forating digital from three toes and a half.
			Anterior tibial . . .	Communicating to deep arch . . .	{ Digital from great toe and half the next.
				external saphenous . . .	{ Branch from dor- sal arch of foot plantar veins from outer side of os calcis cutaneous in the leg.
		articular muscular.	{ Tarsal malleolar communicating to saphenous muscular recurrent.		
				anastomotic muscular . . .	{ Superficial branch deep branch.
		profunda . . .	{ Perforating branches		
				internal circumflex . . .	{ Muscular articular ascending transverse.
internal sa- phenous . . .	{ Branch from dorsal arch of the foot plantar veins about os calcis communicating with posterior and anterior tibial communicating with deep veins of thigh cutaneous from outer and inner parts of thigh external pudic superficial epigastric superficial circumflex iliac.				

TABLE OF THE NERVES OF THE LOWER LIMB.

Nerves of the LUMBAR PLEXUS in the Limb.	1. Iliac branch of ilio-hypogastric.	
	2. Ilio-inguinal.	
	3. Crural branch of genito-crural.	
	4. External cutaneous.	
	5. Obturator	Accessory . . . { To obturator trunk to pectineus to hip-joint. superficial division . . . { Articular . . . To hip-joint. muscular . . . { To gracilis to adductor longus to adductor brevis. to plexus in the thigh and artery to skin sometimes. deep division . . . { Muscular . . . { To obturator externus articular . . . { to adductor magnus. To knee-joint.
	6. Anterior crural	Superficial portion . . . { Muscular . . . { To sartorius to pectineus. middle cutaneous internal cutaneous . . . } Anterior and posterior branches. deep portion . . . { Muscular . . . { To rectus—articular to vastus externus—articular to vastus internus and crureus—articular. internal saphenous . . . { Branch to plexus over patella to leg and foot.
Nerves of the SACRAL PLEXUS in the Limb.	1. Superior gluteal	{ To gluteus medius and minimus to tensor fasciæ latæ.
	2. Inferior gluteal	{ To gluteus maximus.
	3. Small sciatic	{ Inferior pudendal cutaneous to gluteal region, thigh, and leg.
	4. Great sciatic	Muscular . . . { To hamstrings to adductor magnus. external popliteal . . . { Articular external cutaneous of leg peroneal communicating recurrent articular musculo-cutaneous . . . { To peronei cutaneous to foot and toes. anterior tibial . . . { Muscular articular cutaneous to two toes.
	5. To obturator internus and superior gemellus.	internal popliteal . . . { Articular muscular . . . To calf-muscles and popliteus tibial communicating Muscular . . . { To soleus, long flexors of toes, and tibialis posticus. calcaneo-plantar internal plantar . . . { Cutaneous muscular four digital communicating branch.
	6. To quadratus femoris and inferior gemellus.	posterior tibial . . . { Muscular external plantar . . . { superficial part . . . { Cutaneous two digital communicating. deep part . . . Muscular.
	7. Perforating cutaneous.	

CHAPTER X.

DISSECTION OF THE EYE.

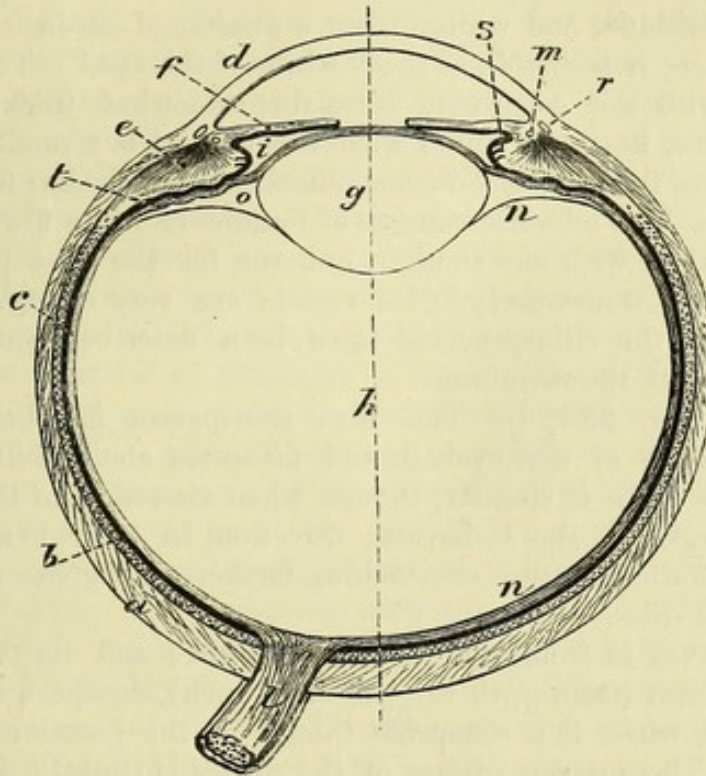
- Situation of the eyeball ;** THE eyeball is the organ of vision, and is lodged in the orbit. Supported in that hollow on a mass of fat, it is surrounded by surrounding muscles which impart movement to it; and a thin membrane (*tunica vaginalis oculi* or *capsule of Tenon*) isolates the ball, so as to allow free movement.
- Parts in front of it.** Two lids protect the eye from external injury, and regulate the amount of light admitted into the interior ; and the anterior or exposed surface is covered by a mucous membrane (*conjunctiva*).
- The dissection to be made on the eye of the ox.** *Directions.* In the absence of specimens of the human eye, the structure may be learnt on the eye of the pig or ox. Let the student procure half a dozen eyes of the ox for the purpose of dissection. One or two shallow basins will be needed ; and some wax or tallow in the bottom of one, or in a deep plate, will be useful.
- Detach the muscles.** *Dissection.* To see the general form of the ball of the eye, and the outer surface of the external coat, the attachments of the different muscles are to be taken away ; and the loose mucous membrane is to be removed from the front.
- Form of the ball.** The *ball of the eye* (fig. 223) consists of two parts, which differ in appearance, viz., an opaque posterior portion, forming about five-sixths of the whole, and a smaller transparent piece (cornea) in front ; these two parts are segments of different sized spheres, the anterior belonging to the smaller sphere. To the back of the eye the optic nerve is attached, rather to the inner side of the axis of the ball ; and around it ciliary vessels and nerves enter.
- Position of optic nerve.**
- Diameter.** The antero-posterior diameter of the ball amounts to nearly an inch ($\frac{1\frac{2}{3}}{10}$ ths), but the transverse measures an inch.
- Composition ; number of coats, and central parts.** The organ of vision is composed of central transparent parts, with enclosing membranes or coats. The coats, placed one within another, are named sclerotic, choroid, and retina. The transparent media in the interior are likewise three, viz., the lens, the aqueous humour, and the vitreous body.
- Dissection.** *Dissection.* To obtain a general idea of the structures to be dissected, the student may destroy one eyeball by cutting through it circularly : he will then be able to recognise the arrangement of the parts mentioned above, with their strength and appearance, and will be better prepared to follow the directions that are afterwards given.

FIBROUS COAT OF THE EYEBALL. The outer casing of the eye consists of an opaque hinder part called sclerotic, and of an anterior transparent portion, the cornea. Fibrous coat.

The **SCLEROTIC** is the firm, whitish, opaque portion of the outer coat of the eyeball, which supports the more delicate structures within. Sclerotic part.

Dissection. To examine the inner and outer surfaces of this layer, Dissection to see the interior.

Fig. 223.*



it will be necessary to cut circularly with a scissors through the cornea close to the sclerotic, and to remove the cornea from the front of the eyeball; on piercing the cornea the aqueous fluid escapes from the containing chamber. The other structures may be then abstracted from the interior of the sclerotic covering, and may be set aside with the cornea for subsequent use.

The sclerotic tunic of the eye (fig. 223, *a*) extends from the entrance of the optic nerve to the margin of the cornea, forming about five-sixths of the ball. Extent of sclerotic;

At its back, and a little to the inner side of the centre (one-tenth of an inch), the optic nerve (*l*) is transmitted through an aperture in it: this opening decreases in size from without inwards, and is cribriform when the nerve is drawn out,—the lattice-like condition being due to the bundles of fibrous tissue between the funiculi of apertures behind,

* Diagram of a horizontal section of the eyeball. *a*. Sclerotic coat. *b*. Choroid. *c*. Retina, continuous with the optic nerve behind, with a dark layer outside it. *d*. Cornea. *e*. Ciliary muscle. *f*. Iris. *g*. Lens. *h*. Vitreous body. *i*. Posterior chamber of the aqueous. *l*. Optic nerve. *m*. Circular fibres of the ciliary muscle. *n*. Hyaloid membrane. *o*. Canal of Petit. *r*. Canal of Schlemm. *s*. Ciliary process. *t*. Suspensory ligament of lens. The dotted line through the centre is the longitudinal axis of the ball.

and before ; the nerve. Small apertures for the passage of vessels and nerves are situate around the optic nerve ; and there are others for vessels ending in front ; at the front and the centre of the ball. Anteriorly the sclerotic is continuous with the transparent cornea.

outer and inner surfaces ; On the outer surface this coat is smooth, except where the muscles are attached ; on the inner aspect it is of a dark colour, with flocculi of fine areolar tissue (*membrana fusca*) uniting it to the next coat, and with the ends of ruptured vessels and nerves.

thickness ; The sclerotic covering is thickest at the back of the eyeball, but it becomes thinner and whiter about a quarter of an inch from the cornea, where it is visible as the "white of the eye." Towards the junction with the cornea it is again somewhat thickened. In its substance, near the union with the cornea, is a small flattened venous space, the *canal of Schlemm* (*sinus circularis iridis* ; fig. 223, *r*).

circular sinus ;
composed of fibrous tissue ;
vessels and nerves. *Structure.* The sclerotic consists of bundles of white fibrous tissue, which interlace with one another, but run for the most part longitudinally and transversely. Its vessels are very scanty. Minute filaments of the ciliary nerves have been described, entering the deep surface of the membrane.

Cornea : CORNEA (fig. 223, *d*). This firm transparent membrane forms about one-sixth of the eyeball, and measures about half an inch across. Its shape is circular, though when viewed from the front it appears larger in the transverse direction, in consequence of the opaque sclerotic structure encroaching farther on it above and below than on the sides.

thickness ; It is convex in front, and concave behind ; and its thickness is nearly uniform (from $\frac{1}{20}$ th to $\frac{1}{30}$ th of an inch), except near the circumference, where it is somewhat thicker at the junction with the sclerotic. The anterior surface of the cornea is slightly less extensive than the posterior, owing to its being overlapped by the sclerotic. Supported by the aqueous humour, it is tense and nearly spherical during life ; but its radius of curvature varies in different individuals, and in the same person at different ages, being shorter in the young. After death it becomes flaccid from the transudation of the aqueous humour ; or if the eye is immersed in water, it is rendered opaque by infiltration of the tissue by that fluid.

surfaces ;
curve ;
condition after death. *Structure.* The substance of the cornea is composed of a special kind of connective tissue, arranged in irregular layers. Over the front the conjunctiva (which is here reduced to its epithelium) is continued ; and covering the back of the cornea proper is a very thin elastic stratum known as the *membrane of Descemet*. The latter may be peeled off, after a cut has been made through it, in shreds which curl up with the attached surface innermost. At the circumference of the cornea the membrane of Descemet breaks up into processes (*pillars of the iris* or *ligamentum pectinatum iridis*) which are partly reflected on to the front of the iris, and partly join the sclerotic and choroid coats.

no vessels ;
many nerves. In the healthy condition the blood-vessels do not permeate the cornea, but cease in capillary loops at the circumference. Numerous fine branches of the ciliary nerves ramify in its substance.

VASCULAR COAT OF THE EYEBALL (fig. 224). The next covering is situate within the sclerotic, and is formed in large part of blood-vessels; the muscles of the interior of the ball also belong to this coat. Vascular and muscular coat.

It is constructed of three parts,—a posterior (choroid) corresponding with the sclerotic, an anterior (iris) opposite the cornea, and an intermediate ring (ciliary muscle) on a level with the union of the sclerotic and cornea. Components.

Dissection. Supposing the cornea of an eye cut through circularly as before directed (p. 717), it will be necessary to take away the sclerotic to lay bare the choroid coat. With the point of the scalpel, or with a shut scissors, detach the fore part of the sclerotic from the front of the choroid by breaking through a soft whitish structure uniting them. Then, the eye being put into water, the outer coat is to be removed by cutting it away piece-meal with the scissors; in taking it off, the slender vessels and nerves beneath are to be preserved. The white ring round the eye in front, which comes into view during the dissection, is the ciliary muscle. Dissection to see the choroid portion.

For the purpose of obtaining a front view of the ciliary processes, which are connected with the anterior termination of the choroid coat, let the cornea be removed as before on another eyeball. Detach next the fore part of the sclerotic from the choroid; and after three or four cuts have been made in it towards the optic nerve, the resulting flaps may be pinned out, so as to support the eye in an upright position. On removing with care the iris, taking it away from the centre towards the circumference, the ciliary processes beneath will be displayed. A posterior view of the processes may be prepared on another ball by cutting through it circularly with scissors, about one-third of an inch behind the cornea, so that the anterior can be removed from the posterior half; on taking away the portion of the vitreous mass adherent to the anterior part of the ball, and washing off the pigment from the back of the iris, the small processes will be made manifest. By means of the last dissection the interior of the choroid coat may be seen. To show the ciliary processes by an anterior and a posterior view.

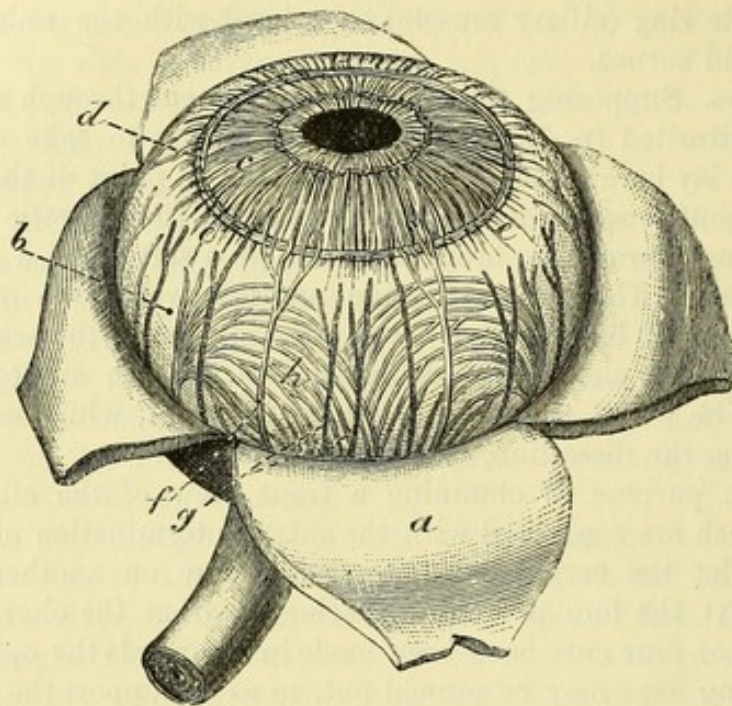
If a vertical section is made of another eyeball, it will show the ciliary processes in their natural position, and will demonstrate the relative situation of all the parts. This section, which is made with difficulty, should be attempted in water with a sharp large knife, and on a surface of wax or wood, after the cornea and sclerotic have been cut with a scissors. When the eye has been divided, the halves should remain in water. To make a vertical section.

The CHOROID COAT (fig. 223, *b*) is a thin membrane of a dark colour, and extends from the optic nerve to the fore part of the eyeball. When viewed on the eye in which the ciliary muscle is entire, it appears to terminate there; but it may be seen in the other dissections to pass inwards behind that muscle, and to end in a series of projections (ciliary processes) at the back of the iris. Choroid : extent ; anterior termination ;

This covering is rather thicker and stronger behind than in front. Its outer surface is for the most part only slightly attached to the sclerotic by delicate bands of areolar tissue, and has a flocculent relations of outer surface,

appearance when detached ; but in front the ciliary muscle unites the two coats more firmly : on this surface may be seen small veins arranged in arches, and the ciliary arteries and nerves (fig. 224).
 of inner ; The inner surface is smooth, and is lined by the thin dark pigmen-

Fig. 224.*



opening
behind.

tary layer of the retina (fig. 223). Posteriorly it is pierced by a round aperture for the passage of the optic nerve ; and anteriorly it joins the iris.

Ciliary
processes :
arrange-
ment ;

The *ciliary processes* (fig. 225, *b*) are solid projections on the inner surface of the choroid coat, disposed radially, and forming a circle beneath the ciliary muscle and the outer margin of the iris. About seventy in number, they comprise larger and smaller eminences, the former being the more numerous, and having a length of about one-tenth of an inch. They increase in depth from without inwards ; and at their inner ends they are united by transverse ridges.

relations
to parts
around.

By their free extremities the processes bound peripherally the space (posterior chamber ; fig. 226, *i*) behind the iris ; in front, they correspond to the ciliary muscle, and at their inner ends to the back of the iris ; while behind, they are closely applied to the membrane on the front of the vitreous body (suspensory ligament of the lens ; fig. 226, *t*), and fit into hollows between eminences on the anterior surface of that structure.

Structure of
choroid :

Structure. The choroid coat and its ciliary processes are composed of blood-vessels supported by pigmented areolar tissue. Most externally is a delicate stratum of connective tissue known as the *lamina*

* View of the front of the choroid coat and iris—external surface (Zinn). *a.* Sclerotic, cut, and reflected. *b.* Choroid. *c.* Iris. *d.* Circular. *e.* Radiating fibres of ciliary muscle. *f.* Ciliary nerves, and *g.* Ciliary arteries, between the two outer coats. *h.* Veins of the choroid coat (*vasa vorticosa*).

suprachoroidea, similar to the *membrana fusca* of the sclerotic, to which it is connected ; next to this is a layer containing the larger ramifications of the arteries and veins ; and in the deepest part the vessels form a very fine and close capillary network (*tunica Ruyschiana*). In the ciliary processes the meshes of the capillary network are larger, and the interstitial pigment disappears towards the free ends of the larger processes.

supra-choroid layer, and vascular networks ; ciliary processes.

CILIARY MUSCLE (fig. 224, *d, e*). In the eye from which the sclerotic coat has been removed, the white ring of the ciliary muscle may be seen covering the front of the choroid coat.

Ciliary muscle :

The muscle forms a circular band, of a greyish white colour, and position ; about one-tenth of an inch wide, on the surface of the choroid coat, close to the outer margin of the iris. It consists of unstriated fibres, which are in two sets, radiating and circular :—

The *radiating fibres* (fig. 226, *e*) arise in front from the sclerotic coat close to the junction with the cornea (beneath *r*), and are directed backwards, spreading out, to be inserted into the choroid coat opposite to, and a little behind, the ciliary processes. Some of the deeper fibres become transverse, and pass gradually into the following set.

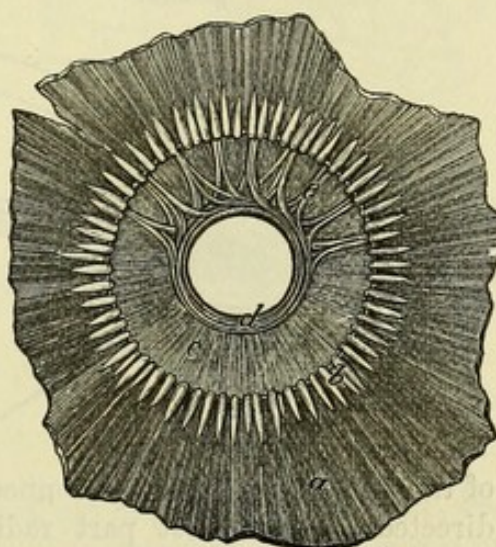


Fig. 225.*

consists of radiating

The *circular fibres* are beneath the radiating, and form a narrow bundle (fig. 226, *m*) surrounding the edge of the iris, opposite the inner part of the ciliary processes.

and circular fibres ;

Action. The ciliary muscle draws forwards the fore part of the choroid coat and the ciliary processes, and relaxes the suspensory ligament of the lens, thereby allowing the lens to become more convex, as required for vision at near distances. The ciliary muscle is therefore the *muscle of accommodation*.

The **IRIS** (fig. 224, *c*) is a vascular and muscular structure, about half an inch in diameter, the vessels of which are continuous with those of the choroid coat. Its position and relations may be observed in the different dissections that have been prepared.

Iris is vascular and muscular ;

Placed within the ring of the ciliary muscle, it is suspended in front of the lens (fig. 223, *f*), and is pierced by an aperture for the transmission of the light. It is circular in form, is variously coloured in different persons, and is immersed in the aqueous humour. By its circumference, it is connected with the choroid coat, and by the

situation ;

form ;

attachment

* Posterior view of the fore part of the choroid coat with its ciliary processes, and the back of the iris. *a*. Anterior piece of the choroid coat. *b*. Ciliary processes. *c*. Iris. *d*. Sphincter of the pupil. *e*. Bundles of fibres of the dilator of the pupil.

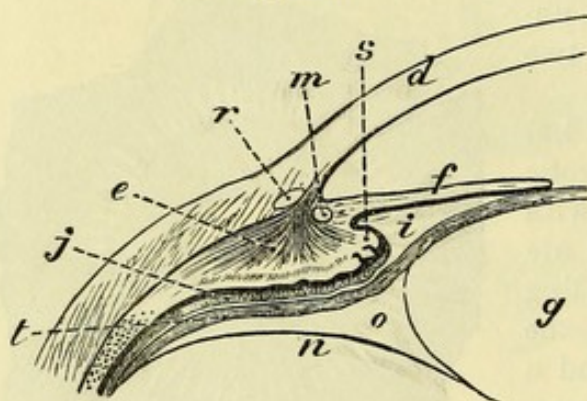
anterior surface: ligamentum pectinatum with the cornea. The anterior surface is free in the aqueous humour, and is marked by lines converging towards the pupil. The posterior surface is covered with a thick layer of pigment (fig. 226), to which the term *uvea* has been applied.

The pupil. The aperture in it (fig. 224) is the *pupil* of the eye; this is slightly internal to the centre, and is nearly circular in form; but its size is constantly varying (from $\frac{1}{20}$ th to $\frac{1}{3}$ of an inch) by the contraction of the muscular fibres, according to the degree of light acting on the retina.

Membrane of the pupil in the foetus: *Membrane of the pupil.* In the foetus the aperture of the pupil is closed by a vascular transparent membrane, which is attached to the

edge of the iris, and divides into two distinct chambers the space in which the iris is suspended. The vessels in it are continuous behind with those of the iris and the case of the lens. About the eighth month the vessels become imperious, and at the time of birth only fragments of the structure remain.

Fig. 226.*



situation;

time of disappearance.

Component structures.

of the iris is composed of connective tissue, the fibres of which are directed for the most part radially towards the pupil. In it are involuntary muscular fibres, both circular and radiating, together with pigment-cells; and vessels and nerves ramify through the tissue.

Sphincter

Muscular fibres. The *sphincter of the pupil* (fig. 225, *d*) is a narrow band about $\frac{1}{30}$ th of an inch wide, which is close to the pupil, on the posterior aspect of the iris. The *dilator of the pupil* (*e*) consists of bundles of fibres which begin at the outer border of the iris, and end internally in the sphincter.

and dilator of pupil.

How they act.

Action. Enlargement of the pupil is effected by shortening of the radiating fibres; and diminution, by contraction of the circular ring. The movements of the iris are involuntary, and regulate the admission of light into the ball.

Situation of pigment.

The *pigment* of the iris is partly interspersed in the substance of the membrane, and partly collected into a thick layer on the posterior aspect, the above-mentioned *uvea*, which is continuous with the pigmentary stratum of the retina. The colour of the iris depends upon the nature and quantity of the interspersed pigment.

* Enlarged representation of the parts of the eyeball on one side opposite the lens: the letters refer to the same parts as in fig. 223. *d.* Cornea. *e.* Ciliary muscle, radiating fibres. *f.* Iris. *g.* Lens. *i.* Posterior chamber. *j.* Ciliary part of the retina. *m.* Circular bundle of the ciliary muscle. *n.* Front of vitreous body. *o.* Canal of Petit. *r.* Canal of Schlemm. *s.* Inner end of ciliary process. *t.* Suspensory ligament of the lens.

The *arteries* of the iris (fig. 227, B) have a looped arrangement: they are derived chiefly from the long and the anterior ciliary branches (*d*), but some come from the vessels of the ciliary processes. On arriving at the ciliary muscle, the long and anterior ciliary arteries form a circle (*e*) round the margin of the iris; from this ring other anastomotic branches are directed towards the pupil, near which they join in a second arterial circle (*f*). From the last circle capillaries run to the edge of the pupil, and end in veins.

The *veins* resemble the arteries in their arrangement in the iris, and terminate in the veins of the choroid coat.

The *nerves* of the iris are the terminal branches of the ciliary nerves: they divide into branches which accompany the blood-vessels, and communicate with one another so as to form a plexus which gets gradually finer towards the pupil (fig. 227, A).

CILIARY VESSELS AND NERVES (fig. 224). The ciliary arteries are offsets of the ophthalmic (p. 45), and supply the choroid, the ciliary processes, and the iris. They are classed into posterior and anterior, and two of the first set are named long ciliary; but they will not be seen without a special injection of the vessels of the eye.

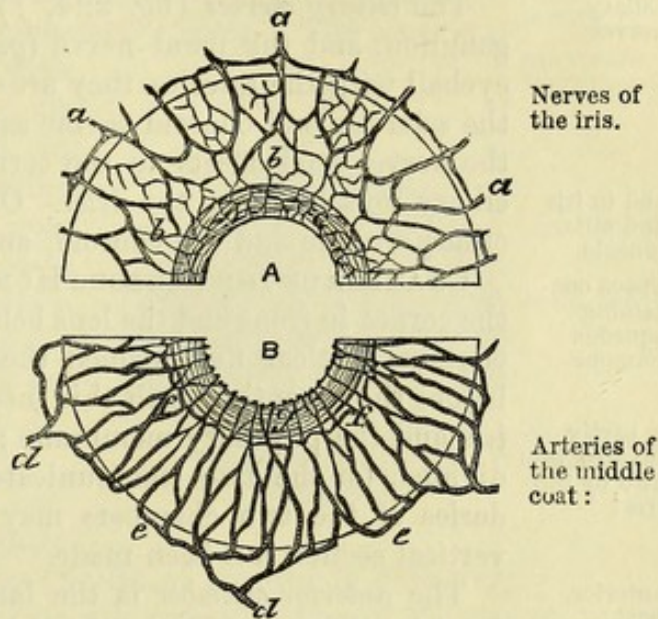
The *posterior ciliary arteries* (*g*) pierce the sclerotic coat around and close to the optic nerve, and running forwards on the choroid, divide into branches which enter its substance at different points.

Two of this set (*long ciliary*) are directed forwards between the sclerotic and choroid, one on each side of the eyeball, and form a circle round the iris in the ciliary muscle, as before explained. In the ball the outer one lies rather above, and the inner, rather below the middle.

The *anterior ciliary arteries*, five or six in number, are smaller than the posterior, and arise at the front of the orbit from muscular branches (p. 46); they pierce the sclerotic coat about a line behind the cornea, supply the ciliary processes, and join the circle of the long ciliary vessels. In inflammation of the iris these vessels are enlarged, and offsets of them form a ring round the cornea.

The *posterior ciliary veins* have a different arrangement from the arteries. The branches form arches (*vasa vorticosa*; fig. 224, *h*) in

Fig. 227.*



* Distribution of the nerves and vessels of the iris. A. Half of the iris showing the nerves. *a*. Nerves entering the membrane, and uniting in a plexus, *b*, within it. (Kölliker.) B. Half of the iris with a plan of the vessels. *d*. Ciliary arteries. *e*. Arch of vessels at the outer edge of the iris. *f*. Inner circle of vessels in the iris. *g*. Sphincter of the pupil.

the superficial part of the choroid coat, external to the arteries, and converge to four or five trunks, which perforate the sclerotic coat about midway between the cornea and the optic nerve to end in the ophthalmic veins.

and anterior ciliary.

The *anterior ciliary veins* begin in a plexus within the ciliary muscle, receiving tributaries from the iris and the ciliary processes, and accompany the arteries through the sclerotic to end in the ophthalmic trunks: they communicate with the venous space of the canal of Schlemm (p. 718).

Ciliary nerves

The *ciliary nerves* (fig. 224, *f*) are derived from the lenticular ganglion, and the nasal nerve (p. 45). Entering the back of the eyeball with the arteries, they are continued with the vessels between the sclerotic and choroid as far as the ciliary muscle: at this spot the nerves send offsets to the cornea, and piercing the fibres of the ciliary muscle, enter the iris. Offsets from the nerves supply the ciliary muscle and the choroid, and fine twigs enter the sclerotic.

end in iris and ciliary muscle.

Space containing aqueous humour

is partly divided into two by the iris:

CHAMBER OF THE AQUEOUS HUMOUR (fig. 223). The space between the cornea in front and the lens behind, in which the iris is suspended, contains a clear fluid named the aqueous humour. In the fœtus before the seventh month this interval is separated into two by the iris and the pupillary membrane; but in the adult it is only partly divided, for the two communicate through the pupil. The boundaries of the two chambers may be seen in the eye on which a vertical section has been made.

anterior part;

The *anterior chamber* is the larger of the two; it is limited in front by the cornea, and behind by the iris.

posterior, its boundaries.

The *posterior chamber* (*i*) is a narrow interval behind the iris at the circumference, which is bounded in front by the iris; behind by the lens capsule, and by a piece of the membrane (suspensory ligament of the lens) on the front of the vitreous humour; and at the circumference by the ciliary processes.

Retina

is in two parts.

THE RETINA (fig. 223, *c*). This layer is the innermost and most delicate of the coats of the eyeball, and is situate between the choroid coat and the transparent mass (vitreous) in the interior. It consists of two parts, viz., a thin membrane internally, continuous with the optic nerve, and a pigmentary layer outside, which adheres to the choroid coat.

Dissection to see the retina.

Dissection. The retina can be satisfactorily examined only on an eye which is obtained within forty-eight hours after death. To bring it into view on the eyeball in which the middle coat was dissected, the choroid must be torn away carefully with two pairs of forceps, while the eye is immersed in fluid. In this dissection the pigmentary layer separates from the nervous portion of the retina, and is removed with the choroid coat.

Pigmentary membrane.

The *pigmentary portion of the retina* is a very thin, dark layer, which lines closely the inner surface of the choroid coat, and is continued over the ciliary processes into the uvea on the posterior surface of the iris (fig. 226).

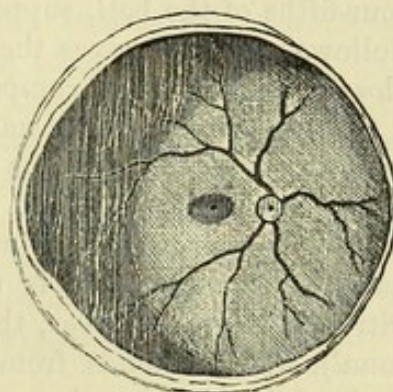
Nervous retina:

The *nervous portion of the retina* is a soft membrane of a pinkish grey tint and semitransparent when fresh; but it soon loses this

translucency, and is moreover rendered opaque by the action of water and other substances. In the living state, however, the retina is characterized by the existence of a purplish red colour, which is discharged under the influence of sunlight. This part of the retina extends over about the posterior two-thirds of the eyeball, reaching from the entrance of the optic nerve to the outer extremities of the ciliary processes, where it ends in an irregular wavy border—the *ora serrata*. Its thickness diminishes from behind forwards.

The outer surface of the dissected retina is slightly flocculent, owing to the tearing away of the pigmentary layer. The inner surface is smooth: it is covered with folds in a preparation of the eye cut in two, but these are accidental, in consequence of the membrane having lost its proper support. At the spot where the optic nerve expands (*porus opticus*, *optic disc*; fig. 228) the surface is slightly elevated (*papilla optica*); but in the centre of this is a slight excavation where the central vessels appear.

Fig. 228.*



thickness ;

outer
surface ;inner sur-
face presents

optic disc,

central
vessels,

In the interior of the human eye, in the axis of the ball, is a slightly elliptical yellow area (fig. 228), one-twelfth of an inch in diameter, which is named the *yellow spot* (*macula lutea*). Almost in the centre of this spot is a minute hollow, the *fovea centralis*, which appears black in consequence of the thinness of the wall allowing the dark pigment outside to be seen.

From the *ora serrata* a very thin layer is continued on as far as the tips of the ciliary processes: it is called the *ciliary part of the retina*, but does not consist of nervous substance. It is not visible to the naked eye.

For a description of the structure of the retina, the student is referred to a work dealing with microscopic anatomy.

Vessels of the retina. The *central artery of the retina*, accompanied by its vein, enters the eyeball through the optic nerve (p. 45). In the central depression of the optic papilla the artery divides into four primary branches,—two inner or nasal (upper and lower), and two outer or temporal (also upper and lower). The outer branches are the larger, and follow an arched course above and below the yellow spot: all ramify in the innermost part of the nervous coat. No vessels enter the pigmentary layer. The veins have a similar arrangement.

In the foetus a branch of the artery passes through the centre of the vitreous mass to supply the lens-capsule.

VITREOUS BODY. This is a soft transparent mass which fills the

yellow spot,
and central
fovea.Ciliary
part of
retina.Artery of
retinahas four
chief
branches ;another in
foetus.Vitreous
body.

* Objects on the inner surface of the retina. In the centre of the ball is the yellow spot, here represented by shading: and in its middle the fovea centralis. To the inner side is the porus opticus, with the branching of the artery (Sæmmerring).

greater part of the space within the coats of the eyeball (fig. 223, *h*).

To obtain a view of it,

Dissection. The vitreous body may be seen on the eye on which the retina was dissected, by taking away the retina, the iris, and the ciliary muscle and processes.

and of its front.

To obtain a view of its anterior part, with the lens in situation, an eyeball should be fixed upright, and the sclerotic and choroid coats cut through about a quarter of an inch behind the cornea; then on removing carefully the cornea, the ciliary muscle and processes, and the iris, the vitreous body will be apparent.

Form and position of vitreous:

The *vitreous body* (fig. 223, *h*) is globular in form, and fills about four-fifths of the ball, supporting the retina. In front it is slightly hollowed, and receives the lens with its capsule (*g*), to which it is closely united. It is composed of a thin watery jelly, contained in a transparent membrane named hyaloid. The jelly consists in great part of fluid, which drains away when the vitreous body is exposed on a flat surface, or placed on a filter, and only a very small amount of solid matter remains; but whether in the natural state it possesses any definite structure is uncertain. In the central part of the vitreous body, however, there is a canal filled with fluid (*hyaloid canal*), which extends from the optic papilla of the retina to the back of the lens-capsule, and served in the fœtus for the transmission of the capsular branch of the central artery of the retina. This canal is not visible without special preparation.

it consists of jelly,

with a central canal,

and of the hyaloid membrane:

The *hyaloid membrane* (*n*) is the thin, glassy, structureless layer enclosing the vitreous body, except at the fore part where the lens is placed. At the bottom of the ball, around the optic papilla, the membrane is closely connected with the retina; and it sends a prolongation forwards to line the canal of the vitreous. In front, the membrane becomes thicker as it approaches the ciliary processes, and is continued into the suspensory ligament of the lens.

both are without vessels.

The vitreous mass and the hyaloid membrane are extravascular, and receive their nutritive material from the vessels of the ciliary processes and retina.

Suspensory ligament:

SUSPENSORY LIGAMENT OF THE LENS (Zonule of Zinn). This is a transparent membranous structure (fig. 226, *t*), placed around the lens-capsule, which joins externally the hyaloid membrane opposite the anterior termination (*ora serrata*) of the retina. After the ciliary processes of the choroid coat are detached from it, dark lines of pigment cover the surface; and when these are washed away, plaits (*ciliary processes*) come into view, which are less prominent and longer than the processes of the choroid coat; but do not quite reach the lens-capsule internally. The two sets of prominences are dovetailed together,—the projections of one being received into hollows between the other; and in the fresh state the two structures are closely adherent. The membrane contains numerous stiff radiating fibres, which internally become collected into bundles, and are attached to the margin, and the adjacent part of the anterior surface of the lens-capsule. The tenseness is influenced by the state of the ciliary muscle, for during its contraction the

extent;

is marked by folds;

inner attachment;

condition how altered.

membrane is rendered lax by the drawing forwards of the ciliary processes.

Canal of Petit. Around the margin of the lens-capsule is a narrow space (fig. 223, *o*) about one-tenth of an inch across, which is situated between the suspensory ligament and the front of the vitreous humour. When the canal has been opened, and filled with air by means of a blowpipe, it is sacculated at regular intervals, like the large intestine, by the inflation of the plaits of the anterior boundary. The margin of the capsule of the lens bounds the space internally.

Canal of Petit : situation ; anterior part sacculated.

LENS AND ITS CAPSULE. The lens is situated behind the pupil of the eye (fig. 223, *g*), and brings to a focus on the retina the rays of light entering through that aperture.

Lens of the eyeball.

The **CAPSULE** is a firm and very elastic transparent case, which closely surrounds the lens proper. The anterior surface (fig. 223) is free, and projects towards the pupil, around which it touches the iris ; but externally the two are separated by a small interval—the posterior chamber (*i*) ; close to the margin of the lens it is joined by the suspensory ligament (*t*). The posterior surface is received into a hollow on the front of the vitreous body, to which it is inseparably united. The circumference of the case gives attachment to the posterior fibres of the suspensory ligament, and behind this bounds the canal of Petit (*o*).

Capsule of the lens : relations of anterior surface, posterior surface, and circumference ;

The capsule is a structureless glassy membrane, much thicker over the front of the lens, as far out as the attachment of the suspensory ligament, than over the back, where it is very thin in the centre. In the adult human eye the capsule of the lens is not provided with blood-vessels ; but in the foetus a branch of the central artery of the retina supplies it (p. 725).

is a homogeneous membrane ; vessels only in foetus.

Dissection. The lens will be obtained by cutting across the thin membranous capsule in which it is enclosed.

Open capsule of lens.

The **LENS** is a solid and transparent doubly convex body ; but the curves are unequal on the two surfaces (fig. 223, *g*), the posterior being greater than the anterior. Its margin is somewhat rounded ; and the measurement from side to side is one-third of an inch, but from before back about one-fifth of an inch. The density increases from the circumference to the centre ; for while the superficial layers may be rubbed off with the finger, the deeper portion is firm, and is named the *nucleus*.

Surfaces are curved unequally ; dimensions ; density ;

On each surface are three lines diverging from the centre, and reaching towards the margin ; they are the edges of planes or “septa,” where the ends of the lens-fibres meet, and are so situated that those on one side are intermediate in position to those on the other. In the human eye they are not distinctly seen, because they bifurcate repeatedly as they extend outwards.

lines on the surfaces ;

Structure. After the lens has been hardened by spirit or boiling, it may be demonstrated to consist of a series of layers (fig. 229) arranged one within another, like those of an onion. The laminae of each surface have their apices in the centre, where the septa meet ; they may be detached from one another at that spot, and turned outwards towards the equator of the lens. The laminae are

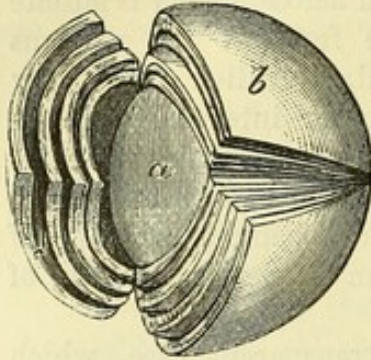
structure is laminar

and fibrous. composed of fine parallel fibres which run between two septa on opposite aspects of the lens.

Change in
form of lens,

Fig. 229.*

in colour
and con-
sistence,
with age.




Changes in the lens with age. The form of the lens is nearly spherical in the foetus; but its convexity decreases with age, particularly on the anterior surface, until it becomes flattened in the adult.

In the foetus it is soft, rather reddish in colour, and not quite transparent; in mature age it is firm and clear; and in old age it becomes flatter on both surfaces, denser, and of a yellowish colour.

* A representation of the laminae in a hardened lens. *a.* The nucleus. *b.* Superficial laminae.

CHAPTER XI.

DISSECTION OF THE EAR.



THE organ of hearing is made up of complex bodies, which are lodged in, and attached to the surface of, the temporal bone. It is commonly divided into three parts, known as the external ear, the middle ear, and the internal ear. Of these, the last is the essential portion, containing the terminal expansion of the auditory nerve ; and the others are to be regarded as accessory, serving to convey to it the vibrations produced by the sonorous undulations of the air.

Subdivision
of auditory
apparatus.

EXTERNAL EAR. This includes the pinna or auricle and the auditory canal : the former has been noticed at p. 33, and the latter remains to be described.

Parts of
outer ear.

The **EXTERNAL AUDITORY CANAL** (meatus auditorius externus ; fig. 230) is the passage which leads from the pinna towards the tympanic cavity (a part of the middle ear), from which it is separated in the recent state by the tympanic membrane.

Auditory
canal :

Dissection. To obtain a view of this canal, a recent temporal bone is to be taken, to which the cartilaginous pinna remains attached. After the removal of the soft parts, the squamous piece of the bone in front of the Glaserian fissure is to be sawn off ; and the front of the meatus, except a ring at the inner end which gives support to the thin membrana tympani, is to be cut away with a bone-forceps.

how to ob-
tain a view
of it ;

The *canal* (fig. 230) is about one inch and a quarter in length, and is formed partly by bone, and partly by cartilage. It is directed forwards somewhat obliquely, and describes a slight vertical curve with the convexity upwards. In shape it is rather flattened from before backwards ; and it is narrowest in the osseous portion. The outer extremity is continuous with a hollow (concha) of the external ear, and the inner is closed by the membrana tympani.

length,
direction,
size and
shape ;

The *cartilaginous part* (a) is largest. It is about half an inch in length, and is formed chiefly by the pinna of the outer ear, which is attached to the margin of the osseous meatus ; but at the upper and posterior aspect the cartilage is deficient, and the tube is closed by fibrous tissue. One or two fissures (fissures of Santorini) cross the cartilage (p. 35).

cartilagi-
nous part
is deficient
above ;

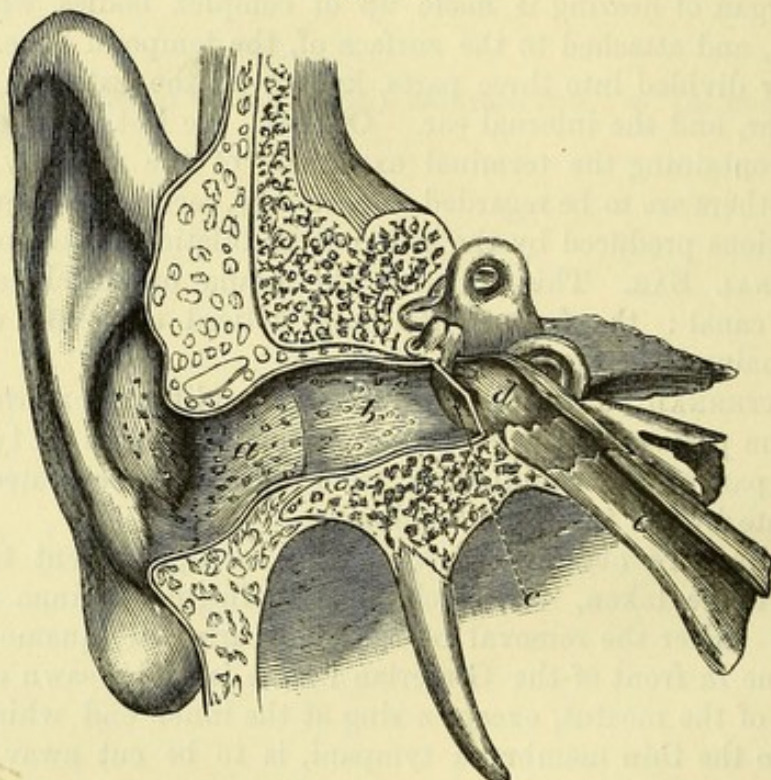
The *osseous part* (b) is about three-quarters of an inch long in the adult, and is slightly constricted about the middle. Its outer extremity is dilated, and the posterior edge projects farther than the

osseous
part,
outer end

inner end. anterior ; the greater portion of the margin is rough, and gives attachment to the cartilage of the pinna. The inner end is smaller, and is marked in the dry bone, except at the upper part where there is a notch in the osseous margin, by a groove for the insertion of the membrane of the tympanum ; it is so sloped that the anterior wall and the floor extend inwards beyond the hinder wall and the roof for nearly a quarter of an inch.

Condition in the foetus. In the foetus the osseous part of the meatus is very imperfect, the floor and anterior wall being composed of fibrous tissue (Symington). After birth the osseous wall is completed by an outgrowth from the ring (tympanic bone) which supports the membrana tympani.

Fig. 230.*



Lining membrane of the skin.

Ceruminous glands.

Vessels.

Nerves.

Lining of the meatus. A prolongation of the integument lines the auditory passage, and is united more closely to the osseous than to the cartilaginous portion ; it is continued over the membrane of the tympanum in the form of a thin pellicle. At the entrance of the meatus are a few hairs. In the subcutaneous tissue over the cartilage of the meatus lie some ceruminous glands of a yellow-brown colour, resembling in form and arrangement the sweat-glands of the skin ; these secrete the ear-wax, and open on the surface by separate orifices ; they are absent in the osseous part, and are most abundant in that small portion of the tube which is formed by fibrous tissue.

Vessels and nerves. The meatus receives its *arteries* from the posterior auricular, the internal maxillary, and the temporal branch of the external carotid (p. 80). Its *nerves* are derived from the auriculo-

* Vertical section of the meatus auditorius and tympanum (Scarpa). *a.* Cartilaginous part of the meatus. *b.* Osseous portion. *c.* Membrana tympani. *d.* Cavity of the tympanum. *e.* Eustachian tube.

temporal branch of the fifth nerve, and enter the auditory passage between the bone and the cartilage (p. 91).

MIDDLE EAR. The chief part of the middle ear is the tympanum or drum, a cavity containing air, which is interposed between the external auditory canal and the labyrinth or internal ear. The space is traversed by a chain of small bones, with which special muscles and ligaments are connected. It communicates in front with the pharynx by a canal named the Eustachian tube; and behind, it is prolonged into a series of excavations in the mastoid part of the temporal bone—the mastoid cells. Small vessels and nerves ramify in the cavity.

Middle ear consists of tympanum,

Eustachian tube, and mastoid cells.

Dissection. The tympanic cavity should be examined in both a dried and a recent bone.

On the dry temporal bone, after removing most of the squamous portion by means of a vertical cut of the saw through the root of the zygoma and the Glaserian fissure, the tympanum will be brought into view by cutting away with the bone-forceps some of the upper surface of the petrous portion, and the anterior part of the meatus auditorius.

to open it in the dry bone,

In the recent bone prepare the dissection as above, but without doing injury to the membrana tympani, the chorda tympani nerve, and the chain of bones with its muscles.

and in the recent bone.

The **TYMPANUM** has the form of a very short cylinder, which is placed obliquely, so that its end-surfaces (the inner and outer walls of the tympanum) are nearer to the median plane in front than behind. The circumference of the cylinder is somewhat irregular, and interrupted at parts: in it a roof, a floor, and an anterior and a posterior wall are distinguished. The cavity measures about half an inch from above down and from before back. Its breadth may be given as one-sixth of an inch; but it is wider above and behind than at the lower and fore parts; and it is narrowest in the centre, owing to the projection towards the cavity of the promontory on the inner wall, and of the tympanic membrane externally.

Tympanum: form and dimensions.

The *inner boundary* of the tympanum (fig. 231) is formed by the outer wall of the osseous labyrinth, by the parts of which the conformation of this surface is mainly determined. Occupying the greater part of the inner wall is a rounded eminence called the *promontory* (*pr*); this becomes narrow behind, and its surface is marked by two or three minute grooves which lodge the nerves of the tympanic plexus. Above and below the narrowed end of the promontory is an aperture: both lead into the labyrinth.

Inner wall is marked by promontory and grooves;

The upper aperture (*fo*) is semicircular in shape, with the convexity upwards, and is named *fenestra ovalis*: it opens into the vestibule, and into it the inner bone (stapes) of the chain is fixed. The lower aperture, *fenestra rotunda* (*fr*), is rather triangular in form, and is situate within a funnel-shaped hollow: in the macerated bone it leads into the cochlea; but in the recent state it is closed by a thin membrane—the secondary membrane of the tympanum.

fenestra ovalis;

fenestra rotunda

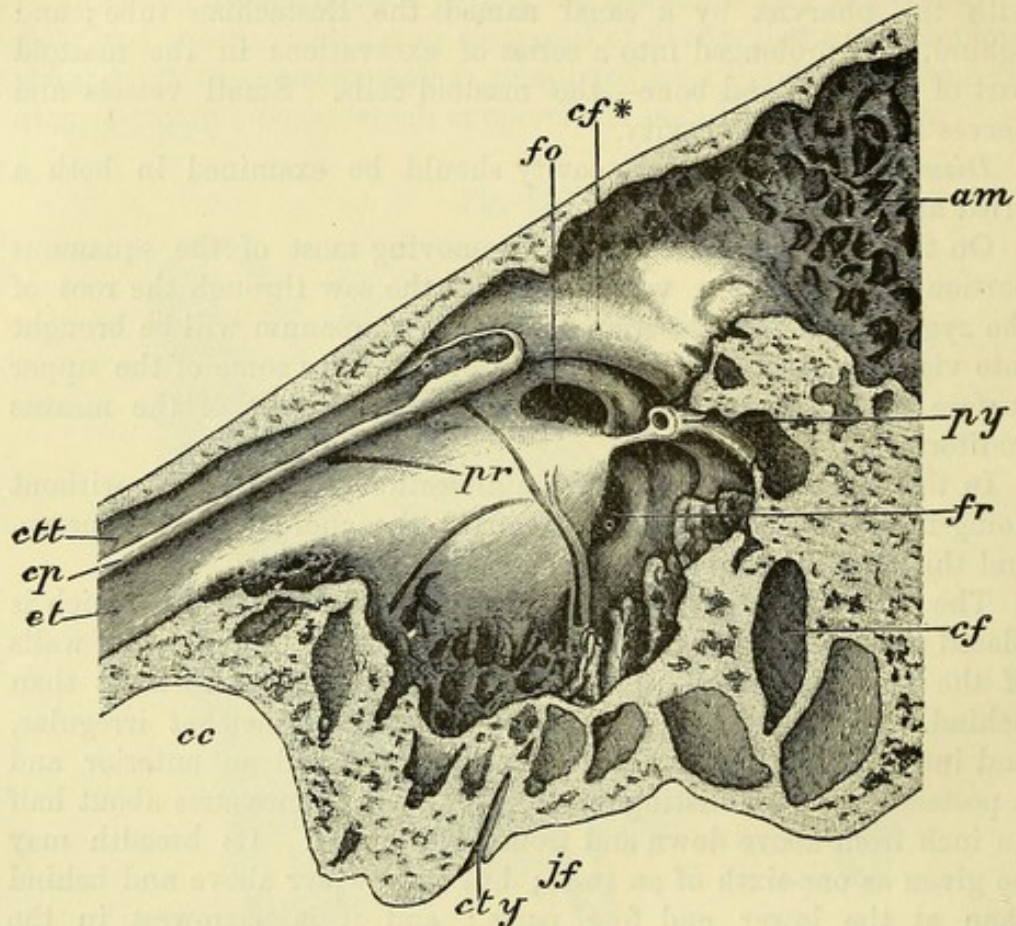
Arching above the fenestra ovalis on this wall is a ridge of bone (*cf**) which marks the situation of the aqueduct of Fallopius, and

ridge of aqueduct of Fallopius

and canal
of tensor
tympani.

contains the facial nerve. Lastly, in front of this ridge, and close to the roof in the fore part of the cavity, is the ending of the *canal for the tensor tympani muscle (ctt)*. The canal is separated from the Eustachian tube (*et*) below it by a thin plate of bone named the *cochleariform process*; this becomes expanded on reaching the

Fig. 231.*



tympanic cavity, and being bent upwards, prolongs the canal beyond the end of the Eustachian tube. In most cases the outer wall of the tympanic portion of the canal is partly formed by fibrous tissue. The aperture by which the tendon of the muscle escapes is placed a little above and in front of the fenestra ovalis.

On outer
boundary,
membrana
tympani
and Glaserian
fissure.

The *outer boundary* of the cavity is formed by the membrana tympani (fig. 230, c), and the surrounding bone. Above and in front of the membrane, is the upper opening of the *Glaserian fissure*, which is occupied in the fresh condition by the long process of one

* Inner wall of the left tympanum : three times the natural size. *pr*. Promontory. *fo*. Fenestra ovalis. *fr*. Fenestra rotunda. *py*. Pyramid. *cf*. Canal of the facial nerve (aqueduct of Fallopius), cut obliquely. *cf**. Ridge formed by the canal of the facial nerve. *am*. Antrum mastoideum. *tt*. Tegmen tympani. *ctt*. Canal of the tensor tympani. *cp*. Cochleariform process. *et*. Eustachian tube. *cc*. Carotid canal. *cty*. Canal of tympanic nerve. *jf*. Jugular fossa.

of the small bones (malleus) and some fibres of its anterior ligament, and by the anterior tympanic vessels. Crossing the membrane towards the upper part is the chorda tympani nerve, which issues through a special aperture close to the Glaserian fissure.

The *roof* (tegmen tympani; fig. 231, *tt*) is a thin plate of bone separating the tympanic cavity from the cranium. It occasionally presents one or more apertures, where the mucous lining of the tympanum comes into contact with the dura mater. The root is sometimes perforated.

The *floor* separates the tympanum from the jugular fossa (fig. 231, *jf*), and is more or less excavated by small cells, which are extensions of the tympanic cavity, and lined by a prolongation of its mucous membrane. Floor is cellular.

An *anterior wall* is present only to the lower half of the space, which it separates from the carotid canal (fig. 231, *cc*); in the upper half is the tympanic orifice of the Eustachian tube. In front is aperture of Eustachian tube.

The *posterior wall* is similarly deficient in the upper half, where there is a large aperture leading into a space called the antrum mastoideum (fig. 231, *am*), from which the mastoid cells are given off. Below this opening, but near the inner wall, and on a level with the narrow part of the promontory, is the small conical projection of the *pyramid* (*py*). At the summit of the pyramid is a small orifice, from which a canal leads backwards and downwards to the aqueduct of Fallopius: the canal lodges the stapedius muscle. Sometimes there is a slender round bar of bone connecting the pyramid to the promontory (fig. 231). Behind are antrum mastoideum and pyramid, with canal of stapedius.

Some objects that have been referred to above, viz., the membrana tympani, the Eustachian tube, the mastoid cells, and the secondary tympanic membrane, require separate notice.

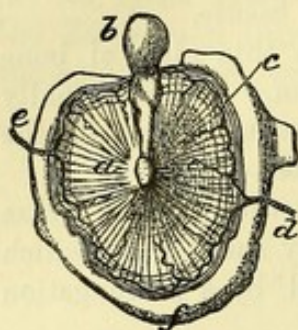
The MEMBRANA TYMPANI (fig. 232) is a thin translucent disc between the external auditory canal and the cavity of the tympanum. It is rather elliptical in shape, and its longest diameter, which is directed from above down, measures about two-fifths of an inch. By its circumference it is attached to a groove at the inner end of the auditory passage. In the foetus it is supported by a separate osseous ring—the tympanic bone (fig. 232, *f*). The membrane is placed very obliquely, so that it forms an angle of about 45° with both a horizontal and a sagittal plane, the outer surface looking downwards and forwards. It is concave towards the auditory canal, being sloped inwards from the circumference to the centre; and it projects into the cavity of the tympanum. The handle of the malleus (one of the ossicles; *b*) is attached to the inner side of the membrane from the centre to the upper margin. Tympanic membrane : form and size attachment; position; is rather funnel-shaped; malleus fixed to it.

Structure. The membrane is formed of three strata,—external, internal, and middle. The outer one is continuous with the integuments of the meatus auditorius; and the inner is derived from the mucous membrane of the tympanum. The middle layer is formed of fibrous tissue, and is fixed to the groove in the bone. From its centre, where it is firmly united to the extremity of the handle of the malleus, fibres radiate towards the circumference; and near the margin, at the inner aspect, lies a band of stronger circular fibres It consists of a cutaneous, a mucous, and a fibrous layer.

(fig. 232, *c*), which bridges across the notch at the upper part of the tympanic bone.

A thin part of the membrane in notch.

Fig. 232.*



Eustachian tube:

Occupying the notch above-mentioned in the upper part of the osseous margin (*notch of Rivinus*), there is a small piece of the membrane which is softer and looser than the rest (*membrana flaccida*), being formed only by lax connective tissue between the skin and the mucous membrane.

The EUSTACHIAN TUBE (fig. 230, *e*) is the channel through which the tympanic cavity communicates with the external air. It is about an inch and a half in length, and is

directed forwards and inwards, as well as somewhat downwards, to the pharynx. Like the meatus auditorius, it is partly osseous and partly cartilaginous in texture.

The *osseous part*, is rather more than half an inch in length, and is narrowest at its anterior end. Its course in the temporal bone is along the angle of union of the squamous and petrous portions, outside the passage for the carotid artery. Anteriorly it ends in a somewhat oval opening, with an irregular margin, which gives attachment to the cartilage.

The *cartilaginous part*. The *cartilaginous part* of the tube is nearly an inch in length, and extends from the temporal bone to the interior of the pharynx (p. 125).

Through this tube the mucous membrane of the drum of the ear is continuous with that of the pharynx; and through it the mucus escapes.

The MASTOID CELLS are air-spaces occupying the interior of the temporal bone behind the tympanum and the external auditory meatus. They reach downwards into the mastoid process, and upwards for a short distance into the adjoining region of the squamous portion of the bone. In front they communicate with the tympanum through a small chamber named the *antrum mastoideum* (fig. 231, *am*). Their size and extent vary greatly in different individuals; and in some cases they are separated only by a very thin layer of bone from the exterior of the skull on the one side, and from the lateral sinus on the other. In the infant the mastoid antrum is present, but the cells are not formed; the latter are developed at, or a little before, the period of puberty.

The SECONDARY MEMBRANE OF THE TYMPANUM is placed in the fenestra rotunda, and is rather concave towards the tympanum, but convex towards the cochlear passage which it closes.

It is formed of three strata, like the membrane on the opposite side of the cavity, viz., an external or mucous, derived from the

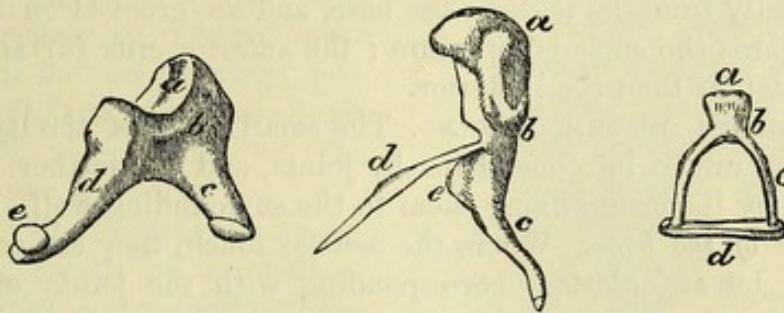
* Inner view of the *membrana tympani* in the foetus, with the malleus attached. *a*. Membrane of the tympanum. *b*. Malleus. *c*. Band of circular fibres at the circumference of the membrane. *d*. Anterior, and *e*, posterior tympanic artery. *f*. Tympanic bone.

lining of the tympanum ; an internal, continuous with that lining of three layers. the cochlea ; and a central layer of fibrous tissue.

OSSICLES OF THE TYMPANUM (fig. 234). Three in number, they are placed in a line across the tympanic cavity. The outer one is named malleus from its resemblance to a mallet ; the next, incus, being compared to an anvil ; and the last, stapes, from its likeness to a stirrup. For their examination the student should be provided with some separate ossicles.

The MALLEUS (fig. 233) is the longest bone, and is twisted and bent. It is large at the upper part (head ; *a*), and small and pointed below (handle ; *c*) ; and it has two processes, with a narrowed part

Fig. 233.*



or neck. The *head* or capitulum (*a*) is free in the cavity, is club-shaped, and at the back has a depression for articulation with the next bone. The *neck* (*b*) is the constricted part between the head and the processes. The *handle* or manubrium (*c*) decreases in size towards the tip, and is compressed from before backwards ; but at the extremity it is flattened from within outwards : to its outer margin the special fibrous stratum of the membrana tympani is connected.

The *short process* (*e*) springs from the root of the handle on the outer side, and is attached to the upper border of the tympanic membrane where it bridges across the notch of Rivinus. The *long process* (processus gracilis ; *d*) is during infancy a slender flattened piece of bone, which projects from the neck of the malleus at the anterior aspect, and extends into the Glaserian fissure ; in the adult this process is most frequently converted into a fibrous band ; and in cases where the osseous process persists, it is joined with the surrounding bone, and cannot be separated.

The INCUS is a flattened bone (fig. 233), and consists of a body and two processes. The *body* (*b*) is hollowed at the fore part (*a*) to articulate with the malleus. The *short process* (*c*) is somewhat conical, and projects backwards nearly horizontally ; its extremity rests against the lower and inner part of the margin bounding the opening into the mastoid antrum. The *long process* (*d*) is almost

* The three tympanic ossicles of the right side : the central bone is the malleus, the left-hand one, incus, and the right-hand one stapes. Malleus : *a*, head ; *b*, neck ; *c*, handle ; *d*, long, and *e*, short process. Incus : *a*, articular surface for malleus ; *b*, body ; *c*, short process ; *d*, long process ; *e*, orbicular process. Stapes : *a*, head ; *b*, neck ; *c*, anterior crus ; *d*, base.

vertical, and descends parallel to the handle of the malleus, behind and internal to which it lies : it diminishes towards the extremity, where it is bent inwards, and ends in a small flattened knob—the *orbicular process* (*e*), for articulation with the stapes.

Stapes : The STAPES (fig. 233) has a base or wider portion, and a head, with two sides or crura, like a stirrup. The *base* (*d*) is directed inwards, and is a thin osseous plate, convex at the upper margin and nearly straight at the lower, corresponding with the shape of the fenestra ovalis, into which it is received : the surface turned to the vestibule is convex, while the opposite is excavated. The *head* (*a*) is marked at the extremity by a superficial depression, which articulates with the orbicular process of the incus ; and it is supported on a slightly constricted part, the *neck* (*b*). The *crura* extend horizontally from the neck to the base, and are grooved on the surface towards the enclosed aperture : the anterior crus (*c*) is shorter and straighter than the posterior.

The bones have two sets of ligaments ; **LIGAMENTS OF THE OSSICLES.** The small bones of the tympanic cavity are united into one chain by joints, and are farther kept in position by ligaments fixing them to the surrounding wall.

either to unite one to another *Joints of the bones.* Where the ossicles touch, they are connected together by articulations corresponding with the joints of larger bones ; for the osseous surfaces are covered with *cartilage*, are surrounded by a thin *capsular ligament* of fibrous tissue, and lubricated by a *synovial sac*. One articulation of this nature exists between the head of the malleus and the incus, and a second between the orbicular process of the incus and the head of the stapes.

by joints, *Union of the bones to the wall.* The bones are kept in place by the reflection of the mucous membrane over them, and by the following ligaments, three being connected with the malleus, and one each with the incus and stapes :—

or to fix them to the tympanic wall. *Ligaments of the malleus.* The *superior* or *suspensory ligament* is a slender band which descends from the roof of the tympanum to the head of the malleus. The *anterior ligament* is the strongest of all : it passes from the fore part of the neck of the malleus to a projection at the anterior margin of the notch of Rivinus, and to the sides of the Glaserian fissure. A part of this ligament entering the fissure has been described as a muscle under the name of *laxator tympani*. The *external ligament* is short and fan-shaped : its fibres radiate from the outer and posterior parts of the neck of the malleus to the edge of the notch.

Ligaments of malleus are superior, anterior, **and external.** The *ligament of the incus* attaches the extremity of the short process of that bone to the tympanic wall at the lower part of the orifice of the antrum mastoideum.

One band to incus, **and one to stapes.** The *annular ligament of the stapes* is composed of very short fibres, which unite the circumference of the base of the stirrup to the margin of the fenestra ovalis.

Membrane in aperture of stapes. *Special ligament of the stapes.* Closing the interval between the crura of the stapes there is a very thin membrane which is attached to the groove of the bone. It is covered above and below by the mucous membrane.

MUSCLES OF THE OSSICLES (fig. 234). Two muscles are connected with the chain of bones, one being attached to the malleus, the other to the stapes. Two muscles to the ossicles.

The TENSOR TYMPANI (fig. 234, *h*) is the larger of the two muscles of the tympanum, and takes the shape of its containing tube, which must be laid open to see it completely. The muscle arises in front from the cartilage of the Eustachian tube and the posterior extremity of the great wing of the sphenoid bone, and it also receives fibres from the surface of its bony canal. Posteriorly it ends in a tendon which is reflected over the end of the cochleariform process, and is inserted into the inner border of the handle of the malleus near its base. Tensor tympani:

Action. The muscle draws inwards the handle of the malleus towards the inner wall of the tympanic cavity, and tightens the membrane of the tympanum; and as the long process of the incus is moved inwards with the malleus, the base of the stapes will be pressed into the fenestra ovalis.

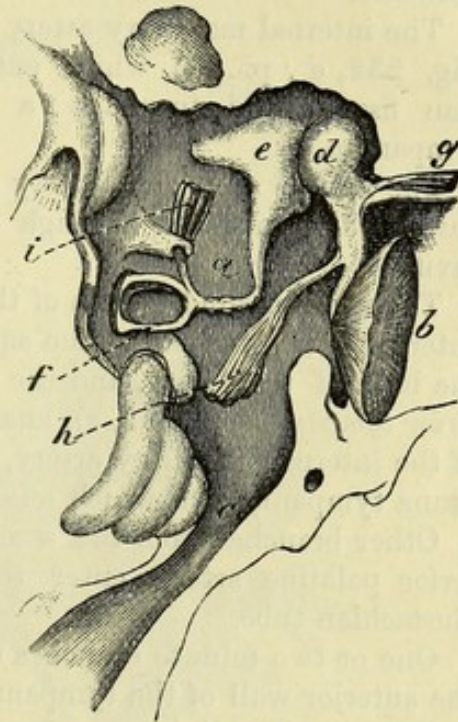
The STAPEDIUS (fig. 234, *i*) is lodged in the canal hollowed in the interior of the pyramid. *Arising* inside the tube, the muscle ends in a small tendon, which issues at the apex of the pyramid, and is inserted into the back of the head of the stapes. Stapedius contained in pyramid;

Action. By directing the neck of the stapes backwards, the muscle raises the fore part of the base out of the fenestra ovalis, diminishing the pressure on the fluid in the vestibule; and supposing it to contract simultaneously with the tensor, it would prevent the sudden jar of the stapes on that fluid. use.

MUCOUS MEMBRANE OF THE TYMPANUM. The mucous lining of the tympanic cavity adheres closely to the wall; it is continuous with that of the pharynx through the Eustachian tube, and is prolonged into the mastoid cells through the antrum. Lining of tympanum

It forms part of the membrana tympani, and of the secondary membrane in the fenestra rotunda; it is reflected also over the chain of bones, the muscles, ligaments, and chorda tympani nerve. In the tympanum the membrane is thin, not very vascular, and secretes a arrangement in cavity; in Eustachian tube.

Fig. 234.*



origin;

insertion;

use.

* Plan of the ossicles of the tympanum in position, with their muscles. *a.* Cavity of the tympanum. *b.* Membrana tympani. *c.* Eustachian tube. *d.* Malleus. *e.* Incus. *f.* Stapes. *g.* Laxator tympani muscle, sometimes described. *h.* Tensor tympani. *i.* Stapedius.

watery fluid ; but in the lower end of the Eustachian tube it is thick and more vascular, and is provided with numerous glands.

Arteries are
branches of
carotids.

BLOOD-VESSELS. The *arteries* of the tympanum are furnished from the following branches of the external carotid, viz., internal maxillary, posterior auricular, and ascending pharyngeal ; and some offsets come from the internal carotid in the temporal bone. The *veins* join the pterygoid plexus, and the large meningeal and pharyngeal branches.

From inter-
nal maxil-
lary,

The internal maxillary artery supplies an *anterior tympanic branch* (fig. 232, *d* ; p. 88), which enters the cavity through the Glaserian fissure, and furnishes a branch to the membrane of the tympanum.

middle
meningeal,

The middle meningeal artery also sends fine twigs to the upper part of the tympanum through small apertures in the roof of the cavity.

posterior
auricular,

The stylo-mastoid branch of the posterior auricular artery (p. 80), entering the lower end of the aqueduct of Fallopius, gives twigs to the back of the cavity, and the mastoid cells. One of this set, *posterior tympanic* (fig. 232, *e*), anastomoses with the tympanic branch of the internal maxillary artery, and forms a circle around the membrana tympani, from which offsets are directed inwards.

inferior
palatine,

Other branches from the ascending pharyngeal, or from the inferior palatine artery, enter the fore part of the space by the Eustachian tube.

internal
carotid.

One or two minute branches of the internal carotid artery reach the anterior wall of the tympanum from the carotid canal (p. 105).

Nerves from
several
sources.

NERVES. The lining membrane of the tympanum is supplied from the plexus (tympanic) between Jacobson's and the sympathetic nerve ; but the muscles derive their nerves from other sources. Crossing the cavity is the chorda tympani branch of the facial nerve.

Dissection
to prepare
the nerves ;

Dissection (fig. 235). The preparation of the tympanic plexus will require a separate fresh temporal bone, which has been softened in diluted hydrochloric acid, and in which the nerves have been hardened afterwards in spirit.

outside
tympanic
cavity,

The origin of Jacobson's nerve from the glosso-pharyngeal is first to be sought close to the skull ; and the fine auricular branch of the pneumo-gastric may be looked for at the same time (p. 107). Supposing the nerve to be found, the student should place the scalpel on the outer side of the Eustachian tube, and carry it backwards through the vaginal and styloid processes of the temporal bone, so as to take away the outer part of the tympanum, but without opening the lower end of the aqueduct of Fallopius.

and inside
cavity.

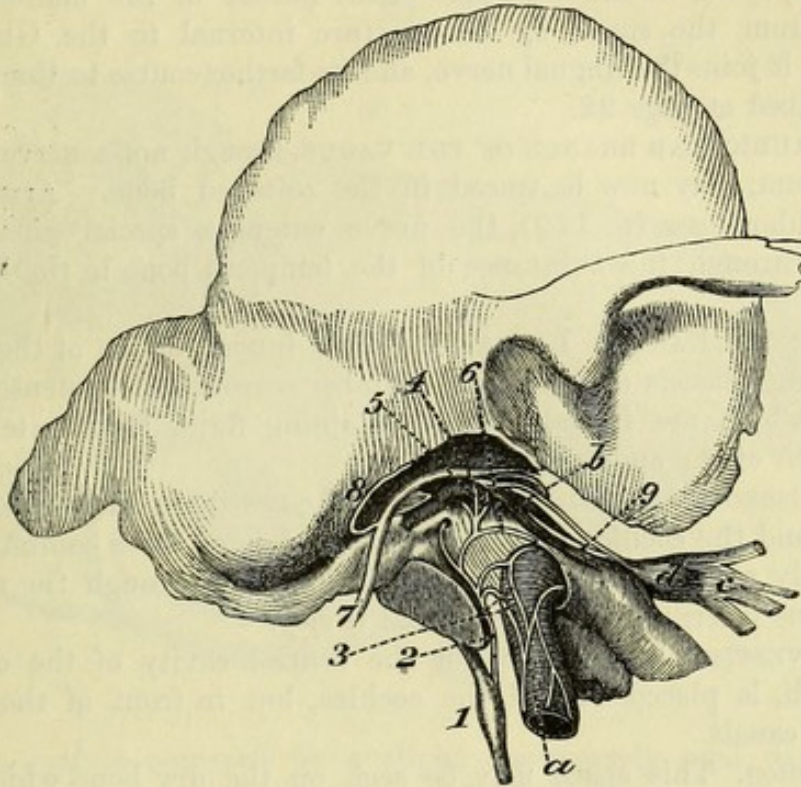
After the tympanum has been laid open, Jacobson's nerve is to be followed in its canal ; and the branches in the grooves on the surface of the promontory are to be pursued ;—two of these, arching forwards, pass to the sympathetic on the carotid artery and to the Eustachian tube ; and two others are directed upwards beneath the tensor tympani muscle.

The course of the chorda tympani nerve can be seen on the preparation used for the muscles.

The TYMPANIC BRANCH OF THE GLOSSO-PHARYNGEAL NERVE (fig. 235,²; nerve of Jacobson, p. 108) enters a special aperture in the temporal bone (fig. 230, *ct*), to reach the inner wall of the tympanum. In this cavity the nerve supplies filaments to the lining membrane, to the fenestra rotunda and fenestra ovalis, and to the

Tympanic nerve
supplies
mucous
membrane,

Fig. 235.*



Eustachian tube; and it terminates in the three undermentioned branches, which are contained in grooves on the promontory, and connect this nerve with others.

Branches. One branch is arched forwards and downwards, and enters the carotid canal to communicate with the sympathetic (3) on the artery (p. 114).

The second (2) is the *small deep petrosal nerve*, which is directed forwards through a canal beneath the cochleariform process, to join the carotid plexus of the sympathetic (sometimes also the large superficial petrosal nerve) in the foramen lacerum.

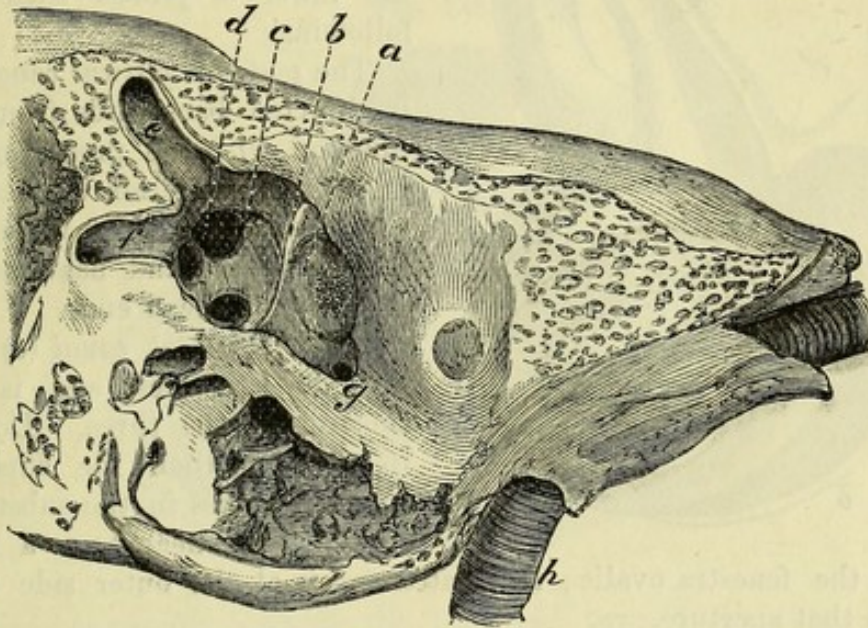
And the third (4) has the following course:—It ascends in front of the fenestra ovalis, and near the gangliform enlargement on the facial nerve, to which it is connected by filaments (fig. 35). Beyond the union with the facial, the nerve is named *small superficial*

* Jacobson's nerve in the tympanum (Breschet). *a.* Carotid artery. *b.* Tensor tympani muscle. *c.* Inferior maxillary trunk of the fifth nerve. *d.* Otic ganglion. *Nerves:* 1. Petrous ganglion of the glossopharyngeal. 2. Nerve of Jacobson. 3. Sympathetic on the carotid. 4. Small superficial petrosal nerve. 5. Small deep petrosal nerve. 6. Branch to Eustachian tube. 7. Facial nerve. 8. Chorda tympani. 9. Nerve of the otic ganglion to the tensor tympani muscle.

- to otic ganglion. *petrosal*, and is continued forwards through the substance of the temporal bone, to end in the otic ganglion (p. 146).
- Nerves for the muscles. NERVES TO MUSCLES. The tensor tympani muscle is supplied by a branch from the otic ganglion (fig. 235, ⁹); and the stapedius receives an offset from the facial trunk.
- Chorda tympani crosses cavity. The CHORDA TYMPANI (fig. 235, ⁸) is a branch of the facial nerve (p. 145). Entering the cavity behind, it crosses the membrana tympani, lying on the inner side of the handle of the malleus, and issues from the space by an aperture internal to the Glaserian fissure; it joins the lingual nerve, and its farther course to the tongue is described at page 92.
- Branch of vagus to the outer ear. The AURICULAR BRANCH OF THE VAGUS, though not a nerve of the tympanum, may now be traced in the softened bone. Arising in the jugular fossa (p. 110), the nerve enters a special canal, and crosses through the substance of the temporal bone to the back of the ear.
- Labyrinth formed of osseous and membranous parts. INTERNAL EAR OR LABYRINTH. The inner portion of the organ of hearing consists of a complex chamber surrounded by dense bone, within which are included sacs containing fluid, for the terminal expansion of the auditory nerve.
- Constituents of the osseous part. The OSSEOUS LABYRINTH comprises the vestibule, the semicircular canals, and the cochlea: in the macerated bone these communicate externally with the tympanum, and internally, through the meatus auditorius internus, with the cranial cavity.
- Vestibule: The VESTIBULE (fig. 236), or the central cavity of the osseous labyrinth, is placed behind the cochlea, but in front of the semicircular canals.
- dissection to see it; *Dissection.* This space may be seen on the dry bone which has been used for the preparation of the tympanum. The bone is to be sawn through vertically close to the inner wall of the tympanum, so as to lay bare the fenestra ovalis leading into the vestibule. By enlarging the fenestra ovalis a very little in a direction upwards and forwards, the vestibular space will appear; and the end of the superior semicircular canal will be opened.
- Other views of the cavity may be obtained by sections of the temporal bone in different directions, according to the opportunities and skill of the dissector.
- form and dimensions; The *vestibular space* (fig. 236) is ovoidal in form, and the extremities are directed forwards and backwards. The larger end is turned back, and the under part or floor is more narrowed than the upper part or roof. It measures about one-fifth of an inch in length; but it is narrower from without inwards. The following objects are to be noted on the boundaries of the space.
- apertures before and behind; In front, close to the outer wall, is a large aperture (*g*) leading into the cochlea; and behind are five round openings of the three semicircular canals (*d, e, f*).
- in outer wall; The outer wall corresponds with the tympanum, and in it is the aperture of the fenestra ovalis. On the inner wall, nearer the front than the back of the cavity, is a vertical ridge or *crest* (*b*). In front of the crest is a circular depression, *fovea hemispherica* (*a*),
- crest on inner wall, with fossa in front,

which is pierced by minute apertures for nerves and vessels, and corresponds with the bottom of the internal auditory meatus. Behind the crest of bone, near the common opening of two of the semicircular canals, is the aperture of the *aqueduct of the vestibule* (c), a narrow canal which ends on the posterior surface of the petrous portion of the temporal bone: it contains a process of the membranous labyrinth called the ductus endolymphaticus, and a small vein. and aque-
duct behind;

Fig. 236.*



The roof is occupied by a slight transversely oval depression, *fossa in roof*, *fovea hemielliptica*; this is separated from the *fovea hemispherica* by a prolongation of the crest (b) on the inner wall.

The SEMICIRCULAR CANALS (fig. 237) are three osseous tubes, Three semi-
circular
canals: which are situate behind the vestibule, and are named from their form.

Dissection. These small canals will be easily brought into view by the removal of the surrounding bone by means of a file or bone forceps. Two may be seen opening near the aperture made in the vestibule, and may be followed thence; but the third is altogether towards the posterior aspect of the petrous portion of the temporal bone. preparation
of them;

The *canals* are unequal in length, and each forms more than half an ellipse. They communicate at each end with the vestibule, but the contiguous ends of two are blended together so as to give only five openings into that cavity. Each is marked by one dilated extremity which is called the *ampulla*. When a tube is cut across length;
termination
by five open-
ings;
one end
dilated;

* View of the vestibule obtained by cutting away the outer boundary in a foetus, enlarged three times. a. Fovea hemispherica. b. Crest of the vestibule. c. Aperture of aqueduct of the vestibule. d. Common opening of two semicircular canals. e. Upper semicircular canal, partly laid open. f. Horizontal semicircular canal, partly opened. g. Opening of the scala vestibuli of the cochlea.

form and
size ;

they are
named

superior
vertical,

posterior
vertical,

and hori-
zontal.

Fibrous
membrane
lines the
labyrinth,

and contains
a fluid.

Cochlea :

dissection
for it in dry

and recent
bone ;

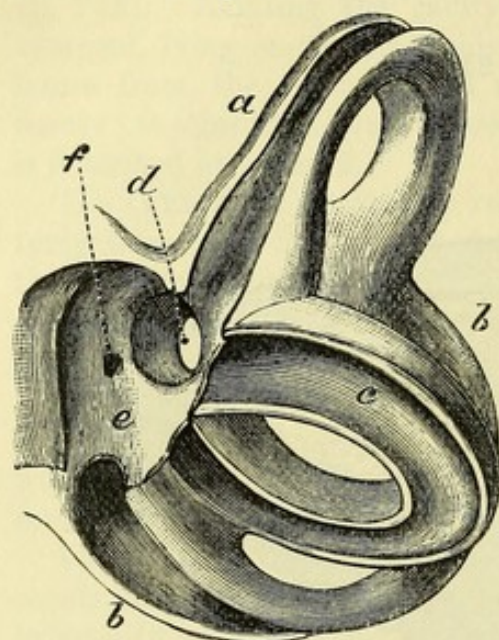
form and
situation ;

it is not circular, but is compressed laterally, and measures about $\frac{1}{20}$ th of an inch, though in the ampulla the size is as large again.

From a difference in the direction of the tubes, they have been named superior vertical, posterior vertical, and horizontal.

The *superior vertical canal* (a) crosses the upper border of the petrous part of the temporal bone, and forms a projection on the surface. Its outer end is marked by the ampulla, while the inner is joined with the following.

Fig. 237.*



The *posterior vertical canal* (b) is directed backwards from its junction with the preceding towards the posterior surface of the temporal bone ; it is the longest of all, and has its ampulla at the lower end.

The *horizontal canal* (c) has separate apertures, and is the shortest of the three. Deeper in position than the superior vertical, it lies in the substance of the bone nearly on a level

with the fenestra ovalis ; its dilated end is at the outer side close above that aperture.

Lining membrane of the osseous labyrinth. A thin fibrous periosteal membrane lines the vestibule and the semicircular canals, and is continuous with the fibrous process in the aqueduct of the vestibule. On the outer wall of the cavity it stretches over the fenestra ovalis ; and in front it is prolonged into the cochlea through the aperture of the scala vestibuli (fig. 236, g). The space between the periosteum and the membranous labyrinth is occupied by a thin fluid—*liquor Cotunnii* or *perilymph*, which also fills the scalæ of the cochlea.

COCHLEA. This part of the osseous labyrinth has a position anterior to the vestibule, and has received its name from its resemblance to a spiral shell.

Dissection. To obtain a view of the cochlea it will be needful to cut or file away the bone between the promontory of the tympanum and the internal auditory canal on the preparation before used for displaying the vestibule ; or this section may be made on another temporal bone in which the semicircular canals are not laid bare. For the like dissection in the recent state, a softened bone should be used.

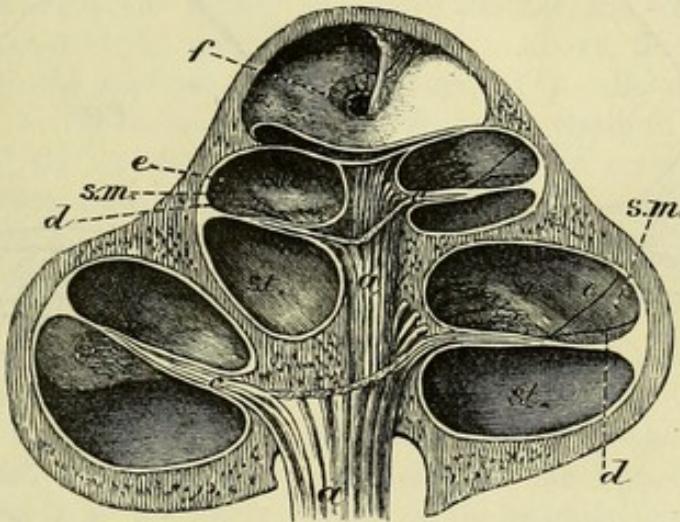
The *cochlea* (fig. 238) is conical in form, and is placed almost horizontally in front of the vestibular space. The base of this body

* Representation of the semicircular canals enlarged (from a model in University College Museum). a, Upper vertical ; b, posterior vertical ; and c, horizontal canal. d, Common opening of the two vertical canals. e, Part of the vestibular cavity. f, Opening of the aqueduct of the vestibule.

is turned to the meatus auditorius internus, and is perforated by small apertures; while the apex is directed to the inner wall of the tympanum, opposite the canal for the tensor muscle. Its length is ^{size;} about a quarter of an inch, and its width at the base is about the same. Resembling a spiral shell, the cochlea consists of a tube ^{resembles a snail-shell in some respects.} wound round a central part or axis; but it differs from the shell in having its tube subdivided by a partition.

The *axis* or *modiolus* (fig. 238, *a*) is the central stem which supports the windings of the spiral tube. Conical in shape, its size ^{Central pillar or axis}

Fig. 238.*



diminishes rapidly towards the last half turn of the tube, but it is conical, enlarges at the tip of the cochlea, forming a second small cone (*b*), which is bent. The axis is perforated by canals as far as the con- and porous. tracted part in the last half-turn, and the central one is larger than the others; these transmit vessels and nerves in the fresh state.

The *spiral tube* forms two turns and a half round the stem, and terminates above in a closed extremity named the *cupola*. When measured along the outer side, it is about one inch and a half long. Its diameter at the beginning is about one-tenth of an inch, but it diminishes gradually to half that size towards the opposite end. ^{A spiral tube, closed at one end, forms $2\frac{1}{2}$ turns; measurement; coils.}

Of the coils that the tube makes, the first is much the largest; this projects towards the tympanum, and gives rise to the eminence of the promontory on the inner wall of that cavity. The second turn is included within the first coil. The last half-turn bends sharply round, and presents a free margin (*b*)—the edge of the axis.

In the recent bone the tube is divided into two main passages ^{Tube divided into two.} (scalæ) by the septum (fig. 238, *c*). In the dry bone a remnant of this partition is seen in the form of a thin osseous plate—*lamina spiralis*, projecting from the axis.

SEPTUM OF THE SPIRAL TUBE (fig. 239). The partition in the ^{Septum bony and membranous.}

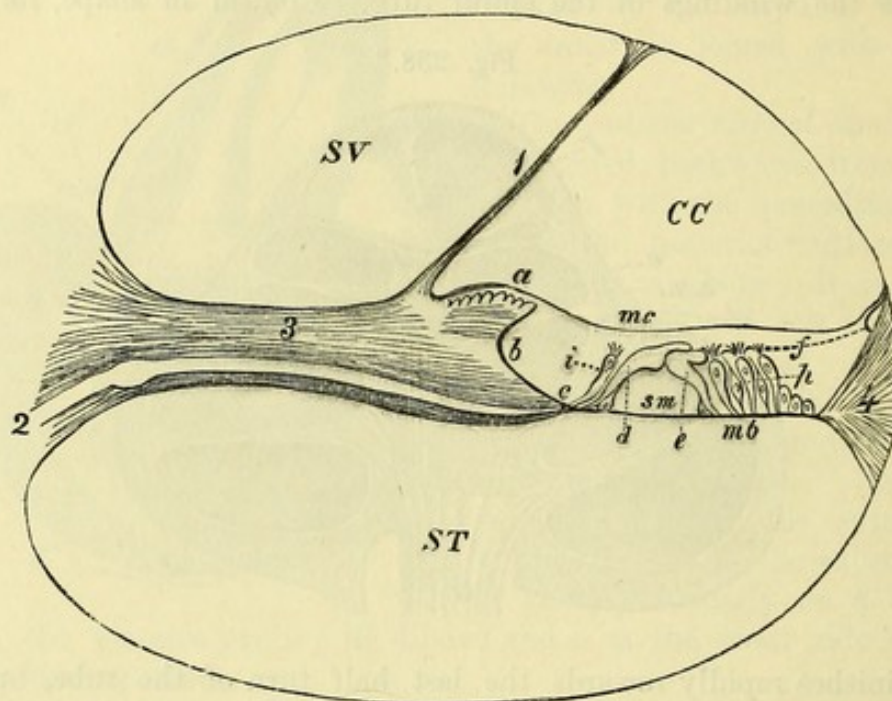
* Section through the cochlea (Breschet). *a*. Branches of the auditory nerve, contained in the canals of the axis. *b*. Enlarged upper end of the axis. *c*. Septum of the cochlea. *e*. Membrane of Reissner. *f*. Hiatus or helicotrema. *s.t.* Scala tympani. *s.v.* Scala vestibuli. *s.m.* Scala media or canal of the cochlea.

recent state dividing the tube of the cochlea into two passages, consists of an osseous and a membranous portion :—

Osseous
part

The *osseous part* (³), formed by the lamina spiralis, extends about half-way across the tube. Inferiorly it begins in the vestibule, where it is wide, and is attached to the outer wall so as to shut out the fenestra rotunda from that cavity ; and diminishing in size, it ends

Fig. 239*.



ends above
in a point

over an
aperture.

Lamina
spiralis

has limbus
on upper
surface.

Spiral
groove.

Mem-
branous
part

above in a point—the *hamulus*, opposite the last half-turn of the cochlea. Between the hamulus and the axis is a space, which is converted by the membranous piece of the septum into a foramen (*hiatus, helicotrema* ; fig. 238, *f*), and allows the intercommunication of the two chief passages of the cochlear tube.

The lamina spiralis is formed by two plates of bone, which enclose canals for vessels and nerves, and are separated farthest from each other at the axis. The upper surface of the lamina is covered in the outer fourth of its extent by a border or *limbus* of fibrous structure (*a*), which ends in wedge-shaped teeth near the margin of the bony plate.

Between the teeth and the underlying bone is a channel (*b*) which is called *sulcus spiralis* : its edges are named vestibular (*a*) and tympanic (*c*).

The *membranous part of the septum* (*membrana basilaris* ; fig. 239,

* A diagram of a section of the tube of the cochlea, enlarged (modified from Henle). SV. Scala vestibuli. ST. Scala tympani. CC. Canal of the cochlea. 1. Membrane of Reissner. 2. Cochlear branch of the auditory nerve. 3. Lamina spiralis ossea. 4. Ligamentum spirale. *a*. Limbus laminae spiralis. *b*. Sulcus spiralis. *c*. Tympanic lip of the sulcus spiralis. *mb*. Membrana basilaris. The remaining letters refer to parts of the organ of Corti.

m b) reaches from the lower (tympanic) edge (*c*) of the lamina spiralis to the outer wall of the cochlear tube, where it is fixed by a fibrous band—*ligamentum spirale* (¹). Its width varies, for near the base of the cochlea it forms half of the partition across the tube; but at the apex, where the lamina spiralis is wanting, it constructs the septum altogether.

includes
basilar mem-
brane
and spiral
ligament.

SCALÆ OF THE COCHLEA (fig. 238). The tube of the cochlea is divided by the septum into two primary passages, of which one is the *scala tympani* (*st*), and the other *scala vestibuli* (*sv*); but the latter is rendered smaller by a third canal being cut off from it by membrane.

Scala of
the coch-
lear tube :

These passages are placed one above another, the *scala vestibuli* (*sv*) being nearest the apex of the cochlea. Above, they communicate through the aperture named helicotrema (*f*). Below, they end differently, as the names express;—the *scala vestibuli* opens into the front of the vestibule (fig. 236, *g*); but the *scala tympani* is shut out from the vestibular cavity by the lamina spiralis of the septum cochleæ, and is closed below by the membrane of the fenestra rotunda, though in the dry bone it opens into the tympanum.

position ;
extent ;
joined
above ;
separate
below ;

Each has certain peculiarities. The vestibular scala extends into the apex of the cochlea; while the tympanic scala is largest near the base. Connected with the last is the small *aqueduct of the cochlea*, which begins at an opening close to the lower end of the scala, and ends at the lower border of the petrous portion of the temporal bone: it transmits a small vein from the cochlea.

they differ
in extent
and size ;
opening in
lower ;

The scalæ are clothed with a thin fibrous membrane, continuous with that in the vestibule: in the *scala tympani* it helps to close the fenestra rotunda, forming the inner layer of the secondary membrane of the tympanum, and joins the fibrous process in the aqueduct of the cochlea. The perilymph fills both scalæ.

lining
membrane,

and con-
tents.

CANAL OF THE COCHLEA. In the upper division of the cochlear tube a fine membrane (fig. 239,¹) extends obliquely across from the upper surface of the lamina spiralis, at the inner border of the limbus, to the outer wall of the cavity a little above the spiral ligament. This is called the *membrane of Reissner*, and separates a small cavity named the *canal or duct of the cochlea* (*cc*) from the *scala vestibuli* (*sv*). The canal thus formed extends from apex to base of the cochlea, and contains a fluid—*endolymph*. Above, it reaches into the cupola and is closed. Below, it is connected by a very small tube (*canalis reuniens*; fig. 240, *c*) with the saccule in the vestibule. Within the canal of the cochlea, resting on the basilar membrane, is the complicated structure known as the *organ of Corti* (fig. 239), in which the cochlear branches of the auditory nerve end.

Cochlear
canal is
between
basilar
membrane
and mem-
brane of
Reissner ;

joined by
duct from
saccule
below ;

contains
organ o
Corti.

MEMBRANOUS LABYRINTH (fig. 240). Lodged in the vestibule are two membranous sacs, the utricle and saccule, from the former of which tubular offsets are continued into the semicircular canals. These, together with the canal of the cochlea and the organ of Corti, which have been referred to above, make up the membranous labyrinth. The sacs and their prolongations are immersed in the

The mem-
branous
labyrinth
consists of
utricle,
saccule,
semicircular
canals, and
cochlear
canal.

perilymph, and are themselves filled with a fluid called the *endolymph*. In them the ramifications of the auditory nerve are distributed.

Dissection
of them in a
fresh bone.

Dissection. The delicate internal sacs of the ear, with their nerves, cannot be dissected except on a temporal bone which has been softened in acid, and afterwards put in spirit. The previous instructions for the dissection of the osseous labyrinth will guide the student to the situation of the membranous structures within it, but the surrounding softened material must be removed with great care.

Utricle :

The UTRICLE (fig. 240, *d*), or the common sinus, is the

situation,

Fig. 240.*

and form ;

macula,

and otoliths.

Semicircular
canals :

not free in
cavity ;

have
ampullæ,

which re-
ceive the
nerves.

Sacculæ

has com-
munications
with utricle
and cochlea ;
macula and
otoliths.

larger of the two sacs, and is situate at the posterior and upper part of the vestibule, opposite the fovea hemielliptica in the roof. It is transversely oval in form, and connected with it posteriorly are three looped tubes, which occupy the semicircular canals. At the fore part of the sac is a thickened and more opaque part of its wall—*macula acustica* (*e*), where the nerves enter ; and opposite this, in the interior, is a small mass of calcareous granules or *otoliths*.

The MEMBRANOUS SEMI-CIRCULAR CANALS (*g*) are about one-third of the diameter of the osseous tubes, along the convex border of which they lie, being closely attached to the periosteal lining of the bony wall ; and the remaining space is filled by perilymph. Each is marked at one end by an ampulla, which is relatively of large size and nearly fills the osseous case. Two are blended at one end, like the canals they occupy, so that they communicate with the utricle by five openings. At each ampullary enlargement there is a transverse projection (*crista acustica*) into the interior of the tube ; and at that spot a branch of the auditory nerve enters the wall.

The SACCULE (fig. 240, *a*) is a smaller and rounder cyst than the utricle, in front of which it is placed, in the hollow of the fovea hemispherica. It communicates with the utricle through the ductus endolymphaticus, and is continuous below by a short and small passage (*canalis reuniens* ; *c*) with the canal of the cochlea. Like the other sac, it possesses a macula (*b*) and otoliths where the nerves enter.

* Petrous bone partly removed to show the membranous labyrinth in place (Breschet). *a*. Sacculæ ; *b*, its macula. *c*. Ductus reuniens. *d*. Utricle ; *e*, its macula. *f*. Ampullary enlargement of a semicircular canal, *g*.

The *ductus endolymphaticus* is a fine tubular offset of the membranous labyrinth, which occupies the aqueduct of the vestibule, and ends in a dilated blind extremity (*sacculus endolymphaticus*), embedded in the dura mater on the posterior surface of the petrous portion of the temporal bone. In the vestibule the duct divides into two small branches, one of which joins the saccule, and the other the utricle.

Endolymphatic duct and sac;

it opens into saccule and utricle.

For an account of the minute structure of the membranous labyrinth, reference must be made to a work on microscopic anatomy.

NERVE OF THE LABYRINTH. A special nerve, the eighth cranial or *auditory* (p. 189), is distributed to the labyrinth. Entering the internal auditory meatus with the facial nerve (p. 145), it divides into an upper smaller, and a lower larger piece, each of which again subdivides into three branches. At the bottom of the meatus, the upper piece is marked by a ganglionic swelling—the *intumescencia ganglioformis* of Scarpa.

The *upper division* of the nerve sends its branches to the macula of the utricle (fig. 241, *c*), to the ampulla of the superior vertical semicircular canal, and to the ampulla of the external semicircular canal.

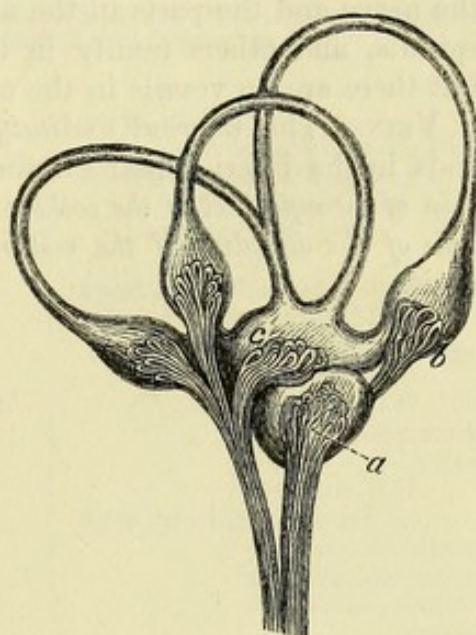
From the *lower division* of the nerve proceed an offset to the saccule (*a*) and a slender branch to the ampulla of the posterior vertical semicircular canal (*b*); but the greater part is destined for the cochlea.

Each of the branches of the auditory nerve breaks up into a bundle of filaments, which pass through minute apertures of the lamina cribrosa, to reach their special part of the membranous labyrinth. The nerves of the semicircular canals enter the ampullæ on their outer flattened side, and end in the crista acustica; while those of the sacs end in the respective macula.

The cochlear nerves traverse the canals of the modiolus, and bend outwards in the passages of the lamina spiralis (fig. 239,²). As they enter the latter, they join a ganglion (*ganglion spirale*) which occupies a winding canal at the junction of the lamina spiralis with the modiolus; and from this they are continued as fine branches, forming a close plexus, to the organ of Corti.

Auditory nerve

Fig. 241.*



divides into two parts;

upper has ganglion,

and supplies utricle, superior and external canals;

lower gives branches to saccule, posterior canal, and cochlea;

ending of vestibular branches;

cochlear nerve has a spiral ganglion,

and ends in organ of Corti.

* Distribution of nerves to the membranous labyrinth (Breschet). *a*. Nerve to the saccule. *b*. Nerve entering the ampullary enlargement on the posterior semicircular canal. *c*. Nerve entering the utricle. The nerve to the cochlea is not represented.

Vessels of
labyrinth.

BLOOD-VESSELS. The membranes of the labyrinth are supplied by an artery which enters the internal auditory meatus with the auditory nerve. The veins are more numerous.

Auditory
artery from
basilar,
has a

The **INTERNAL AUDITORY ARTERY** arises from the basilar trunk within the skull (p. 184), and divides in the internal auditory meatus into two branches,—one for the vestibule, and the other for the cochlea.

vestibular,

The *vestibular artery* subdivides into small offsets which enter the cavity with the branches of the auditory nerve, and ramify over the sacs and the semicircular canals.

and a
cochlear
branch.

The *cochlear branch* breaks up into numerous fine twigs which enter the modiolus and the canals in the lamina spiralis. Offsets supply the nerve and the parts in the neighbourhood of the limbus laminae spiralis, and others ramify in the periosteal lining of the scalæ; but there are no vessels in the outer part of the membrana basilaris.

Veins to
petrosal
sinuses and
internal
jugular.

VEINS. The *internal auditory vein* accompanies the artery, and ends in the inferior petrosal sinus in the base of the skull. The *vein of the aqueduct of the cochlea* joins the internal jugular; and the *vein of the aqueduct of the vestibule* opens into the superior petrosal sinus.

INDEX.

The letter (o) refers to the origin, (c) to the course, and (d) to the distribution of a nerve or vessel which is described in different pages.

- ABDOMEN**, cavity of, 465.
 surface of, 435.
Abdominal aorta, 484, 527.
 hernia, 454.
 regions, 466.
 ring, external, 442.
 internal, 450, 457.
Abducent nerve, (o) 189, (c) 18, (d) 47.
Abductor. *See* Muscle.
Accessorius. *See* Muscle.
Accessory nerve of the obturator, 537, 625.
 pudic artery, 430, 559.
 spleens, 504.
Acromial cutaneous nerves, 57, 263.
Acromio-clavicular articulation, 268.
 thoracic artery, 253.
Adductor. *See* MUSCLE.
Agminated glands, 499.
Air-cells of the lung, 361.
Ala cinerea, 234.
 of nose, 30.
Alar ligaments of the knee, 695.
 thoracic artery, 253.
Alveolar plexus, 89.
Ampullæ, of the semicircular canals, 741.
 membranous, 746.
Amygdaloid lobe of cerebellum, 230.
Anal fascia, 418, 427.
Anastomotic artery. *See* Artery.
Anconeus muscle, 310.
Angular artery, 27.
 convolution, 209.
 vein, 6, 27.
Ankle-joint, 701.
Annectant convolutions, 209.
Annular ligament. *See* Ligament.
Annular protuberance, 198.
Annulus ovalis, *s. Vieussenii*, 342.
Ansa hypoglossi, 77.
 Vieussenii, 114.
Anterior commissure, 223.
Antihelix, 33.
Antitragus, 33.
 muscle of, 34.
Antrum mastoideum, 734.
Antrum of superior maxilla, 136.
Anus, 416, 432.
Aorta, 352.
 abdominal, 484, 527.
 arch of, 352.
 descending thoracic, 363.
Aortic opening in diaphragm, 524.
 orifice of heart, 348.
 plexus, 483.
 sinus, 353.
Aperture of the aorta, 348.
 of the cavæ, 343.
 for the femoral artery, 629.
 of the heart, 348.
 larynx, 127, 158.
 pulmonary artery, 345.
 veins, 346.
 thorax, 117.
Aponeurosis, epicranial, 3.
 of external oblique, 441.
 over femoral artery, 616.
 intercostal, anterior, 258.
 posterior, 370.
 of internal oblique, 444.
 lumbar, 386.
 palmar, 296.
 perineal, deep, 427.
 of the pharynx, 122.
 plantar, 670.
 of the soft palate, 128.
 temporal, 4.
 over tibialis posticus, 667.
 of the transversalis muscle, 447.
 vertebral, 389.
Appendages of the eye, 30.
Appendices epiploicæ, 469, 501.
Appendix auriculæ, 340, 342, 346.
 vermiformis, 470, 501.
Aqueduct of the cochlea, 745.
 of Fallopius, 731.
 of Sylvius, 221, 224, 226.
 of the vestibule, 741.
Aqueous humour, 724.
Arachnoid membrane of the brain, 181.
 of the cord, 406.
Arantii, corpus, 345, 348.
Arbor vitæ cerebelli, 233.
 uterinus, 583.
Arch of aorta, 352.
 crural or femoral, deep, 452.
 superficial, 452, 606.
 of diaphragm, 524.

Arch, palmar, deep, 304.
 superficial, 297.
 plantar, 679.
 of soft palate, 128.
 Arciform fibres, 194, 196.
 nuclei, 198.
 Areola of the mamma, 245.
 Arm, dissection of, 270.
 Arnold's nerve, 110, 740.
 Arteria comes nervi ischiadici, 639.
 phrenici, 259, 357.
 pancreatica magna, 487.
 thyroidea ima, 119.
 Arteriæ receptaculi, 19.
 Arterial duct, 352.
 Artery or Arteries :—
 acromio-thoracic, 253.
 anastomotic of brachial, 276.
 of femoral, 618.
 angular, 27.
 aorta abdominal, 484, 527.
 thoracic, 352, 363.
 articular of knee, azygos, 648.
 inferior, 648.
 superior, 648.
 auricular, anterior, 81.
 deep, 88.
 posterior, 6, 80.
 auditory, 184, 748.
 axillary, 251.
 basilar, 183.
 brachial, 274.
 brachio-cephalic, 354.
 bronchial, 362, 363.
 buccal, 88.
 of bulb, 430.
 calcaneal, internal, 674.
 capsular, inferior, 528.
 middle, 528.
 superior, 528.
 carotid, common, left, 117, 354.
 right, 74.
 external, 77.
 internal, 19, 102, 184.
 carpal, radial, anterior, 289.
 posterior, 313.
 ulnar, anterior, 292.
 posterior, 292.
 central of retina, 45, 725.
 cerebellar, anterior, 184.
 inferior, 183.
 superior, 184.
 cerebral, anterior, 185.
 middle, 185.
 posterior, 184.
 cervical, ascending, 70.
 deep, 71, 397.
 superficial, 388.
 transverse, 70, 388.
 choroid of brain, 183, 184, 185, 219.
 ciliary, anterior, 46, 723.
 long, 46, 723.
 posterior, 45, 723.
 circumflex, anterior, 254, 264.
 external, 621.
 iliac, deep, 454.
 superficial, 439, 601.
 internal, 628, 643.

Artery or arteries :—
 circumflex, posterior, 254, 264.
 coccygeal, 639.
 cochlear, 748.
 coeliac, 487.
 colic, left, 481.
 middle, 480.
 right, 480.
 communicating, anterior, 185.
 posterior, 184.
 plantar, 679.
 coronary, of heart, 340.
 of lips, 27.
 of stomach, 487.
 of corpus cavernosum, 430, 434, 577.
 cremasteric, 452, 454.
 crico-thyroid, 79, 162.
 cystic, 489.
 deep femoral, 613, 627.
 deferential, 522, 559.
 dental, anterior, 101.
 inferior, 87, 91.
 posterior, 89.
 diaphragmatic, 528.
 digital, of foot, 673, 679, 680.
 of hand, 297, 304.
 dorsal, of clitoris, 434, 440.
 of foot, 680, 688.
 of index finger, 314.
 of penis, 430, 440.
 scapular, 254, 269.
 of thumb, 314.
 of tongue, 96.
 epigastric, deep, 453.
 superficial, 438, 601.
 superior, 453.
 ethmoidal, anterior, 46, 143.
 posterior, 46, 143.
 facial, 27, 79.
 transverse, 28, 81.
 femoral, 612, 616.
 deep, 613, 627.
 frontal, 5, 46.
 gastric, 487, 496.
 gastro-duodenal, 488.
 epiploic, left, 487.
 right, 488.
 gluteal, 558, 637.
 hæmorrhoidal, inferior, 421.
 middle, 559.
 superior, 482, 561, 579.
 hepatic, 487, 509, 510.
 hyoid of lingual, 96.
 of thyroid, 79.
 hypogastric, 557.
 iliac, common, 529.
 external, 529.
 internal, 556.
 ileo-colic, 480.
 ilio-lumbar, 557.
 incisor, 92.
 infraorbital, 89, 101.
 infrascapular, 254, 262.
 innominate, 357.
 intercostal, anterior, 260.
 aortic, anterior branches, 260, 364, 453.

Artery or arteries :—

- intercostal, aortic, posterior branches, 364, 397.
- superior, 71, 365.
- interosseous, of foot, 689.
- of forearm, 291.
- anterior, 294.
- posterior, 312.
- of hand, 304, 313.
- intestinal, 479.
- intraspinal, 414.
- labial, inferior, 27.
- lacrimal, 33, 45.
- laryngeal, inferior, 70, 162.
- superior, 79, 162.
- lingual, 79, 96.
- lumbar, 527, 537.
- anterior branches, 453, 538.
- posterior branches, 398.
- malleolar, 667, 688.
- mammary, external, 253.
- internal, 70, 259, 357, 453, 529.
- masseteric, 88.
- maxillary, internal, 87, 142.
- median, 294.
- mediastinal, 259, 364.
- medullary, of femur, 628.
- of fibula, 668.
- of humerus, 276.
- of radius, 294.
- of tibia, 667.
- of ulna, 294.
- meningeal, anterior, 15.
- of ascending pharyngeal, 15, 16, 106.
- large, 15, 88.
- middle, 15.
- of occipital, 16, 80.
- posterior, 16, 182.
- small, 15, 88.
- of vertebral, 16, 182.
- mesenteric, inferior, 481.
- superior, 479.
- metacarpal, radial, 313.
- ulnar, 292.
- metatarsal, 689.
- musculo-phrenic, 260, 529.
- mylo-hyoid, 88.
- nasal, external, 46.
- internal, 46, 143.
- of internal maxillary, 143.
- lateral, 27.
- of septum narium, 27.
- of septum nasi, 143.
- naso-palatine, 143.
- obturators, 559, 630.
- occipital, 6, 80, 397.
- oesophageal, 364, 487.
- ophthalmic, 19, 45.
- orbital (of temporal), 81.
- ovarian, 528, 560, 586.
- palatine, inferior, 79.
- superior, 142.
- palpebral, 33, 46.
- pancreatic, 487.
- pancreatico-duodenal, 479, 488.
- parotid, 81.

Artery or arteries :—

- perforating of femoral, 628, 653.
- of foot, 679, 689.
- of hand, 304.
- of internal mammary, 260.
- pericardial, 364.
- perineal, superficial, 424.
- transverse, 424.
- peroneal, 668.
- anterior, 668.
- petrosal, 15.
- pharyngeal, ascending, 106.
- phrenic, inferior, 528.
- superior, 259, 357, 529.
- plantar, external, 674.
- internal, 672.
- popliteal, 646.
- prevertebral, 106.
- profunda of arm, inferior, 276.
- superior, 276, 281.
- of palm, 297.
- of thigh, 613, 627.
- pterygoid, 88, 143.
- pterygo-palatine, 143.
- pubic, 453, 559.
- pudic, accessory, 430, 559.
- external, 438, 601, 612.
- internal, 421, 429, 434, 559, 639.
- pulmonary, 351, 361.
- pyloric, 488.
- radial, 288, 303, 313.
- ranine, 96.
- recurrent, interosseous, posterior, 313.
- palmar, 304.
- radial, 289.
- tibial, 688.
- ulnar, anterior, 291.
- posterior, 291.
- renal, 515, 528.
- sacral, lateral, 402, 558.
- middle, 527, 561.
- scapular, dorsal, 254, 269.
- posterior, 70, 269, 388.
- sciatic, 559, 639.
- sigmoid, 481.
- spermatic, 521, 528.
- spheno-palatine, 143.
- spinal, anterior, 182, 410.
- posterior, 182, 410.
- splenic, 487, 505.
- sterno-mastoid of thyroid, 79.
- of occipital, 80.
- stylo-mastoid, 80.
- subclavian, left, 116, 354.
- right, 67.
- sublingual, 96.
- submental, 80.
- subscapular, 254.
- superficial cervical, 388.
- perineal, 424.
- volar, 289.
- supraacromial, 388.
- supraorbital, 5, 45.
- suprarenal, 517, 528.
- suprascapular, 55, 70, 269, 388.

Artery or arteries:—

- sural, 647, 648.
 - tarsal, 688.
 - temporal, anterior, 5.
 - deep, 88.
 - middle, 81.
 - posterior, 6.
 - superficial, 5, 80.
 - thoracic, alar, 253.
 - long, 253.
 - superior, 253.
 - thyroid, inferior, 70, 118.
 - lowest, 119.
 - superior, 79, 118.
 - tibial, anterior, 686.
 - posterior, 667.
 - tonsillar, 80.
 - transverse cervical, 70, 388.
 - facial, 28, 81.
 - perineal, 428.
 - of pons, 183.
 - tympanic, 88, 738.
 - ulnar, 290, 297.
 - umbilical, 557.
 - uterine, 560.
 - vaginal, 559.
 - vertebral, 69, 171, 182, 397.
 - vesical, inferior, 559.
 - superior, 559.
 - vestibular, 748.
 - Vidian, 143.
 - volar, superficial, 289.
- Articular popliteal arteries, 648.
 - nerves, 649.
- Articulation, acromio-clavicular, 268.
- astragalo-calcaneal, 704.
 - astragalo-navicular, 705.
 - atlanto-axial, 176, 177.
 - of bones of the tympanum, 736.
 - calcaneo-cuboid, 706.
 - of carpal bones, 322.
 - carpo-metacarpal, 324.
 - of cervical vertebræ, 172.
 - chondro-costal, 373.
 - sternal, 373.
 - of coccygeal bones, 589.
 - of costal cartilages, 373.
 - costo-vertebral, 371.
 - crico-arytenoid, 167.
 - thyroid, 167.
 - of cuneiform bones, 708.
 - cuneiform to cuboid, 708.
 - cuneiform to navicular, 707.
 - femoro-tibial or knee, 692.
 - of hip, 653.
 - humero-cubital or elbow, 317.
 - interchondral, 373.
 - of lower jaw, 85.
 - of metacarpal bones, 324.
 - metacarpo-phalangeal, 326.
 - metatarsal, 709.
 - metatarso-phalangeal, 711.
 - of navicular bone, 705, 707.
 - occipito-atlantal, 176.
 - peroneo-tibial, 700.
 - phalangeal of fingers, 327.
 - of toes, 712.

- Articulation of pubic symphysis, 592.
- radio-carpal or wrist, 320.
 - ulnar, inferior, 322.
 - superior, 319.
 - sacro-coccygeal, 589.
 - iliac, 590.
 - vertebral, 589.
 - scapulo-humeral or shoulder, 314.
 - sterno-clavicular, 177.
 - sternum, pieces of, 374.
 - tarsal, transverse, 707.
 - tarso-metatarsal, 709.
 - temporo-maxillary, 85.
 - of the thumb, 324.
 - tibio-tarsal or ankle, 701.
 - of vertebræ, 374.
- Aryteno-epiglottidean folds, 127, 161.
 - muscles, 156.
- Arytenoid cartilages, 165.
 - glands, 131, 161.
 - muscle, 156.
- Ascending cervical artery, 70
 - colon, 470.
 - pharyngeal artery, 106.
- Association-fibres of brain, 227, 232.
- Atlanto-axial articulations, 176, 177.
 - ligaments, 173, 174.
- Attollens aurem, 2.
- Attrahens aurem, 2.
- Auditory artery, 184, 748.
 - canal or meatus, external, 729.
 - nerve, (o) 189, (c) 18, 145, (d) 747.
 - nuclei, 235, 236.
 - striæ, 234.
 - tubercle, 234.
- Auricle of the ear, 33.
- Auricles of the heart, 339.
 - left, 346.
 - right, 342.
 - structure of, 349.
- Auricular appendages, 340, 342, 346.
 - arteries. *See* Artery.
 - vein, posterior, 6, 80.
 - nerves. *See* Nerve.
- Auriculo-temporal nerve, 8, 90.
 - ventricular aperture, left, 346, 347.
 - right, 343, 344.
 - rings, 348.
- Axilla, 246.
- Axillary artery, 251.
 - glands, 248.
 - sheath, 251.
 - vein, 254.
- Axis, cœliac, of artery, 487, 527.
 - of cochlea, 743.
 - thyroid, of artery, 70.
- Azygos, artery, 648.
 - uvulæ muscle, 131.
 - veins, 365, 538.
- Back, dissection of, 381.
- Bartholin's duct, 99.
 - gland, 434.

- Base of brain, 200.
the skull, arteries of, 15, 19.
dissection of, 12.
nerves of, 16, 20.
- Basilar artery, 183.
membrane, 744.
plexus, 15.
- Basilic vein, 271.
- Biceps. *See* Muscle.
- Bile-ducts, 490, 498, 511.
structure of, 500, 511.
- Biventral lobe, 230.
- Bladder, gall, 512.
urinary, interior of, 570.
ligaments of, 545, 547, 553.
relations of, 548, 555.
structure of, 569, 587.
- Bodies, geniculate, 224, 225.
quadrigenal, 224.
suprarenal, 516.
- Bones of the ear, 735.
ligaments of, 736.
muscles of, 737.
- Brachia of corpora quadrigemina, 224.
- Brachial aponeurosis, 273.
artery, 274.
plexus, 71, 254.
veins, 277.
- Brachialis anticus, 278, 295.
- Brachio-cephalic artery, 354.
veins, 355.
- Brain, base of, 200.
membranes of, 9, 11, 180.
origin of nerves, 186.
preservation of, 11.
removal of, 10.
vessels of, 182.
- Breast, 245.
- Broad ligament of uterus, 552.
- Bronchial arteries, 362, 363.
glands, 367.
veins, 362, 363.
- Bronchi, 360, 362.
- Brunner's glands, 499.
- Buccal artery, 88.
nerves. *See* Nerve.
- Buccinator muscle, 26.
- Bulb of corpus cavernosum, 576.
spongiosum, 551, 577.
olfactory, 203.
of spinal cord, 191.
of the urethra, 551, 577.
artery of, 430, 577.
nerve of, 426.
of the vestibule, 580.
- Bulbo-cavernosus muscle, 425, 433.
- Bulbous part of the urethra, 573.
- Buttock, dissection of, 631.
- Cæcum coli, 501.
relations of, 469.
- Calamus scriptorius, 233.
- Calcaneal arteries, 674.
- Calcaneo-plantar nerve, 669.
- Calcarine fissure, 210.
- Calices of the ureter, 515.
- Callosal convolution, 211.
- Calloso-marginal sulcus, 210.
- Canal, auditory, external, 729.
of cochlea, 745.
crural, 608.
Hunter's, 616.
hyaloid, 726.
inguinal, 455.
lachrymal, 50.
of Nuck, 451.
of Petit, 727.
semicircular, 741.
membranous, 746.
of spinal cord, 413.
of the tensor tympani, 732.
of Wirsung, 504.
- Canalis reuniens, 746.
- Canthus of eyelids, 31.
- Capitula laryngis, 165.
- Capsular arteries. *See* Artery.
ligament. *See* Ligament.
- Capsule, of crystalline lens, 727.
external, of cerebrum, 221.
of Glisson, 510.
internal, of cerebrum, 221, 226.
of kidney, 514.
suprarenal, 516.
of Tenon, 43, 716.
- Caput cæcum coli, 469, 501.
gallinaginis, 572.
- Cardia of stomach, 467, 494.
- Cardiac nerves. *See* Nerve.
plexus, 341, 358.
veins, 341.
- Carotid arteries. *See* Artery.
plexus, 19.
- Carpal arteries. *See* Artery.
articulations, 322.
- Carpo-metacarpal articulation, 324.
- Cartilage, arytenoid, 165.
cricoid, 164.
cuneiform, 165.
of the ear, 35.
septal of the nose, 134.
thyroid, 163.
- Cartilages of the nose, 30, 134.
of Santorini, 165.
of trachea, 168.
- Cartilaginee sesamoideæ, 30.
- Caruncula lachrymalis, 32.
- Carunculæ myrtiformes, 432.
- Cauda equina, 409.
- Caudate lobe, 508.
nucleus, 221.
- Cava, inferior, 356, 484, 530.
superior, 354.
- Cavernous body, 551, 575.
artery of, (o) 430, (d) 577.
plexus, 19.
sinus, 14.
- Central artery of the retina, (o) 45, (d) 725
branches of cerebral arteries, 184,
185.
ligament of cord, 407.
lobe of cerebellum, 230.
of cerebrum, 206, 209.
pillar of cochlea, 743.
point of the perineum, 425.
sulcus, 206.

- Centrum ovale cerebri, 212.
 Cephalic vein, 271.
 Cerebellar arteries. *See* Artery.
 Cerebellum, form of, 228.
 lobes of, 229.
 structure of, 231.
 Cerebral arteries. *See* Artery.
 Cerebro-spinal fluid, 181, 406.
 Cerebrum, division into lobes, 204.
 convolutions, 207.
 fibres of, 226.
 form of, 200.
 interior, 212.
 Ceruminous glands, 730.
 Cervical arteries. *See* Artery.
 fascia, 53, 59.
 ganglion, inferior, 115.
 middle, 114.
 superior, 113.
 glands, 57.
 nerves. *See* Nerve.
 plexus of nerves, deep branches, 74.
 superficial
 branches, 56,
 59, 74.
 Cervicalis ascendens muscle, 392.
 Cervico-facial nerve, 38.
 Cervix uteri, 554, 583.
 vesicæ, 549.
 Chamber of the aqueous, 724.
 Check ligaments, 176.
 Cheeks, 133.
 Chiasma of the optic nerves, 187.
 Chondro-costal articulations, 373.
 glossus muscle, 150.
 sternal articulations, 373.
 Chorda tympani nerve, (o) 145, (c) 92, 145,
 740, (d) 98.
 Chordæ tendineæ, 345, 347.
 Willisii, 10.
 Choroid arteries of the brain, 183, 184, 185,
 219.
 coat of the eye, 719.
 plexuses of the brain, 219, 235.
 veins of the eye, 723.
 brain, 249.
 Cilia, 31.
 Ciliary arteries, (o) 45, (d) 723.
 muscle, 721.
 part of retina, 725.
 processes of the choroid, 720.
 of the suspensory liga-
 ment, 726.
 nerves, long, (o) 43, (d) 724.
 short, (o) 45, (d) 724.
 veins, 723.
 Circle of Willis, 185.
 Circular sinus, 15.
 Circumflex artery. *See* Artery.
 nerve, (o) 256, (d) 263, 264.
 Circumvallate papillæ, 148.
 Claustum, 223.
 Clava, 193.
 Clavicular cutaneous nerves, 57.
 Clitoris, 432, 580.
 Coccygeal artery, 639.
 muscle, 542.
 nerve, 562.
 Cochlea, 742.
 canal of, 745.
 nerve of, 747.
 vessels of, 748.
 Cochleariform process, 732.
 Celiac artery or axis, 487.
 glands, 491, 534.
 plexus, 492.
 Colic arteries. *See* Artery.
 impression on liver, 508.
 Collateral eminence, 217.
 fissure, 211.
 fibres of cerebrum, 227.
 Colon, 469, 500.
 structure of, 502.
 Columna nasi, 30.
 Columnæ carneæ, 344, 347.
 Columns of the rectum, 578.
 of the spinal cord, 412.
 of the vagina, 582.
 Comes nervi ischiadici artery, 639.
 phrenici artery, 259, 357.
 Commissure, anterior of cerebrum, 223.
 of the cord, 413.
 optic, 187.
 posterior of cerebrum, 225.
 soft of cerebrum, 220, 221.
 of vulva, 432.
 Commissural fibres of the cerebellum, 232.
 of the cerebrum, 227.
 Common sinus, 746.
 Communicating arteries. *See* Artery.
 peroneal nerve, 649.
 tibial nerve, 649.
 Complexus muscle, 394.
 Compressor naris muscle, 21.
 Conarium, 225.
 Concha, 33.
 Congenital hernia, 458.
 Coni vasculosi, 520.
 Conical papillæ, 148.
 Conjoined tendon, 447.
 Conjunctiva, 32.
 Conoid ligament, 267.
 Constrictor. *See* Muscle.
 Conus arteriosus, 344.
 medullaris, 411.
 Convulsions of the brain, 204, 207.
 Coraco-acromial ligament, 268.
 brachialis muscle, 274.
 clavicular ligament, 267.
 humeral ligament, 315.
 Cord, spermatic, 451.
 Cordiform tendon, 524.
 Cords of the abdominal wall, 461.
 vocal, 160.
 Cornea, 718.
 Cornicula laryngis, 165.
 Cornua of gray crescent, 413.
 of lateral ventricle, 215.
 Corona glandis, 551.
 radiata, 227.
 Coronary arteries. *See* Artery.
 ligament of the liver, 478.
 plexus of the stomach, 492.
 plexuses of the heart, 342.
 sinus, 340, 355.
 vein of the stomach, 490.

- Corpora albicantia, 202, 221, 224.
 Arantii, 345, 348.
 cavernosa, 551, 575.
 geniculata, 224, 225.
 mamillaria, 202.
 quadrigemina, 224.
 Corpus callosum, 203, 212.
 dentatum cerebelli, 232.
 medullæ, 197.
 fimbriatum, 553.
 Highmorianum, 519.
 luteum, 585.
 Morgagni, 518.
 spongiosum urethræ, 551, 577.
 striatum, 221.
 Corpuscles of Malpighi, 505.
 Corrugator. *See* Muscle.
 Cortex of cerebellum, 231.
 of cerebrum, 212.
 of tongue, 150.
 Cortical branches of cerebral arteries, 184, 185.
 substance of the kidney, 514.
 Costo-clavicular ligament, 178.
 colic fold, 477.
 coracoid membrane, 250.
 transverse ligaments, 372.
 Cotunnus, fluid of, 742.
 nerve of, 140.
 Cotyloid ligament, 656.
 Covered band of Reil, 212.
 Cowper's glands, 429.
 Cranial nerves, 16, (o) 186.
 nuclei of, 235.
 Cremaster muscle, 445.
 Cremasteric artery, 454.
 fascia, 446.
 Crest of the urethra, 572.
 vestibule, 740.
 Cribriform fascia, 601.
 Crico-arytenoid articulation, 167.
 muscle, lateral, 156.
 posterior, 155.
 thyroid artery, 79.
 articulation, 167.
 membrane, 166.
 muscle 154.
 tracheal ligament, 166.
 Cricoid cartilage, 164.
 Crista acustica, 746.
 Crucial ligaments, 695.
 Crura cerebelli, 232.
 cerebri, 200, 201.
 of the diaphragm, 524.
 of the fornix, 216, 224.
 of the penis, 576.
 Crural arch, 606.
 deep, 452, 607.
 canal, 608.
 hernia, 462, 609.
 nerve, 536, 622.
 ring, 463, 608.
 septum, 463, 609.
 sheath, 463, 607.
 Crusta of cerebral peduncle, 202.
 Crypts of Lieberkühn, 499, 503.
 of tongue, 152.
 Crystalline capsule, 727.
 Crystalline lens, 727.
 Cuneate funiculus and tubercle, 193, 198.
 lobule, 211.
 Cuneiform cartilages, 165.
 Cupola cochleæ, 743.
 Curve of the urethra, 550.
 Cutaneous nerves of the abdomen, 437.
 of the arm, 272.
 of the back, 382.
 of the buttock, 631.
 of the face, 37.
 of the foot, back, 683.
 sole, 669.
 of the forearm, 284.
 of the hand, back, 284.
 palm, 295.
 of the head, 6.
 of the leg, back, 660.
 front, 683.
 of the neck, back, 382.
 front, 59.
 of the perineum, 421, 424.
 of the shoulder, 263.
 of the thigh, front, 603.
 of the thorax, 244.
 Cystic artery, 489.
 duct, 512.
 plexus of nerves, 492.
 vein, 490.
 Dartoid tissue, 423, 433, 439.
 Decussation of the pyramids, 192, 195.
 Deep cervical artery, (o) 71, (d) 397.
 crural arch, 452, 607.
 transverse muscle of perineum, 429, 434.
 Deferential artery, 522, 559.
 Deltoid ligament, 702.
 muscle, 263.
 Dental arteries. *See* Artery.
 nerves. *See* Nerve.
 Dentate body of cerebellum, 232.
 of medulla oblongata, 197.
 fascia, 212, 217.
 fissure, 211.
 ligament, 407.
 Depressor. *See* Muscle.
 Descendens noni nerve, 77.
 Descending colon, 470.
 Diaphragm, 371, 522.
 arteries of, 528.
 plexus of, 492.
 Digastric muscle, 76.
 nerve, 36.
 Digital arteries. *See* Artery.
 nerves. *See* Nerve.
 sheaths, 297.
 Dilator of the nostril, 22.
 of the pupil, 722.
 Disc, interpubic, 593.
 intervertebral, 375.
 optic, 725.
 Dissection of the abdominal cavity, 465.
 wall, 434.
 of the arm, 270.
 of the axilla, 246.
 of the back, 381.
 of the base of the skull, 12.

Dissection of the brain, 180.

- of the buttock, 631.
- of the cardiac plexus, 358.
- of the carotid artery, internal, 103.
- of the carotid plexus, 19.
- of the cerebellum, 228.
- of the cerebrum, 200.
- of the corpus callosum, 203, 212.
- of the corpus striatum, 221, 227.
- of the cranial nerves in the neck, 106.
- of the crus cerebri, 202.
- of the deep vessels and nerves of the neck, 102.
- of the ear, 33, 729.
- of the eye, 716.
- of the eyelids, 31.
- of the face, 20.
- of fascia lumborum, 385.
- of femoral hernia, 462, 606.
- of the foot, back, 682.
- sole, 669.
- of the forearm, back, 306.
- front, 282.
- of the fourth ventricle, 233.
- of the hand, back, 283.
- palm, 295.
- of the head, external parts, 1.
- internal parts, 9.
- of the heart, 338.
- of the hypogastric plexus, 483.
- of inferior maxillary nerve, 87.
- of inguinal hernia, 455.
- of Jacobson's nerve, 738.
- of the labyrinth, 740.
- of the larynx, 153.
- cartilages, 163.
- muscles, 154.
- nerves, 161.
- of the left side of the neck, 115.
- of the leg, back, 659.
- front, 682.
- of the ligaments of atlas and axis, 172.
- of the ligaments of atlas and occiput, 172.
- of the ligaments of axis and occiput, 175.
- of the ligaments of clavicle and scapula, 267.
- of the ligaments of hip-joint, 653.
- of the ligaments of jaw, 85.
- of the ligaments of lower limb, 691.
- of the ligaments of pelvis, 589.
- of the ligaments of ribs, 371.
- of the ligaments of shoulder, 314.
- of the ligaments of the vertebræ, 172, 374.
- of the ligaments of wrist, 320.
- of the lower limb, 598.
- of Meckel's ganglion, 138.
- of the neck, 51.
- anterior triangle, 60.
- left side, 115.

- Dissection of the neck, posterior triangle, 53.
- of the nose, 133.
- of the ophthalmic of the fifth nerve, 18, 40.
- of the orbit, 38, 99.
- of the otic ganglion, 145.
- of the pelvis, 539.
- side view, female, 552.
- male, 545.
- of the perineum, female, 431.
- male, 416.
- of the pharynx, 120.
- of the pons, 198.
- of the popliteal space, 645.
- of the prevertebral muscles, 169.
- of the pterygoid region, 81.
- of the sacral plexus, 561.
- of the shoulder, 261.
- of the soft palate, 128.
- of the solar plexus, 491.
- of the spinal cord, 404.
- of the subclavian artery, 65.
- of the submaxillary region, 92.
- of the superior maxillary nerve, 100.
- of the testis, 517.
- of the thigh, back, 644, 650.
- front, 598.
- of the thorax, 330.
- of the tongue, 147.
- of the triangular space of the thigh, 610.
- of the tympanum, 731.
- vessels and nerves, 738.
- of the upper limb, 242.
- Dorsal artery. *See* Artery.
- nerves. *See* Nerve.
- Douglas, fold of, 449.
- Drum of the ear, 731.
- Duct, of Bartholin, 99.
- bile, common, 490, 498, 500.
- of cochlea, 745.
- cystic, 512.
- ejaculatory, 569.
- galactophorous, 245.
- hepatic, 490, 508, 511.
- lactiferous, 245.
- lymphatic, right, 368.
- nasal, 50.
- pancreatic, 490, 498, 504.
- parotid, 28.
- of Rivinus, 99.
- seminal, common, 569.
- of Stenson, 28.
- thoracic, 116, 367.
- of Wharton, 98.
- Ductus arteriosus, 352.
- communis choledochus, 490, 498, 500.
- endolymphaticus, 747.
- Stenosis, 28.
- venosus, 509.
- Duodenal impression on liver, 508.
- Duodeno-jejunal flexure, 469.
- fossa, 478.
- Duodenum, characters of, 496.

- Duodenum, peritoneum of, 477.
 relations of, 469, 485.
 Dura mater, cranial, 9, 12.
 spinal, 404.
 nerves of, 16, 407.
 vessels of, 15, 407.
- Ear, external, 33, 729.
 internal, 740.
 middle, 731.
- Eighth nerve, (o) 189, (c) 18, 145, (d) 747.
- Ejaculator urinæ, 425.
- Elbow-joint, 317.
- Eleventh nerve, 19, 108, 111.
- Eminentia collateralis, 217.
 teres, 234.
- Encephalon, 180.
- Encysted hernia, 458.
- Endocardium, 351.
- Endolymph, 745, 746.
- Ependyma, 213, 221, 235.
- Epididymis, 520.
- Epigastric artery. *See* Artery.
 fossa, 435.
 plexus, 491.
 region of the abdomen, 466.
 veins, 464.
- Epiglottis, 165.
- Epophoron, 586.
- Erector. *See* Muscle.
- Ethmoidal arteries, 46, 143.
 cells, 135, 136.
- Eustachian tube, cartilaginous part, 125.
 osseous part, 734.
 valve, 343.
- Eversion of foot, 705.
- Extensor. *See* Muscle.
- External cutaneous nerves. *See* Nerve.
- Extraventricular nucleus, 221.
- Eyeball, 716.
 brows, 30.
 lashes, 31.
 lids, 31.
 muscles of, 22.
 nerves of, 33.
 structure, 31.
 vessels, 33.
- Face, dissection of, 20.
- Facial artery, 27, 79.
 nerve, (o) 189, (c), 18, 143, (d) 35.
 vein, 27, 80.
- Falciform ligament of the liver, 478.
 border of saphenous opening, 605.
- Fallopian tube, 554, 586.
- Fallopius, aqueduct of, 731.
- Falx cerebelli, 12.
 cerebri, 10.
- Fascia, anal, 418, 427.
 axillary, 243.
 brachial, 273.
 cervical, deep, 53, 59.
 of Colles, 423.
 cremasteric, 446.
 cribriform, 601.
 dentata, 212, 217.
- Fascia of the forearm, 285.
 iliac, 463, 533.
 intercolumnar, 443.
 lata, 604, 645.
 of the leg, 662, 684.
 lumborum, 386.
 obturator, 541.
 palmar, 296.
 palpebral, 31.
 pelvic, 541.
 perineal, deep, 427.
 superficial, 423, 433.
 plantar, 670.
 propria, 609.
 of pyriformis, 541.
 of quadratus, 533.
 recto-vesical, 541, 544.
 of Scarpa, 437.
 spermatic, 443, 457.
 temporal, 4.
 transversalis, 450, 463.
 triangular, 443.
- Fasciculus teres, 234.
- Fauces, 127.
- Femoral artery, 612, 616.
 hernia, 462, 606.
 ligament, 606.
 vein, 613, 618.
- Femoro-tibial articulation, 692.
- Fenestra ovalis, 731.
 rotunda, 731.
- Fibres of the cerebrum, 226.
 of the cerebellum, 232.
- Fibro-cartilage. *See* Interarticular.
 of heart, 349.
- Fibrous coat of eye, 717.
- Fifth nerve, 17, 189.
 ventricle of brain, 216.
- Filiform papillæ, 148.
- Fillet of the corpus callosum, 212.
 of the pons and mid-brain, 225, 227.
- Filum terminale, 407.
- Fimbria of brain, 217.
- Fimbriæ of the Fallopian tube, 586.
- First nerves, 16, 137, 187.
- Fissure, calcarine, 210.
 collateral, 211.
 dentate, 211.
 Glaserian, 732.
 hippocampal, 211.
 longitudinal, of cerebrum, 204.
 parieto-occipital, 206, 210.
 portal, 508.
 of Sylvius, 205.
 transverse of cerebrum, 217.
- Fissures of Santorini, 35.
 of the cord, 411.
 of the cerebrum, 204.
- Flexor. *See* Muscle.
- Flexure, duodeno-jejunal, 469.
 hepatic, 470.
 sigmoid, 471.
 splenic, 470.
- Flocculus cerebelli, 230.
- Fold of Douglas, 449.
- Folia of cerebellum, 229.
- Folium cacuminis, 210.
- Foot, dorsum, 682.

- Foot, sole, 669.
 Foramen cæcum of medulla oblongata, 192.
 of tongue, 147.
 of Monro, 216.
 ovale, 342, 344, 346.
 quadratum, 525.
 for vena cava, 525.
 of Winslow, 477.
 Foramina Thebesii, 343.
 Forearm, dissection of, 282, 306.
 Formatio reticularis, 197, 199, 202.
 Fornix, 216, 224.
 conjunctivæ, 32.
 Fossa, duodeno-jejunal, 478.
 ischio-rectal, 418.
 navicular of the urethra, 573.
 of the vulva, 432.
 ovalis, 342.
 rhomboidalis, 233.
 Fossæ of abdominal wall, 462.
 Fourchette, 432.
 Fourth nerve, (o) 188, (c) 17, (d) 40.
 ventricle, 233.
 Fovea, centralis, 725.
 hemielliptica, 741.
 hemispherica, 740.
 Foveæ of fourth ventricle, 234.
 Frænulum clitoridis, 432.
 labii, 132.
 pudendi, s. vulvæ, 432.
 Frænum epiglottidis, 152.
 of ileo-cæcal valve, 502.
 linguæ, 132, 148.
 præputii, 439, 551.
 Frontal artery, 5, 46.
 nerve, 40.
 lobe of cerebrum, 206, 207.
 sinus, 136.
 vein, 6.
 Fundus of bladder, 548.
 of stomach, 467, 494.
 of uterus, 554, 582.
 Fungiform papillæ, 148.
 Funiculus cuneatus, 193.
 gracilis, 193, 196.
 of Rolando, 193.
 Furrow of Rolando, 206.
 Furrowed band, 230.
 Furrows of cerebrum, 204, 207.

 Galactophorus ducts, 245.
 Galen, veins of, 219.
 Gall-bladder, 512.
 Ganglia of glosso-pharyngeal, 108.
 lumbar, 537.
 sacral, 564.
 semilunar, 492.
 of spinal nerves, 408.
 thoracic, 368.
 of vagus, 109.
 Ganglion, cervical, inferior, 115, 120.
 middle, 114, 120.
 superior, 113.
 Gasserian, 18.
 geniculate, 144.
 impar, 564.
 intervertebral, 408.

 Ganglion, jugular, 108.
 lenticular, 44.
 Meckel's, 140.
 ophthalmic, 44.
 otic, 145.
 petrous, 108.
 spheno-palatine, 140.
 spirale, 747.
 submaxillary, 97.
 thyroid, 114.
 Gastric arteries, 487, 496.
 impression on liver, 507.
 veins, 490, 496.
 Gastro-colic omentum, 476.
 duodenal artery, 488.
 epiploic arteries, 487, 488.
 veins, 481, 490.
 hepatic omentum, 475.
 splenic omentum, 477.
 Gastrocnemius muscle, 662.
 Gelatinous substance, 198.
 Gemellus. *See* Muscle.
 Generative organs, 581.
 Geniculate bodies, 224, 225.
 ganglion, 144.
 Genio-glossus or Genio-hyo-glossus, 96, 151.
 hyoid muscle, 95.
 Genital organs, 551, 572, 579.
 Genito-crural nerve, 452, 536, 603.
 Genu, of corpus callosum, 203.
 of internal capsule, 221.
 of optic tract, 225.
 Gimbernat's ligament, 443, 607.
 Giralès, organ of, 521.
 Gland of Havers, 657.
 lachrymal, 40.
 parotid, 28.
 pineal, 225.
 prostate, 549, 566.
 sublingual, 98.
 submaxillary, 63, 92, 98.
 thyroid, 63.
 Glands, agminated, 499.
 arytenoid, 131, 161.
 Bartholin's, 434.
 Brunner's, 499.
 ceruminous, 730.
 Cowper's, 429, 573.
 labial, 133.
 laryngeal, 161.
 Lieberkühn's, 499, 503.
 lingual, 152.
 lymphatic, axillary, 248.
 bronchial, 367.
 cardiac, 367.
 cervical, superficial, 57.
 deep, 57, 63.
 cœliac, 534.
 concatenate, 57.
 inguinal, 439, 601.
 intercostal, 367.
 lingual, 153.
 lumbar, 534.
 mastoid, 57.
 mediastinal, 367.
 mesenteric, 481.
 meso-colic, 481.
 parotid, 28.

- Glands, lymphatic, pelvic, 565.
 popliteal, 649.
 sternal, 367.
 submaxillary, 63.
 suboccipital, 57.
 mammary, 245.
 Meibomian, 32.
 molar, 29.
 of Pacchioni, 9.
 Peyer's, 499.
 solitary, 499, 503.
 tarsal, 32.
 Glandulæ concatenatæ, 57.
 odoriferæ, 439.
 Glans of the clitoris, 580.
 of the penis, 551.
 Glaserian fissure, 732.
 Glenoid ligament, 315.
 Glisson's capsule, 510.
 Globus major epididymis, 520.
 minor epididymis, 520.
 Glosso-epiglottidean folds, 152.
 Glosso-pharyngeal nerve (o) 190, (c), 19,
 98, 108, (d), 108, 153.
 nucleus, 235.
 Glottis, 158.
 Gluteal artery, 558, 637.
 nerve, superior, 564, 637.
 nerve, inferior, 564, 640.
 muscles. *See* Muscle.
 Graafian vesicles, 585.
 Gracilis muscle, 623.
 Grey commissure of the cord, 413.
 crescent of the cord, 413.
 substance of medulla oblongata, 197.
 of the third ventricle, 221.
 tubercle of Rolando, 193, 198.
 Gullet, 119, 366.
 Gustatory nerve. *See* Lingual.
 Gyri of cerebrum, 204, 207.
 Gyrus fornicatus, 211.

 Hæmorrhoidal arteries. *See* Artery.
 nerve, inferior, 421.
 plexus of nerves, 483, 565.
 veins, 560, 579.
 Ham, 645.
 Hamulus laminae spiralis, 744.
 Hand, dissection of, 295.
 Havers, gland of, 657.
 Head, movements of, 177.
 Heart, 338.
 constituents, 339.
 dissection of, 342.
 position, 338.
 structure of, 348.
 Helicotrema, 744
 Helix, 33.
 fossa of, 33.
 muscles of, 34.
 Hemispheres of cerebellum, 228.
 of cerebrum, 204.
 Hepatic artery, 487, 509.
 ducts, 490, 508, 511.
 flexure of colon, 470.
 plexus, 492.
 veins, 511, 531.
 Hernia, crural or femoral, 462, 606.
 inguinal, external, 455.
 internal, 459.
 umbilical, 461.
 Hesselbach's triangle, 459.
 Hiatus cochleæ, 744.
 Highmore, body of, 519.
 Hilum of kidney, 513.
 of lung, 335.
 of ovary, 585.
 of spleen, 504.
 of suprarenal body, 516.
 Hip-joint, 653.
 Hippocampal fissure, 211.
 Hippocampus major, 217.
 minor, 217.
 Hollow before elbow, 286.
 Hunter's canal, 616.
 Hyaloid canal, 726.
 membrane, 726.
 Hymen, 432.
 Hyo-epiglottidean ligament, 167.
 glossal membrane, 149.
 glossus muscle, 95, 150.
 Hyoid artery. *See* Artery.
 bone, 163.
 Hypochondriac region of abdomen, 466.
 Hypogastric artery, 557.
 plexus of nerves, 483.
 region of the abdomen, 466.
 Hypoglossal nerve, 19, 77, 98, 111, 153, 191.
 nucleus, 191, 235.

 Ileo-cæcal valve, 502.
 colic artery, 480.
 valve, 502.
 Ileum, relations of, 469.
 structure of, 496.
 Iliac arteries. *See* Artery.
 fascia, 463, 533.
 part of fascia lata, 605.
 region of the abdomen, 466.
 veins. *See* Vein.
 Iliacus muscle, 532, 629.
 Ilio-costalis, 391.
 femoral ligament, 654.
 hypogastric nerve, 438, 450, 536, 632.
 inguinal nerve, 438, 450, 536, 603.
 lumbar artery, 557.
 ligament, 591.
 vein, 530, 557.
 psoas, 533.
 tibial band, 604.
 Incisor branch of nerve, 91.
 Incus, 735.
 Indicator muscle, 311.
 Infantile hernia, 458.
 Inframarginal convolution, 209.
 Inframaxillary nerve, 38, 59.
 Infraorbital artery, 89, 101.
 nerves. *See* Nerve.
 plexus, 38, 101.
 vein, 101.
 Infrascapular artery, 254, 262.
 Infrapinatus muscle, 265.
 Infrasternal fossa, 435.
 Infratrochlear nerve, 43.

- Infundibula of the lung, 362.
 of the ureter, 515.
 Infundibulum of the brain, 202.
 of the heart, 344.
 of the nose, 136.
 Inguinal canal, 455.
 fossæ, 462.
 furrow, 435.
 glands, 439, 601.
 hernia, external, 455.
 internal, 459.
 region of the abdomen, 466.
 Innominate artery, 354.
 veins, 355.
 Insula, 206, 209.
 Interarticular fibro-cartilage of the jaw, 86.
 of the knee, 697.
 of the scapula, 268.
 sterno-clavicular, 178.
 of the wrist, 322.
 ligament of the hip, 656.
 of the ribs, 372.
 of sacrum and coccyx, 590.
 Interclavicular ligament, 178.
 Intercolumnar fascia and fibres, 443.
 Intercostal aponeuroses, 258, 370.
 arteries. *See* Artery.
 muscles, 257, 370, 403.
 nerves, 260, 370, 403, 449.
 veins. *See* Vein.
 Intercosto-humeral nerve, 244, 272.
 Intermediate process, 413.
 Intermuscular septa of the arm, 280.
 of the foot, 670.
 of the thigh, 621.
 Internal cutaneous nerve. *See* Nerve.
 Interosseous arteries. *See* Artery.
 ligaments or membrane. *See* Ligament.
 muscles. *See* Muscle.
 nerves. *See* Nerve.
 Interpeduncular space, 201.
 Interpubic disc, 593.
 Interspinal muscles, 401.
 Intertransverse muscles, 171, 401.
 Intervertebral ganglia, 408.
 disc or substance, 375.
 Intestinal arteries, 479.
 canal, divisions, 467, 469.
 structure of, 496, 500.
 Intestine, large, 469, 500.
 small, 469, 496.
 Intraparietal sulcus, 208.
 Intraspinal vessels, 414.
 Intraventricular nucleus, 221.
 Intumescencia ganglioformis, 747.
 Inversion of foot, 705.
 Iris, 721.
 nerves of, 723.
 structure of, 722.
 vessels of, 723.
 Ischio-cavernosus muscle, 425, 433.
 rectal fossa, 418.
 Island of Reil, 206, 209.
 Isthmus cerebri, 224.
 faucium, 127.
 of the thyroid body, 118.
 of the uterus, 583.
 Vieussenii, 342.
 Iter a tertio ad quartum ventriculum, 226.
 Jacobson's nerve, (o) 108, (d) 739.
 Jejunum, relations of, 469.
 structure of, 496.
 Joint, ankle, 701.
 elbow, 317.
 great toe, 709.
 hip, 653.
 knee, 692.
 lower jaw, 85.
 shoulder, 314.
 thumb, 324.
 wrist, 320.
 Jugular ganglion, 108.
 veins. *See* Vein.
 Kerato-cricoid muscle, 155.
 Kerkring, valves of, 497.
 Kidney, 513.
 relations of, 472.
 structure of, 514.
 vessels of, 515.
 Knee-joint, 692.
 Labia pudendi externa s. majora, 432.
 interna s. minora, 432.
 Labial artery, inferior, 27.
 glands, 133.
 nerves, 91, 101.
 Labyrinth, 740.
 lining of, 742.
 membranous, 745.
 osseous, 740.
 Lachrymal artery, 33, 45.
 canals, 50.
 gland, 40.
 nerve, 40.
 papilla, 31.
 point, 31, 50.
 sac, 50.
 Lacteals, 500.
 Lactiferous ducts, 245.
 Lacunæ of the urethra, 573.
 Lamina cinerea, 203.
 quadrigemina, 224.
 spiralis cochleæ, 743.
 suprachoroidea, 720.
 Laminæ of cerebellum, 229, 231.
 of the lens, 727.
 Large intestine, relations of, 469.
 structure and form of, 500.
 Laryngeal arteries, 162.
 nerves. *See* Nerve.
 pouch, 159.
 Larynx, 153.
 apertures of, 127, 158.
 cartilages of, 163.
 interior of, 158.

- Larynx, ligaments of, 166.
 muscles of, 154.
 nerves of, 162.
 ventricle of, 159.
 vessels of, 162.
- Lateral column of the cord, 412.
 cutaneous nerves, 244, 437.
 nucleus, 198.
 sinus, 13.
 tract, 192, 196.
 ventricles, 214.
- Latissimus dorsi, 256, 385.
- Leg, dissection of the back, 659.
 front, 682.
- Lens of the eye, 727.
- Lenticular ganglion, 44.
 nucleus, 221.
- Levator. *See* Muscle.
- Lieberkühn's crypts, 499.
- Lieno-renal ligament, 472, 475.
- Ligament or Ligaments:—
 acromio-clavicular, 268.
 alar of the knee, 695.
 annular, anterior of ankle, 684.
 external of ankle, 684.
 internal of ankle, 669.
 of radius, 319.
 of stapes, 736.
 anterior of wrist, 306.
 posterior of wrist, 307, 314.
 anterior, of ankle-joint, 702.
 of elbow-joint, 318.
 of knee-joint, 694.
 of wrist-joint, 321.
 of carpus, 323.
 arched, of diaphragm, 524.
 of arterial duct, 352.
 astragalo-calcaneal, 704.
 astragalo-navicular, 705.
 atlanto-axial, anterior, 173.
 posterior, 174.
 transverse, 176.
 of bladder, 545, 547, 553.
 calcaneo-cuboid, 706.
 navicular, 705.
 capsular of the hip, 653.
 of the knee, 692.
 of the shoulder, 315.
 of the thumb, 324.
 carpal, dorsal, 323.
 palmar, 323.
 carpo-metacarpal, 324.
 check, 176.
 chondro-sternal, 373.
 common, anterior of vertebræ, 374.
 posterior, 375.
 conoid, 267.
 coraco-acromial, 268.
 clavicular, 267.
 humeral, 315.
 coronary of liver, 478.
 costo-central, 372.
 clavicular, 178.
 coracoid, 250.
 transverse, middle, 373.
 posterior, 372.
 superior, 372.
 vertebral, 371.
- Ligament or Ligaments:—
 costo-xiphoid, 373.
 cotyloid, 656.
 crico-arytenoid, 167.
 thyroid, 166.
 tracheal, 166.
 crucial, 695.
 deltoid, 702.
 dentate, 407.
 falciform of liver, 478.
 of Gimbernat, 443, 607.
 glenoid, 315.
 hyo-epiglottidean, 167.
 ilio-femoral, 654.
 lumbar, 591.
 of incus, 736.
 interarticular of the hip, 656.
 of the ribs, 372.
 of sacrum and coccyx, 590.
 interclavicular, 178.
 interosseous of astragalus, and os calcis, 704.
 of carpus, 323.
 of cuneiform bones, 708.
 of metacarpal bones, 324.
 of metatarsal bones, 709.
 radio-ulnar, 319.
 naviculo-cuboid, 708.
 tibio-peroneal, 700.
 interspinous, 378.
 intertransverse, 379.
 lateral, of ankle, 702.
 of carpus, 323.
 of elbow, 317.
 phalangeal of foot, 712.
 phalangeal of hand, 326.
 of jaw, 85.
 of knee, 692.
 of liver, 478.
 of wrist, 321.
 of larynx, 166.
 lien-renal, 472, 475.
 of liver, 478.
 of lung, 332.
 long plantar, 706.
 of malleus, 736.
 metacarpal, dorsal, 324.
 interosseous, 324, 326.
 palmar, 324.
 transverse, 304.
 metatarsal, dorsal, 709.
 interosseous, 709, 711.
 plantar, 709.
 transverse, 680.
 mucous, 695.
 oblique, 320.
 occipito-atlantal, anterior, 173.
 posterior, 173.
 occipito-axial, 175.
 odontoid, 176.
 orbicular of the radius, 319.
 of the ovary, 555, 585.
 palpebral, 31.
 of the patella, 694.
 peroneo-tibial, 700.
 of the pinna, 35.
 plantar, long, 706.

- Ligament or Ligaments:—**
 plantar, short, 707.
 of Poupart, 443, 606.
 posterior of ankle, 702.
 of carpus, 323.
 of elbow, 318.
 of knee, 693.
 of wrist, 321.
 pterygo-maxillary, 26, 124.
 pubic, anterior, 592.
 superior, 592.
 pubo-femoral, 654.
 recto-uterine, 553.
 of rectum, 545.
 rhomboid, 178.
 round of the hip, 656.
 of the liver, 509.
 of the uterus, 452, 554, 584.
 sacro-coccygeal, 590.
 sacro-iliac, 590.
 sacro-sciatic, large, 591, 644.
 small, 591, 644.
 sacro-vertebral, 589.
 of scapula, 268.
 of stapes, 736.
 stellate, 372.
 sterno-clavicular, 178.
 stylo-hyoid, 102.
 maxillary, 86.
 subpubic, 592.
 suprascapular, 268.
 supraspinous, 378.
 suspensory of axis, 176.
 of liver, 478.
 of lens, 726.
 of penis, 439.
 of uterus, 554.
 tarsal of eyelids, 32.
 tarso-metatarsal, dorsal, 710.
 lateral, 710.
 plantar, 710.
 thyro-arytenoid, 160.
 epiglottidean, 167.
 hyoid, 166.
 transverse of the atlas, 176.
 of the fingers, 296.
 of the hip, 656.
 of the knee, 697.
 of metacarpus, 304.
 of metatarsus, 680.
 of the toes, 671.
 trapezoid, 267.
 triangular of the urethra, 427, 434.
 of the uterus, 552.
 vaginal, 297.
 vesico-uterine, 553.
Ligamenta subflava, 378.
 suspensoria of mamma, 245.
Ligamentum arcuatum, 524, 592.
 denticulatum, 407.
 latum pulmonis, 332.
 nuchæ, 384.
 patellæ, 620, 694.
 spirale, 745.
 teres of hip, 656.
 of liver, 509.
 of uterus, 452, 554, 584.
Ligula, 233.
Limb, upper, 242.
 lower, 598.
Limbus cochleæ, 744.
Linea alba, 442.
 semilunaris, 441, 449.
 splendens, 406.
Lineæ transversæ, 441, 449.
Lingual artery, 79, 96.
 glands, 152.
 nerve, 92, 97, 153.
 veins, 96.
Linguales muscles, 152.
Lingula, 232.
Lips, 133.
Liquor Cotunnii, 742.
Lithotomy, parts cut, 430.
Liver, 506.
 relations of, 471.
 ligaments of, 478.
 lobes of, 507.
 structure of, 509.
 vessels of, 510.
Lobes of the cerebellum, 229.
 of the cerebrum, 204.
 of the liver, 507.
 of the testis, 519.
Lobule, cuneate, 211.
 of ear, 33.
 occipital, 211.
 orbital, 206, 208.
 oval, 211.
 parietal, 208.
 quadrate, 211.
Lobules of the liver, 510.
Locus cæruleus, 234.
Longissimus dorsi, 392.
Longitudinal fibres of cerebrum, 201.
 fissure of the cerebrum, 201.
 fissure of the liver, 508.
 sinus, inferior, 13.
 superior, 10.
Longus colli muscle, 169.
Lower, tubercle of, 342.
Lumbar aponeurosis, 386.
 arteries, 398, 453, 537.
 ganglia, 537.
 glands, 538.
 nerves. *See Nerve.*
 plexus, 535.
 region of the abdomen, 466.
 veins, 531, 538.
Lumbo-sacral cord or nerve, 535.
Lumbricales of the foot, 676.
 of the hand, 300.
Lungs, 360.
 physical characters, 360.
 relations, 334.
 structure, 361.
 vessels and nerves, 362.
Lunula, 345.
Lymphatic duct, right, 65, 368.
 glands. *See Glands.*
Lymphatics of the arm, 272.
 of the axilla, 248.
 of the intestine, 481, 503.
 of the kidney, 515.
 of the liver, 511.
 of the lungs, 362.

- Lymphatics of the neck, 57.
 of the pelvis, 565.
 of the penis, 577.
 of the popliteal space, 650.
 of the spleen, 505.
 of the stomach, 496.
 of the testicle, 522.
 of the thorax, 367.
 of the tongue, 153.
 of the tonsil, 131.
- Lyra, 216.
- Macula acustica, 746.
 lutea, 725.
- Malar nerves, 38.
- Malleolar arteries, 667, 688.
- Malleus, 735.
- Malpighian corpuscles of spleen, 505.
 of kidney, 514.
- Mamilla. *See* Nipple.
- Mamillæ of the kidney, 514.
- Mamma, 245.
- Mammary artery, external, 253.
 internal, (o) 70, (c) 259,
 357, 453.
 gland, 245.
- Marginal convolution, 211.
- Masseter muscle, 81.
- Masseteric artery, 88.
 nerve, 89.
- Mastoid antrum, 734.
 cells, 734.
 lymphatic glands, 57.
- Maxillary artery, internal, 87, 142.
 nerves. *See* Nerve.
 veins. *See* Vein.
- Meatus auditorius externus, 729.
 nerves of, 91, 730.
 vessels of, 81, 730.
 urinarius, 432, 550, 573.
- Meatuses of the nose, 135.
- Meckel's ganglion, 140.
- Median-basilic vein, 271.
 cephalic vein, 271.
 nerve, 256, 277, 292, 298.
 vein, 271, 284.
- Mediastinal arteries, 259, 364.
- Mediastinum of thorax, 332.
 testis, 519.
- Medulla oblongata, 191.
 spinalis, 410.
- Medullary arteries. *See* Artery.
 centre of cerebellum, 231.
 of cerebrum, 212.
 portion of tongue, 152.
 velum, inferior, 230.
 superior, 232.
- Meibomian glands, 32.
- Membrana basilaris, 744.
 flaccida, 734.
 pupillaris, 722.
 tympani, 733.
 secundaria, 734.
- Membrane, costo-coracoid, 250.
 crico-thyroid, 166.
 of Descemet, 718.
 hyaloid, 726.
- Membrane, hyo-glossal, 149,
 of the labyrinth, 742
 obturator, 593.
 pituitary, 136.
 of the pupil, 722.
 of Reissner, 745.
 Schneiderian, 136.
 thyro-hyoid, 166.
- Membranes of the brain, 9, 11, 180.
 of spinal cord, 404.
- Membranous labyrinth, 745.
 part of the cochlea, 745.
 part of the urethra, 550, 573.
- Meningeal arteries. *See* Artery.
 nerves, 16.
- Meninges, 180, 404.
- Mental nerve, 91.
- Mesencephalon, 224.
- Mesenteric artery, inferior, 481.
 superior, 479.
 glands, 481.
 plexuses, 483.
 vein, inferior, 482.
 superior, 481.
- Mesentery, 478.
- Meso-cæcum, 470, 477.
 colon, left, 477.
 right, 477.
 sigmoid, 477.
 transverse, 477.
 rectum, 477, 546.
- Metacarpal arteries, 292, 313.
 articulations, 324.
- Metatarsal artery, 689.
- Mid-brain, 224.
- Midriff, 522.
- Mitral valve, 347.
- Modiolus of the cochlea, 743.
- Monro, foramen of, 216.
- Molar glands, 29.
- Mons Veneris, 435.
- Morgagni, body of, 518.
 columns of, 578.
- Mouth, cavity of, 132.
- Mucous ligament, 695.
- Multifidus spinæ muscle, 400.
- Muscle or Musculus:—
 abductor hallucis, 671.
 indicis, 305.
 minimi digiti manus, 303.
 pedis, 672.
 pollicis, 301
 accessorius pedis, 676.
 ad sacro-lumbalem, 392.
 adductor brevis, 625.
 hallucis, 677.
 longus, 624.
 magnus, 629, 653, 693.
 pollicis, 302.
 anconeus, 310.
 of antitragus, 34.
 arytenoid, 156.
 aryteno-epiglottidean, 146.
 attollens aurem, 2.
 attrahens aurem, 2.
 azygos uvulæ, 131.
 biceps of arm, 273, 295, 315.
 of thigh, 650, 693.

Muscle or Musculus:—

- biventer cervicis, 394.
- brachialis anticus, 278, 295.
- buccinator, 26.
- bulbo-cavernosus, 425, 433.
- cervicalis ascendens, 392.
- chondro-glossus, 150.
- ciliary, 721.
- circumflexus palati, 129.
- coccygeus, 542.
- complexus, 394.
- compressor naris, 21.
- constrictor inferior, 122.
 - isthmi faucium, 130.
 - medius, 122.
 - superior, 124.
 - urethræ, 428.
- coraco-brachialis, 274.
- corrugator cutis ani, 419.
- supercilii, 23.
- cremaster, 445.
- crico-arytenoid, lateral, 156.
 - posterior, 155.
- thyroid, 154.
- crureus, 620.
- deltoid, 263.
- depressor anguli oris, 25.
 - epiglottidis, 158.
 - labii inferioris, 25.
 - alæ nasi, 22.
- diaphragm, 371, 522.
- digastric, 76.
- dilatator naris, 22.
 - pupillæ, 722.
- ejaculator urinæ, 425.
- erector clitoridis, 433.
 - penis, 425.
 - spinæ, 391.
- extensor carpi radialis brevior, 308.
 - longior, 308.
 - ulnaris, 309.
- brevis digitorum pedis, 689.
- communis digitorum, 308.
- indicii, 311.
- longus digitorum pedis, 686.
- minimi digiti, 309.
- ossis metacarpi pollicis, 310.
- primi internodii pollicis, 311.
- proprius hallucis, 685.
- secundi internodii pollicis, 311.
- flexor accessorius, 676.
 - brevis minimi digiti manus, 303.
 - brevis minimi digiti pedis, 678.
 - carpi radialis, 287, 306.
 - ulnaris, 288.
 - digitorum brevis pedis, 671.
 - longus pedis, 666, 675.
 - profundus, 293, 300.
 - sublimis, 289, 300.
 - hallucis brevis, 677.
 - longus, 665, 676.
 - perforans, 293, 666.
 - perforatus, 289, 671.
 - pollicis brevis, 301.
 - longus, 294, 300.
- gastrocnemius, 662.

Muscle or Musculus:—

- gemellus inferior, 642.
 - superior, 641.
- genio-glossus, or genio-hyo-glossus, 96, 151.
 - hyoid, 96.
- gluteus maximus, 633.
 - medius, 636.
 - minimus, 637.
- gracilis, 623.
- of helix, 34.
- hyo-glossus, 95, 150.
- iliacus, 532, 629.
- ilio-costalis, 391.
- indicator, 311.
- infraspinatus, 265.
- intercostals, 257, 370, 403.
- interosseous, of foot, 681.
 - of hand, 305.
- interspinales, 401.
- intertransversales, 171, 401.
- ischio-cavernosus, 425, 433.
- kerato-cricoid, 155.
- latissimus dorsi, 256, 385.
- levator anguli oris, 25.
 - scapulæ, 261, 387.
 - ani, 420, 543.
 - glandulæ thyroideæ, 118.
 - labii inferioris, 25.
 - superioris, 25.
 - alæque nasi, 21.
 - menti, 25.
 - palati, 129.
 - palpebræ, 32, 41.
- levatores costarum, 403.
- linguales, 152.
- longissimus dorsi, 392.
- longus colli, 169.
- lumbricales of foot, 676.
 - of hand, 300
- masseter, 81.
- multifidus spinæ, 400.
- mylo-hyoid, 93.
- obliquus abdominis externus, 441.
 - internus, 444.
 - capitis inferior, 399.
 - superior, 399.
 - oculi, inferior, 48.
 - superior, 42.
- obturator externus, 630, 644.
 - internus, 588, 642.
- occipito-frontalis, 2.
- omo-hyoid, 64, 261, 387.
- opponens minimi digiti, 303.
 - pollicis, 301.
- orbicularis oris, 23.
 - palpebrarum, 22.
- orbitalis, 50.
- palato-glossus, 130, 150.
 - pharyngeus, 124, 130.
- palmaris brevis, 296.
 - longus, 288.
- pectineus, 624.
- pectoralis major, 249, 250.
 - minor, 250, 262.
- peroneus brevis, 691.
 - longus, 682, 690.
 - tertius, 686.

Muscle or Musculus:—

- perpendicular of tongue, 152.
- pharyngo-glossus, 151.
- plantaris, 663.
- platysma myoides, 52, 58.
- popliteus, 664, 693.
- pronator quadratus, 294.
 - radii teres, 286.
- psoas magnus, 531, 629.
 - parvus, 532.
- pterygoid, external, 84.
 - internal, 84.
- pyramidalis abdominis, 449.
 - nasi, 21.
- pyriformis, 588, 638.
- quadratus femoris, 642.
 - lumborum, 533.
- quadriceps extensor cruris, 619.
- rectus abdominis, 448.
 - capitis anticus major, 169.
 - minor, 170.
 - lateralis, 112.
 - posticus major, 398.
 - minor, 399.
- femoris, 619, 638.
- oculi externus, 47.
 - inferior, 47.
 - internus, 47.
 - superior, 42.
- retrahens aurem, 2.
- rhomboideus major, 261, 387.
 - minor, 261, 387.
- risorius Santorini, 26.
- rotatores dorsi, 400.
- sacro-lumbalis, 391.
- salpingo-pharyngeus, 130.
- sartorius, 614.
- scaleni, 67.
- semimembranosus, 652, 693.
- semispinalis colli, 400.
 - dorsi, 400.
- semitendinosus, 650.
- serratus magnus, 257, 262.
 - posticus inferior, 389.
 - superior, 389.
- soleus, 663.
- sphincter ani externus, 420.
 - internus, 420.
- pupillæ, 722.
- vaginæ, 433.
- spinalis dorsi, 392.
- splenius capitis, 390.
 - colli, 390.
- stapedius, 737.
- sterno-cleido-mastoid, 63.
 - hyoid, 64.
 - thyroid, 64.
- stylo-glossus, 95, 150.
 - hyoid, 76.
 - pharyngeus, 102, 124.
- subclavius, 251.
- subcostal, 369.
- subcrureus, 621.
- subscapularis, 262.
- supinator radii brevis, 312.
 - longus, 307.
- supraspinatus, 268.
- temporal, 4, 82.

Muscle or Musculus:—

- tensor fasciæ latæ, 618.
 - palati, 129.
 - tarsi, 49.
 - tympani, 737.
 - vaginæ femoris, 618.
- teres major, 266.
 - minor, 266.
- thyro-arytenoid, 157.
 - epiglottidean, 157.
 - hyoid, 65.
- tibialis anticus, 685.
 - posticus, 666, 681.
- trachelo-mastoid, 392.
- of tragus, 34.
- transversalis abdominis, 447.
 - colli, 392.
 - linguæ, 151.
- transverse of auricle, 34.
- transverso-spinales, 399.
- transversus pedis, 677.
 - perinei, 426, 433.
 - alter, 426.
 - profundus, 429, 434.
- trapezius, 383.
- triangularis sterni, 259.
- triceps of arm, 279.
- vastus externus, 619.
 - internus, 620.
- zygomaticus major, 26.
 - minor, 26.
- Musculi papillares, 344, 347.
 - pectinati, 342, 346.
- Musculo-phrenic artery, 260, 528.
 - cutaneous nerve. *See* Nerve.
 - spiral nerve, 256, 272, 281.
- Mylo-hyoid artery, 88.
 - muscle, 93.
 - nerve, 91.
- Nares, 30, 125.
- Nasal arteries. *See* Artery.
 - cartilages, 30.
 - duct, 50.
 - fossæ, 134.
 - nerves. *See* Nerve.
- Naso-palatine artery, 143.
 - nerve, 140.
- Nates, of brain, 224.
- Neck, anterior triangle of, 60.
 - posterior, 53.
 - dissection of, 51.
- Nerve or Nerves:—
 - abducent, (o) 189, (c) 18, (d) 47.
 - accessory, obturator, 537, 625.
 - spinal, (o) 190, (c) 19, 56, 111, (d) 111, 384
 - acromial cutaneous, 57, 263.
 - Arnold's, 110, 740.
 - articular of popliteal, 649.
 - auditory, (o) 189, (c) 18, 145, (d) 747.
 - auricular anterior, 8, 91.
 - great, 8, 57.
 - inferior, 91.
 - posterior, 8, 36.
 - superior, 8.
 - of vagus, 110, 740.

Nerve or Nerves:—

- auriculo-temporal, 8, 90.
- buccal of facial, 38.
 - of inferior maxillary, 90.
- calcaneo-plantar, 669.
- cardiac inferior, (o) 115, 120, (d) 359.
 - middle, (o) 115, 120, (d) 359.
 - superior, (o) 114, 120, (d) 359.
- of vagus, 111, 357, 359.
- cavernous, 565.
- cervical, anterior branches, 71, 112, 171.
 - posterior branches, 171, 382, 395.
 - branch of facial, 59.
 - superficial, 57, 59.
- cervico-facial, 38.
- chorda tympani, 92, 98, 145, 740.
- ciliary, long, 43, 724.
 - short, 45, 724.
- circumflex, (o) 256, (d) 263, 264.
- clavicular, cutaneous, 57, 244.
- coccygeal, 402, 410, 562.
- cochlear, 747.
- communicating, to descendens noni, 74.
 - fibular or peroneal, 649.
 - tibial, 649.
- of Cotunnus, 140.
- crural, anterior, 536, 622.
- cutaneous, anterior, 244, 438.
 - external, of arm. *See* Musculo-cutaneous.
 - of leg, 649, 660.
 - of musculo-spiral, 272, 281, 284.
 - of thigh, 536, 603, 632.
 - internal, of arm, large, (o) 256, (c) 278, (d) 272, 284.
 - of arm, small, (o) 256, (c) 278, (d) 272.
 - of musculo-spiral, 272, 281.
 - of thigh, 604, 622, 662.
 - lateral, 244, 437.
 - middle, of thigh, 603, 622.
 - palmar, 292, 293, 295.
 - plantar, 669, 674.
 - radial, 284.
- dental, anterior, 100.
 - inferior, 91.
 - middle, 100.
 - posterior, 100.
- descendens noni, 77.
- to digastric, 36.
- digital, dorsal of toes, 683.
 - of median, 298.
 - palmar, 298.

Nerve or Nerves:—

- digital, plantar, 674, 675.
 - of radial, 284.
 - of ulnar, 285, 298. [403.]
- dorsal, anterior branches, 260, 370, [403.]
 - posterior branches, 382, 395, last, 438, 450, 537, 631.
 - of clitoris, 434, 440.
 - of penis, 422, 430, 440.
 - of ulnar, 285, 292.
- facial, (o) 189, (c) 18, 143, (d) 35.
- frontal, 40.
- genito-crural, 452, 536, 603.
- glosso-pharyngeal, (o) 190, (c) 19, 98, 108, (d) 108, 153.
- gluteal, inferior, 564, 640.
 - superior, 564, 623, 637.
- gustatory. *See* Lingual.
- hæmorrhoidal, inferior, 421.
 - superior, 483.
 - of fourth sacral, 562.
- hypoglossal, (o) 191, (c) 19, 77, 112, (d) 98, 153.
- ilio-hypogastric, 438, 450, 536, 632.
- inguinal, 438, 450, 536, 603.
- incisor, 91.
- inframaxillary of facial, 38, 59.
- infraorbital of facial, 38.
- infraorbital of fifth, 50, 101.
- infratrochlear, 43.
- intercostal, 260, 370, 403, 449.
- intercosto-humeral, 244, 272.
- interosseous, anterior, 293, 294.
 - posterior, 313.
- of Jacobson, 108, 739.
- labial, inferior, 91.
 - superior, 101.
- lacrimal, 40.
- of Lancisi, 213.
- laryngeal, external, 110.
 - inferior or recurrent, (o) 111, 357, (d) 111, 162.
 - superior, (o) 110, (d) 162.
- lingual, 92, 97, 153.
- lumbar, anterior branches, 535.
 - posterior branches, 382, 397, 632.
- lumbo-sacral, 535.
- malar of facial, 37.
 - of superior maxillary, 49.
- masseteric, 89.
- maxillary, inferior, 18, 89.
 - superior, 18, 100.
- median, (o) 256, (c) 277, 292, (d) 292, 298.
- meningeal, 16, 407.
- mental, 91.
- musculo-cutaneous of arm, (o) 256, (c) 278, (d) 278, 284.
- musculo-cutaneous of leg, 683, 690.
- musculo-spiral, (o) 256, (d) 272, 281.
- mylo-hyoid, 91.
- nasal, (o) 40, (d) 43, 142.
 - lateral, 101.
 - of Meckel's ganglion, 140, 141, 142.
- naso-palatine, 140.

Nerve or Nerves:—

- obturator, (o) 536, (d) 625, 649.
 - accessory, 537, 625.
- to obturator internus, 564, 641.
- occipital, great, 8, 382, 395.
 - small, 8, 56.
- oculomotor, (o) 188, (c) 16, (d) 43, 47.
- oesophageal, 358.
- olfactory, (o) 187, (c) 16, (d) 137.
- ophthalmic, 18, 40.
- optic, 16, 46, 187.
- orbital, (o) 100, (d) 49.
 - of Meckel's ganglion, 141.
- palatine, external, 141.
 - large, 140.
 - small, 141.
- palmar cutaneous, 295.
- palpebral, 6, 7, 33, 40, 101.
- parotid, 91.
- patellar, 604, 623.
- perforating cutaneous, 422, 564, 632.
- perineal, 421, 426.
 - of fourth sacral, 422, 562.
 - superficial, 424, 433.
- peroneal, 649.
 - communicating, 649.
- petrosal, deep, large, 142.
 - small, 739.
 - superficial, external, 145.
 - large, 20, 142, 145.
 - small, 20, 145, 146, 739.
- pharyngeal, 108, 110, 114, 141.
- phrenic, 74, 356.
- plantar, external, 675, 680.
 - internal, 674.
- pneumo-gastric, (o) 190, (c) 19, 109, 357, (d) 110, 357, 493.
- popliteal external, 649.
 - internal, 649.
- prostatic, 565.
- pterygoid, external, 90.
 - internal, 92, 147.
- pudendal, inferior, (o) 641, (d) 425, 433.
- pudic, (o) 564, (c) 641, (d) 421, 434.
- pulmonary, 358, 362.
- to pyriformis, 564.
- to quadratus femoris, 564, 641.
- radial, 284, 293.
- recurrent laryngeal, (o) 111, 357, (d) 111, 162.
 - articular, 690.
- to rhomboids, 73, 388.
- sacral, anterior branches, 561.
 - posterior branches, 401, 632, 636.
- saphenous, external, 649, 660, 683.
 - internal, 604, 623, 660, 684.
- to scaleni, 73, 74.
- sciatic, great, 563, 641, 652.
 - small, 564, 632, 640, 652, 662.
- to serratus, 73, 256.
- spermatic, 483.
- spheno-palatine, 100, 140.
- spinal, 407.

Nerve or Nerves:—

- spinal, accessory, (o) 190, (c) 19, 111, (d) 111, 384.
 - splanchnic, large, 369, 493.
 - small, 369, 493.
 - smallest, 369, 493.
 - splenic, 492.
 - sternal cutaneous, 57, 244.
 - to stylo-hyoid, 36.
 - to subclavius, 73.
 - suboccipital, anterior branch, 112.
 - posterior branch, 395.
 - subscapular, 256.
 - supramaxillary of facial, 38.
 - supraorbital, 6, 40.
 - suprascapular, 73, 269, 388.
 - supratrochlear, 7, 40.
 - sympathetic, in abdomen, 482, 491, 537.
 - in head, 19.
 - in neck, 112.
 - in pelvis, 564.
 - in thorax, 358, 368.
 - temporal of facial, 8, 37.
 - deep, 89.
 - superficial, 7, 37.
 - of superior maxillary, (o) 50, (d) 8.
 - temporo-facial, 37.
 - malar, (o) 100, (d) 49.
 - to tensor palati, 147.
 - tympani, 146.
 - vaginæ femoris, 623.
 - to teres major, 256.
 - minor, 264.
 - thoracic, anterior, 256.
 - posterior, 73, 256.
 - thyroid, 115.
 - tibial, anterior, 683, 690.
 - communicating, 649.
 - posterior, 668.
 - tonsillitic, 109.
 - trifacial or trigeminal, 17, 189.
 - trochlear, (o) 188, (c) 17, (d) 40.
 - tympanic, (o) 108, (d) 739.
 - ulnar, (o) 256, (c) 278, 292, (d) 285, 292, 298, 304.
 - uterine, 565.
 - vaginal, 565.
 - vagus, (o) 190, (c) 19, 109, 357, (d) 110, 357, 493.
 - vesical, 565.
 - vestibular, 747.
 - Vidian, 142.
 - of Wrisberg, (o) 256, (c) 278, (d) 272.
- Nervi molles, 114.
- Ninth nerve, 19, 108, 190.
- Nipple of the breast, 242, 246.
- Nodule of cerebellum, 230.
- Nose, cartilages of, 30.
 - cavity of, 134.
 - external, 29.
 - meatuses of, 135.
 - muscles of, 21.
 - nerves and vessels of, 137, 140, 143.
- Nostril, 30.
- Notch of Rivinus, 734.
- Nuck, canal of, 451.

- Nuclei arciformes, 198.
 of cranial nerves, 235.
 of medulla oblongata, 197, 198.
 of optic thalamus, 224.
 pontis, 199.
 Nucleus, caudate, 221.
 of funiculus cuneatus, 198.
 gracilis, 198.
 lateral, 198.
 of lens, 727.
 lenticular, 221.
 olivary, 197.
 superior, 199.
 red, of tegmentum, 202.
 Nymphæ, 432.
 Oblique ligament, 320.
 muscles. *See* Muscle.
 Obturator artery, 559, 630.
 fascia, 541.
 membrane, 593.
 muscles. *See* Muscle.
 nerve, 536, 625.
 Occipital artery, (o) 80, (c) 397, (d) 6.
 lobe of cerebrum, 206, 209.
 lobule, 211.
 nerves. *See* Nerve.
 sinus, 13.
 veins, 6, 80.
 Occipito-atlantal articulations, 176.
 ligaments, 173.
 axial ligaments, 175.
 frontalis muscle, 2.
 temporal convolutions, 211.
 Oculomotor nerve, (o) 188, (c) 16, (d) 43, 47.
 Odontoid ligaments, 176.
 Œsophagus, relations of, 119, 366.
 structure of, 131, 366.
 Œsophageal arteries, 364, 487.
 groove in liver, 507.
 nerves, 111, 358.
 opening of diaphragm, 531.
 Olfactory bulb, 203.
 lobe, 201, 203.
 nerves, (o) 187, (c) 16, (d) 137.
 region of nose, 137.
 striæ, 204.
 sulcus, 204, 208.
 tract, 204.
 Olivary body, 193, 197.
 nucleus, 197.
 superior, 199.
 peduncle, 197.
 Omental tuberosity of liver, 507.
 of pancreas, 486.
 Omentum, gastro-colic or great, 476.
 gastro-hepatic or small, 476.
 gastro-splenic, 477.
 Omo-hyoid muscle, 64, 261, 387.
 Operculum, 207.
 Ophthalmic artery, 19, 45.
 ganglion, 44.
 nerve, (o) 18, (c) 18, (d) 40.
 veins, 46.
 Opponens. *See* Muscle.
 Optic commissure, 187.
 disc, 725.
 nerve, (o) 187, 225, (c) 16, 46, (d) 724.
 Optic papilla, 725.
 thalamus, 223.
 tract, 187, 225.
 Ora serrata, 725.
 Orbicular ligament of the radius, 319.
 Orbicularis oris, 23.
 palpebrarum, 22.
 Orbit, 38, 99.
 muscles of, 41, 47.
 nerves, 40.
 periosteum of, 39.
 vessels, 45.
 Orbital branches of nerve, 49, 100, 141.
 branch of artery, 81.
 lobule, 206, 208.
 Orbitalis muscle, 50.
 Organ of Corti, 745.
 of Giraldu, 521.
 of Rosenmüller, 586.
 Orifice of the urethra, 432, 551, 573.
 of the uterus, 582.
 of the vagina, 432.
 Ossicles of the tympanum, 735.
 Os tinæ, 582.
 uteri externum, 582.
 Otic ganglion, 145.
 Otoliths, 746.
 Outlet of the pelvis, 417, 542.
 Oval lobule, 211.
 Ovarian artery, 528, 586.
 vein, 531, 586.
 Ovary, 555, 585.
 appendage to, 586.
 vessels of, 528, 531, 560, 586.
 Ovisacs, 585.
 Pacchionian bodies, 9, 10.
 Palate (soft), 127.
 Palatine arteries. *See* Artery.
 nerves. *See* Nerve.
 Palato-glossus, 130, 150.
 Palato-pharyngeus, 124, 130.
 Palm of the hand, 295.
 Palmar arch, deep, 304.
 superficial, 297.
 cutaneous nerves, 295.
 fascia, 296.
 Palmaris brevis muscle, 296.
 longus muscle, 288.
 Palpebræ, 31.
 Palpebral arteries, 33, 46.
 fascia or ligament, 31.
 fissure, 31.
 nerves, 33.
 veins, 27, 33.
 Pampiniform plexus, 586.
 Pancreas, 503.
 relations of, 486.
 structure of, 503.
 Pancreatic arteries, 487.
 duct, 498, 504.
 veins, 490.
 Pancreatico-duodenal arteries, 479, 488.
 Papilla lachrymalis, 31.
 optica, 725.
 Papillæ of the kidney, 514.
 of the tongue, 148.
 Paracentral lobule, 211.

- Paradidymis, 521.
 Parallel sulcus, 209.
 Parietal lobe, 206, 208.
 lobules, 208.
 Parieto-occipital fissure, 206, 210.
 Parotid arteries, 29.
 gland, 28.
 lymphatic glands, 28.
 nerves, 91.
 Parovarium, 586.
 Patellar nerve, 604.
 plexus, 604.
 Pecten of Reil, 227.
 Pectineus muscle, 624.
 Pectoralis. *See* Muscle.
 Peduncle of the cerebellum, inferior, 193, 233.
 middle, 232.
 superior, 202, 232.
 of the cerebrum, 200, 201.
 of the corpus callosum, 203, 213.
 olivary, 197.
 Peduncular fibres, 226.
 Pelvis, dissection of, 539.
 muscles and ligaments of, 588.
 of ureter, 515.
 vessels and nerves of, 556.
 viscera of, female, 552, 579.
 male, 545, 565.
 Pelvic cavity, 539.
 fascia, 541.
 plexus, 564.
 Penis, 551.
 integument of, 439.
 structure of, 575.
 vessels of, 440, 576.
 Perforated space, anterior, 203.
 posterior, 202.
 Perforating arteries. *See* Artery.
 cutaneous nerve, 422, 564, 632.
 Pericardium, 336.
 Perilymph, 742.
 Perineum, female, 431.
 male, 416.
 Perineal artery, superficial, 424.
 fascia, deep, 427.
 superficial, 423, 433.
 nerves, 421, 424, 426, 433.
 Periosteum of the orbit, 39.
 Peritoneal prolongation on the cord, 451.
 Peritoneum, 473.
 of female pelvis, 552.
 of male pelvis, 546.
 Peroneal artery, 668.
 nerve, 649.
 Peroneus. *See* Muscle.
 Peroneo-tibial articulations, 700.
 Perpendicular fissure, 210.
 muscle of tongue, 152.
 Pes hippocampi, 217.
 Petit, canal of, 727.
 Petrosal sinuses, 15.
 nerves. *See* Nerve.
 Petrous ganglion, 108.
 Peyer's glands, 499.
 Pharynx, 121.
 interior of, 125.
 muscles of, 122.
 Pharynx, openings of, 125.
 Pharyngeal, ascending, artery, 106.
 nerves, 108, 110, 114.
 tonsil, 131.
 veins, 106.
 Pharyngeoglossus muscle, 151.
 Phrenic arteries. *See* Artery.
 nerve, 74, 356.
 plexus, 492.
 Pia mater of the brain, 181.
 of the cord, 406.
 Pigmentary layer of retina, 724.
 Pillars of the abdominal ring, 442.
 of diaphragm, 524.
 of the fornix, 224.
 of the iris, 718.
 of the soft palate, 125, 128.
 Pineal body, 225.
 stria, 223, 225.
 Pinna, or auricle of the ear, 33.
 Pituitary body, 203.
 membrane, 136.
 Plantar aponeurosis or fascia, 670.
 arch of artery, 679.
 arteries, 672.
 ligament, long, 706.
 short, 707.
 nerves, 674, 680.
 Plantaris muscle, 663.
 Platysma myoides muscle, 52, 58.
 Pleura, 332.
 Pleuro-colic fold, 477.
 Plexus of nerves :—
 aortic, 483.
 brachial, 71, 254.
 cardiac, deep, 359.
 superficial, 341.
 carotid, 19.
 cavernous, 19.
 cervical, 56, 73.
 coeliac, 492.
 coronary of heart, 342.
 of stomach, 492.
 cystic, 492.
 diaphragmatic, 492.
 epigastric, 491.
 gulæ, 358.
 hepatic, 492.
 hæmorrhoidal, 483, 565.
 hypogastric, 483.
 infraorbital, 38.
 lumbar, 535.
 mesenteric, inferior, 483.
 superior, 483.
 ovarian, 483, 565.
 pancreatico-duodenal, 492.
 patellar, 604.
 pelvic, 564.
 pharyngeal, 110.
 phrenic, 492.
 prostatic, 565.
 pulmonary, 358.
 pyloric, 492.
 renal, 492.
 sacral, 562.
 solar, 491.
 spermatic, 483.
 splenic, 492.

- Plexus of nerves :—**
 suprarenal, 492.
 tympanic, 738.
 uterine, 565.
 vesical, 565.
 vertebral, 115, 172.
- Plexus of veins :—**
 alveolar, 89.
 basilar, 15.
 choroid, 219, 235.
 hæmorrhoidal, 560.
 ovarian, 531, 586.
 pampiniform, 586.
 prostatic, 560, 567.
 pterygoid, 89.
 spermatic, 522.
 uterine, 560.
 vaginal, 560.
 vesical, 560.
- Plica fimbriata**, 149.
 semilunaris, 32.
- Pneumo-gastric nerve**, (o) 190, (c) 19, 109, 357, (d) 110, 357, 493.
- Pons Varolii**, 198.
- Popliteal artery**, 646.
 glands, 649.
 nerves, 649.
 space, 645.
 vein, 648.
- Popliteus muscle**, 664, 693.
- Portal fissure**, 508.
 vein, 489.
- Portio dura**, 189.
 intermedia, 189.
 mollis, 189.
- Porus opticus**, 725.
- Posterior commissure**, 225.
 pyramid, 193.
 triangle of the neck, 53.
- Postcentral sulcus**, 208.
- Poupart's ligament**, 443, 606.
- Pouch, laryngeal**, 159.
 recto-uterine, 553.
 recto-vesical, 546.
 vesico-uterine, 553.
- Præcentral sulcus**, 207.
- Præputium clitoridis**, 432.
- Prepuce**, 439.
- Prevertebral muscles**, 169.
- Profunda artery**. *See Artery.*
- Promontory**, 731.
- Pronator**. *See Muscle.*
- Prostate gland**, 566.
 relations, 549.
 structure, 567.
- Prostatic part of urethra**, 550, 572.
 sinus, 573.
- Psoas magnus muscle**, 531, 629.
- Psoas parvus muscle**, 532.
- Pterygoid arteries**, 88.
 muscles. *See Muscle.*
 nerves. *See Nerve.*
 plexus of veins, 89.
- Pterygo-maxillary ligament**, 26, 124.
 region, 81.
 palatine artery, 143.
- Pubes**, 435.
- Pubic part of fascia lata**, 605.
- Pubic region of the abdomen**, 466.
 symphysis, 592.
- Pubo-femoral ligament**, 654.
- Pudendal, inferior, nerve**, (o) 646, (d) 425.
- Pudendum**, 579.
- Pudic arteries**. *See Artery.*
 nerve, 421, 434, 564.
- Pulmonary artery**, 351, 361.
 nerves, 358, 362.
 orifice and valve, 345.
 veins, 356, 362.
- Pulvinar**, 224.
- Puncta lachrymalia**, 31, 50.
- Pupil**, 722.
- Pylorus**, 494.
- Pyloric artery**, 488.
 orifice, 467, 494.
 plexus, 492.
 vein, 490.
- Pyramid, anterior**, 192, 195.
 decussation of, 195.
 of the cerebellum, 230.
 of the thyroid body, 118.
 of the tympanum, 733.
 posterior, 193.
- Pyramidal masses of kidney**, 514.
 tract, 195, 199, 202, 222.
- Pyramidalis**. *See Muscle.*
- Pyramids of Malpighi**, 514.
- Pyriformis muscle**, 588.
 fascia of, 541.
- Quadrangle lobe of cerebellum**, 230.
 of liver, 508.
 lobule of cerebrum, 211.
- Quadratus**. *See Muscle.*
- Quadriceps extensor cruris**, 619.
- Quadrigeminal bodies**, 224.
- Radial artery**, 288, 303, 313.
 nerve, 284, 293.
 veins, 289.
 cutaneous, 283.
- Radio-carpal articulation**, 320.
- Radio-ulnar articulations**, 319, 322.
- Ranine artery**, 96.
 vein, 96.
- Raphé of the corpus callosum**, 213.
 of the medulla oblongata, 197.
 of the palate, 132.
 of the perineum, 416.
 of the pons, 199.
 of the tongue, 147.
- Receptaculum chyli**, 534.
- Recto-uterine ligaments**, 553.
 pouch, 553.
 vesical fascia, 541, 544.
 pouch, 546.
- Rectus**. *See Muscle.*
- Rectum, relations of, in the female**, 553.
 in the male, 547.
 structure, 578.
- Recurrent arteries**. *See Artery.*
 nerve of vagus, 111, 162, 357.
 nerve of popliteal, 690.
- Red nucleus**, 202.

- Reil, covered band of, 212, 227.
 island of, 206.
 pecten of, 227.
 sulci of, 207.
 Renal artery, 515, 528.
 impression on liver, 508.
 plexus, 492.
 vein, 515, 531.
 Respiratory glottis, 158.
 region of nose, 137.
 Restiform body, 193, 196.
 Rete testis, 520.
 Reticular formation, 197, 199, 202.
 Retina, 724.
 Retinacula of fascia lata, 605.
 of ileo-cæcal valve, 502.
 Retrahens aurem, 2.
 Rhomboid ligament, 178.
 Rhomboidei muscles, 261, 387.
 Rima glottidis, 158.
 of the vulva, 432.
 Ring, abdominal, external, 442.
 internal, 450, 457.
 crural or femoral, 463, 608.
 Risorius Santorini muscle, 26.
 Rivinus, ducts of, 99.
 notch of, 734.
 Rolando, funiculus of, 193, 196.
 furrow of, 206.
 tubercle of, 193, 198.
 Roof-nucleus of cerebellum, 232.
 Root of the lung, 336.
 Roots of the nerves, 408.
 Rosenmüller, organ of, 586.
 Rostrum of corpus callosum, 203.
 Rotatores dorsi, 400.
 Round ligament. *See* Ligament.

 Sacculæ of the ear, 746.
 Sacculus laryngis, 159.
 Saccus endolymphaticus, 747.
 Sacral arteries. *See* Artery.
 ganglia, 564.
 nerves. *See* Nerve.
 plexus, 562.
 Sacro-coccygeal articulation, 589.
 iliac articulation, 590.
 lumbalis muscle, 391.
 sciatic ligaments, 591, 644.
 vertebral articulation, 590.
 Salpingo-pharyngeus muscle, 130.
 Santorini, cartilages of, 165.
 Saphenous nerves. *See* Nerve.
 opening, 605.
 veins. *See* Vein.
 Sartorius muscle, 614.
 Scala tympani, 745.
 vestibuli, 745.
 Scaleri muscles, 67.
 Scapular arteries. *See* Artery.
 ligaments, 268.
 muscles, 261, 265.
 Scapulo-clavicular articulation, 267.
 humeral articulation, 314.
 Scarpa, fascia of, 437.
 triangle of, 610.
 Schneiderian membrane, 136.
 Sciatic artery, 559, 639.
 Sciatic nerves. *See* Nerve.
 Sclerotic coat of the eye, 717.
 Scrotum, 439.
 Second nerve, 16, 46, 187.
 Secondary membrane of the tympanum, 731, 734.

 Semicircular canals, 741.
 membranous, 746.
 Semilunar cartilages, 697.
 fold of Douglas, 449.
 ganglia, 492.
 Semi-bulbs of vestibule, 580.
 Semimembranosus muscle, 652, 693.
 Seminal ducts, 569.
 Seminiferous tubes, 519.
 Semispinalis muscle, 400.
 Semitendinosus muscle, 650.
 Septum cochleæ, 743.
 crurale, 463, 609.
 intermuscular, of the arm, 280.
 of the leg, 662, 684.
 of the sole, 670.
 of the thigh, 621.

 lucidum, 215.
 narium, 30.
 nasi, 134.
 pectiniforme, 576, 580.
 posterior median of spinal cord, 412.
 posterior intermediate, 414.
 posticum of arachnoid, 406.
 scroti, 439.
 of the tongue, 149.
 Serratus. *See* Muscle.
 Seventh nerve, (o) 189, (c) 18, 143, (d) 35.
 Sheath, axillary, 251.
 crural, 463, 607.
 of the fingers, 297.
 of the rectus, 448.
 of the toes, 671.
 Shoulder-joint, 314.
 Sigmoid artery, 481.
 flexure of the colon, 471.
 Sinus, basilar, 15.
 of the bulb, 573.
 cavernous, 14.
 circular, 15.
 coronary, 340.
 frontal, 136.
 intercavernous, 15.
 of the kidney, 513.
 lateral, 13.
 longitudinal, inferior, 13.
 superior, 10.
 occipital, 13.
 petrosal, inferior, 15.
 superior, 15.
 pocularis, 573.
 prostatic, 573.
 sphenoidal, 134.
 straight, 13.
 torcular, 10, 14.
 transverse, 15.
 of Valsalva, 345, 348, 353.
 Sixth nerve, (o) 189, (c) 18, (d) 47.
 Small intestine, 469, 496.
 omentum, 476.
 Socia parotidis, 28.

- Scemmering's enumeration of the cranial nerves, 187.
 Soft commissure, 220, 221.
 palate, 127.
 muscles of, 128.
 Solar plexus, 491.
 Sole of the foot, dissection of, 669.
 Soleus muscle, 663.
 Solitary glands, 499, 503.
 Spermatic artery, 521, 528.
 cord, 451.
 fascia, 443, 457.
 plexus of nerves, 483.
 veins, 521, 531.
 Sphenoidal sinus, 134.
 Spheno-palatine artery, 143.
 ganglion, 140.
 nerves, 100.
 Sphincter. *See* Muscle.
 Spigelian lobe, 508.
 Spinal accessory nerve, (o) 190, (c) 19, 56, 111, (d) 111, 384.
 nucleus, 190.
 arteries, 182, 410.
 cord, 410.
 membranes of, 404.
 structure of, 412.
 nerves, 407.
 posterior branches of, 395.
 roots of, 408.
 veins, 415.
 Spinalis dorsi muscle, 392.
 Spiral ganglion, 747.
 groove, 744.
 ligament, 745.
 tube of the cochlea, 743.
 Splanchnic nerves. *See* Nerve.
 Spleen, 504.
 relations, 472.
 structure, 504.
 Spleneuli, 504.
 Splenic artery, 487, 505.
 flexure of colon, 470.
 plexus of nerves, 492.
 vein, 490.
 Splenium of corpus callosum, 213.
 Splenius muscle, 390.
 Spongy bones, 135.
 part of the urethra, 550, 573.
 Stapedius muscle, 737.
 Stapes bone, 736.
 Stellate ligament, 372.
 Stenson's duct, 28.
 Sternal arteries, 259.
 cutaneous nerves, 57.
 Sterno-clavicular articulation, 177.
 cleido-mastoid muscle, 63.
 hyoid muscle, 64.
 mastoid artery. *See* Artery.
 thyroid muscle, 64.
 Stomach, form and divisions of, 494.
 relations of, 467.
 structure of, 494.
 Straight sinus, 13.
 Striate body, 221.
 Striæ longitudinales of corpus callosum, 213.
 Stylo-hyoid ligament, 102.
 muscle, 76.
 Stylo-hyoid nerve, 36.
 glossus muscle, 95, 150.
 mastoid artery, 80.
 maxillary ligament, 86.
 pharyngeus muscle, 102, 124.
 Subarachnoid space of the brain, 181.
 of the cord, 406.
 Subclavian artery, left, 116, 354.
 right, 67.
 vein, 71.
 Subclavius muscle, 251.
 Subcostal muscles, 369.
 Suberureus, 621.
 Subcutaneous malar nerve, 49.
 Subdural space, 9, 181, 406.
 Sublingual artery, 96.
 gland, 98.
 Submaxillary ganglion, 97.
 gland, 63, 92, 98.
 lymphatic glands, 63.
 region, 92.
 Submental artery, 80.
 Suboccipital lymphatic glands, 57.
 nerve. *See* Nerve.
 triangle, 399.
 Subpeduncular lobe, 230.
 Subperitoneal fat, 451, 463, 609.
 Subpubic ligament, 592.
 Subscapular artery, 254.
 nerves, 256.
 Subscapularis muscle, 262.
 Substantia ferruginea, 234.
 gelatinosa, 198, 413.
 nigra, 202.
 Sulci of cerebrum, 204, 207.
 of spinal cord, 411.
 Sulcus spiralis, 744.
 Superficial cervical artery, 388.
 fascia of the abdomen, 437.
 of the perineum, 423.
 of the thigh, 599, 601.
 volar artery, 289.
 Supinator. *See* Muscle.
 Supraacromial nerves, 263.
 Supraclavicular nerves, 57.
 Supramarginal convolution, 208.
 Supramaxillary nerves, 38.
 Supraorbital artery, 5, 45.
 nerve, 6, 40.
 Suprarenal capsule, 516.
 impression on liver, 506.
 plexus, 492.
 Suprascapular artery, 70, 269, 388.
 ligament, 268.
 nerve, 73, 269, 388.
 vein, 70.
 Supraspinatus muscle, 268.
 Suprasternal fossa, 52.
 Supratrochlear nerve, 7, 40.
 Suspensory ligament. *See* Ligament.
 Sylvius, aqueduct of, 226.
 fissure of, 205.
 valley of, 203.
 Sympathetic nerve. *See* Nerve.
 Symphysis pubis, 592.
 Synovial gland of Havers, 657.
 Tænia hippocampi, 216, 217.

- Tænia semicircularis, 223.
 Tarsal artery, 688.
 articulations, 704.
 fibrous plates, 32.
 glands, 32.
 ligaments of eyelids, 32.
 Tarso-metatarsal articulations, 709.
 Tarsus of eyelid, 32.
 Teeth, 133.
 Tegmen tympani, 733.
 Tegmentum, 202.
 Temporal aponeurosis, 4.
 arteries. *See* Artery.
 fascia, 4.
 muscle, 4, 82.
 nerves. *See* Nerve.
 veins. *See* Vein.
 Temporo-facial nerve, 37.
 malar nerve, 49, 100.
 maxillary articulation, 85.
 sphenoidal lobe, 206, 209.
 Tendo Achillis, 663.
 palpebrarum, 32.
 Tendon of quadriceps extensor, 620.
 Tensor. *See* Muscle.
 Tenth nerve, 19, 108, 109, 190, 357, 493.
 Tentorium cerebelli, 12.
 Teres muscles, 266.
 Testes, 517.
 of brain, 224.
 Thebesian foramina, 343.
 valve, 343.
 Thigh, dissection of, back, 644, 650.
 front, 598.
 Third nerve, (o) 188, (c) 16, (d) 43, 47.
 ventricle, 219.
 Thoracic arteries. *See* Artery.
 duct, 116, 367, 534.
 ganglia, 368.
 Thorax, boundaries of, 330.
 parietes of, 257, 369.
 upper aperture of, 117.
 Thymus body, 334.
 Thyro-arytenoid ligaments, 160, 161.
 muscle, 157.
 epiglottidean ligament, 167.
 muscle, 157.
 hyoid membrane, 166.
 muscle, 65.
 Thyroid arteries. *See* Artery.
 axis, 70.
 body, 63, 118.
 cartilage, 163.
 veins. *See* Vein.
 Tibial arteries. *See* Artery.
 nerves. *See* Nerve.
 veins. *See* Vein.
 Tibialis. *See* Muscle.
 Tibio-tarsal articulation, 701.
 Tongue, 147.
 muscles of, 149.
 nerves of, 153.
 vessels of, 96.
 Tonsil, 131.
 Tonsillar artery, 80.
 nerves, 109.
 Torcular Herophili, 10, 14.
 Trabeculæ carneæ, 344.
 Trabecular structure of penis, 576, 577.
 of spleen, 505.
 Trachea, relations of, 119, 360.
 structure of, 168.
 Tracheal nerves, 111, 169.
 Trachelo-mastoid muscle, 392.
 Tract, direct cerebellar, 196.
 lateral, 192, 196.
 optic, 187, 225.
 pyramidal, 195, 199, 202, 222.
 Tragus, 33.
 muscle of, 34.
 Transverse arteries of pons, 183.
 carpal articulation, 323.
 cervical artery, 70.
 colon, 470.
 facial artery, 28, 81.
 fissure of the cerebrum, 217.
 of the liver, 508.
 ligament. *See* Ligament.
 muscle. *See* Muscle.
 perineal artery, 424.
 sinus, 15.
 tarsal articulation, 707.
 Transversalis or transversus muscle. *See*
 Muscle.
 fascia, 450, 463.
 Transverso-spinales muscles, 399.
 Trapezius muscle, 383.
 Trapezoid ligament, 267.
 Triangle of Hesselbach, 459.
 of the neck, anterior, 60.
 posterior, 53.
 of Scarpa, 610.
 Triangular fascia, 443.
 fibro-cartilage of wrist, 322.
 ligament of the urethra, 427, 434.
 space of the thigh, 610.
 surface of the bladder, 571.
 Triangularis sterni muscle, 259.
 Triceps extensor cubiti, 279.
 Tricuspid valve, 344.
 Trifacial or trigeminal nerve, (o) 189, (c) 17.
 Trigonum vesicæ, 571.
 Trochlea, 42.
 Trochlear nerve, (o) 188, (c) 17, (d) 40.
 Tube of the cochlea, 743.
 Eustachian, 125, 734.
 Fallopian, 554, 586.
 Tuber cinereum, 202.
 valvulæ, 230.
 Tubercle of Lower, 342.
 of optic thalamus, 223.
 of Rolando, 193, 198.
 Tuberculum cuneatum, 193, 198.
 Tubuli recti, 520.
 seminiferi, 519.
 Tunica albuginea testis, 518.
 propria of spleen, 505.
 Ruyschiana, 721.
 vaginalis, 517.
 oculi, 716.
 vasculosa testis, 519.
 Turbinate bones, 135.
 Twelfth cranial nerve, 19, 77, 111, 191.
 dorsal nerve, 438, 450, 537, 631.
 Tympanic artery, 88.
 membrane, 723.

Vein or Veins:—

- maxillary, internal, 89.
 - anterior internal, 28, 89.
 - median, of the forearm, 271, 284.
 - basilic, 271.
 - cephalic, 271.
 - mesenteric, inferior, 482.
 - superior, 481.
 - oblique, of heart, 340.
 - occipital, 6, 80, 398.
 - ophthalmic, 46.
 - ovarian, 531, 586.
 - palpebral, 27.
 - pancreatic, 490.
 - perineal, superficial, 424.
 - pharyngeal, 106.
 - phrenic, inferior, 531.
 - popliteal, 648.
 - portal, 489, 509, 510.
 - profunda of the thigh, 628.
 - pterygoid plexus, 89.
 - pubic, 530.
 - pudic, external, 602, 613.
 - internal, 421, 430, 560.
 - pulmonary, 356, 362.
 - pyloric, 490.
 - radial, 289.
 - cutaneous, 283.
 - ranine, 96.
 - renal, 515, 531.
 - sacral, middle, 530, 561.
 - saphenous, external, 660, 683.
 - internal, 602, 660, 682.
 - spermatic, 521, 531.
 - spinal, 410.
 - splenic, 490.
 - subclavian, 71.
 - sublingual, 97.
 - sublobular, 511.
 - supraorbital, 6.
 - suprarenal, 517, 531.
 - suprascapular, 70, 269, 388.
 - temporal, 6, 81.
 - temporo-maxillary, 29.
 - thyroid, inferior, 71, 119.
 - middle, 76.
 - superior, 79.
 - tibial, anterior, 689.
 - posterior, 668.
 - transverse cervical, 71, 388.
 - ulnar, 290.
 - cutaneous, 283.
 - umbilical, 509.
 - uterine, 560.
 - vaginal, 560.
 - vertebral, 70, 172, 398.
 - anterior, 70.
 - of the vertebræ, 415.
 - vesical, 560.
- Velum interpositum, 218.
- pendulum palati, 127.
- Vena cava, inferior, 356, 484, 530.
 - superior, 354.
- portæ, 490, 509, 510.

- Venæ cavæ hepaticæ, 511.
- Venous arch of the foot, 682.
- Ventricles of the brain, 213.
 - fifth, 216.
 - fourth, 232.
 - lateral, 214.
 - third, 219.
- of the heart, 240.
 - left, 347.
 - right, 344.
 - structure of, 350.
- of the larynx, 159.
- Vermiform appendix, 470, 501.
 - processes, 228, 230, 233.
- Vermis, 228.
- Vertebral aponeurosis, 389.
 - artery, (o) 69, (c) 171, 397, (d) 182.
 - plexus, 115, 172.
 - veins, 70, 172, 398.
- Verumontanum, 572.
- Vesica urinaria. *See* Bladder.
- Vesical arteries, 559.
 - plexus of nerves, 565.
 - veins, 560.
- Vesico-uterine ligaments, 553.
 - pouch, 553.
- Vesicula prostatica, 573.
- Vesiculæ seminales, relations, 549.
 - structure, 567.
- Vestibule of the ear, 740.
 - artery of, 748.
 - nerves of, 747.
- of the mouth, 132.
- of the nose, 136.
- of the vulva, 432.
- Vestigial fold of pericardium, 338.
- Vidian artery, 143.
 - nerve, 142.
- Vieussens, annulus or isthmus of, 342.
 - ansa of, 114.
 - valve of, 232.
- Villi, intestinal, 498.
- Vincula vasculosa, 297.
- Vitreous body, 725.
- Vocal cords, 160.
 - glottis, 158.
- Vulva, 432, 579.
- Wharton's duct, 98.
- White commissure of the cord, 413.
- Willis, circle of, 185.
 - enumeration of cranial nerves, 187.
- Windpipe, 119, 360.
- Winslow, foramen of, 477.
- Wirsung, canal of, 504.
- Worm of cerebellum, 228, 233.
- Wrisberg, nerve of, 256, 272, 278.
- Wrist-joint, 320.
- Yellow spot of eyeball, 725.
- Zonule of Zinn, 726.
- Zygomatic muscles, 26.



