

Landmarks, medical and surgical / by Luther Holden.

Contributors

Holden, Luther, 1815-1905.

Publication/Creation

London : J. & A. Churchill, 1888.

Persistent URL

<https://wellcomecollection.org/works/bw9nrxwy>

License and attribution

This work has been identified as being free of known restrictions under copyright law, including all related and neighbouring rights and is being made available under the Creative Commons, Public Domain Mark.

You can copy, modify, distribute and perform the work, even for commercial purposes, without asking permission.



Wellcome Collection
183 Euston Road
London NW1 2BE UK
T +44 (0)20 7611 8722
E library@wellcomecollection.org
<https://wellcomecollection.org>


LANDMARKS
MEDICAL AND SURGICAL
—
LUTHER HOLDEN


M15193

HENRY KIMPTON
Medical Bookseller,
& DEALER IN OSTEOLOGY,
82, HIGH HOLBORN,
LONDON, W. C.



22101442382





MEDICAL AND SURGICAL
LANDMARKS

By the same Author.

MANUAL OF DISSECTION OF THE HUMAN BODY.

Fifth Edition. With 208 Engravings, 8vo. 20s.

HUMAN OSTEOLOGY.

Comprising a Description of the Bones, with Delineations of the
Attachments of the Muscles. *Sixth Edition.*

With 59 Plates and 75 Engravings, royal 8vo. 16s.

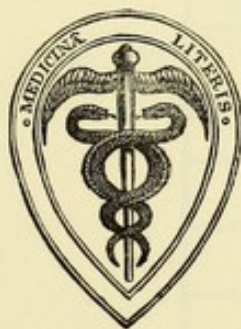LANDMARKS
MEDICAL AND SURGICAL

BY

LUTHER HOLDEN

EX-PRESIDENT OF THE ROYAL COLLEGE OF SURGEONS OF ENGLAND
CONSULTING SURGEON TO SAINT BARTHOLOMEW'S AND THE FOUNDLING HOSPITALS

FOURTH EDITION



LONDON
J. & A. CHURCHILL
11 NEW BURLINGTON STREET
1888

MIS193

WELLCOME INSTITUTE LIBRARY	
Coll.	welM0mec
Call	
No.	Q54
	1888
	H722

TO
THE STUDENTS
PAST AND PRESENT
OF
SAINT BARTHOLOMEW'S HOSPITAL

THESE 'LANDMARKS' ARE DEDICATED

BY THEIR SINCERE FRIEND

THE AUTHOR



Digitized by the Internet Archive
in 2014

PREFACE

TO

THE FOURTH EDITION.

IN the present Edition the author adheres to his decision not to introduce Diagrams. Experience more than ever convinces him that they would frustrate his main object, which is to urge Students to get the habit of making the eye and the hand work together, and to educate the 'touch' upon the normal living body.

Without such practical training, how can we reasonably expect to form a correct diagnosis when called upon to examine an injury or to detect a disease? In truth, this work is intended only for those who are desirous of acquiring the habit recommended.

The author gladly expresses his obligation to his friend Mr. ANTHONY A. BOWLBY, F.R.C.S., the Surgical Registrar of St. Bartholomew's Hospital, for many useful suggestions, and for some additional 'Landmarks' concerning the principal nerve trunks of the limbs.

LONDON : *June* 1888.

PREFACE

TO

THE FIRST EDITION.

THESE 'LANDMARKS' have already appeared in Saint Bartholomew's Hospital Reports. They are now republished, with some additions, in the hope that they may be useful to others besides those for whom they were originally intended.

My object has been to collect into a compact form the leading landmarks which help practical surgeons in their daily work. Those relating to the chest and abdomen have been ascertained, with as much precision as natural variations permit, by needles introduced in various directions.

I have to express my acknowledgments to Mr. WALSHAM and to Dr. GODSON for their contributions.

65 GOWER STREET : *March* 1876.

THE FIRST PART

CHAPTER I

The first part of the book is devoted to a description of the various forms of life which are found in the different parts of the world. It is a very interesting and useful work, and one which every student of natural history should read.

The second part of the book is devoted to a description of the various forms of life which are found in the different parts of the world. It is a very interesting and useful work, and one which every student of natural history should read.

The third part of the book is devoted to a description of the various forms of life which are found in the different parts of the world. It is a very interesting and useful work, and one which every student of natural history should read.

CONTENTS.

	PAGE
THE HEAD	3
THE FACE	7
THE NECK	16
THE CHEST	21
THE BACK	29
THE ABDOMEN	33
THE PERINEUM	44
THE THIGH	47
THE BUTTOCKS	52
THE KNEE	54
THE LEG AND ANKLE	57
THE FOOT	61
THE ARM	63
THE FOREARM AND WRIST	69
THE HAND	73
PALPATION BY THE RECTUM	75
EXAMINATION PER VAGINAM	77

'CHIRURGUS MENTE PRIUS ET OCULIS AGAT QUAM MANU ARMATA.'

LANDMARKS

MEDICAL AND SURGICAL.

1. IN clinical teaching, we have daily occasions to point out, on the surface of the LIVING BODY, what may be called 'medical and surgical landmarks.' By 'landmarks' we mean lines, bony eminences, furrows, depressions, and such like, which are guides to, or indications of, deeper-seated parts. This practice is not only most useful but absolutely necessary; because many, even advanced students of anatomy are not so ready as they ought to be in their recognition of parts when covered by skin. Students who may be familiar enough with bones, muscles, blood-vessels, or viscera in the dissected subject, are often sadly at fault when they come to put this knowledge into practice in the living.

For instance, ask a student to put his finger on the exact spot where he would feel for the head of the radius, the coracoid process of the scapula, the tubercle of the scaphoid bone in the foot; ask him to compress effectually one of the main arteries; to chalk the line of its course; to map on the chest the position of the heart and the several valves at its base; to trace along the walls of the chest the outlines of the lungs and pleura; to point out the bony prominences about the joints, and their relative position in the different motions of the joints; test him about the muscles and tendons which can be seen or felt as they stand out in relief or remain in repose; let him introduce his finger into the several orifices of the body, and say what parts are accessible to the touch:—questions such as these even a good anatomist, unaccus-

tomed to manipulate the living subject, might very often find himself at a loss to answer.

2. **Object in view.**—Our main object, therefore, is to induce in students the habit of looking at the living body with anatomical eyes, and with eyes too at their fingers' ends. The value of this habit cannot be too highly estimated. Is it not of the utmost importance to a surgeon that he should have in his mind's eye the various structures of the body as they lie grouped, connected, and working together? Should he not try at least to see them with the same clearness and accuracy as if they were perfectly transparent?

Moreover, the habit of examining the living body with 'anatomical eyes' and 'surgical fingers' teaches the eye and the hand to act together, and trains that delicate sense of touch which every surgeon should possess.

This habit is within easy reach of any one who has carefully dissected for himself, and learned what to feel for. Plates will not give him this knowledge. Let a student examine his own body with a skeleton before him. Better still that two students should work together, each serving as a model to the other.

Teachers of anatomy should follow the example of Sir C. Bell, who was in the habit of introducing, from time to time, a powerful muscular fellow to his class, 'in order to show how much of the structure of the body, such as the articulations and the muscles, might be learned without actual dissection.'*

At the same time, it is only fair to say that 'landmarks' cannot always be defined with precision. A considerable latitude must be allowed for natural variations in different persons. In some, their anatomy stands out beautifully clear; in others, it is masked by obesity. Selecting, therefore, for study a moderately lean person, let us begin with the head.

* The references throughout are to Notes at the end of the book.

THE HEAD.

3. **Scalp : its density.**—The great toughness of the scalp, more especially at the back of the head, is owing to its intimate connection with the dense aponeurosis of the occipito-frontalis muscle, the scalp vessels and hair bulbs intervening. This density often obscures the diagnosis of tumours on the cranium. A tumour growing upon the head may be either above or below the aponeurosis of the scalp. If below, it will have a firm resisting feel, being bound down by the aponeurosis. Nevertheless its firmness and resistance may depend not simply on its confinement beneath the aponeurosis, but on its having its origin within the skull. Look with suspicion, then on every tumour on the head that will not readily permit you to move it about, so as to be sure of its connections prior to an attempt at extirpation.

The scalp moves freely over the pericranium, to which it is very loosely connected by abundant areolar tissue. When suppuration takes place in this tissue, the pus lies under the aponeurosis of the occipito-frontalis, through which free incisions should be made to let the pus out. The suppuration is always limited by the attachments of the muscle. The pus will therefore accumulate either above the eyebrow, or over the zygoma, or at the level of the superior curved line of the occiput.

4. **Arteries of scalp.**—The supra-orbital artery can be felt beating just above the supra-orbital notch, and traced for some way up the forehead ; the temporal (anterior branch) ascends tortuously about one inch and a quarter behind the external angular process of the frontal bone ; the occipital can be felt near the middle of a line drawn from the occipital protuberance to the mastoid process ; the posterior auricular, near the apex of the mastoid process. All these arteries can be effectually compressed against the subjacent bone.

5. **Nerves of the scalp.**—The nerves of the scalp come some from the cranial, some from the spinal nerves. The supra-trochlear emerges at the inner angle of the orbit ; the

supra-orbital at the supra-orbital notch. The skin of the temporal region is supplied by the temporal branch of the temporo-malar and by the auriculo-temporal which ascends directly in front of the ear close to the temporal artery. At the back of the head are the small and great occipital nerves; these supply sensation to the scalp over the occipital region. The motor nerves of the scalp are derived from the facial, whose temporal and posterior auricular branches ramify in front and behind the ear respectively. Thus, the corrugator supercilii and the occipito-frontalis, both muscles of expression, are associated through their nerve supply with the muscles of the face.

6. **Skull-cap.**—The skull-cap is rarely quite symmetrical. This want of symmetry is often obvious. It may occur in men highly gifted, as in the celebrated French anatomist Bichat. As to shape and relative dimensions, no two heads are exactly alike, any more than are two faces. It is beside my present purpose to go into the question of craniology more than to say that, although the cranium does not exactly follow the brain in all its eminences and depressions so as to be like a cast of its surface, yet it certainly indicates the dimensions of the great cerebral masses. The prominence of the frontal and parietal 'eminences' and of the occipital region may be taken as a general indication of the development of the corresponding lobes of the brain. To ascertain the relative proportions of these three regions, let a thread be passed from one meatus auditorius to the other, across the frontal, parietal, and occipital eminences respectively.

7. **Fontanelles.**—In the head of a new-born child, owing to the not yet completed ossification of the skull-cap, there are six fontanelles, two on the top and two on each side of the head. Of all these, by far the most important practically is the anterior fontanelle, and for the following reasons:—1. It is the last to ossify, and as a rule is not quite closed till between the second and third year. 2. By its feel, whether abnormally bulging or sunken, we can tell if there be excess or diminution of fluid within the skull. 3. By the eye alone we can count here the pulse of a sleeping infant. 4. By its lozenge shape

the finger can detect, during labour, the position of the head of the child.

8. **Frontal sinuses.**—The 'frontal sinuses' formed by the separation of the two tables of the skull vary much in size in different persons and at different periods of life. This fact has an important bearing on wounds in the forehead and on trephining in this situation. These 'bumps' do not exist in children, because the tables of the skull do not begin to separate before puberty. From an examination of many skulls in the Hunterian Museum, I find that the absence of the 'bumps,' even in middle age, does not necessarily imply the absence of the sinuses, since they may be formed by a retrocession of the inner wall of the skull. In old persons, as a rule, when the sinuses enlarge, it is owing to the encroachment of the inner table on the brain case. The inner wall of the skull here follows the shrinking brain. It is, therefore, important to bear in mind that an adult, and more especially an elderly person, may have a large frontal sinus without any external indication of it.

Neither does a very prominent bump necessarily imply the existence of a large sinus, or indeed of even a small one. The 'bump' may be a mere heaping up of bone, a degradation, as in some Australian skulls.

9. **Mastoid process.**—The mastoid process, which can be felt behind the ear, contains air-cells, to which the above observations equally apply. Like the frontal sinuses, they are lined by mucous membrane. When inflamed and full of pus, the process becomes very painful and swollen, and must be trephined early to evacuate the pus.

10. **Occipital protuberance.**—The occipital protuberance, and the superior curved line, can be distinctly felt at the back of the head. The protuberance is always the thickest part of the skull-cap, and more prominent in some than in others.

The posterior inferior angle of the parietal bone, grooved by the lateral sinus, is on a level with the zygoma, and a trifle more than one inch behind the front border of the mastoid process.

11. **Lines of cerebral sinuses.**—A line drawn over the head from the root of the nose to the occipital protuberance corresponds with the superior longitudinal sinus. Another line drawn from the occipital protuberance to the front border of the mastoid process corresponds with a part of the lateral sinus.

12. **Middle meningeal artery.**—The trunk of the middle meningeal artery runs along the front lower corner of the parietal bone, about one inch and a half behind, and half an inch above, the external angular process of the frontal. About this spot the squamous portion of the temporal bone, the great wing of the sphenoid, the frontal and the parietal join together: to the site of their junction the name 'pterion' has been given by craniologists.

An imaginary straight line drawn across from the front of one mastoid process to the other would pass through the middle of the condyles of the occiput, showing how nearly the skull is balanced on the top of the spine in the erect posture.

13. **Thickness of skull-cap.**—The average thickness of the cap of an adult skull is about $\frac{1}{5}$ of an inch. The thickest part is at the occipital protuberance, where it is often $\frac{3}{4}$ of an inch or more, even in an otherwise thin skull. The thinnest part is at the temple, where it may be almost as thin as parchment. Everyone in the habit of making post-mortem examinations knows how much the skull-cap differs in thickness in different persons and in different parts of the same skull. In old persons it is often in some parts not thicker than a shilling, owing to the absorption of the diploë. Another point of interest is that the inner plane of the cap is not always parallel with the outer. Hence, in applying the trephine, this is not a bad rule—'Think that you are operating on the thinnest skull ever seen, and thinner in one half of the circle than the other.'

14. **Levels of the brain.**—The level of the anterior lobes of the cerebrum in front corresponds with a straight line drawn across the forehead, just above the eyebrows. The lower level of the anterior and middle lobes corresponds with a line drawn from the external angular process of the frontal bone to the upper part of the meatus auditorius. Another line drawn

from the meatus to the occipital protuberance corresponds with the lower level of the posterior lobe. The lower level of the cerebellum is covered by the muscles of the nape, and cannot be defined by external examination. It depends upon the extent to which the occipital fossæ bulge into the nape of the neck ; and this bulge varies in different skulls.

THE FACE.

15. The approaches to the organs of the senses, their ever-varying expression, their numerous muscles, and their rich profusion of vessels and nerves, give the face great anatomical importance, which has a most valuable bearing, not only on the practice of surgery, but on the physiognomy of health, and the diagnosis of disease.

16. **Foramina for branches of fifth nerve.**—A surgeon may be called upon to divide any one of the three chief branches of the fifth nerve upon the face. He looks, therefore, with interest to the precise situations where they leave their bony foramina with their corresponding arteries. The supra-orbital notch or foramen can be felt about the junction of the inner with the middle third of the supraorbital margin. From this point a perpendicular line drawn with a slight inclination outwards, so as to cross the interval between the two bicuspid teeth in both jaws, passes over the infraorbital and the mental foramina. The direction of these two lower foramina looks towards the angle of the nose.

17. **Pulley for superior oblique muscle.**—By pressing the thumb beneath the internal angular process of the frontal bone, the cartilaginous pulley for the tendon of the superior oblique muscle can be distinctly felt. We should be careful not to interfere with this pulley in any operation about the orbit.

18. **Lower Jaw.**—The working of the condyle of the jaw vertically and from side to side can be distinctly felt and seen in front of the ear. When the mouth is opened wide, the condyle advances out of the glenoid cavity on to the eminentia

articularis, and returns into its socket when the mouth is shut. The muscle which causes this advance is the external pterygoid; and it gives the jaw a greater freedom of grinding motion. The neck of the jaw can be felt through the mouth, a fact worth remembering under suspicion of fracture. The line of the lower jaw can be distinctly felt. The most frequent place of fracture is near the canine tooth, the deep socket of which tends to weaken the bone in this situation.

The posterior margin of the ramus of the lower jaw corresponds with a line drawn from the condyle to the angle. In opening abscesses in the parotid region, the knife should not be introduced behind this line for fear of wounding the external carotid artery. Punctures to any depth may be safely made in front of it. They are often necessary where inflammation of the parotid gland ensues after eruptive fevers, and runs on to suppuration. The swelling, tension, and pain are most distressing. Owing to the fibrous framework of the gland, the matter is not circumscribed, but diffused. One puncture is not enough. Three or more may be requisite. The blade of the knife should be held horizontally, so as to be less likely to injure the branches of the facial nerve. We are not to be disappointed if no pus flows. The punctures give relief, and pus will probably exude the next day.

19. **Zygoma.**—This prominent arch of bone lies in front of the ear. It forms an important characteristic in the expression of the face; is always perceptible to the touch, and in the lean and aged to the eye.

20. **Parotid gland and duct.**—The parotid gland may be felt, though not very distinctly, lying behind and on the ramus of the lower jaw, immediately in front of, and below the lobule of the ear. A line drawn from the middle of the lobule of the ear to midway between the nose and the mouth gives the course of the parotid duct. Opposite the second upper molar, the duct opens by a papilla into the mouth. The branch of the facial nerve which supplies the buccinator runs with the duct.

21. **Seventh nerve or facial.**—The trunk of this nerve, after coming out at the stylo-mastoid foramen covered by

the parotid gland, divides, close to the posterior border of the lower jaw, into its chief branches, which run towards the temple, the orbit, the cheek, and the jaw, to supply the muscles of the face. It can be readily galvanised in facial palsy by placing one pole at the lobule of the ear, and the other at the desired points of the face.

22. **Temporal and facial arteries.**—The pulsation of the trunk of the temporal artery can be felt between the root of the zygoma and the ear. This is well known to and used by chloroformists. It is also a convenient pulse to feel in a sleeping patient. The facial artery can be distinctly felt as it passes over the body of the jaw at the anterior edge of the masseter; again near the corner of the mouth close to the mucous membrane; and, lastly, by the side of the ala nasi, up to the inner side of the tendo oculi. By holding the lips between the finger and thumb the coronary arteries are felt under the mucous membrane, and might be compressed by a spring clip in 'hare-lip' operations. The facial vein does not accompany the tortuous artery, but runs a straight course from the inner angle of the eye to the front border of the masseter, just behind the artery.

23. **The ear.**—The external auditory canal is about one inch and a quarter in length. It inclines at first somewhat upwards and forwards, and then curves a little downwards to the membrana tympani. Owing to the oblique direction of this membrane, the floor of the canal is longer than the roof. The narrowest portion is about the middle; hence the difficulty of extracting foreign bodies which have passed to the end of it. To examine the canal without a speculum the ear should be pulled upwards and backwards.

24. **Eyelids and eyes.**—The opening between the eyelids varies in size in different persons; hence more of the eyeball is seen in some than in others, and the eye appears larger. Although human eyes do vary a little in size, yet the actual difference is by no means so great as is generally supposed. The size of the fissure and the fat in the orbit have much to do with the apparent size of the eye. Contrast the narrow fissure of the Chinese and Mongolian races, and the apparent

smallness of their eyes with those of Europeans. As a rule the external angle of the lid is higher than the internal. When not exaggerated, it gives the face an arch and pleasing expression.

Evert the lids to see the Meibomian glands ; observe their perpendicular arrangement, in the substance of the tarsal cartilages.

The free borders of the lids are not beveled, as described by J. L. Petit and most anatomists, 'so as to form with the globe of the closed eye a triangular canal for the flow of the tears.' On the contrary, it is easily seen that the lid margins, when closed, come into accurate contact.

Every time the eye is shut, the ball turns upwards and inwards, so that the cornea is completely covered by the upper lid. This may be well seen by raising the lid of a sleeping infant ; also in cases of low fever when the lid is not completely closed. This up-turning of the eye clears the cornea, and protects it from the light.

A careful examination of the motion of the lower lid in the act of shutting the eye proves that it is a double motion. The lid is not only slightly raised, but drawn inwards about $\frac{1}{12}$ of an inch. This second movement sweeps any particles of dust as well as moisture towards the inner canthus.

25. **Puncta lachrymalia.**—The puncta lachrymalia are distinctly visible at the inner angles of the lids. The lower punctum is larger and a little more external than the upper, so that they are not exactly opposite. The direction, too, of the puncta deserves notice. Their open mouths look a little backwards, ready to imbibe the tears. When their proper bearing is lost, as in facial paralysis or by a cicatrix near the lid, the tears overflow the cheek. The length of the lachrymal canals is from three to four lines. The lower is a little shorter and wider than the upper. As each makes a little angle in its course, about a line from its orifice, the lid should be drawn outwards to straighten the canal when we introduce a probe.

26. **Lachrymal sac, and tendo oculi.**—To find the lachrymal sac, draw outwards the eyelids to tighten the tendo

oculi, which crosses the sac a little above its middle. A knife introduced just below the tendon close to the edge of the orbit would enter the sac. The angular artery and vein would be on the inner side of the incision. A probe directed in a line with the inner edge of the orbit, *i.e.* downwards, outwards, and backwards, would pass down the nasal duct, and enter the inferior meatus of the nose.

The tendo oculi serves many purposes besides giving attachment to the cartilages and muscles of the lids. One purpose is said to be to pump the tears into the lachrymal sac. Place a finger on the tendon, and feel that it tightens every time the lids are closed. The tendon, being intimately connected to the sac, draws, as it tightens, the sac wall outwards and forwards, and in this way it may pump along the lachrymal canals any fluid collected at the angle of the eye.

27. **Nasal duct.**—The nasal duct is from six to eight lines long, and narrowest in the middle of its course. Its termination in the inferior meatus lies under the inferior spongy bone, about a quarter of an inch behind the bony edge of the nostril. The appearance of the orifice in the dry bone conveys no idea of its size and shape in life; for it is diminished by a valve-like fold of mucous membrane, so that it becomes, in most cases, a mere slit, not exceeding a line in diameter.

The facility with which instruments can be introduced into the nasal opening of the duct depends upon its position as well as its size. This position varies in different instances. Sometimes it opens directly into the roof of the inferior meatus, in which case the hole is large and round, so that tears readily run into the nose. In other instances the opening is situated on the outer wall of the meatus, and is such a narrow fissure as to be hardly discernible. The practical conclusion then is, that a probe can be easily introduced when the opening is in the roof of the meatus, but not without difficulty and laceration of the mucous membrane when on the outer wall. This difficulty indeed may be increased by the narrowness of the meatus, arising from an unusual curvature of the inferior spongy bone.

28. **Nose and nasal cavities.**—The line where the cartilages of the nose are attached to the nasal and superior maxillary bones can be traced with precision. The close connection of the skin to the cartilages admits of no stretching; hence the acute pain felt in erysipelas and boils on the nose. The external aperture of the nose is always placed a little lower than the floor of the nostril, so that the nose must be pulled up before we can inspect its cavities.

Looking into the nostrils, we find that the left is, in the majority of cases, narrower than the right, owing to an inclination of the septum towards the left. A communication sometimes exists between them, through a hole in the septum as in the case of the celebrated anatomist Hildebrandt. By stretching open the anterior nares, and throwing well back the head, we can get a view of the end of the inferior spongy bone. It might be mistaken for a polypus. The middle spongy bone cannot be seen; its attachment to the ethmoid is high up, nearly opposite the tendo oculi. The cavities are so much narrowed transversely by the spongy bones, that in the extraction of polypi it is better to dilate the blades of the forceps perpendicularly, and near the septum.

29. **Mouth.**—What can be seen and felt through the mouth? The upper surface of the tongue, '*speculum primum viarum*,' is a study in itself. We notice, on its under surface, a median furrow, on each side of which stands out the ranine vein, lying upon the prominent fibres of the lingualis. In the middle line of the floor of the mouth is the '*frenum linguæ*,' with the orifice of the duct of the submaxillary gland on each side of it. The gland itself can be detected immediately beneath the mucous membrane by feeling further back near the angle of the jaw, at the same time pressing the gland upwards from below.

The long ridge of mucous membrane on each side of the floor contains the sublingual glands.

We can feel the attachment of the '*genio-hyo-glossi*' behind the symphysis of the jaw. The division of this attachment would enable a surgeon to draw the tongue more

freely out of the mouth in any attempt to remove carcinoma extending far back into its root.

There is great difference in the shape of the hard palate ; this difference depends upon the depth of the alveolar processes. In some it forms a broad arch ; in others it is narrow, and rises almost to a point like a Gothic arch, and materially impairs the tone of the voice.

Throat.—To examine the throat well, the nose should be held so as to compel breathing through the mouth. Thus the soft palate will be raised, the palatine arches widened, and the tonsils and the back of the pharynx fairly exposed. Pressing the tongue downwards, provided it be done very gently, is also of advantage. Rude treatment the tongue at once resists. The forefinger can be passed into the throat, beyond the epiglottis, as low as the bottom of the cricoid cartilage, and thus search the pharynx down to the top of the œsophagus, and the hyoid space (on each side) where foreign bodies are so apt to lodge. The greater cornu of the hyoid bone can be felt as a distinct projection on either side. In introducing a tube into the œsophagus, the finger should keep the instrument well against the back of the pharynx so as to prevent its slipping into the larynx.

Pass the finger between the teeth and the cheek and feel the anterior border of the coronoid process of the jaw. On the inner side of this process, between it and the tuberosity of the upper jaw, is a recess, where a deeply-seated temporal abscess might burst, or might be opened. Behind the last molar on the inner side of the upper jaw, we can distinctly feel the hamular process of the sphenoid bone ; also the lower part of the pterygoid fossa, and the internal pterygoid plate. Behind, and on the outer side of the last molar, can be felt part of the back of the antrum and of the lower part of the external pterygoid plate.

On the roof of the mouth we can feel the pulsation of the posterior palatine artery. Hæmorrhage from this vessel can be arrested by plugging the orifice of the canal, which lies (not far from the surface) on the inner side of the last molar, about $\frac{1}{3}$ of an inch in front of the hamular process.

When the mouth is wide open, the pterygo-maxillary ligament forms a prominent fold readily seen and felt beneath the mucous membrane, behind the last molar teeth. A little below the attachment of this ligament to the lower jaw we can easily feel the gustatory nerve, as it runs close to the bone below the last molar tooth. The exact position of the nerve can be ascertained in one's own person by the acute pain on pressure. A division of the nerve, easily effected by a small incision, gives much temporary relief in cases of advanced carcinoma of the tongue.

To feed a patient in spasmodic closure of the jaw, it is well to know that there is behind the last molar teeth a space sufficient for the passage of a small tube into the mouth.

30. **Antrum.**—Lift up the upper lip and examine the front wall of the antrum. The proper place in which to tap it is above the second bicuspid tooth, about one inch above the margin of the gum. The fangs of the first and second molars project most of all into the antrum; and when carious are the most likely to set up suppuration in its cavity.

31. **Posterior nares.**—A surgeon's finger should be familiar with the feel of the posterior nares, and of all that is within the feel behind the soft palate. This is important in relation to the attachment of polypi, to plugging the nostrils, and to the proper size of the plug. In the examination of this part of the back of the throat it is necessary to throw the head well back, because, in this position, nearly all the pharynx in front of the basilar process comes down below the level of the hard palate, and can be seen as well as felt. But when the skull is horizontal, *i.e.* at a right angle with the spine, the hard palate is on a level with the margin of the foramen magnum, and the parts covering the basilar process are concealed from view.

The head then being well back, introduce the fore-finger behind the soft palate, and turn it up towards the base of the skull. You feel the strong grip of the superior constrictor. Hooking the finger well forwards, you can feel the contour of the posterior nares. Their size depends upon the anterior,

but rarely exceeds a small inch in the vertical diameter, and a small half-inch in the transverse. The plug for the posterior nares should not be larger than this. Their plane is not perpendicular but slopes a little forwards. You can feel the septum formed by the vomer, and also the posterior end of the inferior spongy bone in each nostril.

32. **Tonsils.**—Before taking leave of the throat, look well at the position of the tonsils between the anterior and posterior half arches of the palate. In a healthy state they should not project beyond the level of these arches. In all operations upon the tonsils, we should remember the close proximity of the internal carotid artery to their outer side. Nothing intervenes but the pharyngeal aponeurosis, and the superior constrictor of the pharynx. Hence the rule in operating on the tonsils, always to keep the point of the knife inwards.

In troublesome hæmorrhage from the tonsils, after an incision or removal, it is well to know that they are accessible to pressure if necessary by means of a padded stick, or even a finger.

33. **Features.**—A word or two on the lines of the face as indicative of expression. Everyone pays unconscious homage to the study of physiognomy when, scanning the features of a stranger, he draws conclusions concerning his intelligence, disposition, and character. Without discussing how much physiognomy is really worth, there can be no doubt that it is a mistake to place it in the same category as phrenology, since the latter lacks that sound basis of physiology which no one can deny to the former.

A person fond of observing cannot fail to have arrived at the conclusion that a man's daily calling, not less than his daily habits, may be read in his face. Place a soldier, a sailor, a compositor, and a clergyman side by side, and who will not immediately detect a marked difference in their physiognomies?

The muscles of the features are generally described as arising from the bony fabric of the face, and inserted into the nose, the corners of the mouth, and the lips. But this

description gives a very inadequate idea of their true insertion. They drop fibres into the skin all along their course, so that there is hardly a point of the face which has not its little fibre to move it. The habitual recurrence of good or evil thoughts, the indulgence in particular modes of life, call into play corresponding sets of muscles which, by producing folds and wrinkles, give a permanent cast to the features, and speak a language which all can understand, and which rarely misleads. Schiller puts this well when he says that 'it is an admirable proof of infinite wisdom that what is noble and benevolent beautifies the human countenance; what is base and hateful imprints upon it a revolting expression.'

THE NECK.

34. **Subcutaneous veins.**—Notice first the direction of the subcutaneous veins. The chief subcutaneous vein is the external jugular. Its course corresponds with a line drawn from the angle of the jaw to the middle of the clavicle, where it joins the subclavian. It is made more prominent by putting the sterno-mastoid into action, or by gentle pressure on the lower end of the vein. It is exceptionally joined by a branch which runs over the clavicle, and is termed 'jugulocephalic.' The anterior jugular generally runs along the front border of the sterno-mastoid. The distension of these veins becomes an important feature in cases of tricuspid regurgitation and in dyspnœa.

35. **Parts in central line. Os-hyoides.**—Immediately below and nearly on a level with the lower jaw we feel the body of the os-hyoides, and can trace backwards on each side the whole length of the cornua. They might easily be broken by the grasp of a garrotter. Below the body of the os-hyoides is the gap above the thyroid cartilage. This gap corresponds with the anterior thyro-hyoid ligament and the apex of the epiglottis; so that in cases of cut throat in this situation, nearly the whole of the epiglottis lies above the wound.

The great cornu of the hyoid bone is the 'landmark' in

the operation for ligature of the lingual artery, which runs parallel to its upper margin. The artery is overlapped by the submaxillary gland, and covered by the hyo-glossus muscle.

36. **Thyroid cartilage.**—The projection and depth of the notch in the thyroid cartilage, or 'pomum Adami,' varies in different persons. Between the notch and the hyoid bone there is a large bursa, which facilitates the play of the cartilage beneath the bone in deglutition. The notch does not appear till puberty, and is throughout life much less distinct in the female than the male. The finger can trace the upper borders and cornua of the thyroid cartilage : its lower cornua can be felt by the side of the cricoid.

On each side of the thyroid cartilage we can recognise the lateral lobes of the thyroid gland. On the upper and front part of the gland we can distinctly feel the pulsation of the superior thyroid artery. This pulsation, coupled with the fact that the gland rises and falls with the larynx in deglutition, gives the best means of distinguishing a bronchocele from other tumours resembling it.

37. **Crico-thyroid membrane.**—Below the angle of the thyroid cartilage we feel the interval between it and the cricoid, which is occupied by the crico-thyroid membrane. In laryngotomy we cut through this membrane transversely close to the upper edge of the cricoid cartilage, in order that the incision may be as far as possible from the attachment of the vocal cords.

38. **Cricoid cartilage.**—The projection of the cricoid cartilage is a point of great interest to the surgeon, because it is his chief guide in opening the air-passages, and can always be felt even in infants, however young or fat. It corresponds to the interval between the fifth and sixth cervical vertebræ. The commencement of the œsophagus lies behind it : here, therefore, a foreign substance too large to be swallowed would probably lodge, and might be felt externally.

Again, a transverse line drawn from the cricoid cartilage horizontally across the neck would pass over the spot where

the omo-hyoid crosses the common carotid. Just above this spot is the most convenient place for tying the artery.

Those who have not directed their attention to the subject are hardly aware what a little distance there is between the cricoid cartilage and the upper part of the sternum. In a person of the average height sitting with the neck in an easy position, the distance is barely one inch and a half. When the neck is well stretched, about three-quarters of an inch more is gained. Thus, we have (generally) not more than seven or eight rings of the trachea above the sternum. None of these rings can be felt externally. The second, third, and fourth are covered by the isthmus of the thyroid gland. The trachea, it should be remembered, recedes from the surface more and more as it descends, so that, just above the sternum in a short fat-necked adult, the front of the trachea would be quite one inch and a half from the skin.

39. **Trachea.**—In the dead subject nothing is more easy than to open the trachea: in the living, this operation may be attended with the greatest difficulties. In urgent dyspnœa you must expect to find the patient with his head bent forward, and the chin dropped, so as to relax as much as possible the parts. The head should not be too forcibly drawn back, lest a paroxysm of dyspnœa threaten instant suffocation. The elevator and depressor muscles draw the trachea and larynx up and down with a rapidity and a force which may bring the cricoid cartilage within half an inch of the sternum. The great thyroid veins which descend in front of the trachea are sure to be distended. There may be a middle thyroid artery. In children the lobes of the thymus may extend up in front of the trachea, and the left vena innominata may cross it unusually high. Thus the air-tube may be covered by important parts which ought not to be cut. Considering all these possible complications, the least difficult and the best mode of proceeding is to open the trachea just below the cricoid cartilage; and if more room be requisite, to pull down the isthmus of the thyroid gland, or in children to divide the cricoid itself. It is important that all the incisions be made strictly in the middle line, the 'line of safety.'

40. **Sterno-mastoid muscle.**—The sterno-mastoid muscle is the great surgical landmark of the neck. It stands out in bold relief when the head turns towards the opposite shoulder. Its inner border overlaps the common carotid, which can be easily compressed for a short time against the spine about the level of the cricoid cartilage.

Between the sternal origins of the sterno-mastoid is the fossa above the sternum, more or less perceptible in different necks. As it heaves and sinks alternately, especially in distressed breathing, it was called by the old anatomists 'fonticulus gutturis.' In beautiful necks, as seen in the 'Venus,' it is filled up by fat.

Notice the interval between the sternal and clavicular origins of the sterno-mastoid. A knife introduced a very little way into this interval would wound, slanting inwards, the common carotid; slanting outwards, the internal jugular vein. These facts are of importance in performing the subcutaneous section of the tendon of this muscle.

41. **Spinal accessory nerve.**—The point where this nerve emerges from the posterior border of the sterno-mastoid, and becomes most superficial, is a little above the middle of a line drawn from the clavicle to the mastoid process. At this point it can be readily galvanised.

42. **Carotid artery.**—The course of the common carotid and the external carotid arteries is in a line drawn from the sterno-clavicular joint to a point (as a rule) midway between the angle of the jaw and the mastoid process. That part of the line below the level of the upper border of the thyroid cartilage represents the course of the common carotid; the part above the level corresponds with the external carotid which divides a little below the neck of the jaw into its terminal branches.

43. **Sterno-clavicular joint.**—Many important parts lie behind the sterno-clavicular joint. There is the commencement of the vena innominata; behind this comes the common carotid on the left side, and the division of the arteria innominata on the right. Deeper still, the apex of the lung rises into the neck.

In a child the arteria innominata often lies in front of the trachea and divides a little higher than the joint : a point to be remembered in tracheotomy (39).

44. **Apex of lung in the neck.**—The extent to which the apex of the lung rises into the neck is greater than is generally supposed. Many observations in reference to this point lead to the conclusion that the lung rises behind the sterno-mastoid, on an average, one inch and a half above the clavicle ; in persons with long necks, as much as two inches. The apex of the lung and pleura, however, is not near the surface but deeply seated, being covered by the clavicular origin of the sterno-mastoid, the sterno-thyroid, and a part of the scalenus anticus. It is also crossed by the subclavian vessels in the first part of their course. This cervical portion of lung being peculiarly liable to tubercular disease, should always be carefully examined. Its condition may be ascertained by percussion over the sternal end of the clavicle.

45. **Supra-clavicular fossa.**—The hollow above the clavicle, between the sterno-mastoid and the trapezius, is very manifest in emaciation and old age. In shrugging the shoulders it becomes remarkably pronounced. Notice the termination here of the external jugular vein. In some necks only a small depression is visible, particularly when the trapezius has a broad insertion into the clavicle, and comes well forwards, so that its front border gives a graceful contour to the base of the neck.

46. **Subclavian artery.**—The pulsation of the subclavian artery can be felt and even seen in the supra-clavicular fossa, near the outer border of the sterno-mastoid, and about one inch above the clavicle. Here the artery lies upon the first rib, and can be effectually compressed. A little pressure is sufficient. But the pressure must be made in the right direction, or the artery will be pressed off the rib instead of against it. The plane of the rib is such that the pressure, to be effectual, must be made in a direction downwards and a little inwards. It is best to stand behind the shoulder and make the pressure with one thumb. The arm should be placed downwards, if convenient, so as to depress the clavicle ; and

the head inclined towards the side on which pressure is made.

It is worth remembering that the outer border of the sterno-mastoid corresponds pretty nearly with the outer edge of the scalenus anticus, which is the surgical guide to the subclavian artery.

The phrenic nerve can be galvanised as it runs over the scalenus anticus. One pole of the battery should be placed in the fossa, the other over the diaphragm. By pressing deeply at the upper part of the supra-clavicular fossa, the transverse process of the seventh cervical vertebra can be distinctly felt. This has been mistaken for an exostosis.

In long and thin necks a thin cord is perceptible, running nearly parallel with and just above the clavicle. It is the posterior belly of the omo-hyoideus. See it rising and falling in breathing, and making tense during inspiration that part of the cervical fascia which lies over the cervical portion of the lung. Thus it may be said to be in all respects a muscle of inspiration, co-operating with the sterno-mastoid and scaleni. In the language of transcendental anatomy, we may say that the central tendon of the omo-hyoid represents a rudimentary cervical rib. Its posterior belly is analogous to a serration of the serratus magnus ; its anterior belly to a sterno-hyoid.

THE CHEST.

47. As a rule, the right half of the chest is slightly larger than the left. Of ninety-two persons of the male sex and good constitutions, seventy-one had the right side the larger ; eleven the left ; ten had both sides equal. The maximum of difference in favour of the right was one inch and a quarter. The measurements were made on a plane with the nipple.

48. **Peculiarities in the female.**—The chest of the female differs from that of the male in the following points :— Its general capacity is less ; the sternum is shorter ; the upper opening is larger in proportion to the lower ; the upper ribs are more moveable, and therefore permit a greater enlarge-

ment of the chest at its upper part, in adaptation to the requirements of pregnancy.

49. The top of the sternum is on a level with the body of the second dorsal vertebra ; and the available space between the top of the sternum and the spine is hardly more than two inches and a quarter.²

50. **Parts behind first bone of sternum.**—There is little or no lung behind the first bone of the sternum, the space being occupied by the trachea and large vessels as follows :—

The left vena innominata crosses the sternum just below the upper border. Next come the great primary branches of the arch of the aorta. Deeper still is the trachea dividing into its two bronchi opposite the junction of the first and second bones of the sternum. Deepest of all is the œsophagus.

About one inch from the upper border of the sternum is the highest part of the arch of the aorta, which lies on the bifurcation of the trachea.

51. **Arteria innominata.**—The course of the arteria innominata corresponds with a line drawn from the middle of the junction of the first with the second bone of the sternum, to the right sterno-clavicular joint. When the artery rises higher than usual into the neck, its pulsation can be felt in the fossa above the sternum.

52. **Rules for counting the ribs.**—In fat persons it is often difficult to count the ribs ; hence the following rules may be useful :—

a. The finger passed down from the top of the sternum soon comes to a transverse projection, slight, but always to be felt, at the junction of the first with the second bone of the sternum. This corresponds with the middle of the cartilage of the second rib.

b. The nipple of the male is placed, in the great majority of cases, between the fourth and the fifth ribs, about three-quarters of an inch external to their cartilages.

c. The lower external border of the pectoralis major corresponds with the direction of the fifth rib.

d. A line drawn horizontally from the nipple round the

chest cuts the sixth intercostal space midway between the sternum and the spine. This is a useful rule in tapping the chest.

e. When the arm is raised, the highest visible digitation of the serratus magnus corresponds with the sixth rib. The digitations below this correspond respectively with the seventh and eighth ribs.

f. The scapula lies on the ribs from the second to the seventh, inclusive.

g. The eleventh and twelfth ribs can be felt even in corpulent persons, outside the erector spinæ, sloping downwards.

h. One should remember the fact that the sternal end of each rib lies on a lower level than its corresponding vertebra. For instance, a line drawn horizontally backwards from the middle of the third costal cartilage at its junction with the sternum, to the spine, would touch the body, not of the third dorsal vertebra, but of the sixth. Again, the end of the sternum would be about the level of the tenth dorsal vertebra. Much latitude must be allowed here for variation in the length of the sternum, especially in women.

53. **Interval below clavicle.**—Immediately below the clavicle we recognise the triangular interval between the pectoralis major and the deltoid, more especially when the arm is raised horizontally forwards by the action of these muscles. This space varies in different cases, depending on the distance between the muscles. It is important as a guide to the coracoid process and the axillary artery. In a case of injury to the shoulder, to ascertain whether the coracoid process is broken, carry the arm outwards, to put the deltoid and pectoral muscles on the stretch, and make manifest the space between their opposite borders. Pressing the thumb into the space we can feel the inner side of the coracoid process, the apex being under the fibres of the deltoid; thus it is easy to ascertain whether it be broken. Moreover, this space corresponds with the line of the axillary artery; here its pulsation can be distinctly felt, and here it can be compressed (but not easily, or for long) against the second rib.

54. **Internal mammary artery.**—The line of the internal mammary artery runs perpendicularly behind the cartilages of the ribs, about half an inch from the sternum. The perforating branch through the second intercostal space is generally the largest.

55. **Outline of heart on chest-wall.**—To have a general idea of the form and position of the heart, map its outline on the wall of the chest, as follows:—

a. To define the base—*i.e.* the part to which its great vessels are attached—draw a transverse line across the sternum corresponding with the upper borders of the third costal cartilages; continue the line half an inch to the right of the sternum and one inch to the left.

b. To find the apex, mark a point about two inches below the left nipple, and one inch to its sternal side. This point will be between the fifth and sixth ribs.

c. To find the lower border (which lies on the central tendon of the diaphragm), draw a line, slightly curved downwards, from the apex across the bottom of the sternum (not the ensiform cartilage) as far as its right edge.

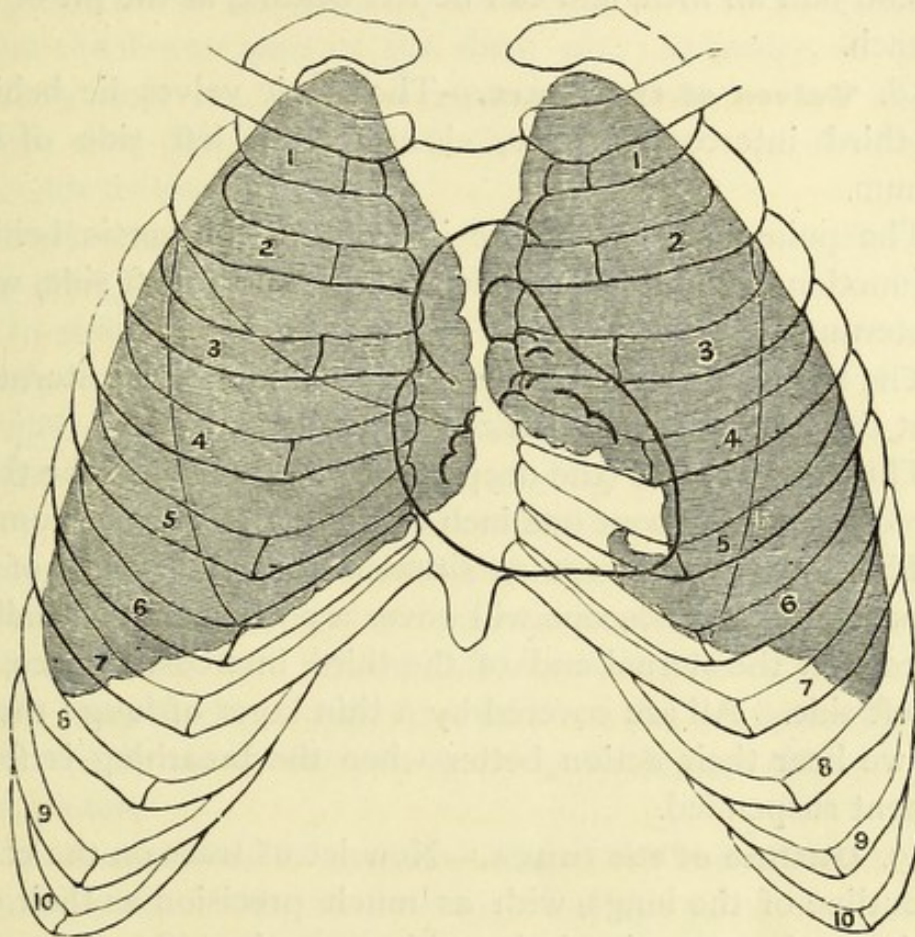
d. To define the right border (formed by the right auricle), continue the last line upwards with an outward curve, so as to join the right end of the base.

e. To define the left border (formed by the left ventricle), draw a line curving to the left, but not including the nipple, from the left end of the base to the apex.

Such an outline (seen in the cut, page 25, with the angles rounded off) shows that the apex of the heart points downwards and towards the left, the base a little upwards and towards the right; that the greater part of it lies in the left half of the chest, and that the only part which lies to the right of the sternum is the right auricle. A needle introduced in the third, the fourth, or the fifth right intercostal space close to the sternum would penetrate the lung and the right auricle.

A needle passed through the second intercostal space, close to the right side of the sternum, would, after passing through the lung, enter the pericardium and the most prominent part of the bulge of the aorta.

A needle passed through the first intercostal space, close to the right side of the sternum, would pass through the lung and enter the superior vena cava above the pericardium.



OUTLINE OF THE HEART, ITS VALVES, AND THE LUNGS (SHADED).

56. The best definition of that part of the præcordial region which is less resonant on percussion, was given by Dr. Latham years ago in his 'Clinical Lectures.' 'Make a circle of two inches in diameter round a point midway between the nipple and the end of the sternum. This circle will define, sufficiently for all practical purposes, that part of the heart which lies immediately behind the wall of the chest, and is not covered by lung or pleura.'

57. **Apex of the heart.**—The apex of the heart pulsates between the fifth and sixth ribs, two inches below the nipple, and one inch to its sternal side. The place and extent, however, of the heart's impulse, vary a little with the position of the body. Of this anyone may convince himself by leaning

forwards, backwards, on this side and on that, feeling, at the same time, the heart. Inspiration and expiration also alter the position of the heart. In a deep inspiration it may descend half an inch, and can be felt beating at the pit of the stomach.

58. **Valves of the heart.**—The aortic valves lie behind the third intercostal space, close to the left side of the sternum.

The pulmonary valves lie in front of the aortic behind the junction of the third costal cartilage, on the left side, with the sternum.

The tricuspid valves lie behind the middle of the sternum, about the level of the fourth costal cartilage,

The mitral valves (the deepest of all) lie behind the third intercostal space, about one inch to the left of the sternum.

Thus these valves are so situated that the mouth of an ordinary sized stethoscope will cover a portion of them all, if placed over the sternal end of the third intercostal space, on the left side. All are covered by a thin layer of lung; therefore we hear their action better when the breathing is for a moment suspended.

59. **Outline of the lungs.**—Now let us trace on the chest the outline of the lungs, with as much precision as their expansion and contraction in breathing permit. (See the cut.)

The apex of each lung rises into the neck behind the sternal end of the clavicle and sterno-mastoid muscle as much as an inch and a half: in females rather higher than in males (44). From the sternal ends of the clavicles the lungs converge, so that their thin edges almost meet in the mesial line on a level with the second costal cartilage. Thus there is little or no lung behind the first bone of the sternum. From the level of the second costal cartilage to the level of the fourth the margins of the lungs run parallel, or nearly so, close behind the middle of the sternum: consequently their thin edges overlap the great vessels and valves at the base of the heart.

Below the level of the fourth costal cartilage the margins of the lungs diverge, but not in an equal degree. The margin

of the right corresponds with the direction of the cartilage of the sixth rib: the margin of the left, being notched for the heart, runs behind the cartilage of the fourth. A line drawn perpendicularly from the nipple would find the lung margin about the lowest part of the sixth rib. Laterally, *i.e.* in the axillary line, the lung margin comes down as low as the eighth rib; posteriorly, *i.e.* in the dorsal or scapular line, it descends as low as the tenth.

It should be remembered that, in a deep inspiration, the lung margins descend posteriorly about one inch and a half.

In children the lungs are separated in front by the thymus gland. Allowance should be made for this. About the approach of puberty the thymus disappears.

60. **Anterior mediastinum.**—The direction of the anterior mediastinum is not straight down the middle of the sternum, but slants a little to the left, owing to the position of the heart. The right pleural sac generally encroaches a little upon the left, behind the middle of the sternum. A needle introduced through the middle of the sternum opposite the third or the fourth rib would probably go through the right pleura.

61. **Reflection of pleura.**—The reflection of the pleura from the wall of the chest on to the diaphragm corresponds with a sloping line drawn from the bottom of the sternum over the cartilages of the ribs down to the lower border of the last rib.

Since the pleura lines the inside of the last rib, a musket ball or other foreign body, loose in the pleural sac, and rolling on the diaphragm, might fall to the lowest part of the sac, which would be between the eleventh and twelfth ribs. The ball might be extracted here. The chest might also be tapped here, but not with a trochar, since a trochar would penetrate both layers of pleura, and go through the diaphragm into the abdomen.

The operation should be done cautiously, by an incision beginning about two inches from the spine, on the outer border of the 'erector spinæ,' on a level between the spines of the eleventh and twelfth dorsal vertebræ. The intercostal

artery will not be injured if the opening be made below the middle of the space, which is very wide.³

62. **Effects of tight lacing.**—The landmarks of the chest described in the preceding paragraphs will be found fairly accurate if the chest be of natural shape and dimensions. But in some women this is not the case. Their habit of tight lacing gradually alters this shape and dimensions, and alters also the relative positions of the internal organs to the chest wall and to each other.

Consider first the effects of this pressure on the bony framework of the chest. Excluding the bones of the shoulders, the normal shape of the skeleton of the chest is, roughly speaking, conical, with the narrow part at the neck and the base below. (See cut, p. 25.) Now tight lacing not only hampers the mobility of the ribs, but narrows all the diameters of the lower part of the chest, presses downwards the lower ribs, and forces the waist lower down also; a displacement just now the height of fashion. In many instances these ribs are forced down nearly as low as the crest of the ilium. The result is a narrowing of the ilio-costal space—in other words of the flank—necessary for freedom of motion, and a wasting of the great muscles which balance the trunk on each side, more especially of the *quadrati lumborum*.

Consider next the effects of this unfair pressure upon the internal organs. One of the plainest results is a proportionate diminution of the room provided for the viscera of the chest and abdomen. It is hard to say which viscera suffer most from the restraint. It is certain that all of them are more or less pressed out of their natural position, and being cramped in the performance of their function, become the more liable to disease. The upward pressure tells upon the free circulation of the blood through the heart and lungs, and makes them pant on even slight exertion. The chief abdominal viscera, namely, the stomach, liver, and spleen, forced down from their position under cover of the ribs, are compelled to encroach upon the space reserved for the more moveable intestines. These again are pressed down among the viscera in the pelvis. And in this region, the superin-

cumbent pressure is likely to give rise to displacements and congestions which sooner or later engender very grievous ailments, especially their own.

To the legitimate use of stays of proper make and material, there can be no objection. A reasonable degree of support round the waist, which is the weakest part of the back, must be comfortable and desirable. But such support should not constrain its natural shape and elasticity. In the Medicean Venus, 'the bending statue which enchants the world,' the waist forms a graceful oval of nearly 27 inches in circumference. To attempt to reduce this to an ungraceful circle of 22, 20, or even 18 inches in circumference is surely to disfigure the person and aggravate the difficulties of the stomach. What wonder then if the pernicious habit of tight lacing gives rise to endless troubles of indigestion, and to the uterine and other complaints so common in women?

THE BACK.

63. **Median furrow.**—In a muscular man, a furrow, caused by the prominence of the erector spinæ on each side, runs down the middle of the back. The lower end of the furrow corresponds with the interval between the spine of the last lumbar and that of the first sacral vertebra.

64. **Spines of vertebræ.**—A little friction with the fingers down the backbone will cause the spines of the vertebræ to be tipped with red, so that they can be easily counted, and any deviation from the straight line detected. Still it is worth remembering that the spine of the third dorsal is on a level with the commencement of the spine of the scapula—that the spine of the seventh dorsal is on a level with the inferior angle of the scapula—that the spine of the last dorsal is on a level with the head of the last rib.

65. **Division of the trachea.**—The division of the trachea is opposite the spine of the third, in some cases the fourth, dorsal vertebra. In front this division is on the level of the junction of the first with the second bone of the sternum.

The root of the spine of the scapula is marked by a slight dimple in the skin. This is on a level with the third intercostal space. A stethoscope placed on the inner side of this dimple would cover the bronchus, more especially the right, since it is nearer to the chest wall.

Make a man lean forwards, with his arms folded across the chest; this will make prominent the spines of the vertebræ. The lower border of the trapezius will guide you to the spine of the twelfth dorsal vertebra.

66. The place where the kidney is most accessible to pressure is below the last rib, on the outer edge of the erector spinæ. The landmarks in the operation of lumbar nephrectomy are the same as those for colotomy. The greatest amount of room is obtained by an incision extending along the outer edge of the erector spinæ, between the last rib and the crest of the ilium; this incision should be joined by another running along the lower edge of the last rib.

67. The highest part of the ilium is about the level of the fourth lumbar spine. The best incision for opening the descending colon is in a slightly sloping line beginning at the outer edge of the erector spinæ, midway between the crest of the ilium and the last rib, and continued across the flank for three inches or more, according to the amount of subcutaneous fat.

68. In the pit of the neck we can feel the trapezius and the ligamentum nuchæ. By pressing deeply we detect the forked and prominent spine of the second cervical vertebra.

69. The spines of the third, fourth, and fifth cervical vertebræ recede from the surface to permit free extension of the neck, and cannot often be felt. But the spines of the sixth and seventh (*v. prominens*) stand out well.

70. Notice that most of the spines of the dorsal vertebræ, owing to their obliquity, do not tally with the heads of their corresponding ribs. Thus, the spine of the second dorsal corresponds with the head of the third rib; the spine of the third dorsal with the head of the fourth rib, and so on till we come to the eleventh and twelfth dorsal vertebræ, which do

tally with their corresponding ribs. All this, however, is best seen in the skeleton.

71. The spines of the vertebræ may be useful as landmarks indicative of the levels of important organs. I have therefore arranged them in a tabular form thus:—

TABULAR PLAN OF PARTS OPPOSITE THE SPINES OF THE
VERTEBRÆ.

CERVICAL.	{	5th. Cricoid cartilage. Œsophagus begins.
		7th. Apex of lung : higher in the female than in the male.
DORSAL.	{	1st.
		2nd.
		3rd. Aorta reaches spine. Apex of lower lobe of lung. Angle of bifurcation of trachea. (65.)
		4th. Aortic arch ends. Upper level of heart.
		5th.
		6th.
		7th.
		8th. Lower level of heart. Central tendon of diaphragm.
		9th. Œsophagus and vena cava through diaphragm. Upper edge of spleen.
		10th. Lower edge of lung. Liver comes to surface posteriorly. Cardiac orifice of stomach. <i>? v. p. 41</i>
		11th. Lower border of spleen. Renal capsule.
		12th. Lowest part of pleura. Aorta through diaphragm. Pylorus.
LUMBAR.	{	1st. Renal arteries. Pelvis of kidney.
		2nd. Termination of spinal cord. Pancreas. Duodenum just below. Receptaculum chyli.
		3rd. Umbilicus. Lower border of kidney.
		4th. Division of aorta. Highest part of ilium.
		5th. Formation of vena cava inferior.

72. **Origins of the spinal nerves.**—It is useful to know opposite what vertebræ the spinal nerves in the different regions arise from the spinal cord. They arise as follows:—

The origins of the eight cervical nerves correspond to the interval between the occiput and the sixth cervical spine.

The origins of the first six dorsal nerves correspond to the interval between the sixth cervical and the fourth dorsal spines.

The origins of the six lower dorsal nerves correspond to the interval between the fourth and the eleventh dorsal spines.

The origins of the five lumbar nerves correspond to the interval between the eleventh and twelfth dorsal spines.

The origins of the five sacral nerves correspond to the spines of the last dorsal and the first lumbar vertebræ.

73. **Movements of the spine.**—The movements of which the spine is capable are threefold: 1. Flexion and extension; 2. Lateral inclination; 3. Torsion. Flexion and extension are freest between the third and the sixth cervical vertebræ, between the eleventh dorsal and the second lumbar, and between the last lumbar and the sacrum. This is well marked in severe cases of opisthotonos, where the body is supported on the back of the head and heels.⁴

Still better may it be observed when a mountebank bends backwards, and touches the ground with his head.

The lateral movement is freest in the neck and the loins.

The movement of torsion or rotation round its own axis may be proved by the following experiment:—Seated upright, with the back and shoulders well applied against the back of a chair, we can turn the head and neck as far as 70°. Leaning forwards so as to let the dorsal and lumbar vertebræ come into play, we can turn 30° more.

74. **Position and motions of scapula.**—There are a few points worthy of observation about the scapula. It covers the ribs from the second to the seventh inclusive. We can feel its superior angle covered by the trapezius. The inferior angle is covered by the latissimus dorsi, which keeps it well applied against the ribs in the strong and athletic; but in weak and consumptive persons the lower angles of the scapulæ project like wings—hence the term ‘scapulæ alatæ.’

A line drawn horizontally from the spine of the sixth dorsal vertebra over the inferior angle of the scapula gives the upper border of the latissimus dorsi. Another line drawn from the root of the spine of the scapula to the spine of the last dorsal vertebra gives the lower border of the trapezius, which stands a little in relief.

75. The sliding movement of the scapula on the chest can be adequately studied only on the living subject. It can move not only upwards and downwards as in shrugging the shoulders—backwards and forwards as in throwing back the shoulders—but it has a rotatory movement round a movable centre. This rotation is seen while the arm is being raised from the horizontal to the vertical position, and is effected by the co-operation of the trapezius with the serratus magnus. The glenoid cavity is thus made to look upwards, the inferior angle slides forwards, and is well held under the latissimus dorsi.

76. For the medical examination of the back, the patient should fold his arms across the chest ; or he may sit with the arms hanging between his thighs, to lower the scapulæ as much as possible. In this position the spine of the scapula corresponds (nearly) with the fissure between the upper and lower lobes of the lung ; the apex of the lower lobe being about the level of the third rib.

THE ABDOMEN.

The student is assumed to be familiar with the conventional lines dividing the abdomen into regions.

77. **Abdominal lines.**—The linea alba, or central line of the abdomen, marks the union of the aponeuroses of the abdominal muscles. It runs from the apex of the ensiform cartilage to the symphysis pubis. As this line is the thinnest and least vascular part of the abdominal wall, we make our incision along it in ovariectomy, and in the high operation of lithotomy ; in it, we tap the abdomen in ascites, and the distended bladder in retention of urine.

The so-called 'linea semilunaris,' at the outer border of the sheath of the rectus, corresponds with a line, drawn slightly curved (with the concavity towards the linea alba), from the lowest part of the seventh rib to the spine of the pubes. This line would be in an adult about three inches from the umbilicus ; but in an abdomen distended by dropsy or other cause, the distance is increased in proportion.

It is important to know the position of the 'lineæ transversæ,' or tendinous intersections across the rectus abdominis. There are rarely any below the umbilicus, and generally three above it. The first is about the level of the umbilicus. The second is about four inches higher—that is, about the level of the lowest part of the tenth rib. These are the principal lines, and they divide the upper part of each rectus into two nearly quadrilateral portions, an upper and a lower: of these, those on the right side are a trifle larger than on the left. We see these muscular squares pretty plainly in some athletic subjects. Much more frequently we see them, too much exaggerated, on canvas and in marble. Artists are apt to exaggerate them, and make the front of the belly too much like a chess-board. It is lucky for artists that all critics do not see with anatomical eyes.

A familiarity with the shape and position of these divisions of the rectus is of importance, lest we should, in ignorance, make a mistake in diagnosis. A spasmodic contraction of one of these divisions, particularly the upper, or a collection of matter within its sheath, has been frequently mistaken for deep-seated abdominal disease.

In the erect position, the anterior superior spines of the ilia are a little below the level of the promontory of the sacrum. The bifurcation of the aorta is about the level of the highest part of the crest of the ilium.

78. **Umbilicus.**—The umbilicus is not midway between the ensiform cartilage and the pubes, but rather nearer to the pubes. In all cases it is situated above the centre of a man's height. It is a vulgar error to say that if a man lie with legs and arms outstretched, and a circle be drawn round him, the umbilicus would lie in the centre of it. This central point is in most persons just above the pubes.

In very corpulent persons two deep transverse furrows run across the abdomen. One runs across the navel and completely conceals it. The other is lower down, just above the fat of the pubes. In tapping the bladder above the pubes in such a case, the trochar should be introduced where this line intersects the linea alba.

Although the position of the umbilicus varies a little in different persons, according to the more or less protuberance of the abdomen, still, as a general rule, it is placed about the level of the body of the third lumbar vertebra. Now, since the aorta divides a little below the middle of the fourth lumbar, it follows that the best place to apply pressure on this great vessel is one inch below the umbilicus, and slightly to the left of it (81). That the aorta can, under favourable circumstances, be compressed under chloroform sufficiently to cure an aneurysm below it, is proved by recorded cases, and by none more effectually than by a case related in the second volume of the 'Reports of St. Bartholomew's Hospital.'

It may be asked, why not apply pressure on the aorta above the umbilicus? The answer is, that the aorta above the umbilicus is farther from the surface, and is, moreover, covered by important structures upon which pressure would be dangerous.

79. **Parts behind linea alba.**—Let us next consider what viscera lie immediately behind the linea alba. For two or three fingers' breadth below the ensiform cartilage there is the left lobe of the liver, which here crosses the middle line. Below the edge of the liver comes the stomach, more or less in contact with the linea alba, according to its degree of distension. In extreme distension the stomach pushes everything out of the way, and occupies all the room between the liver and the umbilicus. When empty and contracted, it retreats behind the liver, and lies flat in front of the pancreas at the back of the abdomen; thus giving rise to the hollow termed the 'pit of the stomach.' But as the stomach distends, it makes a considerable fulness where there was a pit. The transverse arch of the colon crosses the linea alba just above the umbilicus (sometimes quite as low). Here is the most convex part of its arch, and it lies close to the abdominal wall. Here, therefore, would be a fit place to tap it in extreme tympanites. Behind and below the umbilicus, supposing the bladder contracted, are the small intestines, covered by the great omentum.

80. **Peritoneum.**—The peritoneum is in contact with the

linea alba all the way down to the pubes, when the bladder is empty. But when the bladder distends, it raises the peritoneum from the middle line above the pubes; so that with a bladder distended half-way up to the umbilicus, there is a space of nearly two inches above the symphysis where the bladder may be tapped without risk of injury to the peritoneum. For the same reason, we have space sufficient for the successful performance of the high operation for stone. This fact in anatomy must have been well understood by Jean de Dot, the smith at Amsterdam, who, in the seventeenth century, cut himself in the linea alba above the pubes, and took out of his bladder a stone as large as a hen's egg. He lived for some years afterwards. The stone, the knife, and the portrait of the operator, may be seen to this day in the Museum at Leyden.

81. Division of aorta. Iliac arteries.—The aorta generally divides at a point one inch and a half below the umbilicus. A more reliable guide to this division than the umbilicus, is a point (a very little to the left) of the middle line about the level of the highest part of the crest of the ilium. A line drawn with a slight curve outwards from this point to the groin, where the pulsation of the common femoral can be distinctly felt (rather nearer to the pubes than the ilium), gives the direction of the common iliac and external iliac arteries. About the first two inches of this line belong to the common iliac, the remainder to the external. Slight pressure readily detects the pulsation of the external iliac above 'Poupart's ligament.'

As a rule, the length of the common iliac is about two inches, but it should be remembered there are frequent deviations. It may be between three-quarters of an inch and three inches and a half long. These varieties may arise either from a high division of the aorta, or a low division of the common iliac, or both. It is impossible to ascertain during life what is its length in a given instance, for there is no necessary relation between its length and the height of the stature. It is often short in tall men, and *vice versa*. Anatomists generally describe the right as a trifle longer

than the left ; but their average length is pretty nearly the same.

82. Mr. Abernethy, who in the year 1796 first put a ligature round the external iliac, made his incision in the line of the artery. But the easiest and safest way to reach the vessel is by an incision (recommended in the first instance by Sir Astley Cooper, and now generally adopted), beginning just on the inner side of the artery, a little above Poupart's ligament, and continued upwards and outwards a little beyond the spine of the ilium. The same incision extended farther in the same direction would reach the common iliac.

83. **Bony prominences.**—The anterior superior spine of the ilium, the spine of the pubes, and the line of Poupart's ligament, are landmarks with which every surgeon should be thoroughly familiar.

84. **Spine of ilium.**—The anterior superior spine of the ilium is the spot from which we measure the length of the lower extremity. It is a valuable landmark in determining the nature of injuries to the pelvis and the hip. The thumb easily feels the spine, even in fat persons. Its position with regard to the trochanter major should be carefully examined. The best way to do this is to place the thumbs firmly on the opposite spines, and to grasp the trochanters with the fingers. Any abnormal position on one side is thus easily ascertained with the sound side as a guide.

85. **Spine of pubes.**—The spine of the pubes is the best guide to the external abdominal ring. It is generally covered by fat and cannot therefore be easily felt by placing the finger directly over it. To feel it distinctly, we should push up the skin of the scrotum and get beneath the subcutaneous fat. If there be any difficulty in finding it, abduct the thigh, and the tense tendon of the adductor longus will lead up to it.

The position of the spine of the pubes is appealed to as a means of diagnosis in doubt between inguinal and femoral hernia. The spine lies on the outer side of the neck of an inguinal hernia, on the inner side of the neck of a femoral.

The spine of the pubes is nearly on the same horizontal line as the upper part of the trochanter major. In this line,

about one full inch external to the spine, is the femoral ring. Here is the seat of stricture in a femoral hernia.

86. **Poupart's ligament, or crural arch.**—The line of Poupart's ligament (crural arch) is in most persons indicated by a slight crescent-like furrow along the skin. It corresponds with a line drawn not straight, but with a gentle curve downwards from the spine of the ilium to the spine of the pubes. With the help of the preceding landmarks it is easy to find the exact position of the external and internal abdominal rings, and the direction of the inguinal canal.

87. **Abdominal rings.**—The external abdominal ring is situated immediately above the spine of the pubes. It is a semi-oval opening with the long axis directed obliquely downwards and inwards. Though its size varies a little in different persons, yet as a rule it will admit the end of the little finger, so that we can tell by examination whether it be free or otherwise. To ascertain this, the best way is to push up the thin skin of the scrotum before the finger; then, by tracking the spermatic cord, the finger readily glides over the crest of the pubes and feels the sharp margins of the ring.

The position of the internal ring is about midway between the spine of the ilium and the symphysis of the pubes, and about two-thirds of an inch above Poupart's ligament.

88. **Inguinal canal.**—The position of the external and internal abdominal rings being ascertained, it is plain that the direction of the inguinal canal must be obliquely downwards and inwards, and that its length in a well-formed adult male is from one and a half to two inches, according as we include the openings or not. In very young children the canal is much shorter and less oblique, the inner ring being behind the outer. With the growth of the pelvis in its transverse direction, the anterior spines of the ilia become farther apart, and thus draw the internal ring more and more away from (*i.e.* to the outer side of) the external.

An accurate knowledge of the relative positions of the abdominal rings and the inguinal canal is especially required in the diagnosis and treatment of hernial protrusions and the proper adjustment of trusses.

89. **Spermatic cord.**—The spermatic cord can be felt as it emerges through the external ring, and its course can be tracked into the scrotum. The vas deferens can be distinctly felt at the back of the cord, and separated from its other component parts.

90. **Epigastric artery.**—The direction of the deep epigastric artery corresponds with a line drawn from the inner border of the internal ring up the middle of the rectus muscle, towards the chest.

91. **Abdominal viscera.**—Now let us see how far we can make out externally the position and size of the abdominal viscera.

To make this examination with anything like success, it is desirable to relax the abdominal muscles. The man should be on his back, the head, shoulders and thorax being well raised, to relax the recti muscles; and the thighs bent on the abdomen, to relax the several fasciæ attached to the crural arch. To induce complete relaxation, where a very careful examination is desired, chloroform should be given.

In manipulating the abdomen we should not use the tips of the fingers. This is sure to excite the contraction of the muscles. The flat hand should be gently pressed upon it, and with an undulating movement.

92. It is well to bear in mind that the central tendon of the diaphragm is about the level of the lower end of the sternum at its junction with the seventh costal cartilage; that the right half of the diaphragm rises to about the level of the fifth rib—that is, about an inch below the nipple; that the left half does not rise quite so high. In tranquil breathing the diaphragm descends about half an inch.

The position of the abdominal viscera varies, to a certain extent, in different persons. The space occupied by the stomach naturally varies in the same person at different times.

Let us take, first, the largest of the abdominal viscera—the liver.

93. **Liver.**—The liver lies under the right hypochondrium, and passes across the middle line over the stomach into the left hypochondrium, generally speaking, as far as the left

mammary line. The extent to which it can be felt below the edges of the ribs depends upon whether it is enlarged or not, as well as upon its texture, and also upon the amount of flatus in the stomach and intestines. As a rule, in health its lower thin border projects about half an inch below the costal cartilages, and can be felt moving up and down with the action of the diaphragm; but it requires an educated hand to feel it. An uneducated hand would miss it altogether. That part of it, however, which crosses the middle line below the ensiform cartilage is much more accessible to the feel; here it lies immediately behind the *linea alba*, and in front of the stomach, nearly half-way down to the umbilicus. Here, therefore, is the best place to feel whether the liver be enlarged or pushed down lower than it ought to be. If it be much enlarged and much lower, even the most untutored hand could detect its edge.

Even if the edge of the liver be felt very much lower than is normal below the ribs, it does not necessarily follow that the liver is enlarged, since it may be pressed down by other causes—for instance, the habit of wearing tight stays.

To what height does the liver ascend? This can only be ascertained by careful percussion of the chest-wall. The highest part of its convexity on the right side is about one inch below the nipple, or nearly on a level with the external and inferior angle of the *pectoralis major*. Posteriorly the liver comes to the surface below the base of the right lung, about the level of the tenth dorsal spine.

Roughly speaking, the upper border of the liver corresponds with the level of the tendinous centre of the diaphragm; that is, the level of the lower end of the sternum. Thus a needle thrust into the right side, between the sixth and seventh ribs, would traverse the lung, and then go through the diaphragm into the liver.

94. **Gall bladder.**—The gall bladder, or rather the fundus of it, is situated, but cannot be felt, just below the edge of the liver about the ninth costal cartilage, outside the edge of the right rectus muscle. It lies in close contact with the colon.

95. **Stomach.**—The stomach varies in size more than any organ in the body. When empty and contracted (79) it lies at the back of the abdomen, overlapped by the left lobe of the liver, and in front of the pancreas. When very full, it turns on its axis and swells up towards the front, coming close behind the wall of the abdomen, occupying most of the left hypochondrium and epigastrium, displacing the other contiguous organs, pushing in every direction, and often interfering with the action of the heart and left lung. Hence the palpitation and distressing heart-symptoms in indigestion and flatulence.

The cardiac orifice of the stomach lies to the left of the middle line, just below the level of the junction of the seventh costal cartilage with the sternum. 11' 9 d. v

96. **Pylorus.**—The pylorus lies under the liver, on the right side, near the end of the cartilage of the eighth rib; but it cannot be felt unless occasionally when enlarged and hardened by disease.

97. **Spleen.**—The spleen, if healthy, cannot be felt, so completely is it sheltered by the ribs. It lies on the left side, connected to the great end of the stomach, beneath the ninth, tenth, and eleventh ribs, between the axillary lines—lines drawn vertically downwards from the anterior and posterior margins of the axilla. Its upper edge is on a level with the spine of the ninth dorsal vertebra, its lower with the spine of the eleventh.

Its position and size, therefore, in health can only be ascertained, and not very accurately, by the extent of dulness on percussion. The greatest amount of dulness would be over the tenth and eleventh ribs; above this the thin edge of the lung would intervene between the spleen and the abdominal wall. If, therefore, the spleen can be distinctly felt below the ribs, it must be enlarged. In proportion to its enlargement, so can its lower rounded border be detected below the tenth and eleventh ribs, especially when forced downwards by a deep inspiration.⁵

98. **Pancreas.**—The pancreas lies transversely behind the stomach, and crosses the aorta and the spine about the

junction of the first and second lumbar vertebræ. The proper place to feel for it, therefore, would be in the linea alba about two or three inches above the umbilicus. Is it perceptible to the touch?—only under very deep pressure, and very favourable circumstances, such as an emaciated and empty abdomen. It is worth remembering that it may be felt under such conditions. The pancreas of normal size, in thin persons, has been mistaken for disease—disease of the transverse arch of the colon, or aneurysm of the abdominal aorta.

99. **Kidney.**—The kidney lies at the back of the abdomen on the quadratus lumborum and psoas muscles, opposite the two lower dorsal and two upper lumbar spines. The right, owing to the size of the liver, is a trifle—say, three-quarters of an inch—lower than the left. The pelvis of the kidney is about the level of the spine of the first lumbar vertebra: the upper border is about the level of the space between the eleventh and twelfth dorsal spines; the lower border comes as low as the third lumbar spine. During a deep inspiration both kidneys are depressed by the diaphragm nearly half an inch.

Can we feel the normal kidney? The only place where it is accessible to pressure is just below the last rib, on the outer edge of the 'erector spinæ.' I say accessible to pressure, for I have never succeeded in satisfying myself that I have distinctly felt its rounded lower border in the living subject, nor even in the dead, with the advantage of flaccid abdominal walls and the opportunity of making hard pressure with both hands, placed simultaneously, one in front of the abdomen, the other on the back. For these reasons, although we can easily ascertain its degree of tenderness, we cannot actually feel it unless it be considerably enlarged.

We must be on our guard not to mistake for the kidney an enlarged liver or spleen, or an accumulation of fæces in the lumbar part of the colon.

100. **Large intestine.** — Let us now trace the large intestine and see where it is accessible to pressure. The 'cæcum,' or 'caput coli,' with the appendix vermiformis and the ileo-cæcal valve lie in the right iliac fossa. The ascending

colon overlaid by the small intestines runs up the right lumbar region over the right kidney. The transverse colon crosses the abdomen above the umbilicus, sometimes even lower. The descending colon lies in the left lumbar region in front of the left kidney, covered by the small intestines. The sigmoid flexure occupies the left iliac fossa.

Throughout this tortuous course, except at the hepatic and splenic flexures, the colon is accessible to pressure, and we could, under favourable circumstances, detect hardened fæces in it. In a case which occurred in St. Bartholomew's Hospital, a collection of fæces in the transverse colon formed a distinct tumour in the abdomen. All the symptoms yielded to large and repeated injections of olive oil. In another case an accumulation of fæcal matter in the sigmoid flexure during life was mistaken for a malignant disease.

101. **Colotomy.**—The operation of opening the colon (colotomy) may be done in the right or left loin, below the kidney, in that part of the colon not usually covered by peritoneum.

The landmarks of the operation are :—(1) The last rib, of which feel the sloping edge ; (2) the crest of the ilium ; (3) the outer border of the 'erector spinæ.' The incision should be about three inches long, midway between the rib and the ilium. It should begin at the outer border of the 'erector spinæ,' and should slope downwards and outwards in the direction of the rib. The edge of the 'quadratus lumborum,' which is the guide to the colon, is about one inch external to the edge of the 'erector spinæ,' or three full inches from the lumbar spines. The line of the gut is vertical, and runs for a good two inches between the lower border of the kidney and the iliac crest on the left side ; rather less on the right.

Small intestines.—All the room below the umbilicus is occupied by the small intestines. The transverse part of the duodenum crosses the spine at the second lumbar vertebra, about an inch and a half above the level of the umbilicus. On account of its fixity and its close connection to the spine, this part of the small intestine is the most likely to be injured by severe blows on the abdomen. The coils of the

jejunum lie nearer to the umbilicus (one reason of the great fatality of umbilical herniæ). Those of the ilium are lower down.

102. **Bladder.**—When the bladder distends, it gradually rises out of the pelvis into the abdomen, pushes the small intestines out of the way, and forms a swelling above the pubes, reaching in extreme cases to the navel. The outline of this swelling is perceptible to the hand as well as to percussion. More than this, fluctuation can be felt through the distended bladder by tapping on it in front with the fingers of one hand, while the forefinger of the other passed up the rectum feels the bottom of the ‘trigone.’

THE PERINEUM.

The body is supposed to be placed in the usual position for lithotomy.

103. **Bony framework.**—We can readily feel the osseous and ligamentous boundaries of the perineum; namely, the rami of the pubes and ischia, the tuberosities of the ischia, the great sacro-ischiatic ligaments, and the apex of the coccyx. This framework forms a lozenge-shaped space. If we draw an imaginary line across it from the front of one tuber ischii to the other, we divide this space into an anterior and a posterior triangle. The anterior is nearly equilateral, and, in a well-formed pelvis, its sides are from three to three and a half inches long. It is called the urethral triangle. The posterior, containing the greater part of the anus and the ischio-rectal fossa on each side, is called the anal triangle.

104. **Raphé.**—A slight central ridge of skin, called the ‘raphé,’ runs from the anus up the perineum, scrotum, and penis. This ‘raphé,’ or middle line of the perineum, is the ‘line of safety’ in making incisions to let out matter or effused urine, or to divide a stricture.

105. **Central point of perineum.**—It is very important to know that a point of the raphé about midway between the scrotum (where it joins the perineum) and the centre of the anus, corresponds with the so-called ‘central tendon’ where

the perineal muscles meet. The bulb of the urethra lies above this point, and never, at any age, comes lower down. The artery of the bulb, too, never runs below this level. Therefore the incision in lateral lithotomy should always commence below it. A knife introduced at this point, and pushed backwards with a very slight inclination upwards, would enter the membranous part of the urethra just in front of the prostate gland; pushed still farther it would enter the neck of the bladder. This point, then, is a very good landmark to the urethra in lithotomy, or, indeed, in any operations on the perineum.

The incision in the lateral operation of lithotomy, beginning below the central point of the perineum, should be carried downwards and outwards between the anus and the tuberosity of the ischium, a little nearer to the tuberosity than the anus. The lower end of the incision should reach a point just below the anus.

106. **Triangular ligament.**—In a thin perineum, we can feel the lower border of the deep perineal fascia or the 'so-called' triangular ligament of the urethra. The urethra passes through it about one inch below the lower part of the symphysis pubis, and about three-quarters of an inch higher than the central tendon of the perineum. It is important to bear in mind these landmarks in introducing a catheter. If the catheter be depressed too soon, its passage will be resisted by the triangular ligament; if too late, it will be likely to make a false passage through the bulb.

107. **Anus.**—One of the most important landmarks which guide a surgeon in his operations about the anus, is a white line⁶ at the junction of the skin and mucous membrane. It is easily recognised and is of especial interest, because it marks with great precision the linear interval between the external and internal sphincter muscles. From this line the internal sphincter extends upwards, beneath the mucous membrane, for about an inch, becoming gradually more and more attenuated.

The wrinkled appearance of the anus is caused by the contraction of the external sphincter. At the bottom of

these cutaneous folds, especially towards the coccyx, we look for 'fissure of the anus.'

108. **Landmarks in the rectum.**—Many valuable landmarks may be felt by introducing the finger into the rectum with a catheter at the same time in the urethra. The principal of these landmarks are the following :—

a. The finger can feel the extent and powerful grasp of the internal sphincter for about one inch up the bowel (107).

b. Urethra.—Through the front wall of the bowel the finger can most distinctly feel the membranous part of the urethra, exactly in the middle line. This is very important, because you can ascertain with precision whether the catheter has deviated from the proper track.

c. Prostate gland.—About an inch and a half or two inches from the anus, the finger comes upon the prostate gland. The gland lies in close contact with the bowel, and can be detected by its shape and hard feel. The finger, moved from side to side, can examine the size of its lateral lobes, their consistence and sensibility.

d. The finger, introduced still farther, can reach beyond the prostate, as far as the apex of the trigone of the bladder. More than this, it can feel the angle between the 'ductus communes ejaculatorii,' which forms the apex of the trigone. The centre of this trigone is the precise spot where the distended bladder should be punctured through the rectum. The more distended the bladder, the easier can this spot be felt. Fluctuation is at once detected by a gentle tap on the bladder above the pubes (102). The trochar must be thrust in the direction of the axis of the distended bladder ; that is, roughly speaking, in a line drawn from the anus through the pelvis to the umbilicus.

e. The fold of peritoneum, called the recto-vesical pouch, is about four inches from the anus, therefore it is not within reach of the finger ; and we run no risk of wounding it in tapping the bladder if the trochar be introduced in the centre of the trigone.

f. The finger may, perhaps, feel one of the prominent folds of mucous membrane—'Houston's folds'—which are situated

within the rectum. The largest fold projects from the side, and sometimes from the upper part of the rectum, near the prostate. When thickened or ulcerated, this fold occasions great pain in defæcation; and great relief is afforded by its division.⁷

g. Lastly, the finger can examine the condition of the spaces filled with fat on either side of the rectum, called the ischio-rectal fossæ, with a view to ascertain the existence of deep-seated collections of matter, or the internal communications of fistulæ.

109. **Introduction of catheters.**—In the introduction of catheters the following are good rules. Keep the point of the instrument well applied all along against the upper surface of the urethra;—depress the handle at the right moment (106);—keep the umbilicus in view;—in cases of difficulty feel the urethra through the rectum, to ascertain whether the instrument be in the right direction. Attention to these rules diminishes the risk of making a false passage, an injury which under great delicacy in manipulation ought never to happen.

110. **Urethra in the child.**—In children the membranous part of the urethra is, relatively, very long, owing to the smallness of the prostate. It is also more sharply curved, because the bladder in children is more in the abdomen than in the pelvis. It is, moreover, composed of thin and delicate walls. The greatest gentleness, therefore, should be used in passing a catheter in childhood; else the instrument is likely to pass through the coats and make a false passage. Hence the advantage of being able to ascertain through the rectum whether the instrument be in the right track and moving freely in the bladder, which can also be easily felt in children.

THE THIGH.

111. **Poupart's ligament, or crural arch.**—Mark the anterior superior spine of the ilium, the spine of the pubes, and define the line of 'Poupart's ligament' or crural arch, which extends between them. This line is one of our guides

in the diagnosis of inguinal and femoral herniæ. If the bulk of the tumour be above the line, the hernia is probably inguinal ; if below it, femoral. The line is not a straight one drawn from the spine of the ilium to the spine of the pubes, but slightly curved, with the convexity downwards, owing to its close connection with the fascia lata of the thigh. In many persons it can be distinctly felt ; in nearly all its precise course is indicated by a slight furrow in the skin.

For the points about the spine of the pubes, refer to paragraph 85.

112. **Furrow at the bend of the thigh.**—When the thigh is even slightly bent, there appears a second furrow in the skin below that at the crural arch. This second furrow begins at the angle between the scrotum and the thigh, passes outwards, and is gradually lost between the top of the trochanter and the anterior superior spine of the ilium. It runs right across the front of the capsule of the hip-joint. For this reason it is a valuable landmark in amputation at the hip-joint. The point of the knife should be introduced externally where the furrow begins, should run precisely along the line of it, and come out where it ends ; so that the capsule of the joint may be opened with the first thrust. In suspected disease of the hip pressure made in this line, just below the spine of the ilium, will tell us if the joint be tender. Effusion into the joint obliterates all trace of the furrow, and makes a fulness when contrasted with the opposite groin.

113. **Saphenous opening.**—In most persons there is a natural depression over the saphenous opening in the fascia lata, where the saphena vein joins the femoral. The position of this opening is just below the inner third of Poupart's ligament, and about an inch and a half external to the spine of the pubes. This is the place where the swelling of a femoral hernia first appears : therefore it ought to be carefully examined in cases of doubt.

114. **Femoral ring.**—The position of the femoral ring, through which the deep lymphatics of the thigh pass into the pelvis, and through which a femoral hernia escapes from the abdomen, is, on a deeper plane, about half an inch higher than

the saphenous opening, and immediately under Poupart's ligament. As the plane of the ring is vertical in the supine position of the body, the way in which we should try to reduce a femoral hernia is by pressure, applied first in a downward direction, afterwards in an upward. The intestine protruded has to pass back under a sharp edge of fascia, namely, the upper horn of the saphenous opening (known as Hey's ligament). At the same time we bend the thigh, to relax the fascia as much as possible.

A good way to find the seat of the femoral ring with precision is the following:—Feel for the pulsation of the femoral artery on the pubes; allow half an inch (on the inner side) for the femoral vein; then comes the femoral ring.

In performing the operation for the relief of the stricture in femoral hernia the incision through the skin should be about an inch and a half external to the spine of the pubes. Its direction should be vertically upwards, and its middle should be just over the femoral ring.

115. **Lymphatic glands in the groin.**—The cluster of inguinal and femoral lymphatic glands can sometimes be felt in thin persons. The inguinal lie for the most part along the line of Poupart's ligament: they receive the absorbents from the wall of the abdomen, and of the buttock, the urethra, the penis, the scrotum, and the anus. Hence they are generally affected in venereal disease. The femoral glands lie chiefly over the saphenous opening and along the outer side of the saphena vein: they receive all the absorbents of the lower extremity; they receive some also from the scrotum—of which we have practical evidence in cases of chimney-sweeper's cancer.

116. **Trochanter major.**—The trochanter major is a most valuable landmark, to which we are continually appealing in injuries and diseases of the lower extremity. There is a natural depression over the hip (in fat persons) where it lies very near the surface, and can be plainly felt, especially when the thigh is rotated. Nothing intervenes between the bone and the skin except the strong fascia of the gluteus maximus and the great bursa underneath it.

When a man lies on his back, the top of the great trochanter is pretty nearly on a level with the spine of the pubes, and about three-fourths of an inch lower than the top of the head of the femur.

117. **Nélaton's line.**—‘If in the normal state you examine the relations of the great trochanter to the other bony prominences of the pelvis, you will find that the top of the trochanter corresponds to a line drawn from the anterior superior spine of the ilium to the most prominent part of the tuberosity of the ischium. This line also runs through the centre of the acetabulum. The extent of displacement in dislocation or fracture is marked by the projection of the trochanter behind and above this line.’⁸

‘Nélaton's line,’ as it is termed, theoretically holds good. But in stout persons it is not always easy to feel these bony points so as to draw the line with precision. A surgeon must, after all, in most cases trust to measurement by his eyes and his flat hands—his best guides. Thus, let the thumbs be placed firmly on the spines of the ilia, while the fingers grasp the trochanters on each side. Having the sound side as a standard of comparison, a practised hand will easily detect any displacement on the injured side. Hippocrates bids us compare the sound parts with the parts affected (in fractures) and observe the inequalities.

The top of the great trochanter is the guide in an operation recently introduced by Mr. Adams, namely, the ‘subcutaneous section of the neck of the femur.’ ‘The puncture should be made one inch above and nearly one inch in front of the top of the trochanter. The neck of the bone is to be sawn through at right angles to its axis, the saw working parallel to Poupart's ligament, and about one inch below it.’

118. **Spine of the ilium.**—The anterior superior spine of the ilium is the point from which we measure the length of the lower limb. By looking at the spines of opposite sides we can detect any slant in the pelvis. By pressure on both spines simultaneously we test a case of suspected fracture of the pelvis, or disease at the sacro-iliac joint.

119. 'In reducing a dislocation of the hip by manipulation it is important to bear in mind that, in every position, the head of the femur faces nearly in the direction of the inner aspect of its internal condyle.'⁹

120. **Compression of femoral artery.**—The femoral artery can be felt beating and effectually compressed against the pubes about a point midway between the spine of the ilium and the symphysis pubis. How should the pressure be applied when the patient lies on the back? In accordance with the slope of the bone—that is, with a slight inclination upwards. A want of attention to this point is the reason why so many fail when they undertake to stop the circulation through the femoral artery in an amputation, or to cure an aneurysm by digital compression.

If the Italian tourniquet be used, we should be careful to adjust the counter-pad well under the tuberosity of the ischium. If digital pressure be used, it is easy to command the femoral by slight pressure of the thumb, provided the fingers have a firm hold on the great trochanter.

121. **Sartorius.**—The sartorius is the great fleshy landmark of the thigh, as the biceps is of the arm, and the sterno-cleido-mastoideus of the neck. Its direction and borders may easily be traced by asking the patient to raise his leg, a movement which puts the muscle in action. The same action defines the boundaries of the triangle (of Scarpa) formed by Poupart's ligament, the adductor longus and sartorius.

122. **Line of femoral artery.**—To define the course of the femoral artery, draw a line from midway between the anterior superior spine of the ilium and the symphysis pubis to the (spurlike) tubercle for the adductor magnus on the inner side of the knee. The femoral artery lies under the upper two-thirds of this line.

The sartorius begins to cross the artery, as a rule, from three to four inches below Poupart's ligament. The point at which the profunda artery arises is about one and a half or two inches below the ligament. Therefore the incision for tying the femoral in Scarpa's triangle should commence about

a hand's breadth below Poupart's ligament, and be continued for three inches in the line of the artery.

To command the femoral in Scarpa's triangle the pad of the tourniquet should be placed at the apex, and the direction of the pressure should be, not backwards, but outwards, so that the artery may be compressed against the femur.

In the middle third of the thigh the femoral artery lies in Hunter's canal, overlapped by the sartorius. About the commencement of the lower third the artery leaves the canal through the oval opening in the adductor magnus, and, under the name of popliteal, enters the popliteal space. The line for finding the artery in Hunter's canal has been already traced. The incision to reach the artery in this part of its course would fall in with the outer border of the sartorius.

To command the femoral artery in Hunter's canal, the pressure should be directed outwardly, so as to press the vessel against the bone.

123. **Line of the anterior crural nerve.**—This nerve enters the thigh beneath the crural arch about midway between the anterior superior spine of the ilium and the spine of the pubes. It lies about half an inch to the outer side of the femoral artery and immediately divides into its numerous branches.

124. **Line of the great ischiatic nerve.**—The track of this nerve corresponds with a line drawn from a point about midway between the great trochanter and the tuber ischii (a trifle nearer to the latter) down to the middle of the popliteal space. The most superficial part of the nerve is just below the fold of the buttock. An incision here would find it on the outer side of the biceps. Lower down it lies to the inner side of the muscle.

THE BUTTOCKS.

125. **Buttocks.—Bony landmarks.**—The bony landmarks of the buttocks which can be distinctly felt are: 1, the posterior superior spines of the ilia; 2, the spines of the sacral vertebræ; 3, the two tubercles of the last sacral ver-

tebra ; 4, the apex of the coccyx in the deep groove leading to the anus ; 5, the tuberosities of the ischia on each side of the anus.

The posterior superior spines of the ilia are about the level of the second sacral spine, and correspond with the middle of the sacro-iliac symphysis.

The third sacral spine marks the lowest level to which the membranes of the cord and the cerebro-spinal fluid descend in the spinal canal.

The tuberosities of the ischia, in the erect position, are covered by the gluteus maximus. In the sitting position they support the weight of the body, and are only covered by a thick pad of coarse fat. Between this pad and the bones there is a bursa (sometimes called the coachman's), since it becomes occasionally enlarged and inflamed in coachmen.

The prominence of the nates is one of the characteristics of man in connection with his erect attitude. 'Les fesses n'appartiennent qu'à l'espèce humaine.' They are formed of an accumulation of fat over the great muscle of the buttock (gluteus maximus). From their appearance we may gather some indication of the state of the constitution. They are firm and globose in the vigorous ; loose and flaccid in the infirm. Wasting and flattening of one, compared with the other, is an early symptom of disease in the hip.

126. **Fold of the buttock.**—The deep furrow, termed 'the fold of the buttock,' which separates the nates from the back of the thigh, corresponds with the lower border of the gluteus maximus. Its altered direction in disease of the hip is very characteristic. This is the best place to feel for the great ischiatic nerve. We find it by pressing deeply between the trochanter and the tuber ischii, rather nearer to the latter. When we sit upright, the nerve is not liable to pressure ; but it becomes numbed when we sit long sideways.

127. **Gluteal and ischiatic arteries.**—To find at what point the gluteal artery comes out of the pelvis, draw a line from the posterior superior spine of the ilium to the top of the trochanter major, rotated inwards. The junction of the inner

with the middle third of this line lies over the artery as it emerges from the upper border of the great ischiatic notch.

The point of exit of the ischiatic artery from the pelvis is about half an inch lower than that of the gluteal.

128. **Pudic artery.**—The pudic artery crosses the spine of the ischium outside the pelvis. To find it, draw a line from the outer side of the tuber ischii to the posterior superior spine of the ilium. The junction of the lower with the middle third gives the position of the artery. The ischiatic artery lies close to it, but nearer the middle line.

Looking at the course of these arteries it appears that when we sit on hard seats the pressure is sustained by the bones ; when we recline on soft seats the pressure is sustained more by the soft parts, and reaches the arteries ; hence the tendency of modern modes of reposing to drive the blood into the interior of the pelvis and favour the production of piles and uterine disorders. A celebrated French accoucheur used to say that the fashion of high waists, tight lacing, and easy chairs brought him many thousands a year.

THE KNEE.

129. **Bony landmarks.**—The patella ; the tuberosities of the two condyles ; the tubercle of the tibia for the attachment of the ligamentum patellæ ; another (the lateral) tubercle, on the outer side of the head of the tibia ; the internal tuberosity of the tibia and the head of the fibula are the chief bony landmarks of the knee.

Observe that the head of the fibula lies at the outer and back part of the tibia, and that it is pretty nearly on a level with the tubercle for the attachment of the ligamentum patellæ.

In thin persons we can feel the adductor tubercle or spur-like projection of bone above the internal condyle which gives attachment to the tendon of the adductor magnus. This spur-like projection corresponds with the level of the epiphysis of the lower end of the femur, and also with the level of

the highest part of the trochlea for the patella : facts worth notice in performing excision of the knee.

'In reducing a dislocation of the hip, it is important to bear in mind that the inner aspect of the internal condyle in every position of the limb faces nearly in the direction of the head of the femur.' (119.)

The tubercle on the outer side of the head of the tibia gives attachment to the broad and strong aponeurosis (tendon of the tensor fasciæ), which, acting like a brace for the support of the pelvis, is well seen in emaciated persons down the outer side of the thigh. This tubercle indicates the level to which the condyles of the femur descend, and the lower level of the synovial membrane.

The patella, in extension of the knee, is nearly all above the condyles ; in flexion, it lies in the inter-condyloid fossa (more on the external condyle), and thus protects the joint in kneeling. Its inner border is thicker and more prominent than the outer, which slopes down towards its condyle.

130. **Ligamentum patellæ.**—The line of the ligamentum patellæ is vertical. Hence any deviation from this line, one way or the other, indicates more or less dislocation of the tibia. There is a pellet of fat under the ligament, which answers a 'packing' purpose—sinking in when the knee is bent ; rising when the knee is extended, and bulging on either side of the tendon, almost enough to give the feel of fluctuation.

In a well-formed leg the ligamentum patellæ, the tubercle of the tibia, and the middle of the ankle should be in the same straight line. A useful point in the adjustment of fractures.

Behind the upper half of the ligamentum patellæ is the synovial membrane of the knee-joint ; behind the lower half is a synovial bursa and a pad of fat. It is well to remember this in cases of injury to the ligamentum patellæ.

131. **Patellar bursa.**—The patellar or housemaid's bursa is situated not only over the patella, but over the upper part of the ligament. This is plain enough when the bursa becomes enlarged. There is another subcutaneous bursa over

the insertion of the ligament into the tubercle of the tibia. This is quite independent of the deep bursa between the tendon and the bone.

132. **Synovial membrane of knee.**—The synovial membrane of the knee, when the joint is extended, rises like a cul-de-sac above the upper border of the patella about two inches. It ascends, too, a little higher under the vastus internus than the vastus externus—a fact very manifest when the joint is distended. When the knee is bent this cul-de-sac is drawn down—hence the rule of bending the knee in operations near the lower end of the femur.

The lower level of the synovial membrane of the knee is just above the level of the upper part of the head of the fibula. The tibio-fibular synovial membrane is, with rare exceptions, independent of that of the knee.

133. **Popliteal tendons.**—The tendons forming the boundaries of the popliteal space can be distinctly felt when the muscles which bend the knee are acting. On the outer side, we have the biceps running down to the head of the fibula. On the inner side we feel three tendons, disposed as follows:—nearest to the middle of the popliteal space is the semitendinosus, very salient and traceable high up the thigh; next comes the thick round tendon of the semimembranosus; still more internally is the gracilis. The sartorius, which forms a graceful muscular prominence on the inner side of the knee, does not become tendinous until it gets below it.

134. **Popliteal bursa.**—The precise position of the bursa in the popliteal space, which sometimes enlarges to the size of a hen's egg, is between the tendon of the inner head of the gastrocnemius and the tendon of the semimembranosus, just where they rub one against the other. The bursa is from one and a half to two inches long. When enlarged, it makes a swelling on the inner side of the popliteal space, which bulges and becomes tense when the knee is extended, and *vice versa*. I examined 150 bodies with a view to ascertain how often this bursa communicates with the synovial membrane of the knee. There was a communication about once

in five instances. This should make us cautious in interfering too roughly with the bursa when enlarged.

135. **Popliteal artery.**—The popliteal artery can be felt beating and can be compressed through the fat which fills the popliteal space against the back of the femur, close to which it lies very deep. But pressure, sufficient to stop the blood, must be firm, and should be made against the bone nearer to the inner than the outer hamstrings. The line of the artery corresponds with the middle of the ham. It lies under cover of the fleshy belly of the semimembranosus, and the outer border of this muscle is the guide to it. An incision down the middle of the ham would fall in with the vessel just above the condyles.

136. **Popliteal nerve.**—This nerve runs down the middle of the popliteal space, superficial and a little external to the artery, from which it is separated by the popliteal vein.

137. **Peroneal nerve.**—The peroneal nerve runs parallel with and close to the inner border of the tendon of the biceps. It can be felt in thin persons. There is a risk of dividing it in tenotomy of the biceps, unless the knife be carefully introduced from within outwards. Below the knee the nerve can be felt close to the fibula just below the head, and when pressed upon in this situation causes a sensation to run down its branches to the foot.

THE LEG AND ANKLE.

138. **Bony points.**—The tubercle of the tibia (for the attachment of the ligamentum patellæ), the sharp front edge called the shin, and the broad flat subcutaneous surface of the bone can be felt all the way down. The inner edge can be felt too, but not so plainly. The lower third is the narrowest part of the bone and the most frequent seat of fracture.

The head of the fibula is a good landmark on the outer side of the leg, about one inch below the top of the tibia and nearly on a level with its tubercle. Observe that it is placed well back, and that it forms no part of the knee-joint proper, and takes no share in supporting the weight of the body.

The shaft of the fibula arches backwards, the reverse of the shaft of the tibia. The fact of the bones not being on the same plane should be remembered in flap amputations. The shaft of the fibula is so buried amongst the muscles, that the only part to be distinctly felt is the lower fourth. Here there is a flat triangular subcutaneous surface, between the peroneus tertius in front, and the two peronei (longus and brevis) behind. Here is the most frequent seat of fracture.

139. **Malleoli.**—The shape and relative position of the malleoli should be carefully studied, as the great landmarks of the ankle. The inner malleolus does not descend so low as the outer, and advances more to the front: at the same time, owing to its greater antero-posterior depth, it is on the same plane as the outer behind. The lower border of the inner malleolus is somewhat rounded, and the slight notch in it for the attachment of the lateral ligament can be felt. The outer malleolus descends lower than the inner, thus effectually locking the joint on the outer side. Its shape is not unlike the head of a serpent. Viewed in profile, it lies just in the middle of the joint.

In Syme's amputation of the foot at the ankle, the line of the incision should run from the apex of the outer malleolus under the sole to the middle of the inner.

In a well-formed leg, the inner edge of the patella, the inner ankle, and the inner side of the great toe, should be in the same vertical plane. Look to these landmarks in adjusting a fracture or dislocation, keeping at the same time an eye upon the conformation of the opposite limb.

There are several strong tendons to be seen and felt about the ankle.

140. **Tendo Achillis.**—Behind is the tendo Achillis. It forms a high relief, with a shallow gutter on each side of it. The narrowest part of the tendon, where it should be divided in tenotomy, is about the level of the inner ankle; below this it expands again to be attached to the lower and back part of the os calcis. Seen in profile, the tendon is not straight, but slightly concave—being drawn in by an aponeurosis which forms a sort of girdle round it. This girdle proceeds from the

posterior ligament of the ankle ; and, though most of its fibres encircle the tendon, some of them adhere to and draw in its sides. All this disappears when the tendon is laid bare by dissection.

141. **Tendons behind inner ankle.**—Above and behind the malleolus internus we can feel the broad flat tendon of the tibialis posticus and upon it that of the flexor longus digitorum. The tendon of the tibialis posticus lies nearest to the bone and comes well up in relief in adduction of the foot. It lies close to, and parallel with, the inner edge of the tibia, so that this edge is the best guide to it. Therefore in tenotomy the knife should be introduced first perpendicularly between the tendon and the bone, and then turned at right angles to cut the tendon. The tendon has a separate sheath and synovial membrane, which commences about one inch and a half above the apex of the malleolus, and is continued to its insertion into the tubercle of the scaphoid bone. The proper place, then, for division of the tendon is about two inches above the end of the malleolus.

In a young and fat child, where the inner edge of the tibia cannot be distinctly felt, the best guide to the tendon is a point midway between the front and the back of the ankle. An incision in front of this point might injure the internal saphena vein ; behind this point, the posterior tibial artery.

142. **Tendons behind outer ankle.**—Behind the malleolus externus we feel the two peroneal (long and short) tendons. They lie close to the edge of the fibula, the short one nearer to the bone. In dividing these tendons, the knife should be introduced perpendicularly to the surface, and about two inches above the apex of the ankle, so as to be above the synovial sheaths of the tendons.

143. **Tendons in front of ankle.**—Over the front of the ankle, when the muscles are in action, we can see and feel, beginning on the inner side, the tendons of the tibialis anticus, the extensor longus pollicis, the extensor longus digitorum, and the peroneus tertius. They start up like cords when the foot is raised, and are kept in their proper relative position by strong pulleys formed by the anterior annular ligament. Of

these pulleys the strongest is that of the extensor communis digitorum. When the ankle is sprained, the pain and swelling arise from a stretching of these pulleys and effusion into their synovial sheaths. A laceration of one of the pulleys and escape of the tendon is extremely rare.

The place for the division of the tendon of the tibialis anticus, so as to divide it below its synovial sheath, is about one inch before its insertion into the cuneiform bone. The knife should be introduced on the outer side, so as to avoid the dorsal artery of the foot.

Now trace the lines of the arteries, and the landmarks near which they divide.

144. **Popliteal artery.**—About one inch and a quarter below the head of the fibula, or say one inch below the tubercle of the tibia, the popliteal artery divides into the anterior and posterior tibial. The peroneal comes off from the posterior tibial about three inches below the head of the fibula.

Consequently we may lay down, as a general rule, that, in amputations one inch below the head of the fibula, only one main artery, the popliteal, is divided. In amputations two inches below the head of the fibula, two main arteries, the anterior and posterior tibial, are divided. In amputations three inches below the head, three main arteries, the two tibials and the peroneal, are divided.

145. **Anterior tibial artery.**—The anterior tibial artery comes at first horizontally forwards between the bones to get to the front of the interosseous membrane, one inch and a quarter below the head of the fibula, and here lies close to this bone. Its subsequent course is defined by a line drawn from the front of the head of the fibula to the middle of the front of the ankle. This line corresponds pretty nearly with the outer border of the tibialis anticus all the way down. If this muscle be put in action, its outer border (the intermuscular line) is plainly seen, and the incision for the ligature of the artery in any part of its course may be defined with the greatest precision. The artery can be felt beating and can be compressed where it crosses the front of the tibia and ankle.

146. **Posterior tibial artery.**—The posterior tibial commences about one inch and a quarter below the head of the fibula. Its subsequent course corresponds with a line drawn from the middle of the upper part of the calf to the hollow behind the inner ankle, where it can be felt beating distinctly about half an inch behind the edge of the tibia. A vertical incision down the middle of the calf would reach the artery under cover of the gastrocnemius and soleus. A vertical incision along the middle third of the leg, about half an inch from the inner edge of the tibia, would enable the operator to reach the artery sideways, by detaching from the bone the tibial origin of the soleus.

147. **Saphena veins.**—The subcutaneous veins on the dorsum of the foot form an arch convex towards the toes (as on the back of the hand), from which issue the two main subcutaneous trunks of the lower limb, the internal and external saphena veins. The internal saphena vein can be always plainly seen over the front of the inner ankle. Its further course up the inner side of the leg, knee, and thigh to its termination in the femoral is not in all persons manifest.

The external saphena vein runs behind the outer ankle and up the middle of the calf to empty itself (generally) into the popliteal vein.

THE FOOT.

What are the bony landmarks which guide us in the surgery of the foot?

148. **Points of bone.**—Along the inner side of the foot, beginning from behind, we can feel—1, the tuberosity of the os calcis; 2, the projection of the internal malleolus; 3, the projection of the os calcis, termed ‘sustentaculum tali,’ about one full inch below the malleolus; 4, about one inch in front of the malleolus internus, and a little lower, is the tubercle of the scaphoid bone; the gap between it and the sustentaculum tali being filled by the calcaneo-scaphoid ligament and the tendon of the tibialis posticus, in which there is often a sesamoid bone; 5, the internal cuneiform bone; 6, the projection

of the first metatarsal bone ; 7, the sesamoid bones of the great toe.

Along the outer side of the foot we can feel—1, the external tuberosity of the os calcis ; 2, the external malleolus ; 3, the peroneal tubercle of the os calcis, one inch below the malleolus, with the long peroneal tendon below it, and the short one above it ; 4, the projection of the base of the fifth metatarsal bone.

149. **Lines of joints.**—In fat persons the following rules for finding the joints may be of service as regards the surgery of the foot :—

The level of the ankle joint lies about half an inch above the end of the inner malleolus. This is worth remembering in performing 'Syme's' amputation.

The tubercle of the scaphoid bone is the best guide to the astragalo-scaphoid joint which lies immediately behind it ; and the plane of this joint is in the same line as that of the calcaneo-cuboid. Thus a line drawn transversely over the dorsum of the foot, behind the tubercle of the scaphoid, would strike both the joints opened in 'Chopart's' operation.

Place your thumb on the tubercle of the scaphoid, and measure about one inch and a half in front : here you find the joint between the internal cuneiform bone and the metatarsal bone of the great toe. This point is useful in Lisfranc's operation, which consists in the removal of the metatarsal bones.

The line of the calcaneo-cuboid joint lies midway between the external malleolus and the (tarsal) end of the metatarsal bone of the little toe.

The projection of the fifth metatarsal bone is the guide to the joint between it and the cuboid.

Notice that the line of the joints between the metatarsal bones and the first phalanges lies a full inch farther back than the interdigital folds of the skin. This is a point to be remembered in amputating the toes.

150. **Dorsal artery.**—The line of the dorsal artery of the foot is from the middle of the ankle to the interval between

the first and second metatarsal bones. The artery can be felt beating over the bones along the outer side of the extensor longus pollicis, which is the best guide to it.

151. **Bursæ.**—The synovial sheath of the extensor longus pollicis extends from the front of the ankle, over the instep (apex of the internal cuneiform bone) as far as the metatarsal bone of the great toe. There is generally a bursa over the instep, above or, it may be, below the tendon.

There is often a large irregular bursa between the tendons of the extensor longus digitorum, and the projecting end of the astragalus, over which the tendons play. There is much friction here. It is well to be aware that this bursa sometimes communicates with the joint of the head of the astragalus.

152. **Plantar arteries.**—The course of the external plantar artery corresponds with a line drawn from the hollow behind the inner ankle obliquely across the sole nearly to the base of the fifth metatarsal bone; from thence the artery turns transversely across the foot, lying (deeply) near the bases of the metatarsal bones, till it inosculates with the dorsal artery of the foot in the first interosseous space.

The course of the internal plantar corresponds with a line drawn from the inner side of the os calcis to the middle of the great toe.

153. **Plantar fascia.**—To divide the plantar fascia subcutaneously, the best place is about one inch in front of its attachment to the os calcis. This is the narrowest part of it. The knife should be introduced on the inner side; and the incision will be behind the plantar artery.

The subcutaneous section of the tendon of the abductor pollicis should be made about one inch before its insertion.

THE ARM.

154. **Clavicle.**—The line of the clavicle and the projection of the joint at either end of it can always be felt, even in the fattest persons. Its direction is not perfectly horizontal, but

slightly inclined downwards, when the arm hangs quietly by the side. When the body lies flat on the back, the shoulder not only falls back, but rises a little, the weight of the limb being taken off. Hence the modern and very good practice of treating fractures of the clavicle (in the early stage) by the supine position.

On the front surface of the clavicle, not far from its acromial end, there is in many persons of mature age a spine-like projection of bone. So far as I know, it has not been described. A gentleman, himself a surgeon, showed me an instance in his own person. He suspected it was an exostosis.

As a rule the acromio-clavicular joint forms an even plane. But there is sometimes a knob of bone at the acromial end of the clavicle; or it may be only a thickening of the fibro-cartilage, sometimes existing in the joint. In either case this relief might be mistaken for a dislocation, or even for a fracture. A reference to the other shoulder might settle the question.

155. **Bony points of the shoulder.**—We can distinctly feel the spine of the scapula and the acromion, more especially at the angle where they join behind the shoulder. This angle is the best place from which to measure in taking the comparative length of the arms.

In some shoulders, though very rarely, there is an abnormal symphysis between the spine of the scapula and the acromion. There may indeed be two symphyses and two acromial bones, the acromion having two centres of ossification. These abnormal symphyses might be mistaken for fractures, until we have examined the opposite shoulder, which is sure to present a similar conformation.¹⁰

Tuberosities.—Projecting beyond the acromion (the arm hanging by the side), we can feel, through the fibres of the deltoid, the upper part of the humerus. It distinctly moves under the hand when the arm is rotated. It is not the head of the bone which is felt, but the tuberosities, the greater externally, the lesser in front. These tuberosities form the convexity of the shoulder. When the arm is raised, this

convexity disappears ; there is a slight depression in its place. The head of the bone can be felt by pressing the fingers high up in the axilla.

The absence of this prominence formed by the upper part of the humerus under the deltoid, and the presence of a prominence low in the hollow of the axilla, or in front, below the coracoid process, or behind, on the back of the scapula, bespeak dislocation of the head of the bone.

In examining obscure injuries about the shoulder, it is worth remembering that, in the normal relation of the bones, and in every position, the great tuberosity faces in the direction of the external condyle. The head of the bone faces very much in the direction of the internal condyle.

It is worth remembering also that the upper epiphysis of the humerus includes the tuberosities ; and that it does not unite by bone to the shaft till about the twentieth year.

By making deep pressure in front of the shoulder, when the arm is pendent and supine, we can feel the bicipital groove. It looks directly forwards, and runs in a line drawn vertically downwards through the middle of the biceps to its tendon at the elbow. We should be aware of this, lest it be mistaken for a fracture.

156. **Coraco-acromial ligament.**—Under the anterior fibres of the deltoid, we can distinctly feel the position and extent of the coraco-acromial ligament. A knife, passed vertically through the middle of it, goes at once into the shoulder joint and strikes the bicipital groove with the tendon, a point to be remembered in excision.

In persons of an athletic build the triangular form and beautiful structure of the deltoid become conspicuous when the muscle is in action. The depression on the outer side of the arm, indicating its insertion, about the middle of the humerus, is the place selected for issues or setons.

The arm being held up by an assistant, the anterior and posterior borders of the relaxed deltoid admit of being raised so that in amputation at the shoulder the knife can be introduced beneath the muscle to make the flap.

157. **Axilla.**—The anterior border of the axilla, formed

by the pectoralis major, follows the line of the fifth rib. In counting the ribs, or in tapping the chest, it is worth remembering that the highest visible digitation of the serratus magnus is attached to the sixth rib. The angle of the digitation is directed forwards, and corresponds to the upper edge of the rib. The second visible digitation corresponds to the seventh rib; the interval between these digitations, therefore, corresponds to the sixth intercostal space—a convenient place for tapping the chest (52).

In the normal state no glands can be felt in the axilla.

158. **Axillary artery.**—When the arm is raised to a right angle with the body, and the head of the humerus thereby depressed, the axillary artery is plainly felt beating, and can be perfectly compressed on the inner side of the coraco-brachialis. This muscle stands out in relief along the humeral side of the axilla, and is the best guide to the artery. A line drawn along its inner border—that is, down the middle of the axilla—corresponds with the course of the artery.

The depth and form of the axilla alter in different positions of the arm. In the arm raised and abducted the axilla becomes nearly flat; hence this position is always adopted in operations.

In opening abscesses in the axilla, the incision should be made midway between the borders, and the point of the knife introduced from above downwards to avoid important vessels.

159. **Brachial artery.**—When the arm is extended and supinated, a line drawn from the deepest part of the middle of the axilla down the inner side of the biceps to the middle of the bend of the elbow, corresponds with the course of the brachial artery. The artery can be felt and compressed all the way down; but nowhere so effectually as midway, where it lies on the tendon of the coraco-brachialis close to the inner side of the humerus. To apply the pressure effectually it should be made outwards and a little backwards, else the artery will slip off the bone.

160. **Lines of median and ulnar nerves.**—The line of the median nerve in the arm corresponds with the line of the

brachial artery; except that half way down the nerve crosses the artery superficially from its outer to its inner side.

The ulnar nerve in the arm lies at first on the inner side of the brachial artery: but near the middle of the arm it leaves the artery and runs down behind the internal condyle of the humerus.

The musculo-spiral nerve and superior profunda artery wind round the back of the humerus about its middle, and come to the front of the external condyloid ridge. Thus, for full three inches above the condyles, there is not much to interfere with operations on the back of the bone, which is here broad and flat.

161. **Bend of elbow.**—At the end of the elbow, the tendon of the biceps can be plainly felt, as well as the pulsation of the brachial artery close to its inner side, before dividing into the radial and ulnar.

Cutaneous veins.—The bend of the elbow in young children, and in persons with fat and round arms, presents a semicircular fold of which the curve embraces the lower part of the biceps; but in muscular persons we see the distinct boundaries of the triangular space, formed by the pronator teres on the inner side, and the supinator longus on the outer. Here can be traced, standing out in strong relief under the thin white skin, the superficial veins, which, in days gone by, when bloodletting was the fashion, were of such great importance. Their arrangement, although subject to variety, is very much like the branches of the letter M, the middle of the M being at the middle of the elbow. Of these branches the median basilic, which runs over the tendon of the biceps, is the largest and most conspicuous, and is generally selected for venesection; it crosses the course of the brachial artery, nothing intervening but the semilunar aponeurosis from the tendon of the biceps.

162. **Landmarks of elbow.**—It is of great importance to be familiar with the relative positions of the various bony prominences about the elbow. We can always feel the internal and external condyles. The internal is the more prominent of the two, and a trifle higher.

Olecranon.—We can always feel the olecranon. This is somewhat nearer to the inner than to the outer condyle. Between the olecranon and the internal condyle is a deep depression in which lies the ulnar nerve (vulgarly called the 'funny bone').

163. **Head of radius.**—On the outer side of the olecranon, just below the external condyle, is a pit in the skin, constant even in fat persons (when the elbow is extended). This pit is considered one of the beauties of the elbow in a graceful arm; it is seen in a child as a pretty little dimple. To the surgeon it is most interesting, as in this valley behind the supinator longus and the radial extensors of the wrist he can distinctly feel the head of the radius rolling in pronation and supination of the forearm. It is, therefore, one of the most important landmarks of the elbow, since it enables us to say whether the head of the radius is in its right place, and whether it rotates with the shaft.

Can the tubercle of the radius be felt? Yes, but only on the back of the forearm in extreme pronation. Its projection is then distinctly perceptible just below the head of the bone.

164. **Relations of olecranon and condyles.**—To examine the relative positions of the olecranon and condyles in the different motions of the elbow joint, place the thumb on one condyle, the tip of the middle finger on the other, and the tip of the forefinger on the olecranon. In extension, the highest point of the olecranon is never above the line of the condyles; indeed, it is just in this line. With the elbow at right angles the point of the olecranon is vertically below the line of the condyles. In extreme flexion the point of the olecranon lies in front of the line of the condyles.

All these relative positions would be altered in a dislocation of the ulna, but not (necessarily) in a fracture of the lower end of the humerus.

Sometimes, though rarely, we meet with a hook-like projection of bone above the internal condyle. It is called a 'supra-condyloid' process; it can be felt through the skin, with its concavity downwards, and is a rudiment of the bony

canal which, in many mammalia, transmits the median nerve and ulnar artery. A third origin of the pronator teres is always attached to it ; this origin covers the brachial artery.¹¹

165. **Bursæ.**—The subcutaneous bursa over the olecranon, if distended, would be as large as a walnut. A second bursa sometimes exists a little lower down upon the ulna. There is also a small subcutaneous bursa over each of the condyles.

The vertical extent of the elbow joint is limited, above by a line drawn from one condyle to the other ; below, by a line corresponding to the lowest part of the head of the radius.

166. **Interosseous arteries.**—About one inch below the head of the radius, the ulnar artery gives off the common interosseous ; and this divides, about half an inch lower, into the anterior and posterior interosseous. Thus, in amputating the forearm, say two inches below the head of the radius, four arteries at least would require ligature.

By flexion of the elbow to the utmost, the circulation through the brachial artery can be arrested ; but the position is painful, and can be tolerated only for a short time.

167. **Lymphatic gland.**—There is a small lymphatic gland just above the inner condyle, in front of the intermuscular septum. It is the first to take alarm in poisoned wounds of the hand.

THE FOREARM AND WRIST.

168. **Ulna.**—The edge of the ulna can be felt subcutaneous from the olecranon to the styloid process (in supination). Any irregularity could be easily detected. The styloid process of the ulna does not descend so low as the styloid process of the radius, or it would impede the free abduction of the hand. Its apex is on a level with the radio-carpal joint. The head of the ulna is plainly felt and seen projecting at the back of the wrist, especially in pronation of the forearm. It then lies between the tendons of the extensor carpi ulnaris and extensor minimi digiti. There is often a subcutaneous bursa over it.

169. **Radius.**—The upper half of the shaft of the radius is so covered by muscles that we cannot feel it; the lower half is more accessible to the touch, especially just above and just below the part where it is crossed by the extensors of the thumb. Its styloid process is readily felt, and made all the more manifest by being covered by the first two extensor tendons of the thumb. It descends lower, and lies more to the front than the corresponding process of the ulna. The relative positions of these styloid processes can be best examined by placing the thumb on one and the forefinger on the other.

Feel for the little bony pulley on the back of the radius near the wrist, which keeps in place the third extensor tendon of the thumb. This and the bone just above it is the place which we examine for a suspected fracture (termed Colles's) near the lower end of the radius.

170. **Carpus.**—Below the styloid process of the radius, just on the inner side of the extensors of the thumb, we feel the tubercle of the scaphoid bone. Between the styloid process and the tubercle is the level of the radio-carpal joint. A little lower we feel the trapezium.

Just below the ulna on the palm of the hand we feel the pisiform bone; and on the inner side of this, the cuneiform.

There are several transverse furrows on the palmar aspect of the wrist. The lowest of these, which is slightly convex downwards, corresponds with the upper edge of the anterior annular ligament and the intercarpal joint. The line of the radio-carpal joint, as already stated, is on a level with the apex of the styloid process of the ulna.

In forcible flexion of the wrist, the tendon of the flexor carpi radialis and that of the palmaris longus come up in relief. On the outer side of the first-named tendon we feel the pulse, the radial artery here lying close to the radius.

The tendon of the palmaris longus runs near the middle of the wrist, and close to its inner border runs the median nerve. In letting out deep-seated matter near the wrist, the incision should be made close to and parallel with the inner

edge of the radial flexor tendon, so as to avoid injury to the median nerve.

We can feel the tendon of the flexor carpi ulnaris for some distance above the wrist. It overlies the ulnar artery, and somewhat masks its pulsation.

171. **Pulse.**—The 'pulse at the wrist' is felt just outside the tendon of the flexor carpi radialis. In feeling the pulse it should be remembered that, in some cases, the superficialis volæ arises higher and is larger than usual. In such cases it runs by the side of the radial artery, and gives additional volume to the pulse. The old writers call it 'pulsus duplex.' When in doubt, therefore, it is well to feel the pulse in each wrist.

172. **Great carpal bursa.**—The great synovial sheath under the annular ligament common to the flexor tendons of the fingers and the long flexor of the thumb, extends, upwards, about an inch and a half above the edge of the ligament, and, downwards, as low as the middle of the palm. This general synovial sheath communicates with the special sheaths of the thumb and the little finger; not with that of the index, middle, and ring fingers.

173. '**Tabatière anatomique.**'—On the outer side of the wrist we can distinctly see and feel, when in action, the three extensor tendons of the thumb. Between the second and third there is deep depression, at the root of the thumb, which the French humorously call the 'tabatière anatomique.' In this depression we can make out—1, the relief of the superficial radial vein; 2, the radial artery, in its passage to the back of the hand; 3, the upper end of the metacarpal bone of the thumb.

174. **Tendons on back of wrist.**—The relative positions of the several extensor tendons of the wrist and fingers, as they play in their grooves over the back of the radius and ulna, can all be distinctly traced when the several muscles are put in action. The length of their synovial sheaths should be remembered. They vary from one inch and a half to two inches and a half. The longest of all are those of the extensors of the thumb. When these sheaths are inflamed and swollen,

the motion of the tendons becomes painful and gives rise to a feeling of crepitus, called 'tenalgia crepitans' by some writers. It is said to be met with sometimes in pianists.

175. **Lines of arteries.**—The course of the radial artery corresponds with a line drawn from the outer border of the tendon of the biceps at the bend of the elbow down the front of the forearm to the front of the styloid process of the radius. In the upper third of its course the artery is overlapped by the supinator longus. To make allowance for this, the incision for the ligature of the artery in this situation should be made, not precisely in the line of its course, but rather nearer the middle of the forearm.

The line of the ulnar artery runs from the middle of the bend of the elbow (slightly curving inwards) to the outer side of the pisiform bone. To tie this vessel, therefore, in the upper third of its course, the proper way is to make the incision in the line from the internal condyle to the pisiform bone. The artery can be found by separating the flexor sublimis digitorum from the flexor carpi ulnaris.

The radial and ulnar arteries can, in most cases, be effectually commanded by pressure well applied at the wrist, in wounds of the palmar arch.

Before we make incisions along the forearm, it is always desirable to ascertain whether the ulnar artery, which usually runs under the superficial muscles, may not run abnormally over them; in which case its pulsations can be felt all down the forearm.

176. **Lines of median and ulnar nerves.**—The median nerve in the forearm corresponds with a line drawn from the inner side of the tendon of the biceps at the elbow to the inner side of the tendon of the palmaris longus at the wrist, where it is covered only by fascia.

The ulnar nerve in the forearm runs along a line drawn from the back of the internal condyle to the outer side of the pisiform bone. In the lower half of its course it joins the ulnar artery, and runs on the inner side of it over the anterior annular ligament.

THE HAND.

177. It is beside the purpose here to examine the question whether the hand can tell more than the arm, the leg, or any other part of the body, about the physical constitution of its owner, and to what use it has been put. Those who are interested in this subject should read a very elaborate treatise by Carus,¹² 'On the Reason and Meaning of the Different Forms of the Hand.' Still less would I indulge curiosity by inquiring whether the professors of chiromancy, relying on the text 'erit signum in manu tua et quasi monumentum ante oculos tuos,' can advance any reasonable pretensions for their assertion that they can read in the furrows of the palm the future destiny of its master.

178. **Furrow in palm.**—The only furrow in the palm useful as a surgical landmark is that which runs transversely across its lower third, and is well seen when the fingers are slightly bent. This transverse furrow corresponds pretty nearly with the metacarpal joints of the fingers, with the upper limit of the synovial sheaths of the flexor tendons of the fingers (that of the little finger excepted (172); also with the splitting of the palmar fascia into its four slips. The transverse metacarpal ligament lies in the same line with it. Again, a little below this furrow, the digital arteries bifurcate to run along the opposite sides of the fingers.

179. **Interdigital folds.**—By separating the fingers and pressing upon the interdigital folds of skin, we can feel the transverse ligament of the fingers, which prevents their too wide separation. The skin of these folds is much thinner on the dorsal than the palmar aspect; hence deep-seated abscesses in the palm very frequently burst on the back of the hand.

180. **Digital furrows.**—Concerning the transverse furrows on the palmar surface of the fingers, notice that the first furrows, close to the palm, do not correspond with the metacarpal joints. The second and third furrows do correspond with their respective joints.

The slight depression observable between the ball of the thumb and that of the little finger corresponds with the middle of the anterior annular ligament.

181. **Palmar arterial arches.**—In opening abscesses in the palm, it is important to bear in mind the position of the large arterial arches which lie beneath the palmar fascia. The line of the superficial palmar arch crosses the palm about the junction of the upper with the lower two-thirds—that is, in the line of the thumb separated widely from the fingers. From this, the digital arteries run straight between the shafts of the metacarpal bones towards the clefts of the fingers. Incisions, therefore, to let out pus beneath the palmar fascia may safely be made in the lower two-thirds of the palm, provided they run in the direction of the middle line of the fingers. The deep palmar arch lies half an inch nearer the wrist than the superficial.

182. **Digital arteries.**—As the digital arteries run along the sides of the fingers, the incision to open a thecal abscess should be made strictly in their middle line. It should be made not over but between the joints, since the sheath is strongest and thickest over the shafts of the phalanges, and therefore more likely to produce strangulation of the enclosed tendons.

183. **Metacarpal joint of thumb.**—The joint of the metacarpal bone of the thumb with the trapezium can be distinctly felt by tracing the dorsal surface of the bone upwards till we come to the prominence which indicates the joint at the bottom of the 'tabatière anatomique' (172). Supposing, however, there be much swelling, the knife introduced at the angle between the first and second metacarpal bones readily finds the joint if the blade be directed outwards.

184. **Sesamoid bones.**—The sesamoid bones of the thumb can be distinctly felt. Just above them—that is, nearer to the wrist—lies the joint between the metacarpal bone and the first phalanx. We should remember the position of these bones in amputation at this joint. *Mutatis mutandis* the same observations apply to the sesamoid bones of the great toe.

The extensor tendon of the last joint of the thumb crosses the apex of the first interosseous space. Under the tendon, and in the angle between the bones, we feel the radial artery just before it sinks into the palm.

185. **Subcutaneous veins.**—The veins on the back of the hand, and their arrangement in the form of arches which receive the digital veins, is sufficiently obvious. The number and arrangement of the arches may vary, but in all hands it is interesting to notice that the veins from the fingers run up between the knuckles and are out of harm's way.

186. **Interosseous arteries.**—Since the dorsal interosseous arteries, like the palmar, run along the interosseous spaces, incisions to let out pus should always be made over the backs of the metacarpal bones.

187. **Digital bursæ.**—Small subcutaneous bursæ are sometimes developed over the knuckles and the backs of the joints of the fingers. They often become enlarged and unseemly in persons of a rheumatic or gouty tendency.

188. **Knuckles and digital joints.**—The three rows of projections called 'the knuckles' are formed by the proximal bones of the several joints: thus the first row is formed by the ends of the metacarpals; the second by the ends of the first phalanges, and so forth. In amputations of the fingers it is well to remember that in all cases the line of the joints is a little in advance of the knuckles, that is, nearer the end of the fingers.

Long and graceful fingers, coupled with thickness and breadth of the sentient pulp at their ends, and too great arching of the nails, have been regarded, ever since the days of Hippocrates, as not unlikely indications of a tendency to pulmonary disease.

PALPATION BY THE RECTUM.

The following report is from Mr. Walsham, of St. Bartholomew's Hospital, who, having a small hand (somewhat less than seven and a half inches round), has had oppor-

tunities of introducing it up the rectum, in the living subject, for the purpose of diagnosis :—

‘ It is possible to introduce the hand (if small) into the rectum ; in many cases into the sigmoid flexure, and in rare instances into the descending colon.

‘ Once beyond the sphincter, the hand enters a capacious sac, and the following important parts can be felt through its walls :—

‘ Through the anterior wall the hand first recognises the prostate, which feels like a moderately large chestnut. Immediately behind the prostate, the vesiculæ seminales may be distinguished as two softish masses situated one on either side of the middle line. Internal to them, the whipcord-like feel of the vasa deferentia can be readily traced over the bladder to the sides of the pelvis.

‘ The bladder is easily recognised, when moderately distended, as a soft fluctuating tumour behind the prostate ; when empty it cannot be distinguished from the intestines, which then descend between the rectum and the pubes. The arch of the pubes can well be defined when the bladder is empty.

‘ Through the posterior wall of the bowel the coccyx and sacrum can be felt, the curve of the sacrum being readily followed by the hand.

‘ The projecting spine of the ischium on each side of the pelvis is a valuable landmark. From this point the outlines of the greater and lesser sacro-ischiatic foramina can be traced by the fingers ; and any new growth, encroaching on the pelvic cavity through these apertures, could be easily detected.

‘ If the hand be now pushed farther up the gut, the promontory of the sacrum is reached ; the pulsation of the iliac vessels becomes manifest, and the course of the external iliac can be traced along the brim of the pelvis to the crural arch, the loose attachments of the rectum permitting very free movement in this direction. The internal iliac artery can also be followed to the upper part of the great sacro-ischiatic foramen.

‘By semi-rotatory movement, and alternately flexing and extending the fingers, the hand can gradually be insinuated into the commencement of the sigmoid flexure. In the sigmoid flexure the fingers can explore the whole of the lower part of the abdomen, the loose attachment of this portion of the gut permitting the hand to travel freely over the iliac and hypogastric regions.

‘The parts that can here be felt are the bifurcation of the aorta, the division of the common iliac arteries, the iliac fossa, and the crest of the ilium.

‘In the female, the uterus in the middle line, and the ovaries on either side, can be readily distinguished.

‘In the introduction of the hand into the rectum, in a patient under chloroform, the dilatation of the sphincter ani should be very gradual: first two fingers, then four, and finally the thumb should be passed. It is necessary to use considerable force, and unless care be taken, not only the integumentary edge of the anus, but the sphincter itself, may be lacerated. The introduction is facilitated by the application of the other hand upon the abdomen.

‘When the dilatation has been gradual and the hand not too large, no incontinence of fæces and no very considerable amount of pain has resulted.’¹³

We have been informed on reliable authority that permanent incontinence of fæces has occasionally followed these examinations.

Lastly, we think it right to insist upon the important fact that, in some subjects, even a small hand cannot be passed up the rectum beyond the reflection of the peritoneum over the second part of the gut. In such instances the peritoneum offers a resistance like a tight garter, and prevents the farther advance of the hand without great risk of laceration of the parts.

EXAMINATION PER VAGINAM.

For this report I am indebted to Dr. Godson, of St. Bartholomew’s Hospital:—

‘The finger introduced into the vagina comes upon the

carunculæ myrtiformes, which are vascular membranous processes independent of the hymen, variable in number, size, and form. It also feels the transverse ridges known as "rugæ."

' Along the anterior wall of the vagina the finger readily detects the track of the urethra, which feels like a prominent cord and forms an excellent guide to the orifice of the meatus urinarius in passing a catheter. The orifice is indicated by a slight semicircular prominence, situated about one-third of an inch above the orifice of the vagina. Behind the urethra the finger comes upon the posterior wall of the bladder. But the bladder is not perceptible, as such, to the touch unless distended. With a catheter previously introduced it is much more readily explored.

' The septum between the vagina and the rectum is so thin that, should the rectum contain fæcal matter, its presence becomes at once apparent to the finger.

' The cervix uteri is felt protruding from the roof of the vagina in a direction downwards and backwards—that is, in a line from the umbilicus to the coccyx. The os uteri is felt, small and round, in the centre of the cervix. The posterior lip feels a little lower than the anterior. The cul-de-sac formed by the vagina in front and behind the cervix should be perfectly elastic to the touch, and not communicate the sensation of a resisting body. Any resistance here bespeaks an abnormal condition.

' The bony landmarks within reach of a finger, or perhaps two, in a woman who has not borne a child, are the symphysis pubis, the rami of the pubes and ischia. The coccyx and part of the hollow of the sacrum may also be felt, but not without exerting much pressure on the posterior wall of the vagina, which gives considerable pain. If the promontory of the sacrum can be felt, it is a sign that the conjugate diameter of the pelvis is abnormal.

' The finger in the rectum can detect almost everything which has been mentioned in connection with the vagina. The shape and direction of the cervix uteri are almost as perceptible, and the posterior wall of the uterus can be ex-

mined. The peritoneal fold termed recto-vaginal (Douglas's pouch) can also be well explored, and anything abnormal detected in this direction—a point of great importance in the diagnosis of diseases and displacements of the uterus.

'The ovary in its normal state and position cannot be detected by the touch even with the hand firmly pressed on the hypogastrium. If a moveable body be felt through the vaginal roof on one side of the cervix, if this body be exquisitely tender and recede at once from the finger, it is an ovary in a state of prolapse.

'The fundus of an healthy unimpregnated uterus never rises above the level of the brim of the pelvis, and cannot therefore be felt by pressing the hand on the hypogastrium.

'The direction of the uterus is subject to changes which cannot be looked upon as abnormal. The fundus may be thrown backwards by a distended bladder, or forwards by a distended rectum. The axis of its cavity is not a straight but a curved line; and uterine sounds should be shaped to suit it.'

NOTES.

¹ Some pertinent remarks on this subject have been made by Mr. C. Heath in a pamphlet 'On Anatomy in relation to Physic.'

² In several adult normal skeletons measured in the Hunterian Museum, the average diameters of the upper opening of the chest were—antero-posterior, about $2\frac{1}{4}$ inches; transverse, about $4\frac{1}{2}$ inches. In the skeleton of O'Brien, the Irish giant, the antero-posterior diameter measures 4 inches, the transverse $6\frac{1}{4}$.

³ Special experiments with reference to this point were made many years ago by the late Professor Quekett and Mr. Guthrie in the work-rooms of the College of Surgeons.

⁴ See a beautiful illustration of this in Sir C. Bell's 'Anatomy of Expression,' p. 160.

⁵ See some good observations on the position of the enlarged spleen, by Sir W. Jenner, 'Brit. Med. Journ.,' Jan. 16, 1869.

⁶ 'Lectures on Rest and Pain,' by John Hilton, F.R.S., London, 1863, p. 280.

⁷ These folds of mucous membrane in the rectum were first pointed out by Mr. Houston, 'Dublin Hospital Reports,' vol. v. p. 163.

⁸ Nélaton, 'Pathologie chirurgicale,' t. iv. p. 441. 1848.

⁹ Bigelow, 'Mechanism of Dislocation and Fracture of the Hip.' Philadelphia, 1869.

¹⁰ See Pruge on 'Ossa Acromialia' ('Zeitschrift für rationelle Medizin'), 3. Reihe, Bd. vii. 1859.

¹¹ See on this subject a monograph, 'Canalis Supra-condyloideus Humeri.' By W. Grüber. Petersburg, 1856.

¹² 'Ueber Grund und Bedeutung der verschiedenen Formen der Hand.' Stuttgart, 1846.

¹³ For further information on this subject, see a paper by Mr. Walsham, in St. Bartholomew's Hospital Reports, vol. xii.



Catalogue B]

London, 11, New Burlington Street
May, 1888

SELECTION

FROM

J. & A. CHURCHILL'S GENERAL CATALOGUE

COMPRISING

ALL RECENT WORKS PUBLISHED BY THEM

ON THE

ART AND SCIENCE OF MEDICINE



N.B.—As far as possible, this List is arranged in the order in
which medical study is usually pursued.

J. & A. CHURCHILL publish for the following Institutions
and Public Bodies:—

ROYAL COLLEGE OF SURGEONS.

CATALOGUES OF THE MUSEUM.

Twenty-three separate Catalogues (List and Prices can be obtained of J. & A. CHURCHILL).

GUY'S HOSPITAL.

REPORTS BY THE MEDICAL AND SURGICAL STAFF.

Vol. XXIX., Third Series. 7s. 6d.

FORMULÆ USED IN THE HOSPITAL IN ADDITION TO THOSE
IN THE B.P. 1s. 6d.

LONDON HOSPITAL.

PHARMACOPŒIA OF THE HOSPITAL. 3s.

CLINICAL LECTURES AND REPORTS BY THE MEDICAL AND
SURGICAL STAFF. Vols. I. to IV. 7s. 6d. each.

ST. BARTHOLOMEW'S HOSPITAL.

CATALOGUE OF THE ANATOMICAL AND PATHOLOGICAL
MUSEUM. Vol. I.—Pathology. 15s. Vol. II.—Teratology, Anatomy
and Physiology, Botany. 7s. 6d.

ST. GEORGE'S HOSPITAL.

REPORTS BY THE MEDICAL AND SURGICAL STAFF.

The last Volume (X.) was issued in 1880. Price 7s. 6d.

CATALOGUE OF THE PATHOLOGICAL MUSEUM. 15s.

SUPPLEMENTARY CATALOGUE (1882). 5s.

ST. THOMAS'S HOSPITAL.

REPORTS BY THE MEDICAL AND SURGICAL STAFF

Annually. Vol. XVI., New Series. 7s. 6d.

MIDDLESEX HOSPITAL.

CATALOGUE OF THE PATHOLOGICAL MUSEUM. 12s.

WESTMINSTER HOSPITAL.

REPORTS BY THE MEDICAL AND SURGICAL STAFF.

Annually. Vol. III. 6s.

ROYAL LONDON OPHTHALMIC HOSPITAL.

REPORTS BY THE MEDICAL AND SURGICAL STAFF.

Occasionally. Vol. XII., Part I. 5s.

OPHTHALMOLOGICAL SOCIETY OF THE UNITED KINGDOM.

TRANSACTIONS.

Vol. VII. 12s. 6d.

MEDICO-PSYCHOLOGICAL ASSOCIATION.

JOURNAL OF MENTAL SCIENCE.

Quarterly. 3s. 6d. each, or 14s. per annum.

PHARMACEUTICAL SOCIETY OF GREAT BRITAIN.

PHARMACEUTICAL JOURNAL AND TRANSACTIONS.

Every Saturday. 4d. each, or 20s. per annum, post free.

BRITISH PHARMACEUTICAL CONFERENCE.

YEAR BOOK OF PHARMACY.

In December. 10s.

BRITISH DENTAL ASSOCIATION.

JOURNAL OF THE ASSOCIATION AND MONTHLY REVIEW
OF DENTAL SURGERY.

On the 15th of each Month. 6d. each, or 7s. per annum, post free.

A SELECTION

FROM

J. & A. CHURCHILL'S GENERAL CATALOGUE,

COMPRISING

ALL RECENT WORKS PUBLISHED BY THEM ON THE
ART AND SCIENCE OF MEDICINE.

N.B.—*J. & A. Churchill's Descriptive List of Works on Chemistry, Materia Medica, Pharmacy, Botany, Photography, Zoology, the Microscope, and other Branches of Science, can be had on application.*

Practical Anatomy :

A Manual of Dissections. By CHRISTOPHER HEATH, Surgeon to University College Hospital. Seventh Edition. Revised by RICKMAN J. GODLEE, M.S. Lond., F.R.C.S., Teacher of Operative Surgery, late Demonstrator of Anatomy in University College, and Surgeon to the Hospital. Crown 8vo, with 24 Coloured Plates and 278 Engravings, 15s.

Wilson's Anatomist's Vademecum. Tenth Edition. By GEORGE BUCHANAN, Professor of Clinical Surgery in the University of Glasgow; and HENRY E. CLARK, M.R.C.S., Lecturer on Anatomy at the Glasgow Royal Infirmary School of Medicine. Crown 8vo, with 450 Engravings (including 26 Coloured Plates), 18s.

Braune's Atlas of Topographical Anatomy, after Plane Sections of Frozen Bodies. Translated by EDWARD BELLAMY, Surgeon to, and Lecturer on Anatomy, &c., at, Charing Cross Hospital. Large Imp. 8vo, with 34 Photolithographic Plates and 46 Woodcuts, 40s.

An Atlas of Human Anatomy. By RICKMAN J. GODLEE, M.S., F.R.C.S., Assistant Surgeon and Senior Demonstrator of Anatomy, University College Hospital. With 48 Imp. 4to Plates (112 figures), and a volume of Explanatory Text. 8vo, £4 14s. 6d.

Harvey's (Wm.) Manuscript Lectures. *Prelectiones Anatomiae Universalis.* Edited, with an Autotype reproduction of the Original, by a Committee of the Royal College of Physicians of London. Crown 4to, half bound in Persian, 52s. 6d.

Anatomy of the Joints of Man.

By HENRY MORRIS, Surgeon to, and Lecturer on Anatomy and Practical Surgery at, the Middlesex Hospital. 8vo, with 44 Lithographic Plates (several being coloured) and 13 Wood Engravings, 16s.

Manual of the Dissection of the Human Body. By LUTHER HOLDEN, Consulting Surgeon to St. Bartholomew's Hospital. Edited by JOHN LANGTON, F.R.C.S., Surgeon to, and Lecturer on Anatomy at, St. Bartholomew's Hospital. Fifth Edition. 8vo, with 208 Engravings. 20s.

By the same Author.

Human Osteology.

Seventh Edition, edited by CHARLES STEWART, Conservator of the Museum R.C.S., and R.W. REID, M.D., F.R.C.S., Lecturer on Anatomy at St. Thomas's Hospital. 8vo, with 59 Lithographic Plates and 75 Engravings. 16s.

Also.

Landmarks, Medical and Surgical. Fourth Edition. 8vo. [*In the Press.*]

The Student's Guide to Surgical Anatomy. By EDWARD BELLAMY, F.R.C.S. and Member of the Board of Examiners. Third Edition. Fcap. 8vo, with 81 Engravings. 7s. 6d.

The Anatomical Remembrancer; or, Complete Pocket Anatomist. Eighth Edition. 32mo, 3s. 6d.

Diagrams of the Nerves of the Human Body, exhibiting their Origin, Divisions, and Connections, with their Distribution to the Various Regions of the Cutaneous Surface, and to all the Muscles. By W. H. FLOWER, C.B., F.R.S., F.R.C.S. Third Edition, with 6 Plates. Royal 4to, 12s.

General Pathology.

An Introduction to. By JOHN BLAND SUTTON, F.R.C.S., Sir E. Wilson Lecturer on Pathology, R.C.S.; Assistant Surgeon to, and Lecturer on Anatomy at, Middlesex Hospital. 8vo, with 149 Engravings, 14s.

Atlas of Pathological Anatomy.

By Dr. LANCEREAUX. Translated by W. S. GREENFIELD, M.D., Professor of Pathology in the University of Edinburgh. Imp. 8vo, with 70 Coloured Plates, £5 5s.

A Manual of Pathological Anatomy.

By C. HANDFIELD JONES, M.B., F.R.S., and E. H. SIEVEKING, M.D., F.R.C.P. Edited by J. F. PAYNE, M.D., F.R.C.P., Lecturer on General Pathology at St. Thomas's Hospital. Second Edition. Crown 8vo, with 195 Engravings, 16s.

Post-mortem Examinations :

A Description and Explanation of the Method of Performing them, with especial reference to Medico-Legal Practice. By Prof. VIRCHOW. Translated by Dr. T. P. SMITH. Second Edition. Fcap. 8vo, with 4 Plates, 3s. 6d.

The Human Brain :

Histological and Coarse Methods of Research. A Manual for Students and Asylum Medical Officers. By W. BEVAN LEWIS, L.R.C.P. Lond., Medical Superintendent, West Riding Lunatic Asylum. 8vo, with Wood Engravings and Photographs, 8s.

Manual of Physiology :

For the use of Junior Students of Medicine. By GERALD F. YEO, M.D., F.R.C.S., Professor of Physiology in King's College, London. Second Edition. Crown 8vo, with 318 Engravings, 14s.

Principles of Human Physiology.

By W. B. CARPENTER, C.B., M.D., F.R.S. Ninth Edition. By HENRY POWER, M.B., F.R.C.S. 8vo, with 3 Steel Plates and 377 Wood Engravings, 31s. 6d.

Elementary Practical Biology :

Vegetable. By THOMAS W. SHORE, M.D., B.Sc. Lond., Lecturer on Comparative Anatomy at St. Bartholomew's Hospital. 8vo, 6s.

Histology and Histo-Chemistry

of Man. By HEINRICH FREY, Professor of Medicine in Zurich. Translated by ARTHUR E. J. BARKER, Assistant Surgeon to University College Hospital. 8vo, with 608 Engravings, 21s.

A Text-Book of Medical Physics,

for Students and Practitioners. By J. C. DRAPER, M.D., LL.D., Professor of Physics in the University of New York. With 377 Engravings. 8vo, 18s.

Medical Jurisprudence :

Its Principles and Practice. By ALFRED S. TAYLOR, M.D., F.R.C.P., F.R.S. Third Edition, by THOMAS STEVENSON, M.D., F.R.C.P., Lecturer on Medical Jurisprudence at Guy's Hospital. 2 vols. 8vo, with 188 Engravings, 31s. 6d.

By the same Authors.

A Manual of Medical Jurisprudence. Eleventh Edition. Crown 8vo, with 56 Engravings, 14s.

Also.

Poisons,

In Relation to Medical Jurisprudence and Medicine. Third Edition. Crown 8vo, with 104 Engravings, 16s.

Lectures on Medical Jurisprudence. By FRANCIS OGSTON, M.D., late Professor in the University of Aberdeen. Edited by FRANCIS OGSTON, Jun., M.D. 8vo, with 12 Copper Plates, 18s.**The Student's Guide to Medical Jurisprudence.** By JOHN ABERCROMBIE, M.D., F.R.C.P., Lecturer on Forensic Medicine to Charing Cross Hospital. Fcap. 8vo, 7s. 6d.**Influence of Sex in Disease.**

By W. ROGER WILLIAMS, F.R.C.S., Surgical Registrar to the Middlesex Hospital. 8vo, 3s. 6d.

Microscopical Examination of Drinking Water and of Air. By J. D. MACDONALD, M.D., F.R.S., Ex-Professor of Naval Hygiene in the Army Medical School. Second Edition. 8vo, with 25 Plates, 7s. 6d.**Pay Hospitals and Paying Wards throughout the World.** By HENRY C. BURDETT. 8vo, 7s.

By the same Author.

Cottage Hospitals — General, Fever, and Convalescent: Their Progress, Management, and Work. Second Edition, with many Plans and Illustrations. Crown 8vo, 14s.**Hospitals, Infirmarys, and Dispensaries: Their Construction, Interior Arrangement, and Management; with Descriptions of existing Institutions, and 74 Illustrations.** By F. OPPERT, M.D., M.R.C.P.L. Second Edition. Royal 8vo, 12s.**Hospital Construction and Management.** By F. J. MOUAT, M.D., Local Government Board Inspector, and H. SAXON SNELL, Fell. Roy. Inst. Brit. Architects. In 2 Parts, 4to, 15s. each; or, the whole work bound in half calf, with large Map, 54 Lithographic Plates, and 27 Woodcuts, 35s.**Public Health Reports.**

By Sir JOHN SIMON, C.B., F.R.S. Edited by EDWARD SEATON, M.D., F.R.C.P. 2 vols. 8vo, with Portrait, 36s.

A Manual of Practical Hygiene.

By E. A. PARKES, M.D., F.R.S. Seventh Edition, by F. DE CHAUMONT, M.D., F.R.S., Professor of Military Hygiene in the Army Medical School. 8vo, with 9 Plates and 101 Engravings, 18s.

A Handbook of Hygiene and Sanitary Science.

By GEO. WILSON, M.A., M.D., F.R.S.E., Medical Officer of Health for Mid-Warwickshire. Sixth Edition. Crown 8vo, with Engravings. 10s. 6d.

By the same Author.

Healthy Life and Healthy Dwellings:

A Guide to Personal and Domestic Hygiene. Fcap. 8vo, 5s.

Sanitary Examinations

Of Water, Air, and Food. A Vademecum for the Medical Officer of Health. By CORNELIUS B. FOX, M.D., F.R.C.P. Second Edition. Crown 8vo, with 110 Engravings, 12s. 6d.

Dangers to Health:

A Pictorial Guide to Domestic Sanitary Defects. By T. PRIDGIN TEALE, M.A., Surgeon to the Leeds General Infirmary. Fourth Edition. 8vo, with 70 Lithograph Plates (mostly coloured), 10s.

Epidemic Influences:

Epidemiological Aspects of Yellow Fever and of Cholera. The Milroy Lectures. By ROBERT LAWSON, LL.D., Inspector-General of Hospitals. 8vo, with Maps, Diagrams, &c., 6s.

Detection of Colour-Blindness and Imperfect Eyesight.

By CHARLES ROBERTS, F.R.C.S. Second Edition. 8vo, with a Table of Coloured Wools, and Sheet of Test-types, 5s.

Illustrations of the Influence of the Mind upon the Body in Health and Disease:

Designed to elucidate the Action of the Imagination. By D. H. TUKE, M.D., F.R.C.P., LL.D. Second Edition. 2 vols. crown 8vo, 15s.

By the same Author.

Sleep-Walking and Hypnotism.

8vo, 5s.

A Manual of Psychological Medicine.

With an Appendix of Cases. By JOHN C. BUCKNILL, M.D., F.R.S., and D. HACK TUKE, M.D., F.R.C.P. Fourth Edition. 8vo, with 12 Plates (30 Figures) and Engravings, 25s.

Mental Affections of Childhood and Youth

(Lettsomian Lectures for 1887, &c.). By J. LANGDON DOWN, M.D., F.R.C.P., Senior Physician to the London Hospital. 8vo, 6s.

Mental Diseases.

Clinical Lectures. By T. S. CLOUSTON, M.D., F.R.C.P. Edin., Lecturer on Mental Diseases in the University of Edinburgh. Second Edition. Crown 8vo, with 8 Plates (6 Coloured), 12s. 6d.

Private Treatment of the Insane as Single Patients.

By EDWARD EAST, M.R.C.S., L.S.A. Crown 8vo, 2s. 6d.

Manual of Midwifery.

By ALFRED L. GALABIN, M.A., M.D., F.R.C.P., Obstetric Physician to, and Lecturer on Midwifery, &c. at, Guy's Hospital. Crown 8vo, with 227 Engravings, 15s.

The Student's Guide to the Practice of Midwifery.

By D. LLOYD ROBERTS, M.D., F.R.C.P., Lecturer on Clinical Midwifery and Diseases of Women at the Owens College; Obstetric Physician to the Manchester Royal Infirmary. Third Edition. Fcap. 8vo, with 2 Coloured Plates and 127 Wood Engravings, 7s. 6d.

Lectures on Obstetric Operations:

Including the Treatment of Hæmorrhage, and forming a Guide to the Management of Difficult Labour. By ROBERT BARNES, M.D., F.R.C.P., Consulting Obstetric Physician to St. George's Hospital. Fourth Edition. 8vo, with 121 Engravings, 12s. 6d.

By the same Author.

A Clinical History of Medical and Surgical Diseases of Women.

Second Edition. 8vo, with 181 Engravings, 28s.

Clinical Lectures on Diseases of Women:

Delivered in St. Bartholomew's Hospital, by J. MATTHEWS DUNCAN, M.D., LL.D., F.R.S. Third Edition. 8vo, 16s.

By the same Author.

Sterility in Woman.

Being the Gulstonian Lectures, delivered in the Royal College of Physicians, in Feb., 1883. 8vo, 6s.

Notes on Diseases of Women:

Specially designed to assist the Student in preparing for Examination. By J. J. REYNOLDS, L.R.C.P., M.R.C.S. Third Edition. Fcap. 8vo, 2s. 6d.

By the same Author.

Notes on Midwifery:

Specially designed for Students preparing for Examination. Second Edition. Fcap. 8vo, with 15 Engravings, 4s.

A Manual of Obstetrics.

By A. F. A. KING, A.M., M.D., Professor of Obstetrics, &c., in the Columbian University, Washington, and the University of Vermont. Third Edition. Crown 8vo, with 102 Engravings, 8s.

Intra-Uterine Death:

(Pathology of). Being the Lumleian Lectures, 1887. By WILLIAM O. PRIESTLEY, M.D., F.R.C.P., LL.D., Consulting Physician to King's College Hospital. 8vo, with 3 Coloured Plates and 17 Engravings, 7s. 6d.

The Student's Guide to the

Diseases of Women. By ALFRED L. GALABIN, M.D., F.R.C.P., Obstetric Physician to Guy's Hospital. Fourth Edition. Fcap. 8vo, with 94 Engravings, 7s. 6d.

West on the Diseases of Women.

Fourth Edition, revised by the Author, with numerous Additions by J. MATTHEWS DUNCAN, M.D., F.R.C.P., F.R.S.E., Obstetric Physician to St. Bartholomew's Hospital. 8vo, 16s.

Obstetric Aphorisms :

For the Use of Students commencing Midwifery Practice. By JOSEPH G. SWAYNE, M.D. Eighth Edition. Fcap. 8vo, with Engravings, 3s. 6d.

Handbook of Midwifery for Mid-

wives : By J. E. BURTON, L.R.C.P. Lond., Surgeon to the Hospital for Women, Liverpool. Second Edition. With Engravings. Fcap. 8vo, 6s.

A Handbook of Uterine Thera-

peutics, and of Diseases of Women. By E. J. TILT, M.D., M.R.C.P. Fourth Edition. Post 8vo, 10s.

By the same Author.

The Change of Life

In Health and Disease: A Clinical Treatise on the Diseases of the Nervous System incidental to Women at the Decline of Life. Fourth Edition. 8vo, 10s. 6d.

Diseases of the Uterus, Ovaries, and Fallopian Tubes :

A Practical Treatise by A. COURTY, Professor of Clinical Surgery, Montpellier. Translated from Third Edition by his Pupil, AGNES McLAREN, M.D., M.K.Q.C.P.I., with Preface by J. MATTHEWS DUNCAN, M.D., F.R.C.P. 8vo, with 424 Engravings, 24s.

The Female Pelvic Organs :

Their Surgery, Surgical Pathology, and Surgical Anatomy. In a Series of Coloured Plates taken from Nature; with Commentaries, Notes, and Cases. By HENRY SAVAGE, M.D., F.R.C.S., Consulting Officer of the Samaritan Free Hospital. Fifth Edition. Roy. 4to, with 17 Lithographic Plates (15 coloured) and 52 Woodcuts, £1 15s.

A Practical Treatise on the

Diseases of Women. By T. GAILLARD THOMAS, M.D., Professor of Diseases of Women in the College of Physicians and Surgeons, New York. Fifth Edition. Roy. 8vo, with 266 Engravings, 25s.

Backward Displacements of the

Uterus and Prolapsus Uteri : Treatment by the New Method of Shortening the Round Ligaments. By WILLIAM ALEXANDER, M.D., M.Ch.Q.U.I., F.R.C.S., Surgeon to the Liverpool Infirmary. Crown 8vo, with Engravings, 3s. 6d.

Diseases and Accidents

Incident to Women, and the Practice of Medicine and Surgery applied to them. By W. H. BYFORD, A.M., M.D., Professor of Gynæcology in Rush Medical College, and HENRY T. BYFORD, M.D., Surgeon to the Woman's Hospital, Chicago. Fourth Edition. 8vo, with 306 Engravings, 25s.

Gynæcological Operations :

(Handbook of). By ALBAN H. G. DORAN, F.R.C.S., Surgeon to the Samaritan Hospital. 8vo, with 167 Engravings, 15s.

Abdominal Surgery.

By J. GREIG SMITH, M.A., F.R.S.E., Surgeon to the Bristol Royal Infirmary. Second Edition. 8vo, with 79 Engravings, 21s.

Ovarian and Uterine Tumours :

Their Pathology and Surgical Treatment. By Sir T. SPENCER WELLS, Bart., F.R.C.S., Consulting Surgeon to the Samaritan Hospital. 8vo, with Engravings, 21s.

The Student's Guide to Diseases

of Children. By JAS. F. GOODHART, M.D., F.R.C.P., Physician to Guy's Hospital, and to the Evelina Hospital for Sick Children. Second Edition. Fcap. 8vo, 10s. 6d.

Diseases of Children.

For Practitioners and Students. By W. H. DAY, M.D., Physician to the Samaritan Hospital. Second Edition. Crown 8vo, 12s. 6d.

A Practical Treatise on Disease

in Children. By EUSTACE SMITH, M.D., Physician to the King of the Belgians, Physician to the East London Hospital for Children. 8vo, 22s.

By the same Author.

Clinical Studies of Disease in

Children. Second Edition. Post 8vo, 7s. 6d. *Also.*

The Wasting Diseases of Infants

and Children. Fifth Edition. Post 8vo, 8s. 6d.

A Practical Manual of the

Diseases of Children. With a Formulary. By EDWARD ELLIS, M.D. Fifth Edition. Crown 8vo, 10s.

A Manual for Hospital Nurses

and others engaged in Attending on the Sick, and a Glossary. By EDWARD J. DOMVILLE, Surgeon to the Exeter Lying-in Charity. Sixth Edition. Cr. 8vo, 2s. 6d.

A Manual of Nursing, Medical

and Surgical. By CHARLES J. CULLINGWORTH, M.D., Obstetric Physician to St. Thomas's Hospital. Second Edition. Fcap. 8vo, with Engravings, 3s. 6d.

By the same Author.

A Short Manual for Monthly

Nurses. Second Edition. Fcap. 8vo, 1s. 6d.

Diseases and their Commencement. Lectures to Trained Nurses. By DONALD W. C. HOOD, M.D., M.R.C.P., Physician to the West London Hospital. Crown 8vo, 2s. 6d.

Outlines of Infectious Diseases: For the use of Clinical Students. By J. W. ALLAN, M.B., Physician Superintendent Glasgow Fever Hospital. Fcap. 8vo., 3s.

Hospital Sisters and their Duties. By EVA C. E. LÜCKES, Matron to the London Hospital. Crown 8vo, 2s. 6d.

Infant Feeding and its Influence on Life; By C. H. F. ROUTH, M.D., Physician to the Samaritan Hospital. Fourth Edition. Fcap. 8vo. [*Preparing.*]

Manual of Botany:

Including the Structure, Classification, Properties, Uses, and Functions of Plants. By ROBERT BENTLEY, Professor of Botany in King's College and to the Pharmaceutical Society. Fifth Edition. Crown 8vo, with 1,178 Engravings, 15s.

By the same Author.

The Student's Guide to Structural, Morphological, and Physiological Botany. With 660 Engravings. Fcap. 8vo, 7s. 6d.

Also.

The Student's Guide to Systematic Botany, including the Classification of Plants and Descriptive Botany. Fcap. 8vo, with 350 Engravings, 3s. 6d.

Medicinal Plants:

Being descriptions, with original figures, of the Principal Plants employed in Medicine, and an account of their Properties and Uses. By Prof. BENTLEY and Dr. H. TRIMEN. In 4 vols., large 8vo, with 306 Coloured Plates, bound in Half Morocco, Gilt Edges, £11 11s.

The National Dispensatory:

Containing the Natural History, Chemistry, Pharmacy, Actions and Uses of Medicines. By ALFRED STILLÉ, M.D., LL.D., and JOHN M. MAISCH, Ph.D. Fourth Edition. 8vo, with 311 Engravings, 36s.

Royle's Manual of Materia Medica and Therapeutics. Sixth Edition, including additions and alterations in the B.P. 1885. By JOHN HARLEY, M.D., Physician to St. Thomas's Hospital. Crown 8vo, with 139 Engravings, 15s.

Materia Medica and Therapeutics: Vegetable Kingdom — Organic Compounds — Animal Kingdom. By CHARLES D. F. PHILLIPS, M.D., F.R.S. Edin., late Lecturer on Materia Medica and Therapeutics at the Westminster Hospital Medical School. 8vo, 25s.

The Student's Guide to Materia Medica and Therapeutics. By JOHN C. THOROWGOOD, M.D., F.R.C.P. Second Edition. Fcap. 8vo, 7s.

Materia Medica.

A Manual for the use of Students. By ISAMBARD OWEN, M.D., F.R.C.P., Lecturer on Materia Medica, &c., to St. George's Hospital. Second Edition. Crown 8vo, 6s. 6d.

The Pharmacopœia of the London Hospital. Compiled under the direction of a Committee appointed by the Hospital Medical Council. Fcap. 8vo, 3s.

A Companion to the British Pharmacopœia. By PETER SQUIRE, Revised by his Sons, P. W. and A. H. SQUIRE. 14th Edition. 8vo, 10s. 6d.

By the same Authors.

The Pharmacopœias of the London Hospitals, arranged in Groups for Easy Reference and Comparison. Fifth Edition. 18mo, 6s.

The Prescriber's Pharmacopœia:

The Medicines arranged in Classes according to their Action, with their Composition and Doses. By NESTOR J. C. TIRARD, M.D., F.R.C.P., Professor of Materia Medica and Therapeutics in King's College, London. Sixth Edition. 32mo, bound in leather, 3s.

A Treatise on the Principles and Practice of Medicine. Sixth Edition. By AUSTIN FLINT, M.D., W. H. WELCH, M.D., and AUSTIN FLINT, jun., M.D. 8vo, with Engravings, 26s.

Climate and Fevers of India, with a series of Cases (Croonian Lectures, 1882). By Sir JOSEPH FAYRER, K.C.S.I., M.D. 8vo, with 17 Temperature Charts, 12s.

Family Medicine for India.

A Manual. By WILLIAM J. MOORE, M.D., C.I.E., Honorary Surgeon to the Viceroy of India. Published under the Authority of the Government of India. Fifth Edition. Post 8vo, with Engravings. [*In the Press.*]

By the same Author.

A Manual of the Diseases of India: With a Compendium of Diseases generally. Second Edition. Post 8vo, 10s.

Practical Therapeutics:

A Manual. By EDWARD J. WARING, C.I.E., M.D., F.R.C.P., and DUDLEY W. BUXTON, M.D., B.S. Lond. Fourth Edition. Crown 8vo, 14s.

By the same Author.

Bazaar Medicines of India,

And Common Medical Plants: With Full Index of Diseases, indicating their Treatment by these and other Agents procurable throughout India, &c. Fourth Edition. Fcap. 8vo, 5s.

A Commentary on the Diseases of India. By NORMAN CHEVERS, C.I.E., M.D., F.R.C.S., Deputy Surgeon-General H.M. Indian Army. 8vo, 24s.

The Principles and Practice of Medicine. By C. HILTON FAGGE, M.D. Second Edition. Edited by P. H. PYE-SMITH, M.D., F.R.C.P., Physician to, and Lecturer on Medicine at, Guy's Hospital. 2 vols. 8vo. Cloth, 36s.; Half Leather, 42s. [*Nearly Ready.*]

The Student's Guide to the Practice of Medicine. By M. CHARTERIS, M.D., Professor of Materia Medica in the University of Glasgow. Fourth Edition. Fcap. 8vo, with Engravings on Copper and Wood, 9s.

Hooper's Physicians' Vade-Mecum. A Manual of the Principles and Practice of Physic. Tenth Edition. By W. A. GUY, F.R.C.P., F.R.S., and J. HARLEY, M.D., F.R.C.P. With 118 Engravings. Fcap. 8vo, 12s. 6d.

Preventive Medicine.

Collected Essays. By WILLIAM SQUIRE, M.D., F.R.C.P., Physician to St. George, Hanover-square, Dispensary. 8vo, 6s. 6d.

The Student's Guide to Clinical Medicine and Case-Taking. By FRANCIS WARNER, M.D., F.R.C.P., Physician to the London Hospital. Second Edition. Fcap. 8vo, 5s.

How to Examine the Chest :

A Practical Guide for the use of Students. By SAMUEL WEST, M.D., F.R.C.P., Physician to the City of London Hospital for Diseases of the Chest; Assistant Physician to St. Bartholomew's Hospital. With 42 Engravings. Fcap. 8vo, 5s.

Diseases of the Chest :

Contributions to their Clinical History, Pathology, and Treatment. By A. T. HOUGHTON WATERS, M.D., Physician to the Liverpool Royal Infirmary. Second Edition. 8vo, with Plates, 15s.

By the same Author.

Contributions to Clinical and Practical Medicine. 8vo, with Engravings, 7s.

Pulmonary Consumption :

A Practical Treatise on its Cure with Medicinal, Dietetic, and Hygienic Remedies. By JAMES WEAVER, M.D., L.R.C.P. Crown 8vo, 2s.

Croonian Lectures on Some Points in the Pathology and Treatment of Typhoid Fever. By WILLIAM CAYLEY, M.D., F.R.C.P., Physician to the Middlesex and the London Fever Hospitals. Crown 8vo, 4s. 6d.

The Student's Guide to Medical Diagnosis. By SAMUEL FENWICK, M.D., F.R.C.P., Physician to the London Hospital, and BEDFORD FENWICK, M.D., M.R.C.P. Sixth Edition. Fcap. 8vo, with 114 Engravings, 7s.

By the same Author.

The Student's Outlines of Medical Treatment. Second Edition. Fcap. 8vo, 7s.

Also.

On Chronic Atrophy of the Stomach, and on the Nervous Affections of the Digestive Organs. 8vo, 8s.

Also.

The Saliva as a Test for Functional Diseases of the Liver. Crown 8vo, 2s.

The Microscope in Medicine.

By LIONEL S. BEALE, M.B., F.R.S., Physician to King's College Hospital. Fourth Edition. 8vo, with 86 Plates, 21s.

Also.

On Slight Ailments :

Their Nature and Treatment. Second Edition. 8vo, 5s.

Medical Lectures and Essays.

By G. JOHNSON, M.D., F.R.C.P., F.R.S., Consulting Physician to King's College Hospital. 8vo, with 46 Engravings, 25s.

The Spectroscope in Medicine.

By CHARLES A. MACMUNN, B.A., M.D. 8vo, with 3 Chromo-lithographic Plates of Physiological and Pathological Spectra, and 13 Engravings, 9s.

Notes on Asthma :

Its Forms and Treatment. By JOHN C. THOROWGOOD, M.D., Physician to the Hospital for Diseases of the Chest. Third Edition. Crown 8vo, 4s. 6d.

Winter Cough

(Catarrh, Bronchitis, Emphysema, Asthma). By HORACE DOBELL, M.D., Consulting Physician to the Royal Hospital for Diseases of the Chest. Third Edition. 8vo, with Coloured Plates, 10s. 6d.

By the same Author.

Loss of Weight, Blood-Spitting, and Lung Disease. Second Edition. 8vo, with Chromo-lithograph, 10s. 6d.

Also.

The Mont Dore Cure, and the Proper Way to Use it. 8vo, 7s. 6d.
Vaccinia and Variola :

A Study of their Life History. By JOHN B. BUIST, M.D., F.R.S.E., Teacher of Vaccination for the Local Government Board. Crown 8vo, with 24 Coloured Plates, 7s. 6d.

Treatment of Some of the Forms of Valvular Disease of the Heart. By A. E. SANSOM, M.D., F.R.C.P., Physician to the London Hospital. Second Edition. Fcap. 8vo, with 26 Engravings, 4s. 6d.

Diseases of the Heart and Aorta :

Clinical Lectures. By G. W. BALFOUR, M.D., F.R.C.P., F.R.S. Edin., late Senior Physician and Lecturer on Clinical Medicine, Royal Infirmary, Edinburgh. Second Edition. 8vo, with Chromo-lithograph and Wood Engravings, 12s. 6d.

Medical Ophthalmoscopy :

A Manual and Atlas. By W. R. GOWERS, M.D., F.R.C.P., F.R.S., Professor of Clinical Medicine in University College, Physician to University College Hospital and to the National Hospital for the Paralyzed and Epileptic. Second Edition, with Coloured Plates and Woodcuts. 8vo, 18s.

By the same Author.

Pseudo-Hypertrophic Muscular

Paralysis : A Clinical Lecture. 8vo, with Engravings and Plate, 3s. 6d.

Also.

Diagnosis of Diseases of the Spinal Cord. Third Edition. 8vo, with Engravings, 4s. 6d.

Also.

Diagnosis of Diseases of the Brain. Second Edition. 8vo, with Engravings, 7s. 6d.

Also.

A Manual of Diseases of the Nervous System.

Vol. I. Diseases of the Spinal Cord and Nerves. Roy. 8vo, with 171 Engravings (many figures), 12s. 6d.

Vol. II. Diseases of the Brain and Cranial Nerves : General and Functional Diseases of the Nervous System. 8vo, with 170 Engravings, 17s. 6d.

Diseases of the Nervous System.

Lectures delivered at Guy's Hospital. By SAMUEL WILKS, M.D., F.R.S. Second Edition. 8vo, 18s.

Nerve Vibration and Excitation, as Agents in the Treatment of Functional Disorder and Organic Disease. By J. MORTIMER GRANVILLE, M.D. 8vo, 5s.

By the same Author.

Gout in its Clinical Aspects.

Crown 8vo, 6s.

Regimen to be adopted in Cases of Gout. By WILHELM EBSTEIN, M.D., Professor of Clinical Medicine in Göttingen. Translated by JOHN SCOTT, M.A., M.B. 8vo, 2s. 6d.**Diseases of the Nervous System.**

Clinical Lectures. By THOMAS BUZZARD, M.D., F.R.C.P., Physician to the National Hospital for the Paralyzed and Epileptic. With Engravings, 8vo. 15s.

By the same Author.

Some Forms of Paralysis from Peripheral Neuritis : of Gouty, Alcoholic, Diphtheritic, and other origin. Crown 8vo, 5s.**Diseases of the Nervous System:**

Especially in Women. By S. WEIR MITCHELL, M.D., Physician to the Philadelphia Infirmary for Diseases of the Nervous System. Second Edition. 8vo, with 5 Plates, 8s.

Diseases of the Liver :

With and without Jaundice. By GEORGE HARLEY, M.D., F.R.C.P., F.R.S. 8vo, with 2 Plates and 36 Engravings, 21s.

By the same Author.

Inflammations of the Liver, and their Sequelæ. Crown 8vo, with Engravings, 5s.**Gout, Rheumatism,**

And the Allied Affections ; with Chapters on Longevity and Sleep. By PETER HOOD, M.D. Third Edition. Crown 8vo, 7s. 6d.

Diseases of the Stomach :

The Varieties of Dyspepsia, their Diagnosis and Treatment. By S. O. HABERSHON, M.D., F.R.C.P. Third Edition. Crown 8vo, 5s.

By the same Author.

Pathology of the Pneumogastric Nerve : Lumleian Lectures for 1876. Second Edition. Post 8vo, 4s.

Also.

Diseases of the Abdomen,

Comprising those of the Stomach and other parts of the Alimentary Canal, Oesophagus, Cæcum, Intestines, and Peritoneum. Third Edition. 8vo, with 5 Plates, 21s.

Also.

Diseases of the Liver,

Their Pathology and Treatment. Lettsomian Lectures. Second Edition. Post 8vo, 4s.

Acute Intestinal Strangulation,

And Chronic Intestinal Obstruction (Mode of Death from). By THOMAS BRYANT, F.R.C.S., Senior Surgeon to Guy's Hospital. 8vo, 3s.

A Treatise on the Diseases of the Nervous System. By JAMES ROSS, M.D., F.R.C.P., Assistant Physician to the Manchester Royal Infirmary. Second Edition. 2 vols. 8vo, with Lithographs, Photographs, and 332 Woodcuts, 52s. 6d.

By the same Author.

Handbook of the Diseases of the Nervous System. Roy. 8vo, with 184 Engravings, 18s.

Also.

Aphasia :

Being a Contribution to the Subject of the Dissolution of Speech from Cerebral Disease. 8vo, with Engravings, 4s. 6d.

On Megrin, Sick Headache, and some Allied Disorders : A Contribution to the Pathology of Nerve Storms. By E. LIVEING, M.D., F.R.C.P. 8vo, 15s.

Spasm in Chronic Nerve Disease.

(Gulstonian Lectures.) By SEYMOUR J. SHARKEY, M.A., M.B., F.R.C.P., Assistant Physician to, and Joint Lecturer on Pathology at, St. Thomas's Hospital. 8vo, with Engravings, 5s.

Food and Dietetics,

Physiologically and Therapeutically Considered. By F. W. PAVY, M.D., F.R.S., Physician to Guy's Hospital. Second Edition. 8vo, 15s.

By the same Author.

Croonian Lectures on Certain Points connected with Diabetes.

8vo, 4s. 6d.

Headaches :

Their Nature, Causes, and Treatment. By W. H. DAY, M.D., Physician to the Samaritan Hospital. Fourth Edition. Crown 8vo, with Engravings. [*In the Press.*]

Health Resorts at Home and

Abroad. By MATTHEW CHARTERIS, M.D., Physician to the Glasgow Royal Infirmary. Second Edition. Crown 8vo, with Map, 5s. 6d.

Winter and Spring

On the Shores of the Mediterranean. By HENRY BENNET, M.D. Fifth Edition. Post 8vo, with numerous Plates, Maps, and Engravings, 12s. 6d.

By the same Author.

Treatment of Pulmonary Consumption by Hygiene, Climate, and Medicine. Third Edition. 8vo, 7s. 6d.**Medical Guide to the Mineral Waters of France and its Wintering Stations.** With a Special Map. By A. VINTRAS, M.D., Physician to the French Embassy, and to the French Hospital, London. Crown 8vo, 8s.**The Ocean as a Health-Resort :**

A Practical Handbook of the Sea, for the use of Tourists and Health-Seekers. By WILLIAM S. WILSON, L.R.C.P. Second Edition, with Chart of Ocean Routes, &c. Crown 8vo, 7s. 6d.

Ambulance Handbook for Volun-

teers and Others. By J. ARDAVON RAYE, L.K. & Q.C.P.I., L.R.C.S.I., late Surgeon to H.B.M. Transport No. 14, Zulu Campaign, and Surgeon E.I.R. Rifles. 8vo, with 16 Plates (50 figures), 3s. 6d.

Ambulance Lectures :

To which is added a NURSING LECTURE. By JOHN M. H. MARTIN, Honorary Surgeon to the Blackburn Infirmary. Second Edition. Crown 8vo, with 59 Engravings, 2s.

Commoner Diseases and Accidents to Life and Limb: their Prevention and Immediate Treatment. By M. M. BASIL, M.A., M.B., C.M. Crown 8vo, 2s. 6d.**Handbook of Medical and Surgical Electricity.** By HERBERT

TIBBITS, M.D., F.R.C.P.E., Senior Physician to the West London Hospital for Paralysis and Epilepsy. Second Edition. 8vo, with 95 Engravings, 9s.

By the same Author.

How to Use a Galvanic Battery in Medicine and Surgery. Third Edition. 8vo, with Engravings, 4s.

Also.

A Map of Ziemssen's Motor Points of the Human Body: A Guide to Localised Electrification. Mounted on Rollers, 35 x 21. With 20 Illustrations, 5s. *Also.***Electrical and Anatomical Demonstrations.** A Handbook for Trained Nurses and Masseuses. Crown 8vo, with 44 Illustrations, 5s.**Surgical Emergencies :**

Together with the Emergencies attendant on Parturition and the Treatment of Poisoning. By W. PAUL SWAIN, F.R.C.S., Surgeon to the South Devon and East Cornwall Hospital. Fourth Edition. Crown 8vo, with 120 Engravings, 5s.

Operative Surgery in the Calcutta Medical College Hospital. Statistics, Cases, and Comments. By KENNETH MCLEOD, A.M., M.D., F.R.C.S.E., Surgeon-Major, Indian Medical Service, Professor of Surgery in Calcutta Medical College. 8vo, with Illustrations, 12s. 6d.**Surgical Pathology and Morbid Anatomy (Student's Guide).** By ANTHONY A. BOWLBY, F.R.C.S., Surgical Registrar and Demonstrator of Surgical Pathology to St. Bartholomew's Hospital. Fcap. 8vo, with 135 Engravings, 9s.**A Course of Operative Surgery.**

By CHRISTOPHER HEATH, Surgeon to University College Hospital. Second Edition. With 20 coloured Plates (180 figures) from Nature, by M. LÉVEILLÉ, and several Woodcuts. Large 8vo, 30s.

By the same Author.

The Student's Guide to Surgical Diagnosis. Second Edition. Fcap. 8vo, 6s. 6d. *Also.***Manual of Minor Surgery and Bandaging.** For the use of House-Surgeons, Dressers, and Junior Practitioners. Eighth Edition. Fcap. 8vo, with 142 Engravings, 6s.

Also.

Injuries and Diseases of the Jaws. Third Edition. 8vo, with Plate and 206 Wood Engravings, 14s.

Also.

Lectures on Certain Diseases of the Jaws. Delivered at the R.C.S., Eng., 1887. 8vo, with 64 Engravings, 2s. 6d.

The Practice of Surgery :

A Manual. By THOMAS BRYANT, Surgeon to Guy's Hospital. Fourth Edition. 2 vols. crown 8vo, with 750 Engravings (many being coloured), and including 6 chromo plates, 32s.

Surgery: its Theory and Prac-

tice (Student's Guide). By WILLIAM J. WALSHAM, F.R.C.S., Assistant Surgeon to St. Bartholomew's Hospital. Fcap. 8vo, with 236 Engravings, 10s. 6d.

The Surgeon's Vade-Mecum :

A Manual of Modern Surgery. By R. DRUITT, F.R.C.S. Twelfth Edition. By STANLEY BOYD, M.B., F.R.C.S. Assistant Surgeon and Pathologist to Charing Cross Hospital. Crown 8vo, with 373 Engravings 16s.

Regional Surgery :

Including Surgical Diagnosis. A Manual for the use of Students. By F. A. SOUTHAM, M.A., M.B., F.R.C.S., Assistant Surgeon to the Manchester Royal Infirmary. Part I. The Head and Neck. Crown 8vo, 6s. 6d. — Part II. The Upper Extremity and Thorax. Crown 8vo, 7s. 6d. Part III. The Abdomen and Lower Extremity. Crown 8vo, 7s.

Illustrations of Clinical Surgery.

By JONATHAN HUTCHINSON, F.R.S., Senior Surgeon to the London Hospital. In fasciculi. 6s. 6d each. Fasc. I. to X. bound, with Appendix and Index, £3 10s. Fasc. XI. to XXIII. bound, with Index, £4 10s.

By the same Author.

Pedigree of Disease :

Being Six Lectures on Temperament, Idiosyncrasy, and Diathesis. 8vo, 5s.

Treatment of Wounds and Frac-

tures. Clinical Lectures. By SAMPSON GAMGEE, F.R.S.E., Surgeon to the Queen's Hospital, Birmingham. Second Edition. 8vo, with 40 Engravings, 10s.

Lectures on Orthopædic Sur-

gery. By BERNARD E. BRODHURST, F.R.C.S., Surgeon to the Royal Orthopædic Hospital. Second Edition. 8vo, with Engravings, 12s. 6d.

By the same Author.

On Anchylosis, and the Treat-

ment for the Removal of De-

formity and the Restoration of Mobility in Various Joints. Fourth Edition. 8vo, with Engravings, 5s.

Also.

Curvatures and Diseases of the

Spine. Third Edition. 8vo, with Engravings, 6s.

Spina Bifida :

Its Treatment by a New Method. By JAS. MORTON, M.D., L.R.C.S.E., Professor of Materia Medica in Anderson's College, Glasgow. 8vo, with Plates, 7s. 6d.

Diseases of Bones and Joints.

By CHARLES MACNAMARA, F.R.C.S., Surgeon to, and Lecturer on Surgery at, the Westminster Hospital. 8vo, with Plates and Engravings, 12s.

Injuries of the Spine and Spinal

Cord, and NERVOUS SHOCK, in their Surgical and Medico-Legal Aspects. By HERBERT W. PAGE, M.C. Cantab., F.R.C.S., Surgeon to St. Mary's Hospital. Second Edition, post 8vo, 10s.

Face and Foot Deformities.

By FREDERICK CHURCHILL, C.M., Surgeon to the Victoria Hospital for Children. 8vo, with Plates and Illustrations, 10s. 6d.

Clubfoot :

Its Causes, Pathology, and Treatment. By WM. ADAMS, F.R.C.S., Surgeon to the Great Northern Hospital. Second Edition. 8vo, with 106 Engravings and 6 Lithographic Plates, 15s.

By the same Author.

On Contraction of the Fingers,

and its Treatment by Subcutaneous Operation; and on Obliteration of Depressed Cicatrices, by the same Method. 8vo, with 30 Engravings, 4s. 6d.

Also.

Lateral and other Forms of

Curvature of the Spine: Their Pathology and Treatment. Second Edition. 8vo, with 5 Lithographic Plates and 72 Wood Engravings, 10s. 6d.

Spinal Curvatures :

Treatment by Extension and Jacket; with Remarks on some Affections of the Hip, Knee, and Ankle-joints. By H. MACNAUGHTON JONES, M.D., F.R.C.S. I. and Edin. Post 8vo, with 63 Engravings, 4s. 6d.

Electricity and its Manner of

Working in the Treatment of Disease. By WM. E. STEAVENSON, M.D., Physician and Electrician to St. Bartholomew's Hospital. 8vo, 4s. 6d.

On Diseases and Injuries of the

Eye: A Course of Systematic and Clinical Lectures to Students and Medical Practitioners. By J. R. WOLFE, M.D., F.R.C.S.E., Lecturer on Ophthalmic Medicine and Surgery in Anderson's College, Glasgow. With 10 Coloured Plates and 157 Wood Engravings. 8vo, £1 1s.

Hints on Ophthalmic Out-Patient

Practice. By CHARLES HIGGENS, Ophthalmic Surgeon to Guy's Hospital. Third Edition. Fcap. 8vo, 3s.

Short Sight, Long Sight, and

Astigmatism. By GEORGE F. HELM, M.A., M.D., F.R.C.S., formerly Demonstrator of Anatomy in the Cambridge Medical School. Crown 8vo, with 35 Engravings, 3s. 6d.

The Student's Guide to Diseases of the Eye. By EDWARD NETTLESHIP, F.R.C.S., Ophthalmic Surgeon to St. Thomas's Hospital. Fourth Edition. Fcap. 8vo, with 164 Engravings and a Set of Coloured Papers illustrating Colour-Blindness, 7s. 6d.

Manual of the Diseases of the Eye. By CHARLES MACNAMARA, F.R.C.S., Surgeon to Westminster Hospital. Fourth Edition. Crown 8vo, with 4 Coloured Plates and 66 Engravings, 10s. 6d.

Normal and Pathological Histology of the Human Eye and Eyelids. By C. FRED. POLLOCK, M.D., F.R.C.S. and F.R.S.E., Surgeon for Diseases of the Eye to Anderson's College Dispensary, Glasgow. Crown 8vo, with 100 Plates (230 drawings), 15s.

Atlas of Ophthalmoscopy.

Composed of 12 Chromo-lithographic Plates (59 Figures drawn from nature) and Explanatory Text. By RICHARD LIEBREICH, M.R.C.S. Translated by H. ROSBOROUGH SWANZY, M.B. Third edition, 4to, 40s.

Glaucoma :

Its Causes, Symptoms, Pathology, and Treatment. By PRIESTLEY SMITH, M.R.C.S., Ophthalmic Surgeon to the Queen's Hospital, Birmingham. 8vo, with Lithographic Plates, 10s. 6d.

Refraction of the Eye :

A Manual for Students. By GUSTAVUS HARTRIDGE, F.R.C.S., Assistant Surgeon to the Royal Westminster Ophthalmic Hospital. Third Edition. Crown 8vo, with 96 Illustrations, Test-types, &c., 5s. 6d.

Squint :

(Clinical Investigations on). By C. SCHWEIGGER, M.D., Professor of Ophthalmology in the University of Berlin. Edited by GUSTAVUS HARTRIDGE, F.R.C.S. 8vo, 5s.

Practitioner's Handbook of Diseases of the Ear and Nasopharynx. By H. MACNAUGHTON JONES, M.D., late Professor of the Queen's University in Ireland, Surgeon to the Cork Ophthalmic and Aural Hospital. Third Edition of "Aural Surgery." Roy. 8vo, with 128 Engravings, 6s.

By the same Author.

Atlas of Diseases of the Membrana Tympani. In Coloured Plates, containing 62 Figures, with Text. Crown 4to, 21s.

Endemic Goitre or Thyreocele : Its Etiology, Clinical Characters, Pathology, Distribution, Relations to Cretinism, Myxœdema, &c., and Treatment. By WILLIAM ROBINSON, M.D. 8vo, 5s.

Diseases and Injuries of the Ear. By Sir WILLIAM B. DALBY, Aural Surgeon to St. George's Hospital. Third Edition. Crown 8vo, with Engravings, 7s. 6d.

By the Same Author.

Short Contributions to Aural Surgery, between 1875 and 1886. 8vo, with Engravings, 3s. 6d.

Diseases of the Throat and Nose: A Manual. By Sir MORELL MACKENZIE, M.D., Senior Physician to the Hospital for Diseases of the Throat.

Vol. II. Diseases of the Nose and Nasopharynx; with a Section on Diseases of the Oesophagus. Post 8vo, with 93 Engravings, 12s. 6d.

By the same Author.

Diphtheria :

Its Nature and Treatment, Varieties, and Local Expressions. 8vo, 5s.

Sore Throat :

Its Nature, Varieties, and Treatment. By PROSSER JAMES, M.D., Physician to the Hospital for Diseases of the Throat. Fifth Edition. Post 8vo, with Coloured Plates and Engravings, 6s. 6d.

A Treatise on Vocal Physiology and Hygiene. By GORDON HOLMES, M.D., Physician to the Municipal Throat and Ear Infirmary. Second Edition, with Engravings. Crown 8vo, 6s. 6d.

Studies in Pathological Anatomy, Especially in Relation to Laryngeal Neoplasms. By R. NORRIS WOLFENDEN, M.D., Senior Physician to the Throat Hospital, and SIDNEY MARTIN, M.D., Pathologist to the City of London Hospital, Victoria Park. I. Papilloma. Roy. 8vo, with Coloured Plates, 2s. 6d.

A System of Dental Surgery.

By Sir JOHN TOMES, F.R.S., and C. S. TOMES, M.A., F.R.S. Third Edition. Crown 8vo, with 292 Engravings, 15s.

Dental Anatomy, Human and Comparative: A Manual. By CHARLES S. TOMES, M.A., F.R.S. Second Edition. Crown 8vo, with 191 Engravings, 12s. 6d.

The Student's Guide to Dental Anatomy and Surgery. By HENRY SEWILL, M.R.C.S., L.D.S. Second Edition. Fcap. 8vo, with 78 Engravings, 5s. 6d.

Notes on Dental Practice. By HENRY C. QUINBY, L.D.S.R.C.S.I. 8vo, with 87 Engravings, 9s.

Mechanical Dentistry in Gold and Vulcanite. By F. H. BALKWILL, L.D.S.R.C.S. 8vo, with 2 Lithographic Plates and 57 Engravings, 10s.

Principles and Practice of Dentistry : including Anatomy, Physiology, Pathology, Therapeutics, Dental Surgery, and Mechanism. By C. A. HARRIS, M.D., D.D.S. Edited by F. J. S. GORGAS, A.M., M.D., D.D.S., Professor in the Dental Department of Maryland University. Eleventh Edition. 8vo, with 750 Illustrations, 31s. 6d.

A Practical Treatise on Mechanical Dentistry. By JOSEPH RICHARDSON, M.D., D.D.S., late Emeritus Professor of Prosthetic Dentistry in the Indiana Medical College. Fourth Edition. Roy. 8vo, with 458 Engravings, 21s.

A Manual of Dental Mechanics. By OAKLEY COLES, L.D.S.R.C.S. Second Edition. Crown 8vo, with 140 Engravings, 7s. 6d.

Elements of Dental Materia Medica and Therapeutics, with Pharmacopœia. By JAMES STOCKEN, L.D.S.R.C.S., Pereira Prizeman for Materia Medica, and THOMAS GADDES, L.D.S. Eng. and Edin. Third Edition. Fcap. 8vo, 7s. 6d.

Atlas of Skin Diseases.

By TILBURY FOX, M.D., F.R.C.P. With 72 Coloured Plates. Royal 4to, half morocco, £6 6s.

Diseases of the Skin :

With an Analysis of 8,000 Consecutive Cases and a Formulary. By L. D. BULKLEY, M.D., Physician for Skin Diseases at the New York Hospital. Crown 8vo, 6s. 6d.

By the same Author.

Acne : its Etiology, Pathology, and Treatment : Based upon a Study of 1,500 Cases. 8vo, with Engravings, 10s.

On Certain Rare Diseases of the Skin. By JONATHAN HUTCHINSON, F.R.S., Senior Surgeon to the London Hospital, and to the Hospital for Diseases of the Skin. 8vo, 10s. 6d.

Diseases of the Skin :

A Practical Treatise for the Use of Students and Practitioners. By J. N. HYDE, A.M., M.D., Professor of Skin and Venereal Diseases, Rush Medical College, Chicago. 8vo, with 66 Engravings, 17s.

Parasites :

A Treatise on the Entozoa of Man and Animals, including some Account of the Ectozoa. By T. SPENCER COBBOLD, M.D., F.R.S. 8vo, with 85 Engravings, 15s.

Manual of Animal Vaccination, preceded by Considerations on Vaccination in general. By E. WARLOMONT, M.D., Founder of the State Vaccine Institute of Belgium. Translated and edited by ARTHUR J. HARRIES, M.D. Crown 8vo, 4s. 6d.

Leprosy in British Guiana.

By JOHN D. HILLIS, F.R.C.S., M.R.I.A., Medical Superintendent of the Leper Asylum, British Guiana. Imp. 8vo, with 22 Lithographic Coloured Plates and Wood Engravings, £1 11s. 6d.

Cancer of the Breast.

By THOMAS W. NUNN, F.R.C.S., Consulting Surgeon to the Middlesex Hospital. 4to, with 21 Coloured Plates, £2 2s.

On Cancer :

Its Allies, and other Tumours; their Medical and Surgical Treatment. By F. A. PURCELL, M.D., M.C., Surgeon to the Cancer Hospital, Brompton. 8vo, with 21 Engravings, 10s. 6d.

Sarcoma and Carcinoma :

Their Pathology, Diagnosis, and Treatment. By HENRY T. BUTLIN, F.R.C.S., Assistant Surgeon to St. Bartholomew's Hospital. 8vo, with 4 Plates, 8s.

By the same Author.

Malignant Disease of the Larynx (Sarcoma and Carcinoma). 8vo, with 5 Engravings, 5s.

Also.

Operative Surgery of Malignant Disease. 8vo, 14s.

Cancerous Affections of the Skin.

(Epithelioma and Rodent Ulcer.) By GEORGE THIN, M.D. Post 8vo, with 8 Engravings, 5s.

By the same Author.

Pathology and Treatment of Ringworm. 8vo, with 21 Engravings, 5s.

Cancer of the Mouth, Tongue, and Alimentary Tract : their Pathology, Symptoms, Diagnosis, and Treatment. By FREDERIC B. JESSETT, F.R.C.S., Surgeon to the Cancer Hospital, Brompton. 8vo, 10s.

Clinical Notes on Cancer,

Its Etiology and Treatment; with special reference to the Heredity-Fallacy, and to the Neurotic Origin of most Cases of Alveolar Carcinoma. By HERBERT L. SNOW, M.D. Lond., Surgeon to the Cancer Hospital, Brompton. Crown 8vo, 3s. 6d.

Lectures on the Surgical Disorders of the Urinary Organs. By REGINALD HARRISON, F.R.C.S., Surgeon to the Liverpool Royal Infirmary. Third Edition, with 117 Engravings. 8vo, 12s. 6d.

Hydrocele :

Its several Varieties and their Treatment. By SAMUEL OSBORN, late Surgical Registrar to St. Thomas's Hospital. Fcap. 8vo, with Engravings, 3s.

By the same Author.

Diseases of the Testis.

Fcap. 8vo, with Engravings, 3s. 6d.

Diseases of the Urinary Organs.

Clinical Lectures. By Sir HENRY THOMPSON, F.R.C.S., Emeritus Professor of Clinical Surgery in University College. Seventh (Students') Edition. 8vo, with 84 Engravings, 2s. 6d.

By the same Author.

Diseases of the Prostate :

Their Pathology and Treatment. Sixth Edition. 8vo, with 39 Engravings, 6s.

Also.

Surgery of the Urinary Organs.

Some Important Points connected therewith. Lectures delivered in the R.C.S. 8vo, with 44 Engravings. Students' Edition, 2s. 6d.

Also.

Practical Lithotomy and Litho-

trity; or, An Inquiry into the Best Modes of Removing Stone from the Bladder. Third Edition. 8vo, with 87 Engravings, 10s.

Also.

The Preventive Treatment of

Calculous Disease, and the Use of Solvent Remedies. Second Edition. Fcap. 8vo, 2s. 6d.

Also.

Tumours of the Bladder :

Their Nature, Symptoms, and Surgical Treatment. 8vo, with numerous Illustrations, 5s.

Also.

Stricture of the Urethra, and Uri-

nary Fistulæ: their Pathology and Treatment. Fourth Edition. With 74 Engravings. 8vo, 6s.

Also.

The Suprapubic Operation of

Opening the Bladder for the Stone and for Tumours. 8vo, with 14 Engravings, 3s. 6d.

Electric Illumination of the Male

Bladder and Urethra, as a Means of Diagnosis of Obscure Vesico-Urethral Diseases. By E. HURRY FENWICK, F.R.C.S., Assistant Surgeon to the London Hospital and to St. Peter's Hospital for Stone, &c. [*In the Press.*]

Modern Treatment of Stone in

the Bladder by Litholopaxy. By P. J. FREYER, M.A., M.D., M.Ch., Bengal Medical Service. 8vo, with Engravings, 5s.

Diseases of the Testis, Sperm-

atic Cord, and Scrotum. By THOMAS B. CURLING, F.R.S., Consulting Surgeon to the London Hospital. Fourth Edition. 8vo, with Engravings, 16s.

Diseases of the Rectum and

Anus. By W. HARRISON CRIPPS, F.R.C.S., Assistant Surgeon to St. Bartholomew's Hospital, &c. 8vo, with 13 Lithographic Plates and numerous Wood Engravings, 12s. 6d.

The Surgery of the Rectum.

By HENRY SMITH, Professor of Surgery in King's College, Surgeon to the Hospital. Fifth Edition. 8vo, 6s.

Urinary and Renal Derange-

ments and Calculous Disorders. By LIONEL S. BEALE, F.R.C.P., F.R.S., Physician to King's College Hospital. 8vo, 5s.

Fistula, Hæmorrhoids, Painful

Ulcer, Stricture, Prolapsus, and other Diseases of the Rectum : Their Diagnosis and Treatment. By WILLIAM ALLINGHAM, Surgeon to St. Mark's Hospital for Fistula. Fourth Edition. 8vo, with Engravings, 10s. 6d.

Pathology of the Urine.

Including a Complete Guide to its Analysis. By J. L. W. THUDICHUM, M.D., F.R.C.P. Second Edition, rewritten and enlarged. 8vo, with Engravings, 15s.

Student's Primer on the Urine.

By J. TRAVIS WHITTAKER, M.D., Clinical Demonstrator at the Royal Infirmary, Glasgow. With 16 Plates etched on Copper. Post 8vo, 4s. 6d.

Syphilis and Pseudo-Syphilis.

By ALFRED COOPER, F.R.C.S., Surgeon to the Lock Hospital, to St. Mark's and the West London Hospitals. 8vo, 10s. 6d.

Diagnosis and Treatment of

Syphilis. By TOM ROBINSON, M.D., Physician to St. John's Hospital for Diseases of the Skin. Crown 8vo, 3s. 6d.

By the same Author.

Eczema: its Etiology, Patho-

logy, and Treatment. Crown 8vo, 3s. 6d.

Coulson on Diseases of the

Bladder and Prostate Gland. Sixth Edition. By WALTER J. COULSON, Surgeon to the Lock Hospital and to St. Peter's Hospital for Stone. 8vo, 16s.

The Medical Adviser in Life As-

urance. By Sir E. H. SIEVEKING, M.D., F.R.C.P. Second Edition. Crown 8vo, 6s.

A Medical Vocabulary :

An Explanation of all Terms and Phrases used in the various Departments of Medical Science and Practice, their Derivation, Meaning, Application, and Pronunciation. By R. G. MAYNE, M.D., LL.D. Sixth Edition. [*In the Press.*]

A Dictionary of Medical Science:

Containing a concise Explanation of the various Subjects and Terms of Medicine, &c. By ROBLEY DUNGLISON, M.D., LL.D. Royal 8vo, 28s.

Medical Education

And Practice in all parts of the World. By H. J. HARDWICKE, M.D., M.R.C.P. 8vo, 10s.

INDEX.

- Abercrombie's Medical Jurisprudence, 4
 Adams (W.) on Clubfoot, 11
 — on Contraction of the Fingers, 11
 — on Curvature of the Spine, 11
 Alexander's Displacements of the Uterus, 6
 Allan's Outlines of Infectious Diseases, 7
 Allingham on Diseases of the Rectum, 14
 Anatomical Remembrancer, 3
 Balfour's Diseases of the Heart and Aorta, 9
 Balkwill's Mechanical Dentistry, 12
 Barnes (R.) on Obstetric Operations, 5
 — on Diseases of Women, 5
 Basil's Commoner Diseases and Accidents, 10
 Beale's Microscope in Medicine, 8
 — Slight Ailments, 8
 — Urinary and Renal Derangements, 14
 Bellamy's Surgical Anatomy, 3
 Bennet (J. H.) on the Mediterranean, 10
 — on Pulmonary Consumption, 10
 Bentley and Trimen's Medicinal Plants, 7
 Bentley's Manual of Botany, 7
 — Structural Botany, 7
 — Systematic Botany, 7
 Bowlby's Surgical Pathology and Morbid Anatomy, 10
 Braune's Topographical Anatomy, 3
 Brodhurst's Anchylosis, 11
 — Curvatures, &c., of the Spine, 11
 — Orthopædic Surgery, 11
 Bryant's Acute Intestinal Strangulation, 9
 — Practice of Surgery, 11
 Bucknill and Tuke's Psychological Medicine, 5
 Buist's Vaccinia and Variola, 8
 Bulkley's Acne, 13
 — Diseases of the Skin, 13
 Burdett's Cottage Hospitals, 4
 — Pay Hospitals, 4
 Burton's Midwifery for Midwives, 6
 Butlin's Malignant Disease of the Larynx, 13
 — Operative Surgery of Malignant Disease, 13
 — Sarcoma and Carcinoma, 13
 Buzzard's Diseases of the Nervous System 9
 — Peripheral Neuritis, 9
 Byford's Diseases of, and Accidents to, Women, 6
 Carpenter's Human Physiology, 4
 Cayley's Typhoid Fever, 8
 Charteris on Health Resorts, 10
 — Practice of Medicine, 8
 Chavers' Diseases of India, 8
 Churchill's Face and Foot Deformities, 11
 Clouston's Lectures on Mental Diseases, 5
 Cobbold on Parasites, 13
 Coles' Dental Mechanics, 13
 Cooper's Syphilis and Pseudo-Syphilis, 14
 Coulson on Diseases of the Bladder, 14
 Courty's Diseases of the Uterus, Ovaries, &c., 6
 Cripps' Diseases of the Rectum and Anus, 14
 Cullingworth's Manual of Nursing, 6
 — Short Manual for Monthly Nurses, 6
 Curling's Diseases of the Testis, 14
 Dalby's Diseases and Injuries of the Ear, 12
 — Short Contributions, 12
 Day on Diseases of Children, 6
 — on Headaches, 10
 Dobell's Lectures on Winter Cough, 8
 — Loss of Weight, &c., 8
 — Mont Doré Cure, 8
 Domville's Manual for Nurses, 6
 Doran's Gynæcological Operations, 6
 Down's Mental Affections of Childhood, 5
 Draper's Text Book of Medical Physics, 4
 Druitt's Surgeon's Vade-Mecum, 11
 Duncan on Diseases of Women, 5
 — on Sterility in Woman, 5
 Dunglison's Medical Dictionary, 14
 East's Private Treatment of the Insane, 5
 Ebstein on Regimen in Gout, 9
 Ellis's Diseases of Children, 6
 Fagge's Principles and Practice of Medicine, 8
 Fayrer's Climate and Fevers of India, 7
 Fenwick (E. H.), Electric Illumination of Bladder, 14
 Fenwick's (S.) Chronic Atrophy of the Stomach, 8
 — Medical Diagnosis, 8
 — Outlines of Medical Treatment, 8
 — The Saliva as a Test, 8
 Flint's Principles and Practice of Medicine, 7
 Flower's Diagrams of the Nerves, 3
 Fox's (C. B.) Examinations of Water, Air, and Food, 5
 Fox's (T.) Atlas of Skin Diseases, 13
 Freyer's Litholopaxy, 14
 Frey's Histology and Histo-Chemistry, 4
 Galabin's Diseases of Women, 6
 — Manual of Midwifery, 5
 Gamgee's Treatment of Wounds and Fractures, 11
 Godlee's Atlas of Human Anatomy, 3
 Goodhart's Diseases of Children, 6
 Gowers' Diseases of the Brain, 9
 — Diseases of the Spinal Cord, 9
 — Manual of Diseases of Nervous System, 9
 — Medical Ophthalmoscopy, 9
 — Pseudo-Hypertrophic Muscular Paralysis, 9
 Granville on Gout, 9
 — on Nerve Vibration and Excitation, 9
 Guy's Hospital Formulæ, 2
 — Reports, 2
 Habershon's Diseases of the Abdomen, 9
 — Liver, 9
 — Stomach, 9
 — Pneumogastric Nerve, 9
 Hardwicke's Medical Education, 14
 Harley on Diseases of the Liver, 9
 — Inflammations of the Liver, 9
 Harris's Dentistry, 13
 Harrison's Surgical Disorders of the Urinary Organs, 13
 Hartridge's Refraction of the Eye, 12
 Harvey's Manuscript Lectures, 3
 Heath's Certain Diseases of the Jaws, 10
 — Injuries and Diseases of the Jaws, 10
 — Minor Surgery and Bandaging, 10
 — Operative Surgery, 10
 — Practical Anatomy, 3
 — Surgical Diagnosis, 10
 Helm on Short and Long Sight, &c., 11
 Higgens' Ophthalmic Out-patient Practice, 11
 Hillis' Leprosy in British Guiana, 13
 Holden's Dissections, 3
 — Human Osteology, 3
 — Landmarks, 3
 Holmes' (G.) Vocal Physiology and Hygiene, 12
 Hood's (D. C.) Diseases and their Commencement, 7
 Hood (P.) on Gout, Rheumatism, &c., 9
 Hooper's Physician's Vade-Mecum, 8
 Hutchinson's Clinical Surgery, 11
 — Pedigree of Disease, 11
 — Rare Diseases of the Skin, 13
 Hyde's Diseases of the Skin, 13
 James (P.) on Sore Throat, 12
 Jessett's Cancer of the Mouth, &c., 13
 Johnson's Medical Lectures and Essays, 8
 Jones (C. H.) and Sieveking's Pathological Anatomy, 4
 Jones' (H. McN.) Diseases of the Ear and Pharynx, 12
 — Atlas of Diseases of Membrana Tympani, 12
 — Spinal Curvatures, 11
 Journal of British Dental Association, 2
 — Mental Science, 2
 King's Manual of Obstetrics, 5
 Lancereaux's Atlas of Pathological Anatomy, 4
 Lawson's Milroy Lectures on Epidemiology, 5
 Lewis (Bevan) on the Human Brain, 4
 Liebreich's Atlas of Ophthalmoscopy, 12
 Liveing's Megrin, Sick Headache, &c., 9
 London Hospital Reports, 2
 Lückes' Hospital Sisters and their Duties, 7
 Macdonald's (J. D.) Examination of Water and Air, 4
 Mackenzie on Diphtheria, 12
 — on Diseases of the Throat and Nose, 12
 McLeod's Operative Surgery, 10
 MacMunn's Spectroscope in Medicine, 8
 Macnamara's Diseases of the Eye, 12
 — Bones and Joints, 11
 Martin's Ambulance Lectures, 10
 Mayne's Medical Vocabulary, 14
 Middlesex Hospital Reports, 2
 Mitchell's Diseases of the Nervous System, 9
 Moore's Family Medicine for India, 7
 — Manual of the Diseases of India, 7
 Morris' (H.) Anatomy of the Joints, 3
 Morton's Spina Bifida, 11
 Mout and Snell on Hospitals, 4
 Nettleship's Diseases of the Eye, 12
 Nunn's Cancer of the Breast, 13
 Ogston's Medical Jurisprudence, 4
 Ophthalmic (Royal London) Hospital Reports, 2
 Ophthalmological Society's Transactions, 2
 Oppert's Hospitals, Infirmaries, Dispensaries, &c., 4
 Osborn on Diseases of the Testis, 13
 — on Hydrocele, 13
 Owen's Materia Medica, 7
 Page's Injuries of the Spine, 11
 Parkes' Practical Hygiene, 5
 Pavy on Diabetes, 10

[Continued on the next page.]

- Pavy on Food and Dietetics, 10
 Pharmaceutical Journal, 2
 Pharmacopœia of the London Hospital, 7
 Phillips' *Materia Medica* and Therapeutics, 7
 Pollock's Histology of the Eye and Eyelids, 12
 Priestley's Intra-Uterine Death, 5
 Purcell on Cancer, 13
 Quinby's Notes on Dental Practice, 12
 Raye's Ambulance Handbook, 10
 Reynolds' (J. J.) Diseases of Women, 5
 — Notes on Midwifery, 5
 Richardson's Mechanical Dentistry, 13
 Roberts' (C.) Detection of Colour-Blindness, 5
 Roberts' (D. Lloyd) Practice of Midwifery, 5
 Robinson (Tom) on Eczema, 14
 — on Syphilis, 14
 Robinson (W.) on Endemic Goitre or Thyrocele, 12
 Ross's Aphasia, 9
 — Diseases of the Nervous System, 9
 — Handbook of ditto, 9
 Routh's Infant Feeding, 7
 Royal College of Surgeons Museum Catalogues, 2
 Royle and Harley's *Materia Medica*, 7
 St. Bartholomew's Hospital Catalogue, 2
 St. George's Hospital Reports, 2
 St. Thomas's Hospital Reports, 2
 Sansom's Valvular Disease of the Heart, 8
 Savage on the Female Pelvic Organs, 6
 Schweigger on Squint, 12
 Sewill's Dental Anatomy, 12
 Sharkey's Spasm in Chronic Nerve Disease, 10
 Shore's Elementary Practical Biology, 4
 Sieveking's Life Assurance, 14
 Simon's Public Health Reports, 4
 Smith's (E.) Clinical Studies, 6
 — Diseases in Children, 6
 — Wasting Diseases of Infants and Children, 6
 Smith's (J. Greig) Abdominal Surgery, 6
 Smith's (Henry) Surgery of the Rectum, 14
 Smith (Priestley) on Glaucoma, 12
 Snow's Clinical Notes on Cancer, 13
 Southam's Regional Surgery, 11
 Squire's (P.) Companion to the Pharmacopœia, 7
 — Pharmacopœias of London Hospitals, 7
 Squire's (W.) Essays on Preventive Medicine, 8
 Steavenson's Electricity, 11
 Stillé and Maisch's National Dispensatory, 7
 Stocken's Dental *Materia Medica* and Therapeutics, 13
 Sutton's General Pathology, 4
 Swain's Surgical Emergencies, 10
 Swayne's Obstetric Aphorisms, 6
 Taylor's Medical Jurisprudence, 4
 Taylor's Poisons in relation to Medical Jurisprudence, 4
 Teale's Dangers to Health, 5
 Thin's Cancerous Affections of the Skin, 13
 — Pathology and Treatment of Ringworm,
 Thomas's Diseases of Women, 6
 Thompson's (Sir H.) Calculous Disease, 14
 — Diseases of the Prostate, 14
 — Diseases of the Urinary Organs, 14
 — Lithotomy and Lithotripsy, 14
 — Stricture of the Urethra, 14
 — Suprapubic Operation, 14
 — Surgery of the Urinary Organs, 14
 — Tumours of the Bladder, 14
 Thorogood on Asthma, 8
 — on *Materia Medica* and Therapeutics, 7
 Thudichum's Pathology of the Urine, 14
 Tibbits' Medical and Surgical Electricity, 10
 — Map of Motor Points, 10
 — How to use a Galvanic Battery, 10
 — Electrical and Anatomical Demonstrations, 10
 Tilt's Change of Life, 6
 — Uterine Therapeutics, 6
 Tirard's Prescriber's Pharmacopœia, 7
 Tomes' (C. S.) Dental Anatomy, 12
 Tomes' (J. and C. S.) Dental Surgery, 12
 Tuke's Influence of the Mind upon the Body, 5
 — Sleep-Walking and Hypnotism, 5
 Vintras on the Mineral Waters, &c., of France, 10
 Virchow's Post-mortem Examinations, 4
 Walsham's Surgery: its Theory and Practice, 11
 Waring's Indian Bazaar Medicines, 7
 — Practical Therapeutics, 7
 Warlomont's Animal Vaccination, 13
 Warner's Guide to Medical Case-Taking, 8
 Waters' (A. T. H.) Diseases of the Chest, 8
 — Contributions to Medicine, 8
 Weaver's Pulmonary Consumption, 8
 Wells' (Spencer) Ovarian and Uterine Tumours, 6
 West and Duncan's Diseases of Women, 6
 West's (S.) How to Examine the Chest, 8
 Whittaker's Primer on the Urine, 14
 Wilks' Diseases of the Nervous System, 8
 Williams' (Roger) Influence of Sex, 4
 Wilson's (Sir E.) Anatomists' Vade-Mecum, 3
 Wilson's (G.) Handbook of Hygiene, 5
 — Healthy Life and Dwellings, 5
 Wilson's (W. S.) Ocean as a Health-Resort, 10
 Wolfe's Diseases and Injuries of the Eye, 11
 Wolfenden and Martin's Pathological Anatomy, 12
 Year Book of Pharmacy, 2
 Yeo's (G. F.) Manual of Physiology, 4

The following CATALOGUES issued by J. & A. CHURCHILL will be forwarded post free on application:—

A. *J. & A. Churchill's General List of about 650 works on Anatomy, Physiology, Hygiene, Midwifery, Materia Medica, Medicine, Surgery, Chemistry, Botany, &c., &c., with a complete Index to their Subjects, for easy reference.*
 N.B.—This List includes B, C, & D.

B. *Selection from J. & A. Churchill's General List, comprising all recent Works published by them on the Art and Science of Medicine.*

C. *J. & A. Churchill's Catalogue of Text Books specially arranged for Students.*


D. *A selected and descriptive List of J. & A. Churchill's Works on Chemistry, Materia Medica, Pharmacy, Botany, Photography, Zoology, the Microscope, and other branches of Science.*

E. *The Medical Intelligencer, being a List of New Works and New Editions published by J. & A. Churchill.*

[Sent yearly to every Medical Practitioner in the United Kingdom whose name and address can be ascertained. A large number are also sent to the United States of America, Continental Europe, India, and the Colonies.]

AMERICA.—*J. & A. Churchill being in constant communication with various publishing houses in Boston, New York, and Philadelphia, are able, notwithstanding the absence of international copyright, to conduct negotiations favourable to English Authors.*

LONDON: 11, NEW BURLINGTON STREET.



✓

