

**Anatomia universale ... rappresentata con tavole ... ridotte a minori forme di quelle della grande edizione pisana per Antonio Serantoni / [Paolo Mascagni].**

**Contributors**

Mascagni, Paolo, 1755-1815.  
Serantoni, Antonio.

**Publication/Creation**

Firenze : V. Batelli, 1833.

**Persistent URL**

<https://wellcomecollection.org/works/yj4jzd4u>

**License and attribution**


This work has been identified as being free of known restrictions under copyright law, including all related and neighbouring rights and is being made available under the Creative Commons, Public Domain Mark.

You can copy, modify, distribute and perform the work, even for commercial purposes, without asking permission.

**wellcome  
collection**


Wellcome Collection  
183 Euston Road  
London NW1 2BE UK  
T +44 (0)20 7611 8722  
E [library@wellcomecollection.org](mailto:library@wellcomecollection.org)  
<https://wellcomecollection.org>








F.269




D IV  
19/m

















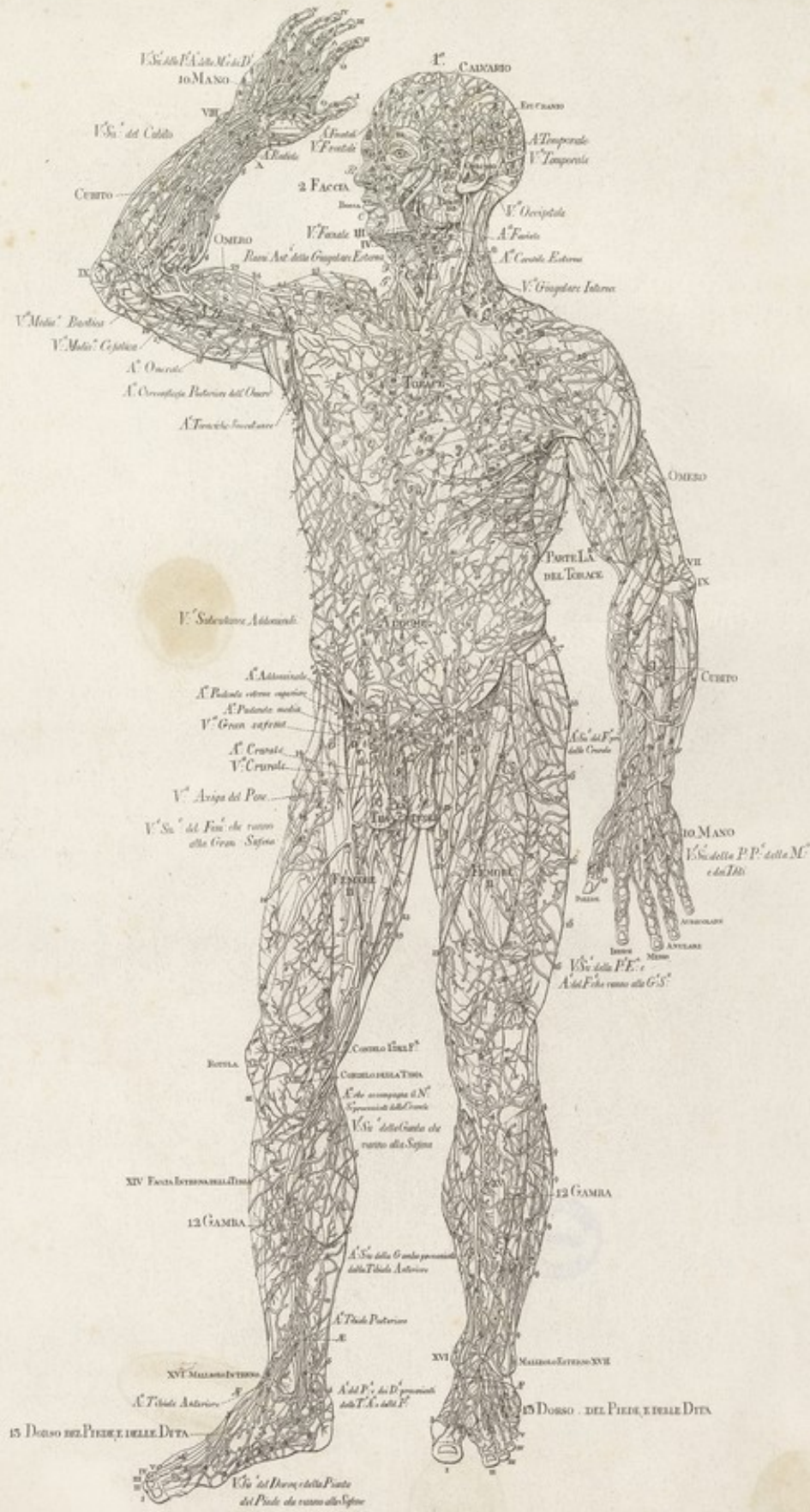


50381  
F.269

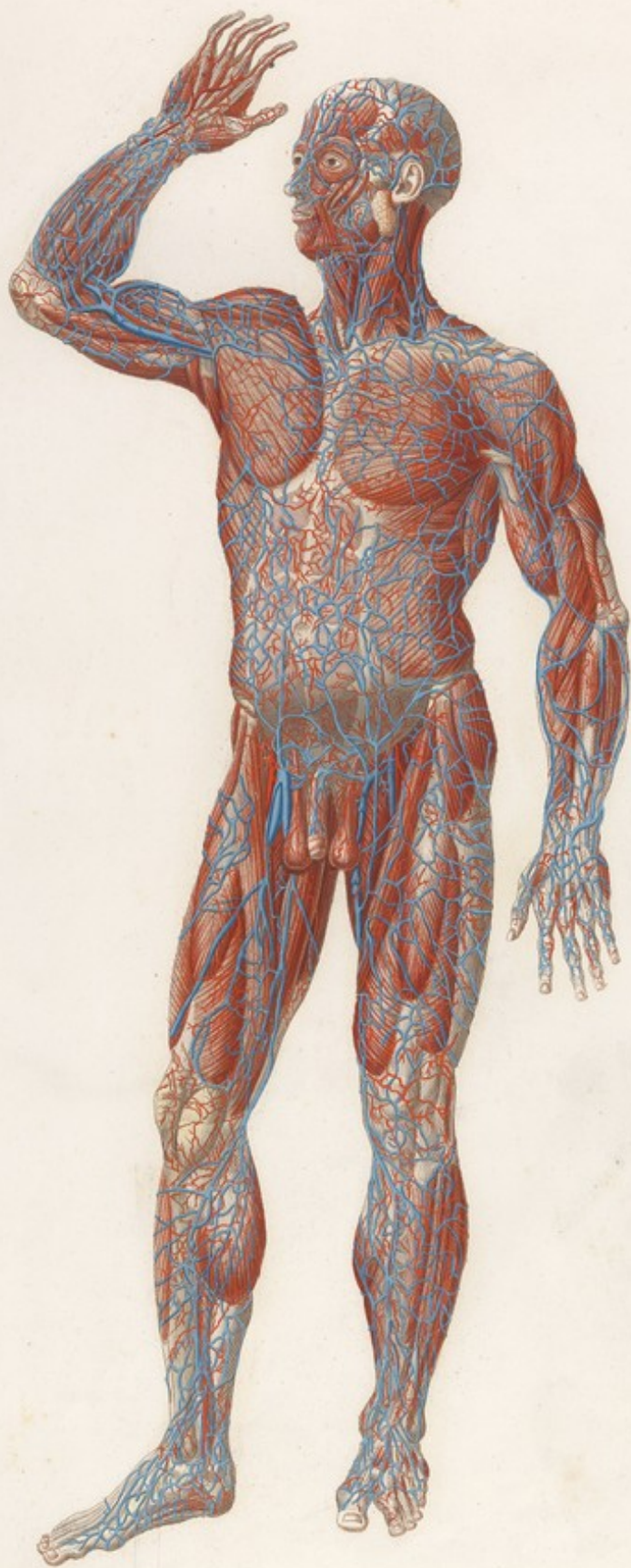




Alasagni VEDUTA ANTERIORE DEL CORPO UMANO Strato Primo Tav. I. Lin.







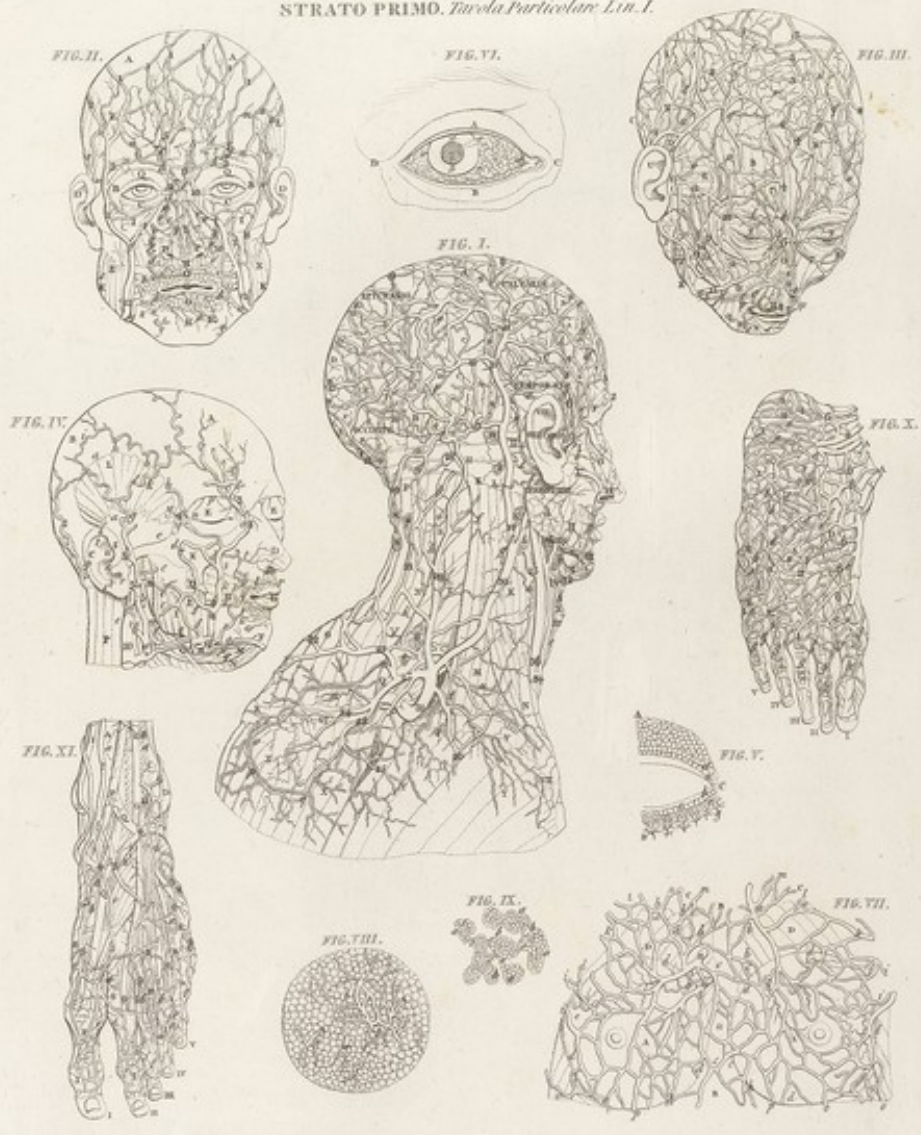





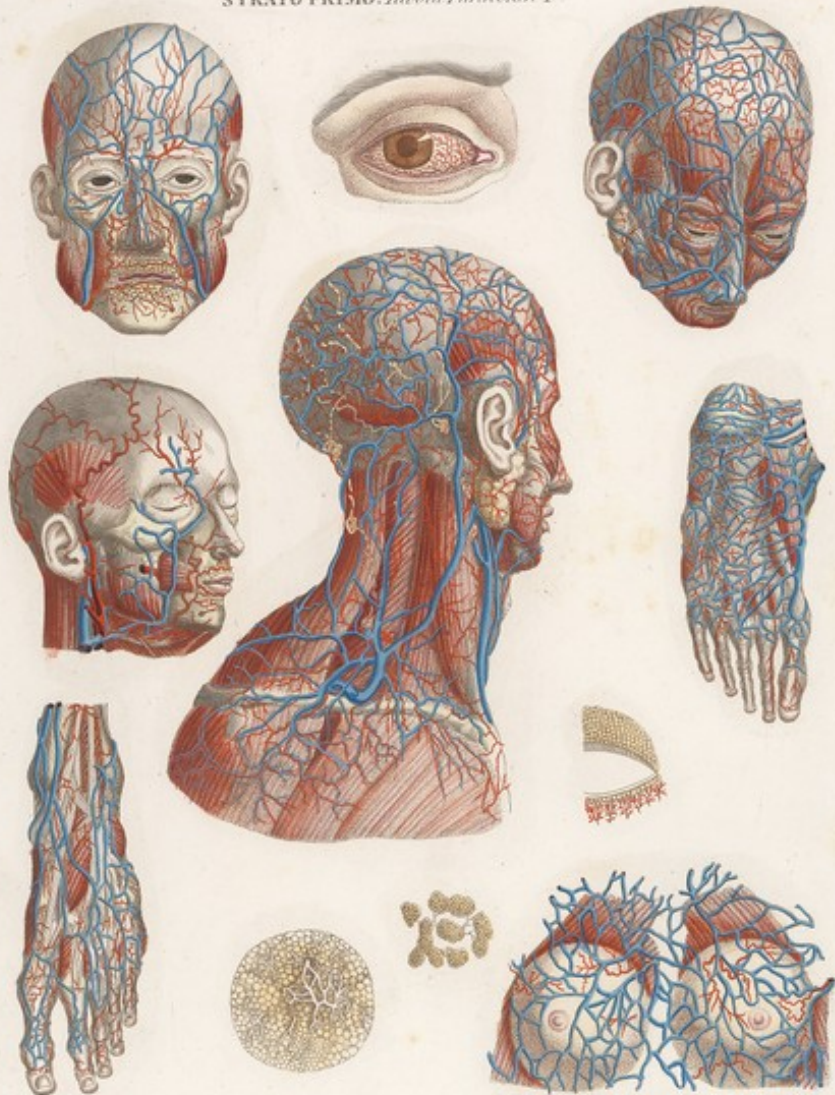


STRATO PRIMO. *Tabula Particulari. Lin. I.*




*Arteriae, Venae, Nervi, et Glandulae.*

STRATO PRIMO. Tavola Particolare I



*Aut. Scanzoni. Pin. Pin. & C.*

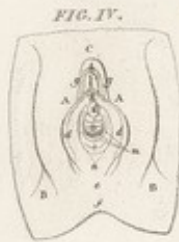
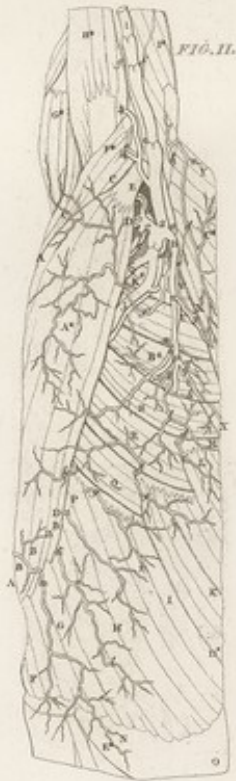
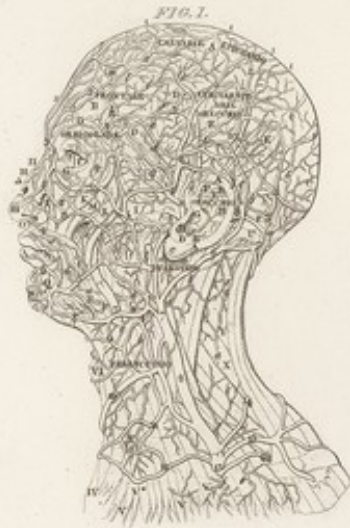
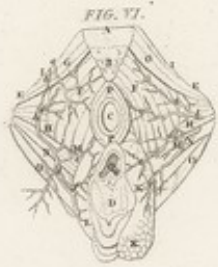
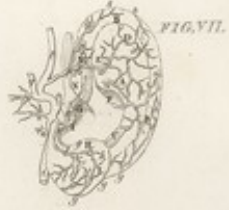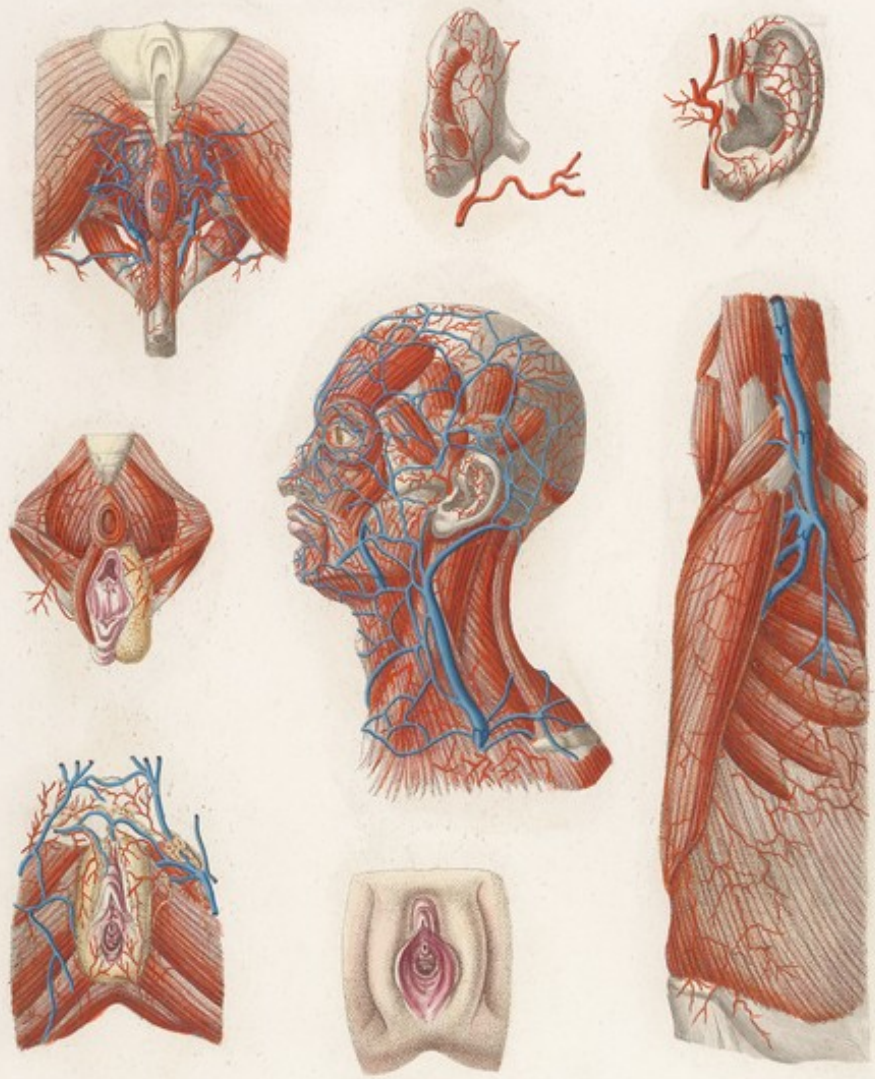




STRATO PRIMO. *Tavola Particolare Lin. II.*





STRATO PRIMO. *Tavola Particolare II*



*Admiranda Anatomia Strato Primi*

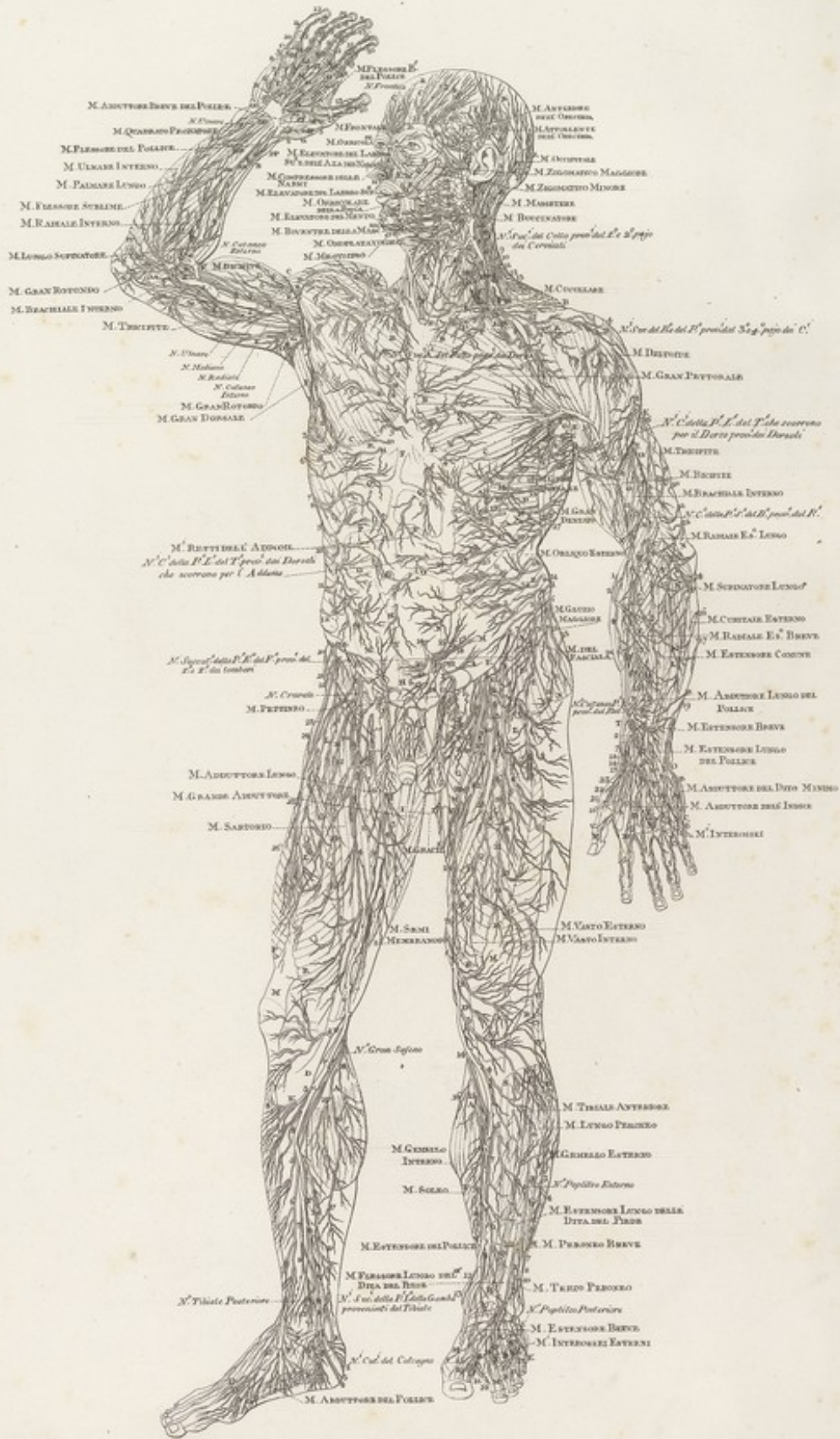




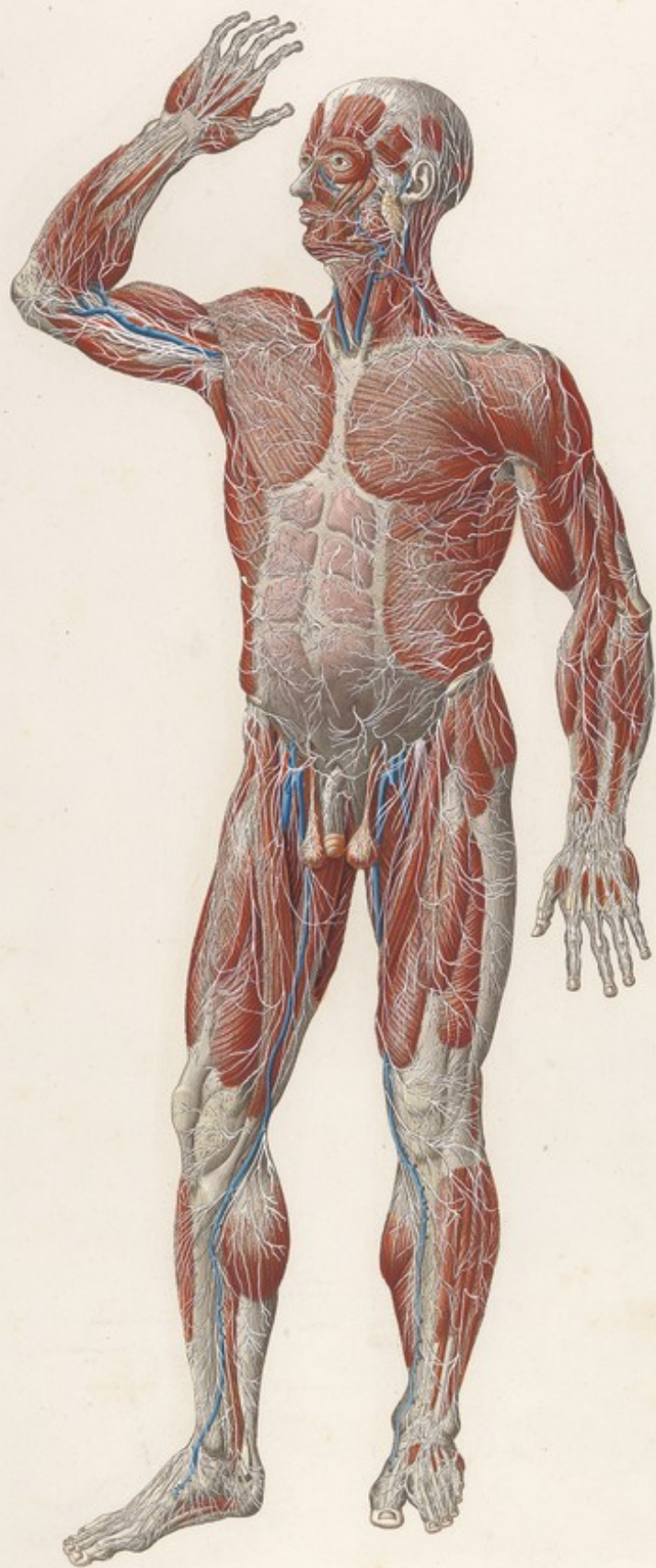



Mascagni VEDUTA ANTERIORE DEL CORPO UMANO *Strato Primo Tav. II. Lin.*















STRATO PRIMO. Tavola Particolare. Lit. III.

FIG. II.



FIG. III.



FIG. I.

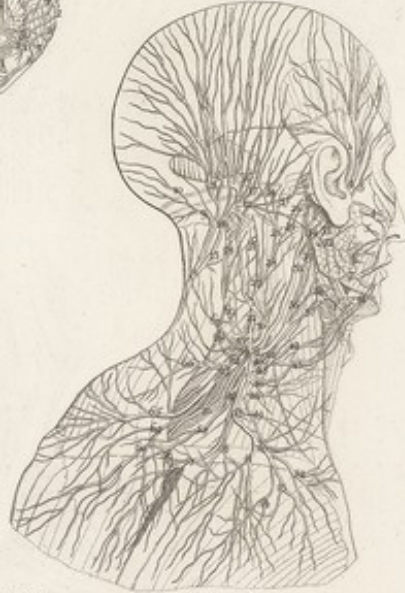

FIG. VI.



FIG. VII.



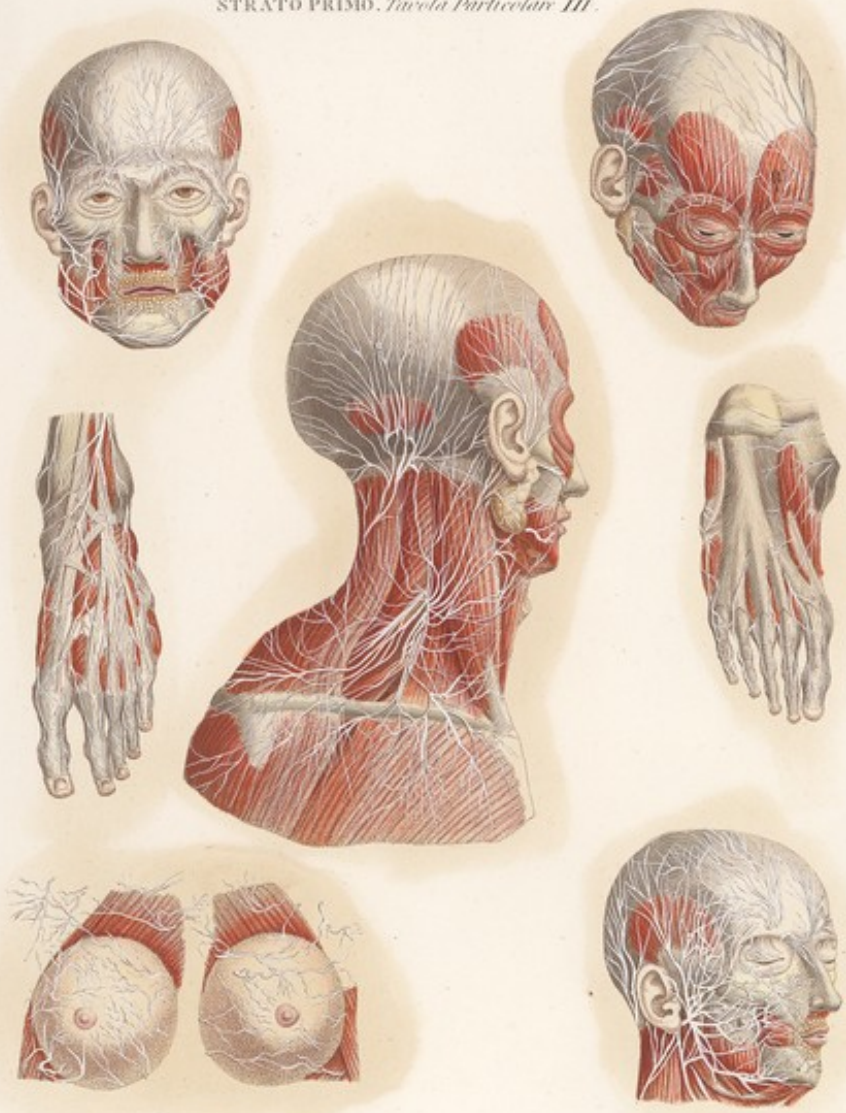
FIG. V.

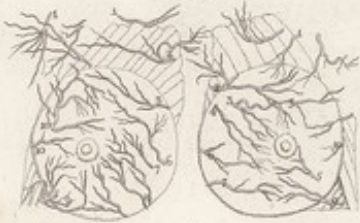

FIG. IV.



STRATO PRIMO. *Tavola Particolare III.*



*Tabula Anatomica Strato, faciei & manuum.*









STRATO PRIMO. *Tavola Particolare Lin. IV.*

FIG. III.



FIG. VII.



FIG. VI.



FIG. IV.



FIG. I.

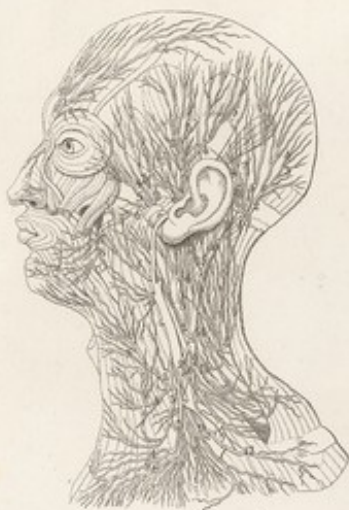

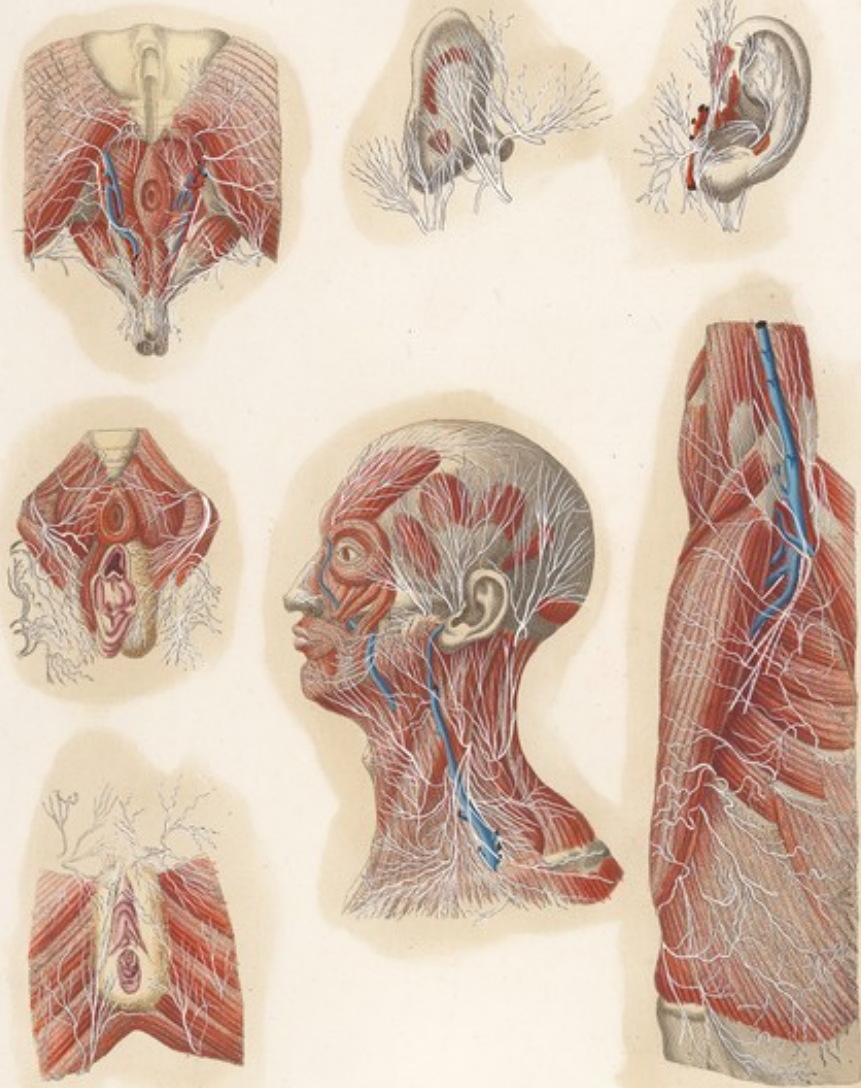
FIG. II.



FIG. V.

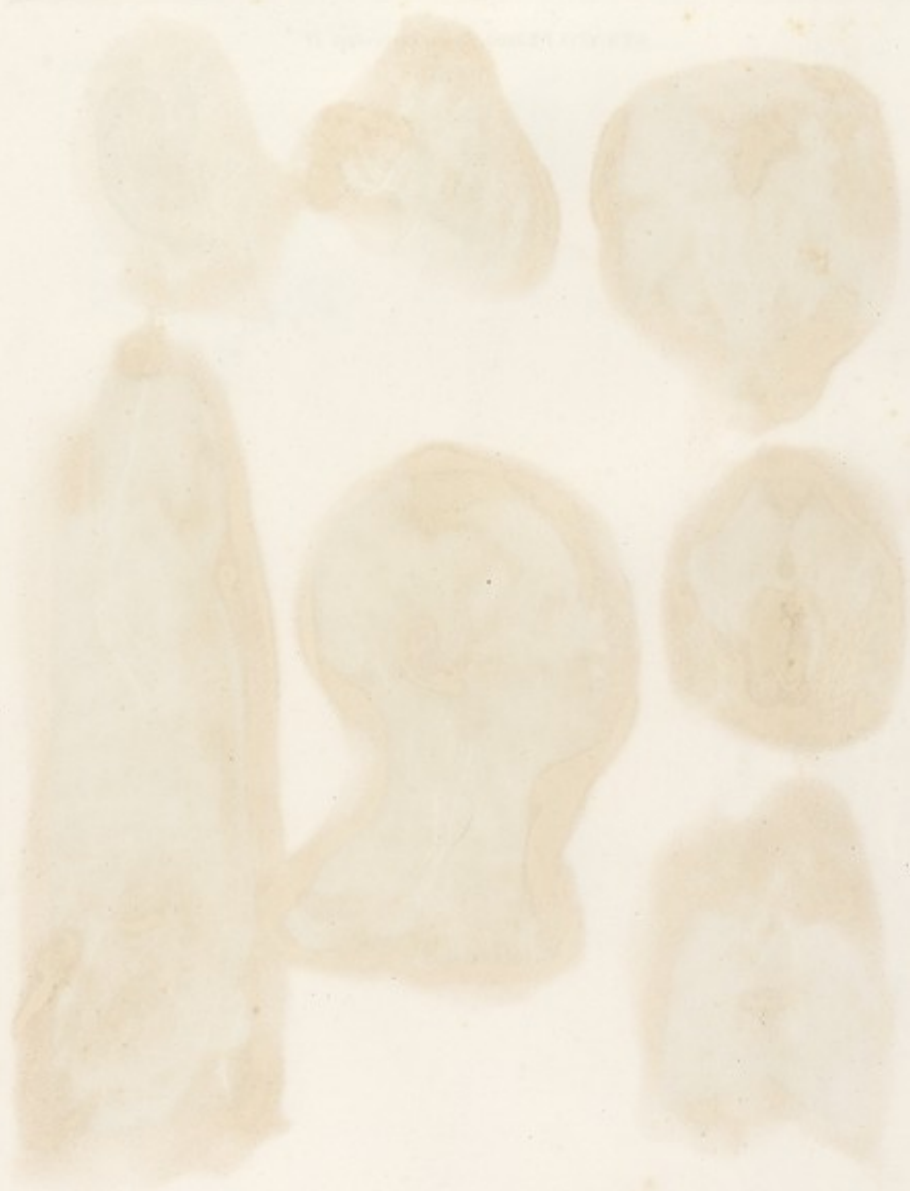

STRATO PRIMO. *Tavola Particolare IV.*



*Antus Scindus. Disquis. nerv. & colat.*

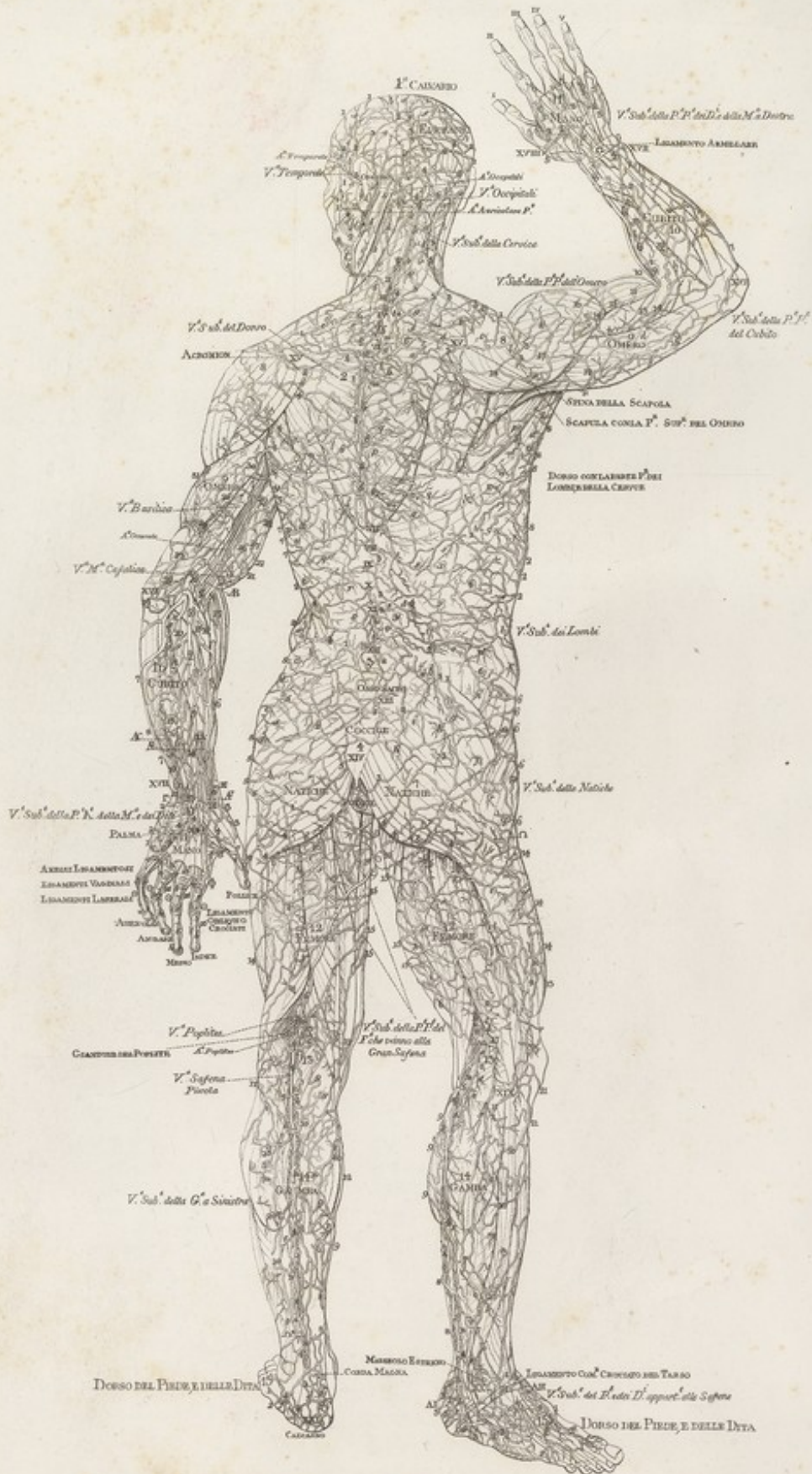




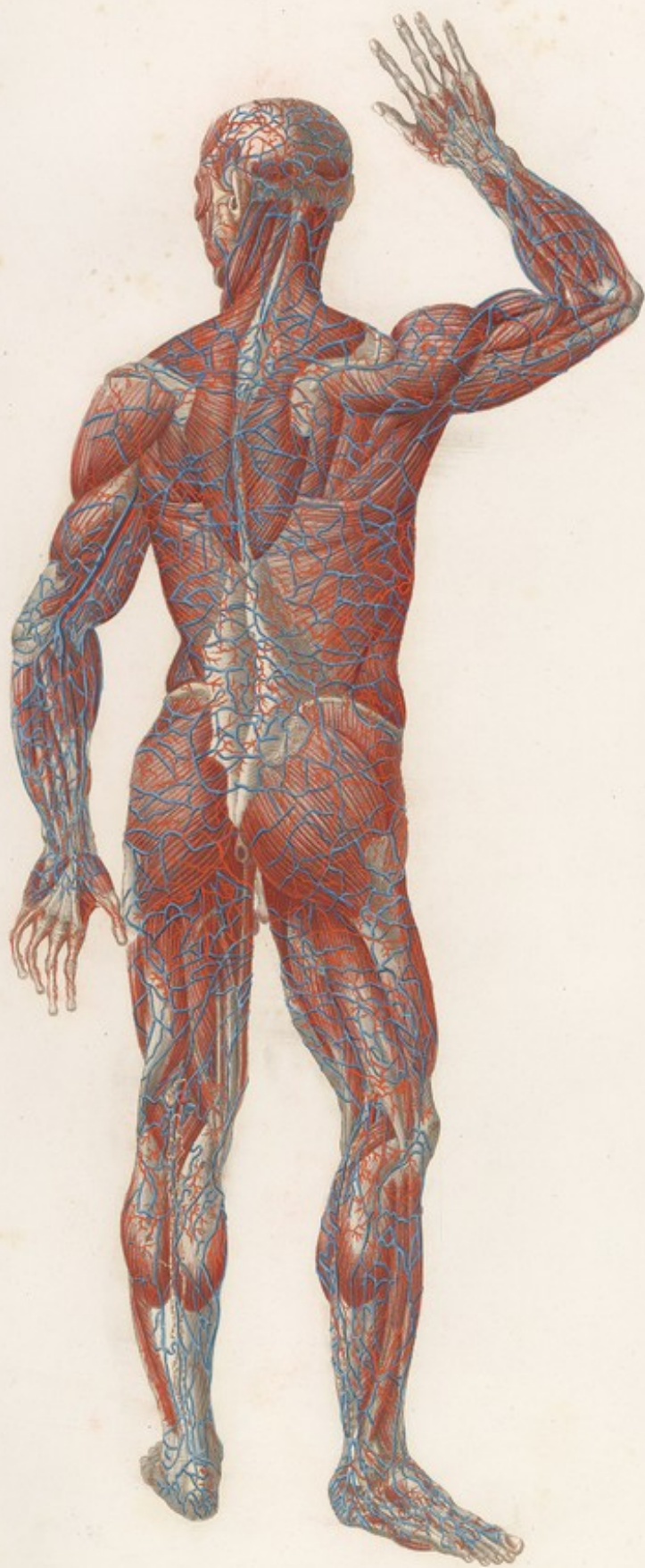




Mascagni VEDUTA POSTERIORE DEL CORPO UMANO Strato Primo Tav. III Lin.
















STRATOPRIMO *Tabola Particolare V. Lin.*

FIG. II.



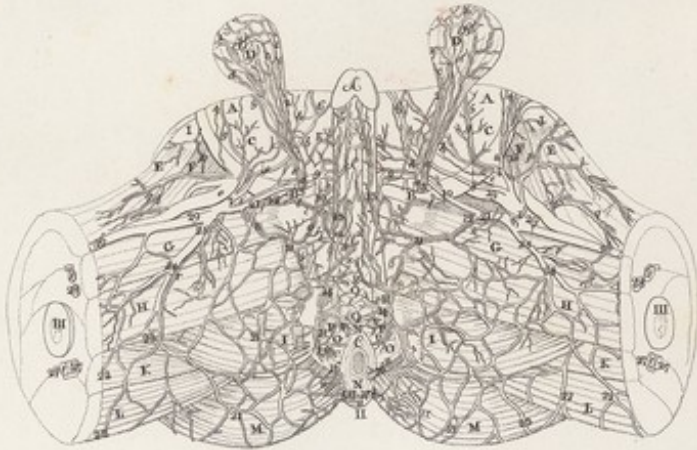
FIG. I.



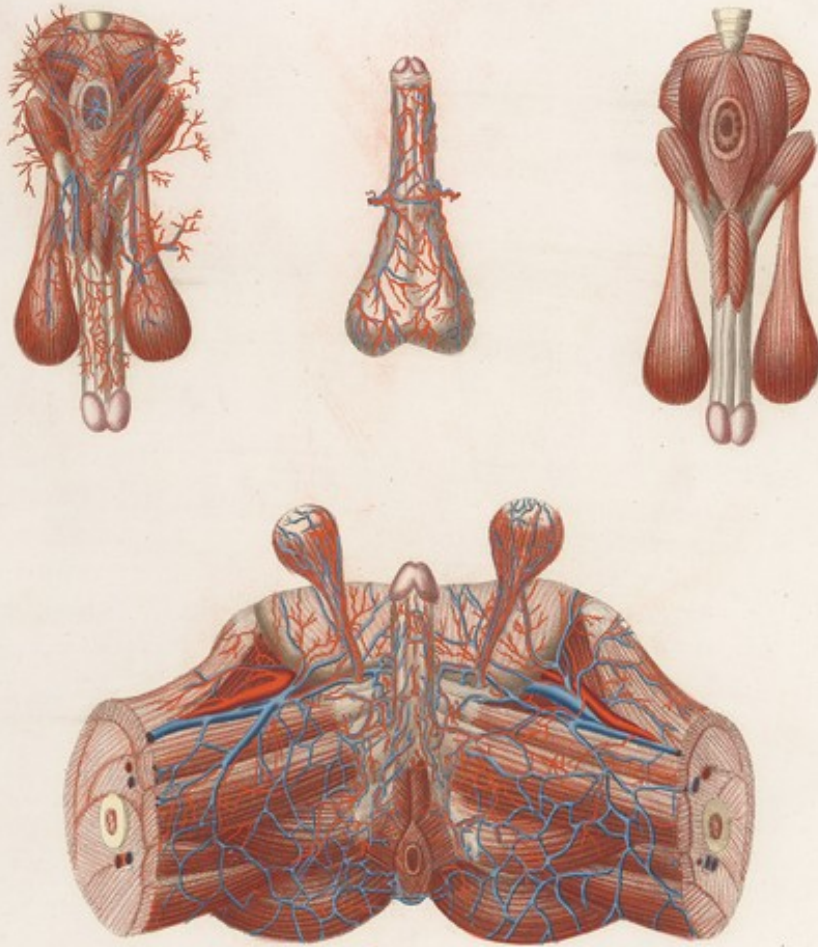
FIG. III.

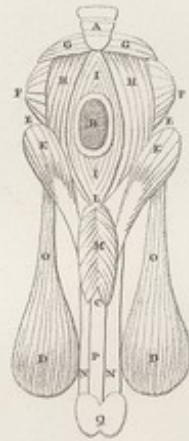

FIG. IV.




STRATO PRIMO *Tabula Particulari V.*



*Autore Jo. de Graaf. Sculpit. G. G. G. G.*





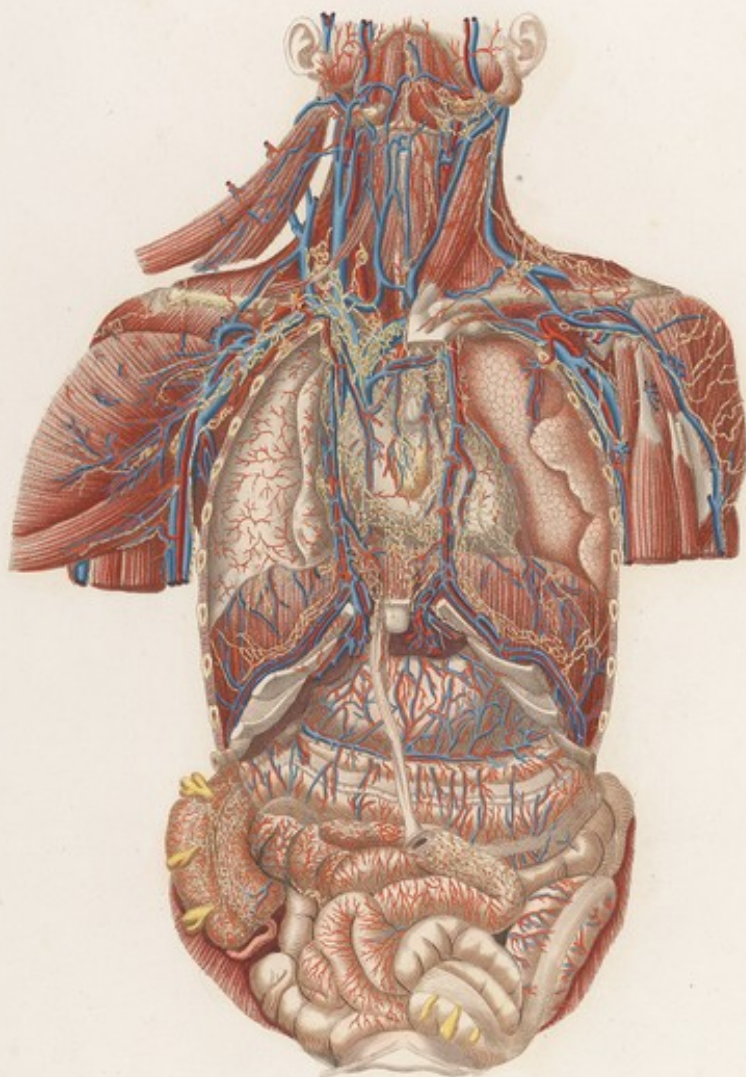




VISCERI Tavola I Lia.




VISCERI Tavola I.



*Adriano Panzani del. G. B. Rossi sculp.*

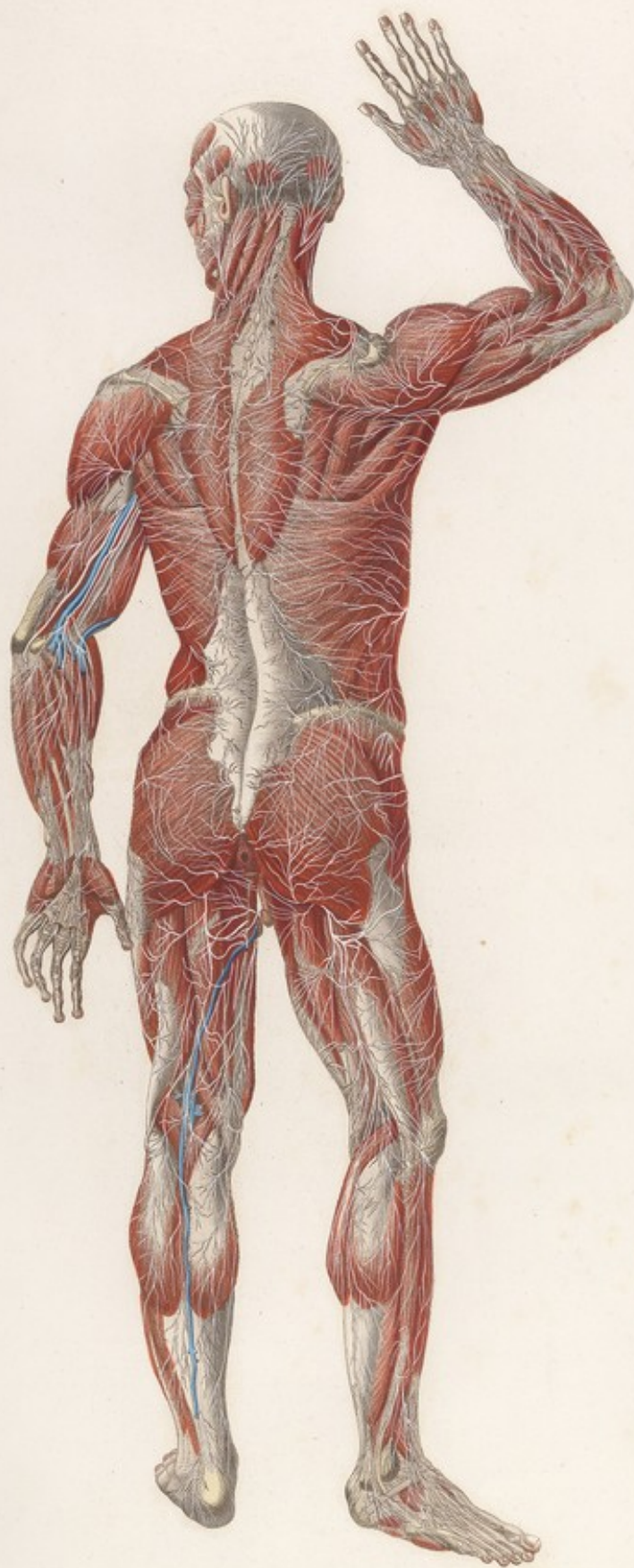



















STRATO PRIMO. *Tavola Particolare VI. Lin.*

FIG. II.



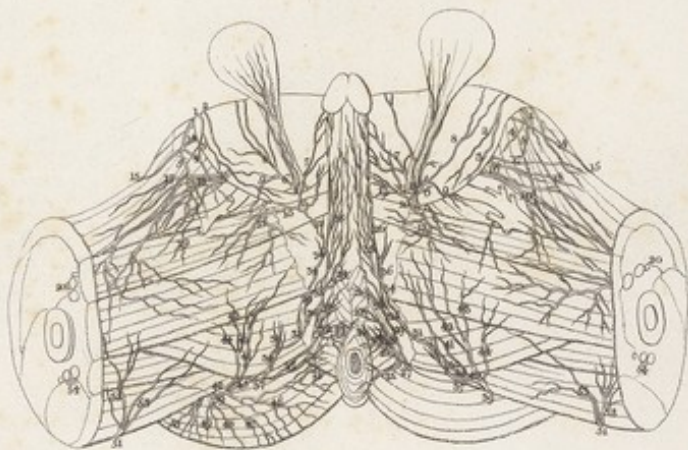
FIG. I.

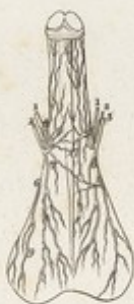

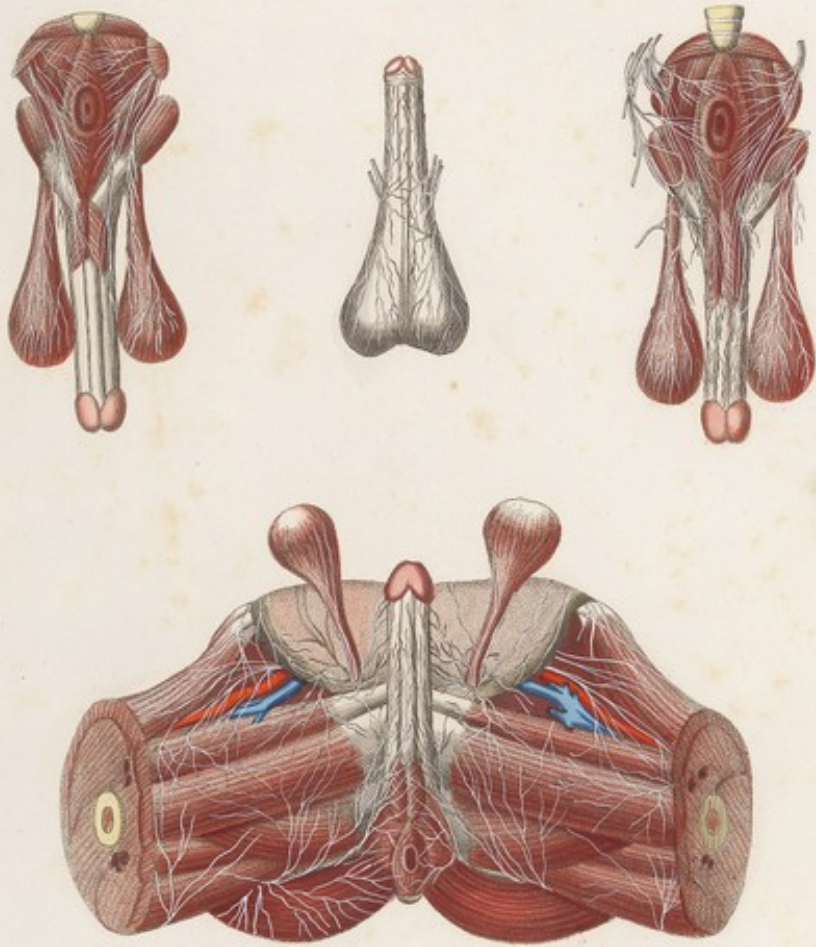
FIG. III.




FIG. IV.




STRATO FRIDIO. *Lavata Particolare VI.*



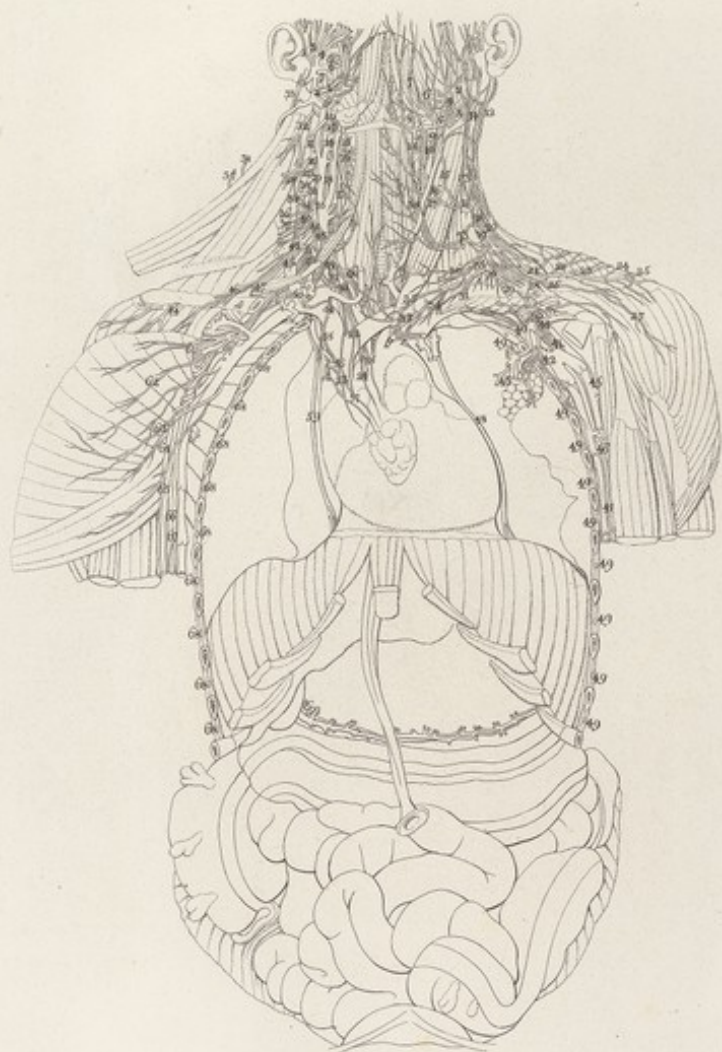


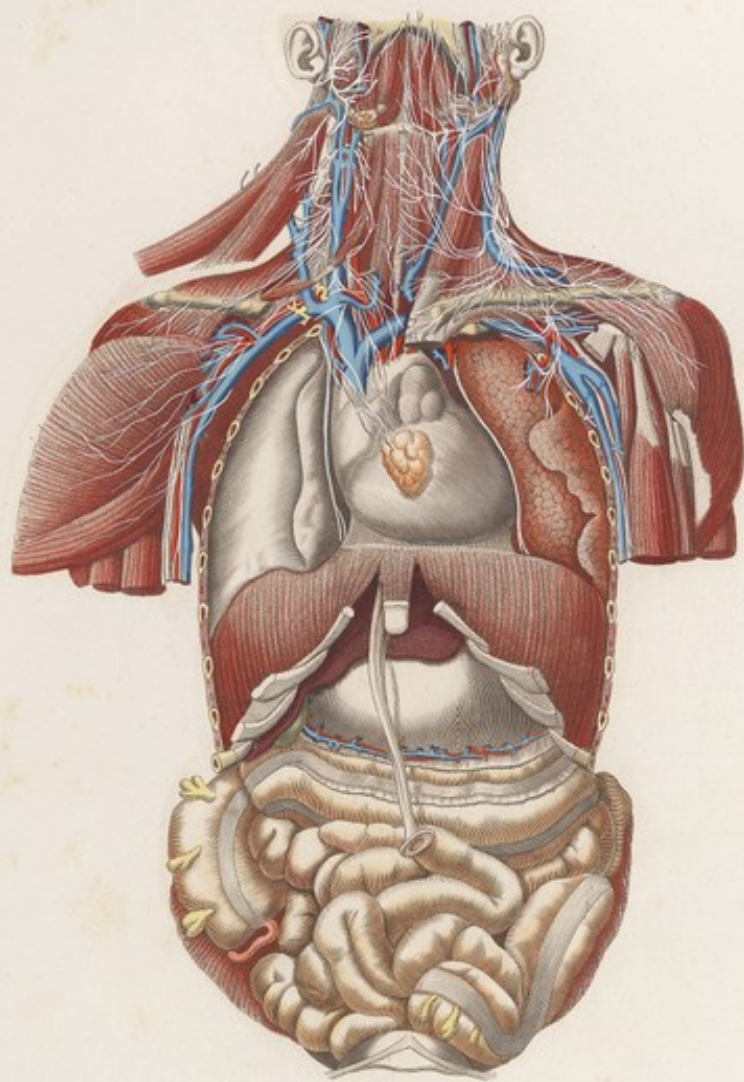







VISCERI Tavola II. Lin.





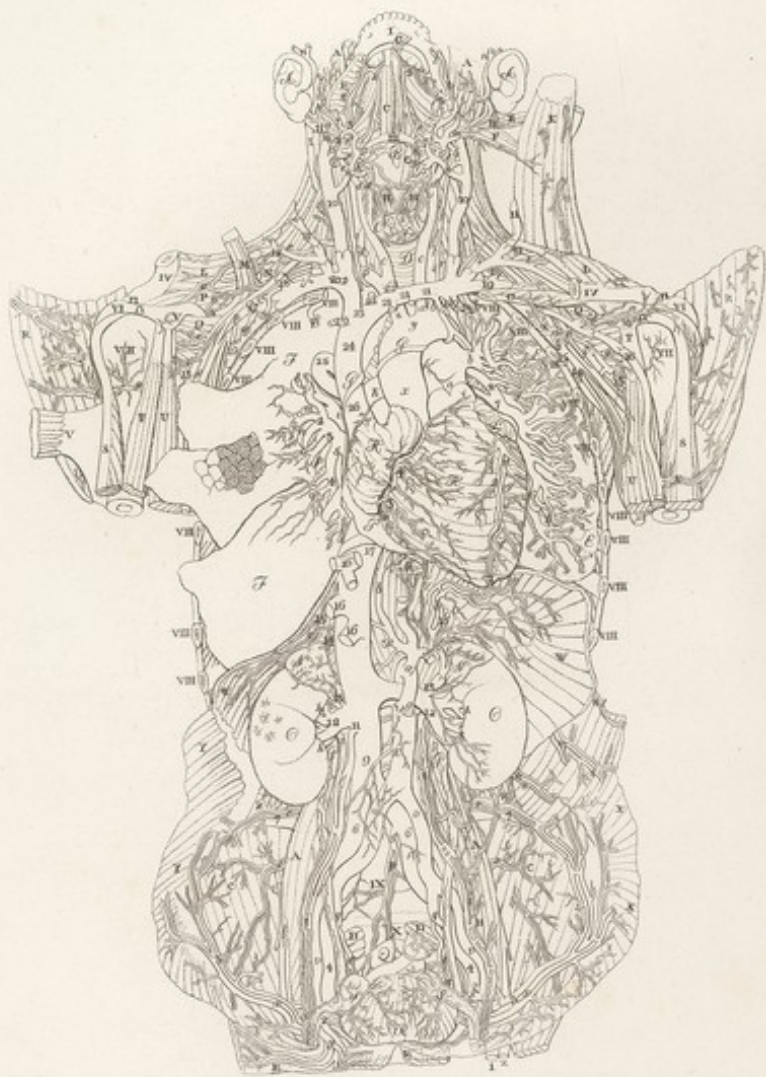



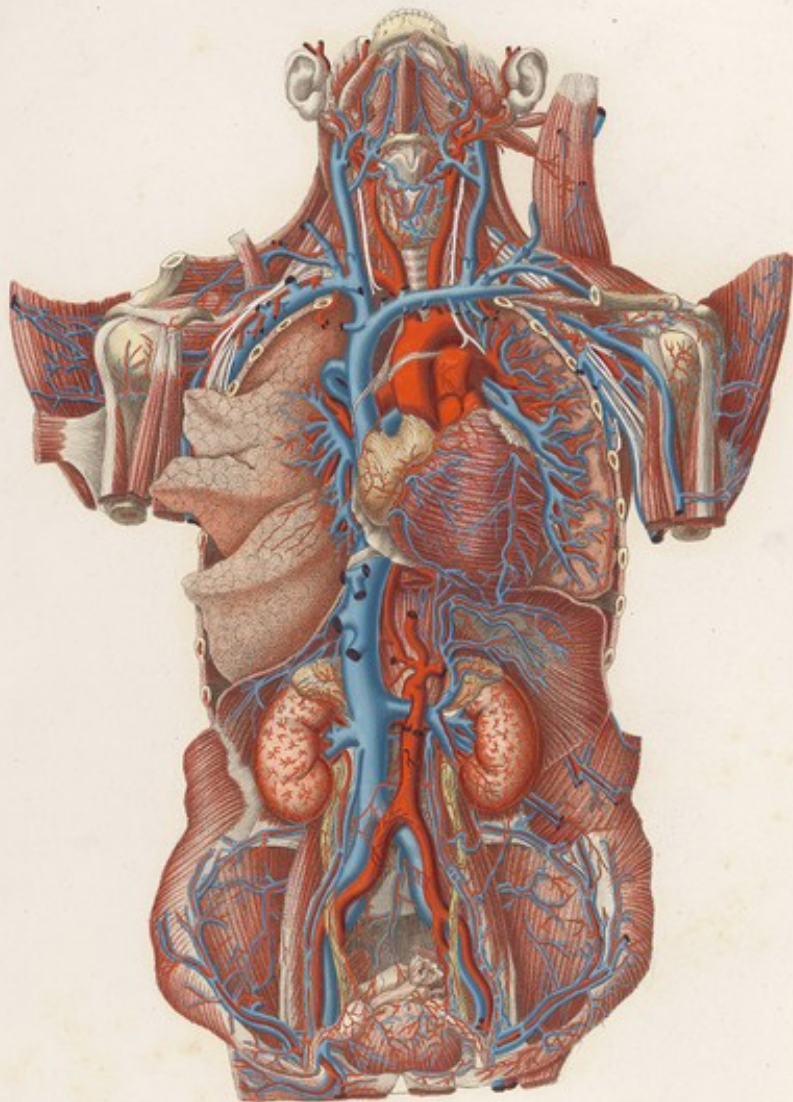




VISCERI Tavola Lin. III.




VISCERI. *Tav. III.*



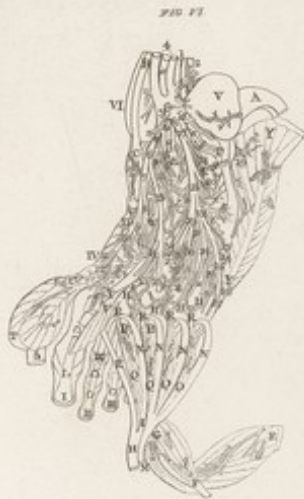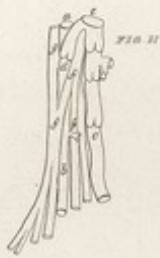*Antoni. Sculp. del. et sculpsit.*

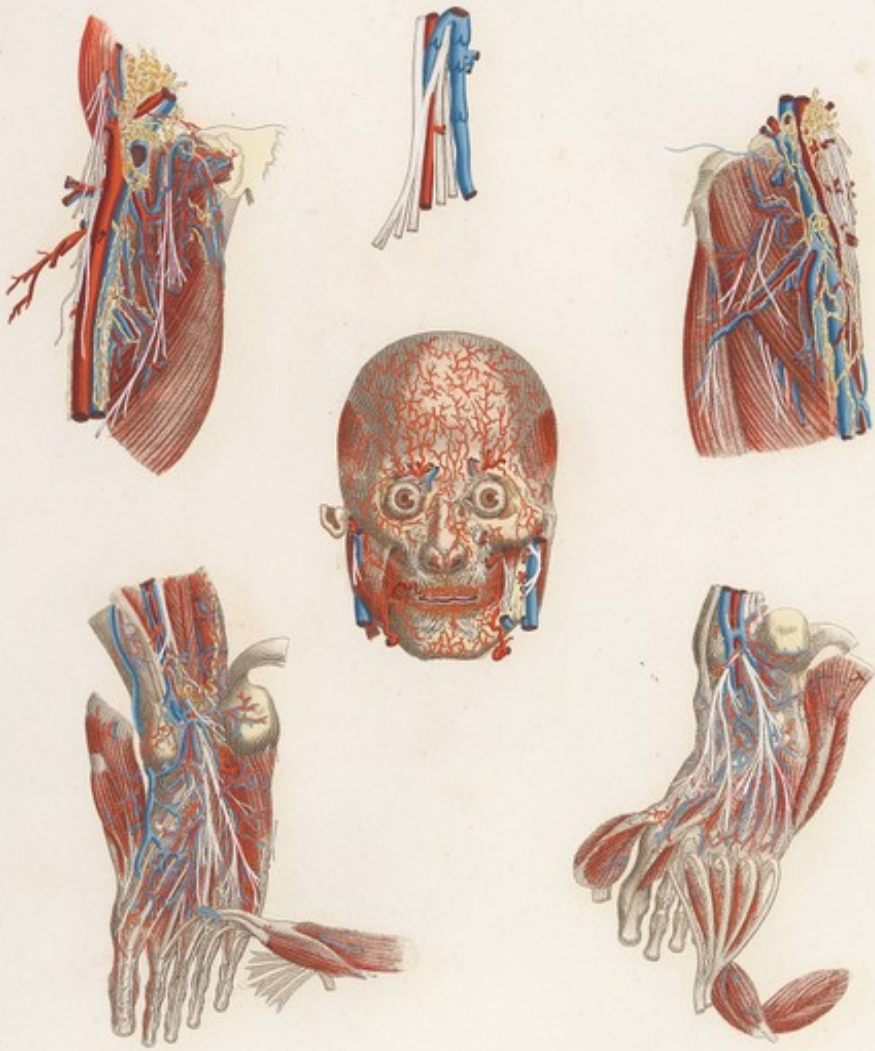













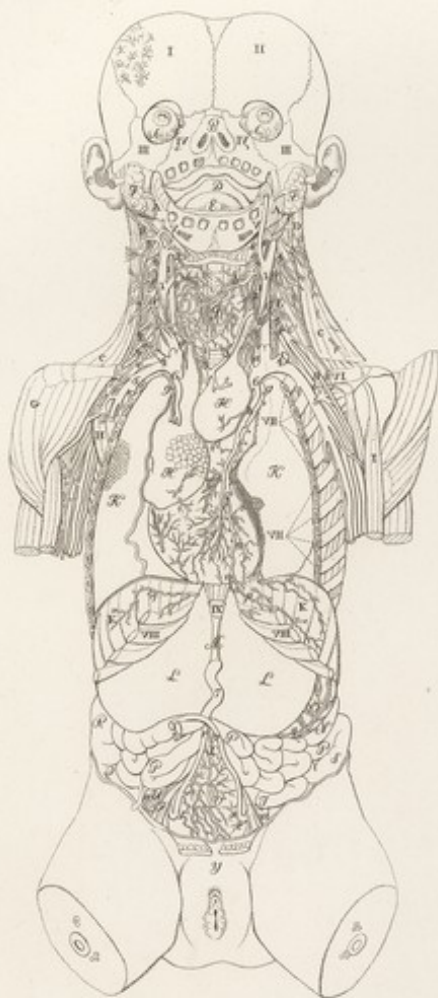




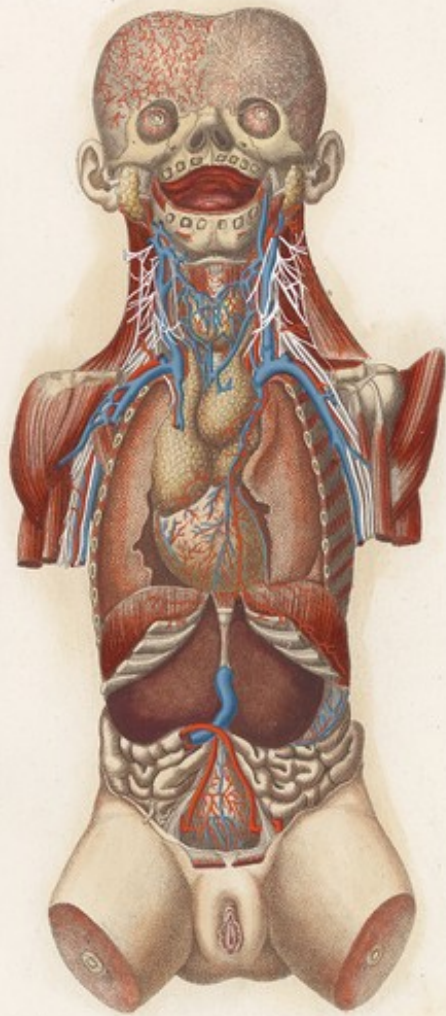




VISCERI Tavola IV. Lin.




VISCERI Tavola II.



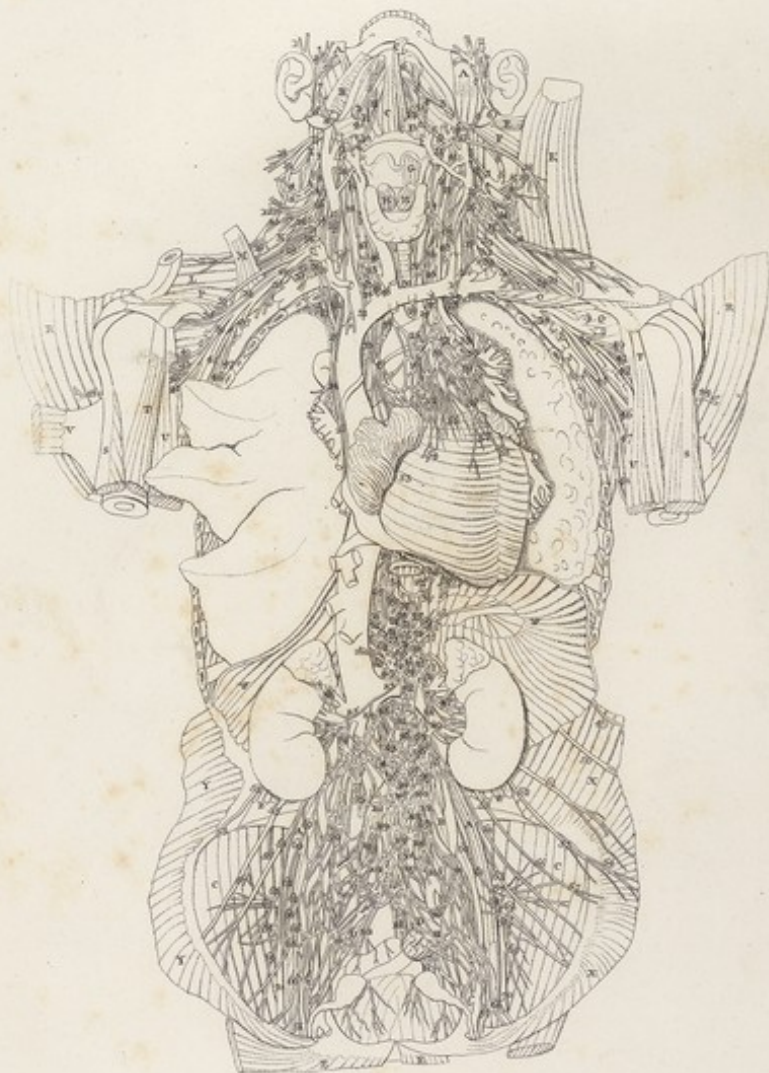



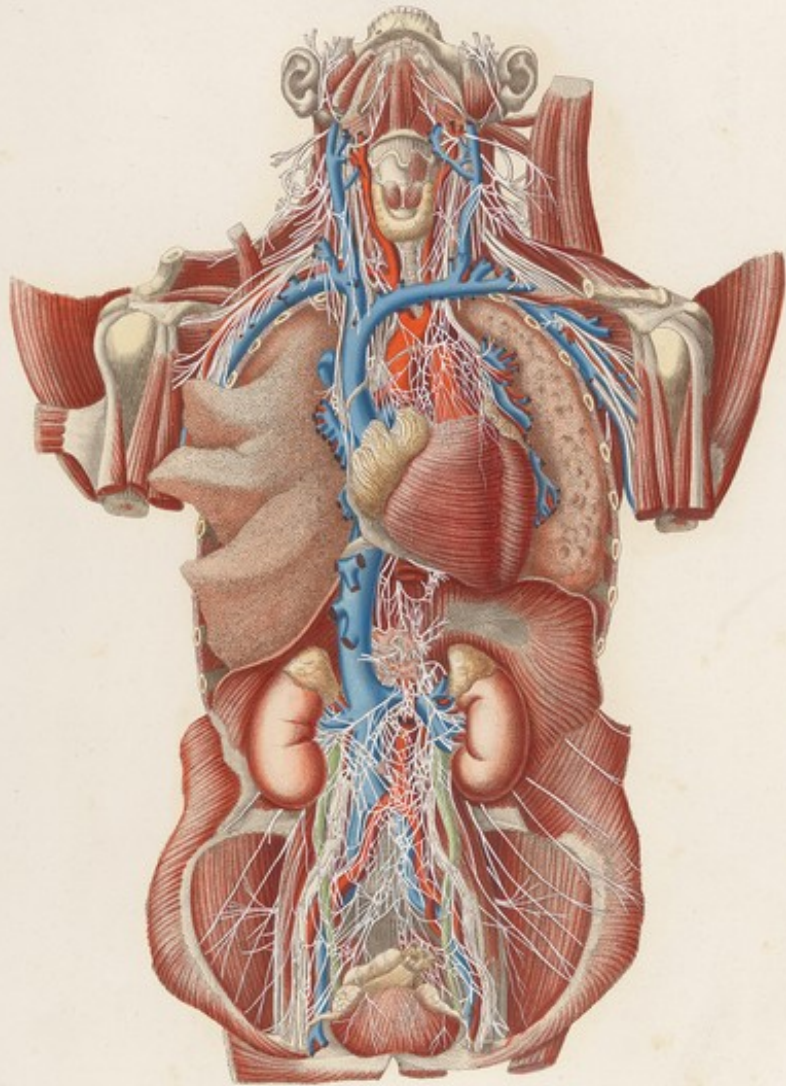




VI  
VISCEA Tab. VIa.




VISCERI *Tab. V*



*Tab. V. Visceri. Tab. V.*





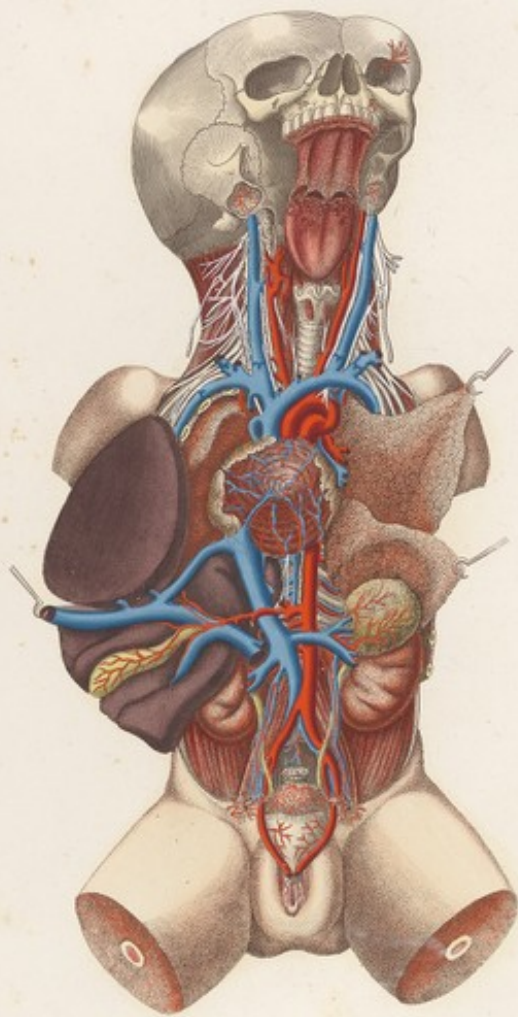




VISCERI Tab. VI. Loo.




VISCERI Tavola VI.



*Tab. VI. Visceri.*









VISCERI Tab. VII. Lva.

FIG. III.

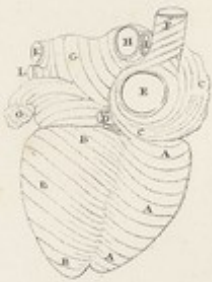

FIG. II.

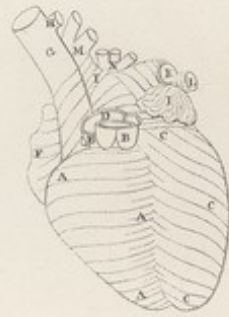


FIG. I.

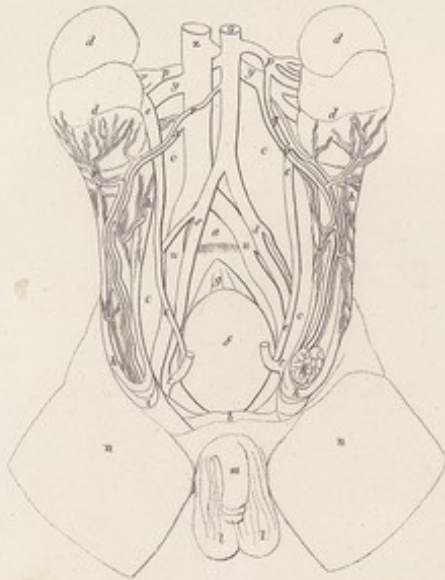
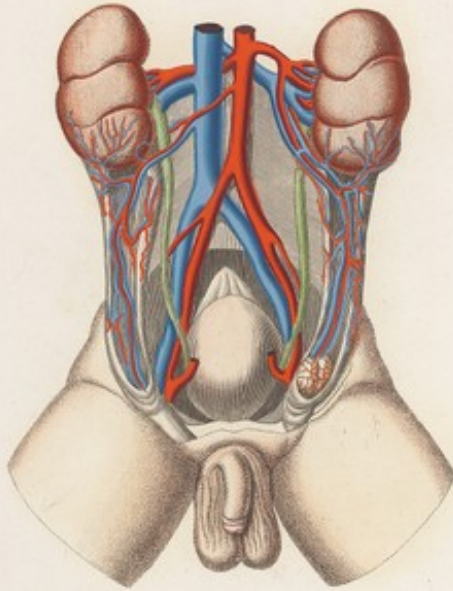



FIG. V.

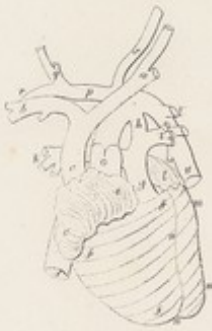
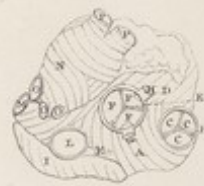
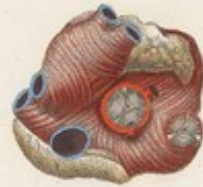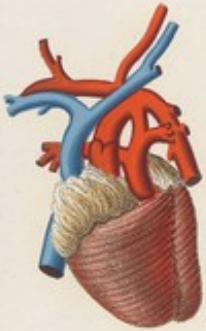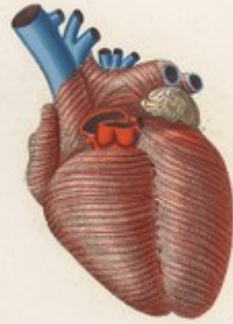FIG. IV.



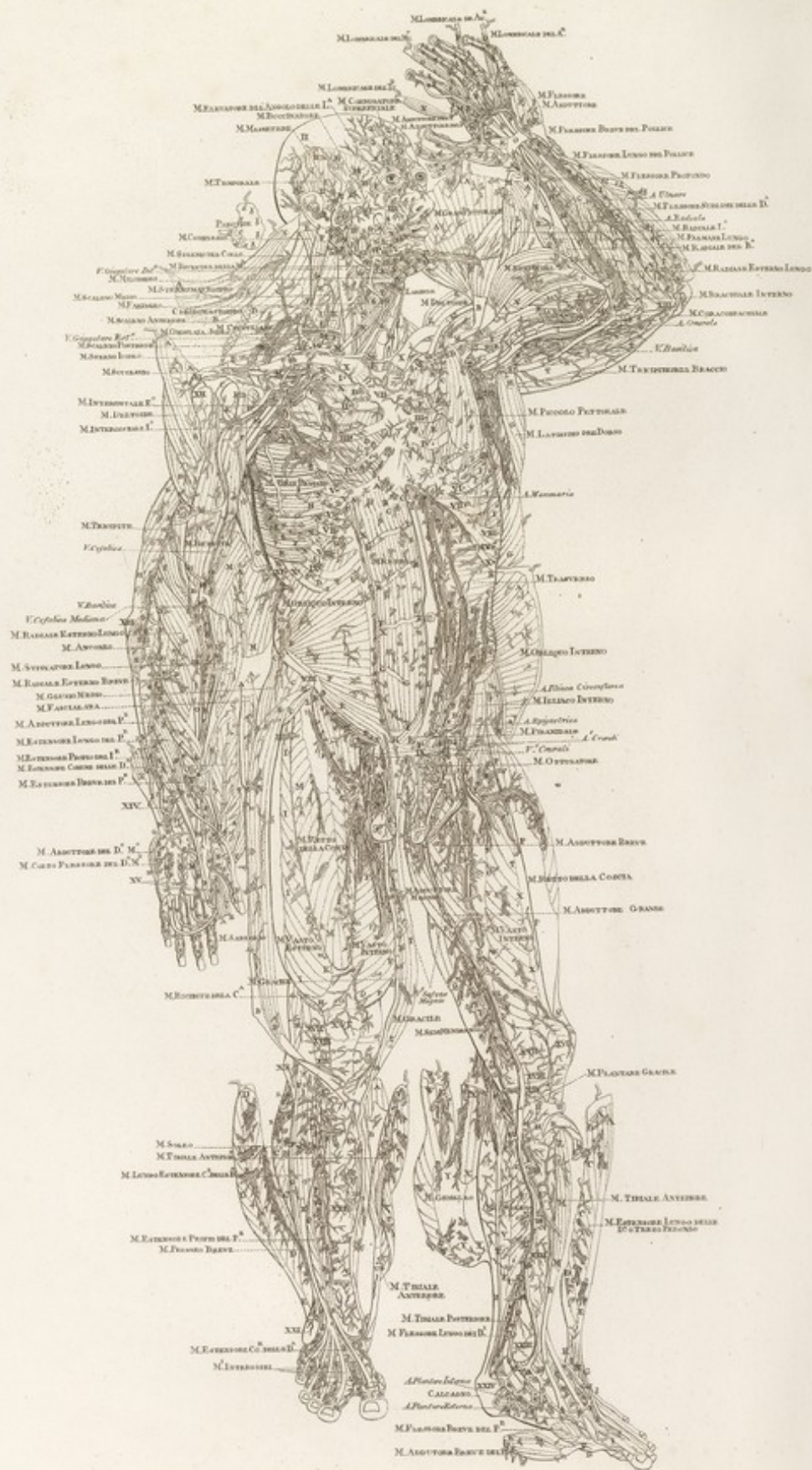




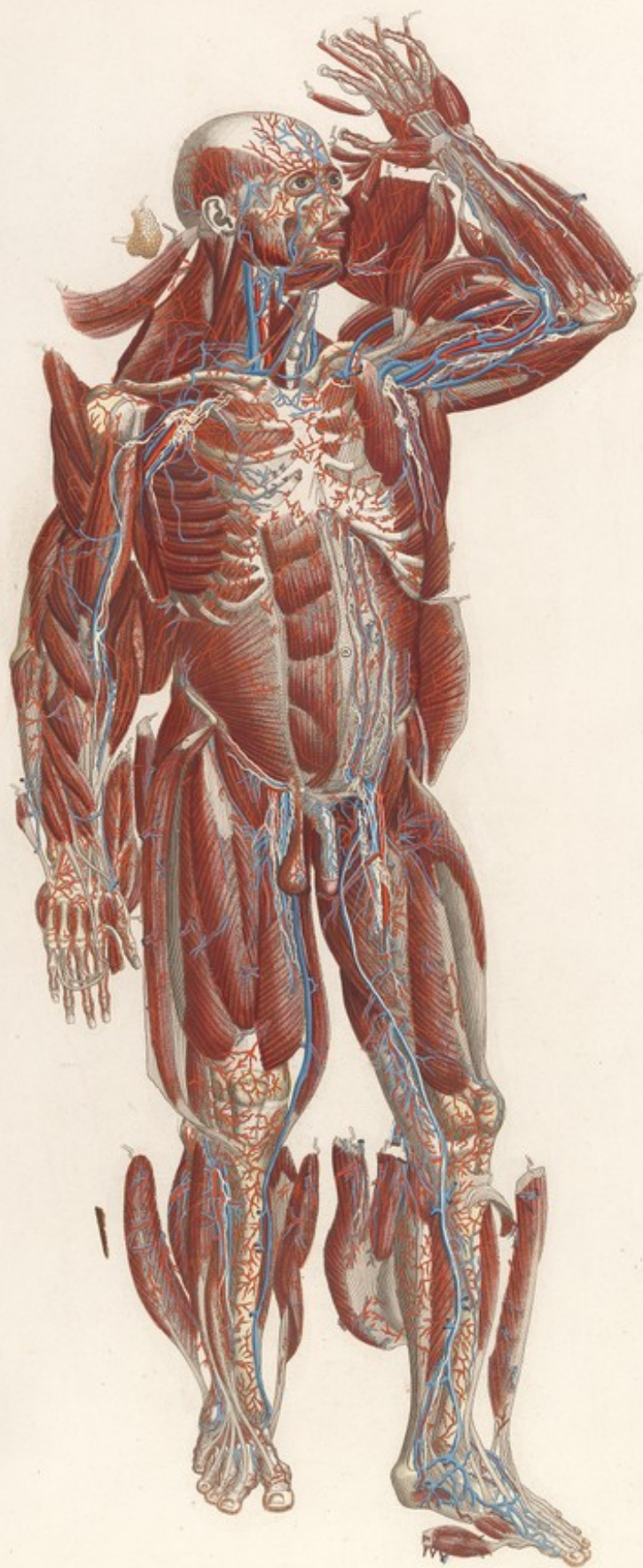





Mascagni VEDUTA ANTERIORE DEL CORPO UMANO *Tratto Secondo Tav. V. Lin.*
















TAVOLA PARTICOLARE. VI. *Lin.*

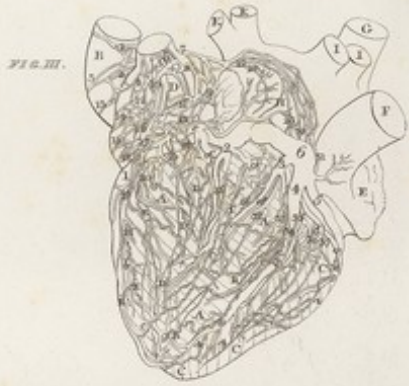
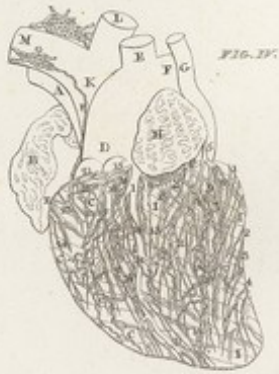

FIG. I.

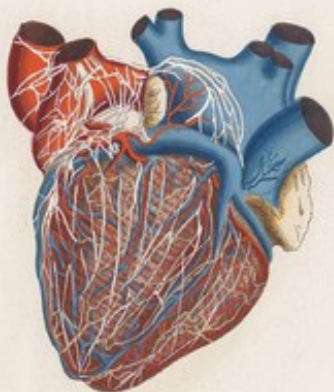


FIG. II.

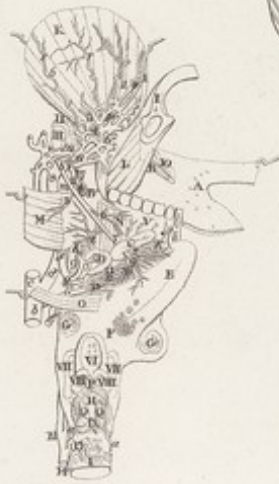
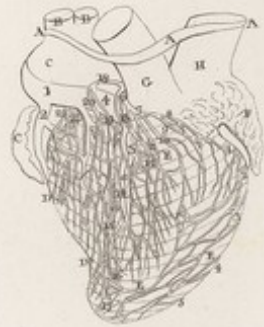
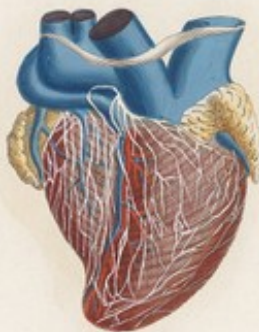
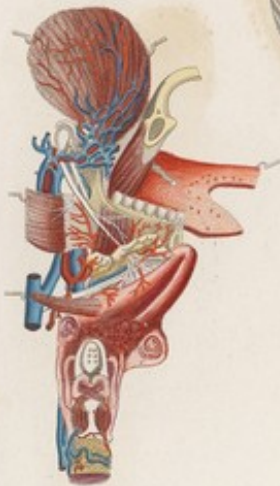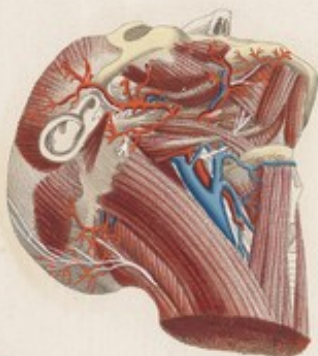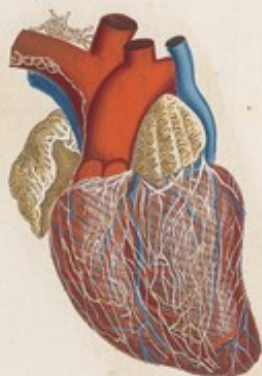FIG. V.













VISCERI. Tab. VIII. Lin.

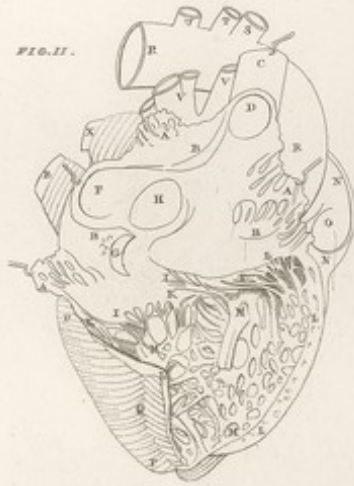

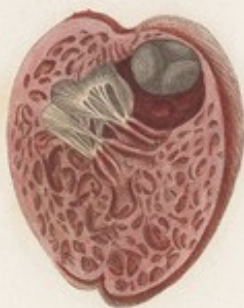
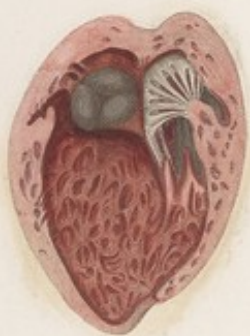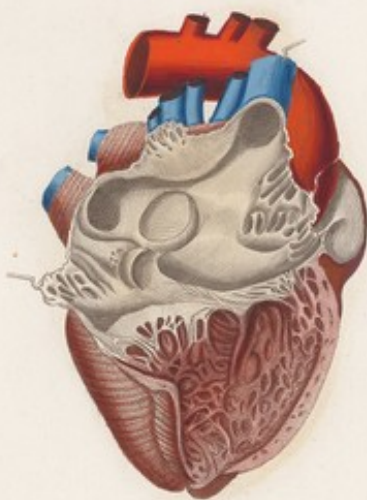
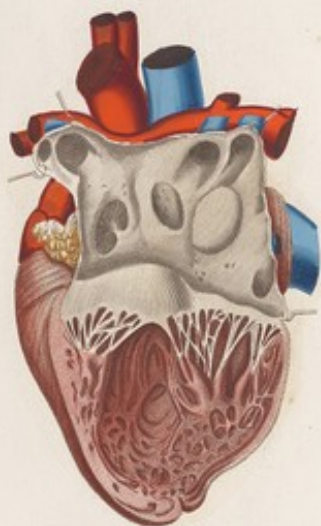FIG. III.



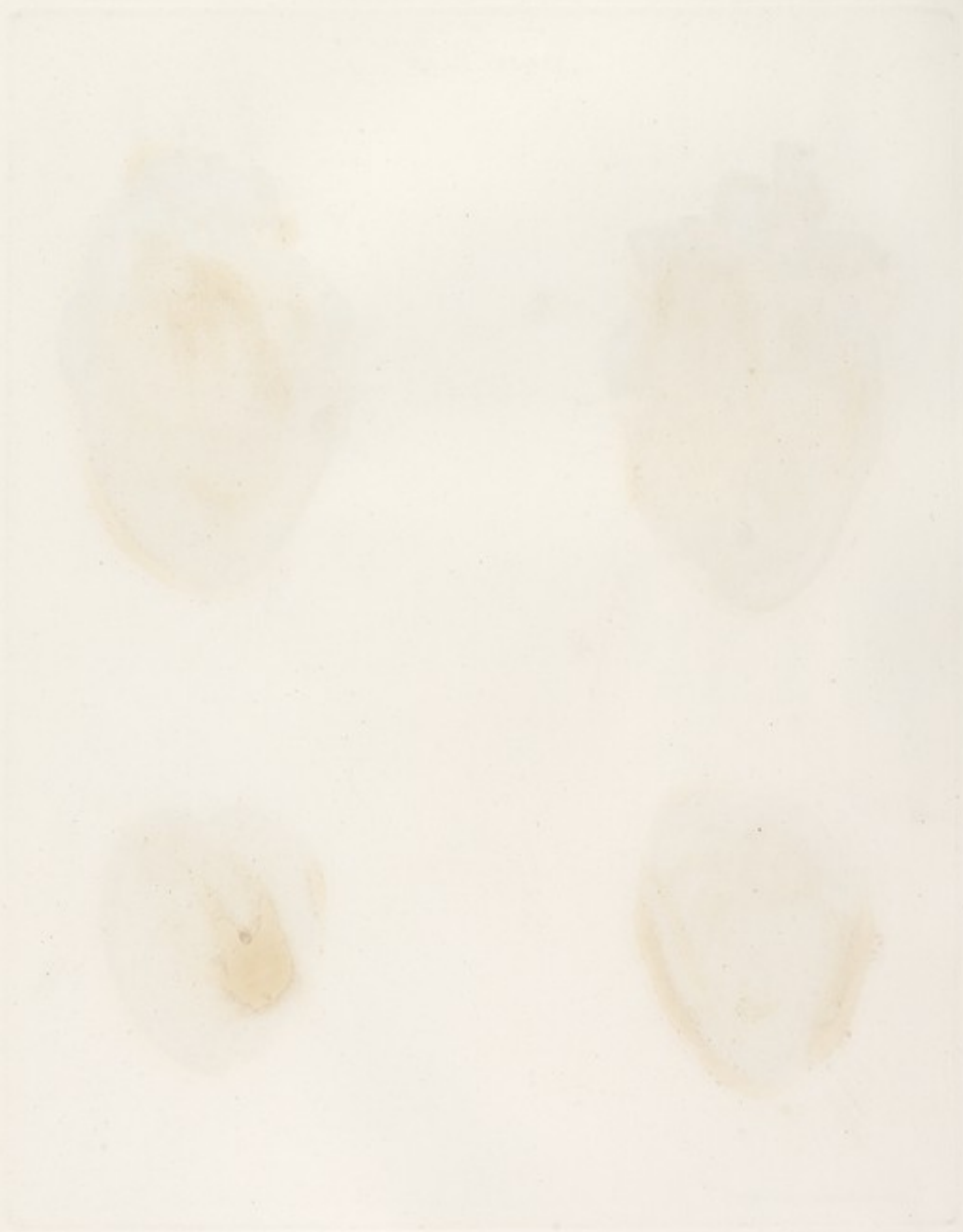FIG. IV.




VISCERI Tab. VIII

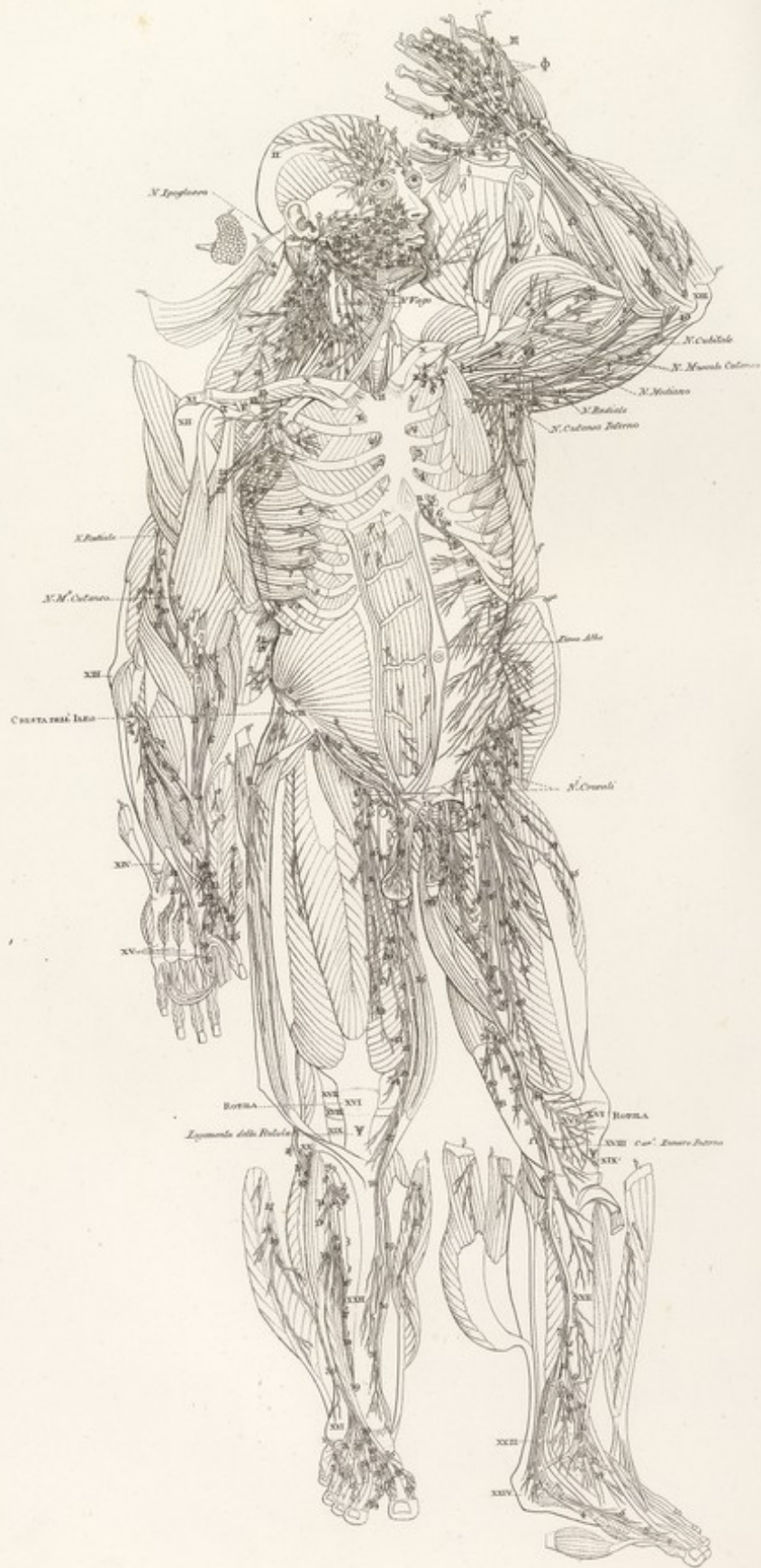


*Arteria pulmonalis, Vena cava inferior & aorta*











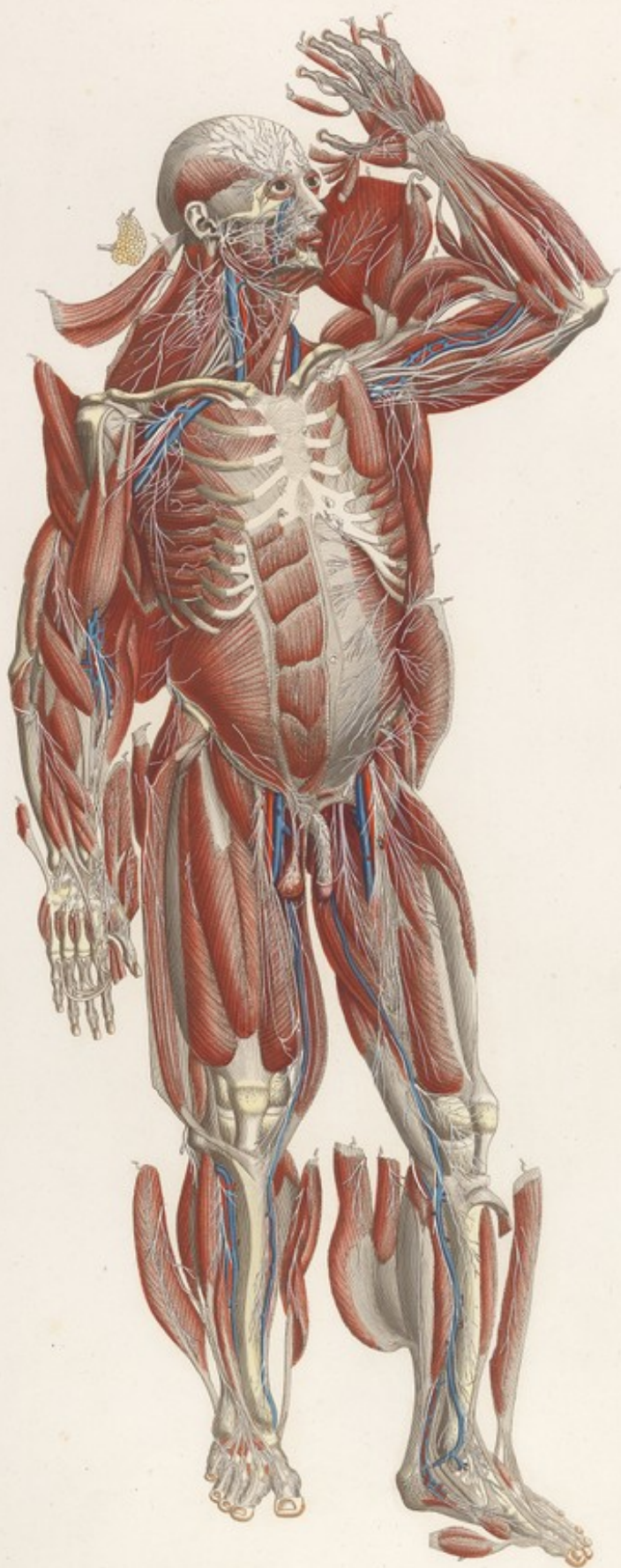










TAVOLA PARTICOLARE VII. Lo.

FIG. I.

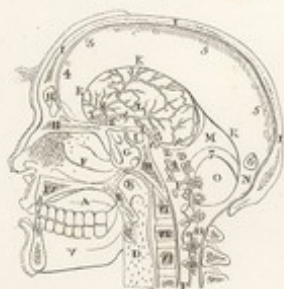

FIG. II.

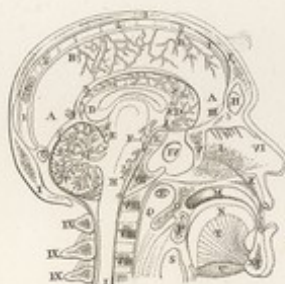

FIG. IV.

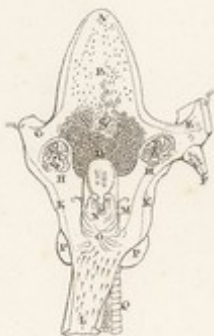
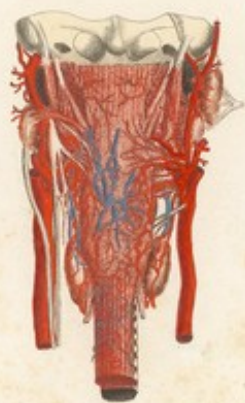
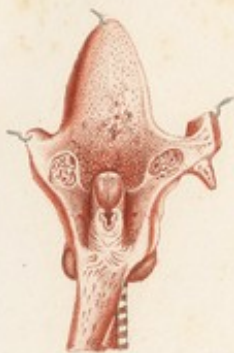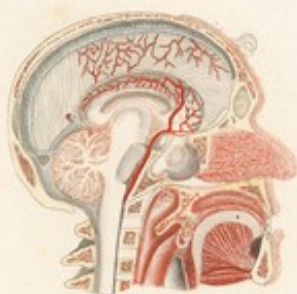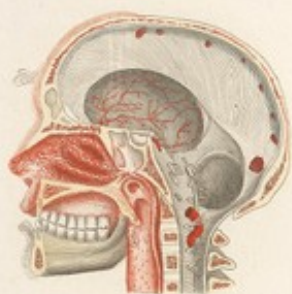FIG. III.



TAVOLA PARTICOLARE VII.



*Altera Pars dissectionis a. c. c.*










TAVOLA ARTICOLARE VIII. L<sup>ta</sup>.

FIG. III.

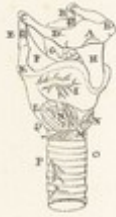

FIG. XII.



FIG. I.

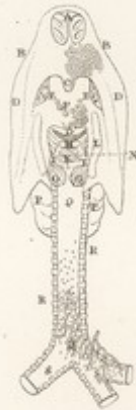

FIG. VIII.

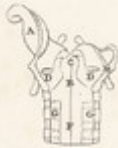

FIG. XI.

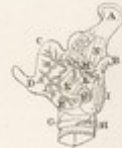

FIG. V.

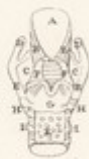

FIG. II.

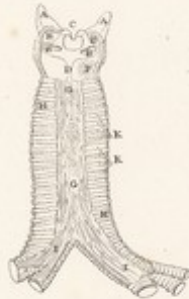
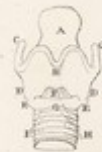
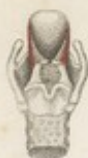
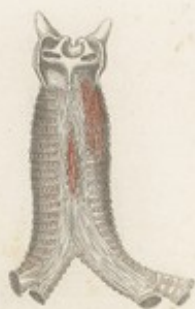FIG. IV.




TAOLA PARTICOLARE VIII.

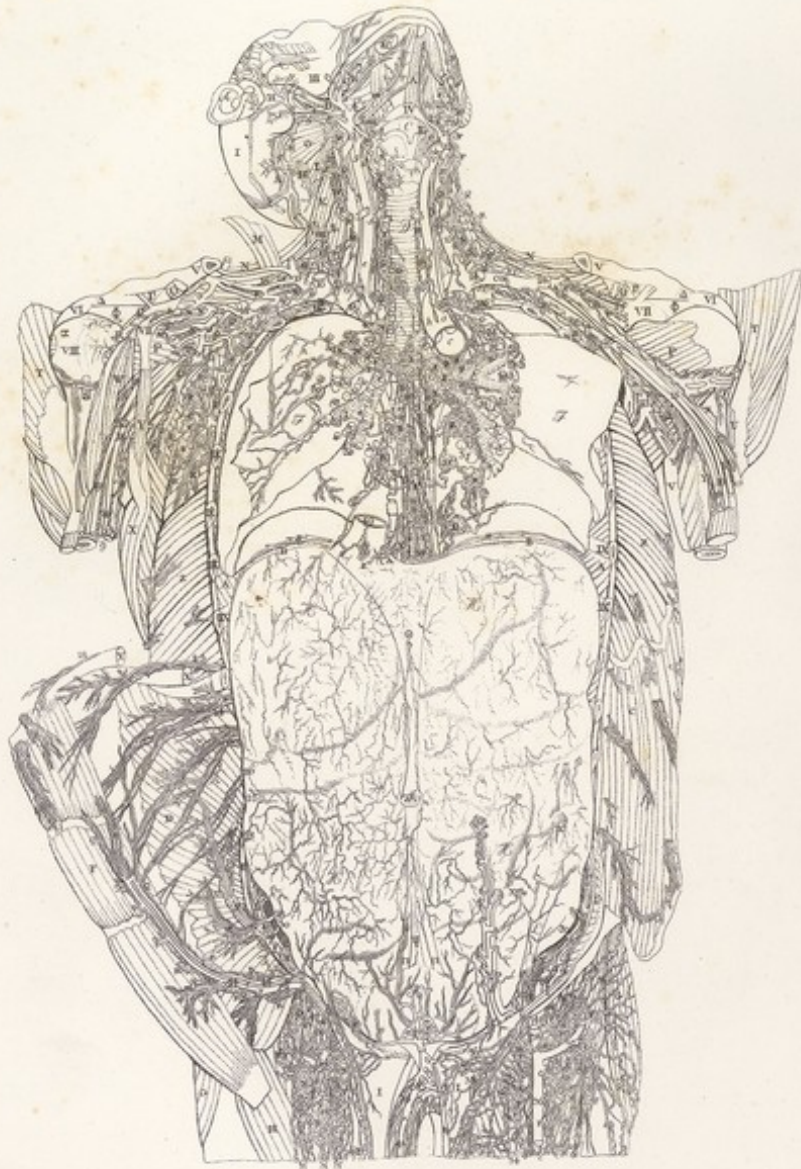





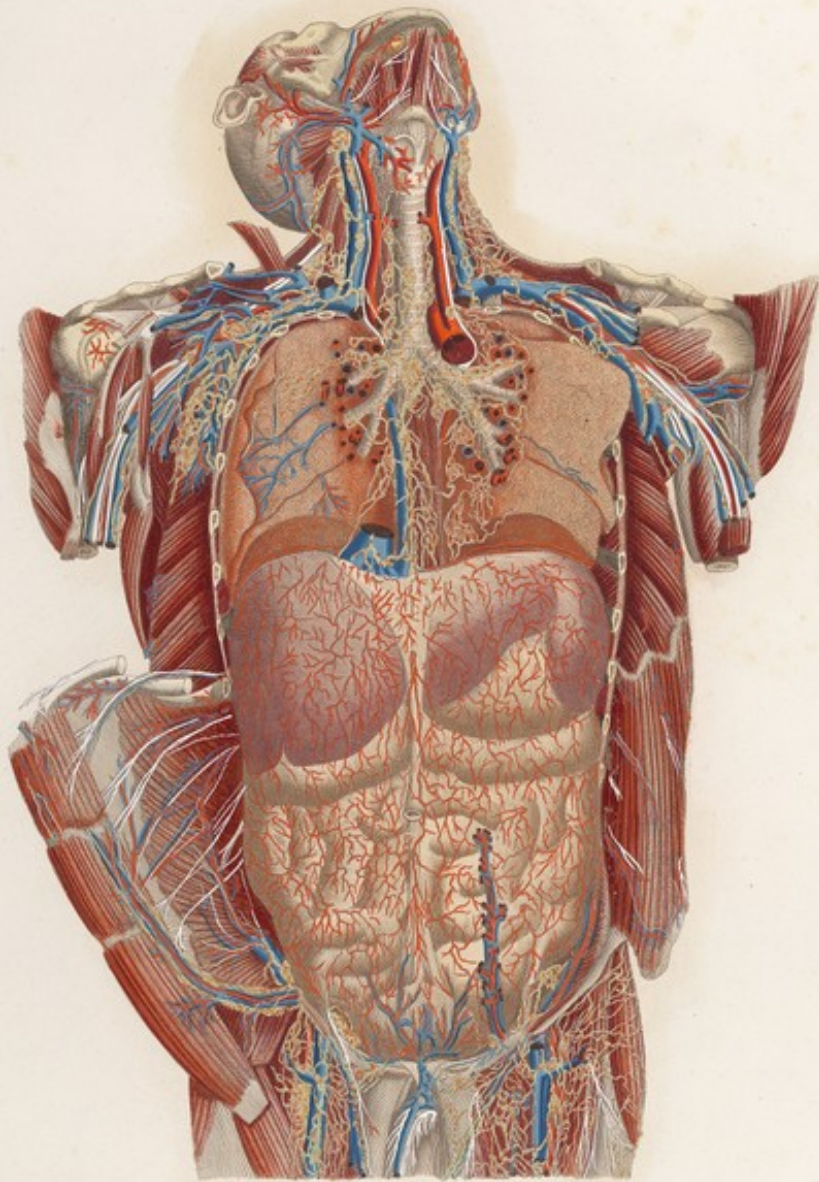


VISCERI *Tab. IX. Lat.*





VISCERI *Tab. IX.*



*W. Cheselden sculp.*








TAVOLA PARTICOLARE L. IX.

FIG. II.

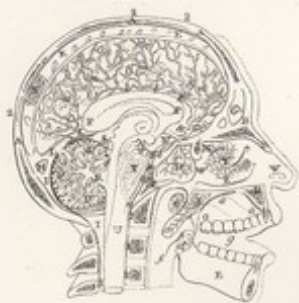

FIG. III.

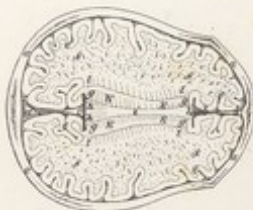


FIG. I.

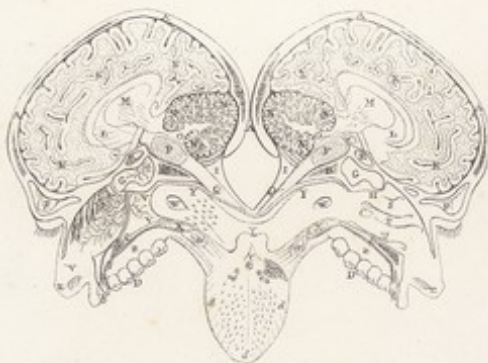

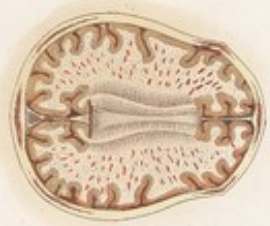
FIG. IV.

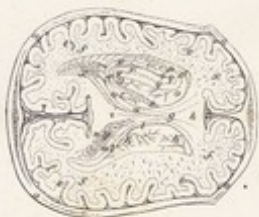

FIG. V.

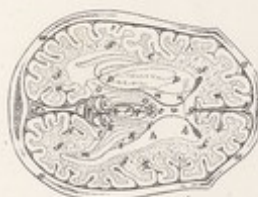
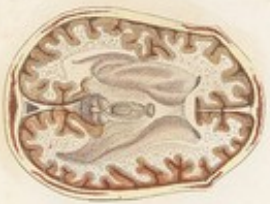
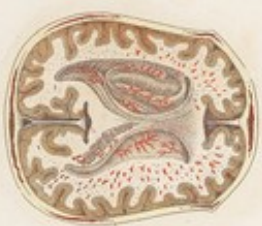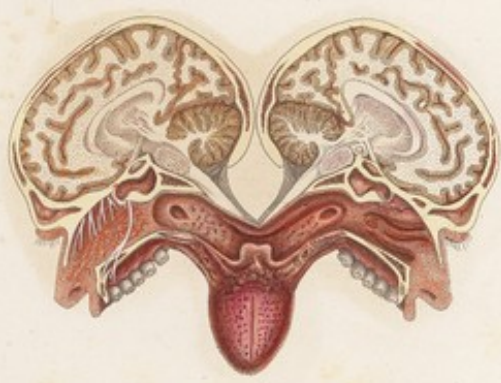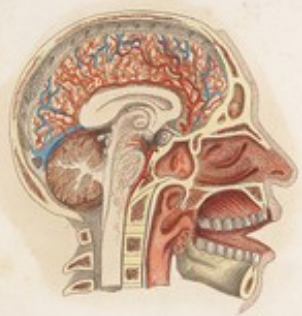TAVOLA PARTICOLARE / X



*Adhuc servatis longis et color*










TAVOLA PARTICOLARE LXX.

FIG. I.

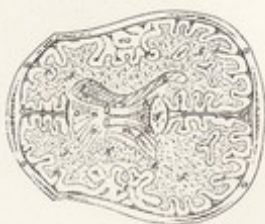

FIG. II.

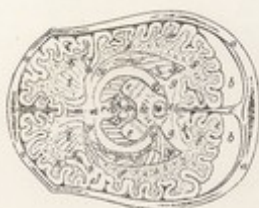

FIG. III.

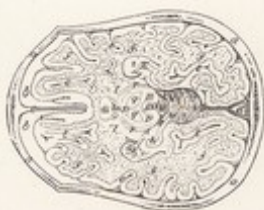

FIG. IV.



FIG. V.



TAVOLA PARTICOLARE X

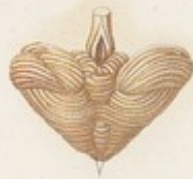
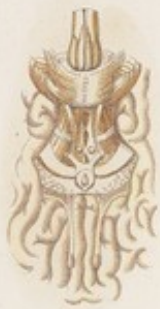
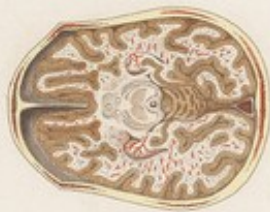
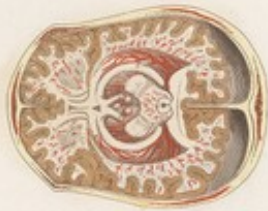
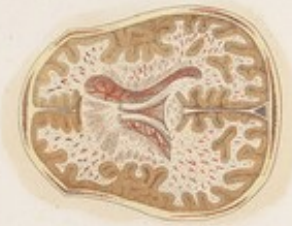




TAVOLA PARTICOLARE L. V.

FIG. I.

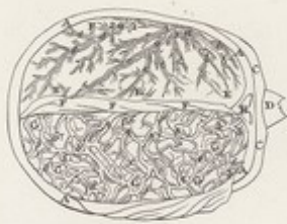

FIG. II.

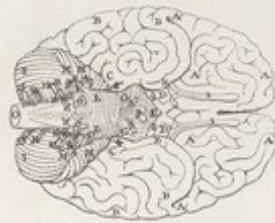


FIG. V.



FIG. III.

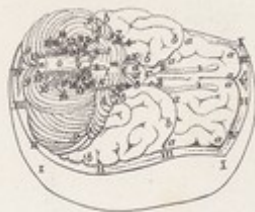

FIG. IV.

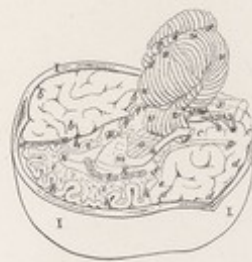
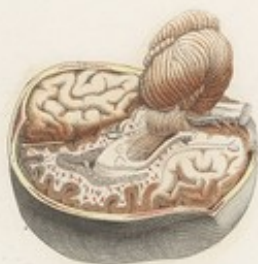
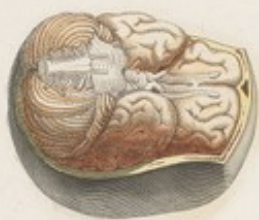
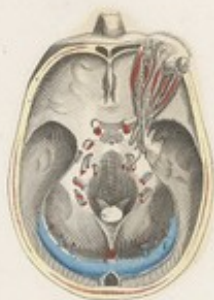
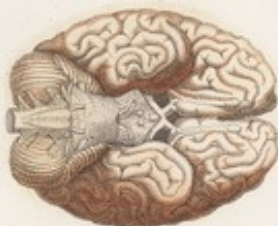
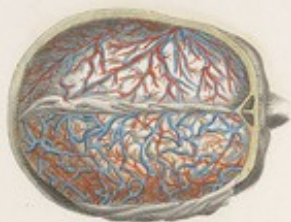TAVOLA PARTICOLARE . XI.

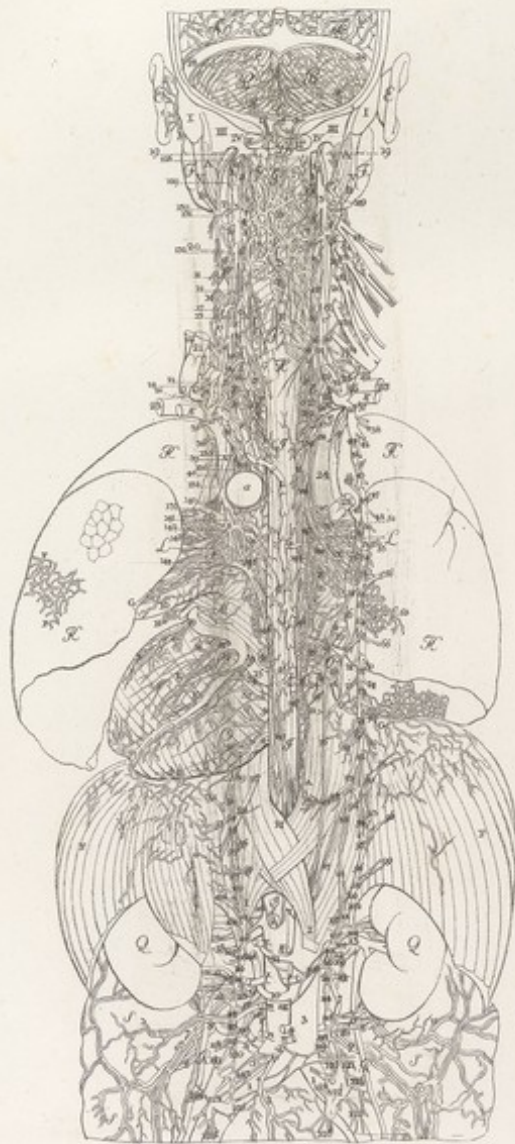


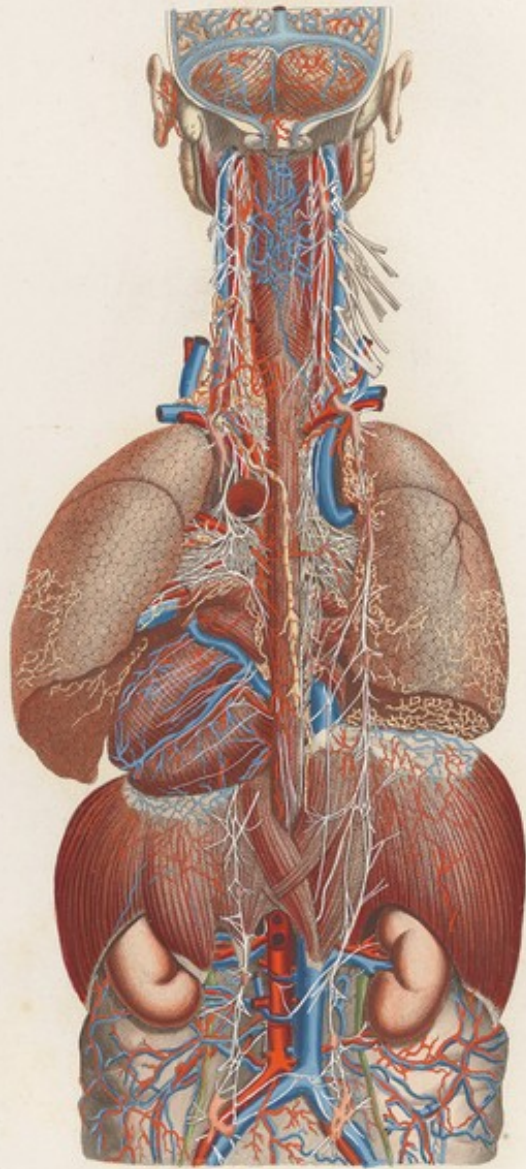





VISCERI *Tab. LXI*





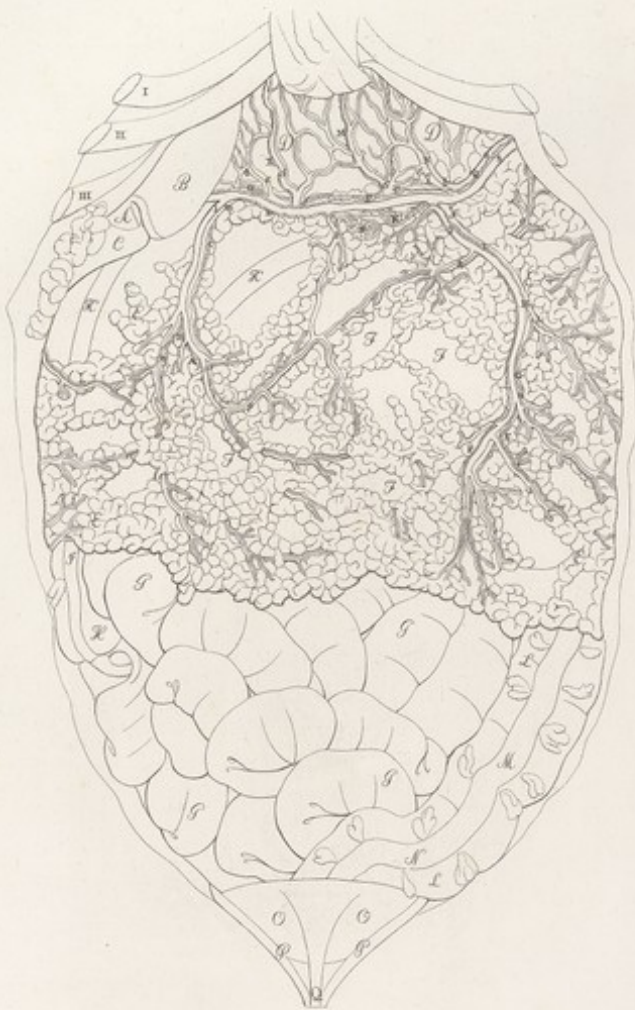


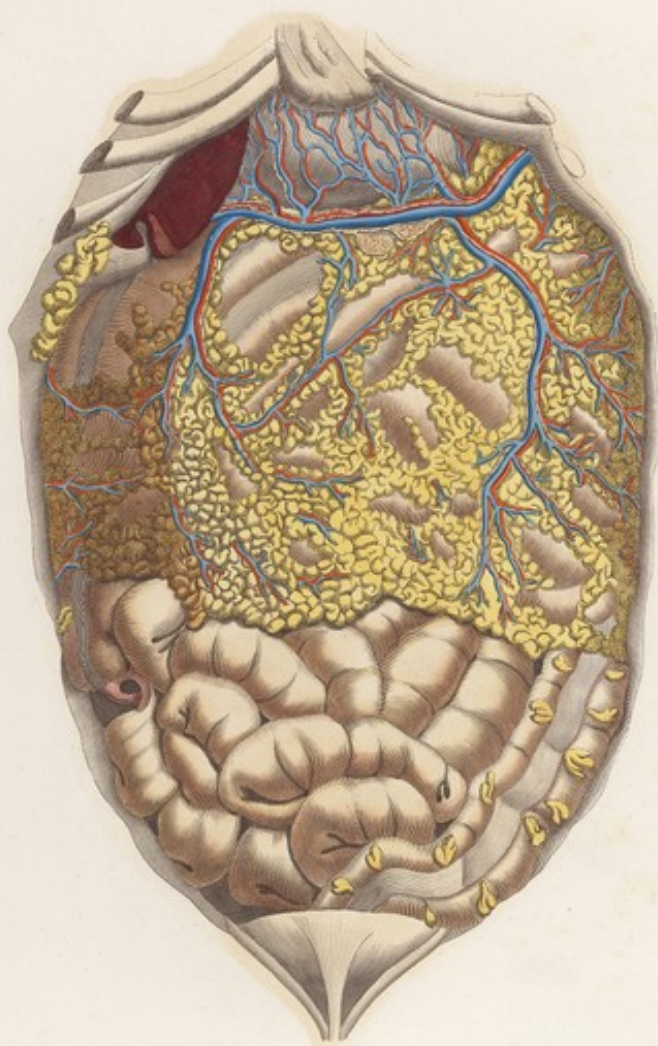







22  
VISCERI Tav. lxxxi.







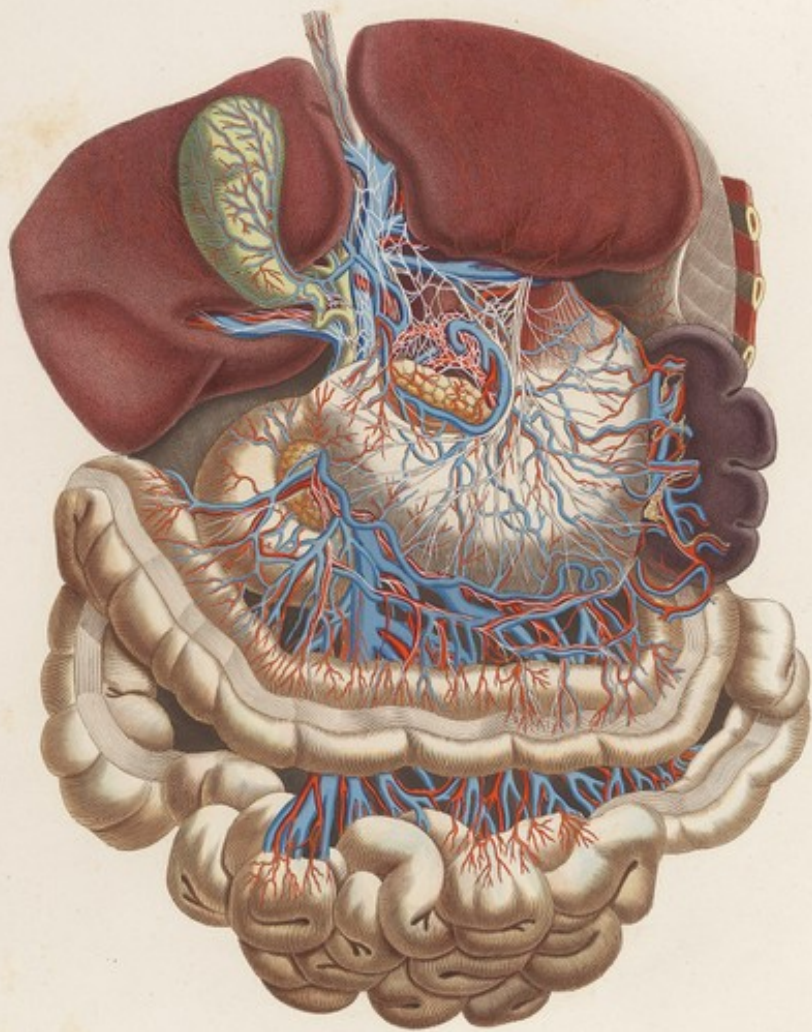









43  
VISCERI Tav. XII.



*Anteriori laterales dissectiones a. v. c.*







VISCERI Tab. XIII. Linn.

FIG. II.




FIG. III.

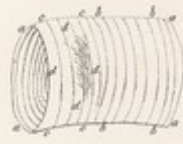


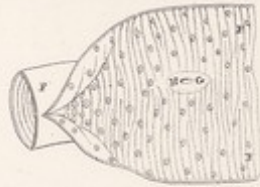
FIG. I.

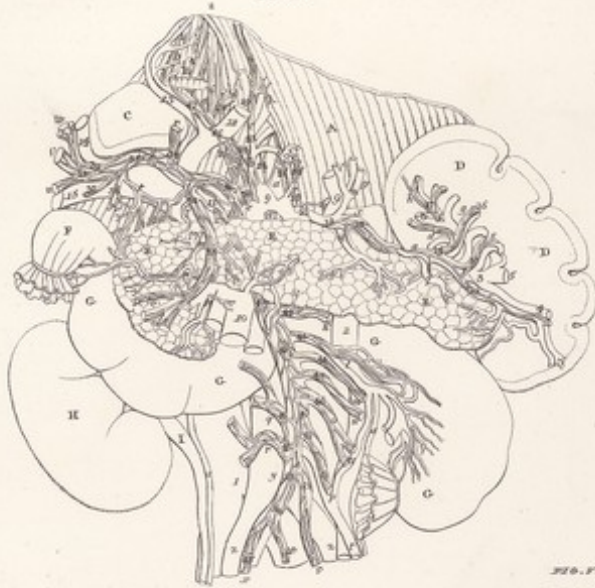

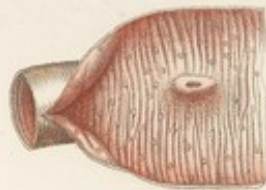
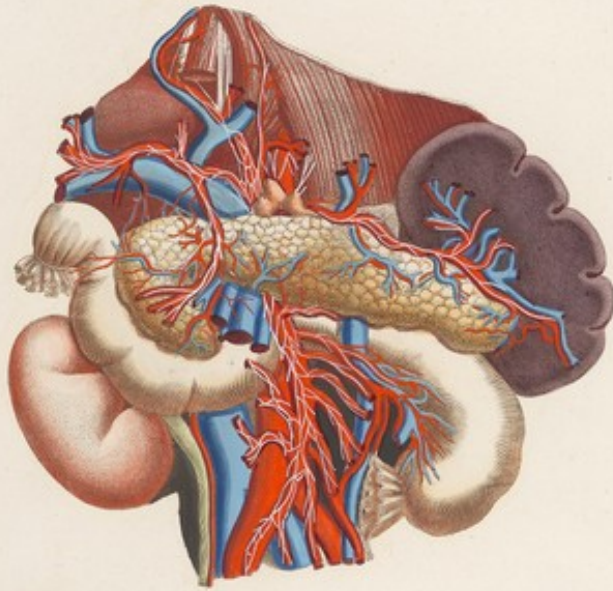
FIG. IV.

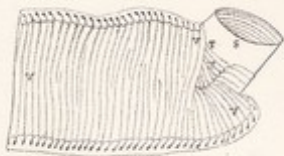

FIG. V.




VISCERI. Tav. XIII.




*Arteria Cruralis dissecta vasibus y coloribus*







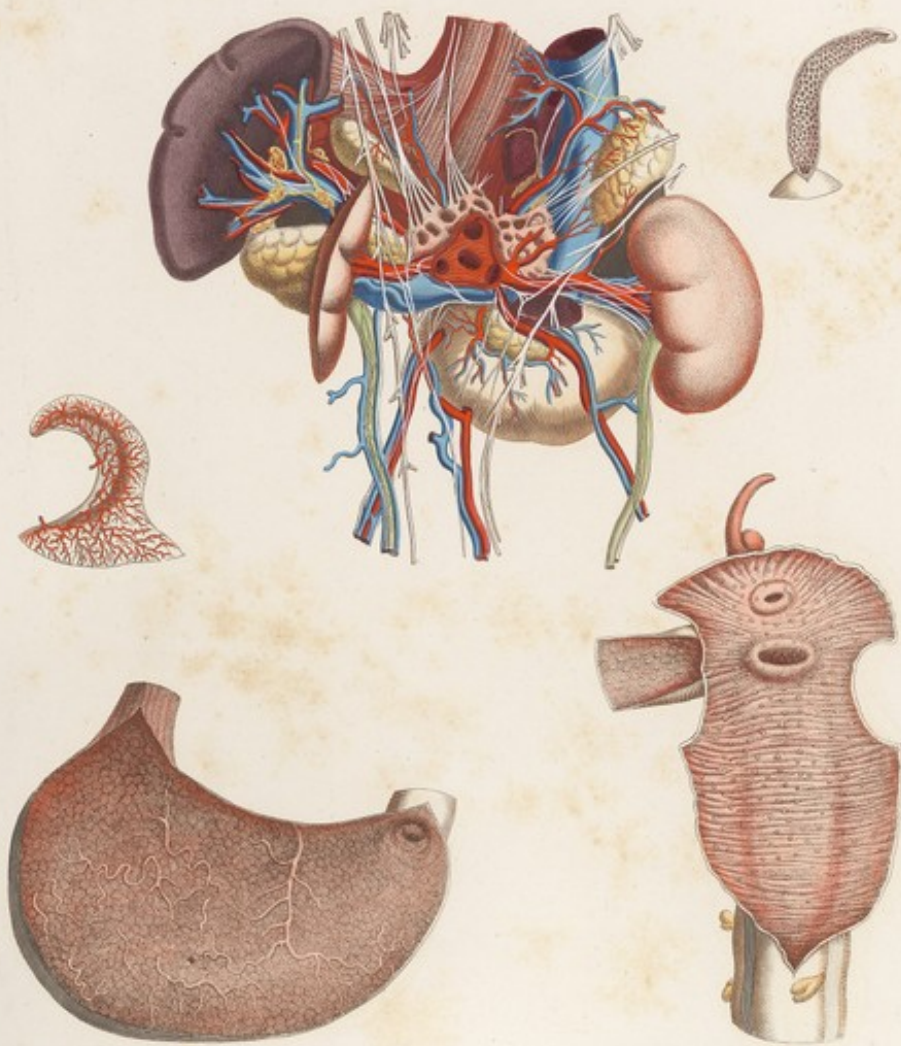


VISERA. Tav. XLII.







VISCERI Tab. XIV.

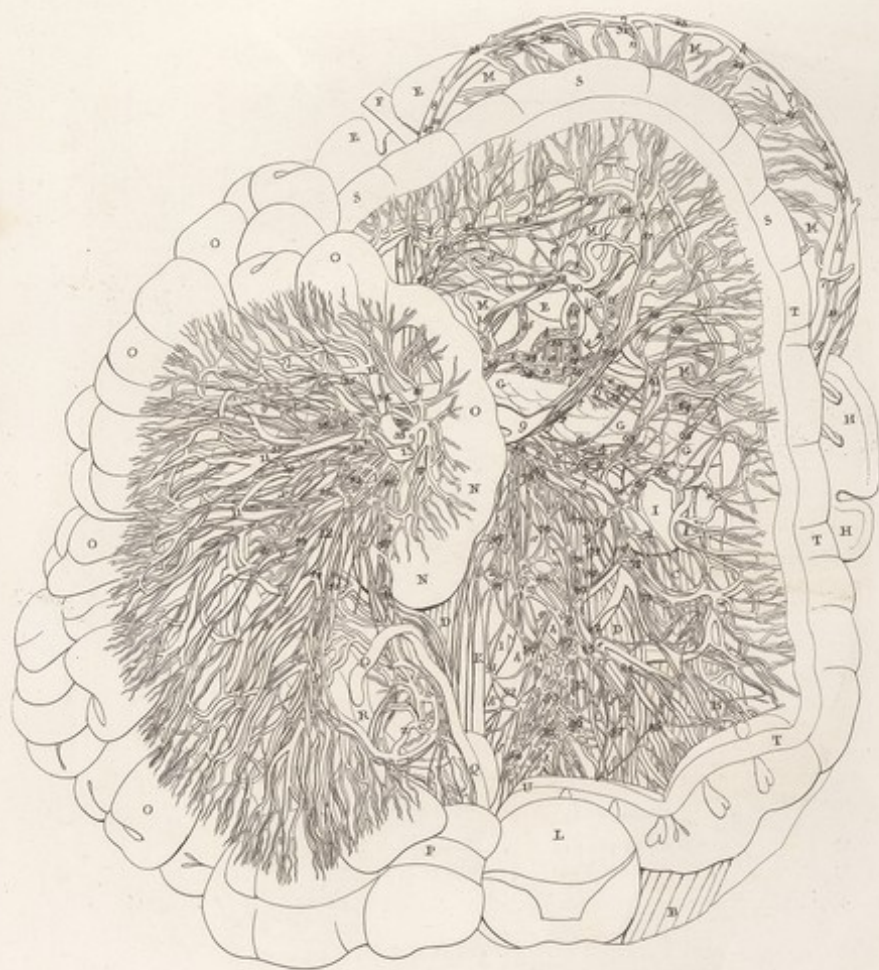


*Tab. XIV. Viscerum. Stomachi, hepatis, & splenis.*

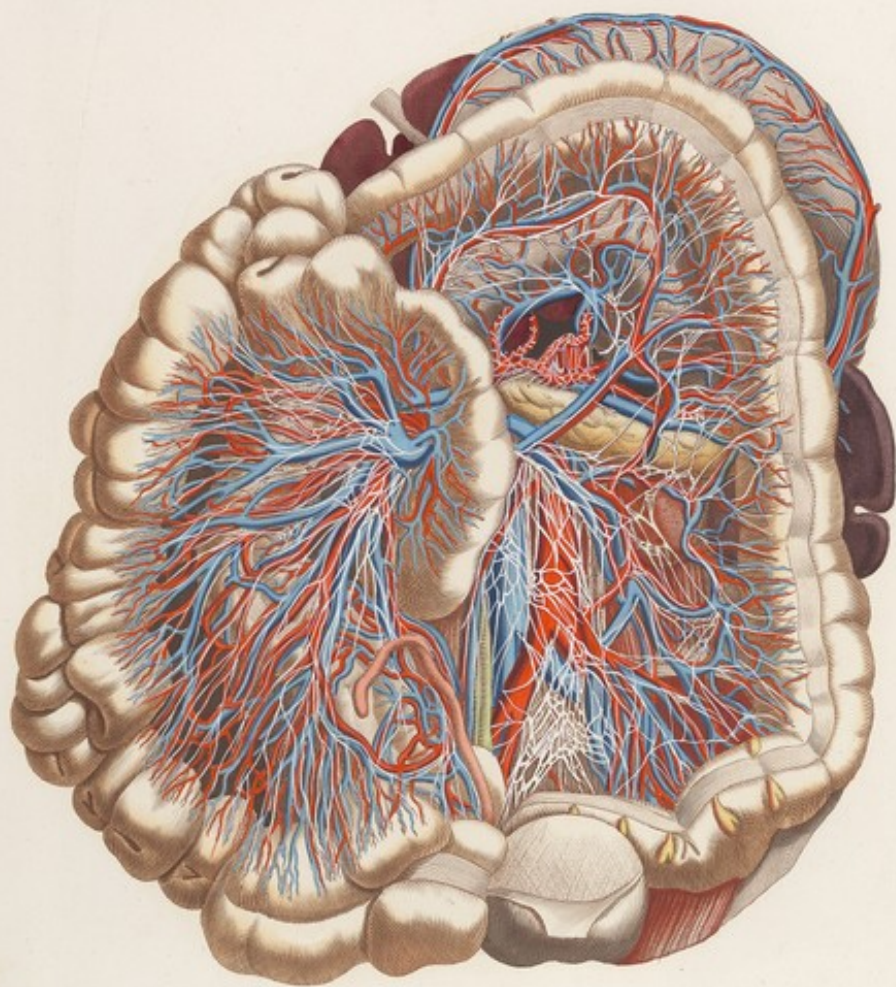










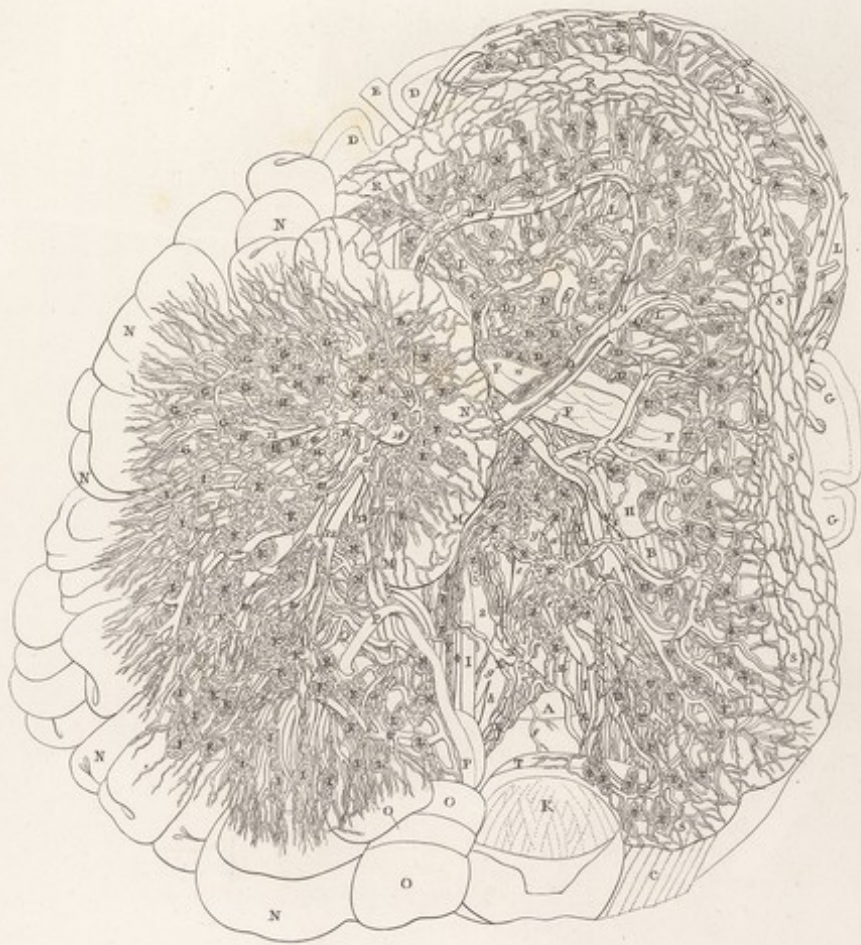



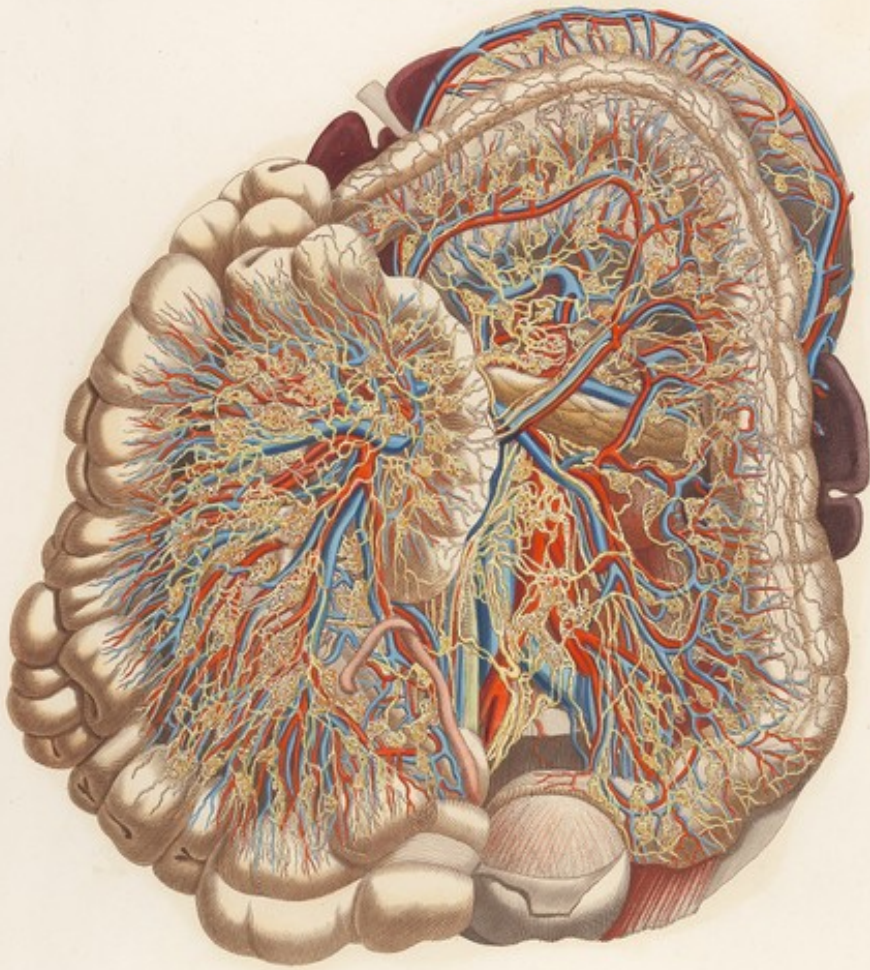
*Anterior Cerebralis, Linguis, sacro, & colici*











*Anterior Superior. Arteriae, nervi, & vasa.*









VISCERI Tab. XVIII. in.

FIG. I.



FIG. II.

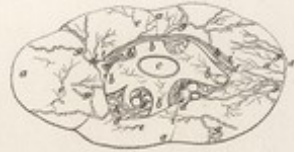

FIG. III.

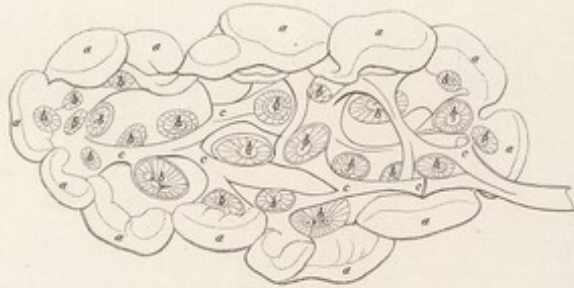

FIG. IV.

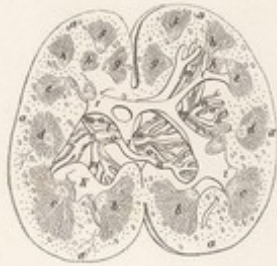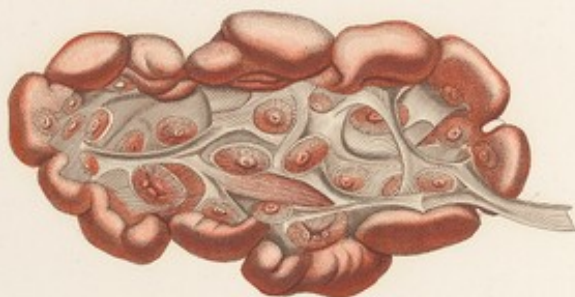


FIG. V.

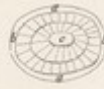


FIG. VI.



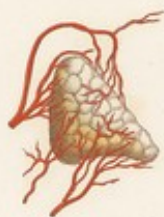
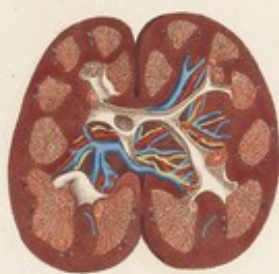

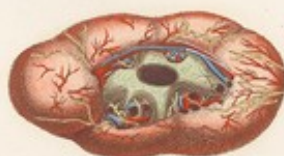
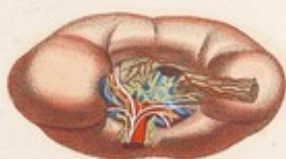


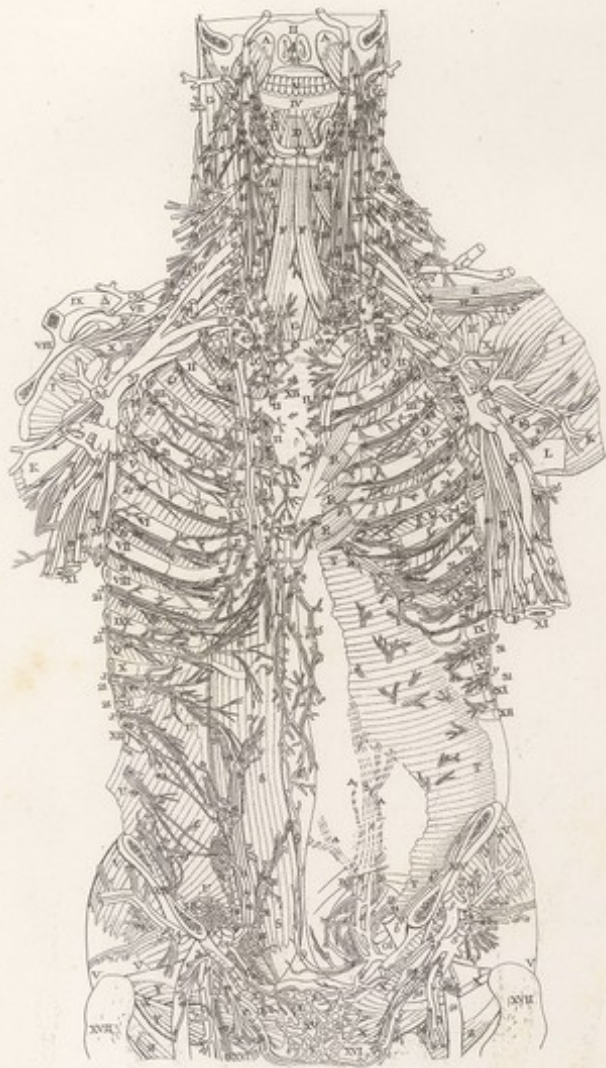
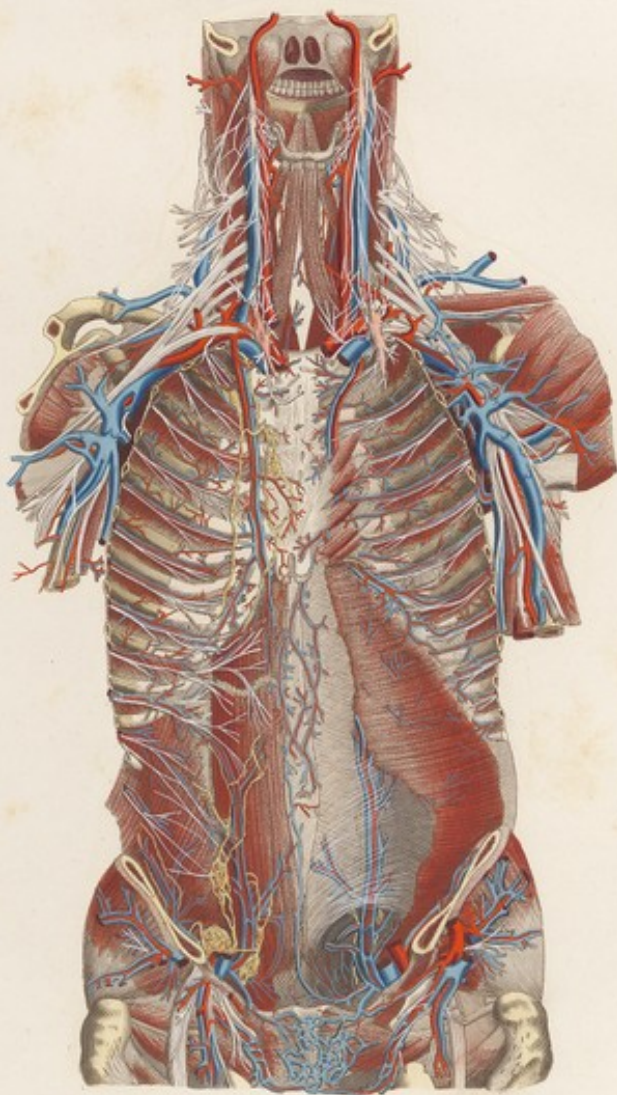


TAVOLA PARTICOLARE *L. II.*







*Anteriori frontalis, demum in loco a cadav.*








TAVOLA PARTICOLARE L. X.

FIG. II.



FIG. III.



FIG. I.

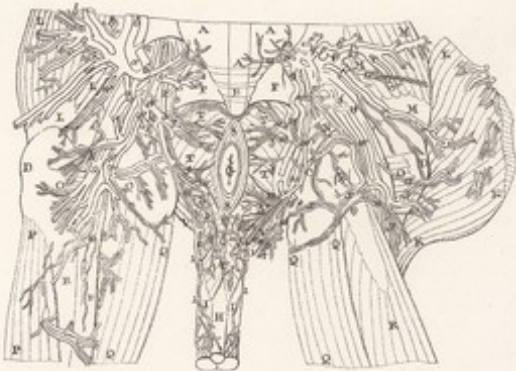

FIG. IV.



FIG. V.

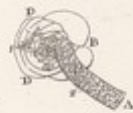
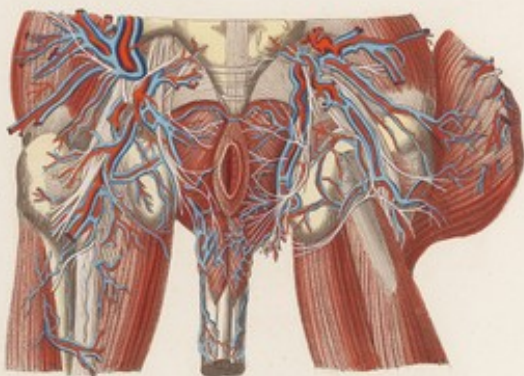
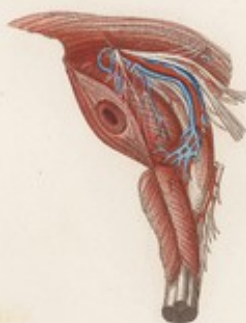
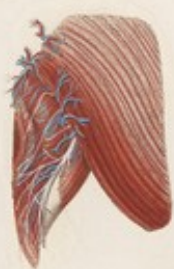

TAVOLA PARTICOLARE X.



*Arteria circumflexa humeri, interna e externa.*








TAVOLA PARTICOLARE L. XI.

FIG. I.



FIG. II.

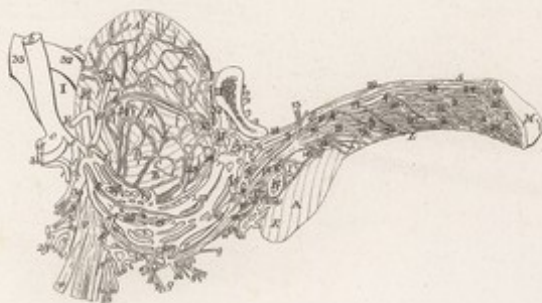
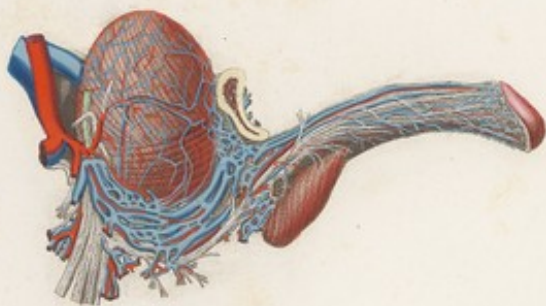
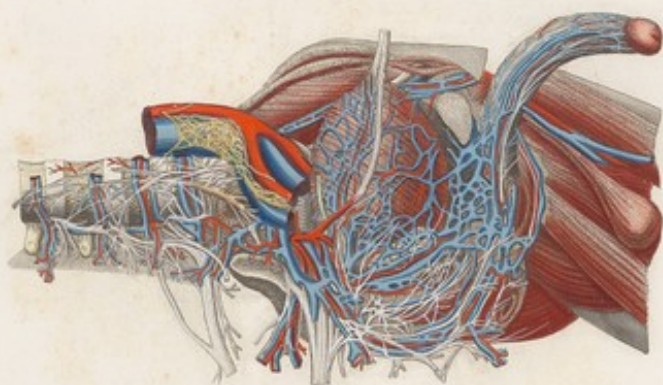

TAVOLA PARTICOLARE XI



*Antea. Scapulae longae, sacra, & colae*













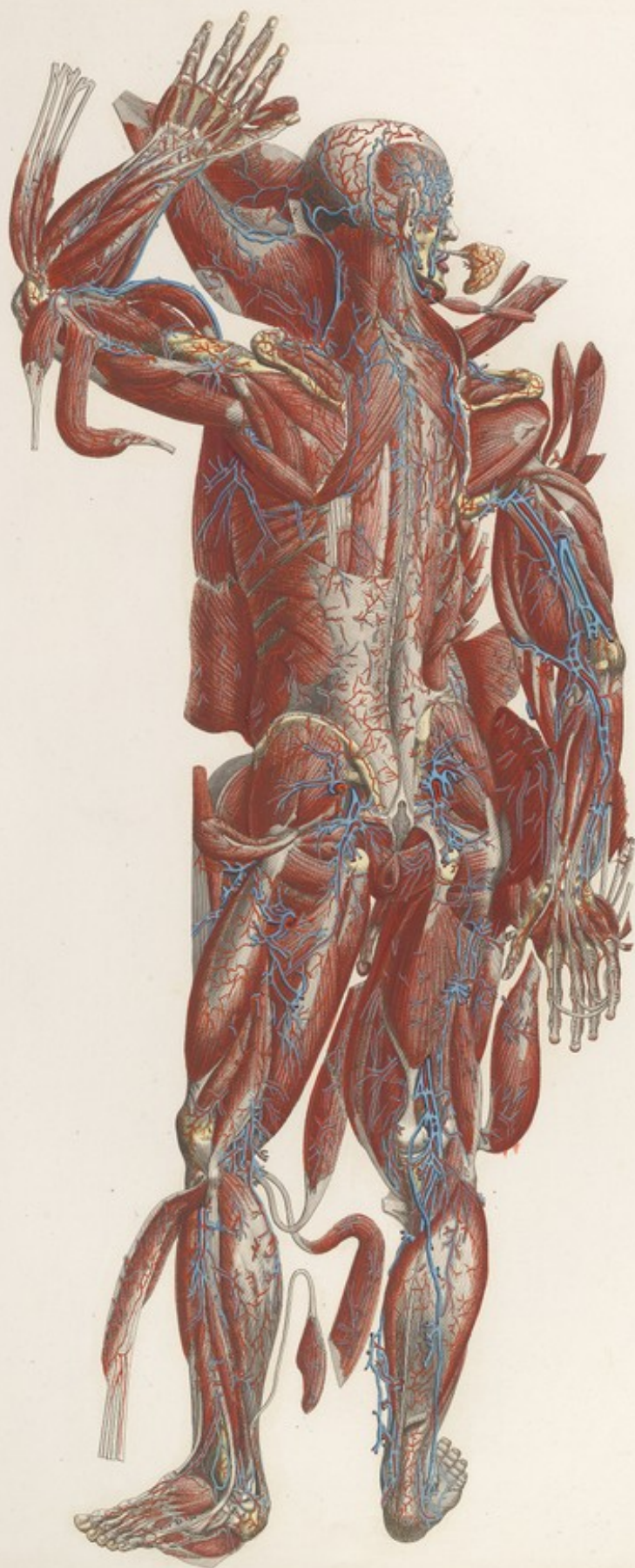
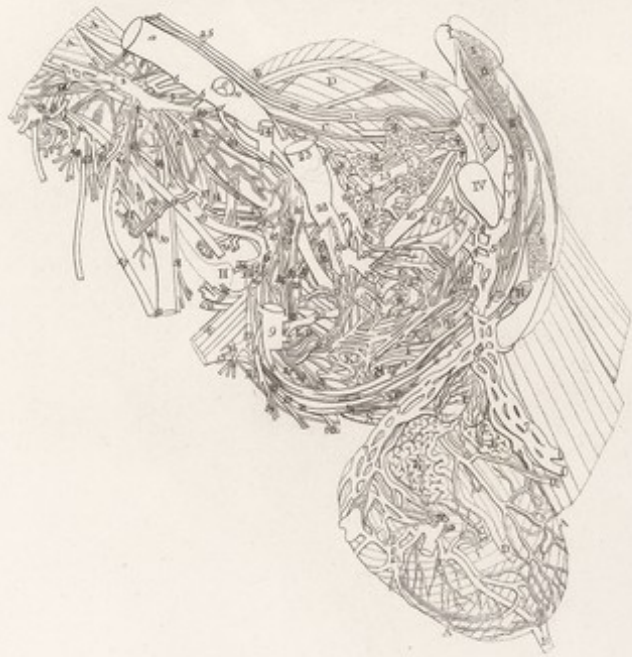





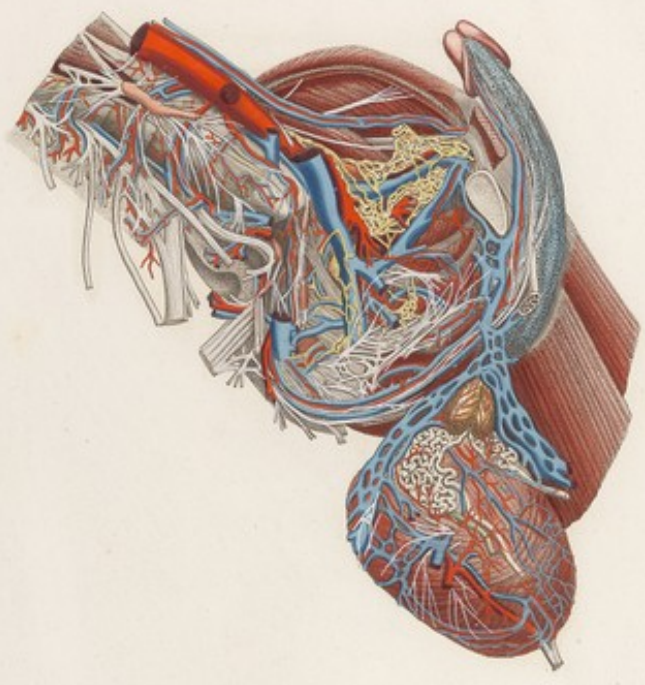


TAVOLA PARTICOLARE XIII *Linc.*



F. 307

TAVOLA PARTICOLARE .XVI.



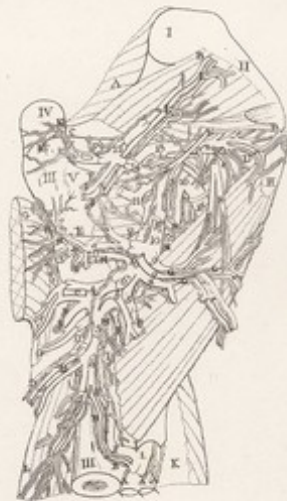*Anteriori laterali dissectione cordis & pulmonum.*






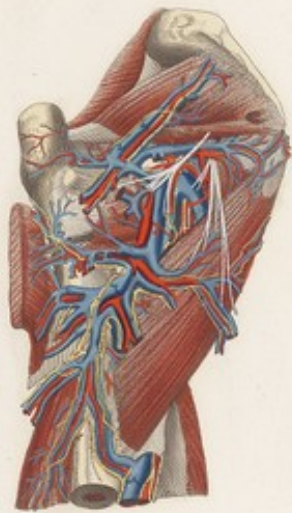


TAVOLA PARTICOLARE XIII Lin.




P. 111


TAVOLA PARTICOLARE XIII.



*Ad. P. de Santis del. J. G. de S. sculp.*













*Quibus tenduntur de v. e. v. b.*



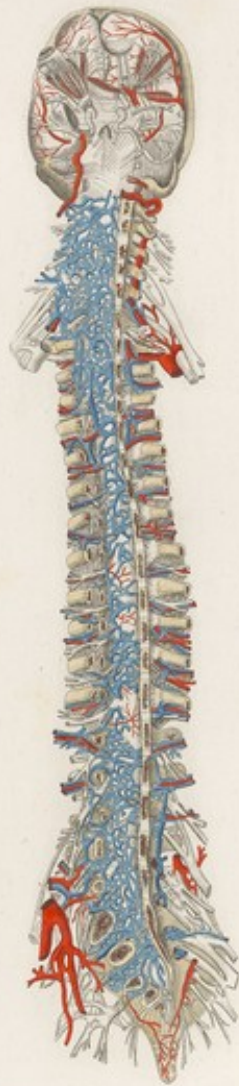




Z. XI<sup>a</sup>

TAVOLA PARTICOLARE XIV. *Luc.*






*Tabula Anatomica de Spina*








*L. XI*

TAVOLA PARTICOLARE *XI. Lina*



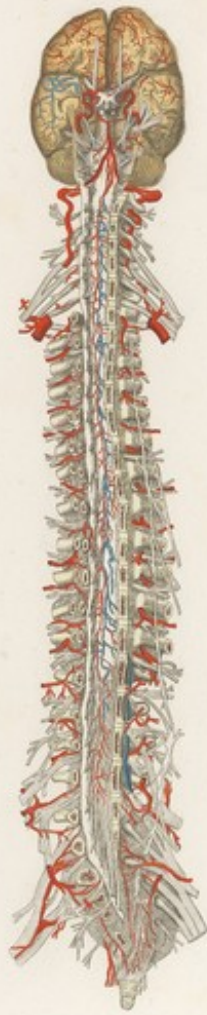








TAVOLA PARTICOLARE *Lin. XVI*

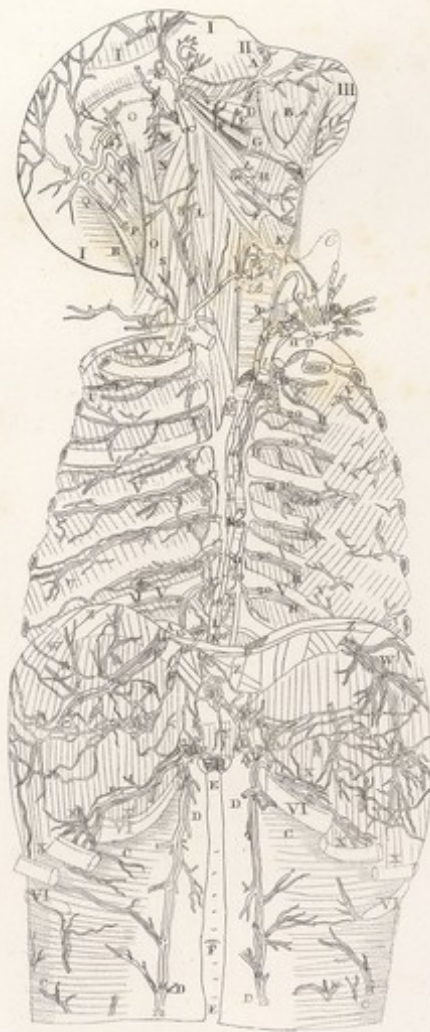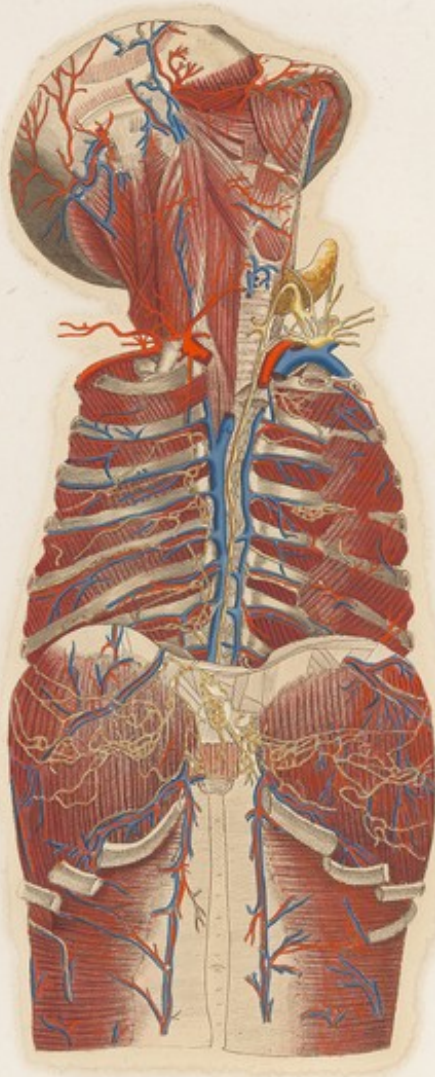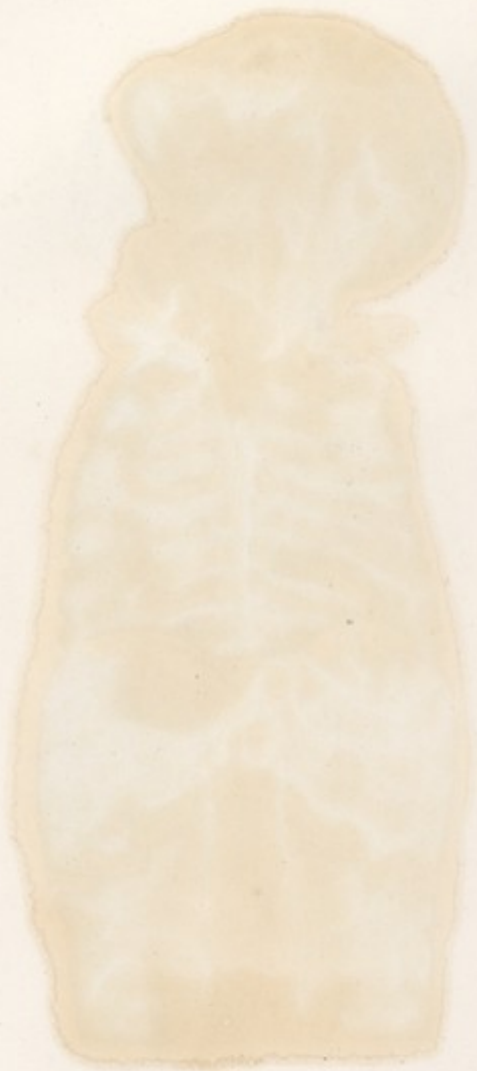




TAVOLA PARTICOLARE XIV



*Donato Cignoni del. et sculp.*








TAVOLA PARTICOLARE *Lin. XVIII*

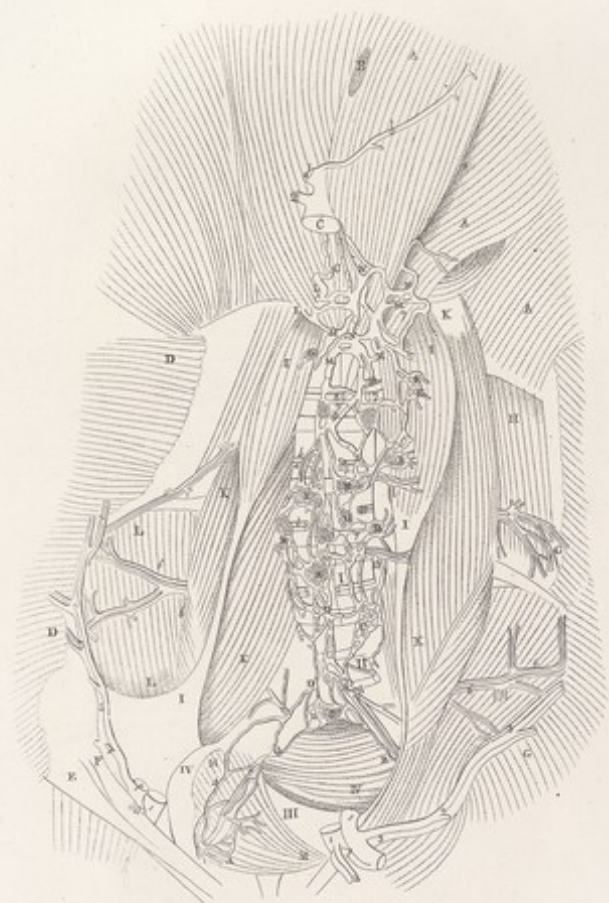
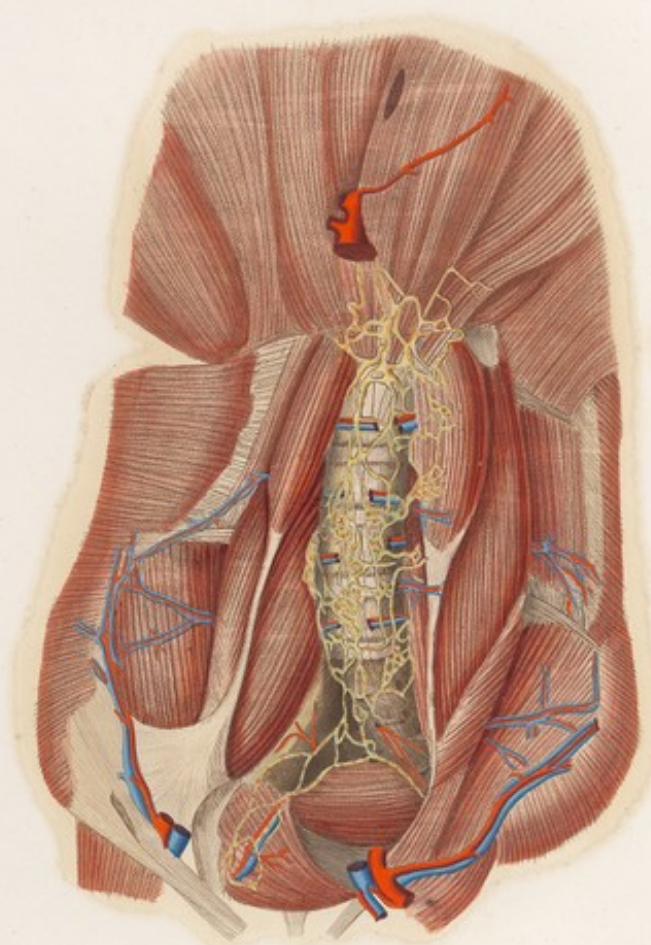


TAVOLA PARTICOLARE XIII



*Dessiné par M. de la Roche*



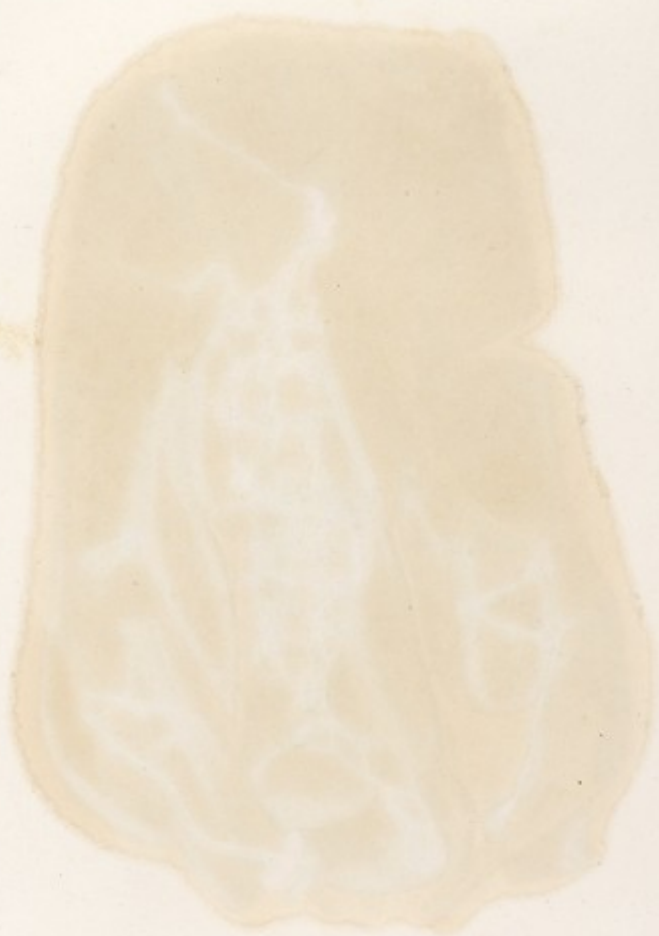




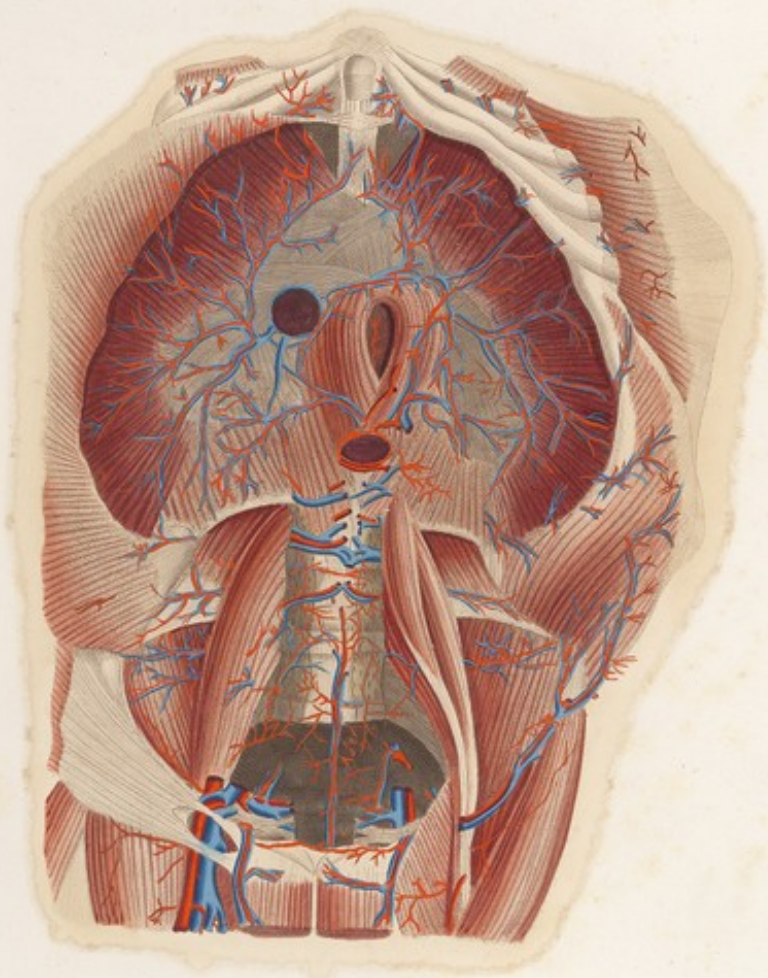


TAVOLA PARTICOLARE *Tab. XVIII*

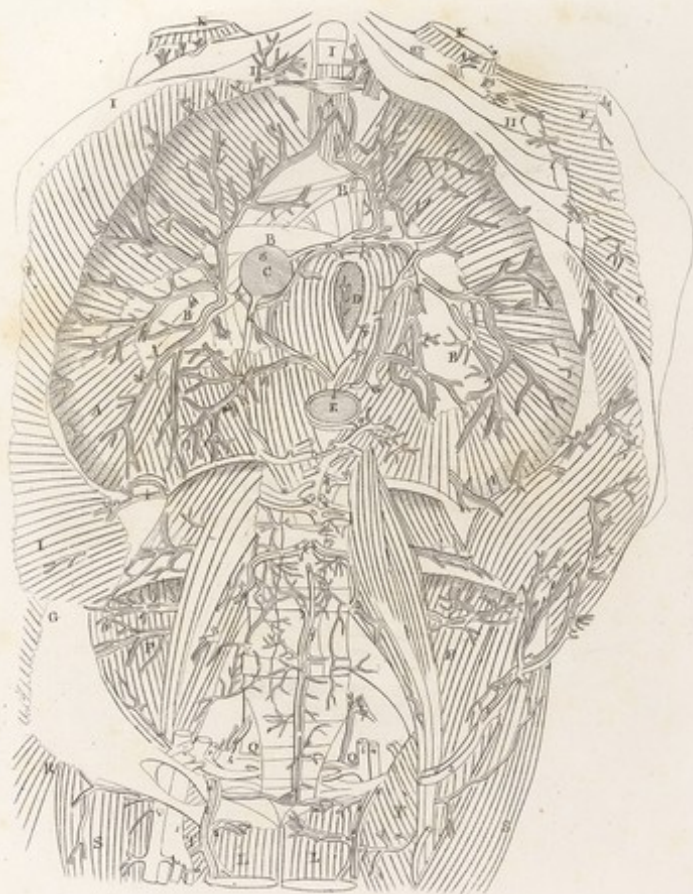

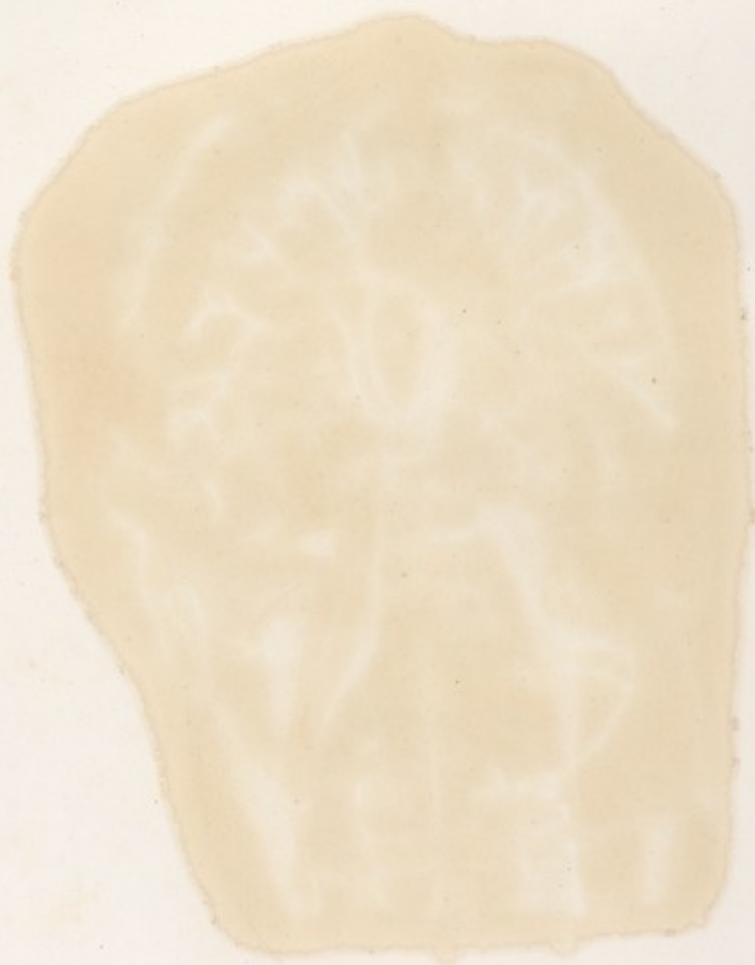



TAVOLA PARTICOLARE XVIII

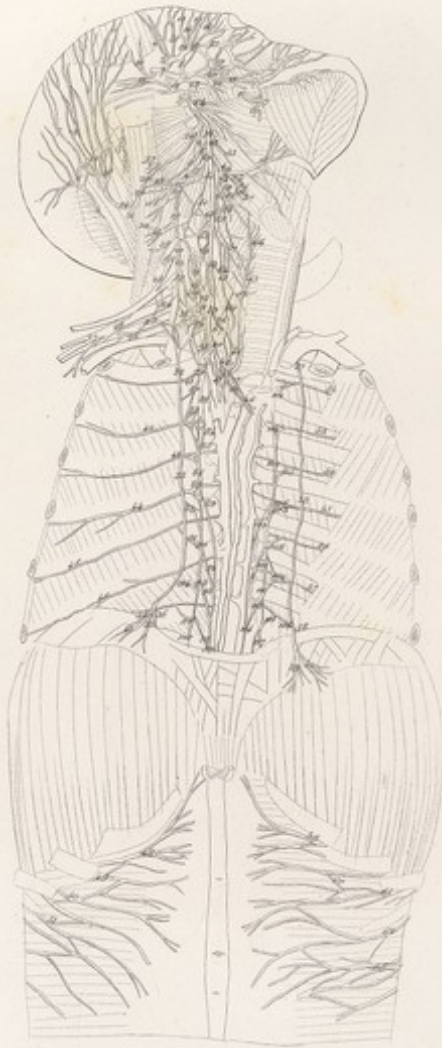


*Tab. XVIII. Musculi et Nervi Capitis et Cervicis.*

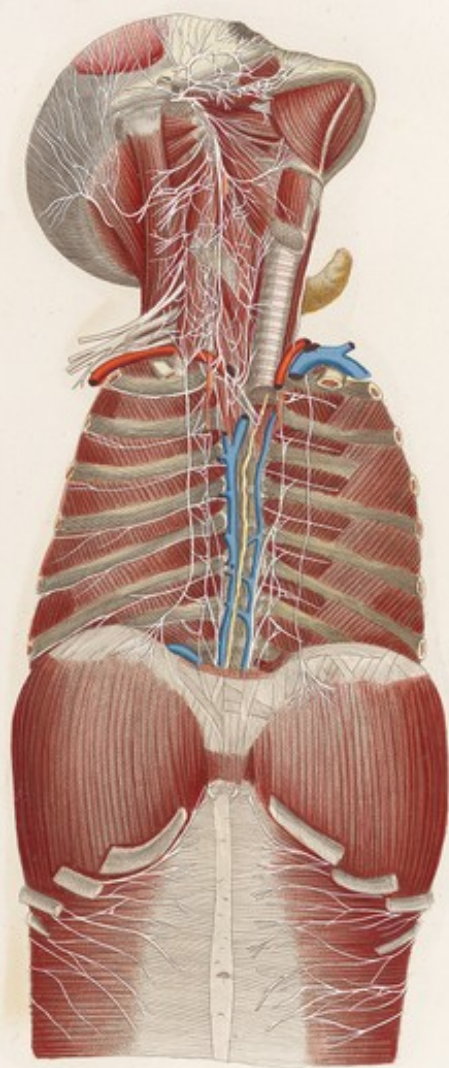


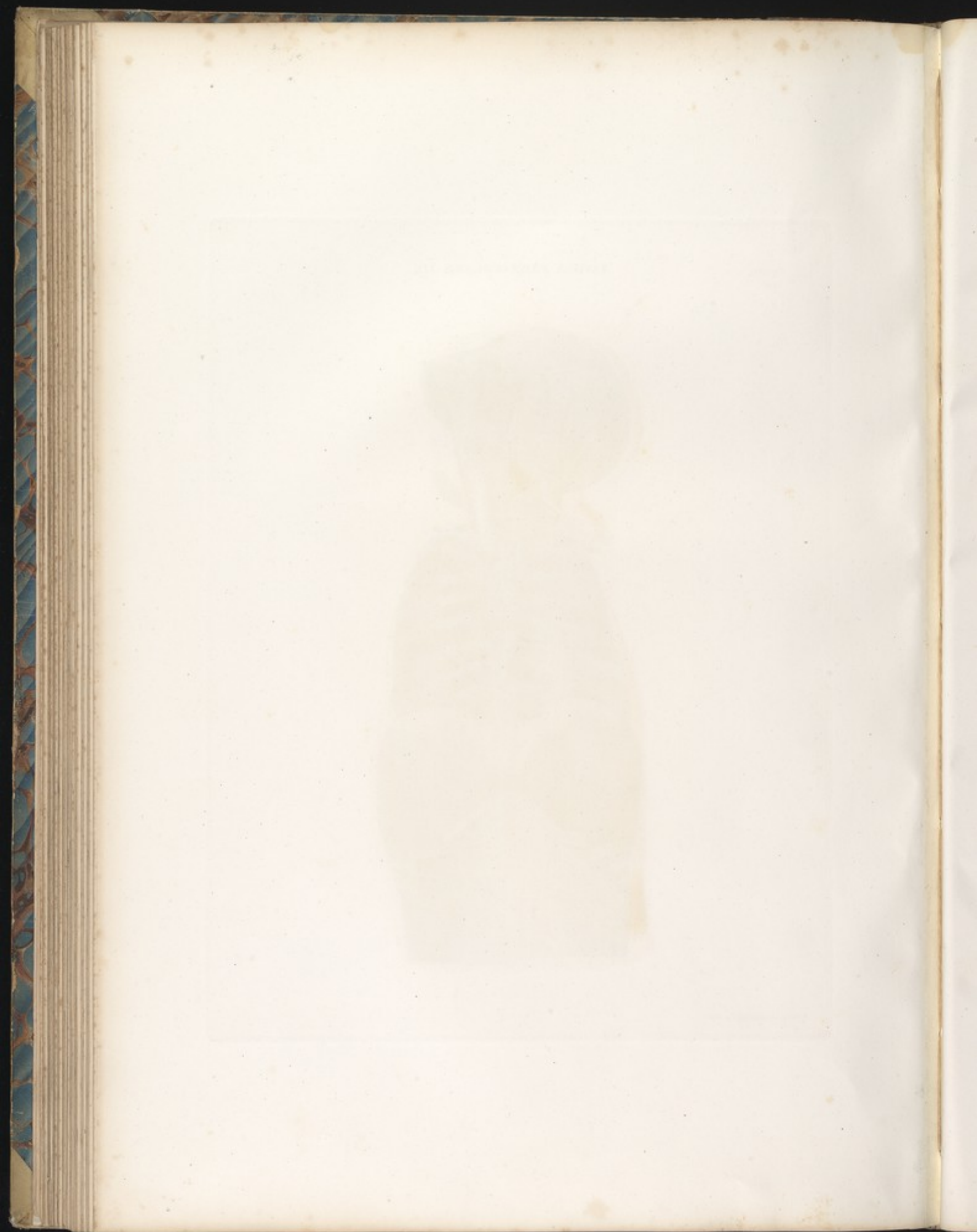








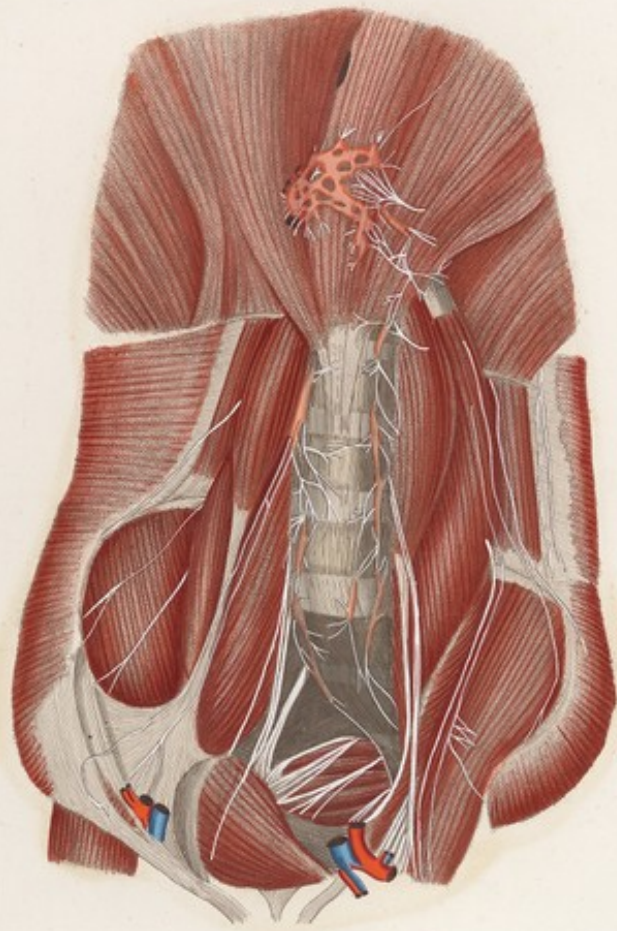












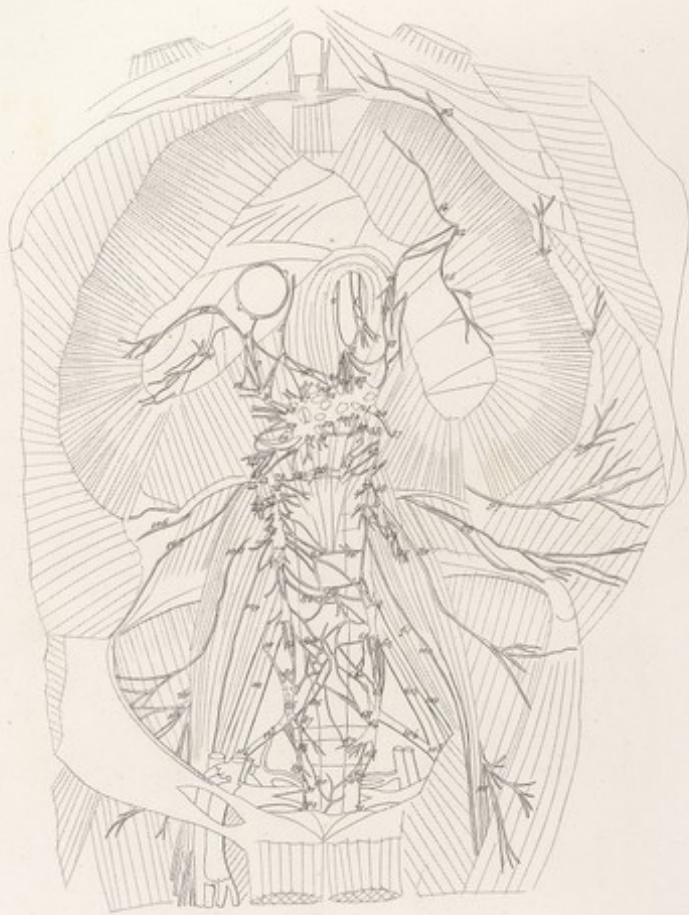




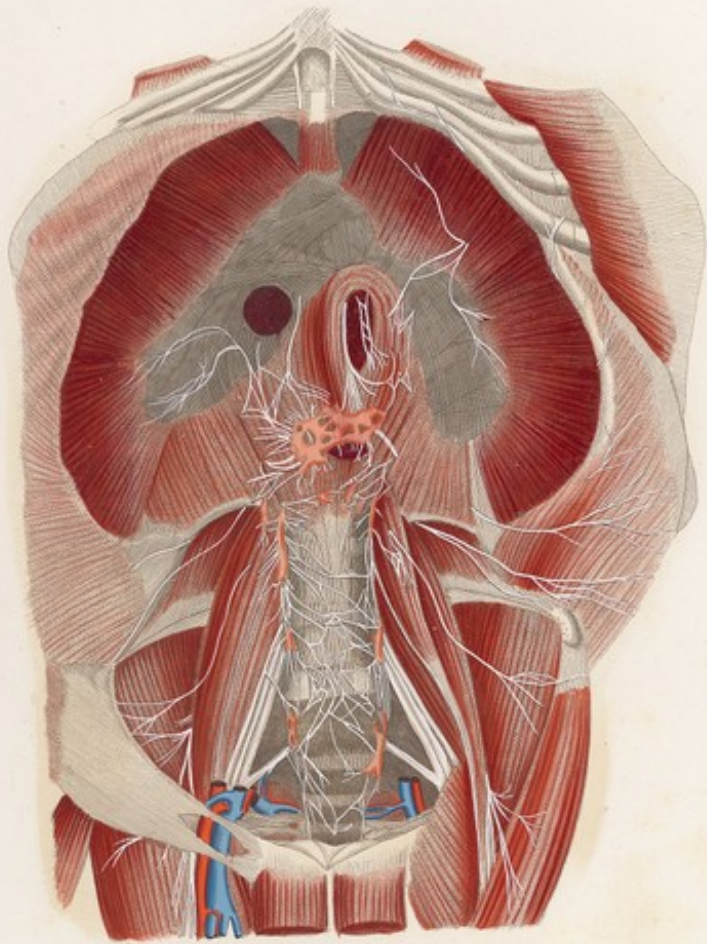












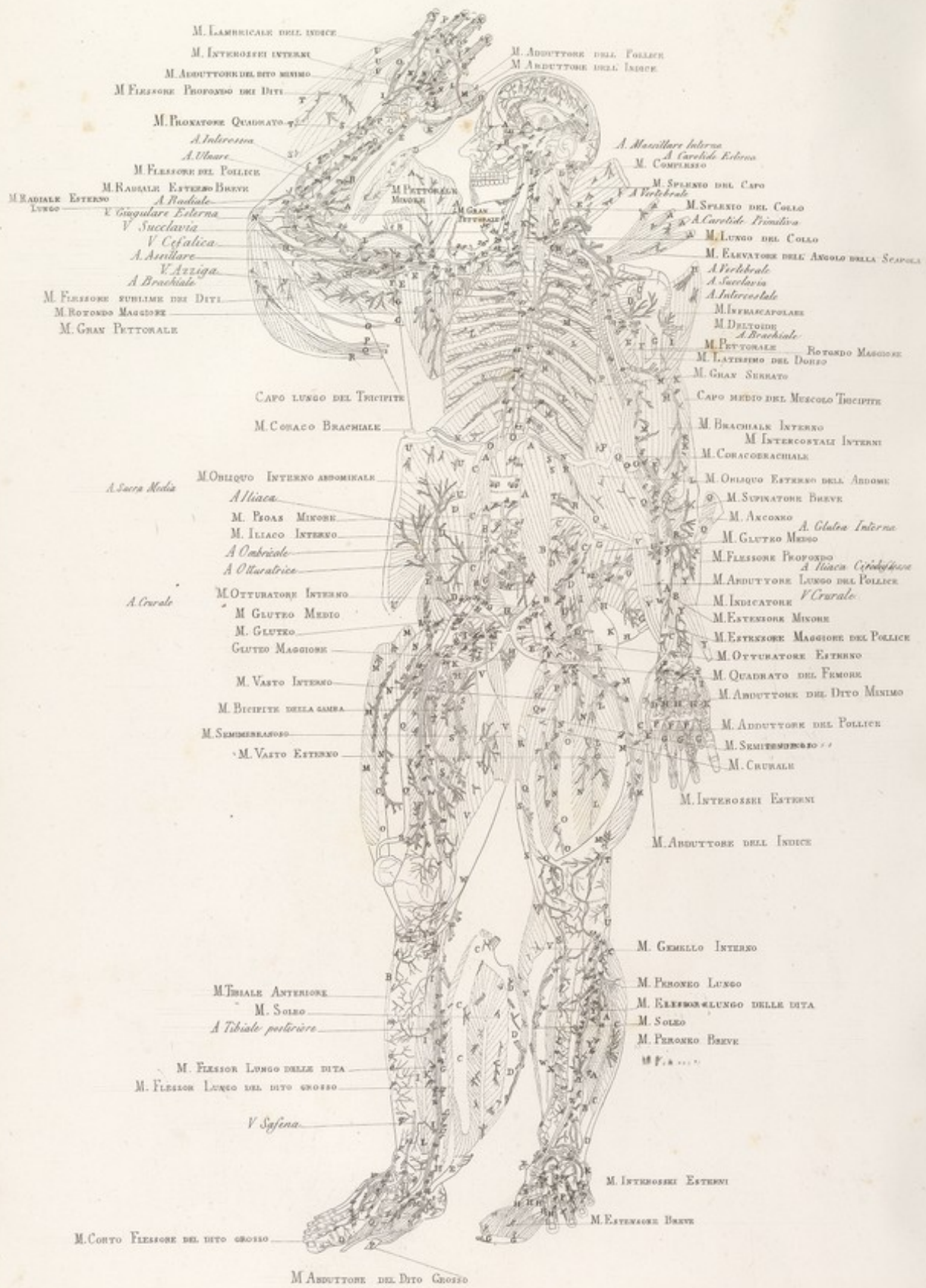






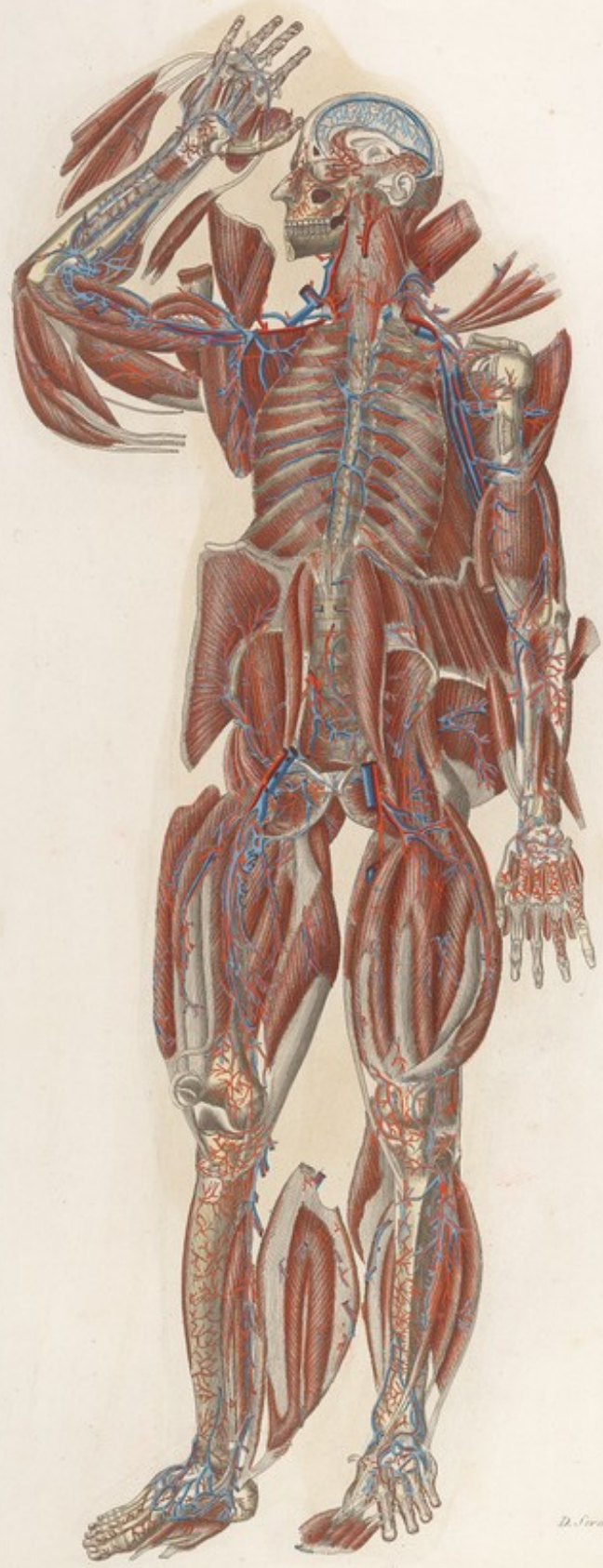


Mascagni. VEDUTA ANTERIORE DEL CORPO UMANO *Strato Terzo Tav. IX. lin.*





Masculi VEDUTA ANTERIORE DEL CORPO UMANO *Strato Torzo Tav. IX*



*D. Serenini del. e inc.*




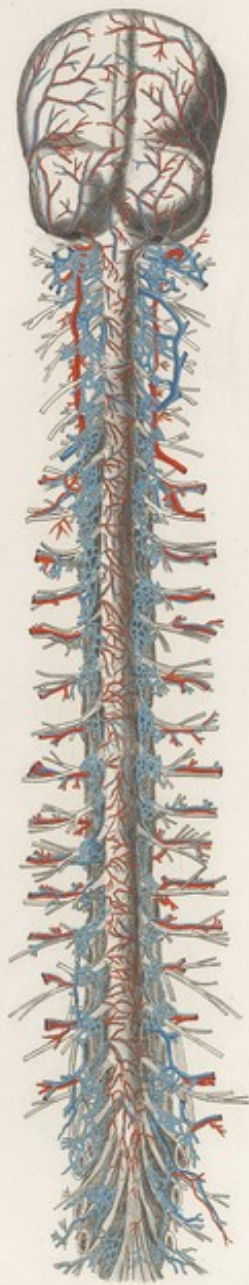




TAVOLA PARTICOLARE XXII. *LLX.*



TAVOLA PARTICOLARE XXII.



*D. Serapenti del. e inc.*











TAVOLA PARTICOLARE XXIII.



*D. Scanzoni Dicitur Inc.*





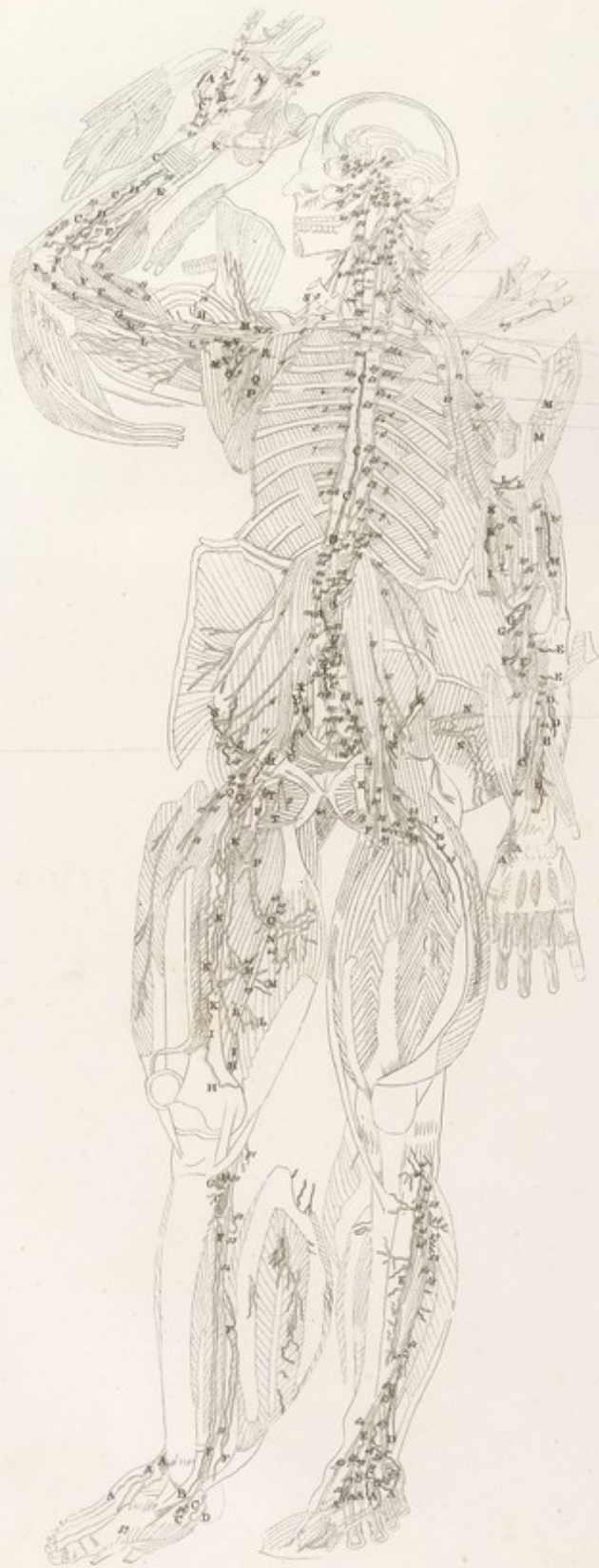


N. N. Cutaneo  
N. Mediano  
N. Cubitale  
N. Radiale

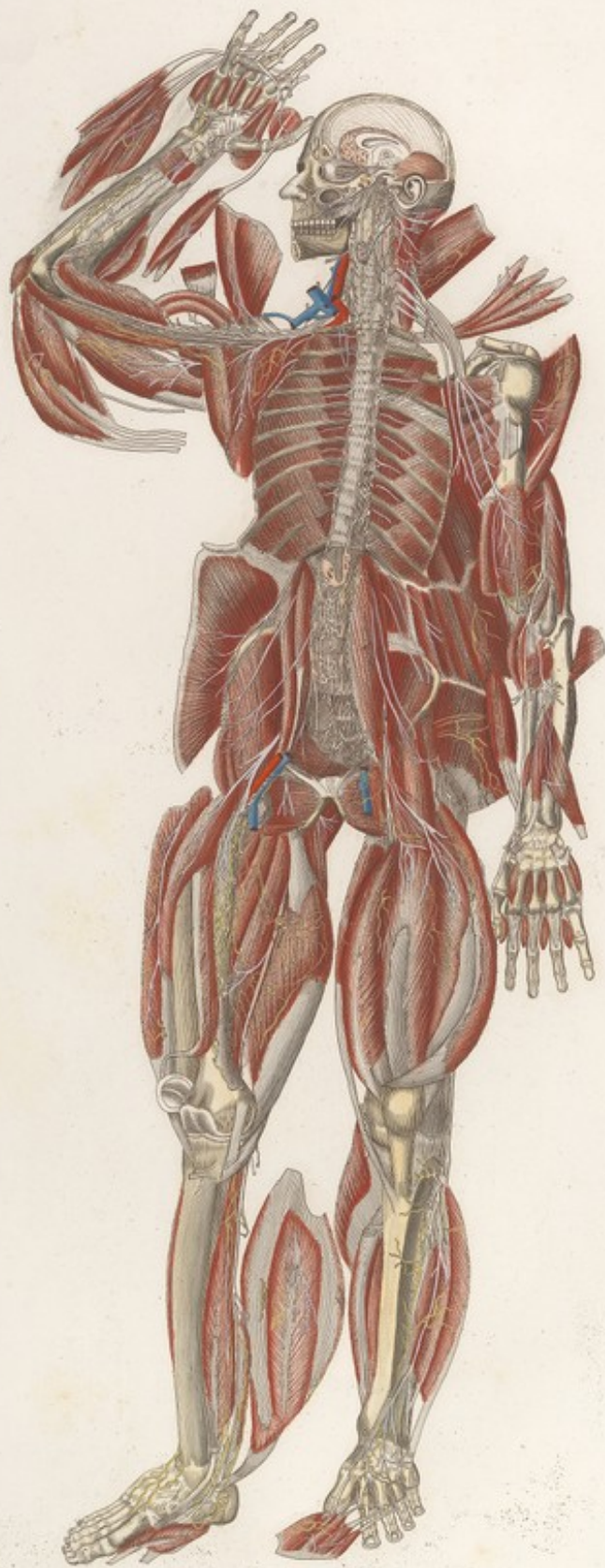
N. Subcrurale  
N. Vago  
Plexus Brachiale  
N. Scapolare  
N. Diaframmatico  
N. Axillare  
N. Ulnare


N. Crurale

N. Crurale





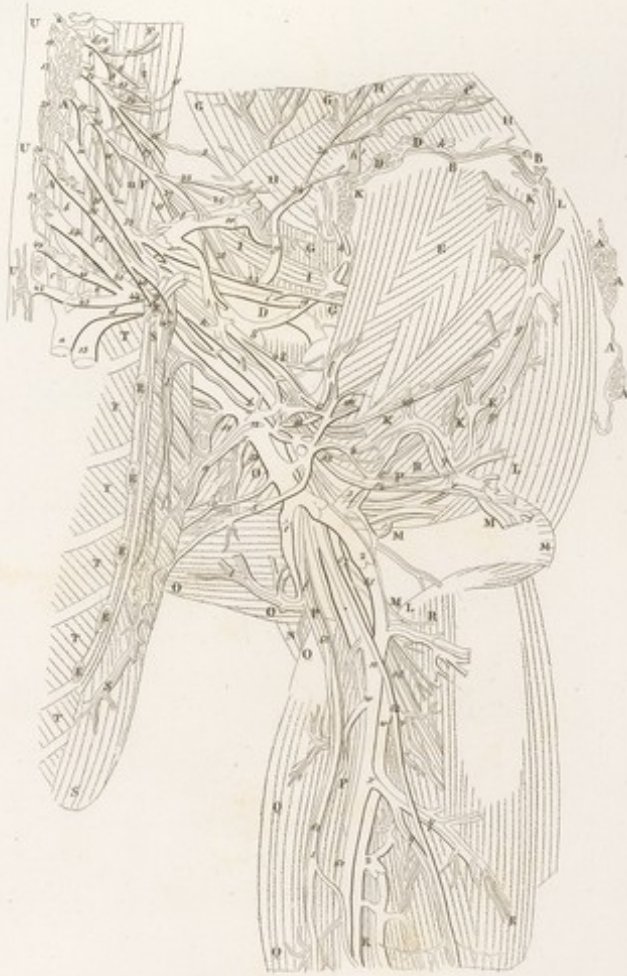


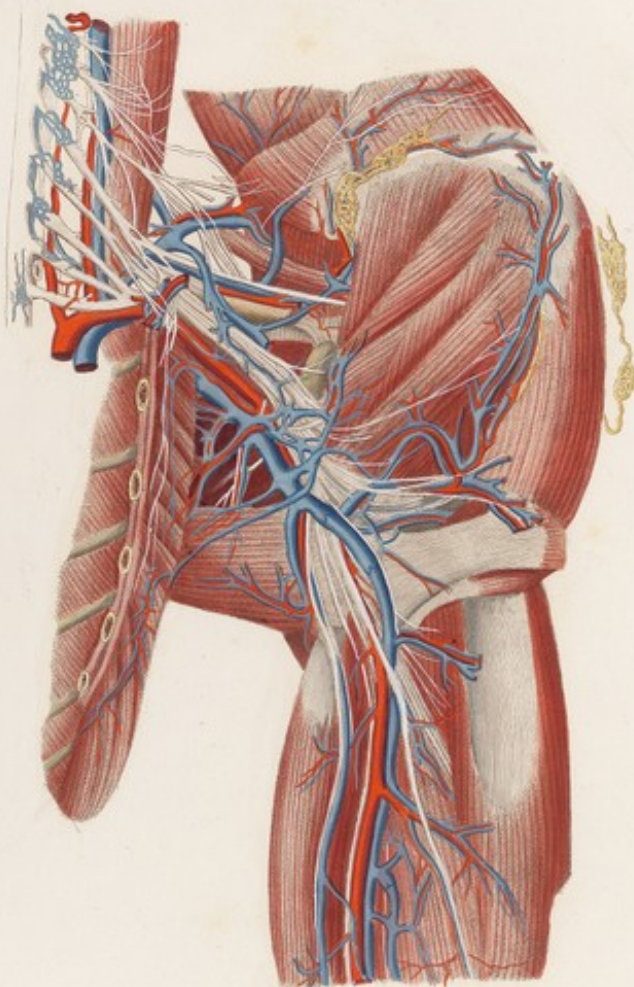












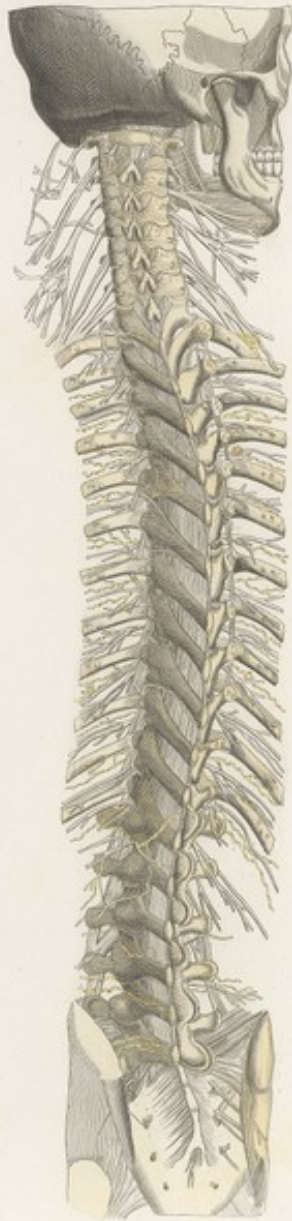















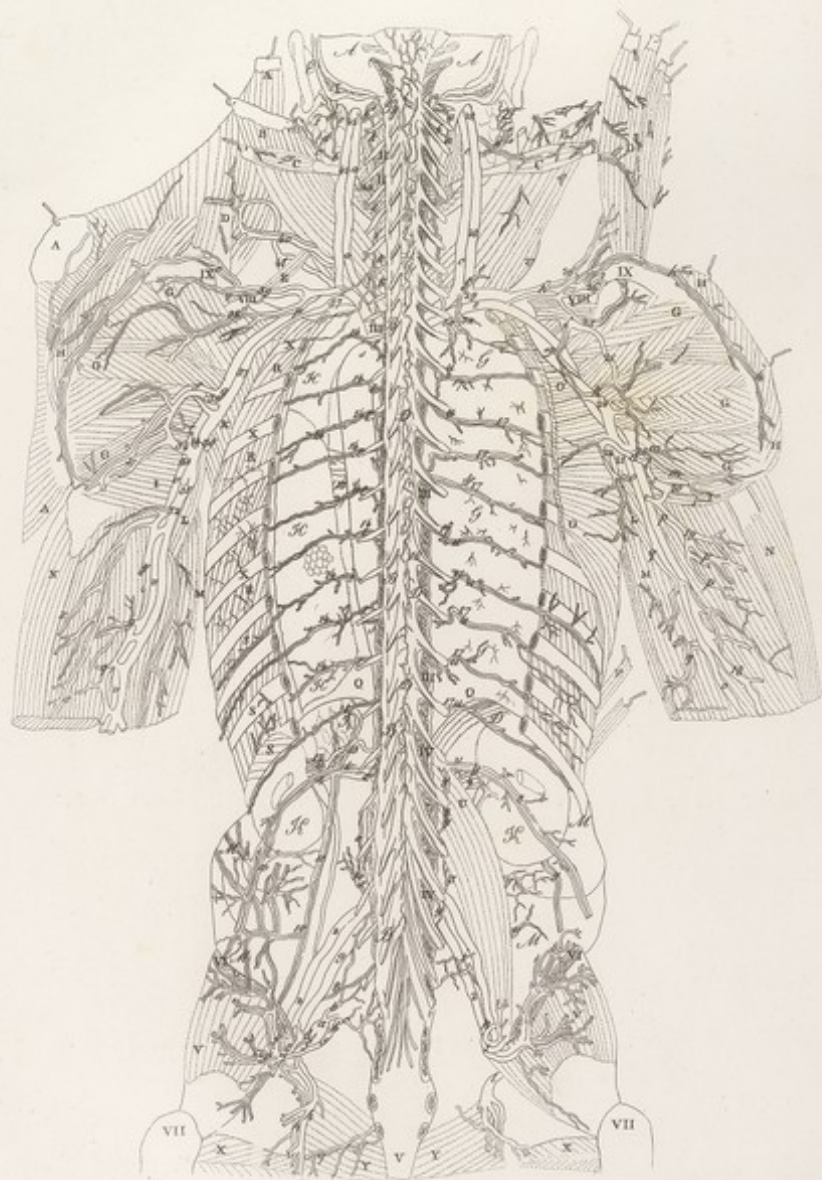
*Scultori Scuderi del. sc.*







VISCERI TAVOLA XVIII. *Lta.*





F. XX

VISCERI Tab. VIII

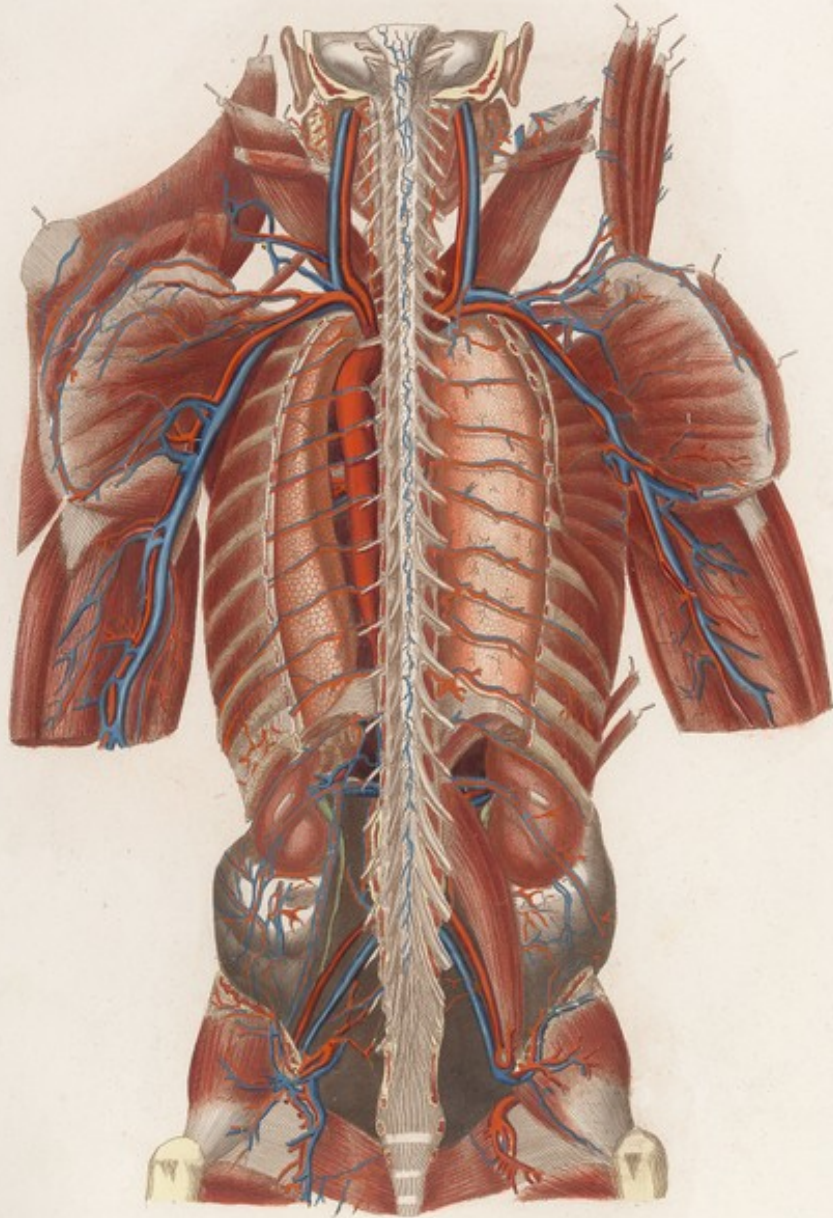
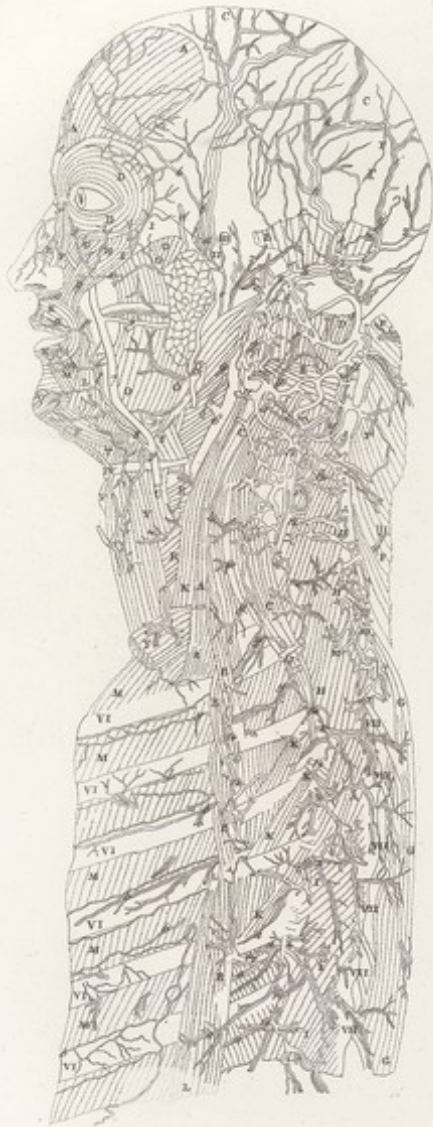








TAVOLA PARTICOLARE XXVI *Lia.*



*F. n.*

TAVOLA PARTICOLARE. XVI

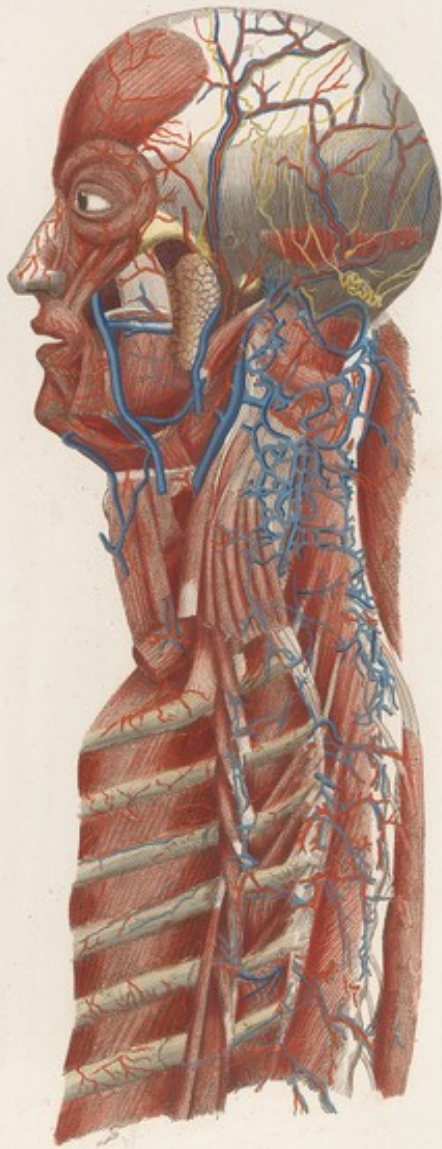
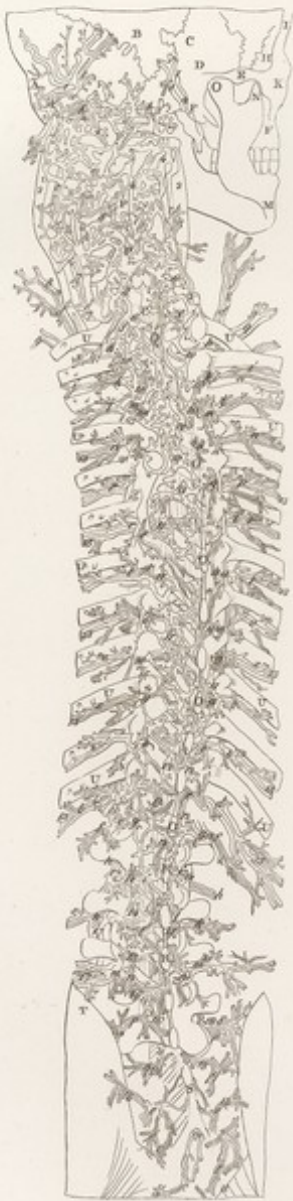





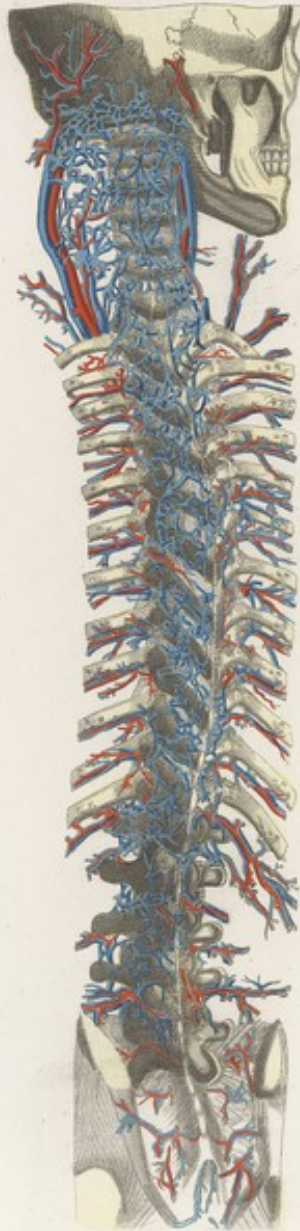




TAVOLA PARTICOLARE *XVII* *Liv.*

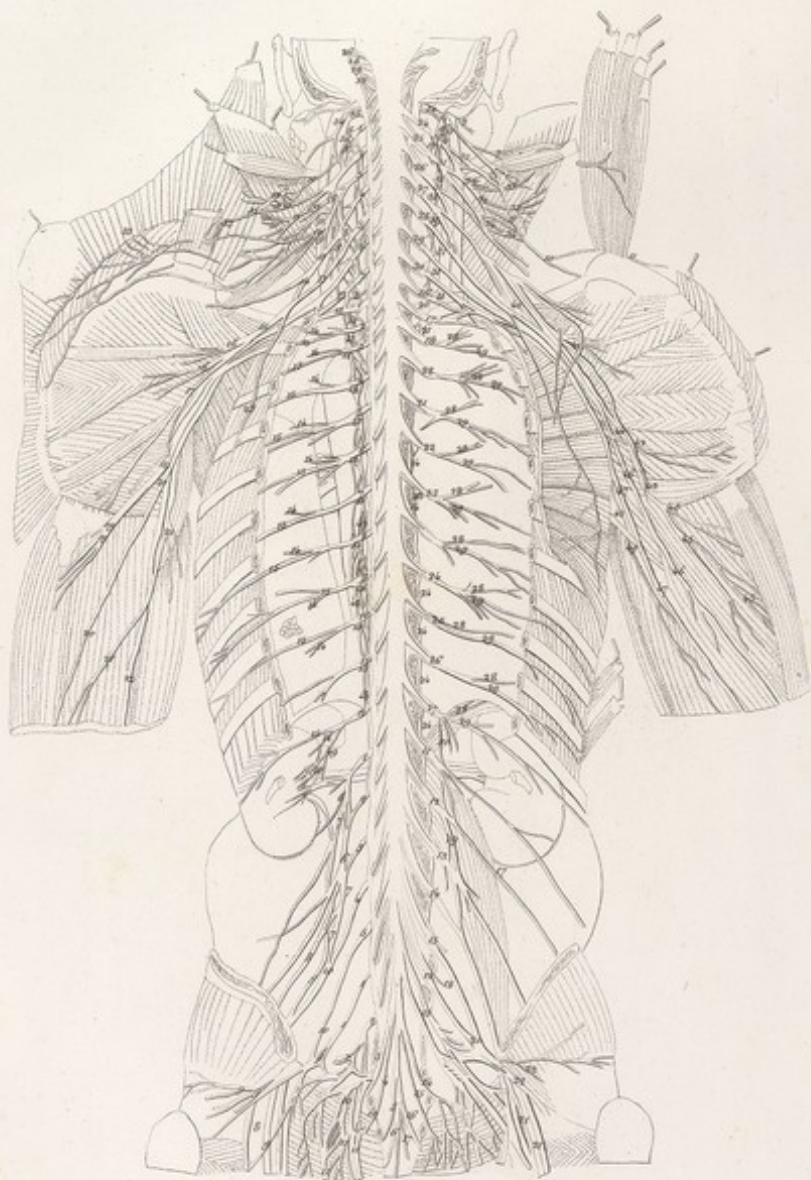








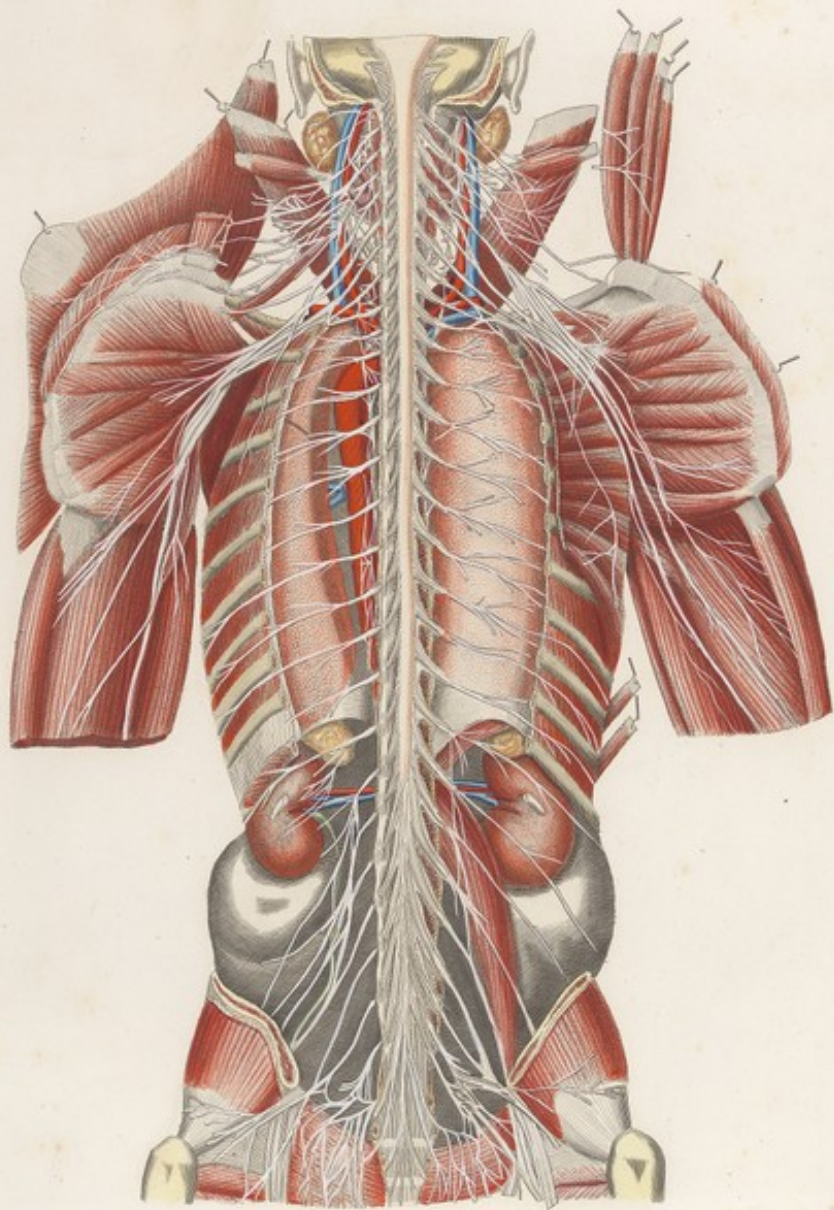








F. XXI

VISCERI Tab. XIX







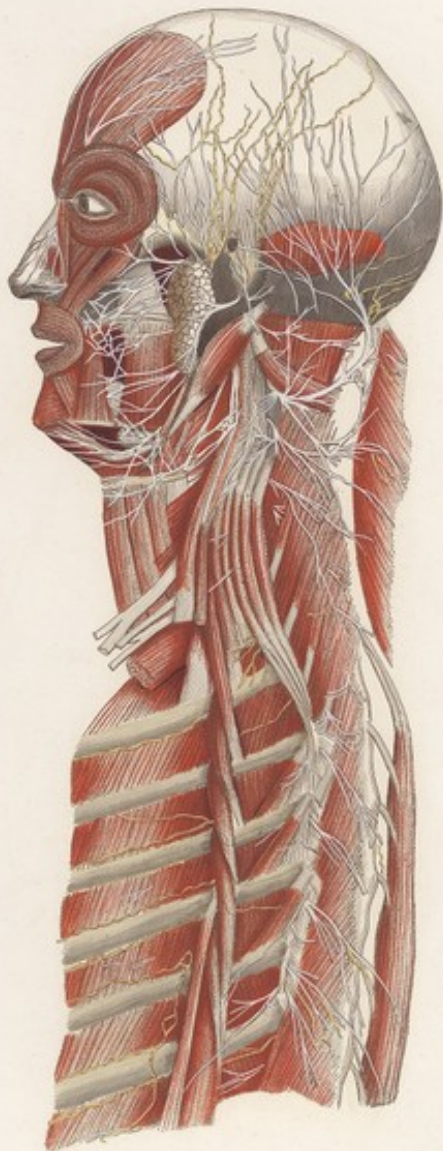








*F. XXI*

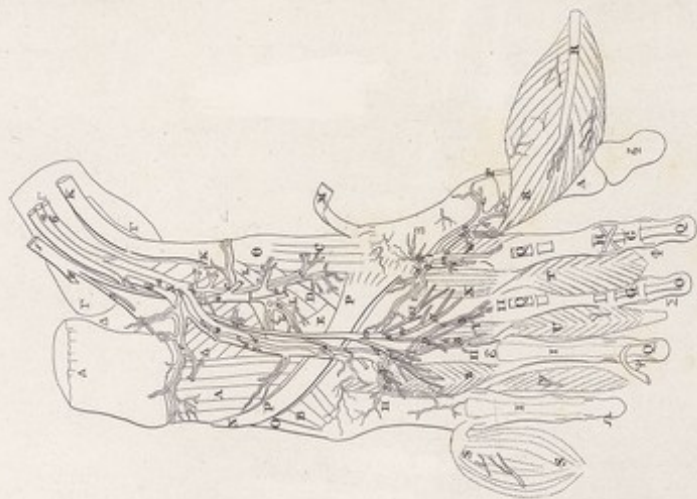
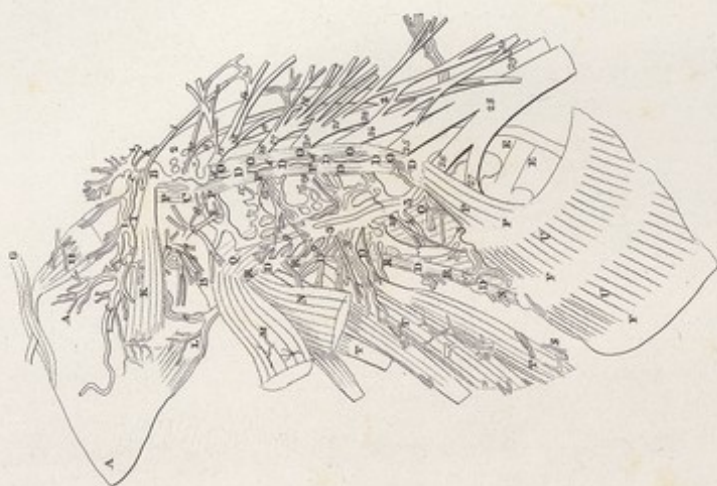
TAVOLA PARTICOLARE XVII



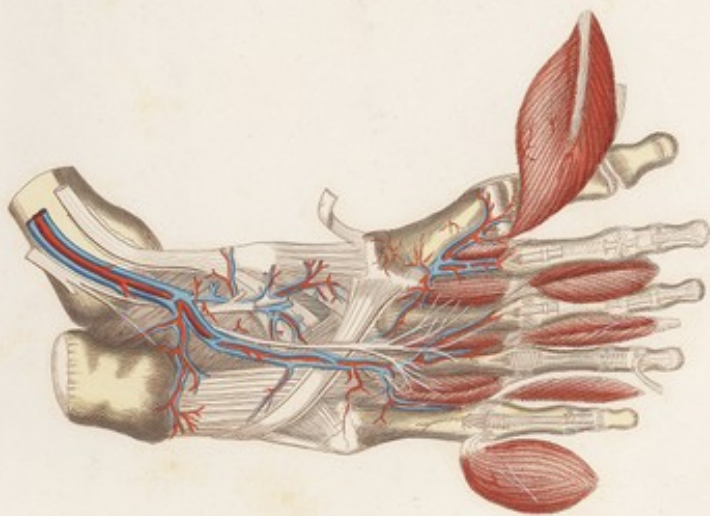
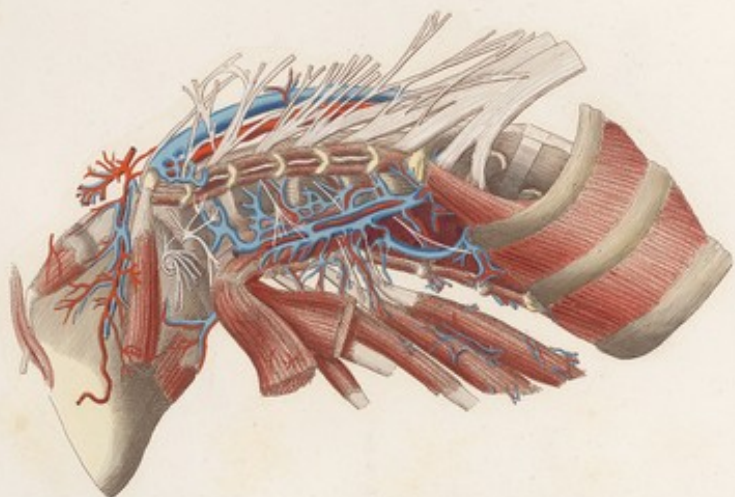












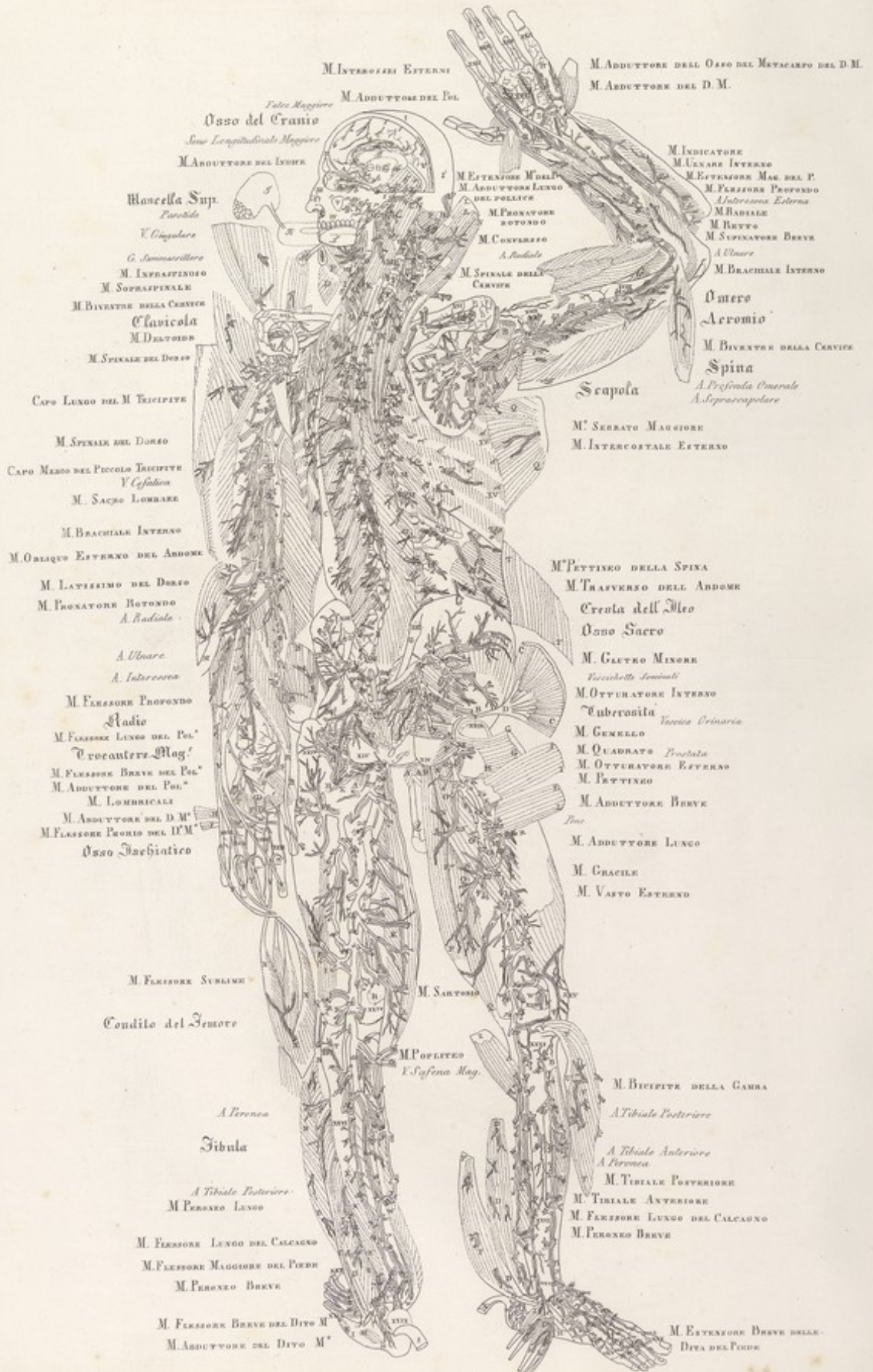




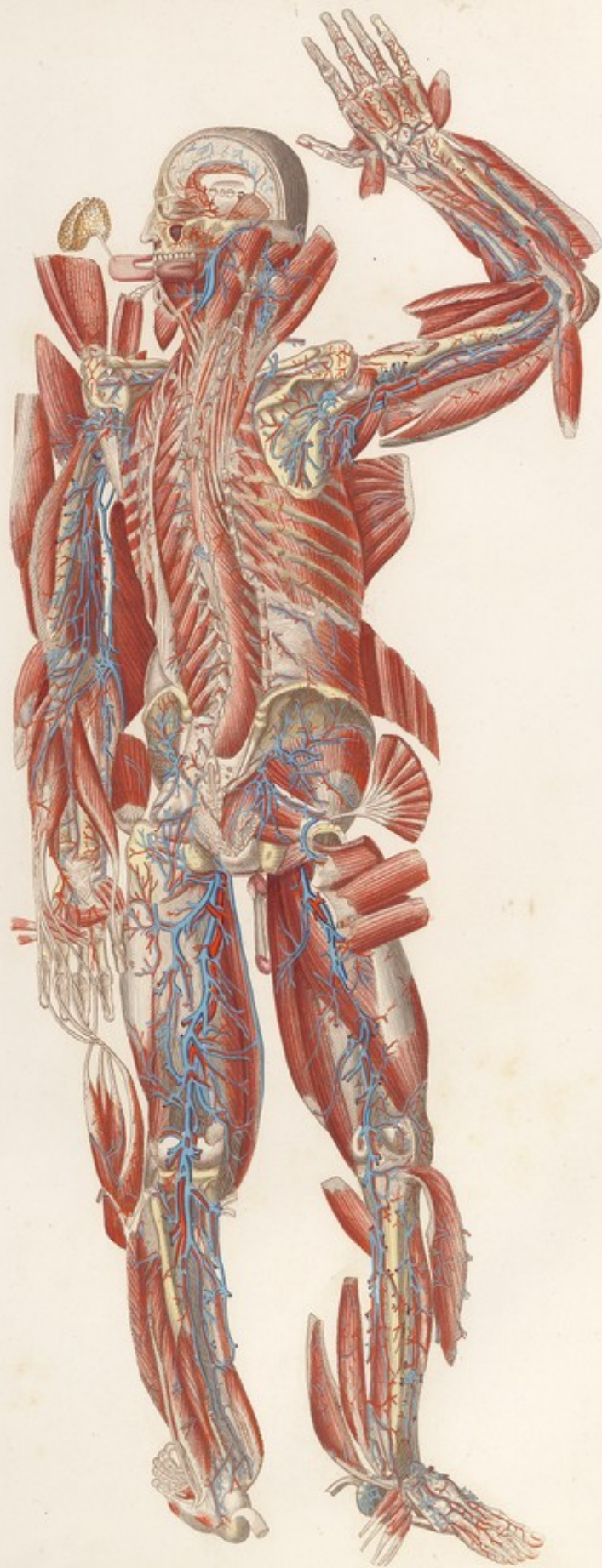












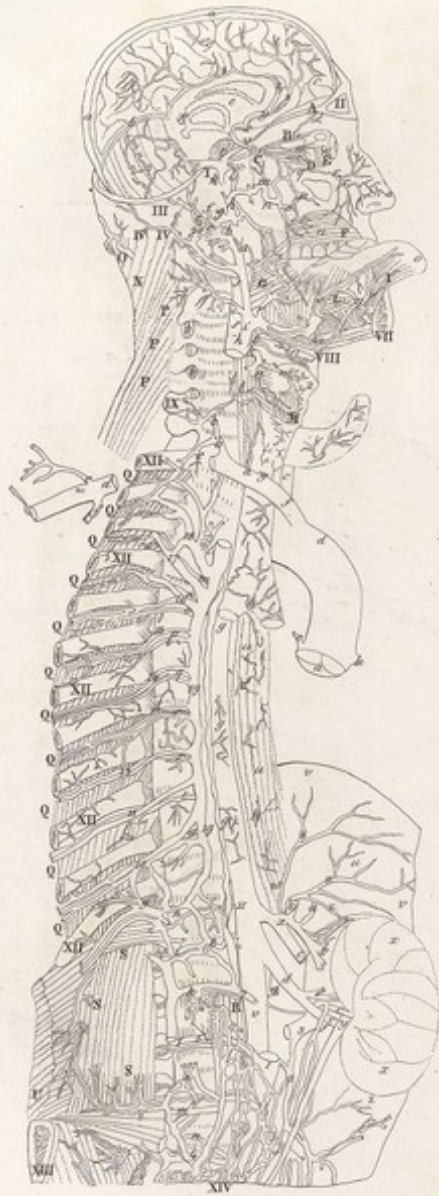






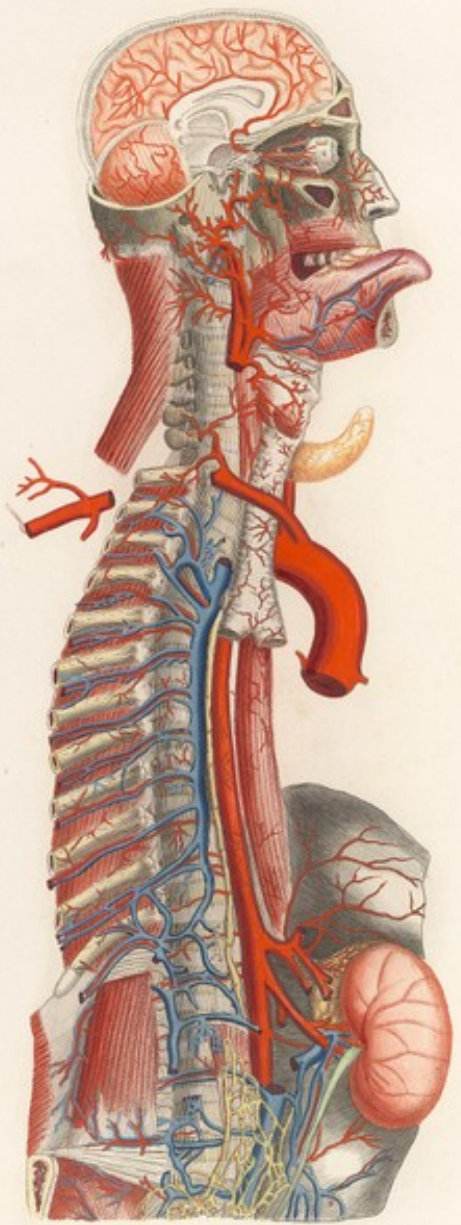







LXXXII


VISCERI Tab. XXI.

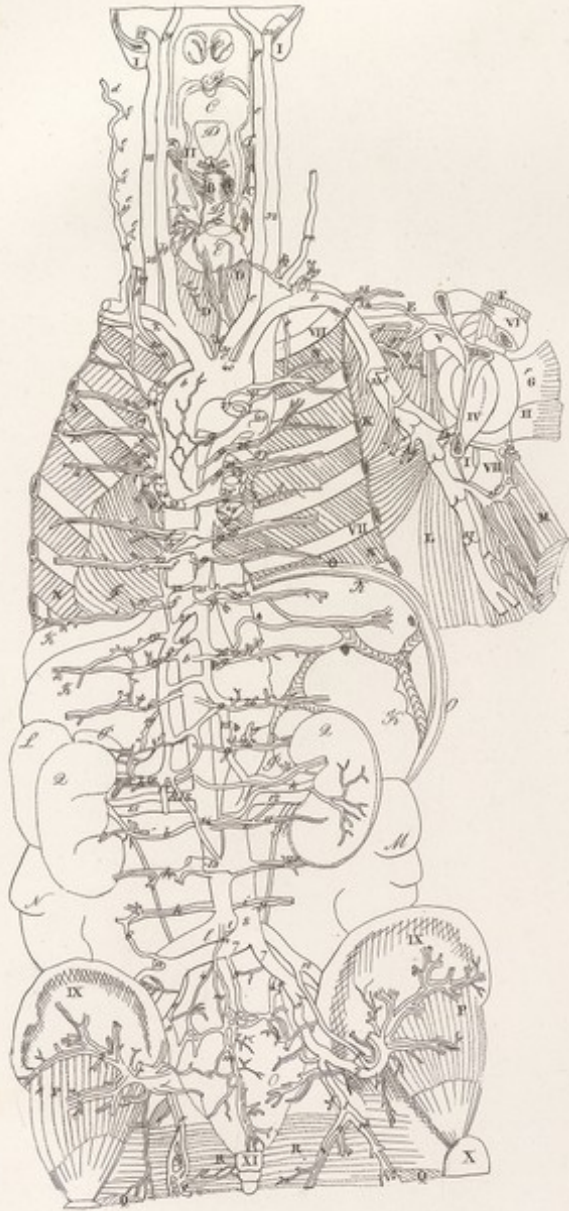




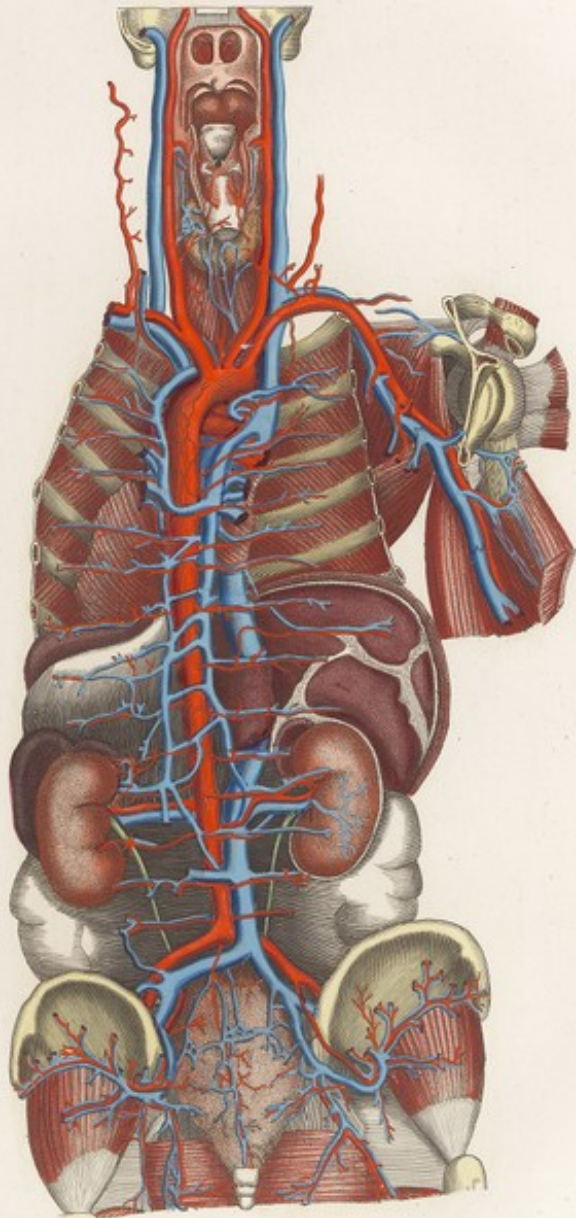









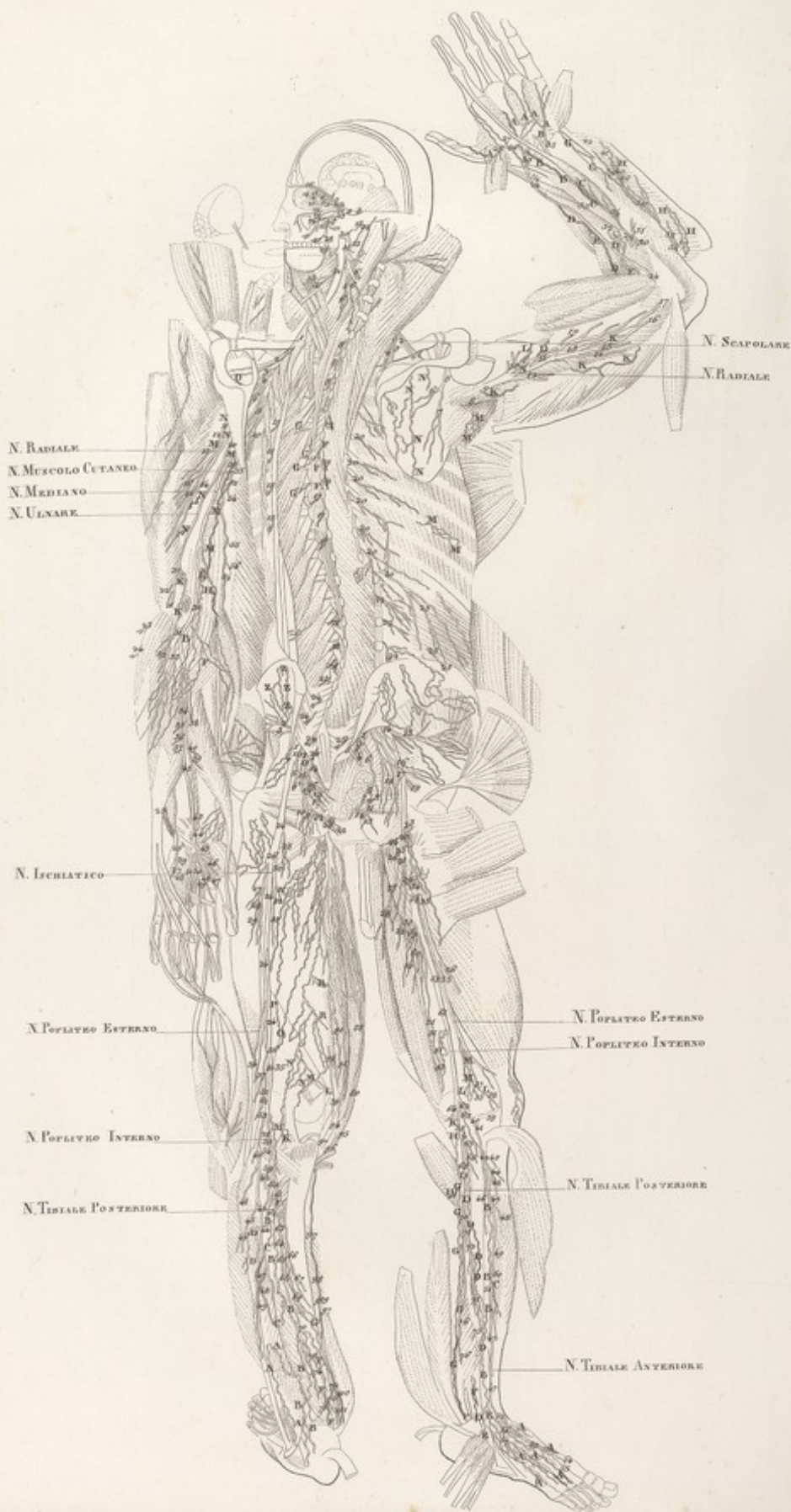




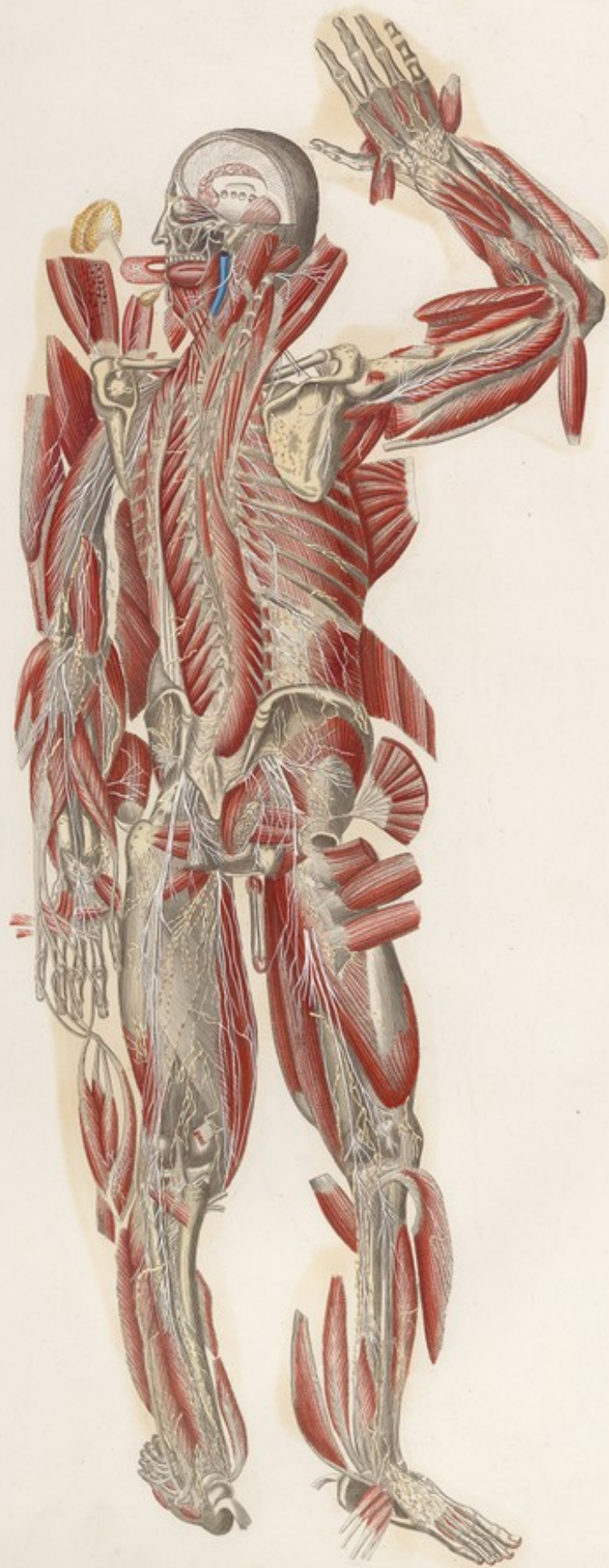











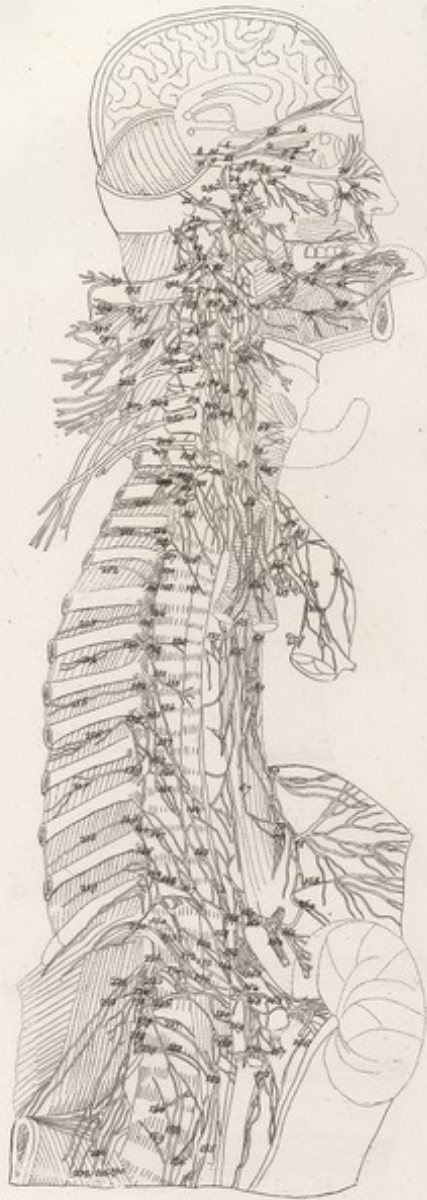







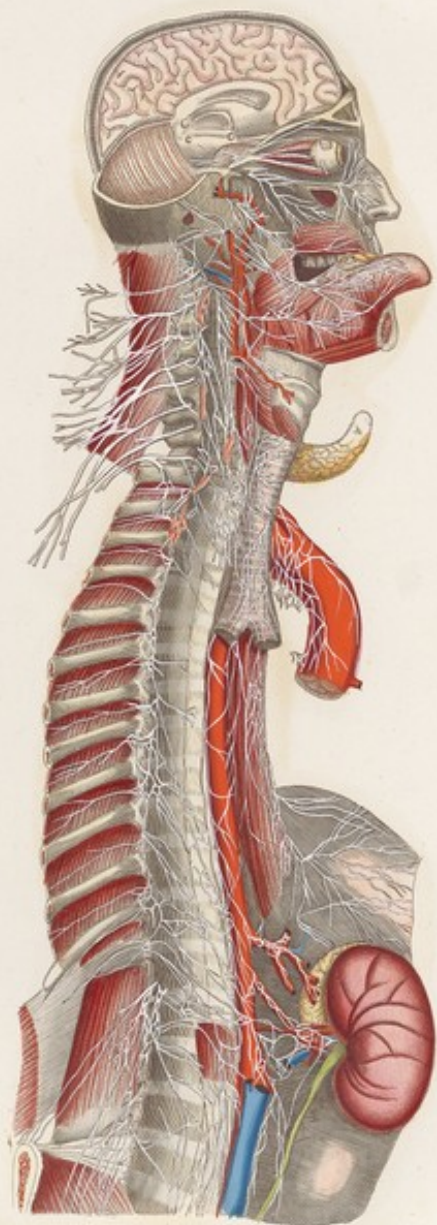


VISCERI *Tab. XXII. Lin.*




F<sup>XXIII</sup>

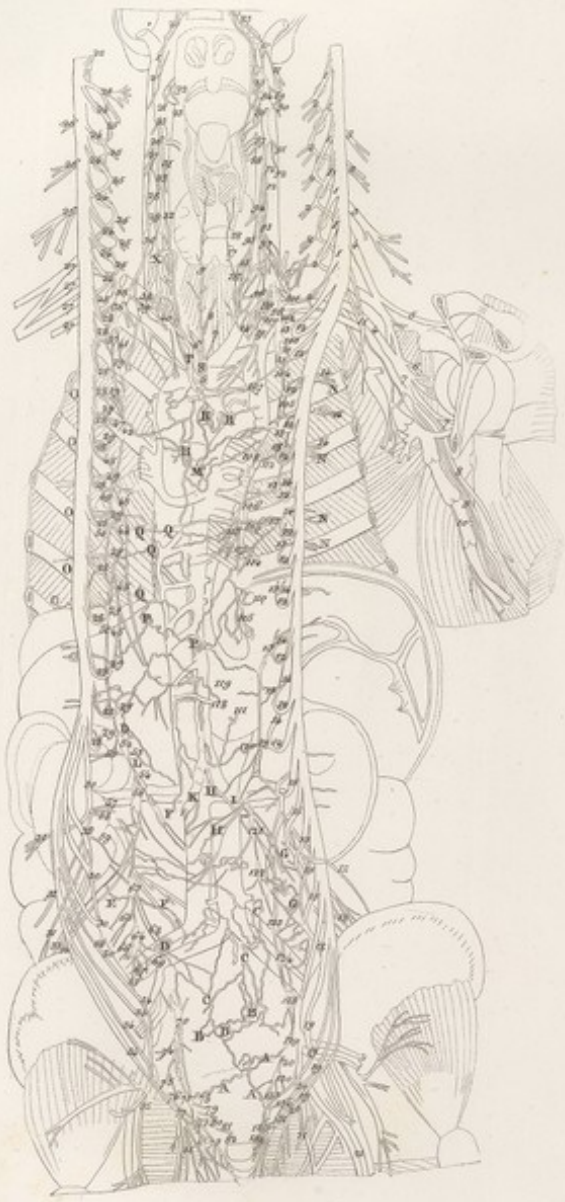VISCERI *Tav.* XXII



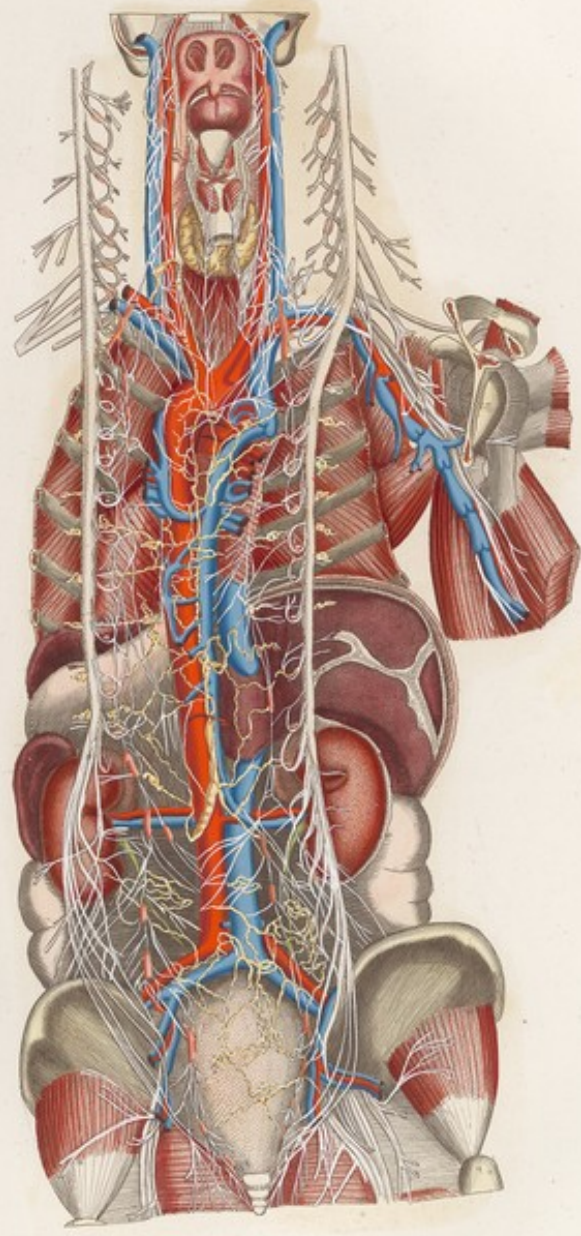










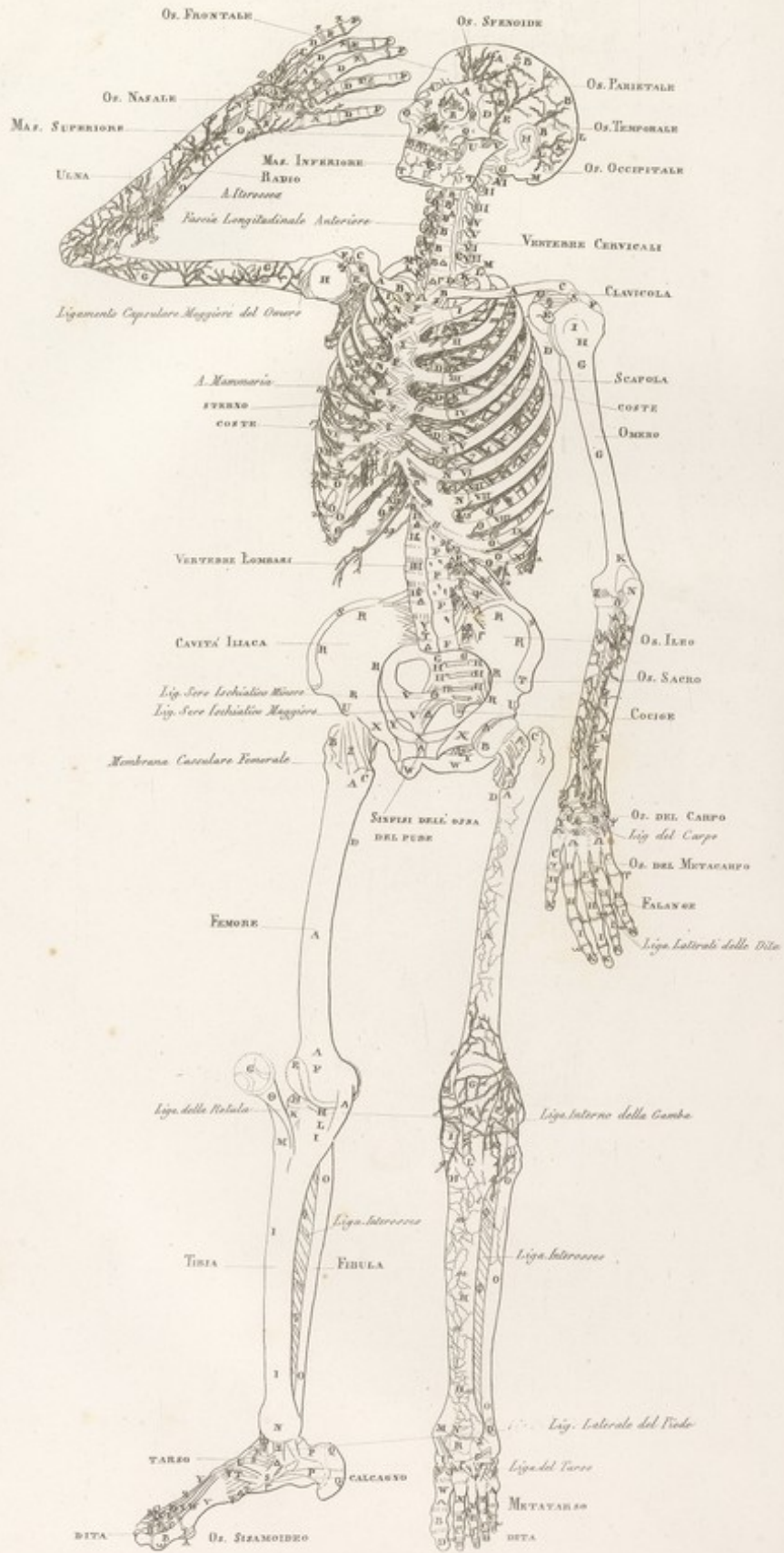




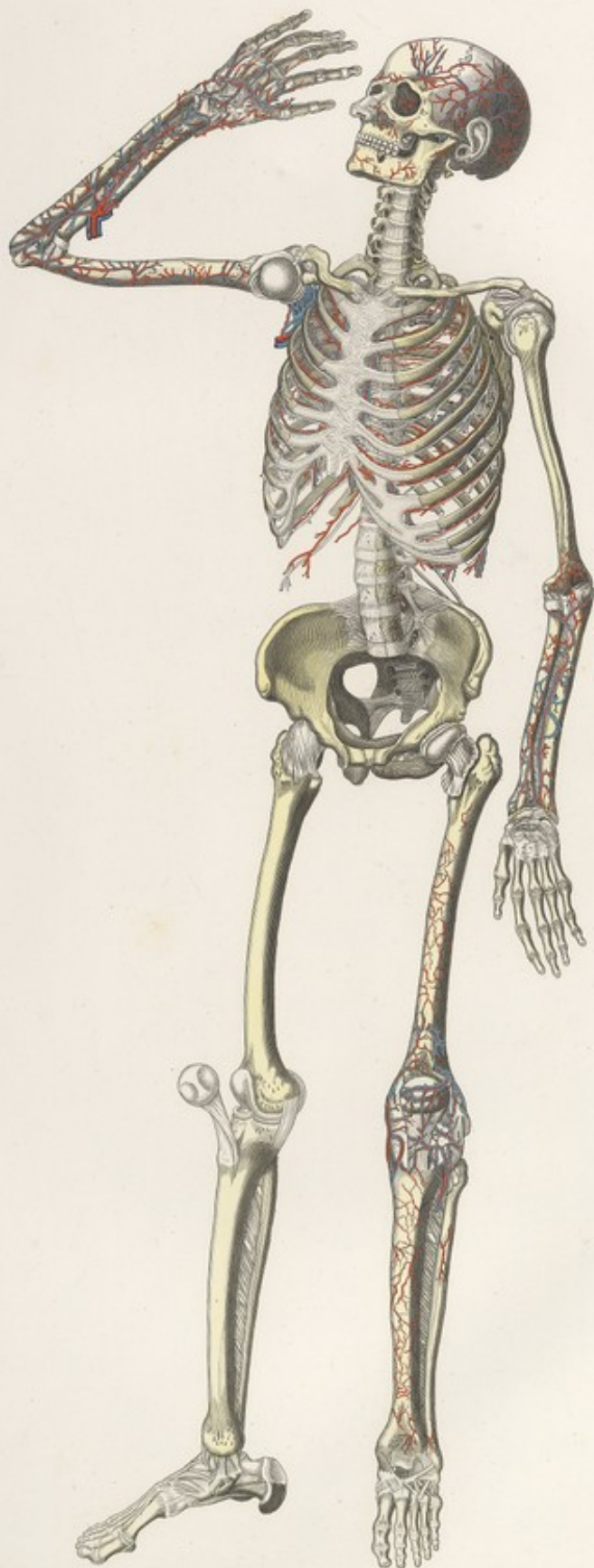






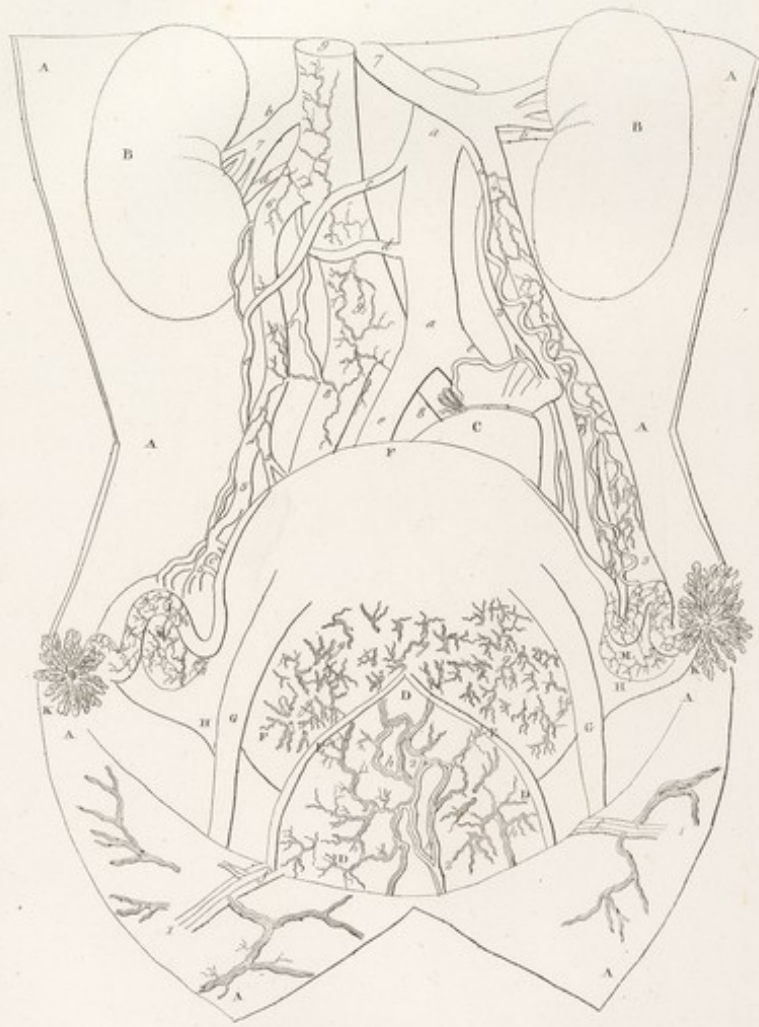




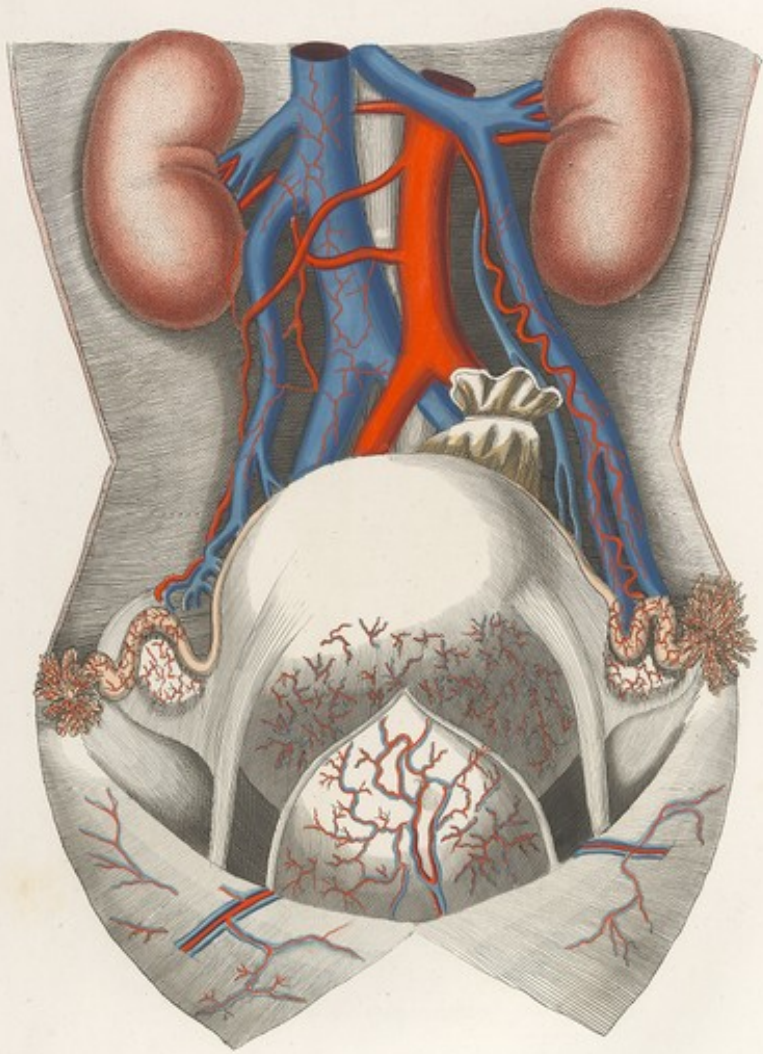












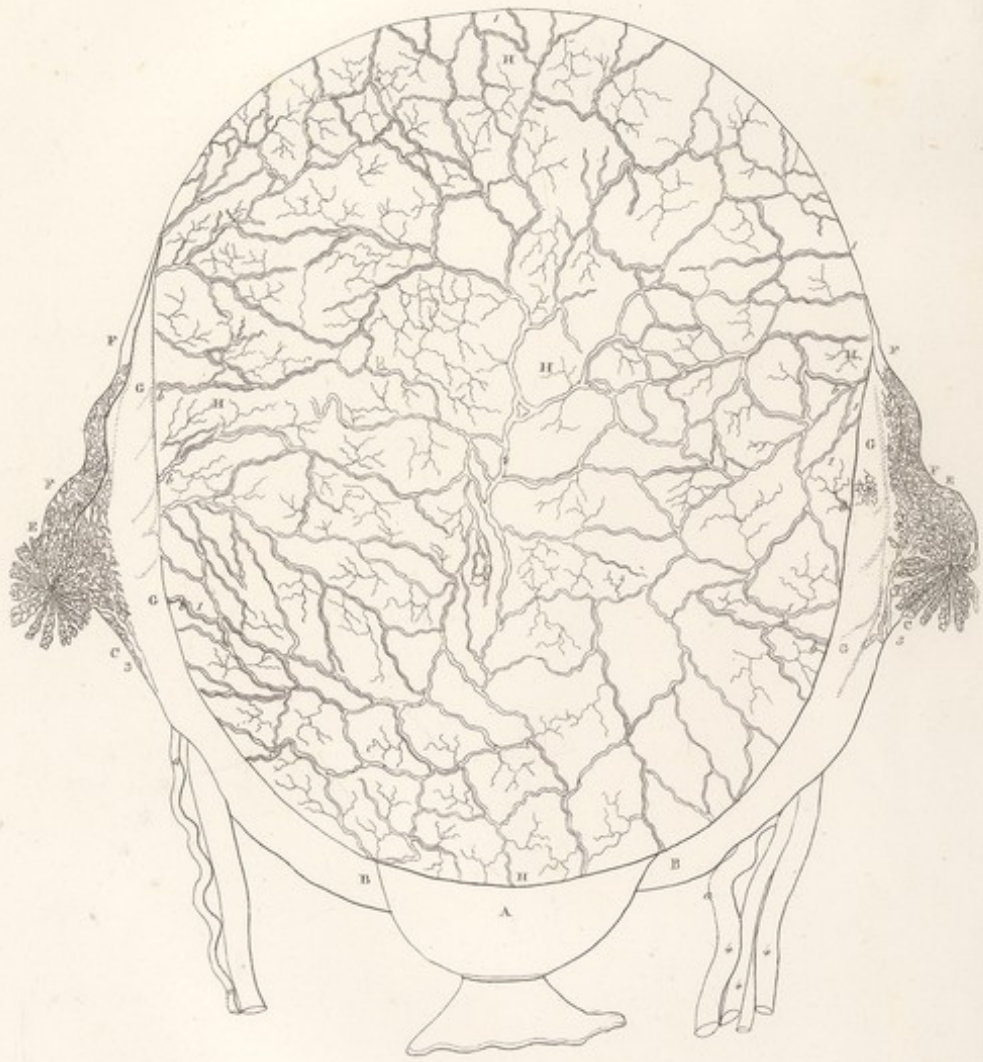




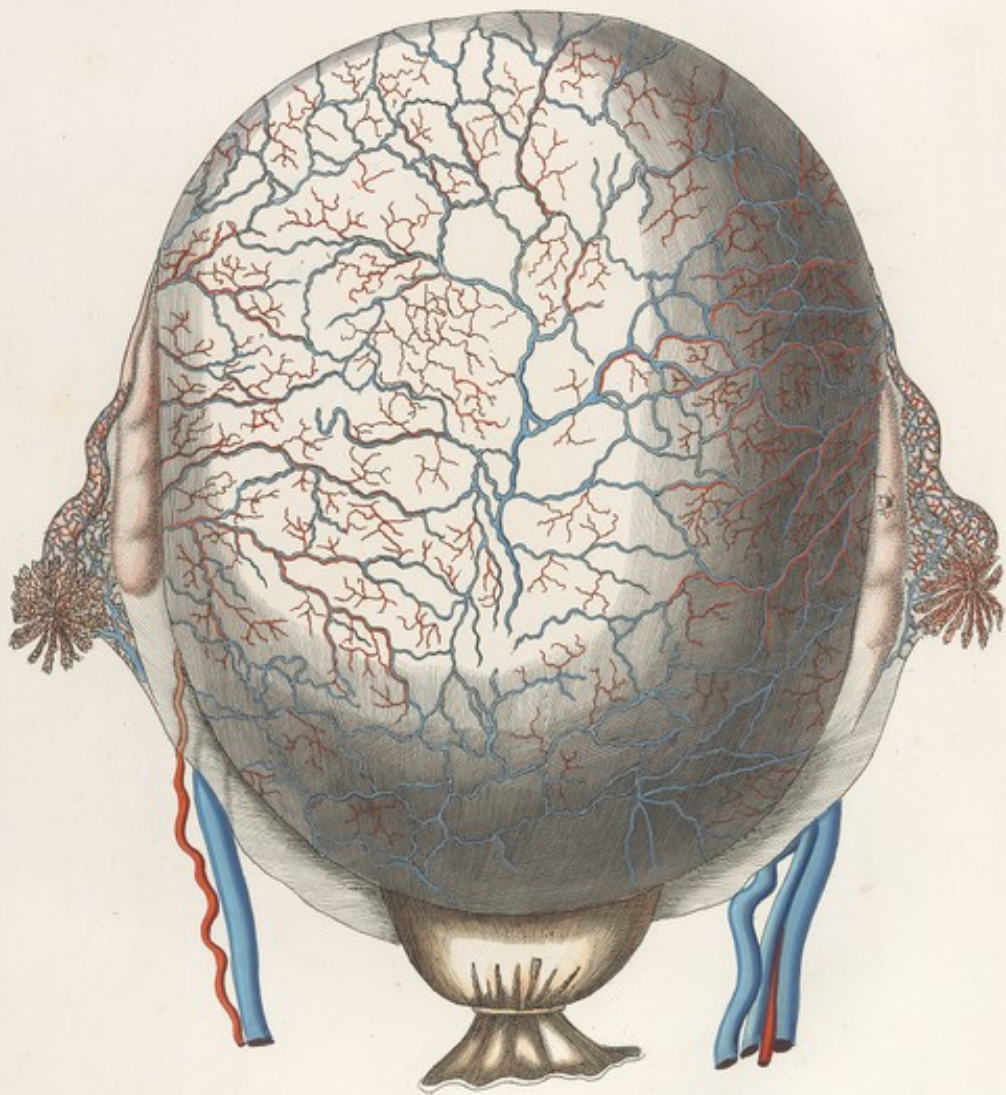
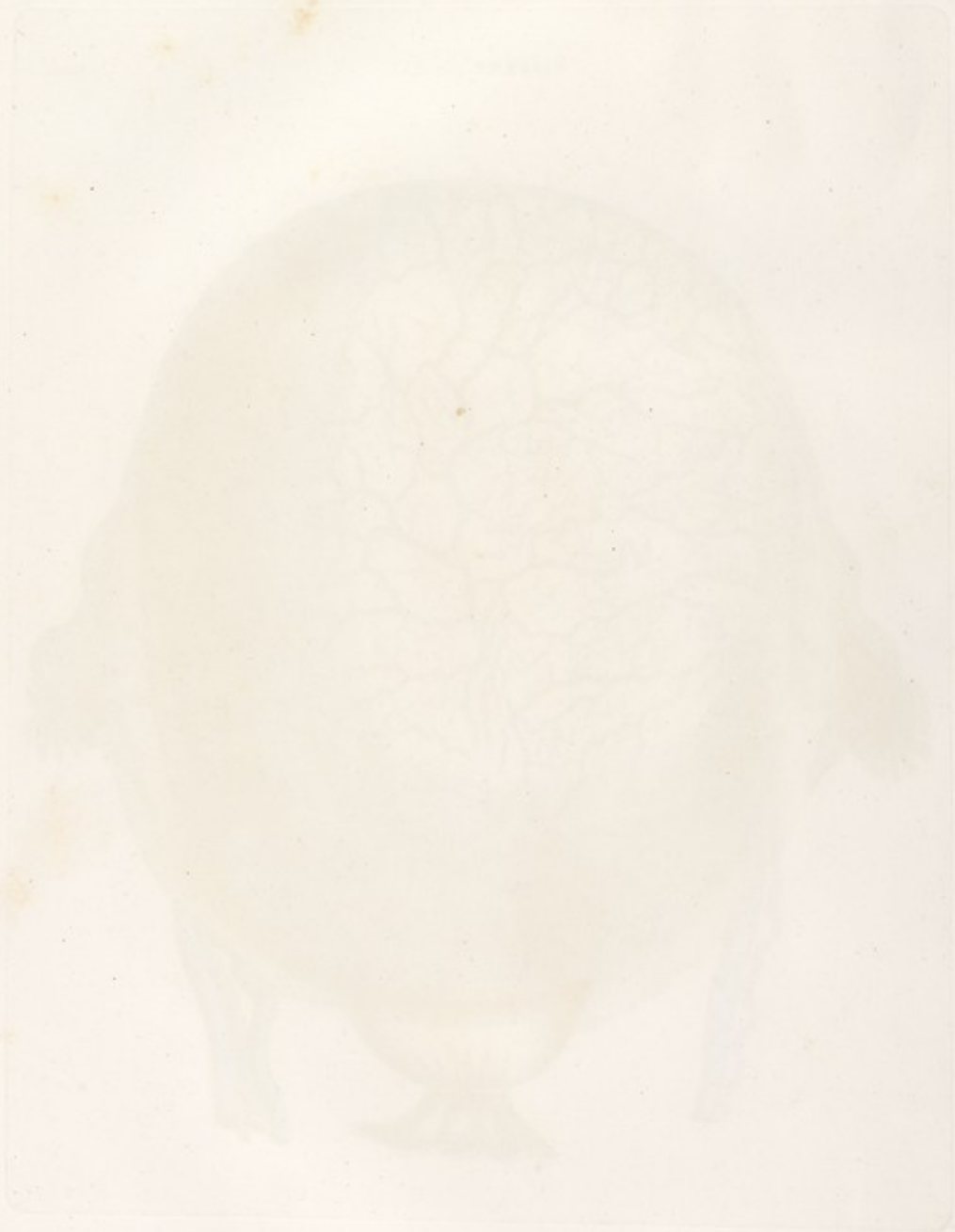








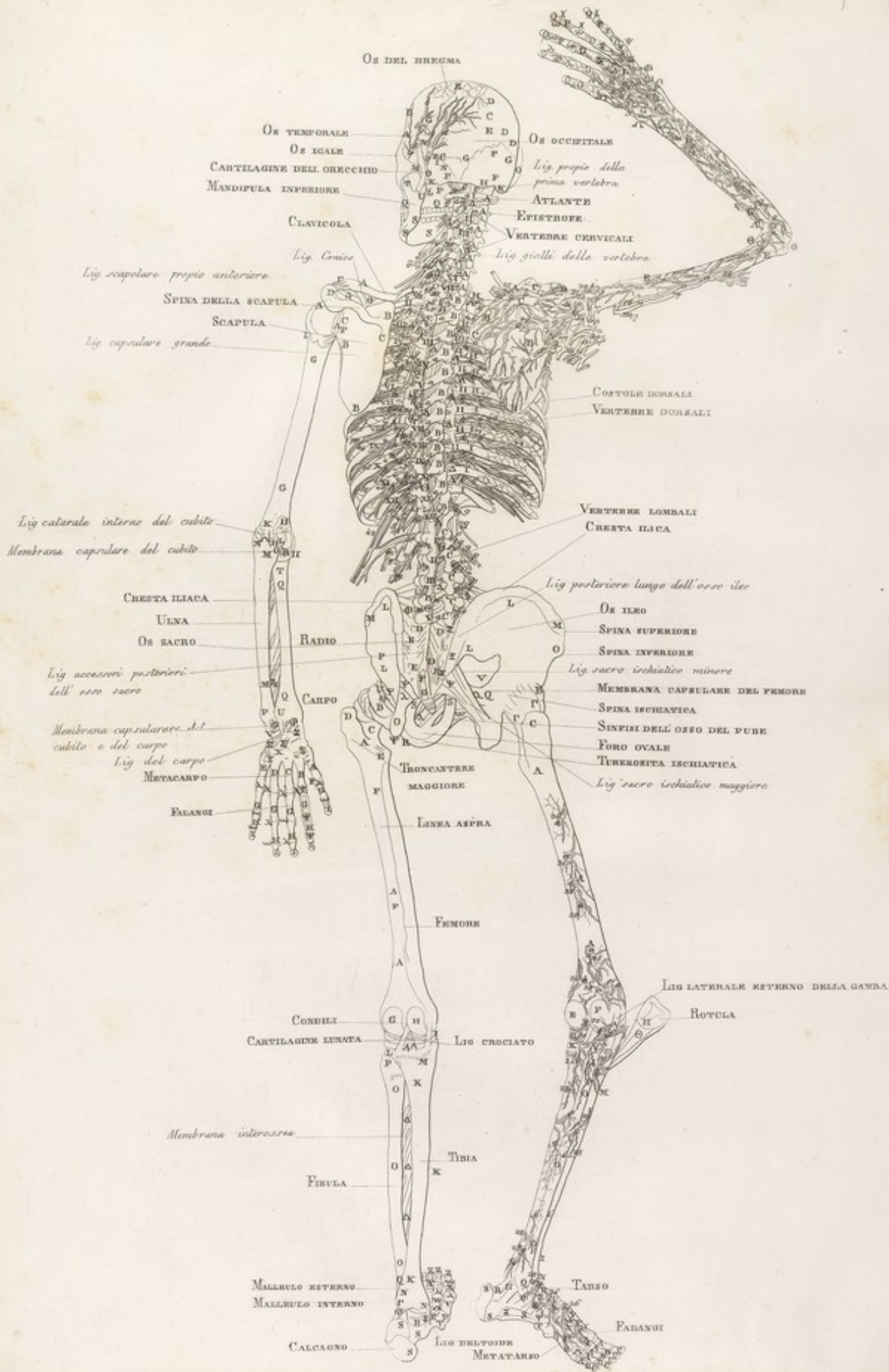




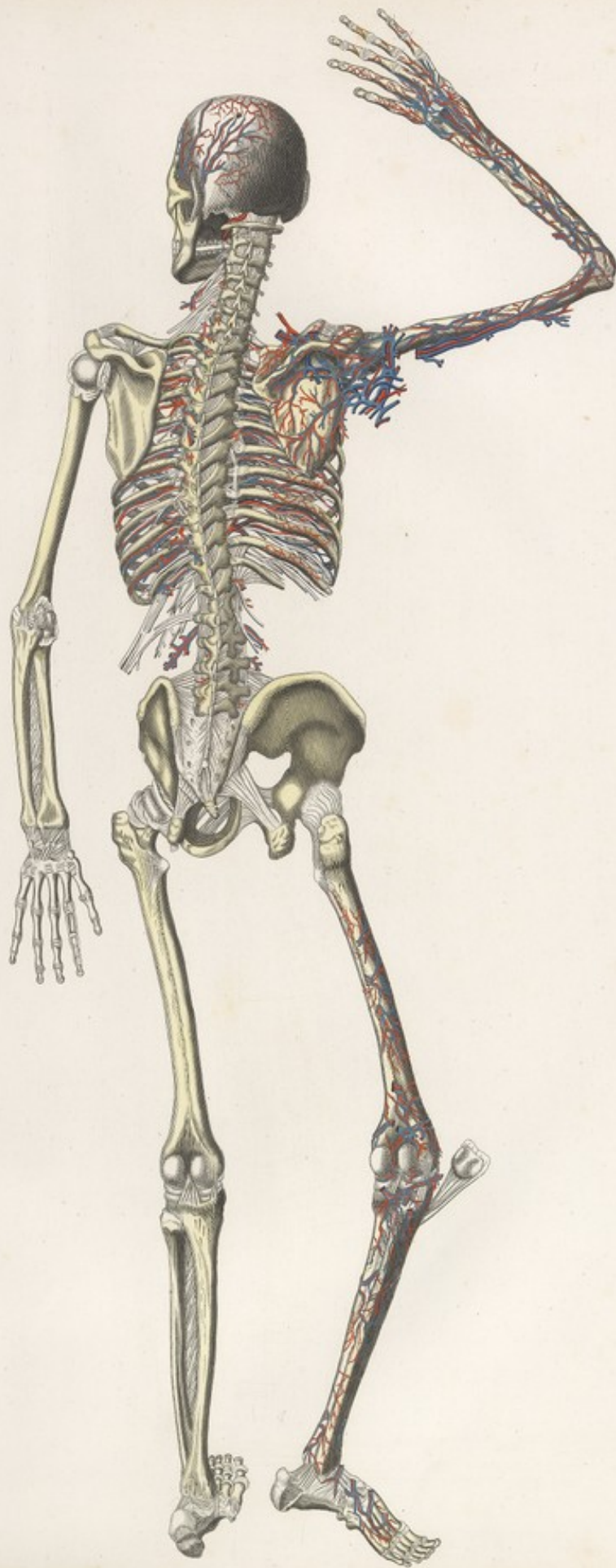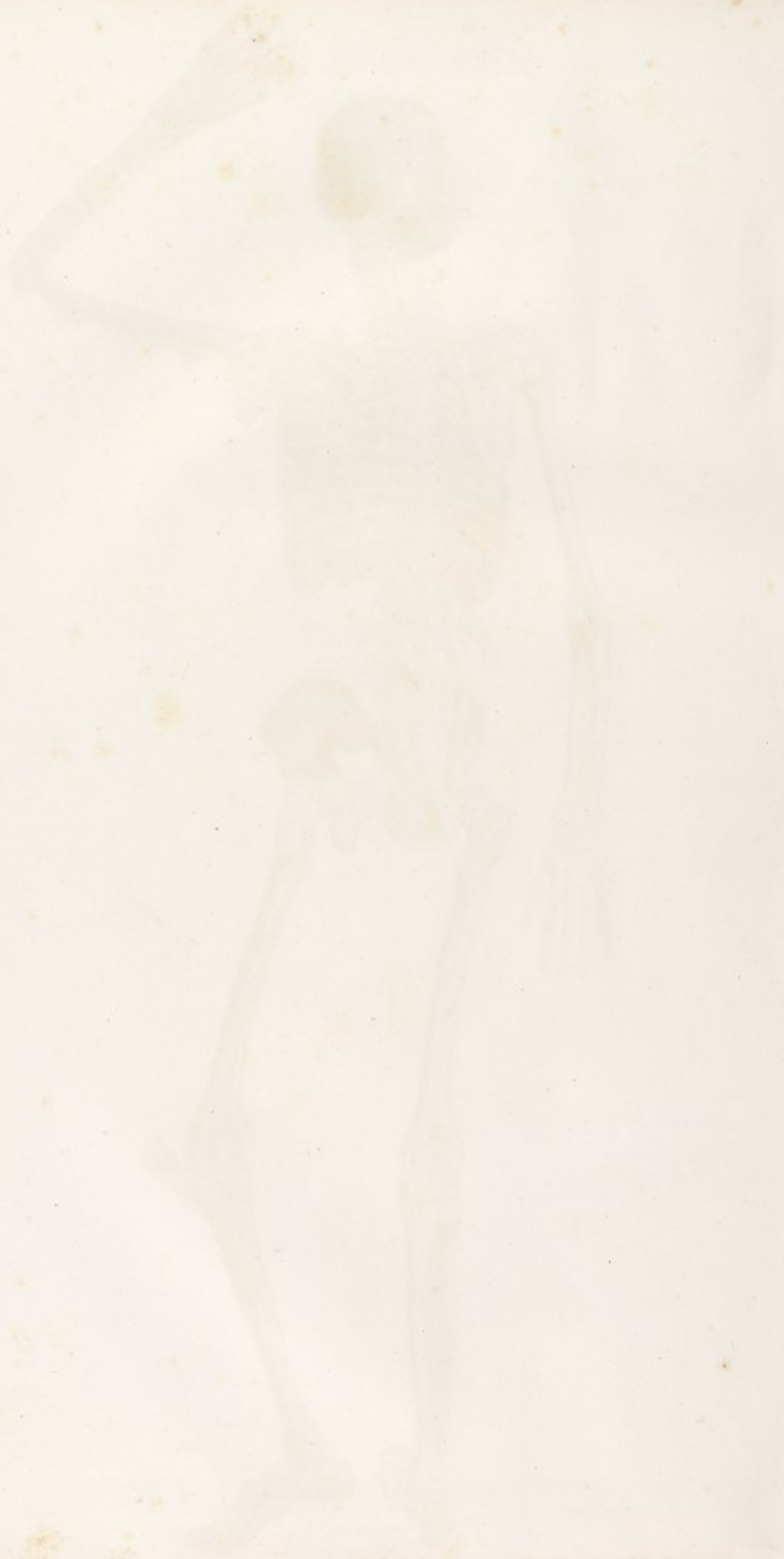





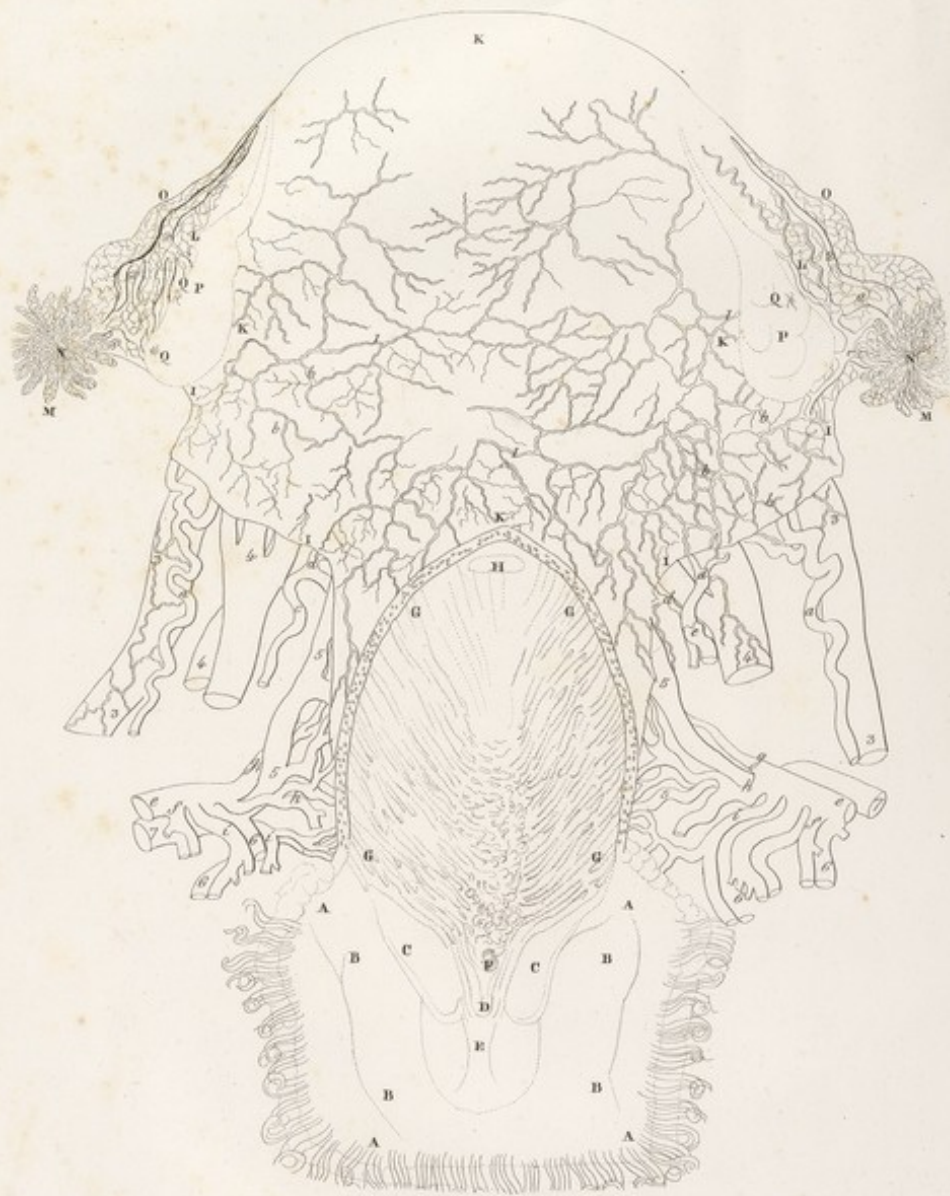





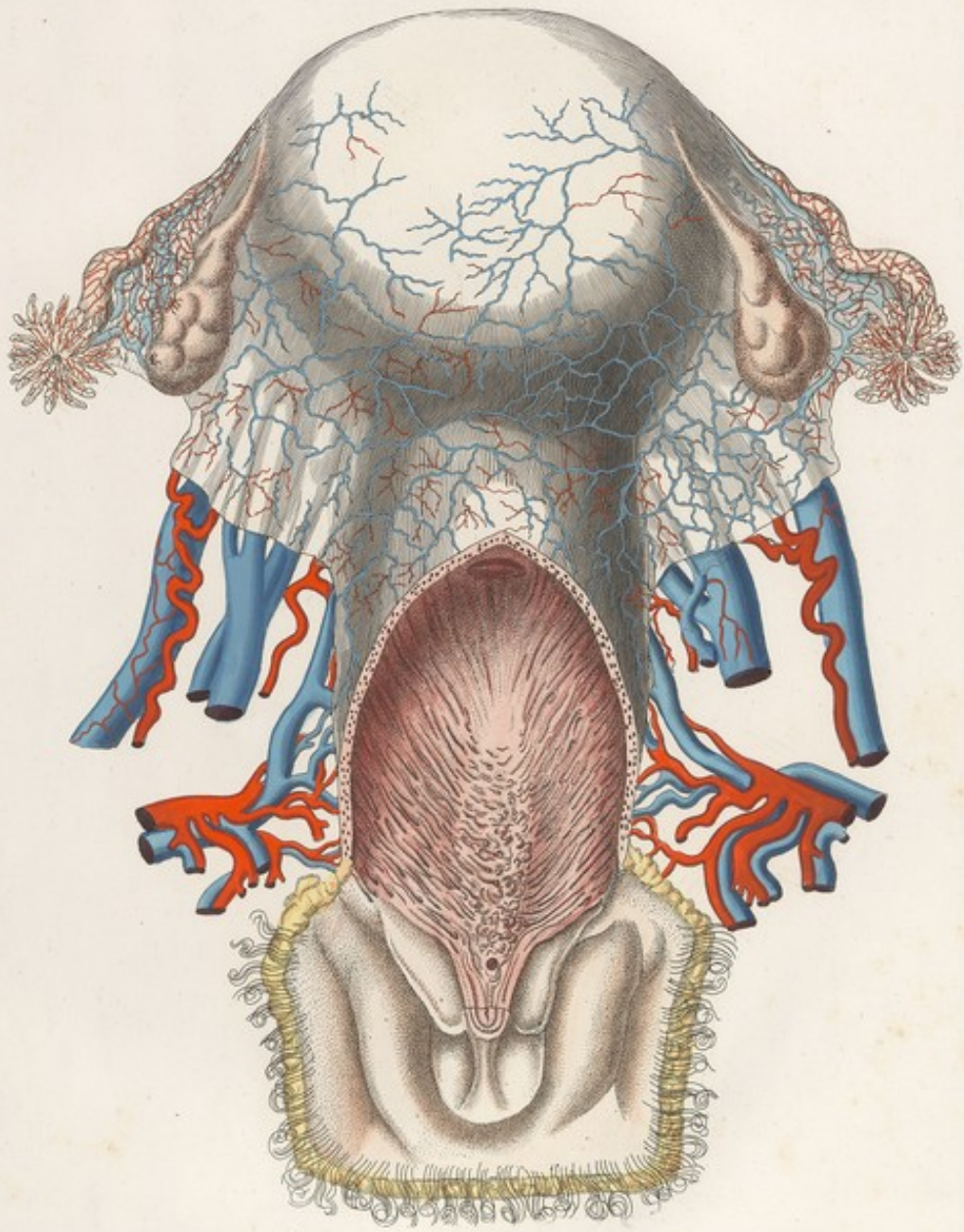











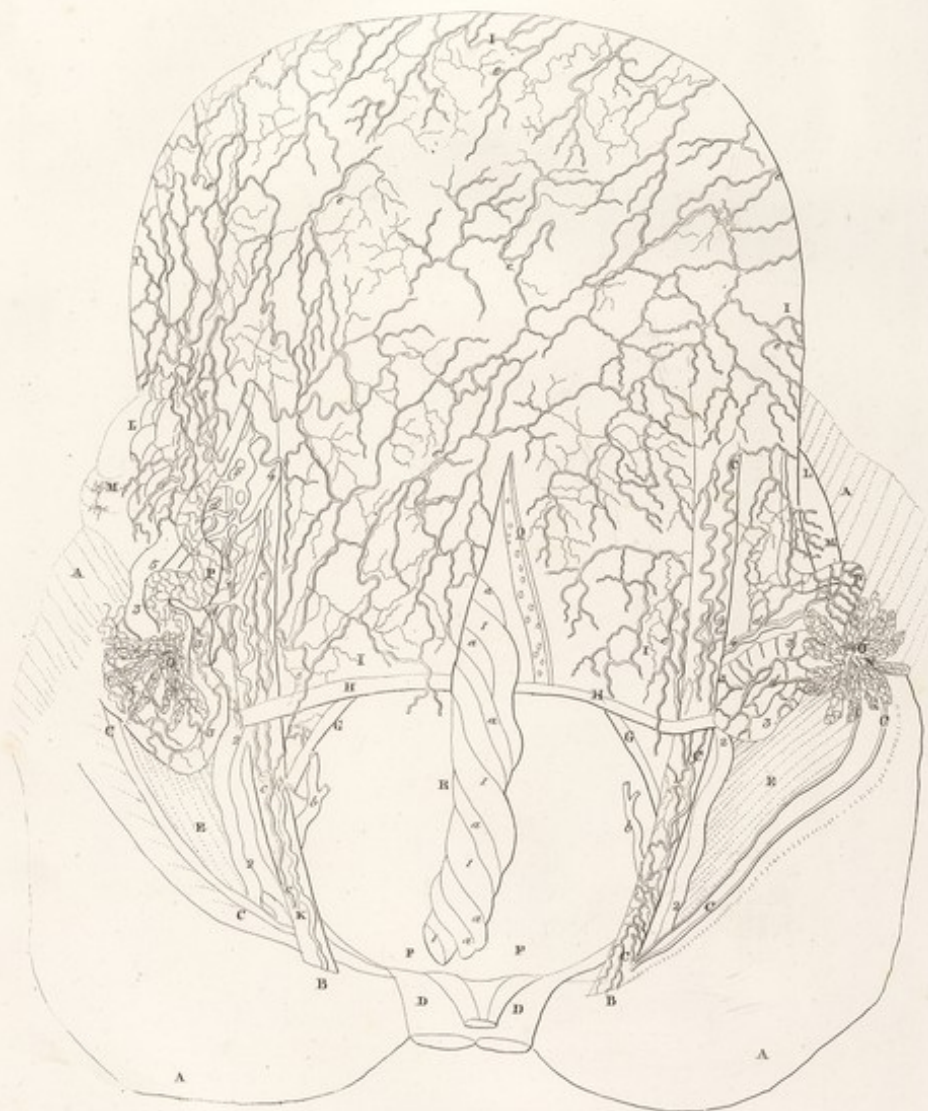




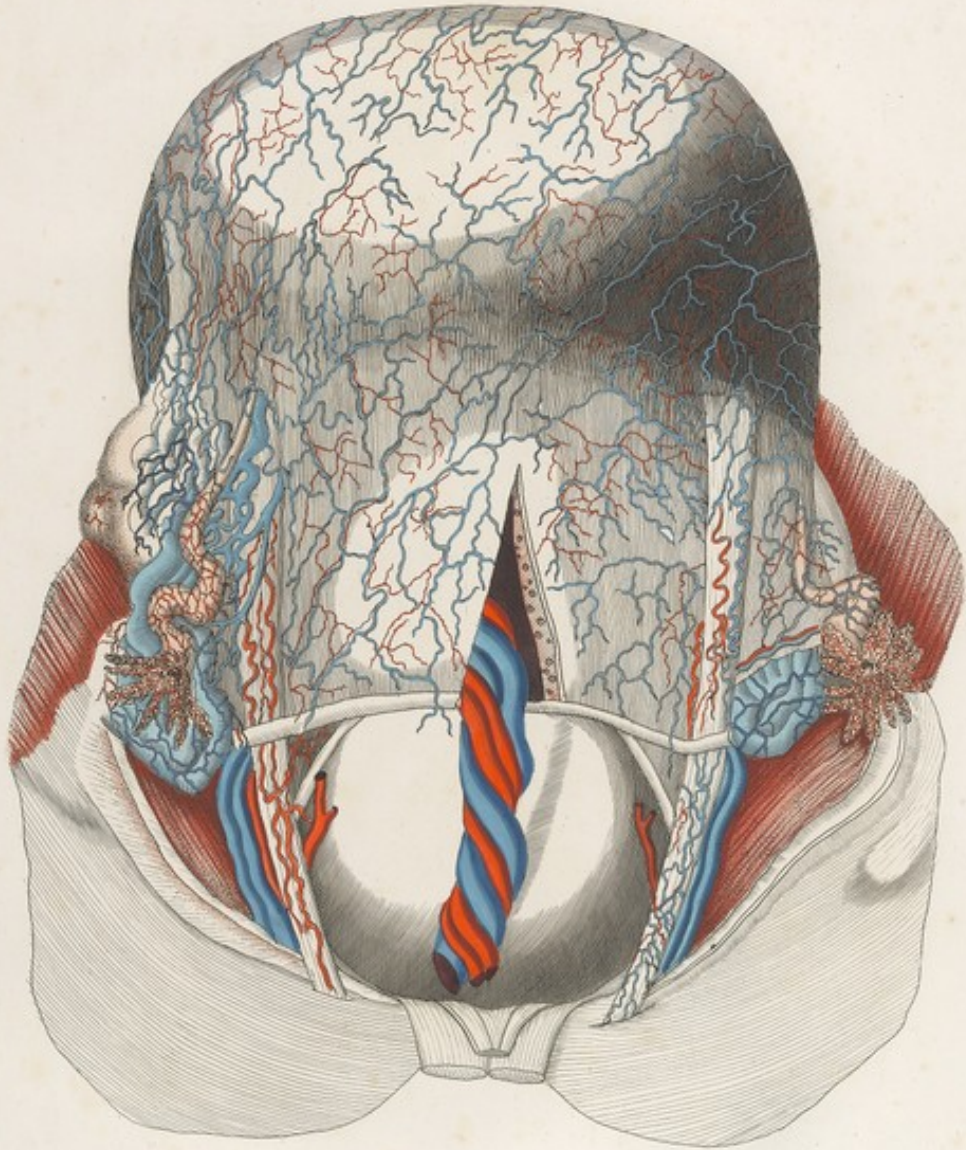
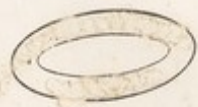
































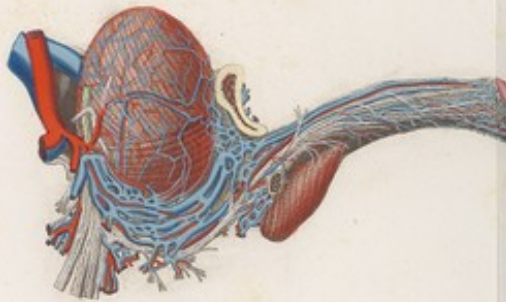
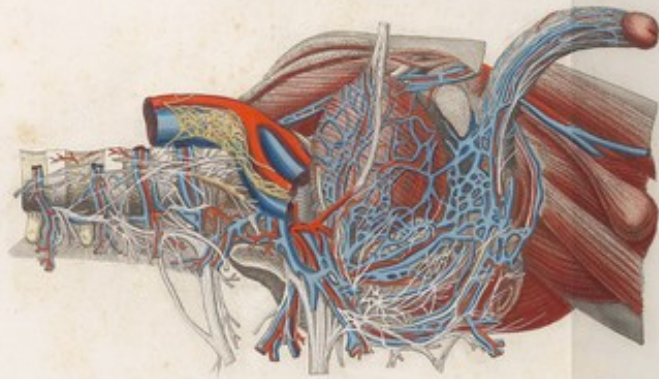







MASCAGNI  
ANATOMIA  
VALERII  
DESCRIPTE

2  
TAFELN

D

IV

TAVOLA PARTICOLARE XI



*Anterior Structure Superior vena cava & aorta*

