CASH

BOOK

1984

No 6 -
1863

Case 2 - Bottom Shelf.

198 A

INDEX.

Month	Date	Cases	Pages

INDEX.

INDEX.

6

INDEX.

INDEX.

Month	Date	Cases	Pages

No 1

~~INDEX.~~

Month	Date	Cases	Pages
		Perineal Section. Stricture	
May	4	Dwarkie Hindoo Barber. aged 26 years Resident of Calcutta admitted 4th May/63 with Stricture & retention of urine. Has had Gonorrhœa six months ago which lasted three months. After this there was no discharge from the urethra. About 20 days ago he contracted Gonorrhœa again. During the last 2 months he has been passing water in a very small stream and with great difficulty & straining. It has become gradually worse and worse & finally ended in complete retention which brought him to the Hospital. After fomentation. Opium & Chloroform a pint deep passed. An hot worked and after some difficulty a small one introduced & the urine drawn off. The stricture had very tight & irritable. bleeding from prostate when touched.
"	5		
"	6	Cut down in the perineum found the tissues of the perineum healthy but the stricture very tight. denied it on a grooved staff. & introduced a Catheter into the bladder through the wound.
"	7	Doing well but has had fever

Month	Date	Cases	Pages
		Perineal Section Stricture	
May	7.	He had pain over the pubes and in the bladder. it appears that the tube has been pushing against the anterior wall of the bladder.	
"	8	He is doing well. no return of fever or pain, urine flowing freely through the wound. Took out the tube and introduced the Catheter No 8. into the bladder through the urethra.	
"	9	Passed No 10. with little difficulty has no fever or pain. urine flows freely through the wound.	
"	10	He is doing very well. Passed No 9 wound looks healthy. has no fever.	
"	11	Passed the Sound No 9 with great ease this morning. he is improving rapidly.	
"	15	Wound rapidly closing. Use 10 passed without ease. He is much better in all respects.	
"	17	No 11 passed easily. He is much improved in every way. wound closing	
"	20	He is doing very well. Pass No 10 sound	
"	22	The wound has nearly healed. Yesterday he passed through it a rough pale colored Prostatic Calculus about the size of a lima bean. He is in excellent health.	
"	25	Passed full sized sound.	

Month	Date	Cases	Pages
		Perineal Section.	
May	29	The wound has very nearly closed. Though a small sinus a few drops still pass but they are controlled by the finger and the orifice is gradually contracting.	
"	31	Catheter slightly swollen. Do not pass any urine. Wound all but healed.	
June	4	Passed N. P. but the swelling after catheter still continues.	
"	6	Better in every way. A drop or two pass through perineal wound and passed full speed urine today.	
"	10	She is well. A very nearly as the eyes he is very anxious to go. He may be discharged cured.	

Admitted May 4th
Operated on " 6
Took out the tube " 8
Discharged June 10
In Hospital 38 days

Month	Date	Cases	Pages
		Tracheotomy. Ulceration of Larynx & Oedema Glottis	
May	8th	Ram Churn. Hindoo Coolie. aged 20 Remaining at Jugganath Ghat. a Beggar. Admitted on the 8th May with the following Symptoms.	
Original report		"Had Cough about a month ago. attended with much expectoration - About 20 days ago had fever which lasted for 12 days during which time he attended the Sooramballa dispensary as an out patient — For the last 8 days his voice has been hoarse. and his respiration difficult. — He has had Syphilitic disease he says. Does not know whether his parents had Syphilitic Disease — Says that he suffered from ulceration of the interior part of the nose. upper lower lips & Skin. about 3 or 4 years ago and the prescribed Medicines. remaining for a hundred and thirty days especially of Sustenance. — He has had ulceration of the fauces — The patient is of a weak ~~and~~ constitution & feable muscular development. — Has some cough"	
		Tracheotomy performed at 2½ P.M. on the 8th by the 2nd Physician into whose wards he had been admitted. and when performed the breathing was great. Dyspnoea & intense pain of sternum. increased on any attempt at inspiration. He had two or three paroxysms of great severity.	

Month	Date	Cases — Tracheotomy, Decanulation, Laryngeal Oedema, Hotchkiss	~~Pages~~

May 8th and O'Connor was ready, female had been delayed. Whilst he was being placed in position for operation another paroxysm came on & he was all but suffocated. I was obliged to perform the operation hurriedly & having divided the integument & drapped the tube forward with a Denonvilliers I saw the scalpel quickly through 2 or 3 rings of the trachea and introduced a full sized double tube. He was rapidly relieved. Expectorated a quantity of mucus tinged with blood which had flowed into the bronchi from the wound. There was a good deal of venous hæmorrhage but it ceased as soon as the respiration was re-established. Covered the tube with piece of Muslin.

" 9 Dry well. breathing easily. ordered Potass. Iodid 5iij to the. Sup. Milk & wine. The tube is frequently cleaned by taking out the inner tube. Bowels have acted.

" 10 Dry well. parts a little inflamed round the lips of the tube. Apply Argent. Nit. Solution. He is the carefully watched

" 11 Breathing easy. Pulse quiet. but he looks so wretchedly cachectic & anæmic that I

Month	Date	Cases: Tracheotomy, ulceration of larynx & cancer of throat	Pages
May	11	Lamb's the result - Examined the throat & fauces well - superficial ulceration & former cicatrices - The back of the throat has notwithstanding a blanched loop. Sprayed it with Argent Nit gr ii ℥ i - added Cod Liver Oil in addition to the other Drs & diet - also soup & pudding	
"	15	He is better: seems better strength. Takes his food well - He cannot hear the least obstruction in the tube. and there is still a purpose muco-purulent discharge from the tube. Continue Medicine - have stopped as usual.	
"	17	Sprayed his throat again with the Argent Nit gr ½ to ℥ i - He is in bed smoke & drank but well - but he breathes easily through the tube - the larynx is apparently returning to the normal state but he can breathe for a time when the tube is closed - Cont Drs & Diet Wine & Food as usual	
"	20	He is better getting stronger. breathes easily. not able to dispense with the tube.	
"	22	Generally improving. He takes Fl. Fluid Muriatic gtt x Tinctur - Cont Drs & Diet	

Month	Date	Tracheotomy - Cases	Pages
May	25	Took out the tube he breathes pretty well without it, when the aperture is closed by the finger. but it is hardly safe to withdraw it altogether yet - Continue the Iron & food diet with wine	
"	29	He is doing well - but still wears his tube	
"	31	He is slowly but steadily improving Taken Cod liver oil & Iron.	
June	4	He is going on well. but breathing without the tube again on the 2d. but the breathing became embarrassed & tube reintroduced -	
"	10	Tried to go on without the tube again to day but he couldn't bear it without it again - Cont. Food:	
"	13	He is getting stronger & stronger. but still compelled to wear his tube	
"	16	Much the same.	
"	20	Comfortable. Coughing more. Sent Pedi.	
"	23	Much better again. less cough. He is getting fatter but still requires the tube	
"	28	Continuing better	
July	9	He is better has less cough. but he cannot do without his tube. We have tried him again a day or two ago, but the usual wheezing followed (very painfully)	
August		breathing	
"	14	In fair health. but cannot do without the tube	

No 2

INDEX.

Month	Date	Cases	Pages
		Tracheotomy.	
July	19th	I took out the tube to try if he could breathe through the natural channel but in a short time his breathing became much embarrassed - and the tube was reintroduced. A fit had fallen over him insensible (asphyxiated) the attendant watching him not giving timely notice. Dr Chenn reintroduced it - and received him by Gaslacher's method. It is evident he cannot dispense with his tube.	
"	25	He has been very well since. Very anxious to get out by Hospital Day. He managed to make his escape & went away with the tube in his throat.	

Month	Date	Cases	Pages
		Epithelioma Penis Amputation.	

May	13th	Lucknum Shaker a Male Hindoo aged 45 years Nature of Calcutta. admitted on the 10th May with an Epithel: growth of the Glans Penis which was almost destroyed & with considerable hardness extending along partly the urethra - The glands in the groin had slightly enlarged. The disease has been there 7 years, and seems to have come on after an attack of Gonorrhoea - He is a healthy looking man not in the least cachectic, but he looks more than 45 - 60 at least - Removed the affected part with an inch of healthy tissue & a simple transverse incision with an amputating knife - Bled to left than 5 vessels dressed with cold water
"	17	He is doing well. wound healing no difficulty with the urine. Has had slight haemorrhage occasionally
"	20	He is doing well. but it bleeds occasionally
"	25	Granulating healthily. He is improved in all respects.
"	29	Nearly well. and in good health.
	31	Doing very well.
June	4	Discharged. Cured. in appearance of return of the disease

Admitted May 10
Operated " 13
Discharged June 4 = 26 Days

INDEX.

Month	Date	Cases	Pages

Month	Date	Particulars of Case
		Malignant growth of foot - removed.
May	13th	Ronald Dogs aged 50. a Bengalee Hindoo beggar. of unhealthy looking appearance with a loose shrunken looking skin and emaciated on the 11th May 1862 with a peculiar growth on the sole of the left foot. It had a fungoid appearance. seemed as tho' it had pushed thro' the skin and was of a dark tint of color in the centre. I imagined it prevented him from walking the days that it commenced as a simple pimple about 4 months ago. had been not painful - It was opened by a barber and about an ounce of blood let out. After this it ulcerated & increased rapidly attended with some pain - He applied various remedies to check its progress but without success. The growth is just in the centre of the sole of the foot. His rest by had no very painful. Removed it by a deep incision and it - a fund that on dissecting it away I had removed all the disease the muscular surface leaving perfectly healthy as well as the bone of the part removed -
On making a section it presented a beautiful specimen of Melanosis

No 4

CASE BOOK.

Month	Date	Particulars of Case
		Melanosis from the foot removed
May	18	The base healthy. cured a base of deep black corresponding to the skin: the sketch gives a more clear the [redacted] section fat & fascia healthy. and size of the part removed. Did use a two vessels and dressed with cold water. I should have noticed that the injury flannel was removed and allowed a good diet & a little wine. His appearance is unhealthy & weak but not cachectic.
"	17	The wound looking healthy. Dress with cold water — good diet
"	20	Healthy granulations
"	22	Continues to improve
"	25	Wound looks well. but he has diarrhoea. and some cachexia or cachectic.
"	29	He is intolerably fair health & appetite. the wound looks healthy but not very active
"	31	Doing well. wound healing but slowly
June	6	His foot is healing. but slowly. He is not in very robust health — He takes some good diet

No 4

CASE BOOK.

Month	Date	Particulars of Case
		Melanosis Fourth of Foot
June	10	He is doing very well. wound in cicatrizing
"	14	wound looks healthy and is rapidly closing by granulations.
"	16	wound reduced to size of a four anna bit —
"	23	wound contracted to a point — He is in much better health —
"	28	There is a mere point unhealed He is in perfectly improved health.
July	1	Discharged Cured.
		Admitted May 11
		Treated " 13
		Discharged July 1.

Month	Date	Particulars of Case
May	13th	An elderly thin but otherwise healthy looking woman named Kristo Mondy aged 50 years. Married but has had no children. Nationality Bengal. Residing in Jorah Bazar of the Lucknow Caste. Admitted on the 8th May 1883 with an ulcerous growth from the posterior part of the labia of one side (right). The history of 2 years growth. Denies that she has had syphilis. "The ulcerated principle on the inner aspect of the labium extends of the right side about 2 inches, which suppurated and discharged its contents in a fortnight or shortly after the patient observed a fleshy growth of the size of a pea which has gradually gone on enlarging until it attained its present shape. It is now about 2½ inches in length, 1½ from side to side. Its pedunculated. The lesser labium and other adjacent tissue is also involved in the disease. There is constant discharge of much purulent matter from its surface and the sulci between the convolutions. It causes her great inconvenience and much pain in and about the affected parts. She has occasional fever. The urine has been tested. It contains no sugar or albumen. Sp. G. 1010. Acid reaction.

No 5 — CASE BOOK. 15

Month	Date	Particulars of Case
		Epithelial Growth of Cornea -
May	13	It will be noticed that she has a well formed Cataract in the right eye, an incipient one in the left - The growth was removed by free incision the vitreous was not escaping. Several vessels required ligature —
"	17	She is delighted by the immediate result and she is in good health, the wound is healing —
"	20	Doing well. Surface healthy.
"	25	Healing rapidly.
"	29	Healing.
June	4	She is very nearly well. It may be noted that she was made over to Dr Archer & I have a hard Cataract removed from the right eye. The operation was performed this morning. Transferred to Dr Archer's care —
"	13	Dr Archer informs me that she is well and is attending as an out Patient —

Discharged Cured
Admitted May 8th
Operated " 13
Discharged June 4
In hospital - 29 Days

CASE BOOK.

Month	Date	Particulars of Case

Month	Date	Particulars of Case
		Left ear cut off by wheel of a carriage
May	15	Sheikh Barroo. Bugdhee Mahomedan aged 30. residing Shoom Bazar. Cooliee admitted at Noon with his ear cut off
Sepoy Ujmal	"	at 10 A.M. he was carrying a heavy load of potatoes on his head and passing along a crowded street, he came in contact with a carriage going at full speed. by the violent blow he fell down insensible with the load. When brought to the hospital it was found that almost the whole of the left pinna was separated - another right ear & left shoulder bruised.
		When I saw the patient in the morning after retiring the wound had been trimmed. the edges of the integument turned were stitched. The ear was entire space. He is a stout healthy looking young man.
"	20	Doing well, cicatrizing.
"	25	Surface healthy. Pattern inclined to enlarge
"	29.	Doing well. Pattern sponge lint with cerat sulph.
June	4	The wound has almost cicatrized.
	5	Left Hospital by request well
		Admitted May 15
		Discharged June 5
		In Hospital 22 days

CASE BOOK.

Month	Date	Particulars of Case

Month	Date	Particulars of Case
		Removal of Foreign body from Nose.
May	25	Mrs Little from Cawnpore brought her little boy, aged 4, saying he had something the matter with the left nostril. There was a swelling, and a foetid fetid discharge. It had been there for more than a year. The boy looks well and strong. She says he has been examined by several surgeons, who told her it was polypus, and recommended that his nose should be slit up. She refused operations & then tried to take it out: a dark looking substance in the upper part of the left nostril — boy very restless and frightened. I raised up a pair of simple grasping forceps and with them a small bottle of plated metal scissors with blade fetid matter — the mother said that a year ago she mixed such a bottle of Iodine that I thought he had swallowed it or put it in his nostril — There was slight haemorrhage after the operation. I syringed the nostril with cold water & found here a solution of fuscous fetid appearance & Dr. Mayne to look at the nostril. The mother was much pleased, and said she should return to Cawnpore immediately

Month	Date	Particulars of Case
		Imperforate Anus.
May	27th	A female native child, one year old, brought, suffering from this malformation. Just posterior to the vulva was a very small aperture, through which the child passed at times fluid faecalent matter. When it had taken castor oil. It was well formed, well nourished, looked in capital health. Had several teeth. – Introduced a director & cut down upon it & cut a slit vertically downwards. A quantity of fluid faecal matter immediately escaped. On introducing the forceps into the wound, which was made through a septum about as thick as skin: I felt a hard round mass. This proved to be a consolidated faecal matter. This I seized with a scissors & frequent injections were thrown in large quantity – & the wound being dilated with a piece of lint soaked in oil. The child was taken away by its mother. There was very little bleeding.
May	31	I have not seen the child again



Month	Date	Particulars of Case
		Radical Cure of Hernia.
May	18th	An American Sailor named David Kehen aged about 36 height 6 ft. a healthy but weather beaten looking man admitted on the 18th May with Inguinal Hernia of the left side caused by an accident a fall at Sea 5 or 6 months ago – The ring is a good size admits two fingers & the Intestine protrudes into the Scrotum directly he stands up – He has not worn a truss and it causes him great inconvenience
	After	May after a few days rest in Infirmary I operated in the usual way with a plug & Needle.
	After	May I took out the plug found a small piece of stitch 2 months old, had persisted – free purulent discharge and a good deal of swelling underneath in about the part – the wound healing well secured.
"	25	He is doing very well his bowels are fully relieved by an Enema on 23rd & he sleeps quite well without pain. He is carefully bandaged, and his hernia does not appear to come down at any time. The discharge is less profuse and the swelling has decreased
"	29	He is doing very well. is ordered to remain up

Month	Date	Particulars of Case
		Radical Cure of Hernia
May	29	Discharge from thread wound pretty free. General health good.
"	31	He is doing remarkably well. wound healing. Inoculation remains up.
June	4	He is doing well. wounds not yet healed. but healthy. Inoculation remains up.
"	10	Wounds nearly healed. The case seems to promise well
"	13	Is allowing his truss to stay & looking very well
"	16	Says he is quite well & strong have tried the hernia but it does not descend. Let him wear the truss & not exert himself.
"	19	Put him to some tents, carrying water up & down stairs - & working up on the 2nd & 3rd floor - without truss. He bore it all well.
"	23	He went to his home in Mr P. Inspector General. Discharged Cured

Admitted May 10th
Operated "
Took out stitches "
Applied truss " 13th
Discharged cured June 23rd
In Hospital Days 45

Month	Date	Particulars of Case
		Median Lithotomy
May	28	A little boy, Bengalli named Prionath Mooto aged 9 years admitted this morning. His father has been bringing him to the hospital several times during the past fortnight: with retention of urine and symptoms of stone in the bladder. He was sounded here each time and found the calculus within in the bladder & in the membranous portion of the urethra. The mass would not be induced to leave his child of water to day. He came this morning with the symptoms aggravated. The bladder distended. The penis & scrotum swollen & edematous. Pain & tenesmus very painful. A fend drop of purulent urine passing. The boy in great pain and said he had been in passing urine under chloroform and passing the sound. I found the stone lying in the urethra & on partially pushing it back. The urine escaped acid & purulent. I immediately secured the stone by an incision through the scrotum in median line. Just in front of the membranous portion. There was not much haemorrhage. The stone was an oval shape size of an almond. Mulberry. a rough surface

21 grains

Month	Date	Particulars of Case
		Median lithotomy.
May	28	No tube a catheter introduced. passed a probe into the bladder & search for other calculi. but none were found
	29	Found a large collection of urine in the bladder this morning. The passage seem to have been obstructed. The urine passed with a quantity of thick purulent matter on passing a catheter. The scrotum is still accumulating and fomentations of Liquor Am. acet. ℥ iv Tr. Hyoscyami ℥ss Liquor Potas. min xx Aquae ℥ iv M. Each med to be applied warm — A dose of Castor oil & plenty of albumen. He took slightly delirious during the night
"	31	He is doing very well. Swelling of scrotum abated, he had it painted yesterday with iodine Tinct. pxxx @ ℥i. There is less purulent discharge. no fever. Instrument passes easily. No urine seems to pass by the wound. Which is rapidly closing
June	4	The wound healthy & rapidly closing. All the urine passes by urethra. The boy is in excellent health. Discharged. No. 5 on day
"	6	He is doing very well. He had an

Month	Date	Particulars of Case
		Medical Lithotomy
June	6	Attack of fever yesterday & day before discontinued the Sulph - given Salines Sanitum & quinine & decoction. pounded with Sol: Acetat: Nit:
"	10	Urine a slight one where the tumour was but been quite well otherwise. some fever - cutting by medicine - Parents anxious to move - Discharged.
		Admitted May 28
		Operated " 28.
		Discharged June 10
		In Hospital 14 Days.

Month	Date	Particulars of Case
		Fungus Testis.
May	20th	Doran aged 25. Hindoo. admitted on the 20th May with Fungus Testis. left. He says that ago he had enlargement of the Testis & separated. Pained & that a protrusion resulted. which became as large as an orange This he has much reduced by application of various caustics. until it has come down to the size of a marble. It is evident that the greater part of the true structure of the Testis has been destroyed and that this is merely the stump of the Testicle nevertheless. to reduce it. I performed the usual operation. free incision round it. until it was detached and could be removed by the separated portion. Red ligature & the cutting knife applied. The section was suspended & closed with a wet cloth. ~~was left~~
	25	The cutting ligature came away in a few days. & the process of separation is going on by 2nd intention. The wound gradually closing over the Testicle. He is much improved in health & spirits
"	29	He is doing well wound healing
"	31	It is healing rapidly
June	4	It is very nearly healed. he is

Month	Date	Particulars of Case

Memo

Chotoor Dhoos a Hindu Male about 35 years old inhabitant of Sahanatod Resident at Nimtola Calcutta has been suffering from Inguinal Hernia for nearly 22 years. The Hernia used to descend and then go back all this time till on the 28th Instant when at about 8 am. it descended and could not be pushed back. suffered much from vomiting and uneasiness of his bowels this day and came to the Hospital at about 2 P.M. for relief – with the following Symptoms:–

The Protusion was as big as a small Pumbalow it was not very hard, the abdomen was tympanitic and there was some acid eructation and the patient was very restless. Skin was of natural temperature and the pulse not excited. Ice was applied over the tumour and then Taxis performed but it produced no good effect At about 3½ P.M. the usual Operation for Strangulated Hernia was performed, the Stricture at the internal ring was divided and the Hernia was partly reduced. the lower part of the sac was accidently cut a small quantity of fluid gushed out and during reduction a bit of the omentum protruded through the Opening. one small artery wanted ones

* There was no Obstructions vomiting

Memo

Chotoor Dhoz a Hindu Male about 35 years old inhabitant of Sahanabad Resident at Nimtola Calcutta has been suffering from Inguinal Hernia for nearly 22 years. The Hernia used to descend and then go back all this time till on the 28th Instant when at about 8 am. it descended and could not be pushed back. suffered much from vomiting and uneasiness of his bowels this day and came to the Hospital at about 2 P.M. for relief – with the following Symptoms:–

The Protusion was as big as a small Pumbalum it was not very hard, the abdomen was tympanitic and there was some acid eructation and the patient was very restly.* Skin was of natural temperature and the pulse not excited. Ice was applied over the tumour and then Taxis performed but it produced no good effect At about 3½ P.m. the usual Operation for Strangulated Hernia was performed, the Stricture at the internal ring was divided and the Hernia was partly reduced. the lower part of the sac was accidently cut a small quantity of fluid gushed out and during reduction a bit of the omentum protruded through the aperture. one small artery was tied ones

* There was no discoloration vomiting

Suture applied and a suspensory bandage for the scrotum. and a lump of Ice was placed on the part.

On the 29th August. at about 8 a.m. the rest of the Protrusion was pushed back. with hand and Spica Bandage put on; the patient now feels much easier.

Memo
Case
of
Doctor Bhoos

Strangulated
Inguinal Hernia

30th August.
1873.

Bama Charan
Chatterje
Dresser

Bonomally. Age. 28. Residence Sonikur addha
Pundit. admitted 24 Oct.

Had gonorrhoea first. used to pass urine freely
before until about 4 days ago, he
had difficulty in passing urine.

Perineum laid open in the centre & stone
extracted this morning.

25 Oct 93.

Month	Date	Particulars of Case
		Funnus Testis.
A		Suture applied and a supendury bandage for the Scrotum. and a lump of Ice was placed on the part.
		On the 29th August. at about 8 a.m. the rest of the Protrusion was pushed back. with hand and Spica Bandage put on; the patient now feels much
		Rama Chunn Chatterjee Dresser
"	31	He is hear
June 4		He is very nearly healed. he is

No 11

CASE BOOK.

Month	Date	Particulars of Case
		Fungus testis.
June	4	much better in all respects — appetite good. sputum better. sleeps well
"	10	very weak, quite bedridden.
"	12	He left the Hospital yesterday quite cured

Admitted May 20th
Operated May — 22?
Discharged June 12th
In Hospital 24 days.

Month	Date	Particulars of Case
		Amputation of foot.
May	29	A wretched emaciated creature of about 40 to 45 years of age. Name Patrick Sing admitted this morning with his left foot in a frightful state of disease. The first completely disorganized the ankle joint the tibia & fibula with the astragalus removed. protruding at the dorsum of the foot. The ligaments & soft parts disorganized & the foot swelled & ulcerated. He says that after the result of running a splinter into the foot 3 years ago & that the foot has gradually passed into this condition. He is thin & allow & cachectic looking from exhaustion of pain & discharge. There are enlarged glands in the groins & axillae in the form below scrofulosis. He has no enlargement of spleen or liver. Heart & lungs healthy. Urine healthy.
		We thought it better to relieve him at once of such a nuisance. and accordingly under Chloroform I proceeded to amputate making the anterior incision first to see that the bones were sound. They proved to be so. apparently by my vascular just above the joint

Month	Date	Particulars of Case
		Amputation of foot -
May	29	accordingly I made the heel flap only from outside of the tissues as afterwards found about the heel - and cutting away sloughing portions and sawing off the end of the tibia & fibula. I made sure as nearly as possible one of the Tibial Arteries & veins were ligatured. I observed that not only the tissues of the heel but the arteries themselves were brittle and so from inflammatory degeneration the ligatures when applied, cut right through them - Brought the stumps together with sutures
"	31	He is bad. has diarrhoea. & great part of the heel flap has sloughed. He is taking P. & Opium. & Chalk Mixture with Aromatics. Foot washed with Chloride of Zinc. & dressed with poultice.
June	4	Since last report. the greater part of the heel flap has sloughed. He has constant Diarrhoea & looks wretchedly ill. but his pulse keeps better than his appearance would indicate - Chemical poultice but. acid & Spirit for the Diarrhoea food food. Plums. Brandy & beef tea. Washed of Chloride of Zinc - the treatment

Month	Date	Particulars of Case
		Amputation of Foot
June	6	Pulse 98. He looks wasted & like Diarrhoea & Cholera. Stools in separation the stools in. but looks anæmic & feeble. & the Rectal. Perineal & Scrotum were both and all sloughing up to the abdomen & the testicles. & have come to Chelle Institution again, have food & treatment prescribed
	8	His friends insisted on removing him to day — He looked much reduced. & with constant tendency to Diarrhoea. The only chance he returned was lost sight of by being taken away. —
		Removed by his relatives.

Month	Date	Particulars of Case
		Hydrophobia
May	29	An old duly Brahmin named aged 68. came with two friends then nursing in the Hospital to seek advice. He was much excited and spoke in a quick spasmodic earnest manner. He had, he said, been bitten by a black snake 3 p months ago on the foot and ankle, and he pointed to several dark coloured cicatrices which he said were painful having became so during the last 8 days. He says that he has been ill for 3 or 4 days. that the sun light on the attempt to swallow water brings on great agony - the intellect is clear. skin cool & moist. but he has an excited pride, fearing death & is unable to control himself. his friends are rather inclined to suppose him. I sent for some water. he immediately with trembling & spasmodic jerks of the hand & arm to get it to his mouth. when there he tried and succeeded in swallowing about ½ a pint -. He said he had had none for 3 days. We brought a looking glass. but this excited him and not seem to increase the spasm. Nine was at this time in Surgeon Simms

Month	Date	Particulars of Case
		Hydrophobia.
May	29	I saw no convulsions of any kind. but evidently great constant exhaustion & irritation from the constantly recurring chorea of patient. He was most intelligent & called kindly for relief. Many to inhaled anything. I tried made "believe" that he might take some water Dr Chuen suggested tracheotomy but as there was no dyspnoea at present I could not assent. Ice recommended ice to spine. Injected Morphia. I suggested that he should be kept under Chloroform & plenty of Beef tea ~~[illegible]~~ fine by enema. On coming down stairs afterwards I found much to my disgust that he had fled. His friends having taken him away

Month	Date	Particulars of Case
		Athera'oris
May	29	A Bengalli Girl aged about 18 Entered the Hospital suffering from the results of Salivation – The tongue was partially protruded from the mouth, and was adherent to the lips and cheeks. She said that her husband when a child, that she had gone to live with her married sister whose husband gave her Syphilis. In Pain she took Mercury to produce Salivation during months ago. her mouth & tongue ulcerated and the result was the present adhesion – The lower surface of the tongue was closely adherent to the lower lip. There was just room to pass the finger in at the angles of the mouth, where it was apparent that the edge & under surface of the tongue was adherent to the inner surface of the cheeks – I undertook among & broke down the adhesions & passed the teeth all in. Consulting with Surgeon & Hayward: Stopped the mouth, where the adhesion had been, with oiled lint & ordered her Sublimate – removed the Carbolic lint & lint teeth.
	31	She is doing very well. no trouble

Month	Date	Particulars of Case
		Atresia Oris
June	4	The pulse perfectly well and the can open her mouth sufficiently for the Surgeon. The sores become almost healed, as yet there is no ~~[illegible]~~ contraction. She is to go to the Dentist tomorrow to have the teeth pulled out.
	6	She has had her teeth polished by the Dental Surgeon & seems the uneasy quite well. —
"	12	Went to the Dentist again to day & have her mouth looked at. Seems quite well.
"	13	Discharged Cured Admitted 29 May Operated " Discharged 13 June In Hospital 16 Days.

Month	Date	Particulars of Case
		Ulcer (Cancerous?) of Tongue
June	4	This morning I received the following note from Dr. Clarke of Benares in reference to the case hereinafter recorded.
Benares June	2	"Will you kindly see Mrs C— who accompanies this note. She is suffering from a Cancerous sore on the tongue, being far back extending — She has had Iodine, weak Caustic & astringent applications to the sore. & strong Doses with Potassa Nitrodate & Sarsaparilla. She otherwise no better, nor do I think the sore will be — Your Opinion will be satisfactory to them — ~~She has~~ The sore has lasted for 3 months, & has all the appearance and symptoms of a Cancer" — Sd A H Clarke —
		I saw this patient at 12 1/4 of the 4th June — She was a tall, slight-elderly (aet 58) lady, whose general appearance was healthy, the skin being thin & pallid appearing the effects of climate than disease — She is the Mother of seven (7) children and has ceased to menstruate some years ago. The general health appears to have been good.
		Years ago she had a small Needle broken in a deep tissue of the

Month	Date	Particulars of Case
		Ulcer (Cancerous?) of Tongue
June	4	After Shoulder Cured by tapping and injecting with Iodine. She says that between 3 & 4 months ago she found some swelling on the left side of the tongue corresponding to the posterior molars. It soon had her in pain. This at night made her uneasy. These gradually increased and some weeks ago spread forward the one pain which she now suffers. She says that she has very little pain except when she attempts to eat solid food. Occasional darting pains shooting towards the ear. Does not think her general health is affected except by anxiety & that she cannot take solid food. Her diet consists of soup - milk & Port wine. She is not for an clean tongue, any hereditary tendency to Cancer. On looking into her mouth I found that the tongue is swollen and thickened on the left side corresponding to the molars. There is also an elevation of the mucous membrane extending forward between the tongue & the gum of that side as the tissue was examined. There is a sore chapped and discharging a dark unhealthy

Corresponding to Sub lingual Gland

Month	Date	Particulars of Case
		Ulcer concerning prepuce —
June	4	looking painless, and as the tumefaction [illegible] which has up purely of the superficial one — There is [illegible] the thickening to lead one to [illegible] that it is a cancer. There is [illegible] lication of the neighbouring [illegible] the tissues all round seem [illegible] ted. The one & thickening are [illegible] f and reach backwards [illegible] further than the proper constituent [illegible] of a Median abscess and [illegible] the sharp sinuating edges [illegible] ding to the one. The edges also [illegible] e feel them irritate it — [illegible] a particularly offensive [illegible] n the one. & the edges are [illegible] en annoyed by pain. [illegible] ng the sharp edges of the [illegible] around the one thoroughly [illegible] hugs & found a good deal [illegible] g of the tissue about it — [illegible] the argent: Nitrat: freely — [illegible] d a lotion of Iron Chloride gr xii [illegible] R: Iodoform — gr i [illegible] Cocoa Ins & Aqua ℥ x ii

Memo.
Case of Dwarkanath Chuckerbutty.

Stricture
Perineal Section.

Rama Chum Chuttop.

To work the mouth frequently —
To have fomentations of hot water &
to take his usual walking exercise

Memo.
Case of Dwarka Nath Chuckerbutty.

Stricture
Perineal Section.

Rama Chun Chatterji.

Memo.
Case of Dwarka Nath Chuckerbutty.

A Hindu male about 30 years old inhabitant of Patna was admitted into the Hospital on the 5th August 1863 with Gonnorhoea followed by Stricture of the urethra for the last 2 years. his bowels were costive during admission and his general health seems to be good.

The Patients bowels were kept open by purgatives and attempts were made to pass Catheters No 2 and 3 but with very little effect.

On the 10th Instant the Stricture has been ~~relieved~~ removed by Perineal Section. It was situated in the membranous portion of the urethra & extended forwards as far as the bulb. it was very hard & of long continuance

Month	Date	Particulars of Case
		Ulcer (Concerning) of Tongue
June	4	After Shoulder Cured by tapping and injecting with Iodine. She says that before ago she found some left side of the ton the posterior mol in pain. Has at tim These gradually in some weeks ago some pain which she She says that the exception when she a solid food. occa Jarvis Nothing to Does not thinks her a effects of cancer & that the cancer her diet consists of Potatoes — There is Cancer, any hereditary or looking into the t that the tongue is s on the left side Cancer. There is also an thickening or incrusta membrane between the tongue & the jaw of that side as the tissue was examined. There is a sore chapped and discharging a little unhealthy

Cancer for 2 days to bite tongue and blood —

Month	Date	Particulars of Case
		Ulcer concerning of tongue —
June	4	looking painless, and as the tubercular elevation which has in parts of it, there is also a superficial sore. There is nothing but the thickening to lead me to believe that it is a cancer. There is no complication of the neighbouring glands & the tissues all round seem unaffected. The sore & thickening are elongated and reach backwards but not further than the posterior pillars. I find that a bullet also and lower have sharp irritating edges corresponding to the sore. The dog says that they feel them irritated. There is not a particularly offensive odour from the sore. & the dog says he has not been annoyed by pain. I filed away the sharp edges of the teeth. examined the sore thoroughly with the finger & found a good deal of thickening of the tissue about it. Applied the argent: Nitrat: freely — and ordered a lotion of Iron Chlorid gtt xii R: Infusion — ℥ss Comp Tr Aqua ℥ss gtt xii To wash the mouth frequently — To have fourth diet. Not wine & to take his usual walking exercise

except that instead as connected with tubling of

Month	Date	Particulars of Case
		Ulcer (Cancerous) of the Tongue.
June	5	She was relieved by the Nit. Silver. The tongue looks rather less irritable & some sloughy matter has separated from the deeper ulcer. She was able to eat & swallow the tongue  more freely after the caustic. About midnight she had a good deal of pain about the parts. Dr Cotter suspects there is much the same. Applied the caustic again freely.
"	6	Feels better today, had less pain & feels stronger. The tongue looks less irritable and is less painful. She was able to eat much better. But there is no difference in the hardness. Some a very guarded prognosis. He is to the last degree suspicious but I have not yet made up my mind that it is absolutely cancer.
"	7	Much the same. Not much pain slept tolerably. The caustic has removed a surface of dirty sloughy matter. It looks much as yesterday. Applied it again not so severely.

℞ Pot: Iodid 3ss
℞ : Aquae 3iv ss
Aquae ℥iv ss
M Cab: Mag: ii ter die.

Month	Date	Particulars of Case
		Ulcer (Cancerous) of the Tongue
June	10	The surfaces of the ulcers look healthier and the hardness may be a little diminished but there is not much change. The Argent Nit: has been applied daily and she is taking Pot: Iodid: pr. with the food diet & wine. She has not so much pain. The taste with wine lost & the tongue is more movable
"	11	The swelling is certainly somewhat smaller and the ulcer more healthy. She says she has very little pain in raising the hardness and can move the tongue more freely. Continue the Argent: Nit:
"	12	Much as yesterday. Applied A. Nitrate
"	13	Mr Partridge saw her today with me. We agreed that the present treatment is to be continued for a few days as the ulcers look more healthy & the tendency is diminished. Spoke with the surgeon Mr Clark who thinks the same. Tried it again with Argent: Nit:
"	15	Not any improvement since the bottle was taken out. Cont: Argent Nit: Slight pain in raising. Last night she had a little more pain in it. The swelling of the hardness the sublingual gland is attended by very slight increasing

Month	Date	Particulars of Case
		Miscellaneous of Jaw
June	20	In change of importance has taken place within the last 3 days. The portion of the jaw particular looked a little more prominent than the other. We decided on Thursday 18th that the operation was to be performed to-day. Accordingly at 12 I did it assisted by Dr Parkes. Mr Hunter from Edinburgh. Raised lip as in the sketch. Found it extended to the mucous membrane — as much as possible of the sublingual & Wharton's Duct. Removed the lost little in no blood. Shave the operation well. under chloroform.
"	8 P.M.	Felt much pain. had an opiate — washed the mouth with hot chlorodyne: She has taken fluids.
"	21	Doing well. pain diminished. Tongue blistered. She had a good night — I ordered 20 drops of tinct: Opii — Led at bed time. Stay & turn if necessary. Wash the mouth frequently with the lotion. She is able to swallow & has taken soup & wine. In pain. Pulse rather bounding but feeble.
	8 P.M.	Face more swollen & under the jaw tongue swollen. Pulse 100. feeble. Not much pain. Let her have her draught tonight. & some more soup & wine

Month	Date	Particulars of Case
		Abscess in head of Tibia

A man named Hanoolah Khan aged 25 yr. descent of Cuttack was admitted on 27 March 1863. with the above disease.
He says that he had ~~some~~ swelling and pain in the left knee joint. some time ago. that it suppurated and was opened by a Barber. and got well. After a short time another abscess formed which was opened by the same barber. This occurred again 3rd time.
This did not heal but continued to discharge pus & became a sinus. When he came to the Hospital – He was treated for about a fortnight with rest – injections of Sul: Zinc: bandages – He complained constantly of intense deep seated pain. which was partially relieved by Opium internally externally.
On the 28th April. the pain having steadily increased Leeches were applied but with no benefit
on 29th ~~March~~ April. He was put under Chloroform & the actual Cautery applied once to the inside of head of tibia – I also made a crucial incision. exposed the head of the tibia. taking out a portion of the cuticle of about bone. & pus & spongy carious cancellated bone and pus. This I pressed out with

Month	Date	Particulars of Case
		Abscess head of Fibula
June	10	the head of the bone was almost exposed. The operation was followed by complete relief. He rapidly lost all pain. Healthy granulations sprung up & soon closed in the cavity. A small bit of the diseased piece, which could not separate at the time of operation came away subsequently. He began to regain his health & strength the knee which had become contracted from inflammation began to extend & he
June	11	walked on the 11 June rapidly recovering. It should be borne in mind that in this case there was a sinus leading from the ulcer into the head of the bone in which the diseased surface could be felt.
"	16	Has had some pain & some purulent discharge. Poultice & perfect rest.
"	17	Better, less pain: discharge diminished
"	21	Are a few bits of bone have come away & he is much better.
"	21	Less pain. Discharge less.
"	27	Several small pieces of bone have come away lately. He has less pain & less discharge
July	1	Pain less. Discharge less. Wound closing.

Month	Date	Particulars of Case
		Removal of left Mamma.
June	11	A woman named Jugo-Windos from Ariadale aged about 40. healthy looking. Her father pulled down of the affected breast was admitted June 10th with disease of the left Mamma. It was hard painful and had several fistulous openings with sloughing tissues leading to the centre of the breast. She gives the following account of it. "About "4 years ago she gave birth to a child & nursed "her only child, she had good health after "this until about a year ago. When she per "ceived a small lump above the nipple "this gradually increased with hardness "and 2 months ago she had shooting pain "from it which exacerbated & gradually "assumed its present painful state, then "small tubercles similar pain left than forming" The growth is hard & heavy but does not think it is cancerous. The axillary glands are affected but slightly & not some than irritation might cause. Her general health is good: the functions of the glands are good but habitually constipated. Removal appears the only hope of saving a cure. The nipple & the boundary of the integument is not affected. I removed the growth under chloroform

Month	Date	Particulars of Case
		Removal of left Mamma
June	11	I left the nipple & lower half of the integument: the tumour was hard and heavy & at the base of left axilla had glands looking tense. I dissected away as much as I could. We became cold & lost considerably in quantity of blood from arterial branches which were numerous. Brought the edges together with wires & placed a pad and bandage round the chest. Dr Chenery & Surgeon Major Menzies H.E.I.C.S. were present and assisted me in the operation. Mr Hayes the Hindoo surgeon being absent from sickness.
"	12	Slightly feverish. No bleeding. Sutures. Milk diet.
"	13	Doing well. Edges of wound rather red. Apply Sol: argent: nit: gr xxx ad ℥i. Slight discharge from between the ~~lips~~ sutures. No fever. Continue all as yesterday
"	14	Ligatures came away. Slight discharge. Much of the wound has united
"	16	Doing very well in all respects.
"	17	Doing remarkably well. Took out the last ~~bunch~~ suture today. Wound has nearly healed
"	20	She is nearly well.

On making a section of the tumour it was found to consist of fibrous tissue & glands enclosing broken down tissue mixed with pus & sanies.

Month	Date	Particulars of Case
		Removal of Left Mammary. Tube Capter Dram
June	21	The wound has very nearly healed. She is in capital health.
"	22	Wound has healed. Very little distortion of breast.
"	24	She is quite well but for one small sinus.
"	27	Injected the sinus with zinc sulph.
July	9.	She is quite well. but ends any thing. She will remain in hospital a few days
July	15	Discharged Cured
		Admitted June 10th Operated on " 11th Discharged end July 15th

Med Opinion case

The patient returned to hospital on 10 August 1883. with a sinus found in the line of cicatrix with an unhealthy ichor. The breast hard & heavy. The glands near the axilla enlarged & hard. It looks very much like the last disease of being malignant. She seems to have a good deal of pain and is anemic. She is admitted & her case will be detailed.

She left the hospital Nov 20th Cancer evidently increasing. Opinion adverse

Nov 8 Her disease rapidly increasing. Medullary cancer. Partly ulcerated. steady. but rapidly spreading with heat. debility & much suffering. Morphia. soothing applications

Month	Date	Particulars of Case
		Fractured Thigh
June	7	Mr Scott - a stout healthy Jersey man about 30 years of age - fell with his horse in the house cleared and fell on him - fracturing transversely the lower third of the left thigh. I said he must to Dr Macrae a few hours after the accident. The limb was shortening & the foot was twisted. Placed the limb between two wood pillows for support & found him an opiate for the night.
"	8	Put him up with Gunn Shee bandage and fastened a catheter as he had retention
"	14	He is doing well. No pain. No starting. Limb in good position. No shortening. Bandage rather loose - Readjusted splints & stretch. He had retention for 3 days. but has none now.
"	18	I learn from Dr Macrae that the union is firm. but he is still in the splints.
July Wednesday	27th	Saw him today with Dr Macrae. Joint & splints. The leg had been removed on the 19th for 8 days after the accident. The limb is perfectly united. Strengths are equal in length to the other.
Aug	23	I learn from Dr Macrae that he walks about on his crutches

Month	Date	Particulars of Case
		Perineal Section for Stricture
June	13	A French Sailor named Lomingue Aimé. aged 34 admitted on the 8th June with the stricture He has had it for 8 years has been in several Hospitals. in Cherbourg France. in Buenos Ayres. ~~Suffered~~. Many attempts to pass an Sound have been made but they caused bleeding and fever. and were not successful. He says no Catheter has been passed into bladder – He is short & strong apparently in good health. but suffers much pain the stricture and is quite unable to perform his duty as a Sailor – The stricture is in the usual place just in front of the bulb. Membranous & very irritable. bleeds on the slightest touch – On the first day I passed No 2. & subsequently passed up to 4. but it caused much haemorrhage & fever. Great prostration muscular pain & debility. Still the urine appears to be gradually healing down. By which a young man appears aged & decrepit Sailor. & feeble. I feared lest consents to have performed a suprapubic operation After 3 or 4 attempts & finding

He had gonorrhoea & syphilis during last 8 years always worse after these attacks –

Month	Date	Particulars of Case
		Perineal Section for Stricture
June	13	each time that the contraction would subsequently increased I determined to divide the stricture and this morning, being 3 days since he had fever. I performed the operation in the usual manner cutting right through the centre of the bulb. There was some haemorrhage, oozing, but it was controlled by pressure & ice. I should say that he had opiate & fomentations. He was very sick after the operation, but this was due to the Morphia given just probably. Which he took in & retained a large quantity. – The usual tube was placed in the perineal wound, & he had a dose of Opium given to him. –
"	14	No fever, no pain, no haemorrhage. Did not sleep. But is doing well. Urine flowing freely through the tube. –
"	15	Had sharp fever to day, tube also got obstructed – Took it out. –
"	16	Less fever. Doing well. Urine flows freely through the wound. Looks sallow. Pulse under 100.

Month	Date	Particulars of Case
		Perineal Section for Stricture
		this morning. Countenance
		anxiety = Pulse 84.
		urine flows freely
		wound - Passed No. 7-8-9
		washed the wound and
		with cold water.
		well. The wound is
		which is excellent & will
		well - passes no 9 very
		is running - wound very
		healthy. Contracting urine
		by the urethra. So is
		with - sore & sleeps well
		is quite a different
		much urine comes by
		passes.
		Closing. Passed No. 10 -
		with ease & without pain
"	24	Going well - Passed No. 9.
"	25	Going well - Perineal wound closing No. 9
"	27	All the urine passes by urethra No. 10.
July	1	Making rapid progress wound nearly
"	6	wound rapidly closing. All the urine passes
		by the urethra. He is in all respects doing
		well
"	25	A very small fistulous hand not entirely
		healed in excellent health. No bougie passed for
		some days. He is to leave hospital shortly

Discharge

August 1st

Kanu Affa Gorder aged 18.
Mahomedan. Residence
Mirzapore. admitted 27 Nov.
Operated on the 27. Nov. for
Congenital Hare-lip.
Horsehair sutures applied.

Month	Date	Particulars of Case
		Perineal Section for Stricture
June	13	each time that the contraction which had since increased. I determined to divide the stricture and the morning, here I d[illegible] he had fea[illegible] Dilatation [illegible] Cutting [illegible] After bula[illegible] Recumbent [illegible] Controlled [illegible] I should [illegible] after such [illegible] Dial: he [illegible] He was very [illegible] but this w[illegible] most probab[illegible] a large [illegible] The usual [illegible] Not permit[illegible] dose of Pu[illegible]
"	14	No fever. [illegible] Did not de[illegible] urine flowing freely through the tube.
"	15	Had sharp fever to day; tube also got obstructed - Took it out.
"	16	Sep fever. Very well. urine flows freely through the wound. Looks well. Pulse under 100.

Month	Date	Particulars of Case
		Perineal Section for Stricture
June	17	Much better this morning. Countenance placid & free from anxiety = pulse 84. wound clean = urine flows freely through the wound - Passed No. 7-8-9 with ease. washed the wound and the urethra with cold water.
"	20	He is doing very well. The wound is clean. His health is excellent & in all respects he is doing well. passes urine every morning —
"	21	Is very well this morning. wound very clean and healthy. Contracting urine begins to flow by the urethra. Is in excellent health. Sets asleep well. looks quite & feels quite a different person.
"	22	He says that much urine came by the natural passage.
"	23	wound gradually closing. Passed No. 10 - with ease & without pain
"	24	Doing well - Passed No. 9.
"	25	Doing well. Perineal wound closing. No. 9.
"	27	All the urine passes by urethra. No. 10.
July	1	Making rapid progress towards recovery
"	6	wound rapidly closing. all the urine passes by the urethra. He is in all respects doing well
"	25	A very small fistulous wound only remains. He is in excellent health. No. 8 passed for some days. He is to leave hospital tomorrow

Acquired 1st Instructed Quick. & attend to leave hospital

Month	Date	Particulars of Case
		Scirrhus of right breast
June	13	A woman named Noor Jehan said the about 40 was admitted yesterday with a tumour of the right mamma – the breast itself had shrunk & the nipple was retracted. The skin over part of it was movable. & the glands of the axilla were very slightly enlarged but not painful – No alcoholism. & no digestive or other interference by any of the native practitioners – She is thin but not unhealthy looking woman. She says she has had the disease for two years. In regards to the last clause – that it is painful & that she is anxious to be rid of it –

Mother of 4 children

The cancer seems to have been preceded by two or three attacks of inflammation of breast

The breast is about the size of a small orange flattened. but very heavy & stony hard except. the finite movable & has no attachment except to the skin and the nipple

Resumed at ten morning by the excision, & by dissection as much sound skin as possible leaving apparent healthy muscle behind. Usual ligatures

Month	Date	Particulars of Case
		Scirrhus of Left Mamma.

were applied — the edge of the tumor were brought into apposition with pins. Dr. Pattison & Mungie assisted me in the operation. — Patient not lose much blood — The tumor was flattened & round — no projection. It was peculiarly dense, cutting almost like cartilage.

The microscopical appearances were these. Dr. Smith's Mamma

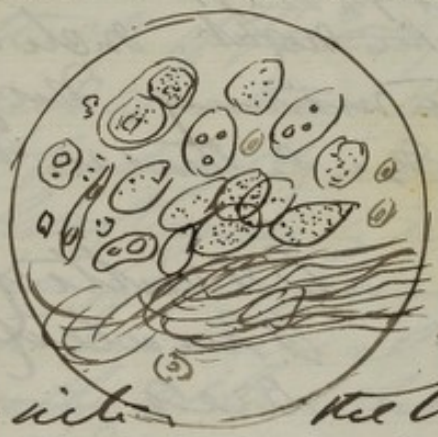

Cells and the No 2 object No 1 eye

Stroma of cancer flap in juice

On cutting into the tumor it presented the usual appearance dense fibrous white bands of fibrous tissue much condensed. and here & there patches of softened, which when squeezed exuded a yellow caseous looking matter

" 14 Had fever & pain last night. no bleeding. Dressed with cold water and fine lotions.

" 15 Dress well. slight oozing of blood

Month	Date	Particulars of Case
		Scirrhous right breast.
June	16	Feverish at times – prepare wound & tablets
"	17	Still feverish. Took out some of the sutures. slight pus. slight purulent discharge. Continue all as before.
"	20	She has been in a feverish condition yesterday but the wound looking. the sluggish. not unhealthy. She was doing well yesterday morning. Had no pain. no Diarrhœa. no hæmorrhage. but towards evening became very bad and died from exhaustion at 7 h am in ~~the night~~. such is the account became the morning. Her friends took away the body. so that no P.M. could be held.

Admitted 12th June
Operated 13th June
Died — 20 June.

Month	Date	Particulars of Case
		Fibro Cystic Tumour of Arm
June	13	A Hindoo woman named Surrosotty, from 25 to 30 years of age. from Bundee Allah, married one was admitted on the 29th May with a tumour about the size of an orange. in the Course of the Brachial artery of the right arm. It was hard and fluctuating. discharging pus and when compressed discharging clear watery fluid in a jet. She says that she noticed its first appearance about a year ago. it came after an attack of fever of 20 days duration. and was then the size of a marble. It gradually increased in size, and lately began to ulcerate It caused her great pain. numbness of the arm. her general health suffering greatly. at last she became unable to work. I dissected the tumour away leaving as much sound integument as possible. It was closely connected with the Brachial artery & median nerve which were contained in its pedicle. I dissected it away as close to the artery as possible & then tied two small arteries. about a quarter of an inch below the bifurcation of the brachial artery. Healed well. Recovered

The tumour consisted of dense fibrous tissue with cysts in it. There had been hæmorrhage & pus formed.

It was remarkable for its attachment to the brachial artery & the median nerve

Month	Date	Particulars of Case
		Fibro Cystic Tumour of Arm
June	13	Wire ligature of. the lips of the wound brought together with wires. She did not do well for some days after the operation. The wound assumed an unhealthy aspect and she had pain during both the tow yielded to simple treatment. Salicin & Tincture with Opium. When the pain was worse very irritable. Keeping the bowels regular. The wound rapidly healing the surface is healthy. The pain subsides. Stimd & Opium
"	16	The wound looks well. Suffer dyspepsia. While the tumour was separated from the sheath of the artery. Aqua 1 Oz
"	20	Wound healing.
"	23	Wound rapidly healing.
"	27	Nearly closed.
July	1	A small fistulous state. unhealed.
"	9	It has cicatrized.
"	15	She is discharged quite cured

Admitted ~~May 29~~
Operated on June 13
Discharged - July 15th

Month	Date	Particulars of Case
		Painted Tumour
June	19	Assisted Dr Partridge to remove a large tumour from right parietal region of a Native Lady aged about 40, married & has had Children. (in mourning the lady) It had ulcerated & had a pungent & semi cicatrized appearance. Dry hard. It was dissected away from the Pericranium & Dura mater the Skull & bone underlying the Cranial bone but the 7th pair Nerve seemed to have been pinched during its prior paralysis resulted. It was brittle dense & of a semi cartilaginous character. It was indeed a specimen of fibro-tumour. Its by large respect. bled. Dammar facies & some tendency mania in spite some hot mf. we by alone was really needed. The bleeding in the dense tissue was difficult to arrest as a ligature would not hold.
	25th	Drain: of the Jaw. In Cachectic good health.
		It appears like fibro-tumour. Patient has a Nerve in It seems remarkable that notwithstanding this dense tumour there was no paralysis of the 7th Nerve.
	26	Shem the is doing well. No pain. No bleeding

Month	Date	Particulars of Case
		Parotid Tumour.
June	21	I hear from Dr P. that she is doing well. no bleeding, no swelling of face, no paralysis of 7th pair – no fever –
"	23	I hear that she is doing well. but pulse keeps at 100.
July	1	I hear she is doing well and the wound is contracting.
"	24	Baboo Ram Narain tells me that she is nearly well.
Aug	25	Baboo R. N. tells me the wound is almost healed. there is slight puffiness of face. and she suffers often in feeling a burning heat.
Dec	24	Dr Partridge writes that she has quite recovered.

Month	Date	Particulars of Case
		Strangulated Hernia. Operation
June	18	I was asked to see Babu Issur Chunder Banerjea at Bhowanipore a man aged about 50 suffering from symptoms of strangulated inguinal Hernia. I found him with a hard-hate right Hernia in left side of scrotum; he has had it for years, but never before strangulated. It came down, began to give him pain about 4 p.m. today. He was vomiting, bowels constipated. Intense pain in umbilicus & seat of structure. The neck of the hernia very painful and rigid. He has had Sneeds Tablets tried by the Native Assistant Surgeon Behary Lal Shaw, under Chloroform but without success. I repeated these with better success. The symptoms increasing. I recommended operation, and it was done immediately. I found a tight structure at the external ring which I divided, without dividing the sac. I thought it probable, that I could not return the hernia, after dividing the structure, that the symptoms of strangulation would cease, for the neck of the peritoneum felt very

Month	Date	Particulars of Case
		Strangulated Hernia. Operation
June	18	my house and hard. It did not seem as tho' the strangulation were also. I determined to wait. Hoping that the hernia might have been incarcerated strangulation time and strangulated neck of sac bowel dilated and constricted at neck of sac but not perforated. Gangrene had not yet set in. for some time whilst hernia incision possible.
		I determined therefore to leave him for the present & call again in — The operation was postponed at 4 P.M. I saw him again before 9 — the strangulation had abated somewhat but still was there. I determined to open the sac with Dr. Parker's aid. I did so and found a knuckle of intestine & some omentum tightly compressed by the dangerous little neck shaped neck of the sac. Nor I slip off. it was black & purple. The intestine was of a deep purple color. I almost feared to cut for fear. however it seemed not to have perished altogether. So I returned it. — A quantity of dark bloody serum came out of the empty sac.

Month	Date	Particulars of Case
		[illegible] ...ia. Ulceration
		...formulation
		...spleen & tongue
		...dry. pulse
		...— Cont Opium
		...Last night —
		...nt time in more
		...cont: Opium &
		...let him have a
		...
		...further eight
		...ch & Meat.
		...Opium has made
		...day slight pain
		...which has always
		...slight pain on
		...for food. says he
		...t his friends see
		...a stand more
		...
		...times. no abdominal
		...the wound. and
		it is slight. wound appears to have almost
		healed. the Baboo has been giving him
		Dimethylarsinic acid ac. fr. Recommend him to use Plumbi Acet: as the
		bowels do not cease.
23		Pulse 2 Motions. Pulse 100. No pain. wound
		healed. Had slight pain last night. Let
		him have Opium

Memo

Shaikh Mahor, a cart-driver, aged about 60 years, has been admitted into the Hospital on the 30th Oct 1880 with a sloughing ulcer in the right leg. The disease is said to have begun in the following way. —

About 8 years ago, he had fever, which was followed by swelling of the right leg. Since that time he gets fever at every lunar change, & during that time the swelling

Memo

Shaikh Fakir, a cart-driver, aged about 60 years, has been admitted into the Hospital on the 30th Oct 1863, with a sloughing ulcer in the right leg. The disease is said to have begun in the following way. —

About 8 years ago, he had fever, which was followed by swelling of the right leg. Since that time he gets fever at every lunar change, & during that time the swelling

Memo

Case of Fever
— sloughing
ulcer

Shaikh Fakir
Bombay

of her leg (elephantiasis) coexistence, & it partially subsides at the mitigations of the fever, which generally lasts for about 3 or 4 days. About a week ago, her had the fever in a more severe character, & her leg swelled in such a manner that the skin became ruptured in several places, & the sores have assumed the sloughing character for the last 4 days.

3rd Oct 163.

Judith Buchanan
Nurse

Month	Date	Particulars of Case
June	18	Strang[illegible]
		any tissue [illegible]
		seem as [illegible]
		also. – [illegible]
		that the [illegible]
		been inc[illegible]
		strangul[illegible]
		time, an[illegible]
		strangula[illegible]
		nearly m[illegible]
		I determ[illegible]
		for the pu[illegible]
		The Rema[illegible]
		I said h[illegible]
		Separatin[illegible]
		but ehle[illegible]
		then the [illegible]
		and. I [illegible]
		Bundel[illegible]
		turn tu[illegible]
		bottle a[illegible]
		sac. N[illegible]

Memo
Case of [illegible]
Surgeon [illegible]
Dr. [illegible]
[illegible]

[illegible] shrivel. The intestine was of a deep purple color. I almost feared to tear it. however it seemed not to have ruptured altogether. So I returned it. – A quantity of dark bloody serum came out of the ruptured sac.

Month	Date	Particulars of Case
		Strangulated Hernia. Operation
June	19	He had Opium & fomentation last night — all symptoms of strangulation gone — Bowels rather dry. pulse under 100 — no pain — cont Opium
"	20	Slept at intervals last night — not much pain. but there is some about the wound. cont: Opium & fomentation — Set him down a Suppository Enema.
"	21	Bowels acted per rectum eight times during the night. Behaving well. has been bathing & electrical — very slight pain around the wound, which has always rested of alternately. Slept pretty well the night — He asks for food. says he is very hungry & that his friends have been starving him. & demand some Put him on a food —
"	22	Weak. diarrhoea continues. no abdominal pain except just about the wound. which is slight. wound appears to have almost healed. He Baby has been giving him Dimsponder Sulphic acid ac fix. recommend him to use Plumbi Acet: as the bowels do not cease.
"	23	Orig 2 motions. Pulse 100. no pain. wound healed. had slight pain last night. Set him have Quinine

Month	Date	Particulars of Case
		Abscess head & thigh
July	1	He is improving.
"	4	He is much better and the wound is rapidly closing in
"	9	He has no pain. Wound closing in rapidly
"	14	Doing very well
"	18	It has nearly closed.
"	21	Has very small suppurating line come away. Wound healing —
"	23	It is gradually closing
Aug	1	It has nearly closed. Small piece of bone as big as a pin head come out from time to time.
"	4	Still a good deal of purulent discharge
"	8	Still some discharge but the wound has nearly healed
"	18	A very small spot still unhealed
"	20	Leave off all dressings.
"	23	None pain. None swelling or serious discharge from the sinus, so far that he had been walking about. Poultice & perfect rest
"	25	Better again. but it is discharging freely.
"	30	Wound nearly closed again
Sept	3	A small sinus still remains
"	10	Still a sinus. but no pain. He is in good health. Fat from the Cod liver oil
"	13	Much same. Sinus still open

Month	Date	Particulars of Case
		Cancer of Tongue -
June	22	Doing well. Rather weak. Pulse at times above 100 - Ligatures & pedicle beginning to separate -
"	23	The part is separating, but a portion is still vascular. She is stronger this morning. Continue all as used.
"	24	Two ligatures came away. 2 pieces. She is weak & fainted during examination of mouth this morning. The part is nearly separated.
"	25	The remaining ligatures and piece of tongue came away this morning - by giving a twist which I threw. but I cannot ch satisfactorily myself as to the state of what remains. Syringed well -
"	27	Part is healing. a portion of the tongue looks suspicious. Improved generally. She is better. Stronger in all other respects. Is unable to take food since since may. Had a better night.
"	28	Better. Stronger. able to take more food. Wound contracting. but the cancer is increasing. It surrounded a blood vessel. Incision -  The appearances are far not satisfactory but it certainly is terrible after mastication, she complains pain. sensitiveness of wound surface

Month	Date	Particulars of Case
		Cancer of Tongue
June	29.	She feels better and the wound is contracting but the suspicion of cancer still remains. Partridge saw it again, we decided not to interfere any further yet.
July	1	Her health is improving and the wound is healing except in the suspicious part in the centre. There is a small hardness and contracting the tongue, none of pain, than can be accounted for by the cicatrization.
"	3	Had slight diarrhoea yesterday but is better to day. Her head troubled. wound is contracting. but still there is a hardness & irregularity about the granulations that is suspicious
"	4	She is better. and the wound, seems to be contracting.
"	6	She is much the same. wound healing in part but some of it suspicious. A gland at the angle of the jaw also is inflamed & painful.
"	7.	Tongue looks much the same. The gland in the neck is ~~apparently~~ still swollen but less tender. Wound contracting. Diminution in the appetite is noticed
"	8	She has been to day with Dr. Goodale he thinks as we do.
"	9	She seems smaller. Gland still inflamed

No 28 Continued CASE BOOK.
from page 58.

Month	Date	Particulars of Case
		Strangulated Hernia Continued.
June	24	It is reported this morning that he has no pain. no Diarrhoea, would they call but he has had sharp pain during the night he is taking fairly nourishment & Disappears when he is free from pain.
"	25	He had Diarrhoea again yesterday from last night: There is slight oozing of pus from the abdominal intervals behind the scrotum, also a patch of Desquamation received on the pubes & the right hip and side, and also on the back. Received Iodoform & applied. and a poultice on the wound. It helped well. P.O. Sup - Dense clinker - Diarrhoea
"	27	He is doing badly. Bruce day. Skin hot. Pulse rapid 130. The fluid of the air now issuing from the lower paralysed wound. indicates that the bowel has given way. he is drowsy sinking. It is odd that this should have been expected long probably until 3 days ago when the typhoid symptoms began to shew themselves.
"	28	In response this morning. I hear he died last night

Month	Date	Particulars of Case Cancer of Tongue. General Health	
July.	10	A small part not looking quite so well: sunken and not inclined to heal.	
"	11	The part of the wound already noticed looks suspicious. Induced it with Zinc Chloride for xxx minutes through xxx in paste — The gland on the left side is still swollen. Looking very strumous pimpled	
"	12	Much the same. I fear it will come to nothing. Applied the Zinc Chloride again	
"	13	Not looking so well. Ulceration surface extending	
"	14	Spoke with Dr. Gordon. (Could he cure) He decided to try it for a few days & then if not better amputate —	
"	16	She is much the same. Continue the Zinc Chl: for a few days — Gum not increased since yesterday. The tongue rather better than she died. Gland under the jaw not so large is pimpled	
"	18	It is increasing slightly. Gland under jaw still swollen. Applied Zinc Chloride infusion with flum. Stronger than before. The sore is excavating under the tongue surface — General health much the same.	
"	19	Pimpled from the Zinc. All the signs of increase of the disease.	

Month	Date	Particulars of Case
		Injury to head & Throat
July	4th	A stout healthy looking Baboo named Hurrichunder Legh aged about 50 was admitted on the 3rd having fallen from a verandah which fact was with him. He was almost insensible they said when picked up. Bled sharply from the nose but not from the ears. The ribs of the right side were broken in several places & he rapidly became stupiferous. He remained in a semi-comatose state, talking about and talking incoherently, but indicating that he understood what was said by putting out his tongue when told to do so. He remained much in this condition. Throat neck and arms stuffing and breathing loud audible on right side, inverted on left. Eyes, especially left, injected with blood. Pulse rapid but little strong. On the 3rd his symptoms seem much the same, but the left lung apparently becoming engorged. Print taken head in st. circular in upper part of right. Pulse rapid & hard with. Dyspnoea. Fresh V.S. Ad ℥xvi. Venam. Ant: Cath: pr. Mist Camph ℥iss 4 hrs. Mist Camph ℥iss 3 hrs & Tonic h

Month	Date	Particulars of Case
		Injury to Head and Thorax
July	4	unable him to expel some of the blood collecting in the lungs. Immediately he had stimulants. When low delirium & when the pulse rose & stertorous became more marked he had artificial fits & Death: fits .. by 3 hours. Fractured fracture to thorax — He died at 5 P.M. of the 3d Inst. Post. at 9 A.M. 4th Inst. Body covered with fat — Thorax. 10 ribs of right side broken front of sternum and 2 or 3 places and in one or two places the bones from the pleura — Worked for long hope I could find every wound in the right lung which was much collapsed. Suspected healthy in this case. At last I found it in the back of the lung lower lobe. a slit not larger than — made by a portion of the 5th rib close to the vertebral attachment. The condition of our had been thus. the lung became collapsed to a certain extent & must have been wounded. There was much bloody serum in the thorax left side suspected healthy lung compressed at the posterior part. Not

Month	Date	Particulars of Case
		Injury to Head and Throat
Jul	4	inflammed - In other injury to the throat. Abdominal viscera not examined - Head. Face much contused and echymosed, scratched as tho' it had come in contact with the ground. On removing the Calvarium a firm black clotted blood was found between the Dura Mater & skull over the orbital plate Dura Mater not there injured - On turning out the brain it was found that there was a longitudinal fracture, the skull commencing in the frontal bone, detaching Crista galli & passing through Sella Turcica terminating in the temporal bone & opening the skull cavity. The brain anterior lobe left cerebrum corresponding to the fracture through orbital plate was lacerated & the olfactory lobe of that side destroyed - The surface of the Brain was highly congested. a quantity of serous fluid - and the depths of the convolutions injected with blood. on the posterior surface of the right hemisphere in a directly oblique line from the fracture in the frontal bone - was an effusion of blood on the surface of the Brain in front of the convolutions slightly torn on lifting the frontal lobe the surface of the Cerebellum & the Brain strongly congested healthy & not congested

Month	Date	Particulars of Case
		Median Lithotomy
July	6	A little Bengalee boy aged 2 years brought by his mother. Said to have retention of urine. Refuse during child healthy. Chloroform – passed a small catheter. found a calculus filling the urethra just above the scrotum. In attempting to push it back into the perineum. it passed back into the bladder. I cut him in the median line and whilst pressing the calculus down forward towards the incision and was secured. It was such a from a black size a small bean There was no hæmorrhage –
"	7	He is very well. no bleeding. urine passing by the urethra. none by the wound.
"	8	Very well. passing urine entirely urethra. wound looks healthy –
"	9	Seems very well. wound nearly healed
"	10	Urine all by natural channel
"	11	Mother assures his on the thirteenth from quite well
"	16	wound nearly healed
"	18	Discharged wound all but healed.

Admitted & Operated July 6.
Discharged – " 18.

Month	Date	Particulars of Case
		Aneurism of splenic from the arm
July	8	A Bengalli name of Tinkowry Mookerjee aged 25 yrs, healthy looking presented himself, saying that he had 14 days previously ~~[illegible]~~ run a thorn into his left forearm. He was walking in the dark fell and the thorn pierced and remained in his arm. A small spot that would not admit a probe above the centre of the muscular part of the forearm without any swelling, but a faint blush of redness indicating where it had entered. As he and his friends said they knew it was still there I made an incision and removed carefully under the skin & underneath the superficial muscles but could not find it. I pursued the examination making the incision deeper along the side of the radial artery, and in the deep layers of muscles close to the interosseous membrane I felt the blood and. This with much difficulty I seized with forceps, guided on my finger, and with second a firmly pulsating leaf my hand & sharp about an inch long. The extraction was followed by some arterial bleeding as the leaf had entered a small artery. This ceased on pressure

Month	Date	Particulars of Case
		Removal of Spleen
Jul	8	He came to day with the arm a good deal swollen & painful. I advised him to remain in hospital. ~~He [illegible]~~
"	9	Much swelling & suppuration with a little fever. Poultice and salve
"	10	Left hand suppuration free
"	11	Much better. Slept with water.
"	16	Discharge still rather profuse, but the wound is healing —
"	17	Arm much swollen & profuse discharge. Dressed this. In consequence of pulse a violent arterial jet. — Dried the wound American Sponge. It arrested the hemorrhage but it is not easily applied. — The bleeding appeared to stop, but as the arm continued to swell, became tense (blue, pulsation stopped, radial fell) I thought it best to cut down on the direction of the ulnar. Then with some trouble was exposed in a sheath of clot, lacerated, and small bladder of macerated by suppuration. I found a wound on the ulnar. On the inferior side a large branch probably the radial, which in attempting the

Month	Date	Particulars of Case
		Median Lithotomy. Stone not extracted.
Jul	8	Name Sorrender Chundra. A little healthy looking native boy aged 3½ admitted with symptoms of stone. Sounded. Concretions felt & found both tends a rough stone just behind Pubes. but high in Median line. (after an enema) Dr. Menzies held the staff. Dr. Mullan also present. I hit the prostate readily divided in the usual way, and then passed a probe into the bladder along the staff. withdrew the staff and passed my finger along the probe reaching the prostate which seemed unusually small. I commenced to dilate and after a time thought the point of my finger had entered the bladder. withdrew it. stood with the probe as I could feel no stone. passed the sound again with more difficulty and found that I could not touch something rough like the stone. made several attempts but without success. did not like to injure the patient to more manipulation. passed some bougie in bed. he had but several ounces of blood.
2 P.M.		He is free from fever & pain. urine flowing freely through the wound
3 P.M.		Do Do He is sleeping. having had 2 drops of Tr. Opii. Friends told him home a few days after this.

Month	Date	Particulars of Case
		Perineal Section for Stricture
July	9.	A man named Pitumber Ghose aged about 25 years. a writer. admitted on the 3rd July 1863 with very hard stricture. urine passing in fine drops & natural passage and thoroughness passing in Permanent & Bougie. He has had it for 3 years. The whole urethra is stricture it begins close to the meatus and is hard and dipped all the way down. Permanent pulse 90 minutes & tongue & there rigors spring close he felt intense distress with great difficulty he urine was passed at last he repented efforts at length a Catheter No 8 was passed into the bladder thus proving the internal stricture that had the external appearance of, and in it passing against the stricture I divided the stricture in the perineum then passing a tortuous hard & contracted portion feeling under the knife. Passed the tube into the bladder at once. There was a little haemorrhage from the perineal artery. it soon ceased on pressure

No 28

CASE BOOK.

Month	Date	Particulars of Case
		Perineal section for Stricture
July	10	He is doing well. Had slight hæmorrhage. Took out the tube and had fol[illegible] passed a catheter down to the wound in perineum.
"	11	Had slight fever - but better well. Reintroduced the perineal tube. Passed No 8 down to the perineal wound
"	12	Doing well. Passed No 6 into the bladder.
"	14	Doing very well. wound looks healthy. passed No 6. — urine rather tinged
"	16	wound looks healthy. Passed No 6.
"	18	Passed No 8 this morning.
"	21	Passed No 8. Injected the bladder with Borac chlor: f.ʒ to ℥j as the urine is rather foul —
"	22	Passed No 8 as usual.
"	25	Doing well. urine clear. No 8 passes easily. wound closing
"	29	Discharging daily. No 9 passing easily
Aug	1	Doing well.
"	4	do
"	8	The urethra is perfectly united and the perineal wound is closing the sinuses are also closing but pell expectorated daily
"	13	Urine again passing through the wound It has two months and then into me

CASE BOOK.

No 27 continued from page 70 –

Month	Date	Particulars of Case
		Median Lithotomy.
Jul	9	He slept well. urine flows both ways. has no pain. no fever. He had medicine Dr Shi last night.
"	10	Had slight fever last night. but he seems to be doing very well. urine flows both ways but mostly the natural channel.
"	11	Boy had slight fever last night. but he is doing well. urine passes freely both ways. Passed an inst. but as there was indication of hour-glass. did not introduce it entirely.
"	12	Doing very well. urine passing chiefly through the wound.
"	13	Passed very finger into the bladder again. but could not touch the stone felt it – as before with a sound
"	14	Doing well. urine passing by wound
"	16	Doing well. no pain. no fever – urine flows through the wound
"	19	Doing well. urine passes chiefly by wound. partly by urethra.
"	21	His friends are tired of constantly urging us to taking him away. I attend as out patient. The boy is doing well
"	25	Brought him again today he looking very well. urine passes through wound. Not so much

Month	Date	Particulars of Case
		Median Lithotomy.
August	6.	The friends brought the boy again to day the wound in the perineum much contracted. passed a catheter through it into the bladder & felt the stone as before — removed catheter passed a grooved staff — and dilated the wound passed a long narrow form of the forceps through it — and with great difficulty forced a part of the stone, which was very hard and friable — crumbled under the forceps, & removed it — 6 further efforts I removed the remainder — & the stone proved to have been a soft phosphatic friable calculus adherent to the bladder just behind the tubes. about the size of a pigeon's egg — The boy lost little blood — Urine & spermaturia passed 49 grs. Boy very faint. Restless pulse. Parents resist — on taking him home Parents took home away yesterday Brought home this morning. he is doing well. urine passing by the wound —
	14	Friends reported this morning that he is doing well. urine begins to come by urethra. he slept at intervals
	15	Friends report that he had all the urine passed by urethra.

Had more severe rigors before the stone was extracted

14 Aug Friends brought the boy Perineal Wound nearly healed All the urine flowing by the urethra. passed 1 grs

Month	Date.	Particulars of Case
		Splinter in arm continued from page 69
July	17	in extending the incision and the arm was divided. Both ends were tied and the haemorrhage ceased. The radial pulsation ceased, and the ulnar returned when the clot which had compressed it was turned out. I sutured up the wound with silver & wrapped the arm in a wet bandage. I visited him at 8 P.M. There had been no more bleeding & the radial and ulnar arteries were both pulsating distinctly —
		
"	18.	Both radial and ulnar arteries beating strongly. Slight fever. Arm painful and inflamed. Discharge rather profuse — Poultice and Saline
"	19	No fever. Less pain. Discharge profuse.
"	21	Doing well. Dressed with water dressing. Ligatures come away
"	22	He is doing very well. but the discharge is rather profuse

Month	Date	Particulars of Case
		Schlutermann. Fracture of Radius Carter
July	23	He is doing well. There is a profuse discharge from the arm. but the surface is healthy
"	26	The wound is rapidly cicatrizing
"	28	Has sharp fever to day. but the wound is still doing well
"	29	No fever to day. wound doing well
"	30	Doing well. no fever. Suppurating
Aug	1	No more fever. he is doing well wound contracting
"	3	No return of fever. wound closing rapidly.
"	6	Nearly well. The ~~one~~ wound is contracting & the edges of the skin are turned in
"	8	Nearly healed.
"	9	Discharged. nearly cicatrized
		Admitted July 8th
		Radical cured " 17th
		Discharged Aug 9th

Month	Date	Particulars of Case
		Cancer of Tongue
July	21	The pain caused by the last application of Liquor Chloridi has subsided. but there is no improvement.
"	22	I removed the diseased part, assisted by Dr Goodeve, Partridge & Charles - Passed a needle and double suspend ligature as far back as possible through the base of the tongue - a second obliquely through the long medium - a third along the floor - the bone the mandible well. and the hæmorrhage was very trifling - It was very difficult as the disease extended so far back that the needle had to be passed through the base of the tongue out of sight and it was very difficult in the first place to dig the ligature in the point of the needle, and in the second place to tie the knot tight enough to strangulate the included part - but the other two ligatures there was no difficulty. — Soon after the operation I gave him a pulse and opium There was slight oozing of blood which I directed with ice - In the morning I found his pulse quiet - He signed that he was

Month	Date	Particulars of Case
		Cancer of Tongue
July	22.	Suffering a good deal of pain. She is able to swallow but with difficulty. Gave her another Pint. ordered fomentations to the head & mouth.
"	23	Did not sleep well last night. but has had less pain. She had two full doses of opium during the night. Pulse 96 in fever. The tongue looks completely strangulated & there is a profuse flow of ~~fetid~~ foul saliva. She is able to swallow and has already taken some Port wine & water. Pulse at Noon 84. The head & submaxillary region are somewhat swollen. but they have been fomented. —
"	24	The circulation is not quite cut off the parts still vascular. Bleeding tendency lessened. The ligature a little. She is more quiet & rational. Made an the mid day — 130 — The mouth is frequently syringed with Sol: Hydr: Chlor: She takes Eggs & Milk & Port wine Jelly.
"	25	The ligature came away the disease extended to the Mass. I fear there is still an extension through which blood finds its way. In other respects she is much as she was yesterday

Month	Date	Particulars of Case
July		Cancer of lower lip.

A man named Alfred Bywater age 37. English Sailor. has been 9 years in India. very slight sallow complexion but not unhealthy looking, admitted on the July with a sore on the lower lip a little to the right of the centre. It is flat, soft and prominent like a pregnancy red granulating one. Quite free from pain and not involving any neighbouring glands. He has had it 8 years. It began as a wart which he used to pick. It dried up. broke away in scales picked again and again until finally became what it now is. It was touched with nitric acid. Nit. should be thought make it worse.

He has blue eyes light hair and fair the sallow complexion. He says that his life lately has not been steady he drank a good deal but he has not the appearance of an intemperate person.

I examined it under the microscope and it is clear of malignancy. Both he says the pipe irritated it but he does not remember whether it actually caused it.

The result of the first examination

Month	Date	Particulars of Case
		Cancer of ~~Tongue~~ Lower lip
July	21.	Removed the disease by a triangular incision. The hemorrhage was very free. The edges of the wound were brought together with one suture.
"	22.	The wound looks well. as the it were uniting — no pain. no bleeding
"	23	Took out the sutures, no bleeding. wound united - Dressed with strapping plaster.
"	25	Doing well. wound nearly healed.
"	28	wound healed
"	29	Has got a severe cold swelling of face
"	31	Abscess forming in the cheek. Poultice — wound quite healed
Aug	2	Opened an abscess under the jaw
"	4	Swelling & pain much less.
"	6	Much better. Left home since Sunday, 2nd. He takes his food some well. The wound on the lip has perfectly closed
"	8	Much better abscess below jaw nearly healed — health improved
"	10	Nearly well.
"	12	Exhibited tonics Red: Convalescence
"	13	Swelling under jaw has taken round parotid. Has it any connection with the Cancer?
"	17	Swelling much abated. but still hard
"	18	Nearly well

Month	Date	Particulars of Case
		Cancer of Lower lip
Aug	19	Still some hardness under the jaw. The body cachectic but he says he feels much better.
"	22	Some hardness under the jaw still but on the whole he is better.
"	25	Discharged cured. Admitted Vacated July 21. Discharged Aug 25.
Oct	5	Returned to hospital with a livid fluctuating swelling under the right jaw. Just where he had the hardness soon after the operation. He looks wasting miserable. In fact dangerous. He looks collapsed, but he says. Otherwise very well. The tumour has not shrunk at all. It seems about as large as at first. Hard. Shows malignant structure.
"	7	Examined and found. Hum Cyst glassy which ended from a puncture in the apex. Several large granular cells mixed in the blood corpuscles. Heart latency.  Urine Sp. Gr. 1.1 x. turbid — He has a sickly cachectic appearance — Not much pain in tumour

Month	Date	Particulars of Case
		Abscess in leg
July	19th	Mr A. M. whose case is recorded in a former note book. Compl: Fract: of leg with excision of bones put to Hanover. Came down to Calcutta on the 1st with pain & swelling in the leg and daily recurring attacks of slight fever. Loss of appetite & general malaise. I found the leg puffed and hot all about the fracture. Especially on the inner side the act of exertion communicated with the fibular and red and tense. No fluctuation but. Still the swelling persisted and on opt. near the fibular cicatrix under impression I wait ed him a few days and as the leg was hot & tense laid him on his back with a bold compressing bandage on it — On the 22nd the pain not abating I called Smith —
	24th	On the 24th with Dr Macrae I put him under Chl: and made a deep incision down between the bones. A quantity 3 ii of pus was evacuated from a cavity between the bones and in the fibula the finger detected a rough bend & pitting necrosis

Month	Date	Particulars of Case
		Abscess in leg
July	24	He appears quite to have been taking any violent medicine as Rhubarb. wearing a high heeled shoe. & having lately, then recently the symptoms of the dist: aspect of leg. He had for some time felt somewhat pain & there could little doubt, I think that he has dropped the fragment. & inflaming a fresh somewhat fibres and that has given rise to this local formation of this abscess He only remembers one distinct shivering fit. but the accompanying pain - just prior of the leg. tightness about the ankle. & dull recurring pain. loss of appetite & impaired secretion. regard the formation as my mind rest more on just
Jul	25	Pain gone. but he is feeling only dull. has had several fits of vomiting & retching. Pulsation in the leg & the discharge to be just perceptible I should notice that on Tuesday I had used the exploring needle 2 in long twice up to the head. but my pain came through the skin. probably permitted by a clot of blood

Month	Date	Particulars of Case
		Abscess of Leg —
July	26.	He is much better this morning. He has had fever. rapid pulse upwards of 100 — and complained of great irritability of stomach. in consequence attempts at vomiting. He is low and depressed. Tr. Macrae had given him a Cal: Pill & ½ — last night and an aperient preparation which had somewhat allayed the irritability. I advised a continuance of Brandy Injection in an ounce of R: Brandy. The discharge from the leg is pale & the colour red dish. not healthy looking. Continue the Injection.
"	27	I did not see him today. as I was not well. Dr Macrae reports him better.
"	28	He was better in the morning — at 10 m. Bleeding recommenced from the wound. but it was trivial. Medicines by presence Mountain had probably caused a small recur. The action has not been healthy. & the tissues pale & flaccid — bandaged the leg.
"	29	I saw him again today. but no bleeding. wound looks somewhat better. Discharge thin. yellow & less in quantity — He is taking Quinine.
"	30	Discharge more healthy. Fever less. He is taking Quinine

Month	Date	Particulars of Case
		Abscess in left Antrum
July	31	Pain in chest left side not so well. Pulse over 100. Skin dry & hot. In the evening he spat a little blood. Macrae ordered him some medicine
Aug	1	In morn: this morning there is Pneumonia of left side & rusty sputa in middle fragments. Fomentations & Linseed tea. P. to 3iv by 4 hourly. B. Tea. Leg loosed & well bled, no pain, no action in it. Macrae ordered him Hy N: Antim Pulv Antim & Morphia & ordered some Jaborandi tea brought in morning
"	2	He is much the same. Bronchial breathing & bronchophony in upper portion left chest. Pulse about 100. Not so hot to hand. Skin tending to moisture. Bronchi have cleared. He has taken P. to. 3iv by 3 hourly & Beef Tea
Morphine		Cough hard. Expect. rusty & tinged with blood. Ordered Antimonial wine 3iii R Spiri — 3i Mist Camph 3vi. On dressing it to the finger nail he acted as a Dead Subject. Dr Ritchie ordered P. to 3vj by 4 hourly. Repeat Fomentations Poultices. He is going on favorably. Leg discharging. Wounds. Slight bronchitis

Month	Date	Particulars of Case
		Cancer of the Tongue.
July	27	This morning I was sent for at 5½ p.m. She had had hæmorrhage from the tongue & had lost in the day about 10 oz. She was much weakened. She came groaning from under the tongue, where the lower ligature had come away. Hæm. was arrested by pressure. But she had undergone a fearful ordeal in the dark. Her daughter dressed under at daylight. — I secured slightly one but was unsuccessful. I saw her several times. She was much weakened
"	28	Very weak. P 100. Not she walked to the chair by the window & sank against the wall. She continued in more bleeding. Tongue looks quite alive. Notwithstanding the deep formic cutting it. Her bowels moved freely — received plenty Beef tea & Port wine —
"	29	On warning it this morning I find that the other ligature came away with a slight pull. One looked at then the other as in 1st Instance — A considerable portion of attachment left — I forced one hand into the tube & with the sponge. I passed another

Month	Date	Particulars of Case
		Cancer of Tongue Continued
July	29.	loop of ligature round the whole. entering it at the frame in the base. This appeared at the time quite sufficient to strangulate the tongue which became livid and swollen - She lost no blood. but was a good deal exhausted by the pain. - In the afternoon I punctured the ligatured portion and a quantity of dark blood oozed out, but without any pain to the patient. She later yielding very well to bromide - Beef tea and Port wine frequently.
"	30	She slept at intervals. Her tongue looks appears perfectly clean - quite sick & weak. but otherwise she is much as usual. Taken wine & beef tea at intervals -
"	31	Removed feat (?) the tongue with scissors. found one small portion still in the centre oozing living blood. Put round the ligature on it -
Aug	1.	She is weak but otherwise doing pretty well. The pain in the tongue has separated both at the posterior & lower half of the tongue - Slept well last night - Slept well in afternoon

Month	Date	Particulars of Case
		Cancer of the Tongue continued
August	2	The last ligature came away this morning. The surface left is convex of an ashy color with granulations appearing one or two suspicious papillæ. No very elevating of the surface is one suspicion but not so much as in pulling any appearance of cancer. She is stronger. The gland under the jaw is certainly less swollen less painful. She can speak but very indistinctly as before. Nutritious wine & astringent gargle
"	4	The surface looks clean, covered with florid granulations. Examined a papilla yesterday and found suspicious cell forms. But the surface up to the present looks favorable. She feels much better. Stronger and better spirits. The speech is altered but she can still articulate.
		Result of the microscopical examination on the 3d August. The day after the ligatures came away. The part examined was a fungoid papilla
"	5	Suspicious elevations of granulations on left side at margin of tongue. Pharynx much inflamed.

Month	Date	Particulars of Case
		Perineal section. Stricture & retention
July	27th	An English steward, a ship named Willis aged 33 was admitted on the 3rd with stricture of 3 years standing with D. P. and I was sent for by Mr Hayes the H.S. to see him. D. P. lay side. I found the bladder distended. Patient in great distress. Could pass no urine. In fact could let passed. Dr Fraser had seen him and tried at 4 p.m. Put him under chl: found an impermeable stricture & a large false passage, which he apprehended to be. He had been when admitted. As he had not let passed. I put him in attitude position and cut him on the median line down through the stricture & fortunately hit the passage without delay. I divided the stricture on a catheter and left the tube in the bladder. No permanent vascular. A some blood oozed under the fascia on the bulb. A few teaspoonfuls of hemorrhage but soon ceased.
"	28	Says he feels quite easy. Slept well. Urine slightly flocculent

Month	Date	Particulars of Case
		Perineal Section.
July	29.	He says he was slightly feverish in the night. Urine flows freely through the tube. Dr Partridge took charge of him. Took out the tube and [illegible] Catheter
		Urine flowing freely [illegible] slightly feverish in the night [illegible] paper both ways [illegible] the pressure [illegible] [illegible] days until the parts are [illegible] Urine passing freely. [illegible] of pain in the [illegible] hitherto used [illegible] [illegible] Dr Pl[illegible] [illegible] of the bulb [illegible] [illegible] with meals [illegible] days. The urine [illegible] natural channel [illegible] bleeding a good deal. [illegible] been passed [illegible] well [illegible]
"	13	Nearly all the urine passes by the [illegible] he is doing well.
"	20	Doing well.
"	22	Doing well. [illegible] to the structure but appears to be suffering from a swelling in left thigh.

James O'Neale aged 30. a sailor Irish was admitted into the Mod. Coll. Hosp. on the 12 Oct. 1873 at 3½ p.m. with the following symptoms. The patient was under the influence of liquor. but was quite sensible. He is a healthy looking stout man. had a stab on the inner part of his right arm, just over the course of brachial at its upper 3rd; it was a horizontal wound about 1½ inch long. The probe went deep down sliding upon upon the muscles. There was a constant dribbling of venous blood. No pulsation of the radial at the wrist of the same arm. There were several other cuts (superficial) on the palm of his right hand. No injury

1st. Nov. Sensation all returned. but cannot still bend the thumb & fore finger.

2d. 3d. 4th. 5th. 6th. 7th. Improving - on the 12th it is noted that he can close the fist - though not very strongly. the fore finger still remaining extended at the time of closure - but can flex it with the aid of the other hand. Sensation of the ~~fo~~ index finger & thumb on the palmar surface still somewhat impaired - Pulse distinct at wrist - ~~but~~ weaker than ~~that of~~ the left -

James Oneale aged 30. a sailor Irish was admitted into the Med. Coll. Hosp. on the 12th Oct. /63 at 3½ P.M. with the following symptoms -

The patient was under the influence of liquor. but was quite sensible. He was a healthy working stout man. had a stump on the inner part of his right arm, just over the coronoid of brachial at its upper 3d.; it was a horizontal wound about 1/2 inch long - the probe went deep down sliding upon upon the muscles. There was a constant dribbling of venous blood - No pulsation of the radial at the wrist of the same arm. There was several other ~~cuts~~ cuts (superficial) on the palm of his right hand - no ecchymosis

~~on~~ for any swelling about the wound on the 13th. The pulse at right wrist was perceptible but very feeble -

14th: Pulse same as yesterday - temp. of fore arm natural. Complained of pain in his arm. Numbness of hand & fingers & the arm, below the wound - rigidity of biceps.

15th Same as before - echymosis at the inside of elbow -

16. Sensation of little finger, ring & inner half of middle finger natural. No pulse at the wrist. temp. natural.

17th: Same.

18 Extreme sensitiveness of the part just above the wound as the mere touch the end of a nerve is touched. pain in the arm left. No pulse at wrist.

19 The radial half of forearm sensitive but the ulnar half numb. Otherwise same -

20th. No sensation ~~only~~ in the index & thumb. A small part of the ulnar side of elbow numb. on the whole improving -

21. Better. Pulse only perceptible.

22nd: Pulse more distinct. Extreme sensitiveness of part about the wound continued but less than before. Numbness of hand & arm much diminished. The fore finger & thumb powerless. Sensation ~~of the back of the finger~~ returning in the back of the hand & fore finger. Slight hardness on the course of artery & biceps. Pulsation of brachial very distinct down to the wound.

23rd & 24th: Improving -

25th: Arm stronger - Can move 3 fingers. echymosis disappearing

26th & 27th: Improving -

28. Pulse perceptible & distinct at wrist. Acute sensitiveness much less.

29th & 30th: Much better

31st: wound healed.

Month	Date	Particulars of Case
		Perineal section. Stricture & retention
July	27th	An English steward, a ship named Willis. aged 33 was admitted on the 3rd with the stricture of 3 years standing under Dr P-ons care. Was sent per S[illegible] from Dr P. [illegible] bladder dist[illegible] distress. [illegible] He first [illegible] had seen [illegible] Just been [illegible] impermeable [illegible] a large bole[illegible] apprehend [illegible] when adm[illegible] by passed. [illegible] position [illegible] external [illegible] the stricture [illegible] the passage [illegible] divided the [illegible] and left the [illegible] No permanent [illegible] some blood oozed under the fascia on the hill. A few days [illegible] of hemorrhage but soon ceased.
"	28	Says he feels quite easy. Slept well. Urine slightly flocculent

1st. Sensation all returned. but cannot still bend the thumb & fore finger.

2. 3. 4. 5. 6. 7. Improving — on the 12th it is noted that he can close the first though not very strongly. the fore finger still remaining extended at the time of closure — but can flex it with the aid of the other hand. Sensation of the index finger & thumb on the palmar surface still somewhat impaired. Pulse distinct at wrist — but weaker than that of the left —

Month	Date	Particulars of Case
		Perineal Section.
July	29.	He says he was slightly feverish in the night. Urine flows freely through the tube. Dr Partridge took charge of him. Took out the tube and passed a No 8 Catheter
"	30	Doing well. Urine flowing freely both ways. Slightly feverish in the night
Aug	1	Doing well. Urine passes both ways
"	2	Doing well, but the pressure of the catheter in the rectum passed today as the parts are bruised. No pain. Urine passes freely.
"	3	Has a good deal of pain in the wound. Urine trickled over the scalds. Let him have more than bit:- 2 oz Pb. to take the influence of the bile which indirectly to alternate with weak solut. aqua Ammon:- He says the urine passes chiefly by natural channel
"	4.	I find him bleeding a good deal. No doubt had been passed
"	6	He is doing well
"	10	Getting on well
"	13	Nearly all the urine passes by natural channel. He is doing well.
"	20	Doing well.
"	22.	Doing well as to structure but appears to be suffering from a swelling in left thigh.

Month	Date	Particulars of Case
		Perineal Section.
Aug	25	He has hard painful swelling on the left thigh. Abscess has been lanced. He is doing well as to the structure. The urine passes freely, & the wound has nearly closed.
	30	Doing very well. Swelling in leg better. Wound in perineum healing
Sept	3	Doing very well. Leg much better on walking yesterday. Wound in Perineum closing. Urine passes almost entirely by the urethra.
"	10	Doing well. He tells me there is some difficulty in passing the bougie but he makes a good stream. Leg better.
"	17	Doing well. Wound healed. Some little trouble in passing the bougie
"	20	He tells me he is quite well. but that Dr. P. still has some difficulty in passing his bougie
Oct	8	So doing very well. Still some difficulty in passing the instrument.
	19	Passed sound to No. 10 – 4 days without much difficulty.
	20	Had slight pain after passing the bougie
	21	Better to day
	24	Doing well. In bed. but feeling a little pain in back & did not pass bougie to day
"	25	Passed No. 8 with ease. He seems quite well again

Month	Date	Particulars of Case
		Ovariotomy (Dr Charles)
July	29	Yesterday at 8 p.m. I assisted Dr Charles to perform Ovariotomy. The patient an emaciated Native woman of about 25 to 30. Had an enormous Hydatid Cystic tumor of the ovary. Her pulse was feeble. She was suffering so much pain presume that the operation was performed as the only chance of life. Passing into a collection of cysts and finding so hard nothing detectable — a long incision was made from ensiform cartilage — a small quantity of ascitic fluid escaped. The cysts were very adherent in front: small ones punctured and finally cut down fitting exit to quantities of Steatomatous matter & hair with flaky pieces somewhat like. The adhesions to the omentum were considerable and also to the intestines. Intestines broken down — enormous mass of dense fleshy looking substance in body encephaloid. Pushed up the spleen & filled the left hypo

Month	Date	Particulars of Case
		Ovariotomy
July	29th	The tumor detached, torn away, & left with the cavity. The hand felt the left lobe of liver. Spleen and heart beating through the Diaphragm. All healthy, blood & steatomatous matter being removed. The pedicle further encephaloid & not included as much as possible. A clamp compressed on the pedicle of the fourth, being the left ovary and it was divided. The abdominal wound then brought together with wires. She became very low on the table, partially rallied & pt up to 148. but died then nearly less than 24 hours after the operation. Examination that she lived so long.
8½ am.		The P.M. revealed nothing more the spleen was small but healthy. The encephaloid was in part remaining in left hypo. Intestines very small. Right ovary healthy. The hand very hard & dried. Intestines healthy generally. Mucous ragged & very much enlarged.

Month	Date	Particulars of Case
		Section of Radius & Ulna in a badly united arm
Aug	1.	An English Sailor named aged 31 years - admitted in the with a piece of necrosed bone protruding from the left humerus above the elbow. He had fallen from a cloth at sea broken the left femur. left humerus left Collar bone - all had been united with much and as the Capt. said fine & with very little deformity. With a piece of the humerus about an inch long and 1/4 thick had exfoliated and was protruding. It was removed by a pair of pliers & the wound sewed. The Collar bone, imperfectly united, was pushed up in the usual fashion. From a former accident the left fore arm was much shortened bent and thickened. To day I cut down on the bones and with some difficulty sawed them across below where large masses of plaster were deposited and then straightening the arm the not so much as I hoped, owing to the extreme pain of the Collar. I brought the edges of the wound together with wire & placed the arm on a straight splint.

Month	Date	Particulars of Case
		Lecture of Radius & Ulna
Aug	2	No pain. Slight oozing of blood. Not much pain
"	3	A good deal of pain. p 120. Arm red & painful. Salines. Bromide & Lead & Opium
4	4	Redness the arm. Violent inflammation & much discharge. Left pain. Keep it covered with Lead & Opium Lotion. Frequently prep out the discharge
"	5	Much discharge & some arterial haemorrhage. tie of a medial vessel. Dressed the arm. He is a good deal reduced.
"	6	Slight haemorrhage in the night. Arm a good deal swollen & painful. Leg swollen less so than it was. Dressed as before
"	7	Slight quantity of blood last night. Murphy's attention of the dressing is very needful than many with tendency to haemorrhage. Still Pulse very rapid. Turned out a quantity of pus & clots
4 Pm		In more bleeding. Arm covered with ice - No pain. Feels better in all ways
"	8	He is better. No fever. Pulse fine. Discharge copious & thin pus & clots. Good Cdn. Continue ditto.

Month	Date	Particulars of Case
		Abscess in Leg. Pneumonia
Aug	8	He slept at intervals. Cough not troublesome in the night. Afterwards, many he had a good deal of cough and expectoration looser and not so sticky. He had no urine passed in the night. His bowels have acted freely this morning. He is weak & depressed in spirits. Pulse ~~[illegible]~~ 116 – He says much heat of skin comes on at 8 P.M. and continues till 3 A.M. Then he sweats & sets down. Let him have his usual Beef tea on Saturday. Wine continue occasionally – He vomited some bilious matter when his bowels acted.
"	4	He is rather better to-day. Pulse – much expectoration. Less wind & less sticky. Breathing easy. Has perspired freely in the night. Respiration distinct – no seat of inflammation. Right pleura sound. Lower third posterior part of chest: Vocal & Bronchial breathing & moist rales. & a small dose of the antimonial occasionally.
Sept	1	Pulse 116. Rather bronchitic: expectoration less – & less sticky. Complains much of want of sleep. Let him have [illegible]. Lig Pip: Sed min 40 at bed time an aperient in the morning. Continue wine & [illegible] antimony occasionally

Month	Date	Particulars of Case
		Abscess neck & Pneumonia
Aug	5	Slept better. P 100 - 28 R. Tongue moist - coated. Dry rales over the chest, right side less, respiration same over upper part of lungs but left chest - dullness rales returned. Right pectoral continue. Small blister. Continue wine & food as usual. The opium last night appears to have checked the secretion. & the sputa are more varied. still muchy but less or than formerly - He says he feels better but is weak.
"	6	Blister applied. He had a restless night & some more pain in left side which was relieved by the blister. Dry bronchial rales on right side. Dullness & some bronchial respiration on left. In expectoration appears in the form of thin mucus. except perhaps the upper part - and left throat. Bowels relieved. Pulse 100. 28 R. He feels low but in the whole is not worse. The wound on the leg looks well. ℞ Continue Dect P 1/8 Sum Dmel P 1/4 hour Continue wine & food as usual Dress the sore with a poultice. In pleuritic bronchitis but very doubtful in bronchial tubes of both sides

Month	Date	Particulars of Case
		Abscess of Lungs & Pneumonia.
"	7	Had a better night. Some clear expectoration fine pink mixed with viscid & opaque. Dullness sounds less marked. but still some crepitations at bottom posterior left side. also some in left side upper back. - Bronchial dry râles also audible. Mucous & old Pneumonic patch. large crepitation arrested - (all return) - Still shortness. pain of hand not at times. Pulse over 100 - but soft. - P.M.: Iodide: pill tr. Ree. Cont: Fomentations. 4 oz of P.W. & Beaufoy in chest.
Dec. 7.		Still bad all day. pulse 104. soft. Cough. expectoration bad not discolored. Hairy & pitty. Chest sounds same as in the morning. respiration all over chest. but still some dullness in left side. and plenty of pain. Bronchial dry râles. in both sides. - Contin: P.M.: Iodid: Foment: 2: Hyp 3ss at bed time. -
"	8	He is better. slept better. p. 100 - soft. - Cough. Continues less expectoration. but better. In pectoral spinal. Bronchial dry râles over both sides

Month	Date	Particulars of Case
		Bronchitis and Pneumonia
Aug.	8	Pt. Cough seems better, breathing and the expectoration is rusty. Added a little spirit to Tr. Camp: Ipec: & Tr. Camp: Mixture. Continued Quantity slightly increased. P. 104. Stat. Treatment - Cough Continues. Very irritable with others. Must be removed all men. Continue the prescription and the Iodide: potash mixture stat. I think part (the upper portion) of left lung is still dull. but I hear no crepitation. Very slight pleurisy, he seems to be gradually improving.
"	9	He is slowly improving. Dry Bronchitis rales all over the chest. No pleurisy or crepitation. A good deal of Cough & Dyspnoea this morning. Rep: Ferment: with Carbonate of Potash: Iodide: Potass: & Cough Mixture. P. 96. Tolerably soft.
"	10	Pt. passes expectoration this morning. Rales increased. Sound Bronchial rales all over chest. Some dullness on lower part of left side & near the old Pneumonic patch. Manage as did yesterday. Cough Mixture continuing & Counter -

Month	Date	Particulars of Case
		Cancer of Tongue continued from page 88
August	6	In my way the secretion better. but there is a suspicious spot at the left side still. She has been not so well again yesterday. She has resumed the Tonique tonic
"	8	The use of potassium & iodine & spots appear have partly extended the rest left to healthy part
		
"	9	She is 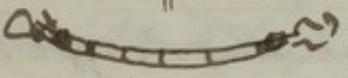 doing well in all respects, except the spot which lasted written more suspicious to day —
"	10	Much the same. no alteration
"	11	Served to day with a violent pt. of Acne - which much perturbed her. prescribed 5 gr. doses of Quinine — ℞ 3 Plum
"	12	Seen returned last night - wd 2 oz a piece of apparent medicine - Cont Quinine
"	13	Seen again last night - but not so much. Cont. Quinine. Mouth rather sore. but slight indication of spreading - the small patch the granulating surface does not look as sore as the rest.

No 16 Continued from page 59 —

CASE BOOK.

Month	Date	Particulars of Case
		Abscess in the cervical region of Spine
Sept	27	He is better again now. but since last report he has had several pieces of bone taken away from the sinus which is still open he has written home
Oct	5	He is still in Hospital with a sinus in nine bone. has considerably lately & will probably soon close.
	8	Sinus still open, but very little discharge & no more bone come away —
	15	Still a sinus: but it seems to be gradually closing in —
	21	Still sinus discharges — no bone come away since last report
Nov	7	He was discharged some days ago the sinus all healed quite healthy & quite free from pain.

Admitted March 27th
Readmitted April 29th
Discharged October

Month	Date	Particulars of Case
		Lateral Lithotomy
Aug	6	A Bengalee boy Kedar Nath Beparee aged 11 years from Cuttack healthy admitted on the 5th Aug: with symptoms of Stone 3 years duration. On sounding him the stone was apparent. Kept him in hospital. and Dr: Simi saw him the following morning — This morning I removed the stone by the lateral operation. It was a smooth oval stone weighing 270 grs and composed with a large of Phosphates. There was nothing remarkable about the operation. It — kept that small by of the matter made it difficult to feel the ~~[illegible]~~ staff. The pain was neither excessive. nor the pulse accelerated. he showed no sign of sinking — except being thin. The Father said he has had the symptoms for 3 years. but that it is only lately he has suffered — since I suppose the deposition of Phosphates. There was not much haemorrhage.
"	7	Has a good deal of fever. urine flowing freely through the wound. No haemorrhage. Sulphate Morphia
4 PM	"	Left fever. urine flowing freely by wound Had slight abdominal tenderness. was fomented.

270 grs. composed with Phosphates

Month	Date	Particulars of Case
		Lateral Lithotomy
Aug:	8	He is doing well. Urine flowing freely by the wound. Less fever. Less abdominal tenderness. Bowels not been freed since a bottle of oil —
"	9	Slightly feverish. Urine flows freely through the wound & few drops by the urethra. Less abdominal tenderness. Bowels moved 3 times by the oil.
"	10	He is doing well. A little urine passing by urethra.
"	11	Wound looking clean. Bowels open. No fever. Urine passes partly by the wound & partly by urethra
"	12	Doing well. No fever. Urine passes mostly through the wound which looks healthy.
"	13	Doing well. Little urine passing through urethra to-day.
"	14	Doing well. Passed a catheter to-day.
"	16	He is passing urine by urethra. Stool
"	17	Much more urine passing by the urethra. The boy is doing very well
"	18	Feverish to-day. Urine passing by wound. Not much pus in fever. Zumine Mixture. Salines & Diet
"	19	Better, no fever to-day. Father took him home.
Sept.	18	I hear he is doing well. He still has a small opening in the wound

continued from page 91

Month	Date	Particulars of Case
		Perineal Section for stricture
Oct	25:	There is a slight inequality upon which the point of the sound catches on a section, but the passage is clear otherwise.
	28	Had slight symptoms of fever after passing on first yesterday.
Nov	3	He walked out a day or two ago. Quite well. Passing a good stream of urine.
		Admitted July -
		Operated " 27 -
		Discharged Nov - 1.

Month	Date	Particulars of Case
		Section of Radius & Ulna.
August	9	Another slight attack of haemorrhage this morning, in other respects he is better. Bleeding arrested by perchloride of iron.
"	10	This morning I was informed that he had haemorrhaged again yesterday afternoon. The House Surgeon applied a figure of 8 compress near the shoulder joint. This I find has not been loosened since 12 noon, yesterday. The hand and arm are cold and senseless, inflammation and all pulsation stopped when the compress was relaxed, which I did immediately. The arm in short has become gangrenous & the tissues above where the parts compressed are completely dead and livid. In the hope that perchance circulation might return I swathed the arm in a warm poultice. At 2 P.M. I said to a friend and as all the symptoms of gangrene were confirmed I amputated as near the shoulder joint as I could. Several vessels were tied here as my weak state I almost fear the result.

Month	Date	Particulars of Case
		Amputation of arm.
Aug	11	Had a pretty good night. No bleeding. No pain. Looks very weak from loss of blood. Pulse quick — Beef tea and wine
"	12	Dressed the stump. Looks well. Min yellow discharge from it. P. 120 — Urine clear — No appearance of retention of urine
"	13	Yellow Pus discharge, no sympathetic. Pulse 120 — No pain. Good diet. 3 oz P. to wine
"	14	Very well. More yellow discharge from stump — P. 120 — Bowels opened twice. Looks better.
"	16	P. 112. Looks better. Sinking to Drawing. Several ligatures came away yesterday. He is taking an astringent — Decided change in becoming healthier
"	17	All the ligatures have come away to day. P. 112. Appetite good. He is doing well. Stump looks inclined to heal.
"	18	He is improving. Takes his food well. Discharge less & more healthy. P. falling fairly
"	19	Sitting up in bed. All the ligatures have come away. He is gaining strength
"	20	All sutures removed. He is sitting up. Takes his food well

Month	Date	Particulars of Case
		Amputation of Arm
August	21	Stump nearly healed. He is doing remarkably well and rapidly regaining his strength. It will have some trouble in —
"	22	He is getting on fast. Stump healing rapidly.
"	23	Spend semi with a very rapid pulse 148 this morning. He had a slumber yesterday afternoon. Shooting pains in the arm & fingers. Over the stump the stump has nearly healed except two small sinuses. Pus which thus is a prejudicial. Upon these masses a bit of lime separating. But all medicine except Sulphuric Quiet & Beef tea
"	25	He has had fever yesterday & he is reduced again by it. Discharge thin P. 120. He is taking pt. Quinine day & morn. & the fever soon left to day. The discharge is rather acting in elbow. Fomentation pulse. Probe passed into sinus close not touch bone. He looks exhausted & faint & emaciated. His constitution is manifestly exhausted. But his heart is miserably & we hope it may be nothing more than fear

No. 30 Continued CASE BOOK. page 97

Month	Date	Particulars of Case
		Abscess in lung & Pneumonia.
Aug	11	Had a better night. no pain in chest. a dyspnoea. pulse 100 – 104 expectoration free. beginning to look some purulent (Concorded) – Cont: Mixture. Stethoscope Chest with the stethoscope He looks weak and pulled down.
"	12	Pulse 98. Breathing easy, Bronchial sounds continue. Expect: moderate Let him take some Quinine
"	13	Better, expectoration free, breath sounds more natural
"	14	P 100 – In Bronchial tube. expect: more concorded – He is doing well
"	16	In Dale. slight dullness left upper chest – Breath sounds natural. Cough less. expectoration still slimy Str: partly mucopurulent – He had a mixture pulling in ach – relieved some to dullness of chest left yesterday. Sweat at times – P 100 – He is to get out for a drive. Bracae fixed here Cat: for last night – his mixture had been w/ iodide.
"	17	He went out for a drive yesterday. slept well: feels better – pulse 92 –
"	18	Respiration almost natural. P – 92. Less expectoration – In all respects improving

Month	Date	Particulars of Case
		Abscess in leg & pneumonia
Aug.	19	To day in a short paroxysm of coughing he expectorate of some blood. a small quantity with the sputum. He had felt some lightness of the chest he said and a slight pain in left side near site of former pneumonia. The expectoration for the last few days has had a tint of pleurisy to it. Exam: chest: again. Respiration generally remarkable for its rapidity. perhaps slightly dull over old pneumonic patch. Respiration in lateral & mamm. region corresponding to the pain, no crepitation or bronchial inspiration as the inflammation is not commencing. Leg nearly healed, a small sinus leading to the bone: and of which on pressure a small quantity serious matter issues — Injected Cod liver oil & Iodine.
"	20	Slight trace again of blood in the sputum in pain occasional tightness. p. 100. He looks much reduced. Mentioned to him the possibility of tubercle lighted into mid chest. recommended Cod liver oil & change from to Bandwoman for a few days. The Bandwoman is strong and he

Month	Date	Particulars of Case
		Abscess in left Pneumonia.
Aug.	20	Cont. from Page. as he has been on board from the swamps, since, & said he is to move to Barracks.
"	21	Had much expectoration & cough this morning. Not much blood. Pulse weak and exhausted. Sordes commenced in chest today & it is of the opinion there is nothing beyond a mere congestion of the Bronchial tubes. and that there is slight dulness by percussion & wandering sounds. The patch is one the Pneumonia was he does not think there is more in the symptoms than the Bronchitis may account for. He complained some expectoration and a little dyspnoea. Pulse 88 & feble.
"	22	He has had some cough & more difficulty of Communication. Speac: & feble. Diarrhoea prevented for some. He says he feels better. Chest less contracted. Expectoration is free & mucopurulent.
"	23	Much the same. P-100. Deterioration more concerted. Lep flying.
"	25	Better. but he still expectorates freely. Pulse between 90 & 100. In pain in chest. In more blood. I should note the wound in the leg has happily closed. In 8 or 10 days. Intermittent

Month	Date	Particulars of Case Abscess in leg and Pneumonia
Aug	26	He appears better. Pulse only 80. Cough & expectoration less.
"	28	He is improving daily. Cough less. Expectoration less. Injury thoroughly healed. Chest sounds nearly natural. Slight Bronchial rales
Sept	1	Much better. He leaves the French steamer "Seymantha" for Sille on 3rd. He is able to walk and write now
"	3	Sailed for Sille this morning
"	19	Returned. Called at my house 4 days and not see him.
"	21	I saw him today. He appears to have quite recovered his health. He says he carefully shifted the cotton bag in steamer which has been hung up. Little cough but he looks well. I fear pain from no trouble. He is going to Guyane shd in a few days.
Oct	2	I hear that his leg again became painful after immersion. He has stopped at Rhapelpme. He demanded price of hire. I hear is working winding opium. Seem behind in the rapid healing
Oct	22	Called and recommended his leg

Month	Date	Particulars of Case.
		Perineal Section for Stricture.
Aug:	13	A Hindoo named Dwarkanath Chuckerbutty aged about 30, from Pubna, was admitted on the 5th August 1863. with stricture of 2 ~~days~~ years duration. the result of Gonorrhoea. He is a tall athletic man. healthy in appearance. The stricture situated in the bulbous portion. very tight. No 1 at first passed with difficulty. gradually increased in a day or two to No 8 - but always filled by fever and contracting the stricture immediately afterwards. On the 10th the stricture was divided and the operation was attended by a good deal of haemorrage which was stopped by perchloride - The stricture was hard and fully 3/4 of an inch in length.
"	12	Doing well. no bleeding, no fever. Did not take out the tube for fear of disturbing the last remaining haemorrage. —
"	13	Took out the tube, no bleeding. P. 120 weak. lotus pace
"	14	Doing well. no fever. Took away the last arterial ligature.
"	16	Passed No 8 yesterday & today without difficulty. Urine quite healthy.

Month	Date	Particulars of Case
		Perineal Section for stricture
August	18	Improving. passed No 9. urine clear. continue injection of Aqua Nat. p 1 to ℥i – Pulse still quick & rather feeble. Impaction in lower
"	19	Doing well.
"	25	He had a slight haemorrhage again last night & had had fever every day, he is taking Quinine. Pel. wound does not look very well & he is rather low – p. quick ner. 100 – Dimin. f. v. ℥ss & hum. P. 10. 2 m
	27	He had more haemorrhage the day before yesterday accompanied with some difficulty – He is doing well again. P. 84 – feeble – R: Ferri Perchl. ℥iss – to be taken with Quinine. He has Beef Tea ℥iv & Eggs bone
	30	Improving, no more haemorrhage.
Sept	1.	Rapidly improving
"	6	Improving perineal wound closing rapidly
"	10	Improving greatly – urine still deposits phosphates even on his thighs – Ext: Buchu & acid Mur. & the urine flows almost entirely by nat. passage
"	15	He is nearly well. wound almost closed. Large nat. passage easily – General health excellent

Month	Date	Particulars of Case
		Perineal Section for Stricture.
Aug:	17	The wound seems inclined to close. He has a full sized bougie passed daily.
"	18	The wound looks healthy where the sinus was divided. The perineal wound is slowly contracting
"	21	Both wounds closing. He denies that his urine now passes by the sinus.
"	25	Wound closing. But he had been yesterday. The weather is very unhealthy. He is taking Quinine
"	29	Improving slowly
Sept	1	do — but urine passes by the sinus again
"	6	Much the same, wound & sinus appear to be closing slowly — but much more pus than lately
"	10	The wound slowly closing, but urine still passes by the sinus —
"	15	Very little urine passes ~~through the perineal wound~~ sinus, the perineal wound is slowly closing — He has a full sized bougie passed occasionally —
"	19	Closing slowly —
"	22.	The sinus appears to have closed. Perineal wound is closing.
"	25.	Making progress slowly. Urine still appears but: Pass full sized bougie
"	29	Much the same

Month	Date	Particulars of Case
		Perineal section for Stricture & Sinus
Oct	4	A hardness in front of the wound, which is very slowly closing – No 10 passed daily. Sinus appears to have closed for the present
	8	Much the same – wound closing very slowly –
	"	9 Left urine a small catheter passed in front of the wound.
	10	Doing well
	15	Washed fever day. Taken Quinine. Wound looks healthy –
	17	Better in all respects
	21	The wound is closing very slowly. but the sinus appears to have healed completely
	25	He is suffering some pain from a hydrocele cause of cord injected 2 days ago –
	31	The hydrocele is being absorbed. but there is much thickening of testicle & tunica vaginalis – The wound is contracting
Nov	3	Very well. Perineal wound healing
	7	Has had the testicle strapped to reduce swelling – P. wound slowly healing large sinus passed daily
	9.	Strapping off. Testicle smaller. – wound healing slowly –
	16	Slowly improving.
	24	Slowly improving wound still open. It looks healthy
	25	Left urine near a catheter in the bladder
Dec	12	Wound still inclined. but contracting

Nov 2nd the catheter introduced by his own accord wound not permanent. Nov 4th Chlor. ⅓ ~~Sat~~ Month by the urine passing by the wound

No 15 Continued from Book 100

CASE BOOK.

Month	Date	Particulars of Case
		Cancer of Tongue
Aug	14	She had a sharp fit of pain again last night - and then moaning and what the friends described as another struggle - paroxysm. Slowly - heat - languating - intermittent. I saw her at Noon. She said she felt weak & exhausted by the fever. but that her mouth felt better since night. & that all pain & swelling in the gland had gone - At 10 Pm I was sent for and found her comatose. Cheeks right side sinking. Left side apparently paralysed - perfect unconscious - They said it came on suddenly with a few convulsive struggles about 1 pm when she laughed. P. 84 & feeble - breathing stertorous pulling legs feet drafty heels. Given a of Pt: Rini. Dulcamara. Brandy - by 4 hours - She continued in the same state. pr stertor, perfect unconscious, throughout the day - in the morning at 5 Pm I noticed Sec in the head
"	15	She never became conscious. Died at 6 h about 6 h am.
		Was this really the result of pain? Was it a vessel giving way - or was it softening. or abscess. the result of embolism?

Month	Date	Particulars of Case
		Amputation of the arm —
August	26	Rather better to-day but pulse still 128. He is taking Dr. Ferrier's mixt. & 2 min. of tinct. Ferr. perchl. & food freely.
	29	Still feverish, discharge thin. P. 120. but he is better than he was. I find that the bone is denuded. a piece about to separate perhaps.
"	30	Skin hot & sallow. Pulse 120. Free discharge from about the bone which is in part denuded.
Sept	1.	Pulse quick. 130. Skin sallow. Has been leaning to the bone which the probe enters some inch and proceeds a good way into the Medullary cavity. I fear he is becoming constitutionally tainted. He had Dr. Mitchell this morning. Plenty of food and Perchloride.
"	2	He is worse this morning. has had some shivering fits & fever. Pulse one 130. Skin sallow & hot. Several ounces of thin pus ran from the stump in the stump — Put him under chl: & cleared out the anterior part of the stump, find the bone denuded & rough near the end. & the Medullary canal broken down & filled with pus. passed a probe nearly to the head in the broken down tissue. — On the surface

Month	Date	Particulars of Case
		Perineal Section for Stricture.
Aug	17	Jansen. A Dane, aged 38 years cook & steward admitted in the Aug: with stricture of 7 years standing. He is not a very strong looking man but has no other disease. He had it more than 7 years & then had pus passed some time ago when in California. Lately he has pain in the right side & has frequent desire to micturate. I could feel no pus. Sounded No 1 – It did not feel suspicious but bubbles pus. I tried it twice and met under chloroform & then described as I said & felt it was not a case curable by dilatation. I with great difficulty passed No 1 of the Bowman Staff and on the 17th August at 2 P.M. I cut upon it. The stricture extended further back than usual and the staff being in the bladder before the whole of the posterior part was divided. I could very feebly feel the curved tube at first with the bladder with great difficulty. I cauterized the Bowman staff and dividing it.

Month	Date	Particulars of Case
		Perineal Section for Stricture
Aug	17	further back. as I seemed to see well into the Prostate. Further I withdrew the bulb & passed with ease the tube into the bladder. There was slight arterial hæmorrhage but it was easily controlled. It is worthy of remark that in cutting into the healthy perineum it is very difficult to keep exactly to the middle line, as the bulb and the muscular coming down and roll under the knife - It is also well to remember that you should be sure you have reached all the stricture before you withdraw the bulb otherwise you may drop the bladder with the tube and the stricture remain in part undivided -
"	18	Slept well. no fever. no hæmorrhage fair much relaxed. no difficulty at micturition. urine passes freely by the tube.
"	19	No fever. took out the tube. a little bleeding. Catheter not passed beyond incision
"	20	Doing very well. no pain. no hæmorrhage. no fever. Passed an iron into the bladder No 9 - and left it so as to mould or remove the passage.

Month	Date	Particulars of Case
		Perineal Section for Stricture.
"	21	Doing remarkably well, not an unfavorable symptom. Passed No 4 with ease into his bladder - left it there by his own request as he felt a little uneasy by the urine passing over the wound. Sunday after the tube was taken out - at 2 PM.
"	22	Doing well. passed the Instrument this morning
"	23	Doing well.
"	25	Urine passes through the wound. He is not looking very well. The weather is very unhealthy & all are more or less suffering from
"	26	Passed the Catheter. He is doing well, but slowly -
"	29	Doing well. passed the Catheter.
"	30	Doing very well.
Sept	1	Passed Inst: wound closing
"	3	No urine passing by the wound today he is getting on well
"	6	He makes a good stream & the wound is closing: all the urine passes by the urethra, but there is difficulty & pain in passing it into the bladder. The canal seems between his perineal health is good
"	10	Much as before - a good stream but great difficulty in passing an Instrument

Month	Date	Particulars of Case
		Perineal Section for Stricture
Sept	15.	The urine flows in a full stream. The wound is healing and his health good. but he still very difficult to pass an instrument.
"	19	Nearly well
"	22	Wound closed. He suffers now he says in passing urine. – But the stream small.
"	26	Stame passed No 4 – 5 – 6 during the last 2 days. He is passed himself
"	27	Had an attack of pain yesterday and then some Dennine
	28	Slight pain today – In bed.
	29	Still feverish & yellow. Salines
Oct	3	He is still yellow & feverish. In pain. but he is not interfering P.W.3. Mr Boyton & Lb. He has had shivering day before yesterday. but no sol in signs of any internal mischief.
"	4	Pulse 108. yellow. feverish. no pain. examination natural – Continue wine & food – Pelle dual & opt. in chest & abdomen
"	5.	Much in the same state. Voice hoarse & depressed. Urine as the urine coming from the vault of the Cranium. – Continue Potassium
	6th	Beef tea – Retching & vomiting yellow: wandering and a urinous smell from the body
"	7	He is worse today. Left the urine passed. Friends & papers mentioned penitentiaries –

Month	Date	Particulars of Case
		Removal of Breast.
August	24	1880 a Hindoo woman whose case is detailed at page 42. was readmitted on the 10th of August. with the left breast much enlarged. two or three sinuses with dark sanious discharge passing through them, a bunch of enlarged and hardened glands in the axilla. & suffering a good deal of pain, the tumor had begun to enlarge soon after she left Bombay the breast is hard and heavy. but not so hard as scirrhous. There are two or three prominent looking livid pustules like blisters in the line of the old cicatrix. This morning I secured the entire breast by horse ligatures. and dissected out two large glands in the axilla. one of which burst under my finger and free vent to some dark blood & medullary looking matter. The breast was not adherent and the fat around it seemed healthy. on making an incision (the nipple was not retracted) it consisted of dense fibrous & glandular structure and cysts. or compartments as it were, filled with gummy medullary looking matter - under the microscope. this  appearance

Month	Date	Particulars of Case
		Removal of breast
August	24	There was a good deal of haemorrhage and many vessels were tied. Leading to the glands are large arterial trunks which had before been cut. The incision was prolonged deep into the axilla and the surface left exposed for further dissection
"	25	Doing well, slightly feverish. No bleeding. Solution. Change the chest bandage
"	26	No fever. Least part of the wound appears to be healing by first intention.
"	29	Suppuration at the free. Healthy looking. No fever.
"	30	Doing well. Discharge free.
Sept	1	Wound healing. Suppuration free
"	3	Wound gradually contracting, all the sutures removed. Strips of sticking plaster applied
	6	She is cicatrizing rapidly. Her general health is better
"	10	The wound is cicatrizing rapidly and her health and strength are improving. She has no sign as yet of any return of the disease.
	15	Wound nearly cicatrized
"	19	Nearly well. Says she has been for the last few days about the shoulder
"	22	A hard swelling forming rapidly increasing about the cicatrix near the shoulder

Month	Date	Particulars of Case
		Scrotal Tumour
Aug	25	This morning I removed a small but very rapidly growing Scrotal tumour from a man named Mooheram Biswas aged 40 years. He has had it only ~~years~~ one month ~~nearly~~ but has had repeated recurrences of pain and a few days ago one of these terminated in an abscess which was opened & had now healed. He was admitted on the 7th August. Not having had pain for some days, I operated. The bleeding arterial and venous was considerable and the ligatures were rapidly applied. He lost at least 2 lbs of blood before the 20th and last ligature had been applied. On the right scrotum covering the left testis were several large venous sinuses, some as large as a crow quill. They were all tied, but poured a pint of blood before they were secured. He was very low when taken off the table and required considerable stimulation with Brandy, warm bottles & injections of milk & brandy. The tumour weighed 9 lbs. — I observed in this, what I have often noticed that the small tumours were very vascular. — 24 ligatures were used

Month	Date	Particulars of Case
		Scalp Tumour
August	26	He was very low after the operation and had cramps of the legs. He is better this morning and slightly feverish. Saline
"	29	He is doing pretty well. has been feverish & low. had taken food pretty well. Dress the wound
"	30	Smooth & weak. Slight haemorrhage
Sept	1	Doing well. but still weak. Maggots in the wound. Dress with Turpentine
"	3	No fever wound looks healthy. Maggots all removed
"	6	Smooth. Pulse rapid. weak. Tumour looks pretty well but inactive. He is taking Quinine & Stimulants when notwithstanding Smooth —
"	10	He has been very low. & has fever at intervals. He is taking Quinine & Stimulants with Beef tea Eggs & Chicken. Wound is inactive
	15	He remains in a low state. he has left diarrhoea & fever. but he is quite making much progress. he is taking Quin. & Iron
"	17	Contents weak. & tendency to Diarrhoea
	22	Still low. but the wound is looking healthy. He takes plenty of stimulants & Beef tea
"	25	He is improving very in all respects. He takes a quantity of stimulants & food

Month	Date	Particulars of Case
		Dislocation of Hip.
Aug	26	This morning I said at the Chandway Hospital with Dr. Baillie a Native of Jabur 35 years of age, thin spare with very healthy looking who two or three days before had been knocked down in the street, when he was carrying a load and was brought to the Hospital with a dislocation of the femur. Examination was made, the bone slipped into the proper position. But this manipulation placed it on the dorsum ilii and when attempts were made to reduce it – it slipped in pulling again. He had by the time lying near the entrance of the Dispensary. I said him on the third day he was lying with his green head & the left knee shorter than the right – Dr. B. put him under Chl. and the pulleys & counter extension were applied. The bone slipped at first in front – then behind and finally with an audible snap into the acetabulum – He was then put in the long splint. and laid in a wooden cot. Dr. B. informed me that this was the second case of dislocation into the pubes he has had recently —

In this case I was struck by the great mobility of head of bone and also of the limb when bone was displaced. It could be abducted & adducted much more than is usually and it could be pulled in such a manner

Month	Date	Particulars of Case
		Amputation of arm - Necrosis of head of bone
Sept	2	some thickened fungiform adhering. On passing my finger up towards the head of the bone I found that there was another abscess corresponding to another part of the denuded bone. I slashed the bone with the saw forceps and dissected it out. Then connecting the amp: into one at the shoulder joint. I and heavy have tied including arm which had become cavalicine, in consequence of the infiltrated tissues: there was no artery of importance but the vein contained much blood. On making a section of the bone I found that the whole cancellated structure was infiltrated with pus. & most horribly fetid — another example of the danger of cutting through a bone as compared with disarticulating or removing clinical experience in future amputations.
		A section of the bone was sent to the Museum to be preserved and a drawing to be made, as illustrating the constitution of Otter morphologically beautifully

Month	Date	Particulars of Case
		Strangulated Hernia.
Aug	28	This afternoon after my lecture, I saw a very interesting case of Hernia. It was on the right side of a 22 year Standing. has been down before & returned in Hospital - Has never worn a truss. - It came down last this morning and symptoms of strangulation came on rapidly. Sharp umbilical pain. Vomiting acid eructation & hiccup. Redness & tenderness at the neck of the sac - The Hernial tumour as large as an Infant's head. Taxis failed under Chloroform. Bearing taxis and the symptoms rapidly increasing. The Chloroform & water, ice, & every fluid I prescribed - The stricture was at the external ring - which I slit up. The hernial sac was tense & a small puncture was accidentally made out of which a few ounces of serum escaped. & a small piece of omentum protruded & found that it was impossible to reduce the protrusion. Chunks of omentum and after as much manipulation as was safe, I sewed the edges of the wound partially together

Name Chotoor Bhooj
age 35 to 38
Caste

Month	Date	Particulars of Case
		Strangulated Hernia
Aug	29	with two wires, and a deep hernial canal closed with ice, in the hope that, the stricture being removed, the hernia would go back. warm fomentation & opium.
	29.	This morning I found all the symptoms of strangulation have gone. they disappeared immediately after the operation. But the hernia still lies in the scrotum, & the small piece of omentum has gangrenous escaped from the fundus in the sac. lies lying in the wound with my little trocar & returned it all within the abdomen. stitched the wound together & hopeful ice to be applied. - Pulse is 84 - He has an hour. & has had a good night.
"	30	He slept well. bowels have been freely moved. he feels exceptionally the wound.
Sept	1	Pulse min 100. & from 20 to the last. Just much pain. Let him have a warm fomentation - & ~~some~~ opium as before
	1	A good deal of pain & some suppuration about the wound. Poultice. opium.

Month	Date	Particulars of Case.
		Strangulated Hernia
Sept	3	The wound has sloughed & the sac is extruded but it looks healthy. his bowels are open. he has little or no fever & left pain –
"	6	Pulse under 90 – Impure discharge. no fever. Bowels regular. wound looking healthier. The bottom of the sac, dressed with strips of muslin & cold water ment.
		Instructed his diet, he asks for meat.
"	7	Had a little fever yesterday.
"	10	The wound is radically but slowly healing by granulation — Increase his diet & let him have his accustomed quantity of wine about 4 to 6 ounces a day –
"	15	Wound healing. he has no bad symptoms & does very well in all respects.
"	19	Wound nearly healed. I find that he is a great spirit drinker he consumes from 1 pint to 1 quart of rum a day. He has had 3 oz ℥vi – daily – I have diminished it to ℥iv –
"	22	A small patch still unhealed –
"	27	He is all but well & wants to go out.
"	28	Operated on Radical Cure of Hernia with the plug needle & 2 threads
Oct	2	Took out the plug yesterday. Discharge impure, but no pain. Stool well (involuntary)

Month	Date	Particulars of Case Perineal Section for stricture.
Sept.	19	He is doing very well. The wound has nearly closed - but there is a small fistula still left which looks like a sinus in potato from the curved edges. Passed a large bougie frequently — He has quite regained his strength and spirits
"	22	Very well. Small sinus with aphthi. Passed full sized bougie
"	26	Sinus closing. He is nearly well
	29	He had fever yesterday owing to the passage of a large bougie but the day before which seemed passed very easily.
	30	No fever to-day
Oct	2	Still feverish. Sallow. In pain in the perineum. Passes his urine freely - ~~Had a very fit yesterday. He does not look quite satisfactory - Pot. Nitrate Bapta. & Tetrac. & Ammonia Carbonate.~~
"	3	~~Pulse 120. Skin sallow. Countenance anxious - he has no pain. but he looks very unsatisfactory - Continue Bapta and Pot. Nitrate -~~
	3	He is doing well
	5	No 10 passed easily. but there is still a sinus
	8.	Gradually closing. The large bougie passed occasionally
	15	Still a small sinus. He says he is well but feels weak. Some urine issues.

Month	Date	Particulars of Case
		Amputation of Arm. Secondary hemorrhage
Sept.	3	Pulse 120. Countenance left sallow. Discharge pus and thicker than yesterday but still far from healthy. He has diarrhoea and is taking astringents. p. s.
"	6	He is not doing well. has had repeated rigors followed by fever. The same rapid pulse. Increased respiration with tightness across the chest. Sallow skin. Chest well. Internally with coarse crepitation at times. Dullness on percussion. Breathing harsh. but not otherwise abnormal. My impression is that pyaemia is setting in. The liver is not tender. Continue food and stimulants. Stump looks well enough, pus withered & the discharge from it thicker & not so profuse.
"	7	Much as yesterday. has had several shivering fits since in the interim.
"	10	He has been very low setting worse and worse. Shivering. Sweats. A thin purulent odour from the body. The rigors perfectly natural. Pulse 120 to 140 - very soft. He gradually sinks. The sallow tint quickly towards the last and died last night at 11 o'clock.

Month	Date	Particulars of Case
		Post Mortem of this Case –
Sept	10	Pill. at 9 A.M. of 10th Sept – by Dr Crouch & myself – Both pleurae contained dark serum in excess – the right considerably inflamed & bakers of bellows & plastic lymph. Lower lobe of the lower right-lobe – Lung congested & mottled in the upper & posterior portions – in parts consolidated in small patches. Both lungs especially posteriorly contained many circumscribed patches from a pea of wheat to a bean in size – of softened matter looking like broken down lung tissue. In them – a hardened purulent matter with deep red & congested lung tissue around them – some of them in the breaking down & softened – The lungs otherwise most healthy. Heart healthy. Pericardium contained much fluid –
		Liver pale & mottled with what Dr Owen thought incipient cirrhosis of a plastic lymph – perhaps amyloid – contain nothing like that of the lung kidneys & the viscera healthy. A large collection of pus near the right knee about seat of an old fracture where there was a permanent plate of bone. I had never attended attention during life

Month	Date	Particulars of Case
		Cut throat.
August	28	A female aged 24 named Sibo. native of Calcutta. of loose and intemperate habits admitted this morning at 6 a.m. with a transverse irregular wound of the front of the throat which had divided the windpipe in the Crico Thyroid space by a jagged irregular wound. She was almost pulseless from loss of blood and fright: no large vessel had bleeding. Some probably divided and the bleeding arrested by pressure. She was wounded about 4 a.m. by a man (paramour) who she says cut her from behind. The wound had been stitched when I saw her at 8 a.m. reaction was setting in. The wound was irregular a flap of skin turning in in a valvular form into the wound and also a band of loose tissue flapping in and into the wound at each inspiration. I therefore introduced a tracheotomy tube and directed her to be closely watched. She was in imminent danger of suffocation. She continued very restless for some time. Tossing & rolling about. Ordered Beef Tea 3 iv every hour.
	30th	Improved. but healthy cases. as the hospital became crowded with typhus

Month	Date	Particulars of Case
		Cut Throat
		tubes were taken out.
	31	Breathing easily by the wound & nose & mouth - pulse & Bronchial tubes in the chest. Wound a dense Cough mixture & formulation to train
Sept	3.	wound in healthy & healthy pulp but she has considerable Bronchitis Cut: Throat: Laryngitis & Bronchitis.
"	6	She is better pulse pretty fair about 90. less Cough. The breathing partly by the wound. partly mouth & nostrils. wound is very puffed & irregular. She lying & sleeping most healthy & in contact —
"	10	She is doing well. Bronchitis better wound looks pale but is healing contracting rapidly. She still takes Cough mixture —
"	15	The wound is rapidly closing, but the skin is a good deal puckered in. She has left cough & is recovering her strength. She is taking 2: Tonic & Extract
"	19	She is doing well. wound contracting. She breathes through nose & mouth.
"	22	Still a fistulous opening but she is well in health.
"	25	Has got some cough. wound nearly healed left Hospital Well

CASE BOOK.

No 87 Continued from Page 123

Month	Date	Particulars of Case
		Removal of Breast
Sept	19.	There is no doubt a return of the disease and it appears the increasing swelling under the skin is so — The wound slowly looks as well, the surface seems healed — She also looks better altogether and has gained strength & flesh. But there is doubt. She will soon be in a very apparent condition —
"	20	The wound has nearly healed, but the swelling alone is still continuing. She is a little less painful to touch but there is no material change
"	27	The wound has quite healed, but signs of the disease are appearing in the cicatrix & the swelling increasing —
"	28	She is attending in the cicatrix in front —
"	30	The swelling is rapidly increasing
Oct	2	The disease is extending
"	4	Steadily extending —
"	8	Has a good deal of pain. Swelling increasing but not so rapidly as at first —
"	10	Much the same
"	21	The Cancer has formed in not a few places in the cicatrix — one in the skin but the rest not progressing very rapidly. Has less pain — Taken Quinine & Iron

Month	Date	Particulars of Case
		Perineal Section for Stricture.
Septr.	11.	Mongoly aged 35 years, native of Aden, admitted 11th Septr. 63 – a thin sickly looking man, about 2 years ago he had Gonorrhoea which lasted for 3 or 4 months and was afterwards cured by some native treatment – He had fair health since that period according to his own statement until about a fortnight ago when he experienced difficulty in micturition with pain. This gradually increased becoming more intense and was accompanied by fever. During the last 3 or 4 days. He says he passed his urine all this time in a full & natural stream but this is doubtful. He has not had any obstruction of retention – About this period he began to feel pain on pressure in the perineum, and after 2 days a decided swelling made its appearance The pain & constitutional disturbance continued & finally brought him to the hospital with a fluctuating swelling in the perineum. An instrument was passed down to a well marked tight stricture just in front of the bulb – The only fluid that could be felt in the bladder was one of the pressed staff in some case.

Month	Date	Particulars of Case
		Perineal section for stricture.
Sept.	11	In this the perineal abscess has been laid open so much of the urine was thus prevented. I dilated the stricture and introduced the curved tube into the bladder. The stricture was thick & hardly admitted to pass tube into the membranous portion. He had diarrhoea at the time & seemed extremely prostrated after the operation. Dysentric symptoms well marked supervened, and depressed him much during the first few days. After he was healthy relieved by the operation he left this. — Sheen —
"	17	He is much better. Stools healthy, appetite good. Urine passes better by wound and urethra. The wound is very healthy. Tube was retained in the bladder for 48 hours.
"	19	Bowels still loose, but he is improving. Cont: Mix Ipecac: ℞ 1 ter die — Pap No 8 Rub — No pain. No pain. The wound looks very healthy.
"	22.	Better but he still has diarrhoea & tendency to dysentery — Cont: Medicine. Urine passes both ways. Large but healed clean

No. 41

CASE BOOK.

Month	Date	Particulars of Case
		Perineal Section for Stricture & abscess —
Sept	26	The dysenteric symptoms continue. Motions frequent with much straining. He is a good deal reduced. Sloughs separating. Small bits detached in [illegible] portions. The wound is looking well. Rx Pulv Doveri gr x. Bismuth gr x every 4 hours. Injection of starch enema. Opii [illegible] Brandy ℥i [illegible] Ammonia & Chalk mixture & Brandy [illegible]
	27	He is very low with hiccough & passing sloughs — but the wound looks well. Continue the Dover's powder Bismuth Enema food & stimulants
	28	Has had several stools and passed one or two large sloughs — Continue the treatment — Stimulants to increase every 2 hours. ~~He is~~ Dover's powder & Bismuth [illegible] by means of [illegible] Injection [illegible] every 6 hours (Hiccup wound all the time looks well
	29	Very low. Stools contain three or four sloughs Continue — Hiccup continues,
	30	Passed two more large sloughs. Hiccup Pulse feeble — Continue Stimulants
Octr	2	Very low still passing sloughs & hiccup. Continue all

Month	Date	Particulars of Case
		wound united with horse hair
Sept	19	An English Sailor named admitted Saturday drunk - with a wound over left knee - cutting deep into the bone - It was much swollen & exquisitely painful. Leg was kept quiet & water adhesive - Hour & test - It - I united it with three sutures of horse hair: It healed more pleasant than usual & will be removed some days when no longer required -
		I have also in the Pathological Soc. Mus. the eyelids together with horse hair after extraction of cataract
"	22	Wound healed united. Slight suppuration at the corners
"	26	Sutures removed two days ago. Wound healed beautifully. Inserted left the sutures
"	27	Wound has healed —
		I have seen [illegible] some cases like mine after cataract with the horse hair & [illegible] adhesive strips - Also written [illegible] the [illegible] in which attention is called. & the seam kept in very small
Oct	3	I have tried many other cases and then succeeded well in all —

No 40 continued from page 135

CASE BOOK.

Month	Date	Particulars of Case
		Cut Throat
Sept	27	Bronchotomy better. wound contracted to a small fistulous opening
	28	Has considerable difficulty of breathing the wound is nearly closed. when tube is left out for a time closing altogether
"	29	A sudden fit of dyspnoea threatens asphyxia yesterday. tube reintroduced through the wound. She is better this morning but has some vomiting
	30	Breathing easily through the tube, but there is still some cough & difficult cough sometimes
Oct	2	She is better. breathing easily through the tube. cough less
"	3	Try her without the tube to day. but had in the watch last time she dyspnoea
	5	Still wears the tube. It has been taken out but she soon felt difficulty of breathing & it has to be returned
	6	Look at the tube again to day
	7	Obliged to return the tube yesterday
	8	Look at and again to day
	10	Tube obliged to be reintroduced as before
	13	Introduce from a larger tube. Try to do away with it by degrees
	15	Getting accustomed to small tube
	17	Does well
	21	A smaller tube introduced yesterday

Month	Date	Particulars of Case
		Wound from Deer horn.
Sept	22	Last night the Prince Azeem and Deen was walking in Indian shrubbery & was suddenly attacked by a fat deer, Chinkara Cervus Axis, from behind - his back was sharply scratched in several places and just behind the first: fold of the left axilla the point of one horn had punctured and caused a puncture bruised wound of an inch & a half in depth. The attendants say he lost a good deal of blood. The Prince is a tall powerful man. he turned on seeing the animal & the horns held and struggled with it till his servants came to the rescue. his arms were bruised by the deer's horns in the struggle & by the violence of the muscular efforts. — Washed the wound and dressed a poultice thereon applied - gave him a solution of Morphia as he has been having sleepless nights lately & an aperient draught in the morning. The Prince is a powerful tall man, of about 48 years of age. He is by far the most powerful man I have seen of the Royal family.
"	25	Dampness & wound looks well. Injection & Poultice. Not supporting well

Month	Date	Particulars of Case
		Wound from Deer horn
Sept	27	Slight inflammation convalescency he is doing very well
	29	He is very well Dressed to injured Hand
Oct	2	His hand has nearly healed. he came to see me yesterday.
	3	Sine in the case for change of air. Discharged Cured on 2d Nov Convalescent

Month	Date	Particulars of Case
		Fracture of Acromion & Crack by Cancer
Sept	27	On A Hindoo nameed Cafoy Ram aged 18 admitted on 21st Sept with symptoms of injury to the shoulder joint right side He had been jumping a ditch and while holding on to a bamboo he fell his shoulder a violent wrench. On the 19th Sept. a snap something gave way. Ever following intense pain inability to use the limb and real swelling of the shoulder — I found on admission that the shoulder is much swollen. No fracture of the clavicle. Cutting the joint forward, the elbow perhaps slightly lower than that of the other side — He could with great pain, swing the arm backwards & forwards but could not lift it sideways — The pain was excessively intense. He fainted under it — On compressing the head of the bone with one hand and rotating the elbow & keeping it up with the other certain crepitus could be felt & heard with the stethoscope. The pain was very intense —
		Ward treatment & bandage with pad in the axilla —
	29	Has no pain.
Oct	2	Has no pain. Arm still bound up
"	8	No pain. Discharged to attend as an out patient

Month	Date	Particulars of Case
		Perineal Section – Continued from page 121
Oct	8	He died last night –
After 6th		Post. Simply fully lobular Pneumonia
Patient a		old adhesions. Acid in upper part of left
Cotton tube		lung a calcareous concretion by age but
& bottom any		Patches of dead lung in the lobular
wind had		portion of inflammation & congestion.
been secured		Other lungs – pale & portions – there
as the nasal		in abscess – a deposit.
symptoms		Spleen contained many patches similar
not well		nature in the lungs –
marked. he		Both kidneys especially right full
had passed		of abscess & patches like those in the
pus from the		lungs –
urinary		Bladder & urethra healthy – Prostate
tract – a		inflamed. Small. Patches of deep
little blood		congestion – & between and apart on
followed the		abscess – Ducts dilated like false
tube when the		passages leading from the urethra
bottom was		portion towards prostate – These I
high coloured		had observed subsequently to the
urine, which		operation when passing instruments –
was healthy		which were sufficient in consequence
in reaction.		of partly the urethra, Bulb, thus
		the incision had been worn natural
		& distinct surface only indicated.
		Where the structure had been divided
		the urethra in fact looked perfectly
		healthy & natural there –
		The bladder contained brine blood

Continued from page 125

Month	Date	Particulars of Case
		Scrotal Hernia Continued from page 125
Sept	27	He is very low, but not otherwise worse. Continue stimulants & dressing as usual
	29	Much the same
	30	very low. Continue stimulants &c
Oct	2	very low & prostrate. bowels depressed – Continue stimulants & food &c
	4	Still in much the same condition
	5	The Testicles are much contracted & the wound looks healthy. the cutting pale. He is very slowly improving in general health.
"	8	Continues in the same state. his pulse tripid. respiration good. is cheerful & speaks. he declares himself fair – pulse very feeble – surface of the body pale. but not unhealthy –
	11	Still the same. respiration good. died 2 days ago. very low a point by the bowels the inspected.
	13	Rather more feeble. respiration good. he is in a sullen state of speaking wound is contracting. looks pale but not unhealthy –
	15	Much the same
	28	Lies in the same tripid state has injection of Beef tea 3 times a day. takes some food.
Nov	1	Discharged at his own request. he looks both mind & bodily & nearly healed

Month	Date	Particulars of Case
		Perineal Section
Oct	19	Still a small sinus. but it is closing — He says he is weak & feverish — Recommended milk to be taken per chance if his urine is bloody —
	23.	Still in Hospital in same state — sinus continuing the same state.
	25	The sinus has very nearly closed and he is better. but he wants change of air badly
	30	He is very well — much improved
Nov	6	Discharged cured No 12 passed with case & the sinus closed

Admitted August 5th
Operated " 10
Discharged cured Nov 6th

Month	Date	Particulars of Case
		Strangulated Hernia —
Sept.	25th	Arnold Bonzalli (about 65 to 70) married Gundap Byrack, admitted in the morning of the 25th with symptoms of strangulated hernia — He was an old infirm man with an enormous tumour on the right side of the abdomen about 3 times the size of the head — he could not clearly say when it descended except that he had long had a tumour there. he thought he was made with a hernia. That 24 hours before admission the hernia came down & the tumour becoming larger — he could not retain it. It became tense & painful at the neck of the tumour in the abdomen. Vomiting & retching came on & he became very weak & then came to hospital about 8 o'clock. He had warm fomentations previous to the tumour. He taken a chlorpform but the tumour could not be reduced. On examination on his position. except that there was great pain at the neck of the tumour & umbilicus — he came & vomiting. Pulse feeble. I opened the sac by a structure at the external ring & left it open on a sponge — Passed my finger into

Renously Suzuhatta Calcutta.

Month	Date	Particulars of Case
		Strangulated Hernia –
Sept	25	and stomach. I could not reduce the omentum or gut – which was partly adhesive, partly sphacelated. I added a blue pill & kept cold water ice on the part. Pain & stimulants to casualty as he was low. I hoped that as the structure of the omentum had been severed it would fall back with the body.
8 P.M.		He was semicomatose with stiff symptoms of obstruction. Continued the same treatment
7 P.M.		I found him much the same the pulse low & the constitution generally very depressed. He had vomited a little & had hiccough. There was less abdominal pain. I put him under chloroform & opened the sac, enlarging the wound downwards – The omentum & gut of intestine large & small with hardening fat & omentum adhering to the testicle & mass – & have been amputated, were opened. I found several coils of small intestine deeply congested – lying behind the scrotum which appeared

Month	Date	Particulars of Case
		Strangulated Hernia —

I have been the usual hernia with occasion. I tried to reduce it but could not succeed. and in vain, as I came upon the patch small intestine usual perforated the large. perfectly sphacelated which fell to my touch and a quantity of black sanious fluid similar to brine that he had vomited. This I left on the coming of relaxing as much as possible above it, into the abdomen cleaning the remainder in the scrotal sac — He was very much exhausted. but he lived for several hours after the operation died 8 p.m. 26th

The original hernia no doubt was the occasion of mortification which had become adherent to the testicle as the bottom of the common sac which reached to the bursa scrotal. The small intestine had passed down behind this & the one strangulated at the ulcerating ring — This I divided immediately after admission but not soon enough to relieve the congestion which terminated in sphacelus. The

Month	Date	Particulars of Case
		Strangulated Hernia —
Sept	25	Symptoms of which in said case commencing a few hours admitted. It is another instance of the necessity of operating soon — had this patient been divided 12 hours earlier it is very probable that the small intestine would have returned within the abdomen & the symptoms passed away — as it was they had been confined 2 days. Hernial sac was thick, inflamed, deep & congested and in the place probably gangrenous. There was no stricture within the sac. The common map-reader daily the small intestine, much of the large & a map of Mountain marked very sufficiently to apply the latter which is totally packed to reduce the protrusion. Even after the stricture had been divided — This old man had no marked symptoms of strangulation. He passed with a state of prospective without any of those accumulative symptoms which are called for by bowel. There was no Post Mortem. Stan

Month	Date	Particulars of Case
		Scrotal Tumour
Sept	26	An Udaly Chunder Hindoo Bengalee aet 45 resides Kally Chunder Sen Zemindar of Pattola Bazar admitted on the 25th with a small aged scrotal tumour of about 30 days growth. He had had my uncle in former days which was tapped & injected. The tumour was about the size of a Children's head. He has had the usual fever but none for 20 days. Very healthy. Operated on the 26th. The tumour was vascular, freed the end, and removed it in the usual manner. The left testicle was healthy. The sac after D.C. obliterated. The right testicle seemed as if it diseased. The tumour separating was connected with a bony sac about the size of an orange. It was found on sounding & probed with very tolerably beautiful. The testicle was flattened but apparently not much diseased. But it was carefully removed in the contentment growth that it was deemed better to remove it altogether. Which was done & the bag simply cut away. 17 ligatures in all were applied. He bore the operation well.
Oct 5th	73	Weight of the tumour was nearly lb x

Mode of Tumour compressed during the operation with Cord —

No. 46

CASE BOOK.

Month	Date	Particulars of Case
		Scrotal Sarcoma
Sept.	29	He had a little sensation of pain yesterday but this day very well. Continue all the same treatment and keep the wound.
Oct.	2	Doing well. healthy looking.
"	4	Doing well.
"	8	Doing well
"	15	It is contracting healing rapidly
"	21	Doing well
"	31.	Contracting healthily
Nov	9	Doing well. near healed
"	27	A small patch still uncicatrized pain superficial cicatrization the cicatrix
Dec.	10	Discharged. Cured (a small spot still uncicatrized)
		Admitted Sept 25
		Operated " 28
		Discharged Dec 10.

Month	Date	Particulars of Case
		Amputation of the leg
Sept.	28	Panchkowri aged 31 years agriculturist - Mahomedan admitted 21st Sept. 1868. "About 6 months ago he had a small pimple on the anterior aspect of his left ankle joint. It inflamed, and the inflammation gradually extended downwards towards the foot. When sloughing came on with great rapidity. The foot became gangrenous, and the toes separated one by one. In about 2 months the foot separated — A corresponding extension of the disease took place upwards, and in two months more the bones part of the fibula and tibia exposed. —  separated of the soft parts the bone was fractured. The stump presents a conical shape nearly two inches in its second surface anteriorly. Internally the ulcerated parts retired higher up — The surface of the stump is brownish moist and with a very foetid brownish watery secretion. The bone of demarcation not well defined — The parts above are painful tender & inflammated. He says he has never had venereal disease. Nor was he ever salivated. Except some slight heat of skin which lasted coincidently with the inflammation

Month	Date	Particulars of Case
		Amputation of the leg
Sept	28	He had no fever prior to the attack. The patient is an inhabitant of a village where malarious fever is rife. He is emaciated, anemic, weak, appetite bad, bowels costive, sleeps badly. No enlargement of spleen or liver, no acute pain in the foot. Pulse small and frequent. Normal urine, albumen distinctly at the 8th: but in the triangle it becomes feebler than in the other. He has a dusky anemic appearance. Stump of amputation healthy, warm & prepared with the tissues about in constant tension. After rest on Friday. It was decided better to do some should wait a bruise of contusion and the leg then upon the middle thigh was amputated by modified circular on the 23rd Sept. — There was intermittent bleeding point, mere oozing. The arteries were twisted & small ones: no ligatures were needed. The soft parts were infiltrated & adhesions agglutinated together. The organs having ceased the flaps were brought together with one suture. Dressed & supported the main part. —

Month	Date	Particulars of Case
		Amputation of the leg.
Sept.	28.	He is doing quite well, pulse rather healthy, the other has sloughed a little on the inner side. He still has pain. The stump looks healthy, wound kept open and good discharge. Stimulating wine. Her tongue has gradually dry & flayed appearance but the pulse I should add be far feeble
"	29	Tongue still dry red but moist & smooth. Stump looks better. but no much discharge
"	30	Stump looks healthy. Tongue red but moist
Oct.	2	Slight tendency to slough in left side of the stump. Tongue still red. Only continue pulse feeble. Taken his food pretty well. Has an opiate at night
"	3	Tongue red & smooth but moist. Has diarrhoea. Taking chalk. Stump looks well except in one place. Dose of three with h: Bismuth.
"	4	Much as yesterday in all respects
"	5	Much the same. Part of the stump looks well. The centre part still sloughing a little. Continue all
"	8	Surface of stump is healthy, he seems like day better. Tongue still red & smooth. Has been D'rrhoea. Taken his food better.

Month	Date	Particulars of Case
		Amputation of the leg –
Oct	10	The bone is found the second at the coil. The soft parts are pretty healthy. Drains still day. tending to Diarrhoea – Continue treatment
	11	Much the same
	13	Much the same
	15	Very better. The bone has not yet separated
	17	Much the same, stiff hope continues from about the received bone – Diarrhoea better
	21	Leg continues in much the same state bone not separated yet – Diarrhoea better but Drains still played yet day –
	23	It looks well but the bones are still connected. General health is improving slightly
	26	Much the same –
	28	Much the same Drains still day played –
	30	Do Do
Nov	3	Very well but bone not yet separated
"	8	Much the same
"	10	Do
"	16	The end of tibia and fibula came away today about an inch of each.
"	17	Very well. No bleeding – tendency to Diarrhoea
"	19	The stump is contracting. Diarrhoea better
"	27	Nearly healed
Dec	12	Much healed all but a speck

Dec 29 – He may be discharged

31 Discharged Pathworker

No 45

CASE BOOK.

Month	Date	Particulars of Case
		Scrotal Tumour
Sept.	27	Bikaree, aged 30. Strong healthy young man. native of Cuttack (Bengal) Has had Scrotal Tumour for 2 years C.S. The tumor commenced & began also with swelling in the left groin. It lasted 4 days & subsided slightly. but he has been subject to frequent paroxysms of pain since. during each of which the groin & scrotum swelled considerably — He had an attack of pain about 15 days ago which lasted 4 days — At present size of the tumor is that of a child's head. The scrotal enlargement as well as the scrotum much swollen. — The tumor was removed in the usual way, neck compressed with a clamp, with the 28th at 8 p.m. Stout 12 & 15 ligatures required. It was moderately vascular. weighed 2 lbs, 3 oz.
"	30	He is doing well. no bleeding, no fever
Oct	2	He is doing well.
"	4	Doing well.
"	8	Doing well.
"	13	Doing well
"	21	Doing well. Contracting healthy
"	31	Contracting
Nov	10	Nearly healed
Nov	24	Discharged. the wound has all cicatrized. Admitted Sept 27th Operated " 28th Discharged Nov 24th

No 40 continued from page 141.

CASE BOOK.

Month	Date	Particulars of Case
		Cut throat
Oct	23	Introduced a still smaller tube, tried again without any but she could not do without it
"	26	She breathes through a tube about the size of a good quill
"	28	She breathes tolerably well through her smaller tube —
"	30	Much the same.
Nov	3	Sitting the immediate Canula without the tube
	9	Much the same. She can't bear without the tube.
	11	Much the same. Setting smaller tube made
	17	She is waiting for the smaller tubes. In all respects she is in the same state —
	26	Going the last two or 3 days. She has been going without the tube breathing through the windpipe. She cannot get breathe of the larynx —
	28	Introduced a very fine tube
	29	Couldn't mean it — obliged to return back the person are
Dec	4	Doing pretty well, but mean the tube
	12	Just the same
-	29	Still in Hospital. She has had 3 doses nitrate Dark Silver applied to larynx. But she cannot do without the tube
		She left the Hospital some after still wearing the tube —

Continued from page 130 –

Month	Date	Particulars of Case
		Strangulated Hernia. Radical Cure
Oct	3	He is doing very well. Discharge in his imagination still adhere to place —
	4	Discharge profuse. He is thus well.
	5	Doing very well. Discharge still profuse
"	8	He is nearly well. Fond him walking about. The wound healing. Canal full of granulation. Hernia at present has no tendency to descend —
"	10	The wound is nearly healed. & as yet the hernia has no tendency to return. The granulation is firm.
"	13	He is apparently quite well. Will then be fitted with a truss
	15	He is quite well —
	16	Discharged cured —

Admitted August 28
Operated S. Hernia " 28
Operated Rad Hern Sept 28
Discharged cured. Oct 16.
In Hospital 18 days. Days - 50.

Continued from page 189

Month	Date	Particulars of Case
		Perineal Section for Stricture and abscess
Oct	3	He is very low, has hiccup: passing dark thin motions with shreds of slough. Continue wine & food. Omit powder & Bismuth as hope —
"	4	Lower than yesterday. Stool passing shreds of slough — a dark stale colored thin stool. Hiccup — pulse rapid. Continue stimulant. "
"	5	He died last night — & the body was taken away by the friends without Post mortem examination — The cause of death in this case was bad Dysentery. He had the disease, it appears, when the lithotomy operation & nursing abscess took place — This carried him both well up to the very last & his wound has been indeed healthy. Death in this instance can only be attributed to anything but the slumbering Dysentery —
		Admitted Sept 11th
		Operated on " 11th
		Died Oct 4th

Month	Date	Particulars of Case
		Amputation of Thigh - (Secondary)
Sept	30	A young Native woman named Bonnie aged about 25: suspected of habitual habits and to have been accustomed to drink Spirits was admitted into Hospital on the with a broken left humerus, & arm bruised and an abrasion over the knee which was also bruised. This was the result of a fall when she was intoxicated. The injury of the knee extended to acute suppuration ensued. attended with great debility & prostration of internal. Later on symptoms of pyæmic constitutional irritation - about the [illegible] the knee became hot that the knee joint was opened and rapidly thus disorganised. The patella rubbed against the condyles, was rough & the [illegible] was more lateral [illegible] there was natural - Profuse discharge - bad smell, & pain the latter on & when the joint was opened. There was no external indication that the joint was injured - Dr Hogg after consultation with Dr Jordine - I determined to remove the limb & did it under Chloroform by modified circular at the junction of lower & mid thirds. Small arteries only needed, the femoral & one other large vein were tied. There was [illegible]

Month	Date	Particulars of Case
		Amputation of the thigh –
Oct.	11	Very weak. Bowels still loose, frequent pulse about 130 – stump looks pale & flabby. There is no sloughing. The bone is protruding & in part dead. But the muscular coat is not retracting. She is very weak & her stomach very unstable rejects, especially in the morning, her food & she requires brandy & wine administered.
"	13	Not worse. Bowels rather better – Pulse still very frequent & feeble. Still the same discharge from stump
	15	Pulse 124. Not much frequent. Stump looks better. The stitch pale & weak but not separated – Takes her food badly –
	16	She is much the same. The parts look pretty healthy all but the bone
	17	Had a good deal of pain last night – became very low, requiring stimulants. But I find her to-day much as she was yesterday.
	19	She has been very low for last 12 days – pain in stump – quick pulse 130 – The medullary portion is no longer living – & from the suppuration extending into the medullary
	21	Still weaker to-day. Some bones denuded parts about it pale. She has taken very little food – but stimulants in

Month	Date	Particulars of Case
		Removal of Mammary Tumour.
Oct	5	This morning I removed a large tumour from the right breast of an old woman named Sexy had one child married to a mendicant by profession named Adony of Hooghly. 60 to 65 years of age. She was a very small woman. Thin & wrinkled with well marked arcus senilis. A tendency to Elephantiasis & oedema of right foot. Heart sounds well marked and a slight murmur? limit at the base. She has had the tumour for 10 years. It has become quite pendulous hanging by a broad neck of integument in which the large vessels can be felt pulsating. The tumour is heavy & nodulated on the surface. The skin is movable on it and the nipple is distinct. In axillary glands enlarged. The old woman's health seems fair. The neck of the tumour was held with a clamp made of wood on purpose and the sides made smooth with a few strokes of a sharp scalpel. A ligature was passed between and veins all secured. There was no artery marked A. large trunk in the radial and small in large encroaching bulk.

Month	Date	Particulars of Case
		Removal of Mammary tumor
Oct	5	She did not lose very much blood. but the operation was done very rapidly. the effusion is much as possible — The tumor weighed lbs 4 & 13. It was solid and when cut it had the appearance of what no doubt it is a case of simple hypertrophy of the gland with increase in fibrous elements. There were some cysts small & containing thick transparent jelly like matter under the microscope structureless — The tumor itself had the appearance of fibrous tissue with cell-like structure. There was no appearance of malignancy about it. and I believe it is a simple glandular tumor. The old vascular sac was.
"	6	Dressed the wound. It looks very well, no bleeding — No fever. No pain. She has had a very good
"	7	Doing well. Slight purulent discharge no fever —
"	8	Doing well. Some hysterics came among —
"	10	Slightly feverish. but wound looks well
"	11	Not so well feverish & restless — wound looking. bale & flabby —

Month	Date	Particulars of Case
		Removal of Mammary tumour.
October	12	Pulse slow. No Dyspnoea. No cough. Pulse quiet —
"	13	About 8 on Saturday the patient became worse and died — She was a very weak little wrinkled old woman with bell mouthed aorta similar to a shell heart. Probably death caused by marked dyspnoea from fatty degeneration. I did not see the P.M. But I am informed that the heart was very fatty. Pus in the pericardium of the heart plus. ~~left~~ right ventricle chiefly. Liver also very fatty. Spleen very small. Other viscera natural

Admitted
Operated Oct 5th
Died — Oct 13th

Month	Date	Particulars of Case
		Case of Cancer. recurring after Substantial removal
April	10	The tumor remains about the same size. slight serous oozing from the apex of the tumor where the puncture was made but on tendency as yet, to fungate —
"	13	Much the same. has occasional dull & stabbing pains in the part
	17	It is steadily, tho slowly increasing.
	19	It is slowly increasing — received 5 minims opium — Laudan alt.
	23	It is slowly but surely increasing the same appearances under the microscope as at amputation.
	27	The tumor is running more and more, and the discharge is increasing complains of weakness — pains in the neck & head
	28	It is rapidly breaking up. ulcerated running, leaving layers. sloughy looking material protruding. A hard deep swelling of face and cheek. sleeps badly. appetite impaired. Cachexia increasing — He has some Opiates. Z: Ferri: & Wrightsford like likes
	29	It is increasing
	31	A quantity of sloughing matter has cumulated freely & he is somewhat relieved. The discharge is profuse

Month	Date	Particulars of Case
		Epithelioma Conjunctivae —
Oct	10th	Sheik Kumar Ally. Hn. aged 45. was admitted on the 5th Oct 1863 - with an epithelial growth on the right eyeball. She states it to be of about 6 months duration - He is a sickly looking thin man. a ship klasie, and he says he is usually the constant pain in the eye - He had Syphilis (Chancre) twice, he says in his youth - but does not remember any constitutional manifestations of the disease - About 8 months ago he says he had paralysis of the right arm. Probably Rheumatism, he should be consulted - he has no syp. at present - About 12 months ago he was seen at Ranpur in the "Sporgetis" and he became blind in the eye on the 2nd month after the injection of the right eye - into side of cornea - which gradually increased causing much pain & interfering with his sight - He had it examined at the Chinsurah Hospital about 2 months after the first appearance, and within a month it was removed a second time, at the same Hospital - It has returned in larger & more painful than before. It now overlaps the cornea & partially

Month	Date	Particulars of Case
		Epithelioma Conjunctiva

interferes with vision in small pain
overlapping the pupil on pain the pain
Inflammation at Cancer. It occupies
all the front of the eye ball adherent
to the Cornea on the outer side. Lot
pushes forward the lids. On
opening the lids it can be seen to
be of a cauliflower like growth
with a broad pedicle in the selerotic
and near the outer margin of the
cornea. A probe can be passed under
it. It looks like a fungoid vascular
growth. and is spongy like a very
prominent pterygium; the sight
painful keep the eye lids bloodshot
apart. and is rapidly encroaching
on the Cornea. It adheres to it but
has no adhesion. There is no
sign of any extension of the
disease. to the palpebral Conjunct.
or to the lids. The glands do not
seem to be affected, and the
interior of the eye cannot be much
affected, as the vision is still good
except for the overlapping of the
growth. Examined it carefully
under the microscope & then & the
healing determined not to remove

Month	Date	Particulars of Case
		Ophthalmia Conjunctiva
		the eyeball as the weight of spring permanently relieved. It had been denied during twice before on each occasion had returned rapidly. The pain meanwhile was nearly gone out.
Oct	5th	I removed the eyeball by snipping through the Ocular fascia & cutting a deep lardum of the nerve. The eyeball presented the appearance I endeavour here to depict. There was no extension of disease to the tissues of the

orbit and the lachrymal gland appeared to be unaffected. There was very little bleeding. & that was soon arrested by ice. Under the microscope the growth presented the following appearance. Large Nucleated Cells. and most irregularly marked laminated capsules.

" 10 He has some pain but it is not very severe. he has had ice to the eye and shade
" 11 Pain much relieved. no inflammation.
" 14 To day I find the lids much swollen & inflamed the change. Ferment & wash with alum

Month	Date	Particulars of Case
		Rhytidemia Compunctum
October	17	The Babu reports. Next morning is a good deal of discharge. Smelling & painless
	19	Air dressing found behind the bed. Left on the contents. He is better.
	23.	Smelling and pain much better. The bark is contracting & beginning to cicatrize. But he looks anæmic & exhausted. He is well fed and has stimulants & tonics
	25.	Better pain & bleeding. Strength improving.
	30	The wound has nearly cicatrized. But he is weak & low. Feels & emaciated. He is taking tonics.
Nov	3	The eye has healed. But he is much broken down. Small ulcerations & sloughs. Urine is slightly albuminous. R: Tinct. Ferri & Quinine & plenty of food & wine
	5	He was better yesterday & discharged at his own request with a supply of R: Ferri

Admitted Oct 5
Operations " 10
Discharged Nov 5

Month	Date	Particulars of Case
		Lithotomy.
Oct	12	Name O'Doyle — Born in Ballinasloe This morning a native aged 15 years resident of Ballinasloe presented himself with symptoms of stone. He was somewhat emaciated and his stature was very a rather small. The bladder very irritable. The urine passed was small in quantity but healthy except that it contained much mucus. He has long been suffering great pain indeed he has had symptoms of stone for many years — The stone was evidently large — The kidneys were much enlarged and the bulk seemed on the cancerous side — The prepuce elongated —
		acute suffering for 7 months past —
		He was very timid & seems to be very as soon as he had been examined left in the presence & with the consent of the 2 relatives who accompanied him — I cut him — First injecting the bladder. I introduced a pelle shaped laterally formed staff — cut him on it — In extracting the stone & found it to be very large, I crushed the stone away. The nucleus came away. & the segments of the shell & phosphates came away they were about 2/3 of an inch thick —
		There was very little bleeding and

Month	Date	Particulars of Case
		Lithotomy
Oct	12	Lithotomy performed & stone extracted from the bladder. Patient stated the period when pain in pelvic necessary development are expected to be subsided. The catheter inserted with the passage of urine on 10th 1882. Day 3/4/83 and the incisions were in healthy
	13	He says he feels much better. He is passing a little abdomen is better. Immediately on taking urine lodes healthy & flows freely through the wound.
	14	He has no fever, urine flowing freely. Some dysuria pubic pain. Fomentations have given a little castor oil & his bowels are confined
	15	Bowels have acted. He has no pain in the urine flows freely. He has been slightly feverish since last report.
	16	No fever. No pain. Urine passes freely.
	17	He continues to do well, wound looks clean. Urine passes through it.
	19	Doing well. But weak
	21	He is doing well. No urine by urethra. Wound looks very healthy.
	23	He is thin & weak. But the wound looks well. The urine flows entirely through it. Passed an instrument

Month	Date	Particulars of Case
		Lithotomy
		took sub some mucus & pated. Urine Immediately
Oct	24	The urine is still pale & unhealthy, but the wound looks well - the wound has granted. he has no pain and says he is much better - he had some pain yesterday in the abdomen & was ordered a pain of opium. Discharged of necessary by the house -
	25	Much the same, no fever - but weak he is to have Acid Int Mineral dil Iron & Cy & Wine -
	26	The Sabor reports that today some fecal matter came mixed with the urine through the wound.
	27	He seems to be doing pretty well. In fecal matter reappeared in the urine, but he is very weak -
	28	Seems pretty well -
	30	Doing well. No urine by the urethra yet.
	31	Doing well. Wound contracting, but the urine still passes entirely that way -
Nov	2	Doing well
	5	~~Doing well. Urine passes through urethra & wound.~~
	6	He is doing very well urine passes through urethra & wound rapidly healing
	26	Wound closed. He is quite well
	27	Discharged cured. admitted Oct 12 Mercy Hospital Nov 27

Month	Date	Particulars of Case
		Jackal bite.
Oct	19	A Hindoo named Nattobur. (Burmanpur) aged 35 years admitted this morning with severe wounds inflicted by a jackal. He had been at early this morning down in a lane attacked by the brute which flew at his face - caught his upper lip and tore away a large portion of it. He caught the Jackal with his hands & held it. The brute tearing his hands also & held it till a policeman came & then and then they beat the animal to death. Does not think the Jackal was rabid. Says several people of his village near Cossipore have lately been bitten by Jackals. He presented a most ~~[illegible]~~ appearance - The left half of the upper lip and part of the ala of the left nostril torn away, the cheek torn as the commissure of the mouth was hanging over on the chin - I turned the detached portion up and brought it [illegible] in apposition with some [illegible] stitches - A flap about [illegible] inches wide from the [illegible] left half of the upper lip - Heavy medicinal vaccinium serum poured during the [illegible]

Month	Date	Particulars of Case
		Jackal bite
Oct	19	Adjusted a splinter retaining them three with three hair sutures. The mouth a good deal distended in size by the spasm but by morning take place. He really well and the so badly damaged after all —
	20	He is doing well. No bleeding. Wound seems to suppurate —
	21	Part of the wound beginning to suppurate but no symptoms of spreading yet —
	23.	He is doing well. Great pain in swallowing.
	24	He is doing remarkably well —
	25	It has healed except at one corner leaving a small opening. Attendant endeavours to close by slope
	26	All but a triangular opening at the upper corner of the puncture which has resulted from sloughing. It is doing well.
	27	All the sutures out. It has united. Healed except the triangular hole at the corner
	29	Doing well.
	31	The wound has united except at one corner where there is a small aperture but with pressure & bringing together with a strapping it is contracting. He is really very little disfigured. His mouth is much reduced in size
Nov	3	The wound has healed & the triangular hole has contracted. There is very slight disfigurement

Discharged 7 Nov 1853

Month	Date	Particulars of Case
		Amputation of Thigh (Female)
October	21	She died last night & was excited just before death
Autopsy		Pelvis – ab q. abn – Body much emaciated
		Thorax – Lungs did not collapse though on opening thorax – Portions portions empty hypostatically – but crepitant throughout & not diseased – Left pleura inflamed & lower part of Pel & Mediastinal surface covered with a thin layer of lymph –
		Heart – natural – but anemic
		Pericardium contained some fluid therein natural –
		Liver large and very pale – internally fatty
		Liver cells filled with fat – no abscess –
		Spleen, slightly enlarged – Kidneys, nothing
		In making a section of the femur we found the medullary cavity injected with pus to the head – normal part of the shaft not affected – 9 or 10 days after the medulla was protruding healthy & thus since the death which commenced about that time. She has begun to show symptoms of sinking with pyaemia – No doubt had she had strength the lungs would have become the seat of matting in the centres in the left & deep thrombi had indeed already commenced

Month	Date	Particulars of Case
		Amputation of Thigh —
Oct	20	A Boy named Talla Chand aged 10 years.
Residence Ramnagar Bar — Agriculturist.		admitted on the 14 Oct/63 with a very large swelling of the left knee — 24½ inches in circumference, involving the knee and upper 1/3 of the femur. but not the tibia. It had very rapid growth not more than 6 months and attributed by the patient to Rheumatism. In view — the nature of the disease. It is cancerous with enlarged veins, soft and fluctuating, the patella pushed forwards — the limb is wasted & emaciated. It gives him a good deal of pain & keeps him awake at night. Causing in the whole considerable constitutional irritation — something like a sheet of lace can be felt over the knee cracking & crepitating when pressed. The glands in the groin are slightly enlarged — the footpaths are edematous. —
		Amputation Femur & Bone
		after I intersected a small vessel and drew off some venous blood serum — which contained large granular cells ⊙ ⊙ here & there.
		after 1st I intersected a vein again & drew off 1½ lb of blood

Month	Date	Particulars of Case
		Amputation of Thigh —

like blood. which coagulated — Hales
ointment & similar compresses —
On the 15th first had filled with
the same & increased to 25 ounces being
after consultation with Drs Gordon
& McPherson, Chown, J. Brown, Jno
Butler — on the 20th it was decided
by the majority that the thigh should
be amputated through the thigh
and not at the hip joint as Drs Gordon
& Dr Butler advised. Secondary
amputation through the affected
compressing abdominal aorta with
an aneurism compressor not a drop
of blood was lost — a splint was used
from the commencement by the bearer a
little remaining — & a tourniquet
was applied — he bore the operation
well. — pulse rising on the other side
& from 130 when operation was
commenced — the amp: was another
Gordon flaps —
on cutting into the tumour it was
found to be a sac of blood & lymph
& blood. in like an aneurism
in the popliteal & was bleeding
from, the patient bade instead
in much fear of the intention

Month	Date	Particulars of Case
		Amputation of Thigh

hand had been opened - hence the
flood of blood. The condyles of the
~~tibia~~ femur were separated by the
shaft & there seemed to be a quantity
of spongy bone. There had been a superficial
osseous cyst, which had given way
& become disintegrated & filled with
blood. The tumour stretched
over the tumour were fatty -
The blood & pus taken from the
joint contained a rare form of large
granular cells, but such indicating
but just like those of a superficial
fungoid cancer. - The
pus scraped from off the fungus
of the capsule contained skin
& cancer structures, & the
idea that this was a superficial form of
medullary cancer - attended with
much bleeding - & true fungus
haematodes. The long skeleton
in specimen - & the deposit from it
seem to point to this as the cause

21 Pulse 132. Shivery shock - Drowsy & coated
tongue. Slept much. & in the afternoon
delirious. Feeling better since the limb was removed

22 Much better today.

Month	Date	Particulars of Case
		Amputation of Thigh
Octr	23	Slept pretty well. Skin still dry & hot. Tongue white & tremulous. Pulse 120. Stump looks well – but of course I cannot say how the bone may be as yet. It is beginning to discharge from about the ligatures – he takes milk & broth – & a little sago with some port wine. The bowels are as he has been taking 2 grs. but I have discontinued it. I forgot to mention that I painted the flaps after the operation with Tr. Benzoin Co & flap thus brought together.
	24	He is not worse. Pulse still rapid. Bowels inclined to be costive. Tongue moist. Not delirious. Some of the ligatures come away. The discharge is better but still profuse. Drinks liberally. Can take food fairly. He takes his food fairly.
	25	He had an attack of haemorrhage but after the dressing this morning. Had taken the stump light at the outset, a small one from which a ligature separated yesterday. Found clots & some pus in the stump, but otherwise healthy. Bone dirty pink. Part of it sloughed off. Remainder. Muscles living

CASE BOOK.

182.
Admitted Oct 14
~~Amputated " 20~~
Died — " 29

Month	Date	Particulars of Case
		Amputating thigh.
	25	His pulse is now 112 then many Bowels than - on leave - the tissues still very soft & rather tender - Wound hæmorrhage is unfortunate - as he was impoverished
	26	Tongue. Pulse quick, 120, today, no more hæmorrhage - Continue all.
	27	Pulse 116. Improved note. Tongue especially towards fingers. Discharge free from the stump. It looks very much as the same from blood time
	28	Pulse 120. Skin hot. Tongue in the evenings. Stump looks much the same. The glands in the groin are certainly smaller.
	29	Pulse 120 - He has ached some in the sacrum. Stump looks pale & weak. Discharge thin. Skin still dry & hot. Tendency to pain in groin - He has some R. Pneu. in Cel. Com. & Hemiplegia -
	30	He became low yesterday afternoon. Abdomen tympanitic & sank.

Post Mortem at 8 p.m. Dec. 30th Rose - faint accounts & blood secondary cavity formed & received - Femoral vein adherent to artery & filled with pus - Sub peritoneal pelvic cell: some pell of thin yellow pus. Some cells in peritoneum - Other pell of pus & other of dead tissue. Some purulent - Some simply dead tissue. No large patch especially at inner edge of right lobe - Spleen enlarged and crowded with similar patches - Lungs generally healthy. Lob. dead sub collapsed. Pelvic & Abdominal

Month	Date	Particulars of Case
		Amputation of the arm –
Oct	24	This morning I amputated by double, antero-posterior flaps. the arm of a Indian leaper named Tarroo Singh aged 32 years. who was admitted on the 9th Oct with a severe injury of the left hand. from a fire hearing brush in his hand. The thumb & the index were shattered & the metacarpal & carpal bones shattered. I tried to preserve the 3 remaining fingers. but the injury was followed by violent inflammatory infiltration of the arm until pus was freely beginning infiltrated. pulse rapid. fever & incipient indications of pyaemia manifesting themselves. I with Dr Fordyce ~~[illegible]~~ decided amputate of the arm above the elbow. The parts were totally healthy except the anterior part of the arm which was a denudation & dried not retracting before the knife – The posterior flap did. On 7 ligatures were needed & the flaps were brought together with horse hairs – He bore the operation well. lost very little blood.
	25	Slightly hemorrh. had one ligature applied yesterday

No 56

Month	Date	Particulars of Case
		Amputation of the Arm.
Oct	26	Doing well. Pulse 100 – no fever – Discharge commencing in the stump – Dressed it.
	27	Pulse 100 – No fever. Doing well
	28	Doing well. No fever.
	29	Broke the ligatures came away – removed the sutures – Stump granulating. He is doing pretty well. Good diet & brandy
	30	No fever. Looks better in all respects
	31	Wound looks healthy. No fever. appetite good
Nov	2	Doing well. Ligatures & sutures came away –
	3	He has had violent rigors since last report. after time. I find himself a pulse at 136 – Dulling among in the respiration on left. He has taken his food well notwithstanding – I introduced my finger into the stump and find that a portion of the bone is denuded of periost. No doubt inflammation is commencing in the medulla. I send him Dr. Davis Rum & Vestible Blunt & milk & support
	5	He has had rigors as usual yesterday & today the morning after amputation. Dressed stump. at first was considered. Left rigors commencing at that time & it was repeated – He is taking pill & opium by Dr. Davis
	7	He has had rigors each day following fever & pulse pulse 120 – Prostration on chest below

Month	Date	Particulars of Case
		Amputation of arm
Nov.	7	Image pale. Pt in a blow. I fear mischief is going on in the lungs. He takes Iron Quinine Potassium
	8	P. 108. Skin cool. but he had fever again last night — Sun fr & 2 from 8th to 4 morn. Stump looks well. Slightly discharge from about the bone is less
	9	Some rigors yesterday. Pulse 140 Skin hot: a petechial eruption like Bronchitis on the Chest. Should have General Consultation as to amp: at Shoulder joint: but it was not recommended
	10	I opened the flaps with a scalpel partially & found that the Medullary cavity was filled — But of the cavity of the bone is clear. Left down. Wrap hand upon with dry. Continue alt
	11	Had rigors again & fever yesterday, but I put him with Wp fever p 10 dr — Image pale but clean — Bowels moved 2 times — Cont: Iron & Quinine
	15	Rigors ~~[illegible]~~ daily. He is getting weaker Breathing indicates tubercular deposit — Cough distressing — Sound with Respiration — Discharge from stump unchanged
	16	He is getting weaker —
	19	Noticed a large Collection of pus over left Shoulder. I fear sinuses forming about that place —

Continued in No 7 Page 16.

Month	Date	Particulars of Case
		Calculus in urethra —
Oct	25	Bonnally. aged 28. healthy lodging Bundor. residently Sri Bux addha a Pundit: admitted yesterday 24th with symptoms of stone in urethra — I passed him this morning in great pain unable to pass his urine. and the urethra blocked up by a calculus just in front of the scrotum — tried to extract it with forceps. but could not succeed. Pushed him under Chloroform passed the instrument pushing with some difficulty, the stone back into the perineum where fixing it — with the finger I felt down on it — through the bulb. and felt it an oblate of lime? oval rough dark coloured Calculus about the size and shape of an almond or a date stone. There was [illegible] pus oozing from the bulb but — no urine or haemorrhage — Just sent to bed with ice & spc pure in perineum
	26.	doing well
	27	Slight tendency to bleed, otherwise doing well
	29	No bleeding, urine passes partly through the urethra partly through the wound — He is weak. Feed him well
	31	Doing well. healthy wound, urine passes both ways

CASE BOOK.

Month	Date	Particulars of Case
		Calculus in Urethra
Nov.	2d	He is doing well. No hernia. Perineal fistula healed but.
"	3	He left the Hospital Sponte sua accord last night he was doing well

Month	Date	Particulars of Case
		Lithotomy Lateral
Octr	28th	Lucky Kanto, aged 50. Thin spare man with feeble pulse. Acute emphysema heart. Cold extremities admitted on the 27th with symptoms of stone. He has been suffering for the last 5 years but only lately severely. The urine is clear and healthy except a faint trace of albumen. Stomach — His bowels being well clean, having had a good night, free from pain and pain — I operated on the 28th at 8½ am — Lateral incision. No Chloroform as Dr Jordan advised. Opened the bladder & rectum & he thought it would perhaps better not — Pulse Permanent very rapid and weak — Gave stimulants & brandy — St. warm. Oval uric acid Calculus, tuberculated and just beginning the contents in form of small crystals of triple phosphates — He bled freely and had several ounces of blood after the operation — ice. Morphine — tube stopping the wound respiration and warm all had recovered.
	29	Had a good deal of bleeding (oozing) yesterday. It has stopped. He is rather low. Pulse & temperature doing well. No fever — Urine flowing from the wound

weight 418 grains

uric acid coating of delicate crystals of triple phosphate

Month	Date	Particulars of Case
		Lithotomy Lateral.
Oct	30	weak & low. urine flows through the wound. Otherwise is much as yesterday
Nov	2	Tongue coated. He pulse is slow & feeble urine passes by the wound — Stimulants & Beef tea with ammonia —
	3	Still very low. pulse slow & feeble (84) Tongue coated. urine passes through wound
	5	very low. Diarrhoea — had wine & other stimulants — wound is healthy
	7	Diarrhoea better. Tongue still very coated & dry. but he is not worse. p 84 — urine flows by catheter.
	8	Lost still but not worse — Diarrhoea a little better
	9	Rather better
	10	Improving slowly
	15	He is in a low state. Tongue furred. but on the whole is improving.
	18	Much better regaining strength & doing well in all respects
	26	Wound nearly closed. Doing well in all respects
Dec	4	Doing well
	12	Wound quite healed & he is much better in health. but has just had albuminuria & the urine contains albumen

He left Hospital Monthly after — Readmitted & the wound quite healed Readmitted Oct 27 28 Discharged Dec

Readmitted

Month	Date	Particulars of Case
		Haematocele
Oct	30	Mr. F. American aged about 45. born bitterly a boy in Scotland about 8 years ago – had a swelling of testicle which nothing ago was tapped by Dr Macnamara and bloody fluid withdrawn – It has filled again – is painful hard and heavy. keep him confined to bed. Immediately – Blood clot seems to have been applied for some time but other wise uniform. Rather in accessory. Introduced a trocar & cannula and withdrew about ℥viii of dirty looking fluid. looked as the ~~[illegible]~~ streaks of pus in it – Said Scrotal Scrotum and took out a quantity of blood clot and semi-purulent layers of fibrinous matter – No tumor. Vas epididymis much thickened – Stuffed it with lint & sponge & poultice. Died one small vessel.
	31	No bleeding. no fever. washed out the cavity & used pure lint & poultice & plaster of Paris.
Nov	1	Dry well. no fever. no suppuration
	5	It is contracting. healthy discharge – P. 84.
	18	It has nearly closed. He is in good health. He now sleeps well and continues. It can sleep well
Dec	15	Sheets Read been perfectly cured

Jany 15/64 – Sent home today. He is perfectly cured & certain always. Nature of Hydrocele – and Scrotal Abscess

Closed

Month	Date	Particulars of Case
		Medullary Cancer of neck
Nov	8.	He is getting gradually weaker and more cachectic. Sallow leaden look with a peculiar appearance in the eyes. The tonsil is open, edges lacerated & simply matter from, but extension to the vicinity. and under the jaw there is much swelling. He has also difficulty in swallowing. He has Sarsp. wine & Dr Griffin's with tonic of Iron & Quinine. Local application Dr Griffin's. It is in use trying to repress the growth & alleviate pain in the only treatment
	9	Rapidly getting weaker
	15	Getting weaker. Exfoliation of neck of face gradually extending. Cachexia rapidly increased now. Nutrient & stimulants
	19	Much the same. Swelling in face slightly abated. The cancer is always progressing
	26	Weakness increasing. Cancer spreading —
Dec	4	Very low. Cancer & cachexia rapidly increasing
"	12	Very low. much weaker. The end seems to be approaching. He wanders at night. Can take very little food
"	16	Died completely exhausted.
Post Mortem.		Partly right lung emphysematous: several nodules of cancer in pleura.

Month	Date	Particulars of Case
		Amputation of the leg —
Oct	31.	A man named Sheikh Kallo aged 50 years admitted on the 30th Oct. with extensive sloughing of an elephantoid leg. He has had elephantiasis of the right leg for 3 years. 10 days ago, as he had an attack of fever which was followed by sloughing of the leg in the upper part of the elephantoid part. The forehand enlargement by the knee & thickened and tense lated to a great extent — The skin is affected as far as the knee but at any in the ~~upper~~ middle third of the leg where the sloughing has ceased to extend itself — As it was beyond hope of repair. I amputated the leg after resting a day — No fever — & no extension of the mischief having occurred since admission — The integument were divided was thickened. but I thought it better to amputate above the knee. In the mode of amputation of the thigh the ligatures were applied. The operation was double flap made in the modified fashion. Getting pain without tension
Nov	2	Dressed the wound. He is doing well so far he has —
"	3	He is doing well so far.
"	5	Doing all right but the large axillary glands are enlarged

It appears that the usual mortality from fever was more than usually since & that it dwells the lightness an extent that of stock into trades which sloughing

Month	Date	Particulars of Case
		Amputation of the leg
Nov	8	He is very well. Pulse still rises a bit of the bone bare. The stump is healthy & his pulse is good in fever
	9	He has symptoms of tremors. Pain in chest neck & back. Wound still looks well. Hemp & Chloroform
	10	Symptoms of tetanus & tremor have abated. Leg looks well. Continue
	11	Stump looks well. But he complains of severe pain in the neck, back & face. Left spasmodic twitching. Ord: Hemp & Chl
	15	He has had tetanic symptoms for the last 2 days. Is taking Ipecac. The clonic tetanic spasm of the muscles of chest & abdomen continues. His jaws are not much affected. Omit the Hemp & Chl: give Ipecac fr xx every 4 hours. Bottle of mixture. Stump still looks well
	16	He is much the same as yesterday. Continue the medicine
	17	It is remarkable how the clonic tetanic state continues. Yesterday it suddenly ceased in muscles, today that is not affected. But the thoracic & abdominal muscles are affected. The tetanic motion continues. Repeat the Hemp & Chl: bottle of mixture. Stump & leg Beef tea internally & Nutritious
	26	He is much better in every way. Tetanus & dysphagia both have stopped. Stump looking
	30	Much better. Stump healing. Pulse & bowels

27th Dec. The left leg is healed but very much. & a bed sore has formed. Stump has almost healed

Month	Date	Particulars of Case
		Lithotomy Lateral.
No.	4	A man named Ram Chund Doloy. aged 50 years. tolerably healthy. residently Khulsinie admitted this morning with symptoms of stone. He has had them for 2 years. The left hand and arm are congenitally deformed — as he was in good health and desires of being relieved immediately. and as he could have left the hospital otherwise. I operated this morning. lateral incision. removed a stone about the size of a walnut.
		Stone weight — probably uric acid nucleus with triple phosphates. Diameter 1½ centimetres.
		The prostate was somewhat enlarged. and he had some hours after the operation considerable haemorrhage from the bladder. The pain he suffered is described as being like labor pains before he expelled the clots by the wound. I saw him at 3 P.M. and ordered ice compresses. He had had 2 doses of Dr. Orr —
	5	Doing well
	7	Doing well. Some urine passed by urethra.
	8	Some collection of blood (urine in bladder) worked out. not he is rather low. p. 120 abdominal tenderness. Extra. Pint of 6 hourly
	9	Not so well. abdomen tympanitic painful. Pulse small & quick. Urine passed clear — bowels loose. pretty well. Stimulants 1½ oz every 4 hours

Much agitated during the last 24 hrs.

214 Grains

No 61

CASE BOOK.

Month	Date	Particulars of Case
		Lithotomy Lateral
Nov.	10	He became very low - yesterday - Abdomen tympanitic and he died at 2½ PM - There was no Post Mortem Examination as the friends took away the body.

Month	Date	Particulars of Case
		Mammary Tumour
Oct	7	Mrs E — aged 26. Stout healthy looking dark complexion. Came to me with a small movable tumour in the right mamma about 4 or 5 months ago. Slow, painless & rather hard. No affection of neighbouring glands. The usual regular menstruation, but was disturbed in spots about the tumour which was increasing in size. I said her mamma some weeks after the tumour was painful & inflamed. She was undertaken — Intra-mammary. — I recommended Iodine — when the inflammatory symptoms had passed away. A few days after I again said her breast increased to the size of an orange — prominent & tender to the touch — her health & mental spirits greatly impaired. I recommended removal as the only hope of getting rid of it — giving a guarded prognosis as to the probability of its being malignant. On May 20 Dr Stewart giving Chloroform I removed it — by making an incision below & external to the nipple passed to the border of the pect. muscle.

No. 62

CASE BOOK.

Month	Date	Particulars of Case
		Mammary Tumour
Mr	7	Small ligatures were required but no large vessel bled – The tumour was capsulated – & only dissected out as a thin suspicious looking the neighbouring glands structure and fat were removed the nipple. I should remark, as was subcutaneous – The tumour was as large as an orange. Very heavy & totally hard – when cut into it looking a beautiful pink, with the colored spots – in between yellow looking tissue – It resembled half a piece which under the microscope presented the very suspicious appearance depicted in that previous case.
		The breath the chloroform well. under Chloroform – & did not lose much blood 3 or 4 ounces of blood
	8	Very hysterical excited after the Chl: & fainting. Did not sleep well on the preceding the sleeping draught – Dressed the wound & broken up well. No bleeding – Sleptin & 7 other sutures were applied fine lint & salve
	9	Discharge commencing. Wound looks well. Slept very uneasy & suffered

Month	Day	Particulars of Case
		Mammary Tumor
		Dry well & ligatures come away. Discharge thin but better. Left hand less pain.
		No pain. Left Pain. She appears to be doing well — Takes her food & much better & some ligatures came away —
		All the ligatures have come away. wound some of the sutures. It looks healthy & she is improving.
		The last sutures taken out. Wound looks remarkably healthy. & is rapidly closing. Her health is much improved. She sits & sleeps well & is in better spirits.
	28	Dr Smart reports to day that the wound has healed and that she is much better health. Stitches that she is perfectly free and
		She came to me complaining of pain in the Cicatrix. It is hard and the tissues some swelling & tenderness in the breasts and the Cicatrix & the needle bones, appearances have a moderate appearance. Spear is as following
	23	Has cough - shortness pain in heart - some nodules like keloids - about the Cicatrix - but no malignant tumors growing yet
May	4	Tumor increasing. Nodules larger & some hard. Pain in shoulder. Cough. Frequent respiratory sounds. Healthy. Bowels healthy.

Not very apparent

Left breast thus by complete excision & the tissues & the tissues of the wound healed. Patient is free only and that is "free" in a state of health. It remains in a state of perfect health. The tumors in the breast have not appeared since the first operation. 23 Feb 1864