

Bound watercolour plates "Injuries and diseases of the femur taken from preparations by Sir Charles Bell, Dr. Barclay, etc., in the Museum of the Royal College of Surgeon, Edinburgh", by J. Macdiarmid

Publication/Creation

1834

Persistent URL

<https://wellcomecollection.org/works/tpatwx2n>

License and attribution

You have permission to make copies of this work under a Creative Commons, Attribution, Non-commercial license.


Non-commercial use includes private study, academic research, teaching, and other activities that are not primarily intended for, or directed towards, commercial advantage or private monetary compensation. See the Legal Code for further information.

Image source should be attributed as specified in the full catalogue record. If no source is given the image should be attributed to Wellcome Collection.



Wellcome Collection
183 Euston Road
London NW1 2BE UK
T +44 (0)20 7611 8722
E library@wellcomecollection.org
<https://wellcomecollection.org>

617



8
(c.2) v

617

K



INJURIES

AND

7

DISEASES

OF THE


FEMUR



*Subscription published by the Medical Library
of the University of the City of New York
under the patronage of the Board of Regents*

By J. Woodhouse

1836



N
Fracture of the Femur in the place, number.

"This was the thigh bone of a Madman, who threw himself out
of a window, and broke & Mangled, so as to frustrate
every attempt made to secure the position of the limb.
The bone in its natural state was 18 inches long It is
now only 13 Up to that termination the French adopted the word."

James P. Smith



Fracture of the Semur written

Call

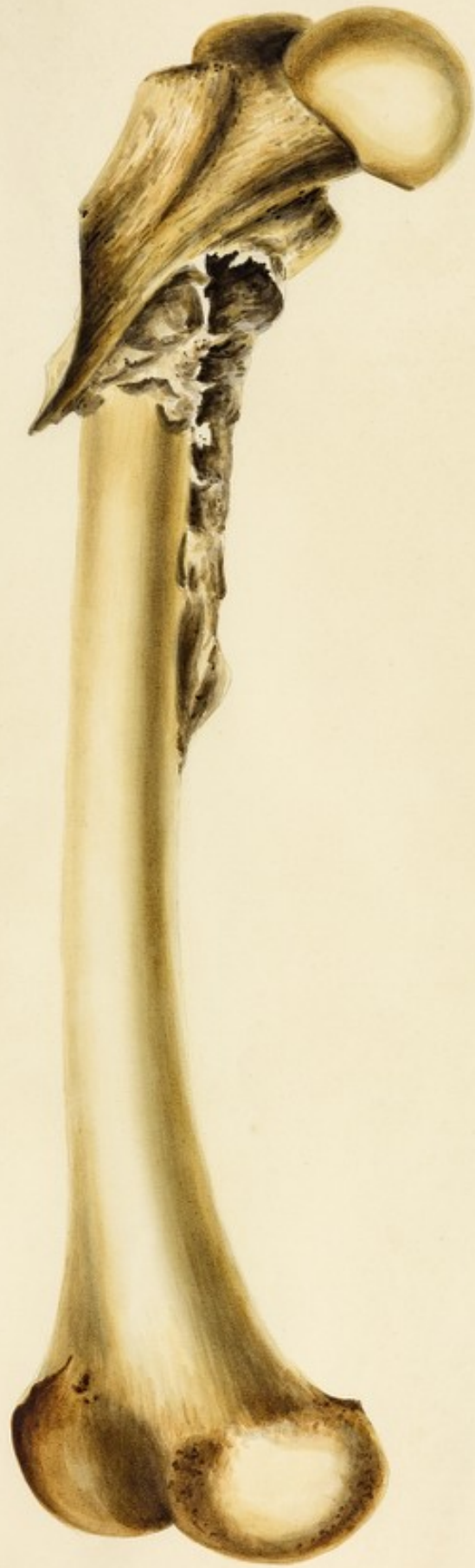

VIII.

Fracture of the Femur.

"The Patient was a Coachman who had fallen from his
box, during the preceding 5 Weeks. The
Specimen shows an amazing growth of Callus
Matter, after extensive injury of the parts."

Wm. Keble



Oblique Fracture of the Femur united


"The extremities of the bone here in this fracture seem to pushed past each other, and stand so apart that the usual surface is now in common both places at the sharp spines of bone project, and the limb must have been very considerably shortened."

Wm. Hunter



Fracture of the Femur. united

base



Fracture of the Scapula

Curiously United.

Case




Prostasis of the lower Head of the Femur

"Case A boy of 13 years of age fell from the parsonage of a house on the floor below, and his right leg was thro' the flooring. When brought into hospital, the House Surgeon exhibited a case of common fracture of the thigh bone. He lay with the usual securities for about a fortnight, before I was called to consult upon it. The Boy was hectic, much reduced, his tongue countable pulse, and upon the inside of the knee there were deep hanging spots, fresh blood in consequence of the restlessness of the leg during the night. I found the bone sticking thro' the integument, and saw from the appearance of it that the case had been Prosthesis, and that instead of a fracture communicating into the joint, it was a Prosthesis or separation of the Epiphysis. - Even now I thought it not too late to amputate with some chance of the Boy surviving, but from an Idea that he would rally by delaying it a day, I was full of time the morning when the Patient died.

The Dissection exhibited great separation within the knee joint, an immense abscess or cavity communicating with the latter, and extending up the bone nearly to the hip. The Prosthesis could be torn off with the finger from half the length of the Bone."

Wm. Keightley



*Fracture of the Femur in a young Bone
united The Fracture being unrepairable
and Deposition of Alveus matter.*



1

Fracture of the Neck of the Femur

with the loss of substance

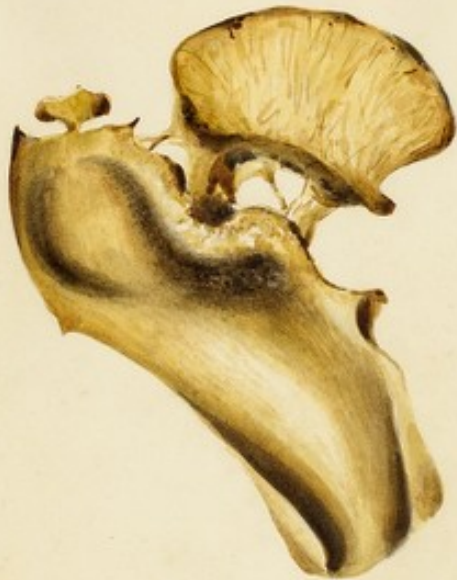Case

2

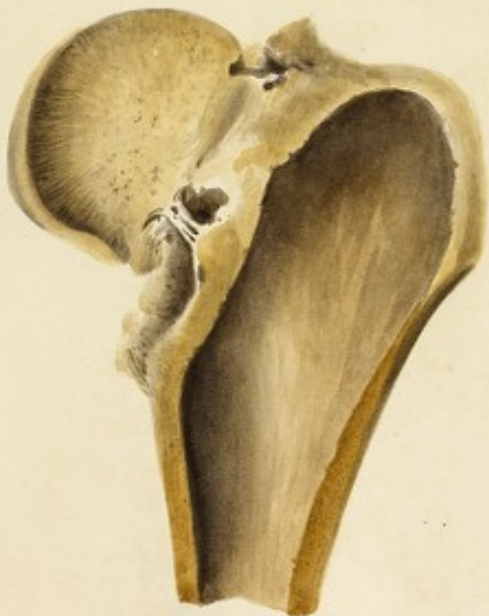Fracture of the Neck of the Femur

Case

1



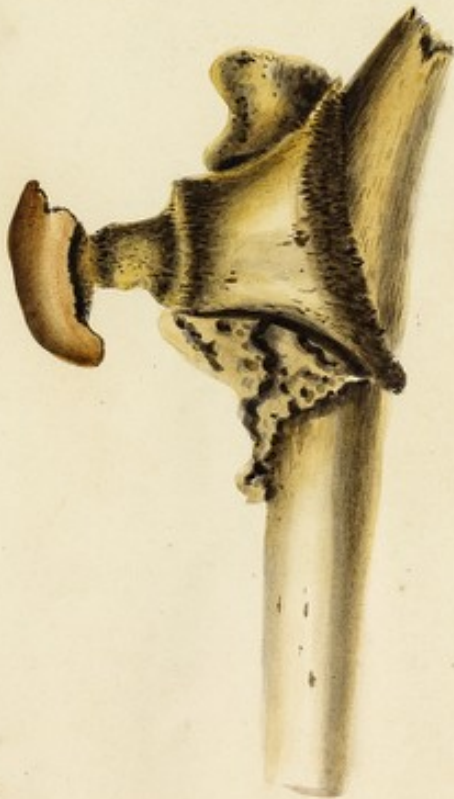2



1
 "Fracture of the Neck of the Femur united
 by bone; the Crown and Trochanters detached from their
 connexion with the Shaft of the bone. All the portions
 were united together irregularly, and with great
 shortening of the limb."

Parsons Report

1
 (Anterior view of the Same bone)



1.

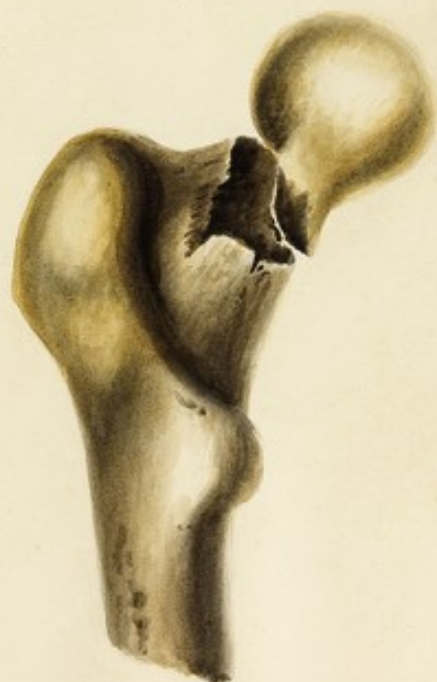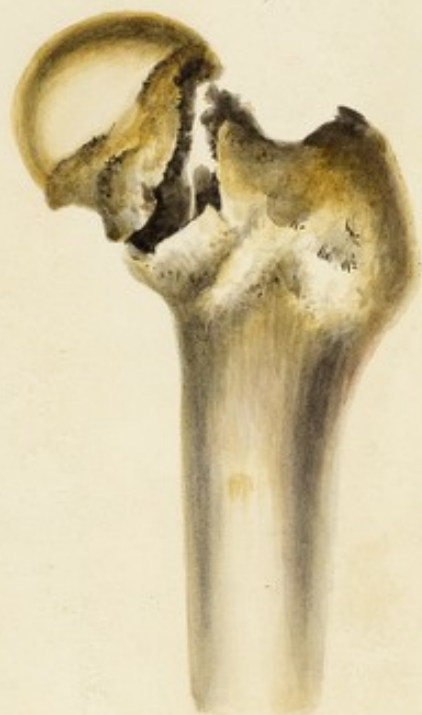Fracture of the Neck of the Femur

Case

2.

Fracture of the Neck of the Femur

Case



1

*Supposed Fracture of the Neck of the Femur
within the Capsular Ligament United.*

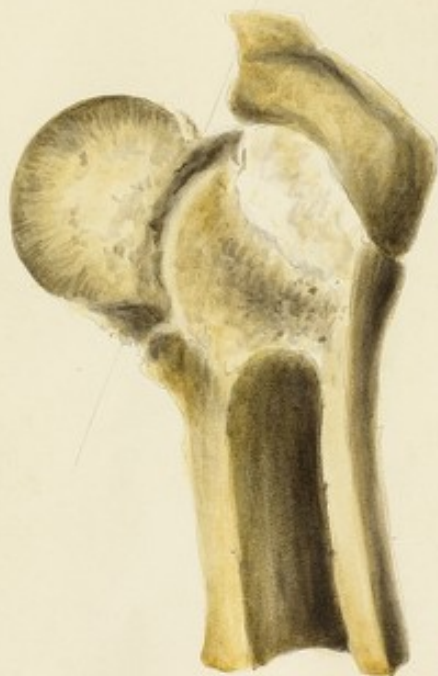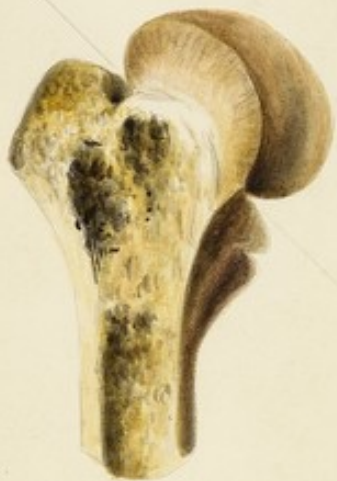Case. "An elderly Lady in Jan^r 1781 on attempting to walk from her bedroom to an adjacent apartment, slipped her foot suddenly and unexpectedly over the edge of the Landing of a flight of Steps and fell on the right hip. She attempted to rise but found that she had completely lost the power of Motion in the limb of that side. The Servants on coming to her assistance found her sitting on the Landing place her feet resting on the Step below she was immediately conveyed to bed, but being in comparative little pain, and it being late in the evening, no medical assistance was procured till next Morning. I found her in the position in which she had remained during the night, resting on her back, the right limb a little bent, and apparently about 1/4 inch shorter than the left. The knee and toe considerably swollen, the heel resting in the hollow between the tibia and Tarsal articulation of the left leg, but she straitly to relate the high occasional considerable pain in the situation of the trochanter Major as did also the extension of the limb to touch the distal intern together which was readily accomplished, but retraction immediately took place and the leg returned to its original position, no crepitus could be distinguished. Judging from the history, and appearance of the case Fracture of the neck of the Femur had taken place. Her Situation soon appeared of the helpless state to which in all probability she would be reduced, from no complete union being expected. The treatment was therefore simple, the upper 1/3 of the thigh was frequently fomented, and broad fine bandages constantly worn from the knee along the thigh, and encircling the body, the limb was supported with pillows, and every attempt made to keep it extended, with the heels in opposition. Under the plan she remained for five months occasionally arising from her bed to a sofa. She then began to make some progress in the leg and with the assistance of crutches, and gently resting her toes on the ground, she was enabled to move thro' the room, she ultimately laid aside the crutches and walked with the assistance of a stout stick, she then relinquishes the use of the stick, and with the aid of a very high heels shoe walks in the course of a year with great facility, ascending and descending Stairs. The knee and foot remain swollen and the leg shortens about 1/4 or upwards of an Inch. April 1784 Cure of her affection of the brain."

2

Præsentia Regula

*Fracture of the Neck of the Femur in which no Union
took place, but considerable Absorption.*

The Woman lived for ten Months after the Accident.



1.

Fracture of the Femur near the Trochanters.

Case " George Sharp aged 70, a laborer of very Intemperate Habits, on the evening of 29th Decr 1832 had been drinking Spirits and on coming home fell on the floor. He managed to get to bed with scarcely any assistance, but violently refused to have the injury examined, or any remedy applied. He died on the 8th April

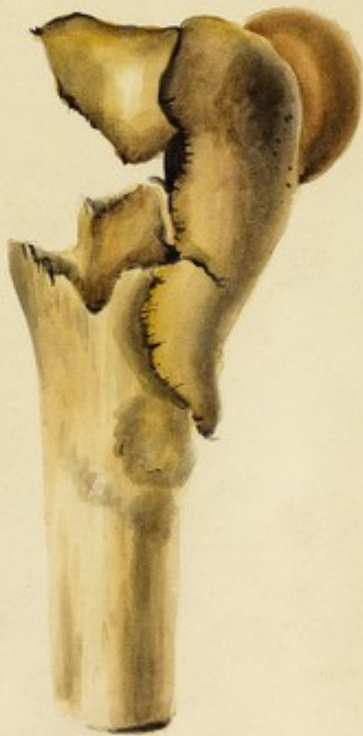On Examination 24 hours after death, it was found, as has been supposed from the post, that the upper part of the Femur was fractured. The surrounding Gashes were in a state of suppuration. "

Museum Regium

2.

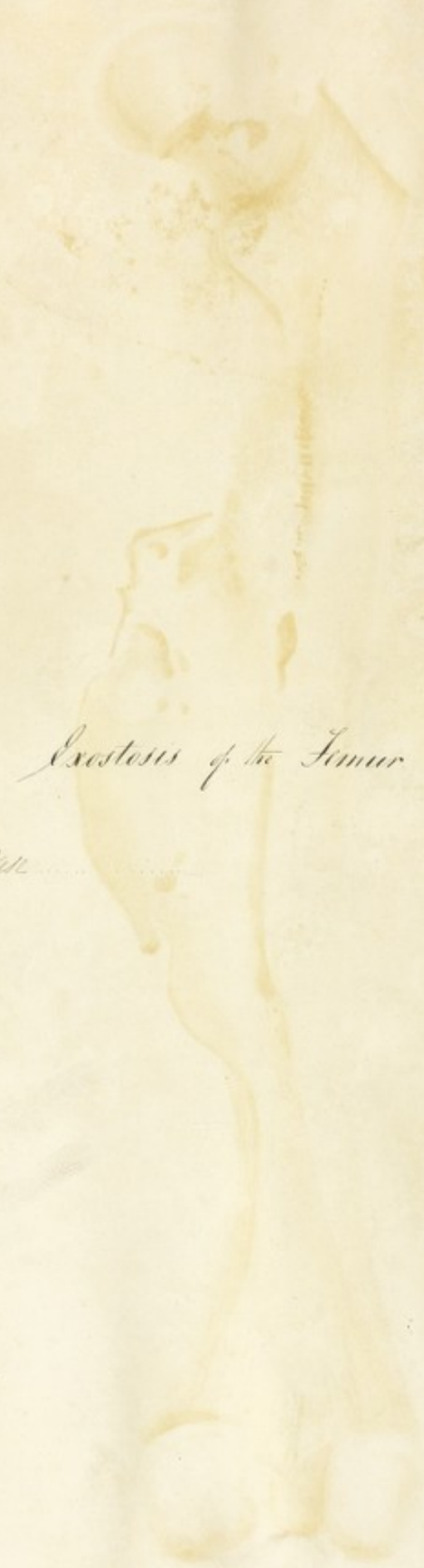
Fracture of the Femur near the Trochanters.

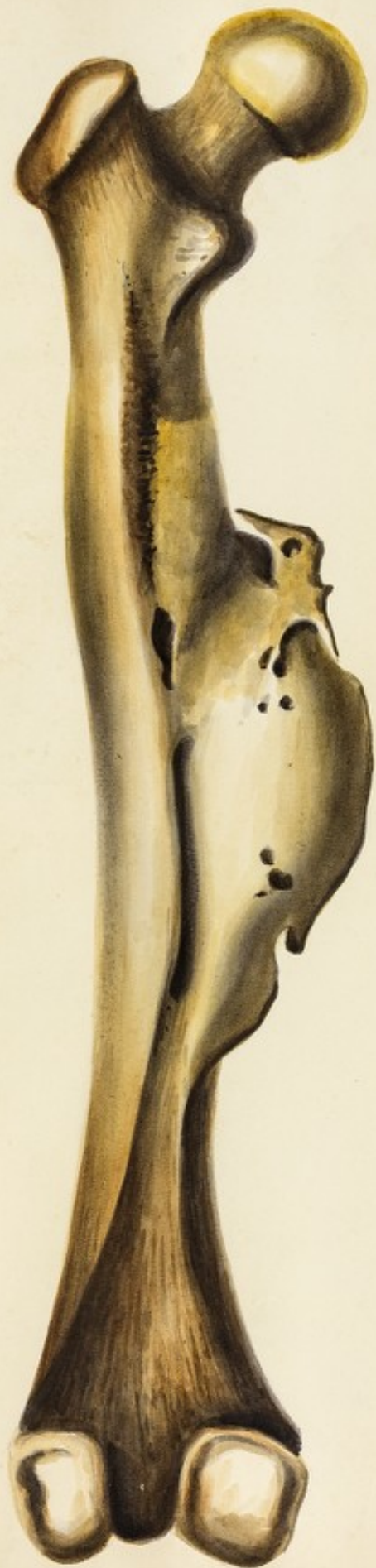Case



Exostosis of the Femur

Case





Necrosis of the Femur.

Case



Osteo Sarcoma of the Femur.

Case



Ostio Sarcoma of the Femur.

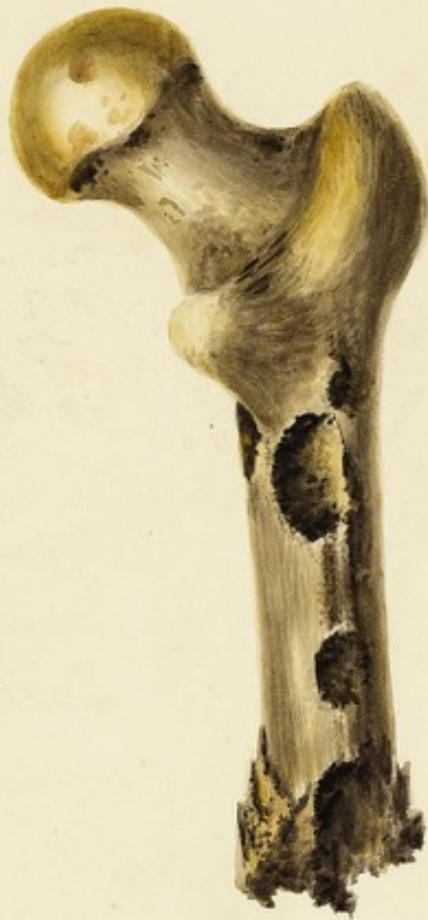Call.



LXVIII

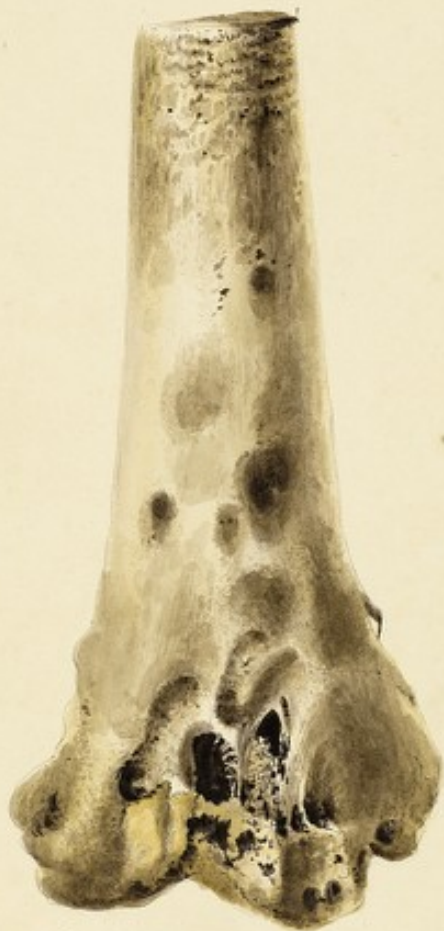• Portion of a Femur deeply affected with
Caries

Plate



Femur affected with Caries and
Deposition of Bone subsequent to Scrophulous Inflammation.
The Iliac, Fibula and tibia equally affected.

Cells



*Portion of a Femur after an attack of acute
Inflammation.*

See



