

Case notebook

Publication/Creation

1913

Persistent URL

<https://wellcomecollection.org/works/gqnmzpw5>

License and attribution

You have permission to make copies of this work under a Creative Commons, Attribution, Non-commercial license.

Non-commercial use includes private study, academic research, teaching, and other activities that are not primarily intended for, or directed towards, commercial advantage or private monetary compensation. See the Legal Code for further information.

Image source should be attributed as specified in the full catalogue record. If no source is given the image should be attributed to Wellcome Collection.



Wellcome Collection
183 Euston Road
London NW1 2BE UK
T +44 (0)20 7611 8722
E library@wellcomecollection.org
<https://wellcomecollection.org>

793

H. S. Carter

Army Book 33.


HOSPITAL DIARY,
PRESCRIPTION BOOK
OR
WARD BOOK,

AND
DAILY RECORD OF
Extras & Medical Comforts
ISSUED TO
PATIENTS
IN
FIELD AMBULANCES.

423 2000 lbs 4-18 HWV

Books
29
31

RAM C 793
16



Concussion

Name Radovan Mitrovitch

Age 25

Occupation Telegraphist

Date of injury ~~24~~ 1st July 1913

Inst. at work with 7th telegraph. when a shell fell near him 40 or 50 yds ^{in front} away, killing several.

He was struck by the earth & was knocked down

He bled from nose mouth & ears & became

unconscious ^{1 hour}. He was not injured. Never suffered from ears before but now offensive discharge.

5 or 6 hours after shift shaking came on more severe next day both arms & legs. His speech was hurried & irregular but sensible.

Shaking stopped 20th July. His treatment was Valerian

& Arsenic

He took daily hot baths cold shower massage.

Rt ear old granulations left. drum normal

Knee jerks + Plantar reflexes -

Concussion

Name Dragomir Lazarevitch

Age 23

Occupation Farmer Infantry

Date of injury 30 June 1913

Bregalnitsa Inst

during attack on hill.

shell burst 6 feet from him became unconscious. 1 hour.

Bled from nose mouth ears.

Arrived Belgrade. 2nd July

He is described as head greatly swollen. Black eyes

face scorched & fine earth on it. Neck &

shoulders black. Carried in. Never had any temperature.

Has constant short cough (was spittle blood on animal)

which has not improved.

Complains of pain in epigastrium & legs.

He states that the cough sometimes keeps him

awake.

Put on Bromide Valerian.

Cough gradually diminished when

he was told it was the only

thing that kept him in TP

Mikhailo Murenkovitch
Age 25. Tailor. Infantry
Scorch forehead.

man states that a
piece of shrapnell
came through $\frac{1}{2}$ metre
of trench & hit him on
the head

Nothing to see except a
scorch on the forehead
He states that he
becomes giddy at times.

Concussion?

Man stuped &
unable to give
any account
rather like an
imbicile. He speaks
very slowly & cannot
remember words

Wad. ~~size~~ 9
Peter Vassiliouitch.
Age 25.
Fracture femur. Left.
Wound of leg. shrapnell
In plaster. septic.

Occurred 2.7.13. Stup.
Put in plaster. 7.7.13

3" shortening
slow union

Wladislaw Rostitch Age 32
date 2/7/13 at Tchumi Vih.

Rt leg. shrapnell
Amputated 8.7.13. compound
Ant. post flaps. septic.

9.

Jovan Velkovitch, age 35.
Rethi Bukve date. 1st July.
Shrapnell
Flesh wound inner side of
thigh.

9

Superficial
depressed. part of frontal
bone operated on.
Bullet

bone bone
retraction of soft
tissues

9 Shrapnell (Tomson)

Lead superficial
ent. 1" above + outside of eye
extracted.
~~XXXX~~ at globe of eye.

Lead finger. Shrapnell.
anf.

Stephan Mitkovitch.

age. 29.

Place. T. Vch on 2 July.

9 Shrapnell.

foot + toe septic
age. 20. name. V. Markovitch.
Place. Vlassova 20.7.13.

Dermatitis
of foot after
transfer to Sch.

Traumatic aneurysm
axilla left-

Milutin Kuz'manovich

41

Saitchan 5 July 13

Hit when returning up
hill He thinks a
misshot bullet

Anty. traps junction
of mid lower third
Exit (removed) anterior
border of trapezius
at level of axilla
Can move fingers & thumb
slightly

Condition when plaster
removed on 4.8.13

Arm very solid & edematous
warm

Large swelling under
anterior wall of axilla
extending to inner third
of clavicle. Pulsation not
cystic but ~~not~~ best
marked at lower border
of pect major at outer
end. Considerable
ecchymosis

Pulse smaller & delayed
at left wrist.

Put up in plaster again
pending X-ray

Due to increase of pain &
swelling the man wished
for operation. He had
rather have died on the
field than suffer the agony
On Aug 15. Under chloroform
incision from centre of
clavicle along deltoid to
upper arm. Pect major cut
& compressed subclavian
All landmarks out of place
from the swelling. Much clot
evacuated. Artery O

found with great difficulty
found behind the artery
and outer cord

Artery ligatured

Patient collapsed

Salines intravenous

Art. respiration

Died two hours later

9

Milada Pablouich 23.
Place T. Vak 2.7.13.
Shrapnell.

Amf. for 2nd H. leg left
02. 10.7.13

Ant Post glaps. below knee

9

M. Stortch 47.
Place Korito 29.6.13
~~the~~ Bullet.

Abdomen.
entry back at 9th rib
~~at~~ scapular line
exit (removed) ^{by schuler} 3" outside
+ 2" below umbilicus left
side

now vomited blood.
lyg out 4 days
no food in mean time
very little water.
now get some pain when
he walks.

9 B. Janich 34.
Place Chapin Viss 11.7.13
Bullet. from left.
Phlegmon.
Injured. 18.7.13.
Baths

9 Givko Rodovanovich 40
Place & date not remembered
cramm bullet.
operated on.
Paralysis leg on face
abscess ~~at~~ at axilla.
incont. urine faeces.

hernia cruralis
formation
recovered Hadden
& rectum

♀

M. Pantuleh 23.

Kusbandul, 9.7.13.

Bullet. left foot

~~to~~ metatarsals

healed by 1st Aug.

♀

D. Antokhentch 42

Treshnovitk. Viss ~~at~~ 6.7.13.

Bullet. fract. tibia left
put in plaster. 20 July.
septic

♀ R. Petkovitch 23.

T. Vsk. 1.7.13.

Shrapnell? left wrist
& hand. septic.

Also. healed bullet
wound at wrist-malleolus

♀ M. Isailovitch age 25

Kochana. 5 July.

Shrapnell. Septic.

gluteal region lodged
near neck of femur.

Operation by me

Great pain in hip.

It turned out that the
wrong plate was given to me
He really had a bullet
in the gluteal muscles which
I extracted easily.

A'tonia Cause unknown
Oedema of ft. foot. fluid in
knee

♀ W. Gossipovitch 22

1st Op 7.7.13

Shrapnell? 11th rib left
side hands heath from
spine. Lodged septic

An X-ray was shown with
Shrapnell pellet in
left apex of lung!

Shrapnell lodged near
spinal column depth
not known

♀ M. Goranovitch 42

Treshniov Viss 8.7.13

Bullet - rt femur.
fractured mid third.

Master J.P.

♀ D. Ditch 35.

Bethi Bukva. 1st July

Bullet left leg

Gampsey.
Amput. below knee

ant post flaps

Septic.

Z

M. Mubishovitch 19.

Tsarov. Vis. 23.7.13.

Bullet - left foot - perfor.
mod septis.

Z Concussion

V. Prikitch 28.

Tsarov. Vis. 29.7.13.

small healed lacerated
wound on hip.

Stone or splinter.

Knocked unconscious by
a shell exploding in
a trench.

Pain in chest & legs

Z S. Stepanovitch 33.

T. Vuk. 26.7.13.

Bullet - left heel perfor.
no fract. clean

Z A. Lazarevitch 31.

Tsarov. Vis. 29.7.13.

Shrapnell flesh wound at thigh

Z

R. Neskovitch 32

Tasarev Viki. 30. 7. 13

Bullet. flesh wound
back. lumbar region to
axilla. healed.

Z M. Restitch 25.

Dukat 22. 7. 13.

Was 8 days in Vranica.

Shapnell? at post-
axilla lodged. mod
septic.Shapnell pellet removed
from under the scapular
muscles at ~~axilla~~ inf.
ang. of scapula left-
under eucaine 4/8/13

Z

A. Pavlovitch 38 July 21st

Selo Brodo 20. 21. night

Bullet. at back.
lodged. haemothorax
up to 7th in scap line.
cough.Coughed blood after
wound.1 1/2 notes from spine.
over 10 11 interspace

Shot in dark from behind.

Temp. Cough.

Evacuated after 2
unsuccessful attempts to
find pus by needle
Heart apex. 6th space.
Live. deposited 2 notes.

Eucaine did not act well.

Operation 1st August.Went in further depth
into villous fibrin.The reason for previous
failures was 1. too small
a needle. 2. not going in
deep enough so that fibrin
closed off the eye of the
needle.

6

Givan Rafilich 40+
Vashka Tchooka 7-7-13
Bullets at knee

- 1 through extensor tendon.
- 2 " head of tibia

Said knee been aspirated
pus + blood removed
knee swollen but ^{thickened} immovable.
T never over 35

6

Mutan Varsitch 33
Bregalnitza 30.6.13

Shrapnell?
Shoulder between acromion
+ neck midway

Plugged septic.
did not cough blood

Cannot abduct shoulder
very painful + stiff } ^{the more} good
To be x-rayed.

6 Tchedomir Nikovitch

Bregalnitza 30.6.13 23.
Shrapnell.

oral septic wound 1 1/2 below
cortic spine of scapula left
X-ray shows pellet
about apex of left lung.

A' thorax pyrexia
Aspirated 3 pints blood
removed.

Very emaciated.
Rash? septic

5 Aug. used vit. very foul
with tube heart was displaced
pneumo h. thorax

6. Budimir Nikovitch 22

Bregalnitza 30.6.13

Splinter from shell in eye
Shrapnell + left arm scars on
hairs shell
unconscious 1/2 hour

He was behind a rock which
was struck.

left arm was very swollen + then
began to feel on hand + fingers

Partial movement of fingers.
Hoarse condition of pharynx. ^{shortly} pain.
heaps catarrh

Total blindness of left eye.
splinter is sclerotic.

Atropin

6/
B. Milevsky ditzkovitch 24

Bregalntza 30.6.13

Shapnell (he says)

Compound com fracture
of ulna at mid + of third
segments removed

unable to move little
finger anaesthesia little
finger

6/
Iovan Kostitch 26
Bregalntza 30.6.13

Shapnell at femur

+ at elbow latter healed

^{1 1/2" deep}
just missed ulna nerve.

Old wounds in forearm

+ thigh at Bilot

Thigh opened for inflammation
by Iovanitch

2nd stab wound left eye
from childhood

knice at present thickened

6/
Georgi Ivanovitch 38

~~Ivan~~ Kirovskak 11.7.13

Bullet (he says Shapnell)

at hypogastrium level of
ant sup spine + center of
Poupart exit buttock
1 1/2 below + outside post sup
spine ilium.

Great pain in region

Wounds healed very slight

Tars ^{2 1/2" deep} post wound part burst open

5 Any + discharged pus

? Retrocaecal abscess

3/ Concussion
Vladimir Milosavitch 32
Tchervai Kamen 24.7.13
No wound. Feels pain in
legs, ears & chest. Bruises
have gone most were on chest.
He was kneeling & firing ^{he was firing}
in a trench. He says that
2 shells fell in the trench
& covered him with earth
unconscious 2 hours.
one man was killed
He bled severely from
mouth ears & nose.
Does not hear quite
well with at ear in which
he has hearing
At first he could not
see clearly but it is
now all right
for a week he had
trembling and now on 6.8.13
has fine tremor of hands.
Knee jerks normal
Trench was very long
(for whole regt.)

3/ Concussion ^(earth)
Mikhail Alexandritch 35
Tchupino Budo 20 July 13
No wound. Pain at end of
spine ^{neck} They were returning.
Two shells ~~fell~~ fell 1
in front ^(not burst) to be at
bank ^{4 or 5 metres} which killed 4 men
The one that did not
explode fell at 5 metres
and he standing was
knocked down by the
earth. He was unconscious
4 hours. 6.8.13
No bruises now but he says
there were when he was
at Kumanovo
He bled from mouth.
no where else.
No trembling
Knee jerks normal.

3

Mikoye Grumich

Struck by Starks of 33

Vilic Kollo 21.7.13

Old fashioned rifle
 was side to outer layer
 crater wound nearly to mid
 at outer side.

through soft parts
 leg.

6 down stairs - 29 July, later

Yovo Kostitch . 25

Bregatutza 18 July

Bullet

lay down firing

Shot from at flank behind

Entry healed 2.5 cc below

at mastoid at post edge

of st mastoid

exit healed through left

body mandible 2 inches

from angle of jaw

muscle floor of mouth

smashed teeth + jaw

Salivated. did not

spit much blood.

Could not eat or drink for
 4 days.

Petar Milenkovich 40

Tzemi Ramen 23 July 13

Shrapnell left tip of

thumb hypothermia

eminence. forearm

+ elbow

In hospital at Mikoye's

Phlegmon. Incision

the doctor wished to amputate

but he refused.

Very foul. arm. discharge

pus disorganized elbow joint

Useless. Very emaciated.

+ worn

operated on to drain

Amf 4th Aug see below.

6 Mikoye Vonjatchitch

Montenegro 23

Goodare 23 July 13

Bullet healed

left foot. middle cuneiform

on 1/2 tip to centre of

plantar aspect of heel

nothing wrong.

5th Aug well washed out with saline

in aft. rejoin letter evening

rejoin in night. Amf mid human

circular Saline Oil with geron

after nearly died in ward.

5th Aug Hemisium digitalis Brandy.

5th Aug still alive. no worse

Died 11.30 5th Aug

Toxaemia.

6. Blagoje Ružičević

25

Wtup. 2 July 13.

Shell + splinters.

left ant aspect of
leg much bruising
& laceration. not
dressed for 5-days before
admission

gangrenous looking.
incised & cleaned.
no general infection

6. David Mitrović

25

Wtup. 2nd July

stones & earth at leg
shell burst 5 or 6 metres
superficial septic
abscess

6. Dragomir Pejovitch

Tserni Ramen. 30.

Bullet-

Rt calf. perforating.

Pugged & full of
pus from Brandzelovaz
Drainage tubing.

6. Peter Ivanovitch

Montenegrin

Bregalnitsa. 19 July.

Bullet- entry over heifer
1" below ant. ax. fold
exit triceps & fingers loose
no bone hit

pulse on left at wrist & above
very feeble. as comp with rt.
edema of forearm.
some loss of sensation at
end of rt thumb.

5 Vlastimir Perjitch

23

Prevalent 30 June

Shrapnell

1. left leg. paralysis cal pop.
healed.

2. shoulder left.

3. r in leg amputated.
gangrene. ant & post
flaps very bad.
no rebelling of bone.

Bed sore

Tovarnitch said he had an aneurism.

5 Svetozar Zoujevitch

43

Saitchan 8 July

Right thigh fractured
Bullet?

Plaster of Paris.

Ran a very high temp
for a while cause

unknown. no
trouble at wound

5 S. Ditch 24

Stef

4 July

Shrapnell. through humerus
muscles

and another lodged
in knee left. X ray
shows nothing.

Knee was aspirated
apparently ~~no~~ blood.
Joint painful thickened
& stiff

5 Milosav. Gijostitch

43

Saitchan 8 July

Shrapnell

Fract humerus below

deltoid

exit
Sapin wound septic
P.O.P.

entirely healed.

5

Shaptn. Fetotitch 25
Tzarevo Selo 29 July
Bullet
along ulnar left.

→ →

no fracture
mod clean hit
arm swollen.

6. Milenko Petrovitch

24

Bregalinitza 30 June
Shrapnell jagged over
cardiac region.

Bullet 1 below knee ^{head of}
soft parts through

2. front of ft back
left. in cont fem an
out middle third of
thigh. behind bone
ft sciatic affected
pain to sole +
weakness of ext pop
some numbness over
dorsum of foot.

to Baths

6

Jagged in on
wounds back of thorax
? Shrapnell - he
says bullet.

6. Tepta. Yotvitch 26

Tzarevo Selo. 29 July

at thumb

bullet.

~~cut~~ base of thumb
emission. upper end
out back between
finger + thumb
through adductor
muscles.

Septic ~~fracture~~

~~sl. fracture~~ ~~some~~ ~~away~~ splintering

6. Perf. buttock
healed.

6. Georg Kovatchevitch

Vlassia 8 July 38.

Shrapnell buttock at
+ fragment of shell. latter
only lodged extracted
in Div. d. station became
very septic + had to be
slit.

6 dose. later 10 Aug

Milosh Jovkovic

River Bonka. 16 July ³⁸

He says Shapnell

I think granate

Unconscious 1 hour

bled a lot.

Entrance large superficial
on inner aspect of forearm

Exit explosive

post aspect. $2\frac{1}{2} \times 4$

in center is a hole into

which 3 fingers can be
placed.

Very septic

20 days in Vaanga

5 days in 7d. Hosp.

2. on train here

X ray radius fractured

+ lower fragment
turned in overlapping
the ulna.

Lower fragment fused
into portion under $C4\ C5$

6 dose

Vidak Voutchclitch

Montenegro 20

Bregalnica 15.7.13

2 bullets

1 perf chest at side

1 ent.

on arm at lower border
of pect major

both healed.

Some difficulty

Complained off

in breathing

at side dull.

No temperature

6
Svetlan

Tzvetan Stphanovitch

40

Zletovo 2 July

1 Bullet thigh ent
ent to hips tendon exit
in pop. space.

2. ? Shapnell. left buttock

no apparent exit

passed much blood

$1\frac{1}{2}$ liter 2 hours after

ent $\frac{1}{2}$ way between ent

post spine + st trochanter.

6. dble. ~~131~~ 16 Aug
tath

Petho P. P.itch 22

Sovidiyé Prdo 22 July

Bullet. Rt thigh
wounds healed.

cut $2\frac{1}{2}$ " above adductor
tubercle and a line

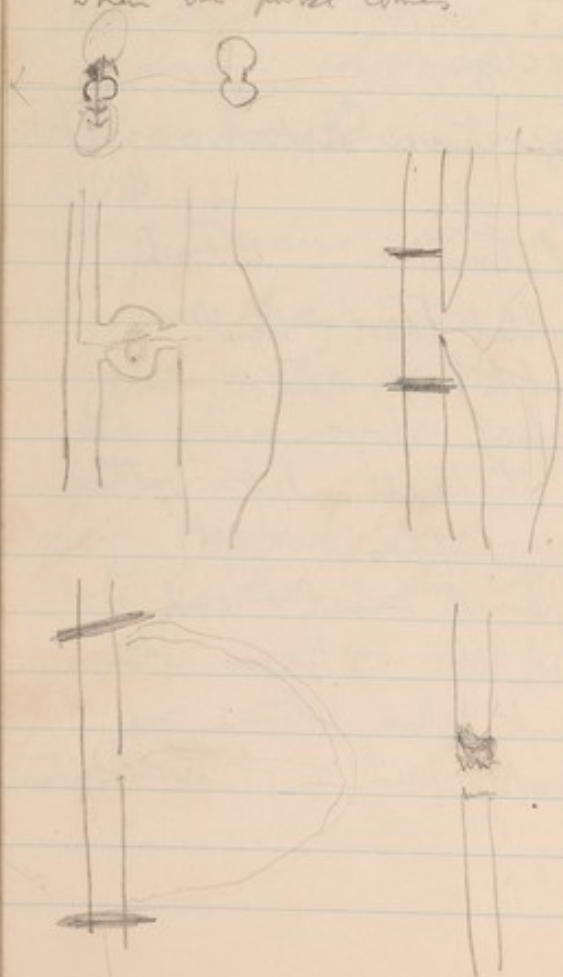
of add magnus.

exit outside just
behind biceps tendon a
hand's breadth above head
of fibula.

Ext pop. cut deep foot.

Echymosis at back of
leg.

Constant hunt with accubation
when the pulse comes.



slight redness of leg &
ankle

sensation gone over outer
side of foot. Pulse 96

No apparent blueness of
limb. or change of temperature
Splint-

6 sore.

Wound. calf perforating.
Discharged to foot from
some other place
with the wound plugged
& leg full of pus
attributed to this place

Sketcher

handles telescope 9"

22" wide

6' long when handles in.

3 fixed iron curved
traverses.

Canvas faced. brown mat.

sloping head end on

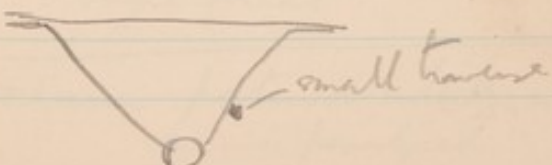racket's + pillows stuffed

on ^{iron} ^{handles} ^{small} ^{wheels}

Runners on small

wheels $7\frac{1}{2}$ " from ground

to top of sketcher.



Rusmanovitch
axillary traumatic
aneurysm.

Milan Milozanitch
ovche polye. 33
billet. 1st July
popliteal traumatic
aneurysm ^{at side} drop foot

ent. outside of knee.
exit 5 miles above on
inner side.
Op. Schuler.

Other Cases

Abdomen

Rt flank to left through left
thac bone Died.

Abdomen

Rt thorax to left hypogastric
bullet ext in abd. wall.

Pelvis

Left ing region ext to vessels
to rt ischio rectal fossa

Thorax 2" below rt clavicle
through scapula. part paralysis
arm.

Abdomen

1" above + outside ~~at~~ of
umbilicus through sacrum
no symptoms.

Scalp. furrow. no
symptoms.

Abdomen. 8th rib right
costal margin healed lodged
no symptoms.

Cheek shrapnell
superficial.

Forearm posterior interosseous
nerve paralyzed

Abdomen superficial
near umbilicus.

Scalp. no bone lesion

Lip to upper jaw exit.

Thorax. exit scapula.

Iliac bone to hypogastrium

Contusion from shell
burst (concussion)

Neck entry inner side
of left st-mastoid at
level of cricoid exit at
inner end of spine of
scapula.

Toes 4 + 5th perforated
by 2 bullets.

Heel. oblique perforation
of os calcis.

Finger 5th cut off clean
? self inflicted.

(two with blackening on
fingers.)

Calcium + iliac bone.

Left buttock - perinaeum
it leg 4 holes
fame in at sole.

Lobule of left ear to rt
sup maxilla. left
facial paralysis.

Instep to heel no symptoms


Rt side of nose to left
orbital margin eye
excised.

**A number of blank pages follow
and have not been photographed.**

Operations

Amputation finger prox. ph.

Exploration of Cranium.



$$\begin{array}{r} 39.5.9 \\ \hline 5 \overline{) 3555} \quad n.8 \\ \underline{75} \\ 82 \\ \hline 8 \end{array}$$

