

**Ms catalogue of drawings, casts, prints, paintings, etc. (in Fort Pitt, Chatham, Kent), of anatomical details including details of cases**

**Publication/Creation**

19th century

**Persistent URL**

<https://wellcomecollection.org/works/u42kj7b7>

**License and attribution**

You have permission to make copies of this work under a Creative Commons, Attribution, Non-commercial license.

Non-commercial use includes private study, academic research, teaching, and other activities that are not primarily intended for, or directed towards, commercial advantage or private monetary compensation. See the Legal Code for further information.

Image source should be attributed as specified in the full catalogue record. If no source is given the image should be attributed to Wellcome Collection.




Wellcome Collection  
183 Euston Road  
London NW1 2BE UK  
T +44 (0)20 7611 8722  
E [library@wellcomecollection.org](mailto:library@wellcomecollection.org)  
<https://wellcomecollection.org>

29

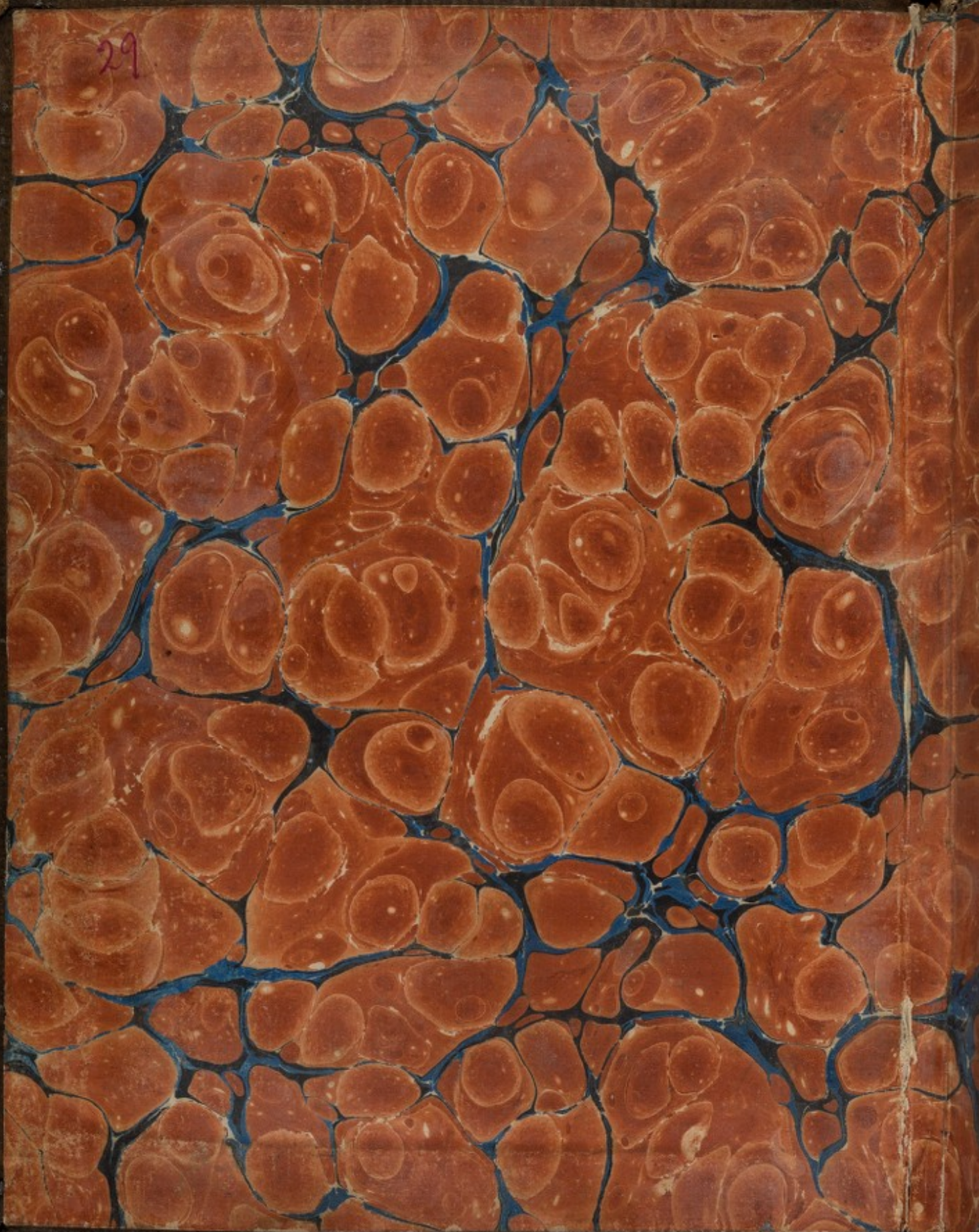
CATALOGUE  
PAINTINGS. DRAWINGS  
PLATES. CASTS.  
VOL. I.



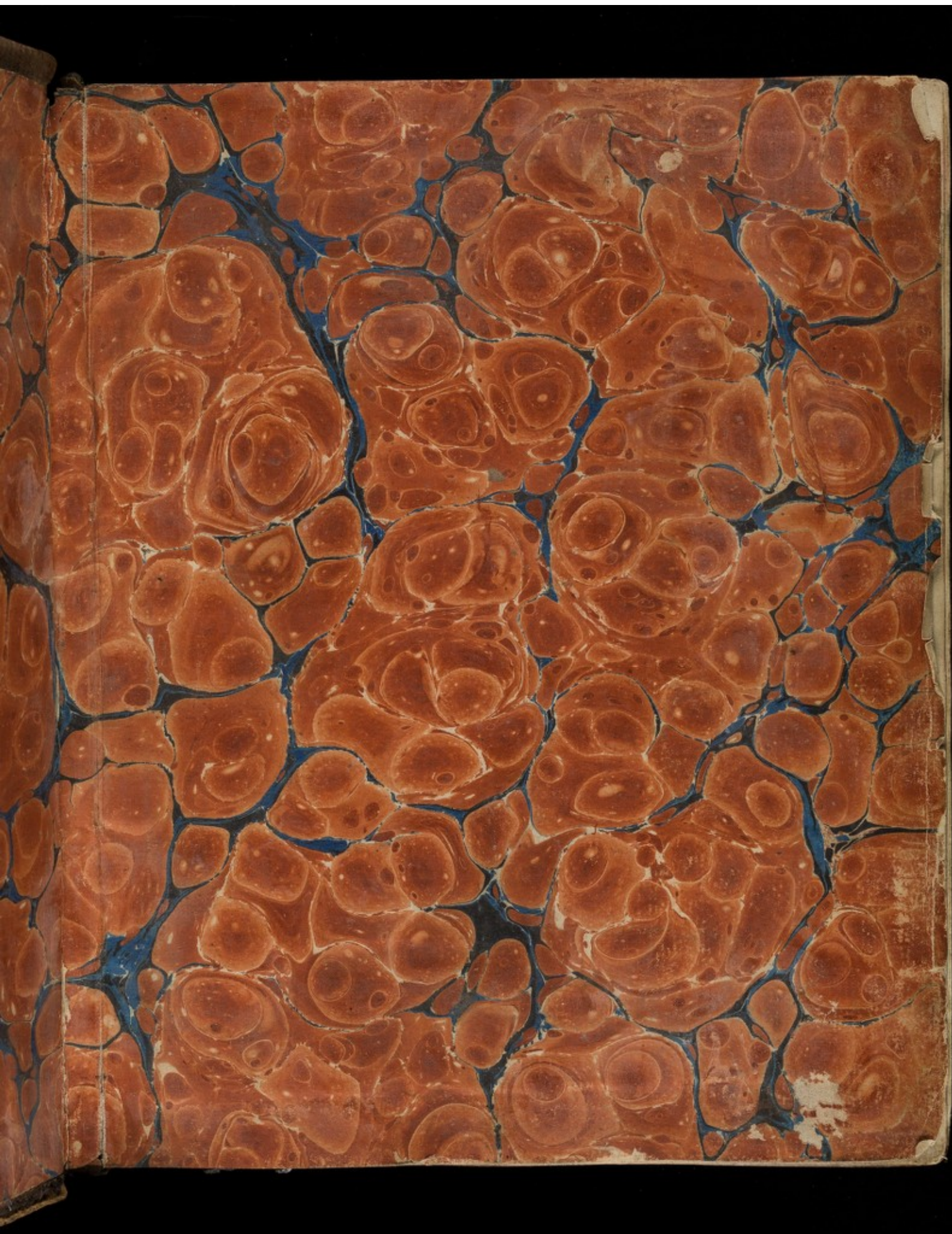





29













RAMC | 29

(5-52)




Drawings in Morbid Anatomy	page 1
Paintings in ditto	181
Casts in ditto	285
Prints in Morbid Anatomy	377

---

Drawings in Natural Anatomy	94
Paintings in Ditto	247
Casts in Ditto	285
Prints in ditto	423
<del>Casts of Crania of different Races</del>	<del>297</del>
Casts of the Crania of distinguished persons	305
Casts of the Crania of Criminals	315
Portraits	281
Miscellaneous Prints	409
Drawings	163



4  
y  
3  
8  
15  
61  
9  
3





# Drawings

in

## Morbid Anatomy

1 Exhibits an internal view of the Larynx and Trachea with a fistulous external opening between the Thyroid and Cricoid cartilages and a highly inflamed state of the mucous membrane. Bengal - Presented by Dr Brown Surgeon 87<sup>th</sup> Regiment

From Thomas Fullerton 87<sup>th</sup> Regiment who in an attempt at suicide divided the Larynx with a razor. The wound healed with the exception of the opening shown in the drawing. The patient died a month afterwards of acute Bronchitis brought on by the continued irritation produced by the opening.



2

- 2 Exhibits the appearance of the Trachea and Bronchia  
✓ in acute and Chronic Bronchitis Fort Pitt — Drawn and  
presented by W Schetty, Deputy Inspector General of  
Hospitals

- 3 a Tuberculated Lung, with a vomica of considerable size  
with tough smooth parietes. — Ibid — Drawn and  
presented by the same. From a patient who died of Phthisis

- 4 a Represents Lungs in a very advanced stage of tubercular  
degeneration: with vomices of various sizes: one of great  
extent. — Ibid — Drawn and presented by the same.  
In Lobby

- 5 Exhibits the pericardium and surface of the heart in  
carditis. Ibid — Drawn and presented by the same  
✓ From the same subject as No 31 flaps Circulation  
Division 1

- 6 Enlargement of the Heart and adhesion of the  
✓ Pericardium to its substance: The right auricle and  
ventricle laid open — History unattainable

- 7 View of the interior of the left auricle and ventricle  
✓ of the same Heart



- 8 ✓ View of the cavity of an Aneurism of the Aorta - History  
Unattainable
- 9 ✓ External view of a carotid Aneurism. Draw and  
presented, by M<sup>r</sup> Stralford Assistant Surgeon to the Forces
- 10 ✓ Represents a diffused Aneurism of the Popliteal Artery  
(Vide N<sup>o</sup> 60 Plaf 1. Circulation. Division 2) - Drawn  
and presented, by M<sup>r</sup> Rolland Assistant Surgeon  
4<sup>th</sup> Regiment
- 11 ✓ An Instrument for the Torsion of Arteries - Hamburg  
— Drawn and presented by the same
- 12 ✓ External and internal view of the effect of Torsion of  
Arteries - Ibid
- 13 ✓ Stricture of the Oesophagus near its termination  
in the Stomach: accompanied by excrescences growing  
externally from the Duodenum - Ireland
- 14 ✓ Another view of the same: with part of a soft fungous  
excrescence growing from the internal surface of the  
Stomach at its Cardiac Orifice. Ibid. Both Drawn -



4  
14

and presented. by D<sup>r</sup> Brown Surgeon 2 Dragoon  
Guards

In this case: the Stomach was highly vascular: the  
inferior extremity of the Esophagus was thickened and  
discoloured for about three inches tapering gradually  
downwards to the Cardia: where it was so constricted  
as to admit with difficulty the passage of the smallest  
catheter: The fungous excrescence represented in  
the second drawing grew from the Cardiac portion  
of the mucous tunic of the Stomach: it was about  
ten inches round at its outer edge: and half an inch  
thick in the centre: gradually becoming thinner  
towards its circumference, and resembled a longitudinal  
section of a bunch of grapes at half growth: There  
was also a morbid enlargement of the Ductus  
Communis Choledochus produced by a fungous  
growth at its entrance into the Duodenum: Two  
opaque caseous excrescences likewise, grew from and  
were firmly attached to the same focus, by broad  
vascular bands: the base of the largest being  
moreover fastened to the Cardiac end of the Stomach  
by a fine pellucid membrane spread along its  
upper curvature



- 15 ✓ View of the peritoneal surface of a portion of the Spleen exhibiting inflammation, and granular effusion of lymph. — Chatham Drawn and presented by Mr. Rolland Assistant Surgeon 4<sup>th</sup> Regiment — History unattainable
- 16 ✓ Represents a portion of the Spleen strangulated in an abnormal aperture of the mesentery — History unattainable
- 17 a Exhibits the appearance of a patch of peritoneal inflammation of intestine: also of an ulcer of its mucous tunics\*
- 18 a Perforation of the Paries of the Cecum from ulceration History unattainable.
- 19 ✓ Portion of colon — showing increased vascularity of its mucous membrane, and small circular ulcers having a pustular character: the inner surface of the Rectum studded with similar ulcers: and a part of the lining tunics of the Spleen in which well defined ulcers also exist. — Drawn and presented by Mr. Rolland Assistant Surgeon 4<sup>th</sup> Regiment  
Taken from a child who died of small-pox

---

\* Drawn and presented by Mr. Rolland Assistant Surgeon 4<sup>th</sup> Regiment. History unattainable



- 6
- 20 Stomach and Duodenum—exhibiting the effects of  
poisons—Edinburgh—presented by D Macintosh  
✓ From N<sup>o</sup> 2 Class 2 Digestion, Division 2
- 21 Exhibits the morbid condition of the Colon contrasted with  
✓ the comparatively healthy state of the jejunum—*Ibid*  
Presented by the same.  
Taken from the same subject as the preceding
- 22 Shows the state of the termination of the Colon and whole  
✓ of the internal surface of the Rectum also the appearances of  
the gums after death—*Ibid*—Presented by the same  
From the same subject as the two preceding
- 23 Portion of the Liver—its external surface, discoloured and  
✓ granulated History unattainable
- 24 Variolar Pustules—Edinburgh—Drawn and presented  
by Mr Holland Assistant Surgeon 4<sup>th</sup> Regiment
- 25 Pustular Eruption, accompanying vaccination. *Ibid*. Drawn  
and presented by the same  
From the Wife of a soldier of the 92<sup>d</sup> Regiment, who  
two days after vaccination was attacked with vomiting and



25

pain in the limbs: On the ninth day the vaccine vesicles appeared on the arm: and on the thirteenth the eruption delineated in the Drawing made its appearance

26

The Face of an infant covered with the pustules of confluent small pox in an advanced stage. Drawn and presented by Mr Holland Assistant Surgeon 4<sup>th</sup> Regiment

27

Exhibits a papular eruption: connected with Syphilis —  
— Edinburgh — Drawn and presented by the same  
From a soldier of the 74<sup>th</sup> Regiment who had been treated for primary Syphilis with Mercury — two months afterwards the eruption here delineated made its appearance and at the same time he was attacked with Ulcerations in the Septum narium; and in the Pharynx.

28

Presents confluent variolar Pustules on the back of the hand. Chatham — Drawn and presented by the same  
From Corporal William Ray Grenadier Guards. Oct 31  
A case of severe small pox which terminated favorably

29

Acne punctata, extensively spread over the back — Chatham  
Drawn and presented by the same  
From Michael Glynn 5<sup>th</sup> Regiment a fair young man of fair



29 complexion. The eruption had appeared some time before and slowly increased

30 Represents Herpes Zoster on the side in an advanced stage. Fort Pitt. Drawn and presented by the same  
 From William Turner 14<sup>th</sup> Regiment at 40. who  
 ✓ was admitted with this cutaneous affection extremely well marked. It was ushered in by considerable fever. The drawing was not made until the vesicles having matured and scabbed had lost their characteristic appearance

31 Pustular eruption on the upper part of the face —  
 ✓ — Edinburgh. Presented by W. Lyons Surgeon to the Forces

From a Soldier of the 92<sup>d</sup> Regiment who had been vaccinated in early life

32 a Presents small Abscesses, with livid integuments  
 ✓ surrounding them in different parts of the body. Ibid.  
 Presented by the same

From a young soldier of the 94<sup>th</sup> Regiment — The disease was accompanied by marasmus: the abscess terminated in ill conditioned ulcers



33 Exhibits Abscess in the right hemisphere of the Brain —  
 — Fort Pitt — Drawn and presented by Mr Schethy  
 Deputy Inspector General of Hospitals  
 From No 4 Class 3 Sensations Division 1

34 External appearances of the left hemisphere of the Brain —  
 — exhibiting venous congestion on the surface and a portion  
 of Dura Mater adherent: also an internal section of the  
 same in a state of softening with bloody puncta effused  
 into its substance — Edinburgh

Taken from a Lady who died three weeks after child-  
 birth. The longitudinal sinus was almost obliterated  
 near the point of lesion seen in the drawing. by thickening  
 and induration of its parietes; and an exudation of  
 lymph. mixed with a hard coagulum of blood  
 which led to the enlargement of veins beyond the  
 obstruction. — These were filled with coagulated blood  
 and their coats thickened and inflamed. Rupture  
 had taken place in many points on the surface  
 and also in the substance of the Brain itself.

35 Inflamed Membranes of the Spinal Chord. Fort Pitt —  
 V Drawn and presented by Mr Schethy Deputy Inspector  
 General of Hospitals



35 From John Owen 13<sup>th</sup> Light Dragoons who having received a contusion on the loins by a fall from his horse became paraplegic. He lingered in this state above a year, and sunk at length from an accumulation of sloughing bed sores. After death on laying open the Spinal Canal it was observed that the Medulla Spinalis was unusually soft and at the situation of the first dorsal and two lower cervical vertebrae, the theca was discovered to be at least twice its natural thickness and morbidly vascular, whilst the medullary matter of the chord itself was converted into a dusky semi-transparent yellowish substance, somewhat resembling paste or jelly both in its colour and consistence (Vide Fasciculus of Anatomical Drawings from the Museum of the Army Medical Department Plate 2 fig 1)

36 Exhibits dense cataract of the right eye. Ibid.  
Drawn and presented by Mr Holland Assistant Surgeon 4<sup>th</sup> Regiment.  
From a Soldier of the 93<sup>rd</sup> Regiment in whom the disease had been many years forming

37 An opaque cataract of the right eye with adhesion of the pupillary margin of the Iris to the capsule. Ibid



- 37 Drawn and presented by the same  
From John Flannson 95<sup>th</sup> Regiment sent home from Bermuda  
with this disease the result of ophthalmia which was brought  
on by the accidental application of paint to the eye
- 38 Transparent Staphyloma of the left cornea Ibid  
Drawn and presented by the same  
From John Ford 9<sup>th</sup> Regiment Oct 27 The consequence  
of an attack of Ophthalmia in the West Indies
- 39 Exhibits Leucoma of the left cornea Ibid. Drawn and presented  
by the same. History unattainable
- 40 Presents extensive Caries of the franium and bones of the face  
Edinburgh. History unattainable. Presented by D Stewart  
Surgeon to the Forces
- 41 Represents a Fracture of the left Parietal bone. Glasgow. History  
unattainable
- 42 Fracture to a considerable extent in the left side of the base of the  
franium. Ibid  
From the same subject as the preceding



- 43 Exhibits deficiency of the greater part of the right parietal bone  
the brain exposed— Presented by Mr Armstrong Surgeon to  
the Forces

From R Hollyhock: This bone was removed by operation for  
the cure of long continued headache after a fall on the  
head, but without any beneficial result

- 44 Exhibits a penis— its external prepuce covered with large clusters  
of verruca— Fort Pitt

These excrescences form the subject of Preparation No 11—  
Plaf 4— Division 1

- 45 Exhibits favcinoma of the Testis, and Scrotum— Ibid— Drawn  
and presented by Mr Rolland Assistant Surgeon 4<sup>th</sup> Regiment  
This disease forms the subject of Preparation No 27 Plaf 4 Division 1

- 46 Presents a more advanced stage of the same— Ibid— Drawn  
and presented by the same

- 47 Induration enlargement and discoloration of the Scrotum  
with fungated ulcer rising from the right testicle— Ibid— Drawn  
and presented by the same

From a soldier of the 2<sup>nd</sup> Regiment who was admitted  
with disease of the testicle



- 48 Exhibits ulceration induration and discolouration of the Labia pudendi—Edinburgh—Presented by D<sup>r</sup> Macintosh  
 ✓ From a Child between three and four years of age—the disease appeared six weeks after an attack of measles which had been attended with much pulmonary and intestinal irritation, and proved fatal in fourteen days
- 49 Anterior view of Elephantiasis of the Labia pudendi Barbadoes—  
 ✓ Presented by D<sup>r</sup> Dease Surgeon to the Forces  
 This disease forms the subject of preparation No 4. Class 4. Division 2
- 50 Posterior aspect of the same mass:—Ibid—presented by  
 ✓ the same
- 51 Exhibits the state of the Labia immediately after the  
 ✓ removal of the morbid growth—Ibid presented by the same
- 52 Shows the parts of generation after the final healing of the wounds  
 ✓ made in the operation
- 53 Exhibits dorsal abscess connected with ulceration of the Vertebrae—  
 Fort Pitt—Drawn and presented by M<sup>r</sup> Schethy Deputy Inspector General of Hospitals Lobby  
 From Bennard M<sup>r</sup> Farrar at 23 50<sup>th</sup> Regiment a feeble scrofulous



subject admitted for fistula in perineo. A slight curvature in the dorsal region of the spinal column was perceptible and tumefaction but without sense of fluctuation to the left of it. No alteration of this state of things took place until his death which followed an attack of acute Bronchitis. On examination a large abscess was found seated on the front of the spine, extending from the sixth Cervical to the eighth dorsal vertebra and containing eighteen ounces of purulent matter.

The Aorta and Oesophagus were thrown in front of this large sac: the bodies of the dorsal vertebrae were in a carious state: and the intervertebral substance was in the same degree absorbed (vide Fasciculus of Anatomical Drawings from the Museum of the Army Medical Department Plate 1)

L. Lobley

54. Internal view of diseased knee-joint Drawn and presented by the same L. Lobley

55. Hypertrophy, with dilatation of the heart and tubercular formation in the substance of its parietes—Edinburgh—presented by Dr Macintosh

From a woman between twenty and thirty years of age, of vicious habits who expired suddenly, without previous indication of disease having been always represented as a remarkably healthy person



56 Front view of a Monstrosity consisting of the junction of the  
 ✓ superior parts of two female Foetus — Malta — Draw  
 and presented by Dr Calvert Deputy Inspector General  
 of Hospitals

✓ 57 Back view of the same Monstrosity Flid Drawn and  
 presented by the same

58 Exhibits phagedenic ulceration of the left groin: knee  
 and foot sphacelated: Edinburgh — Drawn and presented  
 by Mr Holland Assistant Surgeon 4<sup>th</sup> Regiment  
 ✓ In this case the femoral artery ulcerated and was tied  
 above Poupart's ligament. The Patient died twenty  
 days afterwards: of mortification of the knee and foot

59 Malignant ulcers on the nose, cheeks, and upper lip Drawn  
 ✓ and presented by the same

60 Tongue exhibiting morbid secretion Fort Pitt Drawn and  
 presented by the same

✓ From Sergeant Morant 46 Regiment a phthisical patient, taken  
 to show the state of the tongue in that disease. The edge of a crimson  
 colour its centre white, furrowed and rough



- 61 Exhibits left of all the toes. with ulceration and exposure of the metatarsal bones: the effect of congelation. Fort Pitt - Drawn and presented by the same  
 ✓ From George Bateman a negro. whose feet were frost bitten on his voyage to England
- 62 Malignant ulceration of the lower Jaw - Drawn and presented by the same  
 ✓
- 63 Shows the inner aspect of a lower extremity affected with  
 ✓ Fungus haematodes - Drawn and presented by the M<sup>r</sup> Leslie
- 64 Outer view of the same case - Drawn and presented by  
 ✓ the same
- 65 Fungoid Tumour of the elbow - London - presented by  
 ✓ M<sup>r</sup> J Berry Surgeon to the Forces  
 From the case which forms the subject of preparation N<sup>o</sup> 4  
 Class 6
- 66 <sup>a</sup> Appearances of a pestilential Carbuncle - Malta - Drawn and presented by D<sup>r</sup> Calvert Deputy Inspector General of  
 ✓ Hospitals  
 From one of the cases which occurred in 1813



67 Extensive sarcomatous Tumour in the mouth - First  
 Pitt Drawn and presented by Mr Holland Assistant Surgeon  
 & Regiment  
 From Patrick Jordan 41<sup>st</sup> Regiment invalided from India  
 on account of a tumour in the mouth occupying nearly the  
 whole of its cavity and sending processes downwards to the back  
 part of the Pharynx. it apparently had its origin in the left  
 antrum maxillare; it was firm, somewhat moveable and divid-  
 ed into two portions by a deep fissure

68 The same in a more advanced stage. Ibid Drawn and  
 presented by Mr Ware Surgeon 74<sup>th</sup> Regiment

69 a Ulceration of the toes and sole of the foot - Ibid Drawn and  
 presented by Mr Skelley Deputy Inspector General  
 From Peter Lavers et 25 who was admitted with ulcers on  
 the Penis, followed by ulcerations of the tonsils and pustular  
 eruption: The disease on the foot appeared while the patient  
 was under the influence of Mercury but did not heal on its  
 omission (Vide Fasciculus of Anatomical Drawings from the  
 Museum of the Army Medical Department Plate 4 fig 2 & 3)  
 In Lobby

70 Congenital Tumour protruding on the left arm of a child  
 Pratham Drawn and presented by the same



- 70 From John Holloway aged 14 days son of a soldier of the Royal Sappers and Miners. At birth it was about half the size here delineated which was as follows — length  $4\frac{1}{2}$  inches circumference 11 inches — external surface  $5\frac{1}{4}$  inches

In Lobby

- 71 a Large Tumour protruding from the forehead and nose — Edinburgh — Presented by the same

This was a case of congenital deficiency of the ethmoid and orbital portions of the frontal bone with serous effusion projecting from within the Cranium analogous to Spina Bifida. The external appearance resembled fungus haematodes

In Lobby

- 72 Encephaloid Tumour growing from the right side of the head accompanied by an enormous fissure in the palate. —

Ghathann — presented by Mr Pargeter

From the child of corporal Blackwood Royal Sappers and Miners. The head was of a conical shape the tumour resembling a kidney being  $11\frac{1}{2}$  inches in its longest surface and eight in its lateral superficies. It was soft and pulpy to the touch: without pulsation and of low temperature: it appeared to contain the greater part of the Cerebrum. The orbicularis muscle of the right eye was exposed: the eye itself disorganised. The left was also imperfect: the palate was divided from the extremity of the nose by a fissure directly back to the Pharynx. the velum



72 pendulum, uula, and torsels were all deficient: The nose had a horny prominence near its extremity: The tongue was thick and large. There were also malformations of the fingers and toes some wanting phalanges. Others partially or entirely deficient in nails: Other having interdigital membranes like webfooted animals— The child lived 45 days

73 Exhibits Chancre on the Penis with extensive ulceration on the right groin— Drawn and presented by Assistant Surgeon Stewart 28<sup>th</sup> Regiment

The sore in the groin measured eighteen inches reaching from the superior spinous process of the Ilium to the verge of the anus. It ultimately healed. In Lobby

74 Tumour situated on the left side— Fort Pitt Drawn by M<sup>r</sup> Dodson (Wide flaps 6 N<sup>o</sup> 12\*) In Lobby

75 Polypus of the Antrum Maxillare Ibid Drawn and presented by M<sup>r</sup> Schetty Deputy Inspector General of Hospitals. From the same subject as N<sup>o</sup> 88 flaps 3 Locomotion Division In Lobby

76 Carcinoma of the cheek— Fort Pitt Drawn and presented by the same

---

\* From the same case which forms the subject of preparation N<sup>o</sup> 12 flaps 12 b but taken at an earlier stage.



76 From the same subject as preparation 87 - (Lap 3 Division 1)  
In Lobby

77 - Cancer of the under lip six lobulated - Ibid. Drawn and presented by the same

In this case the lymphatic glands in the neck were much enlarged  
In Lobby

78 Pus situated in the subarachnoid cellular serous tissue of spinal marrow and cerebellum - Presented by Dr Pitcairn Assistant Surgeon 58<sup>th</sup> Regiment

79-80 & 81 Three views of apoplexy of the spinal chord - Presented by the same

82 Two views of arachnitis with tubercles - Presented by the same

83 Drawing of apoplexy of the Heart - Presented by the same

84 Two Views of perforations of the intestines - Presented by the same

85 Two views of perforation of Encond Cartilage which occurred in consequence of disease - Presented by the same



- 86 A Drawing of a Rupture of the Aorta into the Oesophagus.  
Presented by the same
- 87 View of an Aneurism of the arch of Aorta - Presented by the  
same
- 88 A Drawing of the Abdominal viscera in a state of Gangrene  
Presented by the same
- 89 Elephantiasis of the left leg Presented by the same
- 90 Tumour of the Maxillary Antrum Presented by Staff Assistant  
Surgeon Dartnell
- 91 Tumour of the Antrum Presented by the same
- 92 Represents a Dwarf (a native of India) remarkably deformed  
Presented by the same
- 93 Aneurism of by Anastomosis situated in the region of the  
right malar bone - Presented by the same
- 94 A Drawing of Purpura Haemorrhagica (coloured) Case of James  
Craig 2<sup>d</sup> Queens Royals. Vide Surgical Register. N<sup>o</sup> 78 - folio 63)



95 A Drawing represented a large abscess in the upper part of the thigh— Connected with a lumbar abscess— Wm. Mealy 89<sup>th</sup> Regiment— see— Surgical Register No 78— folio 63 — Presented by the same

96 Exhibits a remarkable deformity of the face caused by a gunshot wound— Presented by the same

97 A coloured Drawing showing great vascularity and numerous ulcerations in the interior of the Trachea: The upper part of that tube has been perforated by one of these ulcerations Presented by the same

98 A coloured Drawing exhibiting complete agglutination of the intestines to each other, and the peritoneum lining the parietes of the abdomen— Many crude tubercles are seen on the external surface of the intestines— Presented by the same

99 A coloured Drawing showing the peritoneum, thickened, and much tuberculous matter deposited in its substance— also complete agglutination of the intestines with each other, and many tubercles on their surface— Presented by the same

100 A coloured Drawing exhibiting a small aneurism at the apex of the left ventricle— Presented by Mr J McDiarmid




- 100 Exhibits - the foramen Ovale unclused Presented by the same
- 102 Shows a large aneurism of the abdominal aorta. which contained which about 20 pounds of coagula. Presented by the same
- 103 Luxation of the head of the femur into the Ischiatic notch with fracture of the posterior side of the rim of the acetabulum Presented by the same
- 104 A cranium exhibiting deficiency of part of its parietes — Presented by the same
- 105 Exostosis of the Tibia — Presented by the same
- 106 Osteo-Sarcoma of the upper part of the humerus — Presented by the same
- 107 A view of certain parts of the human ear — Presented by the same
- 108 A coloured Drawing exhibiting inflammation of the parenchyma of a lung which is studded with tubercles — Presented by Dr Williams Surgeon 63<sup>d</sup> Regiment



- 109 A coloured Drawing exhibiting inflammation of the  
glottis accompanied with ulceration — Presented by the same
- 110 A coloured drawing exhibiting encysted hydrocele of the  
Spermatic Chord — Presented by the same
- 111 A coloured drawing exhibiting elongated adhesions between  
the Pleura Costalis and P. Pulmonalis
- 112 & 13 — Two coloured drawings taken from the same individuals  
Capt Pat<sup>r</sup> Gibbons 68<sup>th</sup> Regiment. They show one of the cutaneous  
forms of secondary syphilis — Presented by the same
- 114 A coloured drawing exhibiting the appearance which  
the heart presents in Purpura Haemorrhagica —  
Presented by D<sup>r</sup> Dyce — Staff Assistant Surgeon Maidstone
- 115 A coloured drawing a dissection of the parts connected  
with Varicose Aneurism — Presented by the Nephew of the  
late Sir William Franklin
- 116 Another view of the above — Presented by the same
- 117 Coloured drawing exhibiting inflammation, ulceration and



- 117 gangrene of the left colon. Presented by Aps<sup>t</sup> Surgeon Steel, 1<sup>st</sup> Dragoon
- 118 Coloured Drawing illustrative of gangrenous state of the same viscus— Presented by the same
- 119 A drawing showing the consequences of a wound of the Rectum— Presented by Assistant Surgeon Thom 11<sup>th</sup> Regiment
- 120 A water-colour drawing of a portion of the colon exhibiting many ulcers in a granulating state in the interior of that gut— also a sloughing condition of certain parts of the mucous membrane— Presented by Staff Aps<sup>t</sup> Surgeon Courtenay
- 121 A water coloured drawing showing carcioid pustules &c in the interior of the Larynx and Trachea— Presented by Assistant Surgeon Holland—
- 122 Two coloured views of a heart of which the ventricle is dilated presented by Surgeon Callow— Inniskilling Dragoons
- 123 A large coloured drawing 



- 124 Exhibiting Vaccinia in two sisters - Presented by  
Mr Williams Surgeon 68 Regiment
- 125 Exhibiting Syphilis consecutiva. Presented by the same  
From Private William Ford: 68 Regiment
126. Indurated thickening of the prepuce with ulceration  
Presented by the same  
From Private Thomas Stanley 68<sup>th</sup> Regiment
- 127 Coloured Drawing exhibiting four views of an Injury  
of the head - Presented by Mr Holland Assistant Surgeon  
4<sup>th</sup> Regiment
- 128 A Drawing of Osteo-sarcoma of the lower jaw - presented  
by Mr Cuddy - Grenada M Lobby
- 129 A sarcoma of the cheek - Fort Pitt - Drawn and  
presented by Mr Schethy Deputy Inspector General  
of Hospitals  
From the same subject as No 76 in a less advanced  
stage M Lobby
- 130 supposed to represent a horny substance growing from the



130 neck of a female - History unattainable  
In Lobby

131 Exhibits a large fungoid excrescence from the Parotid gland accompanied by tumefaction of the superior extremity of the Sternum - Deal - Presented by Mr Freer Hospital Assistant Surgeon to the Forces

From John Werner 3<sup>d</sup> Foot Guards admitted into Hospital on his arrival from Flanders with extensive gangrenous ulceration of the left groin the result of Syphilitic affection which healed and broke out again during several months when the lesions exhibited in the drawing made their appearance. In Lobby

132. Drawing of Anchylosed Arm with instrument of Cure  
Presented W. J. Giff Esq.

133. Drawing of Preparation N<sup>o</sup> 40 Mis. 40 (Vid Catalogue Vol. ii) by Ap.<sup>m</sup> Staff Surgeon Holland.

134. Drawing of Preparation N<sup>o</sup> 123 of Circulation Division first. (vide Superation & Catatryne) by Ap.<sup>m</sup> Staff Surgeon Holland.

135 Drawing of Superation N<sup>o</sup> 157 of Div 1<sup>st</sup> of ...  
by Ap.<sup>m</sup> Staff Surgeon Holland.



136. Drawing of Suspension No 109 of Locomotion  
Div: 1<sup>st</sup>. by Asst Staff Surgeon Pittard.
- 137 Drawing of Suspension No 99 of Locomotion  
Div: 1<sup>st</sup>. by Asst Staff Surgeon Pittard.
- 138 Drawing of Preparations No 88 & 89 of Div:  
4<sup>th</sup> of Locomotion. by Asst Staff Surgeon Pittard.
- 139 Drawing of Suspension No 52 of Div: 4<sup>th</sup>  
of Locomotion.
- 140 Drawing of Suspension No 80 of Div: 4<sup>th</sup> of  
Locomotion. by Asst Staff Surgeon Pittard.
- 141 Drawing of Suspensions No 108 of Locomotion,  
Div: 1<sup>st</sup>. and of No 31 of Div: 2<sup>nd</sup> of Locomotion.  
by Asst Staff Surgeon Pittard.
- 142 Drawing of Suspension No 52 of Div: 3<sup>rd</sup> of  
Locomotion by Asst Staff Surgeon Pittard.
- 143 & Drawing of an encysted Tumor: By  
Asst. Surgeon Menzies 16 F.



144 Sketch exhibiting hypertrophy of the Pleura, hepatization of the lung, with carbonaceous deposit through its structure and tubercles in an early stage —  
From Surg. Dr Williams B.P.<sup>th</sup> Regt. —

145. Drawing exhibiting a section of Lung with Tubercles in different stages —  
from the same

146 Drawing exhibiting ulceration of the Larynx and inflammation of the Mucous coat of the Bronchi and inferior portion of the Trachea from the same

147 Drawing exhibiting morbid depositions of medullary structure and consistence in the Liver — from the same

148. Drawing exhibiting a tumour of medullary structure in the Mesentery from the same

149 Drawing of a Kidney (nat. size) exhibiting extensive alteration of structure — from the same



50 Coloured drawing exhibiting a portion  
of the Uterus in Yellow Fever

Presented by J. A. S. McDiarmid Sur. Gen.

151. Coloured drawing Exhibiting Ulcers on the  
Surface of Utricle

Drawn and Presented by

Mr Steele 16<sup>th</sup> Feb.

152 Coloured drawing Exhibiting a portion of Mucous  
Surface of Colon. in Dysentery Chronica

Drawn and Presented by  
The Same.

153 Coloured drawing Exhibiting a portion of  
Mucous surface of Colon, in Acute Dysentery  
Drawn and Presented by  
The Same.

154. 1 Coloured drawing Exhibiting a portion  
of Mucous surface of Colon. In Dysentery  
Supervening on Acute Hepatitis

2. A portion of Caput Coli in Same disease  
Drawn and Presented by The Same

55. Coloured drawing Exhibiting another  
specimen of the effects of Acute Dysen.



tery, on a portion of the Mucous Surface of  
the Colon.

Drawn and Presented by the same.

156 Coloured drawing likewise Exhibiting  
the effects of Acute Dysentery on the  
Mucous Surface of a portion of Colon  
Drawn and Presented by the same.

157. 1. A portion of Spleen. (External Surface)  
with Cheesy Excrescences.

2. A portion of Liver, intersected by numer-  
ous ligamentous substances.

3. A portion of Mucous Surface of Colon.

These show the effects of long residence in India  
and habitual Intemperance, the whole from  
Private Collection

Drawn and Presented by the same.

158. & Exhibit a plan of the Hospital and  
Compound at Serampore occupied by



The Regiment of European Infantry  
drawn and Presented by the same -

159 A coloured drawing exhibiting "Cachexia  
Syphiloides, in David Marshall 75<sup>th</sup> Reg<sup>t</sup>  
Presented by Dr. Graham, Surgeon 75<sup>th</sup> Reg<sup>t</sup> -

160 Another drawing illustrative of the same subject,  
taken from the same patient; but at a period  
subsequent to the preceding -  
Presented by the same

for the history of the case relating to these drawings v.  
Med. Register vol. 80 - fol. 44)

161 A coloured drawing of Elephantiasis  
affecting the face  
Presented by Dr. Kinnis, Surgeon, 90<sup>th</sup> Reg<sup>t</sup> -

162 A drawing of Hydrocephalus Chronic.  
History " Adelaide Wild, stat. 2 years & 8  
" months, is reported to have been a healthy child at  
" its birth, & enjoyed good health until the period of  
" dentition, when it suffered very severely - About the  
" same time, or soon after, the mother's attention was



" attracted to the size of the child's head, which  
 " was evidently enlarged, and gradually increased  
 " until it attained its present magnitude; viz  
 " circumference thirty four inches and a half; and  
 " from ear to ear twenty one inches and three  
 " fourths - In this case the functions of the di-  
 " gestive organs vary considerably - the appetite  
 " at times is very voracious - constipation is  
 " frequent; and the urinary secretion is scanty -  
 " There is mesenteric enlargement, & general wasting,  
 " loss of muscular power - lies constantly upon the  
 " back; apparently indifferent to objects - eyes  
 " drawn under the lower-lid by the superior  
 " oblique muscles - conjunctiva injected - eyelids  
 " unusually red, & devoid of hair, as also the  
 " superciliary ridges - eyeballs oscillate a good deal  
 " from side to side - screams, at times, as if from  
 " pain - is very fretful - pressure has caused  
 " ulceration at the posterior part of the head "

" J O'Brien M. D  
 Appt. Surgeon  
 of the Fusiliers "



163 Coloured drawing of an eye affected  
with Fungus Hematodes.  
Drawn & presented by M<sup>r</sup> Maerady.

164 Drawing of a portion of the anterior edge  
of the left lung, showing a large emphysema-  
tous vesicle - Drawn & presented by  
Asst Surgeon Maerady, 52 Reg<sup>t</sup>  
For preparation from which the above <sup>drawing</sup> was taken  
see.

165 Drawing illustrating Rupia Prominens Syph.  
from a patient in the Lock-Hospital, Edin<sup>burgh</sup>  
Drawn & present<sup>d</sup> by Rich<sup>d</sup> Bannatine Esq S. A. S.

166 Another drawing illustrative of the same subject  
R. Bannatine Esq S. A. S.

167 Drawing illustrating whitlow consequent on  
a puncture with a needle - The injury presented itself  
in a shoemaker: the finger became contracted, but was  
restored to a permanent state of extension by removal  
of the portion of the flexor digitorum profundus  
proceeding to the diseased index finger - The



finger, which under many other circumstances would have proved an inconvenience was thus rendered tolerably useful to the patient in the exercise of his trade

Drawn & presented by Mr Bannatine F.R.S.

168 Drawing of a schirous tumour of the left labium. The tumor was removed, and on being cut into shewed the true schirous structure - It involved the posterior wall of the vagina & part of the rectum. The patient had had syphilitic sores two or three years before the operation, for which she never underwent any treatment. Drawn & presented by Mr Bannatine F.R.S.

169. a & b - Drawings of an osteo-sarcomatous tumour occupying the region of the ankle. Presented Dr Andrew Smith Surgeon to the

170 Drawing of Purpura Simplex in a child about 8 years of age. Asist. St. Surgeon Dr Dods

171 Drawing of lung containing tubercular deposit. Asist. St. Surgeon C. D. Dods



172 Drawing of a tumour involving the left eye of a boy - Fungus Homatodes - History unknown.  
Asst. Staff Surgeon G. D. Doole M.D.

173 - Bright's disease of the kidney - No History -  
Idem -

174 Drawing of . . . . .  
Idem -

175 Drawing representing Sphacelus of the middle finger of the right hand - The disease appeared in the person of a groom <sup>stat. 28</sup> soon after having been engaged in cleaning the feet of a greasy horse. Six weeks after the commencement of the disease the finger presented the appearance delineated - About this time the finger was amputated at the metacarpo-phalangeal articulation, after which a speedy recovery took place.  
Idem -

176 Fig 1 Represents the external of Dura mater, investing the right Hemispherical bone, a.a.a. shows the course of the vein, The membrane is divided to expose the Par vagum sensory nerve (B)



177 Fig 2 Intended to represent the cerebral surface of the  
Dura mater divided as in fig. 1. and reversed to as before (b)  
the parasympathetic nerves, a. a. a. a. a. a. course of fibres.

178 Represents a section of the Kidney of a patient in the  
Royal Infirmary of Edinburgh who was admitted with  
Fever and in whom Bright's disease of the Kidney was found  
after death. The density of the Urine was 1015-

Presented by Edwin Adolphus Esq. 98<sup>th</sup> Foot

179 Represents a section of the Kidney of a patient in  
the Royal Infirmary of Edinburgh who had been  
affected with Phthisis Pulmonalis and died from its effects.  
The urine was examined after death had a specific  
gravity of 1010 The Kidneys diseased

Presented by the same as 178.

180. Enormously hypertrophied Heart with dilatation  
of its cavities obliterated Pericardium weight 9 lbs  
Presented by Mr. Allan

181 Dissection of a Necrosed Femur. Vide Catalogue  
Locomotion Div 4 N<sup>o</sup> 23. George Gartnall

182 Dissection of a Necrosed Femur. Vide Catalogue  
Locomotion Div 4 N<sup>o</sup> 23. George Gartnall  
Both Drawings in Lobby



- 183 Drawing of an Aneurism by Anastomosis affecting the Right lower eyelid successfully treated by ligature. Edinburgh. Donor and Presented by Apist Surgeon Marlow
- 184 Drawing of the right shoulder joint affected with Fungus Haematodes. Drawn & Presented by Apist Surgeon Marlow
- 185 Drawing of an Aneurism by Anastomosis affecting the Left Cheek treated by ligature. Edinburgh Infirmary. Drawn & Presented by Apist Surg. Marlow
- 186 Drawing of a cicatrice of a sloughing ulcer situated in the Anterior Inferior triangle of the neck.  
Presented by Dr. Adolphus Apist Surg. 98 Reg
- 187 Drawing of Bryant Bibby aged 35. Affected with Tubercular Elephantiasis. For case see Edinburgh Med & Surg<sup>e</sup> Journal for January 1844.  
Donor Dr. Kimms Staff Surgeon
- 188 Drawing of David Appoo a Singhalese affected with Tubercular Elephantiasis, Reduced from a drawing in the Museum of Natural Size by Mr Ford. For case see Edinburgh Med & Surg<sup>e</sup> Journal for July 1842.  
Donor Dr. Kimms Staff Surg<sup>n</sup>



189. Fig 1. Drawing taken from the uterus of a Woman who died of Fever in the Edinburgh Infirmary. The Fallopian tubes are found to be distended. Considerably as also the ovaries and to be filled with an opaque white substance of a Cheesy consistence. On the anterior part of the right ovary, a cyst of the size of a walnut is found filled with a limpid fluid like water at about an inch from the termination of the rectum, a small cyst containing a similar Cheesy substance was detected, which when subjected to microscopic observation appeared to consist of minute granular bodies of an hexagonal shape as represented at the bottom of Fig. 1. — Donor Dr O'Brien.

Fig 2. Dropsy of ovary Ibid

190 Fig 3 Dropsy of ovary Ibid

Fig 4 Inflammation of Fallopian tubes

191 Fig 5 Subcartilaginous Tumour of uterus Ibid

Fig 6 Cephalomatous Polypus of uterus Ibid




40











**A Number of Blank Pages Follow, which have  
not been Photographed.**



*[Faint, illegible handwriting on lined paper, possibly bleed-through from the reverse side. The text is mostly obscured by stains and fading.]*



# Drawings

in

## Natural Anatomy

- 1 Front view of the Anatomy of the Pelvis and Thighs  
Drawn and presented, by Mr Schetty Deputy Inspector  
General of Hospitals *Mr Lobby*
- 2 Front view of the Anatomy of the neck and upper arm  
Drawn and presented by the same *Mr Lobby*
- 3 Anatomy of the parts connected with the subclavian artery  
Drawn and Presented by the same. *Mr Lobby*
- 4 Nerves of the neck Drawn and Presented by Mr Stratford



- 4 Assistant Surgeon to the Forces
- 5 Nerves of the Trunk. Drawn and presented by the same
- 6 Nerves of the Arm Drawn and Presented by the same
- 7 External Muscles of the face - Presented by Sir James  
Warrigton F.R.S., Director-General of the Army Medical  
Department
- 8 The second order of Muscles on the back of the neck  
Presented by the same
- 9 Muscles of the side of the Trunk and extremities - Presented  
by the same
- 10 A view of the Dorsum of the Scapula - Presented by Dr  
Pitcairn Assistant Surgeon to the Forces 58<sup>th</sup> Regiment
- 11 A view of the Os Innominatum of a young Subject - Presented  
by the same
- 12 A front view of the lower jaw bone - presented by the same



- 13 ~~A~~ A posterior view of the lower jaw bone — Presented by the same
- 14 ~~A~~ A view of the bones of the orbit — Presented by the same
- 15 ~~A~~ A front view of the Skull. Presented by the same
- 16 A front view of the skull of a very aged person presented by the same
- 17 A posterior view of the thigh bone. Presented by the same
- 18 An anterior view of the Os Humerus — presented by the same
- 19 An anterior view of the Ulna — Presented by the same
- 20 ~~a~~ A Front View of the Tibia of a very young subject — Presented by the same
- 21 A Drawing of a section of the Pelvis. Presented by Staff Apt. Dartnell
- 22 ~~A~~ A side view of the lower jaw bone — Presented by Mr. Petitioner Apt. given to the 58<sup>th</sup> Regiment




Anatomy of the Great Sympathetic nerve — Drawn  
and Presented by Aps. Surgeon <sup>Major</sup> Royal Dragoons











**A Number of Blank Pages Follow, which have  
not been Photographed.**







163

## Miscellaneous Drawings

- No 1. Drawing (outline) of Head exhibiting the divisions of Craniology as taught in 1525  
Presented by W. J. Hiff Esq.
- No 2. Drawing exhibiting the ovary of the  
*Ornithorynctus paradoxus*, drawn and  
presented by Hiff Esq Surgeon General Dartnell
- N<sup>o</sup> 3. Drawings illustrative of the Anatomy of the Cyst  
Worm
- Fig 1 Cysticircus of the natural size removed  
from the cyst and the head and neck of  
the worm pulled out. Taken from the  
omentum of the Mexican Deer



Fig 2. Head and neck of the worm magnified and exhibiting the situation and extent of the oval corpuscles which are very abundant in the middle of the neck diminishing in number about the head and near to the claws, and wholly disappearing at (A) where the neck or body begins to expand into the bladderlike extremity of the parasite,

Fig 3. A portion of the neck magnified about 130 times in diameter so as to show more clearly its structure and the disposition of the superficial layer of the corpuscles

Fig 4. Structure of the caudal vesicle exhibited in a portion magnified to the same degree as in Fig. 3. The oil like spherules are very distinct and totally different from the oval corpuscles

Fig 5. A portion of the cyst magnified to exactly the same degree as in figures 3. & 4

Fig 6. The armed proboscis enlarged about 145. in diameter showing the two



circles of claws and the alternate arrangement of those forming the long and the short set. Some of the lateral processes as at (a. a. a.) being seen foreshortened resemble tubercles. Several of the oval corpuscles of smaller size than those situated in the neck are scattered through the parenchyma near to the claws

Fig. 7. one of the short and two of the long claws magnified about 500. linear admeasurement. B. the arms. C. the lateral processes. D. the spines


Fig. 8. The oval corpuscles enlarged about 400 diameters some of them appear homogeneous. Others have granular nuclei. and one has <sup>a</sup> cross split in the shell from drying.

Fig. 9. The same exhibiting their granular interior after the breaking of the shells by compression



160







160



**A Number of Blank Pages Follow, which have  
not been Photographed.**



180



# Paintings

## Morbid Anatomy

- 1 Exhibits an impervious state of the Pulmonary artery with four vicarious pulmonary branches one of them aneurismal—History unattainable. Painted and presented by Mr Schetty Deputy Inspector General of Hospitals

H. Lobby

- 3 Ulceration of the stomach, Intestine and lung Fort Pitt. Painted and presented by the same

From the same subject as preparation N<sup>o</sup> 19 Class 2 Digestion Division 2  
 Quide Fasciculus of Anatomical Drawings from the Museum of the Army  
 Medical Department Plate 9 fig 1 H. Lobby



- 3 Exhibits extensive intestinal Intus-susception - Foot Pitt  
Painted and presented by M. Schelby Deputy Inspector General  
of Hospitals  
From the subject of Preparation No 20 Class 2 Digestion Division 4  
In Lobby
- 4 Stomach, liver, small intestines, and urinary Bladder affected  
with large masses of vesicular structure growing from their  
peritoneal coat and sending down pendulous portions supported  
by processes of Peritoneum. Painted and presented by the same  
Taken from a soldier of the 88<sup>th</sup> Regiment In Lobby
- 5 Vesicular masses in the omentum and Colon. Painted and  
presented by the same  
From the same subject as the preceding In Lobby
- 6 Phagedenic ulceration of the Penis - Edinburgh - Painted and  
presented by the same  
From a patient in the Royal Infirmary the disease first commenced  
by a slight abrasion unconnected with any syphilitic cause  
or with Cortion In Lobby
- 7 Brain - exhibiting Hydrocephalus internus - The right side of the  
brain is laid open and some of the fluid still left: the septum lucidum  
is perforated by an irregular ragged opening showing the



- 7 depth of the fluid of the left ventricle: and divided (without dissection) into two layers one of which is folded and supported by a hook: the plexus choroides is seen coming from the cornu ammonis, and passing through the foramen Monroianum: blood vessels insinuate round the thin walls of the ventricle: Painted and presented by the same

From a child seven years of age In Lobby

- 8 View of the base of the Skull greatly enlarged from Hydrocephalus Edinburg — Painted and presented by the same

From a young fisherman who attained the age of twenty years before he died: The Skeleton is preserved in Mr Liston's Museum In Lobby

- 9 Exhibits ulceration of the buttocks. Ibid — Painted and presented by the same

From Robert Sims tailor a patient in the Royal Infirmary. This disease was originally syphilitic: he had two chancre on the prepuce which appeared eight days after suspicious connexion and were followed by buboes: after using mercury slightly for two months his complaints yielded: About this time a bright red spot appeared on the perineum. and afterwards a small tumour on the hip which ulcerated and spread until it joined the other attended by much pain. At length the ulceration reached the extent presented in the painting In Lobby



- 10 Inflammation of the Theca of the Medulla Spinalis - Fort Pitt. Painted and presented by Mr Schethy Deputy Inspector General of Hospitals

From John Burch 67 Regiment et 60 who was admitted into Hospital moribund with gangrenous swelling of the right arm previous to death which took place in a few hours afterwards he became affected with tetanus: On dissection the vessels in the spinal chord were found gorged with blood and the theca was very red: the inflammation however did not extend to the substance of the spinal marrow itself (vide Fasciculus of Anatomical Drawings from the Museum of the Army Medical Department Plate 2 fig 3) In Lobby

- 11 Exhibits Molluscarum pendulorum in the face accompanied by tubercular affections of the back and upper extremities - Edinburgh - Painted and presented by the same

This disease which occurred in a wearer a patient in the Royal Infirmary was of long standing, free from pain and of imperceptible origin: The principal tumour which was soft and moveable was appended to the right eyelid: When extirpated its structure was found to be cellular and moderately vascular. It was not ascertained whether regeneration subsequently took place. In Lobby



- 12 Elephantiasis of the right lower extremity - *Id.* - Painted and presented by the same

From a woman a patient in the Royal Infirmary in whom the disease appeared suddenly after a slight febrile attack at Gibraltar and in a few days attained the size represented in the painting In Lobby

- 13 Exhibits pustular eruption: mixed with eroded ulcers diffused over the whole surface of the body also a female head with ulceration of the tongue and under lip - Fort Pitt - painted and presented by M Schirky Deputy Inspector General of Hospitals

From the same subject as preparation 7. Class 1 Respiration Division 1 (Vide Fasciculus of Anatomical Drawings from the Museum of the Army Medical Department Plate VI In Lobby

- 14 Exhibits pustular eruption on the face with pustules and ulcers on the shoulders and upper extremities - Edinburgh - Painted and presented by the same

From Mary Waddell æt 50 a patient in the Royal Infirmary who had been profusely salivated ten years before for a supposed syphilitic affection - The eruption rapidly disappeared by appropriate treatment the cast remaining by desquamation In Lobby



- 15 Exhibits medullary Sarcoma in the leg - also a section of a small Fungus haematodes. Ibid. Painted and presented by the same.

This tumour adhered but slightly to the surrounding the gastrocnemius and soleus were pale and attenuated stretched over the tumour and perforated by it at a spot where a fungus had begun to appear one coagulum of blood was obvious. The mass was intersected by septa of a consistence not firm enough to resist forcible tearing. from these different the portions could be turned out with the fingers. Two such portions are represented. Amputation being performed the man did well. The Fungus haematodes was also successfully extirpated from the calf of the leg In Lobby

- 16 Cancerous ulcer on the hand and fore-arm. Ibid.

From a woman a patient in the Royal Infirmary. The arm was amputated and the disease had not returned two months after the operation. This picture also represents a fungoid malignant ulcer above the heel of which the history is unknown. In Lobby

- 17 Ulcerated opening in the left side of the perineum the result of lithotomy History unattainable. In Lobby




- 18 *Fungus haematodes* springing from the under surface of the  
great Toe - Canterbury - Presented by Dr Logan Surgeon 5<sup>th</sup>  
Dragoon Guards. In Lobby
- 19 Exhibits deep ulcerations in the Nates - Edinburgh - Presented  
by Professor Lizars - History unattainable. In Lobby
- 20 A Oil Painting shewing transverse fracture of the patella. a  
partial necrosis of the upper fragment. magnified from a  
preparation in the collection of Mr Lister. presented by Staff A. Hughes  
Gulliver
- 21 ~~An~~ Oil Painting shewing Disease of the Ankle joint  
. presented
- 22 An Oil painting framed, of four Crania.  
Presented by Assistant Staff Surgeon Mr Diamond
- 23 A painting of a Foetal Monster in the collection  
of Dr William Campbell - Presented by A. J. J. J.  
Stewart 2<sup>d</sup> Dragoons In Lobby
23. Painting exhibiting extensive destruction of the  
inter table of the frontal bone from Mercurial  
Inflammation. Presented by Mr Diamond  
In Lobby




24. Painting exhibiting Epistosis of the superior  
maxillary bone in a native of Sierra Leone  
by S. A. S. M<sup>r</sup> Dearmid - presented by himself  
In Lobby.

25. Anterior & posterior view of a Cranium  
extensively affected with Caries. vide Chap<sup>3</sup>  
Locomotor Div 1<sup>st</sup> pages 535. No 158  
In Lobby











**A Number of Blank Pages Follow, which have  
not been Photographed.**







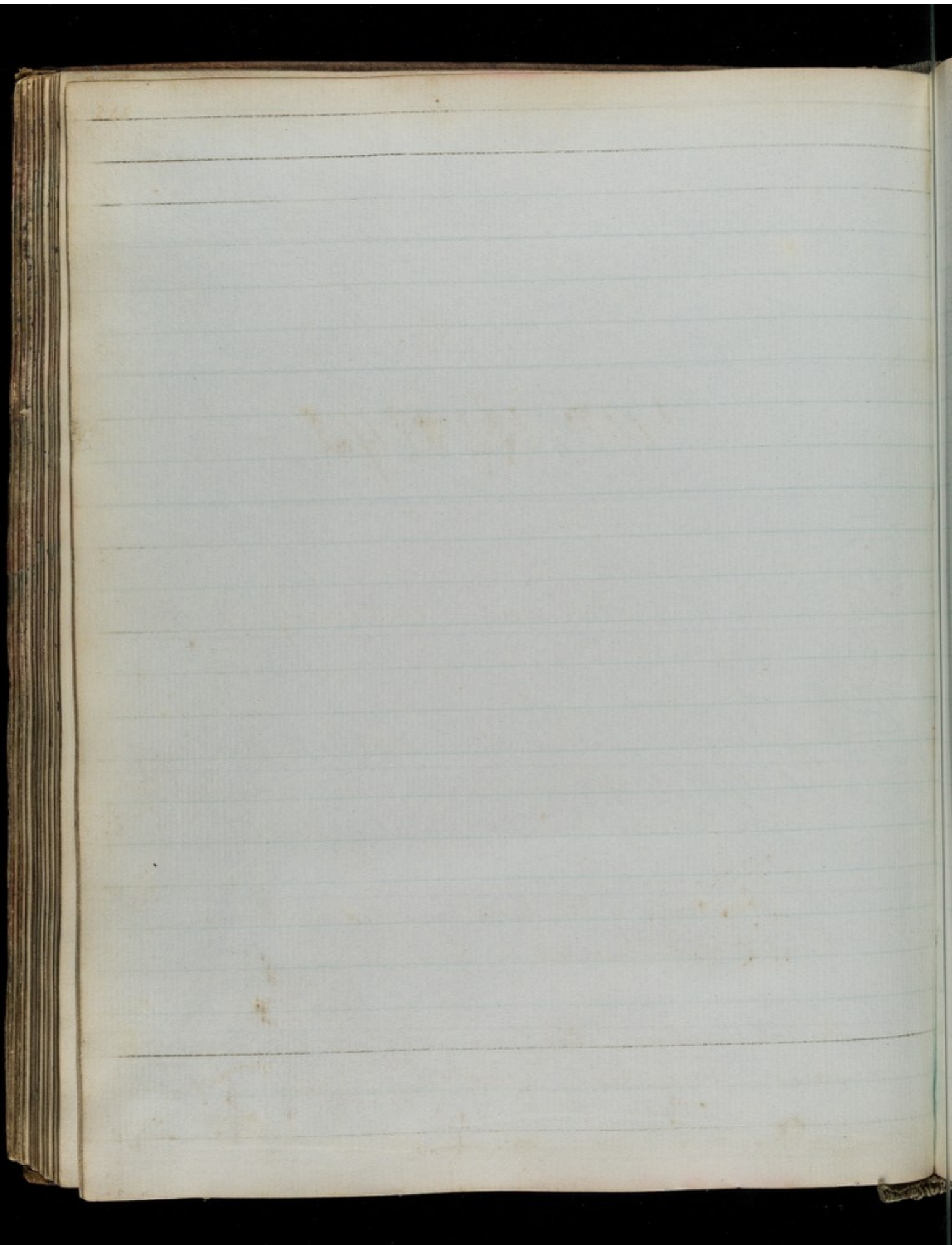
# Paintings

in

## Natural Anatomy

- 1 Staff Surgeon Millar demonstrating the Anatomy of the neck to Mr Schethy — Painted and presented by Mr Schethy Deputy Inspector General of Hospitals
- 2 The Anatomy of the parts concerned in Hernia — Painted and presented by the same
- 3 An Oil Painting of the crania of four persons of different races — Presented by Assist<sup>t</sup> Staff Surgeon M'Donnell

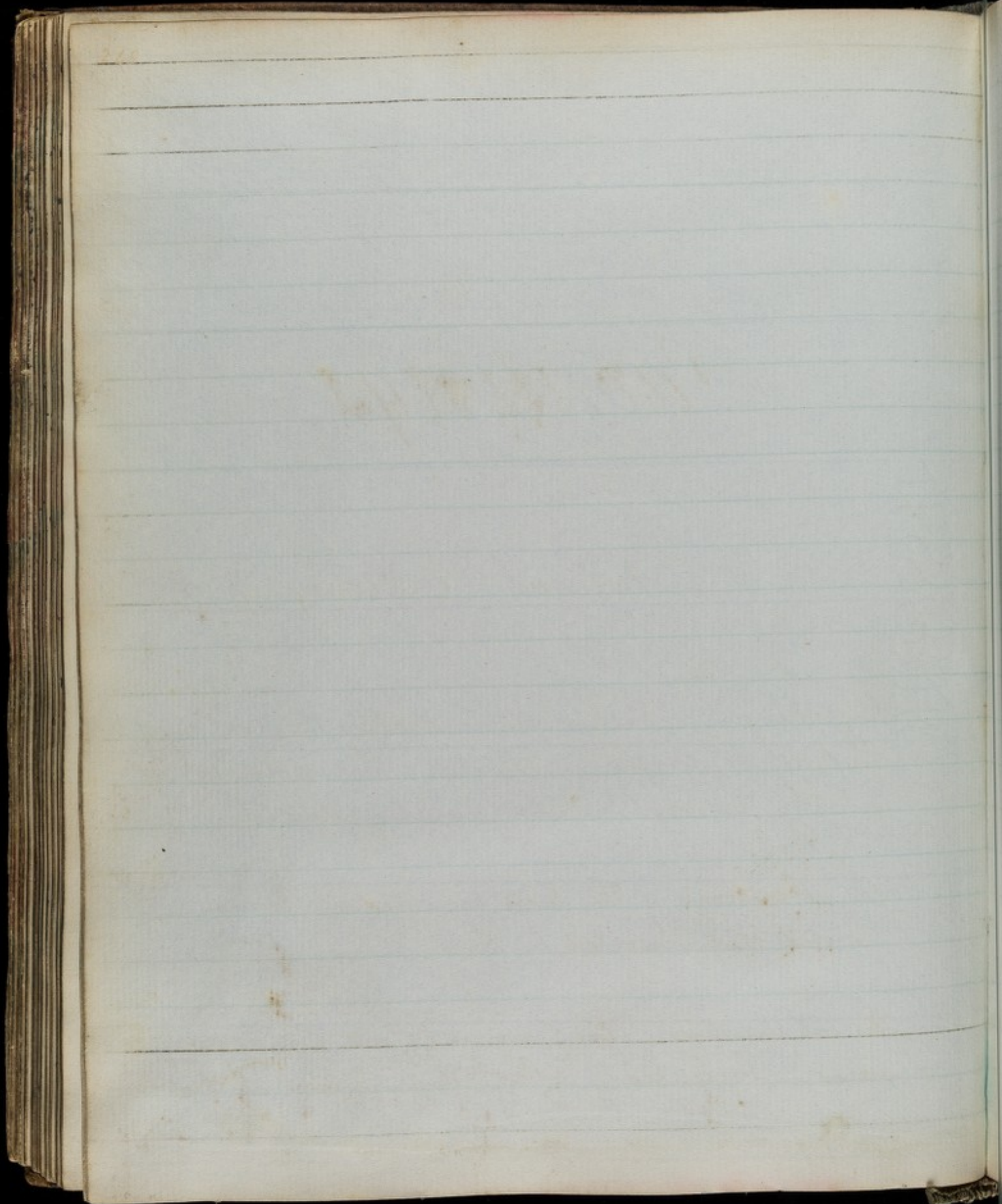














**A Number of Blank Pages Follow, which have  
not been Photographed.**







# Portraits

1 Portrait of Sir James M'Quigon Director General  
Army Medical Department  $\frac{3}{4}$  length — Painted  
by David Milkie Esq<sup>r</sup> R.A.

2 Portrait of D<sup>r</sup> Forbes: Inspector General of Hospitals







**A Number of Blank Pages Follow, which have  
not been Photographed.**







## Casts in *Pathological Anatomy.*

- 1 Female Monster having a double body and extremities with single head— Presented by Sir James Mcgrigor Bart. M.D. F.R.S.  
 Director General of the Army Medical Department  
 On dissection of this lusus, the bones of the head were found correct in number, but unduly large the cerebrum was natural. There were two medulla oblongata; one Trachea, one pair of lungs; one heart, a perforation in the diaphragm through which the right lobe of the liver protruded into the chest, two spleens, two large kidneys, two coronary blood vessels, one Esophagus; one stomach: one Aesculapian, divided at its lower end into two parts; and two Uteri



- 2 Exhibits a large fissure in the forehead created by Necrosis and separation of a great part of the Os frontis—Fort Pitt—Taken and presented by Dr. Hennen Assistant Surgeon: Royal Military Asylum

From the same subject as Preparation N<sup>o</sup> 96—Class 3 Locomotion Division 1

- 3 Sarcomatous Tumour in the mouth—Ibid

From the same subject as Drawings N<sup>o</sup> 67 and 68

- 4 Sarcomatous Tumour in the cheek—Edinburgh—Presented by Sir George Ballingall, Professor of Military Surgery

The tumour of which this is a cast was removed from Hugh Minson at 51 by the donor (Vide Clinical Lecture delivered at the Royal Infirmary July 1837 p 31)

- 5 Sarcomatous Tumour situated behind the angle of the jaw—Ibid—Presented by the same

This Tumour when removed was found adherent to the mastoid and stiloïd processes of the temporal bone: in dissecting it out: the facial artery was divided and the trunk of the carotid laid bare for nearly an inch and a half of its course. It was of a dense sarcomatous structure and contained within it several large cells filled with a bloody fluid. The Patient a fine young woman made a speedy recovery







2501 weight from an ear and a half and two scapulas and  
had been forty years in the bladder. Presented  
by the Operator, W<sup>t</sup> Ferguson, Edinburgh.

13. Nineteen Coloured Casts of the most remarkable  
specimens of urinary Calculi in the Norfolk and  
Norwich Hospitals. (a) Tray containing Casts of 9  
Calculi from a Man at 69. they might from once  
the Man was cured. (b) Tray containing five Casts.  
the Patient was cured by operation. (c) Tray containing  
the Cast of a Mulberry Calculus. the Patient was cured  
by operation. (d) (e) (f) (g) Four trays, each containing  
the Cast of a Calculus. Presented by W<sup>t</sup> Smith  
1<sup>st</sup> Dragoons.

14. Three Casts of a Diseased Ankle joint. Presented  
by W<sup>t</sup> Lander. 7<sup>th</sup> Hussars. already entered as  
No 11.

14. Cast of a Section of a urinary Calculus which  
had a Pinpoint ball for a nucleus.  
Presented by Sir G. Ballingall.

15. Part of a Calculus taken from the bladder of  
Sir W<sup>t</sup> Adams. Sir W<sup>t</sup> Adams, 1<sup>st</sup> Baronet  
London, was born at Wen, in Shropshire, edu-  
cated at ~~Trinity~~ Cambridge and afterwards



brought up a scholar in London. In 1609 he was  
Chosen alderman of the City And in 1645, served the office  
of Lord Mayor. His loyalty was so great that the  
Republicans searched his house, in hopes of finding  
the King, and though they were disappointed, yet they  
confined Mr Adams in the tower. He sent Charles  
the second £10.000 during his exile, and when the  
restoration was effected on, he was appointed by  
the City to wait on the King, who knighted  
him at the Hague, and in 1661 created him a  
Baronet. He died in 1667, aged 81, and after his  
death a stone was taken from him, weighing  
twenty five ounces, which is now in the labora-  
tory at Cambridge. He founded a school at  
Wren, and an Arabic Professorship at Cambridge  
and was at the expense of printing the Gospels  
in Persian and sending them to the East.

See Bibl. account  
Presented by W. I. Stiff Esq<sup>r</sup>

16 Port of a Calculus taken after death from the  
Necropsy of a man who died at Leitham near  
Maidstone.

Presented by W. I. Stiff Esq<sup>r</sup>



17. Part of the right foot and ankle joint of  
 W<sup>m</sup> Newton, et 28, who was thrown off  
 a baggage Cart in Oct: 1835, and received a  
 compound dislocation of the Astragulus. He was  
 admitted into the Cadlow infirmary immediately.  
 Dr. Newton, Surgeon to the infirmary, on exami-  
 -nation, finding it impossible to reduce the bone  
 removed it by operation. The Os Calcis was  
 then pushed up into the articular surface of  
 the tibia and the wound dressed with Con-  
 -junctives. He recovered rapidly and has now  
 a good foot.

Mounted by Dr. Rawson. Carlew.

8. Buot of a Person, whose Artits are filled  
with Humours similar to those described  
in Vol. 1<sup>st</sup> of Guy's Hospital Reports.  
And Museum of Guy's Hospital.

19. Cost of an Elephantiasis leg.

East of an *Aspermatodes* sp.  
 Neurology: Register } Mr Williams Surgeon General Ship  
 Vol V. p. 135 } Boston Mass.  
 The Father  
 Hallamham  
 7 Dec.



296  
27. Cast of the face of a ~~female~~ murderer.  
(the mother). *Intentional*  
*murder* Asst. Surg: Gallagher  
27<sup>th</sup> Aug.

20. This cast was taken from the head of a boy at the age of five years and four months, who had presented the congenital form of hydrocephalus. During the first three years and two months of his life, he had been under the care of various practitioners; but appears to have enjoyed vigorous health for about fourteen months previous to the cast being taken. The body at that time was well developed; the fontanelle closed; the pupils rather dilated, but perfectly contractile on exposure to light, and vision perfect. His disposition was mild & interesting; his intellect precocious beyond his years. He was easily put to sleep, and never fretful. He also suffered under congenital inguinal hernia of the right side, which was gradually disappearing. The parents were healthy, and of the labouring class.

Presented to  
Asst. Surgeon Genl. F. W. H. H. H.



21. A Wax cast exhibiting the superficial  
Anatomy of the Perineum  
Presented & prepared  
by Dr. Williamson. I.A.S.

22. Cast of the left leg of Mrs. Sinclair exhibiting great enlargement  
of the lower end of the Femur & head of Tibia with great relaxation  
of the ligaments of the knee joint. Dr. Williamson M.D. I.A.S.

23. Wax Cast of the superficial Parts of the Leg of Dr. Williamson I.A.S.

23. Wax Cast of left Femur which was affected with  
Osteo medullary sarcoma. Amputation was  
performed at the hip joint by Dr. Handyside  
The patient survived the operation 19 weeks and  
three days, having entirely recovered from its  
effects. Donor Dr. Brien Surgeon

24. Cast of the Stump from which the previous  
preparation was taken.

Donor Dr. Brien Surg<sup>n</sup>

25. Wax cast of a large Condylomatous excrescence  
occupying the Perineum and partly surrounding  
the Anus. Vide Secretion Division V. No 51

Dr. Williamson I.A.S.

26. Cast of the right arm, showing a dislocation of the  
ulna & radius - backwards & outwards. From Pivots & Thoms  
Person 41<sup>st</sup> Regt. Several attempts at reduction were made



Six weeks after the accident but without success

J. Williamson C. S. S.



299




295

# Casts

## Natural <sup>live</sup> Anatomy

1. Brown Cast of a human Figure displaying the external layer of Muscles








297  
Casts of Crania of different Races.

- N<sup>o</sup> 1. Cast of the Skull of a New Hollander  
brought to this Country by Sir J. Banks.  
From Museum of Guy's Hospital.
- N<sup>o</sup> 2. Cast of a female of the same Race,  
Invented at the same time.  
From Museum of Guy's Hospital.
- N<sup>o</sup> 3. Cast of a Skull of a Native of Moram-  
-bique.  
From Museum of Guy's Hospital.
- N<sup>o</sup> 4. Cast of a Skull of a Flat headed American  
from the neighbourhood of the Columbia  
River. From Museum of Guy's Hospital.
- N<sup>o</sup> 5. Cast of a Skull of a Native of Madag-  
-ascar.  
From Museum of Guy's Hospital.







299

**A Number of Blank Pages Follow, which have  
not been Photographed.**







305

# Casts of the Crania of Distinguished Persons

- 1 Cranium of King Robert Bruce — Presented by Sir  
James M'grigor M.D. F.R.S. Director General of the Army  
Medical Department
- 2 Cranium of George Buchanan — Presented by the same
- 3 Cast of the Head of the late Sir Walter Scott Bart  
Presented by Dr. Monro Edinburgh








**A Number of Blank Pages Follow, which have  
not been Photographed.**







# Casts

of the

## Crania of criminals

- 1 Head of John Hutton an executed Malefactor - New South Wales Taken and presented by Dr Gibson Assistant Surgeon to the Forces
- 2 Head of William Webb an executed Malefactor - Ibid Taken and presented by the same
- 3 Head of Anne Campbell an executed criminal - Ibid Taken and presented by the same
- 4 Head of Patrick Malony an executed Malefactor - Ibid Taken and presented by the same



- 5 Head of Thomas Mustin an executed Malefactor —  
Ibid — Taken and presented by the same
- 6 Head of Lot McNamara an executed Malefactor  
Ibid — Taken and presented by the same
- 7 Head of Thomas Regan an executed Malefactor  
Ibid — taken and presented by the same
- 8 Head of John Wright an executed Malefactor — Ibid  
Taken and presented by the same
- 9 Head of John Gough an executed Malefactor — Ibid  
Taken and presented by the same
- 10 Head of John Amy Bird Bell at 14 executed for  
Murder at Maidstone 1831 — Presented by Mr  
Ply the Assistant Surgeon Royal Marines
- 11 Cast of the head of Patrick Carroll who was executed at  
Maidstone May 18<sup>th</sup> 1835 for the murder of of Elizabeth  
Brown Woolich April 27: 1835 — Presented by



12. Cast of the face of — Hayes, executed  
for Murder.

Ap<sup>t</sup> Surg<sup>r</sup>: O'Callaghan 27<sup>th</sup> Aug

13. Cast of the face of the wife of Hayes  
(N<sup>o</sup> 12) who was also executed for murder,  
as was her son by Hayes. The son's  
Cranium N<sup>o</sup> 32.

Ap<sup>t</sup> Surg<sup>r</sup>: O'Callaghan 27<sup>th</sup> Aug

14. Cast of the Head & face of Goenacore — who  
murdered & mutilated the body of a woman.

W. J. Miller — &

He kept a paramour, — and she was  
transported for her share in the transaction.  
The murdered woman's name was Hannah  
Brown, a widow.







# Prints

in

## Morbid Anatomy

1 Represents inflammation of the Theca of the Medulla spinalis  
— Fort Pitt — Engraved from Painting N<sup>o</sup> 10

2 Elephantiasis of the face — Edinburgh —

This disease occurred in a boy, a native of the West Indies about sixteen years of age. It was accompanied by ichthyosis ulceration of the fauces: great debility and excessive sensibility to cold. *McLobby*

3 Congenital Tumour in the arm of an infant — Chutham



Engraved by D<sup>r</sup> Neale Assistant Inspector General of Hospitals— From Drawing N<sup>o</sup> 70

4 Fatal Polypus in the right side of the heart.— Engraved by M<sup>r</sup> Stewart Assistant Surgeon 2nd Dragoons. In Duplex.

5 Tumour growing from the Perineum— Presented by M<sup>r</sup> Murray Assistant Surgeon to the Forces

6 A lithographic drawing of <sup>all entire</sup> Necrosis of the distal end of the Fibia— Presented by Staff Surgeon Dartnell

7 Sarcoma of the Uterus weighing 15 lbs— Presented by D<sup>r</sup> Hunter

8. a In this plate certain Pathological Conditions of the Stomach are displayed, viz Cancerous ulceration of its inner Surface, fungoid excrescences of the mucous membranes, also destruction of the great arch <sup>by</sup> of the action of its own secretions after death, scirrhous of the pylorus, perforation (by ulceration) of all its coats. Presented by H. J. Jeff Esq.

9. b The figures in this Plate display the vascularity



379  
Thickening, ulceration and sphacelus of the Colon  
which occur in some cases of acute & chronic  
dysentery; also the Ileo Colic valve in a scirrhus  
state, and its opening completely obstructed  
by coagulable lymph.

Presented by W. J. Hiff Esq.

10. In this Plate some diseased Conditions of the  
Liver are displayed. viz Hydatids, and a large  
Abscess in its substance, general induration  
with hypertrophy of the white part. Melanosis,  
also two specimens showing different stages  
of development of what is commonly denomi-  
nated the tuberculated Liver of hard drinkers.

Presented by W. J. Hiff Esq. —

11. In this Plate are represented certain pathological  
Conditions of the small Intestines. viz enlargement  
of the aggregate & solitary glands of Peyer and  
Brunner, & that ulceration with perforation of  
the gut, which sometimes is the consequence of  
fever. Besides these there are displayed crudi-  
tubercles on the Brachio peritoneal Coat, and ul-  
cerated ones in the mucous membrane of the



Intestines, enlargement of the Valvulae Conniventes  
and deposits of lymph on the Ileum, caused by  
Dysentery: also specimens of Intus-susception  
structure of the Jejunum, and a portion of gut  
which was voided by stool, without any  
bad results.

Presented by W. J. Giff Esq.

12. Print of Master Thomas Jones, the youngest but one of  
Ten Children, son of John & Martha Jones of Tyrekeel  
in the Parish of Gredhyn, Pembrokeshire. Born  
on the 19 October 1830, representing a case of Scrophulous  
which made its appearance about five or six weeks  
after his birth, The rest of the Family are quite healthy.



**A Number of Blank Pages Follow, which have  
not been Photographed.**







*Miscellaneous Prints.*

No 1. Coloured Engraving of "The Dissecting Room."  
Presented by W. J. Hiff Esq<sup>r</sup>.

No 2







411

**A Number of Blank Pages Follow, which have  
not been Photographed.**







# Prints

in

## Natural Anatomy

- 1 A Diagram of the Human Eye from a perpendicular section of the left Orbit with the parts contained in it (coloured)
- 2 A Diagram of the Human Eye (coloured)
- 3 A Map of the Ear magnified to four times its natural size  
— coloured —
- 4 A Series of the Throat








425

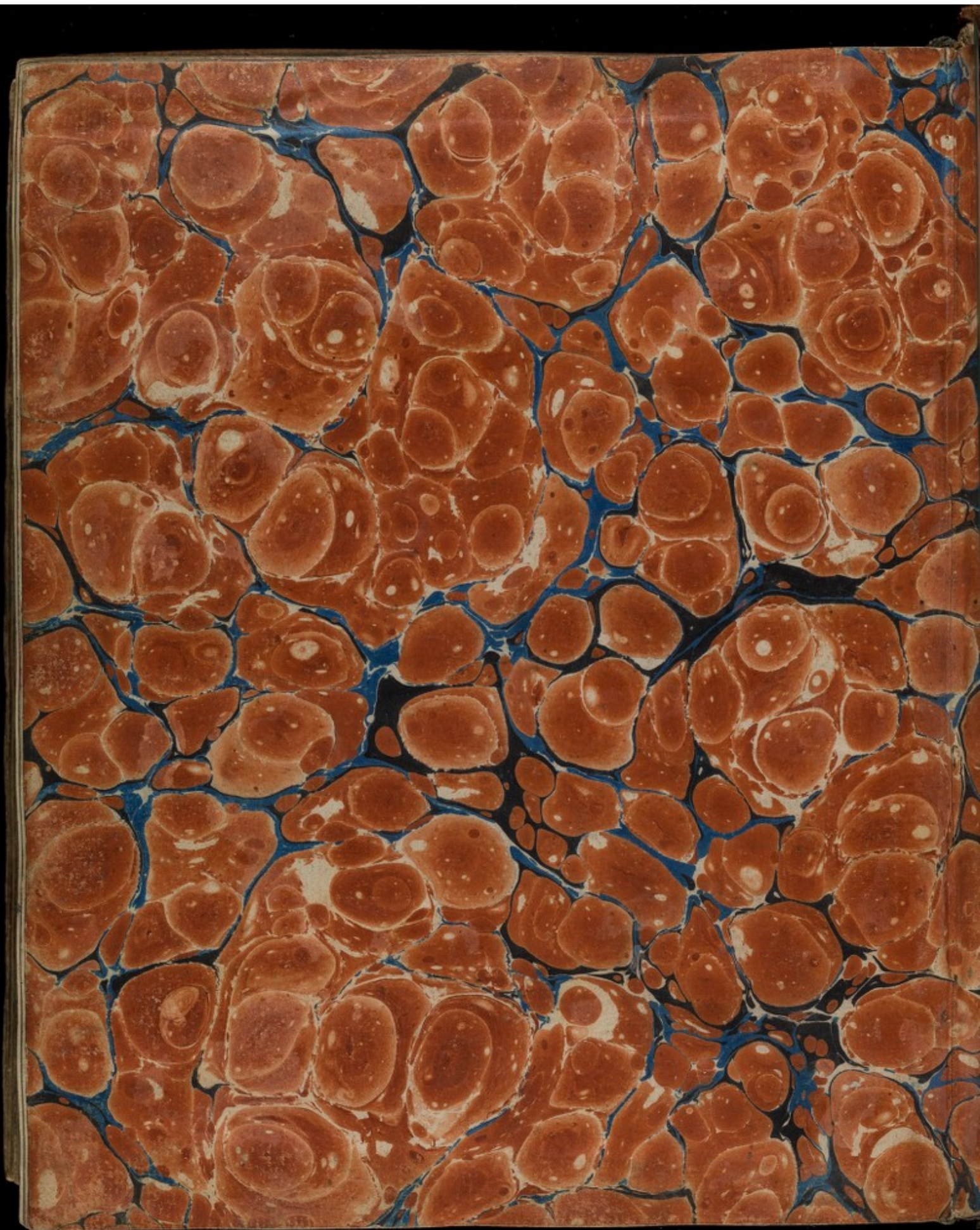
**A Number of Blank Pages Follow, which have  
not been Photographed.**













JOHN SMITH,  
*BOOK-BINDER,*  
TO HIS MAJESTY'S  
STATIONARY OFFICE,  
49, Long Acre.



