

**Dr. (later Sir Joseph) Fayrer's register of operations (at the Medical College Hospital, Calcutta)**

**Publication/Creation**

1858-1872

**Persistent URL**

<https://wellcomecollection.org/works/nj3ekkpw>

**License and attribution**

You have permission to make copies of this work under a Creative Commons, Attribution, Non-commercial license.

Non-commercial use includes private study, academic research, teaching, and other activities that are not primarily intended for, or directed towards, commercial advantage or private monetary compensation. See the Legal Code for further information.

Image source should be attributed as specified in the full catalogue record. If no source is given the image should be attributed to Wellcome Collection.

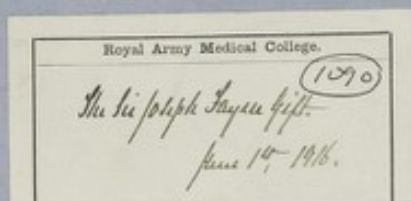


Wellcome Collection  
183 Euston Road  
London NW1 2BE UK  
T +44 (0)20 7611 8722  
E [library@wellcomecollection.org](mailto:library@wellcomecollection.org)  
<https://wellcomecollection.org>





16-4-







*State of* *Date of* *Duty*  
*Operation* *Discharge* *Death*

*Result or cause of Death*

*Remarks*



Date of Admission	No.	Name	Sex	Age	Occupation	Country	Disease	Operation
25/10/68	72	Bhoyron	M	40	French	India	Fatty tumour	Removal

26.10.68	73	Mrs. Matilda Taylor	F	41	Stones	Swiss	Epithelial Cancer of tongue	By ligature & excise
----------	----	---------------------	---	----	--------	-------	-----------------------------	----------------------

November 7/68

19/8/68	75	Charles Smith	M	43	Sailor	Dutch	Inguinal Hernia	Radical cure
---------	----	---------------	---	----	--------	-------	-----------------	--------------

17/10/68	76	Isaac Bonnil	M	27	Sailor	Hebrew	Palmar Epithelioma	Amputation of the arm at the arm after excision of the joint
----------	----	--------------	---	----	--------	--------	--------------------	--



Date of Operation	Date of Discharge	Date of Death	Result or cause of Death	Remarks
25/10/68	2/1/69		Cancer	Had a large lobulated growth, tumor about the size of a child's head. The tumor has been growing for the last 8 years - found a large cavity in the left maxillary cavity - occupying chiefly the left infra-orbital fossa, encroaching a little onto the antrum. The tumor contained in a small pedicle - reddish, which has been growing since then, painless & unaltered with any constitutional disturbance - Removed under chloroform tumor weighed 2 lbs. but very late blood - 7 ligatures applied
27.10.68	12/11/68		Appearance of Cancer - Lymphatic glands separated, tumor about the size of a child's head - There is no more of a healthy - piece - tumor before - Patient got drunk & returned for chloroform -	About 3 years ago, had small pimples about the lips & tongue - These disappeared few days after - Except one at the margin of the tongue, which was growing a little subsequent to ulcerated, & this ulcer since then increasing. At present there is a large ulcer about the size of a finger at the middle of the right margin of the tongue - It is painful - hard - & ragged - ulcerated - tongue at present - There is also a small ulcer of the floor of the mouth - One of the glands of the right neck enlarged - Spunked & ligature & cauterized
2/11/68	12/11/68		Dissected remains of the right side of tongue showing back of ham - the bottom of the tongue -	Dissected remains of the right side of tongue showing back of ham - the bottom of the tongue -
3/11/68	3/11/68		Dissected of Carotid	Came in with long anchylosis of the right elbow of 9 months duration - Both the Carotid arteries & veins were found in the 22/10/68 by J. J. with water & pork - It showed marked anchylosis of secondary lamellae of the right elbow - presented several small white papules - each of the glands - The main part of the tumor of the right elbow - filled with oil substance - The glands in the antrum were



Date of Admission	Name	Sex	Age	Occupation	Country	Disease	Operation
6/11/68	75 Bhogobau	M	40	None	India	Stricture urethra	Perineal section

9/11/68	76 M Harding	M	22	Clerk	India	Intero-internal Hemorrhoids	Ligature
---------	--------------	---	----	-------	-------	-----------------------------	----------

9/11/68	77 E Joshua	M	50	None	India	Intero-internal Hemorrhoids	Ligature
---------	-------------	---	----	------	-------	-----------------------------	----------

6/11/68	78 R F Westfield	M	37	None	England	Intero-internal Hemorrhoids	Ligature
---------	------------------	---	----	------	---------	-----------------------------	----------

4/11/68	79 Banachurn	M	30	Farmer	India	Scrotal Tumour	Excision
---------	--------------	---	----	--------	-------	----------------	----------



Date of Operation	Date of Discharge	Date of Death	Result or cause of Death	Remarks
6/11/68	12/12/68		Cured - Perineal wound healed - metastasis of the cancer - all blood vessels in the perineal area were removed	Has pt. structure method for the last 9 months. Coming on after perineal. The patient had 3 months prior to that had been all along passing water in narrow stream, but since then before. There is complete stoppage of water. Attempts made to draw off the water, but as it was not could be passed, Perineal section performed on 12/12/68.
9/11/68	23/1/69		Apparently cured - 20 more files seen	Has pt. internal file for the last 12 months. It used to bleed very much, before - but after the last operation it has been internal file - those files about the margin of the tumor - and it is all right.
9/11/68	11/11/68		Relieved - Discharge of urine & admission to the hospital - 6 months later	Internal file for the last 20 years - they used to bleed frequently before, but at present no blood at all. Comes at internal & not to the & blood files at the & all right.
9/11/68	12/1/69		Relieved - Discharge of urine & admission to the hospital - 6 months later	Internal file for the last 20 years & also admission of the patient. They bleed occasionally but they are worse & again as since last week - internal one & blood files about the tumor all right by itself.
10/11/68	15/5/69		Cured	Small tumor a little bigger than a marble bead for the last 3 years - tumor between the perineal & the rectum - not quite embedded - does not get from the perineal & the rectum - tumor weighed 7 1/4 lbs - 10 lymphatics affected - 6 of them - small lymphatics of the lymphatic system

Date of Admission	Name	Sex	Age	Occupation	Country	Disease	Operation
30/10/80	Ally, Bura	M	40	lyce	Sierra Leone	Comp. fracture of the left internal malleolus.	Amputation of the leg at the upper third.

9/11/80	81 Rana Ransam	M	34	Farmer	Hind	Subst. Tumor	Excision
---------	----------------	---	----	--------	------	--------------	----------

6/11/82	82 Kasun	M	55	Victim	Sierra Leone	Comp. fracture of the right internal malleolus.	Amputation of the leg at the upper third.
---------	----------	---	----	--------	--------------	---	---



Date of Operation	Date of Discharge	Date of Death	Result or cause of Death	Remarks
14/11/68	19/11/68		Post Op. Inflammation	On the morning of the 20/10/68 - Present at the site was knocked down by a car moving of the chest & collection of Has got two lacerated wounds at semi lymph gland. The outer aspect of the left ankle, Long hypostatically caused the lower one superficial & the upper otherwise lateral - hypostatic deep - Probe goes down to the bone patch - Right Caerh - 8 which is fractured over the internal the right filled with ec- mallophs which is rough & & caused colored blood - Nerves & of its perosteum. Leg was put in a spleen healthy - Liver & splints - but the wound began to congest - General & slough - Patient had several attacks Optic Nerve Center of shivering, with a high temperature thin, long, long, colored rapid pulse & a dry tongue, with blood, with some redness other Constitutional disturbance, clot floating here & there inappetence & an pulseless, On the morning of the 14/11/68, an pulsation of the leg at its upper third, below the tunic, formed by antero-posterior flap in the calf - 8 ligatures applied left calf 22g of 6 thin long clot of blood - Flap draped with carbamide
17/11/68	15/3/69		Cured	After partial tumor about the size of a walnut 8 6 7 years standing - The tumor is round - skin thin & normal - Surface of skin hypertrophied - Embedded in the mass - It has been accidentally - Has been removed - In the end of the 2nd of the disease - Removed with calf Tumor weighed 9lb - 5oz - but about 12oz of blood - tubercles, Transposed - 20 ligatures applied -
20/11/68	28/1/69		Inflammation	Has got Compound comminuted fracture of the right internal malleolus & simple comminuted fracture of the external one, with simple fracture of the lower part of the tibia & fibula, all caused by the patient being knocked down by a car moving, about 1/2 hour before admission - Patient had collection of matter about the joint & fracture, Leg amputated by a circle for tumor of the a little below the tubercle - 4 ligatures applied - but very little blood



Date of Admission	Name	Sex	Age	Occupation	Residence	Disease	Operation
20/10/85	Inafoo	M	40	History	Island	Compd Comp. Fracture of phalanx of the 5th	Amputation & flaps

9/10/85	Ram Sutha Roy	M	32	Farmer	Hind	Scrotal Tumor	Excision
---------	---------------	---	----	--------	------	---------------	----------

16/10/85	Gyadordem	M	35	Cooley	Island	Compound fracture of the right internal leg, below the tubercle malleolus	Amputation of the
----------	-----------	---	----	--------	--------	---	-------------------



Date of Operation	Date of Discharge	Date of Death	Result or cause of Death	Remarks
20 Nov/68	25/12/68	Cured		Has got Compound Comminuted fracture of the last two phalanges of the last digit of the right hand caused by the hand being caught in a machine about 16 hours before admission - Injury removed at the junction of the 1 <sup>st</sup> & 2 <sup>d</sup> Phalanges - unresolvable
23 Nov/68	15/3/69	Cured		Has got scrotal tumor about the size of a man's head for the last 80 or 90 yrs. Had more applied to it about 4 yrs ago, but it was found - skin thickened by tubercles - Refused by patient, half embossed - felt for a time a bank - Had no removal - Reasoned unresolvable - weighed 5 lb - 93 - but 603 gbs and 23 ligatures applied -
25 Nov/68	17/2/69	Cured - removed by spine	On dissecting the leg	Came in with Compound fracture of the right internal malleolus, found removed of periosteum - Caused by a ball of lead striking in several places. There was the part while moving it about - necrosis of the internal malleolus - bone before admission - No small extent of the articular surface of bone were removed through the surface of the tibia - Opening few days after admission - The astragalus - The inter-art. patient was doing well, the some color fibro-cellular - some time ago when collection of matter formed - The medulla of the femur seen the head, there was found bone exposed - opened with subsequent death found in hip joint - ingested - had parts of the leg - There was proper healthy pus in them, neither in the solid discharge from it - burrowing upon it - & the bone was removed of periosteum in several places. The patient had a large dry & red - Temperature high - spoke rapidly - Leg supported below the tubercle, by antero-posterior & lateral clamps - but right the blood 9 ligatures applied - Bones sprayed with strong Carbolic Acid - & the stump dressed with Carbolic Acid soil - Patient kept here at the table after operation - Medulla of the bone white - anemic & not healthy -



Date of Admission	Name	Sex	Age	Occupation	Country	Disease	Operation
26 Nov 86	Pitamburjee	M	30	Iron	Hindu	Section between 7 mineral patches	Peroneal section

December 1886

25 Nov 87 Chundry 7 19 Bone Inadeq. elevation of the stump with cast up little higher up of the bone protruding. Amputation of the

27 Dec 88 Russen M 20 Servant India Rapidly forming Abscesses in the hip - Amputation at the hip -



Date of Operation	Date of Discharge	Date of Death	Result or cause of Death	Remarks
27 <sup>th</sup> Dec/62	28.5.63		Obscured with the perineal sinus ring now closed.	Had proctitis about 10 yrs ago & two yrs after, an abscess on the left ischio-sphincteric fistula & formed into a sinus, through which it has been through the ischio-anal sinus used to flow - Perineal section was performed in this and 5 yrs ago & he was all along perfectly well after this, till about 8 months ago, when he got pain after which the stricture came back & the old sinus & abscess & several other points in the perineal space - but proctitis has the same nature, & several abscesses & fistulae in the rectum - Perineal section performed 24.4.63 - Has operated once before in 9 <sup>th</sup> July 1863 & discharged 12 July 1863.
5 Dec/62	9/3/63		curd	About a year ago while the patient was in his third month of gestation, she had very severe hemorrhoids, which were operated on & resulted in many losses. The amputation was in the middle of the leg - but the stump after that, did not heal properly. There is elevation at the end, with which one inch of the bone protruding. - Now anterior & posterior flaps more & the bones seen a little higher.
6 Dec/62	7/2/63		Enlargement - In the P. M. State, all the internal organs were found pretty healthy, except the right lung - where 2 Cancerous nodules, about the size of a large marble, were found. One at the upper apex of the middle lobe, & the other at the upper surface of the lower lobe.	Has got a large diffuse, rapidly growing Cancerous tumor on the middle of the left thigh for the last 2 months, coming on spontaneously with pain & swelling appearing on the middle of the anterior aspect of the tumor. The tumor goes round the limb, above & very nearly reaches the groin, where is a hard lump about the size of an egg - & bulges to the lower 3 <sup>d</sup> of the thigh. It is hard, elastic, painful & immovable. - The circumference of the limb round the widest part is 20 inches. Plunkett for her & then - Anemia - pale mouth, full & quick - <sup>normal</sup> - removed at the hip joint - 25 ligatures applied - lost about 12 oz of blood - flaps sponged with strong Carb. Acid - Stumps packed with Carbolic acid wool - Plunkett with the cable, but retained afterwards by the tumor.



Date of Admission	Name	Sex	Age	Occupation	Country	Disease	Operation
20. 8. 88.	Paul Anthony	M	16	None	Native	Fibrous Polypus of Colon, the left position on hand -	Excision
4. Dec. 89	Spurfin & Co	M	56	Dr. Collector	India	Tumor under the muscle of the left stern. measured 8 in front and with the nipple.	Removal by ligatures



Date of Operation	Date of Discharge	Date of Death	Result or cause of Death	Remarks
4th Dec 1887 9.20.00	"	7/12/87 5.15.00	Of exhaustion & perhaps of internal hemorrhage - the day taken away -	Has got a fibrous polypus at the left position basis, of 8 months growth. Coming on gradually after a severe catarrh - It was 6 lbs. very much before, but now, 6 lb. in quantity & at a longer interval - Patient weak & anemic, but on bitter & ferruginous tonic, & after he got little strength. The tumor removed by volcillum - It was about the size of an egg - but about 4 oz. 1 lb. & hostial plumped - Pale rather pale
10th Dec 1887 9.05.00	"	18/12/87	Has taken away by his brother before death while the patient was at French Bells, near of Inghamstown & he had an attack of fever & throat, Laryngitis, this being the former lasting for about 10 days, but the cancer by the irritation of the Pneumoniae here.	About six months before a diagnosis by his brother before death while the patient was at French Bells, near of Inghamstown & he had an attack of fever & throat, Laryngitis, this being the former lasting for about 10 days, but the cancer by the irritation of the Pneumoniae here. From early after the diagnosis of the tumor, a small swelling had been noticed, appeared at the middle of the left sternum - marked tumor, the swelling increased in size, & then a cough & expectoration became affected, the former principal & the latter & the brain. Tumor for the last 3 or 4 days, the tumor has been affected, it is large & has 1 lb. & 1/2. At present the tumor is about the size of an egg - placed under the middle of the sternum, the tumor is firm & round the neck - Pericardium & esophagus affected - Tumor removed by volcillum by lines - but very little blood - 2 or 3 small vessels cut & by nature of the tumor was affected at the center for some about 3/4 of an inch came out - the base of it attached to the sheath of the vessels, both behind - Breathing became easier after the operation - The fibers of the muscle were incorporated with the mass of the tumor, the lower end of it was, it is highly mal-odorous -



Date of Admission	Name	Sex	Age	Occupation	Country	Disease	Operation
11.12.68.91	Rogers, Peter Bangor	11	2	Stone	Ireland	Slit abscess	Drained

11.12.68.92	Rogers, Peter	30	2	Corley	Ireland	Simple comminuted fracture of left humerus. The shoulder-scapulae separating.	Amputation at fracture of left humerus. The shoulder-scapulae separating.
-------------	---------------	----	---	--------	---------	---	---

6.12.68.93	James, Terence	34	2	Carpenter	Ireland	Stricture urethra	Dilatation by Holtz dilator
------------	----------------	----	---	-----------	---------	-------------------	-----------------------------



Date of Operation	Date of Discharge	Date of Death	Result or cause of Death	Remarks
11.12.68	"	24/12/68	Brain haem. and Embolism -	Has pt a large fluctuating swelling over the left knee again; Com mended about 4 1/2 months before admission, coming on after fall - The left thigh is contracted knee could be extended - patient drowsy - pt. for occasionally - pulse small but & quick - swelling spread & tip of left leg. but not - What felt relieved after this -
17/12/68	"	18/12/68	Enlarged Liver Sp. clts. in the stomach - Lung - Liver - Kidneys & healthy - auxiliary vein - arterial - X	Has pt simple comminuted fracture of the left humerus, a lacerated wound over the outer aspect - of the left elbow - on very large one over the point of the scapula; Caused by the fall of a bag of cloth from his head, while carrying - On improvement of the symptoms of Jaundice the limb was removed by amputation at the shoulder but very little blood - 25 l. of plasma applied -
28/12/68	12/3/69		Cured Catheter no 12 easily inserted	Has been suffering off & on from Stricture urethra for the last 10 years beginning after gonorrhoea, Had in a London Hospital 8 yrs ago, when thought he was cured & he was discharged much relieved - He was much better all things, till about 3 yrs ago when the stricture got worse - Took admission in this Hospital - Cath. no 5 passed & discharged immediately much relieved - Since last few hours of admission, water dribbling in drops - the line worse - when it tried, but could not be passed by the office in dept - Next morning catheter no 4 passed with great difficulty by the Surgeon - Stricture placed almost throughout the whole length of the urethra - Dilated by Hottel's Dilator



Date of Admission	Name	Sex	Age	Occupation	Country	Disease	Operation
23/12/68 94	Anon. Pouch	Ir	55	Beaver	Hein	Suppuration in the knee joint -	Amputation at the middle of the thigh



Date of Operation Date of Discharge Date of Death

Result or cause of Death

Remarks

29/12/68

"

8/1/69

Sakaguchi

Is pyramic patch long  
where found on back  
intertransverse line.  
There was slight hypostatic  
congestion of the lungs -  
effusion of the left side

About a fortnight before admission  
a wheel in motion struck his left  
knee, causing then little or no  
injury, except slight pain and  
swelling over the point struck - By  
degrees both these increased,  
suppurated, and about 10 days  
prior to admission opened of itself  
in 2 places, one above & at the outer  
aspect of the joint & the other below  
& at the inner aspect, involving  
the joint which is now well swollen,  
& cannot be bent fully - Pus comes  
with the joint though both the openings  
then a good deal of discharge - more  
frequent & rapid - Limb remains  
at the middle of the thigh, by external  
extension flaps, but about 4 oz of  
blood - 18 lig. applied - flaps pale  
& fleshy - blood thin & stony - flaps  
sprung with sharp carbolic acid - skin  
rough with acid & oil - Patient sits  
very low at the table -



Date of Admission	Name	Sex	Age	Occupation	Country	Disease	Operation
-------------------	------	-----	-----	------------	---------	---------	-----------

2

[illegible]



Date of Operation Date of Discharge Date of Death

Result or cause of Death

Remarks

formed in 1860 by Dr. Jagers

Number	Names of operation	Result				Cause of death							Remarks
		Surv.	Rel.	Dis.	Total	Caustic & Amputation	Hæmorrhage	Septicæmia	Shock	Exhaustion	Other	Causes	
28	Reduction of	"	"	"	"	"	"	"	"	"	"	"	"
	Dislocation of	"	"	"	"	"	"	"	"	"	"	"	"
	Sub-coracoid	2	"	"	2	"	"	"	"	"	"	"	"
	Acromion	"	"	"	"	"	"	"	"	"	"	"	"
	Subglenoid	1	"	"	1	"	"	"	"	"	"	"	"
29	Division of Tendon	"	"	"	"	"	"	"	"	"	"	"	"
	of	1	"	"	1	"	"	"	"	"	"	"	"
30	Dislocation	1	"	"	1	"	"	"	"	"	"	"	"
31	Resection of	"	"	"	"	"	"	"	"	"	"	"	"
	Acromion	1	"	"	1	"	"	"	"	"	"	"	"
32	Gynæc. Operation	"	"	"	"	"	"	"	"	"	"	"	"
	for Hernia Testis	1	"	"	2	"	"	"	"	"	"	"	"
33	Plastic Operation	1	"	"	1	"	"	"	"	"	"	"	"
34	Excision of	"	"	"	"	"	"	"	"	"	"	"	"
	of Vagina & Uterus	1	"	"	1	"	"	"	"	"	"	"	For Epithelioid Cancer
	Total				10								
	Total				84								
	prostituted				94								of this
	blat				17								
	68 9 17 94												
	of this					1	2	"	1	1	9	3 = 17	death
	=					94							

Date of Admission	Name	Sex	Age	Occupation	Country	Disease	Operation
January 1869							
16 Dec 68	William Huggins Jr	M	44	Carpenter	England	Recto-fallopian	Lateral Ligation

11 Dec 68	2	Shah Jemal	M	40	Moslem	India	Rectal Tum <sup>or</sup>	Excision
-----------	---	------------	---	----	--------	-------	--------------------------	----------



Date of Operation	Date of Discharge	Date of Death	Result or cause of Death	Remarks
June 1869				
7th May/69	18/2/69		Cardiac Involvement & pyæmia	<p>The patient was a man from Bangalore, by a lady, father he died his way &amp; fell down on the stump of a young tree which went in right into his Rectum &amp; injured his bladder. Patient fainted at the spot, lying for little for about 3 or 4 hours after which he got distance to the P. L. Artery up &amp; rose home. Next morning was taken very much enlarged &amp; inflamed by Dr. Kennedy who selected Spotted all over with pyæmia an opening communicating the bladder &amp; deposit about the size of a pea. Sp. L. Artery &amp; passing urine through the Rectum as soft as - Bedraggled as another - On the same day after through himself enlarged admission of the stone found a very small nucleus membrane of the stone &amp; during the bladder, symptoms bladder, enlarged &amp; thickened stone selected - Operation of lateral Recto-urethral fistula seen &amp; the stone removed &amp; a stone about 1 lb by lying open the rectum &amp; size of a large marble, length about 1 1/2 inches - Patient was discharged - It weighed 13 1/2 lbs.</p> <p>As cured - with the exception of slight pain - from which he was suffering since a boy &amp; was known to that - Came with few days after in a state of emphysema</p> <p>Cured</p>
12 May/69	23.5.69			<p>Has got a large tumor about the size of a man's head in the back of head &amp; neck - Brother this tumor, most abundant - Peris Brachioradialis the 2nd of the 2nd - It is full with bone changes - Tumor inflamed during febrile paroxysm - Had frontals about 10 3/4 up &amp; closed - 10 years ago - Has a pharynx of the right by &amp; full for the last 10 years - Patient anemic - Tumor removed - weighed 2 1/2 lbs. 25 1/4 - 1/2 of blood - about 6 oz of hyaline fluid came out from each side - Patient weighed 75 - 7 lbs - On the day of operation 75 - 13 1/2 -</p>



Date of Admission	Name	Sex	Age	Occupation	Country	Disease	Operation
18 Sept 1896	J. Hallgren	M	40	Cook	Sweden	Ecthyma of the upper lip.	Excision

21 Sept 1896	Shank's General	M	22	Student	Sweden	Compd. comm. fr. of the fracture of right tibia & fibula.	Amputation of the leg - upper third
--------------	-----------------	---	----	---------	--------	---	-------------------------------------

29 Sept 1896	Radab	M	12	Student	Sweden	Fracture of left leg, compound on comp'd fracture of tibia & fibula above the ankle.	Amputation of leg - upper 3/4
--------------	-------	---	----	---------	--------	--	-------------------------------



Date of Operation	Date of Discharge	Date of Death	Result or cause of Death	Remarks
18 Jan / 69	10/2/69		Wound healed by immediate union	That 5 years ago had a small pimple above the upper lip. This was scratched & some serum fluid let out; and the pimple instead of healing, has been since then enlarging - Has at present an ulcer, oval, about the size of a nickel - over his upper lip - Scarpin entered - some pain on stretching from it. Some of the neighboring glands enlarged - No fear of history of Cancer - While I was removing this morning - & the scarpin brought large clot by suction (three lumps) Two small abscesses near one on each angle of the mouth, & skin around
20 Jan / 69	2/2/69		Cancer Imbolition & Pyemia - P. M. H. T.	Small pyemic patches in the lungs - especially the right - Quite matured also in the right Cavalier of the heart - A large abscess in the right side of the liver - Pus in the Popliteal - General run as high as the middle of the thigh - A thin red blooded old child - A hoarse cough at the upper half - Said run badly - Spleen - Kidneys Enlarged
21 Jan / 69	9 am.	25/1/69	Cancer Imbolition & Pyemia - P. M. H. T.	Transferred from the chestnut of the left gangrene of the foot of the left leg - Improving in the 19th partial Compound fracture of the Tibia & Fibula 2 inches above ankle, caused by the fall of a bunch of tea over the limb on the 16th inst. - On admission whole left leg was gangrenous - Patient very low - with achy tongue - pale & rapid pulse - & Constipated delirium - Stimulants were given - Patient got little better - limb removed next morning at the upper 3rd of the thigh by antiseptic flap - lost very little blood - 12 lbs. - 4 lbs. solid - cellular tissue & epithelium muscles healthy



Date of Admission	Name	Sex	Age	Occupation	Country	Disease	Operation
22 May 68	Wm. J. H. H. H.	M	20	Farmer	Ohio	Wound with (Chronic inflammation) Exposure on driving wound.	Actual Caustic

2 <sup>d</sup> May 69	Wm. J. H. H.	M	60	None	Ohio	Compound fracture of leg of left Tibia & Fibula after 3? Tetanus supervening	
-----------------------	--------------	---	----	------	------	--	--

February 1869

16 Dec 60	Mr. Huggins	M	44	Careless	English	Suppurating Throat Abscess	Opened
-----------	-------------	---	----	----------	---------	-------------------------------	--------

5/2/69	Samuel H. H.	M	35	Watch-maker	Ohio	Scrotal Tumor	Excision
--------	--------------	---	----	-------------	------	---------------	----------



Date of Operation	Date of Discharge	Date of Death	Result or cause of Death	Remarks
22 Aug/69	27/8/69		Cure d	<p>Went 2 months ago, had a fissure of wound over the outer &amp; middle part of the dorsum of the left hand, this healed 6 or 7 days after, without any Constitutional disturbance - About 3 weeks after, he had fever &amp; with it inflammation of the left foot; the fever &amp; acute symptoms of inflammation gradually subsided, leaving the hand &amp; wrist in a swollen &amp; painful state, pain being troublesome at night. On admission to ward of the left hand &amp; wrist found swollen &amp; painful - pain increased at night, hoping - Actual Caustic applied. One on each side, each about 5 inches long.</p>
31 Aug/69	18/9/69	Exhaustion		<p>Came in with compound fracture of left tibia &amp; fibula at their lower parts, caused by being run over &amp; starved by a carriage. Leg was put on in Dec: Jones's Splint - tetanus supervened &amp; the leg was amputated at its upper 3rd by antiseptic flaps - lost very little blood - Iodoform applied.</p>
2 Feb/69	18/2/69	Carotid Embolism Pyæmia - Vide No 1 of Aug/69		<p>Came in with Pseudo-epithelioid &amp; vesicular Calculus - &amp; for the latter of which, lateral lithotomy was performed. During the course of treatment after operation deep-seated matter formed in the right iliac region - Patient put under chloroform &amp; matter let out by opening the Spinal Canal. Vide No 1 of 1868</p>
12/2/69	3rd-69	Chorea		<p>Had Sarcoid tumor about the size of a man's head, for the last 8 yrs. Com - mencing on the right in hydrocele, The penis is embedded in the tumor, felt for urethra &amp; testis, but with no communication with the urethra - Hard mass removed - Had hydrocele tapped before about 3 yrs ago - Removed. In weight 6 lbs. 2 oz hydrocele - lost about 4 oz when 30 lbf. applied -</p>



February/69

Date of Admission	Name	Sex	Age	Complexion	Country	Disease	Operation
12/2/69	10 Jacob (Jung) Chackerbuthy	Male	25	Priest	India	Scrotal Tumor <sup>144</sup>	Excision
15/1/69	11 Goroogal Karmakon	Male	30	Farmer	India	Scrotal Tumor <sup>145</sup>	Excision
27/7/69	12 Karamet	Male	9	Slave	India	Synovial disease of right ankle	Incision of the joint



February 1869

Date of Operation	Date of Discharge	Date of Death	Result or cause of Death	Remarks
16/2/69	10.4.69	1869	Cured	Scrotal tumor about the size of a large orange, for the last 2 years - Scrotum thickened - penis hypertrophied but unhardened - had to get penile before, but now now - Had Syphilis about 4 or 5 yrs ago - Remained - weighed one pound - 15 lb. applied - no hydrocele but very little blood -
16/2/69	26/2/69		Right <sup>testicle</sup> became gangrenous & removed	Scrotal tumor about the size of a man's head for the last 12 years - Commencing in right side in hydrocele has tapped about 5 yrs ago, when some fluid let out - Scrotum thickened - penis unhardened, Had never removed - Tumor combined with hernia of the right side - Remained under chloroform very painful but about 8 oz of blood 2 lb. applied - weighed 2 lbs. 100g. Hydrocele on both sides about 10 lb of fluid, containing crystals of cholesterine, Came out from each sac - Tunica Vaginalis thickened -
17/2/69	27.3.70		The foot became what better; but still there was a few sinuses, leading into softened bone. He had been gradually becoming more & more exhausted, & scrofula breaking out in most of the small joints of his hands & feet, when he was taken away by his friends -	About 5 months before admission. Sprained his right ankle while playing, & held it very much in pain - A month after the accident it was found by a quack on dissection of existence of matter, but nothing except little blood came out. The swelling having instead of healing is found with an abscess - Subsequently 3 or 4 swellings formed about the joint & formed into many abscesses of which about the size of a goose's egg & communicate with the joint - The ankle very much swollen - thickened - & with the motion - no flexion - Leg put on splint & after the patient improved in health, incision performed - 3 incisions made, one on each side of the ankle & third one behind the heel - The matter came out - but very soft & mucous in places - A bit of callous scrofulous removed as near as shell - no report of impurities drained



February 1869

Date of Admission	Name	Sex	Age	Occupation	Country	Disease	Operation
17/2/69	13 Ayce Ahmed	En	56	Miller	India	Stricture urethra	Bilobation by Holtz bilator

March 1869

9 <sup>th</sup> March/69	14 Charles Morrison	En	52	Superior	E. Ind.	Stricture urethra	Bilobation by Holtz bilator
--------------------------	---------------------	----	----	----------	---------	-------------------	-----------------------------

2 <sup>nd</sup> Jan/69	15 James Broadfoot	En	33	Clark	Scotch	Inguinal Hernia	Radical cure
------------------------	--------------------	----	----	-------	--------	-----------------	--------------

1 <sup>st</sup> March/69	16 Fakier	En	28	Farmer	India	Fibrocystic tumor of the sup. maxillary bone	Excision of anterior portion of the right sup. maxillary
--------------------------	-----------	----	----	--------	-------	--	--



February/69

Date of Operation	Date of Discharge	Date of Death	Result or cause of Death	Remarks
21/2/69	25/2/69		Cured. Patient absconded. pale sized instrument & no sign of testis.	Has got stricture in the last 5 or 6 months, coming on gradually after gonorrhea from which the patient has been suffering for the last 5 or 6 years. There is smarting during micturition - Urine not passed with great difficulty - Stricture dilatation & Cat. 20/12/68
12 <sup>th</sup> March/69	6/6/69		Cured. Full sized instrument @ 1/2 passed with ease.	Suffering from stricture in the urethra for the last 5 or 6 years, as a sequel of gonorrhea, the patient had prior to that. Was in St. Peter's hospital about 3 yrs ago when Cat. 12/5/68 passed & he was discharged & he released. Was much better for some time - after, but the stricture got worse again. Instrument was tried by Dr. Leach, but nothing could be passed - he found that he was dilated by Dr. Ferguson & Cat. 20/12/68 passed -
9 <sup>th</sup> March/69	18.5.69		Cured	Suffering from sigmoid hernia of the right side for the last year & a half. It came on first in an effort to jump over a fence while riding. Say that a bundle of straw came down with the patient at once - & he broke off a rib - hernia at once since then, except once when he was in the clothes band - The internal abdominal organs were displaced in a croup - Patient of poor health - When first informed by Dr. Leach, then he was referred to Dr. Leach - Plug came out of rectum on the 15/3/69 -
12 <sup>th</sup> March	2/4/69		Cured absconded	Has got a hard swelling about the size of a large marble, growing since last year from the right superior maxillary, under the right half of upper lip - It commenced in a swelling at the root of the right incisor - The right nostril is slightly encephalic - upon the mouth at the level of the lower maxilla with anterior of sup. max. bone with 5 teeth - by the maxilla mode in the median line, reflecting the lips & cutting through the nostril - floor of which measured - Blowing stuff & actual cutting



March/69

Date of Admission	Name	Sex	Age	Occupation	Country	Disease	Operation
22/2/69	17 Chas. H. 45p	M	46	Swamp	India	Stricture urethra	Perineal section

24/2/69	10 Murish (L. Nanyu)	M	50	Man	India	Scrotal Tumor	excision
---------	----------------------	---	----	-----	-------	---------------	----------

12 <sup>th</sup> Feb/69	19 R. J. M. 6	M	40	British	India	Phymosis	Circumcision
-------------------------	---------------	---	----	---------	-------	----------	--------------

20/3/69	20 Mrs. Rant	F	17	Former	India	Subcutaneous	Radical Cure
---------	--------------	---	----	--------	-------	--------------	--------------



Date of Operation	Date of Discharge	Date of Death	Result or cause of Death	Remarks
14 <sup>th</sup> March		4.4.69	Oxygen and kidney disease	Has Throat matter for the last year Suffering gradually in front of he had 2 yrs prior to that - Had abscess in the perineum 6 or 7 months ago. There spread of the matter & formed with fistula Communicating with the matter, has at present - very bad Throat - with any fistula & abscess on the face has been a enlargement of the testicles - Perineal section performed with chloroform and S. S. tube kept in -
16/3/69	11.7.69		Cured -	Testicular tumor about the size of a man's head of 5 yrs growth, It commenced on the left side & then gradually extended to the right - skin thickened - pain embarrassed - had to get down before with lunar changes, but none since last 3 or 4 months - Tumor used to inflame with febrile paroxysms - Discovered not hereditary - Tumor re- moved weighed 4 1/2 lbs - 2 1/2 lbs. applied - there was hydrocele of the left testis - but about 1/3 of blood
17/3/69	6.5.69		Cured	Has phymosis for the last year, resulting from the cicatrization of Chancres, the patient had seen about the margin of the Prepuce a little white before that - Skin cannot be drawn back, it is adherent to the Glans Internal urinary orifice Contracted - makes water in small streams - Phymosis Circumcised - Orifice dilated by an incision.
22/3/69	29.4.69		Cured for hernia	Small oblique inguinal hernia of Concorda kind not quite the left side of the groin healed at the time of coming on spontaneously & gradually enlarged Ring well defined - admits middle finger easily - Distinct impulse on coughing - Operated under chloroform by Dr. Brown



March 1869

Date of Admission	Name	Sex	Age	Occupation	Country	Disease	Operation
22 <sup>nd</sup> March 21	Khetan hase th Khetan hase	Mr	18	None	Hindu	Fatty Tumor	Excision

24/5/69	22	Jaman	Mr	40	Driver	Hindu	Scrotal tumor <sup>169</sup>	Excision
---------	----	-------	----	----	--------	-------	------------------------------	----------

April 1869.

5.4.69	23	Jahan	Mr	30	Rheumatism	Hindu	Hernia Testes	Reduction by syme's operation
--------	----	-------	----	----	------------	-------	---------------	----------------------------------

7 <sup>th</sup> 4.69	24	Koyash Chakraborty	Mr	30	None	Hindu	Syphilis	Tapped
----------------------	----	--------------------	----	----	------	-------	----------	--------

"	25	Goderich Gargay	Mr	26	None	Hindu	abscess (scrophulous) opened in the neck	
---	----	-----------------	----	----	------	-------	---	--



March 69

Date of Operation	Date of Discharge	Date of Death	Result or cause of Death	Remarks
22 <sup>nd</sup> March	5 <sup>th</sup> 69		Discharged very much healed.	Has got a soft movable tumour about the size of an egg, over the left hip. Similar to ulcers from the last 4 years. Coming on in a small pea-like swelling which gradually increased to the present size. The skin over the tumour shranked & is - Coloured like a cicatrix lipae & the tumour mostly painless - Remained more enlarged by oral medicine only. Had very little blood-letting applied.
26 <sup>th</sup> March	15 <sup>th</sup> 69		Discharged very much healed	Scrofulous tumour about the size of a large walnut of one from the groin. The scrofulous is thickened, Penis hypertrophied, and embedded. Had syphilis about 6 or 7 years ago - Set free - now & then remained more enlarged - it weighed 2 lbs. Ligatures applied - but about 2 or 3 of the 2 -
6 <sup>th</sup> April	30 <sup>th</sup> 69		Cured	Hernia testes of 3 months standing followed after an abscess - structure of the testes much altered and adhesion. General health of the patient pretty good. Had syphilis 3 years before this - Very little bleeding & 2 ligatures applied.
16 <sup>th</sup> April	2 <sup>nd</sup> 69		Discharged cured of his syphilis - but still of his right ankle which came a phlegmonous was not better - the knee though a little stiff was yet quite useful.	Chronic sinusitis of the left knee of 2 yrs standing stopped and about 6 ounces of thick oily and yellowish almost-puriform fluid came out. Patient had syphilis 10 yrs ago. General health of the patient tolerable.
16 <sup>th</sup> April	31 <sup>st</sup> 69		Relieved - sinuses nearly healed.	Patient - scrofulous. Has got - on any abscesses on the left side of the neck. General health much pulled down.



Date of Admission	Name	Sex	Age	Occupation	Country	Disease	Operation
11 <sup>th</sup> 4. 69	25 Darmi Souds	m	50	Cook	A.H.T.	Tumour cystic on the forehead as the wry the nose	Excision

8 <sup>th</sup> 4. 69	26 Hossein ali	m	35	Printed	Kahed	Scrofula tumour	Excision
-----------------------	----------------	---	----	---------	-------	-----------------	----------

Baboo Issur Chunder Roy is directed operation immediately after it has been A-  
 Hazrat. 28<sup>th</sup> May 1869.

29/3/69	27 Abujahe	F	26	none	Bengal	Aggravitis of nose (left side)	Tapped
---------	------------	---	----	------	--------	--------------------------------	--------

12 <sup>th</sup> April	29 Kadir	m	40	none	Bengal	Fracture of Patella ununited - right side - by joining the two bones fracture. Surfaces - bringing them together	Plastic operation
------------------------	----------	---	----	------	--------	--	-------------------



Date of Operation	Date of Discharge	Date of Death	Result or cause of Death	Remarks
12 <sup>th</sup> April	26/5/69		Cured -	Tumor about the size of a large nut of 7 years standing - full of sebaceous matter - removed by one incision almost bloodless without chloroform Patient - a good strong man
13 <sup>th</sup> April	19-7-69		Cured - latter became placid opened skin with cicatrizing ointment & infection of this -	Small Tumor very vascular never had syphilis - general health of the patient good - inhabitant of a malarious district - (Pepore) - 12 ligatures applied -
30/3/69	11/6/69		Synovitis cured. Discharged with rather imperfect movement of the joint -	Synovitis of left knee coming on a month after recovery from an attack of diphtheria. 2oz of straw colored fluid let out by a small trocar punctured on the outer side of the joint - 6 months after the first beginning of it, was <del>it</del> stopped - It became less painful - <sup>after</sup> 5 days <del>the</del> the joint was <del>stopped</del> - It has since been improving. Embrocations begun on 12 <sup>th</sup> May -
17 <sup>th</sup> April	29/4/69		Pyæmia & corditis Embolism -	Patella broken by a fall. Simple fracture - a transverse incision was made over the line of fracture - the surface of bone pried off & the bones approximated by S-Bandage. Joint not opened but a <sup>phlegmon</sup> abscess gradually went into it - General health of the patient was good.

In response each entry you written that I may see and approve



Date of Admission	Name	Sex	Age	Occupation	Country	Disease	Operation
10/4/69	J. F. Forsberg	M.	29	Swiss Seaman	Switzerland	Stricture bladder	Holt's Dilatation by the longer Instrument

23/4/69	30. Wil. Cray.	M.	43	Seaman	England	Do.	Do
---------	----------------	----	----	--------	---------	-----	----

26/4/69	31. Bahr Sheikh	M.	30	Do.	Bengal	Compound Fracture of Right Ring Finger - above the head of the metacarpal bone.	Amputation
---------	-----------------	----	----	-----	--------	---	------------

16/4/69	32. Loughckow	F.	25	Do.	Bengal	Fracture of the Irish Cartilage with cartilage -	Actual Country in 3 lines across the wrist -
---------	---------------	----	----	-----	--------	--	--

30/4/69	33. Kellatam	M.	23	Do.	Do.	Piles (External & Internal)	Excision Ligature
---------	--------------	----	----	-----	-----	-----------------------------	-------------------



Date of Operation	Date of Discharge	Date of Death	Result or cause of Death	Remarks
12/4/69.	23-4-69.		Cured.	Stricture of 6 years standing coming on after gonorrhoea - General health good - Had again 2 days after operation No: 10 catheter passed on 16 <sup>th</sup> & No: 12 on 18 <sup>th</sup> April -
24/4/69	24-7-69.		Cured of his stricture. Gonorrhoea infected -	Stricture of a year & a half's duration improving upon venereal <sup>or syph.</sup> for 8 years before - Had retention of urine once before - & was admitted to with this - No: 5 Catheter could be passed then - Holts Dilator proposed on the succeeding day: No: 10 Catheter was passed - He got fever in the evening - He went on his bowring; but <del>getting</del> <sup>got</sup> procturnal fever whenever the passage was dilated or irritated by Catheter or sound - Every attack lasting for 2 or 3 days & passing off by Quinine -
26/4/69.	26-5-69		Cured.	Immediate amputation was done - Carbolic Dressing was used: & the granulations were copious, with but little discharge.
29/4/69.	12/6/69		Cured - with full power of the hand. Speedy motions.	Had Rheumatism implicating all the joints - with fever - a month or a half before - All these got well; but the worst remained swollen & painful - Pain relieved some at night - Much it was relieved immediately after the Castration Issues left them for about 3 weeks. Friction gradually diminished & ultimately disappeared by the beginning of June -
2/5/69	3/6/69		Cured.	Admitted with inflamed piles - after the inflam <sup>n</sup> was subdued, the external ones were excised the internal ones ligatured - He had been doing well, when he got erysipelas in the buttocks; & we reduced him much. He was discharged cured after a month.



Date of Admission	Name	Sex	Age	Occupation	Country	Disease	Operation
May 1889							
6/3/89	34 mil. Solway	m.	38	None	England	Cleft nose. left ala.	Edges paired & stitched with 1/2 inch ligith Horse hair -
14/4/89	35 Dorantoolch	m.	40	Cartman	Bengal	Traumatic arthritis of the right knee -	Knee tapped several times - Ligaments on inside opening made above the joint on the inside -
14/5/89	36 Corruendo	m.	10	Knigh	India	Slit above left side -	An oblique incision above Papez's ligament -
21/5/89	38 H. Charyoll Baul	m.	9	Schoolboy	India	Compound Fracture above the condyle of humerus (left) with Collie's fracture of the same -	Amputation at shoulder joint



Date of Operation	Date of Discharge	Date of Death	Result or cause of Death	Remarks
7/5/69.	19/5/69		Cured.	Had his left ala nasi cut by a knife in a row about 12 years before - The paired flaps united by direct adhesion in less than 24 hrs. - But the following day the entire necrotic tissue off - only the very end of the flaps did not unite -
10/5/69				
24/5/69.	10/6/69		Phthisis laryngea & Tuberculosis thoracis - Black tubercles throughout the lungs -	Arthritis of 8 months duration brought on by a blow in the knee - The patient Phthisical. Extensive suppuration set in within the joint - On the 1 <sup>st</sup> tapping on the outside, one ounce of purulent fluid obtained - 9 days after it was tapped again on the inside & an opening made <del>into</del> on the outside of the tubercle of the tibia, about 6 ounces of yellowish green pus obtained & the puncture kept open. The joint used the syringe out with Carbolic Acid lotion: the opening gradually enlarged & another one was made above the inner one on 26/5/69. The fever he had been getting abated. Laryngeal Phthisis & Tuberculosis supervened, & continued unchecked, & of which he at last died -
14/5/69	31/5/69		Relieved -	Abscess very deep. Almost within the true pelvis, near the back part of rectum - One or two ounces of pus came out. It continued discharging purulent matter till he was considered safe, & he taken out by his friends, under medical attendance
27/5/69	31/5/69		Osteomyelitis causing Pyæmia & pulmonary embolism -	Injury from a fall from a tree 7 days before admission - External wound Attempt was at first made to preserve the limb. But repeated sequestra (about 4) ensued: the simple Colles' fracture became compound. Fever



Date of Admission	Name	Sex	Age	Occupation	Country	Disease	Operation
May 1869.							
6/5/69	34 bil. Solway	m.	38	None	England	Cleft nose. left ala.	Edges joined by <sup>stitching</sup> & covered up with horse hair -
14/6/69	35 Dorantoollel	m.	40	Cartman	Bengal	Traumatic arthritis of the right knee -	Knee tapped several times - Saphenous vein incised opening made above the joint - in the inside -
14/5/69	36 Corraudo	m.	10		Brazil	Hiac abscess left side.	An oblique incision above Papez's ligament.
21/5/69	38 Bichangol Baul	m.	9	Schooling Hindu		Compound fracture above the condyle of humerus (left) - with Colles' fracture of the same.	Amputation at shoulder joint



Date of Operation	Date of Discharge	Date of Death	Result or cause of Death	Remarks
7/3/69.	19/5/69		Cured.	Had his left ala nasi cut by a knife in a row about 12 years before - The paired flaps united by direct adhesion in less than 24 hrs. - But during day the sutures were taken off - only the very end of the flaps did not unite.
10/5/69				
24/5/69.	10/6/69		Phthisis laryngea & Tubercular Eriothosa - Black tubercles throughout the lungs -	Arthritis of 8 months duration brought on by a blow on the knee. The patient Phthisical. Extensive suppuration set in within the joint. On the 1 <sup>st</sup> of June on the outside, one ounce of purulent fluid let out. 9 days after it was stopped again on the inside & an opening made <del>on</del> on the outside of the tubercle of the tibia, & about 6 ounces of yellowish green pus let out & the puncture kept open. The joint used the syringe out with Carbolic Acid lotion: the opening gradually enlarged & another one was made above the inner canthol on 24/5/69. Thereafter he had been getting abated. Laryngeal phthisis & Eriothosa supervened, & <del>the</del> continued unchecked, & of which he at last died.
14/5/69	31/5/69		Relieved.	Abscess very deep. Almost within the true pelvis, near the back of rectum - One or two ounces of pus came out. It continued discharging purulent matter till he was considered safe, & was taken out by his friends, under medical attendance
27/5/69	31/5/69		Osteomyelitis causing Pyæmia & pulmonary Abscess & Eriothosa	Injury from a fall from a tree 7 days before admission - External wound extensive, sloughing & suppurating. Attempt was at first made to preserve the limb. But repeated sequestræ (about 4) ensued: the simple Colles' fracture became compound. I am



Date of Admission	Name	Sex	Age	Occupation	Country	Disease	Operation
21/5/69.	Behazoll.	M.	9	Schoolboy		Comp. Fracture	Amputation
	(Continued)						

24/5/69	37 Hugh Jones.	M.	17	Student	Carson	Badly united Fracture of Left Radius at its middle,	Broken again.
---------	----------------	----	----	---------	--------	---	---------------

June 1869.

28/5/69.	40 Rogers Lath	M.	26	hore	Payel Hindin	Scrotal Tumor.	Excision -
----------	----------------	----	----	------	-----------------	----------------	------------



Date of Operation Date of Discharge Date of Death

Result or cause of Death

Remarks

P. Mortem Exam<sup>n</sup>

A large gangrenous patch at the base of left lung. Pyemic patches of variable magnitude, mostly white & curdy, with some with a dark branching central nucleus - were chiefly found in the right lung. Diffuse pleuritis of right side with soft - not thin lymph & blood serum in left pleura & pericardium. A quantity of purulent fluid also was found in the right pleura.

Right heart - filled with autolysed clots - from auricle to pulv<sup>us</sup> & vessels.

Osteomyelitis & Pyemia

aged abt 104 Feb 1837. blue heron shape off - Amputation at joint done at the upper third of the arm, showed the bone to possess thickened periosteum, & suppurated medulla (offensive & dark yellow). Amputation immediately again was performed at the shoulder. The dark yellow fluid stopped just at the upper epiphyseal line, above which the head of the bone was all pink & healthy (typical osteomyelitis)

24/5/69

14/6/69

Discharged convalescent. Fracture not then quite firm - but was pretty firm straight.

Fracture from a fall 8 months ago united with a concavity upwards i.e. back - was broken again by forcible straightening of the forearm by the hands & the knee (as fulcrum) of the surgeon. I put a straight splint, & he was discharged with quite a straight limb. The union pretty firm -

3/6/69.

28/9/69

Andromeda leafy black.

Tumor of the size of a child's head, of only 2 years' duration, increasing irregularly with the lunar changes, without any periodical fever, but with a periodical aching of the left testicle & the inside of the left lower limb. Lasting for only a day, leaves the scrotum larger & temperament sanguineous. Got acid stomach for 8 or 9 years. Had syphilis <sup>15</sup> years before - he weighed 7<sup>st</sup> 7<sup>lb</sup>. Tumor weighed 5<sup>lb</sup> 2oz. no hydrocele; but seems infiltration of the hypertrophied scrotum & penis with Phymosis - 19 discharges were required after the excision, & he lost but little blood, about 4<sup>oz</sup> 8oz. By the 6<sup>th</sup> the first dressing changed: & by the 10<sup>th</sup> the sore was healthy granulating under Eothal oil & gentle foot - dressings



Date of Admission	Name	Sex	Age	Occupation	Country	Disease	Operation
5th June/69	41 Prokium Shaid	M.	40	Koolay	India	Fractured tibia - upper third - a Contused Wound at inside of left knee with severe sprain of the joint - bringing on Traumatic gangrene. Spreading -	Amputation of leg one inch below the Tubercle of Tibia -

4/6/69	42 Maj Bish Baharja	M.	30	Trade	India	Anal Fistula (open)	Sphincter ani (only the external?) cut through upon the Director -
--------	---------------------	----	----	-------	-------	------------------------	---

19/6/69	43 Suppon	M.	23	Shopkeep.	Burma	Hiac Abscess. on the inner of this. right side -	opened by a curved incision above Papert's lig.
---------	-----------	----	----	-----------	-------	--	---



Date of Operation	Date of Discharge	Date of Death	Result or cause of Death	Remarks
13/6/69	25-6-69		Pyæmia & Colicæ Embullism -	was knocked down by a horse, & sustained the injury with a severe twist of the foot outwards. The wound communicated with the joint, gangrene of the adjacent parts set with blistering of the foot & gangrenous infiltration in the different cellular planes of the leg, set in within 5 days. At first incisions were made to relieve the tension at the ankle - but the doughy oedema & the crackling infiltration advancing rapidly up the limb; & the patient getting rigid, amputation was performed 8 days after the injury - 10 ligatures were required - he lost but very little blood. The separated leg when dissected showed dark gangrenous infiltration of the lower 2/3 <sup>rd</sup> of the leg, muscles & bone, all remaining healthy. Flaps sloughed a good deal with blisters on their surfaces. Secondary bleeding ensued (6) six days after operation - & was stopped by ligature, for by this time the stump was pretty clean & of good quality, the 1 <sup>st</sup> very healthy. Pyæmia & pleuritis set in by the 17-6-69 - from which time he was getting frequent rigors & fevers, chills & pains in his chest, until he died quite exhausted with difficulty of <sup>of himself</sup> respiration. There was some secondary hæmorrhage on the 19 <sup>th</sup> .
17/6/69	37-6-69		Cured.	Fistula of a year's standing, communicating with the bowel about an inch above the anal margin - from the left.
19/6/69	4-8-69		Cured - limb quite extensible, but the core was superficial, not healed when he absconded -	Abscess began of itself with fever about 3 weeks ago. There was very little rigidity of the thigh towards the abdomen. Abscess a pretty large one - swelling about a boy's fist. Above the ligament - discharged 2 oz of rather thick pus - no history of rigors. But getting fever all the while he was ill.



Date of Admission	Name	Sex	Age	Occupation	Country	Disease	Operation
31/5/69.	F. Westman	M.	39	None	Irish	Cystic Tumor at the back of the left eyelid. 2 by 1/2 by 1/2 inches.	Excised by one longitudinal cut. Sent 3 inches long.
80	44	80	.	.	80	80	Entropion of the left eye lid with trichiasis. About an inch long & half an inch broad of the skin <sup>folded</sup> excised.
26.6.69.	John Richards	M.	65	Carman	English	Stricture bladder.	Dilated by Holt's Large Instrument. Tho: 12 passed.
40	46	80	.	.	.	Hydrocele	Tapped & injected with iodine.
22.4.69	Gunga Ram Hagra	M.	45	Driver	Bengal	Scroful Tumor.	Excised.
29.6.69	D. Whitehouse	M.	24	Driver in E.I.R.	English	Stricture bladder.	Holt's dilatation, dilatation of urethra by large instrument. Tho: 12 passed.



Date of Operation	Date of Discharge	Date of Death	Result or cause of Death	Remarks
31/5/69	8.10.69		Cured by the 29/6/69.	Tumor of 1 1/2 years standing. There were several large venous enlargements at base of the tumor, which was irregular, serpentine, dark, & but slightly raised from the surrounding parts. 4 ligatures were required to tie the vessels, only one artery was tied & the rest were veins. He lost about 4 or 5 oz of blood.
19/6/69.	8.10.69		Relieved, a good deal.	Encephalium of 9 years standing. Was open the last 2 years. There was slight haziness of the cornea & defect of vision in the eye. There is also ichthiosis. The clitoris has been frequently removed.
27.6.69.	19.7.69.		Cured.	More than 30 years before he had penile. Stricture of 6 or 7 years standing. Once been treated by Dr. Parkes, 2 years ago; <sup>unsuccessfully</sup> & came on again & disappeared. He became hard & sore for the last 2 months. No instrument above him: he could be passed. Stricture existing about the prostate. Had no urethral fever at all.
4.7.69.	19.7.69.		Cured.	about 10 oz of pale limpid fluid was drawn off.
28.6.69.	13.12.69.		Transferred for Pneumonia & left by hypostaphia.	Tumor of 7 years standing. Both the penis & the scrotum are thickened & enlarged. Elephantiasis was used to come on once, twice, three, & then ultimately even 4 times in the month. Fever lasted 2 or 3 days. Tumor weighed at the 502. 15 ligatures were applied & tumor was a very vascular one, solid & without any hydrocele: & the stump bled a good deal & patient became very low. There was no after bleeding.
30.6.69.	30.7.69.		Cured - but the morning remaining.	Admitted with retention of urine for 4 days. bladder was immediately relieved by him: & catheter in succeeding day passed & dilated by Holt's instrument. Got the urethral fever. Stricture of 2 years standing. Had gonorrhoea 5 years before.



Date of Admission	Name	Sex	Age	Occupation	Country	Case	Operation
5-7-69	John Samuel	m.	18	Sailor	English	Hydrocele.	Tapped & injected with Iodine.
30-6-69	Arthur Doss	m.	30	hore	English	Contraction of Fore skin	Refused opening. later by the Dorsal Incision.
9-7-69	R. B. Bidwell	m.	32	Engineer	English	Stricture Uracina	Dilated by Holt's large instrument: & then No: 11 & 12 passed.
23-7-69	Frank C. Jones	m.	12	Student	English	Cystic Tumor	Removed by a transverse cut. about 2 inches long.
28-7-69	Fattah Khan	m.	53	hore	English	Thigh Abscess	opened.
						Abcess of left side -	



Date of Operation	Date of Discharge	Date of Death	Result or cause of Death	Remarks
5-7-69.	9-8-69.		Cured - transferred to the medical hospital from the prison.	Small hydrocele of 2 years standing. of the size of an egg. Operated, and has found in the fluid - 200 of milky white fluid cells, this consisting of an abundance of granular cells.
6-7-69.	22-7-69.		Cured - comes healthy.	opening closed from a sore with syphilis according to the patient's account. opening of the size of an ordinary pupil of the eye. Dilated by separating the lamellae of a dressing forceps <sup>of an</sup> - which was passed in.
9-7-69.	15-7-69.		Cured -	Stricture from his boyhood from a cut in the perineum - he had from when 18 months ago the passage was once dilated by 8 fingers. Again it became worse since the last 5 or 6 days when it stopped the flow <sup>of urine</sup> - Had syphilis 8 years ago & he would be forced before operation - Got another fever after the dilatation.
23-7-69.	27-8-69.		Cured.	Swelling between eye for a month <sup>ago</sup> before - about an inch prominent now at the outer angle of the eye - hard & movable. pushing the bones aside, which were (the lower margin of the orbit was) operated in a peculiar way. The tumor situated between those of the eye-ball. The thick dark, muddy contents scooped out, & the cavity left to granulate from the bottom. Lost but little blood. No ligatures applied nor any sutures. The wound filled up nicely.
26-7-69.	16-8-69.		Cured.	Abscess without any injury. began 3 months before. Counter opening was required. Chopped time for burning of the skin at the neck of the abscess - Abscess very deep - only 202 of pus thick.



Date of Admission	Name	Sex	Age	Occupation	Country	Disease	Operation
23-7-64	54 Thakoor	M.	30	Trader	Bengal	Arthritis of the right wrist	Actual Caution in 2 lines along the joint.

30-7-64	55 Nam Gokhar Bhakag	M.	30	hine	Bangal	Scrofula Tumor with Squinid Borna of the right side	Excision in the scrofula - and the right side -
---------	----------------------	----	----	------	--------	---	---



Date of Operation	Date of Discharge	Date of Death	Result or cause of Death	Remarks
28-7-69	25.2.70		Relieved but not cured.	Prostatis without any injury. never had syphilis. Has gonorrhea since last months.
31-7-69	4.1.70		Cured - Perfectly cured -	<p>Tumor of 7 years standing - came in after he was operated for the radical cure of his disease. Has been getting the elephantiasis fever twice in the month - all along his life he has been at his home in Darjeeling District. Gets immense secreted pain with the groin.</p> <p>Tumor after operation weighed 4 lbs 15 1/2 oz. He bled a good deal. Tumor was peculiarly vascular. patient weighed before 75 lb. 8 oz. lost weight afterwards for he was as low as 28 lb. 12 oz. were required for the bleeding. During the operation the perineal sac was cut through for about 2 or 3 inches. This was stitched up with wire. They became en- cysted &amp; they were then taken off - got some sympptoms of proctitis but this abated soon.</p>



Date of Admission	Name	Sex	Age	Occupation	Country	Disease	Operation
-------------------	------	-----	-----	------------	---------	---------	-----------

August 1869

1-8-69	56 W. J. Bryan	M	52	Business	Engl.	Stricture bladder	Dilated by Holt's large instrument & then No: 12 passed.
--------	----------------	---	----	----------	-------	-------------------	--

2-8-69	57 Mokebur Khan	M	30	Cook	Bengal	Recess of the lower jaw	Expended by the Forceps
--------	-----------------	---	----	------	--------	-------------------------	-------------------------


4-8-69	58 Bhadaroo	M	15	Home	Hindustani	Thyroid Abscess	Simple cut - left side
--------	-------------	---	----	------	------------	-----------------	------------------------

12-8-69	59 Frank Elmer	M	24	Common	American	Stricture bladder	Holt's Dilator by the large instrument then No: 12 passed.
---------	----------------	---	----	--------	----------	-------------------	--



Date of Operation	Date of Discharge	Date of Death	Result or cause of Death	Remarks
1-8-69	23-8-69		Cured -	Had venereal 20 years ago & gonorrhea about 25 years ago. Got stricture since lost 20 years. Had been under treatment several times - but all these efforts to have been simply catheterism. 2 years ago he had been under treatment & lost got the symptoms again since 6 months back - had stopped on 10 days. Shows rather a combination of pyemia with organic disease of the prostate - did get the throctural fever. & a perineal abscess formed - but the opening for it did not communicate with the proctum. Pyemia returned once after the operation.
3-8-69	13-8-69		Relieved - The wound sore not quite healed when he went out.	Eccrosis coming on after a fall on the chin, 3 months <sup>ago</sup> before. A sinus from without, as well as one within the mouth led into the dead piece, which was protruding through the gums & it thus felt as feel dead piece about 1/2 longer & 1/2 inch broad.
4-8-69	6-9-69		Moribund &	Abscess behind the tooth socket of a month & a half's duration. Came on itself with fever - 18th of pus let out at once. The patient then very low, coming in with a trace of the typhoid.
13-8-69	6-9-69		Cured.	Pericistis 5 years <sup>ago</sup> duration of only 2 1/2 months. <sup>duration</sup> of pus & water in the only for the previous weeks he had stricture.



Date of Admission	Name	Sex	Age	Occupation	Country	Disease	Operation	
6-8-69	60 Whorlun	M	40	none	Kenya	Swelling of the Left 5th Rib near the mamma	Extracted by a simple cut.	13
11-8-69	61 Mrs Laurence	F	40	none	Eschail	Tumor of the Left Breast Partly cystic. Generally similar to the other Hard & stony 	Removal by an oblique incision about 6 inches long Tumors removed Skin & muscle preserved - closed ligatures applied Hose horn suture used.	14



Date of Operation    Date of Discharge    Date of Death    Result or cause of Death

Remarks

13. 8. 69.

6 Sep 69. Died of exhaustion from Pthiisis.

Abscess near the mamma about a year or half ago. It was never healed since. Constitution much pulled down. A piece of dark dead bone, soft within, in its cancelli, about 2 1/2 inches long & half broad & as thin as a 1/2 inch long, was extracted. There was some bleeding. The discharges seemed to come out from some cavity within, through an oblique opening at the bottom) on coughing: but no lung-tissue could be seen or felt.

14. 8. 69.

20. 10. 69.

Discharged cured.

Tumor began after birth of her first child about 20 years ago. Mother of 3 children, then two died in childhood. Tumor increased by degrees. <sup>It was</sup> never had it been painful. Health quite well in other respects.

Breast of the size of an ordinary coconut shell - high, hard, nodulated, with 3 lumps at its upper part, & 2 at the outer side. Below, the breast was soft. Skin not pinched at the upper part. The skin appears healthy, with the nipple, which was not retracted, was left entire. The tumor & the gland removed. The tumor was lobular but adherent to skin; when cut into it was partly cystic. The mass had a suspicious look. The gland in structure under microscope consisted of granular cells of different sizes -

Thick woman came again with 11<sup>th</sup> of January 1891 with a large distinctly malignant tumor at the site of her left breast - said when commenced 6 or 7 months after the operation. <sup>of carcinoma</sup> - Dr. J. B. W.



Date of Admission	Name	Sex	Age	Occupation	Country	Disease	Operation
14. 8. 62	Khoyum	M.	62	India	Hindustan	Piles Internal	Lithotome applied.
14. 8. 62	Bunsaally Koon	M.	40	Shopkeeper	Bengal	Epithelioma Sore on the right knee.	Amputation above the middle of the interosseous flap (modified) operation. Modified circular operation.
18. 8. 62	J. Foorde	M.	41	Cook	England	Incised Hemorrhoid right scrotal	Operation for radical cure. Epithelioma of the penis. Plast. byptostoma



Date of Operation	Date of Discharge	Date of Death	Result or cause of Death	Remarks
15. 8. 69.	12. 9. 69.		Cured	Kils of my 8 years standing. Had been bleeding before 2 years ago. Since became blind; & trouble some.
18. 8. 69.	2 <sup>nd</sup> Oct 69.		Pyæmia -	<p>Since became stiff from some injury 16 years ago - a fungating tumor appeared on 8 Sept months ago before admission. I saw this as it ulcerated: it never healed since. I tried to pain him a good deal, with purpose felt discharges &amp; lots of carious bones &amp; necrotic tar, at times coming out. Has been getting hectic every day. The patient not at all in a favorable condition before operation. He was thin, anæmic, &amp; low in health with some enlargement of spleen &amp; but the inguinal glands not at all enlarged.</p> <p>On amputation, the stump muscles were found very flabby, &amp; the bone brittle. He lost but little blood &amp; only a few ligatures applied.</p> <p>Had a few symptoms of pyæmia - quick pulse 140 &amp; then died of hurried breathing.</p>
19. 8. 69	22 Sept 69.		Cured.	<p>Ordinary oblique inguinal hernia. Had once been operated on by Mr. Watson, but about 6 years before; &amp; the time only 7 or 8 months after he got the rupture first (on that operation the plug was removed on the 9<sup>th</sup> day). The rupture reappeared in 2 years: &amp; it has become worse than the previous one.</p>



Date of Admission	Name	Sex	Age	Occupation	Country	Disease	Operation
18.9.68	Sham Shere	M	30	Tailor	Bengal Haleghang	Fibrocystic Swollen larynx, pendulous	Excision - The Tumor with an Tumor from under elliptical piece of the soft jaw. Skin extracted from the very bottom of the angle between the jaw & the neck.



Date of Operation	Date of Discharge	Date of Death	Result or cause of Death	Remarks
19. 8. 69.	20. 1. 69.		Cured. Docked very well with a little scar. His health evidently getting better.	<p>Tumor of 4 years standing - about the size of an ordinary coconut shell. It began as a pea like swelling from the middle of the left lower jaw - Tumor attached by a broad base to the very angle of the jaw track. A year before it broke out with fever into a sinus at the lower part of the outer aspect - No history of cancer. The patient weak &amp; pallid, but was in a proper condition for operation. Tumor soft &amp; movable the firmly attached by a broad base - Shaved with difficulty, dissected off from the deep parts. It used to bleed at times - &amp; the sinus discharged clumps of fatty matter, darkish serum discharge. The skin was a good deal thickened &amp; hypertrophied &amp; oedematous too (this was pure fibrous tissue?). Many cysts were found within this tough investment of hypertrophied skin, much like to Elephant's skin. Among others, there was an egg sized cyst (communication with the sinus) with dark gangrenous looking walls. One contained pure serum fluid - A few of the vessels were calcified thickened or rather elephantized as it were. During operation, it bled tolerably freely. A good number of ligatures were applied. The carotid lay deeper &amp; was left uninjured. The tumor lay in contact with the thyroid cartilage, behind the tongue, dipping into the interspaces of the hyoid muscles, the digastric much pushed aside.</p>



Date of Admission	Name	Sex	Age	Occupation	Country	Disease	Operation
6.2.64.	66 Mackoon	M.	36	Tailor	Bengal Mussoorie	Scrotal Tumor <sup>182</sup> Elephantiasis commencing with hypertrophy of the cord & thickening of the skin.	Excision in the usual way for scrotal tumor
23.8.69.	67 Poran	M.	11	Labourer	Bengal Buck	Traumatic Tetanus	Amputation of the injured finger at the metacarpophalan- geal joint, the head of the bone being removed. A section of the tendon above the wrist.
23.8.69.	68 E. J. Gray	M.	40	Labourer	English	Inguinal Hernia right scrotal.	Radical operation by the inguinal route.



Date of Operation	Date of Discharge	Date of Death	Result or cause of Death	Remarks
21.8.69		11.9.69	Died of Tetanus.	<p>Tumor began eight years <sup>ago</sup> ago - led to left &amp; right hydrocoele - but the tumor was worst, that of the left hydrocoele, &amp; the right testis &amp; hydrocoele felt - The latter, however, some symptoms of disappearance before it was operated - Tumor about the size of a large coconut. Had been tapped several times - The stump especially the right cord &amp; testis bled a good deal at about a 100 ligatures required - Tumor within the water weight 2 lbs 3 oz. The right tunica vaginalis contained some fibrous matter - together with some sero-purulent fluid - Viscera normal before operation.</p>
23.8.69		6.9.69	Laceration.	<p>Sustained injury of his right middle finger about 15 days ago. It was crushed between some wheels in a millinery. The wound was deep &amp; long when on the 8<sup>th</sup> day he got his finger. On the 10 or 11<sup>th</sup> day he began to feel the pain. On the 15<sup>th</sup> day of the injury the finger was removed &amp; the bone divided. Since that time he has been in much better improvement.</p>
25.8.69	4.11.69		Cured.	<p>An ordinary oblique inguinal hernia of 2 years standing. Had been twice operated before, but both times the rupture came back again some time after. This time it was only 6 weeks before it was operated.</p>



Date of Admission	Name	Sex	Age	Occupation	Country	Disease	Operation
11-8-69	Tofail	M	25	Boatman	Bengal	Comp'd Fracture of the left Tibia at its lower end, leading into the joint (ankle)	Amputation of the leg below the knee, the tibia by the modified circular operation.

21-8-69	Provo	M	24	Domestic Hindustani		Fatty Tumor from outside the upper part of the right arm.	Excision of the tumor with an elliptical piece of skin.
---------	-------	---	----	---------------------	--	---	---

15-8-69	Kumud Kishore	M	28	Govt. Clerk	Bengal	Comp'd Comminuted Fracture of the 1st Phalanx of the right toe after high foot.	Amputation of the toe at the metatarsophalan-geal joint. The head of the bone removed.
---------	---------------	---	----	-------------	--------	---	--



Date of Operation	Date of Discharge	Date of Death	Result or cause of Death	Remarks
26.8.69		5.9.69	Died of pyæmia -	<p>Some heavy iron-shed fell upon head-side of the ankle &amp; made 2 wounds near the lower end of tibia - one behind &amp; the other in front, deep, chopping off the malleolus &amp; exposing the cavity of the joint - the wounds went on well for some time - but they rather suddenly assumed a nasty aspect with a peculiar forward appearance of the patient &amp; himself - but he never had any distinct rigors before he was operated - tho' pt. fever every evening - there was no osteomyelitis seen after operation in the exposed portions - but the articulating cartilage was loose &amp; dried, whitish &amp; off from the bones - being separated from them by a thin layer of thick redish gelatinous matter - the cartilage can be peeled off entire from the bones - Rigors began after the operation - &amp; on the 7<sup>th</sup> day my record -</p>
31.8.69	15.10.69		Cured	<p>Tumor began from infancy - It was a large oval pendulous soft semi-solid elastic mass hanging down from the outer aspect of the upper part of the leg - beginning from the a crural tubercle the middle of the shin - It was pedunculated &amp; movable with the skin joint free - like size of an ordinary "kubero" Tumor weighed 4 lbs 2 oz - before operation - 7th 9th of the leg - lost 1 lb 0 oz of blood -</p>
1-9-69		13.9.69	Cardiac Embolism from Pyæmia. Pyæmic patches found in the lungs & the muscles -	<p>Foot crushed between 2 boats - the other injured wound at the ball of the foot - healed, but the fractured bones &amp; suppurated, the matter burrowed the foot &amp; the leg &amp; would not heal - patient got high fever &amp; the leg was taken off -</p>



Date of Admission	Name	Sex	Age	Occupation	Country	Disease	Operation
27.8.69.	72. Kothoorra	m	32	Scrub- binder	Madras	Inguinal Hernia (Strangulated) Left side.	Operation for Strangulated Hernia.
30.8.69.	73. Mohamed Ali	m	35	honor.	Malabar	Blind Intestine perineal.	Perineal section on the ground staff.
3.9.69	74. Ed. Prateron.	m	29	Haridwar	Englishman	Hernia of the Left Testicle.	Some operation for the reduction of Hernia of Testicle.



Date of Operation	Date of Discharge	Date of Death	Result or cause of Death	Remarks
27-8-69	21-9-69		Cured - Parts still tender	Hernia of ten years standing - an ordinary oblique inguinal hernia - Hernia did not go up for the last 4 days, but he had had no symptoms of strangulation, only a little edema & discomfort. Construction was found at the outer ring, formed mostly by the subcolumnar fibres. Hernia was of the size of a large mango. It was tough hard & irreducible. The wound separated extensively.
2-9-69	15-9-69		Abandoned, evidently doing well.	Had prosthesis a year before. The prosthesis succeeded an abscess in the perineum 6 months ago, without any history of stricture (excepting the few days of inflammation of the prosthesis itself) preceding. It was about 2 inches deep, imbedded amidst 3 tubercular prominences of the skin - Perineum divided in its whole length. The prosthesis divided quite back to the perineum. The prosthesis was the toughest possible.
3-9-69	15-9-69		Discharged with the wound healing.	Hernia of 2 years standing, coming on after gonorrhea & orchitis, the former about 7 years before. He used to snip it off as soon as it off by nitric acid, whenever it grew out. This he had remained well for some six months & it again broke out & grew up 4 months ago. The fungus about the size of a walnut growing out of the middle of the port of the scrotum, pale & whitish. The superficial parts were <sup>cut</sup> chopped off, & the structure got in by a longitudinal cut 5 inches long, & kept interrupted only at the fungus. The constructed opening of the albuginea tube with a part of the tunica itself was then cut off & the organ was mostly found to have been mostly spilt, a little of it only remaining.



Date of Admission	Name	Sex	Age	Occupation	Country	Disease	Operation
30.8.69.	Mohamed Ali.	M.	35	None.	Bengal	Urinary Fistula at perineum.	Perineal Section.
10.9.69.	Francis Walter	M.	32	Horsebreaker	Hartford	Samuel Recurva.	Left digitalis of External Osac by a curved incision which
						(right) Left	about 1/2 inch from the upper <sup>base</sup> of the pubic
							Incision extended from a point at the junction of the inner and middle third of a line drawn from the Ant. Sup. Spine of the Pelvis to the pubic symphysis to about 2 inches internal to and a little higher than the Ant. Sup. Spine. It was about 4 inches in length & 1/4 inch above Pampas's ligament.

\* in it. He looked quite stout & there was no complaint whatever about the tumor or the limb - both limbs felt equally swollen. but there was no pulsation in the left posterior tibial -



Date of Operation	Date of Discharge	Date of Death	Result or cause of Death	Remarks
2-9-69.	27-10-69		Went away of his own accord with the wound almost healed up: it however mostly gone down; the limbs equally swollen throughout - the ankle was a little painful - in lifting up a 250 lb weight.	Fistula of 6 months duration arising on legs months after gonorrhoea - never had syphilis before - Perineum mesially divided throughout this structure divided down to the prostate.
	27-10-69.		Went out of his own accord though repeatedly advised to stop here - The wound has not then healed up well. The tumor still remaining a little & a little pain in the ankle.	Shaved his thigh about 11 months ago, himself a stout vigorous man - had been in the Cavalry 6 years before - 3 months ago the numbness of his limb began first - then pain at the spot of injury (thigh) - This spot then gradually swelled up: at present the tumor is about the size of an ordinary orange - It pulsates regularly with a strong expansive impulse & local rappings bruit - He gets fever whenever he exerts his limb to any length of time.
+ swelling a little pain now & then in the instep, whenever he walks or rests much.			with foot & heel & callus & a branch of the femoral artery probably was included in the ligature - as he had severe pain in the scrotum & the thigh & the leg for some time after the operation - he got very much better - the temperature of the limb continued about the same as the opposite one by the thermometer - and the pulse in the femoral artery was situated above the middle of the Cooper's triangle, between 3 & 4 inches below the Poupart's ligament, & its upper boundary left bore an inch of space from the origin of the deep femoral - No return of tumor in the thigh was seen in the posterior iliac - Tumor diminished from end of Sept. On 10-10-69 he was allowed to sit up - & by the next day he could walk well in the ward - about this time he used to complain of a pain in his abdomen rather along the aorta & the left iliac & across the liver. There was no other discomfort - locally at all.	



Date of Admission	Name	Sex	Age	Occupation	Country	Disease	Operation
15.9.69. 77	Sham.	M.	40	hickte	Bengali Hindu	Stricture of urethra.	Dilatation by Holt's Long's instru- ment & no: 12 passed.

22.9.69. 78	Banomal	M.	35	hane	Bengali Hindu	Swampy (fibrous) in the outside of the upper part of left prostate.	Removal by enucleation.
-------------	---------	----	----	------	------------------	---	----------------------------

20.9.69. 79	Grimanto	M.	45	hane	Bengali Hindu	Right scrotal Inguinal Hernia.	operation by the Physician - performed by Dr. Govil.
-------------	----------	----	----	------	------------------	-----------------------------------	--

24.9.69	Ganga Ram.	M.	50	hane	Bengali Hindu	Calculus Vesicae.	lateral operation for distention.
---------	------------	----	----	------	------------------	-------------------	--------------------------------------



Date of Operation	Date of Discharge	Date of Death	Result or cause of Death	Remarks
18.9.69.	24.10.69		Cured.	<p>Stricture of 4 months' duration arising out of a fall on his buttocks, when he bled a good deal through the rectum. Symptoms began within 15 days of the accident - Stricture was almost imperceptible. During dilatation some pus came out probably from in front of the prostate at which the instruments found most difficulty to go in -</p> <p>It was again dilated on the 21.9.69. Has got hydrocele of the left side tapped &amp; again filled up -</p>
22.9.69.	11.10.69		Cured.	<p>Began as a pimple 14 years ago. It increased by the last 2 or 3 years. It was a moderately hard, movable, non-adherent swelling. It came out of itself without pain or any uneasiness. It existed quite unheeded within the extensor muscle of the forearm. It lay quite encysted &amp; it was removed by a single longitudinal incision through which it was pulled off by the fingers. Still he bled a good deal by the minute vessels. 26 ligatures were applied -</p>
24.9.69	26.10.69		Cured.	<p>Ordinary oblique inguinal hernia of a month &amp; a half's duration. Ring felt in the top of the finger ring.</p>
25.9.69.				<p>Has suffered from dysplasia of the bladder since the last 16 or 17 years. Stomach for 16 years. Had before red sand before. Got difficulty in micturition for time of micturition for the last 2 years. The stone - The calculus stone was a big hard blackberry calculus. It was oval &amp; weighed 20g weighing 202.5 grains minus 2 grs. The stone bled very unusually: it was plugged by the tube &amp; the handkerchief -</p> <p>53 mumps -</p> <p>Papae deep seated by the tube &amp; the handkerchief -</p> <p>Removes the stone -</p> <p>Supplies the stone -</p> <p>Plug of meat -</p>



Date of Admission	Name	Sex	Age	Occupation	Country	Disease	Operation
24.9.69.81	Gunga Ram.	M.	50.	None	Bengali Kishor.	Calculus Vesicae	Lateral operation for Lithotomy

27.9.69.82	Emael.	M.	16.	Khilasi Sub.	Compd Fracture of big toe of left foot	Amputation below head of the first phalangeal bone
------------	--------	----	-----	--------------	---	--

29.9.69.83	Chinta Money.	M.	22	Husbandman	Bengali.	Medullary Disease of the lower ends of the bones of the right Forearm.	Amputation of lower third of the Arm -
------------	---------------	----	----	------------	----------	---	--

October 1869.

29.9.69.84	Eliza Chapman	M.	32	Seaman	English	Inguinal Hernia Left Scrotal	Lithabical Case by plug & ligature
------------	---------------	----	----	--------	---------	---------------------------------	---------------------------------------



Date of Operation	Date of Discharge	Date of Death	Result or cause of Death	Remarks
25.9.69.		27/11/69.	Died of pyæmia	The patient suffered from symptoms of stone exhaustion from Oxyphos for sixteen years. Pain in micturition for two years. Calculus was coal & weighed 2 1/2 & some minus gr. It - Profered deep seated hæmorrhage stopped by silicate & plug of lint. Stone was coated with phosphates probably of uric acid & carbonate.
30.9.69.	11 Oct. 69		Cured.	A bar of iron fell upon his toe; the sharp end divided it - through - only a little of the lower aspect remaining (about 1/4 of the whole thickness).
30.9.69.	26.11.69.		With a good stump.	Began as a small swelling from the radial side of the front aspect of the right wrist about a year ago. The swelling increased a good deal by the last two months. It pains him night & day. The wrist was mobile before. But since the last month it has become stiff. Tendons passed over the swelling. The bones softened, degenerated & smelted into the cerebroid matter of the tumor. The wrist bones were in a state of fatty degeneration but the articulations were in tact.
4.10.69.	17.11.69.		Cured.	Hernia of the ordinary oblique sort of ten years standing. Had once been operated on before, within three months of his disease. It came down again very shortly after his discharge from the Hospital (general)



Date of Admission	Name	Sex	Age	Occupation	Country	Disease	Operation
20-4. 69. 85	Gungahem	M	45	Sikhar	Bengali	Elephantiasis of scrotum operated on (before no. 48. 69) L of the left leg L Foot.	Ligature of Saphenous Vein of the left thigh. 4 to 5 inches below the Poupart's ligament

27. 9. 69	of Monali Ross.	M	40	hwa.	Portia	Scrotal Tumour	Excision
-----------	-----------------	---	----	------	--------	----------------	----------

10. 10. 69	Ed. Benson	M	39	Sailor	Danish	Dislocation of left Shoulder on the Thyroid gland with probably fracture of the Rib of Acetabulum	Reduced by pulling under Chloroform.
------------	------------	---	----	--------	--------	---	--







Date of Admission	Name	Sex	Age	Occupation	Country	Disease	Operation
24.10.69.88	Tarini Noshad.	M.	25	Writer	Bengali	Stricture Nostrum.	Dilatation by Holt's Large Instrument & No. 12 pt. in.

November/69

1.11.69.	89. Okhoychurnabis	M.	25	Peasant	Bengali	Fibrous Tumor from the interior of the right Antrum of High more.	Excision of the right upper jaw with a portion of the maxillary bone by a curved incision from a little above the right angle of the mouth to the right prominence of the cheek & the palatine saw through with the narrow saw at the central incisor. — The whole pulled out by the Lion Forceps; & the soft palate with the lacerated bones left entire.
----------	--------------------	----	----	---------	---------	---	--

5.11.69.	90. Broomechurn	M.	38	hmc.	Bengali	Stricture Nostrum.	Dilatation by Holt's large Instrument & No. 3. & 9 passed.
----------	-----------------	----	----	------	---------	--------------------	--



Date of Operation	Date of Discharge	Date of Death	Result or cause of Death	Remarks
24.10.69.	25.10.69.		Relieved.	Difficulty in making water, & the smallness of the stream only for six months duration. Had gonorrhoea 5 years ago - has very narrow, & no instrument could be passed <sup>before</sup> <del>in the outside</del> - but there was no difficulty here.
3.11.69.	2.1.70.		Went out quite cured without any sign of return of the disease; but with a tolerably hard, thick, tough band, in the place of the upper jaw - most of the gap filled up, excepting a little that corresponds to the nostril. His speech was still a little thick.	Swelling first began in the gums about a year ago - for which two of the right upper molars were extracted: after which the parts inflamed & the cheek swelled; & the latter burst of itself about 3/4 inch below the right eye - about 8 months ago. The sinus never healed since. The right side of the upper jaw greatly thickened & swollen especially about the <del>first</del> <sup>upper</sup> molars. Some of the teeth were cut, & the gums there looked quite fibrous: & the cheek still a little swollen. On microscopic examination it was found to be a purely fibrous tumor, containing no distinctly nucleated cells. The jaw greatly thinned to a shell. The tumor alone weighed 5 1/2 oz. The gap in the cheek filled up with lint - 10 ligatures were used & actually cautery applied to several spots: Still the wound healed for 2 or 3 hours after operation, when it was stopped by taking off 2 of the sutures, & then exposing the spots to cold air, & then restuffing lint into it. By the tenth day of operation, the wound completely healed: he could eat well, but speech rather indistinct. The sinus wound healed 4 weeks after.
3.11.69.	9.11.69.		Relieved went at at his own earnest wishes.	Had gonorrhoea & Syphilis 14 years before. A second attack of the former 5 years ago. & since then pain & difficulty in passing water, never had retention of urine: but at times the urine comes away by drops. No instrument above he could be passed before operation.



Date of Admission	Name	Sex	Age	Occupation	Country	Disease	Operation
8-11-69	J. Williams	M.	42	Seaman	Engl.	Stricture	Dilatation by Holtz' large instrument: No. 10 got in  + For a few days after, instruments up to No. 9 were introduced almost daily: but daily every time it caused moderate bleeding - so irritate the passage was.
12-11-69	W. Wright	M.	31	Engineer	E. India	Hæmorrhoids	The three outer folds internal & external were cut off by the scissors & (6) six inner folds ligatured.
19-11-69	Abraham Rose	M.	25	Sugar	Barbadoes	Stricture	Dilated by Holtz' with many fistulae large instrument & in the perineum - No. 10 passed.



Date of Operation	Date of Discharge	Date of Death	Result or cause of Death	Remarks
9.11.69.	8.12.69.		Cured.	<p>Has had stricture for the last 5 years: &amp; had gonorrhoea 10 years ago. Had retention of urine once only 3 years ago, when some instruments were passed - For the last 3 days urine has been coming out in drops. The stream is very thin: &amp; even No. 4 could not be passed - Sympes probe points round was given: Then the Holt Director introduced &amp; the passage dilated to No. 10. Micturition however did not become very free by that: but the pain becoming very very soon any further use of instruments was postponed until then. Had venereal 5 months ago: &amp; has got the scaly eruptions about the same time ago. &amp; the piles appeared about a month ago: It was very painful &amp; bleeding from the beginning: &amp; had to get feces for it. Had suffered from some diarrhoea complaint a year ago.</p>
12.11.69.	14.12.69.		Cured.	
19.11.69.	26.11.69.		Abandoned - micturition was then quite free & painless.	<p>Had an attack of gonorrhoea 8 years ago, which has never been cured - was here once for urinary trouble in the perineum about 4 years ago - Stricture becoming bad again for the last 2 or 3 years. Micturition very painful &amp; difficult, the water coming out in drops for the last 3 months (but never had retention of urine) a fistula has again broke out in one of the former places. Micturition again becoming bad very soon after operation, the passage was again dilated similarly 3 days after. &amp; this time he got the urethral fever just after operation.</p>



Date of Admission	Name	Sex	Age	Occupation	Country	Disease	Operation
17.11.69.	Henry Mendies.	M.	39	Shipping & Indian Master.		Scrotal Tumor <sup>184</sup>	Excision
22.11.69.	Kally <del>son</del> of Kue.	M.	25	Indhar	Bengali.	Scrotal Tumor <sup>185</sup>	Excision —
5.12.69.	Boornofomar	M.	25	none	Bengali Brahmin.	Elephantiasis of the Penis.	Excision as in ordinary cases of scrotal Tumor.
13.12.69	W. L. Mendies.	M.	48	Sailor	Portugal	Hæmorrhoids	Internal all cut off. External & Internal. & the internal's ligatured.



Date of Operation	Date of Discharge	Date of Death	Result or cause of Death	Remarks
20-11-69.	15.3.70		Cured. Wound nearly healed.	Elephantiasis of leg 7 years ago. Was not sub- ject to the periodic attacks of fever or pain. Patient weighed before operation 118 lb. 9 lbs. after 102-13 lbs. Tumor weighed 5 lbs. Loss There was old-standing haematocoele of the left tunica vaginalis testis, with laminated fibrine adhering to the walls & thick greenish dark <sup>brown</sup> matter at centre.
2. 12. 69.			16.12.69. Died of tetanus oper- ation on the night of the 14.12.69.	Disease is of 8 years standing: has increasing rapidly by the last 2 years. Had to get elephantiasis. It was a very vascular tumor weighing after removal 12 lbs. There was no hydrocele: & the left testicle was found at with some difficulty imbedded in the hypertrophied mass. 4 ligatures applied.
14.12.69. 9.2.70			Cured.	Prepuce hypertrophied for the last 3 years. It was double the usual size both in length & thickness. Left elephantiasis. Had never syphilis. Scrotum having been found hyaline like diseased, was also removed with the prepuce. The removed part was within a lb in weight. 10 ligatures applied.
14.12.69. 10.1.70			Cured.	Suffering from Piles for the last 6 years. Used white lead and other. Latterly they have become very painful & swollen - 2 ligatures applied, came out on the 18 <sup>th</sup>



Date of Admission	Name	Sex Age Occupation Country	Disease	Operation
10.12.69.	J. Cornin	M. 25 Sailor. English.	Inguinal Hernia.	for Radical cure by Hugb. & Co.
15.12.69.	Kamini	F. 25. home Bengali.	Fistula in ano.	Division of the Sphincter Ani.
28.11.69.	Kalla Chaud.	M. 24. Goldsmith Hindu Bengali.	Scrofula Tumor. <sup>156</sup>	Excision
			Amputation of the toe. Hydrocele of the scrotum.	
18.12.69.	Sarkhos.	M. 25. Korday. Hindustani	Shingling of the right 2nd toe from a head of the tumor previous injury.	Amputation of tarsus.
20.12.69.	W. Lym.	M. 25. home Englishman	Hydrocele (left)	Tapped & injected with 3 of Jact. Sod.
31.12.69.	Najibur Rahman	M. 28. Clerk. Bengali Brahmin.		Amputation at the left shoulder joint with a portion of the scapula removed. Index at the 1st joint, Ring finger with the middle of the metacarpal bone. The thumb of the right hand amputated.



Date of Operation	Date of Discharge	Date of Death	Result or cause of Death	Remarks
16.12.69.	15.3.70.		Cured.	Disease of 3 months standing. It is an ordinary oblique inguinal hernia into the scrotum. Very taken out on the morning of the 4 <sup>th</sup> day after.
4 <sup>th</sup>	26.12.69.		Cured.	Disease of 3 weeks standing. Had syphilis before.
18.12.69.				Disease of 2 months standing. never had venereal. Tumor weighed after operation no more than a pound. There was some hydrops of the right side. 2 lb of straw-colored fluid taken. 28 ligatures applied.
22.12.69.	11.2.70.		Cured.	Sustained the injury about 3 months ago. He knocked it against some stone in the street. It has since inflamed, suppurated & sloughed. The two of the last phalanges were already gone - no stitches were applied after the operation. The gap partly healed up by first intention & partly by the second.
23.12.69.	26.1.70.		Cured.	It began 2 years ago: became worse for the last 4 months - never used to get fever. It existed only in the right left side, & on tipping 4 or 5 of lymphoid fluid drawn out.
31.12.69.	<del>1.1.70</del> 1-1.70.		Shock of the injury	Sustained the accident in the Richmond at 7 <sup>30</sup> P.M. Admitted into the Hospital at 11 <sup>15</sup> P.M. He was then very low, collapsed: clothes full of blood: but no blood on them going on. The left shoulder was comminuted with the head of the humerus & the ridge of the scapula. The clavicle laid bare, the muscles lacerated & brachial plexus was exposed, under which the vessel laid in tact. The right hand was crushed too. Amputation performed at 1 <sup>15</sup> P.M. pulse having risen a little under chloroform. Died about 2 A.M.







*Date of*  
*Operation*

*Date of*  
*Discharge*

*Date of*  
*Death*

*Result or cause of Death*

*Remarks*







Date of Date of Date  
Operation Discharge Death

Result or cause of Death

Remarks



Date of Admission	Name	Sex	Age	Occupation	Country	Disease	Operation
29.12.69.	1. J. Ellis.	Mr.	22.	Constable	English.	Compound comminuted fracture of the lower end of the left leg - opening into the ankle joint. Simple fracture of the tibia 3 inches above ankle. Spreading gangrene setting in on the 3rd day of injury.	Amputation about 3 inches below the seat of the fracture.

N.B. Dr. Fayrer did not attend the Hospital from 6<sup>th</sup> Jan. to 10<sup>th</sup> March. During which period all the operations were done by Dr. Quark who officiated in his place.

27.12.69.	2. Shorrop Dalk.	Mr.	60.	House	Bengali.	Simple fracture of the middle of the right leg bones with a wound at the heel - causing gangrene of the sole of the foot & ultimately involving the seat of fracture.	Amputation of the lower third of the thigh. 2 <sup>nd</sup> wound.
-----------	------------------	-----	-----	-------	----------	---	--

8.1.70.	3. Futeck Kumar	Mr.	25.	Wagoner	Bengali.	Scrofula Tumor	Excision.
---------	-----------------	-----	-----	---------	----------	----------------	-----------



Date of Operation	Date of Discharge	Date of Death	Result or cause of Death	Remarks
2.1.70.		22.1.70.	Died of clumping of the foot remaining in the stump - The foot for which he had been suffering twisted outwards, the inner malleolus forming from before the accident.	Fell with his horse upon his left side, the foot twisted outwards, the inner malleolus projected out of a wound about an inch piece on the breadth of the process - It consumed the bone nothing particular was left with the joint - Several pieces of bone were a few patches in the path of the liver - lungs simple - large patches of clumping bones in the section & the descending color.
8.1.70.		11.1.70.	Exhaustion.	He fell with his horse upon his left side, the foot twisted outwards, the inner malleolus projected out of a wound about an inch piece on the breadth of the process - It consumed the bone nothing particular was left with the joint - Several pieces of bone were a few patches in the path of the liver - lungs simple - large patches of clumping bones in the section & the descending color.
11.1.70.	10.7.70.		Cured from head, healed.	He had been suffering from 12 years. It has been 3 months before since when he has been getting from almost every fortnight, accompanied by pain in the section - has admitted with pain swelling of the section & penis - but he had no fever then - The tumor weighed 2 lbs. 25 ligatures applied - There was some hypoderm of the left side.



Date of Admission	Name	Sex	Age	Occupation	Country	Disease	Operation
1. 12. 69	James Dact	M	32	Seaman	English	Aggravated + hydrocele +	Ward's operation - as modified by Dr. Prestidge - performed by Dr. Gurnell  + tapid +

8. 1. 70	5. Tai (very good)	M	28	Indo	Bengali	Stiffened jaw from a cicatricial band (costalagium) stretching between the jawbone on the right side - coming on after Cancerous Ovis - necrosis of the lower jaw -	Removal of the dead bone. Portions of the lower jaw also engaged. The tight band divided - Dr. Gurnell
----------	--------------------	---	----	------	---------	---	---

14. 1. 70	6. John D. Cruz	M	27	Seaman	Indian	Stricture of urethra with perineal abscess	Perineal section in the left side of the perineum - + dilata- tion of the urethra by Hallett's large instru- ment - Back part of the urethra cut off as far as the prostate -
-----------	-----------------	---	----	--------	--------	---	--



Date of Operation	Date of Discharge	Date of Death	Result or cause of Death	Remarks
13.1.70	22.1.70		Gross pretty firm	Swelling of the right side of the scrotum was noticed for the last 3 months or so. It was pear shaped, ascending up to nearly the inguinal ring, without fluctuation, the testis & the epididymus were felt (larger than usual) in the lower part of the swelling. It was lapped & some lympho fluid leaked & then a lump went up & applying taxis. This never came down since. But the cord remained swollen & hard for some time, during which some salivation was brought by the patient him self using some blue ointment.
13.1.70	17th July		He lived - jaw open & more than an inch	was discharged from here 3 months ago after recovery from Cancerous abs. affecting the back part of the lower jaw. The coronoid process was then laid bare by the sloughing. But the bone was not before exposed, it was seen being covered up by granulation. He came back with the same swelling about the angle of the jaw as when he was discharged - He could not open his mouth more than 1/5 or 1/6 inch wide - The jaw freed out by cutting the tight band from within & the bone dead pieces being extracted & the bone being gorged, the gap was stuffed with lint & the jaw kept wide by cork.
15.1.70	7.3.70		Relieved of the stricture & minor remained open when discharged.	Exonerated for last 4 years. Syphilis destroyed his glands 2 years ago. Difficulty of micturition for the last year. Stricture became very thin latterly. Urine comes in drops now. I have had attention of urine. S-shaped like kept in after the section of the prostatic on the stricture.



Date of Admission 1870.	Name.	Sex.	Age.	Occupation.	Country.	Disease.	Operation.
16.1.70.	7. Ram Chandra Dutt	M.	45	Retired	Bengal	Cystic tumour on the hand	Excision by a longitudinal incision.
20.1.70.	8. Gobind Kumar Doss	M.	20	None	Bengal		
22.1.70.	8. Abbas.	M.	16	Khalasha	Lahore	Necrosis of the last phalanx of the great toe of the	Necrosed portion removed by two lateral cuts.
16.1.70.	9. Parriah.	M.	35	Husband	Lahore	Ulcer from necrosis of the ends of the leg bones	Amputation at the upper third of the leg.
30.1.70.	10. Henry Thomas	M.	26	Fireman	S. India	Fistula in ano.	Division through the rectum.
21.1.70.	11. Koyas Chandra Doss	M.	24	Shopkeeper	Bengal	Inguinal Hernia.	Woods operation for radical cure.



Date of Operation	Date of Discharge	Date of Death	Result or cause of Death	Remarks
19.1.70	5.2.70		C. Wound <del>unhealed</del> <del>healed when wanted</del>	Began as a pimple 8 years before. Gradually increased into the present size of an walnut. The wound healed up by granulation.
24.1.70	22.2.70		C. Wound <del>unhealed</del> <del>healed</del>	Necrosis coming on after a bruise of the left big toe about 5 months ago. Healed up once, but it has been discharging again for the last 3 days. Wound healed up by secondary adhesion.
29.1.70	19.3.70		C. <del>Wound unhealed</del> <del>Perfectly healed up</del>	Foot sloughed off from an injury by a fall about 9 months ago. The sore thus formed never healed up since the bones of the leg were quite intact: & were nearly covered up by the surrounding skin drawing over. The wound of the secondary amputation soon healed up by a secondary adhesion without any constitutional or local disturbance.
1.2.70	13.2.70		C. Wound <del>unhealed</del> <del>healed</del>	Fistula of 3 months standing coming on after an abscess on the left nabs. Tried several local applications but all to no purpose. Wound was healing when he went back.
3.2.70	18.3.70		C. <del>Wound unhealed</del> <del>Perfectly healed</del>	Ordinary oblique inguinal Hernia of the right side - of a pair standing. Ring a pretty large one. He was about getting some chest complication, when on the 8 <sup>th</sup> day the wires were taken out: He then went on improving well.



Date of Admission	Name	Sex	Age	Occupation	Country	Disease	Operation
1870- 19.1.70	12. S. J. Disowza.	M.	28	house.	E. India	Scrotal tumour. <sup>157</sup>	Excision by Dr. Ewart
24.1.70.	13. Mauck.	M.	40.	Cultivator	Bengal	Melanotic Tumor in the Groin	Removal with the surrounding skin & the underlined fascia.
31.1.70	14. Dandoloyal Chatterjee.	M.	50	Peon	Bengal	Fractured skull.	Trephined



Date of Operation	Date of Discharge	Date of Death	Result or cause of Death	Remarks
22.1.70		7.2.70	I. Exhaustion.	Rad. Chancere a month & half before. Penis swelled 3 weeks before & the scrotum 2 weeks before admission. Getting fever for the last 2 weeks. The urethra was cut during operation & was stitched up with silver wire sutures & it was doing well. But he gradually sank under typhoid symptoms. The tumour weighed about 2 half lbs.
24.1.70.	25.2.70		Chronic skin disease	Disease began 18 months ago as a dark patch at the hollow of the right foot. Within 6 months it began to protrude as a wart & this increased & sciered. It had once been taken out but has grown out again. The dark patch never increased though. Did not feel any more inconvenient for it than from the discharge of its ulcerated surface. Several dark points were seen in the skin. Carefully extracted from the muscular structures beneath. The wound cicatrizing well.
31.1.70	31.1.70		Exhaustion and Compres- sion at about 10. m.	At 4.10 a.m. in the morning he fractured the vault of his head by a fall from a house 12' feet high. He was brought in at 7.45 a.m. in a state of complete insensibility & semiparalysis. He has been bleeding from the mouth and nose. A hematoma was apparent on the vault of the head. The pterion was divided and radiating lines of fracture were seen beneath. A spicule having been observed depressed the adjoining portions of bone were trepanned and the depressed portions elevated and about a half of the left parietal bone was extracted besides several smaller pieces. The brain was seen depressed in a regular hollow by a mass of clot on the dura mater.



Date of Admission	Name	Sex	Age	Occupation	Country	Disease	Operation
2.2.70	B. Lila Kungli	m	25	house	Bengal	slipped sheep.	opened
						blinding.	
31.1.70	Khonsaly	F	7	house	Bengal	Gangrene of toes.	Disarticulation of the metatarsal bones



Date of Operation	Date of Discharge	Date of Death	Result or cause of Death	Remarks
4.2.70	4.2.70		Went out with the sore nearly healed up & the health much improved.	<p>that was deluding (after post-mortem examination no corresponding lamination of the brain substance was seen however.)</p> <p>Has suffering from malarious fever and spleen for the last five months. The abscess was situated about the left angle of the lower jaw going downwards to the middle of the neck. It was opened in the out-door dispensary, then it bled a little. Was admitted for the low state of health. He was getting better when on the morning of the fourth instant it began to bleed very freely and the swelling was laid open behind the bleeding vessel but the hemorrhage was from the whole surface so that it had to be stopped with difficulty by tamponing and pressure. He is now doing well.</p>
7.2.70	14.6.70		Sore quite healed. Could walk well on the heel that remained all right.	<p>Has been suffering from malarious fever for the last two months. The foot began to mortify 10 days ago. The front half of the right foot was quite gangrenous, dark and shrivelled up. Line of separation formed but it spread a little even after her admission. All tendency to mortification having ceased and the bones falling off the metatarsal ones were removed by a few cuts at their basal articulations. She is getting on satisfactorily.</p>



Date of Admission 1870.	Name	Sex	Age	Occupation	Country	Disease	Operation
7. February 17	Kangali	M.	25	Bearer	Bengal	Conjugal Strangulated Hernia	Reduction by opening into the sac.
7. February 18	Kurrim Bux.	M.	16	Sailor	Bengal	Fibrous tumour on the right Masseter.	Excision by a single incision.
13. Feby. 19	William Limond	M.	20	Clerk	E. Indian	Inguinal Hernia.	Radical cure with the Plug and ligature.
13. Feby. 20	Harrao Chunder	M.	33	Peon.	Bengal	Urinary fistula in the Perineum, with Stricture of the Urethra.	Perineal section.



Date of Operation	Date of Discharge	Date of Death	Result or cause of Death	Remarks
7 Feb, 1870	9 Feb, 1870		Died of exhaustion.	The strangulation occurred seven days before admission. Taxis, Ice, and Chloroform were tried without success, and it was operated on three <sup>hours</sup> after admission, but the obstruction was not confined to the ring alone but there were also some adhesions within the sac. It was consequently opened and the gut was found highly congested and gangrenous looking. Still it was thought advisable to return it which was accordingly done without any improvement in the symptoms, and the patient died of exhaustion on the second day after the operation.
20 Feb, 1870	1 April 1870		Cured. <i>Wound requires attention</i>	Tumour of three years duration. It was of the size of a large bottle but adherent and incorporated with the surrounding structures so that in removing it a large portion of the Masseter muscle had to be dissected removed with a portion of the skin. Some secondary hemorrhage ensued and the wound ultimately healed up by granulation.
15 February 1870	20 March 1870		Cured. No impulse could be felt at the groin on coughing.	Ordinary oblique inguinal hernia of the right side for the last 2½ years. Wound healed up in three weeks.
16 Feb, 1870	18.9.70		Was transferred to the Medical wards for Syphilis.	Stricture of the urethra of 15 or 16 years standing. Had had retention of urine once about 14 years ago, after which he got abscesses in the perineum - these healed up without any treatment and he remained well for about 8 years. The present stricture broke out two years ago, and he now passes his water in a very thin stream.



Date of Admission 1870.	Name	Sex	Age	Occupation	Country	Disease	Operation
16. February 21	Thomas Thomson	M	27	None	England	Inguinal hernia	"Nod's" operation for radical cure.
16. January 22	Thomas Earle	M	46	None	England	Erysipelas of the right hand.	Amputation of the middle finger with the head of the Metacarpal bone, and of the last joint of the index finger with free incisions on the dorsum of the hand.
19. Februry 23	Sree Churn Mistry	M	30	Carpenter	Bengal	Condylomata ani and ulcer in the Rectum.	Removal of Condylomata and the ulcer by ligature and the ulcer cut down upon.
27. Feby 24	George Mendes	M	25	Clerk	E. Indian	Fistula in Ano.	Lined open deeply; not into the Rectum.
24. Feby 25	Jadhum Chund	M	35	Servant	Madras	Retention of urine. Infiltration of urine. Erysipelas of Scrotum.	Catheterism forcible, 6 to 12. Perineal section.



Date of Operation	Date of Discharge	Date of Death	Result or cause of Death	Remarks
17. Feb. 1870.	7. April 1870.		He went to Hospital with the groin pretty firm.	Ordinary oblique inguinal hernia of the right side of 20 years standing. Had been operated on about 10 years ago by Dr. Hays with the Plug and ligature. The gut came down again two years after the operation. As the conjoined tendon was very distinct "Wood's operation" was performed this time.
22 <sup>d</sup> February 1870.	24. 4. 70		Wound healing.	<del>Crysipelas</del> Was admitted with a few superficial sword-cuts on the face, hand, &c. Crysipelas set in a few days after admission - most part recovered but the right hand continuing erysipelatos for a long time, with deep infiltration extending from the wrist to the tips of the fingers, the skin sloughing off in several places, the parts most affected were removed. The other parts still remain erysipelatos (April 16 <sup>th</sup> .)
22 <sup>d</sup> Feb. 1870.	29 April 70.		Relieved of the discharges but the sore was not healed when discharged.	Cordylomata of a year's standing, three in number, of the size of an ordinary bean,
22 <sup>d</sup> Feb. 1870.	26. 4. 70		Wound and nearly well.	Ward in the Medical Ward for Pulmonary Consumption, the fistula (3) broke out a month ago. One of them about three inches deep going up by the side of the rectum but not perforating it.
27. Feb. 1870.		1. March 1870.	1. March. D. Gangrene.	Stricture of 14 years duration. For the last few days the urine has only been coming away in drops and was admitted for retention, which was relieved by general treatment & fomentations. Catheterism did him apparent good, but on the third day the Scrotum, prepuce, and perineum swelled up greatly, and perineal section was performed, but he gradually sank from exhaustion.
3. March 1870.				



Date of Admission 1870.	Name	Sex	Age	Occupation	Country	Disease	Operation
28. February	26 Haradhan.	M.	15.	Cultivator	Kalaband.	Scrotal tumour <sup>158</sup>	Excision.
4. March	27 Henry Cooper.	M.	52	Sailor.	Wales.	Dislocation of the right shoulder (sub-coracoid)	Reduction by Cruise's apparatus.
19. Febry.	28. Bodhat Chunder Kundu.	M.	40	None.	Bengal.	Scrotal tumour <sup>159</sup>	Excision.
7. March	29. Charles Braiger.	M.	43.	Black.	E. Prussia.	Strangulated hernia.	Reduction without opening the sac by an oblique cut on the groin.



Date of Operation	Date of Discharge	Date of Death	Result or cause of Death	Remarks
2 <sup>d</sup> Mar 1870.		11 Mar 1870.	Died of Tetanus.	Tumour of 10 years duration. Moxas had been applied 12 years ago which diminished the swelling for a time: on admission this was about the size of an ordinary Coconut. No regular Elephantiasis fever. Penis not imbedded. There was a large hydrocele on the left side and a small one on the right. Tumour weighed $4\frac{3}{4}$ lbs. Fifty ligatures were applied. Wound left exposed for an hour after which the bleeding ceased. Tetanus superadded on the eight day after operation.
6 Mar. 1870.	15 Mar 1870.		Arm not useful yet.	Dislocation of four weeks duration, caused by a fall on the side. Left the Hospital of his own accord - Arm improving at the time.
7 March 1870.	11 Mar 1870.	11 Mar 1870.	Died of Peritonitis. P.M. Recent bands of adhesion about the right ilium or 11 years.	Suffering from hydrocele of the right side with some hypertrophy of the scrotum for the last 10 years. Had been tapped several times within the peritoneum, and out of Hospital, and once after admission on the 21 <sup>st</sup> Feb. when about 4000 of serous fluid was withdrawn. During operation a large haematocoele was on this (the right) side. The testicle of the same side lay imbedded in the hypertrophied structures and was removed with them. The cord retracting into the canal caused some bleeding ensued, which was with difficulty stopped by laying that part open and applying two accupressure needles. Some Peritonitis ensued and though the symptoms abated he died exhausted.
8 March 1870.		10 Mar 1870.	Died of Peritonitis.	Came in with a strangulation of 5 hours duration. Chloroform and Taxis failed and the symptoms continuing he was operated on the following morning, 21 hours after strangulation. There was no stercoraceous vomiting. The hernia was returned in a mass. The operation afforded him no relief, and Peritonitis setting in he died with hurried respiration without any clots in the heart.



Date of Admission 1870.	Name	Sex	Age	Occupation	Country	Disease	Operation
9. March	30 Ananta Hazari	M	22	peasant	Bengali	Fistula in ano	Opened into the Rectum
13 <sup>th</sup> March	31 Prosunno	F	20	Servant	Bengali	Ulceration of cartilage of both wrists.	Actual Caustics in two lines on each wrist
21 <sup>st</sup> March	32 Ananda Lal Paul	M	45	Trader	Bengali	Necrosis of the right half of the lower jaw	Removed
22 March	Bhoot Katti	M	35	Cultivator	Bn	Tumor of the knee joint containing bloody liquid fluid 192 oz of fluid causing absorption of femur.	Tapped at 10 AM
30 <sup>th</sup> March	33 Montag	M	16	Stone cutter	Bengali	Gun-shot wound of the right hand	Removal of the phalanges + metacarpus bone of the ring + the phalanges with the head of the metacarpus bone of the middle finger by Dr. Saunders
18 <sup>th</sup> March	34 Kishu Chakr	M	40	Cole	Brial	Scrofula tumor	Removed



Date of Operation	Date of Discharge	Date of Death	Result or cause of Death	Remarks
10 <sup>th</sup> March 1870	22-4-70		Relieved - other sinuses breaking out -	Sinus of 12 months duration, perhaps Syphilitic they were on either side of the Rectum, going deep but not perforating it through.
20-3-70	1-4-70		Cured.	Pain & Swelling came on 10 days before admission, that of the right appearing first. Had tabs a month ago, Rest & cooling lotions, good food & tonics relieved her a little. Actual Caustery cured the right wrist by the 10 <sup>th</sup> April.
22-3-70	11-4-70		Relieved - Right side was quite soft & flexible when discharged -	The patient was an anæmic one, but no history of malarious fever. Necrosis began 2 months ago. The whole of that right side of the jaw was found loose & mobile & a large piece of bone from below the condyle to the Chin was removed. The gap healed up, but all that side of the jaw was quite soft & hollow when discharged.
23-3-70	25-3-70		Relief of exhaustion from the shock of the enormous discharge.	Swelling was of one year's growth. Measured the size of a large melon circumference 37 in. x 16 in. 37 in. 32. Then still larger pointing, swelling reduced to original size by the use of caustic.
30-3-70	30-4-70		Wound was healed.	It was shot by accident from the discharge of a loaded pistol. The shot entering through the palmar aspect opposite the 3 <sup>rd</sup> & 4 <sup>th</sup> Metacarpal-phalangeal joint. The wound was a ragged one. Fingers removed immediately.
1-4-70	15-10-70		C.	Hypertrophy of 3 years duration - The skin was covered up with numbers of warty eminences on the penis & Scrotum - Sumner weighed 3 lbs - 12.53



Date of Admission	Name	Sex	Age	Occupation	Country	Disease	Operation
1870 3 <sup>rd</sup> March	James Viller	M	40	Stewer		Stricture of Urethra	Perineal Section

1 <sup>st</sup> April	36 Luteh Khan	M	55	Jomades Pathan		Calculus Vesicae	Lateral Lithotomy
-----------------------	---------------	---	----	----------------	--	------------------	-------------------

6 <sup>th</sup> April	37 Edward Bremie	M	28	Stewart Scotch		Varicose Ulcer	3 <sup>rd</sup> artery passed through its base across the course of the vein.
-----------------------	------------------	---	----	----------------	--	----------------	---



Date of Operation	Date of Discharge	Date of Death	Result or cause of Death	Remarks
2-4-70		July 70	The stricture was quite cured. The stream was big: but he became gradually more & more exhausted from the pain in his knee: & died of exhaustion from diarrhoea & cystitis.	Stricture of many years standing - Had once been in here in 1855 in Dr Partridge's ward, and perineal Section had been performed in July 1855 to relieve him. He had been doing well until 2 months ago, when the perineal wound began to break out. His urine on admission coming out through the fistula as well as through the urethra. The latter mostly in drops. Several attempts were made on different occasions to pass an iron tube into through. But even the probe-pointed Small sound of Sims could not be got in, until the 2 <sup>nd</sup> April, when the perineal Section was performed. The left knee suppurated: pus let out from above the patella on the 10 <sup>th</sup> April: but without any permanent relief of his sufferings. The perineal & the knee wound healed up soon. But his suffering continuing unchecked actual cautery was applied on the 5 <sup>th</sup> June since.
4-4-70.	May		Cured - Stone probably of the renal Coarctation of the aorta. There was no real disease in him, but a dull hypodermic condition of the whole system. He has since done well.	Complaint about the urinary organs only of 2 years standing - Stone weight 3 vi + xxiii grs. The patient a very healthy one before: but old & infirm. He began to urinate soon after operation. It was thought prudent to send him to his home - But was irregular even there. There was thought to send him to his home - But was irregular even there.
2-4-70.		17.5.70	Discharged cured	The inner vein of the right leg swollen for the last 10 years. He had been a digger of gold before. Had an ulcer in the leg in 1856. & the present one broke out only 4 days ago. Wounds healed within a fortnight.



Date of Admission	Name	Sex	Age	Occupation	Country	Disease	Operation
24 Jan'y 38	Mr. Matthews	M	23	None	Engl'd	Dislocation of the lens of left eye.	Removal by (upper) flap operation by Dr. Saunders.

6 <sup>th</sup> May - 39	Karoonah.	M	26	Beggar	Indian	Cancer of the lower third of the left thigh.	Excision of the tumor.
--------------------------	-----------	---	----	--------	--------	--	------------------------



Date of Operation	Date of Discharge	Date of Death	Result or cause of Death	Remarks
17.4.70	26.5.70		Closed. Eye cleaning & the sight getting better	2 1/2 years before he had his right hand dislocated itself & removed by Dr. Innes a man. The left eye gradually became bad during the previous 9 or 10 months. He has been getting it treated by the local doctor 6 months & there was enlargement of pupil. The eye became so with sight almost on 26.5.70. As the pain became troublesome he came to hospital. Remains for a long time to have his health improved. By the 10th of April the eye inflammation more violently than usual, & the cornea becoming very tense & bulging. The lens was removed. Very soon he got better.
7th May 70.	7.5.70		Sid of the cheek.	The tumor was about the size of a big coconut, mostly affecting the inside of the back of the lower part of the left thigh. It began 2 years before as a small swelling about the left condyle of the femur. The circumference measured 2 1/2 inches. The encysted growth lay quite encysted beneath the hamstring muscle, involving the femoral artery in itself. It was removed mostly by excision, & the femoral artery was torn through. He was bound with a good deal of gauze, were tied; hard with oiled and from the position & the bone laid bare about the arm. Wound was re-opened, actual cautery used, but it did not heal. Two hours & a lump of encysted matter was seen like the tumor of the other arm.



Date of Admission	Name	Sex Age Occupation Country	Disease	Operation
9-May	George Stewart	43 Black American	Reguma of the right side of the face	Amputation of the right upper canine & 1st premolar teeth.
7-March	41 Loomis	40 Roanoke Indian	Compound fracture of the left leg, at its lower third; mischief of the foot; & exhaustion.	Amputation of leg at its upper third by the antiseptic method; modified flap bringing on pyemic operation.
11-May	42 Kichary	40 Dorset Hindu	Intestinal ulcer at the anus & rectum.	Division of the nerve through the anal sphincter.  Removal of the lumpy growth from the anus & redressing of the wound.
18-May	43 Robert Higgins	40 Irish Home Irish	Haemorrhoids	Excision.
			Fistula in ano remaining	laid open into the rectum



Date of Operation	Date of Discharge	Date of Death	Result or cause of Death	Remarks
11th May -	25.5.70		Cured	<p>beginning of cloudy days duration. Coming in with fever &amp; toothache, resulting from exposure to cold air. The abscess was all confined to the right side - with the exception of a few teeth on the left side - the malocclusion was going to the lower margin of the jaw. I spreaded over the front of the jaw but there was no more in it. The two teeth were found loose &amp; tender &amp; were pulled out. Henceforth, the fever subsided, &amp; the abscess healed. The abscess cured when discharged.</p>
13 May -	1st 8.70		Discharged with a good stump. Cicatrizing completely.	<p>Sustained the injury from the leg being accidentally caught between two boats. The fracture was oblique, &amp; comminuted: the wound was three inches long &amp; situated on the skin. He had been doing well; but pyæmic symptoms, fever, rigors &amp; suppuration: the bones of the tibia &amp; metatarsus lost their cartilage fastened, &amp; the leg was removed. Henceforth he got better, the stump healed &amp; was within 2<sup>nd</sup> June.</p>
13 May 70	21.6.70.		Cured	<p>The case was of only a weeks duration. The part has been always burning for the previous 4 days. All cured by the incision. Again the tumor &amp; again it was divided. Pain not continuing still, it was again divided on 6<sup>th</sup> June.</p>
6 <sup>th</sup> June 70.				
9 <sup>th</sup> May -	29.9.70.		C	<p>Had been suffering from this for some time - was admitted with retention of urine - suffered a long time while in hospital from hepatitis.</p>
15.8.70.				




Date of Admission	Name	Sex	Age	Occupation	Country	Disease	Operation
18 <sup>th</sup> May 44	William Jones	M	29	Sailor	English	Swelling of the Dorsal duct of the right side	Dilatation by a fine probe
30. May 45	Boongaram	M	24	Farmer	Bengal	Synovitis of the right knee -	Knee joint tapped at its wide -
June 46	Ram Tori	M	40	Master	Wya.	Shank bone dislocation of the right foot & of the leg.	Manipulation of leg - upper third by the modified flap



Date of Operation	Date of Discharge	Date of Death	Result or cause of Death	Remarks
22 <sup>nd</sup> May	28.5.70		C. D. Smith	Had syphilis 10 years ago. He was almost excluded from an accident 8 years ago. This chopped off the whole of the back of the nose & the eye bones & cheek. It has dilated on 2 or 3 days. The nose is changed being well.
31 <sup>st</sup> May	27.6.70		Cured. Since perfectly mobile & natural. but the original sinus that he had from before the syngonitis remained discharging some foetid pus, & led into dead bone, just above the knee -	Swelling of the knee was of 3 years standing. Had gonorrhoea 2 months before that but no syphilis. The swelling was about the size of a nut. Through a pin canal about 500 of tenacious yellowish straw-colored fluid drawn out. This coagulated by heating, & contained some cells like rounded bodies with dark outlines probably oil globules. soluble or became shrivelled by the addition of acetic acid.
1 <sup>st</sup> June	21.9.70		Cured.	Sustained the injury in knee at the age of a few hours before. The laceration was extensive, beginning from wrist up to the middle of the leg, opening over the scapula scapula & ankle joints & scraping off the tibia & femur deep by the calf. Immediate operation was performed.



Date of Admission	Name	Sex	Age	Occupation	Country	Disease	Operation
7 June 47	Shorma	m	35	boone	boone	Epithelial cancer of the lower lip, invading the cheek on right side	Excision of the affected part



3 June 48	Keno	m	17	laborer	Do	Compound comminuted fracture of the left carpus & metacarpus with extensive comminution & laceration of the soft parts, as healing up to lower 1/3 of the forearm & opening & dislocating the wrist joint almost throughout	Amputation at the middle of the left forearm by the modified flap operation - flaps were anterior & posterior
-----------	------	---	----	---------	----	---	---

3 March 49	James Willis	m	40	Steward	English	Disease of the knee	Actual Caution in three lines along the inside of the patella of the left knee.
------------	--------------	---	----	---------	---------	---------------------	---



Date of Operation	Date of Discharge	Date of Death	Result or cause of Death	Remarks
2 <sup>nd</sup> June	11.7.70	C	Wound nearly healed. A scar visible that was visible on the cheek.	The sore began in his infancy, but has rapidly increased by the last year. It was situated upon a growth & indurated base at the right angle of the mouth. There was no discharge from it, but the surface scraped off showed numerous rounded cells with indistinct nucleus; but numbers of small dark outlined granules appeared on the addition of water to the surface of the cells that disappeared. The tumor was about the size of a little nut. This with a wound of the part of the surrounding soft part removed: the outer portion of the wound brought together by S. procedure, suturing it. The inner portion left open - healed by 11.7.70. The <sup>edges of the</sup> wound did not unite; but gaped & went on cicatrizing & then the plastic operation was performed. The hand was seriously crushed by the fall of a heavy beam a few hours before admission. Almost the whole of the dorsum of the hand was smashed. The hand hanging loose by some attachments at its ulnar side only. Amputation was performed. Had bled a good deal before admission. The stump inflamed soon after operation, inflammation extending to near the elbow. Eight ligatures required on operation.
21.6.70	11.7.70.			
3 <sup>rd</sup> June	8.7.70.		Cured with a good stump.	
5 <sup>th</sup> June	8.7.70	10.7.70	Death from Euphorbia from skin head & height	This patient was admitted & operated upon for Stricture Uractura. During the administration of chloroform for the perineal section 2 <sup>nd</sup> April, he hurt his knee. It suppurated in a few days - 4 oz of pus let out from above the patella: the wound healed, but the knee continued very painful: this continuing vexed him more & more; & neither excision nor amputation being advisable, a trial cautery was tried. It relieved his suffering; but he gradually sank exhausted of diarrhoea.



Date of Admission	Name	Sex	Age	Occupation	Country	Disease	Operation
5 <sup>th</sup> June 50	Mukherjee	M	50	Wagon Driver	Bengal	Ossous Tumor of the right side of the lower jaw.	Removal of the whole of that portion of the jaw included between the left posterior premolar to the right angle of the jaw - by an incision (curved) commencing from beneath the lower lip a little to the left of the middle line, which is the right angle of jaw -
8 <sup>th</sup> June 51	Deby Pershad	M	25	Chaprai Binder	Hindustan	Compound fracture of the metacarpus with extensive laceration & dislocation of the wrist.	Amputation above the wrist by the anterior & posterior flaps
8 <sup>th</sup> June 52	Holland Bird	M	21	Scam	Scotch	Compound comminuted fracture of the phalanges of the great & the 2 <sup>nd</sup> toes of the left foot with extensive laceration.	Removal of the 1 <sup>st</sup> & 2 <sup>nd</sup> toes of the left foot with the heads of their metatarsal bones



Date of Operation	Date of Discharge	Date of Death	Result or cause of Death	Remarks
7 <sup>th</sup> June		22.7.70	Died of gangrene or gangrenous pneumonia of the right lung. The whole of the upper lobe of his right lung was disintegrated & free	The tumor was of about 6 or 7 years growth. commenced in the gums as a small softish swelling about the right premolar. Gradually the firm swollen & a tumor of firmness formed. It has been increasing ever since. It had once been incised by a barber & the wound resulting from it has not healed. It now leads into softened cavity in the bone - The whole swelling was hard & gradually lost itself in the substance of the maxilla. It was about the size of a large orange, most prominent at a point a little to the outside of the right angle of the mouth - He was rather a weak & unsocial individual, suffered a little from the shock, but gradually got better -
8 <sup>th</sup> June		24.7.70	Good stump - cicatrix complete.	Sustained the injury by a Railway accident a few hours before admission amputation was immediately performed. The lower ends of the bones of forearm removed -
8 <sup>th</sup> June		29.7.70	Cured.	Sustained the injury by a Railway accident - Immediate amputation was performed by Dr. Lauder.



Date of Admission	Name	Sex Age Occupation	Country	Disease	Operation
1870. 10 June	52 Charles Macdonald	33 Engineer	Scotl.	Stricture of the Uræthra.	Dilatation by Holt's Large instrument

15. 6. 70 53. Inosomohing F 38 Prostet. Bengali Syphilitic Laryngitis. Tracheostomy  
Kyasta causing oedema of glottis. (Dr. Saunders)



Date of Operation	Date of Discharge	Date of Death	Result or cause of Death	Remarks
12. 6. 70.	29. 7. 70.		Drain well. No. 12 was passed daily.	Had syphilis 12 years ago; but does not admit of ever having had gonorrhoea. Had a sudden attack of bleeding from the bladder about three months ago. This was soon followed by difficulty in micturition. He had fever & ague then, & the bleeding continued for about ten days. On admission no instrument could be passed into the bladder, & the urine flowed rather in drops. The next day No. 3 sound was got in with some difficulty, the passage dilated by Holt's large instrument; but in making the passage contracted so much, that it was with much difficulty that No. 11 could be got in after the dilatation. & on several days after the same specimen was offered the passage often instrument. Had fever & ague each time the instrument was passed. On the 16 <sup>th</sup> again none could be passed except Holt's director & it was again dilated to the full size; but only No. 9 could be passed afterwards. - Therefore he gradually improved.
15. 6. 70.	29. 8. 70.		Relieved of the dyspnoea, once went out on 28. 7. 70. & came back again on 3. 8. 70. & was again discharged with the tube on 29. 8. 70.	Had syphilis 20 years ago, for which she had been caliculated 8 times. Had secondary sores about 10 years ago, & lost her voice 5 years ago. The sore throat was about 10 years standing. Difficulty of breathing for that month, became worse for the last three days, & she almost gasping on admission. Tracheotomy was at once performed & a large cannula got in. This was taken out on the 27 <sup>th</sup> .



Date of Admission	Name	Sex	Age	Occupation	Country	Disease	Operation
15 June.	54 Charles Jackson	ln	30	look	English	Stricture Urinary	Pilectomy by Holt's Large Instrument
17 June.	55 Mothera hald	m.	55	here	Bengali Brahmin.	Strangulated Inguinal Hernia (right side)	Operation for strangulated Hernia done by Dr. Saunders.
20 June	56 Lady	ln	60	Khalasi	Madagascar	Strangling with deep infiltration (1/4 in) of the whole middle finger of the left hand -	Finger removed with the head of the meta-carpal bone by L.R.



Date of Operation	Date of Discharge	Date of Death	Result or cause of Death	Remarks
16. 6. 70.	19. 7. 70.		Cured	<p>Had <sup>12 months</sup> gonorrhoea &amp; Syphilis 3 months ago. The latter was followed by difficulty in micturition. Had been salivated &amp; salivation before &amp; there were nodes on the shin bones. On admission he passed his water mostly in drops - never had any retention of his urine. No. 4 was passed with some difficulty - &amp; the passage delayed by No. 5 large instrument, &amp; No. 11 passed. Had a fit of ague in the evening &amp; the passage <del>was</del> several times delayed by the <del>instruments</del> afterwards by the passages of Nos. 10, 11, &amp; 12.</p>
17. 6. 70.	30. 6. 70.		Exhaustion from diarrhoea	<p>Hernia of 15 years standing. never had strangulation before. This time it occurred 2 days before admission. He had hiccup ever since that time, had no stereoracious vomiting, the abdomen was tympanitic &amp; the tumor a dense tough &amp; large one - could not be reduced by taxis &amp; chloroform - &amp; it was opened on. It was partly Omentum &amp; partly intestinal - there was a good deal of difficulty in reducing the former &amp; the sac was opened - even then it went in with much difficulty - had a slight attack of peritonitis afterwards - but this was mostly local &amp; subsided speedily.</p>
20. 6. 70.	24. 8. 70.		Discharged with a stiff index finger, for this had been ultimately affected	<p>The last phalanx was smashed about 3 weeks ago &amp; it was removed then - It ultimately smelted, &amp; the smelling gradually invaded the whole hand - Has been getting far with veins - all vanished from the next day by Amputation.</p>



Date of Admission	Name	Sex	Age	Occupation	Country	Disease	Operation
20 June 57	Ramchunder	M	40	Trader	Bengali Bengali	Gangrene from a sharp bite of the left arm	Amputation below the shoulder joint - $\times$
5 June 58	Bunomally	M	26	Laborer	Congo	Disorganization of the knee joint consequent upon a puncture	Amputation at the lower third of the thigh by transposition - the flaps were antiseptic & posterior flaps.
22 June 59	Gobuck	M	36	home	Bengali Bengali	Calculus vesicae	Lateral lithotomy



Date of Operation	Date of Discharge	Date of Death	Result or cause of Death	Remarks
20. June. 70.	21. 9. 70.		Cured.	The shock hit him the day before: there was extensive laceration & contusion of the soft tissues of the arm: the bone not injured, nor the joints opened. The laceration was at the outer side of the lower third of the arm: the laceration nearly encircled the limb & extended to the bone - All below was gangrenous: & the arm was amputated by a sort of modified flap operation just below the insertion of the humerus - The flaps were internal & external. He had bled a good deal after the accident, but none after the operation - Ten ligatures applied -
21. June 70	11. 7. 70.		Death from Pyæmia, & also Septicæmia?	was admitted ten days after sustaining an injury to his left knee - Probably the joint was opened. He remained without treatment at home: getting fever every day, & the puncture discharging blood & pus all the time. There were all the symptoms of disorganization of the joint apparent on admission - He was kept on trial for a few days, during which time he improved a little in general health: extensive infiltration of the leg & thigh recurring, the operation was performed. The cartilages of the joint were thoroughly disorganized. & looked shaggy & shaggy: & infiltration encircled the lower two fifths of the thigh bone -
27. 6. 70.	6. 10. 70.		Cured.	Symptoms of three years standing. Stone about the size of a mul. gall. weighing 57 7/8 gr. probably of triple phosphate -



Date of Admission	Name	Sex	Age	Occupation	Country	Disease	Operation
25 June 60	M. Davies	M	3	home	Indian	Necrosis of tibia (left)	Removal of the dead bone by enlarging the upper sore.

28 June 61	John Hawkins	M	27	brewer	Irishman	Osteo-arthritis of the left ankle.	Actual cautery in two lines on either side.
------------	--------------	---	----	--------	----------	------------------------------------	---

27 June 62	Rash Behary	M	22	refractor	Bengali	Scrofula Tumor	Excision.
------------	-------------	---	----	-----------	---------	----------------	-----------



Date of Operation	Date of Discharge	Date of Death	Result or cause of Death	Remarks
25 June.	19.1.71		C.	Went out with the leg transferred from the hindwings, leg nearly straight without wound, where had been for fever & swelling the least deformity in it of the left knee <sup>of a fortnight's duration</sup> with unhealthy bones size or strength. A wound on the same leg. One of these latter was sinus remaining at the joint below the tubercle of Tibia, & led into side of the two original dead <del>thorax</del> <sup>bones</sup> at the bottom. There was another just above the inner prominence of the ankle. The whole shaft of the Tibia was cut once removed, extending from the tubercle to <sup>about</sup> its lower end. He had a severe attack of dysentery soon after, but he gradually recovered from that.
29 June.	15.11.70		fixed.	Had been in the Medical wards for Mauritius Fever with rheumatism of most of his joints, from which he had <del>been</del> <sup>was</sup> suffering for the last 2 years. The patient attributed the origin of his ankle disease to these attacks. He was anemic man, but had improved in health by treatment in Hospital; the ankle however became worse & worse, & he was transferred. All the structures of & around the joint was enormously thickened; the swelling was of two months duration, gradually increasing. Stiffness of the limb came on 3 weeks since, & gradually becoming worse. Actual cautery relieved him at once, & the limb went on progressing well.
24.6.70.	19.12.70		Discharged with the wound nearly healed.	The disease was of only three weeks duration. no history of fever, no elephantiasis of leg. Had gonorrhea a year ago. The tumor after removal weighed 19 1/4 lbs. The penis was greatly swollen about double its usual size, the scrotum but slightly diseased. Operated by Dr. Saunders. Wound granulated in 4 days.



Date of Admission	Name	Sex	Age	Occupation	Country	Disease	Operation
18 <sup>th</sup> July 1863	Stuffer	Male	40	Carpenter	Bengali	Serous Tumour	Excision

19 July 64	Louisiana	Female	11	English	Home	Old Cicatrix from a Burn extending from the right arch of the lower jaw to the right pectoral region.	A triangular incision over the cicatrix, fixing the flap to the lower jaw: the gap closed by sewing; & the tension removed by loosening the structures, & making an incision on either side about 3 inches off -
------------	-----------	--------	----	---------	------	---	--



Date of Operation	Date of Discharge	Date of Death	Result or cause of Death	Remarks
23 July 1870	1.11.70		Curd.	The disease is of 12 years' standing - without any history of regular elephantoid face. The tumor was of the size of a baby's foot; but has increased a good deal lately with numbers of tubercular prominences on it. The patient was a weak infirm man & became very low during the operation; so that a bit of the fore skin with most of the tumor & epinial testis (of the right side) that was much thickened, were left unremoved. The wound took a long time to granulate.

29 <sup>th</sup> July 1870	8.10.70.		Relieved.	Was burnt when she was 3½ years old. Had once been operated upon at St. James Hospital about 4 years ago. The cicatrix contracted again, in form of a tight band stretching between the right angle of the mouth (drawing it down) & the right arm pit. It went as far as the right ear. The limbs of the angular incision were about 2 inches long. The distant cuts were also of the same length.
----------------------------	----------	--	-----------	---



Date of Admission	Name	Sex	Age	Occupation	Country	Disease	Operation
18 <sup>th</sup> July, 1876	65 Mr. J. Stewart	m	43	Iron	Scotch	Contused wound of the scalp bringing on necrosis of the cranial bone; & Abscess of the brain:	Exposing the skull. & opening of the Dura mater, & letting out the pus from beneath.

" 66

Do Do Do Do



Date of Operation	Date of Discharge	Date of Death	Result or cause of Death	Remarks
1 <sup>st</sup> August/70	22.8.70		Abscess of the Brain	Received a contused wound of the scalp beneath the seat of injury. On the 15 <sup>th</sup> July: there was no injury to the bone. P.M. 10 <sup>th</sup> : a large abscess about the size of an egg in the substance about 1/4 inch square. It was situated in front of the left middle lobe of the brain, <sup>original to the</sup> not communicating with the lateral ventricle, & perforated from it by only a thin layer of softened substance. Extensive softening of the brain substance <sup>for an inch</sup> around he was doing well on the whole till the 24 <sup>th</sup> July: Fever & hemiparesis set in on the 27 <sup>th</sup> & gradually with the other symptoms <sup>of the</sup> encephalitis aphasia with loss of power in the right limbs appeared on the 30 <sup>th</sup> . There was complete loss of speech with paralysis of the right arm on the 31 <sup>st</sup> when the cicatrizing wound looked puffy & flabby. A circular incision being made upon it, the bone beneath appeared roughened. The next day symptoms meninges congested - not disappearing this post was trephined. Dura large & lobulated. The symptoms still continuing the dura mater was opened the next day on the right side. Other organs healthy, when all the symptoms ceased gradually. I continued doing very well till the 11 <sup>th</sup> when the corners of the wound were brought together with strips of sticking plaster. Then, with the closing of the wound of the dura mater, he began to get worse, <del>his</del> <sup>his</sup> standing his speech & intelligence remained perfect. A general feeling of uneasiness with slight headache & fever now & then began to annoy him more & more: until the 18 <sup>th</sup> of Aug: when the right arm, which never regained its original strength, became quite helpless; & the inner part of the wound being flabby & the granulations there overlapping the bone, it was & another circle of bone was removed by the trephine. A slight improvement was visible for a day, after which he became worse again. <sup>completely</sup> lost his speech on 20 <sup>th</sup> Aug: Stupor gradually set in on the 21 <sup>st</sup> & he died comatose early in the morning of the 22 <sup>nd</sup> Aug.
18 <sup>th</sup> Aug: /70	"	"	"	of the dura mater extensively laid open -



Date of Admission	Name	Sex	Age	Occupation	Country	Disease	Operation
12.8.70	67 Bholu Bala Das	M	36	Sirker	Bengal	Stricture Urinary	Dilatation by gradual catheterism
22.8.70	68 Gopal Chandra Chakraborty	M	33	Accountant	Bengal	Urinary Fistula in the perineum	Perineal Section
24.8.70	69 Banny Madhub	M	32	Carpenter	Bengal	Gynorrhea (Hæmorrhagic)	Tapped with a fine trocar & cannula



Date of Operation	Date of Discharge	Date of Death	Result or cause of Death	Remarks
14.8.70.	18.9.70		Cured.	Stricture of five years duration - result of gonorrhoea 15 years back. No instrument could get in above or admissum, but there was no retention of urine. No. 3 was got in two days after with much difficulty, & thence forth it was dilated by degrees.
23.8.70.	4.10.70		Cured	Gonorrhoea & stricture only of 1 year's duration. An abscess broke out in the perineum about 2 months ago. No. 9 & 10 could be easily passed into the bladder, but it passed through a region of quite dense stricture, which on performing the section cut like cartilage with a perceptible noise. An instrument was occasionally passed afterwards.
25.8.70	18.10.70		Cured	Had gonorrhoea 14 years ago. never had rheumatism before. The knee became painful 5 months ago, & it began to swell three months after it. He had been under treatment in the oldoor Dispensary & had a few blisters applied on the knee: Has been getting fever for the three days before admission. This morning by Dr. Irvine, the joint was tapped the next day, at a spot a little below middle of the patella & about 4 oz of thickish straw-colored fluid let out, which evaporated after hours after. No fever or uneasiness ensued by the operation, but he felt himself much better & easier. The limb was kept upon a Dr. Boyce's splint.



Date of Admission	Name	Sex	Age	Occupation	Country	Disease	Operation
26.2.70	Mr. J. Brarwell	M	21	Fireman	India	Hydrocele (impl.)	Tapped & injected with Fuch's Dye.
29.10.70	Shah Jafarally	M	36	Barman	Hindustani Brahmin	Achylosia Pilon (right)	Forcibly skeleton under chloroform
13.2.70	Hassan Chunder	M	33	Peon	Bengal	Perineal section wound with indurated margins -	Plastic Operation
22.2.70	Kitto loll Laha	M	36	Knacker	Bengal	Absorption of the head & neck of the all femur from an injury -	Actual Caution in two lines about 6 inches long, one at the neck, & another over the trochanter.



Date of Operation	Date of Discharge	Date of Death	Result or cause of Death	Remarks
26.8.70	13.9.70		Swelling much reduced	Disease of two years standing. Right side larger than the left. Joints contained 7 ounces of milky fluid & the latter only 1/2 oz of straw-colored fluid. Both tapped & injected at the same time by Holt.
31.8.70	13.12.70		Cured.	Had Rheumatism 6 or 7 years ago, & ever since the knee & ankle joints were contracted. The leg was at right angles with the thigh, the foot slightly mobile, & the extent of abuse an inch or two in the circumference. General health was pretty good. The knee looked distorted. It was forcibly straightened out (under chloroform) by applying firm pressure on the patella. The tissue gave way with distinct crackling sounds. Some superficial patches of gangrene set in on the 5th day after operation.
30.8.70	12.9.70		Transferred to the medical ward for Hepatitis.	The perineal did not heal since the operation of the 6.2.70., but the parts were much improved: the edges were pared off & brought together with iron wire sutures: but it did not unite fully. Sustained a bruise at the hip (left) 2 1/2 months ago. There was no fracture, but he could not walk at all for upwards of three weeks after the accident: & though on admission he could walk with a stick, the limb was evidently far more swollen, & slightly misshapen. A long splint was put on after the operation.
2.9.70	6.10.70		Cured. Went out with an useful limb, but yet not perfectly right.	



Date of Admission	Name	Sex	Age	Occupation	Country	Disease	Operation
9.9.70	Alley Mochan	M	22	Cooly	Hindustani	Silvestria Malignant of the head of the Tumor with the Hybrid form	Reduced by Manipulation by Bandages just after the accident
10.9.70	Mirza Abdul Qadir	M	24	Khatib	Hindustani	Lumbar Abscess Malignant	Opened by a curved cut about 3 inches long & 702 of pus let out -
8 <sup>th</sup> Sept	Shitā Ratha Nayak	M	40	House	Bengali	Epididymitis of the Glans	Amputation of Penis.
19 <sup>th</sup> Sept	Shudjibhushan	M	16	Schoolboy	Do.	Adenoid Tumor below the left angle of the jaw	Removal through an oblique incision
25 <sup>th</sup> Sept	Gunga Ram	M	50	Spinster	Hindustani	Enlargement of Uterus from long standing stricture, causing strangling of contents.	Perineal Section & Free incision.



Date of Operation	Date of Discharge	Date of Death	Result or cause of Death	Remarks
9.9.70.	18.10.70		Cured.	A hole of spurs fell upon his hip & dislocated it downwards, & fractured the tibia at its lower third.
14.9.70.		25.10.70	Died of exhaustion	Came in a very poor state of health, complaining of severe pain in the right side of the chest. This he says followed an attack of fever that he had about six weeks ago. There is no history of any injury: but he had a fall about 2 1/2 years ago.
19 <sup>th</sup> Sept 70.	23.10.70		Cured	Disease of eleven months duration, involving the whole gland & a portion of the penis. No enlargement of the inguinal glands.
19 <sup>th</sup> Sept 70.	27 <sup>th</sup> Sept 70.		With the wound healing by granulation.	A gland below the left angle of the jaw has swelled for the last two months. It was about the size of an almond.
26 <sup>th</sup> Sept 70.		11.10.70	Exhaustion (gradual)	Had gonorrhoea thirty years ago: irregular micturition ever since: difficulty in making water of 20 years standing. The swelling of pain in the scrotum of only 5 days duration. The scrotum was gangrenous & the congested swelling extended up like the left iliac crest. Three incisions were at once made - no instrument could be got in the bladder & perineal section performed the next morning; & after much difficulty the S-shaped tube introduced into the bladder at night. There was an encysted hydrocele on the left side which perplexed our diagnosis at first.



Date of Admission	Name	Sex Age Occupation Country	Disease	Operation
7 Aug 70 79	Lazil.	M 25. House Keeping Mahomedan	Fibroid Tumor (diffuse) over the left angle of the jaw.	Removal of a portion of the Tumor.
20 Sept 80	Luckeera	M 40 Boatman Hindustani	Anal Fistula.	Laid open by a number of cuts.



Date of Operation	Date of Discharge	Date of Death	Result or cause of Death	Remarks
26 Sept 70	16-10-70	<del>16-10-70</del>	Relieved. Jaw could not be opened more widely than before. Inflammation was much reduced. The wound completely healed.	The swelling <sup>about</sup> the left angle of the jaw of three years' standing - coming on after an attack of fever. It was a diffused swelling of the part extending as far as the parotid gland, the cheek bone, & the upper part of the neck below. Patient stated that it enlarged with the full moon. Under the application of <del>iodine</del> Iodide of Mercury ointment, it became softer: yet a few nodular diseased portions were removed by operation.

26 Sept 70	30.12.70		Cured	The fistulae were of 14 years duration, involving both the testes: the left one was especially indurated & dark & traversed by numerous sinuous channels, some of which opened into the rectum. There were sinuses even in the anterior portion of the perineum & in the scrotum, but there was no fistulae.
------------	----------	--	-------	--



Date of Admission	Name	Sex	Age	Occupation	Country	Disease	Operation
23 Sept. 81	Brojo Ratta Kuumak	M	40	Blacksmith	Kangah	Scrotal Tumor <sup>163</sup>	Removal by Dr. Enoch
5th Aug. 82	Go bind toll ween	M	36	house	Kangah	Hernia (presumed) <sup>164</sup> with Scrotal Tumor	Portion of the scrotum removed & attempt made to reduce the hernia - but it was firmly adherent.



Date of Operation	Date of Discharge	Date of Death	Result or cause of Death	Remarks
3rd Oct/70	7.1.71		Cured.	Disease of two years duration. The penis and of normal size before, but eventually became elephantine. Had had swollen scrotum five years before; but that went off after the first prostatic or straphed. The present elephantiasis has been accompanied by monthly fevers. The scrotum was about the size of a coconut, weighing only 2 lbs after removal. <del>No testis</del> There was some hydrocele on either side, & the left sac was thickened.
8. Sept/70.	9.10.70		Death from <sup>gangrene of</sup> a patch (anterior) of the scrotum about 3 or 4 inches square.	The patient was admitted with a large pendulous scrotum, encroaching upon the right groin, which looked fuller than the opposite side: but there was no impulse felt in the scrotum on coughing; nor could the tumour be diminished in size by manipulation, & it felt quite & solid & hard. He was a fatty-looking ancient person: & some time was required to prepare him for operation: & operation was begun as for a case of scrotal tumour, when on carefully incising upon the right side a large scrotal hernial sac (filled with mostly a thick omentum) was found. The surrounding skin was loosened on either side of the sweeping cut, & an attempt was made to reduce the hernia: but the sac being very thin it gave way in several places, & it was left unreduced. A portion of the thickened scrotum was removed from the other side, & this side cut with the other side flap were stitched up: & the whole kept up supported nearly a box of ice. He remained well all that day of the operation; but towards the next morning became very low; the abdomen swelled up, a patch of the scrotum mortified, & he died at 5 o'clock the next evening.
			x There were two or three urinary fistulae on different parts of the surface.	
			On P.M. Sept. - no peritoneal congestion or effusion was found either in the abdomen or in the scrotum. The heart was fatty, flooded with fat, but the other organs were healthy. The sac of the hernia was found filled with a thick layer of omentum from the top to the bottom part of the tumour, & was so firmly adherent at its lower part that it required the help of a knife to separate it. Under cover of this were found more than a foot in length of the large intestine from the caecum upwards, together with about 3 feet of the adjoining ileum. There was no strangulation anywhere.	
			The former history of the case is that he first noticed the tumour when he was 25 years old. & it continued as an ordinary sized tumour until his 34th year, when he had (a very difficult perhaps) stricture: & since it has enlarged & produced elephantine fever was of only three months duration.	



Date of Admission	Name	Sex	Age	Occupation	Country	Disease	Operation
9.10.70	83. Khil Chunder Lal	M	24	Apprentice	Bengal	Calculus Vesicae	Literal Lithotomy
12.10.70	84. S. K. Somar Day	M	20	look	Bengal	Hernia (inguinal) obstructed.	operation for strangulated Hernia
30 Sept 70	85. Francis Paul	M	42	herald	French	Compd. Colloid Fracture with Fracture of the lower end of humerus into the elbow joint - of the left side.	Amputation at the middle third of the arm



Date of Operation	Date of Discharge	Date of Death	Result or cause of Death	Remarks
10 Oct. / 70.	4.11.70.		Cured.	Disease was of three years standing coming on after an attack of fever. The calculus weighed 2oz 2scruples. Dose of the triple phosphate 30rb. a flat oral in form. The haemorrhage (a little more than usual) was stopped by plugging the wound with lark mud & a Shepherd's note.
13.10.70	14.12.70		Cured.	It was an ordinary oblique inguinal hernia of both sides. The left one was large & of 4 months standing: obstructed for 24 hours before admission. Taxis with ice & chloroform & guiding operation was performed & the patient did well. (then see he: 94.4.70)
15.10.70.	6.2.71		Cured. X	Sustained the injury by a fall - was gradually becoming weakened by no other ailment than constant sweat & slight disorder of the bowels: & on the amputation being performed he rapidly improved. After removal of the limb, the muscles & the subcutaneous areolar tissue were found infiltrated & darkened: & a large collection of purulent matter was let out from the seat of the fractured elbow on the day preceding the amputation. Both fractures were found comminuted & let into the joint. Had a few symptoms of cholera, etc. afterwards for which he had to stay in hospital for a long time, but ultimately he did well.



Date of Admission	Name	Sex	Age	Occupation	Country	Disease	Operation
21. 9. 70	86	Omah (amb.)	In 45	Ploughman	Kangah Brahmin	Phlebotomy of the thrombosed penis	Amputation of the Penis
21	87	"	"	"	"	occlusion of the arterial circulation from amputation of the penis	
20/10/70	88	Ray Honey	40	Scrubber	Bengal	Compd Fracture of both bones of the right leg, at the lower third	Amputation of the leg at its upper third in the modified flap way.



Date of Operation	Date of Discharge	Date of Death	Result or cause of Death	Remarks
3/10/70.	26 Dec 70		Apparently cured. Still a drop of urine comes out through the perineal wound.	Had syphilis 8 years ago. The primary sore gradually assumed the epithelial structure & extended wherever the glands by the time he was admitted. Inguinal glands were but slightly enlarged & one in the left appeared like a cyst containing pus. The whole glands & a portion of the body of the penis were involved: the patient was an inferior looking man. The penis was amputated with the crescentic needle to base & a ligature had to be applied. The wound healed in about 3 weeks. but the urine flowed through a sinus & veins instead of the natural passage, that was completely occluded. Some & several attempts failed to pass an instrument into the bladder. Hence the perineum was laid open & the instrument passed from that side & the front of the urethra made out & freed. This
30/10/70	D.		D.	
2. 11. 70.	1.3.71		Cured.	Injury received from a fall. Symptoms of Septicæmia setting in. She became very exhausted, amputation was performed with but little hope, as the affording her the last chance of her life: She had been altogether <sup>4 days</sup> lower since her admission; & she came in a day after sustaining the injury, with her leg perfectly regrettive. The operation did not do her the least good & she was considered to be quite devoid of any stamina. She could not retain her food or medicine the course began to lengthen by the 10 <sup>th</sup> of November, but yet with all these she gradually rallied by the 18 <sup>th</sup> of the month. wonderfully!



Date of Admission	Name	Sex	Age	Occupation	Country	Disease	Operation
31.10.70	89 Bunka Behary	M	20	None	Kangali	Stricture Uræthrae	Perineal Section.
28 Sept.	90 Pitoke (number)	M	37	Teacher	Kangali	Caries of Tibia (left)	Excising the carious portion by cutting through the soft structure of foot.
28 Sept.	91 Kangul	M	30	Scoundrel	Assam	Hydrocele (left)	Tapped & injected with the same fluid.

Left - Planning all night.



Date of Operation	Date of Discharge	Date of Death	Result or cause of Death	Remarks
3.11.70.	1.1.71.		fired. no. 12 could be passed pretty easily - only at times hitching at the umbilical region by age incised wound.	The stricture was a traumatic one due to a fall upon a ladder a year & a half ago. This fall caused haematuria lasting for three days; he <sup>was then</sup> <del>was then</del> could defecate into the bladder, the general health was good: & on performing perineal catheter a small calculus was found at the perineum about the size of a mill's head.
13.11.70.	12 Dec.		brought home in a very bad state - not hearing one alarm -	The patient was a very infirm looking anaemic man. The disease said to have set in after a long walk, with pain in the whole limb. It involved the tubercle of the tibia, & the middle third of the shaft of the same. The operation prostrated him more. All the cancellous tissue of the bone was quite softened & a large hollow made by gouging at both ends of the disease.
24.11.70.		30.12.70.	Death from pyæmia & cardiac embolism - gradually sinking from diarrhoea (bilious). P.M. 8.45. he spat out on the lungs - several large ones in the upper surface of the liver & a large cavity containing dirty matter with shreds of kidney rather granular.	Has been suffering from the disease for the last 6 or 7 years. Had been tapped twice. On tapping 8 oz of dark brown fluid at one time & 12 oz at another. In about a week the sac was again full & on tapping it again, it was found to have been filled up with gelatinous puriform fluid containing shreds of lymph. a free opening was then made for giving exit to the discharges: by which the system had been doing well & was really well, but he gradually sank from diarrhoea & exhaustion.



Date of Admission	Name	Sex	Age	Occupation	Country	Disease	Operation
14.11.70	92 James Kelly	M	36	Fireman	Ireland	Hydrocele (right)	Taffia injected with 37 of strong Linc. Sol.
11.11.70	93 Charles Rochester	M	30	Guard	American	Inguinal Hernia (right side) (ordinary stricture)	operation for Radical cure with Plessig's ligature.
12.10.70	94 John Connor	M	20	Book	Ireland	Sc.	Sc.
						(left side)	
14.11.70	95 Edgar Davies	M	4	Imm.	London	Double Hernia	Plastic operation
20.11.70	96 Sarut (Chunder)	M	7	Imm.	Bengali	Calculus in the bladder	lithotomy laid open the stone removed & plastic operation performed to prevent the return on the wound after the operation.



Date of Operation	Date of Discharge	Date of Death	Result or cause of Death	Remarks
14.11.70.	23.11.70		Swelling going down -	Disease of a long duration. Had been tapped twice before. This time 12 oz of dark brownish fluid let out.
15.11.70.	1.12.70		Cured - from prolapse	Disease of two years standing. Heavily had strangulation before, but he came in with the hernia down for 4 days without any symptoms of strangulation setting in. but nevertheless it could not be put up. Under the continuous application of ice however for 24 hours, it was reduced with a good amount of pressure. Three days after this it was operated on for radical cure: the plug was removed on the 5th day after.
do.	14.12.70		Cured - from firm -	This was a case operated upon for strangulated hernia on the 13th Oct 70. After that wound had healed, it was operated on for radical cure. There is another hernia on the other side.
18.11.70.	2.12.70		Cured.	Congenital malformation of the hip with the pelvis. The intertrochanteric space from the lateral pieces, projecting forwards with bony masses on it. This portion chipped off. The hip situated with the legs fixed.
20.11.70.	8.12.70		Discharge with a small sinus or fistula at the lower aspect of the wound, after the nature of the operation.	A thorn was known passing through the skin on admission, when some difficulty in reduction was noticed. On the 19th Nov. he came in on a sudden: the bladder could not be relieved twice. Several attempts made to bring out the stone, as it lay just at the bulbous portion but failed.



Date of Admission	Name	Sex Age Occupation Country	Disease	Operation
23.11.70	99 James Smith	m 46 Carpenter American	Compound Fracture of the middle phalanx of the little finger of the left hand.	Amputation at the Metacarpophalangeal joint
27.6.70	98 Raschke	m 20 00 Hungarian	Large surface tumor on scrotal	Transplanting a bit of skin from the abdomen on the surface made raw by slicing off
Below:	99 Proca	m 7 months	Imperfect anus	Opened out in a crucial way.
20 Nov 100	100 Kiti (Lund)	m 27 Trade	Stricture of the urethra & Perineal Abscess.	Perineal Section.



Date of Operation	Date of Discharge	Date of Death	Result or cause of Death	Remarks
				After letting out the Calculus; hard catheters were passed & retained kept in prosth. house, with the wounded brethren stitched up with horse hair as for a plastic operation.
23.11.70	9.12.70		Wound healing.	Injury sustained from the tubes of an ace - Immediate operation was performed by Ant. Meelanger.
24.11.70	19.12.70		The bit of skin died in two days on another one.	This was done merely for an experiment. & though the bit was seen faintly adhering at one of its corners the next morning, yet on the third morning it was found completely gone & gangrenous.
25.11.70	11.12.70		Relieved still the victim regarding the biliousness then.	The child was born with an imperforate anus, opened up then by some native doctor - Ever since there has been some difficulty in defecation - The opening on admission was a very small one & the lower bowels were distended with hard faeces.
25.11.70	29.11.70		Death from haemorrhage.	The patient was at first being treated with simple catheterism - Urine was opened ultimately for the abscess: & he was then doing well & all appeared when on the 5 <sup>th</sup> day he died from excessive bleeding from the wound, brought on perhaps by his incessant straining after a dose of oil with Turpentine.



Date of Admission	Name	Sex	Age	Occupation	Country	Disease	Operation
10 Oct 70	101. Satta Kalla Gupta	25	m	Printed	Uganda	Chylous ascites	Excision by O'Meara
2.12.70	102. Kuma Achine	10	F	None	India	Asphyxia from obstruction at the larynx	Laryngotomy
"	103. W. J. Koka	2	m	None	India	Thyroid (simple) Congenital.	Plastic operation
5 <sup>th</sup> Dec	104. Cally Chatur	43	m	Khaanawagga		Scrotal Tumor <sup>166</sup>	Removal
16 <sup>th</sup> Dec	105. Chika Johnson	43	m	Sailor	American	Hydrocele of the tunica of testis. 3 of the cord. & of the cord.	Exposure with 3 of the cord.



Date of Operation	Date of Discharge	Date of Death	Result or cause of Death	Remarks
22 <sup>nd</sup> Nov 70. 14.2.71			C.	<p>Disease often years standing. Head hydrocephalic with left side - left finger twice in the mouth. Tumor after removal weighed 17 3/4 lbs. with good deal of hydrocephalic on left side - 28 ligatures applied. There was not much bleeding. He was a healthy looking young man. The dressings were changed on the 3<sup>rd</sup> day after operation &amp; within 2 days of that there being a case of erysipelas in the ward then, he had erysipelas of his thighs, which gradually assumed a fearful type, of which he was about to die, when on the 23<sup>rd</sup> Dec. he was removed on the roof in a tent, where he gradually improved.</p>
2.12.70				<p>This woman had twice been operated upon for the same thing. The last time she was discharged with the tube in; but &amp; remained well. But by taking the tube out she brought the difficulty of breathing again &amp; was brought by her friends, quite suffocated.</p>
6 <sup>th</sup> 12-70	14.12.70		Cured	<p>A congenital malformation on the left side - wound healed by the first intention</p>
13 Dec 1870 9.2.71			C.	<p>The disease is of eight years standing. The tumor after operation weighed 19 lbs 3 oz. He bled but a little. The total loss of weight was 12 3/4 lbs including a large quantity of blood on either tunic &amp; against bottles: 33 ligatures were applied.</p>
17 Dec 1870				<p>This case was peculiar insofar that the swelling had come on by lifting up a heavy weight 3 months before &amp; the whole of the right <sup>side</sup> enormously distended up with my giving a new idea of rupture. 16 oz of serum (clear) let out from the tumor &amp; 12 oz of red blood fluid from the upper one on the next day &amp; <sup>this was</sup> was injected with 3 p of Lind. Sol.</p>



Date of Admission	Name	Sex	Age	Occupation	Residence	Disease	Operation
10 <sup>th</sup> Dec: 1878	Dolu	M	36	look	Kepek Inchomda	Stricture of Urethra (Traumatic)	Dissected by Holt's No. 9 instrument & No. 12 Sound passed.
18 <sup>th</sup> Dec: 1878	David Clarke	M	51	Sailor	Amst.	Hydrocele of the tunica vaginalis.	Tapped & injected with Quin. Sol. 3j
26 <sup>th</sup> Nov: 1878	Per boy	M	30	look	Winkham Inchomda	Synovitis of the left knee.	Tapped with a fine trocar & 4 oz of thickish, greenish lymphoid fluid let out.



Date of Operation	Date of Discharge	Date of Death	Result or cause of Death	Remarks
20th Decr 1870	8-2-71		Relieved	Disease of the month's duration, consequent upon a fall on his privy, which brought on some bleeding from the urethra at the time continuing for a couple of days - he: 34th could be passed with much difficulty through a dense & tight stricture at the membranous portion of the urethra. It then it was dilated by Holt's instrument, after which the urethra began to discharge & he did well.
22nd Decr	13-1-71		C.	The disease was of only a few days standing, & probably of chancreal was the cause.
30th Decr/70				This patient had been admitted for tetanus in November last: He got rid of all tetanic symptoms by the middle of December (It was a very successful case of tetanus treated with opium & Hemp & Chloroform; as much as 1/2 of the extract of Sassafras India with 1/2 of Chloroform was given him every two hours without the slightest effect at first.) but pains in his body continuing, the right hip & the left knee swelled & became very painful by the last week of December. Had an attack of pleurisy at the middle of Decr but that fever had all passed by & he was evidently doing well when he got this symptoms of his left knee. This after having continued for a few days with Iodine, Turpentine, Iodine, &c. was tapped with fine Trocar at the outer part of the joint above the patella & the inflammatory lymphatic fluid let out. This relieved his suffering at once, the fever abated & he did well.







*Date of*  
*Operation*

*Date of*  
*Discharge*

*Date of*  
*Death*

*Result or cause of Death*

*Remarks*







*Date of*  
*Operation*

*Date of*  
*Discharge*

*Date*  
*of Death*

*Result or cause of Death*

*Remarks*



Date of Admission	Name	Sex	Age	Occupation	Country	Disease	Operation
2			1871.		January.		
2 January 1871.	William Luch	M	47	Sailor	Irish	Stricture Uræthrae & Perineal Abscess	Perineal Section
2 <sup>nd</sup> January 2	D' Silva	M	50	horne	Portuguese	Stricture Uræthrae with hyperæsthesia of Urine & Urinary of the Uræthra.	Perineal Section with free incisions in the Perineum by the same Surgeon.
2 <sup>nd</sup> January 3	Lokool	M	30	Printer	Bengali	Stricture Uræthrae	Dilatation by Holt's large Instrument & No. 11 & 12 sounds passed.



Date of Operation	Date of Discharge	Date of Death	Result or cause of Death	Remarks
2.1.71.	22-6-71		Cured. he is now cured he easily passed and the wound completely healed.	Stricture of 19 years standing due to gonorrhoea which he first had 27 years ago. He had retention of urine. Had been operated on before for the stricture. The perineal abscess was up 4 days duration - urine coming out in drops. The smallest proved stuff was introduced with the greatest difficulty, (the patient not bearing chloroform well, it had been done without it). About 2 oz of matter came out after the perineum was opened - after which the stricture was divided backwards & forwards - cut like a potatoe. The S-shaped tube was removed on the 4 <sup>th</sup> day. after which the ureter was occasionally dilated with a full sized instrument, at times obstructed by some band or other - suffered from time to time from ischioanal abscess which were opened on the 8 <sup>th</sup> Feb'y.
2.1.71.	19-6-71		Cured. he is now cured he easily passed and the wound completely healed.	The stricture was a result of gonorrhoea that he had ten years ago. The retention of urine was of about a week's duration. He was not quite pulled down, but he had diarrhoea. With some difficulty it was checked by the third week of January. The catheter was kept in only for 4 days. This case was cured.
3.1.71.	4-8-71		Relieved.	Disease of 5 years standing - urine coming out in a narrow & forked stream. never had any retention of urine. The patient had synovitis of his knees.



Date of Admission	Name	Sex	Age	Occupation	Country	Disease	Operation
5 Sept 1870	Lt. Talbot	M	52	Clerk	English	opacity of the Cornea (partial)	for artificial pupil

11 Jan'y. 8	Rose Weatherall	F	23	Home	English	Angular Curvature of the spine -	Actual Castrating in two lines, one on either side of the spine <sup>at the dorsal region</sup> , each about 4 inches long & 2 inches distant from the spine - each about an inch broad.
-------------	-----------------	---	----	------	---------	----------------------------------	--

28.12.70	Mashal Koopah	M	40	Boatman	Bengali	Compd. Fracture of both bones of the right leg at its lower third.	Amputation of the leg at its upper third by the circular flap operation.
----------	---------------	---	----	---------	---------	--	--



Date of Operation	Date of Discharge	Date of Death	Result or cause of Death	Remarks
9.1.71.	13.3.71		Relieved -	Lost the use of his <sup>right</sup> eye eight years ago, from what appears to be (from his account) an attack of ophthalmia. The lower portion of the cornea & the outer white of the eye was quite opaque. The upper looked rather free & transparent. A portion of the iris behind this was removed by cutting through the cornea at its upper & inner part. During the operation a quantity of a peculiar sort of tuberculous looking matter came out from the anterior chamber.
12.1.71.	8-2-71		Relieved The back was quite firm Painless when discharged	The disease was of four years standing; during which time she has been getting attacks of fever with pain in her back. The spine began to protrude 2 years ago. & has been gradually becoming more prominent. At admission it appeared to make an angle of about 120°. The legs have become weak for the last month. She used to dance much - not married & was subject to slight nervous cough for some time since she had the pain in her back. She was then & slightly anæmic, from the last attack of fever that she had a month ago. The disease has since been progressing very fast, & the actual Caution was at once performed. She had been under the treatment of several medical men, who treated her with blisters & the like, with only a temporary benefit.
24.1.71.	30.1.71		D.	The injury was due to a fall, being knocked down by a carriage. The wound was small about 1/2 inch in length. & the fracture was comminuted. Attempt to heal up the wound by the 1st intention having failed, a few pieces of bone were removed & the separated ends of Tibia & Fibula chipped off by cutting the wound on the 30th January. after which the leg was in all appearance doing remarkably well. But tremor, without any distinct tetanic fits, having set in by the 21st January, the leg was removed -

This patient came in again on 20th/71 for pain in about the lumbar region for which see operation no. 15/71.



Date of Admission	Name	Sex	Age	Occupation	Country	Disease	Operation
18 <sup>th</sup> January 7	Mrs. Rita	F.	54	None	English	Cancerous Tumor of the right Breast.	Removal of the whole breast with the skin call.
Do 8	Edy.	M.	3	Child	Indian	Abscess of the Eyeball.	Excision of the Eyeball.
14 Feb.	Chinta Kony Ghose	M.	19	Student	Bengali	Calculus <del>bladder</del> Vesicae.	Median Lithotomy
24.10.70	10 Bago Lashan	M.	60	Tanner	Bengali	Cataract (left)	Flap operation



Date of Operation	Date of Discharge	Date of Death	Result or cause of Death	Remarks
26.1.71.	5.2.71		Death from Pyemia Hæmic Embolism No: P.M. allowed.	Disease of three years standing. The tumor originally not painful has become <sup>stiff</sup> so for the last year. It has become very hard since the last month. The nipple was retracted & a portion of the skin above it was adherent. The breast was tender. Her mother died of cancerous breast, which could not be removed. Has a son 23 years old. She is otherwise pretty fair in health. She did not lose much blood.
29.1.71.	14.3.71		Cured.	This was a case of exular abscess of the eye ball resulting from purulent conjunctivitis. This child was brought in with purpl inflammation of both of his eyes, the right cornea having already inflamed. The conjunctivitis subsided by treatment, & he recovered the perfect use of his left eye but the right through otherwise good was quite useless. This gradually inflamed within, & the hazy cornea bulging as it was excited with the iris & the lens. A quantity of pus escaped. The whole contents of the eye ball were found degenerated into purulent matter.
3.2.71.	17.2.71		Cured.	This boy had once been operated upon for the same complaint in 1864 (which see in the preceding volume) & it was that lateral lithotomy <sup>day before</sup> <del>was done</del> . The cicatrix <del>was</del> found was. The stone present stone was a very small one about the size of a bean, flat oblong in shape & apparently phosphatic. The present complaint was of two months duration. The stone weighed 28 grains.
5.2.71.	5.4.71		Cured.	This patient was admitted for a metasthe growth on his left cheek, from which he has been under treatment <del>for</del> <sup>for</sup> <del>some</del> <sup>with</sup> the application of escharotics. The last being very & the sight impaired, it was removed & he did well. The operation was done without Chloroform.



Date of Admission	Name	Sex	Age	Occupation	Country	Disease	Operation
6 July	11 Phiroj Nath	M	28	Director	Bangal.	(calculi in bladder)	Cut open & removed.
24 Oct '70	12 Bupodindar	M	60	Farmer	Bangal.	(cataract in right eye)	Removal by the Flap operation.
15 Feb '71	13 Selol Ch. Bhatia	M	26	Industrious	D.C.	A gap in the lower lip & chin, resulting from Cancer of the	Plastic operation.



Date of Operation	Date of Discharge	Date of Death	Result or cause of Death	Remarks
6.2.71.	13-3-71		Cured, the wound healed by secondary intention.	This patient was suffering from obstruction in the bow of his water for the last two months. The obstruction was at the bulbous portion of the urethra. The stone lay impacted in this part the urethra forming a regular cylindrical sac there, it could not be pushed out through the meeting workman. It weighed only a few grains, triangular in shape, mulberry-like in appearance & of the size of a small bean.
12 Feb. 71	5-4-71		Complete failure, the eye ball cicatrized when discharged.	The left eye had been operated upon a few days ago: & the right fungoid disease was then operated upon. <del>The</del> <sup>The</sup> stone remained by the flap operation. The patient took off the pad & bandage soon after the operation & the flap turning back, sloughed: & the lens not having been removed during the operation lodged in the eye causing it to be inflamed, but it ultimately came out through the sloughy gap in the corner on the 21 <sup>st</sup> .
19.2.71.	12-3-71		Cured satisfactory	The patient had Canineum Orit, when three years old - was in fair health on admission. The gap was a pretty large one, extending from about 1/4 inch from the left commissure of the lips to the central incisor of the left side; & going downwards as far as about an inch below the gums. The edges of the gap were joined; & the parts separated, the canine & the incisors pulled out, & the wound stitched up with horse hair. The patient did well.



Date of Admission	Name	Sex	Age	Occupation	Country	Disease	Operation
Feb 20 <sup>th</sup> 14	F. W. Lakin	M	32	home	English	Compd. Emphysema Fracture of the two <del>middle</del> fingers of the left hand, resulting from a gun shot injury -	The two outer inner fingers removed with the heads of their metacar- pal bones.

20.2.71. 15	Miss Wootton	F	23	home	English	Curvature of the Spine -	Actual Castration on either side of the spine.
-------------	--------------	---	----	------	---------	-----------------------------	--

Jan 2. 16	D. Silva	M	50	home	Portuguese	Structure Wrote	Perineal section
-----------	----------	---	----	------	------------	-----------------	------------------

13.2.71. 17	Goburdhun	M	45	Servant	Bengal	Scrophulous Abscess on the right side of the neck causing laryngismus -	Tracheostomy.
-------------	-----------	---	----	---------	--------	--	---------------



Date of Operation	Date of Discharge	Date of Death	Result or cause of Death	Remarks
20.2.71.	4.6.71		Cured	The fingers were almost blown off, hanging only by bits of skin like Ventrals. The first phalanx of the thumb was also broken with a fine deep wound communicating with the <del>external</del> air: but it was saved.
23.2.71.	27.3.71		Relieved	This patient had once been similarly treated here & was discharged almost well a few days ago. The operation was performed on the dorsal spine where the spine was of slight pain at the time, but protruding. This part was quite firm & painless on admission, but the small of the back having been very painful since & tender too, with pains in her legs & difficulty in locomotion, actual cautery was applied in either of the present out of disease of the spine.
24.2.71.	19.4.71		Cured. No. 11 could be easily passed - wound completely healed & scutum.	This patient was admitted for extra-vesical section of prostatic with stricture of the urethra. Perineal section had then been performed: but the wound cicatrized, left no free passage for the water; nor any instrument could be passed with ease into the bladder. Consequently the adhesions were broken & the perineum divided again.
25.2.71.	29.3.71		Died of asphyxia	The whole posterior superior triangle of the neck was diseased, swollen & hard & tender & very painful. The swelling was enormous & the parts were very tightly stretched, pushing the larynx on the opposite side - several spots of gangrene were opened, but large portions continuing, the trachea was opened, &



Date of Admission	Name	Sex	Age	Occupation	Country	Disease	Operation
23 Dec 1870	18. Teodoro Nauti	M	15	Nave	Brazil	Spontaneous gangrene of both feet	Spines amputation of the left foot

19

Modified flap operation at the middle of the right leg

Dr. Ewart

7-12-70	20. Sophie Bass	M	40	Laundry	Denmark	Scrotal Tumors	Removed
---------	-----------------	---	----	---------	---------	----------------	---------

Dr

15-3-71	21. Theda Kate Morken	M	28	Laundry	Brazil	Scrotal Tumors	Removed
---------	-----------------------	---	----	---------	--------	----------------	---------



Date of Operation	Date of Discharge	Date of Death	Result or cause of Death	Remarks
9-3-71	6.11.71		Discharged with good stump	This was a case of spontaneous gangrene consequent upon a rather severe attack of malarious fever - 10 days after which the foot began to mortify - 12 days after he was admitted with the right foot completely gangrenous and so also the front half of the left. He was in a miserable state then, very low - pulse quite thready. Remained a long time the stumps beginning to cicatrize - the lower ends of right leg bones remaining exposed and the left tarsus becoming diseased, both operations were performed at the same time - The patient still not being in a good state of health.
10-3-71	6.6.71		Cured	Disease of seven years standing - got Elephantiasis - Tumours increasing - with by monthly attacks of Elephantiasis fever. Tumour weighed 18½ lbs after operation - there was no hydrocele on either side - the wound bled liberally freely and about 50 ligatures applied. On the third day the dressing was changed.
16-3-71	17.6.71		Discharged with a small bit of wound remaining to heal at the request of the patient.	Disease of seven years standing. Had elephantiasis fever before but for the last 2 and half years. Instead of the fever, no of pimples break out on the scrotum. No discharge of coarsely purulent fluid now - then without any regularity either appearance or of this discharge. On admission the scrotum was flabby and red and discharging a sub of bloody fluid on puncturing. The tumour weighed 3¼ lb. after removal. about 10 ligatures applied, but the wound bled very freely owing to the vessel being so profusely very large.



Date of Admission	Name	Sex	Age	Occupation	Country	Disease	Operation
7 Dec 70	John Clapp	M	40	Husker	Mich	Scrotal P <sup>167</sup> unum	Removal
8 <sup>th</sup> March 22	Robert McCallister	M	32	None	English	Stricture Uræthra	Dilatation by Holt No: 9 Dilator No: 11 Fondle
26.3.71	22 Madox Edwin	M	55	None	English	Hydrocele (double)	Tapped & injected with Tine of Iodine
26.3.71	24 Tobin	M	40	Husker	Engls	Scrotal P <sup>168</sup> unum	Removal



Date of Operation	Date of Discharge	Date of Death	Result or cause of Death	Remarks
10.3.71.	4.6.71.		Lived	Disease of seven years standing: increasing rapidly for the last two years. Is subject to elephantiasis fever, ever since the beginning of the disease. His health was poor and he was suffering from dysentery when admitted. After a few days treatment the fecal tumour was removed, without his pulses becoming quite steady. The tumour after removal weighed 18 1/2 lb. without any hydrocele on either side: the wound healed pretty freely. A 50 ligature was applied a little after bleeding ensued, the dressing was changed on the 3 <sup>rd</sup> day. Apoplexy of acute cerebral action suddenly on the morning of the 20 <sup>th</sup> March he passed off in 2 days. After 20 <sup>th</sup> he got symptoms of Tetanus from the 28 <sup>th</sup> of March: The spasms, kept the beginning for a few days were confined only to the jaws & the thighs but gradually spread up to the trunk, the jaws remaining free.
23.3.71.	15.71		Cured, while he is Catat Could be easily passed into the bladder.	Stricture from gonorrhoea, was of about 10 years standing - he: 5' could be passed very well, but it caught at a bend at the bulb. The urethra was very small, hence the operation. There was a chain of fistulae behind.
	18 July 71		Lived	Disease of 12 years standing with periodical attacks of fever. The right side was larger and the more recent contained 48 oz of clear straw colored fluid: the left contained 24 3/4 a light colored fluid. The former sac was injected with one ounce and the latter with 1/2 ounce of the strong Tine of Iodine. The 1st beginning of suppuration opened on
27.3.71.	4.6.71		Discharged with a small bit of wound remaining 1 1/2 inch.	The disease of seven years standing, proved by hydrocele of three years on the right side. Was subject to Elephantiasis fever. The tumour weighed a little more than 2 lb after removal. There was some hydrocele on both sides, and the sacs were thickened. His patient had Tetanus in the midst of treatment which was treated in ordinary way.



Date of Admission	Name	Sex	Age	Occupation	Country	Disease	Operation
22.2.71	Naboo	M.	28	Cultivator	Bengal	Fibro-plastic Tumor from the gums on the right side of the upper jaw.	Removal of the diseased portions of the upper jaw by cutting through the upper lip.



Date of Operation	Date of Discharge	Date of Death	Result or cause of Death	Remarks
28.3.71	24/4/71		<p>Also covered on 28/4/71. In this case of fibroplastic growth from the lip was completely healed. A small communication remaining patent from the nostril into the nostril - The internal wound was also much healed, about a third at the middle still remaining sore - The right 10 of the cicatrix looked suspicious of fibroplastic growth, but much unlike the appearance of the original tumor. When the mass absconded -</p>	<p>growth of the upper jaw, involving the alveolar portion of the bone. The rest of the right maxillary bone was free from disease, neither the nostril, nor the alveum, nor the palate was diseased - Hence no osteotomies were performed in the operation - The tumor began as a small swelling about the gums about the right upper canine, but gradually involved those of the front teeth, pushing <sup>upwards</sup> the incisors of the other side. Most of the teeth on the diseased side were fallen off - The tumor was of the size of about the size of an egg, but rather longer &amp; shorter - thinner in shape - it was grown at its lower part where it corresponded to the surface of attachment of the lower row of teeth - It overlapped the alveoli, &amp; was very hard - The patient was a pretty stout man, but he had chronic bronchitis since his infancy - For this the operation was postponed for some time. Even on the day of operation there was still some chest-complication existing - The patient bore the operation remarkably well without the chloroform. The lip was cut through as far as the right nostril; after which a triangular piece of the bone was removed by sawing through the body of the left maxillary just behind the alveum, &amp; coming down obliquely in front of the 2nd molar of the right side, &amp; in front of the canine of the left side, both of these teeth were kept intact, for putting a set of artificial teeth afterwards - There was free bleeding especially from the enlarged blood vessels of the bone. The wound was stitched up with horse hair, &amp; the gap in the jaw was plugged with druid. The wound healed up without any bad consequences at all. May the Congress be a good deal after the operation -</p>



Date of Admission	Name	Sex	Age	Occupation	Country	Disease	Operation
12.3.71	Gorn Churn	M.	40	Farmer	Benjal	Epitheliomas on the glans Penis	Amputation of the Penis
4 <sup>th</sup> April	Unmed ally	M	32	Lascar	8 <sup>th</sup>	Morbus Coxaris of the right side (from brucea in the ship)	Actual Caution in 2 places at the gluteal region.
10 <sup>th</sup> April	James Watkins	M	32	Mar	English	Inflamed cyst on the right side.	Removed by making a transverse incision over it. D. Wood



Date of Operation	Date of Discharge	Date of Death	Result or cause of Death	Remarks
30.3.71	16.5.71		Cured,	<p>He has been suffering from Phymosis of the Penis for the last seven years ever since he was a child; and this has been discharging for the last 5 or 6 years; two or three years previous to which the part used to tickle a good deal. The discharge stops at times, but has been continuous for the last 6 months. The patient's general health is good and he does not admit of ever having had any syphilitic disease. For a few days after cutting open the phymosis the diseased portions (the glans and the inner aspect of the prepuce) &amp; the umbilicus &amp; the penis were touched daily with strong Carbolic acid without any tangible effect consequently the organ was amputated at the middle with the Forcissors.</p>
4.4.71	19/5/71		Cured,	<p>This patient had had an injury to the hip by falling on his right side from the top of a carriage. This was about 2 months ago. It was thought to be a mere bruise &amp; he was discharged. But ever since that time the joint has become partially stiff. The gluteal muscles were being atrophied. The limb was a little longer too; but there was not much pain in it.</p>
13 <sup>th</sup> April 71	15.4.71		Cured,	<p>The cyst was of about 20 years standing; inflamed for the last 4 days. It contained crystals of cholesterine mixed with purulent matter. It was of the size of a small egg.</p>



Date of Admission	Name	Sex	Age	Occupation	Country	Disease	Operation
14 April 1928	James Kerr	M	37	carpenter	India	Stricture urethrae with abscess in the perineum & rectum.	Perineal section. Dr. Wood.

15 April 29	Rameshwarday	M	40	none	Hindustan	Epithelioma of the glans penis.	Amputation of the Penis at its root, with the crura per Dr. Ford
-------------	--------------	---	----	------	-----------	---------------------------------	--



Date of Operation	Date of Discharge	Date of Death	Result or cause of Death	Remarks
16 April 1871.	18. 12. 71		Discharged with a curable lesion in the perineum until it is removed could be passed.	The abscess was of about 20 days duration but the stricture was of about 15 years standing. No instrument could be passed in. Hence the perineum was opened without a guide. There were 2 or 3 false passages detected there; the stricture divided, urethra cutting like potato. The patient had once had retention of urine about 3 years ago, when the urethra had <sup>been</sup> dilated the 1st time. The S-shaped tube was removed within day after the operation.

18 April 71. 24. 5. 71

Cured

It was a large outgrowth from the body of the penis & the glans, especially affecting the lower aspect. It was about the size of a large potato, & it looked like it too. It was lobulated, with localities on its surface as well as in its substance, containing purulent matter. The juice scraped from its surface on section, exhibited distinctly myeloid cells — large, granular, with large nuclei. It was of two years standing. The sigmoidal glands were but very slightly enlarged. Most part of the penis was diseased, it was with difficulty that the ergogen was applied at the very root of the organ. The tumor used to bleed occasionally.



Date of Admission	Name	Sex	Age	Occupation	Country	Disease	Operation
4 <sup>th</sup> May/71	Bhosban	Male	35	Cooly	Bengali	Stricture Urathra with sloughing of the deep fibres of the perineum from extravasation of urine.	Perineal Section
26.3.71	Moshusudan	M	55	House	Bengali	Internal & External Haemorrhoids	Excision of the external ones and ligature of the Internal ones.



Date of Operation	Date of Discharge	Date of Death	Result or cause of Death	Remarks
5.5.71		12.5.71	Pyæmia & cardiac embolism? (No post-mortem could be made)	This patient was brought in by the Police in a wretchedly low state of health suffering from diarrhoea and difficulty in passing water. The scrotum was oedematous; the perineum swollen and dense. There was phymosis & discharge from the urethra. The meatus urinarius was very much contracted. No. 4 could be passed with great difficulty. The prepuce was slit up and the urethra found dense & contracted almost throughout its whole length. The chief difficulty in getting the instrument through was about the membranous portion; hence the perineum was divided upon a small grooved staff, and a S-shaped tube was kept in for 48 hours. He did not bleed much; but the diarrhoea from which he had been suffering for about 2 months lowered him the more, delirium set in with hectic fever & he died with hurry of respiration. The respiratory murmur being quite blowing and pecuni with mucous and submucous rales throughout the chest. The sloughing of the perineal tissue was perhaps of about a week's duration; for, it was this time that he <sup>had</sup> suffered the most before he was brought in this Hospital.
26.5.71	6 <sup>th</sup> July 71		The patient discharged with the wound entirely healed.	This patient was the person operated on for big hydrocele on either side. The hydroceles were doing well, but the piles beginning to ulcerate; the internal ones were removed & six ligatures applied to the internal ones. He has since been doing well.



Date of Admission	Name	Sex	Age	Occupation	Castles	Disease	Operation
1.5.71.	33 Sita katha	M	50	Blacksmith	Bengal	Epithelioma of the lower lip.	The tumor with the lip was removed and plastic operation performed at the same time.



Date of Operation Date of Discharge Date of Death

Result or cause of Death

Remarks

18.5.71.

14.7.71

Discharged with a pretty good lip sufficient to cover the lower set of teeth

The disease was about six years' standing growing very rapidly for the last 8 or 10 months. There was no enlargement of the cervical or the submaxillary gland, but the gums were slightly implicated. It was situated about the middle of the lower lip, the middle third completely diseased and ulcerated and dense. The application of the ordinary Carbolic acid oil diminished the swelling a good deal but yet it was thought proper to operate; almost the whole of the lower lip was taken out; a triangular incision made at the chin along the lower border of the jaw on either side and the flap included between this and the gap above left by the removal of the lip was divided in the centre glans from its attachments as far as the nostrils on either side & stitched up again at the centre in front of the teeth; the central incisors were pulled out and the frenum linguae cut off. Bled tolerably freely but has been doing well since. The patient was in a fair state of health



Date of Admission	Name	Sex	Age	Occupation	Castle or Country	Disease	Operation
7 Nov. 70. 34	Notober	M	40	Barber	Bengali	Epithelioma of the left foot.	Syme's amputation at the ankle.



Date of Operation	Date of Discharge	Date of Death	Result or cause of Death	Remarks
10.5.71.	15.5.71		Pyæmia & Cordæ Embolus. Pyæmic patches in the lungs & kidneys. Fibrinous clot in the right ventricle up with the Pulm. artery. Congested kidneys.	This was a genuine case of epitheli- oma beginning <sup>about 2 years ago</sup> as a corn which ulcerated & ulcerating left a sore rapidly increasing since. The large, dense, irregular, in- dented, rough, granular, whitish sore was situated at the inner side of the instep and foot extending from the toes to the back of the hollow of the foot and from the subcutaneous surface of the 1st Metatarsus to about the position of the 4th at the sole. The patient was a very weak, anæmic, elderly man, hence several attempts <sup>were</sup> made to make some good by the application of escharotics, e.g. strong Carbolic Acid, Chloride of Zinc &c. But without the slightest effect on the sore. The bones began to be invaded & the health of the patient having improved by the time; the foot was removed at the ankle. The wound bled freely, <del>but</del> <sup>and</sup> 7 ligatures had to be applied; still the heel flap began to slough within and at the edge from the 4th day after the operation. He getting rigors and sweats from the 5th day on the after noon of the very day.

Bahar Isham Khan, Dr. of House Surgeon to the  
Senior Surgeon Medical College made over  
his charge to Sub. assistant Surgeon Soojee  
Coormah Phuntarwallah on the after noon of the  
27<sup>th</sup> May 1871.



Date of Admission	Name	Sex	Age	Occupation	Country	Disease	Operation
15 <sup>th</sup> May 1871	35 <sup>th</sup> Madam Brohm	F	45	Ser Car	Bengal	Inguinal Hernia (Right side) pedunculated of ligament	Operation for Strangulated Hernia without opening the sac.
2 <sup>nd</sup> May 1871	36 <sup>th</sup> Mohadul Chatterjee	M	30	Stone	Bengal	Woe abscess on the inner of the Pelvis Left side.	Opened by a curved incision above the perforator ligament & then to the anterior superior spine process & then
5.6.71	37 <sup>th</sup> Boykonthammatt	M	37	Cloth dealer	Bengal	Compound longitudinal fracture of the 1 <sup>st</sup> phalanx and posterior flap of of the index finger (1 <sup>st</sup> )	Amputation by anterior flap of the finger Keeping the head of the Metacarpal bone intact



Date of Operation	Date of Discharge	Date of Death	Result or cause of Death	Remarks
15 <sup>th</sup> May 1871	29. 6. 71		Cured	Admitted with ordinary oblique inguinal Hernia of 4 years standing. Hernia did not go up for the last 10 hours. He had no symptoms of strangulation and feeling sickness & Constipation. The Hernia was of the size of a large tumour the construction was found at the outer ring formed mostly by the Intercolumnar fibres. Taxis & Cold having failed the Hernia was reduced by operation under chloroform.
22 <sup>nd</sup> May 1871	2-7-71		Cured	Abscess began of itself with fever about 6 weeks ago. There was very little rigidity of the thigh towards the abdomen. The abscess was a pretty large one swelling about the size of a man's fist above the hymanal little towards the median line. discharged about a pint & half of rather thick pus. It was considered to be a superficial abscess but on examination it was found communicating with the Pelvic Cavity. There was a little Ulcer and stopped by Dressing - no history of Rigors.
14. 6. 71	1. 8. 71		Discharge cured with a few Stumps -	This was a case of neglected Compound fracture of the 1 <sup>st</sup> phalanx of the right index finger of 16 days standing caused by a hammer. He was admitted with fearful inflammation of the whole finger and the palm. The deep flexor tendon of the finger was found sloughing with burrowing of matter in the palm. The palm and the finger was freely incised on admission. The health got better and the finger was amputated at its root by anterior and posterior flaps keeping the head of the



Date of Admission	Name	Sex	Age	Occupation	Country	Disease	Operation
12.6.71 38	Trenoth	M	40	Servant	Bangla	Oblique Inguinal Hernia (Right)	Radical cure by plug and ligature
16.6.71 39	Laurance	F	20	Nurse	Bangla	Tumor attached to the clitoris and elephantiasis of the left labium major	Excision
14.6.71 40	William Luth	M	40	Carpenter	Scotch	Hydrocele (Left) (double)	Tapped and injected with 37 of Lint: Iodide



Date of Operation	Date of Discharge	Date of Death	Result or cause of Death	Remarks
				metacarpal bone intact. The phalanx was found split throughout its extent into two lateral halves.
21 <sup>st</sup> June 71	22-7-71		The internal ring strong enough to support the testis.	Ordinary oblique inguinal hernia of 4 months duration. Came on spontaneously and gradually. The ring well defined. Semite middle finger easily. Distinct impulse felt on coughing. Operated under chloroform by modified Syme method. The plug removed fourth day after the operation, and the patient continued doing well.
26. 6. 71	15-7-71		Discharged. Case with the wound entirely healed up.	This was a case of tumor of one year's standing, it was of the size of a man's fist, free from the labia on either side. The tumor with the hypertrophied clitoris and the adjacent portion of nymph removed with a scalpel and the hypertrophied left labium major excised separately by a curved incision on either side of it. The first wound bled tolerably freely and about ten ligatures were applied.
30. 6. 71	1-8-71			The disease began about two years ago but became worse for the last fortnight. Says he never used to get fever. The disease existed only on the left side and on tapping about 13 xi of fluid (straw colored) drawn out.

Single ligament was taken on the 11th August 1871 without 2 mm of straws and fluid at rest. The sack was injected with fluid of iodine.

Curish



Date of Admission	Name	Sex	Age	Occupation	Country	Disease	Operation
5-7-71	41 Ayder Sby	M	30	Fireman	Bengal	Stricture rectum with abscess in the Perineum	Perineal section
14 <sup>th</sup> May 71	42 Shumsher	Im	44	Active ship	Bengally	Fistula in Ano.	Sphincter Ani (both external & internal) divided upon a Director
17/6/71	43 Mooktaran	m	55	Weaver	Bengally, Hyderabad	Both of Tapped and injected the Tunica Vaginalis with solution of Iodine and the chord (left side)	



Date of Operation	Date of Discharge	Date of Death	Result or cause of Death	Remarks
5-7-71	24-11-71		Discharged at his own request	The patient was admitted in a very bad state of health with an abscess in the Perineum at the seat of the wound. No 12 catheter could be passed easily into the bladder. The patient was of three days duration and structure of three years standing. No instrument was passed before. He had stricture once about a year ago. There was also retention of urine. The Perineum divided on a grooved staff under Chloroform. The further cutting like a spot. S shaped tube was introduced after operation. The wound healed pretty freely. Patient doing well since then. The tube was taken out after three days.
27 July 71	10.9.71		Found	Fistula of eight years standing; came on after an abscess in the ischio-rectal fossa, communicating with the rectum about two inches above the anal opening from the right side. The sphincter divided and the patient healed freely.
12/7/71	17.8.71		Found	A large hydrocele of 15 years standing came on spontaneously, with fever which used to come periodically. In size it was like that of a large pumpkin both the sacs communicating. Contained about a pint and a half of straw-colored fluid which coagulated on nitric acid being added. The sac was injected with two drachms of strong Tincture of Iodine.



Date of Admission	Name	Sex	Age	Occupation	Country	Disease	Operations
13/7/71	44 Shambhas	Male	60	Farmer	Bengal	Elephantiasis of the 169 prepuce & scrotum	Excision as in ordinary cases of scrotal tumours
3-7-71	45 Inouia	Female	6	None	Bengal	Dislocation of the left Femur on the dorsum of the Ilium	Reduced by extension under Chloroform
17-7-71	40 Kristi Chauder	Male	36	Shepherd	Bengali	Hydrocele (Right)	Tapped and injected with half an ounce of strong tincture of Iodine



Date of Operation	Date of Discharge	Date of Death	Result or cause of Death	Remarks
14-7-71	20-10-71		Left the Hospital at his own request with a wound of wound remaining & healed	The disease began with an ulcer on the rectum in its median line about a year ago. The fissure was five times larger & thicker than natural. Used to get abscesses & fistulae in a month. Suffered from having had syphilis but admits that he had gonorrhea about a year and half ago. Both the stricture and fissure were removed and the patient did well. About 15 ligatures were applied, tumours weighed 3 lbs and 6 ounces.
14-7-71	2-10-71		Exchanged with nearly equal legs only a slight shortening of the right leg.	Said to have fallen on her left side & hurt the hip about two months ago. That limb was shorter than the other by almost 2 inches. The child was able to walk (though with difficulty) until she complained of severe pain in the left knee & pain. The joint was freely movable in all directions and the bones were healthy. The dislocation was reduced with great difficulty and the head of the bone kept in its place by the limb having been put upon a long splint. The limb is even now shorter than the other by half an inch.
20-7-71	12-8-71		Relieved.	Disease of five years standing. Came on spontaneously. Attended with fever which is to come periodically twice in a month. Right side larger than the left. On tapping about 3 pints of clear straw colored fluid came out and the cyst was expected with strong liniments of Iodine.



Date of Admission	Name	Sex	Age	Occupation	Country	Disease	Operation
16-7-71	47 Bisheshwar	M	31	None	Benegal	Stricture urethrae	Perineal Section

12-7-71	48 Joseph Seade	M	45	Seaman	English	Cystic tumour of the neck.	Tapped and injected with weak solution of Carbolic acid.
---------	-----------------	---	----	--------	---------	----------------------------	--

26-7-71	49 James Edca	M	17	None	English	Hydrocele (left)	Tapped and injected with strong Tinct of Iodine.
---------	---------------	---	----	------	---------	------------------	--



Date of Operation	Date of Discharge	Date of Death	Result or cause of Death	Remarks
19-7-71.	29/8/71		Discharged with cure and no wound could be passed easily into the bladder	This patient was admitted in a very poor and wretched state of health with stricture of 6 years standing which evidently came on after an attack of Gonorrhoea. This was followed by an abscess in the Perineum which was opened by a Noting. The wound healed but there remained a sinus communicating with the urethra. The patient says that he had been passing thin streams of urine for the last 4 years; never had a retention of urine. On admission No 2 sound was passed with a good deal of difficulty and bleeding. For this perineal section was performed under Chloroform. The Perineum was divided on a small grooved staff; the urethra was found hard and calling like potatoes. After operation S shaped tube was introduced and kept in for 48 hours. The wound bled pretty freely and the patient doing well since then.
13-7-71.	24.8.71		Cured	This patient was admitted with a large Cystic tumor about the size of a good big apple. Occupying all the space between the chin and the stern. clavicular notch. Had slight difficulty in deglutition. The Cyst was tapped and about an ounce and half of coffee brown colored fluid let out. Under microscope a few blood corpuscles were seen in that fluid but no Cholesterol was found.
27-7-71.	2.9.71		Cured	Hydrocele of 6 months standing. Came on after a blow. It was of the size of an orange. On tapping about 14 oz of straw colored fluid. Came out and the cavity injected with 3 drms. of Solution of Iodine



Date of Admission	Name	Sex	Age	Occupation	Country	Disease	Operation
21-7-71	50 Sul Mahomed	M.	30	Portman	Bengali	Vertebral Tumour <sup>170</sup>	Excision
19-7-71	51 Schwarz (Kattaya)	M.	24	book	Bengali	Inflammatory Softening of Vertebrae.	Actual Caution along the transverse processes of the Vertebrae - a like side of the spine
5-7-71	52 E. Beuman	M.	27	clamaa	Wilah	Inguinal Hernia (Right).	Radical Cure by plugs and ligatures
12-7-71	53 Harraadhun	M.	40	Colly	Bengali	Lacerated Wound on the left foot.	Amputation at the upper third of the leg by modified circular.



Date of Operation	Date of Discharge	Date of Death	Result or cause of Death	Remarks
27-7-71	27-10-71		Cured	Admitted with a scrotal tumour of 1 year standing. The tumour was about the size of a child's head. Used wet elephantiasis fever twice a month. The tumour is said to have become larger during fever. Whole of the elephantiasis fever removed under Chloroform and about 12 ligatures applied. The tumour weighed 13 lb.
23-7-71	19-10-71	Cured	Transference of the disease and for others	The patient states that he fell upon his back with a bag of rice which he was carrying and hurt his spinal column about 11 months ago. Since then he has got Carvature of the spine and been complaining of pain in that curved spot. With the view of relieving him from pain and stopping the progress of inflammation, actual casting was resorted to under Chloroform. Patient doing well since operation.
9-7-71	29-8-71		Discharged cured with the hernia well supported above the external abdominal ring.	Suffering from Inguinal Hernia for the last 2 days. Hernia is said to have caused Case down after a kick on the right groin by a sailor. It was small one and did not come down to scrotum. Operated under Chloroform by plugs which were removed on the fifth day of the operation.
31-7-71	1-8-71		On Post-mortem exam	This patient was admitted with a laceration, lungs were large lacerated wound at the front healthy, but the root of the great larynx involving right heart, killed a large portion of the wall of the with fluid venous foot. This is said to have been blood, other organs crushed by the fall of bag of rice pretty healthy, except. On the third day after accident, slight conj. gangrene set in on the turn of the kidneys the patient became low







Date of Operation Date of Discharge Date of Death

Result or cause of Death

Remarks

therefore, he was ordered a little carbonate of ammonia and chloric ether. Nature gradually worked off & separated the dead portion on the twenty-third. Since then the patient continued improving till the thirtieth July when he was suddenly attacked with tetanus. On the same day, a amputation by modified circular operation was performed at the upper third of the leg. The tetanic fits gradually became less, and the patient died of exhaustion.

7-8-71

9-8-71

Death. No Postem allowed. Septicemia from shock

This patient came in a very low and wretched state of health with extravasation of urine of six days' standing. His friend states that he has been suffering from stricture for the last fourteen years. On examination urine was found in the scrotum, groin, and perineum. Number three sound was passed into the bladder with great difficulty, and the stricture was divided on a ground staff; two sections were made in the two Oschie's Reclat forceps, a third on the scrotum, and the fourth on the groin. The patient sunk gradually, and never recovered since the operation. The s-shaped tube was introduced but there being bleeding it was taken off the wound was plugged with lint.



Date of Admission	Name	Sex	Age	Occupation	Country	Disease	Operation
3/13/71	55 William Reid	Male	32	Blacksmith	Irish	Femoral aneurysm left (Traumatic)	Ligation of the left femoral artery at the lower third by an incision about seven inches long extending from the middle of the thigh to about an inch above the popliteal space at the inner & anterior aspect of the thigh, both the upper & lower end of the artery was tied just when it comes out of the Hunter's Canal.

12/17/71	56 Joseph Sands	Mr	45	Farmer	English	Internal hemorrhoids	Ligated
----------	-----------------	----	----	--------	---------	----------------------	---------



Date of Operation	Date of Discharge	Date of Death	Result or cause of Death	Remarks
3/15/71		11/6/71	Death from pyæmia & pulmonary embolism. In the necropsy 10 hours after death (in situ) the clot the lungs were found complete perforating. The Rt heart was occupied by a large fibrinous clot extending from the auricle to the ramus of the pulmonary artery. In the left ventricle was found a thrombus and to be an abscess. After living failed, he came to the West Hospital where the tumour was punctured & some venous blood let out. On the next day the tumour was thoroughly examined by Dr. Haygarth who found it was an aneurysm & made an incision, turned out the blood-clot, then a great deal of arterial blood came out & then it was resolved to remove him to the Hospital where the above-mentioned incision was extended both upwards & downwards to about seven inches & the artery was found with a small hole on its anterior surface, getting out blood constantly. Both the ends of the artery were tied by strong ligatures & four other small blood vessels were secured. The anastomotic circulation was established without any trouble by the third day of the operation since when the temperature of the limbs continued to be higher by one degree than the opposite. On the third day of the operation, both the ligatures came out & there was bleeding & consequently the ligatures were reapplied. On the fifth day the lower ligature came off again & was tied for the third time. He was suddenly taken ill with diarrhoea on the fifth day of the operation, which became more & more & died with symptoms of pulmonary embolism.	The patient states that about five months ago, he accidentally struck his thigh at its base, striking against a strong bar of iron that was projecting from some work. He noticed some pain at the time but continued work. 12 hours were after the accident when the lower end of the thigh suddenly swelled accompanied with severe throbbing pain at that spot & numbness of the leg. He kept him awake for several nights. From this time he placed himself under regular medical treatment and applied different sorts of embrocations & leeches etc. suspecting it was found a tumour and to be an abscess. After living failed, he came to the West Hospital where the tumour was punctured & some venous blood let out. On the next day the tumour was thoroughly examined by Dr. Haygarth who found it was an aneurysm & made an incision, turned out the blood-clot, then a great deal of arterial blood came out & then it was resolved to remove him to the Hospital where the above-mentioned incision was extended both upwards & downwards to about seven inches & the artery was found with a small hole on its anterior surface, getting out blood constantly. Both the ends of the artery were tied by strong ligatures & four other small blood vessels were secured. The anastomotic circulation was established without any trouble by the third day of the operation since when the temperature of the limbs continued to be higher by one degree than the opposite. On the third day of the operation, both the ligatures came out & there was bleeding & consequently the ligatures were reapplied. On the fifth day the lower ligature came off again & was tied for the third time. He was suddenly taken ill with diarrhoea on the fifth day of the operation, which became more & more & died with symptoms of pulmonary embolism.
14/8/71	28. 8. 71		Cured with a little trouble in the morning after being only left.	Internal Haemorrhoid of 9 or 10 years, & standing in about the morning after being only left. The patient gave good deal of trouble. Says that he was subjected to inflammation of the rectum. The Haemorrhoids were tied and or chloroform & the patient continued doing well.



Date of Admission	Name	Sex	Age	Occupation	Country	Disease	Operation
28 <sup>th</sup> July 57	Shait Saluak	M	30	Farmer	Bengalee	Madura Foot	Lymce's Amputation at the ankle

9. 8. 71	Hajeer Ibrahim	M	52	Brick	Persian	Lagimal Hernia oblique (Right)	Operation for Radical Cure by plugs and ligature
----------	----------------	---	----	-------	---------	--------------------------------	--



Date of Operation	Date of Discharge	Date of Death	Result or cause of Death	Remarks
13 <sup>th</sup> Aug.	24/8/71		Left the hospital with the wound completely healed and pretty good stump	<p>This was a genuine case of <i>trycetoma</i>. The disease commenced about four months ago from a corn produced by a foreign body which happened to lodge in the sole of the right foot. The corn inflamed and suppurated leaving a large ulcer to heal by granulation. From that time sinuses leading into the foot hole from dorsal and plantar aspects made their appearance. Sinuses of never having had seen any black discharge coming from those sinuses. The foot swelled to a good big size but the swelling did not extend above the ankle. It measured 13 inches while the patient was admitted. After which it began to grow so rapidly that it attained the size of 15 inches within a fortnight. The patient was very pale &amp; healthy man. The foot was removed at the ankle by Syme's amputation after which the lower flap was found diseased. Consequently much part of it was sliced off. The patient lost a good deal of blood and about 5 ligatures were applied. Second day after the operation he was suddenly attacked with fever and a large portion of the lower flap, sloughed off from want of nutrition.</p>

18-8-71	25-9-71	Discharged with the hernia well supported by the above the external abdominal ring		<p>Admitted with Inguinal Hernia of 8 years standing, said to have brought on by a severe fit of Cough. The ring was big enough to admit two fingers. The Hernia was as big as a man's fist. Never Strangulated. The patient was operated under Chloroform and the plugs were removed after the fifth day of operation. The patient doing well since then.</p>
---------	---------	--	--	--



Date of Admission	Name	Sex	Age	Occupation	Country	Disease	Operation
26. 8. 71	59. Radha Kanto	ma	80	None	Bengals	Traumatic stricture.	Dilatation by Hodge's large instrument and No. 8. 9. Catheter passed.

7-9-71.	60 John Lyons	m	47	Translator E. India		Stricture urethrae.	Dilatation by Hodge's instrument and No. 10 Catheter passed.
---------	---------------	---	----	---------------------	--	---------------------	--

13-9-71.	61 Manick Ch. Bose	m	45	Broker	Bengals	Religuo long. Urethra Right. Strangulated.	Operation for strangulated Urethra without opening the Sac.
----------	--------------------	---	----	--------	---------	--	---



Date of Operation	Date of Discharge	Date of Death	Result or cause of Death	Remarks
26-8-71	17-1-72		Discharged while a No 12 catheter could be passed into the bladder and the wound almost closed	Disease of 4 months duration. Caused by a Buffalo's horn which was thrust in the inner aspect of the thigh at its upper part causing laceration of the urethra about 1 1/2 in. The urine used to come through the wound. A No 3 sound was passed into the bladder without difficulty. There existed a false passage from the prostatic end of the instrument outside from which good deal of purulent discharge comes out every day. The urine now partly comes out through the natural passage but mostly through the wound.
	23-9-71		Discharged at his own request and as so cannot be cured as easily hoped	Disease of 5 years standing resulted from gonorrhoea 15 years back. A No 3 sound was introduced with much difficulty. Had severe retention of urine. There was an abscess in the Perineum which burst off itself and left sinuous things which urine comes out in drops. Most of the urine comes through the natural passage.
13-9-71	13/12/71		Discharged cured as far as the obstruction is concerned but any attempt for the cure of radical cure was 15 years. It was Strangulated once before thought useless since then when reduced by cold and taxis; but this was so much delayed as to time all the means of reduction having give way to the gut which failed. Operation of Herniotomy was a good time was put on.	Came in with symptoms of Strangulation of 7 hours duration. The patient says that he is suffering from a Hernia for the last 15 years. It was Strangulated once before thought useless since then when reduced by cold and taxis; but this was so much delayed as to time all the means of reduction having give way to the gut which failed. Operation of Herniotomy was performed under Chloroform. The Stricture was found on the External abdominal Ring formed mostly by intercolumnar and Cremasteric fasciae. He failed during the operation. Consequently Stimulants and nourishing enemata were administered. The patient revived after a while and since he is doing well.



Date of Admission	Name	Sex	Age	Occupation	Country	Disease	Operation
21-5-71	62. Poghoo	M	47	Booly	Hindustan	Inflammation of the Elbow Joint (supp.)	Actual cautery.

21-7-71	63. Pori Khit	M	30	Farmer	Bengal	Fibro Cystic Swollen in the right popliteal space.	Excision
---------	---------------	---	----	--------	--------	--	----------



Date of Operation	Date of Discharge	Date of Death	Result or cause of Death	Remarks
12-9-71	23-10-71		discharged with a good deal of motion of the elbow joint	The patient was admitted with acute inflammation of the right Elbow joint. Said to have been caused by a blow which accidentally struck at the elbow. On admission it was put on an angular splint which relieved the pain to a certain extent but the deep seated pain attended with fraying never left him. Under these conditions hot iron were applied longitudi- nally on the outer and anterior aspect of the joint under Chloroform. Since then the pain is at once gone and the patient improving.
7-9-71	R			<p>Was admitted with a large tumour in the Popliteal space extending upwards to about 3 inches in the posterior aspect of the thigh. The popliteal vessels and nerves were free from pressure. The tumour was quite movable and measured about 14 inches in Circumference with the limb.</p> <p>After the removal of the tumour the wound was healing very rapidly but in the mean- time his knee-joint inflamed which was tapped by a small trocar and about 20 ounces of thick greenish- colored fluid let out. After tapping the wound was dressed with Chloroform and Gutta serena and the inflammation gradually subsided. About a month ago the tumour was found growing again. A long longitudinal incision was made from the base of the popliteal space extending upwards into the thigh. On putting a bid under microscope it was found distinctly to be of an albugi- naceous nature.</p> <p>The father of the patient states that there had been a small swelling on the outer side of the knee-joint since his birth: that was operated by a native Mobiray about 3 years ago. Since then it has slowly enlarged and acquired the present size within an year and half. The patient was a healthy looking when he was admitted. A long longitudinal incision was made extending from the thigh along the pop- liteal space to within 2 inches of the posterior aspect of the leg. And the tumour was dissected out. There was a very little bleeding at the time. About 18 days after were applied. The tumour weighed 2lb 6oz. The wound was dressed antiseptically and the patient is doing well.</p>



Date of Admission	Name	Sex	Age	Occupation	Country	Disease	Operation
20-9-71	Mr Noor Ally	M	22	Cooley	Bengali	Scrotal Tumour	Excision
18-9-71	65 - Henry Gonsalves	M	52	Writer	E. India	Epithelioma of the Penis	Amputation of the Penis by Eraseur.
1-10-71	65 - Shaik Nassim	M	40	Shepherd	Bengali	Stricture (traumatic)	Perineal Section



Date of Operation	Date of Discharge	Date of Death	Result or cause of Death	Remarks
20-9-71	14-1-72		Cured	The patient states that the disease commenced from a hydrocele about 6 years ago. The hydrocele was tapped twice but not injected. The scrotum gradually became thicker and attained the size of a coconut. The operation was performed immediately after admission. There were hydroceles on both sides. The parts were so vascular that about 53 ligatures were required. The patient was never subject to periodical fever. Tumour weighed 3lb. 9oz.
4-10-71	9/11/71		Left the hospital when the wound was healed	This was a genuine case of Epithelioma began about 18 months ago with a small pimple on the inner surface of the Prepuce which ulcerating left a rapidly increasing sore. The ulcer was large, dense, irregular sore. Covered with granular whitish bodies like lumps. Involving whole of the Penis at its anterior surface. It used to bleed at the slightest touch and discharge a foetid matter. Denies of ever having had syphilis. The lymphatic glands in the groin were not affected. General health being pretty good. Amputation of the Penis at the Root was performed by the Craseur without any bleeding. On placing some portion of diseased structure under microscope. it was found to be infiltrated with granular matter.
2-10-71	14/11/71	C.	Absconded	The patient states that about 15 years ago - a piece of Bamboo accidentally penetrated the Perineum and lacerated the Urethra. Since then the urine was flowing through both the ways. He came in with dribbling of urine and was diagnosed of bladder. A catheter was passed with great difficulty. On the following morning



Date of Admission	Name	Sex	Age	Occupation	Country	Disease	Operation
28-9-70	66 Summons	40 m	Cooley	Beazale	Simple disunited fracture of the R. thigh	Resection	
11/10/71	67 Grawski	40 m	Prue	hangalia	Contused wound on the tip of left index finger	Amputation at the second joint of the index finger under chloroform	



Date of  
Operation

Date of  
Discharge

Date of  
Death

Result or cause of Death

Remarks

The peniculum was divided on a Syme's  
pinned Staff. The ureters was found  
hard and cutting like potatoes. S. shaped  
tube was introduced and kept in 48 hours  
there was very little bleeding at the time  
or subsequent to the operation. No II  
Catheter Can be easily passed now and  
the patient doing well.

11/10/71

This Was a case of simple fracture  
of the thigh bone - produced by being  
knocked down by a Carriage. Within  
4 weeks the fracture united but the  
limb remained flexible and soft. The  
thigh was put on a starch Bandage -  
the ends of the bone were rubbed against  
each other - Electric Currents were tried  
but to no effect. At last resection  
of the Femur was performed under  
Chloroform. A longitudinal incision  
was made along the outer aspect of  
the thigh in its middle and the end  
broken ends of the bone were found  
overriding each other and covered with  
muscular fibres. The soft parts ha-  
ving carefully dissected - an inch &  
half of the upper and 2 inches of the  
lower ends were cut out by bone  
nippers & saw. The ends of the bones  
were then brought in apposition and  
the limb put on a long Splint - There  
was profuse bleeding at the time - and  
hence six ligatures were required - The  
wound was dressed antiseptically.

12-10-71

10/14/71 Cured

Patient States That about 6-12 days ago  
he received a small superficial cut  
on the tip of the left index finger, which  
was now almost cicatrized.



Date of Admission	Name	Sex	Age	Occupation	Country	Disease	Operation
7-7-71	J. G. Mallins	m	41	Head Ree- mains in Cage (Dph)	East Sea	Scrotal Tumour	Excision
9-10-71	J. MacGowan	m	33	Sailor Irish		Oblique inguino- scrotal Hernia (Rt)	Radical Cure by ligatures



Date of Operation	Date of Discharge	Date of Death	Result or cause of Death	Remarks
				<p>About 6 days ago he noticed pain in his back &amp; neck for which he applied all sorts of Quack medicines. But suddenly at 11 o'clock yesterday he began to get regular tetanic fits. This morning with the intention of removing the irritation, amputation under chloroform was performed and the patient being well since then.</p>
20-10-71	22/10/71		Death from exhaustion. No Post mortem was allowed	<p>Came in with Scrotal Tumour of 5 years standing which commenced with double Hydrocele. Each of the Hydrocele was tapped and injected for 5 times. On the 5th day the right Hydrocele inflamed and suppurated. The pus was let out by a hired Cat Man and he came in with a sinus leading into the sac of the Abscess and discharging profusely. The Tumour was as big as an adult's head. Was subject to periodical fever when the Tumour used to increase and become painful. The patient's health being bad he was detained &amp; treated for a long time to mend his Constitution. The operation of excision was performed under Chloroform. On making an incision on the right side the testicle was found quite disorganised and consequently removed. On the left there was very little Hydrocele but healthy. The patient bled very freely and about 20 ligatures applied. The Tumour weighed 3 lbs 6 oz.</p>
20-10-71	11/11/71		Discharged with the Urinary wall saphagated above the external abdominal ring.	<p>Oblique inguinal Hernia of 12 years standing came on after an accident. The hernia was never strangulated. The right testicle was atrophied and seated above the Poupart's Ligament. Operation for radical Cure was performed under Chloroform. The plug was removed on the 4th day and the patient improving.</p>



Date of Admission	Name	Sex	Age	Occupation	Country	Disease	Operation
15-8-71	Radha Kanta	m	30	House	Bengal	Traumatic Fracture	Spinal Section
2-10-71	William Trauer	m	28	Seaman	American	Contused wound communicating with the second joint of the right Index finger -	Amputation of the Index finger at the 2 <sup>nd</sup> Joint by Antero-Posterior flaps.
23-10-71	Shaik Sapally	m	30	Cooly	Bengal	Compound fracture of the 2 <sup>nd</sup> phalanx of the left great toe.	Amputation of the 2 <sup>nd</sup> phalanx and part of the toe.



Date of Operation	Date of Discharge	Date of Death	Result or cause of Death	Remarks
20-10-71	1.1.72		Discharge at his own request	<p>See p 57</p> <p>Disease of about 4 months standing. Caused by a buffalo's horn which accidentally penetrated into the inner aspect of his thigh and the most probably ruptured the Pelvic fasciae. The stricture was dilated by Holt's instrument before but notwithstanding that the urine used to flow through the Sinus in the thigh as well as in the Perineum. He could be passed easily after the dilatation. The Perineum was divided on a big sized propped staff and S shaped tube put in. After 48 hours, the tube was taken out and the urine commenced to flow through the Sinus in the Perineum. Consequently the tube was re-introduced and kept in until the Sinus closed. The Sinus in the thigh were slit up on a director and left to heal by granulation. Had retention of urine before admission which was relieved by a Catheter outside.</p>
25-10-71	1/11/71		Left the hospital of his own accord while the wound was not healed quite	<p>Admitted with a wound on the dorsal aspect of the Index finger at its second joint. Caused by a blow. On examination the wound was found communicating with the joint which was quite disorganized and inflamed. Every means to produce Ankylosis was tried but to no effect. Consequently the finger was removed at the 2nd joint under Chloroform. On ligature was applied.</p>
26-10-71	29/11/71		Discharged with a good stump	<p>Came in with Compound Comminuted fracture of the 2nd phalanx of the left great toe. Caused by a Cornish wheel which passed over it. The wound was stitched up and the toe put up on a splint. But on the next day the toe was found gangrenous and consequently removed under Chloroform.</p>

The remaining portion of the first phalanx was removed while the patient was an inmate with Salivary glandular infection on the 29.11.1871



Date of Admission	Name	Sex	Age	Occupation	Country	Disease	Operation
23-10-71	73. Gomes Quacha	Boys	53	Clerk	Angola	Stricture urethrae	Perineal Section

30-10-71	74. Francis Mander	an	14	Sailor	English	Badly united fracture of the left thigh	Forcible extension Broken again
----------	--------------------	----	----	--------	---------	---	------------------------------------



Date of Operation	Date of Discharge	Date of Death	Result or cause of Death	Remarks
27-10-71	13-11-71	Died from Uræmia. As Post-mortem was allowed		Suffering from Stricture for a year & half. The disease began with Gonorrhoea which lasted for 6 years. In the last February, he was attacked with fever and swelling in the perineum & most of the penis came on spontaneously. Had retention of urine outside, which was released by catheter. Urine went & flow both by the sinusses & the natural passage. On admission attempt to pass No. 7 Catheter was made but without success. The perineum & scrotum to the slightest disturbance. The Perineum was divided in a ground staff equal to the size of No. 2 round under Chloroform & I shaped tube into desired & kept in until the sinusses closed. The patient held pretty freely & was stopped by cold & pressure.
31-10-71	22/11/71	Left the hospital with a quite straight thigh and the leg quite equal		This was a case of badly united fracture straight thigh and the leg of 8 weeks standing. The accident occurred while a loa and fractured the left thigh in two places; one at its lower third, the other at the middle. These fractures not being regularly reduced united in a obtuse angle with its condylar directed upwards. On admission the patient was placed under the influence of Chloroform the thigh was broken again & put up in a long splint. Since then the legs are nearly of equal length.



Date of Admission	Name	Sex	Age	Occupation	Country	Disease	Operation
30-10-17	75 Prosenno	F	25	Prostitute	Bengal	Discharge of blood from vagina	Laid open on the left side
11/11/71	70 Fakir Chandra	M	70	Merchant	Bengal	Left oblique inguinal hernia strangulated	Operation for strangulated hernia without opening the sac.
25/10/71	77 Pray	F	30	Midwife	Bengal	Cancer of the breast	Excision of the breast



Date of Operation	Date of Discharge	Date of Death	Result or cause of Death	Remarks
5-11-71			Cured	The patient is suffering from external piles for a month since. The fistulae communicating with the rectum & vagina commenced with a pimple on the internal surface of the left labium majora which burst & filled of itself leaving a sinus mentioned above. The fistulae was cut through & left open to be healed by granulation.
11/14/71		23/11/71	Died from gangrene of the Scrotum which was having for the last three months. The hernia used to be brought on by exertion. It descended and go up of itself but this time by making the patient it did not go up for the last 24 hours. There was a large clot in the sac. The symptoms of strangulation were all the symptoms of strangulation found. Coagula present. Taxis, cold and all the other there was a large clot in the sac. Of reduction having failed the right Coarctation of tuberosity operation was performed under chloroform. Evidently antihernia. The structure was found at the external Small portion of ilium abdominal ring, the hernia was not sitting. Was found gangrenous. Opening the sac, which however proved irreducible and the patient is doing well since then.	Has been suffering from inguinal hernia. The hernia used to be brought on by exertion. It descended and go up of itself but this time by making the patient it did not go up for the last 24 hours. There was a large clot in the sac. The symptoms of strangulation were all the symptoms of strangulation found. Coagula present. Taxis, cold and all the other there was a large clot in the sac. Of reduction having failed the right Coarctation of tuberosity operation was performed under chloroform. Evidently antihernia. The structure was found at the external Small portion of ilium abdominal ring, the hernia was not sitting. Was found gangrenous. Opening the sac, which however proved irreducible and the patient is doing well since then.
12/14/71		18/12/71	Died from gangrene of the Axilla and arm.	The patient states that the disease began about a year ago from a small hard nodular swelling on the upper part of her left breast. The swelling, she says, came on itself. It was never painful previous to the last eight months, since which period it has been growing rapidly and has involved the whole of the mamma and also the axillary glands. No symptoms of cancer had been present excepting the pain and the indurated nipple, which appeared about a month ago. It was of the size of a large apple. The tumor was removed under chloroform by two curved incisions, one on each side of the affected mamma. There



Date of Admission	Name	Sex	Age	Occupation	Country	Disease	Operation
10/11/71	78 Ganza Ehen	m	52	Farmer	Bengal	vesical calculus	lateral operation for Lithotomy
20/9/71	79 Bueko Kati	m	40	Farmer	Bengal	Prostat. Tumour <sup>173</sup>	Excision



Date of Operation	Date of Discharge	Date of Death	Result or cause of Death	Remarks
				incisions were extended upwards and outwards into the axilla and the affected glands were very carefully dissected out. The patient bled pretty freely and about 25 ligatures were applied. The loose cellular tissue of the axilla, several large arterio-venous glands and diseased nodules were discovered. These being situated almost immediately over the situation of the axillary vessels and required very careful dissection.
11/4/71	8/12/71		Discharged with the wound quite healed up.	Has been suffering from symptoms of stone in the bladder for the last 15 months - complained of pain during micturition only for the last two months - never passed any gravel or blood which is said to be mixed with blood. The calculus was an oval one most probably of the acid weighing 3 1/2 grains. The wound after operation bled freely which was stopped by pressure alone.
13/11/71				The patient was admitted with scrofula tumour of five years standing. The disease began with hydrocele which was tapped three or four times and water drawn out. For the last three years the tumour was growing rapidly and attained the size of an adult's head. He was subjected to periodical attacks of fever when the tumour used to be painful was admitted in a very weak state of health from profuse discharge from the tumour at the same time it was full of bristles. His <sup>health</sup> body improved under treatment & was operated under chloroform this morning. The parts being very vascular about 25 ligatures were required. The tumour weighed 12 lb 5 ounces. There was hydrocele of both sides present.



Date of Admission	Name	Sex	Age	Occupation	Country	Disease	Operation
11/10/71	Jhonesh	Male	40	Boysen	Bengala	Relieve Traumatic	Amputation of the last Phalanx of the left index finger.
2/10/71	Am Chand Ali	M	41	Scrubber	Bengala	Elephantiasis of the scrotum & penis <sup>176</sup>	Excision
2/10/71	W. H. Wright	M	43	Black	East India	Fracture Clavicle	Terrible Chilblain fracture by Holt's large cushion



Date of Operation	Date of Discharge	Date of Death	Result or cause of Death	Remarks
13/10/71	19/10/71		Cure	The patient was admitted with a small cicatrix on the tip of the left index finger which was supposed to be the exciting cause of the disease. Therefore the finger was removed by anterior & posterior flaps & the patient improved remarkably after that.
20/10/71		20/10/71	Died from shock. on making the P. M. Ex.	<p>During the P. M. Examination the tumour was found to be firm, soft &amp; fatty also the organs healthy.</p> <p>Was admitted on the 2<sup>nd</sup> Oct. 1871 with a large hip sized Scrotal tumour of 14 years standing. The tumour he said commenced with Double Hydrocele which was tapped 4 times &amp; fluid let out. He was subjected to periodical attacks of fever when the tumour used to become painful &amp; increased in size. In the last 4 years it was growing very rapidly. The patient was anemic &amp; emaciated &amp; like admitted. But he improved under treatment &amp; then the tumour was removed under chloroform by the ordinary method draining the testicles. There was hydrocele on both sides. The patient had pretty fully forty ligatures were applied. The man with the tumour weighed 16 stone 3 lbs. The tumour after removal weighed 75 lbs. The patient became very low on the table &amp; remained under stimulants &amp; Galvanism, but afterwards he gradually sank and died within 48 hours after Operation, notwithstanding the stimulants that were very much pushed. The body after death weighed 7 stone 10 lbs.</p>
28/11/71	5/12/71		Relieved.	Admitted with stricture between 14 years standing; had gonorrhea about 14 years ago. passed water in thin streams sometimes in drops. At times stops altogether. Had retention of urine 3 months ago which was relieved by a Catheter catheter. The stricture was a very tight one, so that no. 3 Catheter was passed with great difficulty. On the next morning the catheter was retained by Halls' instrument & was used sound passed easily into the bladder. After the operation he began to pass water in a good stream.



Date of Admission	Name	Sex	Age	Occupation	Country	Disease	Operation
26/1/71	1800 Benomally	m	20	Heptah	Bengal	Stricture of the Urethra Right with stone & bladder removed by a finger. Test	Dissected portions of testis

1/12/71	1801 Longuevalhatten	m	30	Black	Bengal	Elephantiasis of the Scrotum.	Excision
---------	----------------------	---	----	-------	--------	----------------------------------	----------



Date of Operation Discharge Death

Result or cause of Death

Remarks

4/12/79

This patient was admitted with sinuses all around the ankle joint leading to disunion of bone at their bottom. The disease began about 8 months ago with swelling of the ankle joint which came on spontaneously. After a few days he had an attack of fever which was followed by suppuration in and around the joint. The pus was let out by a Native doctor. Since then the wound healed leaving the sinuses above mentioned. There were sinuses along the joint leading into disunion of the bone. Had syphilis about 1 year & 2 of age cured by Native drugs. The ankle joint is present is swollen, hard, cold & ankylosed. An incision about 4 or 5 inches long was made on the inner aspect of the leg and extending down to the foot. Disunion of bone were removed by force. The part healed pretty good and the patient is doing well since then.

2/12/79

He was admitted with abscesses in the scrota of 15 years standing. The disease began with inflammation of one of the testicles attended with fever. After a while inflammation subsided but the swelling remained. The tumour was of the size of a child's head. He was subjected to periods of attacks of fever when the tumour would grow but very slowly. He is an inhabitant of Burmah which is a very malarious province. The tumour was removed under Chloroform & about 22 ligatures were applied. The tumour weighed about 14 lb. after operation. There was hydrocele on both sides present.



Date of Admission	Name	Sex	Age	Occupation	Country	Disease	Operation
6/10/11	Mr. Jomah Allah	M	40	Farmer	Bagdad	Stricture Urthrae	Forcible dilatation of the urethra by Holt's instrument

13/10/11	Mr. Luckha	M	Small	None	Bagdad	Cystic tumour attached to the lower part of the occipital bone a little removed from the right of median line.	Ligatures were applied to the pedicle & the tumour removed.
----------	------------	---	-------	------	--------	--	---



Date of Operation	Date of Discharge	Date of Death	Result or cause of Death	Remarks
7/13/71	27/12/71		Left the hospital when 40 cm. Catheter could be passed easily.	Admitted with stricture of ureters of a month's standing. Had gonorrhea about 2 months ago which was treated by a native medicine. Saw urine pass in the stream sometimes in drops. Never had actual retention of urine except on one occasion - when a large urethral calculus obstructed the passage. The stricture was a very tight one, no instrument could be passed in the bladder. Consequently the ureters were dilated by Holt's instrument & then No. 10 Catheter was passed.
12/12/71	12/12/71		Death from Tetanus	Admitted with cystic tumor of 2 months standing. Attached to the lower part of the occipital bone a little to the right of its median line by a pedicle about 1 cm. long. The mother states that since the birth of the child there was a small soft fluctuating swelling on the above mentioned situation that has grown & attained the size of an ordinary ball point within 2 months. After Admission the tumor was thoroughly examined & suspected to have communication with the brain. It was tapped and about 8 gms of straw colored fluid was obtained which on analysis was found to contain much of albumen, no sugar & trace of Phosphates. This analysis at once removed the suspicion. The tumor refilled & became larger than the original size within a month. The child being too small to bear the operation it was kept in the Hospital & nursed. Under treatment the child improved rapidly & the tumor was removed under Chloroform. Two ligatures were applied on the pedicle by making superficial cuts to give firm hold to the ligatures. Then the pedicle was cut in the middle. The child lost very little blood & is doing well since the operation. The tumor with its pedicle weighed 1 lb. 9 gms. & the fluid alone measured 12 gms.



Date of Admission	Name	Sex	Age	Occupation	Country	Disease	Operation
1/6/71	87 Roy Lal Chandra	M	24	Blacksmith	Bengali	Spontaneous fungous	Amputation at the upper third of the leg by a motor for a circular

15/12/71	88	Minors	M	28	Book	Bengali	Hydrocele (right)	Tappes and injection with Trichloro of Iodine
----------	----	--------	---	----	------	---------	-------------------	---

13/12/71	89	Fr. Fox	M	28	(Book)	Bengali	Hydrocele (double)	Tappes and injection with Trichloro of Iodine
----------	----	---------	---	----	--------	---------	--------------------	---



Date of Operation	Date of Discharge	Date of Death	Result or cause of Death	Remarks
10/12/71				<p>Says that about 5 months ago he had an attack of remittent fever, which was followed by gangrene of the right foot. Within a few days the foot sloughed off at the ankle joint leaving a cancrulous hole healed by granulation. While admitted there were small bits of ulcers on the stump &amp; the knee joint - and he found Anchylosed evidently from disease. His health being poor &amp; as it was kept under treatment &amp; gr. of Chlor. of Lime &amp; Iron were ordered to be taken 3 times a day. Gradually he improved in health and the leg was amputated a little above the knee under Chloroform. The bones were found so much diseased &amp; softened that the saw went through while an attempt was made to make an off-cut. Before the commencement of the operation the surrounding tendons were divided by two long knives to straighten the leg. He lost very little blood &amp; about 7 ligatures were applied.</p>
16/12/71	24/12/71		Relieved	<p>Admitted with hydrocele of right side of 6 yrs duration. It came on spontaneously. Its hereditary tendency can be traced and was not subjected to periodical attacks of fever. The hydrocele was tapped and ten ounces of clear straw-colored fluid let out. The sac was injected with four drachms of solution of Iodine.</p>
17/1/72	30/1/72		Relieved	<p>Came in with hydrocele of four months duration. The disease commenced from an injury to the testicle. He was never subjected to periodical attacks of fever but both testicles were painful at times. Its hereditary tendency can be traced. The right hydrocele was tapped and an ounce of straw-colored fluid was let out. The sac was injected with 2 drachms of Iodine. The left one was not injected.</p>



Date of Admission	Name	Sex	Age	Occupation	Country	Disease	Operation
4/12/71	Gunga Saran	m	41	merchant	Bengal	Ephentiasis of the Prothium <sup>175</sup>	Excision
18/4/71	Chunderkeshun	m	50	Siccar	Bengal	Lacerated wound on the posterior aspect left forearm at its of the left forearm laceration performed leading to traumatic by antero-posterior tetanus.	Flaps and Chloroform



Date of Operation	Date of Discharge	Date of Death	Result or cause of Death	Remarks
17/12/71				<p>Has admitted with elephantiasis of the scrotum and perine of 4 years duration. The disease began with inflammation of the testis attended with pain and swelling. A few days after the inflammation subsided but swelling remained as it was. Since then the tumour is growing. It is at present as big as an adult's head. He is subject to periodical attacks of fever (once a month) when the tumour used to become inflamed and become painful. Has syphilis a few years previous to the commencement of the disease. The tumour was removed in the ordinary way under chloroform. The parts were very vascular. Consequently 20 ligatures were applied. The tumour after operation weighed 6 lbs 6 ounces. There were hydatids of both sides present.</p>

24/12/71	27/12/71	Death from exhaustion	Admitted with a large lacerated wound. No post-mortem was allowed.	<p>Caused by being trodden down by a carriage on the outer and posterior aspect of the left forearm and fracture of distal clavicle. The wound was as big as a dollar and covered with superficial slough. On the 23<sup>rd</sup> of December he was suddenly attacked with tetanic spasms and the parts around the wound were inflamed and swollen. Consequently it was thought advisable to remove the wounded limb. On the same day the limb was amputated under chloroform. 12 ligatures were applied. On the next day the patient improved a little and tetanus abated. Towards evening he began to sink and died of exhaustion. The tetanus on the whole was much better when he died.</p>
----------	----------	-----------------------	--	--



Date of Admission	Name	Sex	Age	Occupation	Country	Disease	Operation
22/12/71	72 Doyal	m	37	Cook	Bengal	Fibrosis of the tarsal bone of the second toe	The diseased bone removed by a longitudinal incision
11/12/71	73 Naithe Prasad	m	28	Sillar	Bengal	Elephantiasis <sup>176</sup> of the scrotum	Excision
22/12/71	94 Kaya Bahary	m	10	none	Bengal	Badly united fracture of right thigh	Refracture of bone



Date of Operation	Date of Discharge	Date of Death	Result or cause of Death	Remarks
23/12/71				Admitted with a fungating ulcer on the root of the second toe of a horse and a half standing. The disease began as a small pimple on the <sup>root</sup> of the second toe which broke out and assumed the fungous size within a very short time. On admission the second and first phalanges were found necrotic and quite denuded of their periosteum though not evidently entirely disorganized. The diseased bones were removed under chloroform. As history of injury to the diseased toe can be traced but <sup>has</sup> syphilis sometimes previous to commencement of the disease for which he was treated.
29/12/71				Admitted with elephantiasis of the scrotum and prepuce of 16 years duration. The tumour was as big as a child's head. It was growing very rapidly for the last 7 months with fever which he was subject to. The disease began at first with hydrocele. Had syphilis about 2 years ago. His father has the same disease. The tumour was operated in the ordinary way under chloroform and 20 ligatures were applied. The tumour after removal weighed 2 lbs 6 ounces. There was hydrocele of the right side only.
22/12/71	19-1-72		Cured	Admitted with badly united fractures of 22 days' standing. It might have been caused by a fall from a height of 2 feet. The fracture united in an obtuse angle with its apex directed outwards. The right leg was shorter than the left by $2\frac{1}{2}$ inches. On admission the thigh was retracted and put up on long splint.



Date of Admission	Name	Sex	Age	Occupation	Country	Disease	Operation
-------------------	------	-----	-----	------------	---------	---------	-----------

Yearly abstract of surgical operations in the 18 Surgical Ward of the Medical College Hospital for the year 1871

Number of Operations	Names of Operation	Number	Cured	Relieved	Wounds in the Hospital	Died	Caecum	Cervix	Pyemia	Phlegm	Ischemia	Ischemia	Shock	Exhaustion	Other Causes	Remarks
1	Amputation of leg below the knee	4	2	"	"	2	"	"	"	"	2	"	"	"	"	"
2	by Ligament method	3	2	"	"	1	"	1	"	"	"	"	"	"	"	"
3	Amputation of Arm	1	"	"	"	1	"	"	"	"	"	"	1	"	"	"
4	" of the finger	5	4	1	"	"	"	"	"	"	"	"	"	"	"	"
5	" of the Toe	2	2	"	"	"	"	"	"	"	"	"	"	"	"	"
6	" of the Penis	3	3	"	"	"	"	"	"	"	"	"	"	"	"	"
7	Actual Caustic to the spine	3	1	2	"	"	"	"	"	"	"	"	"	"	"	"
8	" of the spine	1	1	"	"	"	"	"	"	"	"	"	"	"	"	"
9	Badly united fracture	2	1	1	"	"	"	"	"	"	"	"	"	"	"	"
10	Dilatation by Adams Instrument	5	3	2	"	"	"	"	"	"	"	"	"	"	"	"
11	Actual Caustic to the throat	1	1	"	"	"	"	"	"	"	"	"	"	"	"	"
12	Incision of Hygroma	1	1	"	"	"	"	"	"	"	"	"	"	"	"	"
13	Incision of Hemorrhoid	3	2	1	"	"	"	"	"	"	"	"	"	"	"	"
14	Ligation of Femoral Artery	1	"	"	"	1	"	"	1	"	"	"	"	"	"	"
15	Removal of Tumor	8	6	"	"	2	"	"	"	"	1	"	1	"	"	"
16	Median operation of Cystostomy	1	1	"	"	"	"	"	"	"	"	"	"	"	"	"
17	Relection	1	"	1	"	"	"	"	"	"	"	"	"	"	"	"
18	Perineal Section	12	10	"	"	2	"	1	"	"	"	"	"	"	1	"
19	Hydrocele	8	8	"	"	"	"	"	"	"	"	"	"	"	"	"
20	Cataract	7	7	"	"	"	"	"	"	"	"	"	"	"	"	"
21	Artificial Pupil	1	1	"	"	"	"	"	"	"	"	"	"	"	"	"
22	Cervical Tumor	13	11	"	"	2	"	"	"	"	"	"	1	1	"	"
23	Tracheotomy	2	1	"	"	1	"	"	"	"	"	"	"	"	1	"
24	Urethral Calculus	1	1	"	"	"	"	"	"	"	"	"	"	"	"	"
25	Radical Cure of Hernia	4	4	"	"	"	"	"	"	"	"	"	"	"	"	"
26	Strangulated Hernia	3	2	"	"	1	1	"	"	"	"	"	"	"	"	"
27	Fistula Anal	2	2	"	"	"	"	"	"	"	"	"	"	"	"	"
28	Plastic Operation	1	1	"	"	"	"	"	"	"	"	"	"	"	"	"
29	Dislocation of Hip joint	1	1	"	"	"	"	"	"	"	"	"	"	"	"	"
30	Hiac abscess	1	1	"	"	1	"	"	"	"	"	"	"	"	"	"
31	Fracture	1	1	"	"	"	"	"	"	"	"	"	"	"	"	"
Total number of operations		99	84	Totally Cured		15	Total number of deaths									

Agate from top of face incised into tumor on the nose



*Date of  
Operation*

*Date of  
Discharge*

*Date  
of  
Death*

*Result or cause of Death*

*Remarks*



Date of Admission	Name	Sex	Age	Occupation	Country	Disease	Operation
January 1872							
29-12-71	1 John Pogue	m	28	Collier	America	Laryngitis with intra-thoracic tumour (Encephaloid)	Tracheotomy
1-1-72	2 Gony	f	30	Maiddat	Bengal	Thigh Abscess (deep seated)	opened
5-1-72	3 Norma Churn	m	24	Carpenter	Bengal	Right inguinal abscess Bubon (Rosenbach)	Radical cure by Phys.



Date of Operation	Date of Discharge	Date of Death	Result or cause of Death	Remarks
2-1-72.		5-1-72	P.M. Examination 10 hrs. After death - On opening the chest a large circumscribed apple shaped encapsulated tumour was found occupying whole of the anterior mediastinum and pressing on the ascending & transverse portions of the Arch of the Aorta - Behind P. Arteries (Rt) Occurrent Laryngeal nerves and the Pharynx. There were condempments of the same substance of the free margin of the esophagus and the lower lobe of the liver. Both the lungs were emphysematous and congested posteriorly - other organs healthy.	Came in with Cough and difficulty of breathing of 12 months duration. The disease began with cold while working at Coal mines at Roseburg. Repeated attacks of fever for the last two months felled him down too much. After admission the vocal cords were found thickened and intensely congested - Resp. all over the chest was bronchial - and attended with mucous Rales. He was then troubled with fits of dyspnoea but on the second of January the fit was so severe that the opening of the trachea was thought to be advisable to give him relief. After the operation he was a little better but he suddenly died in a fit of dyspnoea notwithstanding all the precautions taken.
5-1-72.	25-1-72		Cured.	Came in with a large deep seated cyst above on the posterior aspect of the right thigh. said to have occurred spontaneously. No history of injury. The diseased thigh can be treated. The abscess was opened and about a pint of decomposed pus let out.
6-1-72.	30-1-72		Discharged with the hernia	Admitted with inguinal hernia (plus great well supported above the umbilication. used to come down in the scrotum only lately. The disease is said to have been brought on by a severe fit of cough; was never strangulated before. excepting on this occasion it remained in the scrotum for three hours. The urgent symptoms of strangulation being present - Ice and enema were used after which it was reduced by taxis. On the next day operation for radical cure was performed under chloroform and he is doing well.



Date of Admission	Name	Sex	Age	Occupation	Country	Disease	Operation
1.12.71	4 Peter Phear	m.	36	Seaman	India	Cleft nose Rip ala.	Plastic operation
7.1.72	5 Sham Churn	m.	30	Medical Officer Pratban	India	Fistula in ano with external haemorrhoids & ulcer in the Rectum	Fistula was slit up & internal haemorrhoids removed.
13.12.71	6 Nally Prassanna	m.	26	Print	Bengal	Elephantiasis of the Scrotum and penis	Excision



Date of Operation	Date of Discharge	Date of Death	Result or cause of Death	Remarks
6.1.72	22.1.72		Discharged with a pretty good nose	Came in with a triangular gap on the free margin of the left ala nasi. Result of being bitten by a man in 1837. He was under treatment for palpitation of the heart; afterwards when the general health improved he was placed under the influence of Chloroform and the edges of the above mentioned gap were paired and brought together by a horse hair. The wound united by the first intention and Sutures were cut off.
7.1.72	18.1.72	Relieved		Was admitted with fistula in ano & internal haemorrhoids of two years duration. The fistula is said to have resulted from an abscess in the neighbourhood of anus. The haemorrhoids he says came on themselves. After admission the fistula was slit up on a dissector and the Piles removed by Scissors. On examination with Speculum a good deal of purulent discharge was found coming the ulcers in the rectum which was ordered to be washed with Nitrate of Silver.
14.1.72				Came in with hypertrophied prepuce and scrotum of 16 months duration but growing rapidly for the last four months with pericircal attack of fever which he was subjected to. The penis was three times bigger than its natural size but the scrotum was not much involved. Had Syphilis about 3 years ago, followed by secondary symptoms and bubos. There was no lymphatic. The tumour was removed and phlores form. The parts around were very vascular and 12 ligatures were applied. The tumour after removal weighed 1 lb 6 ounces.



Date of Admission	Name	Sex	Age	Occupation	Country	Disease	Operation
29.12.71	7 Joseph Schepalick	m	30	Black	East Prussia	Hydrocele (left)	Ligature and injected

15.1.72	8 Abdollah	m	32	Merchant	Arabia	Internal hemorrhoids	Ligatures
---------	------------	---	----	----------	--------	----------------------	-----------

11/1/72	9 Haylach Chumra	m	25	Angler	Black	Elephantiasis of the extremities	Excision
---------	------------------	---	----	--------	-------	-------------------------------------	----------



Date of Operation	Date of Discharge	Date of Death	Result or cause of Death	Remarks
12.1.72				Is transferred from St. Luke's Bath to ward with a large fusiform hydrocele of 18 years standing. Says that it was growing rapidly for the last 4 years. No hereditary tendency can be traced, says that it came on spontaneously. He was never subjected to periodical attacks of fever. The hydrocele was tapped and two pints of straw-colored fluid let out and the sac injected with four drachms of Liniment of Iodine.
15.1.72	19.1.72		Relieved	Admitted with Intestinal bleeding piles of 18 years standing. Says that they were very troublesome for the last 2 years. The constant bleeding has broken down his constitution and reduced him to bones and skin. The piles commenced, he says, with common hemorrhoids. No hepatic complication can be traced. On introducing the anal speculum a large vessel was found pumping out from the outer wall of the Rectum which was drawn out by a Vallislini and tied and left to be sloughed itself.
24/1/72				Admitted with Elephantiasis of the scrotum & foreskin of 3 years standing. He claims commenced with fever about 4 years ago but was gaining rapidly in the last 8 months & obtained the size of a child's head. Had syphilis about 4 months ago. was never subjected to periodical attacks of fever. The testicles rather anæmic & thin. As the disease advanced his constitution improved. The tumour was removed by Chloroform in the ordinary way. The tumour at the removal weighed 16 lb. 2 oz. The parts around were very vascular. About 15 Ligatures were applied. There are little Hydradenæ on both sides.



Date of Admission	Name	Sex	Age	Occupation	Country	Disease	Operation
22/1/12	S. S. Humphrey	M.	45	Boatman	Kenya	Stricture urethrae	Excision by Haeblap instrument - no. 11. Urethra laid in the labium.
19.12.71	11 Shamos	M.	50	C. driver	Kenya	Spontaneous gangrene of the right hand after fever.	Amputation by Modified Circular method performed under Chlorform at middle third of forearm & the flaps brought together by stitches.



Date of Operation	Date of Discharge	Date of Death	Result or cause of Death	Remarks
24/1/72				<p>Admitted with stricture Urinary as a consequence of gonorrhoea which he suffered from about 20 years ago. was troubled much with constant Calls for Micturition. he used to pass urine in thin stream &amp; sometimes in drops but never had actual retention. This urine was mixed with blood-clots which caused some sometimes, after some time before the evacuation of the bladder.</p>
24.1.72				<p>Was admitted with sprain ancom Jangrene of right hand of 20 days duration. The disease began after fever on the dorsal aspect of the hand which gradually involving the whole hand excepting the little finger. The patient came in with the metacarpophalangeal articulation quite exposed &amp; the tummy around sloughing. Taken in fact was hanging with the thumb by sloughy tissues. His general health was much reduced by Diarrhoea &amp; Fever. Consequently he was kept under treatment for a long time. His health improved under treatment &amp; the hand was removed by amputation. The parts bled pretty freely - 15 ligatures were applied. The ulnar artery was found plugged &amp; did not bleed at all. The wound was dressed antiseptically on the 20th the dressing was removed &amp; the flaps found united by the first intention. There was a good deal of inflammation &amp; the flaps were found covered with small blots. On the 27th a small collection of matter was noticed between the anterior flap which was cut through &amp; matter let out.</p>



Date of Admission	Name	Sex	Age	Occupation	Country	Disease	Operation
1.9.71	12	Porikhit	M	30	Farmer	Bengal	Medullary cancer of the right popliteal space thigh at the junction of the middle with the upper third performed by transfexion by antero-posterior flaps

24.1.72	13	Dyam	M	31	Farmer	Bengal	Vesical Calculus Lateral operation of Lithotomy performed under Chloroform
---------	----	------	---	----	--------	--------	--



Date of Operation	Date of Discharge	Date of Death	Result or cause of Death	Remarks
26.1.72		30.1.72	P.M. Examination 24 hours after death. Opening fibre cystic tumour of the right pleural space the chest, the left heart about 3 months ago. While the wound was healing, was found firmly contracted rapidly the tumour was found recurring from right heart contained a large bottom of the pleural space. The tumour was elongated fibrous clot was distinctly lobulated & used to bleed to the extent of protruding from the slightest touch. It was growing rather rapidly to the ramification of the from the latter part of last December. The Pulmonary artery is deep substance of the tumour under microscopical Congestive prostatically fine examination was found composed of medullary Soft and fatty Kidney and cancer cells. The constant discharge of them spleen healthy. There was purulent matter & blood from the wound as well Secondary cancerous as the thigh reduced him gradually to bone deposits on the hypochondria skin. All attempts to regain his health was Liver, but superficial, tried but without any material effect. Further Bone looked healthy. The delay in surgical interference having thought flaps were found through hopeless amputation at the upper third was on their inner aspect performed. He lost very little blood. About 25 ligatures were applied. He is getting on pretty well after the operation.	See case 65 of 1871 for further information.
			Died from Cancerous Infiltration	

28.1.72				Has been suffering from symptoms of stone in the bladder for the last 3 years. Complained of pain during micturition only for the last 12 months. Passed a small gravel with urine, a long time previous to the beginning of the disease. The Calculus was of an oval shape, most probably lithic acid, coated with phosphate, weighing 3iv & gr vi. The wound, after operation bled profusely, on failing to stop the bleeding by ice, S. shaped tube was introduced into the bladder, and the wound plugged with lint.
---------	--	--	--	--



Date of Admission	Name	Sex	Age	Occupation	Country	Disease	Operation
24. 11. 71	14. Monomally	M.	28	Shepherd	Bengalee	Arthritis of the ankle joint with sinuses of the ankle, perforated all around it reaching under the sole of the foot. After dissection of the cavity of the joint a bony ankylosis was detected in the joint. Consequently the bone was sawn through.	Symes Amputation
29. 12. 71	18. Russick Lall Chatterjee	M.	43	Broker	Bengalee	Elephantiasis of the scrotum and perineum.	Excision



Date of Operation	Date of Discharge	Date of Death	Result or cause of Death	Remarks
28.1.72.				<p>This patient was operated on, about 2 months ago, for necrosis of the lower end of Tibia and Astragalus, with the intention of giving him a chance to recover with an artificial foot. To this standing, new sinuses began to appear all around the joint. On careful examination, the articular surfaces of the bones were found roughened. Constant discharge of a thin purulent fluid was reducing him rapidly. Consequently, to relieve him from exsufflation, the foot was removed at the ankle. Only 6 ligatures were required. The bone bled pretty freely. It was therefore, thought inadvisable to put up the flaps, which were slightly undermined, until the bleeding ceased. After 12 hours, they were put up, as they are doing well.</p>
4.2.72				<p>Has been admitted for Scrotal tumour of 4 years duration. The disease commenced with hydrocele which was tapped and injected. For the last 3 years the tumour has been growing rapidly and has attained the present size like that of an adult's head. It was subject to periodical attacks of fever when the tumour used to become painful and increase in size. Has got elephantiasis of the right fore-arm. The tumour was removed under Chloroform in the ordinary way. It weighed after operation 8 1/2 lbs., 8 ounces. The parts were very vascular and 30 thirty ligatures were required. There was hydrocele of both the sacs. The testicles were healthy.</p>











[illegible]



Date of  
Operation

Date of  
Discharge

Date  
of  
Death

Result or cause of Death

Remarks



[illegible]



*Date of  
Operation*

*Date of  
Discharge*

*Date  
of  
Death*

*Result or cause of Death*

*Remarks*

**A Number of Blank Pages  
Follow, which have not  
been Photographed.**







