

E.R. Davies sculp.

1094

Identification see Beclard, Meckel, Cruveilhier.

The Anatomy of Man

A relational Description of the Structures of the Human Body.

Alex Halley

Anatomy

Mr Richard Quain
Professor

London University College

1840

Medium weight of a child at birth (full period
is 7 lbs - length 19 Inches Eng.

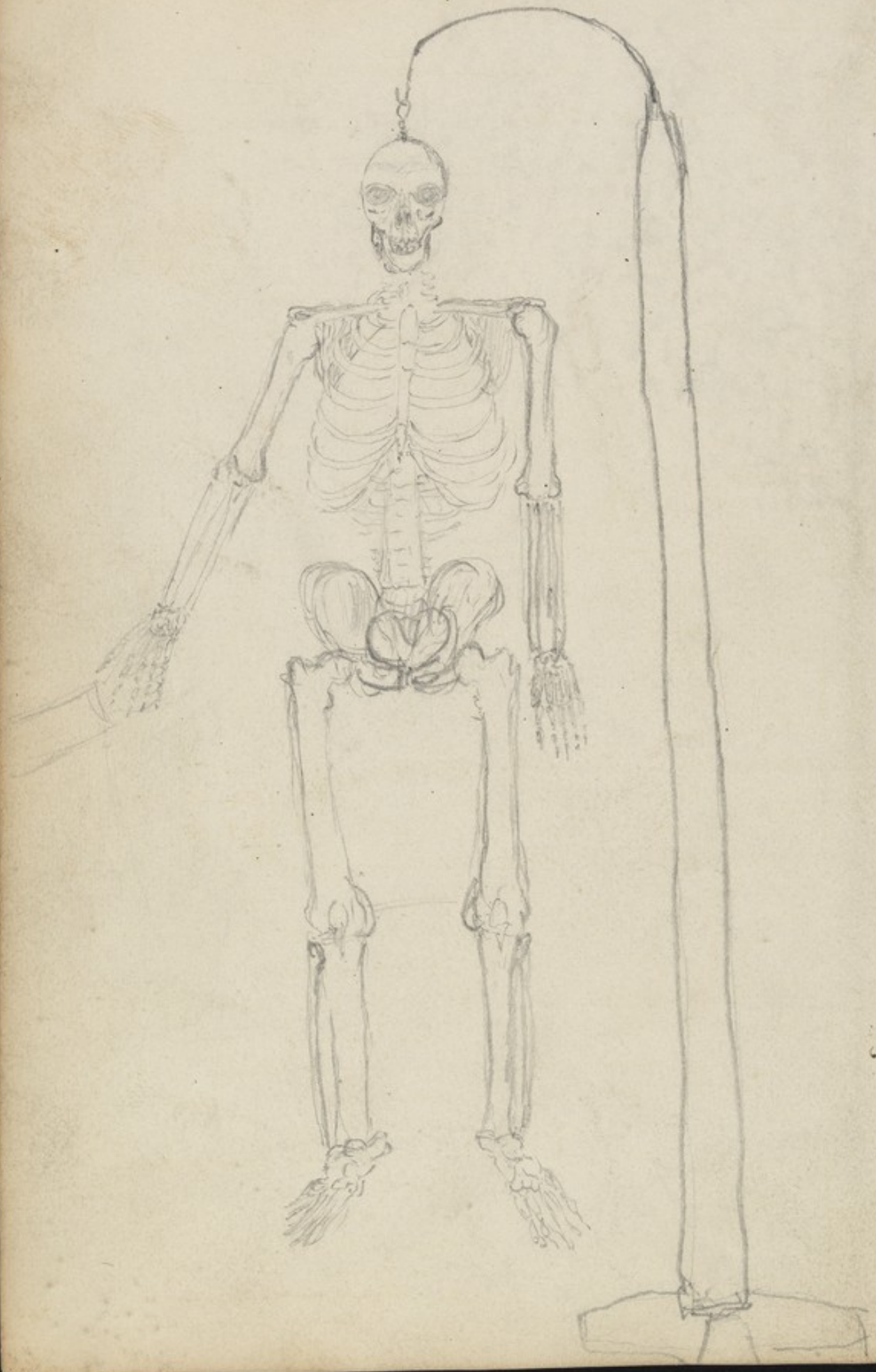

Trunk 55

Extremities 132

Head 63

The Bones.

Skeleton of Adult consists of.

Trunk 55	Vertebrae or Spinal Segments		7 12 5	24
	Costae or Ribs			24
	Sternum or Breast Bone			3
	Ossa innominata	Hip Bones	Pelvis or Basin 5	2
	Os sacrum	Seat Bone		1
	Coccygis	Tail Bones	4	1
Extremities 132	Claviculae	Key Bones or Collar Bones		2
	Scapulae	Shoulder Blade or Spade Bones		2
	Ossa Humeri	Arm Bones		2
	Ulnae	Cubit Bone } Forearm Bones		2
	Radii	Spoke Bone }		2
	Ossa carpi	Short Wrist Bones		16
	— metacarpi	Long Wrist Bones		10
	Phalanges digitorum manus	Fingers		28
	Ossa sesamoidea	accessory Bones		2
	— femoris	Thigh Bones		2
	Patellae	Knee Caps		2
	Tibiae	} Leg Bones		2
	Fibulae			2
	Ossa tarsi	Short Ankle Bones	Feet 7 + 7	14
	— metatarsi	Long "	5 + 5	10
	Phalanges digitorum pedis	Toes	14 + 14 = 26	28
	Ossa sesamoidea	accessory Bones		2
Head 63.	Os frontis	Forehead Bone		1
	Ossa parietalia	Side Bone of Head		2
	Os occipitis	Back Bone of Head		1
	Ossa temporum	Temporal Bone or "Temple"		2
	Ossicula auditus	Ear Bones		8
	Os sphenoides	"Bat" Bone or Wedge		1
	— ethmoides	Sieve Bone		1
	Ossa malarum	Malar Bones		2
	— maxillaria superiora	Upper Jaw Bones		2
	— nasi	Nose Bones		2
	— lachrymalia	Tear Bones		2
	— Palatina	Palate Bones		2
	turbinata	Cope Bones		2
	Vomer	The Plough share Bone		1
	Os maxillare inferius	Lower Jaw		1
	Dentes	Teeth		32
	Os Hyoides	Tongue Bone		1

246

246

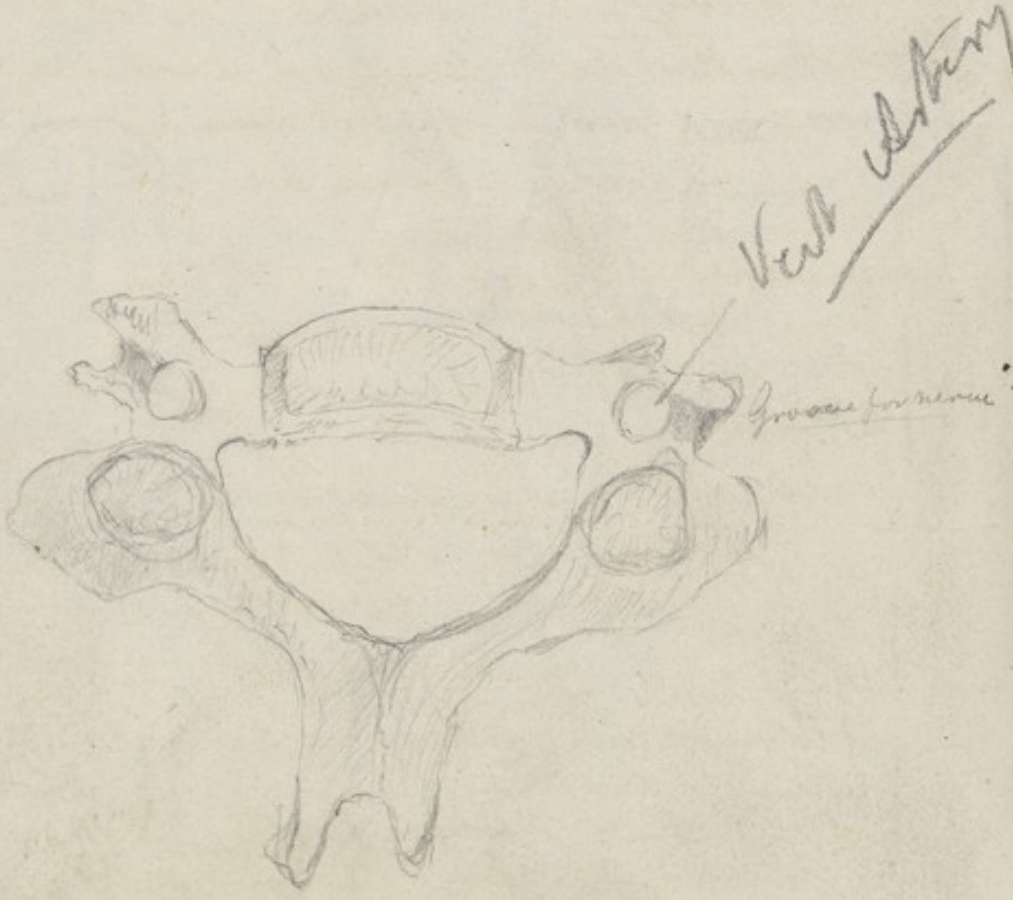
Vertebral Artery
Groove for nerve



Cervical Vertebrae

Number.
7

Situation
Neck

Connection
By Bodies with contiguous vertebrae
1st articulates indirectly with Occipital Bone
7th articulates with 1st Dorsal.

Peculiarities
smallest of 3 sets.

Body -
Elongated transversely -
* ~~Thicker anteriorly than posteriorly~~ (Quain) Mt.
Ant - Inf. Part dips down & forwards
Upper surf broadest, Concave from Side to Side
Lower — convex & rounded off ~~from side to side~~
(Lower — — — concave antero Posteriorly
(Lower largest ant post. owing to the ant lip dipping forward).

Foramen
Triangular & larger than in other Vertebrae

Superior Articulating Process
Flat - & looks backwards & Upwards & a little out -

Inferior Art. Pro -
look downwards & Forwards - Concave & downwards

Transverse Process
Short & Bifid
Groove for Nerve
Foramen for Vertebral artery.

Sup surf of Atlas

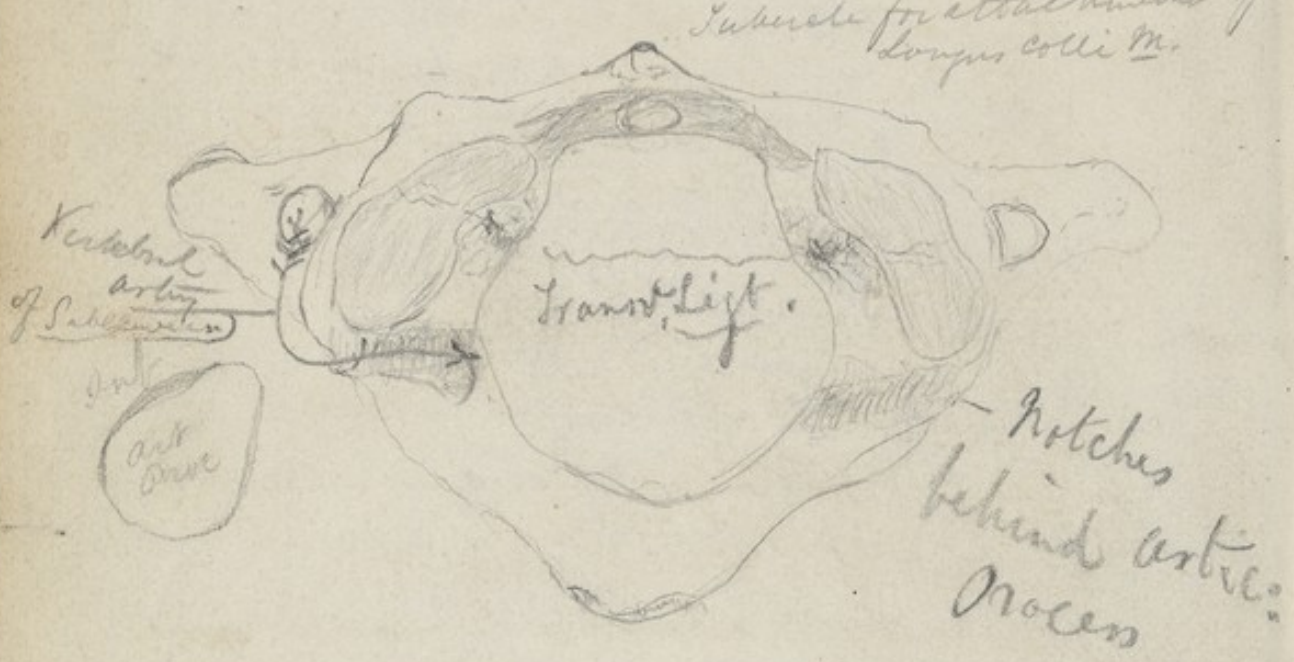

Cervical Vertebræ

Spinous Process

Short. – Bifid – nearly Horizontal –

Laminæ

Narrower & longer than in other Vert. Flat.

Notches –

larger & deeper in upper than in lower Border of the Pedicles except in the 2nd – 1st & 3rd – 4th
Placed before the articular Process except in 1st – where they are behind them.
(in line with the art Process)
in most of the Vert.

Exceptions

1st Cervical – Atlas –

No. Body very small & hollowed out with articular surface posteriorly for odontoid Proc of 2nd

Sup Art. Proc – irregularly oval, length ant Post to Vert. – concave – looks up & in –

Inf art. Proc
Broad & nearly flat.
Downwards & inwards.

Transverse Proc.
not Bifid but large
foramen for Vertebral artg.

Foramen
Large (very)

Notches Post vertebral
Behind roots of artg. Process.

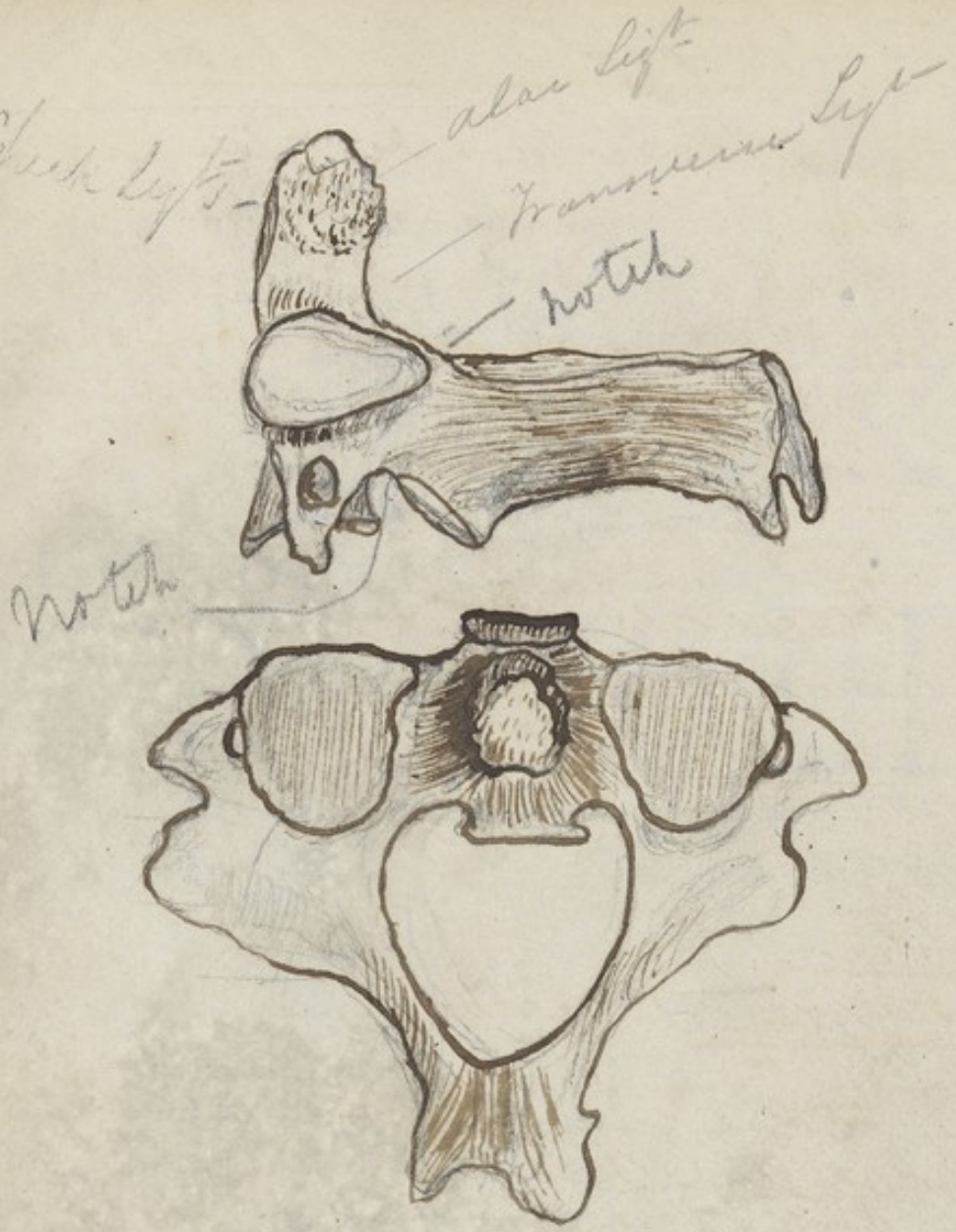

or very slightly cleft

Cervical Vertebræ

2nd – Axis – Vertebra Dentata.

all that is remarkable

Body + odontoid Process – (Head & Neck)
Ant. oval – art. surf – for hollow of atlas.
Sup Art Proc are somewhat circular
very broad & nearly flat – looks up & out –
placed laterally to odontoid

Inf art. Proc –
Placed more Post. – looks – forwards & down

Transverse Proc.
small & single
foramen – looking up & out.

Foramen
large

Notches
Sup – behind upper art Proc very small –
Inf. before lower ——— middling –

7th Cervical (Prominent)

larger than the other cervical –
~~Spinous process long & felt under skin~~

Transverse Proc. Foramen
single with a ~~hole~~ for Vert. veins & smooth surface in front of their roots over which Vert. Artery passes to enter into holes in transverse proc. of 6th.

Spinous Process
Single – long – slightly hooked downwards like dorsal. Felt and visible
Ligt. Nuchæ is attached to it

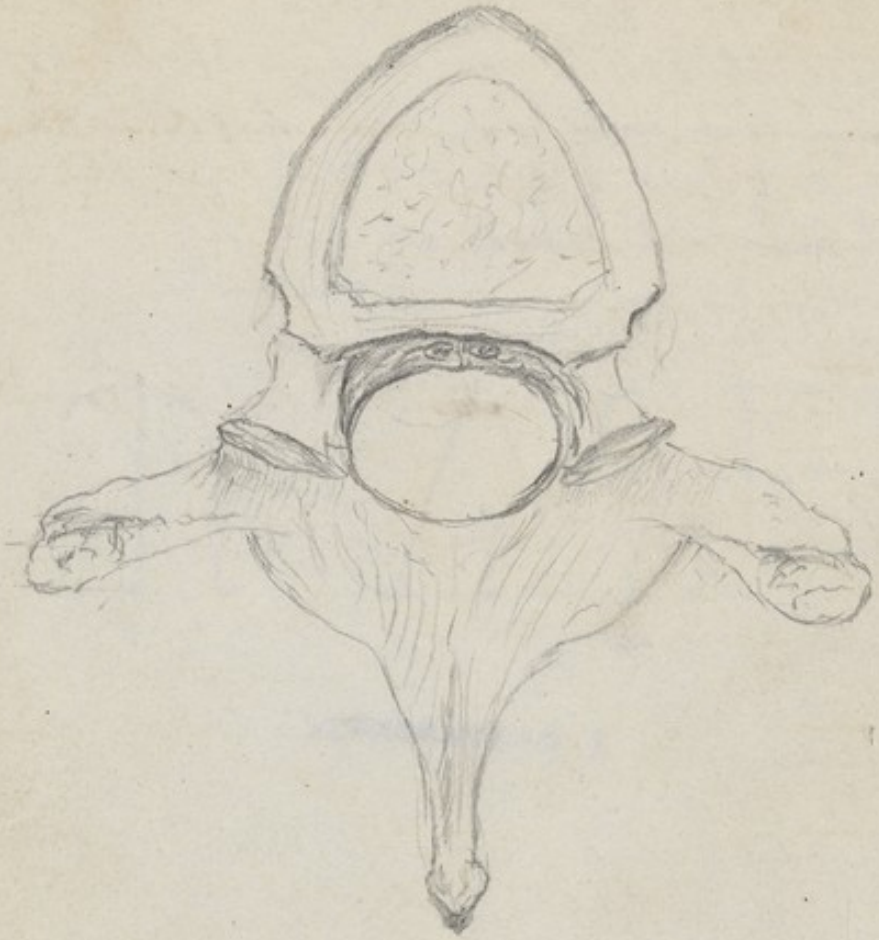

-deeper posteriorly than Anteriorly.

Dorsal Vertebra.

Number

12

Situation

Back.

Connection

By Bodies with contiguous vert. & ribs -
1st " with last. Cervical -
12th " with 1st " Lumbar

Peculiarities

Intermediate in size. Diminish in size from the 1st to the 4th or 5th then increase gradually down

Body.

Length ant. Post. Breadth from side to side.
Convex anteriorly (½ oval).
Concave Post. — & from above downwards -
Flat above & Below.
Inf surf largest.
Sup & Inf notch on each side for ribs -

Foramen

smallest of the three
oval or nearly circular

Sup. Art. Pro.

almost perpendicular - look backwards & slightly outwards - Flat.

Inf. art. Pro.

almost perpendicular - look forwards & slightly inwards - Flat

Transverse Pro.

Long - strong - directed outwards & slightly back - single.
Concave art. surf. on tubercular termination for tubercle of rib.

(Wilson Surg p. 11
9th only one half art. Surf at each side
10th single entire art. Surf ——)

Distance between the 2 inf art surf is
AH. smaller than in any other either Dorsal or
Lumbar except perhaps the 1st Lumbar.

Dorsal Vertebrae.

Spinous Process.
Long - Triangular - directed downwards
Concave ant & inf. - terminates in a tubercle

Laminae
Broader but shorter than Cervical - Flat.

Notches -
Below Pedicle large & deep
above ——— scarcely any.
Sup & Inf Notches on Body form ½ oval depressions for heads of rib other ½ form from next vert. so that each rib articulates with 2 Dorsal Vertebrae.

Exceptions

1st Dorsal.
Sup Art. Pro.
Oblique.
Spinous Pro
Alone Horizontal. sometimes slightly cleft
Notches (on Body)
whole, art. surf sup for 1st Rib. besides ½. ——— inf for 2nd

10th Dorsal
only sup - ½ art surf
Spinous pro terminates more bluntly

11th Dorsal.
whole sup art. surf.
Transverse Pro. smaller & no art. surf.

12th Dorsal
whole sup art. surf.
Trans Pro smallest & no art surf.
Inf Art. Pro - convex laterally & looks forw & out.

Beyond the 1st Lumbar there is no Spinal Cord, so that here commences the Cauda Equina

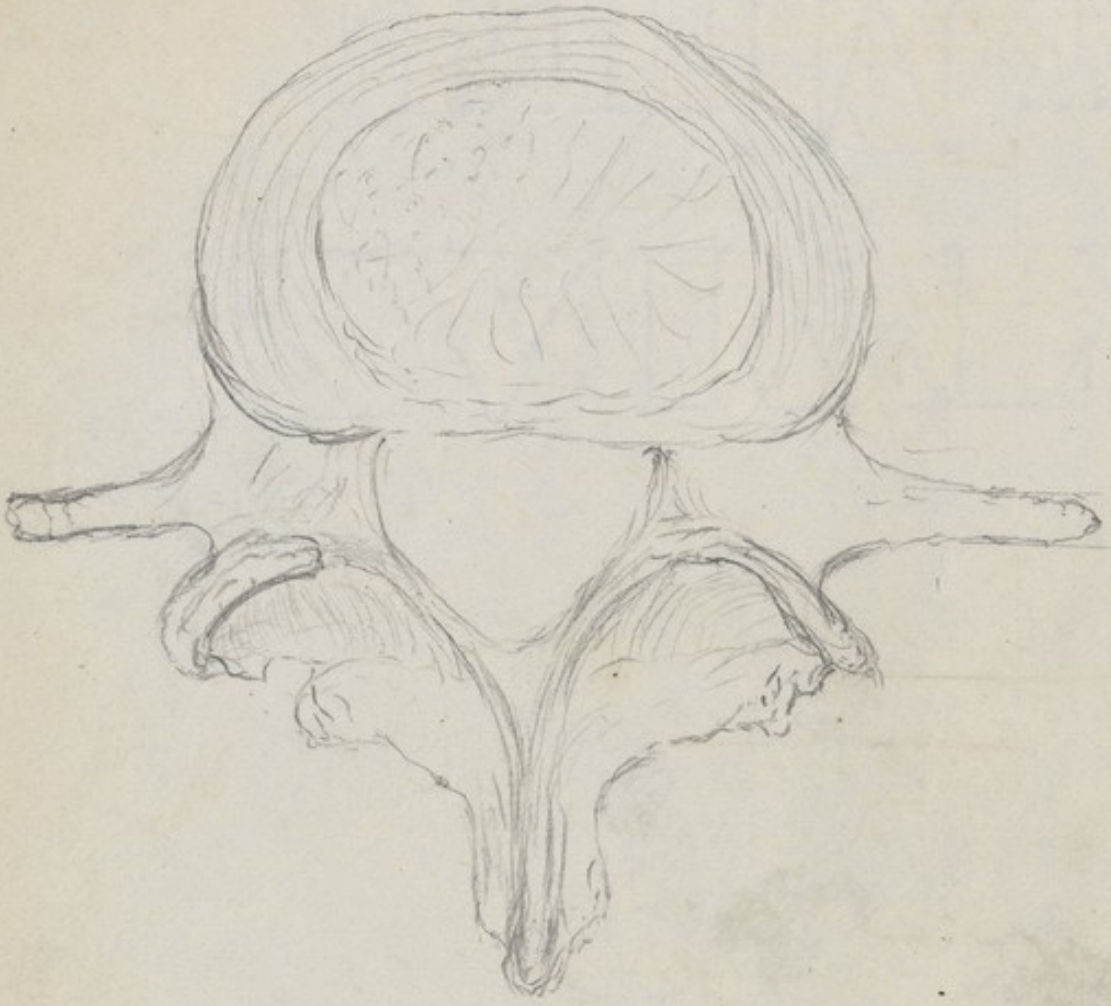

Higher Dorsal Vertebra

Lumbar Vertebræ

Number
5.

Situation
Loins.

Connection
By Bodies to Contiguous Vert
1st ——— Last Dorsal Vert
5th or last ——— Sacrum -

Peculiarities.
Largest.

Body.
Largest from side to side -
Convex ant - but not so much as in Dorsal
Concave from above downwards -
Flat sup & inf

Foramen
2nd largest. & triangular -

Sup. Art. Pro.
Thick & strong.
Perpendicular
Concave & look back & in.

Inf. Art. Pro
Thick & strong. nearly perpendicular
Convex & look For. & Out. & being
nearer to each other than Sup are received into & embraced by them -

Transverse Pro.
Long, slender
Directed out, & slightly back & up.

Pyramids of Spine (Wilson p12)

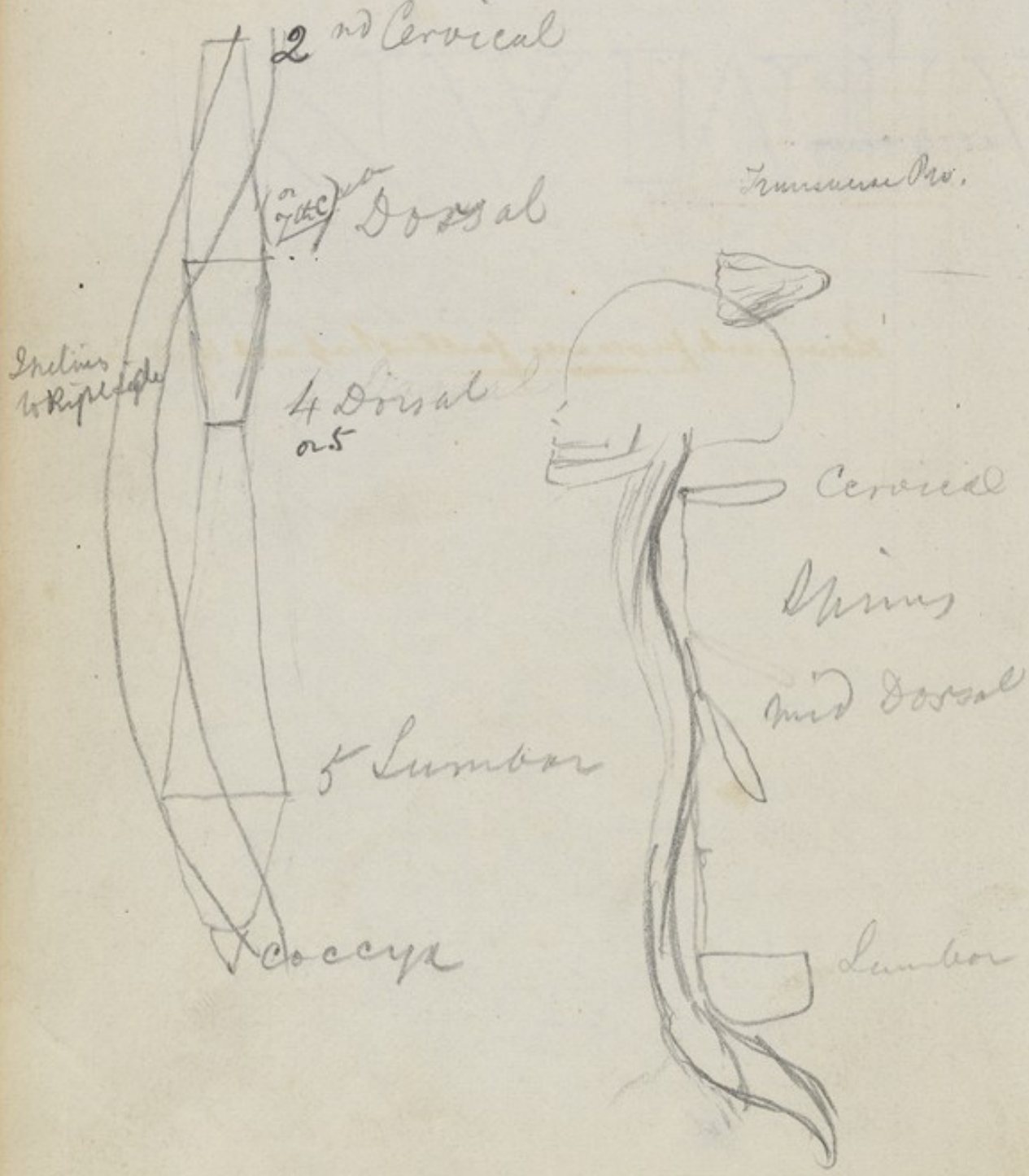

Lumbar Vertebræ.

Spinous Pro.

Broad, flat, nearly square, horizontal terminates by rough border.

Laminæ

Shorter deeper & thicker than in Dorsal Vert.

Notches

deep particularly below Pedicle.

Exception

5th Lumbar.

Body thicker ant than Post.

Transverse Proc. short, thick, & rounded.

Spinous Pro – more hooked downwards.

Lower art processes farthest apart to fit Sacrum

In Foetus



Mr. Quain
J. Cruveilhier

3 { 2 ossified centres Arches (Laminae) - proceeds from above-downwards 7 W
1 " Body + processes of 9th or 10th Dorsal Vert. + proceeds upwards & downwards.
Ossification progressing after birth.

Laminae meet behind at - - - - - - - 2½ Y
Transverse process having first jutted out from the middle of the arch

Body meet arch at - - - - - - - - - - 6 Y

5 { 1 Epiphesis for Spinous process
1 ——— each Transverse - } come 16 to 18 Y
1 ——— upper part of Body
1 ——— under ——— } join 20 to 25 Y

Lumbar Vert.

+ 1 { 1 more Epiph for each Art Pro in Lumbar Vert. (C)

Atlas

Some anatomists give it { 1 or 2 pts for Ant arch
2 pts — Lat. Masses
3 ——— post arch

C { Cruveilhier never saw but 2
Post arch formed in 40 or 50 Day
Ant " ——— 1 year.
arches alone are formed at Birth
Body soon after.

Axis. (Dentata)

2 Pieces extra for Odontoid Pro.
C { Body formed from 2 pieces (C).
Between Body & Odontoid 1 other piece { Meckel / Nesbit } C.
Centre for the Body appears in 6 M
——— Odontoid & shortly after (C)
Laminae unite behind in 1st Y
Body & Odontoid unite 4 to 5 Y

7th Cervical.

+ 1 { 1 Extra Pt for Ant part of Transv. Pro.
This is sometimes the case with 1st Lumbar (C).

Ossification of Vertebræ

(3 primary ptes & 5 Epiphyses)

7 Epiphyses in Lumbar

Sacrum is sometimes called the "False Vertebrae.)-

- Cornua

Sacrum

Number

1 Bone but originally composed of 5.

Situation

Posterior part of Pelvis.

Connection

Sup to last Lumbar vert. Inf to Coccyx
Laterally to Ossa innominata. (between them)

Description.

Triangular in shape - Base up & forwards.
Curved inf so that apex looks forwards
Concave anteriorly & even
Convex Posteriorly but irregular

Ant. Surface

Concave from above downwards - nearly flat sideways
(4 Transverse lines dividing it into 5 parts)
4 Ant. Sacral foramina. one at each end of the lines for Ant. Br. of Sac. Ner. - look outwards - sup larger than Inf.
Lat. surf give attachment to Pyriformis Mus.

Post. Surface.

Convex.
4 small Rudiments of Spines (forming a Ridge) 2 lower ones generally bifid so as to leave the Spinal canal open & give attachment to a ligament that closes the canal.
4 Post. Sac. For. lying in a groove on each side & smaller than ant. to transmit Post. Sac. N.

Sup. Border. (Iliac)

Large & Irregular

Inf Border.

Narrowing to an edge gives attachment to the Sacro Sciatic ligaments.
Notch which with another on Coccyx forms a Foramen for transmission of 5th Sacral nerve

Post Vieno AH.

Sacrum & Coccyx

Sup Ext. or Base.
Oval - length from side to side
(Triangular orifice of Sacral Canal behind this)
Ant. Pro - concave f side to side - looks back & in
& receives Inf. Art. Pro. of 5 Lumbar Vert.
Groove before Art. Pro forming pt. of Cost. Int. Ver. For.
Border of Orifice behind Art. Pro - Curved, sharp
& depressed, giving attachment to last
Lig. subflavum. - It corresponds to Lat. Arches
of Vertebrae.

Inf. Extremity or Apex.
Oval convex surface for articulation with Coccyx

Foramena
1 Sacral Canal - Triangular - narrows as it descends
4 Ant } on each side of Median line.
4 Post }

Muscles (attached to
Pyriforme to Lat. Part of Ant Surf.
Gluteus maximus
Sacro lumbalis
Longissimus Dorsi } to each side of Post. Surf.
Multifidus Spinae
Coccygeus (Part of) Inf. Pt. of each Border.

Coccyx. (Cuckoo's Bill)

Number
4 generally united late in life
Situation & Connection
Inf Extremity of Sacrum
Description
Triangular, Base attached by oval art surf to Sacrum
apex rounded to a point. | & by the Coccyx of Both
concave ant. convex Post.
Muscles attached to
Gluteus maximus & Coccygeus on each side
Sphincter Ani at its apex.



I have seen a case in which the 1st piece was soldered to the Sacrum before it had united to the other pieces - also where the 2 & 3 pieces united first in Mr Stocks possession.

A.H.

15
6
10
2
33

4

Ossification of Sacrum & Coccyx.

15	3,	First Vert. have 5 pts { 1 Body, 2 Plates, 2 Lat. Mass. }	Bodies appear	2 or 3 M
6	2	last Vert have 3 pts.	Lat. Masses	5 or 6 M
10	2	Epiphyses for Body of each Vert.	—	6 to 9 M
2	1	— on each Iliac surface	—	15 to 18 Y
				25 Y
33				

1st The Plates unite
2nd The Lat Masses of first 3 vert unite.
3rd These unite with the Body. beginning with the 4 or 5.

Although Ossification proceeds from above downwards yet they unite from Below upwards.

The 5 pieces are still separable at 15 Y but begin to unite from 15 Y & 18 Y & the 1st is not completly united till 25 or 30 Y

Body ossifies from without inwards so the outside may be Bone & inside may be cartilaginous.

Coccyx

4	1 Point for 1st Bone	sometimes 2 Lat. Pts.	1st Y
	1 — 2nd —		5 to 10 Y
	1 — 3rd		10 to 15 Y
	1 — 4		15 to 20 Y

They unite before the Sacrum ? No

First 1st & 2nd Bones unite
Next 3 & 4th —
Then 2 & 3 —
Last Coccyx to Sacrum — (later in Women) 50 to 60 Y

(Latissimus Dorsi M.) Outer Surface (Ext oblique M)

Crista Ilii

Ilium

Sup Curved line

Surface for (Gluteus Maximus)

Post sup spin Pro.

Post Inf. Spin Pro.

Sacro Sciatic Notch

Inf curved line

Spine of Ish

Lesser Sacro Sciatic Notch

Ischium

Tuberosity of Ischium

o. Sartorius M. & Poupart's Lig. Ant. Sup. Spinous process

o. Tensor Fasciae Femoris

o. Cutaneous Nerve

Ant inf spinous process

Rectus Femoris M & Acc. Lig.

Tendons of Psoas Magn & Iliac Intsly.

Body of

Pubes

Ramus Pubis

Int. Oblique M.

Quad. Lumb. M.

Transversalis M.

Inner Surface

Iliac Fossa

Iliac Fascia

Ilio Pect. Line

Ilio Sacral Eminence

Iliac Ligaments

Pectineus Mus. & Pubic Fascia

Ext. Oblique & Ext. abd. Ridge

Spine or Tubercle

Crest of Pubes

Angle of Pubes

Int. Oblique & Ext. abd. Ridge

Post. Inf. Spin. Proc. Ilii

Ext. Sciatic Notch

o. Gemellus Sup. Ext. Coccygeus Int.

Spine of Ischium

Lesser Sciatic Notch (Tendon of Obtur. Int.

o. Quadratus Femoris, Gemellus Inferior } Post.

+ Ext. Sacro Sciatic Lig.

Tuberosity of Ischium

o. Biceps

Infl. { tendinous, membranous

Triangular Lig.

Pectineal Fascia

Crura Penis

Sheath Penis M.

Ossa Innominata (Unnamed Bones)

Number
2

Situation
Lat & Ant to Sacrum & with it form Pelvis.

Connection
By Ilium with Sacrum
By Acetabulum with Femur.

Divided into 3 Parts for description

1st Ilium

Situation
Sup & Lat part of Pelvis (& Os Innom.)

Ext. Surface (dorsum ilii)
Convex ant. concave Post.
1 Sup Line from ant. sup. spin. Pro. curved downwards to Sacro Sciatic notch.
On Post part a rough surface for Gluteus Maximus muscle
Between Sup line, Rough Surf, & Crista Ilii a space for attachment of Gluteus Medius
1 Inf Line less marked than Sup line from ant. Inf. Spin. Pro. curved backwards to the Sacro Sciatic notch
Space between Sup & Inf curved lines gives attachment to Gluteus minimus.

Ant Surface
divided into 3 parts
1st Ant. large, Concave, smooth is Iliac Fossa
2nd Post, Rough & Uneven for Sacrum
3rd Smooth, smaller forms pt. of true Pelvis

Sup Border (Crista Ilii) (Spine)
Convex - Curved in, ant. out, Post,
Ext & Int Lip (labium) with a rough interval

(/3

Ossa Innominata

Ilium

Ant Border

Irregular descends from Crista to Os Pubis.
Ant, Sup, Spin, Pro, at junction of Ant Pro Dec with Crista
Ilio Pectineal Eminence ——— Pubes
Ant Inf Spin Pro - between these
1 Excavation between Ant Inf Spin Proc. & Ilio Pect. E gives transmission to Iliacus Psoas Mus
1 ~~Excavation~~ between Spin. Processes transmits Ext Cutaneous nerve & gives origin to some fibres of Sartorius Mus.

Post. Border.

Post. sup, spin, Pro.
Sup Notch
Post inf, spin, Pro.
Inf notch forms part of Sacro Sciatic notch.

Inf angle

3 surfaces
- 1 where it joins pubes - ant
- 1 ——— forms pt of acetabulum - Ext
- 1 ——— joins Ischium. Post.

(13) Muscles attached to

Gluteus Medius - between Crista & Sup Curv. Line
——— Minimus ——— Curved Lines
——— Maximus to post. rough surf.
Iliacus attached to Iliac fossa
- Obliquus Ext. Abdominis to Ant half of Ext lip of Crista
- Latissimus Dorsi to Post 3rd ———
- Obliquus Int. to Ant 2/3rd of Interval
- Erector Spinae to Rest ———
- Transversalis Abdominis to ant 3/4 of Int. lip of Crista
- Quadratus Lumborum to Rest ———
- Tensor Vaginae femoris to Ext surf of ant sup Spin Pro.
- Sartorius to notch beneath & to ———
- Straight tendon of Rectus femoris to ant. Inf Spine
- External ——— to Brim of Acetabulum

ant view from Nature
A.A.



Ossa Innominata - Pubes

2nd Pubes.

Situation

ant & Int Part of Os innom.

Body - (sup & thick part)

Placed Horizontally.

3 surfaces separated by 3 lines

- sup - slightly depressed is covered by Pectineus
- Int - smooth forms part of Pelvis
- Ext or Inf. grooved transversely, overhangs obturator Foramen & looks down on femur.

Ext. Extremity -

Thick & has 3 faces

1 Concave forms part of acetabulum

1 Superior joins Ilium (at Ilio Pectin Em).

1 Inferior — Ischium

Int Extremity

Flat & compressed joins opposite one by intervening cartilage & forms Symphysis pubis -

Crista

is horizontal part above Symphysis -

Angle

formed by junction of Crista & Symphysis

Tuberosity (& spine) pt of Ilio Pect Eminence

nodule of Bone projecting from Crista.

Ilio Pecteneal line

from tuberosity runs outwards & gives attachmt to Gimbernat's ligt & Pectineus Mus

Ramus.

ant & down from Body - forming an angle & uniting with asc. Ramus of Ischium.

Inner surf is smooth with art surface

Outer —— rough

One of its borders forms with the opposit border arch of the Pubes

Other Border

Sharp & thin forms pt of margin of the Obturator Foramen.

Ossa Innominata Pubes - Ischium

13 Muscles attached to.

{Pyramidalis to ———— Crista
{Rectus abdominis ————

Obliquus Ext to Tuberosity & Ant Surf.

{Pectineus ———— to Pectineal line
{Gimbernats ligement ————

{Obliquus Int to Crista & Part of ————
{Transversalis ————

Adductor longus to Ext. Surf at angle
———— Brevis between angle & Obturator for
Gracilis to line of Symphysis & the Ramus
Obturator Exet to whole marg. of Obt. Foramen

{Part of Obturator Int to Inner surf of Pubes
{Levator Ani ————

3rd Ischium -

Situation
Post & Inf of Os Innominatum.

Body
Larger part - short, thick has {3 surfaces, 3 Borders, 2 Extremities}

Exet Surf
Smooth concave part forming more than 2/3 rds of Acetabulum surrounded by a Curved Prominent line forming lower border of it. Groove beneath this horizontally backwards for tendon of Obturator Externus muscle - Rough line still lower for quadratus femoris

Int. Surf.
Smooth & forms part of Pelvis &
Spinous Pro =
Smooth notch for obt. Int Mus to pass on.

Post Surf
Broad between Spine & Acetabulum but narrows gradually & becomes depressed & ends in Tuberosity of Ischium on which we sit for it - 3 impressions for 3 long flexor Muscles of Leg.

Ossa Innominata - Ischium

Sup Ect. (when separated has 3 surfaces)
2 Flat & triangular for Ilium
1 ——— Pubes
1 Concave & smooth forms part of Acetabulum

Inf Ect
Same as Tuberosity.

Ramus.
Flat & thin part ascending forwards & inwards & joins Ramus of Pubes.
One margin (thick) forms part of inf outlet of Pelvis
another (thin) — bounds obturator foramen
Ext surf - rough & looks out & down
Int surf - forms pt. of Pelvis

12 Muscles attached to.
adductor magnus - to outer border of tuberosity & contiguous part of Ramus.
Erector Penis to forepart of inner marg. of tuberosity.
Transversus Perinæi to adjacent marg of Ramus.
Int Obturator - to inner surf behind Obt. Forn.
3 tensors of leg { Biceps ——— to Post. Surf of Tuberosity
Semitendinosus ———
Semimembranosus ———
Quadratus femoris to roughline on out surf of Tuberosity.
Gemellus superior to Ext surf of Spine.
——— inferior to adjacent border of Tuberosity
Levator ani to Int surf of the Bone
Coccygeus to spinous Process.

Mr Quain

Rami of Ischium & Pubes ossify at 6 Years.
but acetabulum is still Cartilage. ——

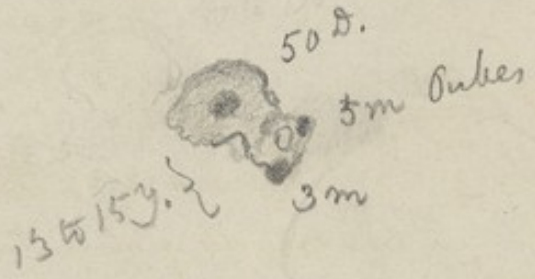

Pelvis

True & False

Symphysis Pubis
Sub Pubic arch
Thyroid or Obturator Foramen
Acetabulum
Sacro Sciatic notch
Ilio Pectineal line
Promontorium

(C) Ossification of Ossa Innominata

		appear	Unite
3	1 Point for Ilium	50 D	13 to 15 Y
	1 ——— Ischium	3 M	
	1 ——— Pubes	5 M	

		appear	unite
5	1 Y shaped Epiphyses in Acetabulum	13 to 15 Y	18 to 20 Y
	1 Epiphyses on Tuberosity & des Ramus of Ischium	"	"
	1 ——— Ant. Inf. Spine of Ilium (not constant)	"	"
At	1 ——— angle of Pubis (still less constant)	"	"
	1 ——— Round Crista Ilii	"	& 20 to 25 Y

At Birth - Acetabulum is mostly Cartilaginous
——— asc. Ram - of Ischium ———
——— Des. ——— Pubes ———
——— Circumference of Ilium ———

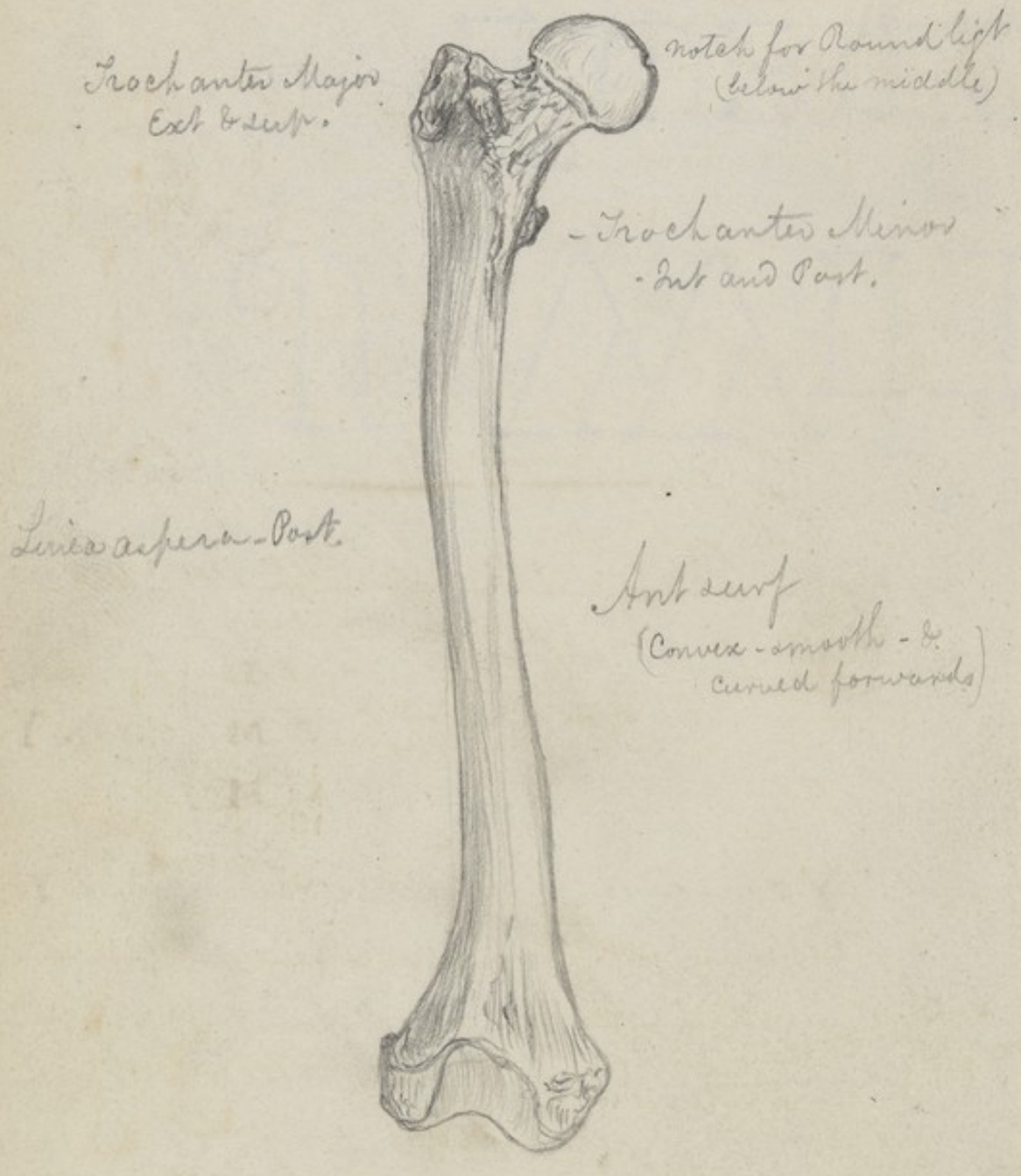

Post Intra condyloid fossa deepest
Inter Condyle lowest

Femur - Os Femoris - Thigh -

Number
2

Situation
Between Pelvis & Tibia

Connection
By head or upper Extremity with Acetabulum
By Condyles Inferiorly with Tibia
——— Anteriorly —— Patella -

Description
Longest Bone in human body.

Body or Shaft:
Compressed but nearly cylindrical in centre
Arched forwards - Expanded - at the Ends -
ant Ant surf - convex & smooth. Broadest Inferiorly - (Curved to outwards)
Lat. & — flattened. Ext (one) slightly concave.
Surf which sup - looks In - but Inf - looks back.
2 lines separating Ant from Lat surf.
Post Linea Aspera at junction of 2 lat surf posteriorly
" Most prominent towards Centre.
" 2 Margins & a rough interstice.
" Bifurcates towards Extremities { Sup { 1 to lesser Trochanter / 1 to greater ——— ; Inf { 1 to each Condyle.
" " " Triangular space between them where Popliteal Art. vein & Nerve lay -
" " "
Foramen from below upwards at sup part of linea aspera

Trochanter major
Prolonged from Ext. surf. of the Body. quadrilateral
Convex & rough Ext surf -
smooth on outer & back part.
line directed down & forwards. for Gluteus medius -
Post. line ——— " & inwards - to Trochanter minor

Trochanteric or digital fossa
between Trochanter major & Neck of Femur
sup border - flat & straight
Post ——— thick & rounded

Trochanter Minor -
Eminence at Sup, Post, Int side of Bone

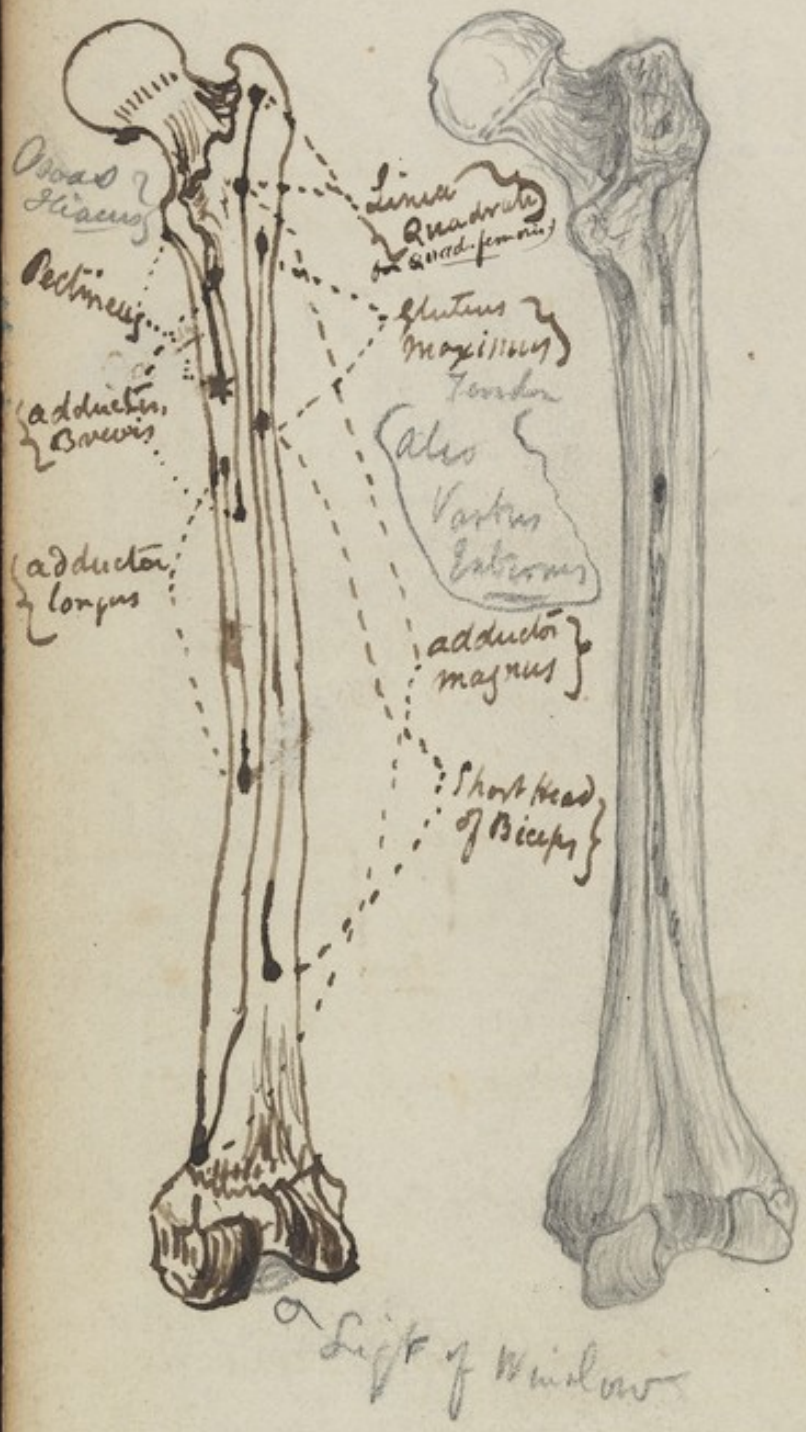

Triceps Adductor Femoris

Femur.

Neck.

Constricted sup. part of the Bone & forms an obtuse angle with it.
Greatest diameter vertically from side to side.
Ant surf - broad & smooth
sup — shorter & more concave than Inf.

Head

Globular part above the neck.
Small Cavity placed a little beneath its most prominent points for round ligament.

Inf Extremity

Thicker & broader than Sup.

Ext Condyle

Longer & projects more forwards than Int. its articulating surf is broader & rises higher ant.
Ext surf. Rough -
Deep Pit for attachment of Popliteus
Ext. Tuberosity just above it for Ext Lat lig.

Int Condyle

appears longer & lower down than Ext.
Tuberosity on Inner side for Int. Lat. lig. & add. mag.

Articular surface of Both Condyle are United Ant & Pulley like surf formed. Ant (for Patella) but diverge as they pass inferiorly & Post form Condyloid Fossa — Post. for Crucial ligts.

Muscles attached to.

Crureus — to ant surf.
{Vastus Ext to lat surf & to both lips of linea aspera
— Int
{3 adductors to Centre of linea aspera
Short head of Biceps flexor
{Gluteus medius to sup-bord of Trochanter Major
— minimus — ant
Ext. Rotators - to fossa at Post surf
Psoas to lesser Trochanter
Iliacus
Quadratus femoris to post part of Inter Trochanteric line
Pectineus to line below lesser Trochanter.

(Quain)


unite at 18 Y.
end of 1 Y
Gt. Trach
3 or 4 Y
12 (2)
Little Trach. 13 or 14 Y
30 or 40 D
8 (2)
unite at 20 Y
9 M

Femur

Muscles Cont.

Gluteus Maximus to rough pt. beneath Gt. Trochanter
2 heads of Gastrocnemius to just above In & Out Condyle
Plantaris to Ext Condyle
Popliteus to Fossa beneath Ext Tuberosity.

Ossification of Femur (C)

		appear	Unite
1	Point for Body	30 or 40 D	
1	——— upper Extrem	end of 1st Y	
1	——— Great Troch.	3 or 4 Y	18 Y
1	——— Little ———	13 or 14 Y	
1	——— Lower Extrem	Last fortnight of I. U. L.	20 Y

5

(Natural size)
Post surf.

Largest side Ext
apex Downwards

(Size proportional to others)
Ant surf.

2½ V

Patella - Rotula - Knee Pan -

Number
2
Situation
Ant. Inf part of Femur.
Connection
By Ligamentum Patellae to Tibia
Description
Triangular sides rounded off - Base Sup.
Convex Ant.
Smooth Post.
Divided into two parts by vertical line
Ext - broadest.
Inf. small irregular depression - - - - for Lig. Pat.
? (Ext Border thinner than Int.) 2)

Muscles. &c.
Extensors to - - - - - - - - - to Base or Sup Ext
Ligamentum Patellae _____ to Apex or Inf —

Ossification of Patella.
1 Point. appearing at 2 1/2 years (C)

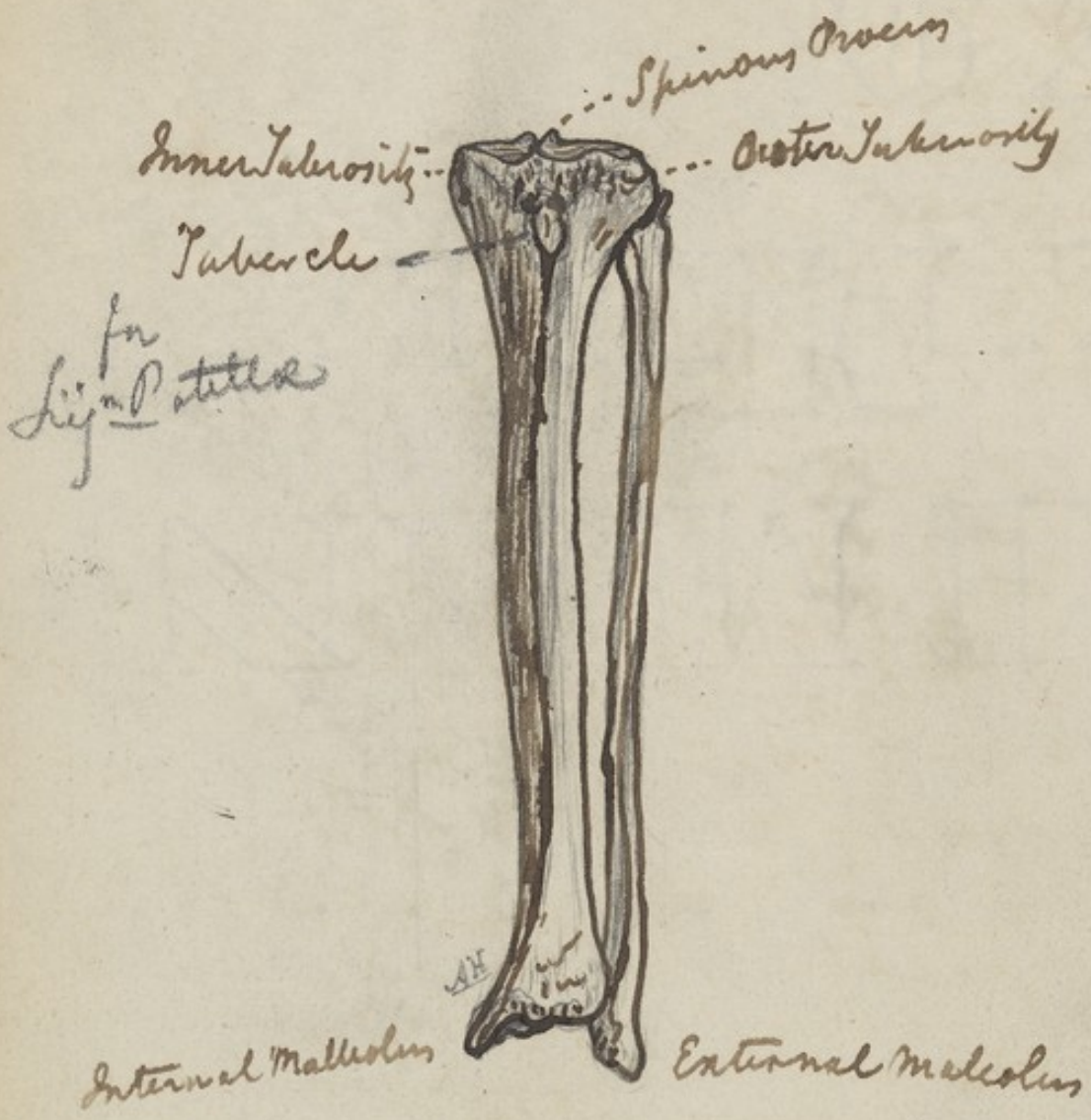
Spinous process
Inner Tuberosity
Outer Tuberosity
Tubercle for Lig.m Patellæ
Internal Malleolus
External Malleolus

Lizzie.

Tibia (Inner Bone of Leg)

Number
2

Situation
Inner side of Leg -

Connection
Sup with femur & lig Pat with Patella
Ext —— Fibula
Inf —— Astragulus -

Description.
Next longest bone to Femur.

Body -
Triangular & twisted on itself. a little
Diminishes in size for 2/3rd of length & then gradually increases towards lower end.
Ant surf convex & subcutaneous except above.
Ext —— concave above - convex & inclined forw. below
Post —— deeply seated.
× Line from Upper 3rd up & out to Ext Tub.
Part above this is Triangular.
Large medullary foramen - above down - near line -
Ant Border curved, subcutaneous, sharp & prominent - hence called Crista or Spine of Tibia - subsides below
Int. Border. Thick & rounded. (sharpish dn.)
Ext —— sharp - divides inf where it articulates with the Fibula : To this the Int. Ps. lig is inserted.

Sup Ext.
Thickest & most expanded part of Bone,
Broader from side to side
Circumference Rounded & Convex Ant & lat - hollowd Post
Ant - Tuberosity (Tubercle) Rough Inf - smooth - Sup for Bursa
Ext ~~Tuberosity~~ largest
Int ~~Tuberosity~~ smaller than Ext - smooth Sup Post for Patella
Int Condyle, or Sup pt of Bone deepest. gr. diam Ant. Post
Ext —— —— nearly circular.
Spinous Pro between Condyles divided into 2 tubercles.
Depressed surf before & behind Sp. Pr. for Crucial ligt Semilunar cart.

Ruwin)


20 to 25 y
End of 1st
6 or 8 not infrequent.
30 to 40 D. before femur
18 to 20 y
2nd yr
or
3

Tibia

Inf or Tarsal Extrem -
smaller than Sup
nearly quadrilateral
Ant surf - Convex & smooth
Rough margin inf.
Post surf - Flat & marked by a groove
Ext — slightly concave is rough sup smooth Inf
Int. Malleolus projects from Int Ext
Int surf - Convex
Ext — smooth & articulates with astragalus.
Ant — rounded border
Post — has 2 grooves & a ridge At
Surface - Ext. Horizontal, concave, quadrilateral at right angles with Ext Surf of Malleolus for the astragalus

Muscles &c attached to.

Tibialis anticus — to Ext. surf & Ext. Tab.
Extensor longus digitorum to ———
Sartorius ——— to Inner surf
Gracilis ———
Semi tendinosus ———
— membranosus ———
Popliteus - to triangular space on Post surf.
Soleus — to rest of Post surf
Tibialis Posticus ———
Flexor longus digitorum ———
(Extensors of leg to Patella & its lig)

Ossification of Tibia (C)

		appear	unite
3	1 Point for Body	35 to 40 D	18 to 25 Y
	1 ——— Upper Ext -	end of 1st Y	
	1 ——— lower ———	2nd Y	lower Ext. first.

Pocersey not seen till 6 or 8 (2)
Bellard has seen one pt for Int Mall.
Epiphyses does not cover all sup Ext but only the Ant. Surf & Ant Tab is formed from it - rarely from a separate Point.

about the thickness of the ring finger

a flat space between 2 rough lines to Inner surf.

Ext surface convex.

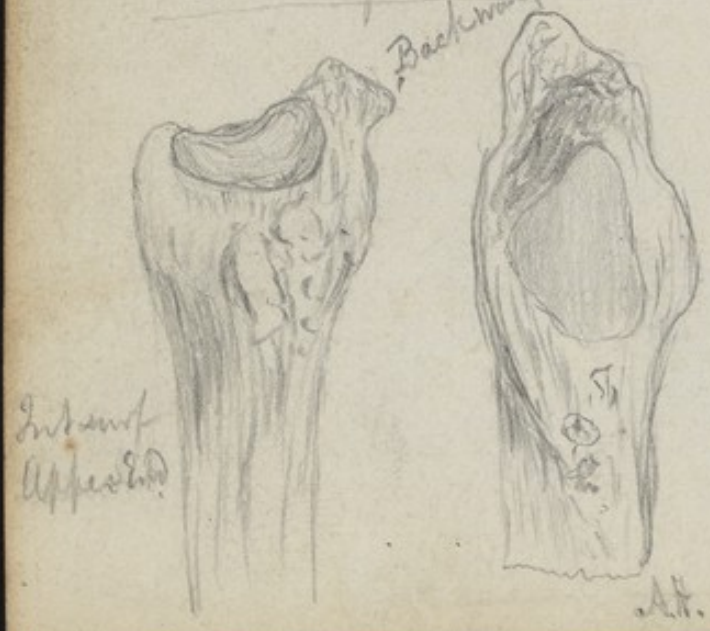

Fibula - (Peroné G. a clasp)

Number
2
Situation
outer side of leg.
Connection
sup with Tibia
Inf ——————— & outer border of astragulus

Description

Thinner but nearly as long as Tibia. when it is placed in its natural position its lower Ext is a little farther forward than upper & the Body is convex backward & inwards.

Body.
~~Triangular~~. Pentagonal 5 sided or surfaces
Ant line - most prominent bifurcates inferiorly
concave triangular surf enclosed by ———
Int line for muscles & int. oss. lig -

Int surf. inf 2/3 looks back - rest forwards & in
divided into 2 unequal part by longitudinal line
to which about 2/3rd Int. oss. lig is attached
Part Posterior to this line is larger & grooved
Ext surf. mostly concave - Inclines back - inf.

Post surf convex & smooth.
Medullary foramen near middle - down -
Inf inclines inwards & terminates by rough surf for Tibia

Sup Ext. (head)
Smaller than Inf.
oval, flat surf, on Sup, Int. part. for articulation with
External tuberosity of Tibia
Rest is rough.
Inf Ext. (Tarsal) -
Forms Ext Malleolus - longer & more prominent than Int.
Groove Post. Convex & subcut - Ext.
Triangular surf Int. Convex above down - flat - Ant. Post.
Rough depression Post for Trans Lig - apex for Ext lat lig -

(Quain)



Fibula.

Muscles.

Extensor Communis digitorum to Ant part of Ant Surf
— Proprius Policis ——
Peroneus Tertius ——
Tibialis Posticus to Depression on Post pt. ——
Peronei to Ext surf —
Soleus — to Post surf
Flexor longus Policis ——
Biceps flexor Cruris to head (Up End) of Fibula

Ossification of Fibula - (C)

		appears	unite
3	1 Point for Body	40 to 50 D	21 to 25 Y Inf Ext unite first
	1 Inf Extremity	2nd Y	
	1 Sup ——	5th Y	

Foot

Ossification

1st Tarsus

7
- os Calcis — 6 M. neck of bone
- astragalus — Birth 2
- cuboid — 1 year old 3
- Scaphoid 12
- Cuneiforme Int. — 5
- Med 5 5 years 6
- Ext. — 4

2nd Metatarsus

5 { 1st 2nd 3rd 4th 5th

3rd Toes

14
- 1st Phalanx 5 Bones
- 2nd — 4
- 3rd — 5

Upper Surface

Post

Ossification. Lucaus

os Calcis — 6 or 7 M.
Astragalus — Birth
Cuboid — 1 y
Ext Cuneif.
Int —
Scaphoid } 5 y
Med Cuneif. }

Int

Ant surface.

15 y { 8 or 10 y
6 M

1849

Os Calcis - (Calcaneum)

Number
2 viz one in each foot.

Situation
heel. Post part of Tarsus.

Connection.
Astragalus sup
Cuboid — ant

Description.
Largest Bone of foot
Length Ant-Post.

Sup Surf (from behind forwards) we see
Rough Border
Flat Surface
Convex tuberosity
Concave portion
Convex articulatory surf
Smaller concave ——— projecting inwards (sustentaculum tali)
& horizontal end of Bone

Inf surf (from behind forwards).
Broadest Behind
2 Tubercles - Int largest
Fossa between them
another Eminence in front.

Ant surf
Smallest - concave articular surf. for Cuboid.

Post surf
Rough for tendo achilis.

Ext. surf
Broadest behind - Grooved before

Int Surf
Concave
Groove on sup edge & under tubercle.

Muscles.
Extensor Brevis digitorum Pedis — to sup part.
Common tendon of Gastrocnemius & soleus & also Plantaris to inf ½ of Post surf
Flexor accessorius & 1st of Abd Pollicis to Inna side of Inf surf.
Abductor digiti minimi — to Outer
Flexor Brevis digitorum between to abductors.

Ossification.
2 { 1 Pt for Ant Part in 6 M. after birth
1 — Post — 8 or 10 Y } unite 15 Y (C)

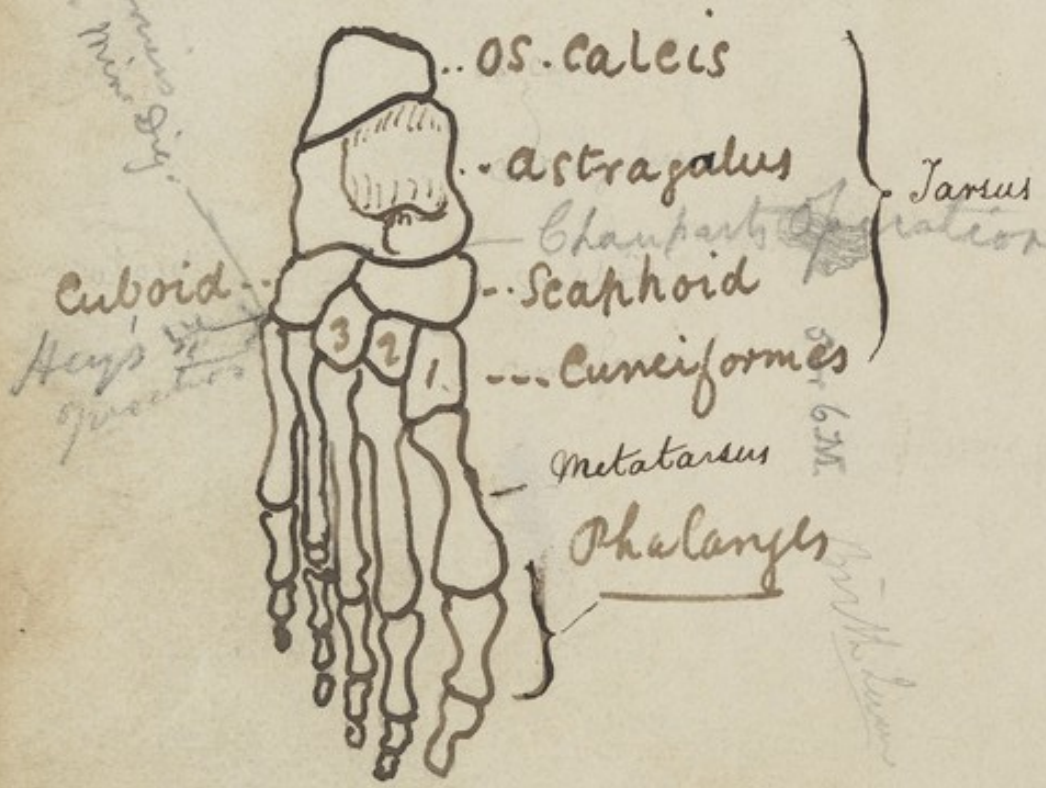
os. calcis
astragalus
Tarsus
Chaupart's Operation
Cuboid
Scaphoid
Heyn's Operation
3
2
1
Cuneiformes
Metatarsus
Phalanges


Upper Surface
Post
Ant
Ext

Astragalus (G. a die)

Number
2 viz 1 in each foot.

Situation
Sup part of Tarsus

Connection
Sup & Ant with Tibia
Ext with Fibula
Inf — os Calcis
Ant — Scaphoid -

Description -
Sup Surf (from behind forward)
Large Convex art surf. (square)
Fossa
Ridge
Excavated part
Border -
Inf Surf -
Large Concave art surf (oblong part)
Deep groove
Smaller art surf
Narrow convex art surf -
Ant Surf
Convex
Post surf
Grooved
Ext surf
Larger art (heart shaped) pro for Malleolus Ext
Int Surf
Smaller art surf for Malleolus Int.
Fossa under it -

Ossification
1 Point which appears in the 5th or 6th M (C)

Cuboid (os Cuboides. Cuboideum) -

Number
2 viz 1 in each foot.

Situation
Ext side of Tarsus.

Connection
Ant with 4th & 5th Metatarsal
Post — os Calcis
Int with Ext Cuneiform & sometimes with Scaphoid

upper surface.

Post.

Post art surf
Int + Inf

Int.

Ant

Inf

Int

Post art surf

Ext

Ant.

Sup



Cuboid Cont.

Description

As shape resembles a cube

Sup surf

Rough inclined obliquely up & out.

Inf surf. (from behind forwards)

Irregular surf for Calcaneo Cuboid lig.

Transverse Ridge (Tuberosity) — — — — } lig. long & Plant

Depression* in front for tendon of peroneus long.

Ant surf

Smooth looks In & forw, divided into 2 parts

Int Part - square & articulates with 4th Metatarsus

Ext — Triangular — — — — — — — 5th — — — — —

Post surf

for articulation with os Calcis

Ext Border

Short & has a groove* contiguous to that on Inf surf

Int. Surf.

Rough part behind

Flattish, smooth, elongated surf for cuneiform bone

Rough part before.

Muscle

Part of Adductor Pollicis to Inf surf.

Ossification

1 { 1 Pt which appears at { some M after birth - Béclard
1½ or 2 Y — Blumenbach
in 8 M I.U.L - Meckel
at Birth — Cruveilhier

Scaphoid - Os naviculare

Number

2 - 1 in each foot.

Situation

Int border of foot

Connection

Ant with the 3 Cuneiform Bones

Post with — astragalus

Ext - often with the Cuboid -

ant end (Scaphoid)

Sup

Int

Post aspect

Ext

Int

Ant aspect

Int

Ext

Scaphoid Contd.

Description

Called Navicular &c. from being excavated (Boat)

Sup surf

is uneven

Inf surf & Inner Border

Tubercle for Tibialis Posticus

Ant surf

Convex with 3 art surf for Cuneiform bones

Post surf

Concave surf for head of astragalus.

Ext. surf

sometimes art for Cuboid.

Muscles

Tibialis Posticus – to Tubercle.

Assification (C)

1 Pt. –

Cuneiform Bones (Ossa Cuneiformia)

Number

6 – 3 In each foot.

Situation

Ant & Int part of Tarsus.

Connection

Ant with 1st 2nd & 3rd Metatarsal Bones

Post — Scaphoid

Int 1st is subcutaneous

— 3rd articulates ant with 2 metatarsus

Ext 1st ——— with 2 metatarsus

— 3rd ——— 4 ——— & Cuboid

Description

1st or Int. largest, Base or Broad surf downwards

2 or mid – smaller } Base ——— upwards

3rd ant with 5 bones

Muscles

Tibialis ant & Post to Base of 1st

Flexor Brevis Policis (Post) to 2 & 3rd.

Ossification

1 Pt for 1st ——— end of 1Y (C)

3 { 1 ——— 2nd 3rd } – – – – 4Y

Convex border Ext

Bases.

The sup corners of the bases point outward

Last to appear.
Venus-
2, 3, 4, 5th "

1st

7W (2 main)

2 or 3y

Meta-Tarsus

Number
10 – 5 in each foot.

Situation & Connection
Post first 3 to 3 Cuneiform
— other 2 — Cuboid
Ant to 1st Phalanx.

Description
1st Int – shortest, thickest,
Sup or dorsal surf look Int bound Ext by line –
Inf or Plantar — broader than in others
Post Extr. Oval concave surf broader above (Tubercle below)
Ant Extrem Convex – like a head – flattened sides & elongated from above down & (behind it a groove but marked on sup side)

2nd Longest.
Sup surf has line about mid –
Post Ext – Triangular ant. surf & is placed between 1st & 3rd Cuneiform as 2 Cunei is short.
Ant ie same as in 1st.

3rd smaller than 2nd
Post Ext – Triangular but smaller than in 2nd.
(same as 2nd otherwise)

4 smaller than 3rd
Post Ext – Cuboical Base Monoval. ant surf of

5th 1st same smallest. projects
Sup surf looks ant & is bounded Int by line
Post — Pyramidal –
Extremities of all are larger than Bodies
particularly Post Ext –

Ossification

10 { 1 Pt for Body of each — (3 M) 45 D Blumenbach Richard
1 Pt. — Ant Ext of 2, 3, 4, 5 — } 2 Y (C) appears
— Post — 1st — } 2 Y (C) appears
The Pt of 1st unites with the Body about a year before others } 18 to 19 Y (C) unite

At the 1st Joint of the Great Toe there are generally 2 Ossa Sesamoidea which increase the power of the Muscle by removing it farther from the axis of the Bone on which it is intended to act.

Convex sup
Concave inf.
Largest concave A & surf Post
Smallest Pulley —— Ant.

19 or 20 yrs

3 to 4 yrs

8 or in 2-3-4-5-1st Cart
(2 ossa)

Phalanges of the Toes.

Number

3 in each foot

5 Bones in 1st two 4 in last Phalanx or rather in 2nd

Articulation

1st with Meta Tarsus & 2nd

2nd with 1st Phalanx & 3rd

3rd —— 2nd ——

Description

1st Phalanx

Sup surf

Convex

Inf surf

Concave

Post Ext

Broadest – Concave

Ant Ext

2 projections with smooth surf between

Lat ~~Ant~~ surf at Extremities

2 except in first & last which have only one

2nd Phalanx – differ

Post Ext

2 Concave parts separated by prom line –

Ant Ext

2 small condyles like Post Ext of 1st

3rd Phalanx differs – only 4 Bones

More conical in shape

Post Ext

has art surf

Ant Ext

no art surf but rough point –

Ossification

			appear	unite
10	2	1 Pt for Bodies of 1st Phalanx	2 or 4 M of 1st Toe 50 or 60 D	16 Y
	1	—— Post Ext ——	4 Y	
10	2	1 Pt L Bodies of 2nd ——	nearly same as first	to
	1	—— Post Ext	6 or 7 Y	17 Y
10	2	1 Pt Bodies of 3rd –	45 D except 5th Toe which is later 1st is sooner	
	1	—— Post Ext —		


1
2
1
2
3
4
5
6
7

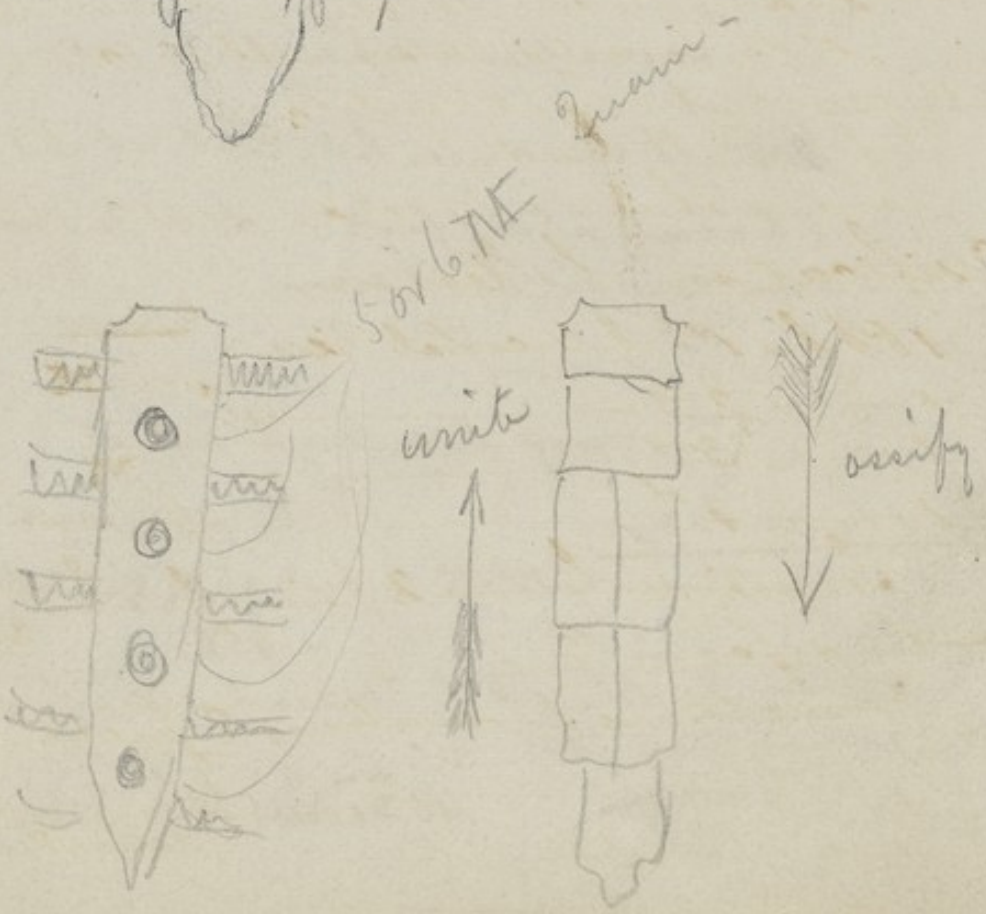
5 or 6 NE
unite
ossify

Sternum & Ensiform Cartilage

Number
1, generally composed late in life of 3 Bones. or 2.–

Situation
Median line - ant part of Thorax.

articulation
Laterally with the True Ribs
Sup angles — Clavicles
Inf with the Ensiform Cart

Description
Flat - Broad sup - & narrow inf - directed down & for-
ant surf
Slightly convex & subcutaneous
4 Transverse lines showing it was 5 pieces
These lines are each of the art pro in two so that
have the art pro of each rib is above & half below them
Post surf
Looks towards the Cavity of the Thorax.
Borders
Thick & have 7 angular depressions on each side
for articulation with the True ribs.
Sup Extremity
Broad & thick - concave in the middle & on each
side for articulation with the Clavicle

Ensiform or Xiphoid Cartilage
Inf part of Sternum -
Varies in shape & direction - sometimes has a hole in

Ossification of Sternum (C)

			appear	
4	1 Pt for 1st Intercostal Piece		5 or 6 M	unite last 20-25 Y
	1 ——— 2nd ———			
	1 ——— 3rd ———		6 M after Birth	second.
	1 ——— 4th ———			first

Sometimes there are 2 points for the Int. Cost. piece

— **Ensiform Cart** (2)
sometimes 1 & sometimes 2 pieces, appear 12 to 14 Y

Their Extremities are superior to their middle portion and their posterior extremities are above the anterior - 7 Ribs (deep) or Sternal & 5 false or asternal (Inferior)

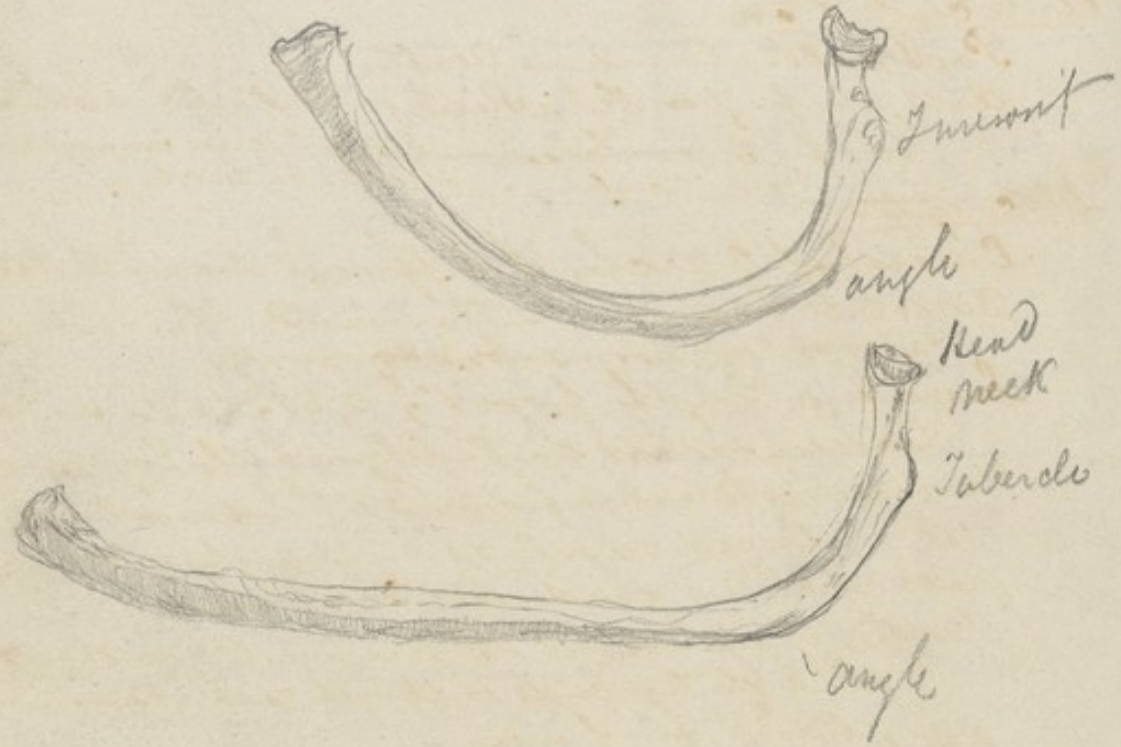

The Ribs - Costæ

Number
24 viz 12 on each side.

Situation
ant & lat parts of the Thorax

Articulation
Post with Lumbar Vert
ant, sup 7 or True Ribs with the Cart between } Sterno ribs
(Inf 5 or False — } 8th 9th 10 are connected with other by cartilage.
no articulation.

Description
Consist of 2 arches of different diameters ant larger
Directed backwards to Transverse Pro of Lumbar Ver then outwards & forwards & downwards
Increase in length from 1st to 8th Pair & then decrease so that the 12th is very little longer than 1st
× Decrease in Breadth from 1st to 12th but in all ant Ext greater
1st is placed nearly at Right angles with Vert Col.
Rest incline gradually downwards
Bodies of all except 1st are twisted on themselves so that the two ends will not rest at same time on a plain surface of themselves - ff

Ext surf
convex & smooth

Int surf
concave

× **Sup Border**
smooth & rounded

× **Inf Border**
Groove on inner side - sharp edged.

Post Ext
Thick & rounded & hence called the **Head**.
2 Art. surf separated by a slight ridge
Narrow part supporting the head called **Neck**
Terminating the neck externally is the **Tubercle**
smooth on one part for art with Transver Pro
Rough on another — attachment of ligts.

Ant Ext
Broad, flat & has oval pit for Cart.

Between the Tuberosity & the most convex part of each rib is a rough line marking the **Angle**
× The distance between the angle & Tuberosity increases from the 2nd to 11th
In the 1st it is not distinguishable in 12 not seen

Mature Adt
Mr Stocks

The Ribs

Exceptions

1st Rib.

Shorter & Broader & flat – & is placed horizontally

× { Sup surf – 2 slight depressions with rough Interval
Inf —— looks downwards & direct.

Ext Border convex & round & has tuberosity & angle

Int —— thin & concave

Ant Extremity broad & thick

Post. —— head small with undivided articular surface & neck is slender

2nd Rib.

Longer than 1st

Ext prominent line & Int grooved posteriorly

11th Rib Floating Rib.

× { has neither groove nor tubercle. Ant Ext. pointed.
angle hardly perceptible & Art surf undivided

12th Rib – Floating Rib.

Loose & unattached shorter than 11th.

Shorter than 11th has neither groove angle or tubercle head only single art. surface – Ant. Ext. pointed.

Ossification (6)

		appear	unite
3	1 Pt for the Body	40 to 50 D	about 25 Y
	1 —— Head	16 to 20 Y	
	1 —— Tuberosity		

(1) { In the 11 & 12 Ribs there is only 1 pt for the Body as they have neither head nor tuberosity


acromion
Spine
Superior Border
1st Rib
Supra Scapular Notch
Coracoid Process
Triangular Smooth surface over which the tendon of Subscapularis slides
Glenoid Cavity
Base or Post. Border
Inner
anterior Inf. Border
Outer
or
Axillary Border
Inf. angle
7th Rib

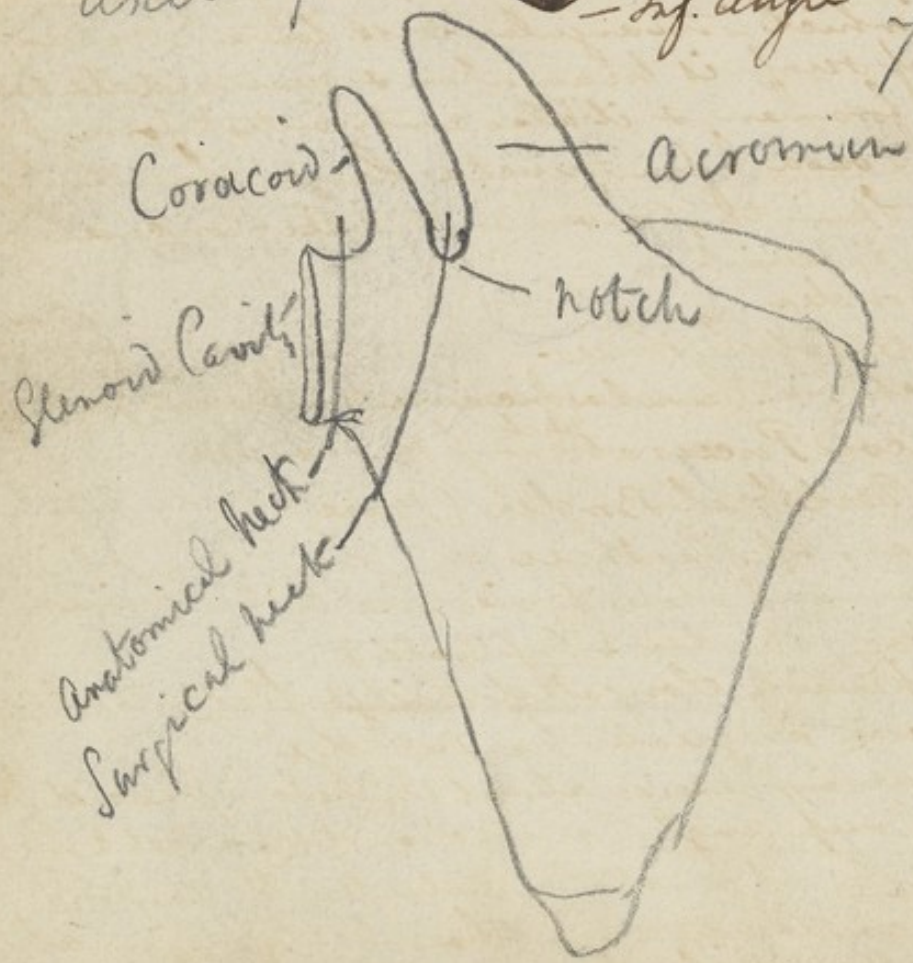
Coracoid
acromion
notch
Glenoid Cavity
Anatomical Neck
Surgical Neck

Scapula

Number
2 viz 1 on each side
Situation
Back part of Shoulder from 2nd to 7th Ribs
Articulation
By Glenoid Cavity with Humerus
— Acromion Pro — clavicle.
Description
Irregularly Triangular Base superior.
Ant surf - (Fossa subscapularis)
slightly concave.
marked by prominent lines directed out & up.
Post surf (Dorsum Scapulae)
Spine is a prominent ridge of Bone dividing the Scapula into 2 parts. rising at Post Border & projects across it outwards & up. terminating in the Acromion Process - it is flat from above down.. Ant surf for Clavicle -
Sup surf is Concave partly forms Fossa Sup Spin which is triangular - base towards median line
Inf surf is triangular & near middle has small foramen & it also contributes to form the Fossa Infra Spinata larger than the Supra Spinata, Convex in Middle - Concave or grooved Inferiorly -
Sup Border
Shortest of the three.
Notch viz: (Cumula; Incisura semilunaris) at Ext Part
Coracoid Process at Ext end of this border
(Int) Post or Vertebral Border (Base)
Longest of the three
~~Prominent where it gives rise to the Spine~~ - A H
(Ext) Axillary Border (Inf Costa)
Thickened by elongated Ridge flattened at Inf Ang
Groove on greater part of Edge
Linear impression about 1 In below Glenoid fossa
Postero-sup angle (at junction of sup & Post. Bord)
Inf angle at junction of Post & Axilly Borders.)
Neck constricted part bounded by a Rim at the junction of the Sup & Axilly Borders)

(Lucain)


16 y
14 y
In 1st year after birth
8 or 9 W
15 y
18 y.


Sternal end
Ant border
Fracture usually.
For Rhomboid Lig.
Largest convexity - Internal
Flat end to acromion
Ht
Italic Small.


30 to 35 D
15 or 16 y

Scapula — & Clavicle

Glenoid Cavity
oval, fossa formed at the Sup Ant Ext pt of Scapula articulating with the Head of the Humerus - greatest diameter is from above downwards & it is directed outwards & forwards

Ossification.

		appear	Unite
6	1 Pt for Body	2 M	15 to 16 Y when full grown
	(Spine grows from the Body in the 3 month)		
	1 Coracoid Process	at Birth or 1 Y after	
	1 Pt for Base of acromion	before 15 Y	
	1 ——— summit ———	15 to 16 Y	
	1 Epiph Inf Angle	~~15 to 16 Y~~	
	1 Epiph - Post Border Base	17 to 18 Y	last to join

Clavicle } Collar Bone

Number
2 viz 1 on each side
Situation
Sup part of Thorax
Articulation
with acromion Pro of Scapula & sup pt of Sternum
Description
acromial End highest -
Curved somewhat like the letter f most in Males
Sup Surf is Subcutaneous
Inf ——
Long depression, foramen, & rough line Ext. in the Centre
Int Extremity. Thickest part of Bone
Inclined down & forwards - Ends in triangular art surf
Convex from above down Concave Ant Post.
Ext Extremity
Compressed & flat - oblong art surf for acromion
Ossification
1 Pt which is one of the first to appear - 30 to 35 D
1 Epiphyses at ant Part of Sternal End - 15 to 18 Y

Anterior

Anterior Surface



Lesser Tuberosity — Ant & Int^l (Subscapularis)

Greater Tuberosity — (Supra spinatus, Infra spinatus, Teres minor)

Head

Neck (anatomical)

upper 1/3rd is Surgical Neck

Bicipital Groove (Pectoralis Tuberosity)

Ant Bicipital Ridge

Post. Bicipital Ridge

Int^l Bicipital

Cross Bracket form

Rough surface for insertion of Deltoid m.

Nutritious foramen down & outw.

Ant Hammock form

Inner Condyle

Outer Condyle

Rough Depression

Prominent ridge received into the sigmoid Cavity of Ulna

Wide groove (trochlea for sigmoid cavity of Ulna)

Olecranon fossa

Round eminence for Radius (Capitulum)

Styloid process

Semicircular Ridge

Humerus

Number
2 viz 1 in each Arm

Situation
upper part of the Arm

Articulation
Sup with Glenoid Cavity
Inf — Ulna & Radius

Description
Largest Bone of the Upper Extremity
Long & Irregularly cylindrical

Body
Twisted on itself
Thick & rounded superiorly - expanded laterally Inf
ant surf
Groove directed down & in for about 1/4 of the length of the Bone
Part internal to this groove presents near the middle a linear Elevation & lower down a foramen
Ext to the groove & a little above the middle of the Bone Rough Eminence & beneath it an oblique depression for Musculo Spiral nerve & accompanying artery -
Post surface
Round sup & inclined a little inwards -
Broad, flat, & turned outwards Inf
Small foramen near middle
Ext, Ant, longitudinal line
Rises from the Ext. Condyle
Int, Post, long - line
Rises from the Int - Condyle

Sup Extremity
Spherical Eminence called the Head
Separated by constricted part the Neck
Inf & Ext to the head are the Greater & lesser Tuberosities
Greater tuberosity
Ext & Post. Convex & has 3 flat surfaces
Lesser Tuberosity
Rounded & most prominent
Bicipital groove separates them

Posterior view

(2 main). 2y — unite 5 or 6y

2 1/2 y

20 y

30 to 40 D

outer Condyle 16 y

(Trochlea) 1 y

Inner Condyle 7 or 8 y

Ulnar articulation 12 y



Humerus

Inf Extremity

Presents Ant the Inner Condyle inclined back
Ext is smaller process the External Condyle
Between the Condyles is Inf Art. Surf
(Coming from the Radial (Ext) to the Ulnar side we see)

called the Trochlea
- A Rounded Eminence which art. with Radius
- Slight groove
- Semicircular Ridge lodged between Radius & Ulna.
- Wider deep groove receiving the prominent part of the larger Sigmoid Cavity of the Ulna
- Prominent Ridge* received into that cavity.

above the Trochlea Ant is Superficial Depression which receives the Coronoid process of the Ulna during flexion
Posteriorly a larger fossa which lodges the olecranon during extension of the forearm

Ossification (C)

			appear				Unite
1	1	1 Pt for Body	30 to 40 D				
2	1	Head	beginning of 2Y			9Y	18 to 20 Y
	1	Grt. Tuberosity	24 to 30 M				
7	1	Ext Condyle	2½ Y				
4	1	Trochlea	7Y		2Y	16Y	
	1	Int Border of Trochlea	12Y				
	1	Int Condyle	16Y				

The Sup Ext appears first but the Inf — unites —

*So called from the old Greek Sigma C not the modern S


Glenoid Cavity for articulation of Humerus
Coronoid Process
Olecranon Process
Lesser Sigmoid Notch articulates with Head of Radius
Greater Sigmoid Notch
Smooth Border of Radius for Orbicular Lig.
Nutritious Foramen
Neck
Tuberosity for Tendon of Biceps
Ext. Radius
Ulna Int.
Sharp Edges for Interosseous Lig. mech.
Oblique line
Styloid Process
Styloid Process
Int. lat. lig.
Ulna
Ext. Scaphoid
Semilunar
Int.
Ext.
carpal end of Radius
Ant.
Foramen Nutritium in Foramen directed upw.

Radius

Number
2 viz 1 in each arm

Situation
Ext side of the Forearm

Articulation
Sup with Humerus
Int. (Sup & Inf) with Ulna
Inf with Scaphoid & Semilunar

Description
Shorter than Ulna by length of Olecranon Process.
Broader below than above. & is slightly Curved
Body is somewhat triangular.-
Ant surf.-
× Longitudinal groove along middle
× Foramen - superior part. directed up
× Flat surf - broad - Inf.
Post surf.-
× Convex in greater part of its Extent
× Grooved at its central third.-
Ext surf
× Round & convex
× Rough impression towards middle
Post margin distinct only at the middle part
Ext _____ round - gets smooth inf
Int _____ acute & sharp for Int Oss. lig
Bicipital Tuberosity at the Sup Ant Int pt of Body
Neck is constricted part above this Tuberosity
Head is larger part above Neck
" Margin is smooth & convex & rolls in lesser Sigmoid Cavity of the Ulna
" Upper surf smooth & concave for (small head of) the Humerus-
Inf Extremity.
Ant surf flat & expanded bounded by a Ridge for the Ant lig of Wrist joint.
Post surf convex & has 1 narrow & oblique groove near middle line - 1 Int to this broader & 1 Ext divided into two by a linear impression
3 grooves
another groove directed obliquely forwards at Ext Border & divided into 2 parts.

2mai



Radius & Ulna

Ext surf is prolonged downwards & named the Styloid Process for Ext lat ligt.
Inner surf is the Semilunar Cavity
Inf surf has Ext Triangular surf for Scaphoid
——— Int Square ——— Semilunar
——— line - Ant Post. dividing them
——— Rough margins - bounding them (before behind)

Ossification		appears	unite
3	1 Pt for the Body	35 D	12 Y
	1 ——— Sup Ext	9 Y	18 to 20 Y
	1 ——— Inf	12 Y	

Ulna (Cubitus)

Number
2 viz 1 in each arm
Situation
Inner side of the Fore arm
Articulation
Sup & ext with the Humerus
Ext - sup & inf with Radius
Inf (by inter art fibro cart) with cuneiform Bone
Description
Long & rather irregular - sup End largest
Body has 3 surfaces & 3 lines
ant surf
Slightly depressed - Grooved longitudinally
Foramen at upper 3rd directed upwards
Int surf
Smooth & slightly excavated superiorly
Round & subcutaneous — inferiorly.
Ext surf
Rough & irregular & is divided into 2 parts sup is the smallest.
Int & Post Borders are rounded & pretty smooth
Ext Border is sharp for int oss. lig.

Int. View of Ulna + Atl.

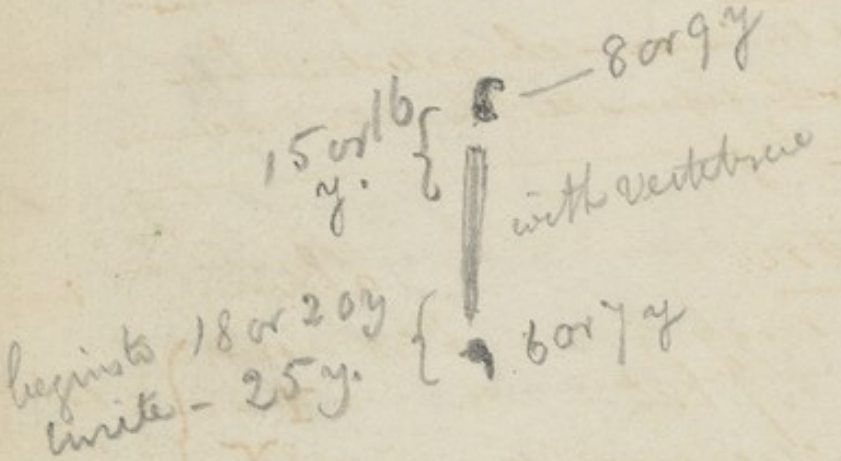

Ulna (Cubitus French)

Sup Extremity

Olecranon Process - is nearly on a line with the shaft of the Bone

ant smooth & hollowed out

Post flat, triangular surface, subcutaneous

Terminates in a rough tuberosity & an obtuse point

Coronoid Process

Rises up & forwards from ant surf.

Terminates in a sharp ridge received into ant depression of the Humerus during flexion

ant surf rough & triangular

sup smooth & excavated

Smaller Sigmoid Cavity

is a smooth depression on Ext Border which articulates with the head of the Radius -

Σ Great sigmoid Cavity

is in both surf between the two processes

smooth ridge divides it into 2 parts Int larger

2 notches at the margin separating the olecranon from the Coronoid process -

Inf Extremity.

Head

External Eminence - round & has 2 aspects

Inf aspect. circular

Ext ——— narrow & convex is received into the semilunar cavity of Radius -

Styloid Process

Internal Eminence - elongated in shape

* Groove Post separates the two Processes

Depression Inf ———

Ossification (6)

			appear	unite
3	1	Pt for the Body	35 to 40 D	18 to 20 Y
	1	——— Inf Ext	6 Y	15 to 16 Y
	1	——— Olecranon Pro	7 or 8 Y	

Hand *Manus*

1st Carpus

1st Range
- Scaphoid — 8 y.
- Semilunar — 5 y
- Cuneiform — 3 y.
- Pisiform — 12 y

8 in all

2nd Range
- Trapezium — 5 y
- Trapezoid — 8 y
- os magnum } 12 y.
- Unciforme }

2nd Meta carpus

5 { 1st 2nd 3rd 4th 5th

3rd The Fingers

14 {
- 1st Phalanx 5 Bones
- 2nd ——— 4 ———
- 3rd ——— 5 ———

Sup aspect

Sc, Lu, Cu, pi

Tr Tz osm. un.

Sclercupi
Tratrosmum

Scaphoid (Boat shaped)

Number
2 viz 1 in each hand

Situation
1st or Ant & largest of the first Row of the Carpus.

Articulation
5 { Post with the Radius
ant ——— Trapezium Trapezoid & O magnum
Ext ——— Semilunar.

Description.
Has 4 articular surfaces.
Concave or Scaphoid surf looks form & In. for O magn
Sup surf - largest, convex for Radius
~~Post~~ inf - convex & ~~prominent~~. ant inf Ext
~~Ant~~ Ext & sup - small & flat. for Semi lunar

Ossification
1 Pt which appears at 8 or 9 Y (C)

Semi-lunar Bone

Number
2 viz 1 in each hand

Situation
next the Scaphoid in the Carpus. 1st Row

Articulation
Sup with the Radius
Inf ——— O magnum & uniformis
Ext ——— Scaphoid
Int ——— Cuneiform

Description
4 art. surfaces
Sup - convex
Inf — concave
Ext — flat
Int — — also
+ Ant end largest.

Ossification
1 Pt which appears at. 4 to 5 Y (C)


Sup aspect
Ulnar Int art Cart
semilunar
Pisiform
unciform
Ad


art surf for Unciform


Sup aspect
cuneiform
Ad


(art surf)

Cuneiform. Wedge shaped
Pyramidalis

Number
2 viz 1 in each hand
Situation
1st Row of the Carpus
Articulation
sup with Lt art Cart of Ulna
Inf — uniform
Ext — lunar
Ant — biniform
Description — Wedge shaped base out apex in
4 art surfaces —

Ossification
1 Pt which appears at. 3 to 4 Y (c)

Pisiforme Pea shaped

Number
2 viz 1 in each hand
Situation
Ext part of 1st Row of Carpus.
Articulation
Post with the Cuneiform
Description
Like a bay pea
Ant convex,
Post flat art surf.

Ossification
1 pt which appears at 12 to 15 Y (c)

Sup Surf.

Sup surface.

Trapezium

Number

2 viz 1 in each hand

Situation

Ext bone of 2nd Range of Carpus –

Articulation

4 { Sup to Scaphoid
Ext — metacarpus of thumb
Int — Trapezoid
Inf — metacarpus of fore finger –

Description

Deep groove ant. & a tubercle
Sup — concave surf for Scaphoid
Int — ——— — Trapezoid
Ext large ——— from above down convex ant post for metacarpus of thumb
Inf very small ant surf for pt of M.C. of fore finger

Ossification

1 Pt which appears at – 4 to 5 Y (C)

Trapezoid

Number

2 viz 1 in each hand

Situation

In 2 range of Carpus –

Articulation

4 { Sup with the Scaphoid
Inf ——— metacarpus of fore finger
Ext ——— Trapezium
Int ——— Os magnum –

Description

Broadest; smooth & convex behind
Has 4 art surfaces all connected
Sup
Inf
Ext
Int

Ossification

1 Pt which appears at. 8 or 9 Y. (C)

Sup aspect

Inf aspect

Os-Magnum

Os capitatum

Number
2 viz 1 in each hand

Situation
2 Range of Carpus -

Articulation
7 { Sup - with - Scaphoid & lunar
Inf - —— - 3 middle metacarpal bones -
Ext - —— - Trapezoid
Int - —— - Unciform

Description
Round Eminence or head superiorly -
Has 6 art surfaces -
Ext for Trapezoid
Int —— Unciform
Inf concave surf.
" Outer edge smaller } metacarpus - { 3rd, 4th, 2nd
" Inner ——

Ossification
1 Pt which appears at end of first Year (C)

Unciform

hook shaped

Number
2 viz 1 in each hand -

Situation
Ext of 2nd Range of Carpus -

Articulation
5 { Sup with the Cuneiform & semilunar
Ext —— os magnum
Inf —— metacarpus of ring & little finger

Description
Large process on ant int Edge
4 art surf
Int —— large oblong - for Cuneiform
Ext —— for os magnum
Inf two divided by a ridge - outer smallest -

Ossification
1 Pt which appears at end of 1st Year (C)

A.H.

A.H.

A.H.

Exit Vein

A.H.

A.H.

Order of Development = 2 min

3 - 2, 4, 5 - 1st & last.

Meta Carpus

Of the Thumb.

Articulation with Trapezium Sup

Description

resembles 1st Phalanx of fingers –
Shortest, placed obliquely on Carpus
same breadth throughout – Sharp Edge laterally
art surf on Base large – convex lat. – concave ant. – post –
Head slightly convex ant Post – flat laterally –

Of the First Finger –

Articulation

Sup with Trapezium Trapezoid & Os magnum
Int — metacarpus of 2nd finger –

Description

Basis has 3 art surf divided by 2 edges { outer smaller / mid – largest
1 art surf immediately below the Inner one for that of 2nd finger

Of the Second Finger –

Articulation

Sup with the Os magnum
Ext — metacarpus of 1st finger
Int — 3rd —

Description

It has 3 art surf { 1 large at end on Basis / 1 Ext surf concave / 1 Int — for 3rd finger.

Of the Third Finger

Articulation

Sup with Os magnum & Unciform
Ext — metacarpus of 2nd finger
Int — 4th —

Description

Basis has 2 art surf { small Ext & upper Part / large Int
1 art surf on each side for meta Carp of 2 & 4th fingers

Of the Fourth or little Finger –

Articulation

sup with os unciforme
Int — meta carpus of 3rd finger

Description

Base has one Squarish art surf
1 art surf Int for neighbouring meta carp –

Ossification (8)

		appears	unite
	1 Pt for Body of each	40 to 50 D	18 to 20 Y
2	1 — Int Ext of 2, 3, 4, 5th	20 or 3 Y	
	1 — Sup — of 1st		

at the Root of the 1st. Phalanx of Thumb
there are usually 2 Ossa Sessamoidea

3 by
40-50 D

Phalanges Digitorum

Number — Fingers

28 in all viz 14 in each hand

Situation

Fingers & Thumb

Articulation

1st Phalanx with Metacarpus
other two with those behind –

Description

1st Row. consists of 5 Bones –

Base – Concave, oval length from side to side

Head – Pulley surf Concave laterally convex from above down

Body of all Round behind – flat before & 2 projecting lateral edges for attachment of sheath of tendons –

2nd Row

Wanting in the thumb – Consists of 4 Bones

Base, Concave laterally, deepened in middle by a lip ant & post with a ridge between making 2 parts

Body smaller than 1st

3rd Row. Phalanges Unguium (Semm)

Consists of 5 Bones

Bases same as in 2nd

Head or rather apex expanded, thin, rough & pumice

Ossification (C)

		appear	unite
1	1st for the Body	40 or 50 D	18 to 20 Y
2	1 ——— Sup Ext	3 to 7 Y	

The point for the Sup Ext appears in the 3rd Phalanges before than in the 2nd Phalanges – (C)


Groove for Post Part of sup. Long.l Sinus
Int. Occip.l for Trocalar Mastoids
Cerebral Fossa
Groove for Lat.l Sinus
Spine for Falx Cerebelli &
Groove for occip.l Sinus
Cerebellar Fossa
Termination of Groove for Lateral Sinus bounded Ext by Jug.r Emin.ce
Jug.r Em.ce
Basilar Process
Jugl.r Fossa articulates with Petrous P.t of Temp.
Sup Curved Line
Occipital Protuberance
Spine
Inf Curved Line
For.n magnum
Condyles
Part of Jugl.r For.
Ant Condy.d For.n for Hypoglossal nerve
For Odont.d Lig.ts
Basilar Process
Protuberantia Occipitalis Externa
arcus transversus superior
inferior
Spina occipitalis
Sulci occipitales
Foramen magnum
Processus Condyloides
Foramina Condyloidea anterior
Posterior
Processus Basilaris
Part of For Lacera Post.
Spina Interna
Transversa
Protuberantia occ. Interna
sup occipital fossa
Inf
Grooves
Basilar Groove
Fossa Normiana
angulus occipitalis

Os Occipitis – Occipital Bone

Number

1

Situation

Post & Inf part of Skull

Articulation

6 { Sup Border with the 2 Parietal
Inf ——— ——— 2 Temporal
By Basilar Process — Sphenoid
— Condyles —— Atlas.

Description.

Part – Convex – External
Ant – Concave – Internal.
Irregularly Hexagonal – length above trapezoid down
Ext surface – (Convex)
—— Occipital Protuberance – rough – about centre of Bone
..... Sup Curved line from Protub to the Borders.
—— Inf ——— below Sup Curved line
—— Vertical line crosses the other from Protub to For.
—— Occipital Pits – just below Inf Curved line
—— ——— foramen – Inf – oval length ant Post.
Condyles Art Proc on each side, ant of for Mag.
They are irregularly oval, length ant Post face down
out & back – ant & inner edges deepest – Convex
2 Fossae at ant & Ext part of Condyles
..... 2 Foramina in the fossae (rough) look ant & forward
2 larger Fossae behind these Condyles –
..... 2 Foramina generally in them –
..... Basilar Process in front
Ridge on each side but Post to Basil Pro.
..... Part of For. lacera, Post on each side but Ext to Condyles.

Int surface – (Concave)

..... Vertical line
..... Transverse line
..... Int Occipital Protuberance where the lines cross –
..... 2 fossae above Transverse line
—— ——— below ———
Grooves on the lines – Inf for Falx cerebelli
? + Do on ant Border of Basil Pro – continuous with
Basilar Groove which supports the medulla oblongata

Sup Border

Rough & have often Bony Islets – Ossa Triquetra Wormiana

Superior Angle

at junction of 2 sup Borders – it is acute ?

2 little points of Bone on Int Surf – towards Border

(Quain)

1st. Developed (as soon as Dent) Part behind — anguli parietales

2d. Basilar Part

3. Condyloid Part — anguli temporales

union — angulus sphenoidal

3 to 4 y. Condyloid to Basilar Part

5 to 6 y. Basilar unites.



Inner Surf

Os Occipitis

Inf Border
Occipital eminence at each side
Excavation just under it forming fossa of jugular fossa
2 Sup Lateral Angles
at junction of Sup & Inf borders - are obtuse
2 Inf angles
1 Sphenoidal angle
3 Margins -

Ossification

		appears
4	1 Pt for Body or Post Part about middle of 2 DL	
	1 —— each lateral part.	
	1 —— Basilar Process in median line at 2½ DL	

Ossa Parietalia - Parietal Bones

Number
3 - viz 1 on each side of the Skull

Situation
Sup & Lat parts of skull forming the apex or vertex

Articulation
with fellow on opposite side
ant with the frontal
Inf —— Sphenoid & temporal
Post —— occipital

Description
of an irregularly square shape / quadrilateral
Ext Surf
Parietal Elevation - where pieces join above mid
Curved line below it for Temporal Fascia
Flat surf
Foramen Parietale at sup & Post border
Int. Surf
Parietal fossa towards middle
Groove for longitudinal Sinus Sup Border
Little Pits for the Glandulae pacchionae
Groove with ramifications for mid, meningeal artery begins at ant point of Sphenoidal angle
Groove at post part of Sent and angle for part of Lateral Sinus.
4 Borders - Post. Convex - Sup Convex
Ant Concave - Inf Concave
nearly flat -

45 D.

External Surface

Sup. Coronal Border

Frontal Eminence

Temporal Ridge

Pt. of Temporal fossa

Superciliary Ridge

Supra orbital Ridge

Supra orbital notch for

Nasal Tuberosity

Int. Ang. Pro.

External Ang. Process

Nasal Spine

Internal Surf.

Grooved Ridge for lodgement of Sup. long Sinus and attachment of Falx

Orbital Plate

Ant. and Post. Ethmoidal Foramen

Depression for lachrymal Gland

Supra orbital notch

Ethmoidal Tissue

Depression for pulley of Sup. oblique muscle of Eye

Foramen Cecum

Opening of Frontal Sinuses

Ossa Parietalia

4 Angles
ant sup — angulus frontalis — sharp
Post — — occipitalis —
ant Inf — — Sphenoidalis } Truncated
Post — — Temporalis }

Ossification
1 Point at Parietal Protuberance at. appears 45 D (6)

Number **Os Frontis** - Frontal Bone, Coronale

1

Situation
Forehead

Articulation
Sup — 2 Parietal
Post + lat - Sphenoid
Inf — Ethmoid
12 By nasal spine — 2 nasal bones
+ with the 2 Ossa unguis
+ — ascending process of Sup Max
+ — the 2 malar Bones

Description
Composed of a perpendicular + a Horizontal Part.
Ext Surf
Convex + smooth
Frontal Eminence on each side.
Arched depression below this.
Superciliary ridge —
Orbital arch —
* Ext angular Process is outer part of the Arch
Supra orbital foramen at Inner third —
Notch sometimes also —
Nasal Eminence between the Sup. Cil. Ridges
Rough surf for nasal bones + sup maxilla
Spine, thin projecting pro in median line
* Int angular Pro at Inner part of the Arch -

The orbital plates are thin & translucent.

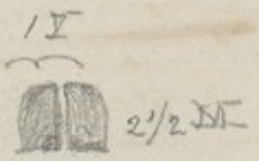



a fence dump before occip & Parietal (Crenum)

Os Frontis

Int Surf
Concave
Groove in Median line - forming a Ridge Ant.
Foramen Coecum at end of Groove
Orbital Plates lamellae orbitales.
Smooth & concave inf. - Convex & rough sup
Incisura Ethmoidalis separates them
Ant orbital foramen } in the margin
Post ——— }
× Depression or Spina trochlearis near Int Ang. Pro
——— (fossa lachrymalis) near Ext Ang. Pro
Frontal sinuses seen in a dult.

Ossification appear unite
2 Lat pieces at 2½ M unite in the 1 Y (6)
at frontal Eminences

Ossa Temporum

Number on which the hair first turns white
2 viz 1 on each side of the Skull
Situation
In the Inf - Mid & Lateral Part of the Skull
Articulation
7 { Parietal sup border of Squamous part.
Malar by malar process of Zygoma
Inferior Maxillary by glenoid fossa
Sphenoid - By ant part of Squamous portion & apex of Petrous
Occipital. — Post sup of Mastoid part.
Description
Squamous (or Scaly) part.
Ext surf - smooth & forms part of Temporal fossa
Bounded above by Convex border - below by Zygom
Inner surf - Concave - has cerebral impressions &
arterial grooves - Upper Border - Scaly -
Zygoma - Joins the Temporal & Malar Bones together
Broad at Base but soon narrows - turns out & forward
Ext surf - Convex & subcutaneous - Int surf concave & bounds Temp Fossa
Sup margin thinnest & longest
Inf ——— forms border of Glenoid Cavity & has 2 Roots
1 Root runs horizontally post forms outer margin of G. cavity
——— ——— Inwards & forms ant Border.

External Surf.

Internal Surface



Temporal Bone

* Tubercle at junction of Roots for Ext lat lig of lower jaw
Fossa Temporalis - Pulley between Roots & Scaly part.
Shell shaped — Glenoid fossa - elongated from out inwards. above downwards
Fissura Glaserii divides fossa into 2 parts - Ant Tym Cavity
Eminentia Articularis - between Tubercle & Malar Process
Processus Malaris - terminates the Zygoma -

Mastoid Part - (nipple shaped)

* Digastric fossa behind the
Nipple shaped — Mastoid process - part prolonged downwards.
* Groove for occipital artery between biggest groove & edge
Large fossa — Groove on inner side curves forwards & downwards -
* Foramen Mastoideum opens from out surf into lateral Sinus

Petrous Part. (stony or hard part).

Is a Triangular Pyramid projecting forwards & Inwards.
Ext orif of Ear — Meatus auditorius Externus - Canal in Base
Auditory Process - a curved uneven lamella bounds it inf.
Apex - truncated & forms part of foramen lacerum medium
* Carotid canal - Commences at the Inf surf of the Bone Ant to Jugular fossa - ascends first perpendicularly & then forwards & Inwards & ends in the Apex.
Ant surf A — Groove at Ant surf of Apex for Ganglion of 5th Prof nerves
a Hiatus Fallopii narrow groove runs back & out.
Rounded Eminence little further back showing situation of the superior semicircular Canal.
Aqueduct of Fallopius - begins at Int Aud Meatus as a small aqueous tube in Interior of Bone arches first out & up & then back & down & ends in Stylo Mastoid foramen * 7

Post surf B — Meatus auditorius Internus large orifice at Post surf leading to - directed out & forward
B — Lamina Cribrosa divided by a Ridge forms it fundus
Foramen at upper part
several small apertures at lower part
Behind Meat. Process C — Narrow fissure the Termination of Aqueductus Vestibuli
a — a little further back than orifice of Meatus - Post inferior
d — Irregular depression for a small process of the Dura
Meatus between them. & above them.
Inf surf — * Rough surf on Inf part. for Levator Palati & Tensor Tympani
* Carotid foramen or Hole opening to Carotid Canal -
D — Jugular fossa.
Sometimes divided by a spicula of Bone
Styloid Process directed down & forwards - Ext to fossa -
Vaginal Process - compressed bony plate
* 7 — Stylo-Mastoid Foramen between the Styloid & Mastoid Part is Termination of aqueduct of Fallopius transmits Portio Dura and nerves thro Hiatus Fallopii - the Tympanic nerve
* 6 Sup border — Groove for Petrosal Sinus -



Remains.

3 to 4 m
1 Zygoma – a little before Vert.
2 Squamous Ps. with Vert.
3 Annulus Auditus a little later.

18 to 20
4 Petrous Ps. from which is formed the Mastoid – but which has sometimes 2 pts for itself
5 Styloid.

Temporal Bone.

ant. Border Orifice of the Eustachian tube in the angle at junction of the ant Border & Squamous Part.
*1 assess tube for Tensor Tympani muscle, just above it.
* Processus cochleariformis - thin horizontal lamella between them
Post Bord * Small foramen opening of aqueductus Cochleæ about the middle of the Posterior Border

Ossification

(6)

		appears	Unite
5	1 Pt for Squamous Portion	end of 2 M	1st Y
	1 — Petrous —	shortly after	
	1 — auditory Process		
	1 — Mastoid Part	5 M	3 to 4 Y
	1 — Styloid Process		

Sphenoid Bone

Number 1 Wedge shaped

Situation
Transversely at Base of the skull -

Articulation
12
Post with Basilar Process of Occipital
ant — Ethmoid
By Alae with Orbital Process of Frontal
By great alae with ant inf angles of 2 Parietal
— — Squamous portion of 2 Temporal
By Rostrum — Vomer
— Ext Bord of Orbital Plates with the 2 malar Bones
By Pterygoid Process with the 2 Palate Bones -

Description.

Body has 6 aspects -
sup surf Pituitary fossa or Sella Turcica on Sup Surf
Depressed surf corresponds with Cavernous sinus on each side of the Fossa
2 Grooves farther back from behind forwards for Internal Carotid Art
Slightly depressed part, before the fossa for commissure of the Brain
Lamella of square form behind it.
Post. Clinoid. Processes. are the Corners of this lamella
ant — behind Sella Turcica
before —

¶ Optic foramina are for Optic Nerves and Ophthalmic artery which lies between and external to the nerve and is not accompanied by the gein.

Round or Sup. Maxillary For. transmits the Sup. Maxillary nerve 2nd of 5th

Oval or Inf. ——— Inf. ——— ~~[illegible]~~

Spinous foramen transmits middle Meningeal Artery. 3rd of 5th

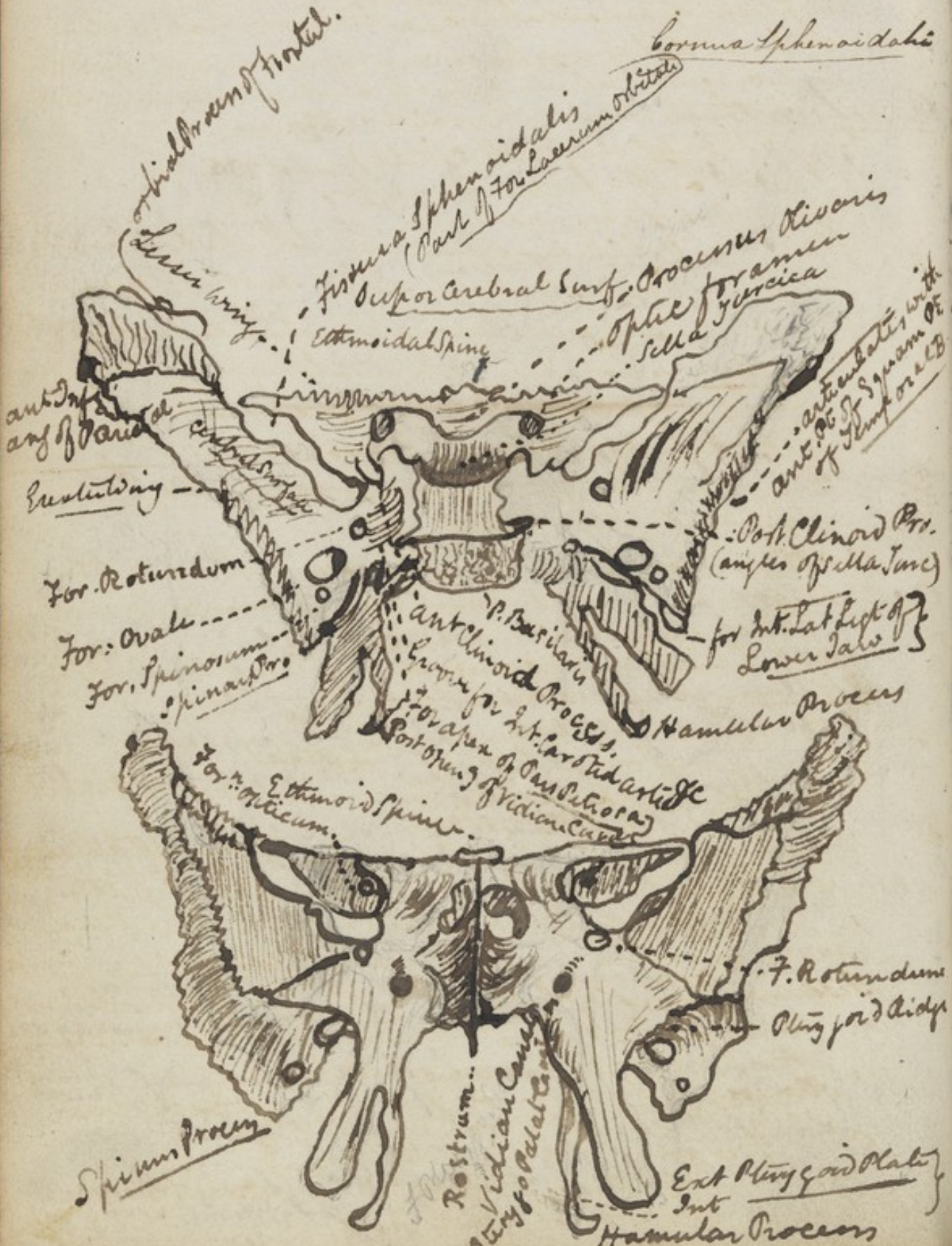

Sphenoid Bone

Inferior Rostrum or Azygos Process - a prominent spine with very
2 Lamellae on each side
Groove ext to lamellae which with the head of the Palate Bone contributes to form Pterygo Palatine Canal
anterior Sphenoidal Sinuses
(do not exist in young children)
Septum Sphenoidale - a partition separating them.
—— Sphenoidal Spongy Bones cover sinuses in ant. but leave a circular aperture by which they communicate with the Post Ethmoid cells.

Great Wings - (Alae Majores)
Project out - forwards - up.
Have 3 surfaces each
1st Ant - or Orbital - square - smooth - looks forwards
2d Sup. - Cerebral - larger - length - ant Post. concave -
3d Ext — Temporal - concave —— above down - divided by Ridge - so that upper pt. larger & forms part of Temp Fossa & inf & smaller — of Zygomatic fossa

Small Wings - (Alae Minores) or Wings of Ingrassias
triangular - horizontal & extend forwards & outwards -
Upper surf plain & flat.
Ethmoidal Spine - angular process on - Sharp between them ant Border,
Post Border - Rounded - smooth & free - corresponds with Fissura Sylvii
Ant Clinoid Processes are Post Ends of these Processes [Wings]

Pterygoid Process consist of -
Pterygoid lamellae
—— fossa between lamellaae
Hamular or hook like Process - at end of the longest thinest & ant lamella
Fossa Navicularis - depression at Root of ant lamella
Angular interstice between the lamellae is filled up by part of the Pyramidal Process of Palate Bone
* Processus olivaris - small elevation ~~between optic foramen~~
Fissura Sphenoidalis - triangular, elongated - between the less & greater Wings - opens into orbit - hence named sometimes Foramen lacerum orbitale
Narrow Plate of Bone separates it from For Opticum & gives attachment to Recti Muscles of Eye
Optic Foramen - inclines out & forwards
Foramen Rotundum - Round - behind Optic F. in Gt. Wing -
—— Ovale - Oval - more Post & Ext. very large
Spinous Processes Project at Post angle of Great Wings -

Mr Lewis

unite some w a few bits { Ent Wing & Ext Pterig - 40 D
2 Pc in Post Part of Body 50 D

These unite

1 Int Pterygoid
unites to Ext 5 SS

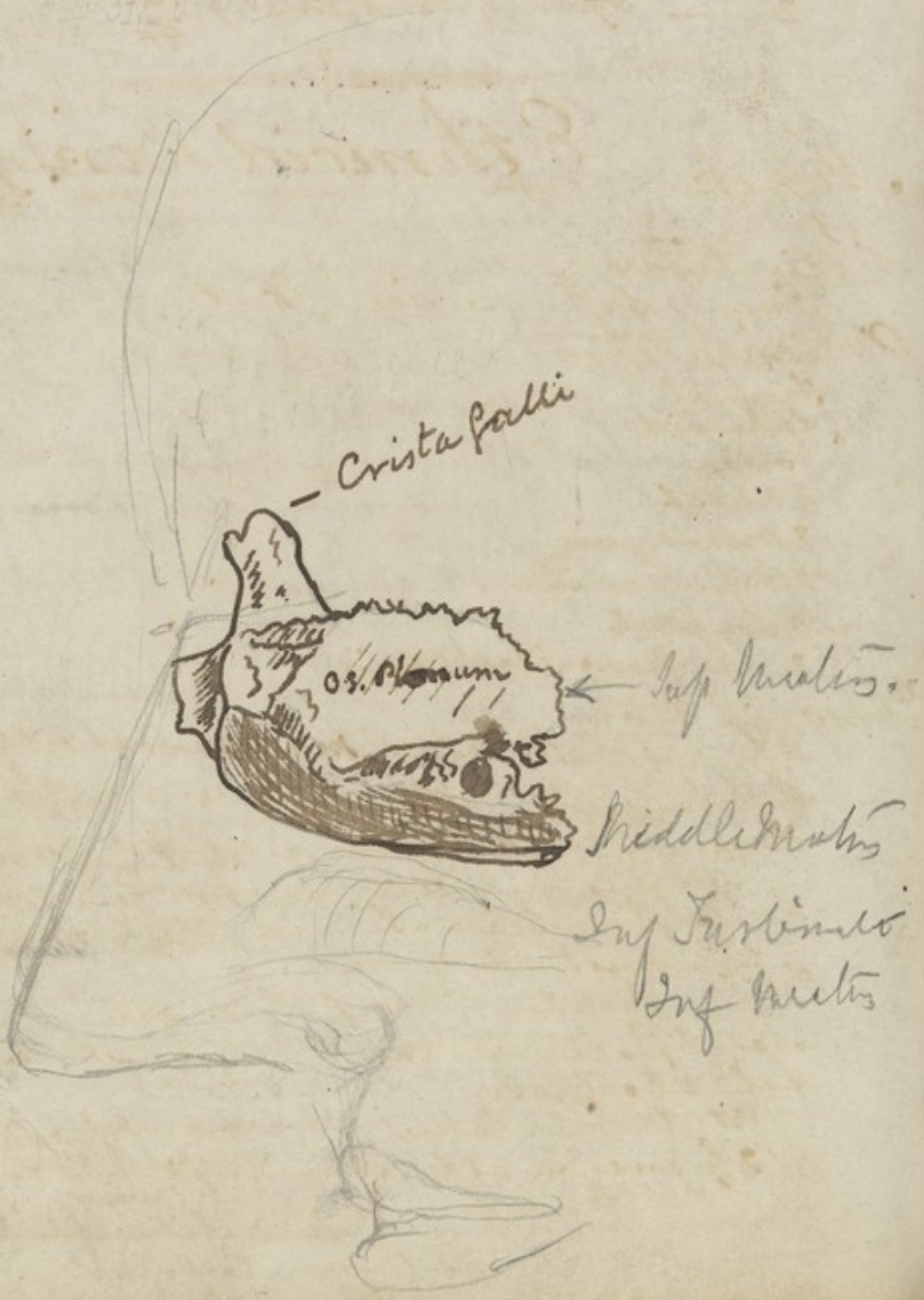

Sphenoid Bone

Foramen Spinosum - small - near post angle of the ala
—— Pterygoideum - circular - at Base of Pterg. Pro.

Ossification

(6)

			appear	unite	
12	2	Pts for Ant Part of Body	end of 3 M	8 or 9 M	8 or 9 M
	2	little Wings	about 50 D	3 or 4 M	
	2	Sella Turcica	end of 2 M	3 or 4 M	
	2	Great Wings	40 to 45 D	5 or 6 M	
	2	Ext Pterg.d lamellae	about 4 M	6 M	
	2	Spongy Bones (Cornets)	7 M Beclard 2 Y Bertin	----	15 or 18 years

Ethmoid Bone

Number 1 — Sieve shaped

Situation
Forepart of Base of the Skull

Articulation
13
- Frontal
- Sphenoid
- Vomer
- 2 Nasal
- 2 Ossa Unguis
- 2 Sup. Maxillary
- 2 Palatal
- 2 Inf. Spongy (Lachrymal)

Description
Composed of 1 lateral mass on each side of Vertical Plate
Crista Galli - triangular process on the Superior of "
Foramen Cæcum fissure sometimes between 2 Bony Masses - in middle line when this bone joins Frontal
Cribriform Plate - behind crista - pierced with holes for Olfactory Nerves
2 Grooves beside the Crista.
Perpendicular or Nasal Plate. ant.
Nasal fossae separated from lateral masses.
Lateral Masses
Os Planum lateral or orbital Surfaces
2 Grooves on upper Margin which with the Grooves in the Frontal Bone form { Foramen orbitarium Internum Ant / Post.


Cribriform Plate
crista Galli
os unguis
Lateral maps
Sup. Jaw Bone
mid. Jaw Bone
central lamellae

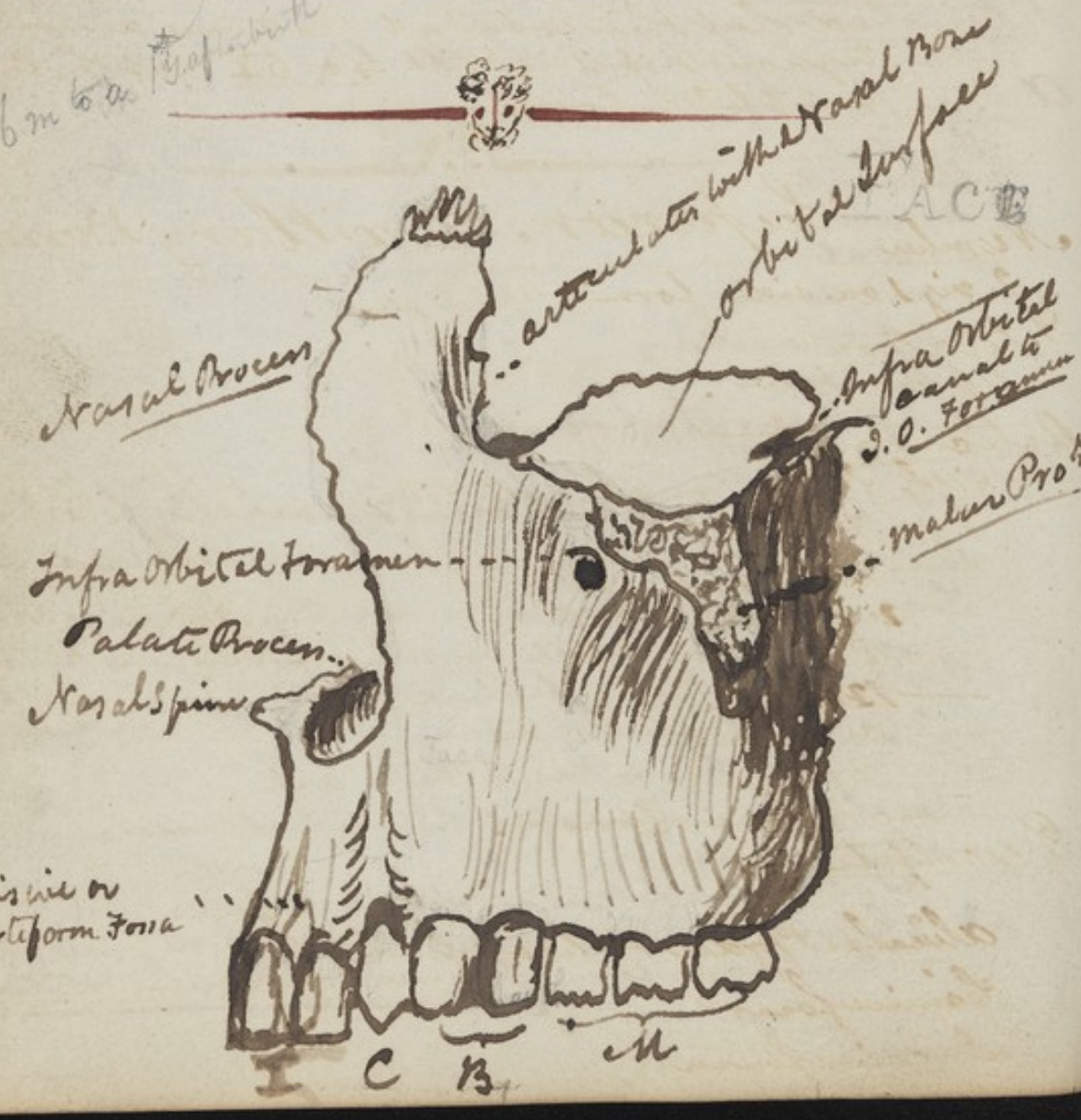
articulates with the nasal bone
orbital surface
Nasal Process
Infra Orbital canal to I. O. Foramen
malar Proc.
Infra Orbital foramen
Palate Process
Nasal Spine
Incisive or Myrtiform Fossa
C
B
M

Ethmoid Bone.

Sup Turbinate Bones
Mid. ——— ——
Meatus naris superior - formed by the Curve of the Sup Turbinate Bone & communicates with
Post Ethmoidal Cells - 4 or 6 in number
Meatus naris inferior - by curve of inf Turb. Bone & communicates with -
Ant Ethmoidal Cells -
Infundibulum

Ossification

	(b)	appear
3	1 Pl for Each Lat. Mass	5 M
	1 —— Perpendicular Plate	6 M to 1 Y after birth

As Birth the lateral Masses are so little developed that their Ext & Int Plates are almost contiguous & it is not till 4 or 5 Y that the Cells are completely formed -

Superior Maxillary Bones.

Number
2 viz 1 on side forming upper jaw.
Situation
upper jaw.
Articulation
with fellow on opposite side.
— Frontal
— Ethmoid
— Nasal
— Palate
— Malar
— Os Unguis
— Vomer
— Inferior Spongy.
Description.

Alveolar Border & Alveoli for Teeth.
Canine fossa
Incisor foramen

as early as we can see we find the bone united, but it is originally divided into three pieces.

1 Inferior pieces.
1 Facial nasal and palatine pt.
1 Orbital and malar part.
Alveolar border has small granular articulates with Lacrimal

articulates with Zygoma

Superior Maxilla.

Malar Process.
Ant Nasal spine
Concave Margin.
Ascending Process. Grooved Ext.
Lachrymal groove
Tuberosity behind the last Molar Tooth.
Palate Plate
Post Palatine Canal.
Antrum Highmori
Orbital Plate
Infra orbital Canal
——— foramen
Part of Zygomatic fossa behind Malar Process.
— Spheno Maxillary fissure towards Post Border.

Ossification.

before vertebrae

3 Pieces - 30 to 35 D

Malar Bone

Number
2 viz 1 in side of Face.
Situation
most prominent part of the Cheek.
Articulation
with Frontal
— Sup. Maxilla
— Temporal
— Sphenoid.
Description.
Quadrangular.
Ant surf convex & pierced with foramina.

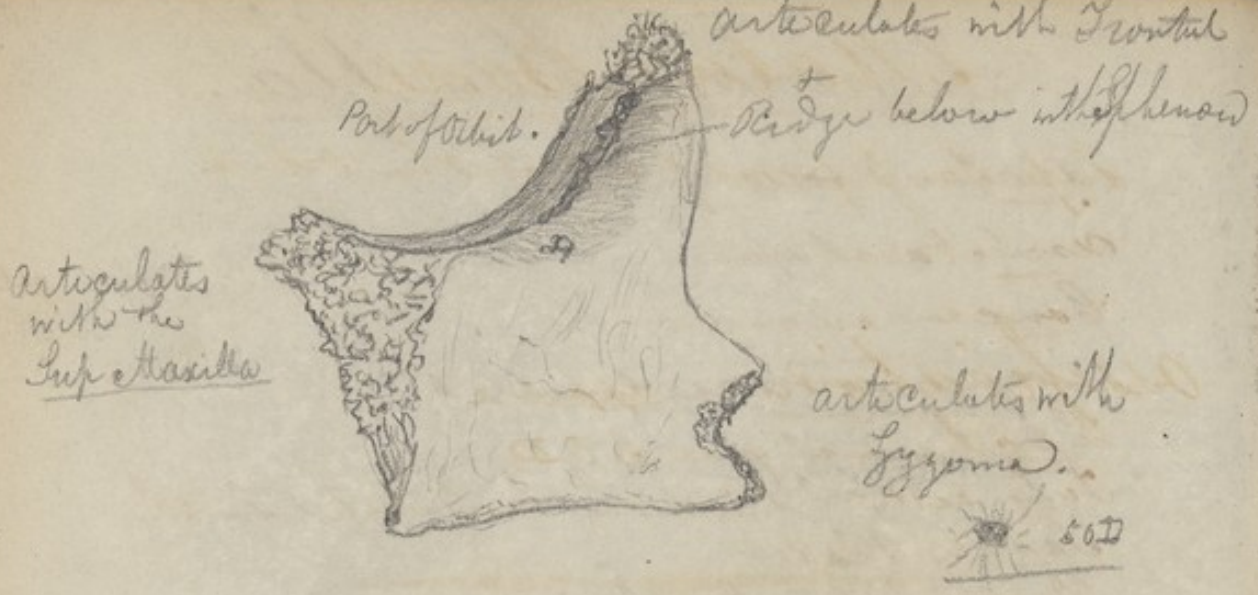
articulates with Frontal
Part of orbit.
Ridge below in the Sphenoid
articulates with the Sup Maxilla
articulates with Zygoma.
60D

2 or 3m Quern

Malar Bone

Sup Surf forms part of the Orbit.

Ossification appears
1 Pt ------ 50 D

Nasal Bones

Number 2

Situation
They form the "Bridge of the Nose".

Articulation
with Frontal by sup border
— Nasal Cart inf.
— Maxillary — Ext.
— fellow — Int.
Supported by Nasal spine of frontal & Perpendicular Plate of Ethmoid

Description
Sup — Narrow & Thick
Inf — Wider & Thinner.
Ant surf — Concave above down — Convex side to side —
Small foramen —
Post surf has mark for passage of branch of nasal nerve

Ossification
1 Pt which appears — end of 2nd M (8)

Os Unguis or Lachrymale

Number 2

Situation
Inner & Ant part of the Orbit.

Articulation
Orbital Process of Frontal Bone
Sup Maxilla
Inf Spongy
Os Planum of the Ethmoid

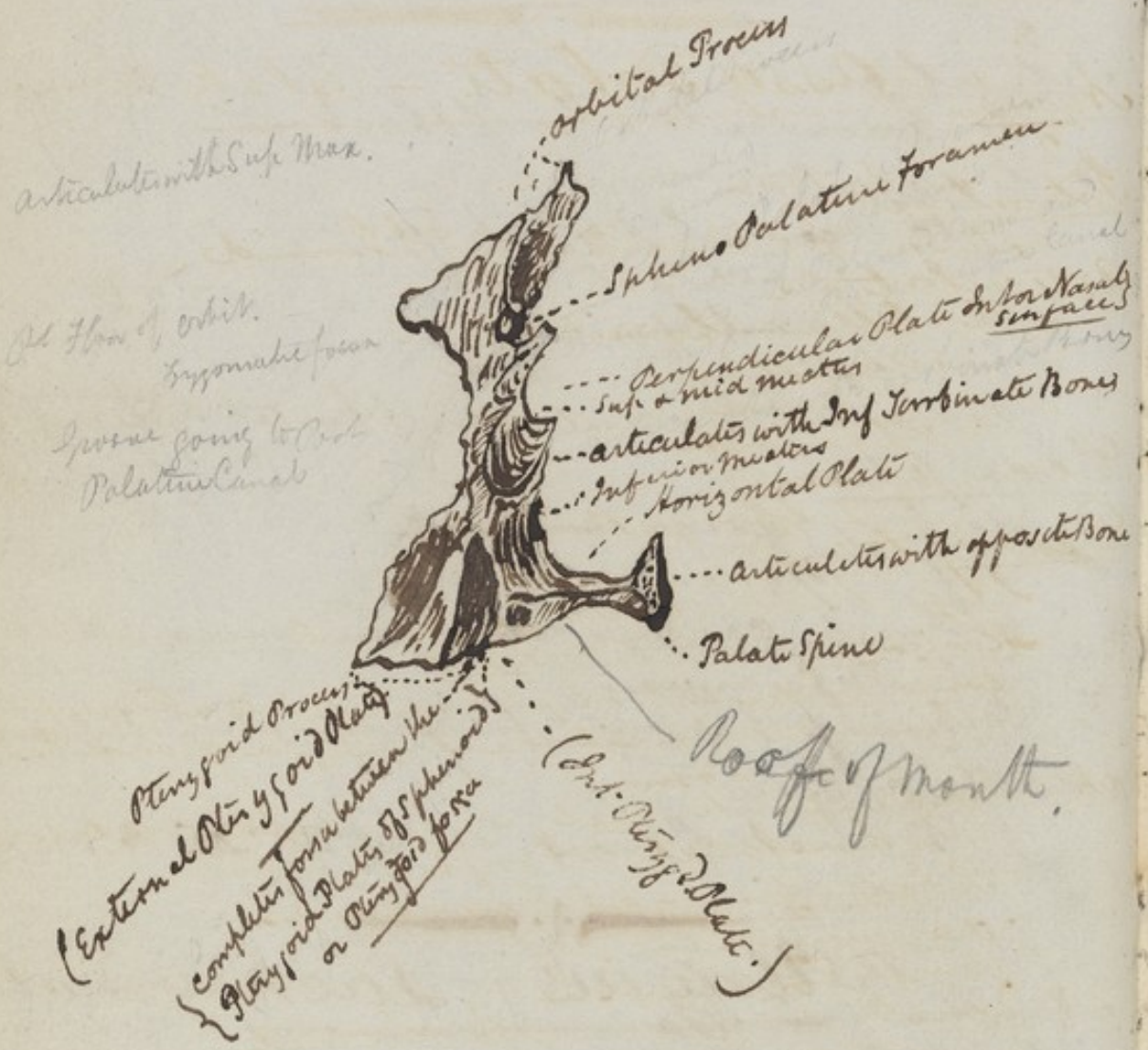
Orbital Process
Spheno Palatine Foramen
Perpendicular Plate
Sup & mid meatus
articulates with Inf Turbinate Bones
Inferior meatus
Horizontal Plate
articulates with opposite Bone
Palate Spine
Pterygoid Process
(External Pterygoid Plate)
completes fossa between the Pterygoid Plate of Sphenoid & Pterygoid fossa
(Int. Pterygoid Plate.)
Roof of Mouth.

Os Unguis — Nail shaped.

Description

Resembles a Finger Nail.
Groove which with another in superior maxilla forms the Lachrymal groove
Ext or orbital Surf – has the groove anteriorly

Ossification

1 Pt – appearing in the 3 M (4)

Ossa Palati – Palate Bones

Number 2.

Situation

Between Sup Maxilla & Sphenoid.

Articulation

with – fellow of opposit
Maxillary
Ethmoid
Sphenoid
Vomer
Inf Spongy Bone

Description

Shape like the letter **L**
Horizontal or Palate Plate
Rough Border int which rises up into a Ridge which joins the opposit one forming a groove between for the Vomer
Pst. Thin free Border Post, the limit of hard Palate & from it the soft Palate hangs.
Palate Spine – at Inner angle.
* Transverse Ridge Inf.
Oval foramen – —
small — — — — farther back. } lead to the groove to Post Palatine Canal.

Tuberosity or Pyramidal Process – rough, thick, at the junction of the two Plates (or Angle)
3 Vertical grooves middle smooth – lateral rough

Vertical Plate

Int surf or nasal divided by
Transverse Ridge for Inf Spongy Bone

40 to 50 D

3 M. Quan

Palate Bones.

Ext surf - rough, divided by a
Vertical Groove which with the Maxilla
forms the Post Palatine Canal
Notch at sup Border which with Sphenoid forms
Spheno-Palatine Foramen
Sphenoidal Process - smallest & least prominent -
3 surfaces - Int, Ext, Sup -
Sup, Grooved & with under surface of Sphenoid
forms the Pterygo Palatine Canal
Orbital Process - inclines out & forwards.
5 surfaces. (2 free & 3 articulated)

Ossification (b)

1 Pt at union of Horizontal & Vertical Plates. - appears 40-50 D

Vomer - Plough share

Number 1

Situation
Vertically - length ant. post, in Nasal fossa.

Articulation
with Sphenoid
— Ethmoid
— Superior Maxilla
— Palate.

Description
Flat & irregularly quadrilateral
Sup Border - thick & deeply grooved.
Ant — also grooved

Ossification

1 Pt - (beginning at inf Border) in appears 2 M (b)
Begins as two thin plates with a groove between them

(Right)
A12


Condyle
Sigmoid notch
Coronoid Process
End of Mylohyoidean Ridge
Inf Dent.l For.
alveolar Process
Ramus
The angle
groove for Facial artery
Symphysis
Fossa for Depressor Labii Inferioris M.S
Mental (chin) Foramen
External Oblique Ridge
Body
mylohyoidean groove

Inferior Spongy or Turbinate

Number

Situation
Extends, Ant. Post, alongside of Nasal fossae

Articulation
with Sup Maxillae
— Palate
— as Unguis.

Description
Int surf convex
Ext — concave.

Ossification appears
1st — 5th after Birth (6)

Inferior Maxillary

Number.

Situation
Lower Jaw

Articulation
with Glenoid Cavity of Temporal Bones by Cartilage

Descriptions
Convex - like a horse's shoe,
Body
Ext surf convex
Vertical line in Middle — Symphysis.
Incisor fossa on each side
Foramen Mentale - Ext -
External Oblique line runs up to ant Border of Ramus
Int surface - Concave - with Symphysis.
2 prominent tubercles on each side.
2 slight depressions
Mylo Hyoidean Ridge from lower margin - up & out to the Ramus.
Inf Border thicker ant & everted forwards.
Rami -
Form the Angle with the Body - nearly right angle in Adult. obtuse in infancy -
Int Surf
Inf Dental foramen leading to Dental Canal.
Groove beneath the foramen.
Ant Border terminates in
Coronoid process
Grooved at the commencement


Quain
4 ½
30 to 35 s
1 ½


anterior Surf.
Lesser Cornu
Greater Cornu

Inferior Maxilla

Post Border
Neck - constricted part
Condyle - (or head) convex oblong - length from side to side - direction oblique inwards -
Sigmoid Notch between Condyle & Coronoid pro-

Ossification

	appear	unite
2 Pts - one on each side at chin part.	30 to 35 D	IV (C)
(50 or 60 D Groove for dental Sinus)		
(3 Needle shaped points of Spine -	50 to 60 D (C)	4 M Spine)

·S·

Os Hyoides

Number 1
Situation
Base of the Tongue

Description
Body - quadrilateral -
ant surf convex & marked in middle by Vert line
Post — concave.
Cornua - Project backwards & end in a Rounded Tubercle
Cornicula short, & conical

Ossification (C)

	appear	unite
1 Body (some say 2 Pts) -	- - shortly after Birth	very late
5 1 each Cornu	- - - - - - - end of 9 M	
1 — Corniculum	- - - some months after	

Finis

Foramina on Base of Skull

Anterior Palatine – transmits Naso Palatine nerve

Posterior ——— (at Base of Alveolar Border) for Post Palatine nerves and artery.

Anterior Condyloid for 9th Pr of Nerves (Hypoglossal)

Jugular Fossa behind Styloid & vaginal Processes completed into Foramen Lacerum Posterius by the Border of Occipital Bone divided into 2 parts by a Spicula of Bone or Fibrous Band –

Ant & Int. Pt. for Glosso Pharyngeal – Par Vagum & Spinal accessory nerves –

Post Pt. for Jugular Vein.

Foramen Lacerum anterius or Sphenoidal fissure (By inner Part Vena Ophthalmica leaves orbit & terminates in Cavernous sinus) –

Transmits 3, 4, 5th & Ophthalmic Branch of 5th nerves & Ophthalmic Vein

Post Condyloid F. for Small Artery & Vein

Spinous F. of Sphenoid – transmits Mid: Artery of Dura Mater a Branch of Int. Max. a Branch of Ext. Carotid

Articulations.

Classes		Varieties		Examples
I Synarthrosis or Immovable	1	1. Sutura	1 Serrata	Parietals
			2 Squamosa	Temporal & Parietal
			3 Harmonia	Nasal & Sup. Maxillary Bones
	3	2 Gomphosis - Nail in Board		Teeth in Jaws
	4	3 Schindylesis - fissure for reception		Vomer & Sphenoid
	2	4 Symphysis - unite by Bone		Inf. Maxilla
		5 Planiform as between Upper Mort. Surf. of Vertebrae		
II Diarthrosis or Moveable	2	1 Arthrodia (simple moveable joint)		Occip & Atlas, Carpus & Shoulder
	3	2 Ginglymus (Hinge)	1 angular	Elbow Joint
			2 Rotatory	Atlas & Axis
			3 Double Lateral	Radius & Ulna
	1	3 Enarthrodia (Ball & Socket)		Hip Joint
III Amphiarthrosis or Mixed				Vertebral Column

Additional Classes seldom Employed.

Classes		Examples
Synneurosis	union by ligament	Various Articulations
Syssarcosis	~~Capsule~~ tissues of flesh	Hyoid Bone & Skull
Meningosis	membrane	Skulls of Children
Synchondrosis	Cartilage	Same as Symphysis, but has Motion

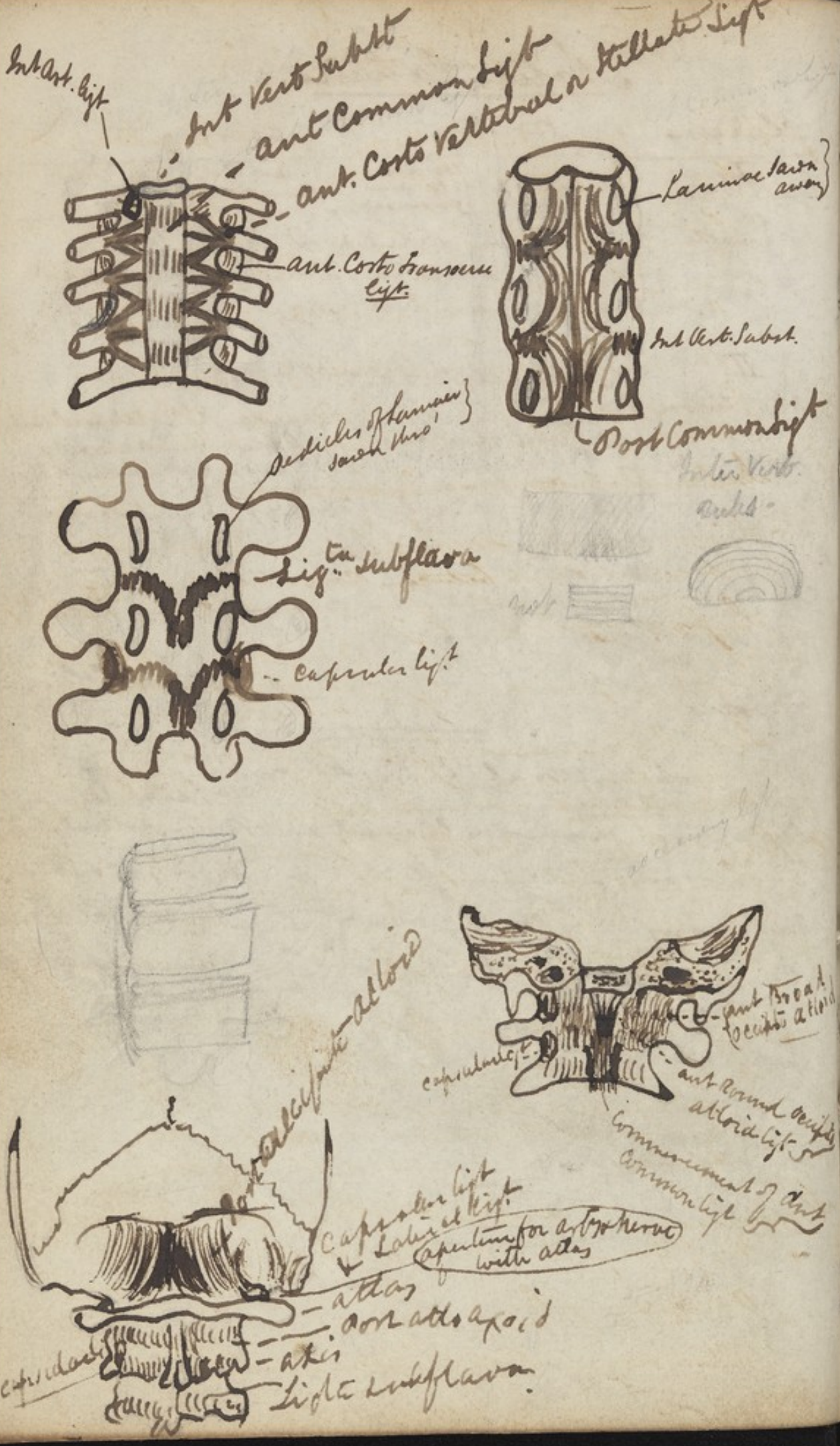
Int Art. lig.
Int Vert Sabst
ant Common lig
ant. Costo Vertebral & stellate lig
ant. Costo transverse lig.
Laminae sawn away
Int Vert. Sabst.
Pedicles of lamina sawn thro'
Post Common lig
Inter Vert. arts.
Lig.ta subflava
capsular lig.
ant Round ocipital atlo-axoid
capsular lig.
ant Round ocipital atlo-axoid lig.
Commencement of ant Common lig
Capsular lig
Lateral lig.
Aperture for art. nerve with atlas
atlas
post atlo axoid
axis
capsular lig.
Lig.ts subflava

Articulations

Spine (Bodies Amphiarthrosis) (Articular Pro Diarthrosis Vertebrae)

Ant Common ligament
From axis to Sacrum -
Thickest opposite the Bodies
Thinnest but best attached at margins
3 sets of Fibres { 1 to 4 or 5 below / 1 — 3 d — / 1 — next

Post Common lig.
Within the Spinal Canal at Post part of Bodies
From Axis to Sacrum
Broadest opposite Int. Vert. Substance

Inter Vertebral Substance of Fibro cartilage
Disc of Fibro Cart between the Vertebrae.
Composed of Vertical plates whose fibres are planting & decussating
~~Inter Articular Fibro cart.~~

Ligamenta sub flava. Yellow lig of Laminae
Does not exist between Axis & Occipital & Atlas. } Fibrous membrane supplies place

Supra spinous lig
Infra spinous lig. } Inter spinous in back and loins only from spine of upper to next vertebra are attached to border & point of process.

Int. transverse lig (Indistinct)
Between transverse process of lower Dorsal vert.

Articular lig between articular pro of 2 contiguous Vert.

Atlas & Axis - (Diarthrosis Lateral ginglymus)

Transverse lig. (Cruciform)
2 Capsular

Ant Atlo Axoid lig.

Post atlo axoid lig.

4 Synovial membranes
2 Between Art Proc of atlas & axis
1 ——— odontoid & transverse lig
1 ——— ——— & arch of atlas.

Cranium occipito Atloid. (Arthrodia)

Ant Occipito Atloidean lig { 2 portions { superfi. { Broad / thick; Deep. Broad & Thick

Accessory lig.

Post Occipito Atloidean lig { divides into Ant. & Post lamellae. Ant. attached to theca vertebralis. Post to upper border of Ring of atlas. Extremities form apertures for nerves & A. & V.

2 Synovial membranes.



The Styloid Hyoid Lig. narrow & long from Styloid Process of Temporal to smaller Horn of Hyoid Bone

Articulations

2 Odontoid ligaments – (ligts alaria) check ligts
short thick round below fixed to odontoid Pro. above inner side of condyles of occiput

Occipito Axoidean ligts
seems a prolongation of Post Common ligts.

Lower Jaw.

Ext lat. ligt.

Int lat ligt.

Stylo Maxillary ligt

Inter Art Fibro Cart.

2 Synovial membranes

Ribs. (Costo Vertebral) (angular fin ligments

Ribs & Sternum
- Ant ligt. (Stellate)
- Int Art ligt.
- 2 Synovial membranes. does not exist in 1 – 11 – or 12th ribs.

Ribs & Transverse Process
- Post Costo Transverse (arthrodia
- Mid. Costo Transverse
- Sup or Ant Costo Transverse.

Ribs and Sternum
- Ant Costo Sternal ligts (angular fin ligments)
- Post Costo Sternal ligts.
- Costo Xiphoid ligt.
  Between 7 Rib & Xiphoid cart.

Ant & Post Sternal ligts.


Inter Articular fibro cartilage
Inter Clavicular lig.
ant. Sterno Clavicular lig.
Costo Clavicular or Rhomboid lig.
ant. Costo Sternal lig.


sup. acromio Clavicular
Coraco Acromial or Deltoid
Coraco Clavicular
Transverse lig.
Capsular l.
Coraco humeral
Long tendon of biceps

Articulations

Sternum & Clavicle

Figures are Lucien's arrangement.

1 Ant Sterno clavicular

2 Post Sterno clavicular

5 Inter art. Fibro Cart.

6 2 Synovial membranes

4 Inter Clavicular ligt. Ligt. m Transversum

3 Costo Clavicular ligt. (Rhomboid)

Scapula & Clavicle

Sup ligt
Inf ligt } 1 Capsular Ligt Acromio Clavicular

2 Synovial membrane

3 Coraco Clavicular divided into
Post or Int – Conoid)
Ant or Ext – Trapezoid)

Proper ligts of Scapula

Coracoid ligt. (Propium Post)

Coraco Acromion (Propium ant)

Scapula & Humerus –

1 Capsular ligt.

2 Coraco Humeral ligt (accessorius)

3 Glenoid ligt continuous with tendon of Biceps

Tendon of Biceps

4 Synovial membrane

Bursa Mucosa.

Eva Wilson

Internal view of Ligts of Elbow Joint. External view

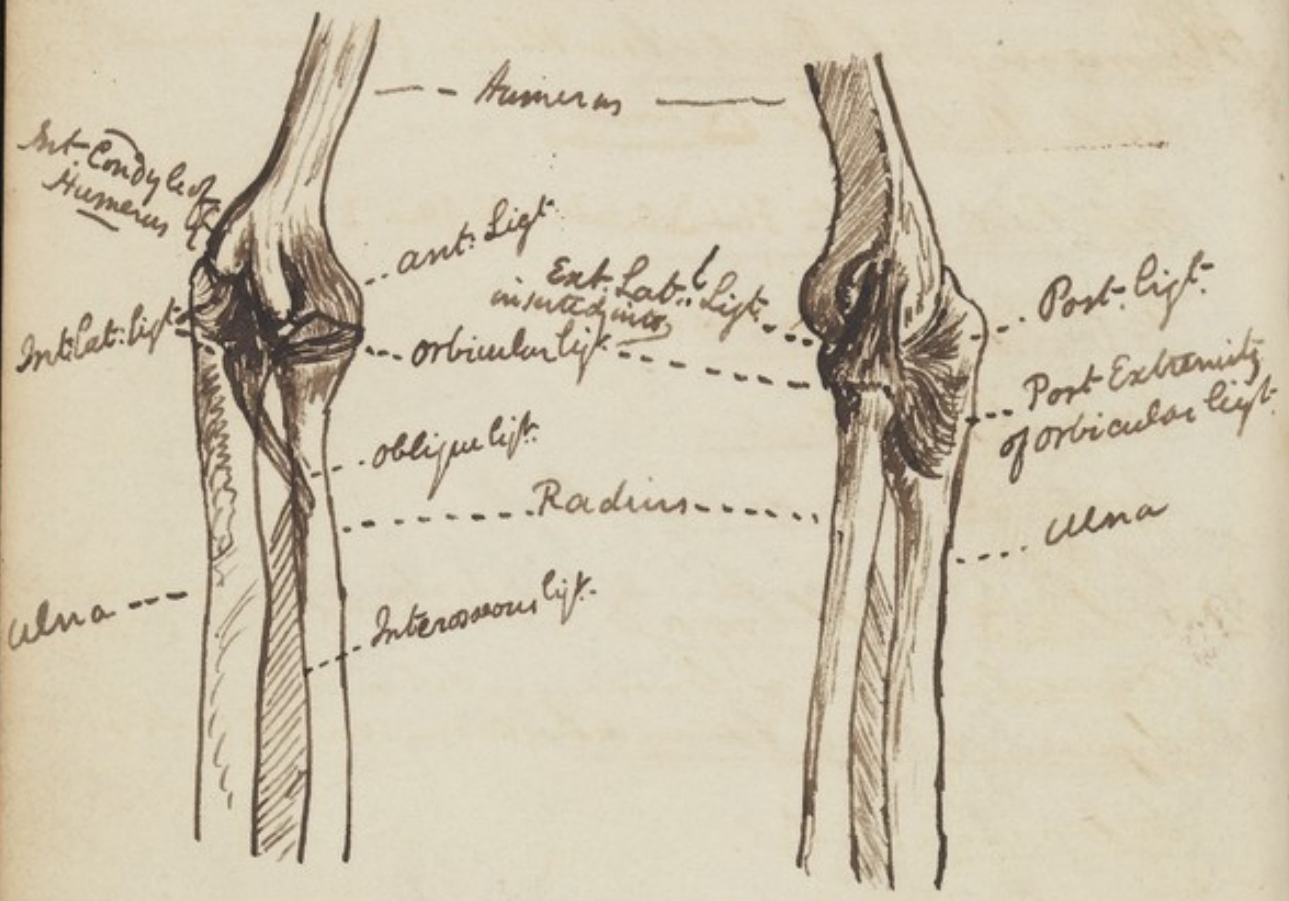

Articulations

Humerus & Radius & Ulna (Humero Cubital)

Int lat ligt △ (triangular from ulna)

Ext lat. ligt. Flat △ O. outer condyle of Hum. I Annular ligt & Decorum

Ant ligt - Broad - thin, irregular

Post ligt. do.

Synovial mem

Radius & Ulna (Radio Cubital) double lateral pivot joint

Sup { Annular ligt (Coronary or Orbicular) / Synovial mem. } between head of Radius & small C cavity of Ulna

Mid { Int osseous ligt. / Round ligt (oblique) } Check

Inf. { Fibro Cart (at Inf articulation)  Ulna / Synovial membrane (sacciformis) }

Radius & Carpus

Int lat ligt

Ext lat ligt

Ant ligt

Post ligt

Synovial membrane.

Carpus

Inter osseous fibro Cart.

2

2

Articulations

2 Palmer ligts

2 Dorsal ligts

Lateral ligts

Ant ligt

Post —

Synovial membrane

Carpus & Metacarpus

Palmer & Dorsal ligts

Transverse ligts (at digital ends)

The Metacarpus of the Thumb has a capsular ligt.

Phalanges

Lat ligts

Ant ligts.

Accessory ligts

Vaginal ligts

Ant annular ligts

Post annular ligts.

Articulations

Sacrum & Spine -

Sacro Vertebral Ligt. - (Ant. Com. Post Com. Articular - Interspinous -)

Ilio Lumbar ligt. strong and triangular between transverse pro of 5 lumbar and crest of Ilium where post and mid thirds meet.

Sacrum & Coccyx

Ant ligt - thin membranous

Post ligt. flat. triangular stronger

Fibro Cart. thin

Synovial membrane

Movements Backwards & forwards

Sacrum & Ischium (Synarthrosis - ~~Symphysis~~

Post Sacro Sciatic ligt (great.)

Ant or Small Sacro Sciatic (Lesser) Small

Sacrum & Ilium

Post Sacro Iliac

Ant Sacro Iliac.

Cartilage

Symphysis Pubis.

Fibro Cart between

Ant Pubic ligt

Post Pubic ligt

Obturator ligt. membrane

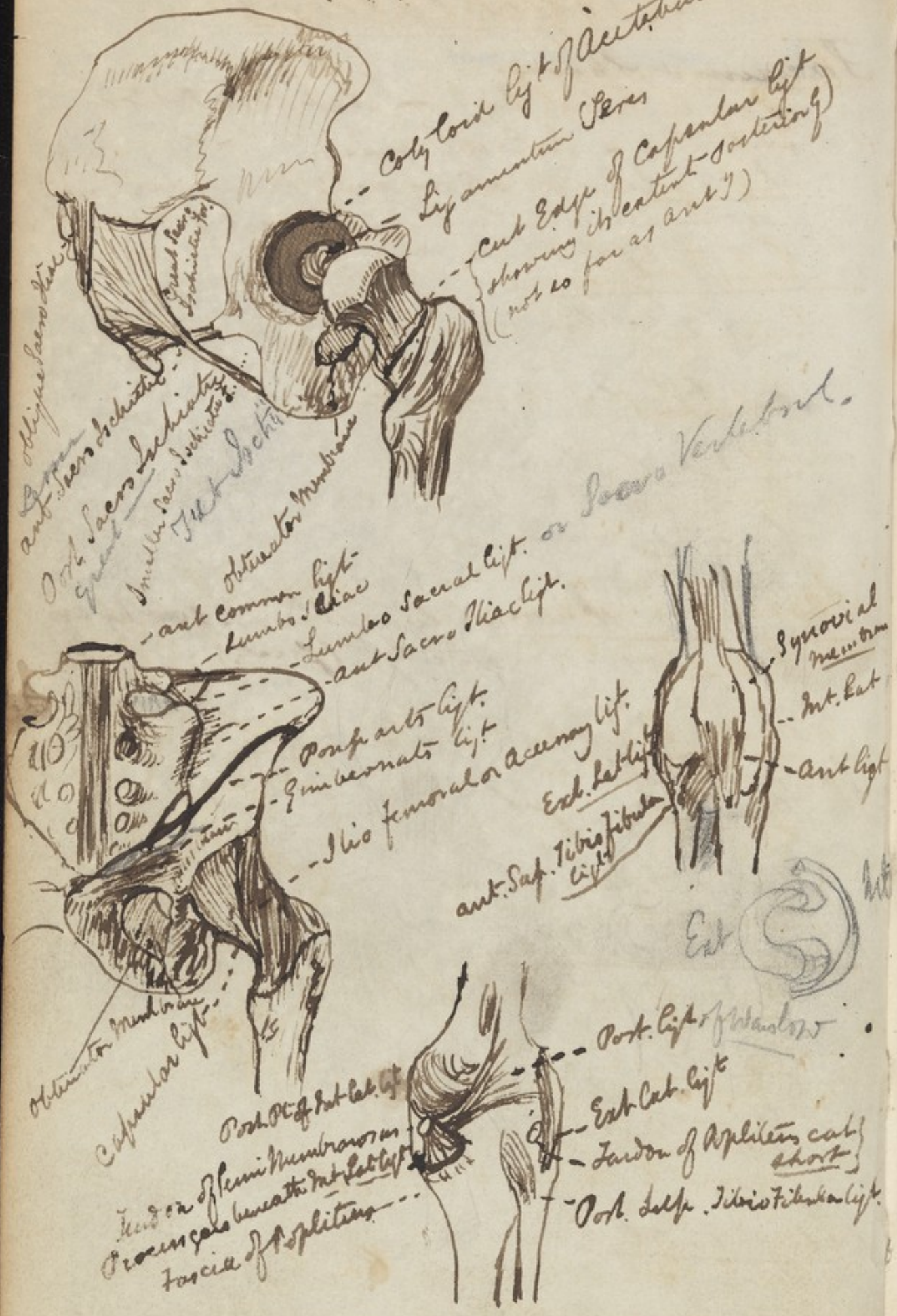
Cotyloid lig. of Acetabulum
Ligamentum teres
Cut Edge of Capsular lig.
showing its extent posteriorly
(not so far as ant.)
Great Sacro Sciatic for.
Oblique Sacro Iliac
ant. Sacro Sciatic
Post. Sacro Sciatic
Small Sacro Sciatic for.
Obturator Membrane
ant. common lig.
Lumbo Iliac
Lumbo Sacral lig. or Sacro Vertebral.
ant. Sacro Iliac lig.
Synovial membrane
Int. lat.
ant. lig.
Post. arch lig.
Ischiocapsular lig.
Ilio femoral or accessory lig.
Ext. lat. lig.
ant. Sup. Tibio fibular lig.
Obturator Membrane
Capsular lig.
Post. lig. of Wardrop
Post. Pt. of Int. lat. lig.
Ext. Cat. lig.
Tendon of Semimembranosus
Tendon of Popliteus cat. short
Process goes beneath Int. lat. lig.
Post. Sup. Tibio Fibular lig.
Fascia of Popliteus

Articulations

Ilium & Femur

Capsular lig.

Ilio femoral (accessory lig.

Cotyloid lig.

Transverse lig.

Inter Articular lig (Round)

Synovial membrane.

Femur & Tibia & Patella (Knee)

ant. Lig.tum Patellae.

Int, lat, lig.

Ext lat lig.

Post lig (Popliteal)

ant Crucial lig

Post Crucial lig

Semi lunar Cart. Int

Ext Semi lunar Cart.

Transverse. lig.

Synovial mem

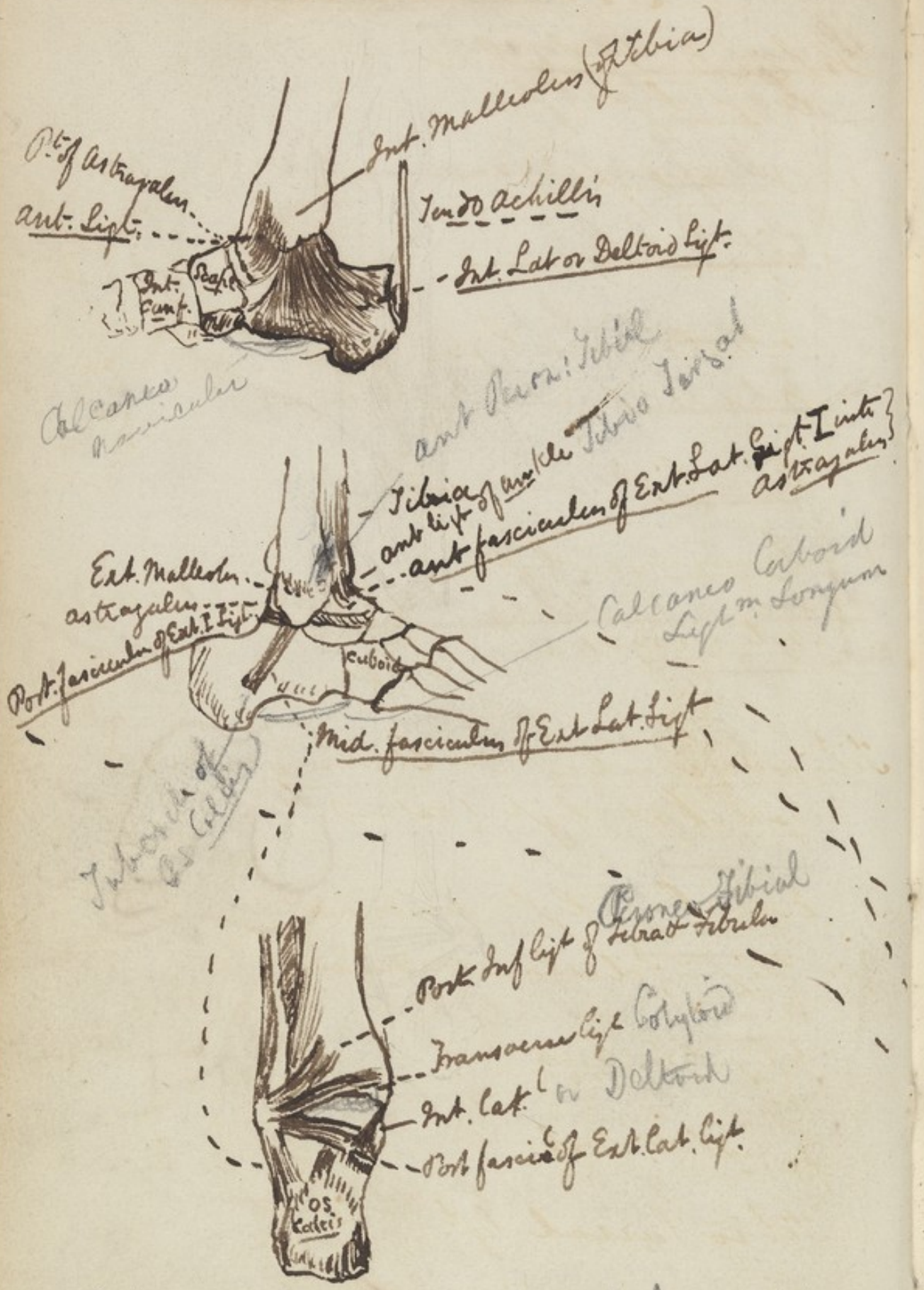

Astragalus Navigular Most Moveable
has Synovial Membrane.

Articulations

Tibia & Fibula.

sup
- Ant ligt
- Post ligt
- Synovial mem.

Interosseous ligt.

Inf
- Ant ligt
- Post ligt
- Transverse ligt
- Interosseous

Tibia & Fibula & Astragalus

Int lat ligt (Deltoid)

Ext lat ligt divides into
- Ligt. Fibulae medium
- Lig. Fib. Ant
- Lig Fib. Post.

Tibio Tarsal ligt.

Synovial membrane

Tabular view of Ligaments of the Tarsus (Lizars Text Book)

Calcaneum — Dorsal, superficial deep & Plantar Lgts — Interosseous External and Posterior Lgts — Astragalus

Inf and Ext Plantar Lgts — Dorsal Ligament

Cuboid — Dorsal & Plantar Lgts — Plantar Lgts — Scaphoid

Dorsal & Plantar Lgts

Dorsal & Plantar Lgs — External Cuneiform — Dorsal & Plantar Lgs — Mid Cuneiform — Dors & Plant Lgs — Internal Cuneiform

Bone

Articulation

Os Calcis & Astragulus –

Inter Osseous lig.t –

Ext lig.t

Post lig.t

Synovial mem.t

Os Calcis & Scaphoid –

Inf lig.t

Sup or Ext lig.t

Os Calcis & Cuboid

Sup – lig.t

Inf lig.t (2 layers) lig.tum longum Plantae

Interosseous lig.t

Astragulus & Scaphoid

Lig Astrag Scaph – (Ligtum sup.)

Synovial mem –

Scaphoid & Cuboid

Dorsal lig.t

Plantar lig.t

Interosseous lig.t –

S

C

3 C

Articulations

Scaphoid & Cuneiform
Dorsal lig
Plantar lig
Synovial mem

Cuboid & Cuneiform.
Dorsal lig
Plantar lig
Interosseous lig
Synovial mem

3 Cuneiform Bones —
Dorsal lig
Plantar
Interosseous lig
Synovial mem.

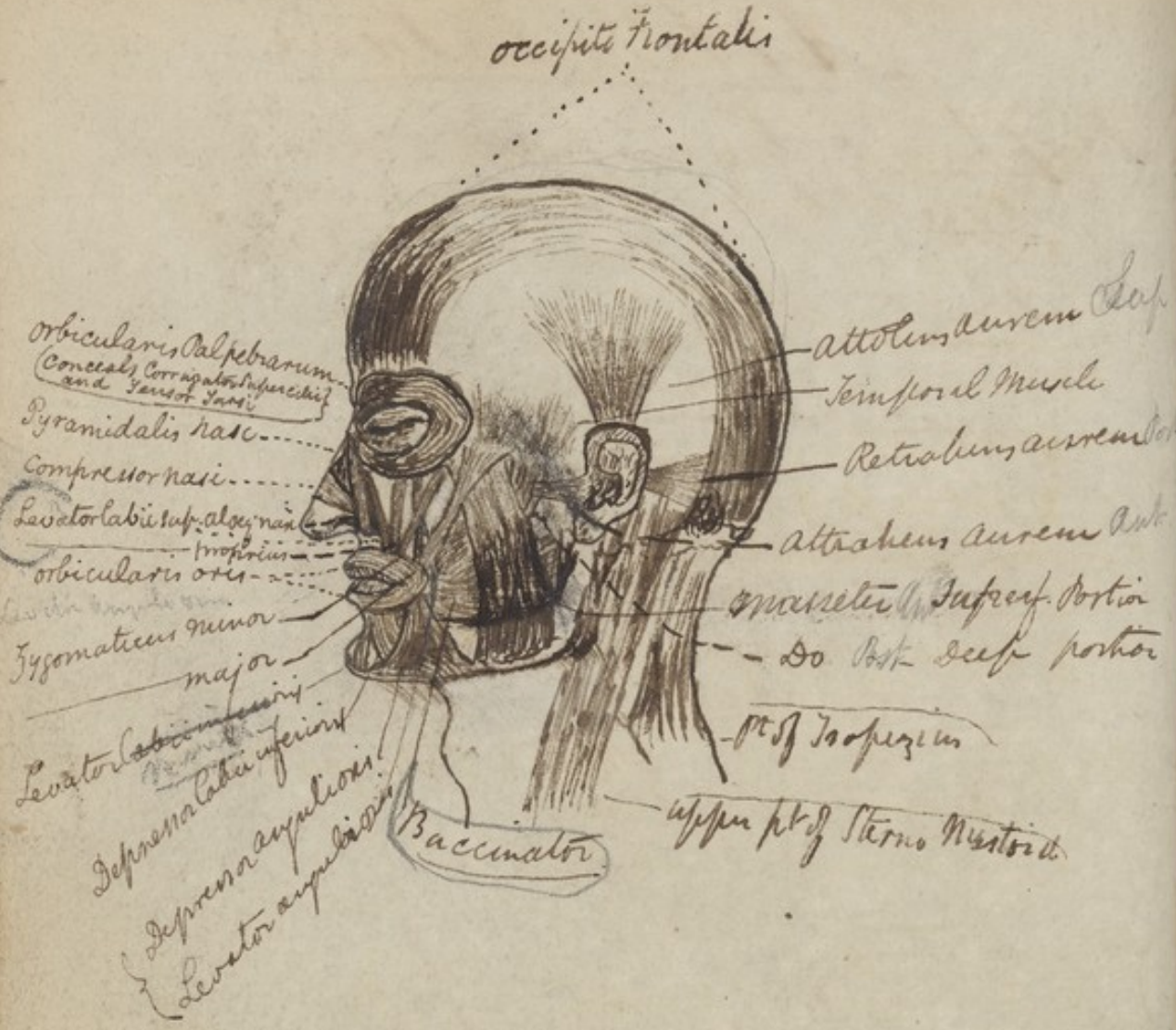
occipito Frontalis
Orbicularis Palpebrarum
Concealed Corrugator Supercilii
and Tensor Tarsi
Pyramidalis nasi
Compressor nasi
Levator labii sup. alæq. nasi
proprius
orbicularis oris
Zygomaticus minor
major
Levator
Depressor labii inferioris
Depressor anguli oris
Levator anguli oris
Baccinator
attollens aurem Sup.
Temporal Muscle
Retrahens aurem Post.
attrahens aurem Ant.
masseter Superf. Portion
Do Deep portion
Pt of Trapezius
upper pt of Sterno Mastoid

The Muscles.

Occipito Frontalis

O. Ext. 2/3rd of Sup Curved ridge of Occipital Bone + of Sup & Ext part of Mastoid part of Temporal

I Integuments of the Eyebrows, Nasal Bones.

—·—

Orbicularis Palpebrarum.

1 O Int. ang: proc. of Os Frontis & upper edge of Tendo oculi

2 O Nasal pro. of sup Maxilla & inf edge of Tendo oculi

I Ext Angle of orbit.

Corrugator Supercilii.

O Int. ang. pro. of Os Frontis

I Middle of Eye Brow.

Levator Palpebrae (Quain) Belongs to Ocular group.

O Sup edge of foramen Opticum

I Sup border of Tarsal Cart.

Tensor Tarsi

O Post edge of Os Ungois

I Lachrymal Ducts as far as the puncta.

—·—

Pyramidalis Nasi

O Occipito Frontalism.

I ½ way down nose to Compressor Nasi

Compressor Nasi.

O Canine fossa of Sup Maxilla

I Dorsum of the Nose

Nasal Group.

Levator Labii superioris alaeque nasi.

O. Sup Ext. of nasal process of sup. Maxilla + Edge of the orbit above infra orbital foramen

I Ala Nasi, upper lip, & orbicularis oris m.

D

Le

Z

Z

D

De

Le

S

Ca

Muscles

Depressor, labii superioris alaeque nasi.

O. Alveoli of Canine & Incisor teeth of Sup Maxilla

I Integument of Upper lip & fil. cart. of Septum & ala nasi

Levator anguli oris

O. Canine fossa below infra orbital foramen & above alveola of the 1st Molar Tooth

I The commissure of the lips & the orbicularis oris.

Zygomaticus - Minor

O. Sup part of Malar Bone

I Upper lip near the commissure.

Zygomaticus Major

O. Inf part of Malar Bone near Zygomatic Suture

I angle of the mouth.

—.—

Depressor anguli oris. (Triangularis).

O. Ext oblique line on lower jaw from ant. Edge of Masseter to the Mental Foramen

I Commissure of the lips.

Depressor labii inferioris

O. Side & front of flower Maxilla.

I Half the lower lip & orbicularis oris.

Levator labii inferioris. or Menti

O. Alveoli of Incisor teeth of lower jaw by the side of the symphysis

I Integuments of the Chin.

—.—

Buccinator

O. 1. The two last alveoli of the sup Maxilla &
2. Ext surf of post alveoli of lower Maxilla & Inter Maxillary ligament

I Commissure of the lips

Orbicularis Oris

Surrounds the Mouth by two fleshy fasciculi joining at the angles

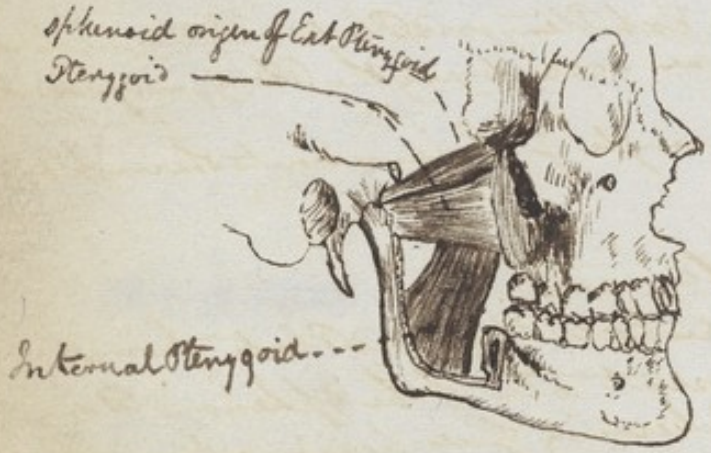

Ext Pterygoid Plate
Int. Pteryg.

Muscles

Masseter -

Consists of two portions

Anterior Portion

O. Sup Maxilla where it joins Malar Bone
Inf edge of Malar Bone

I Outer surface of Angle of the lower jaw.

Posterior Portion

O Edge of Malar Bone & Zygomatic Arch as far as the Glenoid Cavity

I Ext side of the Angle & Ramus of the lower jaw

Temporalis.

O. Side of Cranium beneath Semicircular Ridge of Parietal Bone, Temporal fossa & aponeurosis.

I Coronoid Process of inf Maxilla to last Molar tooth.

Pterygoideus Internus.

O. Inner side of the Ext Pterygoid Plate & Pterygoid Process of the Palate Bone - occupying the Pterygoid fossa.

I Inner side of the angle of the jaw & into the rough surface above it.

Pterygoideus Externus

O. Outer side of the Ext Pterygoid Plate from the Crest on the great ala of the Sphenoid Bone
Back part of Tuberosity of superior Maxilla.

I Ant & Int part of neck of lower jaw -
Interarticular Cart. & inf synovial membrane.

EAR

Superior Auris. Attolens aurem

O Cranial aponeurosis above Ext Ear.

I Upper & ant part of the Cartilage of the Ear

Anterior Auris. Attrahens aurem

O. Post Part of Zygoma & Cranial aponeurosis

I ant part of Helix.

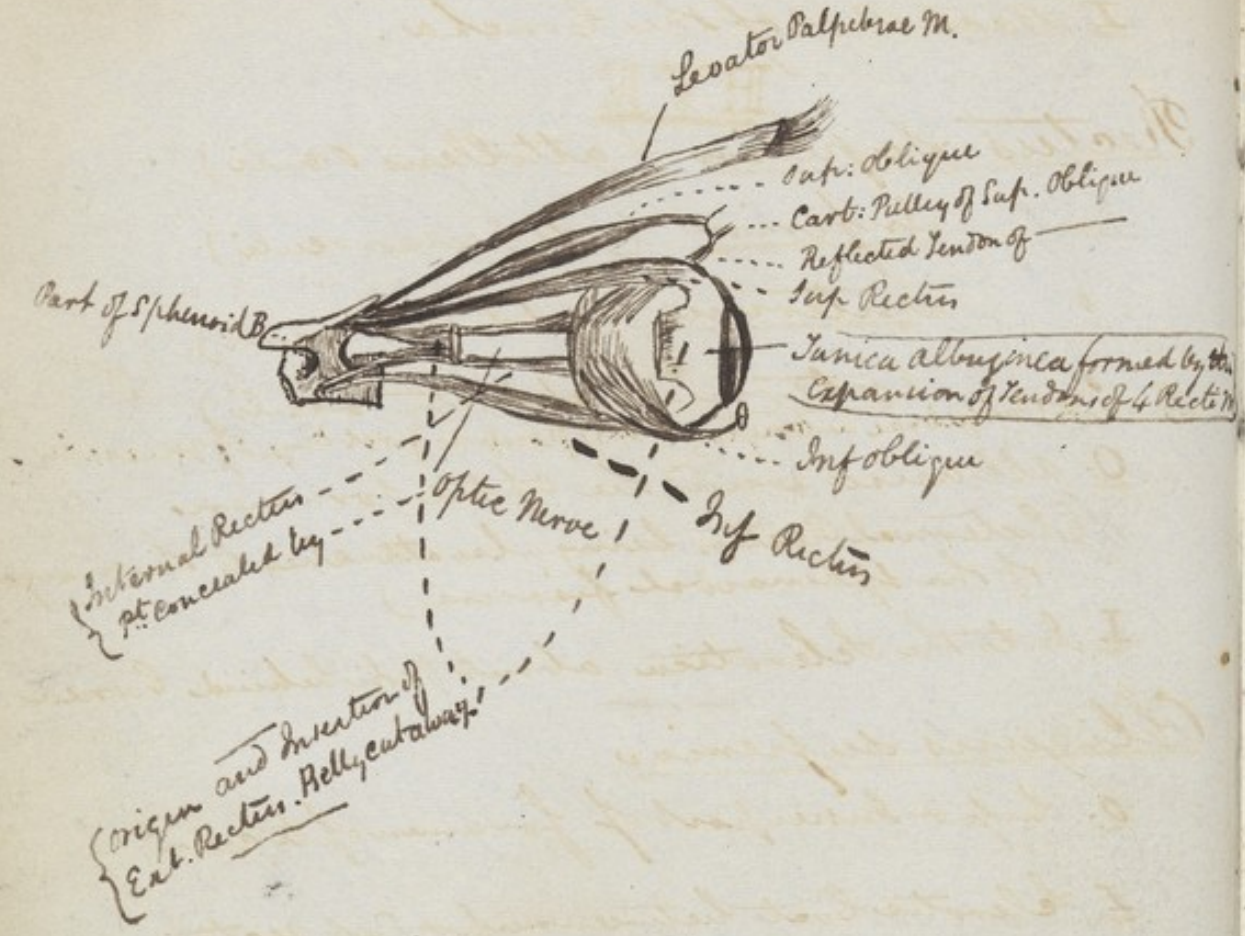
Levator Palpebrae M.
Sup: Oblique
Cart: Pulley of Sup. Oblique
Reflected Tendon of
Sup Rectus
Part of Sphenoid B.
Tunica albuginea formed by the
Expansion of Tendons of 4 Recti M.
Inf oblique
Optic Nerve
Inf Rectus
Internal Rectus
pt. concealed by
origin and Insertion of
Ext. Rectus. Belly, cut away.

Muscles.

Post Auris - Retrahens Aurem

O. Mastoid Process. above Sterno Mastoid m.

I Back Part of the Concha.

EYE

Rectus Superior (attollens oculi)

" Inferior (depressor oculi)

" Internus (adductor oculi)

" Externus (abductor oculi)

Levator Palpebrae belonging to this group in first page of muscles.

O. all arise round the optic foramen
(External Rectus being also attached to the margin of the sphenoidal fissure)

I Into the Sclerotica about 1/8 in behind Cornea.

Obliquus superior

O. Sup & Inner part of foramen opticum

I Sclerotic Coat between sup & Ext recti.

Obliquus Inferior

O. orbital Edge of sup Maxilla

I Ext & Post part of Sclerotica.

NECK

Platisma Myoides.

O. Cellular membrane covering the upper & outer part of the Deltoid & great Pectoral Muscles & Clavicle

I The Chin, the fascia along the side of the lower jaw
The fascia covering the Parotid gland.

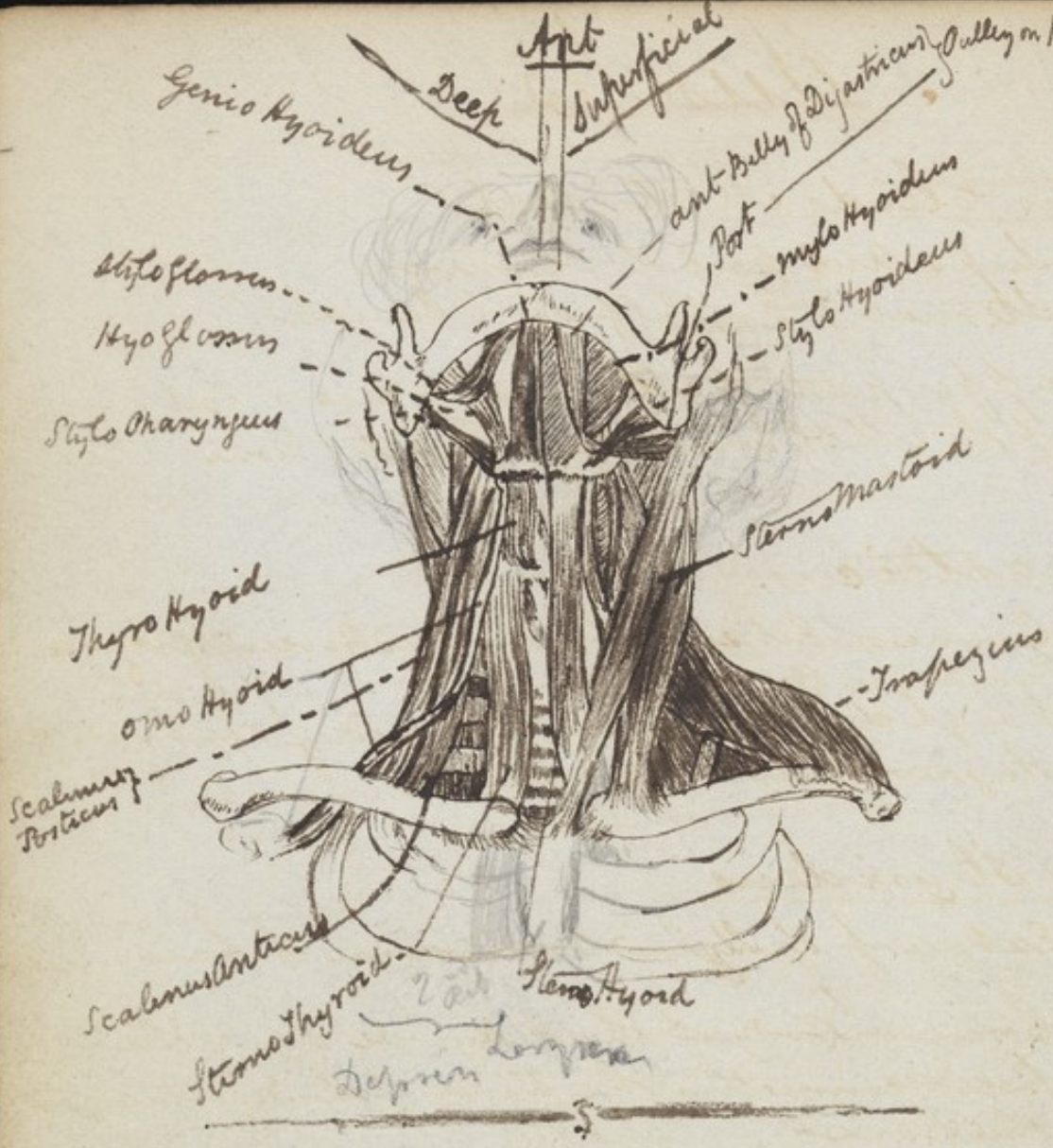

Omo shoulder
Genio Chin

Muscles.

Sterno Cleido Mastoideus

O. 1 Sup & Ant part of Sternum
2 Sternal 3rd or half of Clavicle.

I upper part of Mastoid Process & Ext third of the sup. Curved Ridge of Occipital Bone

Digastricus. (2 bellies)

O Groove on Int surf of Mastoid Process of Temporal Bone
passes thro' a loop of Sub Cranial fascia

I Rough depression on Inner side of the Base of the jaw near the Symphysis.

Stylo Hyoideus

O. Ext surf of Styloid Process near its base

I Cornu & Body of the Os Hyoides & into the fascia connecting the tendon of the Digastricus to this Bone

Stylo Glossus.

O Styloid Process (tip) & Stylo Maxillary ligament

I Side of the Tongue as far as the Tip.

Stylo Pharyngeus

O Back part of the Root of the Styloid Process

I Side of the Pharynx, Cornu of Os Hyoides & Thyroid Cartilage.

Mylo Hyoideus.

O. Mylo hyoid ridge on inner surface of side of inf Maxilla.

I Base of Os Hyoides, Chin, & middle tendonous line common to it & its fellow between Os Hyoid & Chin

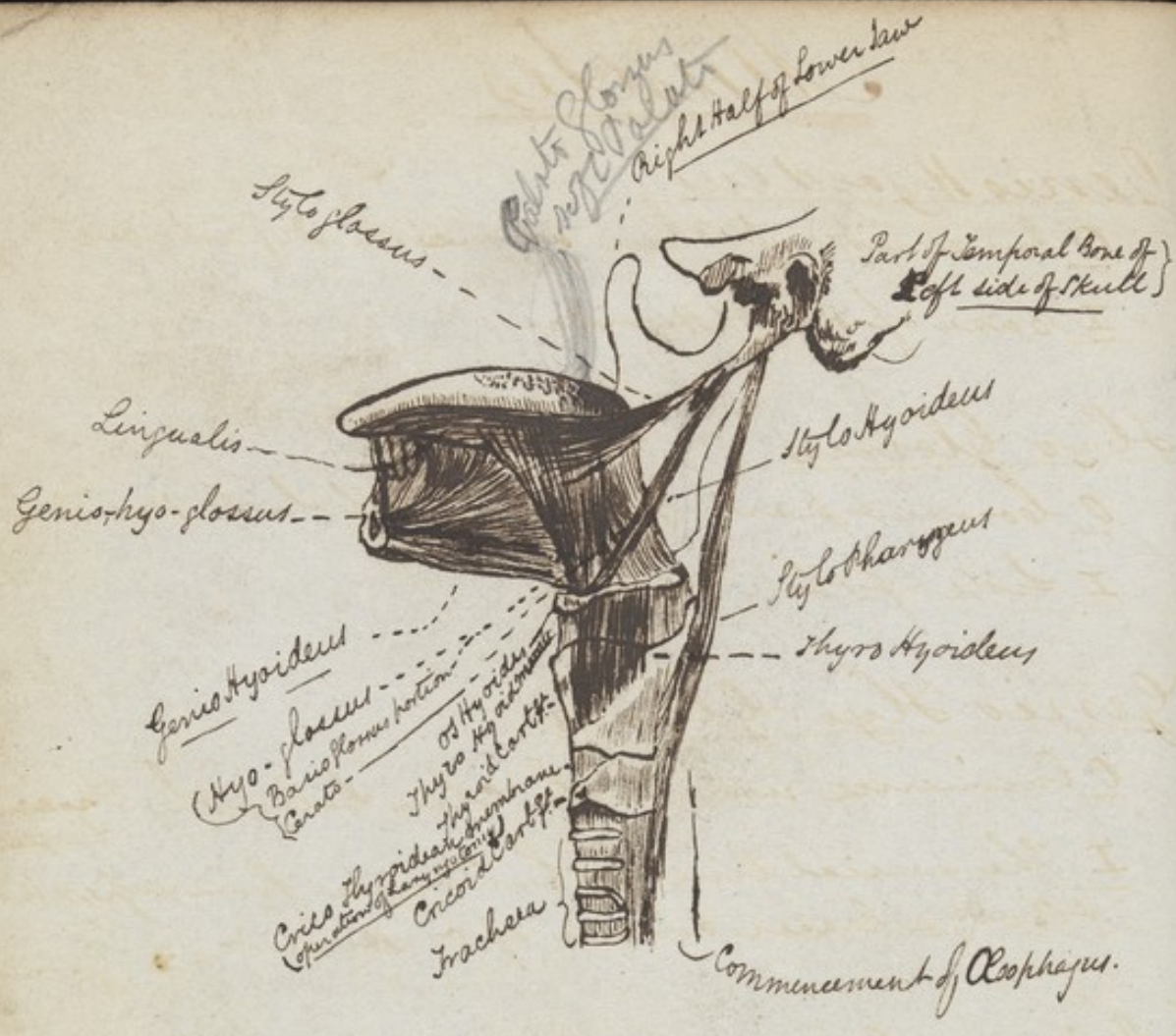
Palato Glossus
Palato Pharyngeus
Right Half of Lower Jaw
Stylo glossus
Part of Temporal Bone of left side of Skull
Lingualis
Stylo Hyoideus
Genio-hyo-glossus
Stylo Pharyngeus
Thyro Hyoideus
Genio Hyoideus
Hyo-glossus
Basio glossus portion
Cerato-
Os Hyoides
Thyro Hyoid membrane
Thyroid Cartlg.
Crico Thyroidean membrane
Operation of Laryngotomy
Cricoid Cartlg.
Trachea
Commencement of Oesophagus.


Inserted into Basilar Proc of Occip B
Orbicularis oris
Buccinator Muscle
Pterygo maxillary ligt
Mylo Hyoideus M.
Superior Constrictor
Stylo Pharyngeus between Sup and Middle
Stylo Hyoid Ligament
Middle Constrictor
Os Hyoides
membrane
Thyroid Cartilage
membrane
Cricoid Cartilage
Inferior Constrictor
Pharynx
Larynx
4th Cervical
Trachea
Oesophagus
Trachea
Oesophagus
end of 3 Dorsal

Muscles

Genio Hyoideus.

O Inner side of Chin above the Digastricus Insertion

I Base of the Os Hyoides.

Hyo Glossus

O Cornu & part of the Body of the Os Hyoides

I side of the Tongue

Genio Hyo. Glossus.

O Eminence inside the chin below the Frenum Linguae

I The mesial line of the Tongue from apex to Base & Body & lesser cornu of Os Hyoides.

Lingualis

is Between the Genio Hyo & the Hyo Glossus.

O Os Hyoides

I apex of Tongue & lying in it's substance

Sterno Hyoideus.

O Post surf of sup Ext of Sternum, Cart of 1st Rib. Sternal End of Clavicle & Sterno Clavicular Capsule

I Inf border of Body of Os Hyoides

Sterno Thyroideus.

O Post surf of sup Ext of Sternum, & Cart of 2nd Rib.

I Oblique line on the ala of the Thyroid Cartilage


Thyroid Gland
Isthmus of Thyroid

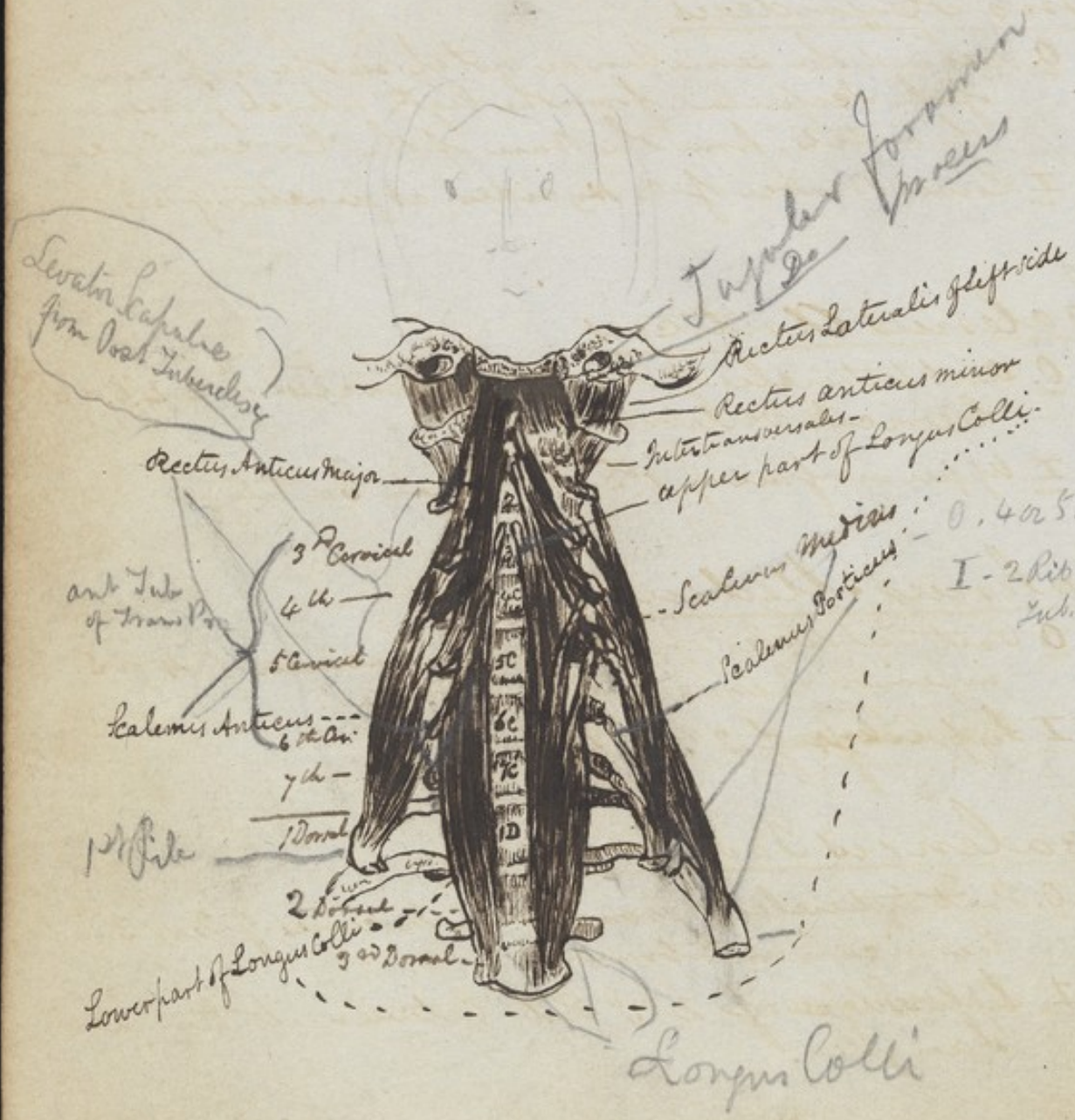
Jugular Foramen
Do
Process
Levator Capitis
from Post Tubercles
Rectus Lateralis Left side
Rectus anticus minor
Interstransversales
upper part of Longus Colli
Rectus Anticus Major
3rd Cervical
4th
5 Cervical
ant Tub of Trans Pr
Scalenus Medius
Scalenus Posticus
0, 4 or 5 Inf C.V.
I - 2 Rib beneath
Sub. & Ang
Scalenus Anticus
6th Ant
7th
1st Rib
1 Dorsal
2 Dorsal
3rd Dorsal
Lower part of Longus Colli
Longus Colli

Muscles

Thyro Hyoideus

O. Oblique line on ala of Thyroid Cartilage

I Lower edge of Cornu of Os Hyoides.

Crico Thyroideus.

O Fore part of the Cricoid Cartilage

I. Lower border of Thyroid Cartilage

Omo Hyoideus

O. Behind the semilunar notch in the sup. costa of the Scapula, from the ligt. which passes over the notch, from the Base of the Coracoid Process.

I Lower Border of Os Hyoides. at junction of Body & Cornu

Scalenus Anticus

O. Ant tubercles of Transverse Processes of 3. 4. 5. & 6th Cervical vertebrae.

I Upper surface of 1st Rib near Cartilage

Scalenus Medius

O Post Tubercles of Transverse processes of 4 or 5 inferior Cervical vertebrae.

I ~~Upper Surface~~ of 2nd Rib.

Scalenus Posticus

O. Post tubercles of Transverse Processes of 2 or 3 inf Cervical vertebrae.

I Upper Surface of 2nd Rib between its tubercle & angle.


Lateralis
1st Cervical
minor
2
Major
3
4

Muscles

Rectus capitis anticus major.

O. Ant. tubercles of Transv. pro. of the 4 inf Cerv. Vert.

I. Basilar process of occipital Bone (or Cuneiform)

Rectus capitis anticus minor.

O. Transverse process of the atlas.

I. Cuneiform process of occipital Bone.

Rectus: Capitis lateralis

O Transverse process of Atlas

I Jugular process of occipital Bone in semilunar Ridge

Longus colli.

O Bodies of 3 sup Dorsal & 4 Inf. Cervical Vert. Intervertebral lig.ts head of 1st Rib. & ant tubercles of the Transverse pro. of the 4 Inf Cerv. Vert.

I Fore part of 1st 2nd & 3rd Cervical vert.

Constrictor Pharyngis inferior.

O. Side of Cricoid Cart. — inf Cornu & ridge at side of the Ala of the Thyroid Cart.

I. Mesial line on back of the Pharynx.

Constrictor Medius.

O Cornu & appendix of Os Hyoides. & Style Hyoid & Thyro Hyoid Lig.

I Medial line & Basilar pro of Occipital Bone (Cuneiform)

X Round Hamular Process of
of Int. Pterygoid Plate

Muscles

Constrictor Superior

O. Petrous Portion of the Temporal Bone. inf part of Int. Pterygoid Plate. & hamular process of Sphenoid post 1/3rd of the Mylo Hyoid Ridge & side of the Base of the Tongue.

I Basilar Process of Occipital Bone & median line of the Pharynx.

Levator Palati.

O Petrous portion of Temporal Bone in front of the foramen carotidum & behind Eustachian tube

I into the Velum (broad).

Tensor - vel circumflexus Palati.

O Depression at the Root of Int Pterygoid Plate Spinous process of the Sphenoid Bone & ant part of the Eustachian tube. (tendon turns round the hamular process.)

I By a broad expansion in median line of Velum

Azygos Uvulae - Motor Uvulae

O Post extremity of the spine of the Palate Bones.

I Cellular tissue of the Uvulae

Palato Glossus. Vel. Constrictor Isthmii faucium -

O. Inf surface of the Velum

I Side of the Tongue

Posterior View of Larynx.

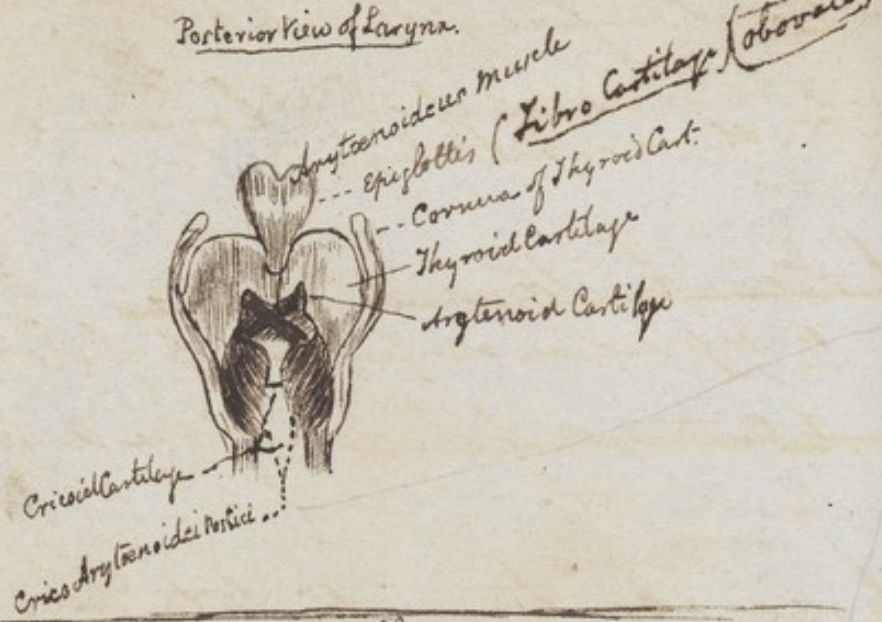

Side View of Larynx

Sacculus Laryngis or Ventricle of Galen is formed on each side of Thyr.d Cartg

Muscles.

Palato Pharyngeus

O. Inf surface of the Palate

I Side + Back of the Pharynx + sup cornu of the Thyroid Cartilage.

Crico Arytenoidei postici

O Depression on post surf of the Cricoid Cart

I Outer side of the base of the Arytenoid Cart.

Crico Arytaenoidei laterales

O Upper edge of the side of the Cricoid Cart.

I Base of Arytenoid Cart.

Thyro Arytaenoidei.

O. Post surf near angle of Thyroid Cart.

I Ant edge of Arytaenoid Cart.

Arytenoideus.

Consists of oblique + transverse fibres closely united, at Post Concave surf of Arytenoid Cart. Oblique fibres cum from apex of one Cartilage to Base of opposite Transverse — are attached to Posterior surface of each Cartilage

BACK

Trapezius.

O Ext 1/3 of sup Curved line of Occipital Bone Lig. Nuchae. + Spin Pro. of last Cerv + all Dors. Vert.

I Post Border of Ext 1/3 of Clavicle + Acromion Process also sup edge of the spine of the Scapula.

Splenius Capitis } Or. Lig Nuch. & Sup Cer V & Sup 6 Dors V. & spines
Splenius Colli } In. Post pt of Mast Proc. below Sup Ridge of occip: + Transv. Proc of 3 or 4 Sup Cerv. Vert.

Complexus lies immediately Below Splenius

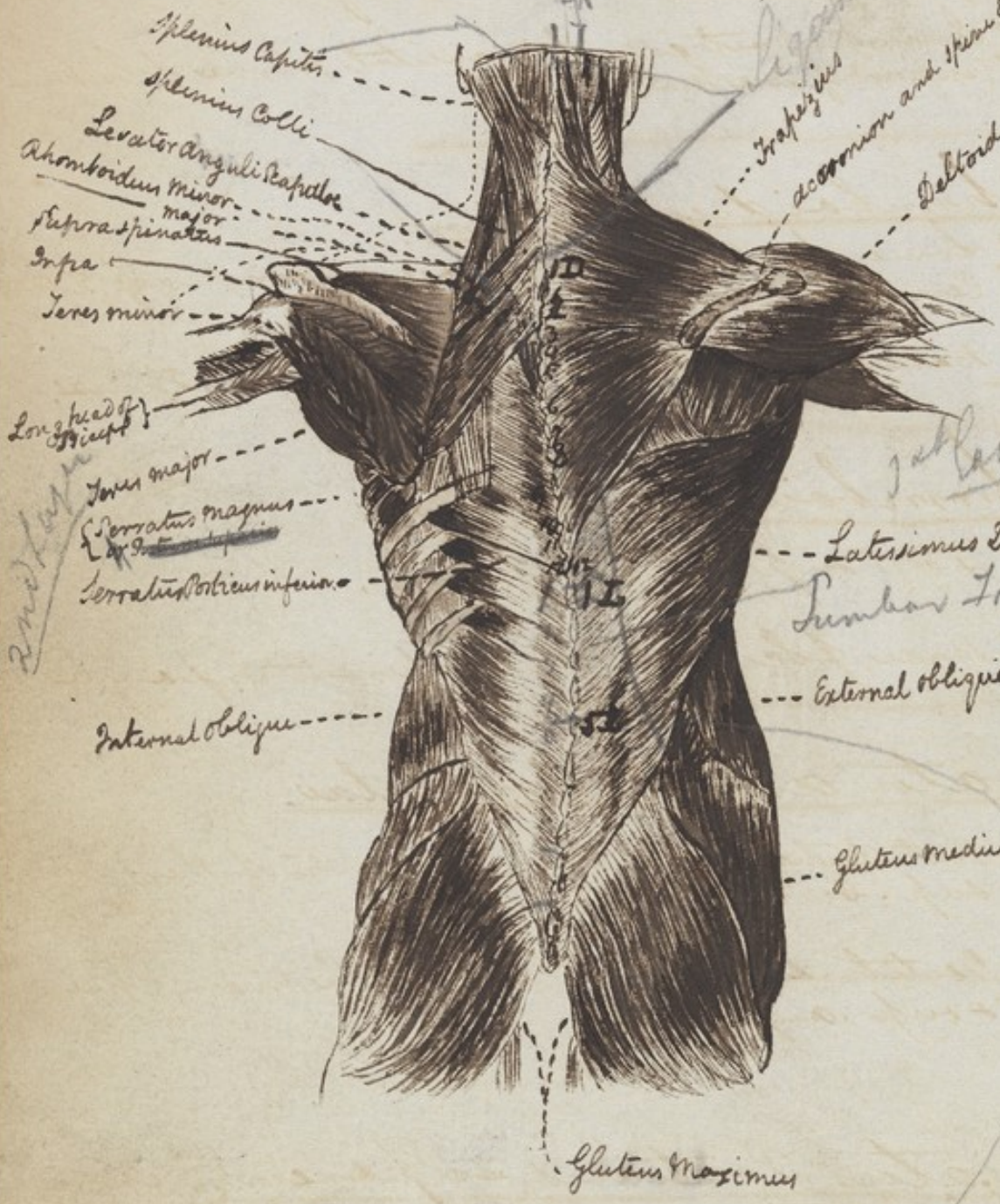

O of Sacrolumbalis lies beneath Latissimus Dorsi + Longissimus Dorsi

Muscles

Latissimus Dorsi.

O. 6 Inf Dorsal spines - by lumbar fascia from all the Lumbar spines, back of the Sacrum, post 1/3 of the Crista Ilii & 3 or 4 Inf Ribs.

I ~~Inserts~~ post edge of bicipital groove of the humerus (in front of Teres Major)

Rhomboideus Minor

O. Lower part of Lig Nuchae. & spin pro of (2) last Cervical vert

I Base of Scapula opposite to & above the Spine.

Rhomboideus Major

O. 4 or 5 sup Dorsal Spines.

I Base of Scapula from Spine to Inf angle

Levator anguli Scapulae.

O. Post tubercles of Transverse Pro of the 4 or 5 sup. Cervical vert.

I Base or Vertebral Border of Scapula between Spine & sup. angle.

Serratus Posticus superior (~~S. Magnus~~)

O. Lig. Nuchae & 2 or 3 Dorsal Spines.

I 2nd 3rd & 4th Ribs, external to their angles.

Transverse Section of Neck

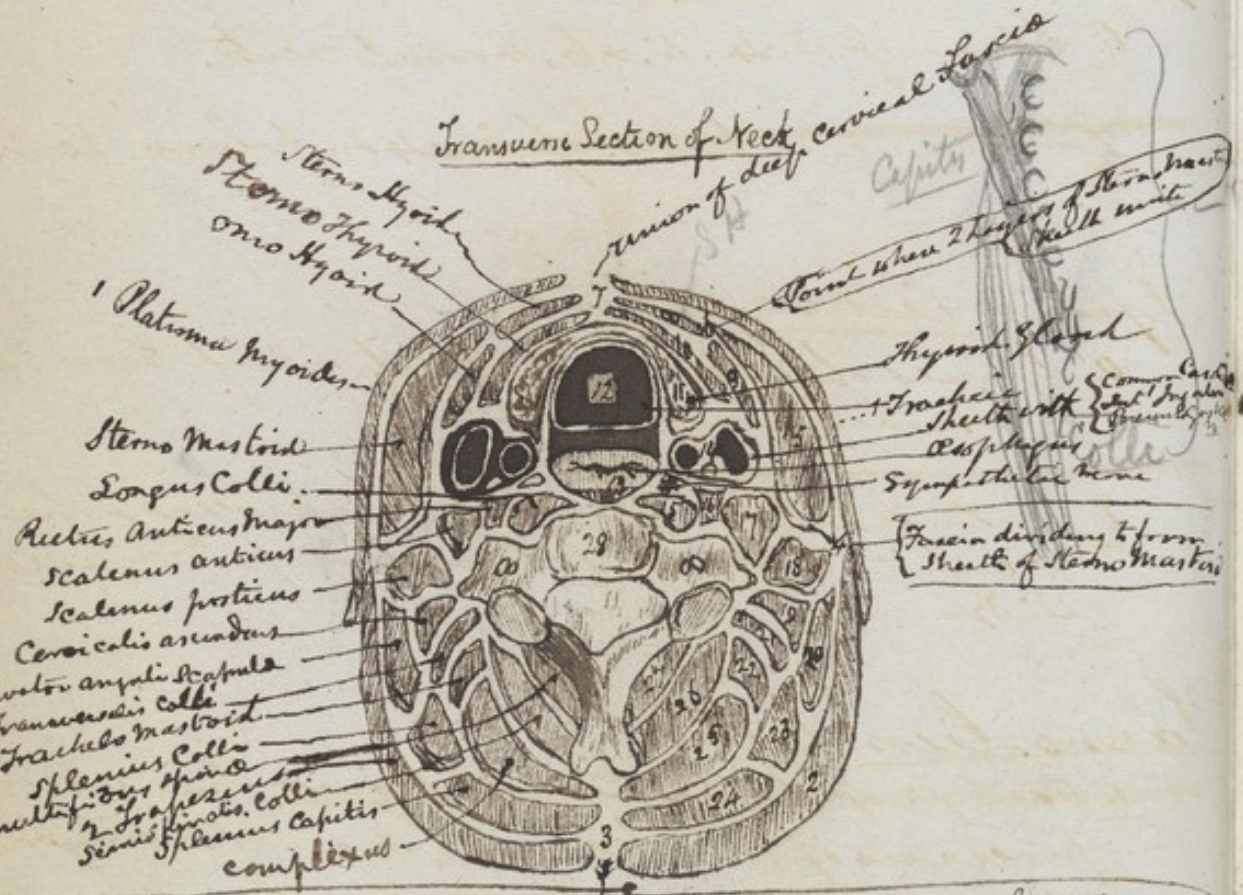

1 Platisma myoides - 2 Trapezius - 3 Ligamentum Nuchae from which there are prolongations of Fascia enclosing Muscles of neck - 4 Point at which Fascia divides to form a Sheath for Sterno Mastoid m. 5 - 6 Point where 2 layers of Sterno Mastoid Sheath unite - 7 - Point of Union of Deep Cervical Fascia of opposite sides - 8 Sterno Hyoid - 9 - Omo Hyoid - 10 Sterno thyroid - 11 - Lateral Lobe of Thyroid gland - 12 Trachea 13 - Oesophagus - 14 Sheath containing Common Carotid artery - Internal Jugular vein and pneumogastric nerve - 15 Longus Colli - The nerve in front of this muscle is Sympathetic* - 16 Rectus Anticus Major 17 Scalenus anticus 18 Scalenus Posticus 19 - Cervicalis ascendens 20 Levator Anguli Scapulæ 21 - Transversalis Colli 22 - Trachelo Mastoid 23 - Splenius Colli 24 Splenius Capitis - 25 Complexus - 26 - Semispinalis Colli - 27 Multifidus Spinæ 28 Cervical Vertebra -

Muscles

Serratus Posticus inferior.

O 2 last Dorsal & 2 or 3 sup Lumbar Vert. Spins

I Lower border of the 4 Inf ribs ant to their angles.

Splenius Colli.

O. Spines of 3. 4. 5. & 6 Dorsal vert.

I Transverse proc. of 3 or 4 sup Cerv. Vert.

Splenius capitis

O. Spines of the 2 sup Dorsal & 3 inf Cerv. Vert & Ligamentum nuchae.

I Post part of the Mastoid process & the occipital Bone below its sup Transverse ridge

Sacro-lumbalis

O Part 1/3 of Crista Ilii, oblique & Transverse processes of the Sacrum, Sacro Iliac ligt. Transverse & oblique art processes of Lumbar Vert

I all the ribs near angles—

Longissimus Dorsi

O. Part sup of Sacrum & Transverse & art processes of Lumbar Vert.

I All Internally Dorsal Vert. & Externally all ribs between their tubercles & angles.

4th Layer

3rd Layer

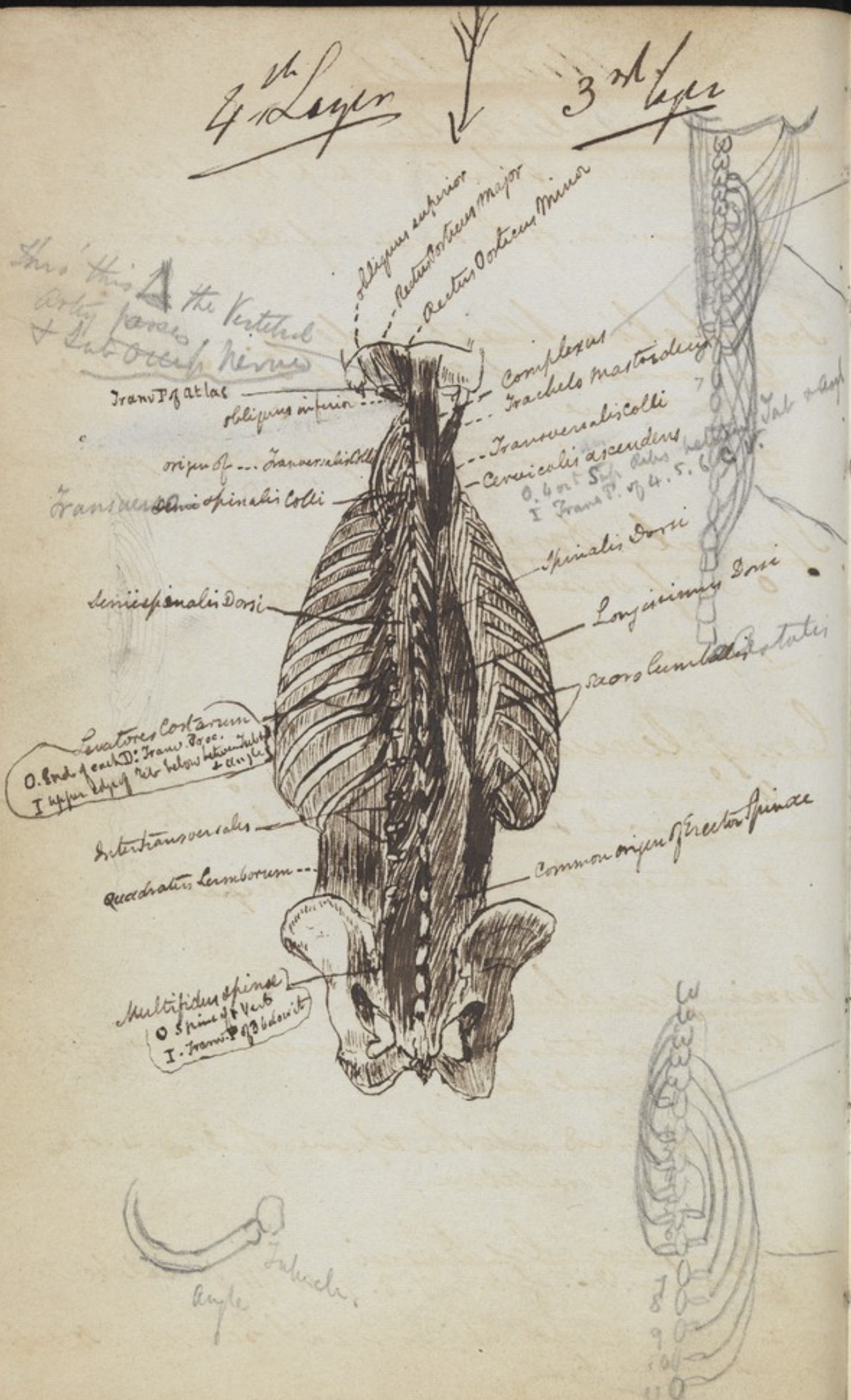

Muscles

Transversalis Colli.

O Transv. Pro of the 5 or 6 sup Dorsal vert.

I Transv. Pro. of the 3 or 4 inf cervical vert.

Trachelo Mastoideus.

O Transv. Pro of 3 or 4 inf Cervl & 4 sup Dorsal vertebrae

I Inner & post part of mastoid process

Spinalis Dorsi.

O 3 inf Dorsal & 2 sup lumbar Vert Spines

I 9 sup Dorsal Spines.

Complexus

O Transverse process & oblique art pro. of 3 or 4 inf Cervical & 5 or 6 sup Dorsal vert.

I Between Curved lines of Occipital bone

Semi spinalis Colli.

O. Extremities of the Transverse pro. of 5 or 6 sup Dorsal vert.

I By 4 heads into the spines of 2, 3. 4. & 5 Cervical vertebrae.

Semi spinalis Dorsi

O Transv. Pro. of 5. 6. 7. 8. 9. 10 & 11 Dorsal vert.

I Extremities of the spines of 2 inf Cerv & 3 or 4 sup Dorsal vert.


Rectus Dort. Minor
Obliquus Sup
Obliquus Inf
Rectus D. Major

Muscles

Rectus capitis posticus major

O Spinous pro of 2 Vertebra.

I Inf curved line of occipital bone.

Rectus capitis posticus minor.

O. Post part of Atlas.

I Occipital bone behind foramen magnum.

Obliquus capitis inferior

O Spinous pro of the 2nd Vertebra

I Extremity of transverse pro of the Atlas.

Obliquus capitis superior.

O Upper part transv. pro of Atlas.

I Occipital bone between curved lines past. to the Mastoid Process.

Inter-spinales

Situated between Spinous pro. of the Vertebrae (most distinct in the neck appear double in neck)

Intertransversales

Situated between the transverse processes of the Vertebrae, seen best in Cervical Region

Spine of 1st
Transverse of 3rd

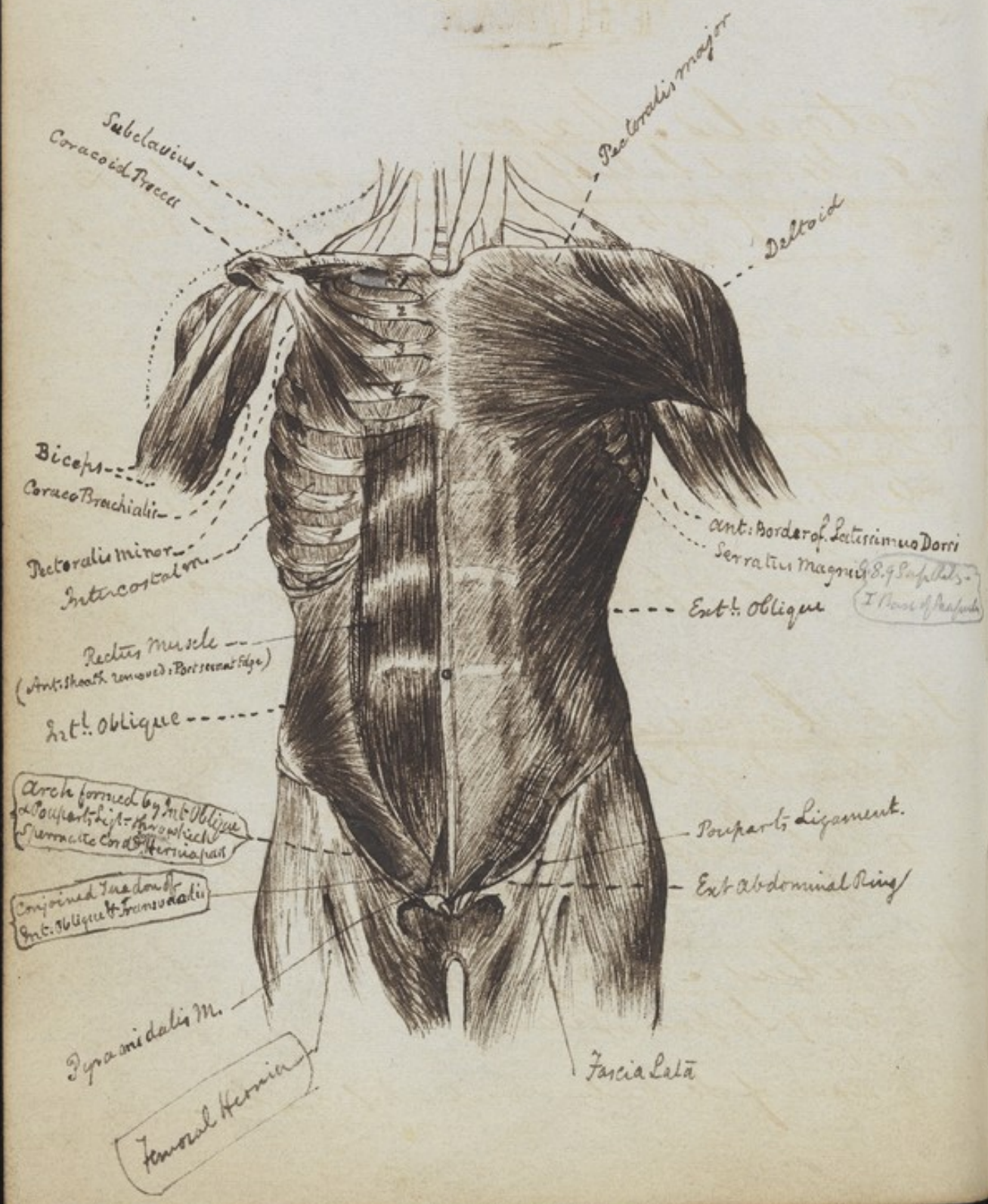

Muscles

Multifidus Spinae.

It is a combination of muscles — each —

O. 1st Vertebrae & every other.

I Sacrum, & every 2 or 3 vert.

(The first arises from spine of Dentatus and is inserted into transverse process of third and so on to last which arises from spine of Last Lumbar Vertebra and is inserted into tube Transverse Proc. of Sacrum

THORAX

Pectoralis Major.

O. Sternal half of Clavicle. ant surf of Sternum Cart of 3, 4, 5, & 6 Ribs. (True) & from the aponeurosis common to it & the Obliquus Exct.

I Ant Edge of Bicipital groove and fascia of arm

Pectoralis Minor

sometimes 2nd Rib

O Ext. surf & upper edges of 3, 4, & 5 True Ribs

I Inner & sup surf of Coracoid process

Subclavius

O Cart of 1st Rib

I Exct half of inf surf of the Clavicle. (between Conoid & Trapezoid ligaments.)

Serratus Magnus.

O 8 or 9 Superior Ribs

I Base of Scapula (& sup & inf angles).

Fünfter Zehenstrahl



Muscles

Upper Extremity

Deltoideus

O. Lower edge of spine of Scapula, ant edge of the Acromion & External 1/3 of Clavicle.

I Rough surf on middle of Ext surf of Humerus

Supra Spinatus

O all the Scapula above the spine.

I Sup & ant parts of the great tuberosity of the Humerus.

Infra Spinatus

O Inf surf of spine & Dorsum Scapulae as low down as the post ridge on it inf costa

I Middle of greater tuberosity of Humerus.

Teres Minor

O Depression between the two ridges on inf costa of the Scapula, (fascia covering it) & ligamentous enclosing it separate

I Inf depression on greater tuber of Humerus

Teres Major

O Rough surf on inf angle of the Scapula below infra spinatus.

I Inner Edge of Bicipital groove in the Humerus behind the insertion of Lats. Dorsi

Anterior Aspect of ~~Upper~~ Arm

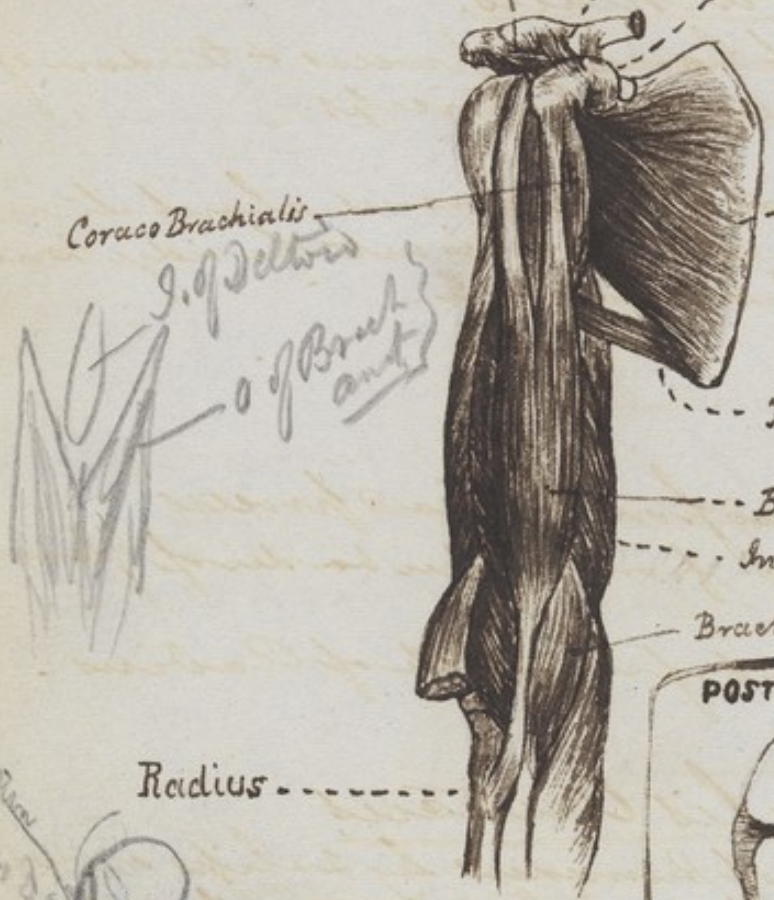



Muscles

Sub-scapularis.

O All the surf of subscapular fossa.

I lesser tubercle of the Humerus.

Coraco Brachialis.

O Point of Coracoid process & tendon of the short head of the Biceps.

I Inner side of the Humerus about its middle & by an aponeurosis into the ridge leading to the Inner Condyle.

Biceps

O. Short head from Coracoid process
Long head from upper border of Glenoid Cavity

I Post part of Tubercle of Radius.

Brachialis Anticus

O. Middle of Humerus by 2 slips on sides of insertion of the Deltoid & from fore part of the humerus to the Condyles.

I Coronoid process & rough surf beneath it in Ulna

Triceps Extensor Cubiti

O. Middle or Long head from lower part of neck of the Scapula & ant pt of Inf Costa
Ext Hd from ridge on Humerus below insertion of Teres minor. Ext. Condyle
Int or short head from ridge below insertion of Teres major leading to Inner Condyle & intermuscular septum

I Olecranon process of Ulna & fascia of forearm

8 Flexors & Pronators { 5 Superficial, 3 Deep } Int. Cond. except Flexor of Thumb

Superficial Muscles of the Forearm



Muscles

Pronator radii teres.

O Ant part of Inner condyle fascia of forearm Intermuscular septa & Coronoid 2nd & 3rd phs. of Ulna

I Middle of outer & back border of the Radius.

Flexor Carpi Radialis

O Inner condyle & intermuscular septa

I Base of metacarpus of Index finger.

Palmaris longus.

O Inner Condyle & fascia of forearm.

I Annular lig^t. & palmar aponeurosis near the root of the Thumb.

Flexor Carpi Ulnaris.

O Inner condyle, Inner side of the Olecranon Inner border (nearly all) of Ulna & fascia of the forearm

I Os hiniforme & Base of 5th. metacarpus.

Flexor Digitorum sublimis (perforatus

O Inner condyle Int. lat. lig^t, Coronoid proc & Radius below its tubercle

I Ant part of 2 Phalanx of each finger.

Deep Muscles of Forearm

Muscles

Flexor digitorum profundus (perforans)

O 3 sup fourths of ant surf of Ulna
Inf. 1/2 of Int Osseous lig. sometimes from the Radius below its tubercle.

I Last Phalanx of each finger.

Flexor Pollicis longus

O Ant part of Radius below tubercle - Interosseous membrane to within 2 In of Carpus

I Last Phalanx of the Thumb.

Pronator Quadratus.

O. Inf 1/5 of ant surf of Ulna

I ant part of Inf 1/4 of Radius.

Supinator Radii longus

O Ext ridge of Humerus from below Delt. to within 2 In of the outer Condyle & Intermuscular lig.

I Rough surface on out side of Radius near Styloid process.

Extensor Carpi radialis longior

O Ridge of Humerus between supinator longus & ext Condyle.

I Back part of Carpal Extremity of Metacarpus of Index finger.

Extensor - Brevior

O. Inf & Post part of Ext. Condyle & Ext lat lig.

I Carpal end of 3rd Metacarpus

Superficial Muscles of Back of Forearm

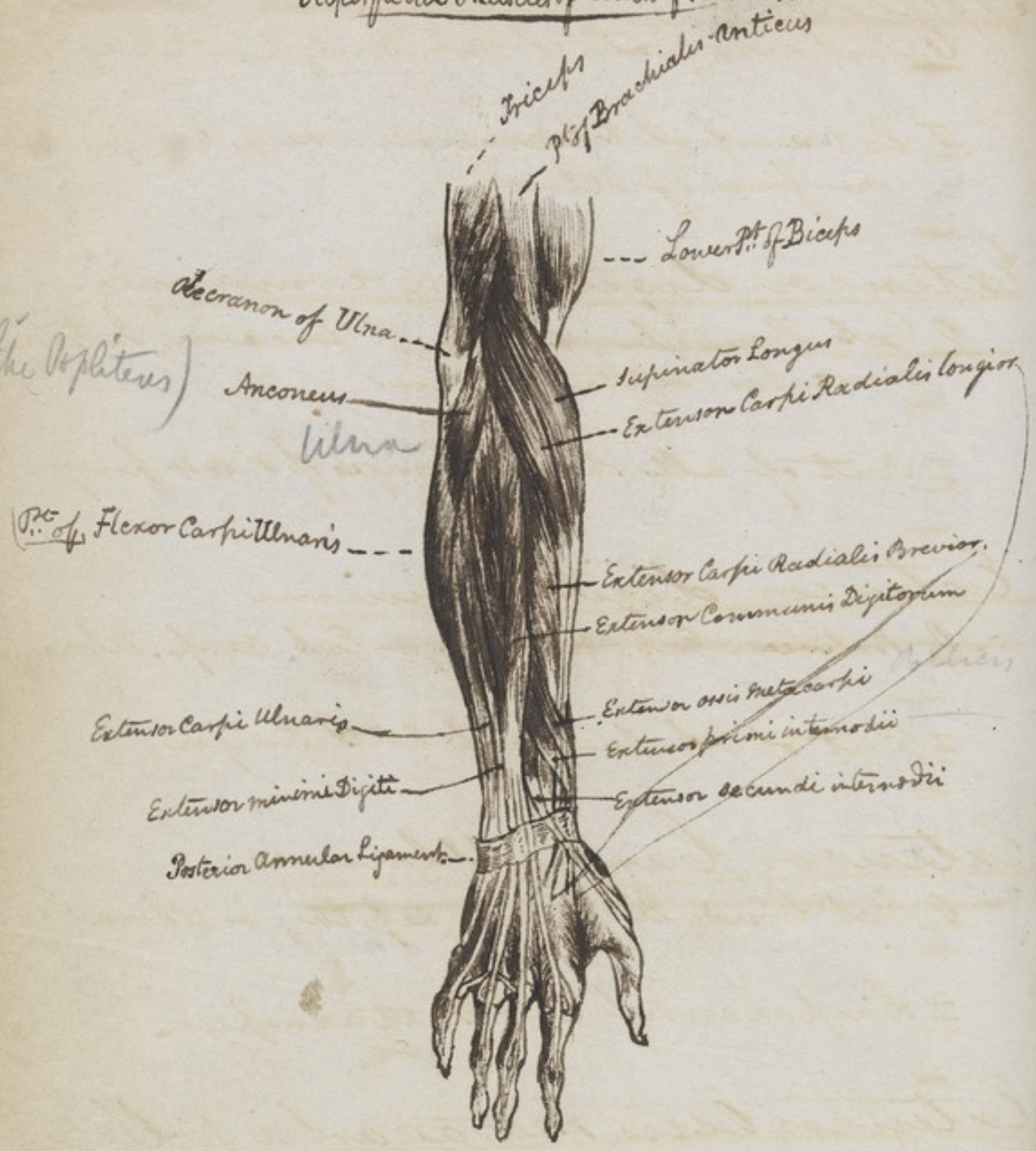

Muscles

Anconeus.

O Post & Inf part of Ext. Condyle & lat lig.

I Ext surf of Olecranon & sup 1/3 of post surface of Ulna.

Extensor digitorum Communis.

O Ext Condyle, fascia of forearm, Intermuscular septa & Ulna

I Post of all the Phalanges of the 4 fingers.

Extensor digiti minimi

O. Between Ext. dig. Com, & Ext. carp. Ulnaris

I Post of Phalanges of little finger.

Extensor Carpi Ulnaris.

O Ext Condyle, fascia, septa, & Ulna

I Carpal end of 5th Metacarpus.

Extensor Ossis Abductor metacarpi pollicis.

O Middle of Post surf of Ulna below Anconeus Int osseous lig & post surf of Radius below Supinator Brevis

I Os Trapezium & sup & post part of metac of Thumb

Extensor Minor primi internodii pollicis

O Post part of Ulna Int. Osseous lig & Radius

I Post part of 1st Phalanx end of thumb 2d

Deep Muscles of Back of Fore Arm

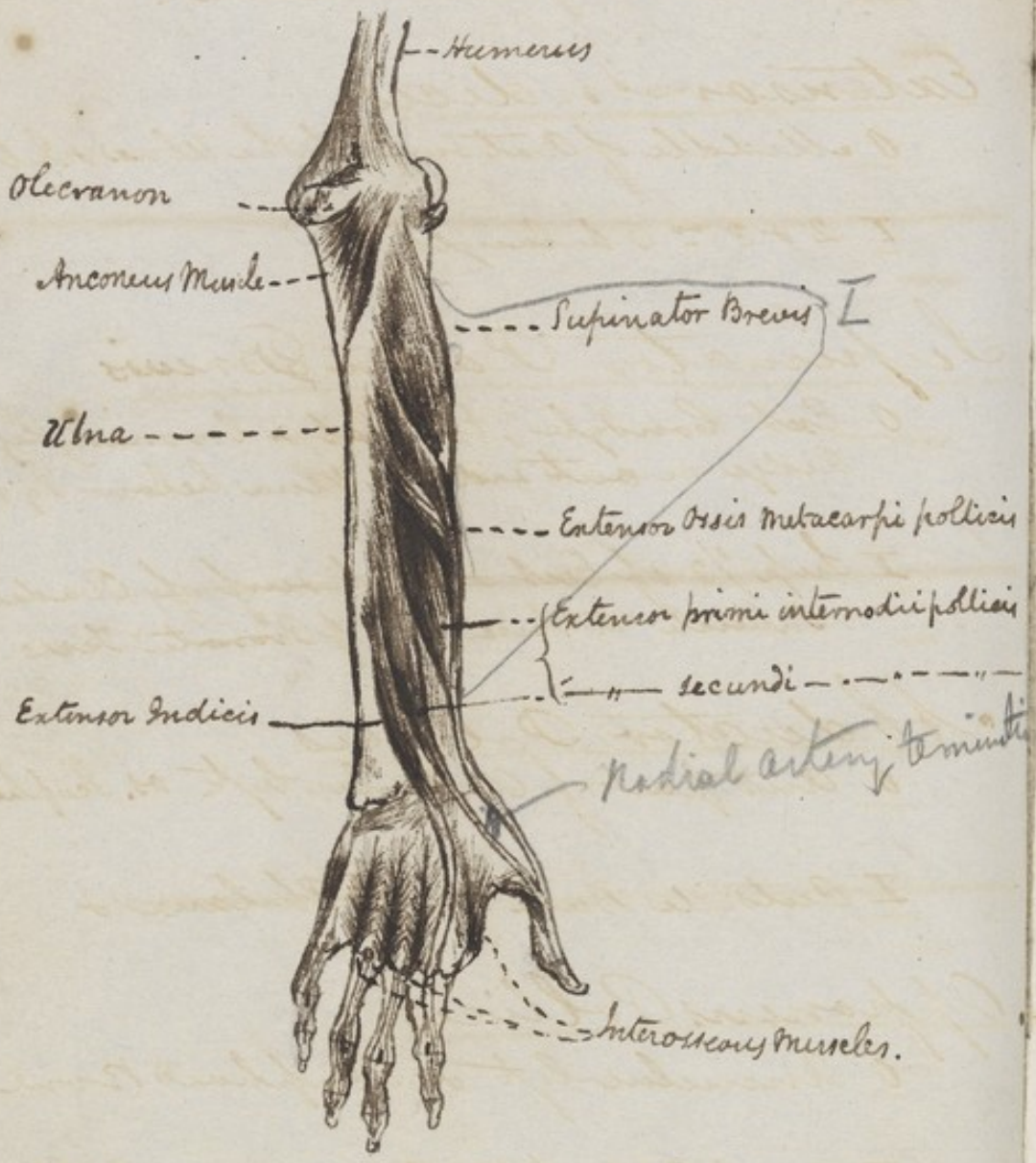

Muscles

Extensor secundi internodii pollicis (major)

O Post surf of the Ulna sup 1/2) & Int oss. lig.

I Post part of last Phalanx.

Extensor Indicis (Indicator)

O Middle of Post surf of the Ulna & Int oss lig.

I 2 & 3rd Phalanges. (of Forefinger)

Supinator Radii Brevis

O Ext Condyle, Ext lat, & Coronary lig. Ridge on outside of Ulna below (Olec) Sigmoid Cavity

I Sup 1/3 of Ext & ant surf of Radius from Tubercle to Insertion of Pronator Teres.

Abductor Pollicis

O Ant part of Annular lig. os. Scaphoid & Trapezium

I Outside Base of 1st Phalanx & process to 2nd

Opponens Pollicis. (Flexor ossis Metacarpi Pollicis)

O Annular lig & Scaphoid Bone (& Navicular)

I Ant Ext of Metacarpus of Thumb.

Flexor Brevis Pollicis.

O Ext head (ant) Inside Ann. lig & Scaphoid & Trapezium

Int head (post) os magnum & Trapezoid (& base of metacarp of mid finger)

I Ext into Ext, Int into Int Sesamoid Bones & Bases of 1st Phalanx of the Thumb

Muscles of the Hand

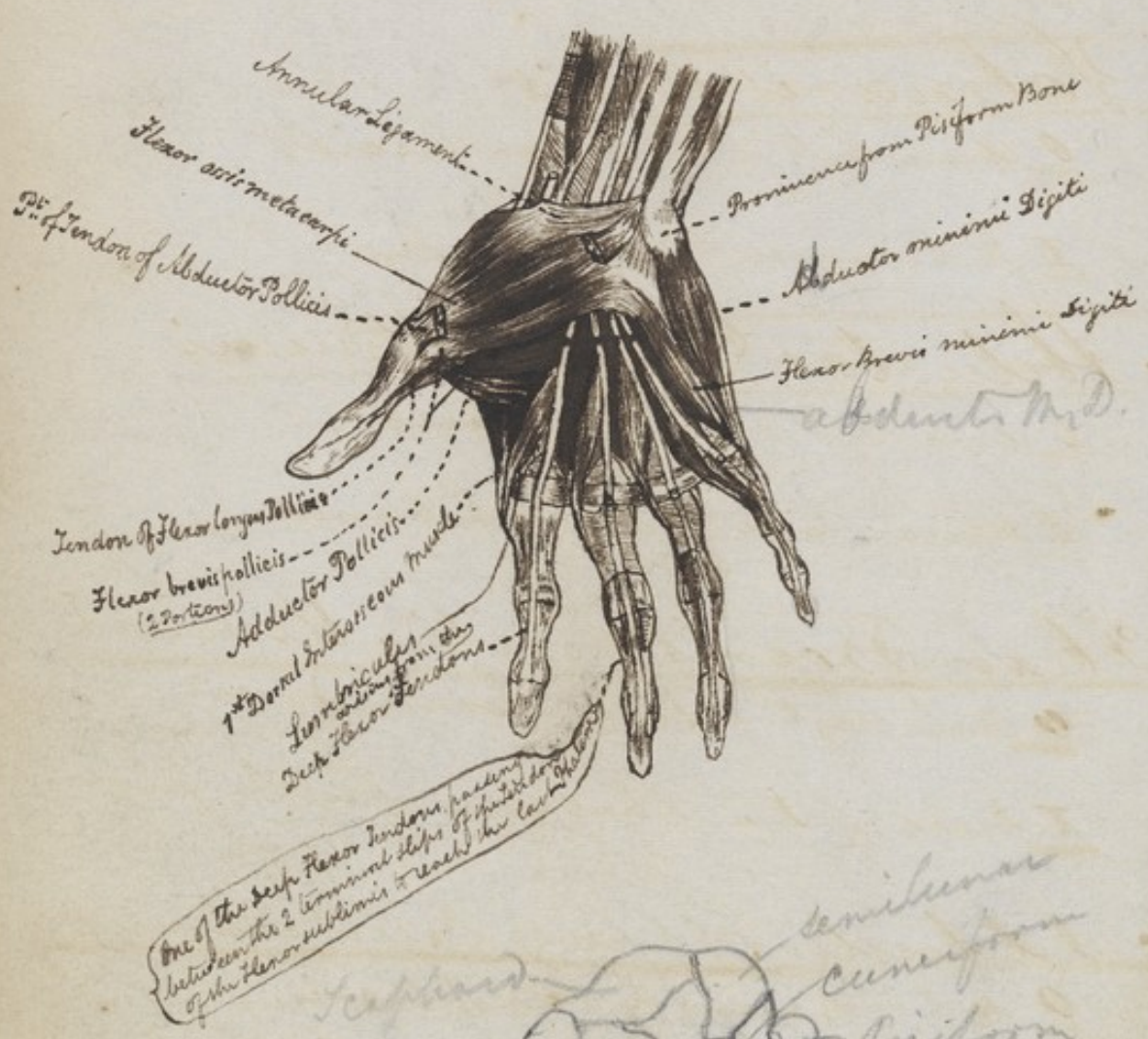

Muscles

Adductor Pollicis

O 3/4 of Ant surface of 3rd Metacarpus

I Inner side of the root of the 1st Phalanx

Palmaris Brevis

O Ann lig & Palmar fascia.

I Integument ~~inside~~ inner side of Palm Palm

Abductor Digiti Minimi

O Ann lig & Os Pisiforme

I Ulnar side of 1st Phalanx

Flexor Brevis Digiti Minimi

O Ann lig & Unciforme Bone

I Base of 1st Phalanx of little finger

Adductor (Opponens) Digiti Minimi

O Int to & Covered by Flexor Brevis.

I all the Metacarpus of little finger.

Lumbricales

O. Outer side of the Tendons of Flexor Profundus, near the carpus, beyond Ann lig

I Middle of 1st Phalanx into Tendinous Expansion on Back of each finger.

According to Lizars

Dorsal Interossei

1st Abductor indicis	3rd Adductor medii digiti
2 ——— medii digiti	4th ——— annularis

Palmar Interossei

1 Adductor indicis	2d Abductor annularis
	3rd Abductor minimi digiti

The Abductor	of Fore Finger is	1st Dorsal Inteross.
The Adductor		1st Palmar ———
Abductor	of mid Finger is	2nd Dorsal
Adductor		3 Dorsal
Abductor	of Ring Finger is	2 Palmar
Adductor		4 Dorsal
Abductor	of Little Finger is	4 Dorsal
Adductor		3 Palmar

Muscles

Interossei Posteriores - Dorsal

1st O 2 & 3rd Metacarpas (Abductor indicis)
I out side of Base of 1st Phalanx of Mid finger

2nd O 3 & 4th Metacarpus. (Abductor medii digiti
I Inner side of 1st Phalanx of mid. finger.

3rd O 4 & 5th Metacarpus
I Inner side of Ring finger.

Interossei Anteriores Palmar

1st O Radial side of 2nd Metacarpus.
I Ext side of 1st Phalanx of forefinger

2nd O Ulnar side of 2nd Metacarpus (Adductor Indicis)
I Inner side of 1st Phalanx of Fore finger

3rd O Radial side of 4th Metacarpus (Adductor annulari)
I Ext side of 1st Phalanx of little finger

4th O Radial side of 5th Metacarpus Abductor Min. Dig.
I Ext side of 1st Phalanx of little finger

ABDOMEN

Obliquus Externus abdominis. (descendens)

O Ext surface of 8 or 9 Inf ribs at a little distance from their cartilages.

I Ensiform cart. linea alba. os pubis, Poupart's lig. ant sup. spin process of Ilium & outer edge of 2 and 3rd of Crista

Lateral View of the Trunk of the Body

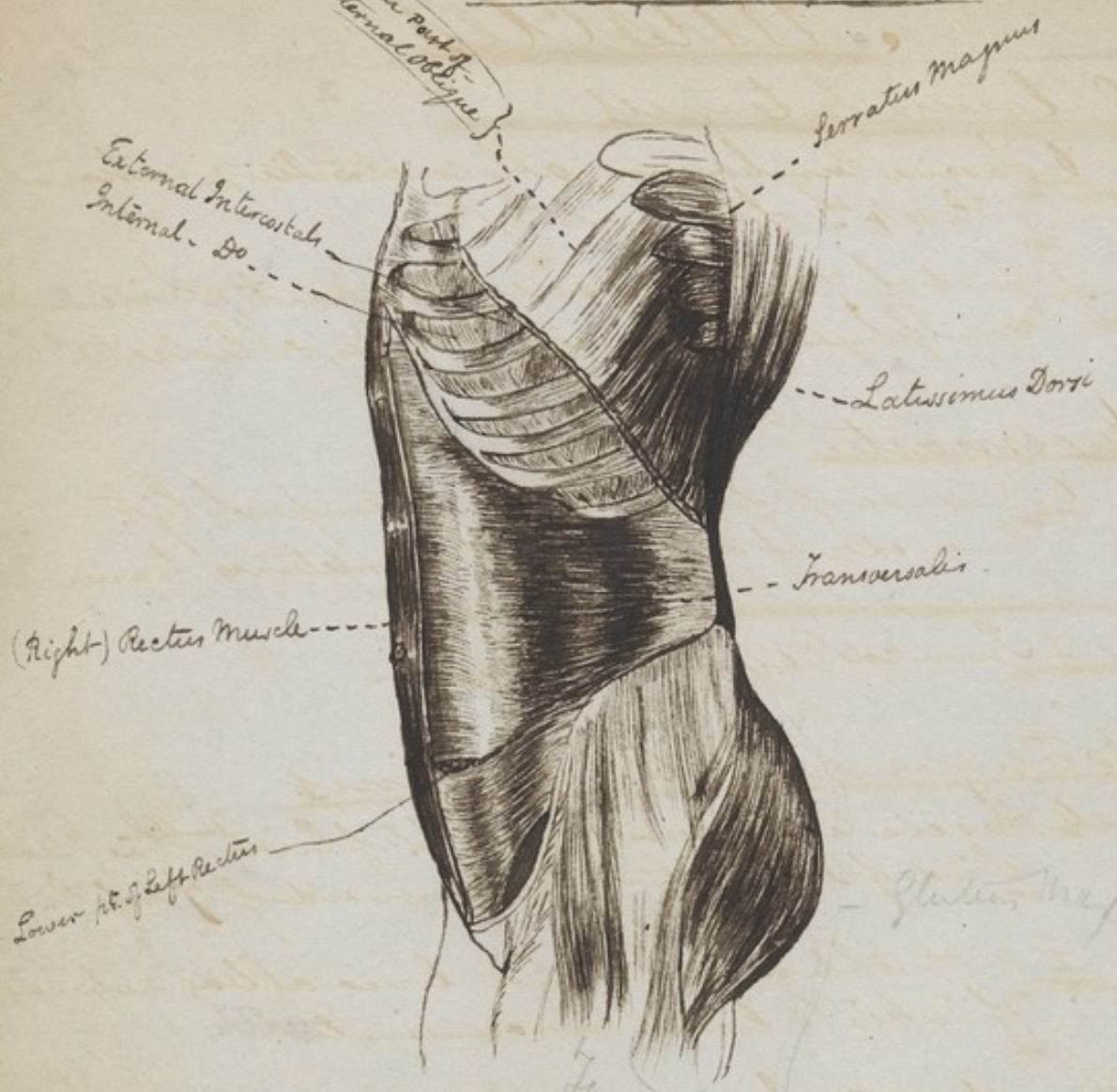

Muscles

Obliquus Internus

O Fascia lumborum, all Cristæ ilii & external 3rd or 4th of Poupart's lig.

I Cart of 7 Inf ribs - ensiform cart, linea alba symphysis & upper edge of Pubis, & Ilio Pectineal line

Cremaster

O Inner surf of the Ext 1/3 of Poupart's lig. & lower edge of Obliquus Int & sometimes Transversalis (sometimes tendon from Pubis)

I Tunica Vaginalis (& Scrotum)

Transversalis Abdominis

O Fascia lumborum, post pt of Crista Ilii, Iliac third of Poupart's lig. & inner side of 7 Inf Ribs

I with obliquus Int into linea alba, sup edge of Pubis & linea innominata. Ilio Pectineal

Rectus Abdominis

O Sup & ant part of pubis

I Ensiform Cart. Internal Costa xiphoid lig & Carts of 6th & 7th Ribs. 5th Mid Ext.

Pyramidalis

O Pubis

I linea alba midway to Umbilicus.

Quadratus lumborum

O Post 1/4 of Spine of Ilium, & Ilio lumbar lig.

I Extremity of Transverse Proc. of 4 sup Lumbars last dorsal vert. & Int surf. of Post half of last rib

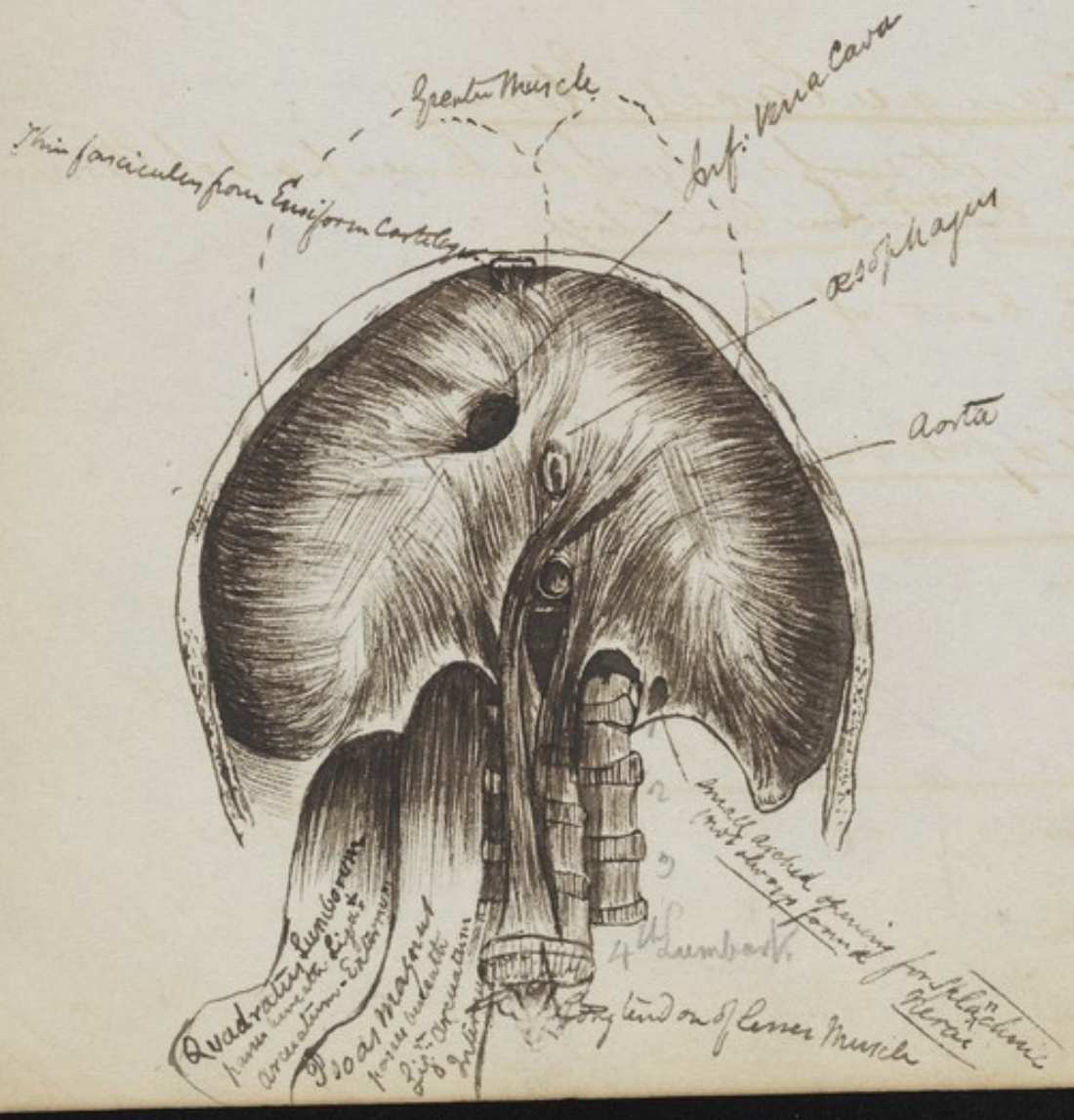
Greater Muscle
Inf. Vena Cava
This fasciculus from Ensiform Cartilage
Oesophagus
Aorta
Small opened opening for Sympathetic Nerve
2
3
4th Lumbar
Quadratus Lumborum
Psoas Magnus
Long tendon of Lesser Muscle

Muscles

Intercostales Externi (11 in number)

O Inf edge of each rib commencing at Tuber Proc Vert

I Ext lip of sup edge of rib beneath as far as behind the costal Ext of the Cartilage.

Intercostales Interni 11 in number

O At sternum from Inner lip of the lower edge of each cartilage & rib as far as the angle

I Inner lip of sup edge of the Cart & rib beneath

Levatores Costarum.

O Extremity of each Dorsal Transverse pro.

I Sup edge of rib beneath between Tubercle & angle

Triangularis Sterni

O Post surf & edge of the lower part of sternum Ensiform (Xiphoid) Cartilage

I Cart of 4, 5, & 6 ribs.

Diaphragm.

Muscles of Perineum

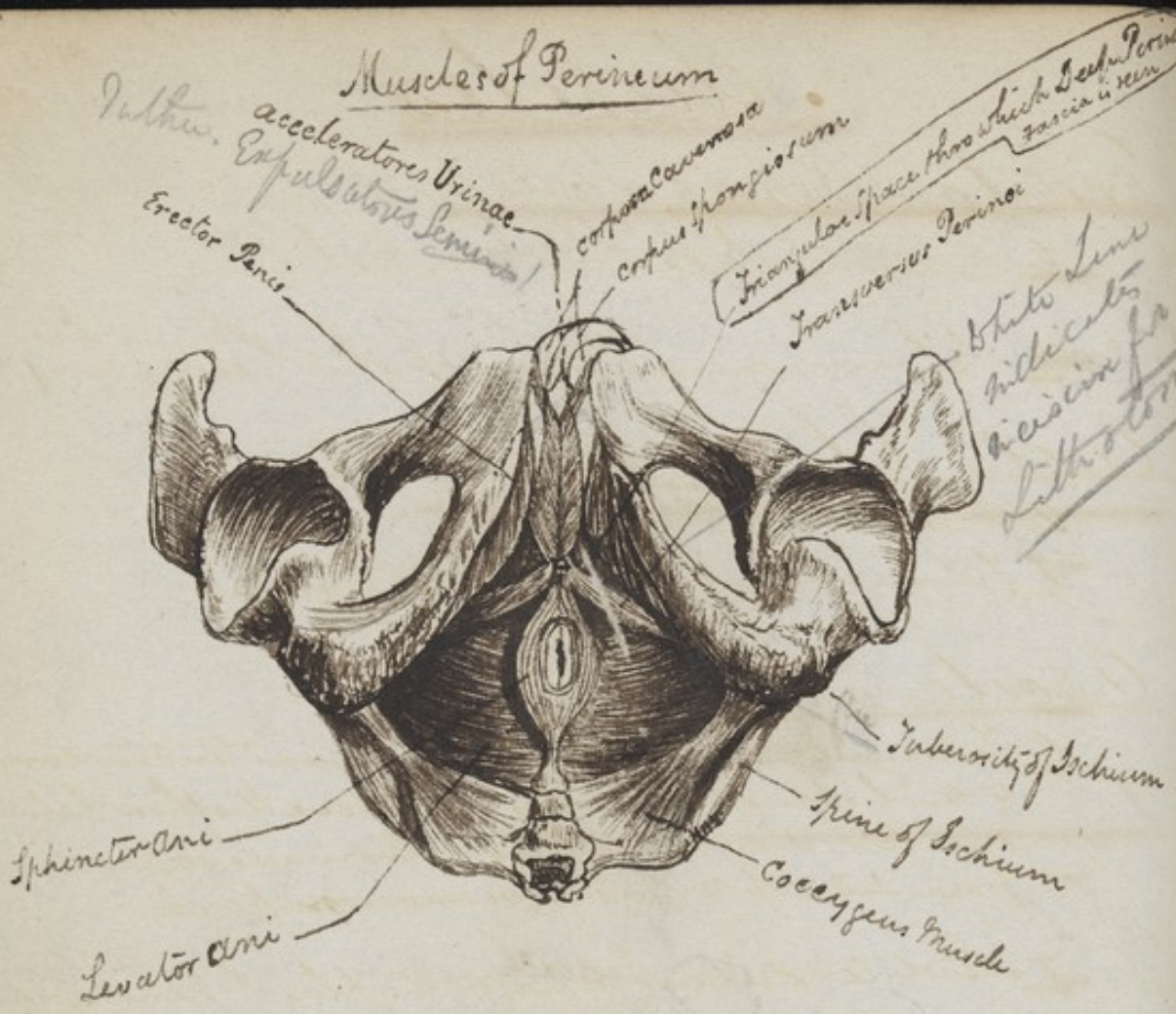

Muscles

Erector Penis (Male)

O. Inner surface of Tuber. Ischii

I Fibrous membrane of the Crus penis.

Erector Clitoridis (female)

O Inner surf of Tuber Ischii.

I Fibrous membrane of Crus Clitoridis.

Accelerator Urinae.

O Triangular lig of Urethra, Broad tendon common to both opposite muscles lies above Urethra between it & pubis. & more ant by a tendinous expansion from side of Corpus cavernosum penis

I Mid tendinous line or Raphe of perineum

Transversus Perinei.

O Inside of Tuber Ischii

I Central point of the perineum.

Compressor Urethrae. (male)

O Inside of Symphysis Pubis.

I Below membranous portion of Urethra. into the narrow tendinous line which becomes lost in the central point of the Perineum.

Compressor Venae dorsalis penis. male

O Inner margin of Ramus Pubis. just above Erector Penis.

I Medial line just over the dorsal vein

Constrictor (Sphincter) Vaginae. (female)

Extends from the Clitoris superiorly round each side of the Vagina to the Central point of the Perineum in front of the Anus.

Muscles

Sphincter Ani

O Anus Coccygeal lig.

I Into the raphe superficial fascia, & common central point of perinaeum.

Sphincter Internus

Encircles the lower part of the Rectum.

Levator Ani.

O Post pt. of symphysis Pubis. obturator fascia Ilium above thyroid foramen & inner surf of Ischium & its spinous process.

I Ant fibres. into central pt of Perinaeum & lower part of Rectum, Middle, into side of Rectum & Posterior, into back part of the Rectum - os coccygis, & last bones of Sacrum.

Coccygeus

O Inner surf of spine of Ischium

I Extremity of Sacrum & side of Coccyx.

Psoas Magnus

O Sides of the Bodies of 2 last Dorsal & Bodies & Transv. Pro of Lumbar Vert. & Intervertbl.

I Inf part & ridge below lesser Trochanter.

Psoas Parvus.

O Side of last Dorsal & 1st Lumbar vert.

I Iliopectineal line, fascia Iliaca, fascia lata & behind femoral vessels.

Anterior Muscles of Thigh

Muscles.

Iliacus

O Transverse pro of last lumbar vert. int marg of three ant fourths of Crista Ilii, ant spin process & notch between, brim of acetabulum, capsular lig. Iliac fossa & Iliac fascia.

I Into Psoas magnus. inf fibres into Ant & Inner surf of femur below trochanter minor.

Tensor Vaginae femoris.

O Ext pt. of ant sup spin pro of Ilium.

I Fascia lata 3 in below gt. Trochanter

Sartorius

O Ant sup. spine & notch beneath it of Ilium

I Inner side below tubercle at sup end of Tibia

Rectus femoris.

O Ant inf spine of Ilium, acetabulum & cap lig.

I Sup edge of Patella & its lig.

Vastus Externus

O Root & ant part of gt. Trochanter, outer edge of linea aspera, oblique ridge leading to outer condyle,

I. Ext surf of tendon of the Rectus side of Patella & head of Tibia

Muscles

Vastus Internus.

O. Ant part of femur, Inter trochant. line, inner edge of linea aspera &c

I. Inner side of the tendon of the Rectus, patella & head of the tibia.

Crureus. & Subcrureus

O. Ant & Ext pt of the femur

I. Up & out edge of Patella & synovial membrane of knee joint.

Gracilis

O. Lower half of the Symphysis & inner edge of the descending ramus of the os Pubis.

I. Sup pt of the Internal of the tibia

Pectineus

O. Linea innominata on the horizontal ramus of the pubis

I Rough ridge leading from the lesser trochanter to the linea aspera

Adductor Longus

O. Ant surface of the pubis between the spine & symphysis.

I Middle third of the linea aspera.

Posterior Muscles of Thigh

Outer Hamstring formed by the tendon of the Biceps muscle

Inner do — Sartorius M. with tendons of the
— Gracilis
— Semitendinosus
— Semimembranosus
~~3rd head of~~

Muscles

Adductor brevis.

O. Ant inf surf of the pubis between its symphysis & the thyroid foramen.

I Sup third of the Int rough of linea aspera to 3rd below lesser trochanter.

Adductor magnus.

O Ant surf of the descending ramus of pubis Ramus of the Ischium & ext border of its tuberosity

I Rough ridge leading from the great trochanter to the linea aspera, the linea aspera & int condyle of the femur.

Gluteus Maximus

O Post 1/3rd of Crista ilii, rough surface between it & sup semicircular ridge, post ilio sacral lig, lumbar fascia & spines of sacrum, side of coccyx & gr sciatic lig.

I Rough ridge leading from the great trochanter to linea aspera, upper 1/3 of linea aspera & fasciculatus.

Gluteus Medius.

O Deep surf of fascia covering it. 3 ant 4ths of Crista ilii sup semicircular ridge & surf of ilium above & below it.

I Int & Ext part of great trochanter.

Gluteus Minimus

O Inf semicircular ridge on dorsum ilii & rough surface between it & edge of acetabulum

I Sup & ant pt. of the gr. trochanter

Deep Muscles of Hip

Gnurcles of Hip

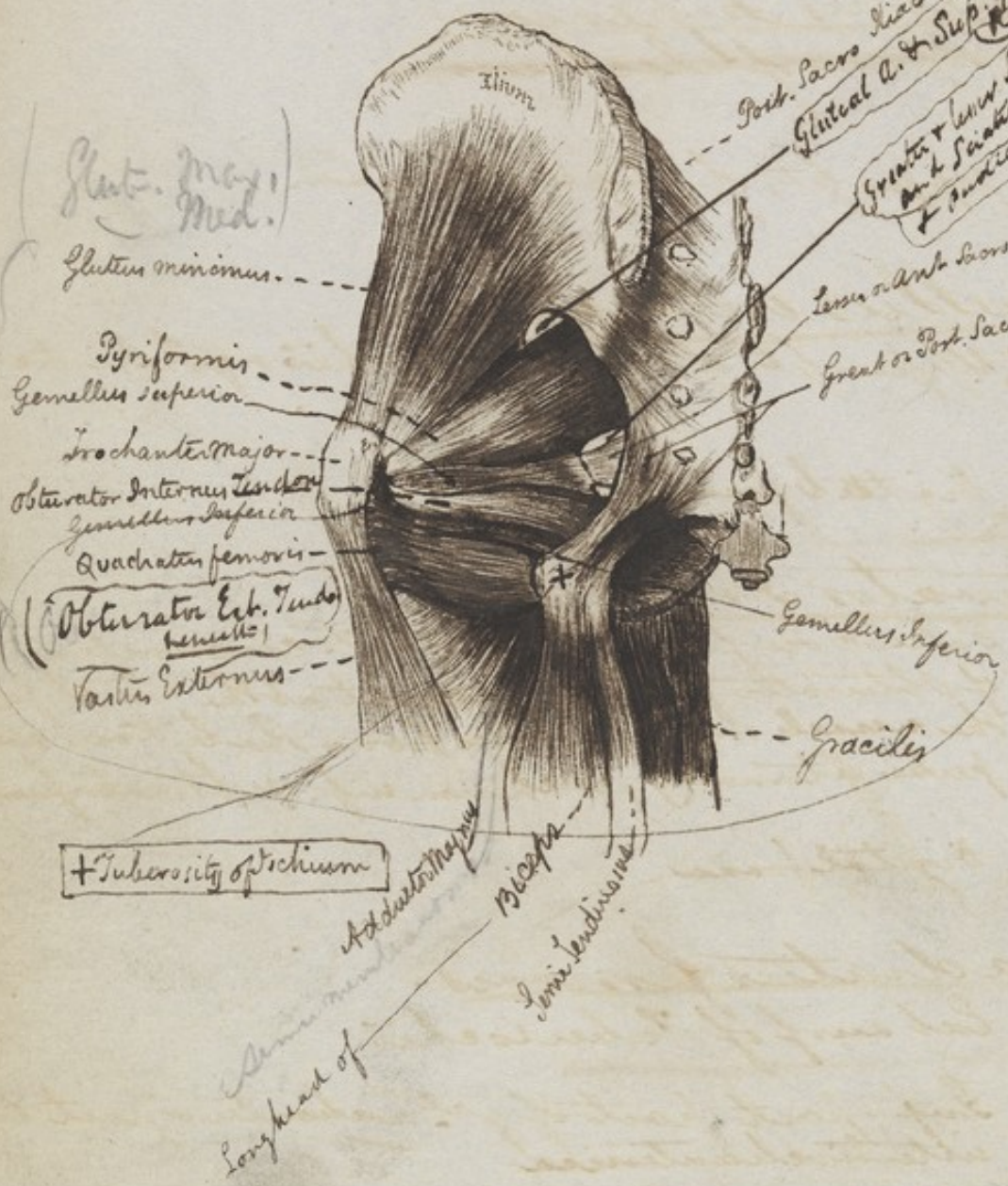

Muscles

Pyriformis

O Concave surf of 2, 3, 4 divisions of the Sacrum, upper & back part of the Ilium & ant surf of grt sciatic ligt.

I Post Root of grt. Trochanter.

Gemellus superior

O Spine of Ischium

I Upper pt. of digital fossa.

Gemellus inferior

O Upper pt of the Tuber ischii & grt. Sciatic ligt.

I Digital fossa.

Obturator Internus

O Pelvic surf of Obturator ligt. circumference of Obturator foramen except at the notch for the vessels where it rises from the ligtous arch pubis internally, ischium inf. & obturator fascia

I Digital fossa.

Quadratus Femoris.

O Ext surf of Tuber ischii

I Inf-post part of grt. Trochanter & post line intertrochanterica

Obturator Externus.

O Inf surf of Obturator ligt. & surrounding surfs of Pubis & Ischium

I Digital fossa.

D

Ser

Se

T

E

Muscles

Biceps (flexor cruris) femoris.

O Long Head Ext & post pt of Tuberosity
Short Head Linea aspera from below the ins of Gluteus Maximus to within 2 inches of the Ext Condyle

I Head of the Fibula.

Semitendinosus

O Tuberosity of the Ischium & 3/4 of Tendon of Long hd of Biceps

I Ant angle of the Tibia below its tubercle

Semimembranosus

O Upper outer pt of Tuberosity

I Ext condyle of femur forming Lip of Wins low
Post Heads of Tibia & Fibula & head of Tibia.

Tibialis Anticus

O Outer part of 2 sup 3rds of Tibia head of Fibula
Inner half of Interosseous lig & fascia of leg & intermuscular septa

I Inner side of Int Cuneiform Bone & Base of the first Metatarsal –

Extensor Pollicis Proprius.

O Inner edge of middle 3rd of Fibula, Interosseous lig & lower pt of the Tibia

I 2 fasciculi, one into Base of 1st other into Base of 2nd Phalanx of the great Toe.

Anterior Muscles of Leg.

Muscles

Extensor Digitorum Longus. Communis

O Ext part of the head of Tibia, head of fibula & sup 3/4 of its length, part of Inteross. Lig., fascia of the leg. & Intermuscular septa

I Last Phalanx of the 4 Ext Toes.

Peronæus tertius

O Ant surf of lower 1/2 of Fibula.

I Base of 5th Metatarsus & fibres of tendon of Extensor Communis

Extensor Digitorum Brevis.

O Upper & Ant pt of Os Calcis, astragalus & Annular lig.

I Int tendon into Base of 1st Phalanx of the great Toe, the 3 others join the outer edges of Extensor longus.

Peronæus longus

O head of fibula & upper half of its ext angle adjacent surf of Tibia, fascia, & septa.

I Outer side of Metatarsus of great Toe & sesamoid Bone, Int. Cuneiform & Base of 2nd Metatarsus.

Peronæus Brevis.

O Outer & Back part of lower half of Fibula & Intermuscular septa.

I Os Cuboides & Base of Metatarsus of little toe.

Posterior Superficial Muscles of Leg.

Muscles

Gastrocnemius

O Int head sup & post pt. of Int Condyle of femur & oblique ridge above it.
Ext head above Ext condyle

I By tendo achillis into lower & Post part of os Calcis.

Soleus

O Ext head from the back pt. of the head & sup third of fibula
Int head mid 1/3 of tibia

I Forms tendo achillis with Gast. Nemu.

Plantaris

O Back part of femur above Ext Condyle & post lig of the knee.

I Post part of os Calcis ant to Tendo Achillis

Popliteus

O Depression on Ext Condyle of femur

I Flat triangular surface occupying the sup part 1/3rd of the Tibia

Flexor longus Digitorum Pedis.

O Post flat surf of Tibia from below the Popliteus to within 3 in of the ankle, fascia, & septum

I Last Phalanx of 4 lesser toes.

Posterior Deep Muscles of Leg

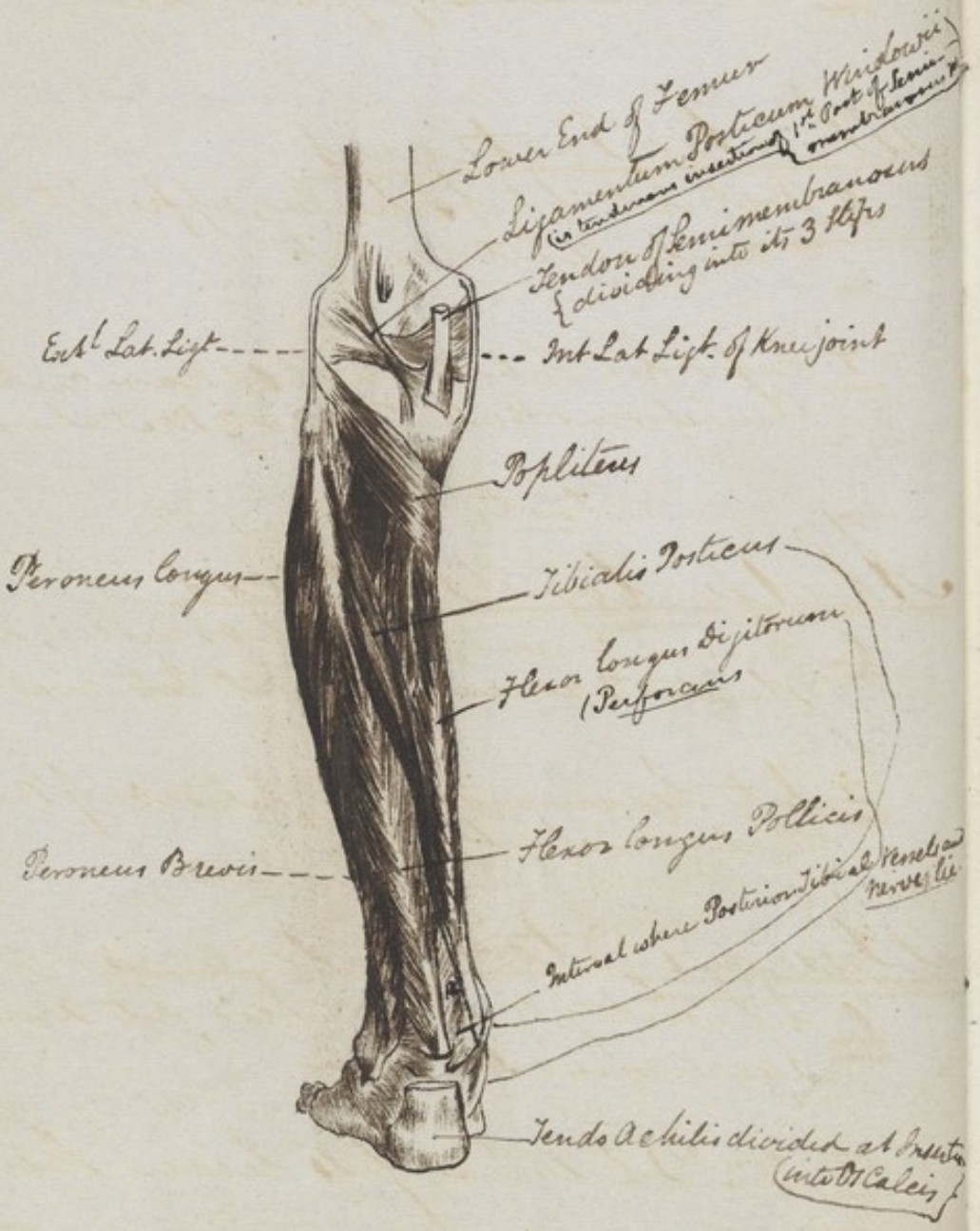

Muscles

Flexor Pollicis longus.

O 2 inf 3rds of Fibula

I last Phalanx of great Toe

Tibialis Posticus

O Post Int sft of Fibula, upper sft of Tibia & nearly all Int ass lig.

I Inf & Int Tuberosity of Os Navicular, Int Cuneiform & Cuboid & 2 & 3 Metatarsal Bones.

Foot

Abductor Pollicis

O Lower & Inner part of Os Calcis, Int Ann lig. Plantar Aponeurosis, & Int Intermus septum

I Int Sesamoid Bone, Int side of Base of 1st Phalanx of gt Toe.

Flexor digitorum Brevis

O Inf & Int pts of Os Calcis, Int Ann lig. Plantar Aponeurosis & Int Septa.

I 2nd Phalanx of 4 lesser Toes.

Abductor Minimi digiti

O Outer side of Os Calcis, lig from Os Calcis to 5 Metatarsal Plantar fascia, Ext septum, & Base of 5 Metatarsal

I Outer side of Base of 1st Phalanx of little Toe.

1st Layer of Muscles in Sole of Foot {exposed by removing Plantar Fascia}

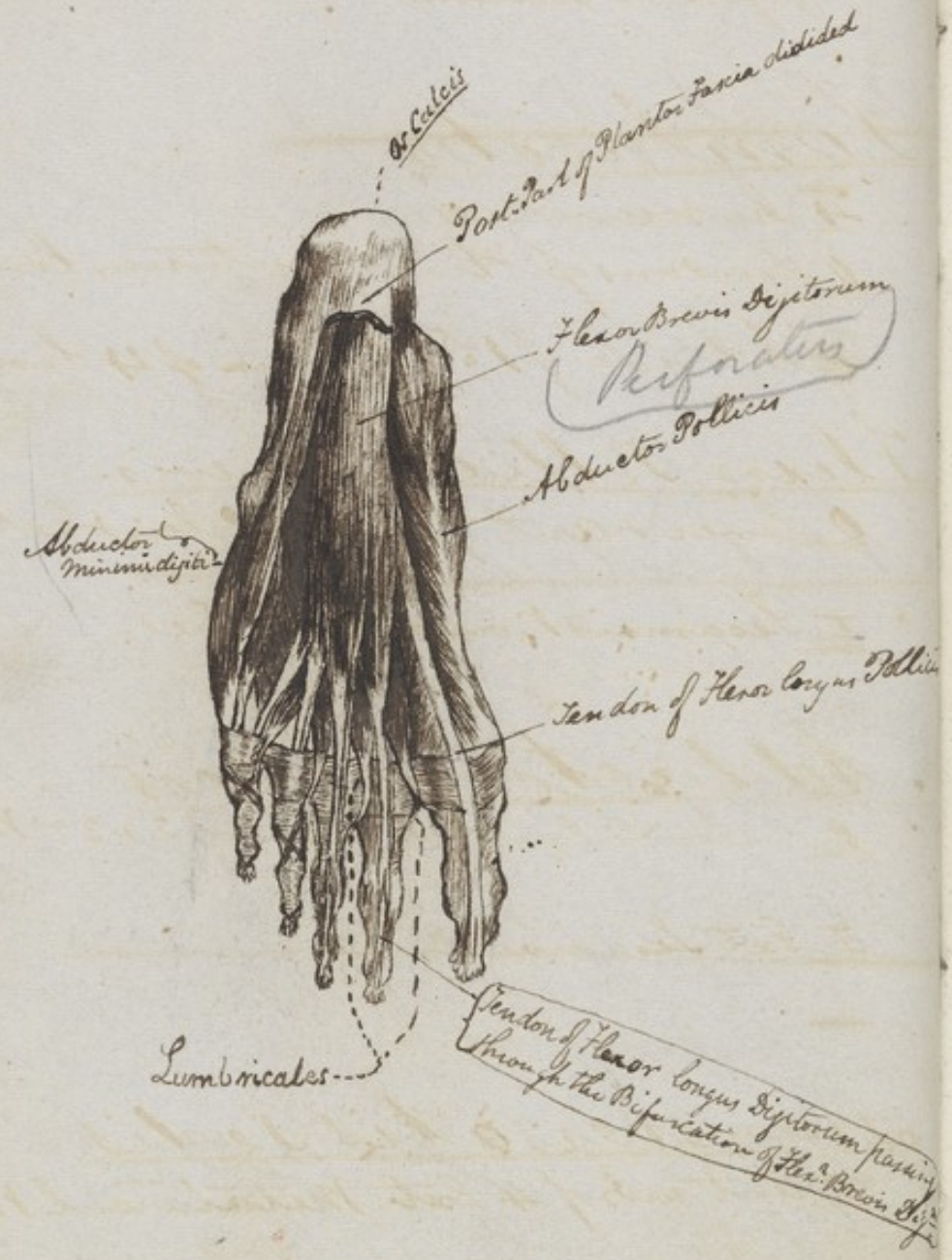

Muscles.

2nd layer

Musculus Accessorius.

O Inf & Int part of Os Calcis

I Outer part of Tendon of flexor longus Digitorum before it divides

Lumbricales

4 In number

O Tendons of Flexor Digitorum longus

I Int side of 1st Phalanx of 4 lesser Toes -

3rd layer

Flexor Pollicis Brevis.

O Lower & ant pt. of Os Calcis & Ext Cuneiformis

I Sesamoid Bones of Gt Toe.

Adductor Pollicis

O Calcis Cuboid Lig & Base of 2 & 3rd Metatarsus

I Ext Sesamoid Bone

Transversalis Pedis

O Ant ends of 4 Ext Metatarsal Bones

I Ext sesamoid Bone.

3rd & 4th Part of 2nd Layer of Muscles of Sole of Foot

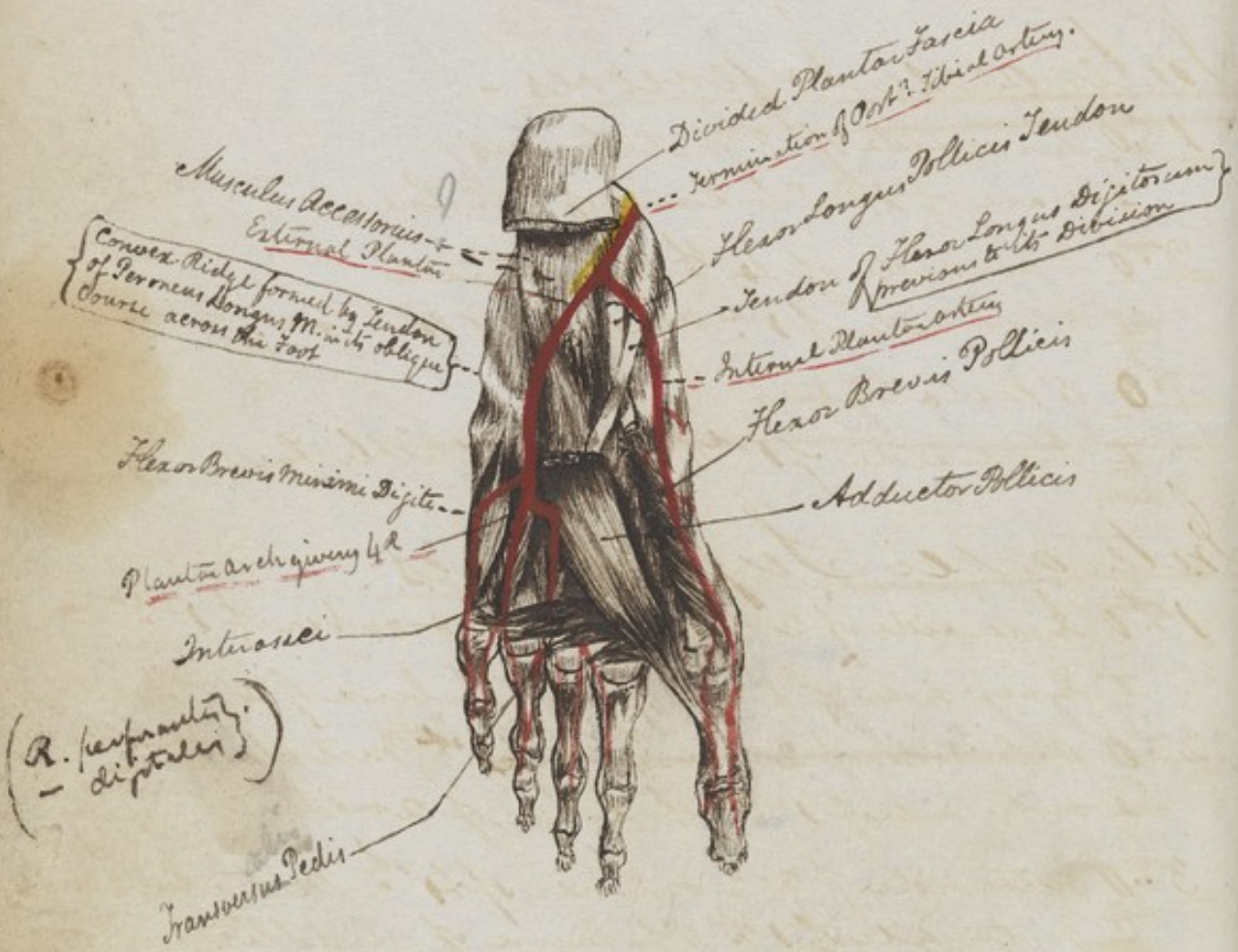



Muscles

Flexor Brevis Minimi Digiti

O Cuboid & 5 Metatarsal Bones & sheath of the tendon of Peroneus longus.

I Inner side of Base of 1st Phalanx of little Toe.

Interossei Inferiores -

1st O Inner side of 3 Metatarsus
I Base of 1st Phalanx of 3rd Toe.

2nd O Inner side of 4th Metatarsus
I Inner side of 1st Phalanx of 4th Toe.

3rd O 5 Metatarsus
I Inner side of 1st Phalanx of little Toe

Interossei Superiores.

1st O Inner side of 2nd Metatarsus & outer of 1st
I Inner side of Base of 1st Phalanx of 2nd Toe.

2nd O Outer side of 2nd & Inner of 3rd Metatarsus.
I outer side of 1st Phalanx of 2nd Toe

3rd O outer side of 3rd & Inner of 4th Metatarsus
I Outer side of 1st Phalanx of middle Toe

4th O Outer side of 4th & Inner of 3th Metatarsus
I Outer side of 1st Phalanx of 4th Toe.

End of the Muscles

Epicra
Region

Temporal
Region

Palpebral
Region

Orbital
Region

Nasal
Region

Oral
Region

Zygomatic
Region

Superficial
Cervical
Region

Regional Tables of the Muscles.

Cephalic Extremity

Cranium

Epicranial Region
- Epicranial aponeurosis
- Occipitalis m.
- Frontalis m.

Temporal Region
- Temporal asp.
- Attolens auris m.
- Attrahens ——
- Retrahens ——
- Temporalis m.

Face

Palpebral Region
- Orbicularis Palpebrarum
- Corrugator Supercilii
- Tensor Tarsi
- Tendon of Levator Palpebrae Sup.

Orbital Region
- Levator palpebrae superioris
- Levator oculi
- Depressor ——
- Abductor ——
- Adductor ——
- Obliquus sup.r oculi
- —— inf.r ——

Nasal Region
- Pyramidalis nasi
- Triangularis ——

Oral Region
- Orbicularis oris
- Levator labii sup.r alaeque nasi
- Depressor ——
- Levator labii inferioris
- Depressor ——
- Zygomaticus major
- —— minor
- Levator anguli oris
- Depressor ——
- Buccinator

Zygomatic Region
- Masseter
- Part of Temporalis
- Pterygoideus Externus
- —— Internus

Neck

Superficial Cervical Region
- Superficial Cervical fascia
- Deep ——
- Platysma myoides
- Sterno Mastoideus

Neck Cont.d

Sup.r Hyoid Region
- Digastricus
- Stylo Hyoid
- Mylo Hyoid
- Genio Hyoid

Infr Hyoid Region
- Omo Hyoid
- Sterno ——
- —— Thyroid
- Thyro Hyoid

Lingual Region
- Stylo Glossus
- Hyo ——
- Lingualis
- Genio Hyo Glossus

Pharyngeal Region
- Stylo Pharyngeus
- Constrictor Infr.
- —— Medius
- —— superior

Palatine Region
- Palato Glossus
- Palato Pharyngeus
- Levator Mollae
- —— Palati
- Tensor ——

Deep Cervical Region
- Rectus Capitis ant. Major
- —— Minor
- —— Lateralis
- Scalenus anticus
- —— Posticus
- Longus Colli

Trunk

Dorsal Region

1st Layer
- Lig.t Nuchae — Aponeuroses
- Cervical apon.
- Post. Layer of Dorsal Apon
- Trapezius
- Latissimus Dorsi

2nd Layer
- Levator anguli Scapulae
- Rhomboideus Minor
- —— Major

Regional Tables of Muscles

I Dorsal Region Cont'd

3 Layer
- Serratus Posticus Sup.
- —— Inf.
- Vertebral aponeurosis
- Pt. of deep cervical fascia

4 Layer
- Splenius Capitis
- —— Colli

5th Layer
- Sacro lumbalis
- Longissimus Dorsi
- Spinalis ——
- Erector ascendens
- Transversalis Colli
- Complexus Minor
- —— major

6th Layer
- Obliquus Capitis inferior
- —— superior
- Rectus capitis posticus major
- —— minor
- Transversospinalis
- Interspinales
- Intertransversales
- Levatores Costarum
- Mid layer of lumbar aponeurosis

II Intercostal Region
- Intercostalis externi
- —— interni
- —— aponeurosis

III Ant. Thoracic Region
Triangularis Sterni

IV Ant. Abdominal Region
- Superficial fascia
- Abdominal aponeurosis
- Fascia transversalis
- Obliquus Abdominis Ext.
- —— Int.
- Transversalis ——
- Cremaster (male)
- Pyramidalis Abdominis
- Rectus ——

V Post. Abdominal Region
- Ant layer of lumbar aponeurosis
- Iliac fascia
- Psoas parvus
- —— magnus
- Iliacus Internus
- Quadratus Lumborum

VI Sup. Abdominal Region
Diaphragm

VII Perineal Region Male
- Sup. Perineal aponeurosis
- Deep ——

Anal
- Sphincter Ani
- Levator ——
- Coccygeus

Genital
- Transversus Perinei
- Erector Penis
- Accelerator Urinae

VIII Perineal Region Female
- Sup. Perineal aponeurosis
- Deep ——

Anal
- Sphincter ani
- Levator ——
- Coccygeus

Genital
- Transversus Perinei
- Erector Clitoridis
- Constrictor Vaginae

Sup. Extremity

Shoulder

Ant Pectoral Region
- Pectoral fascia
- Costo coracoid ligament
- Pectoralis Major
- —— minor
- Subclavius

Lat. Rect. Axis
- Serratus Magnus

Ext. Scapular Region
- Deltoid aponeurosis
- Deltoid

Post. Scapular Region
- Supra spinal aponeurosis
- Infra ——
- Supra spinatus
- Infra ——
- Teres minor

Regional Tables of Muscles

Shoulder Cont.

Ant Scapular Region
- Subscapularis
- Latissimus dorsi
- Teres Major

Arm

Ant Brachial Region
- Brachial aponeurosis
- Biceps Flexor Cubiti
- Coraco Brachialis
- Brachialis Anticus

Post. B. Reg.
- Triceps Extensor Cubiti

Forearm

Ant Cubital Region
- Cubital aponeurosis
- Pronator radii teres } 1st Layer
- Flexor carpi radialis } 1st Layer
- Palmaris Longus } 1st Layer
- Flexor carpi ulnaris } 1st Layer
- Flexor digitorum Superfic. } 2 Layer
- ——— profundus } 2 Layer
- Flexor longus pollicis } 3 Layer
- Pronator quadratus } 4th Layer

Post Cubital Region
- Extensor digitorum communis
- ——— & proprius minimi digiti
- ——— carpi ulnaris
- Anconeus
- Extensor ossis metacarpi pollicis
- ——— Brevis pollicis
- ——— longus ———
- ——— proprius indicis

Radial Region
- Supinator Radii longus
- Extensor Carpi radialis longior
- ——— brevior
- Supinator radii Brevis (deep)

Hand

Dorsal Region
- Post annular ligt
- Dorsal Fascia
- Tendons

Hand Cont.

Palmar Region
- Ant Annular ligt.
- Palmar fascia
- Fibrous Sheath of Fingers
- Palmaris Longus
- ——— Brevis
- Flexor digit. superficialis
- ——— profundus
- Lumbricales
- Abductor pollicis
- Flexor ossis metac. pollicis
- ——— brevis pollicis
- ——— longus ———
- Adductor pollicis
- Flexor proprius min. digiti
- Adductor min. digiti
- Abductor ossis metac. m. dig.

Interosseous Reg.
- Dorsal Interosseous
- Palmar ———

Haunch

Gluteal Region
- Gluteus Maximus
- ~~Gluteus~~ medius
- ——— minimus
- Pyriformis
- Gemellus Superior
- Obturator Internus
- Gemellus Inferior
- Quadratus femoris
- Obturator Externus
- Fascia Lata

Thigh

Post Femoral Region
- Biceps Flexor Cruris
- Semitendinosus
- Semimembranosus

Regional Table of Muscles

Thigh Cont.

Ant. Femoral Region
- Tensor Vaginae Femoris
- Sartorius
- Rectus femoris
- Triceps Extensor Cruris
  - or { Vastus Externus / —— Internus / Crureus
- Quadriceps tendon
- Psoas Magnus Part of
- & Pso. of Iliacus Internus

Int. Femoral Region
- Pectineus
- Gracilis
- Triceps adductor femoris
  - { Adductor longus / —— Brevis / —— Magnus
- Obturator Externus
- Tendon of Psoas Magnus &
- Iliacus Internus
- Fascia Lata

Leg

Gastrocnemial Region
- Gastrocnemius
- Soleus
- Plantaris
- Tendo Achillis

Popliteal
- Popliteus

Post. Tib. Reg.
- Flexor Longus Digitorum
- —— Pollicis
- Tibialis Posticus

Ant. Tib. Reg.
- Tibialis anticus
- Extensor proprius Pollicis
- —— longus Digitorum
- Peroneus Tertius

Peroneal Reg.
- Peroneus Longus
- —— Brevis
- Tibial aponeurosis

Foot

Dorsal Region
- Tendons of Tibialis Anticus
- —— Extensor proprius pollicis
- —— —— longus Digit.
- —— Peroneus tertius
- —— —— Brevis,
- —— —— longus
- Extensor Brevis Digitorum
- Anti Annular lig. & Dorsal fascia

Plantar Region

1 Layer
- Adductor Pollicis
- Abductor Minimi Digiti
- Flexor Brevis Digitorum

2
- Tendon of Flexor longus Digitorum
- Musculus Accessorius
- Lumbricales

3
- Tendon of Flexor longus Pollicis
- Flexor Brevis Pollicis
- Abductor Obliquus pollicis
- —— transversus
- Flexor Brevis Minimi Digiti
- Tendon of Peroneus longus

- Post. annular lig.
- Plantar fascia
- Fibrous sheaths of Toes

Interosseii

Dorsal
1. Adductor Secundi Digiti
2. Abductor ——
3. —— Tertii ——
4. —— Quarti ——

Plantar
1. Adductor Tertii digiti
2. —— Quarti digiti
3. —— minimi ——

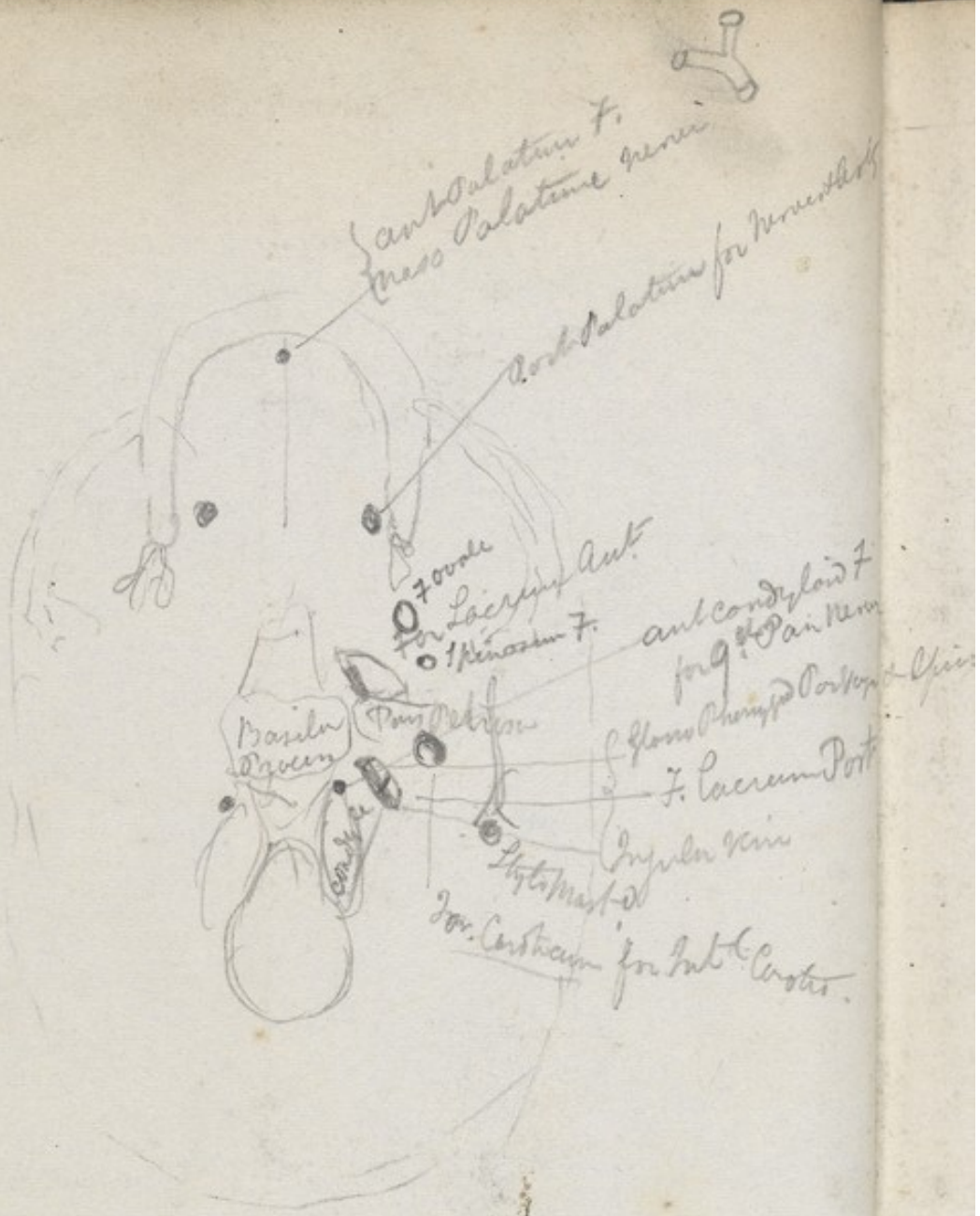
Ant. Palatine 7.
Meso Palatine nerve
Post. Palatine for Meatus
7 ovale
For Lacrym. Ant.
1 Renosum 7.
ant condyloid 7
for g. & Pain Nerve
Basilar Process
Pons Petrosus
Glosso Pharyngeal
7. Lacrum Post
Condyle
Jugular vein
Styloid Process
For. Carotid for Int. Carotid.



Articulations

Spine (Bodies Amphiarthrosis) (Articular Pro Diarthrosis Ex Arthrodia)

Ant Common ligament 3 sets of { 1 to 4 or 5 below

Atla

Cranium Occipito atlo. (Arthrodia) 2 portions { superfi. { Ext. Thick Deep. Broad & Mem.

Ant Occipito atloidean lig

Accessory lig.

Post Occipito Atloidean lig { divides into Ant. & Post. lamellae. Ant. attached to thecal tubercle. Post. overlapped by edge of Ring of atlas. Extremely fatty. aperture for nerve & A.V.

2 tympanic membranes.