

**Typical physical skin complaints caused by the HIV virus that leads to AIDS including rashes, purple blistering, emaciation and open sores; an AIDS prevention advertisement by The Ministry of Education Training, Vietnam. Colour lithograph, ca. 1995.**

### **Publication/Creation**

[Vietnam] : Bo Giao Duc Va Dao Tao [Ministry of Education Training], [1995?]

### **Persistent URL**

<https://wellcomecollection.org/works/zjqrq4sq>

### **License and attribution**

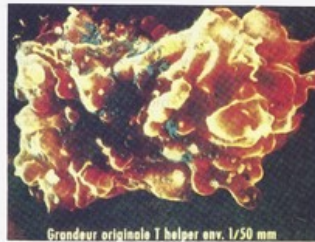
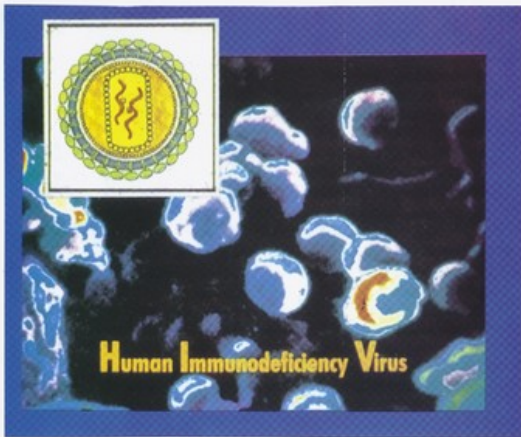
You have permission to make copies of this work under a Creative Commons, Attribution, Non-commercial license.

Non-commercial use includes private study, academic research, teaching, and other activities that are not primarily intended for, or directed towards, commercial advantage or private monetary compensation. See the Legal Code for further information.

Image source should be attributed as specified in the full catalogue record. If no source is given the image should be attributed to Wellcome Collection.

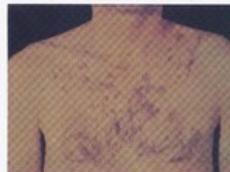
**wellcome  
collection**

Wellcome Collection  
183 Euston Road  
London NW1 2BE UK  
T +44 (0)20 7611 8722  
E [library@wellcomecollection.org](mailto:library@wellcomecollection.org)  
<https://wellcomecollection.org>



**TẾ BÀO LIM - PHÔ - T**  
 Các tế bào LIM - PHÔ - T có vai trò rất quan trọng trong hệ thống miễn dịch của cơ thể.

# TÌM HIỂU VỀ AIDS



Những nốt phát ban đỏ do bị SIDA

