

Female genital organs before, during and after pregnancy. Colour lithograph by O. Gríuñ, 1925.

Contributors

Gríuñ, O., active 1919.
Soviet Union. Otdel okhrany materinstva i mladenchestva.

Publication/Creation

[Leningrad?] : Izdanie Otdela Okhrany Materinstva i Mladenchestva NKZ, [1925?] (Leningrad (Pr.s Aleksandr. 10) : Lit. Goskart Fabr. Narkomfina)

Persistent URL

<https://wellcomecollection.org/works/w8usjsdq>

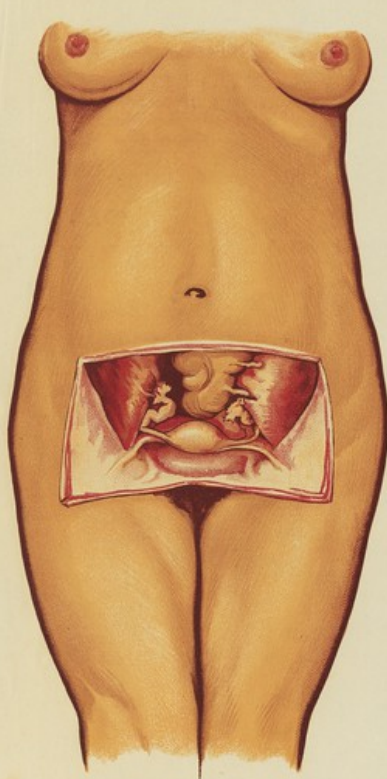
License and attribution

Conditions of use: it is possible this item is protected by copyright and/or related rights. You are free to use this item in any way that is permitted by the copyright and related rights legislation that applies to your use. For other uses you need to obtain permission from the rights-holder(s).

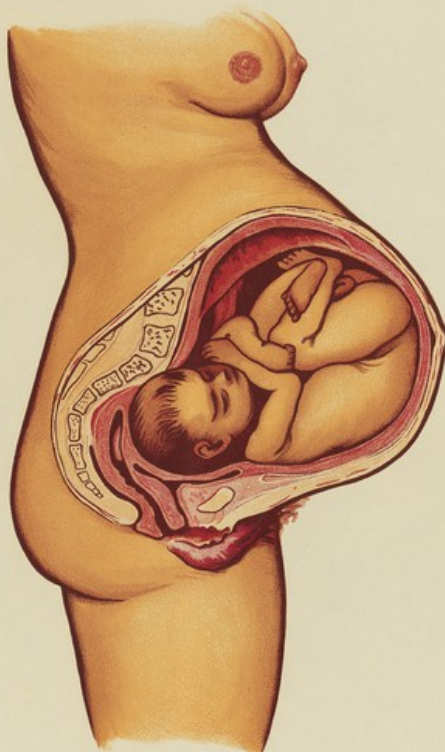**wellcome
collection**

Wellcome Collection
183 Euston Road
London NW1 2BE UK
T +44 (0)20 7611 8722
E library@wellcomecollection.org
<https://wellcomecollection.org>

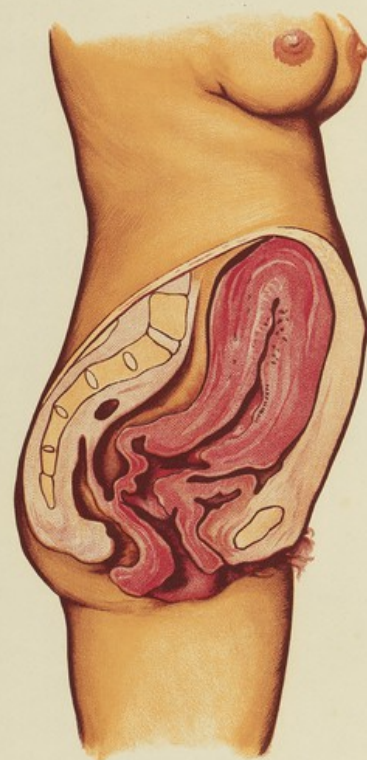
ЧТО ДОЛЖНА ЗНАТЬ КАЖДАЯ ЖЕНЩИНА.



**Женские половые органы
в обычное время.**



Матка на 9-ом месяце беременности.



**Момент/Матка после родов-большая
открытая рана. В это время легко
занести заразу.-Соблюдайте чистоту,
не работайте 7 дней.**